

# REVIEW<sup>®</sup> of OPTOMETRY

March 15, 2024 • reviewofoptometry.com

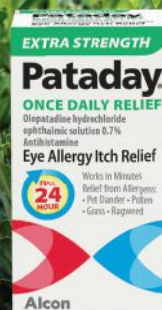Leadership in clinical care

## OPTOMETRIC SCOPE: Breaking Down Barriers

*Here's how ODs are challenging old boundaries  
and what they can do once freed from them*



INTRODUCE YOUR PATIENTS TO  
**THE HEAVY HITTER**  
AND KNOCK OUT ITCHY, ALLERGY EYES



There's no need for your patients to go 12 rounds with itchy, allergy eyes. Extra Strength Pataday **works faster and outperforms** Claritin and Flonase for eye allergy itch relief, even at 24 hours.\* Get your patients back in the ring with one drop, once a day of Extra Strength Pataday.

Reference: 1. Alcon data on file, 2022.

\*Based on conjunctival allergen challenge vs. Claritin Tablets and Flonase Allergy Relief at 15 minutes and 24 hours post-treatment.

© 2024 Alcon Inc. US-PTD-2300148





# REVIEW<sup>®</sup> *of* OPTOMETRY

March 15, 2024 • reviewofoptometry.com

Leadership in clinical care

## OPTOMETRIC SCOPE: Breaking Down Barriers

*Here's how ODs are challenging old boundaries  
—and what they can do once freed from them.*

**PAGE 32**

### 17TH ANNUAL PHARMACEUTICALS REPORT

*Have You Kept Up With the Recent 'New Drug' Deluge?*

**PAGE 44**

*Safe and Savvy Prescribing of Oral Pharmaceuticals*

**PAGE 52**

### ALSO THIS MONTH

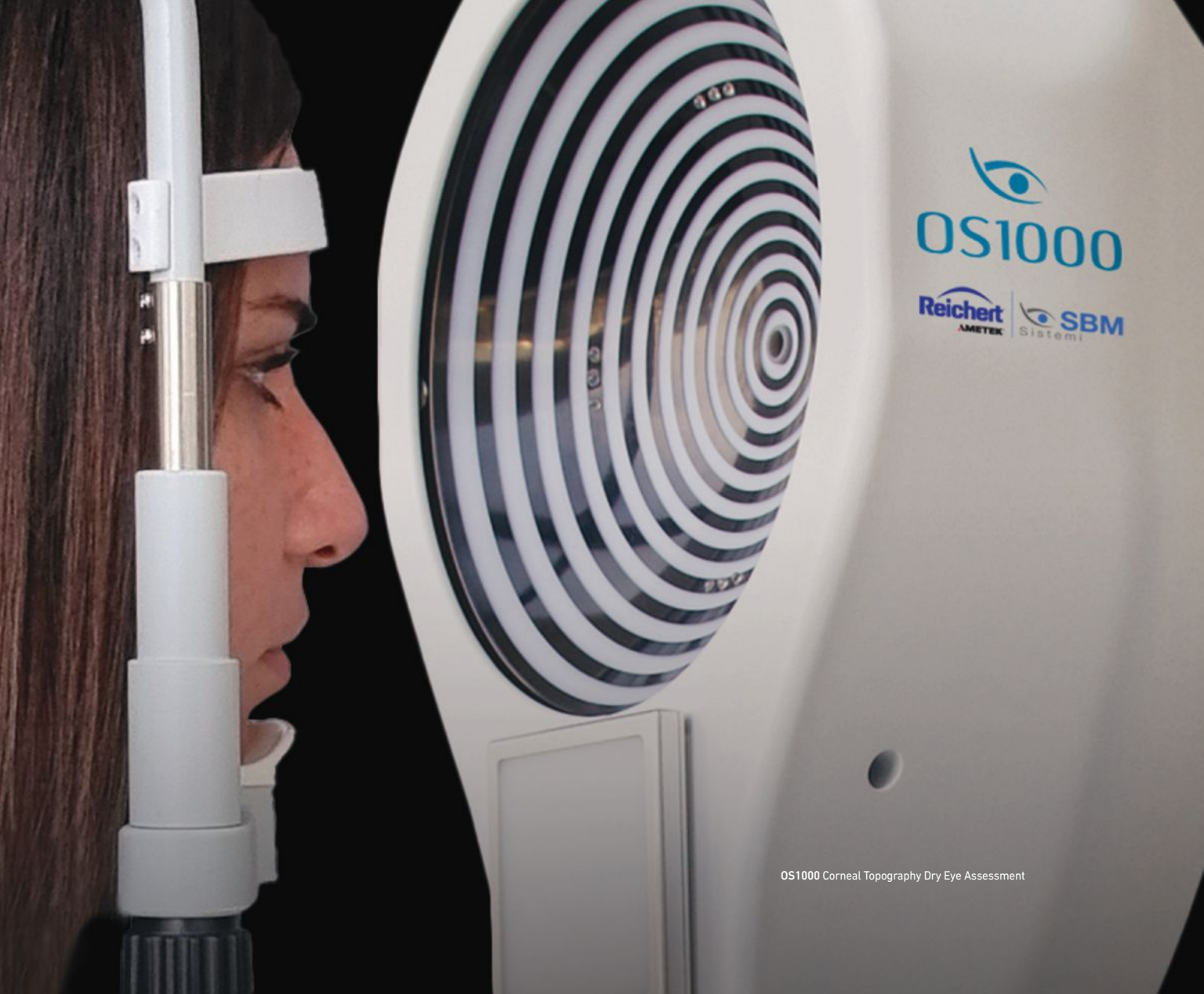*Ease Yourself Into Myopia Management*

**PAGE 60**

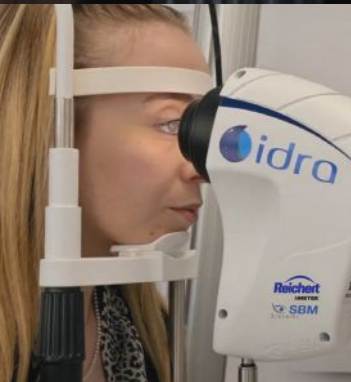*OCT Beyond the Basics: Unlock the Power of This Essential Tool*

—EARN 2 CE CREDITS

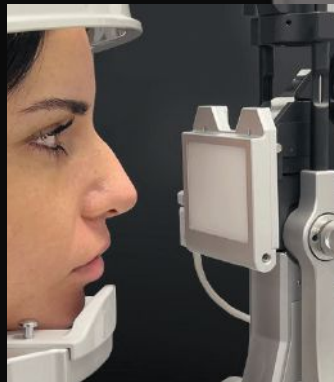**PAGE 66**



OS1000 Corneal Topography Dry Eye Assessment



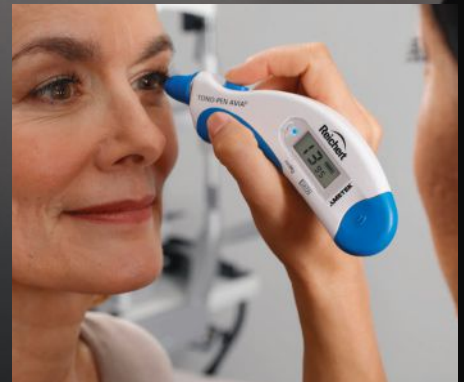Idra Comprehensive Dry Eye Assessment



DEM100-DSLC200 Anterior Segment Imaging with Dry Eye Assessment



Activa Med Non-Invasive Therapy



Tono-Pen AVIA® Tonometer



# EFFORTLESS DRY EYE EVALUATION, RELIABLE REFRACTION, AND TRUSTED TONOMETRY

We share in your passion to personalize and improve eye care.  
Reichert's comprehensive family of devices seamlessly integrates into  
your practice, empowering you to deliver exceptional patient outcomes.

LEARN MORE



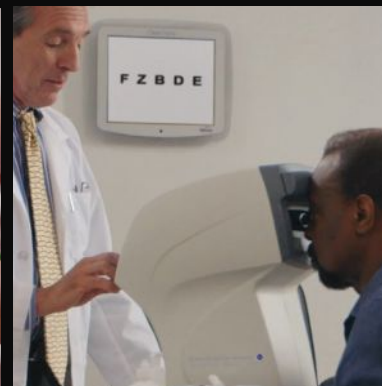**DEMO TO WIN \$500 DAILY AT VISION EXPO EAST!**  
**LEARN MORE & SEE PROMOS AT REICHERT.COM**



Tono-Vera® Tonometer\* - Coming Soon








Phoroptor® - Digital or Traditional featuring Phoroptor® VRx with ClearChart®



Ocular Response Analyzer® G3  
with Corneal Hysteresis + IOPcc

**Reichert® / AMETEK®**  
*passionate about eye care*

© 2024 AMETEK, Inc. & Reichert, Inc. (03-2024) Phoroptor, ClearChart, Ocular Response Analyzer, Tono-Pen AVIA, and Tono-Vera are all registered trademarks of Reichert, Inc.

\*Pending FDA Clearance -     



## Central Retinal Artery Occlusion Rates Highest During Winter

*Over 15 years, incidences peaked in the colder months and were lowest in the summer.*

The medical community has previously identified an established connection between cold temperatures and an elevated risk of stroke. Central retinal artery occlusion (CRAO)—“a stroke of the eye” as it’s sometimes called—shares etiologic and risk factors with other ischemic vascular disorders. Researchers recently set out to determine if CRAO incidence would align with patterns observed in ischemic vascular diseases and ischemic cerebral strokes. They found it does indeed.

Their 15-year retrospective study confirmed a correlation not only with air temperature but air pollution as well. It included a total of 432 patients who were newly diagnosed with CRAO in the region of southwestern Germany. Data demonstrated significant variations in incidence rates across months and seasons, with the highest proportion occurring in winter (30.4% of cases) and spring (26.4%), contrasted with the lower rates of 19.5% in summer and 23.7% in fall. Incidence during winter was 1.55 times higher than summer, and February had the highest cumulative adjusted incidence—11.7% of all cases occurred then—more than double that of June (5.4%), which was the month with the lowest incidence of CRAO.

Air pollutants also showed increased concentrations in the winter months. With the exception of O<sub>3</sub> (ground level ozone), which peaks in the summer, pollutants NO<sub>2</sub> (nitrogen dioxide), PM<sub>2.5</sub> and PM<sub>10</sub> (airborne particulate matter) were elevated in relation to lower temperatures. These pollutants

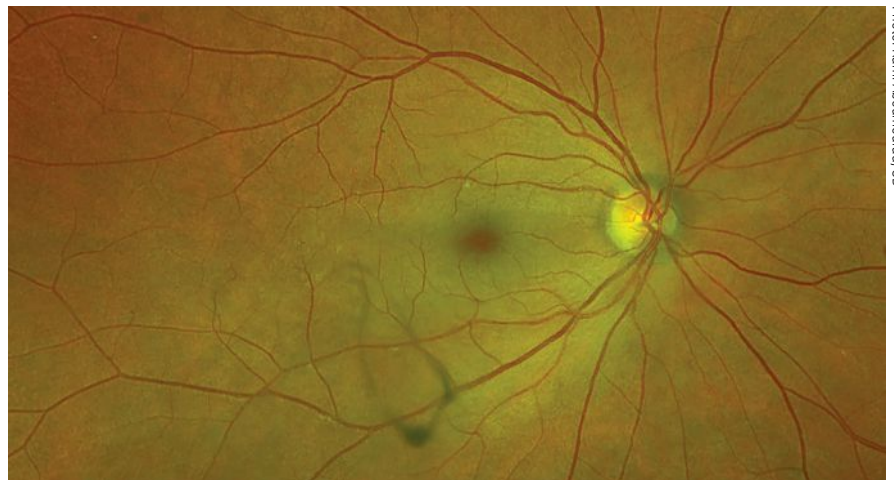


Photo: Rami Aboumoud, OD

**The incidence of central retinal artery occlusion was significantly higher during months with lower temperatures and increased air pollution levels compared to warmer months.**

infiltrate the respiratory system, suggesting they exacerbate vascular risk factors that then correlate with the rise in CRAO incidence.

“This study aligns with a growing body of evidence suggesting the potential influence of seasonal variations, climatic factors and air pollution on vascular events,” stated the authors in their paper on the work for *Frontiers in Neurology*. “Notably, it marks the first instance of demonstrating seasonal fluctuations in CRAO incidence. However, further exploration is necessary to fully grasp the mechanisms connecting these seasonal shifts with CRAO occurrences. Understanding these mechanisms could pave the way for targeted public health interventions, particularly during high-incidence seasons, mitigating CRAO risks related to air pollution.”

The authors identified the study’s limitations, including the retrospec-

tive design focusing on one singular institution’s records and the fact that the location isn’t a city with extremely high levels of air pollution, and suggested further studies should be carried out in cities with higher concentrations of air pollutants or in regions with less pollution.

“This comprehensive 15-year analysis reveals evidence of seasonal and monthly variations in CRAO incidence, with a pronounced peak during winter,” the authors concluded. “These findings prompt further research into the underlying mechanisms and potential modifiable risk factors associated with these temporal patterns. Such investigations could ultimately lead to more effective and targeted preventive strategies to reduce the risk of CRAO.”

Gassel CJ, Andris W, Poli S, Bartz-Schmidt KU, Dimopoulos S, Wenzel DA. Incidence of central retinal artery occlusion peaks in winter season. *Front Neurol* 2024;22:15:1342491.



# Wisconsin ODs Embrace Broad Scope, Brace for MD Challenge

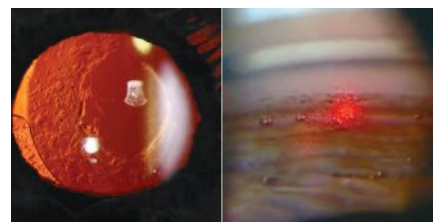
*The current law does not require explicit enumeration of every privilege and procedure, giving optometrists more autonomy to evolve their skillsets and offerings as the profession grows.*

An increasing number of optometrists in Wisconsin are providing advanced procedures, including lasers and removal of lumps and bumps, under a scope law that hasn't changed since its adoption in 1990. How? When the law was drafted, the Wisconsin Optometric Association had ensured it was phrased in such a way that would permit the state's ODs to implement new procedures, treatments and therapeutics as they become available in the profession rather than having to repeatedly go back to the legislature. It's fair to say, then, that optometric laser privileges are now being put to use in 11 US states rather than 10, as is commonly believed.

Contrary to the 10 other laser states—which had to pass legislation specifically clarifying the inclusion of surgical procedures in their practice scopes—Wisconsin's law doesn't require optometrists to acquire a specific num-

ber of training hours or postgraduate credentials to perform various laser and advanced procedures, including YAG capsulotomy, SLT and lesion removal. Like MD/OME licenses, Wisconsin law puts the onus on the doctor to ensure their own competency and training before performing advanced procedures.

Peter Theo, executive VP of the Wisconsin Optometric Association, comments, "Over the last few years, a growing number of WOA members have been performing various advanced procedures and, to the best of my knowledge, no adverse outcomes have been reported." He adds that during this time, in response to the growing demand for these procedures, several training courses have been held for Wisconsin ODs by optometric educators in other laser states; one, for example, is an intensive four-day course by Nate Lighthizer, OD, and his colleagues from Oklahoma, where optometrists have



Photos: Nathan Lighthizer, OD

**Including Wisconsin, there are currently 11 states in the US where ODs can perform laser procedures like capsulotomy and SLT.**

been safely performing laser procedures since 1998.

Now that organized medicine and ophthalmology have caught wind that a growing number of ODs in Wisconsin are pursuing advanced procedure training, they've begun putting wheels in motion to challenge the state's decades-old scope law, even going so far as threatening lawsuits to have it overturned. However, Mr. Theo is confident that "our statute will prevail in court should it be challenged." ◀

## Centrally Located Drusen Associated with AMD Risk

Few proposed classifications for early AMD put much emphasis on drusen location. Rather, they often define the early stage of the condition as the presence of drusen and pigmentary abnormalities in the ETDRS grid (3000µm from the foveal center). Researchers from Bordeaux, France explored the hypothesis that drusen location could be strongly linked with known AMD risk factors and possibly provide a better stratification of early AMD. Their analysis of an elderly French population revealed that central drusen location was strongly associated with known AMD risk factors.

The study, published in *Acta Ophthalmologica*, assessed the associations of drusen location (central or pericentral) with known AMD risks (various systemic, ocular and genetic factors) and with the incidence of late AMD to identify more

specific early abnormalities associated with an increased risk of late AMD. On retinal photographs, the researchers defined central drusen as at least one soft drusen (>63µm) within 500µm from fovea and pericentral drusen as at least one 500µm to 3000µm from fovea, in the absence of any central drusen. Late AMD (atrophic and/or neovascular) was diagnosed using multimodal imaging. In total, 481 eyes were included in the analysis: 160 central and 321 pericentral. The researchers believed they obtained a good follow-up rate (81%), with a six-year follow-up and three time point evaluations.

In multivariate logistic regression, central drusen were associated with smoking (odds ratio [OR]: 2.95 for smoking more than 20 pack-years), high-density lipoprotein cholesterol (OR: 1.57 for one standard deviation increase), pulse

pressure (OR: 0.77 for one SD increase), Age-Related Maculopathy Susceptibility 2 (ARMS2) genetic risk score (OR: 1.42) and complement genetic risk score (OR: 1.55). The central location of drusen (at baseline or during the follow-up) was associated with a 4.41-fold increased risk for an incident late AMD.

"Characterization of the central location of drusen could modify the classification of early and intermediate AMD," the team concluded in their paper. "A more accurate classification of the early stages of the disease will help identify AMD risk factors and predict evolution to the late stage of disease, providing better identification of high-risk patients." ◀

Sénéclauze A, Le Goff M, Cougnard-Grégoire A, et al. Associations of drusen location with risk factors and incidence of late age-related macular degeneration in the Alienor study. *Acta Ophthalmol.* January 26, 2024. [Epub ahead of print].

# Suboptimal Sleep Patterns Increase POAG Risk

*These included ease of getting up in the morning and poor duration of rest.*

**T**he early bird gets the... glaucoma? Maybe so, says a new study. Previous research has investigated the connections between glaucoma and sleep behavior, but any causal relationship has remained largely unclear. A novel study aimed to elucidate just that by analyzing genetically predicted sleep traits with primary open-angle glaucoma (POAG) using a two-sample bidirectional Mendelian randomization method. In other words, it tested the association of POAG and sleep trouble for cause-effect dynamics in either direction.

The bidirectional analysis included data from publicly available genome-wide association studies of European descent. The results indicated a positive correlation between genetically predicted ease of getting up in the morning and sleep duration with POAG. The researchers found that the adverse effects of these two traits on glaucoma persisted after adjusting for factors of BMI, smoking, drinking and education. However, the relationships between genetic liability of POAG and different sleep behaviors were not significant in the opposite direction.

Glaucoma may not change sleep-related behaviors, but the study authors noted in their paper for *Nature and Science of Sleep* that “although there was no potential causal inference between these genetically predicted sleep traits and POAG, we still need to pay atten-

tion to sleep-related health to mitigate the incidence of POAG.”

The authors point to multiple studies indicating similar relationships or connections. Poor sleep quality and disruption are commonly observed in POAG and glaucoma patients; one study indicated glaucoma patients scored worse compared with controls for sleep latency, sleep duration and subjective sleep quality.

The authors offer an explanation for this observed relationship, caused by underlying mechanisms between sleep-related behaviors and POAG that biologically makes sense. One possibility is the pathogenetic mechanism involving systemic inflammation-related processes, such as C-reactive protein, neutrophil-to-lymphocyte ratio, systemic immune inflammation index and cytokine TNF- $\alpha$ , which are relevant to vision in POAG. Recurrent hypoxia with increased vascular resistance and oxidative stress damage to the optic nerve are both vascular factors that have shown implication in POAG pathogenesis.

Yet another possibility has to do with chronic insomnia. Its related physiological responses may stimulate neurotransmitter secretion as well as activating the autonomic nervous system, thus affecting intraocular pressure regulation and optic nerve perfusion. Comorbidities may further lead to this observation, as mood disorders like anxiety and

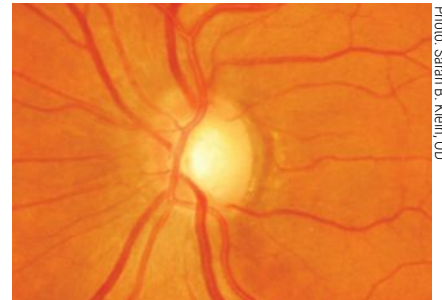

Photo: Sarah B. Klein, OD

**Poor sleep duration confers a 1.66-fold higher risk of POAG, this study found.**

depression often occur with insomnia and may result in IOP elevation through dysregulated levels of cortisol.

The authors conclude that their analysis indeed demonstrates ease of getting up in the morning and poor sleep duration are indicative risks of POAG. “To better understand and manage both phenotypes in our clinical implications, potential ophthalmologic screening and intervention among individuals with chronic sleep problems should be made to help prevent POAG,” they advise. Doctors can consider incorporating questions about sleep patterns and behaviors into routine patient assessments, especially for individuals at higher risk for POAG. For patients already diagnosed with POAG, consider discussing sleep patterns and behaviors as part of the overall management plan. ◀

Zhang J, Chen X, Zhu Y, et al. Investigating the causal relationship between sleep behaviors and primary open-angle glaucoma: a bidirectional two-sample Mendelian randomization study. *Nat Sci Sleep*. 2024;16:143-53.

## IN BRIEF

### **Nasal and Paracentral Regions of Optic Disc are Most Vulnerable to Visual Field Progression.**

Authors of a new study say they've identified that the nasal and paracentral regions are likely more prone to a reduction in sensitivity in patients with ocular hypertension (OHTN). These results included both event- and trend-based analyses, and was observed in both the early- and delayed-treatment groups.

The study included over two million test points from 58,115 visual fields of 1,188 patients who met their criteria and they aimed to determine which 24-2 VF grid locations changed most rapidly and frequently in eyes with OHTN. Their findings were in agreement with previous reports on the most common locations of VF defects in early glaucoma, and while the pattern of progression was similar in both the early- and delayed-treatment groups, **the rate of change and frequency of events were higher in the delayed-medication**

**group.** This further supports the use of IOP-lowering therapy.

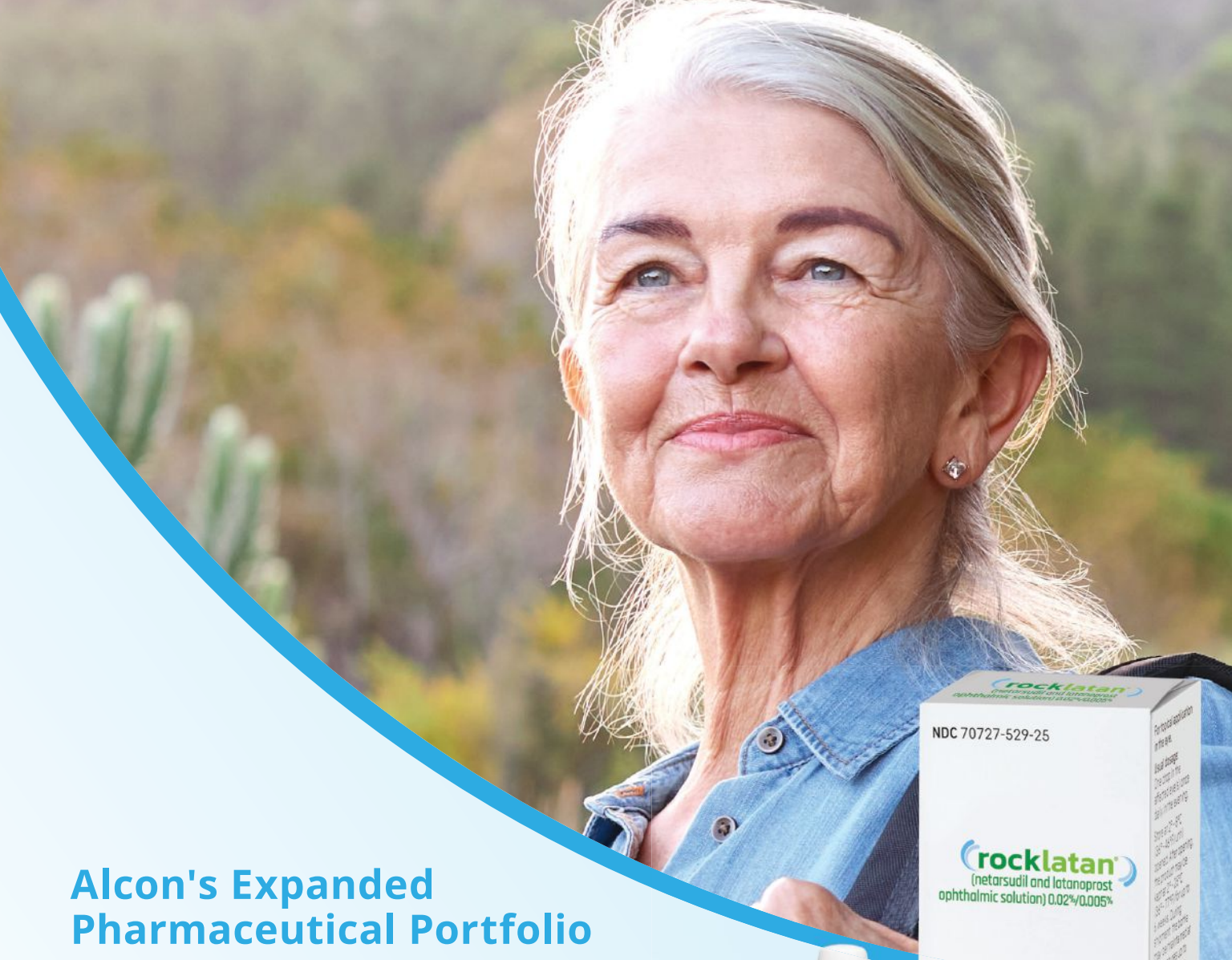“Supported by previous observations regarding the areas of vulnerability, our results suggest that **providing hypotensive treatment to slow down the rate of glaucoma progression might be more effective in the vulnerability zones, at least at the early stages of the disease,**” the authors wrote. But they cautioned, “While our findings indicate IOP lowering mainly reduces the rate of progression in the vulnerability zones, the exact relationship between baseline IOP,

degree of IOP lowering and patterns of progression need to be clarified and warrant further investigation.”

The team concluded that, based on these results, “it seems that **it might be prudent to carefully monitor [the nasal and paracentral regions] to facilitate early detection of progression and that timely treatment may help reduce the rate of progression in these locations.**”

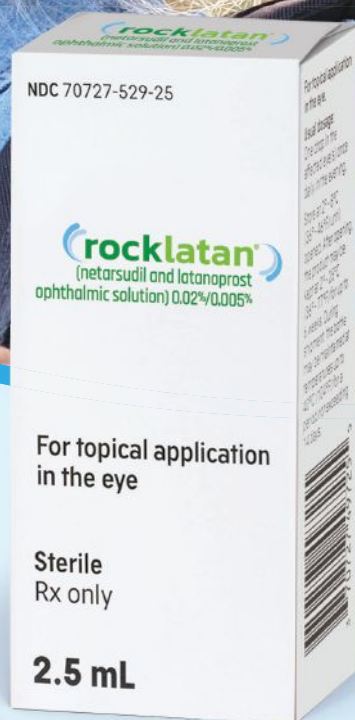Leshno A, Bommakanti N, De Moraes CG, Gordon MO, Kass MA, Cioffi GA, Liebmann JM. Visual field progression patterns in the ocular hypertension treatment study correspond to vulnerability regions of the disc. *Eye (Lond)*. February 14, 2024. [Epub ahead of print.]





Alcon's Expanded  
Pharmaceutical Portfolio

# Have You Tried **ROCKLATAN®?** (netarsudil and latanoprost ophthalmic solution) 0.02%/0.005%



CONTACT YOUR LOCAL ALCON SALES REPRESENTATIVE TO FIND OUT MORE.

**Alcon**

© 2023 Alcon Inc. US-ROC-2300027

**rocklatan**  
(netarsudil and latanoprost  
ophthalmic solution) 0.02%/0.005%

# Cataract Surgery May Cognitively Benefit Older Patients

*A recent literature review showed a 25% lower risk of impaired mental faculties in those who underwent the procedure vs. individuals with uncorrected lens opacity.*

Globally, cataracts are the leading cause of preventable blindness, especially among older individuals. Previous research has discovered that cataracts, or visual impairments in general, are associated with cognitive decline in the elderly. Since cataracts can easily be managed with surgical treatment, researchers in Singapore conducted a study to find out if there were any potential cognitive benefits to cataract surgery.

In their systematic review and meta-analysis, researchers included 24 studies comprising 558,276 participants.<sup>1</sup> They included studies with populations of patients diagnosed with cataracts who had undergone some form of surgery as well as some comparing patients with uncorrected cataracts to control subjects without lens opacification. Additionally, they included single-arm studies without a control group if the study featured results comparing cognitive outcomes before and after cataract surgery. The mean age for the participants in this study was 66.4 years old.

The researchers pooled their data and results into various groups and subgroups. From a group of 246,640 participants, they discovered there was a 25% lower risk of long-term cognitive impairment and dementia in patients who had undergone cataract surgery compared to those with uncorrected cataracts. Interestingly, in a pool of

308,795 participants, healthy controls without cataracts had a risk of long-term cognitive decline similar to the patients with surgical treatment. In a much smaller pool of 662 patients, researchers noted a statistically significant 4% improvement in short-term cognitive test scores, which assessed general cognitive function among participants with normal cognition.

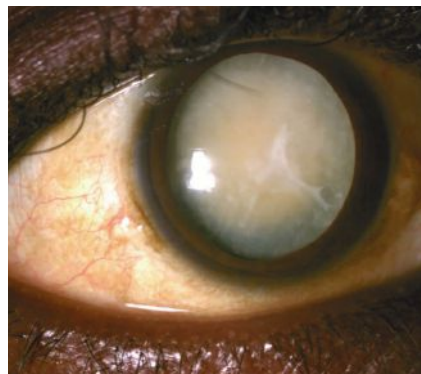

Photo: Joseph Sowka, OD

**Researchers referenced in their paper that prior studies estimated that visual impairment is present in about 32.5% of dementia patients.**

“Two further observations may be inferred from our findings,” mentioned the researchers in their study, published recently in *Ophthalmology*. “Firstly, participants who underwent cataract surgery had comparable hazards for cognitive impairment and dementia as healthy controls without cataracts, possibly suggesting that cataract surgery

may negate the excess risk of cognitive impairment and dementia imposed by cataracts. Secondly, for patients with pre-existing cognitive impairment, cataract surgery was not associated with subsequent improvement in short-term cognitive test scores.”

There were two studies the researchers reviewed that disagreed with their meta-analysis findings. One concluded that cataract surgery did not strongly correlate with better cognitive test scores in health adults.<sup>2</sup> Another observed patients in a nursing home who had undergone cataract surgery, but these patients showed no improvement in cognitive function.<sup>3</sup>

While there are limitations to their study, the researchers bolstered the possibility of vision impairment from cataracts being a modifiable risk factor for cognitive decline. “Physicians should be aware of the cognitive sequelae of cataract-associated vision impairment, and the short- and long-term cognitive benefits of cataract surgery,” they concluded. ◀

1. Yeo BS, Ong RY, Ganasekar P, et al. Cataract surgery and cognitive benefits in the older person – a systematic review and meta-analysis. *Ophthalmology*. February 7, 2024. [Epub ahead of print].

2. Anstey KJ, Lord SR, Hennessy M, et al. The effect of cataract surgery on neuropsychological test performance: A randomized controlled trial. *J Int Neuropsychol Soc*. 2006;12(5):632-9.

3. Marx MS, Werner P, Billig N, et al. Outcomes of cataract surgery in nursing home residents. *Psychosomatics*. 1995;36(3):254-61.

## IN BRIEF

**Thin Double Layer Sign in the Fovea on OCT Predicts GA.** A recent study assessed the relationship of OCT findings and progression to foveal atrophy in a cohort of eyes with extrafoveal GA and AMD at inclusion. The researchers identified OCT risk factors for two-year foveal atrophy in eyes with untreated extrafoveal GA at baseline.

The study analyzed 45 participants (45 eyes) with extrafoveal GA

at baseline and with two years of regular follow-ups. **At month 24, 57.8% of eyes developed atrophy in the foveal central circle, while 24.4% of eyes developed atrophy in the foveal central point.**

Significant independent predictive features for the development of atrophy in the foveal central circle included foveal outer retinal thickness (OR: 0.87), minimum distance from the foveal central circle (OR: 0.99) and foveal thin double layer sign (OR: 0.04). **The only independent**

**predictive feature for the development of atrophy in the foveal central point was the presence of foveal thin double layer sign (OR: 0.14).**

When the foveal central point became involved, a dramatic loss in vision occurred. **“This study’s finding of an increased risk to develop atrophy in the foveal central circle in eyes with a shorter minimum distance from the foveal central circle at baseline may indicate that early changes in the retina surrounding the atrophic lesion may be involving**

**the fovea, this eventually leading to foveal atrophy over time,”** the researchers wrote in their paper. “Assuming that pegcetacoplan-treated eyes are characterized by a significantly slower GA lesion progression toward the fovea, the identification of risk factors for progression toward the fovea is clinically relevant,” the team concluded.

Borrelli E, Barresi C, Berni A, et al. OCT risk factors for two-year foveal involvement in non-treated eyes with extrafoveal geographic atrophy and AMD. *Graefes Arch Clin Exp Ophthalmol*. February 8, 2024. [Epub ahead of print].



# Could it be KC (KERATOCONUS)?

## KC File #1: The Patient Who Corrects to 20/20



**Mitch "Private Eye" Ibach OD, FAAO**, Vance Thompson Vision

A 29-year-old patient came to our office for a LASIK consult because she was unhappy with fluctuating vision in her contact lenses. The patient had ocular allergies but had no other ocular diagnoses.

Her entering glasses prescription was a modest one and we were able to refract her to 20/20. However, the refraction in the right eye was our first clue that something was not quite right.

Not only is  $>2.00$  D of refractive cylinder a warning signal for keratoconus, but the oblique axis is also unusual. About 90% of young corneas have with-the-rule (WTR) astigmatism.<sup>1</sup> The change in myopic spherical equivalent (SE) from baseline (the glasses prescription) was not what we would expect to see in an adult patient, either.

Autokeratometry from her referring optometrist was on the steeper side of normal, and our pachymetry measurements showed that both eyes had borderline thin corneas. Upon further questioning, the patient recalled that her sister had keratoconus. Having a first-degree relative (a parent, sibling, or child) with keratoconus increases the risk of developing the disease by 15- to 67-fold.<sup>2</sup>

At this point, we have some risk factors, but not a clear diagnosis. A closer look at topography, tomography, and anterior segment OCT epithelial mapping provided further information to make a decisive diagnosis of progressive keratoconus in the right eye.

This case illustrates that patients who see 20/20 at the phoropter can still have keratoconus. At 29, our patient was at an age where there is greater risk of progression,<sup>3</sup> and her ocular allergies and family history elevate that risk. She was fortunate to be diagnosed and treated early in the course of her disease, while she was still correctable to 20/20. **Simply by following the KC clues that are hiding in plain sight, you can help patients like this one preserve their vision by referring them to a corneal specialist. If further testing confirms the patient has progressive KC, iLink® cross-linking could slow or halt its progression. Visit [iDetectives.com](https://www.idetectives.com) to learn more.** ●

### REFERENCES:

1. Kojima T, et al. *Am J Ophthalmol* 2020;215:127-34. 2. Wang Y, et al. *Am J Med Genet* 2000;93(5):403-9. 3. Ferdi AC, et al. *Ophthalmology* 2019;126(7):935-45.

### #FollowTheClues



**INDICATIONS:** Photrexa® Viscous (riboflavin 5'-phosphate in 20% dextran ophthalmic solution) and Photrexa® (riboflavin 5'-phosphate ophthalmic solution) are indicated for use with the iLink System in corneal collagen cross-linking for the treatment of progressive keratoconus and corneal ectasia following refractive surgery.

**IMPORTANT SAFETY INFORMATION:** Corneal collagen cross-linking should not be performed on pregnant women. Ulcerative keratitis can occur. Patients should be monitored for resolution of epithelial defects. The most common ocular adverse reaction was corneal opacity (haze). Other ocular side effects include punctate keratitis, corneal striae, dry eye, corneal epithelium defect, eye pain, light sensitivity, reduced visual acuity, and blurred vision. These are not all of the side effects of the corneal collagen cross-linking treatment. For more information, go to [www.livingwithkeratoconus.com](https://www.livingwithkeratoconus.com) to obtain the FDA-approved product labeling. You are encouraged to report all side effects to the FDA. Visit [www.fda.gov/medwatch](https://www.fda.gov/medwatch), or call 1-800-FDA-1088.

iLink®

SPONSORED AND SUPPLIED BY GLAUKOS

GLAUKOS®

© 2023 Glaukos PM-US-1553 Rev.1

### Refraction and exam findings

	RIGHT EYE	BCVA	LEFT EYE	BCVA
Lensometry	-0.50 -1.50 x31	20/30	-1.50 -0.50 x172	20/20-
Refraction at Phoropter	-0.75 -2.25 x34	20/20	-1.75 -0.75 x160	20/20+
Pachymetry	478 µm		483 µm	
Autokeratometry	45.5 / 47.50 x 112		44.9 / 46.75 x80	

### KC File #1: THE CLUES

- Large change in refraction from lensometer to phoropter
- High astigmatism (-2.25 D) with an oblique axis
- Borderline thin corneas (478/483 µm)
- Relatively steep auto Ks (47.5)



**iDetective**  
Following the clues  
for early KC detection

# Nonarteritic AION Incidence Increases After Age 50

Considered as the most common cause of acute optic nerve-related vision loss in patients over age 50, nonarteritic anterior ischemic optic neuropathy (NAION) is a multifactorial disease linked to a combination of system and ocular risk factors. Some of these are thought to include systemic hypertension, diabetes mellitus, obstructive sleep apnea and hyperlipidemia, which have been reported as increasing in the American population in recent decades. However, a new retrospective study may dispel the correlation between the rise in risk factors with an uptick in NAION incidence.

Researchers used the database from the Rochester Epidemiology Project, including patients diagnosed with an optic neuropathy from 1990 to 2016 and who received care in Olmsted County, Minnesota. A total of 1,791 patients were identified with optic neuropathy, of which 104 were diagnosed with

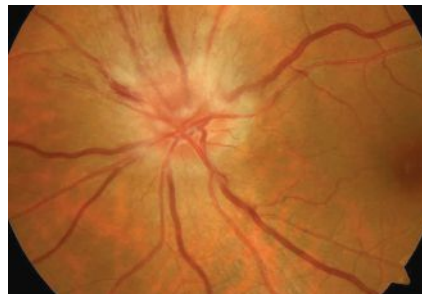


Photo: Neil Miller MD

**Patients age 50 and older are at higher risk for NAION, while incidence rates have been stable across four decades.**

NAION. Median age at diagnosis was 65. NAION incidence in patients 40 or older was 7.73 (per 100,000) and 10.19 in patients 50 and older. The highest incidence was noted in the 80 to 89 age bracket: 14.56 per 100,000 for women and 26.09 per 100,000 for men.

This data is consistent with a prior Rochester Epidemiology Project study conducted between 1980 and 1990 in which the NAION incidence rate was

10.2 in patients 50 and over, indicating its stability over a 40-year span, in spite of the associated risk factors found, including hypertension (79.8%), diabetes (39.4%), obstructive sleep apnea (23.1%) and hyperlipidemia (74%).

Other previous reports were also confirmed with this study. “A small c/d ratio is a well-established ocular risk factor for NAION, likely due to compartment syndrome in the region of the lamina cribrosa,” stated the authors. “Our study confirms this with a median c/d ratio of 0.2. It also confirms an altitudinal defect as the most common visual field defect.”

Despite some limitations, this study shows there hasn’t been a dramatic increase in NAION diagnoses in this population and maintains that those 50 and older are at the most risk. ◀

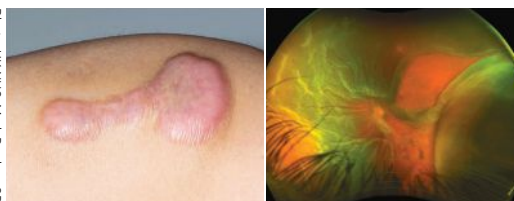Foster RC, Bhatti MT, Crum OM, Lesser ER, Hodge DO, Chen JJ. Reexamining the incidence of nonarteritic anterior ischemic optic neuropathy: A Rochester Epidemiology Project Study. *J Neuroophthalmol*. February 15, 2024. [Epub ahead of print].

# Keloids & Hypertrophic Scars: Potential PVR Risk Factors

Aggressive cutaneous wound healing can produce keloids and hypertrophic scars of the skin, both resulting in thickened, raised lesions. In particular, keloids uniquely expand horizontally, do not regress and may present years after injury. Keloids and hypertrophic scars have recently been associated with numerous health conditions and surgical complications, and researchers explored a potential association between cutaneous keloids, hypertrophic scarring and fibrosis and risk of postoperative proliferative vitreoretinopathy (PVR) after rhegmatogenous retinal detachment (RRD) repair. They found that such a dermatologic history may be a risk factor.

The retrospective cohort study in *Ophthalmology* assessed patients ≥ 18 years who underwent initial RD repair with pars plana vitrectomy with or without scleral buckle, pneumatic retinopexy and

Photo: UK NHS, Mark Dunbar, DO



**Including all RD repair types, the rate of PVR was still greater in those with keloids, hypertrophic scars and fibrosis within six months of surgery.**

primary scleral buckle for prevalence of PVR and complex RD repair within 180 days after RRD repair. The cohort was split into two groups of 1,061 patients: one with history of cutaneous keloids, hypertrophic scarring and fibrosis and one without.

Within 180 days, 10.1% of patients in the keloid, hypertrophic scar and fibrosis cohort and 3.4% in the other cohort had a diagnosis of PVR. (odds ratio [OR]= 3.2). The study also found that 8.3% of patients in the keloid cohort and 5.4% of patients in the other cohort underwent

complex RD repair (OR= 3.2). When including all retinal detachment repair types, the rate of PVR diagnosis was still significantly greater in the keloid, scar and fibrosis cohort (9.0% vs 4.2%; OR= 2.28).

“This carries potential prognostic implications for our RRD patients with preexisting keloids, hypertrophic scars and fibrosis; it also adds to the list of risk factors for PVR, which can help guide vitreoretinal surgeons using medical treatments to either prevent or regress PVR,” the researchers wrote in their paper. They concluded by noting that further research is necessary to explore whether or not these patients may benefit from current and future therapies aimed at preventing or treating PVR. ◀

Mammo DA, Wai K, Rahimy E, et al. Association of cutaneous keloids, hypertrophic scarring and fibrosis with risk of postoperative proliferative vitreoretinopathy. *Ophthalmology*. January 29, 2024. [Epub ahead of print].





# Discover the ergonomic benefits of Vantage Plus BIO

with our free whitepaper



## Leading the way in comfort, balance and intuitive design:

### 1: Cushioned comfort

Ergonomically designed, prioritising comfort and weight distribution. The soft, plush headband padding delivers a secure and comfortable fit, reducing the risk of slipping or shifting.

### 2: Balanced stability

Keeler's balanced, lightweight design reduces strain and discomfort during prolonged examinations, requiring half as much force to maintain a neutral position compared to other models.

### 3: Ergonomic fit

The fully adjustable headset enables clinicians to customise optics and headband positioning for comfort, reducing strain and pressure on the head and neck.

Visit **Keeler at VEE, stand F2810** to discover our extensive range of BIOs and more!

# Fetal Growth Restriction Leads to Enlarged Vertical c/d Ratio in Adulthood

A study published in *American Journal of Ophthalmology* attempted to discover any associations between fetal growth restriction (as well as excessive fetal growth), perinatal factors and the optic nerve head development process as manifested in adulthood.

In this retrospective cohort study, the researchers examined individuals born full term between the years 1969 and 2002 at a single institution. The team had the participants undergo non-mydratic fundus photography of the optic disc, followed by manual measurements. Researchers then examined and analyzed the vertical cup-to-disc (c/d) ratio and optic disc area in relation to each participants' birth weight relative to their gestational age (SGA: small for gestational age, LGA: large for gestational age), assigning each to one of the following five categories:

- *severe SGA*: birth weight <3rd percentile
- *moderate SGA*: 3rd to 9th percentile
- *normal SGA*: 10th to 90th percentile
- *moderate LGA*: 91st to 97th percentile
- *severe LGA*: >97th percentile

The experiment observed 535 eyes from 280 individuals. The mean age for the experiment was  $29.74 \pm 9.23$  years (range: 18 to 52), and 144 women and 136 men who were born full term participated in the study. According to the researchers' multivariate analysis, they found a significant association between a larger vertical c/d ratio and severe SGA status. According to the researchers' univariate model, placental insufficiency—but no other perinatal factor—was associated with greater vertical c/d ratio.

Interestingly, the researchers did find an indication that a smaller optic disc area was associated with individuals from the moderate SGA group. "No studies have established a direct correlation between lower birth weight for gestational age and optic disc area," mentioned the researchers in their article on the study. "To date, it has been mainly demonstrated that prematurity is associated with a smaller optic disc."

The researchers noted that this study was conducted at a single center and, due to inaccessible contact information

from some of the cohorts, the sample was not entirely representative. Additionally, most study participants were of white ethnicity, so the results and conclusions made could only represent this specific population. Also, since this was an exploratory study and researchers did not adjust for multiple testing, they mentioned that more studies would be needed to further understand this area of research.

"Our findings provide novel insights into the impacts of fetal growth restriction on the optic nerve head morphology in full-term born individuals, revealing that the vertical c/d ratio increases in individuals born severely SGA at-term," concluded the researchers in their paper. "These findings indicate that fetal growth restriction has a lasting impact on the optic nerve head morphology until adulthood and may indicate a lower neuronal reserve for degenerative optic disc diseases." ◀

Fieß A, Gißler S, Mildnerberger E, et al. Fetal growth restriction leads to an enlarged cup-to-disc ratio in adults born at full term. *Am J Ophthalmol*. February 7, 2024. [Epub ahead of print].

# Red Light Slows Myopia in Kids, Lit Review Says

Repeated low-level red light (RLRL) therapy is showing promise outside the United States as a new myopia treatment for children, even though recent reports have questioned its long-term safety. This phototherapy involves administering low doses of red and near-infrared light that are intended to cause a tissue response. A recent paper in *BMC Ophthalmology* presented the first systematic review and meta-analysis of RLRL therapy investigating only randomized controlled trials. The analysis showed that RLRL was effective at reversing myopia progression but still requires long-term studies.

The meta-analysis included five randomized controlled trials with 833 total

subjects (407 receiving RLRL, 426 controls). Results showed that at three months, there were significant differences between the two groups in axial length ( $-0.16\text{mm}$ ), spherical equivalent refraction (SER) ( $0.33\text{D}$ ) and subfoveal choroidal thickness (SFCT) ( $43.65\mu\text{m}$ ). At six months, significant differences remained in axial length ( $-0.21\text{mm}$ ), SER ( $0.46\text{D}$ ) and SFCT ( $25.07\mu\text{m}$ ). At 12 months, there were significant differences in axial length ( $-0.31\text{mm}$ ) and SER ( $0.63\text{D}$ ).



RLRT therapy bested other noninvasive myopia treatments in the study.

"The present review revealed the clinical significance of RLRL for myopia control in terms of AL, SER and SFCT," the researchers wrote in their paper. "It has slowed down and reversed the myopia progression in a large proportion of children."

However, they did note that "the effect of long-term treatment and the rebound effect after cessa-

tion require further investigation." ◀

Youssef MA, Shehata AR, Adly AM, et al. Efficacy of repeated low-level red light (RLRL) therapy on myopia outcomes in children: a systematic review and meta-analysis. *BMC Ophthalmology*. 2024;24:28.

## Get *more* out of your eyedrop bottles



Have you ever heard patients complain about their eyedrops? Maybe they ran out before the end of the month and had to wait for insurance to cover their next refill, or they suffer from side effects that are hard to tolerate? Have you noticed how much of the drop runs down your patients' faces when you dilate their eyes?

That's because eyedrops are too large for the eye to absorb. The Nanodropper Adaptor has solved this problem. Here's how it works!

### What's the problem with eyedrops?

They're too big! About five times too big. This means 80% of every eyedrop (and thus, every bottle) is wasted due to overflow and/or systemic absorption. This waste contributes to financial barriers to care, and clinical research has shown that oversized drops increase both local and systemic side effects!

### How does Nanodropper help?

Pretty simple — just twist the Nanodropper on to your current bottle to reduce the size of eyedrops to just what the eye can absorb! Smaller drops triple the number of drops per bottle, while maintaining therapeutic efficacy and improving tolerability.

*The Nanodropper is compatible with most of your commonly used in-office drops like phenylephrine and proparacaine, OTC drops like Lumify, and expensive glaucoma medications like Rhopressa, Rocklatan, Lumigan, Vyzulta, and many more!*



The Nanodropper Adaptor is quickly becoming the new standard of care, not only addressing patient concerns and challenges, but also a larger societal medical waste issue. It's not just a want to have, but a need to have.

**-Robert Wooldridge, OD, of the Eye Foundation of Utah and advisor for Nanodropper**



Use discount code  
**ROM10** for 10% off  
your first order!



The Nanodropper is the only FDA-listed, volume-reducing adaptor for eyedrop bottles designed to deliver precisely the amount of fluid the eye can absorb. Smaller drops reduce the waste and cost of in-clinic and Rx formulations while minimizing local and systemic side effects.



# FEATURES

REVIEW OF OPTOMETRY • Vol. 161, No. 3 • MARCH 15, 2024

## COVER STORY

### 32 Optometric Scope: Breaking Down Barriers

Here's how ODs are challenging old boundaries—and what they can do once freed from them.

*By Leanne Spiegle, Associate Editor*



## ANNUAL PHARMACEUTICALS REPORT

### 44 Have You Kept Up With the Recent 'New Drug' Deluge?

Optometrists have access to many new meds right now, with a flood of more on the way. Here's a comprehensive review of what's out right now and what's in the pipeline.

*By Roya Habibi, OD, Mark Buboltz, OD, and Jacob Lang, OD*

### 52 Safe and Savvy Prescribing of Oral Pharmaceuticals

Two experts share their best "dos and don'ts" to help you confidently handle the most common scenarios across several different categories of medications.

*By Blair Lonsberry, OD, and Mitch Ibach, OD*

## ALSO IN THIS ISSUE

### 60 Ease Yourself Into Myopia Management

While it's true that going "all-in" on this new area of care can give you the most control over outcomes, novices can find ways to begin gradually and still see success.

*By Andrew Pucker, OD*

EARN 2 CE CREDITS

### 66 OCT Beyond the Basics: Unlock the Power of this Essential Tool

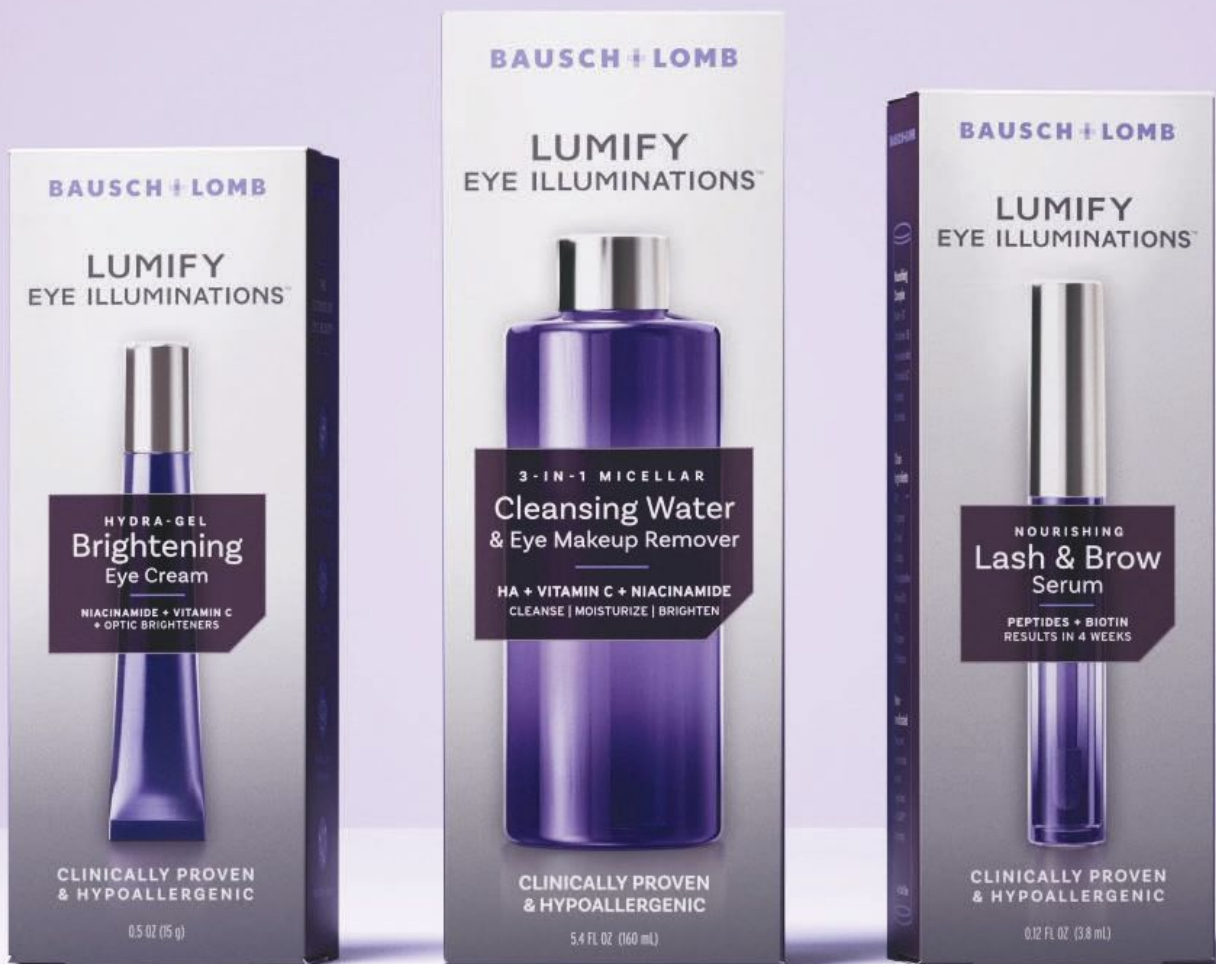How to maximize use of this instrument based on the specific pathology at hand.

*By Lee Vien, OD, and David Yang, OD*

REVIEW OF OPTOMETRY (ISSN 0147-7633) IS PUBLISHED MONTHLY, 12 TIMES A YEAR BY JOBSON MEDICAL INFORMATION LLC/WEBMD, 283-299 MARKET STREET, 2 GATEWAY CENTER, 4TH FLOOR, NEWARK, NJ 07102. PERIODICALS POSTAGE PAID AT NEWARK, NJ AND ADDITIONAL MAILING OFFICES. POSTMASTER: SEND ADDRESS CHANGES TO REVIEW OF OPTOMETRY, PO BOX 81, CONGERS, NY 10920-0081. SUBSCRIPTION PRICES: US: ONE YEAR \$56; TWO YEARS \$97; CANADA: ONE YEAR \$88; TWO YEARS \$160; INT'L: ONE YEAR \$209; TWO YEARS \$299. FOR SUBSCRIPTION INFORMATION CALL TOLL-FREE (877) 529-1746 (USA); OUTSIDE USA, CALL (845) 267-3065. OR EMAIL US AT REVOPOTOMETRY@CAMBEYWEST.COM. PUBLICATIONS MAIL AGREEMENT NO: 40612608. CANADA RETURNS TO BE SENT TO BLEUCHIP INTERNATIONAL, P.O. BOX 25542, LONDON, ON N6C 6B2.

FROM THE EYE CARE EXPERTS AT **BAUSCH+LOMB**

# LUMIFY EYE ILLUMINATIONS™



Non-irritating formulas

Developed with Eye Doctors  
and Dermatologists

Clinically-proven

A trio of specialty eye care products scientifically formulated for the sensitive eye area.  
Clinically proven with 15,000 product applications up to 12 weeks.

Your patients can find this **in the eye care aisle.**

© 2023 Bausch + Lomb LEM.0152.USA.23 [LUMIFYeyes.com](https://www.LUMIFYeyes.com)

# DEPARTMENTS

REVIEW OF OPTOMETRY • MARCH 15, 2024

FOLLOW US ON SOCIAL MEDIA

Facebook: revoptom

Twitter: revoptom

Instagram: revoptom

Threads: revoptom

LinkedIn: company/review-of-optometry

## 4

### NEWS REVIEW

Clinical, legislative and practice updates for ODs.

## 18

### OUTLOOK

#### 51 Flavors of Optometry

The profession's fragmented legal basis lets some states surge while others languish, creating dozens of varieties.

**Jack Persico, Editor-in-Chief**

## 20

### THROUGH MY EYES

#### Power Up Your Prescribing

Start e-scribing new medications to specialty pharmacies.

**Paul M. Karpecki, OD**

## 22

### CHAIRSIDE

#### Platitudes, Schmatitudes

Listening, learning and being yourself leads to success.

**Montgomery Vickers, OD**

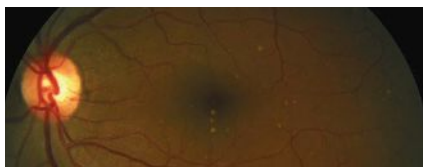
## 24

### THE ESSENTIALS

#### A Look at Lutein

This lipid-soluble pigment is an integral part of maintaining ocular health.

**Bisant A. Labib, OD**



## 26

### CLINICAL QUANDARIES

#### Down the Tubes

Tube shunt erosion can be rare, but it is a serious complication for glaucoma patients.

**Paul C. Ajamian, OD**



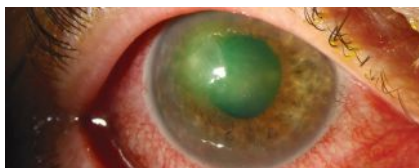
## 28

### YOU BE THE JUDGE

#### Bad History, Bad Patient, Bad Bug

A misdiagnosis can cause a vision-threatening complication exacerbated by a noncompliant patient.

**Jerome Sherman, OD,  
and Sherry Bass, OD**



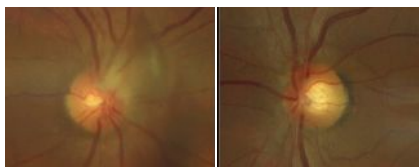
## 76

### URGENT CARE

#### Not So Nerve-ous

Know the signs of this frequently misdiagnosed condition.

**Alison Bozung, OD**



## 78

### OCULAR SURFACE REVIEW

#### Shining the Slit Lamp on ADCs

ODs can help ovarian cancer patients who are taking this advanced therapeutic agent, specifically Elahere.

**Paul M. Karpecki, OD**



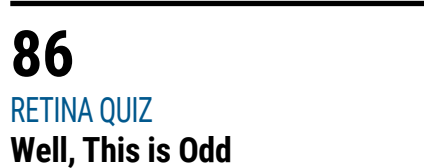## 80

### ADVANCED PROCEDURES

#### Uprooting Misdirected Lashes

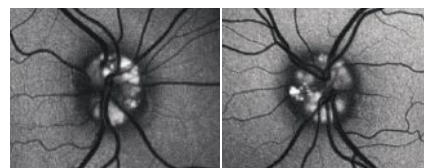
Trichiasis ablation with radiofrequency can be a more permanent treatment option.

**Komal Patel, OD**



Headaches with TVO led to this diagnosis.

**Rami Aboumourad, OD**



## 90

### DIAGNOSTIC QUIZ

#### The Ol' Switcheroo

Blurring of central vision indicated to the patient—and us—that something was amiss. Do you know what happened?

**Andrew S. Gurwood, OD**





# Changing SIGHT Overnight.

Overnight Orthokeratology

1.

NCLE certified consultation experts to guide you through the entire fitting process

2.

Highly adjustable parameters with an online lens design calculator

3.

Dynamic Edge Profile™ delivers remarkable comfort

4.

Diameter & optic zone options allow the doctor to customize the lens to the patient



Scan to learn more about REMLens® and get certified today.



**X-CEL**  
SPECIALTY CONTACTS

800.241.9312  
[xcelspecialtycontacts.com/remlens](http://xcelspecialtycontacts.com/remlens)

Vision Shaping  
Treatment VST™

MADE EXCLUSIVELY WITH  
BOSTON® EQUALENS® II  
LENS MATERIALS

**EDITOR-IN-CHIEF**  
**JACK PERSICO**

(610) 492-1006 • jpersico@jobson.com

**SENIOR EDITOR**  
**JULIE SHANNON**

(610) 492-1005 • jshannon@jobson.com

**SENIOR ASSOCIATE EDITOR**  
**MARK DE LEON**

(610) 492-1021 • mdeleon@jobson.com

**ASSOCIATE EDITOR**  
**LEANNE SPIEGLE**

(610) 492-1026 • lspiegle@jobson.com

**ASSOCIATE EDITOR**  
**RACHEL RITA**

(610) 492-1000 • rrita@jobson.com

**SENIOR SPECIAL PROJECTS MANAGER**  
**JILL GALLAGHER**

(610) 492-1037 • jgallagher@jobson.com

**ART DIRECTOR**  
**LYNNE O'CONNOR**

lyoconnor@jobson.com

**GRAPHIC DESIGNER**  
**JAINE KOPALA**

jkopala@jobson.com

**DIRECTOR OF CE ADMINISTRATION**  
**REGINA COMBS**

(212) 274-7160 • rcombs@jobson.com

**Clinical Editors**

Chief Clinical Editor • Paul M. Karpecki, OD

Associate Clinical Editors

Joseph P. Shovlin, OD, Christine W. Sindt, OD

Clinical & Education Conference Advisor  
Paul M. Karpecki, OD

Case Reports Coordinator • Andrew S. Gurwood, OD

**Columnists**

Advanced Procedures – Nate Lighthizer, OD

Chairside – Montgomery Vickers, OD

Clinical Quandaries – Paul C. Ajamian, OD

Cornea and Contact Lens Q+A – Joseph P. Shovlin, OD

Diagnostic Quiz – Andrew S. Gurwood, OD

The Essentials – Bisant A. Labib, OD

Focus on Refraction – Marc Taub, OD, Pamela Schnell, OD

Glaucoma Grand Rounds – James L. Fanelli, OD

Ocular Surface Review – Paul M. Karpecki, OD

Retina Quiz – Rami Aboumourad, OD

Surgical Minute – Derek Cunningham, OD, Walter Whitley, OD

Therapeutic Review – Jessica Steen, OD

Through My Eyes – Paul M. Karpecki, OD

Urgent Care – Alison Bozung, OD

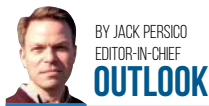You Be The Judge – Jerome Sherman, OD, Sherry Bass, OD

**Editorial Offices**

19 Campus Blvd., Suite 101 • Newtown Square, PA 19073

Jobson Medical Information/WebMD  
283-299 Market Street, 2 Gateway Center, 4th Floor  
Newark, NJ 07102Subscription inquiries: (877) 529-1746  
Continuing Education inquiries: (800) 825-4696

Printed in USA



# 51 Flavors of Optometry

*The profession's fragmented legal basis lets some states surge while others languish, creating dozens of varieties.*

This month's cover story lays out in detail the status of optometric scope expansion in the US, highlighting the many gains earned in recent years and the vigorous efforts presently underway in at least a dozen states. There's a lot to be excited about right now. But if you'll flip to page 36 and look at the chart detailing the range of optometric scope state by state, you'll see a dizzying amount of variation.

In researching the legal status of 10 different advanced responsibilities—laser procedures, oral meds, injections, minor surgeries and the like—we found that not a single category has been uniformly rolled out yet in the US. Instead, all 50 states plus the District of Columbia each present to their communities a slightly (sometimes radically) different conception of optometry than their neighbors. It's confusing, frustrating and just plain exhausting.

It's also here to stay. The prospects for enacting a nationwide optometry law, settling once and for all the legal status of the profession uniformly, are dim. Any effort of that sort would need the vigorous support of numerous optometric institutions that may not have the time or resources to put in the work on such a Herculean task. So, we're left with the image of optometry as the biggest Baskin Robbins freezer case you could ever imagine.

This certainly doesn't help optometry integrate into the broader healthcare delivery system. When the capabilities of practitioners diverge so widely across state lines, it makes it easier for insurers, policymakers and doctors from other corners of healthcare to just wash their hands of it and favor ophthalmology, the known quantity in eye care.

But there are a few encouraging developments that might ease the path to legal parity for optometrists across states.

First, if optometry's advocates are able to craft "as-taught" legislation, which allows practitioners to perform any procedure they trained on, it will cut down on the number of scope bills and battles. It recently came to light that ODs in Wisconsin have been quietly—and successfully—performing a variety of advanced procedures under such a philosophy instead of formally seeking legal action on every specific new responsibility (*see news story, page 5*). Naturally, opponents are already crying foul. If the Wisconsin model survives challenges from ophthalmology, it can be emulated elsewhere.

Second, the case being made for scope expansion is evolving. The long-standing argument that it would expand access to care in rural areas does still have merit, of course, but we're approaching a time when we'll no longer need that crutch. California got a laser bill to the one-yard line in 2022 and New Jersey, the most densely populated US state, has one in session now. Everyone benefits from optometric scope expansion (*psst*, including ophthalmologists, if they could ever abandon their blinkered view of things).

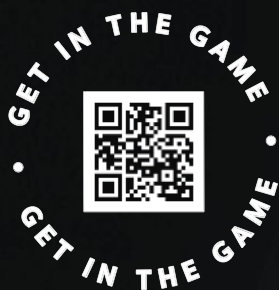Third, a rising tide lifts all boats. Every successful expansion bill makes the next one that much easier to pass, as advocates have more precedents to point to.

Lastly, of course, surging demand for eye care and a declining supply of ophthalmologists pretty much make it a foregone conclusion. Whether it'll take years or decades, the endgame of scope expansion is obvious.


Until then, enjoy your time in the ice cream parlor. I hear Pralines & Cream is nice. ■

# SPEED. EASE. RANGE.

**MyDay® daily disposable  
multifocal with CooperVision  
Binocular Progressive System®  
is a game-changer.<sup>1</sup>**



Micaela Crowley, O.D.  
Lexington, MA



MyDay® multifocal leverages the latest innovation in multifocal contact lens technology with **CooperVision Binocular Progressive System®** to optimize vision for all levels of presbyopia and visual acuity at all distances.<sup>2</sup> With its speed and ease of fit using OptiExpert™, you can **successfully fit 98% of the time** with two pairs or fewer.<sup>3,4</sup> Plus, with the **incredible comfort of Aquaform® Technology** that patients' eyes deserve<sup>5</sup>, MyDay® multifocal has changed the game.

**If you haven't fit MyDay® multifocal,  
what are you waiting for? Get in the game.**

1. CVI data on file as of May 2023 vs. leading manufacturers. 2. CVI data on file 2020. Prospective, double-masked, bilateral, 1-week dispensing study with MyDay daily disposable multifocal; n=104 habitual MFCL wearers. 3. CVI data on file 2020. Prospective, double-masked, bilateral, one-week dispensing study UK with MyDay® multifocal; n=104 habitual multifocal contact lens wearers. 4. CVI data on file 2021. Prospective, subject-masked, randomized, bilateral, two-week dispensing study at 5 US sites with MyDay® multifocal; n=58 habitual multifocal contact lens wearers. 5. CVI Data on file 2022. Based on global product sales and internal estimates of products using Aquaform® Technology over 12 months in 2022. ©2024 CooperVision 14777ROO 1/24





BY PAUL M. KARPECKI, OD  
CHIEF CLINICAL EDITOR

## THROUGH MY EYES

# Power Up Your Prescribing

*Start e-scribing new medications to specialty pharmacies.*

I recently took my daughter to urgent care for an upper respiratory infection and the doctor recommended OTC decongestants; I was miffed. I informed him that I had already tried OTC products and that's why we scheduled this visit. He then prescribed a medication but, rest assured, I'd never go back to that clinic. I often wonder if that's the same for optometry when we choose OTC products alone as treatments for dry eye, blepharitis and other conditions. How many of those patients feel the same way and go on to find another optometrist?

Several new therapeutic agents have become available, and note that the lowest price a patient will pay for an ophthalmic medication is when it first comes on the market. Keep in mind that new medications require e-scribing to a specialty pharmacy and proper ICD-10 codes greatly help. The minor but important insights listed below should help you power-up your prescribing.

### Xdemvy

The first prescription drop approved for *Demodex* blepharitis is extremely effective and works faster than I anticipated. By having patients instill Xdemvy (lotilaner ophthalmic solution, 0.25%, Tarsus Pharmaceuticals) in their eye twice a day and gently rubbing any excess drop into the base of their lashes, I'm seeing impressive results within a week or two. Since *Demodex* mites feed on

oils, the use of a surfactant lid wipe (e.g., OcuSoft Lid Scrub Plus) to remove dysfunctional oils is a good use of OTC products but must accompany Xdemvy. If you only use wipes or microblepharoexfoliation (which I recommend), you are essentially removing the sawdust but not killing the termite. I've also learned that patients must continue the medication for the entire six weeks; one bottle has more than sufficient drops.

“Keep in mind that new medications require e-scribing to a specialty pharmacy and proper ICD-10 codes greatly help.”

As for helping your patients obtain Xdemvy, e-prescribe to one of four specialty pharmacies: Alliance Rx Walgreens, BlinkRx, Carepoint or CVS Specialty. Most patients pay \$50 or less. To help get the drug to the patient, include both ICD-10 codes: H01.00 (unspecified blepharitis) and B88.0 (other acariasis). If a PA is needed, the pharmacy will initiate the PA form with CoverMyMeds. The office must complete it with the doctor signing it and submitting it to the PA. Inform the patient that they will hear from the specialty pharmacy, often by text, within 48 hours and to respond—otherwise the medication will not be shipped. These pharmacies are also trained specifically

on this drug and affordable options for Medicare patients.

### Semi-fluorinated Alkane Drugs

Miebo (perfluorohexyloctane, Bausch + Lomb) and VeVye (cyclosporine 0.1%, Harrow Health) are very effective. Both deliver a drop about one-fourth of the typical drop size and, because they are incredibly comfortable agents, it can be difficult for patients to feel the drop going in. Miebo resides in the tear film at least six hours and in the meibomian glands for more than 24 hours. It creates a monolayer that prevents evaporation at a rate that is four times greater than our own healthy meibum. The drug can be administered up to four times per day.

VeVye has a sister SFA vehicle plus 0.1% cyclosporine, which is the highest concentration of CsA available in an ophthalmic drop. It's dosed BID and was assessed on primarily aqueous deficient dry eye patients.

Like Xdemvy, these drugs are best prescribed through a specialty pharmacy: BlinkRx for Miebo and PhilRx for VeVye. Most patients are receiving the first drug for free (often after a PA) and this includes Medicare patients. Many commercial patients continue to get Miebo for \$0, but it can depend on a patient's choice of insurance plans. Should a patient choose a high deductible insurance plan to save on premiums, they may have a higher cost, which should easily be offset with their insurance cost savings. VeVye has a buydown program in place where no patient should pay over \$79 and most pay \$0.

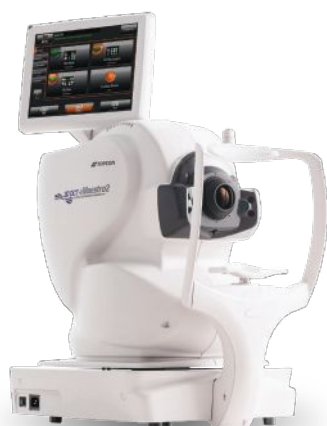While optometrists write about two-thirds of all new drug prescriptions, we could still use these insights to improve prescribing results. ■

About  
Dr. Karpecki

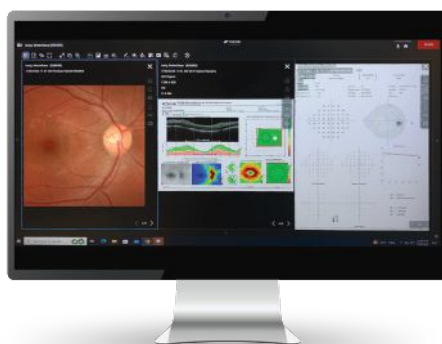Dr. Karpecki is the director of Cornea and External Disease for Kentucky Eye Institute and an associate professor at KYCO. He is the Chief Clinical Editor for Review of Optometry and chair of the New Technologies & Treatments conferences. A fixture in optometric clinical education, he consults for a wide array of ophthalmic clients, including ones discussed in this article. Dr. Karpecki's full disclosure list can be found in the online version of this article at [www.reviewofoptometry.com](http://www.reviewofoptometry.com).

# NEW! Glaucoma Management Suite

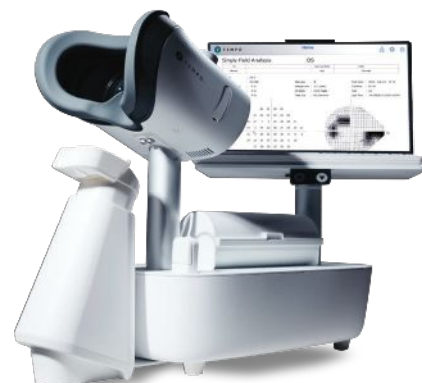Combine the power of Maestro2 structural imaging with TEMPO™ visual field function through Topcon Harmony® clinical data management.



**MAESTRO2**  
OCT & Color  
Fundus Camera



**HARMONY®**  
Clinical Data  
Management



**TEMPO™**  
Visual Field  
Analyzer

Visit [topconhealthcare.com/glaucomasuite](https://topconhealthcare.com/glaucomasuite) to learn more.





BY MONTGOMERY VICKERS, OD  
**CHAIRSIDE**

# Platitudes, Schmatitudes

*Listening, learning and being yourself leads to success.*

**“D**o what you love and you’ll never work a day in your life,” they say. What a crock. Don’t get me wrong, I tell every kid who comes into my office that the definition of success is to find something they love to do and figure out a way to get paid doing it. Sounds great? But consider the audience.

When I was 16, if my optometrist told me that, I would have thought he was the biggest dork I had ever met, and that’s saying something because up until then, I, myself was the biggest dork I had ever met.

I remember my 40th Montgomery High School Class Reunion way back in 2011. The head cheerleader back then came up to me and asked, “Why didn’t we ever go on a date in high school?” My answer: “Did you not know me in high school?” For nearly all four years I had worn the same outfit: white painter pants bib overalls, a polka-dotted purple shirt, a brown belt with a giant slide rule in a plastic sheath, all topped off by a canvas dove hunter’s jacket with a big peace symbol hand-painted on the back (when I wasn’t wearing my dark brown suede fringed hippy vest).

I was a catch for sure. Should have asked her out, right?

So, if somebody told me how to move in a direction of happiness and success in my work, they probably would want to start with advising a better outfit. That leads us to...

**“Dress for success.”** When I got off the waiting list at Pennsylvania College of Optometry, I had to borrow my younger brother’s dress shirt and clip-on tie since I didn’t own one and I

had been told all the first-year students would have to wear a tie the first day of class. My brother was twice as big as me so I looked like David Byrne/Billie Eilish sans the dyed hair. Thank goodness they let us dress like the bums we were after that first day.

In optometry, we need to dress better than I did in high school, college and optometry school, but that will not, by itself, make you successful—just a little more likely not to get laughed at when you open your office’s first checking account.

**“Grab the low-hanging fruit.”** This is apparently the mantra of many of our esteemed colleagues as they race to the bottom by giving their time away and accepting every vision plan, even if the reimbursement is so low you’d be lucky to break even when you see that low-hanging patient. I guess I was lucky to spend 99% of my career in a little town in a little state with little—but wonderful—small businesses that didn’t employ 80% of my patients. So, if I didn’t accept a plan, I’d temporarily lose two or three families, not my whole practice.

**“Win-win or no deal.”** It’s not that simple. I remember when my brother said it this way: “It’s not whether you win or lose. It’s whether I win or lose.” This is the attitude that gets you that date with the head cheerleader in high school and can determine if you see enough patients to keep putting bread on the table. However, this does not mean stomp all over anyone who gets in the way; just try hard.

Business platitudes have their place. I have tried many of them along the way and have done OK for myself, my wife of 43 years and my kids and their kids. But the deal is to just glean a bit of wisdom from each one and from everyone you meet. One of my writing mentors, the late, amazing Jack Runninger, OD, sat me down and talked with me

at SECO. He gave me tons of specific critique soon after my very first Chairside column hit these pages.

Two years later, he found me again and told me he was truly thrilled that I was smart enough to ignore everything he had told me. We both

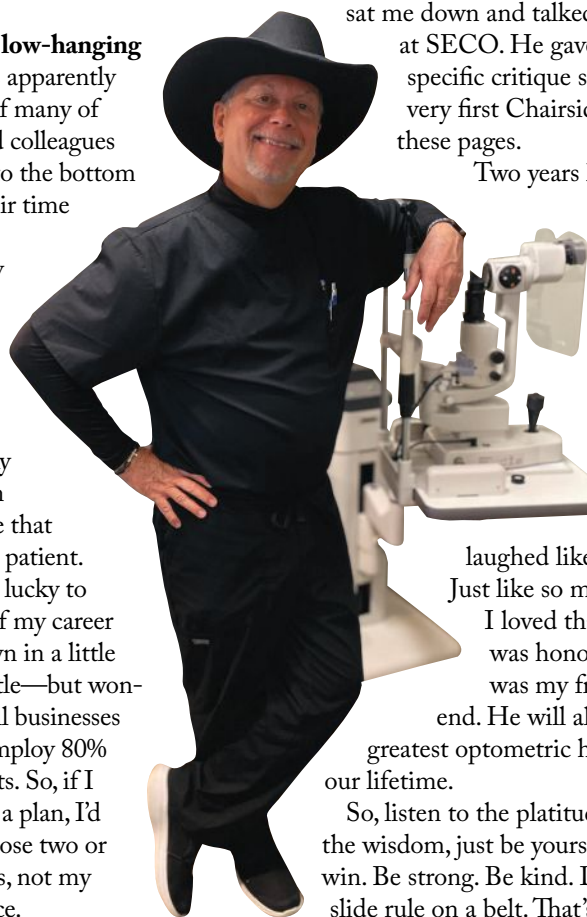
laughed like hyenas.

Just like so many of you,

I loved that man and was honored that he was my friend to the end. He will always be the

greatest optometric humorist in our lifetime.

So, listen to the platitudes, look for the wisdom, just be yourself and you do win. Be strong. Be kind. Don’t wear a slide rule on a belt. That’s all. ■



About  
Dr. Vickers

Dr. Vickers received his optometry degree from the Pennsylvania College of Optometry in 1979 and was clinical director at Vision Associates in St. Albans, WV, for 36 years. He is now in private practice in Dallas, where he continues to practice full-scope optometry. He has no financial interests to disclose.



From the makers of the #1-prescribed dry eye brand in Europe\*

# Covering the spectrum of *Dry Eye Relief*

Over-the-counter iVIZIA® lubricant eye drops protect the ocular surface and deliver a unique combination of immediate and long-lasting relief in a **preservative-free** formulation.

- A unique formulation—including povidone (active), trehalose (inactive), and hyaluronic acid (inactive)
- Proprietary, **multi-dose preservative-free (MDPF)** bottle

## Chronic Dry Eye Patient Usage Study†:

Up to  
**8 hours**  
of relief

as well as improved comfort during  
computer work, reading, and driving¹

**84%**

of users reported iVIZIA worked  
better than their previous eye drops¹



Safe for use with  
contact lenses‡



Scan here.

**Recommend iVIZIA and request  
samples by visiting [iVIZIA.com/ECP](https://www.ivizia.com/ECP)**

\*Prescription market data, Dec. 2022 – S01K without cyclosporine.

†In a chronic dry eye patient usage study, participants from a variety of socioeconomic backgrounds answered questions about their experience with iVIZIA lubricant drops. In the study, 203 chronic dry eye patients, 28-80 years old, switched from their dry eye artificial tears to iVIZIA for a month.¹

‡To limit blurriness when using contact lenses, remove contacts, apply drops, then insert contacts.

Reference: 1. Thea Data on File.

Copyright ©2024 Thea Pharma Inc. | All Rights Reserved. | PRC-IED-1030-v4 1.2024

 **Thea**  
let's open our eyes



BY BISANT A. LABIB, OD

## THE ESSENTIALS

# A Look at Lutein

*This lipid-soluble pigment is an integral part of maintaining ocular health.*

There are many unique features distinguishing the macula from other areas of the retina. Some of these include, but are not limited to, the density of cones, lack of retinal vasculature and presence of macular pigment. All these properties contribute to the macula's ability to maintain the sharpest acuity for optimal vision. An often underthought contribution to ocular health and function is the presence of carotenoids in the macula, particularly of the lutein carotenoid.

Lutein, along with its two stereoisomers—zeaxanthin and meso-zeaxanthin—is the only carotenoid found in human tissue. This is a significant minority, since well over 800 types of carotenoids actually exist in nature through various microorganism and plant sources. The human body, however, does not have the ability to synthesize lutein on its own. Instead, it relies on dietary intake to fulfill its needs. To truly understand the function and benefit of lutein, it is necessary to evaluate its unique structure and biochemical properties.<sup>1</sup>

## Line of Defense

Lutein belongs to the carotenoid class known as xanthophylls; this class of carotenoid differs in structure from the carotene class. Unlike the carotenes, lutein possesses additional

hydroxyl groups, allowing it to be a more polar and hydrophilic structure. As such, it can react with oxygen more readily, facilitating its antioxidant function—an integral part in maintenance of ocular health. Free radicals that may exist throughout the body and ocular structures contain an unpaired electron in their outer shell, making them susceptible to reacting with various molecules for stability and thus causing damage to these structures. Lutein interferes with this process by binding with free radicals which in turn eliminates their potential to bind to other structures.<sup>1,2</sup>

Lutein also contains a particular liposomal cell membrane and is located in the highest density within the outer

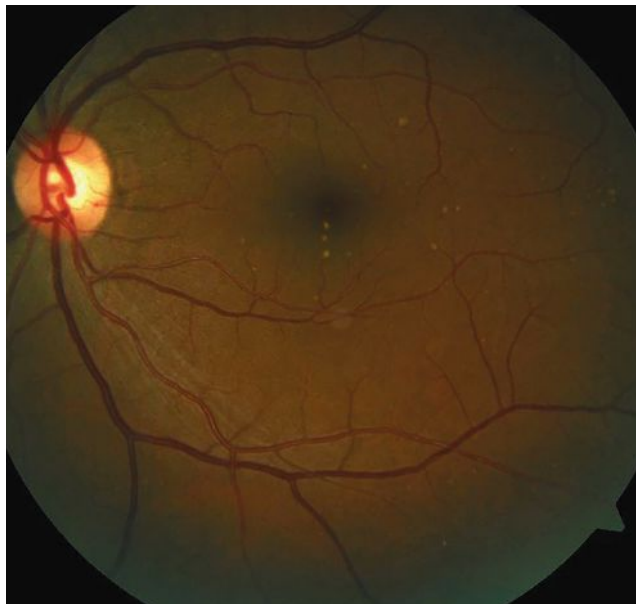plexiform layer of the fovea. In addition to the macula, studies have found the presence of lutein in the crystalline lens. Because of these characteristics, lutein is the most effective blue-light blocker when compared with other carotenoids. This is of particular interest in the present day, as prolonged screen use from computers and phones has significantly increased individuals' exposure to blue light.

The effects of blue light on the eye are well documented and are known to increase the presence of free radicals, leading to macular damage and lens opacification. The peak wavelength of absorption of lutein is 460nm; this is within the range of blue light wavelengths. Subsequently, lutein has the potential to absorb 40% to 90% of these harmful rays, protecting the photoreceptors from their deleterious effects. As they reside in the lens as well, their protective properties extend there, too.<sup>3</sup>

## Additional Benefits

In addition to these protective effects, studies have indicated that lutein also possesses anti-inflammatory properties against the agents of cyclooxygenase-2, inducible nitric oxide synthase and nuclear factor-kappa B. This is owed to lutein's ability to prevent oxygen-induced cytokine formation as well as to upregulate inflammatory gene expression. Moreover, lutein has been able to reduce VEGF expression by reducing the inflammatory effects of ischemic disease.<sup>4</sup>

Finally, lutein has been shown to impact cellular apoptosis and increase glial cell function. Due to this observation, there is a suggestive potential for neuroprotective benefits derived from



**Patient with dry age-related macular degeneration, one of the conditions lutein supplementation can benefit.**

About  
Dr. Labib

**Dr. Labib** graduated from Pennsylvania College of Optometry, where she now works as an associate professor. She completed her residency in primary care/ocular disease and is a fellow of the American Academy of Optometry and a diplomate in the Comprehensive Eye Care section. She has no financial interests to disclose.



**TABLE 1. LUTEIN'S DEFINING CHARACTERISTICS**

Property	Function
Presence of additional hydroxyl group	Reacts with oxygen as free radical scavenger
Peak wavelength of absorption is 460nm	Natural blue-light blocker
Prevent oxygen-induced cytokine formation	Anti-inflammatory and anti-VEGF effects
Increase glial cell function and cellular communication	Neuroprotection

lutein. Additional evidence supports lutein's role in improving visual and contrast acuities.<sup>4</sup>

### Delivery Methods

Since the beneficial effects of lutein are many, it is paramount in maintaining ocular health. To procure it, though, it is necessarily acquired through external sources, as lutein is not synthesized by humans. Foods high in lutein include a wide variety of vegetables, grains, nuts and other sources. Leafy green vegetables, particularly kale, are excel-

lent sources. Additionally, pistachios, certain types of wheat and egg yolk also contain lutein.

Once lutein is ingested, it is absorbed via lipid droplets into the bloodstream for transport. Dietary fat allows for better absorption of carotenoids; this is due to lutein's hydrophobic structure. In fact, it has been suggested that because lutein is distributed into adipose tissue, there is an inverse correlation between lutein levels and obese patients, increasing their susceptibility for ocular diseases.<sup>5</sup>

For clinicians, understanding the structure and biochemical properties of lutein gives us a clearer picture of the many benefits it poses—and the hazards that arise from deficiencies. We already know that lutein plays an integral role in treatment and management of age-related macular degeneration, but it can potentially benefit many other ocular conditions as well, such as diabetic retinopathy, retinopathy of prematurity, myopia and cataract. Further studies are ongoing and will likely impact future treatments.<sup>6</sup> ■

1. Maoka T. Carotenoids as natural functional pigments. *J Nat Med.* 2020;74(1):1-16.

2. Li LH, Lee JCY, Leung HH, et al. Lutein supplementation for eye diseases. *Nutrients.* 2020;12(6):1721.

3. Junghans A, Sies H, Stahl W. Macular pigments lutein and zeaxanthin as blue light filters studied in liposomes. *Arch Biochem Biophys.* 2001;391(2):160-4.

4. Li SY, Fu ZJ, Lo ACY. Hypoxia-induced oxidative stress in ischemic retinopathy. *Oxid Med Cell Longev.* 2012;2012:426769.

5. Perry A, Rasmussen H, Johnson EJ. Xanthophyll (lutein, zeaxanthin) content in fruits, vegetables and corn and egg products. *J Food Compos Anal.* 2009;22(1):9-15.

6. Nian S, Lo ACY. Protecting the Aging Retina. In: *Neuroprotection.* IntechOpen; London, UK: 2019.

Olleyes VisuALL brings you unparalleled office efficiency, cutting edge testing technology, and the new era of patient comfort, in just one device.

### 3 essential elements that place you at the cutting edge.



#### Dynamic Matrix

Our proprietary eye tracking algorithm can reduce fixation losses to zero, automatically.



#### Scientific Validation

Reliable, accurate results validated by esteemed scientific institutions.



#### AI Virtual Assistant

Annie can increase office efficiency, monitor patients, speak over 35+ languages and so much more.



Pupillometry



Extraocular Motility



Visual Acuity



Visual Field



Color Vision



Contrast Sensitivity



Equip your practice with a game-changing technology today.

Scan code to know more or visit [www.olleyes.com](http://www.olleyes.com)

**olleyes**  
watch this





EDITED BY PAUL C. AJAMIAN, OD

## CLINICAL QUANDARIES

# Down the Tubes

*Tube shunt erosion can be rare, but it is a serious complication for glaucoma patients.*

**Q** A glaucoma patient called the office stating that she rubbed her eye and a “piece of plastic came out.” What is going on?

**A** “Advanced glaucoma patients can be a challenge from a treatment standpoint,” says Justin Schweitzer, OD, of Vance Thompson Vision in Sioux Falls, SD. “Like this case, these patients have had glaucoma for a long time. They have maxed out on medications, had multiple selective laser trabeculoplasties, stents, goniotomies and, still, they continue to progress.”

Enter our more advanced glaucoma surgeries, tube shunts and trabeculectomies. These procedures are great from an efficacy standpoint but carry a higher complication profile than other glaucoma treatment options. The Tube vs. Trabeculectomy Study Group revealed that 39% of patients in the tube group and 60% of patients in the trabeculectomy group had postoperative complications.<sup>1</sup> These include diplopia, iritis, hypotony, infection, bleb leaks and exposures. In this study, tube erosion occurred in 5% of patients in the tube shunt group.<sup>1</sup> In another study, exposure of the tube and/or plate is estimated to occur in approximately 2.5% to 8.9% of cases.<sup>2</sup> Exposure is one of the most serious complications due to the risk of vision-threatening endophthalmitis.

“It is important to first recognize the cause of the tube exposure to communicate with the glaucoma surgeon and to decide on management,” Dr. Schweitzer says. Early postoperative

tube exposure is likely caused by a dehiscence of the sutures securing the conjunctiva/materials overlying the device.

“Our patient was seven weeks post-surgery, meaning that a combination of etiologies could be in play that led to the total expulsion of the shunt,” Dr. Schweitzer notes. “Eye rubbing, micro-movements due to blinking or ocular movements, or incomplete healing can lead to an erosion of the overlying conjunctiva or the patch graft over the plate.”

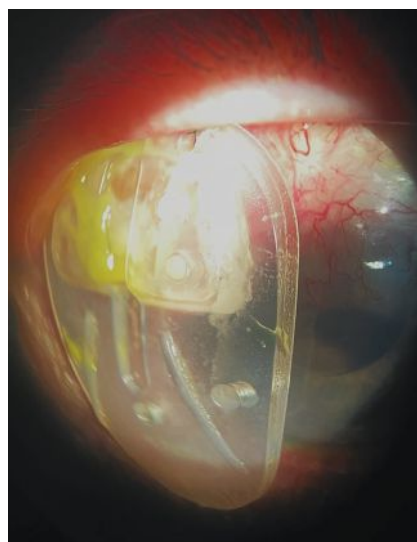
## Management

The level of exposure will dictate whether immediate repair needs to occur or if medical management can be attempted. Erosions can be small (millimeter), large (3mm to 5mm) or, like

this patient, a complete exposure. She had a true emergent complication that needed immediate repair. In the clinic, initiate a topical antibiotic every one hour to reduce the risk of endophthalmitis. Dr. Schweitzer recommends closing the eyelid with a taped tarsorrhaphy will hopefully prevent further movement of the tube shunt until the patient can see the glaucoma surgeon.

Even with immediate repair, a study has shown that 45% of repaired exposed tubes required a second operation, and 13% eventually needed the tube removed.<sup>3</sup> In certain situations, if the tube is only partially exposed or a small conjunctival defect exists over the plate, medical management can be considered, which includes antibiotic ointment prescribed two times per day, a topical antibiotic three to six times a day and a trial of doxycycline tablets 50mg to 100mg twice per day (to assist in healing). If the examination results are the same after one to two weeks of medical management, a referral for repair or removal will be needed.

As the primary provider of glaucoma care for many patients, optometrists play a critical role in the postoperative management of these surgeries. “Advanced glaucoma patients with glaucoma drainage devices are in many of our clinics, and these devices can have early or late complications, including tube erosions,” Dr. Schweitzer says. “Many of these patients will do well if the erosion is recognized early and repaired.” ■



**Ahmed valve after it was expelled from the eye seven weeks post-op.**

1. Gedde SJ, Schiffman JC, Feuer WJ, Herndon LW, Brandt JD, Budenz DL. Treatment outcomes in the Tube vs. Trabeculectomy (TVT) study after five years of follow-up. *Am J Ophthalmol.* 2012;153(5):789-803.

2. Wishart PK, Choudhary A, Wong D. Ahmed glaucoma valves in refractory glaucoma: a seven-year audit. *Br J Ophthalmol.* 2010;94(9):1174-9.

3. Huddleston SM, Feldman RM, Budenz DL, et al. Aqueous shunt exposure: a retrospective review of repair outcome. *J Glaucoma.* 2013;22(6):433-8.

About  
Dr. Ajamian

Dr. Ajamian is board certified by the American Board of Optometry and serves as Center Director of Omni Eye Services of Atlanta. He is vice president of the Georgia State Board of Optometry and general CE chairman of SECO International. He has no financial interests to disclose.

# A WIDER VIEW OF THE RETINA ADVANCES CARE

The decision to upgrade retinal imaging technology is giving one eyecare provider more opportunity to uncover pathology



By: Peter E. Wilcox, OD

**H**aving been in practice for over three decades, I have continually invested in the latest technologies that yield the most accurate findings to improve patient care. My busy practice in Hayes, VA, demands that I have the tools needed to perform detailed studies of the fundus so I can confidently document subtle changes over time.

In 2016, I invested in the iCare EIDON AF confocal fundus imaging system, our practice's fifth evolution of a fundus imaging system. I made the investment because the system produced phenomenal clarity and delivered a wide field of view of the retina, including through pupils as small as 2.5 mm.

In addition to offering superior image quality and capturing an unsurpassed level of detail, the system's confocal imaging technology reduces scattered and reflected light outside the focal plane; and deftly captures ERM, drusen, dot-blot hemes, etc. through cataract and media opacities.

The resulting image findings, paired with "flicker" functionality, allows a side-by-side image comparison over time. This enables me to successfully monitor patient ocular health and track progression of disease, which is especially critical in challenging cases.

## CASE #1: HOLLENHORST PLAQUE

FIGURE 1

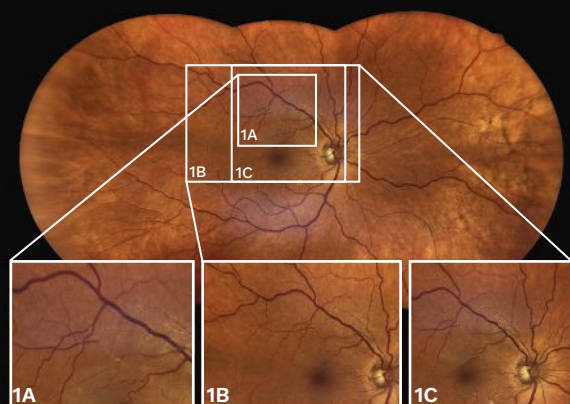
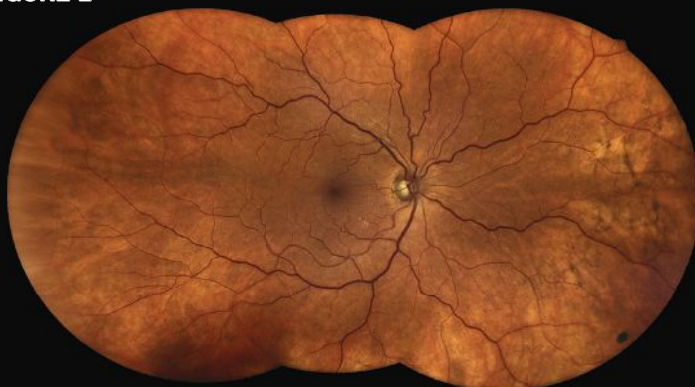

FIGURE 2



**A** 71-year old female patient fell in a parking lot, striking the right side of her head near her brow. Three days later she developed a visual field loss just below fixation. On day five the patient presented to her PCP, who referred her to me. I accepted her on a same-day basis. The patient has used anticoagulants for many years for a longstanding cardiac condition and has had stents implanted due to cardiac events.

My staff performed the workup, dilated the patient, and took the first image using the iCare EIDON Ultra-Wide-field (UWF) Module at 4:35 pm. A long intra-arterial plaque and an area of "smoky" appearing retinal edema over a 2 disc diameter was documented.

**Figure 1.** The iCare EIDON UWF reveals an intra-arterial deposit, presumed a Hollenhorst (HH) plaque, seen on 12/5/23. **1A** shows pre-treatment imaging at 4:35pm. Patient received PEMF/microcurrent treatment the same day and **1B** shows same area post-treatment at 6:06pm. Post-treatment the HH plaque moved into the far retinal periphery and the retinal edema immediately improved. **1C** shows same area revealing two new small HH plaques found in other arterioles. **Figure 2.** Post-treatment imaging on 12/6/23 at 11:21am. The patient successfully regained her central vision.

**Images:** Peter E. Wilcox, OD

The iCare EIDON UWF also captured the post-plaque intra-arterial hypo-oxygenated burgundy colored blood. After my review, I confirmed the patient's infra-central visual field loss by a facial Amsler Grid test, which correlated with the retinal findings. The patient reported severe blurring of my nose and mouth when fixating on my left eye at a distance of 1m.

My staff performed microperimetry

(iCare MAIA) and R-OCTA scanning, and documented retinal edema and visual field loss. Near 5:45 pm, the patient accepted an offer to receive, in addition to the standard of care, exposure to pulsed electromagnetic fields (PEMF) and microcurrent. These energies were simultaneously delivered for 15 minutes.

Then my staff, upon my instructions, took a central-only photo of the patient's OD to check for any visible delta.

I truly expected nothing. At 6:06 pm, a post-treatment image was taken and reviewed, revealing an intra-arterial deposit (presumed a Hollenhorst [HH] plaque) had moved into the far retinal periphery. Two new small classic HH plaques were found in other arterioles, the once-burgundy-colored arteriolar

blood was turning more pink (oxygenated), and the retinal edema was immediately improving. When the patient covered her OS, she noted a 50% improvement of her visual field defect, with increased resolution 10 minutes later. One day later, the patient had successfully regained her central vision.

Physiological improvements in the patient's retinal vasculature and near immediate recovery of her loss of vision are the presumed result of iatrogenic vasodilation due to energy imparted from the alternative treatment. The patient scheduled a return visit for additional evaluation and treatment.

In 2023, I took my practice capabilities to the next level when I acquired the iCare EIDON Ultra-Widefield (UWF) Module by taking advantage of a great trade-in program from iCare. The system produces lattice-to-lattice-width images and crystal-clear resolution enabling me to see the barely detectable changes occurring. This means I am better equipped to accurately diagnose and manage ocular health and disease.

The decision to upgrade to the iCare EIDON UWF was easy. Why wouldn't a caring and careful practitioner want

tens of degrees more fundus imaging capability without sacrificing any of the image quality delivered with previous iCare EIDON iterations? The ability to illuminate early signs of ocular pathology (up to 200° panoramic view) means I can provide better care for patients and medically follow more conditions while maintaining a comprehensive patient record. And from my experience, competing "ultra-widefield" systems I have encountered seem to sacrifice local and global image quality in order to capture a wider field of view.

## CASE #2: VITREOUS HEMORRHAGE

FIGURE 1

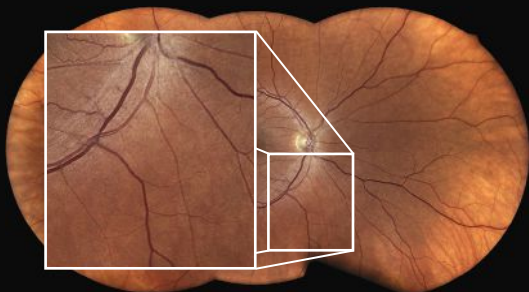


FIGURE 2

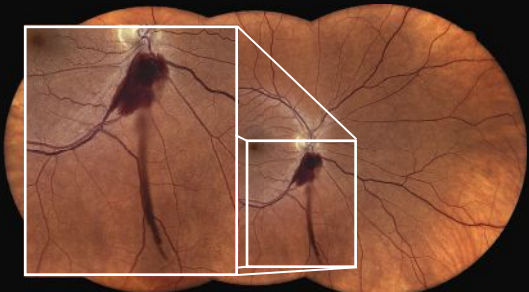
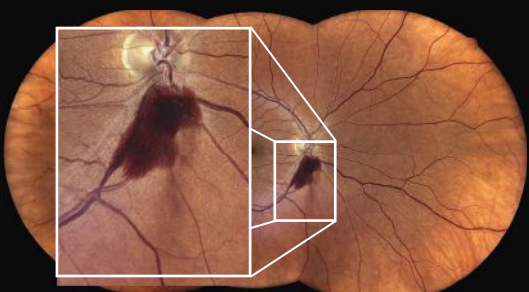


FIGURE 3



**Figure 1.** This individual was seen for a contact lens exam. We noted changes in the retinal vascular appearance OD when imaged with the iCare EIDON UWF. **Figure 2.** Six months later vitreous and retinal hemorrhages as well as vitreous degeneration was imaged in the OD. **Figure 3.** Follow-up two days later imaging confirmed what patient reported - a substantial improvement in the floater OD.

**A** 58-year-old male patient presented to our practice on June 23, 2023, for a contact lens exam. His presenting systemic medications included diclofenac 1% topical gel and atorvastatin 10 mg tablets. During his appointment we noted changes in his retinal vascular appearance OU and we diagnosed him with hypermetropia. We continued to monitor the patient.

He presented to the practice on January 2, noting a black spot OD that first appeared days earlier that now appeared to have "jellyfish tentacles" attached to it. The patient said the spot was not in his line of sight and reported no associated pain.

Upon imaging the patient with the iCare EIDON UWF, we noted in the right eye vitreous and retinal hemorrhages, and vitreous degeneration.

We diagnosed the patient with acute vitreous heme due to a posterior vitreous detachment (PVD), no hypertension, and our plan was to re-image the patient in two days and continue monitoring.

On two-day follow-up, the patient noted a substantial improvement in the visually disturbing floater OD.

Given the subtle resolution of the acute vitreous heme, our plan is to re-image the patient in a month and initiate Ocufolin 3q AM PO. Ocufolin is a medical supplement formulated to increase retinal blood flow.

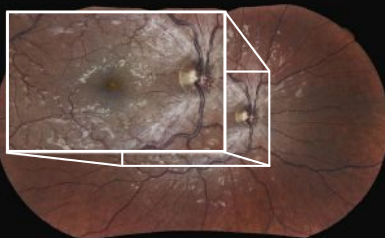

## EXPANDING CARE

The iCare EIDON AF and now EIDON UWF have increased my practice's ability to manage more retinal conditions. Though patients with symptomatic flashes and floaters still get a dilated BIO evaluation, I have found the associated iCare EIDON UWF findings better document potential retinal tears, holes, and detachments. The system can capture arterial fields to the 8th and 9th bifurcations.

### CASE #3: GLAUCOMA WITH RVO

FIGURE 1



1A

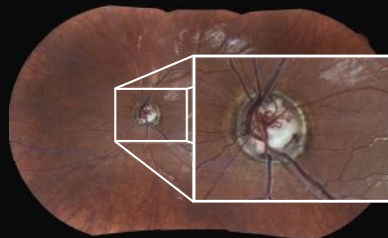
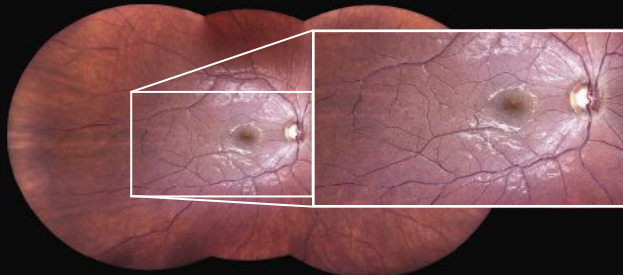
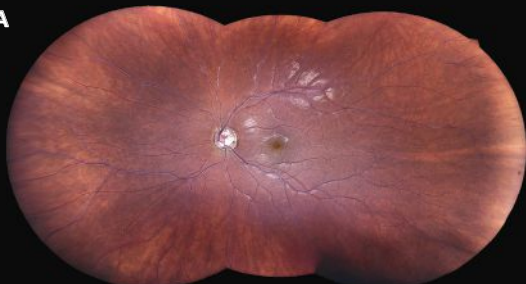


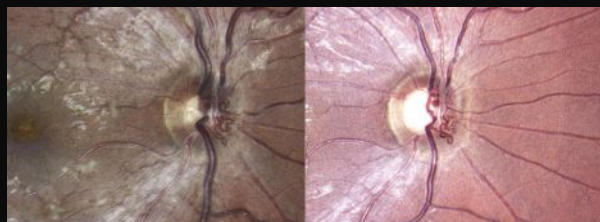FIGURE 2



2A



2B



**Figure 1, 1A.** This patient presented with bilateral optic nerve collaterals (signs of old RVOs and chronic optic disc ischemia), minimal cupping OD, significant cupping OS, and active retinal venous stasis OD. **Figure 2, 2A.** February 2023 office visit retinal imaging of OD and OS respectively. **2B** shows the nearly threefold increase in cupping between March 2022 and February 2024. The change is even more remarkable when viewed using the iCare EIDON flicker feature.

A 30-year-old male patient initially presented to our office in March 2022 with significant bilateral retinal

vein occlusions (RVOs), also receiving Eylea injections OD for severe active venous stasis and petechial hemor-

## MY OTHER ICARE TECHNOLOGIES

In addition to the iCare EIDON AF blue autofluorescence confocal fundus imaging system and iCare EIDON Ultra-Widefield, I've added several other iCare technologies that have improved clinical efficiency and patient experience.

- The **iCare rebound tonometer** is quick, easy to use, and produces confident readings without mobility restrictions. New technicians can become competent in using the device with little training.
- **iCare HOME2** offers a solution to the glaucoma patient who needs or desires to have more IOP readings over time or throughout the day. Our office also rents the iCare HOME2 tonometer for newly diagnosed patients and those with advanced disease so we can obtain around-the-clock readings in order to make the best management and treatment decisions.
- I purchased the **iCare MAIA** in conjunction with the iCare EIDON AF blue autofluorescence confocal fundus imaging system so I could best manage macular degeneration and diabetic retinopathy, which are associated with a significant degree of vision loss. I research and provide alternative procedures for those interested in preserving or regaining vision, including photobiomodulation, pulsed electromagnetic fields, and microcurrent, necessitating that I provide evidence that these treatments are effective. The iCare MAIA documents improvements in functional vision that helps build my patients' trust in my recommendations and in continuing with my prescribed alternative and standard-of-care protocols. Another benefit is the iCare MAIA operates very similarly to the iCare COMPASS with active retinal tracking during the visual field exam.

rhaging. He had minimal cupping OD, significant cupping OS and post-RVO collaterals OU. The patient was co-managed by his PCP and cardiologist for sarcoidosis and atrial fibrillation, and was taking the calcium channel blocker diltiazem. The patient was seen at our office 7 times between March and October 2022.

At the last visit, his IOPs were recorded over 30mmHg range so the patient was referred to a glaucoma specialist for a trabeculectomy.

The patient didn't return to our practice until February 2024, when our iCare EIDON Ultra-Widefield documented significant differences in the OD from 2022.

The patient's OD vascular disease and physiology was much improved although his cupping OD had nearly tripled. The patient's casual eyedrop compliance immediately improved when he was shown the obvious loss of his optic nerve tissue over time using the iCare EIDON flicker feature.

As well, the "flicker" function creates a 'wow' factor for me and my patients when they see firsthand what is occurring in their structural anatomy. The flicker function is included on all iCare EIDON systems and uniquely registers two images in order to show the smallest of changes in the retina. As a doctor with a medically based practice, this capability helps me more confidently make assessment of patients as "better, worse or about the same." And it has increased patient compliance with my management decisions.

With the help of the iCare EIDON UWF, the following are examples of pathologies I now follow:

**Macular conditions:** AMD, GA, various drusen types, ede-

ma, DR, ERM, and macular holes.

**Other retinal conditions:** Hypertensive retinopathy, various vascular diseases, Hollenhorst plaques.

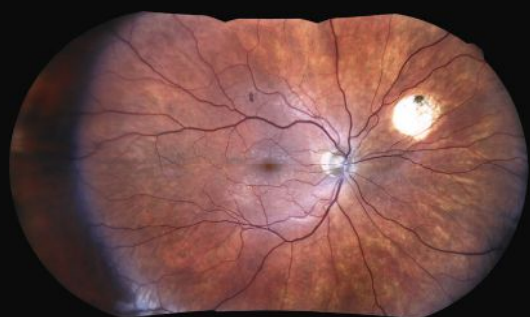**Optic nerve conditions:** Glaucoma, papilledema, and OA.

**Peripheral retinal conditions:** Lattice, holes, WWOP, tears and detachments, and choroidal nevi.

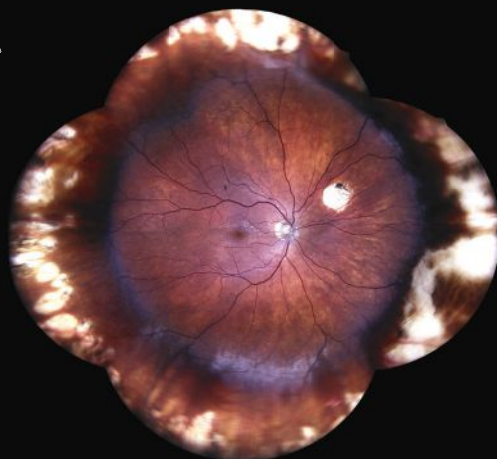
Every day I have patient cases that I can positively impact with the detailed images and findings I get from my iCare EIDON AF and EIDON UWF systems. I have detected glaucoma progression with brilliant images revealing cupping, and phenomenal images of Hollenhorst plaque and retinal edema that have enabled me to rapidly start therapy and help arrest disease progress.

## CASE #4: TOTAL RETINAL DETACHMENT

FIGURE 1



1A



**Figure 1.** The iCare EIDON captured the patient's OD images at his visit in 2021. The 160° image documents a flat posterior pole, a C/D ratio of 0.7/0.7, a pink disc, subtle peri-macular ILM reflections, vessels within normal limits, a stable retinotomy for subretinal fluid management adequately sealed by chorioretinal scarring, and an intact leading edge of the post-surgical buckle. Two years later, **1A** shows the patient's OD. The 200° image captured by the iCare EIDON UWF enabled me to capture additional clinical documentation and built my confidence in my ability to see a 360° elevated dry buckle with adequate cryopexy scarring.

**T**his male patient presented to our office in June 2017 with a total retinal detachment OD, four days after noticing symptoms. A year earlier, in 2016, the patient had suffered a total rhegmatogenous retinal detachment and underwent subsequent surgical repair.

At the patient's visit to our office in March 2021, the iCare EIDON captured vivid images. Two years later, the iCare EIDON Ultra-Widefield (UWF) Module captured an even greater field of view with enhanced mosaic features. This provided better documentation, patient education, and confident communication with the patient's PCP and retinal surgeon, building tremendous practice loyalty from the patient.

A Medscape **LIVE!** CONFERENCEReview of Optometry®  
presents a collaboration betweenNEW  
TECHNOLOGIES  
& TREATMENTS IN

EYE CARE



Intrepid

**MAY 17–19, 2024**

OMNI LA COSTA | CARLSBAD, CALIFORNIA

IN-PERSON **CHAIRS**

**Paul M. Karpecki, OD, FAAO**  
 Director of Cornea and External Disease  
 Kentucky Eye Institute  
 Lexington, Kentucky  
 Associate Professor  
 University of Pikeville Kentucky  
 College of Optometry  
 Pikeville, Kentucky  
 Director, Cornea and External Disease  
 Center for Sight  
 Carmel, Indiana



**Selina McGee, OD, FAAO, Dipl ABO**  
 Owner/CEO BeSpoke Vision  
 President  
 Intrepid Eye Society  
 Edmond, Oklahoma

**REGISTRATION OPEN!**

For more information and to register, visit:  
[www.reviewedu.com/ntt-ies](http://www.reviewedu.com/ntt-ies)

*Save These  
Dates!*Medscape **LIVE!** PRESENTS**2024 CE CONFERENCES**

Join MedscapeLIVE! and Review Education Group at an upcoming conference.  
 Join renowned faculty as they discuss important topics in eye care to keep your  
 practice ahead of the curve. Locations to be determined.

LIVE COPE\*

Review of Optometry®

presents a collaboration between



Intrepid

WEST COAST  
OPTOMETRIC GLAUCOMA  
SYMPOSIUM

THE OPTOMETRIC RETINA SOCIETY AND REVIEW EDUCATION GROUP PRESENT

**RETINAUPDATE2024****November 15–17, 2024****December 6–7, 2024****December 7–8, 2024**

To see information as it becomes available,  
 scan the code or visit: [www.reviewedu.com/events](http://www.reviewedu.com/events)



Follow us on social media!

Search: Review Education Group

Postgraduate Institute  
for Medicine

\*Accreditation pending

**REVIEW**  
Education GROUP





BY JEROME SHERMAN, OD, AND SHERRY BASS, OD

**YOU BE THE JUDGE**

# Bad History, Bad Patient, Bad Bug

*A misdiagnosis can cause a vision-threatening complication exacerbated by a noncompliant patient.*

**A** 14-year-old girl presented with a complaint of a painful left eye of one day's duration. The doctor wrote "CL" in the history but nothing about the patient's past activity the days preceding the pain, the degree of her pain or her contact lens hygiene. The patient's mother filled out the history form and did not check off that she wore contact lenses. She did check off two boxes of the reason for visiting: "eyes itch" and "eyes water." There was no box for "eye pain." There was no mention of red eye. Other health history included an ear infection for which the patient was taking an antibiotic. There was no indication in the history of how long the patient had the ear infection, what antibiotic was prescribed and how long she was taking it.

## Clinical Findings

Entering unaided visual acuities were 20/200 OD and 20/400 OS. Pinhole visual acuities were not measured, nor was best-corrected visual acuity (BCVA) measured through a spectacle lens. Anterior segment examination was normal OD. Examination OS revealed grade 2+ conjunctival hyperemia, a central small corneal abrasion that exhibited "+ staining" with fluorescein dye, a deep and quiet anterior chamber and clear lens. The picture the

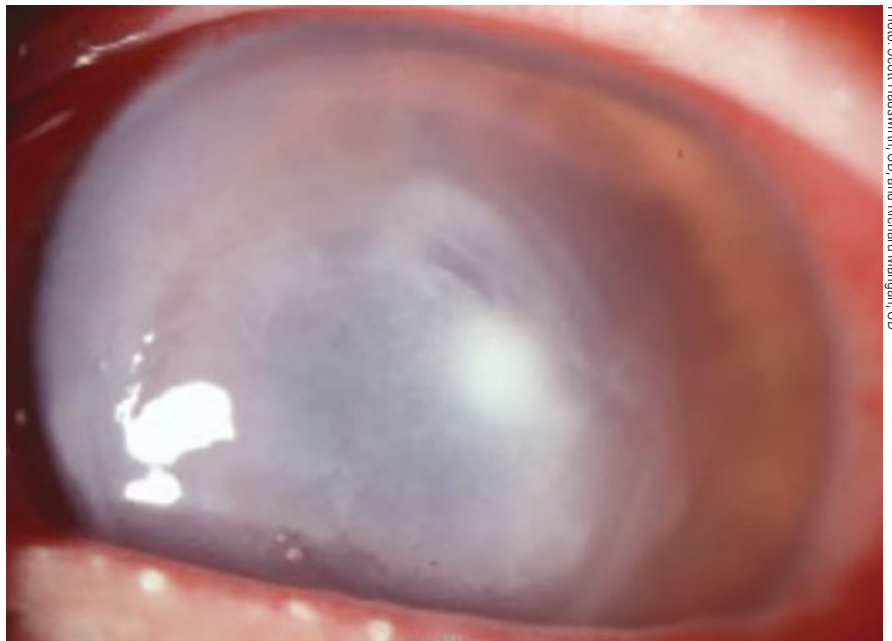
practitioner drew in the record had the central corneal opacity be about 1mm to 2mm in size, but the practitioner did not measure it.

## Diagnosis and Follow-Up

The patient was diagnosed with a corneal abrasion and was prescribed erythromycin ointment BID OS. She was also told to "patch as needed" and to discontinue contact lens wear. The patient was told to return the next day.

Her pain worsened, and she went to an emergency room in the middle of the night. She was seen by an emergency room physician. The diagnosis and antibiotic remained unchanged, and the patient was prescribed Voltaren (diclofenac, GlaxoSmithKline) for the eye pain. That next morning, she returned to the doctor's office and was seen by a second doctor. At this visit, the patient complained of increasing pain, photophobia and tearing. The cornea was now noted for a large 6mm central corneal infiltrate with surrounding haze and 3+ conjunctival injection. The patient was immediately referred to be seen by a cornea specialist the same day.

The cornea specialist obtained a history of "red eye left eye for three days—went to ER, given diclofenac one drop Q6h and erythromycin ung once a day, patient wears contact lenses



**Fig. 1. Pseudomonal ulcer in another patient. Untreated infection causes a gray necrosis that can destroy a cornea in 24 hours.**

Photo: Scott Hauswirth, OD, and Richard Mangano, OD

About Drs.  
Sherman  
and Bass

**Dr. Sherman** is a Distinguished Teaching Professor at the SUNY State College of Optometry and editor-in-chief of *Retina Revealed* at [www.retinarevealed.com](http://www.retinarevealed.com). During his 53 years at SUNY, Dr. Sherman has published about 750 various manuscripts. He has also served as an expert witness in 400 malpractice cases, approximately equally split between plaintiff and defendant. Dr. Sherman has received support for *Retina Revealed* from Carl Zeiss Meditec, MacuHealth and Konan. **Dr. Bass** is a Distinguished Teaching Professor at the SUNY College of Optometry and is an attending in the Retina Clinic of the University Eye Center. She has served as an expert witness in a significant number of malpractice cases, the majority in support of the defendant. She serves as a consultant for ProQR Therapeutics.

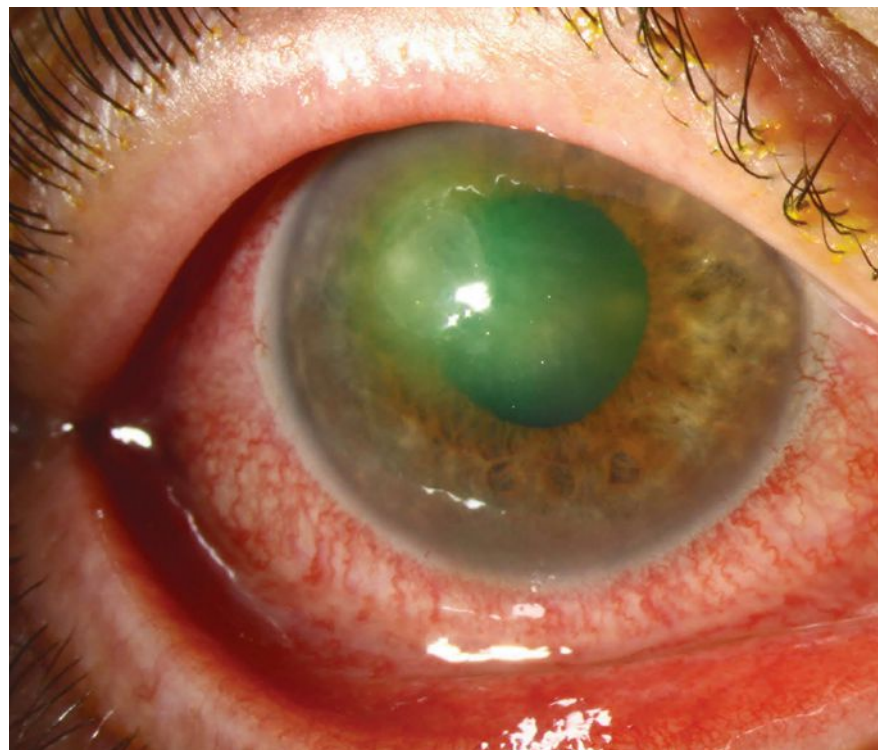daily, occasionally sleeps in them” and a history of the ear infection treated with neomycin ear drops, two drops a day, left ear and amoxicillin 875mg PO.” Pinhole visual acuities were 20/40 OD and 20/400 OS. Cornea examination was noted for a 7mm x 6mm large ring ulcer surrounding the pupil with 2+ cells and flare in the anterior chamber (Figure 1).

The cornea specialist performed a corneal scraping for a diagnostic smear. The patient was started on homatropine 5% BID OS, chlorhexidine 0.02% QID OS, polyhexamethylene biguanide (PHMB), an anti-*Acanthamoeba* medication, 0.02% QID OS, vancomycin 50mg/cc every hour while awake and tobramycin ointment at bedtime. The patient returned the next day feeling much better, reporting no pain and only slight sensitivity to light. The patient’s father forgot to bring in her drops and didn’t know when they were last administered. Examination revealed a 30% enlargement of the infiltrate with 2+ cells/flare and now a 0.5mm hypopyon. Due to the imminent threat of corneal perforation, the patient was referred to an eye hospital for an emergency corneal transplant. Multiple drops of Besivance (besifloxacin, Basuch + Lomb) and gentamicin eye drops were instilled every five minutes in-office, and the patient was told to continue this regimen until she got to the eye hospital.

The patient’s family sought a second opinion from a children’s hospital the same day. On that visit, the history revealed the fact that she had been swimming in the ocean while wearing her contacts. It also included notes about her lens hygiene and wearing schedule. She said that she never slept in her lenses (which differed from what she told the cornea specialist) and that she cleaned them daily with Optifree solution. She also claimed that she changed her lenses at



**Contact lens patients must be warned not to wear their contact lenses while swimming or in the shower. This can easily be accomplished by providing a handout on care and handling.**



**Fig. 2. Early pseudomonal ulcer in another patient. Note the extensive hyperemia and near central location.**

the appropriate times. At this visit, the patient was diagnosed with a contact lens associated corneal ulcer, which was cultured at bedside. The patient was admitted to the hospital due to the intensive treatment regimen. For the first hour, she was treated with fortified vancomycin and PHMB one drop each five minutes apart for the first hour and then chlorhexidine and tobramycin one

drop every five minutes for the second hour, then each drop q1h and homatropine BID. A corneal transplant was not recommended. Four days later, the culture came back positive for *Pseudomonas aeruginosa*. Over

the next several weeks, the medications were tapered. Two months later, the patient was left with a central corneal scar in the left eye and corrected to 20/70 VA.

## Malpractice Allegation

The first and second eyecare practitioners and the cornea specialist who initially examined the patient were sued for failure to properly diagnose and treat the corneal ulcer that led to vision loss in her left eye. The emergency room doctor and hospital were not named in the suit because there was no eyecare specialist in the ER that night and the patient was seen by a general physician who treated her for pain.

## You Be the Judge

In light of the facts presented thus far, consider the following questions:

- Did the first practitioner get enough information in the history and examination to differentiate an abrasion from a central corneal infiltrate/ulcer?
- Was the first practitioner correct in diagnosing a corneal abrasion since the opacity was so small?
- Did the first practitioner consider the grade 2+ conjunctival hyperemia when he diagnosed an abrasion?
- Did the first practitioner deviate from the standard of care in the history,

examination and treatment of the patient?

- Did the second practitioner deviate from the standard of care by referring the patient to a cornea specialist?
- Did the cornea specialist deviate from the standard of care by not adequately treating the patient and then recommending a corneal transplant?

## Our Opinion

One of us (SB) opines that, based on the history, that this patient rubbed her eyes after swimming in the ocean, and perhaps sand may have embedded under her contact lens and caused an epithelial break. Although *Pseudomonas aeruginosa* is most common in freshwater and soil, it has been demonstrated to be found in marine habitats.<sup>1</sup> Patients who present as such, especially contact lens wearers, must be treated with a strong antibiotic before the organism has a chance to invade a cornea that has an epithelial break.

The first practitioner who examined this patient noted a small abrasion but did not obtain (or record) a history of what the patient was doing that day or the day before. In addition, the BCVA was never determined. A large decrease in the affected eye might have been a red flag for an ulcer, not an abrasion.

The patient should have been asked about the level of pain in her left eye. A more painful eye makes a corneal ulcer more suspect. The first eyecare practitioner did not specify any details about the staining of the lesion. In early ulcers, the dye will seep into the stroma as opposed to remaining on the corneal surface. In suspicious cases like this, the practitioner should have waited a few minutes to see if the dye infiltrated into the stroma. In addition, corneal ulcers are associated with significant conjunctival hyperemia, present in this patient. The patient should have been instructed about what to do if the pain increased over the next few hours instead of being told to just return the next day.

Since the pain increased enough to drive the patient into an emergency room in the middle of the night, the

## Red Flags to Differentiate Small Corneal Abrasions from Early Bacterial Keratitis

- Contact lens wear
- Poor contact lens hygiene
- History of swimming with contact lenses
- Intensity of pain in the presence of a small epithelial defect
- Degree of hyperemia in relation to the size of the epithelial defect
- Infiltration of fluorescein dye into the stroma
- Central location of the defect
- Decrease in BCVA not proportional to the size of the epithelial defect

ulcer and the pain obviously increased significantly. It was likely the size of the ulcer in *Figure 2* in another patient. *Pseudomonas* ulcers can be devastating and can destroy a cornea in less than 24 hours.<sup>2</sup>

The eyecare practitioner also told the patient to “patch as needed.” Patching an abraded cornea in a contact lens patient is contraindicated since bacterial ulcers are more common in contact lens patients, and bacteria can more easily invade an abraded epithelium when patched. Additionally, the antibiotic prescribed (erythromycin ointment) was not strong enough to kill the invading *Pseudomonas*—erythromycin is bacteriostatic, not bactericidal. A bacteriostatic drug controls bacterial growth but does not kill off all the bacteria. If an ulcer is suspected, the patient should have been treated with a bactericidal antibiotic, like a fluoroquinolone—and aggressively. The patching (if the patient did patch) would have only made matters worse. The patient also reported an ear infection one day after swimming. *Pseudomonas* is a known cause of “swimmer’s ear.”<sup>3</sup>

The second eyecare practitioner, who referred the patient immediately to a cornea specialist, was sued but was not culpable since there was a timely referral. The cornea specialist who treated the patient appropriately was sued because the patient got worse under their care. But the patient and her parents were apparently noncompliant with the drops and were unsure if all the drops were being used. Bad patient behavior unfortunately may or may not support

a malpractice defense, based on the specific circumstances.

## Takeaways

This case highlights the importance of obtaining a thorough history, especially if the patient is a contact lens wearer. It also demonstrates the reason why contact lens patients must be warned not to wear their contact lenses while swimming or in the shower. This can easily be accomplished by providing a handout specifying how to care for and when not to wear contact lenses. This patient was fit for contact lenses in the practice where she first presented. There is no evidence in the records that the patient was ever provided with such a handout or that the patient was verbally told not to wear contact lenses while swimming and showering.

Corneal ulcers are not as common as corneal abrasions. However, there are specific criteria that should alert the practitioner to differentiate a corneal ulcer from a corneal abrasion. Pain, BCVA and conjunctival hyperemia are certainly significant, but a good history can make a huge difference to avoid a huge mistake.

The case was settled for an undisclosed amount. ■

1. Khan NH, Ishii Y, Kimata-Kino N, et al. Isolation of *Pseudomonas aeruginosa* from open ocean and comparison with freshwater, clinical and animal isolates. *Microb Ecol*. 2007;3(2):173-8.

2. McElvanny AM. Doxycycline in the management of *Pseudomonas* corneal melting: two case reports and a review of the literature. *Eye Contact Lens*. 2003;29(4):258-61.

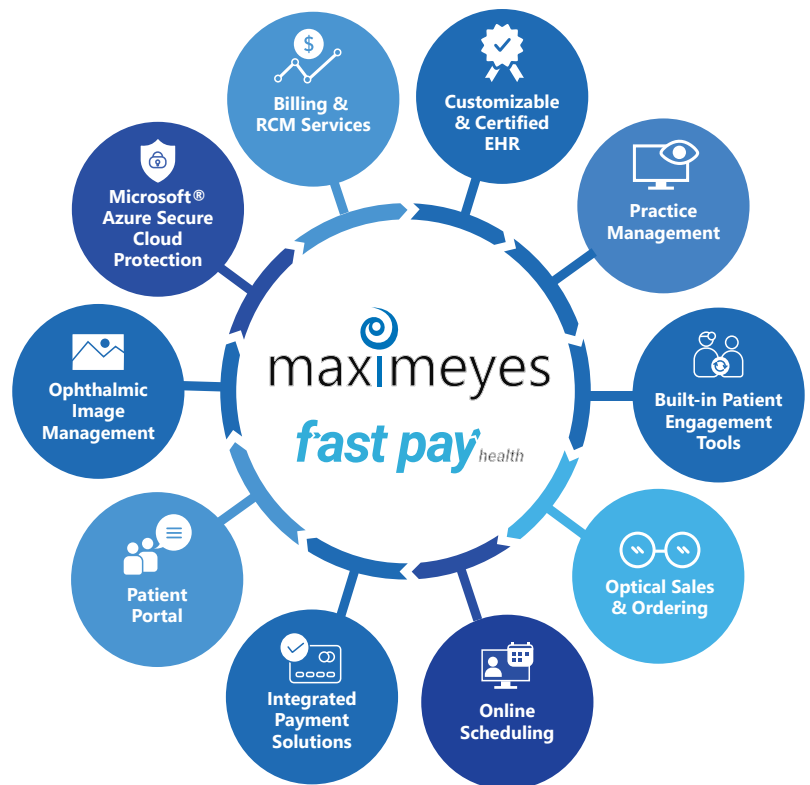3. Maclean K, Njamo FOJP, Serepa-Dlamini MH, et al. Antimicrobial susceptibility profiles among *Pseudomonas aeruginosa* isolated from professional scuba divers with otitis externa, swimming pools and the ocean at a diving operation in South Africa. *Pathogens*. 2022;11(1):91.



# Unlock the POWER of MaximEyes.com EHR/PM Software & Optometric Billing Services

See Us At Vision Expo East, Booth F2451  
Ask About Our 30<sup>th</sup> Anniversary Special

- Are you tired of clunky and poorly designed EHR and practice management software?
- Fed up with too many clicks, multiple screens and slow navigation?
- Struggling with unreliable customer support and training tools?
- Are your accounts receivable out of control? Looking to simplify billing processes and insurance claims management?



**We have the solutions!**



"Transitioning to MaximEyes.com was an excellent decision for our office: great price, support, training, and ongoing enhancements." –Rebecca Verna, OD

First Insight Corporation | [www.first-insight.com](http://www.first-insight.com) | [sales@first-insight.com](mailto:sales@first-insight.com) | 800.920.1940

# OPTOMETRIC SCOPE: BREAKING DOWN BARRIERS

Here's how ODs are challenging old boundaries—and what they can do once freed from them.

BY LEANNE SPIEGLE  
ASSOCIATE EDITOR

**T**wenty-six years ago this month, Oklahoma ODs earned the right to perform minor laser surgeries, the first such law in the nation. In time, nine other states followed with laser laws of their own—five of those within the last five years alone. At least 10 more states have laser bills active currently, setting up a contentious year for optometry as advocates and opponents vie for the favor of elected officials. Clearly, the pace of change is quickening.

Laser laws get the most attention—and, from detractors, condemnation—but optometry has been racking up wins all across the board in practice scope, be it lid lesion removal or collagen cross-linking or controlled substance prescribing. For decades, optometric advocates have been fighting legal battles to modernize the profession's practice scope, which, in many states, comprises the same language it did in the '90s. Not only have eyecare treatments and technology evolved dramatically during this time, but training and education curricula have intensified, the population has aged and the ophthalmology workforce has declined, putting optometrists in a prime position to meet the nation's growing eyecare demands and improve patient access to necessary care.

"The more well-educated and well-qualified providers there are who can provide a service—like a laser procedure, an injection or an eyelid lesion removal—the sooner patients can get the care they need, and that's the biggest reason why scope expansion is so important," says Nate Lighthizer, OD, associate dean at NSU Oklahoma College of Optometry and one of the foremost educators on advanced procedures in optometry.

Educational institutions have admirably evolved their curricula to meet current and future eyecare needs. Today's optometry students are being taught to perform minor surgical procedures, such as lesion removal, subcutaneous injection and laser procedures including selective laser trabeculoplasty (SLT), YAG capsulotomy and laser peripheral iridotomy (LPI). Trouble is, newly minted optometrists too often find their capabilities throttled by regressive optometry laws and an inhospitable or just plain clueless medical community that doesn't know how to integrate optometry into the broader healthcare system.

Scope expansion is by its very nature fragmented—rules are set at the state, not federal level—perhaps masking the extent of evolution now taking place. In the first portion of this article, we'll discuss scope expansion wins that various states have secured over the last five years, followed by a state-by-state break-

down of current legislative efforts in play. Afterwards, we'll explore which optometric privileges are on the rise and how to implement these new services into your practice once your state allows it.

## Trends and Challenges

Since 2019, more than 20 scope expansion bills have been introduced. While not all were successful, these efforts granted additional privileges to optometrists in at least 13 states, five of which passed laws that include the use of lasers.

Not every state must return to the legislature to authorize new procedures, however; one such exception is Wisconsin, where an increasing number of ODs are embracing expanded practice rights under a scope law that's been untouched since 1990, but due to its specific phrasing, ODs there are able to implement new procedures and therapeutic agents at their own discretion, thus quietly bringing the number of laser states up to 11 (*for more, see the news story on page 5*).

Here's a brief timeline of some legislative wins in optometry just since 2019:

- **South Dakota** (intense pulsed light, October 2023)
- **New Hampshire** (vaccine authority for influenza, COVID-19 and shingles, August 2023)
- **Washington** (non-laser advanced procedures, May 2023)
- **Colorado** (lasers, June 2022)

- *New Hampshire* (expanded glaucoma treatment authority to include all glaucoma types, May 2022)
- *Virginia* (lasers, March 2022)
- *California* (intense pulsed light and foreign body removal, October 2021)
- *New York* (topical/oral meds, October 2021)
- *Texas* (oral medications, June 2021)
- *Wyoming* (lasers, April 2021)
- *Mississippi* (lasers, March 2021)
- *Massachusetts* (topical/oral meds, January 2021)
- *Iowa* (non-laser advanced procedures, June 2020; in April 2023, the law was clarified to authorize anesthesia injections for lid lesion removal)
- *Arkansas* (lasers, March 2019)

At a glance, it may seem like the scope expansion wave has decelerated, given that 2023 was the first year in the last five in which no states were granted laser authority despite attempts in Alabama, South Dakota and Idaho, and following the high-profile veto of California's bill in 2022. In actuality, enthusiasm and advocacy for scope expansion is at an all-time high, with more states actively pushing for laser rights in 2024 than in any previous year.

Standing in the way of these efforts time and again are ophthalmologists and organized medicine, which consistently present to legislators the same spurious claim that optometrists are not properly trained to perform surgical procedures. Governor Newsom of California cited this reasoning when he vetoed the state's first laser bill attempt in 2022, though his letter defending his decision included inaccuracies regarding the number of years optometrists undergo training.

"This is the only argument that ophthalmology has been able to claim, and it's never come to fruition, but that's what they cling to in every scope battle that comes along," says Angelique Sawyer, OD, legislative co-chair of the New Hampshire Optometric Association, which is currently pushing to authorize lasers and advanced procedures. "We're not asking for things that are outside of our training and education, and we've proven time and time again that when the legislature grants us authority and

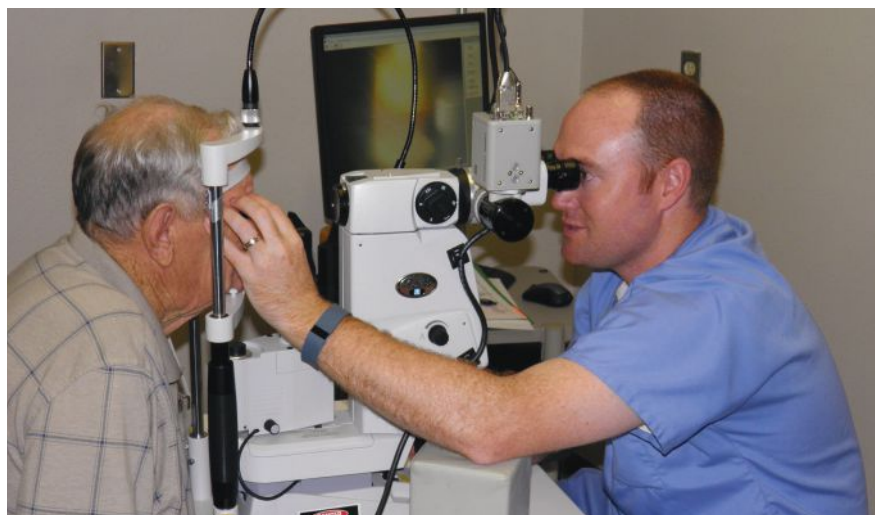

Photo: Nathan Lighthizer, OD

**Dr. Lighthizer—a leading educator on advanced optometric procedures—performing YAG capsulotomy on a patient.**

increased scope, we do it responsibly and to the benefit of our patients," she says.

Dr. Lighthizer reiterates that "optometrists have a great track record of safely performing these procedures," but adds that there will always be political opposition. "I think the reason why some states struggle is because you have to have the right people in place to pass a law," he notes. For example, scope advocates in states with legislators who are also medical doctors—such as West Virginia and California—may have a more difficult time hammering home the safety and necessity of OD-performed procedures.

As optometric scope expansion becomes embraced in more states, evidence to validate the inclusion of these procedures in optometry's skillset will continue to mount. Next, we'll discuss the status of various scope efforts in pursuit across the nation.

## The State of the States

This year is bound to be a disruptive one for scope expansion, with at least a dozen bills in pursuit literally all over the map, including in Alabama, Idaho, Nebraska, New Hampshire, New Jersey, Missouri, Ohio, South Dakota, Utah, Vermont, Washington D.C. and West Virginia. Laser bills in California and Kansas have already flamed out for 2024, but the aforementioned others remain live issues. Let's survey the status of current efforts:

**Alabama.** After getting stonewalled in 2023, Alabama ODs and advocates are prepped to pursue a second battle this year. Last year's bill, HB 249, which proposed certain laser and advanced procedures, passed the House only to be terminated weeks later by the Senate Healthcare Committee, which refused to bring it to the floor for a vote. This year, Alabama plans to introduce a similar bill, the details of which are still being hashed out at the time of this writing.

**Idaho.** Like Alabama, this state also attempted to pass a laser bill last year, but despite strong support in the Senate, the legislation was ultimately canned by the House. Idaho Optometric Physicians reports that it plans to introduce another laser bill this year but is still in negotiations with the Speaker of the House.

**Nebraska.** This state's scope bill, LB 216, currently remains in the Health and Human Services Committee, where it's been residing since last January without any movement, though the state's optometric association is optimistic that it will be voted out soon.

Nebraska's bill differs from others by proposing to add only one laser procedure to optometry's practice scope: SLT, which is growing in acceptance as a first-line option to treat glaucoma. Considering how aggressive the opposition has proven to be in other states' recent laser battles, the Nebraska Optometric Association says that focusing their efforts



## A Refresher on Controlled Substances in Eye Care

Here's a quick review of which types of drugs, substances and chemicals make up each schedule and some examples in each category, though not all will be used in eye care. (Note: There are no Schedule I drugs used in eye care, hence its exclusion from this list).

**Schedule II:** This schedule of drugs—the second-most dangerous—is characterized by agents with a high potential for abuse and the possibility of use leading to severe psychological or physical dependence. Some examples include morphine, oxycodone (OxyContin), hydrocodone (Vicodin), hydromorphone (Dilaudid) and combination products with less than 15mg of hydrocodone per dosage unit.

**Schedule III:** These drugs have a moderate to low potential for physical and psychological dependence. Some examples include products containing less than 90mg of codeine per dosage unit (Tylenol with codeine), ketamine and anabolic steroids.

**Schedule IV:** Drugs in this category have a low potential for abuse and low risk of dependence. A few examples include alprazolam (Xanax), carisoprodol (Soma), lorazepam (Ativan), midazolam (Versed), tramadol (Conzip, Ultram), pentazocine (Talwin) and zolpidem (Ambien).

**Schedule V:** Schedule V drugs have even lower potential for abuse than those in Schedule IV. Many of these are anti-anxiety medications, sleep agents, antidiarrheals or analgesics. Some examples include pregabalin (Lyrica), cough medicine with less than 200mg of codeine or per 100ml (Robitussin AC) and diphenoxylate-atropine (Lomotil).

initially on advocating SLT will give the state a solid starting point for future scope expansion endeavors.

**New Hampshire.** This state made two changes to its practice scope in the last few years, in 2022 gaining the right to treat all types of glaucoma (rather than only POAG) and the following year winning authority to administer adult vaccines for influenza, COVID-19 and shingles. Hoping to keep this momentum going, local ODs are now pursuing YAG capsulotomy, SLT and other minor surgical procedures that fall within the profession's education.

So far this year, SB 400 is moving quicker than similar legislation in other states, having passed the Senate in early February and now awaiting a committee assignment in the House. Dr. Angelique Sawyer of the New Hampshire Optometric Association explains that while this is a scope bill, it's also a regulatory bill that would give more authority to New Hampshire's optometry board to determine training and certification requirements, something that several other states are also advocating for.

"If this bill goes through as is, the board will have more ability to approve certain things as new training and technology comes along without having to go back for legislation every time," she explains.

While improved access to care is a leading argument for expanding optometry's scope, this is especially true in more rural states like New Hampshire. "For six out of 10 counties in New Hampshire, access is a very significant issue," Dr. Sawyer points out. "There are just not enough providers to go around, and it's going to get worse. So, for the benefit of patients, every state needs to be able to get to this point where patients have more access to the full complement of what optometry has to offer," she stresses.

**New Jersey.** Like Nebraska, this state is currently pursuing laser legislation that was introduced last year during a two-year legislative session. The identical bills, A-920 and S-354, have not moved yet in 2024 and are awaiting hearings in their respective branches of government. The bills propose adding several practice privileges for New Jersey ODs, including three laser procedures—SLT, capsulotomy and LPI—removal of styes and skin tags and an expansion of vaccine and prescription authority. As New Jersey is the most densely populated state in the US, allowing its optometrists to offer these services would have a profound impact on access to care.

"By expanding the scope of practice, optometrists can provide critical eye care when and where it's needed most

and ensure all New Jersey residents have timely access to vision and medical eye care," says Keira Boertzel-Smith, executive director of the New Jersey Society of Optometric Physicians. "It also lowers costs by eliminating duplication of services and extra co-pays for redundant office visits and reduces patient travel time and missed hours at work," she adds.

Despite the opposition's claims that New Jersey ODs lack adequate training to perform these procedures, the state has one of the most rigorous continuing education requisites in the country, requiring ODs to complete 50 hours of CE every two years to retain their licensure. With continued advocacy, legislators will hopefully recognize the illegitimacy of these claims.

**Missouri.** Two identical laser bills are in the running here this year, SB 956 and HB 1963, which propose the expansion of optometry's practice scope to encompass all procedures taught in optometry schools today, including minor surgery and the use of lasers. SB 956 is still awaiting an initial hearing in the Senate, while HB 1963 completed a public hearing in the house on February 13, the verdict of which had not yet been finalized at the time of this writing.

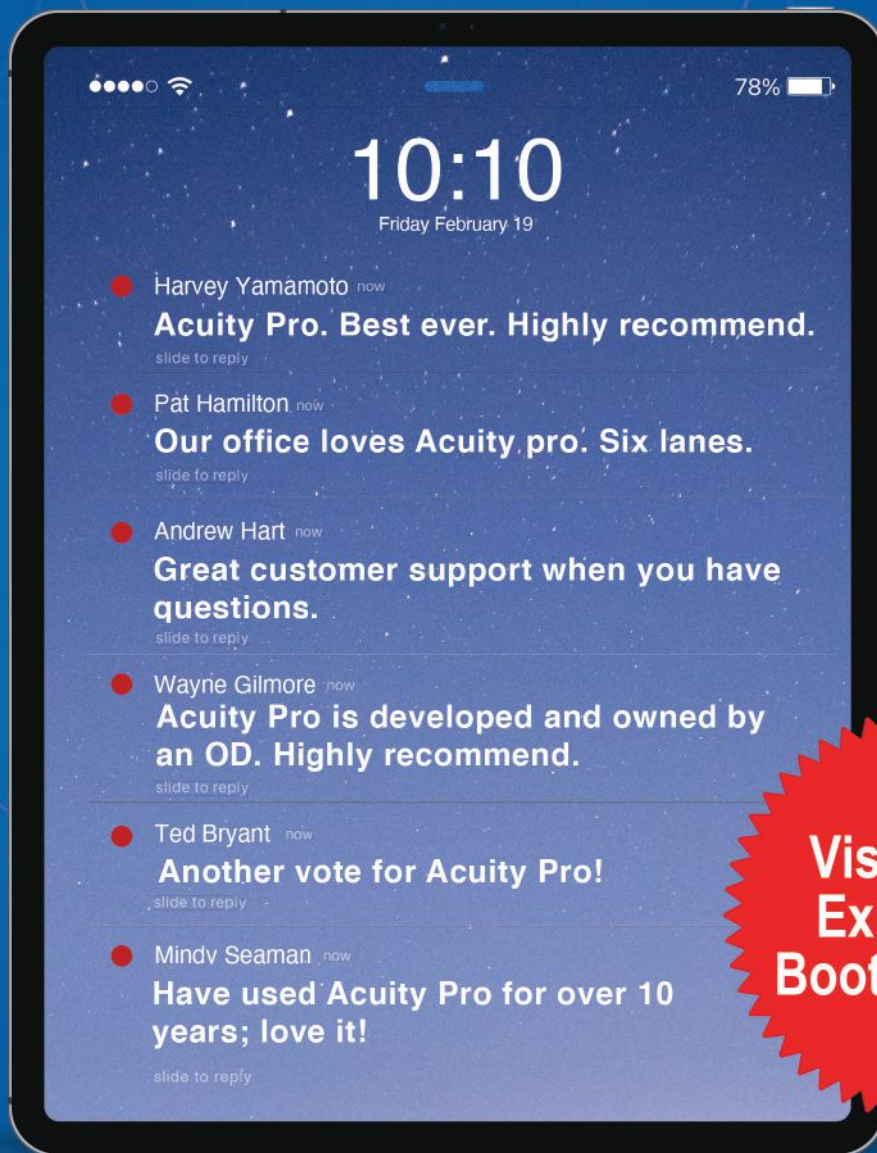
**Ohio.** The last update to optometry's practice scope in Ohio dates back to 2007, highlighting the need to modernize the law to reflect the many changes in technology and training that have occurred since that time. That's the goal of SB 129, a two-year bill introduced last June that proposes allowing Ohio ODs to remove benign lesions, cysts and skin tags, as well as use lasers for YAG capsulotomy, SLT and LPI. It also seeks to update ODs' pharmaceutical authority to permit the treatment of any eye condition and epinephrine injection. Additionally, like many other states pushing for expanded practice rights, the bill advocates increasing authority of the Vision Professionals Board to establish training guidelines.

The bill hasn't seen any movement yet this year, but a hearing was scheduled in the Senate Health Committee for February 28. During this waiting period, Lindsay Florkey, OD, president



Over 20 years of 👍 and ❤️!

I'm looking for a reputable solution for a digital acuity system – any suggestions?



Visit Vision  
Expo East  
Booth #F2723

Disaster proof by design | [acuitypro.com](http://acuitypro.com) / 580-243-1301

Sloan / Snellen / Numbers / Contrast / ETDRS / White On Black Option / Randomize  
Custom Remote / Marco Integration / Free Support / No Annual Fees

	LASER PRIVILEGES	LUMPS AND BUMPS	OTHER PROCEDURES	CONTROLLED SUBSTANCES	ORAL STEROIDS	ORAL IMMUNO-SUPPRESSIVES	ORAL ANTIFUNGALS	GLAUCOMA MEDS	INJECTABLE AGENTS	BLOOD DRAW
Alabama				3, 4, 5					A	
Alaska				2*, 3, 4, 5						
Arizona				2*, 3					A	
Arkansas				2*, 3, 4, 5						
California				2*, 3						
Colorado				2*, 3, 4, 5						
Connecticut									A	
D.C.									A	
Delaware				2*, 3, 4, 5					A	
Florida				3, 4*				T	A	
Georgia				2*, 3, 4, 5						
Hawaii									A	
Idaho										
Illinois				2*, 3, 4, 5					A	
Indiana				4**						
Iowa										
Kansas										
Kentucky				2*, 3, 4, 5						
Louisiana										
Maine				3, 4, 5					A	
Maryland								T	A	
Massachusetts				3, 4, 5						
Michigan				2*, 3, 4, 5						
Minnesota				4, 5					A	
Mississippi				2*, 3, 4, 5						
Missouri										
Montana										
Nebraska	SLT only								A	
Nevada				3, 4, 5						
New Hampshire			IPL	3, 4						
New Jersey				2*, 3, 4, 5					A	
New Mexico				2*, 3, 4, 5						
New York										
North Carolina										
North Dakota				3						
Ohio				2, 3, 4					A	
Oklahoma				2*, 3, 4, 5						
Oregon				2*, 3, 4, 5						
Pennsylvania				2*, 3, 4, 5					A	
Rhode Island				2*, 3, 4, 5						
South Carolina				2*, 3, 4, 5						
South Dakota			IPL							
Tennessee										
Texas				3, 4, 5					A	
Utah				2*, 3, 4, 5						
Vermont				3, 4, 5					A	
Virginia				2*, 3, 4, 5						
Washington				2*, 3, 4, 5						
West Virginia				2*, 3, 4, 5						
Wisconsin										
Wyoming				2*, 3, 4, 5						

2\* = hydrocodone products only    4\* = Acetaminophen with codeine and tramadol only    4\*\* = Tramadol only    A = injections for anaphylaxis only    T = topical glaucoma meds only

Chart data compiled by the American Optometric Association and Review of Optometry. Will be continuously updated at [reviewofoptometry.com](http://reviewofoptometry.com).



of the Ohio Optometric Association, says, “OOA members have been actively meeting with the members of the Senate Health Committee in their respective legislative districts, continuing to educate them about how our members are their constituents’ primary eye doctors and the importance of SB 129 in allowing ODs to provide enhanced vision services based on our proven comprehensive training and education.”

**South Dakota.** Last year saw both highs and lows for scope expansion advocates in this state. First, the good news: A change in regulations last fall now allows South Dakota ODs to perform intense pulsed light treatment, which is increasingly being recognized as a mainstay treatment for the large population of patients with dry eye and/or meibomian gland dysfunction.

Unfortunately, South Dakota still lags behind most other states with an optometry law that hasn’t been updated since 1994. Optometrists in the state hoped to change this by introducing a laser bill in 2023; however, its progress was ultimately halted by the House Health and Human Services Committee.

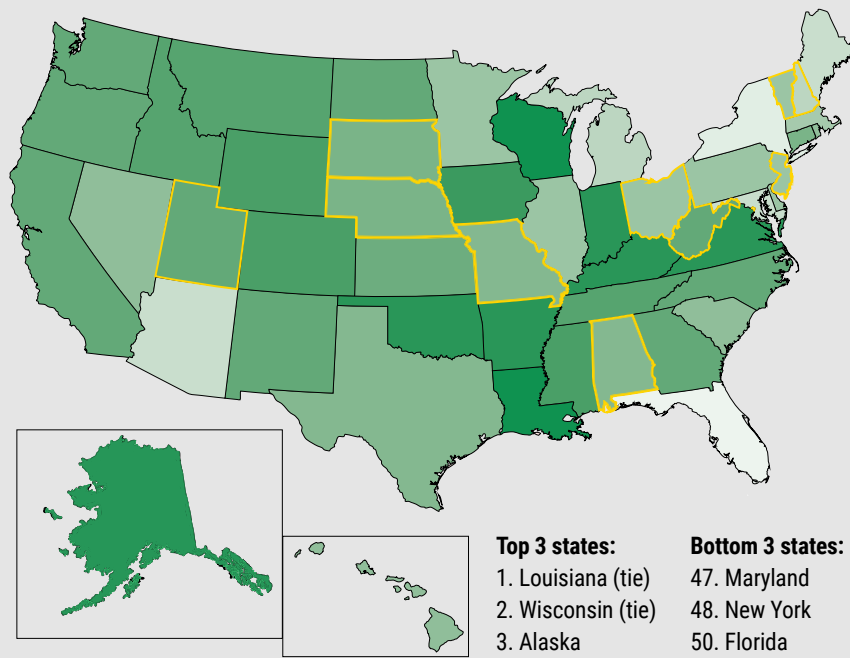
Ready to try again, scope advocates in South Dakota have once again introduced laser legislation in the 2024 session, and it’s already gotten further than it did last time around. HB 1099—proposing that state ODs gain the right to use certain lasers and inject and remove chalazion and skin tags—passed the House in early February and now resides in the Senate.

**Utah.** Two years ago, the Utah Senate voted against the modernization of optometry’s scope of practice, though the state hasn’t made any major changes to these guidelines in over 30 years. Fortunately, Utah ODs and advocates are lobbying another laser bill—SB 210—this year, and contrary to last, it already received the green light by the Senate on February 16. The bill will move on to the House in the coming weeks.

“We are excited because this was one of the most difficult hurdles to passing the bill,” commented Weston Barney, OD, legislative chair of the Utah Optometric Association. Dr. Barney

## Scope Variance in the US at a Glance

Color densities in the map below represent composite scores calculated for each state from the details on p. 36. Darker colors indicate more permissiveness toward optometric advanced procedures. States outlined in yellow have scope expansion bills active right now.



explains that while “many legislators have expressed their desire for SB 210 to become law, the specific certification requirements for ODs to use lasers is where opinions differ.” He adds that one of the main hurdles Utah has encountered while pushing for scope expansion is the lack of public understanding as to what exactly optometrists do. “If we can overcome the public perception that graduating from medical school is required to make all healthcare decisions, patients would see a significant improvement in national healthcare costs and access to care.”

**Vermont.** The failure of a 2020 attempt to add in-office procedures (*e.g.*, injections, lesion removal and certain lasers) to this state’s scope of practice was attributed to a negative report from the state’s Office of Professional Regulation (OPR), which cited concerns over education and training. But last September, the OPR communicated its newfound support for the expansion of optometry’s practice scope to include various in-office procedures. The reason for the change of heart: optometry’s persistent advocacy.

After receiving pushback from ODs and the Vermont Optometric Association, the state Assembly tasked the OPR with reinvestigating the matter, this time including more data on advanced procedure training and education curriculums in US optometry schools.

Armed with this new positive report from the OPR, Vermont is pursuing another laser bill (S.233) in the state’s 2024 legislative session. It currently awaits a hearing in the state’s Senate Healthcare Committee, which is expected to take place soon.

**Washington D.C.** While not pursuing laser privileges, this jurisdiction is looking to modernize the scope of practice for numerous allied health professionals, including optometrists. Bill 25-0545 seeks to allow ODs in D.C. to prescribe and administer controlled substances for ocular conditions, which is currently authorized nearly everywhere else in the country (except for in Hawaii, Maryland and New York). A hearing to discuss this bill was held this past December, and no further actions have been filed since.

**West Virginia.** A laser bill introduced here last January cleared the House but was ultimately killed in the Senate. This year, however, West Virginia ODs rebounded from the loss and have reintroduced an identical bill, HB 4783, which proposes the modernization of the practice scope to encompass all procedures taught in optometry schools today. This includes minor and surgical procedures such as lesion removal, capsulotomy, SLT and LPI.

In late January, HB 4783 passed the House Health Committee and now heads to the state's Senate Health and Human Services for consideration. Since this is where the bill's progress came to a halt last year, the West Virginia Optometric Association and other advocates are preparing for the battle ahead.

"As most states, we have legislators with opposing opinions of what the changes will actually do," explains Chad Robinson, the association's executive director. "We also have two state Senators who are medical doctors in their day jobs, so this is definitely one of the challenges. Others include the scare tactics and misinformation that will continue to be spread by the opposition."

The last change to West Virginia's practice scope was in 2010, when ODs there gained the authority to perform minor surgical procedures (foreign body removal, punctal plugs and lash epilation), epinephrine injections and expanded pharmaceutical privileges.

## Integrating New Services

With at least 12 states currently lobbying for scope expansion of some sort in 2024 and more planning to in the future, thousands of optometrists will likely soon find themselves asking, "*How do I implement these new services into my practice?*" To help prepare you for when this time comes, below several seasoned ODs share their best practices and advice on adding various privileges, including lesion removal, injections, oral medications and laser procedures.

**Incisions and injections.** Two practice privileges being increasingly embraced as responsibilities of optometry's profession include intralesional injections and mi-

nor in-office procedures such as removal of lesions in and around the eye. The most recent state to adopt these procedures was Washington last May, bringing the total count of states where ODs have injectable authority to 41, though 17 of these only permit injections to treat anaphylaxis. Additionally, optometrists in 19 states can now remove lumps and bumps.

The first step of implementing these procedures is to equip your office with the right tools for the job. To accommodate more clinical uses, it helps to have a wide variety of different sizes and types of syringes, needles, clamps, scalpels and blades, many of which can be purchased at once as part of a surgical instrument kit. You'll also need forceps, gauze pads, a high-temperature cautery, eye patches, a sharps container and several other items. For a full shopping list of materials you may need, see "*Equipping Your Office for Minor Surgical Procedures*" from our December 2023 issue.

One thing to be vigilant about for the safety of you, your patients and your staff is proper sanitation of tools and equipment before and after each procedure, as well as the use of PPE. Corri Collins, OD, who practices in Kentucky, says that before removing a lesion, for example, she first creates a sterile environment and positions the necessary equipment nearby (a sterile betadine swab, sterile gloves and erythromycin ointment).

Remember that the standard of care in all 50 states is that lesions with risk of malignancy be tentatively diagnosed as cancerous and biopsied, and most states legally prohibit ODs from removing a cancerous growth. Therefore, if there is any doubt a lesion could be malignant, referral to an ophthalmologist for excision and biopsy is warranted.

Lastly, ensure you and your staff have defined a plan of action to handle emergencies or adverse events that arise when patients are under the needle or scalpel.

Confidence performing these procedures comes with experience, but several resources are available for optometrists who wish to brush up their knowledge and skills for performing incisions and injections. Most importantly, take advantage of courses and training sessions held

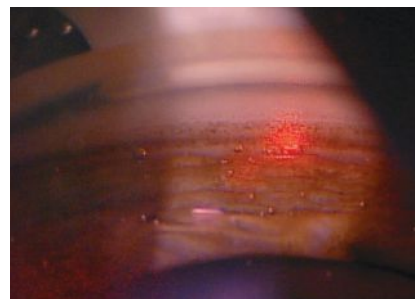


Photo: Nathan Lightizer, OD

**ODs in 11 states—and counting—can now perform SLT, an increasingly common first-line treatment for glaucoma.**

by your state's optometric association or optometry board. It can also be valuable to pick the brains of colleagues from other states who have years of experience performing these procedures. For reading material, *The Atlas of Primary Eyecare Procedures* can be a useful resource to keep on-hand at your practice.

**Oral medications.** Patients in all 50 states can now prescribe some form of oral medication, such as antivirals, antibiotics, antifungals, anti-inflammatories, analgesics, antihistamines and steroids. Here's a breakdown of the states that allow ODs to prescribe some of these specific drugs:

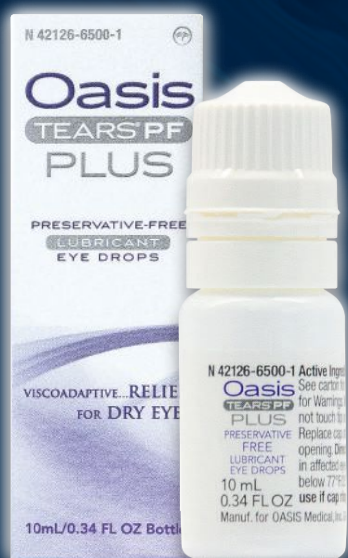- **Controlled substances:** 47 (exclusions: Hawaii, Maryland, New York, D.C.)
- **Oral glaucoma meds:** 48 (exclusions: Florida, Maryland)
- **Oral immunosuppressives:** 46 (exclusions: Arizona, Florida, New Hampshire, Maine)
- **Oral antifungals:** 44 (exclusions: Arizona, Delaware, Florida, New Hampshire, Maryland, New York, D.C.)
- **Oral steroids:** 44 (exclusions: Florida, Maine, Michigan, Minnesota, New York, South Carolina, D.C.)
- **Hydrocodone:** 36

Taking advantage of expanded pharmaceutical privileges in your state gives you the opportunity to provide your patients with more comprehensive care. Additionally, prescribing oral meds in-house can help reduce referrals to ophthalmology.

"Many common ocular and periocular conditions and their sequelae are treated with oral medications," says Jill Autry, OD, RPh, who practices in Texas, which passed a law in 2021 allowing ODs to

*Recommended by Eye Care Providers  
to Eye Care Providers*

OASIS® | VISION



**Oasis TEARS® PF Plus**



**SOFT PLUG®**  
EXTENDED DURATION  
180-T TAPERED

## Attending Vision Expo East?

Visit OASIS®  at Booth #F2108 at VEE 2024.


Download the Vision Expo App and follow the steps to redeem the OASIS® Offer.



Download on the  
App Store



GET  
Google Play





## Circling Back to Scope Success Stories

We touched base with two laser states—Alaska (2017) and Colorado (2022)—to see how things have been going since the scope expansion. Speaking on Alaska's experience is Paul M. Barney, OD, president of the Alaska Optometric Association and on the Board of Trustees at the AOA. From Colorado, answers were provided by past presidents of the Colorado Optometric Association and Fellows of the AAO, Deanna Alexander, OD and Jon Pederson, OD.

### How has expanding the practice scope affected patient care and access in your state?

**Alaska:** In a state that has a limited road system and where optometric care is the only eye care in many rural areas of the state, our expanded scope has reduced travel costs to patients, who prior to our scope expansion, often had to fly to other areas of the state to access care.

**Colorado:** It has allowed patients to receive the care they need through the doctors they trust and have established relationships with. Enabling doctors to provide the care they are trained to perform increases access and decreases duplication of services. Over 200 doctors have gone through the certification process outlined in our law and specified by our state board. The COA has worked hard to help doctors integrate these procedures into their offices.

### Did you experience any major setbacks during the legislative process?

**Alaska:** We ran our first scope expansion bill including laser privileges in 2015, which passed the Senate and House committees, but it needed a passing House floor vote to be sent to the Governor for signature. Before our bill could be heard, the session ended, and we had to start over with a new bill in the next session. Through that heartbreaking defeat, we learned a valuable lesson; had we been more effective in educating the leadership, our bill would have been placed higher in the queue and would likely have gotten a floor vote.

**Colorado:** We ended up having additional hearings in more committees than we anticipated, many of which differed from those that typical healthcare bills move through; however, we overcame this with our incredibly strong grassroots. Our doctors had relationships with members of all these committees. Establishing these relationships was a multi-year process.

### How did you deal with pushback from the opposition?

**Alaska:** The ALOA is a small organization with limited resources, so it was difficult combatting the attack ads and rhetoric put out by those opposed to our bill. Despite this, many of our members were engaged and well-connected to their legislators, which helped us send them an accurate and reasoned message untainted by the fear tactics used in many of the attack ads.

**Colorado:** Ultimately, legislators realized that we were capable of performing these procedures. Data from other states demonstrated a strong safety profile, and there was a need to increase access to care throughout Colorado. The opposition could not overcome those points.

### What role did advocacy play in the bill's success?

**Alaska:** Without advocacy and legislator relationships, our scope bill would not have passed. We wouldn't have been able to accurately explain to legislators the access to care issues that Alaskans faced, the level of education and training optometrists receive or that by not expanding scope of practice, Alaska was underutilizing the potential that optometry brings to our healthcare system.

**Colorado:** Advocacy is paramount to the bill's success. Legislators make decisions about so many issues; it is our job to be a resource to educate legislators about our profession, training and businesses. This cannot be done in the middle of a bill; the groundwork needs to be done years in advance.

prescribe oral meds. "It is important for optometrists to be able to use these options, as most patients have easier access to an OD when an ocular condition arises. This is because there are many more optometrists than ophthalmologists, optometry offices are often open later and often on Saturdays and most patients have an established relationship and medical/ocular history with an optometrist," she explains.

Prescribing a wider range of oral medications as your state allows it can essentially help you morph from a primary to a secondary care provider, which is increasingly needed in optometry given the progressive decline in the ophthalmology workforce and the aging population, Dr. Autry argues. "A large portion of the US is uninsured or underinsured, and optometry tends to be a more cost-effective option for patient care," she adds.

If learning the ins and outs of prescribing oral medications seems daunting at first, Dr. Autry points out that it's important to remember that these drugs are routinely used by several other medical personnel, including general and nurse practitioners and physician's assistants. "They use the same meds over and over that they are comfortable prescribing as they learn the pros and cons, dosages and side effects of each, as well as the rare pitfalls that may occur," she notes.

When preparing to offer oral meds at your practice, the first step is becoming familiar with your state's laws and requirements. Some oral medications may not have restrictions, while others, such as oral steroids, may have defined limits on the number of pills or length of therapy. You can always contact your state's optometric association with questions on the logistics of prescribing.

When you're ready and able to adopt this service, Dr. Autry shares some general advice to consider in the prescribing of various oral meds:

**Antivirals:** These drugs are typically well-tolerated with rare prescribing issues and have fewer side effects than topical trifluridine. Current research suggests that oral antivirals should be used over topical treatments for herpetic disease.

**Antibiotics:** While these are usually well tolerated, be sure to check allergies first. Oral antibiotics are mostly used for periorbital skin infections, so prescribe these in addition to hot compresses and watch out for poor response. If there's no improvement in 72 hours, consider a change in antibiotic and take note of MRSA signs, symptoms and risk factors.

**Antifungals:** The application of these drugs in primary eyecare is limited; however, antifungals can be used along with topical antifungal treatment for fungal keratitis. If there is any suspicion of a fungal infection, these cases must be referred or at least heavily comanaged with an ophthalmologist or cornea specialist.

**Anti-inflammatories:** By and large, optometrists use OTC ibuprofen and not Rx NSAIDs, though these may be combined with topical steroids for systemic treatment of uveitis or with acetaminophen OTC for analgesia.

**Antihistamines:** These drugs can be prescribed OTC for systemic aid to topical allergic treatments. They're typically safe and well tolerated, aside from the potential of somnolence and eye dryness.

**Oral steroids:** These have great potential in treating certain ocular conditions but also the biggest potential for severe side effects that vary based on age, systemic conditions, other medications, etc.

It is critical to read up on the potential adverse effects, treatment protocols and contraindications of the different oral medications to improve patient selection and avoid negative outcomes.

Dr. Autry also recommends having a "go-to" medication for each condition you treat at your practice. "Make a chart

for the dosages and length of therapy normally used to make it easier and faster when first learning to prescribe," she suggests. "Add a column for special population concerns—such as allergies, pregnancy, kidney or liver dysfunction, diabetes and so on—so you are triggered to ask the right questions and consider medication or dosage changes."

Once you put in the work in preparing your practice to prescribe oral meds, Dr. Autry assures, "It's not that hard, and you get comfortable very fast."

**Laser procedures.** The use of lasers by an optometrist for glaucoma treatment and post-cataract care is permitted in fewer states—11—than any other optometric privilege, though every year more states are lobbying to have it included in their practice scopes. With 10 more pursuing lasers this year alone, there is likely an impending surge in the number of optometrists who can perform procedures such as SLT and YAG capsulotomy.

While this high-profile responsibility may feel intimidating to integrate into your practice at first, there are many ways to set up for success when your state adds lasers to its scope. Implementation involves ensuring you have the proper training based on your state's law, purchasing or accessing equipment and determining how to fit the procedures into your practice schedule.

"You first have to decide what kind of laser to purchase: a YAG, an SLT laser or a combination system," says Dr. Lighthizer, a longtime laser-use advocate and educator. He notes that his personal choice is a combination laser since it can perform both capsulotomy and SLT.

Rather than purchasing a laser, another option is to lease or share one with a colleague. To determine the best route, as well as the type of laser to acquire, consider how frequently your practice refers patients out for each procedure and what the return on investment will be.

One plus that Dr. Lighthizer points out is that since a laser can double as a slit lamp, it doesn't have to take up additional space. "You could set this up in one of the exam

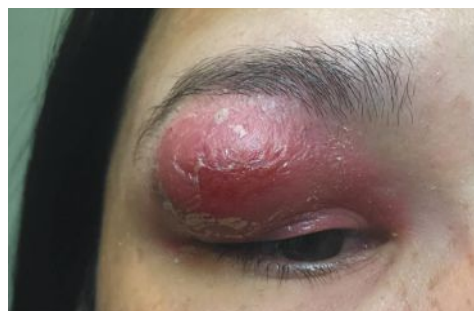

Photo: Jill Autry, OD, RPH

**This severe preseptal cellulitis due to MRSA should be treated promptly with oral antibiotics.**

rooms, and when it's not being used as a laser, you could also examine patient's eyes with it," he says.

Capsulotomies probably represent the bigger optometric opportunity, simply because of the higher volume of cataract surgeries performed each year vs. the size of the glaucoma population. Still, SLT is becoming a mainstream first-line glaucoma treatment and its importance to optometry practices will only continue to grow.

When you're getting comfortable performing procedures like SLT, YAG capsulotomy and LPI, it's worthwhile to reach out to ODs in states with longstanding laser laws. Attending trade shows and meetings with your state's optometric association also allows you to get hands-on experience and ask questions.

Finally, when fitting laser procedures into the workflow, Dr. Lighthizer likes to designate chunks of time on the schedule for laser and surgical procedures. That way, he can direct his focus on that for an entire morning or afternoon without having to juggle things like general exams and dry eye evaluations in between.

## Takeaways

It's only a matter of time before the use of optometric lasers and procedures such as lesion removal are mainstream across the profession. If your state is among those currently pursuing expanded practice rights, remember to support and reach out to your optometric association to learn how you can aid in advocacy efforts. If you already practice in a state with a broad scope, consider taking advantage of these opportunities to provide your patients with more comprehensive, timely and accessible care. ■




Photo: Jill Autry, OD, RPH

**A cornea presenting with herpes simplex dendritic keratitis. Dr. Autry notes that oral antivirals typically outperform topical treatments in cases of herpetic disease.**

**tyrvaya**<sup>®</sup>  
(varenicline solution)  
nasal spray 0.03 mg

FOR THE SIGNS  
& SYMPTOMS OF  
DRY EYE DISEASE

SHE'S LOOKING TO YOU FOR A  
DIFFERENT APPROACH WHEN  
ARTIFICIAL TEARS ARE NOT ENOUGH.<sup>1</sup>

BEFORE ANOTHER DROP

# ACTIVATE REAL TEARS

WITH THE FIRST AND ONLY NASAL  
SPRAY FOR DRY EYE<sup>2</sup>



## Tyrvaya<sup>®</sup> is not another drop

It's an **ocular surface-sparing** nasal spray.<sup>2</sup>



## Activates real, basal tears

Tyrvaya<sup>®</sup> is believed to work by activating the trigeminal  
parasympathetic pathway resulting in **basal tear production**.<sup>2\*</sup>



## Real tears, real fast

In 2 clinical trials with **mild, moderate, and severe** dry eye disease  
patients, Tyrvaya increased tear production from baseline by **≥10 mm**  
in **Schirmer's Test Score (STS)** in **nearly 50% of patients at week 4**,  
with increased tears seen as early as the first dose and over 12 weeks.<sup>2-8†</sup>

SEE WHAT  
TYRVAYA  
CAN DO



\*The exact mechanism of action is unknown.

†Tyrvaya was evaluated across 3 randomized, vehicle-controlled, double-masked studies in which adults aged ≥22 years diagnosed with dry eye disease received 1 spray of either active drug or vehicle in each nostril twice daily. Primary endpoint: % of patients with mean change from baseline in STS of ≥10 mm at week 4 in ONSET-1: 52% with Tyrvaya (n=48) vs 14% with vehicle (n=43) and in ONSET-2: 47% with Tyrvaya (n=260) vs 28% with vehicle (n=252). Onset of action: mean change from baseline in STS ~5 minutes after first dose (not a prespecified endpoint) in ONSET-1 was 17.2 mm with Tyrvaya (n=48) vs 4.0 mm with vehicle (n=43) and in ONSET-2 was 16.5 mm with Tyrvaya (n=260) vs 6.9 mm with vehicle (n=251). Observed data. On Day 1 in clinical studies, a baseline anesthetized Schirmer's test was performed. Tyrvaya was then administered concurrently with Schirmer's test. Schirmer's test results were measured at ~5 minutes. Mean change from baseline in STS at week 12 in the MYSTIC study was 10.8 mm with Tyrvaya vs 6.0 mm with vehicle. Limitations: Ex-US, single-center study. All subjects were Hispanic or Latino. Tyrvaya group mean baseline STS 5.5 mm (n=41); vehicle group mean baseline STS 5.3 mm (n=41). All randomized and treated patients were included in the analysis and missing data were imputed using last-available data.<sup>2-8</sup>

See references on next page.

## Indication

Tyrvaya<sup>®</sup> (varenicline solution) nasal spray is indicated for the treatment of the signs and symptoms of dry eye disease.

## Important Safety Information

The most common adverse reaction reported in 82% of patients was sneezing. Events that were reported in 5-16% of patients were cough, throat irritation, and instillation-site (nose) irritation.

Please see Brief Summary of Prescribing Information on the next page and the full Prescribing Information at [Tyrvaya-pro.com](http://Tyrvaya-pro.com).



**BRIEF SUMMARY:** Consult the full Prescribing Information for complete product information available at [www.tyrvaya-pro.com](http://www.tyrvaya-pro.com).

## **INDICATIONS AND USAGE**

TYRVAYA<sup>®</sup> (varenicline solution) nasal spray is a cholinergic agonist indicated for the treatment of the signs and symptoms of dry eye disease.

## **ADVERSE REACTIONS**

**Clinical Trials Experience:** Because clinical trials are conducted under widely varying conditions, adverse reaction rates observed in the clinical trials of a drug cannot be directly compared to rates in the clinical trials of another drug and may not reflect the rates observed in practice.

In three clinical trials of dry eye disease conducted with varenicline solution nasal spray, 349 patients received at least 1 dose of TYRVAYA. The majority of patients had 31 days of treatment exposure, with a maximum exposure of 105 days.

The most common adverse reactions reported in 82% of TYRVAYA treated patients was sneezing. Other common adverse reactions that were reported in >5% of patients include cough (16%), throat irritation (13%), and instillation-site (nose) irritation (8%).

## **USE IN SPECIFIC POPULATIONS**

**Pregnancy: Risk Summary:** There are no available data on TYRVAYA use in pregnant women to inform any drug associated risks. In animal reproduction studies, varenicline did not produce malformations at clinically relevant doses.

All pregnancies have a risk of birth defect, loss, or other adverse outcomes. In the US general population, the estimated background risk of

major birth defects and miscarriage in clinically recognized pregnancies is 2% to 4% and 15% to 20%, respectively.

**Data: Animal Data:** Pregnant rats and rabbits received varenicline succinate during organogenesis at oral doses up to 15 and 30 mg/kg/day, respectively. While no fetal structural abnormalities occurred in either species, maternal toxicity, characterized by reduced body weight gain, and reduced fetal weights occurred in rabbits at the highest dose (4864 times the MRHD on a mg/m<sup>2</sup> basis).

In a pre- and postnatal development study, pregnant rats received up to 15 mg/kg/day of oral varenicline succinate from organogenesis through lactation. Maternal toxicity, characterized by a decrease in body weight gain, was observed at 15 mg/kg/day (1216 times the MRHD on a mg/m<sup>2</sup> basis). Decreased fertility and increased auditory startle response occurred in offspring at the highest maternal dose of 15 mg/kg/day.

**Lactation: Risk summary:** There are no data on the presence of varenicline in human milk, the effects on the breastfed infant, or the effects on milk production. In animal studies varenicline was present in milk of lactating rats. However, due to species-specific differences in lactation physiology, animal data may not reliably predict drug levels in human milk.

The lack of clinical data during lactation precludes a clear determination of the risk of TYRVAYA to an infant during lactation; however, the developmental and health benefits of breastfeeding should be considered along with the mother's clinical need for TYRVAYA and any potential adverse effects on the breastfed child from TYRVAYA.

**Pediatric Use:** Safety and efficacy of TYRVAYA in pediatric patients have not been established.

**Geriatric Use:** No overall differences in safety or effectiveness have been observed between elderly and younger adult patients.

**References:** 1. Jones L, Downie LE, Korb D, et al. *Ocul Surf.* 2017;15(3):575-628. 2. Tyrvaya. Prescribing Information. Oyster Point Pharma; 2021. 3. Oyster Point Pharma. Data on file. OPP-002 (ONSET-1) Clinical Study Report. August 4, 2019. 4. Oyster Point Pharma. Data on file. OPP-101 (ONSET-2) Interim Clinical Study Report. October 13, 2020. 5. Quiroz-Mercado H, Hernandez-Quintela E, Chiu KH, Henry E, Nau JA. *Ocul Surf.* 2022;24:15-21. 6. Wirta D, Torkildsen GL, Boehmer B, et al. *Cornea.* 2022;41(10):1207-1216. 7. Wirta D, Vollmer P, Paaauw J, et al. *Ophthalmology.* 2021;0(0):379-387. 8. Oyster Point Pharma. Data on file. OPP-004 (MYSTIC) Clinical Study Report. March 19, 2020.

Manufactured for Oyster Point Pharma, Inc. 202 Carnegie Center, Suite 106, Princeton NJ 08540. For more information, visit [www.tyrvaya-pro.com](http://www.tyrvaya-pro.com). To report an adverse event, contact 1-877-EYE-0123.



© 2023 Viatriis Inc. and/or its affiliates. All rights reserved. VIATRIS and the Viatriis Logo are trademarks of Mylan Inc., a Viatriis Company. Oyster Point<sup>®</sup>, Tyrvaya<sup>®</sup>, and the Tyrvaya logo are trademarks of Oyster Point Pharma, Inc., a Viatriis company, in the United States and certain jurisdictions. OP-TYR-002308 7/23

# HAVE YOU KEPT UP WITH THE RECENT 'NEW DRUG' DELUGE?

Optometrists have access to many new meds right now, with a flood of more on the way. Here's a comprehensive review of what's out now and what's in the pipeline.



BY ROYA HABIBI, OD,  
MARK BUBOLTZ, OD, AND  
JACOB LANG, OD  
TAMARINDO, COSTA RICA;  
WOODBURY, MN; HUDSON, WI

Last year was a standout in the advancement of medical treatment of eye disease, as we clinicians and our patients dually benefited from a wealth of new FDA drug approvals. From presbyopia to glaucoma to dry eye and much more, we gained an even greater arsenal of tools to improve the lives of our patients. This influx of innovative therapies not only marks a pivotal moment in the evolution of eye care but also reinforces the commitment to elevating patient outcomes through the continuous pursuit of excellence in the field.

This comprehensive review aims to help every eye doctor be knowledgeable about new medications in the field so that we may offer up-to-date and effective treatments and build patient trust through evidence-based care practices.

Note that most of the product details and efficacy claims described below come from the manufacturers them-

selves and have not always been independently verified.

## Pupil Mechanics

From presbyopes hoping for lens-free clarity of vision to ODs performing clinical dilation in an office setting, manipulation of the pupil is being addressed with multiple new drugs. Described below are the current two presbyopia drops on the market and two recently approved drops for pupil dilation and reversal, plus a glimpse of some upcoming agents.

**Presbyopia drugs.** Early disenchantment with medical therapy for presbyopia prompted development of longer-acting agents and more patient-friendly regimens, two of which are now available, one wholly new to the market and the other a retooling of the original presbyopia drop:

### ■ Qlosi (pilocarpine hydrochloride 0.4%), Orasis Pharmaceuticals

• Status: FDA-approved October 2023.

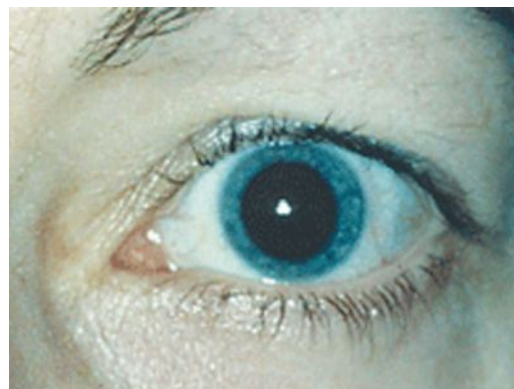


Photo: Ellen M. Petrella, OD

**New drugs Mydcombi and Ryzumvi can be used to return dilated pupils to baseline more quickly.**

• Preservatives: Preservative-free.

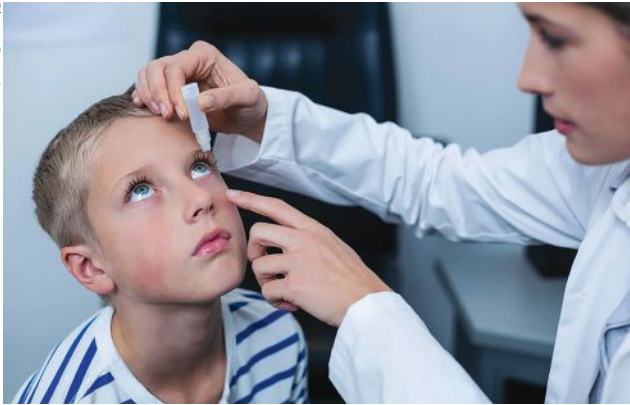• Mechanism of action: Cholinergic muscarinic agonist that activates receptors on the smooth muscles of the iris sphincter and ciliary muscle. This stimulates contraction, constricts the pupil and leads to miosis, enhanced depth of focus and improved near vision.

• Clinical trial data: NEAR-1 and NEAR-2 found statistically significant three-line or more gain in distance-corrected near visual acuity.

• SIG: Topical ophthalmic drop dosed QD-BID.

## About the authors

**Dr. Habibi** is a UC Berkeley trained optometric doctor with a specialized focus on ocular surface disease and specialty contact lenses. She currently is the owner and fellowship director at Ojos Del Mar in Tamarindo, Costa Rica. She is an education consultant for Valley Contax. **Dr. Buboltz** graduated from Illinois College of Optometry and completed residency at Minnesota Eye Consultants. He is the residency coordinator at Minnesota Eye Consultants, specializing in dry eye care, specialty contact lenses, anterior segment disease and glaucoma. His financial disclosures include Tarsus and Oyster Point (Viatris). **Dr. Lang** is the medical director of dry eye services and residency director at Associated Eye Care, practicing full-scope optometry with expertise in dry eye disease, comprehensive optometry, therapeutic contact lenses and surgical comanagement. He is vice president of the Intrepid Eye Society and chief editor of *Presbyopia Physician*. A full list of his disclosures can be found in the online version of this article.



**While atropine is currently used off-label as a myopia control agent, FDA approval is likely coming for as many as three drugs.**

- **Side effects:** Headaches (6.8%), instillation site pain (5.8%), blurred vision and ocular discomfort.
- **What's exciting?** This is a preservative-free formulation, and its low concentration maintains some pupillary response to light.

#### ■ **Vuity (pilocarpine hydrochloride 1.25%), AbbVie**

- **Status:** The original 2021 formulation received an updated FDA approval for BID dosing in March 2023.
- **Preservatives:** Benzalkonium chloride 0.0075%.
- **Mechanism of action:** Cholinergic muscarinic agonist that activates receptors on the smooth muscles of the iris sphincter and ciliary muscle. This stimulates contraction, constricts the pupil and leads to miosis, enhanced depth of focus and improved near vision. Ciliary muscle contraction may shift the eye to a more myopic state.
- **Clinical trial data:** VIRGO (BID); 230 patients in 14-day trial receiving BID dosing six hours apart. Clinically significant portion of participants gained three lines or more in mesopic, high contrast, binocular distance corrected near VA without losing more than one line of corrected DVA.
- **SIG:** Topical ophthalmic drops dosed QD-BID; second dose may be administered three to six hours after first dose.
- **Side effects:** In Phase III GEMINI I and II trials, 14% reported

headaches (typically mild) being most notable. There have also been rare reports of retinal detachments after use of Vuity, which was not a side effect reported in clinical trials (n=750 patients in Phase III trials).

- **What's exciting?** Now able to use twice daily for longer effect.

There are several other presbyopia medications in the pipeline, with interesting new approaches to instillation and mechanism of action. Below are the likely next two to come:

#### ■ **MicroLine (pilocarpine hydrochloride 2% with Optejet microdose dispenser), Eyenovia**

- **Status:** Phase III (Vision-1).
- **Mechanism of action:** Non-selective alpha-1/2 adrenergic antagonist that inhibits the contraction of smooth muscles within the iris dilator muscle, causing a decrease in pupillary diameter.
- **What's exciting?** Its "microdose" dispenser releases far less medication to the eye than a conventional drop.

#### ■ **Nyxol (phentolamine 0.75%), Ocuphire Pharma**

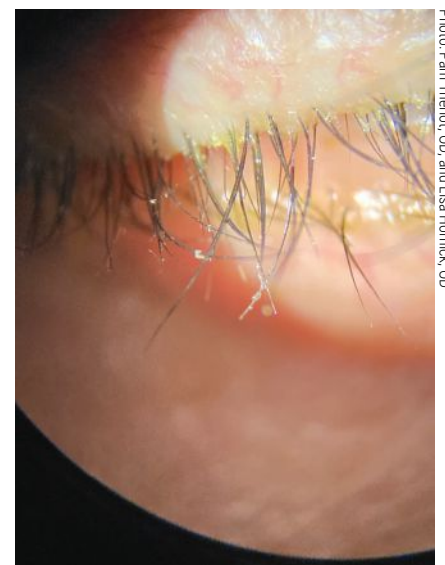- **Status:** Phase III (VEGA-2).
- **Mechanism of action:** Non-selective alpha-1/2 adrenergic antagonist that acts on the adrenergic nervous system and inhibits smooth muscle contraction in the iris, causing a decrease in pupillary diameter.
- **What's exciting?** Doesn't engage the ciliary muscle, so no risk of retinal complications. Aiming to receive indication for both presbyopia as well as dim light or night vision disturbances. Durable effect of pupil reduction (up to 24 hours), so QPM dosing effective. Only side effects are transient red eye and instillation discomfort.

#### **Clinical dilation and reversal agents.**

Despite the popularity and impressive imaging capabilities of ultra-widefield retinal cameras, there's no substitute for a dilated exam of the fundus. Two recent drug approvals aim to make that experience more patient friendly by hastening the return to baseline pupil size:

#### ■ **Mydcombi (tropicamide 1% + phenylephrine 2.5%), Eyenovia**

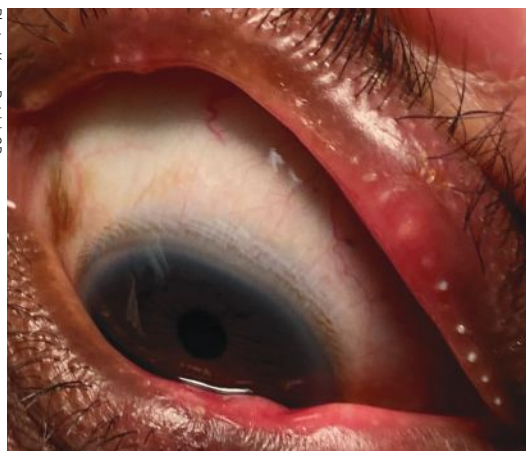- **Status:** FDA-approved May 2023 for mydriasis.
- **Preservatives:** None.
- **Mechanism of action:** Induces mydriasis and cycloplegia for diagnostic purposes.
- **Clinical trial data:** Approximately 94% of treated eyes achieved >6mm pupil dilation 35 minutes after instillation with <1% reporting stinging.
- **SIG:** Topical ophthalmic spray, administered as needed for diagnostic purposes.
- **Side effects:** Mild stinging resolving quickly, blurred vision.
- **What's exciting?** Uses the company's Optejet formulation, instilling the drop as a spray within 80 milliseconds (faster than the blink reflex) and delivering 80% less medication (around 8µL).



**Collarettes are pathognomonic for Demodex blepharitis. Xdemvy should help eliminate the mites by reducing the population in and around the meibomian glands.**



Photo: Korey Patrizi, OD



**Severe obstructive MGD can exacerbate dry eye signs and symptoms. The new drug Miebo is approved to help with signs and symptoms associated with this dysfunction.**

- **Ryzumvi (phentolamine 0.75%), Ocuphire** (see previous discussion on *Nyxol*, the same active ingredient under research for presbyopia therapy)
  - **Status:** FDA-approved September 2023 for reversal of pharmacologically induced mydriasis.
  - **Preservatives:** Preservative-free.
  - **Mechanism of action:** Non-selective alpha adrenergic agonist that inhibits contractions of smooth muscles (works directly on the radial muscles, indirectly on sphincter muscles) without affecting ciliary muscle.
  - **Clinical trial data:** Percentage of eyes returning to within 0.2mm of baseline pupil size was greater at all time points from one hour to 24 hours in Ryzumvi group compared to placebo. Maximal effect in 60 to 90 minutes.
  - **SIG:** One to two drops as needed after ophthalmic exam in which pupils were pharmacologically dilated. If two drops administered, wait five minutes between.
  - **Side effects:** 16% stinging, 12% hyperemia.
  - **What's exciting?** Pupil returns to baseline in 60 to 90 minutes. This is the first time in decades that clinicians have a dilation reversal drop available.

## Myopia Treatments

Management of refractive error has come a long way from just addressing kids' visual acuity demands with a pair

of glasses. With many newer myopia management interventions available, atropine is the primary pharmaceutical option. While this agent is being used off-label today, a few companies are nearing the end of the development pipeline, making FDA-approved atropine a real possibility in 2024 or 2025.

- **NVK002 (0.01% & 0.02% atropine), Vyluma**
  - **Status:** Phase III (CHAMP). Its PDUFA date of January 31, 2024 came and went without FDA action. No further details available at press time.
  - **Mechanism of action:** Interestingly, the desired MOA is not related to anti-muscarinic effects on the iris sphincter muscles and ciliary body (which in this case would be undesired side effects). The exact MOA is still unknown, but it is thought to be related to modulation of dopamine release, which has been correlated with the rate of growth of axial length.<sup>1</sup>
  - **What's exciting?** Preservative-free drop with QPM dosing.

- **MicroPine (atropine microdose), Eyenovia**
  - **Status:** Phase III (CHAPER-ONE), PDUFA date March 2024.
  - **Mechanism of action:** See above.
  - **What's exciting?** Opte-jet dispenser delivers a 8μL mist horizontally onto the eye (vs. a typical 40μL drop).

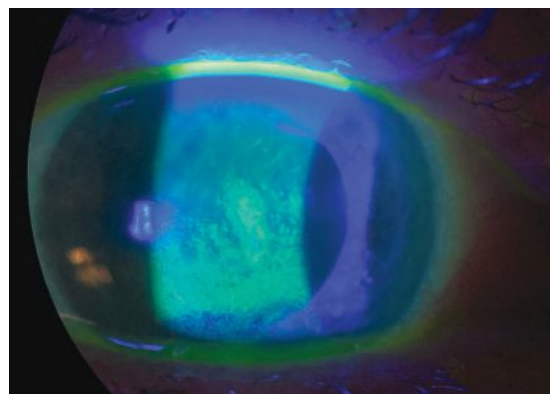
- **SYD-101 (0.01% and/or 0.03% atropine), Sydnexis**
  - **Status:** Phase III (STAR), data anticipated this June.
  - **Mechanism of action:** See above.
  - **What's exciting?** Includes a stabilizing agent. Traditionally, atropine is very unstable, so its pH is lowered (pH<5) to stabilize it; however, this decreases

bioavailability and also leads to its notorious stinging side effect. SYD-101 aims to maintain pH at a comfortable level without loss of efficacy.

## Dry Eye and Ocular Surface Treatments

It's an exciting time for this condition, as some truly innovative drugs have recently entered the market. New avenues for intervention are being explored for the first time with pharmacologic agents, including treatments for meibomian gland dysfunction (MGD) and *Demodex* blepharitis, both of which may contribute to ocular surface irritation. Let's look at those two first:

- **Xdemvy (lotilaner 0.25%), Tarsus Pharmaceuticals**
  - **Status:** FDA-approved July 2023 for *Demodex* blepharitis.
  - **Preservatives:** Potassium sorbate.
  - **Mechanism of action:** Anti-parasitic, lipophilic drop that acts via mite GABA-gated chloride channels to target, paralyze and kill *Demodex*.
  - **Clinical trial data:** Saturn 2 study: 60% total eradication of mites, 50% reduction of collarettes. Now has longitudinal data from Saturn 1 study out to six months and one year time points. Complete collarette cure vs. control was 39.8% vs. 2.7%, respectively, at six months and 23.5% vs. 2.9% at one year. The proportion of subjects with 10 or fewer collarettes (grade 0 or 1) was



**Sodium fluorescein staining reveals a compromised corneal surface due to dry eye. The new Vevye cyclosporine drop should help patients with this condition through improving visual clarity but without the potential for blurring to occur.**

Photo: Pam Theriot, OD, and Lisa Hornick, OD

# Look for choroidal hypertransmission, a marker of Geographic Atrophy (GA) on OCT<sup>1\*</sup>

- While BCVA is poorly correlated to lesion size, visual function continues to decline as lesions grow<sup>2,3</sup>
- It is critical to recognize GA and refer patients in a timely manner, as disease progression is relentless and irreversible<sup>1,3-7</sup>

Learn more about identifying GA  
at [RecognizeAndReferGA.com](https://RecognizeAndReferGA.com)



**RECOGNIZE  
AND REFER**


\*GA is defined by atrophic lesions, resulting from loss of photoreceptors, RPE, and underlying choriocapillaris. This results in a choroidal hypertransmission defect on OCT.<sup>1A9</sup>  
BCVA=best-corrected visual acuity; OCT=optical coherence tomography; RPE=retinal pigment epithelium.

**References:** 1. Fleckenstein M, Mitchell P, Freund KB, et al. The progression of geographic atrophy secondary to age-related macular degeneration. *Ophthalmology*. 2018;125(3):369-390. doi:10.1016/j.ophtha.2017.08.038. 2. Heier JS, Pieramici D, Chakravarthy U, et al. Visual function decline resulting from geographic atrophy: results from the chroma and spectri phase 3 trials. *Ophthalmol Retina*. 2020;4(7):673-688. doi:10.1016/j.oret.2020.01.019. 3. Sunness JS, Margalit E, Srikumaran D, et al. The long-term natural history of geographic atrophy from age-related macular degeneration: enlargement of atrophy and implications for interventional clinical trials. *Ophthalmology*. 2007;114(2):271-277. 4. Boyer DS, Schmidt-Erfurth U, van Lookeren Campagne M, Henry EC, Brittain C. The pathophysiology of geographic atrophy secondary to age-related macular degeneration and the complement pathway as a therapeutic target. *Retina*. 2017;37(5):819-835. doi:10.1097/iae.0000000000001392. 5. American Optometric Association. AOA Comprehensive adult eye and vision examination. *Quick Reference Guide: Evidence-Based Clinical Practice Guideline*. 1st ed. Accessed July 13, 2023. [https://www.aoa.org/documents/EBO/Comprehensive\\_Adult\\_Eye\\_and\\_Vision\\_%20QRG.pdf](https://www.aoa.org/documents/EBO/Comprehensive_Adult_Eye_and_Vision_%20QRG.pdf). 6. Holz FG, Strauss EC, Schmitz-Valckenberg S, van Lookeren Campagne M. Geographic atrophy: clinical features and potential therapeutic approaches. *Ophthalmology*. 2014;121(5):1079-1091. doi:10.1016/j.ophtha.2013.11.023. 7. Lindblad AS, Lloyd PC, Clemons TE, et al; Age-Related Eye Disease Study Research Group. Change in area of geographic atrophy in the age-related eye disease study: AREDS report number 26. *Arch Ophthalmol*. 2009;127(9):1168-1174. doi:10.1001/archophthalmol.2009.198. 8. van Lookeren Campagne M, LeCouter J, Yaspan BL, Ye W. Mechanisms of age-related macular degeneration and therapeutic opportunities. *J Pathol*. 2014;232(2):151-164. doi:10.1002/path.4266. 9. Chakravarthy U, Bailey CC, Scanlon PH, et al. Progression from early/intermediate to advanced forms of age-related macular degeneration in a large UK cohort: rates and risk factors. *Ophthalmol Retina*. 2020;4(7):662-672.

# Apellis

The APELLIS® name and logo is a registered trademark of Apellis Pharmaceuticals, Inc.  
©2023 Apellis Pharmaceuticals, Inc. 8/23 US-GA-2300089 v1.0





**The vehicle in the Vevye drop, called EyeSol, uses inert semifluorinated alkanes to spread rapidly over the ocular surface, forming a flat, transparent layer. This is due to it possessing low surface and interface tension.**

also significantly higher in study group than in control at 70.3% vs. 18.0% at six months and 62.6% vs. 21.9% at one year. Erythema cure (grade 0) was 21.1% in study group vs. 6.3% for controls at six months and actually improved at one year 28.7% in study group vs. 14.3% in control group.

- **SIG:** BID dosing for six weeks.
- **Side effects:** Stinging and burning (10%), chalazion/hordeolum (<2%), punctate keratitis (<2%).
- **What's exciting?** This is the first FDA-approved medication for the treatment of *Demodex* blepharitis. Treatment entails a six-week regimen.

■ **Miebo (100% perfluorohexyloctane), Bausch + Lomb/Novaliq**

- **Status:** FDA-approved May 2023 to treat signs and symptoms of dry eye disease associated with MGD.
- **Preservatives:** None.
- **Mechanism of action:** Exact mechanism unknown. Creates monolayer at air-liquid interface of tear film, reducing evaporation.
- **Clinical trial data:** GOBI and MOJAVE met primary signs and symptoms endpoints of total corneal fluorescein staining and eye dryness via Visual Analog Scale score. Symptomatic relief as early as day 15.
- **SIG:** Topical ophthalmic drop QID dosing.
- **Side effects:** Blurred vision, conjunctival redness in 1% to 3% of patients.
- **What's exciting?** Its non-aqueous liquid formulation precludes microbial growth potential, so a preservative is

not necessary. The agent is also non-blurring.

Again, each of the above address MGD-mediated ocular surface conditions in wholly new ways: Xdemvy by reducing the *Demodex* population in and around meibomian glands,

and Miebo by stabilizing the tear film in a way that mimics the natural lipid layer's role. But we also now have the chance to consider a new formulation of dry eye treatment mainstay, cyclosporine:

■ **Vevye (0.1% cyclosporine), Harrow**

- **Status:** FDA-approved June 2023 for treatment of dry eye disease.
- **Preservatives:** None.
- **Mechanism of action:** A calcineurin inhibitor that exerts immunomodulatory effects. This is achieved through blocking T-cell infiltration, activation and the subsequent release of inflammatory cytokines.
- **Clinical trial data:** Up to 71.6% of patients responded within four weeks with a clinically meaningful improvement of  $\geq 3$  grades in total corneal staining.
- **SIG:** BID.
- **Side effects:** Eye irritation (8%) and temporary blurred vision (3%).
- **What's exciting?** Another cyclosporine may not sound exciting, but the vehicle, EyeSol, is a water-free base that uses inert semifluorinated alkanes. By having low surface and interface tension, the drops can spread rapidly over the ocular surface and form a flat, transparent layer that could allow for improved visual clarity—without potential blurring. All lead to higher bioavailability, faster efficacy and higher patient satisfaction.

Running up behind these new players are many just out of reach, but which will likely be available very soon:

■ **APP13007 (clobetasol propionate 0.05%), Eyenovia**

- **Status:** NDA May 2023, PDUFA date March 2024 for inflammation and pain treatment after cataract surgery.
- **Mechanism of action:** Activation of either glucocorticoid receptor or the mineralocorticoid receptor in target tissues to cause anti-inflammatory effects.
- **What's exciting?** Stronger steroid compared to others on the market for postoperative pain and inflammation; BID dosing.

■ **AR-15512, Aerie Pharmaceuticals**

- **Status:** Phase III (COMET-3).
- **Mechanism of action:** TRPM8 receptors are cold-sensitive thermoreceptors that play a key role in tear film homeostasis. AR-15512 is a potent and highly selective TRPM8 agonist. This product stimulates tear production and produces a cooling sensation.
- **What's exciting?** A new therapeutic for dry eye and potentially neuropathic keratitis, given its agonistic effect on TRPM8 receptors.

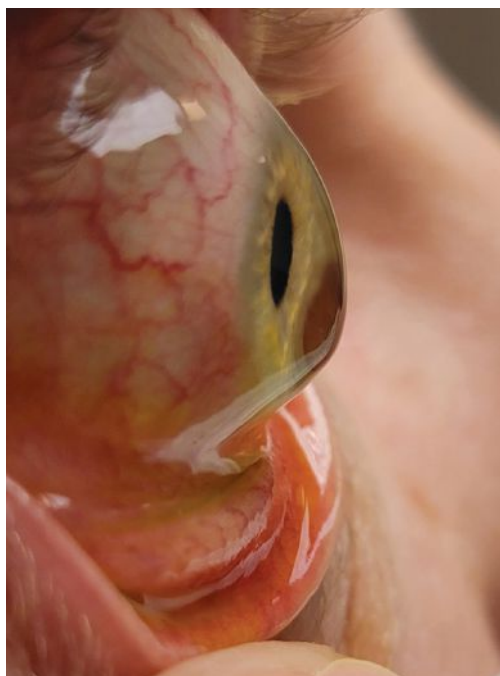■ **OCS-1 (dexamethasone 15mg/mL), Oculis**

- **Status:** Phase III (OPTIMIZE).
- **Mechanism of action:** Activation of either glucocorticoid receptor or the mineralocorticoid receptor in target tissues to cause anti-inflammatory effects.
- **What's exciting?** QD, preservative-free topical steroid for pain and inflammation following ocular surgery.

■ **Reproxalap (0.25%), Aldeyra**

- **Status:** Phase III (INVIGORATE-2/Tranquility-2). The initial NDA submission of November 2023 was not approved because the "the NDA did not demonstrate efficacy for the treatment of ocular symptoms associated with dry eye," according to the release. The current plan is to resubmit an NDA for approval to the FDA this year with more positive clinical data.
- **Mechanism of action:** Reactive aldehyde species (RASP) inhibitor. RASP refers to a class of electrophilic organic aldehyde molecules that facilitate inflammation.





**One eye drop in the later stages of clinical trials might be able to mimic the effects corneal collagen crosslinking surgery.**

- **Clinical trial data:** A Phase III trial also met its primary endpoint and was significantly superior for its two pre-specified endpoints: Schirmer's test ( $p=0.0001$ ) and  $\geq 10\text{mm}$  Schirmer test responder proportions ( $p<0.0001$ ) after a single day of dosing.

- **What's exciting?** A new anti-inflammatory mechanism of action! Positive implications for a number of inflammatory ocular conditions, most notably looking to get label indication for dry eye syndrome and allergic conjunctivitis.

#### ■ AZR-MD-001 (selenium sulfide ointment), Azura Pharma

- **Status:** Phase II.
- **Mechanism of action:** Keratostatic/decrease meibomian gland hyperkeratinization of ducts and orifices, keratolytic/loosen meibomian gland blockages, lipogenesis/increase secretion of meibomian gland lipids.
- **What's exciting?** Twice weekly nightly treatment that met co-primary endpoints: improvement of meibomian gland yielding liquid secretions and improved Ocular Surface Disease Index scores.

## Keratoconus Drops

Corneal collagen crosslinking has improved many patients' visual prognoses since FDA approval in 2016. Now, a new drop may offer similar results without the surgery, but is still in the process of being studied.

#### ■ IVMED-80 (copper sulfate), Glaukos

- **Status:** Phase III (Study); FDA orphan drug designation for treatment of keratoconus.
- **Mechanism of action:** Copper sulfate is a necessary cofactor for lysyl oxidase, an important enzyme for extracellular matrix epistasis. This causes the formation of crosslinks between extracellular proteins leading to reduction in corneal curvature.
- **What's exciting?** As it's an eye drop, this would be the first non-surgical, non-laser treatment for crosslinking of the cornea.

## Glaucoma

In a crowded corner of the ophthalmic market, three new drugs have recently been FDA-approved. However, each has at least one attribute that distinguishes it from other glaucoma therapies: one delivers the therapeutic agent through an injectable device while two new eye drops have advantages in preservative status and mechanism of action.

#### ■ Omlonti (omidenepag isopropyl 0.002%), Visiox

- **Status:** FDA-approved September 2022, launch early 2024.
- **Preservatives:** 0.005% benzalkonium chloride.
- **Mechanism of action:** Relatively selective prostaglandin EP2 receptor agonist, which increases aque-

ous humor drainage through the conventional (or trabecular) and uveoscleral outflow pathways, and the only product with this pharmacological action.

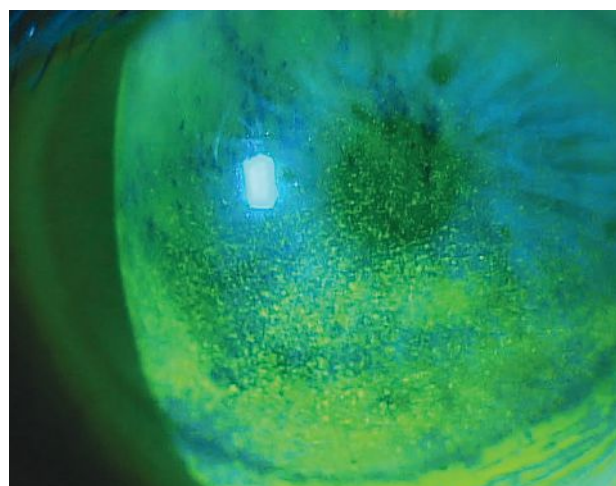
- **Clinical trial data:** Lower mean diurnal IOP by 3.7mm to 7.4mm Hg (20% to 30%) from baseline.<sup>2</sup>
- **SIG:** 1gtt qHS.
- **Side effects:** Notably, contraindicated for pseudophakic and aphakic patients due to incidence of cystoid macular edema of nearly 50%.
- **What's exciting?** A new-to-market selective prostaglandin EP2 agonist. Perhaps more effective than latanoprost, although no head-to-head studies.

#### ■ Iyuzeh (0.005% latanoprost), Thea Pharma

- **Status:** FDA-approved Dec 2022 for treatment of POAG and OHT.
- **Mechanism of action:** Prostaglandin F2 $\alpha$  analog increasing aqueous humor drainage through trabecular and uveoscleral pathways.
- **Preservatives:** None.
- **What's exciting?** First and only commercially available preservative-free latanoprost, a clear advantage for patients on chronic therapy.

#### ■ iDose TR (travoprost 75mcg intracameral implant), Glaukos

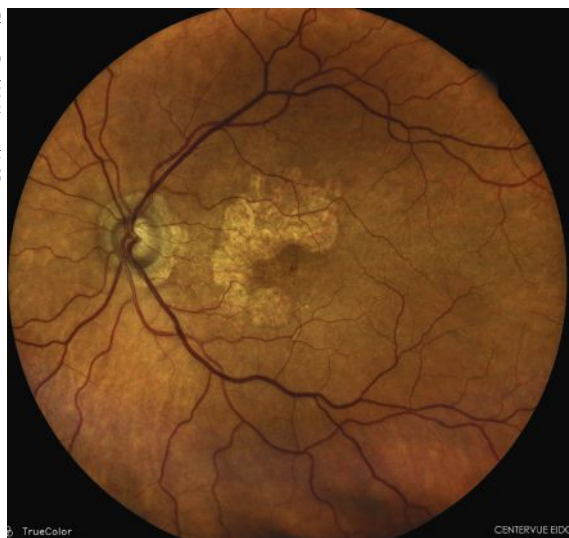- **Status:** FDA-approved December 2023 for POAG and OHT. Launch expected Q1 2024.



**Often, glaucoma medications can cause unwanted ocular surface side effects. Both Iyuzeh and iDose TR are intended to minimize this risk, as neither contain preservatives.**

Photo: Paul M. Karpecki, OD

Photo: Paul M. Karpecki, OD



**2023 was a historic year for AMD treatments with the first two drugs approved for GA.**

- **Preservatives:** None.
- **Mechanism of action:** An intracameral implant, or canister, inserted into the trabecular meshwork, which slowly elutes travoprost for at least one year.
- **Clinical trial data:** Both Phase III trials successfully achieved the pre-specified primary efficacy endpoints through three months and demonstrated a favorable tolerability and safety profile through 12 months. IOP reductions from baseline over the first three months were 6.6mm to 8.4mm Hg in the iDose TR arm vs. 6.5mm to 7.7mm Hg in the timolol control arm. In addition, 93% of iDose TR participants remained well-controlled (vs. 67% of timolol control participants) in both studies.
- **Side effects:** Conjunctival hyperemia occurred at a low rate (3%), while the most frequent adverse event for this dosage was mild transient iritis (rate of 6% for both trials). No corneal or peri-orbital fat atrophy adverse events were noted, nor was any corneal endothelial cell loss.
- **What's exciting?** A new, minimally-invasive surgery technique to treat open-angle glaucoma with a well-established medication but without the concern for topical ocular side effects (dry eye, blepharitis, peri-orbital fat atrophy).

There is one other glaucoma drug not yet approved but in the development process:

■ **PDP-716 (brimonidine 0.35%), VisioX Pharma**

- **Status:** NDA accepted December 2022 with an original PDUFA date of August 2023. The company states that it expects to launch in early 2025.
- **Preservatives:** Not listed.
- **SIG:** QD.
- **What's exciting?** First QD-dosed brimonidine, made possible by a new drug delivery platform the

company calls TearAct. The drop is a suspension in which fine resin particles adsorb the active agent; then, these bonds are broken from the shearing force of the blink, prolonging the release of drug by reducing the immediate exposure and providing a slow, consistent and sustained exposure.

**AMD, Diabetic Retinopathy and RVO**

Although the eyecare community has had access to drugs to treat wet age-related macular degeneration (AMD) for nearly 20 years now, it was only last year that we finally saw the launch of not one but two drugs for a specific presentation of the dry form, that being geographic atrophy (GA). Even though the GA drugs do not deliver the visual improvement gains that anti-VEGF agents do in wet AMD, their release is historic and finally makes intervention here a viable option.

■ **Syfovre (pegcetacoplan injection 15mg), Apellis**

- **Status:** FDA-approved February 2023 for treatment of GA secondary to AMD.
- **Mechanism of action:** Synthetic peptide-based inhibitor of C3. Acts on the central protein in the complement cascade to help regulate complement overaction.

• **Clinical trial data:** OAKS and DERBY; reduced GA lesion growth up to 36% (monthly injections) and increasing treatment benefit with time.

- **SIG:** Injections monthly or every other month.
- **Side effects:** Ocular discomfort (>5%), neovascular AMD, vitreous floaters, conjunctival hemorrhage, endophthalmitis, retinal detachment, retinal vasculitis, intraocular inflammation (0.24%).
- **What's exciting?** The first FDA-approved GA treatment.

■ **Izervay (avacincaptad pegol intravitreal solution), Iveric Bio**

- **Status:** FDA-approved August 2023 for treatment of GA secondary to AMD.
- **Mechanism of action:** RNA aptamer that binds to and inhibits complement protein C5.
- **Clinical trial data:** GATHER2: 14% mean reduction in GA growth.
- **SIG:** Injections monthly or every other month.
- **Side effects:** Conjunctival hemorrhage, increased IOP, blurred vision, CNV, neovascular AMD, endophthalmitis.
- **What's exciting?** Bimonthly dosing after one year resulted in a 19% reduction of mean GA growth rate.

We also saw in 2023 an update to one anti-VEGF mainstay that can now reduce the burden of treatment. By allowing for a longer interval between injections, patients may feel some time has been given back to them. As well, there was the expansion of another drug to be indicated for diabetic macular edema (DME) following retinal vein occlusion (RVO).

■ **Eylea HD (aflibercept 8mg), Regeneron Pharmaceuticals**

- **Status:** FDA-approved August 2023 for treatment of AMD, DME, diabetic retinopathy (DR).
- **Mechanism of action:** Inhibits the activation of cognate VEGF receptors by binding VEGF-A and PlGF proteins.

- **Clinical trial data:** PULSAR and PHOTON: compared to Eylea 2mg, Eylea HD demonstrated noninferior and clinically significant vision gains at 48 weeks when compared with bi-monthly 2mg treatment.

- **SIG:** 8mg monthly for three months, then 8mg every two to four months with either AMD or DME or two to three months for DR.

- **Side effects:** Cataract, conjunctival hemorrhage, increased IOP, vitreous floaters, vitreous detachment, corneal epithelial defect, retinal hemorrhage.

- **What's exciting?** A higher dose of aflibercept allows less frequent injection with the same effect of stable vision.

## ■ Vabysmo (faricimab), Genentech

- **Status:** FDA-approved October 2023 for treatment of macular edema following RVO. Previous approval February 2022 for wet AMD and DME.

- **Mechanism of action:** Dual inhibition of VEGF and angiopoietin-2.

- **Clinical trial data:** Post-hoc analyses from four Phase III studies indicate Vabysmo had dried retinal fluid faster and with fewer injections in both wet AMD and DME. More wet AMD patients displayed absence of retinal fluid at 12 weeks in a post-hoc analysis from the Phase III TENAYA and LUCERNE studies. DME patients had less blood vessel leakage in the macula at 16 weeks in a post-hoc analysis from the Phase III YOSEMITE and RHINE studies.

- **SIG:** 6mg dose injected intravitreally every four weeks.

- **Side effects:** The most common adverse reactions ( $\geq 5\%$ ) were cataract (15%) and conjunctival hemorrhage (8%).

- **What's exciting?** Vabysmo now has three indications for retinal disease: macular edema related to DR and RVO, as well as wet AMD.

Finally, an intriguing alternative to intravitreal anti-VEGF is also being developed that, if successful, would provide an oral therapy to combat angiogenesis. In addition to the benefits this would afford patients in safety, comfort and convenience, such an approval might (in theory) also allow optometrists to

## Drugs for Rare Posterior Segment Diseases

The world of retinal drug development is one of the most active areas for ophthalmic research. Anyone who follows this category of biotech news will be accustomed to reading reports of promising new agents and dashed hopes in equal measure. What may one day come to market is anyone's guess, but the agents below are notable for their unique approaches to some of the most visually disabling conditions in eye care.

### • KIO-301 (benzyl ethyl aminoazobenzene quaternary ammonium) for RP, Kiora Pharmaceuticals

- **Mechanism of action:** The company describes it as "a visible light-sensitive small molecule that acts as a reversible 'photoswitch' specifically designed to restore the eyes' ability to perceive and interpret light in visually impaired patients."

- **Clinical trial data:** Preliminary data shows it is capable of improving light perception in patients who have ultra-low vision or are completely blind. Functional MRI shows significant increase in relevant areas of the brain (v1 region of visual cortex) at days three and 15.

- **Side effects:** No adverse effects reported.

### • QR-110 for Leber's congenital amaurosis, ProQR Therapeutics

- **Mechanism of action:** This RNA-based drug candidate has the potential to restore sight or slow down the process of vision loss in patients with LCA10 by correcting the most common mutation implicated in the disease (p.Cys998X).

### • MCO-010 for Stargardt's and RP, Nanoscope Therapeutics

- **Status:** Phase IIb trial of optogenetic therapy for retinitis pigmentosa; received orphan drug and fast track designation from FDA.

- **Mechanism of action:** Targets retinal degenerative diseases via gene delivery encoding for the ambient light-sensitive MCO protein into retinal cells.

- **Clinical trial data:** 89% of participants demonstrated two or more luminance level improvement with single intravitreal injection.

- **Side effects:** Well tolerated with no serious side effects.

- **What's exciting?** Also potential for Stargardt's, Usher's, rod-cone dystrophy.

### • ALK-001 (gildeuretinol), Alkes Pharmaceuticals

- **Status:** Phase III (TEASE): FDA breakthrough status granted 2021 for Stargardt's.

- **Mechanism of action:** Acts as a replacement for vitamin A to prevent the formation of toxic vitamin A dimers (bad byproduct).

- **What's exciting?** This is an oral QD drug with applications for many retinal dystrophies.

### • Kimmtrak (tebentafusp-tebn) for metastatic uveal melanoma, Immunocore

- **Clinical trial data:** The first and only FDA-approved treatment that, in a randomized clinical trial, was proven to significantly extend overall survival for HLA-A\*02:01-positive adults with uveal melanoma that cannot be removed by surgery or has spread.

directly manage angiogenic diseases for the first time, as no intravitreal injection would be needed for administration.

## ■ APX-3330, Ocuphire Pharma

- **Status:** Phase IIb (ZETA-1).

- **Mechanism of action:** Inhibits reduction-oxidation effector factor-1 to block downstream pathways involved in angiogenesis and inflammation.

- **What's exciting?** BID oral drug intended to help prevent development of proliferative diabetic disease or macular edema. Current trials are studying its use in nonproliferative DR, but it could also have uses in DME and AMD.

## Takeaways

New drug development is continuously being undertaken within every eyecare specialty. Luckily for practitioners, we're in a phase where many are making it to market after long periods of gestation. Especially at the moment, there's no shortage of exciting new options to inform our patients about—and put to good use for their benefit. ■

1. Kaiti R, Shyangbo R, Sharma IP. Role of atropine in the control of myopia progression- a review. *Beyoglu Eye J.* 2022;7(3):157-66.

2. Matsuo M, Matsuoka Y, Tanito M. Efficacy and patient tolerability of omeidenepag isopropyl in the treatment of glaucoma and ocular hypertension. *Clin Ophthalmol.* 2022;16:1261-79.



# SAFE AND SAVVY PRESCRIBING OF ORAL PHARMACEUTICALS

Two experts share their best “dos and don’ts” to help you confidently handle the most common scenarios across several different categories of medications.



BY BLAIR LONSBERRY, OD,  
AND MITCH IBACH, OD  
FOREST GROVE, OR; SIOUX FALLS, SD

**A**s scope of practice continues to expand in optometry, oral pharmaceuticals prescription has become a mainstay in many practices in the treatment and management of a variety of ocular and periocular conditions. Optometrists don’t hesitate when prescribing topical medications, but when it comes to oral pharmaceuticals we often hesitate or at least think twice about what we are going to prescribe. Let’s review the “dos and don’ts” of the most prescribed oral pharmaceuticals that optometrists use in the management of ocular and periocular conditions.

## Case History

Patients present to our offices with urgent or emergent eye care concerns, and the first step of the management plan is a thorough case history. Review the patient’s chief concern and the various signs and symptoms, and then think about possible etiologies and treatment options for the patient. A thorough

medical history will include important considerations such as allergies to medications, age, sex, pregnancy, current health conditions and medication use.

Be aware of possible cross-sensitivity with other medications (*e.g.*, someone with a penicillin allergy may also be sensitive to certain cephalosporins).<sup>1</sup> It is important to ask the patient whether they had experienced any reactions with any medications. Patients often misinterpret experiencing a side effect of a medication as being allergic to it. For example, nausea and diarrhea after taking amoxicillin is not an allergic response but a well-known side effect of that medication. The CDC reported in 2017 that 10% of the population reports being allergic to penicillins, but less than 1% are truly allergic upon testing.<sup>2</sup> Side effects often take several days to develop, while a person who is allergic will often develop symptoms shortly after administration of the medication.

Signs and symptoms of an allergic response to a medication include the development of skin rashes/hives, blistering of mucous membranes and/or breathing issues.<sup>3</sup> Educate all patients whenever prescribed an oral medication

(especially sulfa-based antibiotics) that, if they develop any rashes/hives, blisters or breathing issues, they should stop the medication immediately and contact the clinic. Also, teach them about potential side effects of the medication like nausea, diarrhea, paresthesia, sedation, etc.

Any medical conditions the patient may be experiencing that affect the kidneys and liver should be carefully explored (*e.g.*, diabetes and chronic kidney disease or alcoholism and liver function). Dosing may have to be altered or the medication entirely avoided, depending on the patient’s liver and kidney functioning.<sup>4</sup>

In addition, the medications the patient takes to manage their medical conditions have the potential to either cross-react or alter the patient’s “normal” physiology, making the patient have an adverse reaction even in typical or normal dosing. For example, the monoamine oxidase inhibitors (MAOI) were one of the very first antidepressant medications, but they have largely been replaced by newer drugs due to several dietary restrictions, side effects and safety concerns. Prescribing tramadol for a patient’s corneal abrasion would

### About the authors

**Dr. Lonsberry** is a professor of optometry at Pacific University College of Optometry. His financial disclosures include roles at Dompe, Sun Pharmaceuticals and Thea Pharmaceuticals. **Dr. Ibach** works at Vance Thompson Vision in Sioux Falls, SD. There, he is the residency co-coordinator. His financial disclosures include roles at Alcon, Allergan, Avellino, Bausch + Lomb, Dompe, Equinox, Glaukos, Heru, Kala, New World Medical, Ocular Therapeutix, Ocuphire, Sight Sciences, Sun Pharmaceuticals, Thea Pharmaceuticals, Viatriis and Zeiss.

be contraindicated in a patient taking an MAOI because it could lead to serotonin syndrome, which can develop within minutes to hours in a patient leading to possible hallucinations, tachycardia, abnormal eye movements, loss of coordination and other effects.<sup>5</sup>

## Systemic Antibiotics

Infections involving the periocular soft tissues (*e.g.*, preseptal cellulitis, dacryocystitis and internal hordeola) require the systemic antibiotics (*Figure 1*). When prescribing these, consider that the overuse or the inappropriate prescribing of antibiotics can lead to the development of resistance. When deciding which antimicrobial agent to prescribe, the clinician should consider the spectrum of action, the route of administration and the suspected site of infection. In addition, patient factors such as allergy status, age, renal and liver function and weight must be considered.<sup>6</sup>

The antibiotic is often chosen based on the knowledge of what is the most common pathogen found in that tissue or site. For example, the most common bacteria associated with periocular tissue infections is *Staphylococcus aureus*, a gram-positive bacterium. Additional consideration must be given to patients who may have an increased risk of their infection being secondary to methicillin-resistant *Staphylococcus aureus* (MRSA) (*Figure 2*). The clinician will need to consider covering for a MRSA infection if the patient reports prolonged hospitalization, intensive care admission, recent hospitalization, recent antibiotic use, previous MRSA infection, invasive procedures, HIV infection, admission to nursing homes, open wounds and hemodialysis.<sup>8</sup>

The cell wall synthesis inhibitor group of antibiotics is one of the most prescribed for soft tissue infections, as they have good soft tissue penetration and good activity against gram-positive bacteria. The cell wall synthesis inhibitor antibiotics include the  $\beta$ -lactam antibiotics, vancomycin and bacitracin.<sup>9</sup> The  $\beta$ -lactam group of antibiotics includes

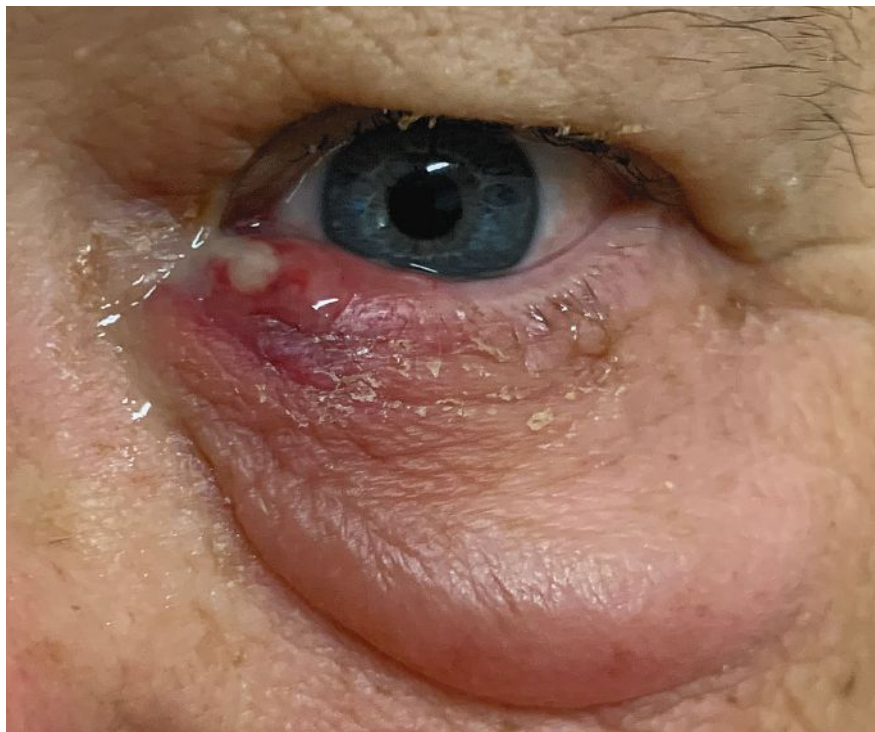


Photo: Joseph W. Sowka, OD

**Fig. 1.** Mild cases of dacryocystitis in children often self-resolve, while more severe forms should be managed with antibiotic therapy, dose-adjusting based upon weight.

penicillins (*e.g.*, amoxicillin) and cephalosporins (*e.g.*, cephalexin).<sup>10</sup> There are penicillinase-resistant antibiotics that have a natural resistance to penicillinase such as dicloxacillin, oxacillin and nafcillin.<sup>11</sup>

**Penicillin.** Note that penicillin allergies, or hypersensitivity, are one of the more common drug allergies that patients report. Approximately 10% of the population reports an allergy to penicillins; however, in reality only about 1% of the population has a true penicillin allergy. Even if an individual had a penicillin allergy as a child, approximately 80% of patients often lose their sensitivity after 10 years.<sup>2</sup>

The CDC and other organizations that monitor antibiotic use and resistance strongly recommend all healthcare professionals take a proactive role to delabel penicillin allergy in patients who report a penicillin allergy. To do so, initiate skin testing and review the patients' medical history in relation to what reaction the patient had to the penicillin. Skin testing is recommended for those individuals who report an anaphylactic

response to a penicillin. For most other patients with histories of penicillin allergy that are vague or benign, prescribing without preceding skin testing is the preferred approach.

Another side effect of the penicillin group of antibiotics is antibiotic-associated-diarrhea (AAD). Amoxicillin is most associated with AAD. The administration of systemic antibiotics can kill not only pathogens also disrupt the natural symbiotic flora of the gut resulting in gastrointestinal upset (GI), nausea and diarrhea. AAD occurs in patients from the start of the treatment and can last up to two months after the end of the treatment. Taking antibiotics with food and recommending taking probiotics approximately two hours after the antibiotic can mitigate the symptoms of AAD by helping normalize an unbalanced flora.<sup>12</sup>

**Cephalosporins.** These are one of the most prescribed antibiotics due to their wide clinical utility and good tolerability with a low chance for allergic response. As the cephalosporins are part of the  $\beta$ -lactam group like penicillin, patients

## Allergies vs. Side Effects

Allergic responses typically occur within an hour of taking a medication. Symptoms include red and unusually warm skin, blotchy rash, hives (nettle rash), itching, swollen mucous membranes, fluid retention in the body's tissues (edema). Severe allergic responses can also include anaphylaxis and lead to breathing difficulties, confusion and drowsiness or even cardiac arrest.<sup>1</sup>

Side effects of medications can happen at any time and typically include upset stomach, diarrhea (loose stools), dry mouth, drowsiness, flushing/sweating and changes in mood or behavior.<sup>2</sup>

1. Drug allergies: Overview. InformedHealth.org [Internet]. Cologne, Germany: Institute for Quality and Efficiency in Health Care (IQWiG). [www.ncbi.nlm.nih.gov/books/NBK447110/](http://www.ncbi.nlm.nih.gov/books/NBK447110/). Last updated May 7, 2020. Accessed February 11, 2024.

2. Due A. What are side effects? Eur J Philos Sci. 2023;13(1):16.

with supposed penicillin allergies are treated similarly because of concern of cross-reactivity and an allergic response. The cross-reactivity of cephalosporins with penicillin allergy was originally thought to be approximately 10%, but more recent research indicates that it is likely closer to about 1% to 4%.<sup>10</sup> Cross-reactivity allergic response also depends on the generation of cephalosporin prescribed with the most likely chance of response occurring with the first-generation cephalosporins like Keflex (cephalexin, Advancis Pharmaceutical). There are five generations of cephalosporins, with an increase in gram-negative coverage as you go up in generation.<sup>1</sup> Third-generation cephalosporins are the mainstay treatment for patients with gonorrhea.

**Macrolides.** If patients have a penicillin allergy and you are hesitant in prescribing a cephalosporin, the macrolide group of antibiotics are a good alternative. Azithromycin, clarithromycin and erythromycin are prescribed to treat a variety of conditions including pneumonia, sinusitis, pharyngitis, tonsillitis and uncomplicated skin infections. Like any other antibiotic, macrolides carry a certain level of risk from typical adverse effects like nausea, vomiting, abdominal pain and diarrhea.<sup>13</sup>

As of 2021, azithromycin is no longer considered the mainstay treatment for chlamydia and gonorrhea. It is used in patients who are either allergic to or unable to take doxycycline (100 mg BID for seven days) or a ceftriaxone injection

(500mg or 1g if there is ocular involvement).<sup>14</sup>

Traditional management of meibomian gland dysfunction (MGD) has included the use of oral doxycycline. Two recent studies have demonstrated that azithromycin is equally if not more effective than doxycycline without the side effects of doxycycline (GI upset, photosensitivity). The first study compared a 30-day treatment with doxycycline vs. a five-day course of azithromycin, and both were found to improve signs and symptoms of MGD.<sup>15</sup> The second study demonstrated that a three-week course of weekly oral azithromycin was equivalent to a six-week course of oral doxycycline in treating moderate to severe MGD (Figure 3).<sup>16</sup> Azithromycin should be used with caution in patients who have a history of or taking medications for arrhythmias (specifically, QT interval prolongation).<sup>17</sup>

**Tetracyclines.** These have traditionally been used in the treatment of rickettsial infections, Lyme disease, acne and chlamydial infections.<sup>18</sup> Several conditions have an indication for doxycycline treatment, including ocular/acne rosacea, MGD, recurrent corneal erosion (RCE) and chronic corneal wounds. These medications have been shown to inhibit the production of pro-inflammatory mediators, thus reducing the production of inflammatory compounds, such as cytokines and chemokines, and matrix-metalloproteinases (MMP). Doxycycline and minocycline are the most frequently prescribed members of the

tetracycline group and are the most used tetracyclines in eye care.<sup>19</sup>

Tetracyclines can commonly cause GI distress, including abdominal discomfort, epigastric pain, nausea, vomiting and anorexia. Some patients experience photosensitivity, which can manifest as a red rash or skin blistering.<sup>18</sup> The tetracyclines, in particular minocycline, have been linked to an increased chance of patient's developing idiopathic intracranial hypertension (IIH).<sup>20</sup> Despite traditional wisdom, recent studies have demonstrated that there is a very low chance of teeth discoloration in children taking doxycycline. Recommendations have changed stating that doxycycline, but not other tetracyclines, can be used for short courses (<21 days) regardless of age. Clinicians should be aware of this because doxycycline use may extend to disease states apart from tick-borne illnesses in pediatric patients.<sup>21</sup> Remember the common dos and don'ts for taking doxycycline: avoid calcium and antacids, do not take before lying down, recommend sun protection and take with food.<sup>18</sup>

Trimethoprim/sulfamethoxazole (TMP-SMX) is available as a generic and branded (Bactrim, Roche or Septra, Pfizer). It is an antimicrobial used to treat and prevent many bacterial infections. It is probably most familiar to clinicians for being prescribed for patients with MRSA skin infection or suspects. The treatment of *Staphylococcus aureus* infections, including MRSA, is a non-FDA approved use of this medication. It comes in two dosages: standard strength, at 400mg of sulfamethoxazole and 80mg of trimethoprim dosed two pills every 12 hours, and double strength, which is 800mg/160mg dosed one pill every 12 hours and is more commonly used. Other treatments for MRSA include doxycycline (100mg BID for seven days), minocycline (200mg orally once, then 100mg orally twice daily) or clindamycin (450mg orally three times daily).<sup>22</sup>

TMP-SMX has many potential adverse side effects and interactions with other drugs to be aware of. The most common/serious possible adverse



reactions are the development of *Clostridium difficile* colitis, hyperkalemia (possible development of kidney stones), hypoglycemia, photosensitivity and—probably one of the most severe adverse events—bone marrow suppression, if combined with other folate-inhibiting medications such as methotrexate (first-line treatment for many rheumatological conditions). It is a sulfa-based drug, so the patient cannot have a sulfa allergy. Also, recommend drinking lots of fluids (to help kidney function) as well as sun protection and ensure the patient is not taking any other folate-inhibiting medications.<sup>23</sup>

### Antiviral Therapy

Herpes simplex virus (HSV) keratitis and herpes zoster ophthalmicus (HZO) are two of the more painful and potentially sight-threatening infections that an optometrist can encounter in practice (Figure 4).

HZO occurs due to the reactivation of the latent varicella-zoster virus (VZV). VZV primary infection most commonly occurs in childhood and is spread by airborne, droplet or direct transmission. HZO is secondary to the reactivation of the VZV typically decades after the initial infection. Ocular manifestations can include conjunctivitis, uveitis, episcleritis, keratitis and retinitis and is considered an ophthal-

mic emergency because of the potential of severe vision loss.

Antiviral therapy is required for treating these two. There are three oral antivirals available for treatment. For HSV keratitis, oral acyclovir (400mg five times daily) or valacyclovir (500mg three times daily) are both effective. Valacyclovir has the advantage of less frequent dosing and higher bioavailability but may be more expensive than acyclovir. Famciclovir (250mg to 500mg three times daily) may be used for allergic patients or resistant disease.<sup>24</sup> For HZO, acyclovir 800mg five times daily, valacyclovir 1000mg three times daily or famciclovir 500mg three times daily is recommended, and treatment is preferable within 72 hours of the outbreak.<sup>25</sup>

Acyclovir is remarkably well tolerated in most patients, though there are a couple of important considerations. Acute renal failure, produced by the precipitation of relatively insoluble acyclovir crystals in the renal tubules, is an occasional complication of intravenous therapy. Neurologic toxicity is a rare, reported condition that has included agitation, tremors, delirium, hallucinations and myoclonus typically occurring in patients with underlying renal failure.<sup>26</sup> Valacyclovir and famciclovir have similar side effects.

Vaccination with Shingrix (Glaxo-SmithKline) is indicated to reduce

the risk of developing herpes zoster and postherpetic neuralgia in those at increased risk for disease (immunocompetent individuals  $\geq 50$  years of age, immunocompromised patients  $\geq 19$  years of age at increased risk of herpes zoster). Shingrix requires two doses administered intramuscularly for protection with the second dose being administered two to six months after the first.<sup>27</sup>

### Oral Steroids

With the ever-expanding scope of practice for optometrists, the ability to prescribe oral steroids is now available in 44 states. Their potential for serious patient side effects cannot be overstated. Oral steroids work to control the body's immune response and help prevent damaging consequences such as scarring and neovascularization. Steroids are best suited for controlling acute inflammation whereas chronic inflammation is likely better managed with immunomodulators.<sup>28</sup>

Oral steroids (glucocorticoids) are used to treat a variety of anterior and posterior ocular conditions including non-infectious uveitis, periocular dermatitis, Bell's palsy, scleritis, thyroid eye disease, arteritic anterior ischemic optic neuropathy (giant cell) and optic neuritis.<sup>29</sup> The most common steroids prescribed by optometry are prednisone and methylprednisone.<sup>30</sup>

Dosing for oral corticosteroids is dependent on the patient's clinical presentation and course, but prednisone is commonly used at a dose of 0.5mg/kg to 1.5mg/kg daily. Typically, an initial dose of 20mg to 40mg of prednisone per day may be reasonable for mild inflammation; 40mg to 60mg per day might be considered for severe inflammation; and doses as high as 80mg to 100mg daily (or more) may be necessary for resistant inflammation 48 hours after the initial dose.<sup>31</sup>

A convenient way to prescribe an oral steroid for a patient is by using a Medrol Dosepak (Pfizer), as it delivers a higher dose of steroids on day one with a built-in tapering schedule that is easy to follow. Several retrospective reviews have shown long-term glucocorticoid

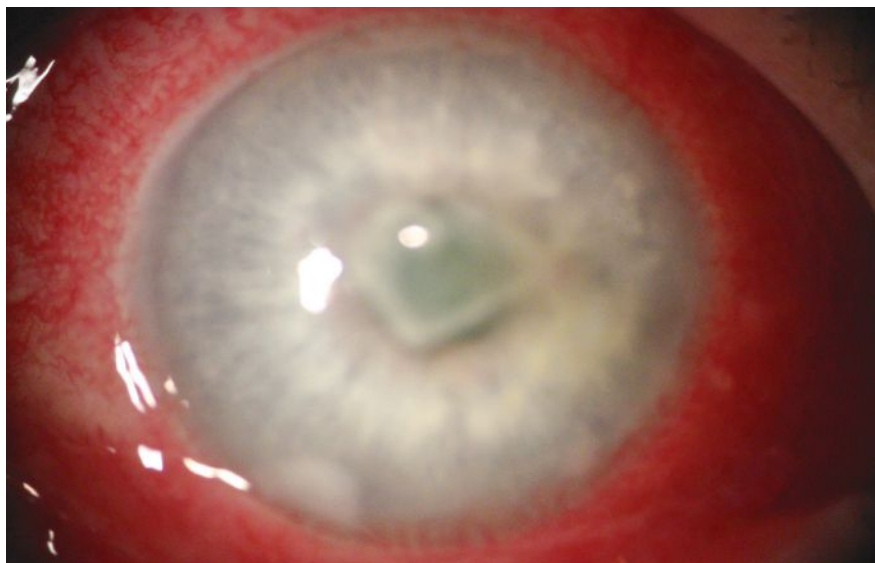
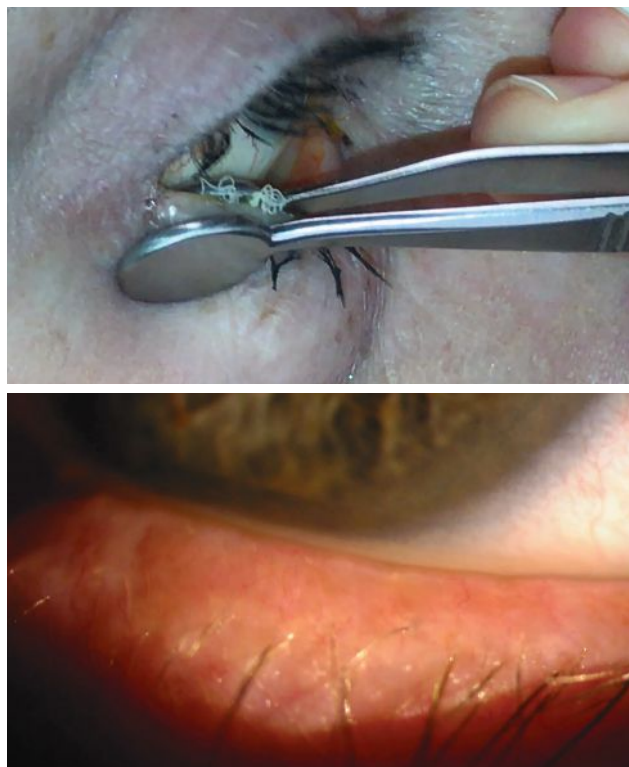


Fig. 2. Non-MRSA *Staph. aureus* corneal ulcer.



**Fig. 3. A three-week course of weekly oral azithromycin was deemed equivalent to a six-week course of oral doxycycline in treating moderate to severe MGD in a recent study.**

use, even in low doses, is a significant independent predictor of numerous adverse effects and that the risk is both dose- and duration-dependent. The daily dose of glucocorticoid is a key factor in toxicity, with higher doses carrying a higher risk of adverse effects. Longer duration of glucocorticoid therapy, and therefore higher cumulative doses, are associated with adverse effects.

However, even shorter-term glucocorticoid use may also be associated with serious adverse effects, particularly with higher doses.<sup>33</sup> There are many potential adverse side effects of glucocorticoid treatment and with removal from treatment. Some hyperglycemia (patients with diabetes will have elevated blood glucose levels), weight gain, thinning of the skin, fluid retention, hypertension, arrhythmias, GI complications, osteoporosis, sleep disorders, psychoses, mood disorders and well-known ophthalmic complications including cataracts, increased IOP, central serous chorioretinopathy and exophthalmos (Figure 5).<sup>32</sup>

## Pain Management

A common reason for patients to present to their eyecare professional is secondary eye pain. Nociceptive pain is often adequately managed with topical agents, whereas neuropathic pain is better managed with oral pain relievers and other adjunctive therapies.<sup>33</sup>

When considering oral pain management, the clinician has the choice of recommending either non-narcotic (e.g., acetaminophen, nonsteroidal anti-inflammatory drugs; NSAIDs, gabapentin) and narcotic agents (e.g., codeine, hydrocodone, oxycodone). In 1986 the World

Health Organization proposed an analgesic ladder for pain management. The “original” analgesic ladder included:

- **First step.** Mild pain: non-opioid analgesics such as NSAIDs or acetaminophen with or without adjuvants.
- **Second step.** Moderate pain: weak opioids (hydrocodone, codeine, tramadol) with or without non-opioid analgesics and with or without adjuvants.
- **Third step.** Severe and persistent pain: potent opioids (morphine, methadone, fentanyl, oxycodone, buprenorphine, tapentadol, hydromorphone, oxymorphone) with or without non-opioid analgesics and with or without adjuvants.<sup>34</sup>

The latest update to the analgesic ladder keeps the basic tenets of the original, with some additions:

- Oral dosing of drugs whenever possible (as opposed to intravenous, rectal, etc.).
- Around-the-clock rather than on-demand administration. The prescription must follow the pharmacokinetic characteristics of the drugs.

- Analgesics must be prescribed according to pain intensity as evaluated by a pain severity scale. For this purpose, a clinical examination must combine with an adequate pain assessment.

- Individualized therapy (including dosing) addresses the concerns of the patient. This method presupposes that there is no standardized dosage in pain treatment. This is probably the biggest challenge in pain medicine, as the dosology must be continuously adapted to the patient, balancing desired effects and possible side effects.

- Proper medication adherence, as any dosing alterations can lead to pain recurrence.<sup>35</sup>

When considering pain management, make sure you know the underlying cause for the pain. Over-the-counter (OTC) non-narcotics are recommended unless they will not adequately manage the patient’s pain over a 24-hour time period. These are indicated for patients with mild to moderate pain, while narcotic medications should only be considered for severe pain that is not able to be managed by other means and for the minimal time possible.<sup>35</sup>

Acetaminophen is one of the most widely used non-opioid analgesics and antipyretic agents used to treat pain and fever. Often, they are lumped into the same group as NSAIDs, but they lack the anti-inflammatory effects of the latter.<sup>36</sup>

- Regular strength: 325mg and is dosed at two tablets every four to six hours and not to exceed 10 pills in 24 hours (max 3250mg/day).

- Extra strength: 500mg and dosed two caplets every six hours, not to exceed six caplets in 24 hours (max 3000mg/day).

- Eight-hour relief: 650mg in each bi-layer and dosed at two bi-layer tablets every eight hours, not to exceed six bi-layer tablets in 24 hours (3900mg/day).

Patients can experience a variety of adverse side effects with the most serious being hepatotoxicity. Due to patients potentially taking multiple products that contain acetaminophen, the FDA limited the amount of

acetaminophen that can be found in a prescription product to 325mg (regular strength tablet). Other reactions that patients can have are skin rashes secondary to hypersensitivity and hematological/metabolic issues, though these are uncommon.<sup>36,37</sup>

NSAIDs are FDA-approved for use as antipyretic, anti-inflammatory and analgesic agents. The main mechanism of action of NSAIDs is the inhibition of the enzyme cyclooxygenase (COX). Non-selective NSAIDs have more potential to affect the GI mucosa and result in GI upset and even development of gastric ulcers, whereas the COX-2 selective NSAIDs that are more selective for inflammatory processes have less potential for GI disorders while still providing pain-reducing and anti-inflammatory properties.<sup>38</sup>

The most recommended OTC NSAIDs and their dosing are:

- Ibuprofen: 200mg tablets, one to two tablets every four to six hours while symptoms persist. The daily limit for ibuprofen is 1200mg.
- Aspirin regular strength: 325mg tablets, one to two tablets every four hours or three tablets every six hours. The daily limit for aspirin is 4000mg.
- Naproxen sodium: 220mg tablets, one to two tablets every eight to 12 hours. The daily limit for naproxen sodium is 660mg.<sup>38</sup>

For patients who have mild to moderate pain, a good option for controlling their pain is the alternation of acetaminophen and ibuprofen. The most common “algorithm” is alternating two pills of 325mg acetaminophen followed two hours later be two pills of 200mg ibuprofen and continuing until the pain has subsided. By alternating these medications every two hours, the patient will not exceed the typical dosing regimen of each of the medications individually which is every four hours. The analgesic action of acetaminophen and ibuprofen is limited by a ceiling effect when an increase in dose produces only a minor increment in effect and increases the chance of toxicity.<sup>39</sup>

With the current opioid epidemic, clinicians are looking for ways to treat

acute pain reliably without having to always default to an opioid. Several studies have demonstrated that a patient taking 1000mg of acetaminophen and 400mg of ibuprofen at the same time is equivalent to prescribing an opioid.<sup>40,41</sup>

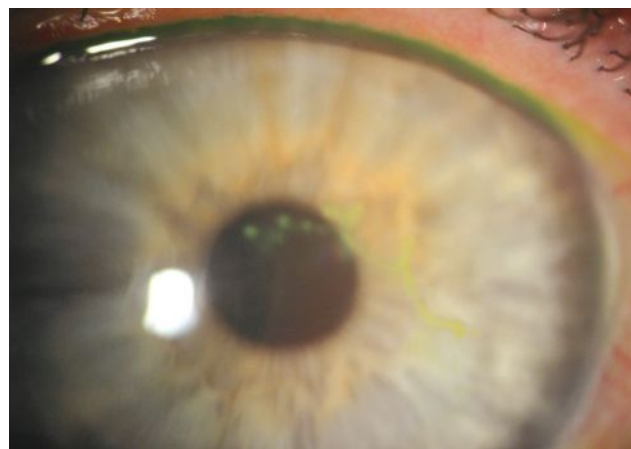
Prescriptions NSAIDs most used in optometric practice include:

- Indomethacin: available in 25mg, 50mg and 75mg capsules. Indicated for treatment of inflammatory conditions like scleritis; however, it is not commonly used as a pain medication, as patients do not like the side effects of the medication.

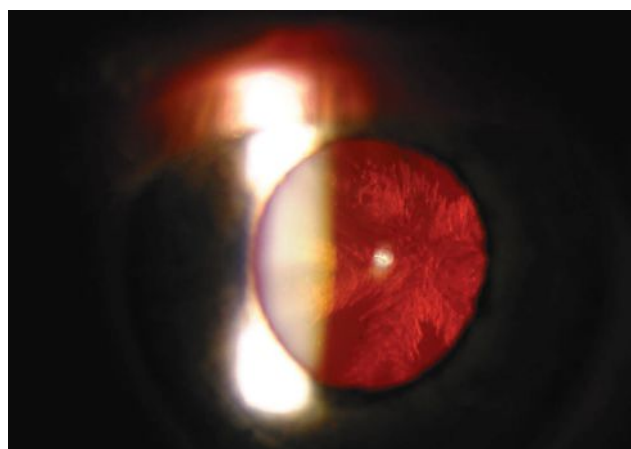
- Ketoprofen: available in 50mg and 75mg immediate release and 200mg extended release. Dosing can be 50mg orally four times a day or 75mg orally three times a day with maximum dose: 300mg/day. For extended release: 200mg orally once a day with maximum dose: 200mg/day.

- Celebrex (celecoxib, Pfizer) is available in 50mg, 100mg, 200mg and 400mg. Dosing is typically 200mg per day unless for acute pain, where it can be up to 400mg/day.<sup>42</sup>

NSAIDs have well-known adverse effects affecting the gastric mucosa, renal system, cardiovascular system, hepatic system and hematologic system. Gastric issues include GI upset, nausea and diarrhea with the most serious complication is the development of peptic ulcers. In order to prevent these problems, the patient should either be put on a proton pump inhibitor (*e.g.*, omeprazole) or switched to a COX-2



**Fig. 4. HSV with classic dendritic epithelial involvement.**



**Fig. 5. Posterior subcapsular cataract on retroillumination.**

selective NSAID. NSAIDs interfere with normal prostaglandin production which is crucial for kidney hemodynamics.

NSAIDs can also interfere with patients' blood pressure medications—especially diuretics. Patients who are on the maximum daily dose of NSAIDs for more than a couple of weeks can have decreased activity of their blood pressure medications. NSAIDs have been linked to increased chance of cardiovascular complications including myocardial infarction, thromboembolic events and atrial fibrillation. Diclofenac has been reported to be the one most linked to these complications. Hematological adverse effects are also possible especially with the non-specific NSAIDs, which can inhibit platelet aggregation but generally only affect those patients with pre-existing peptic ulcers or bleeding disorders.<sup>38</sup>



Gabapentin (Neurontin, Pfizer) is an anticonvulsive drug with FDA approval for post-herpetic neuralgia, adjunctive therapy for partial seizure and restless leg syndrome. It is used off-label for neuropathic pain, fibromyalgia, bipolar disorder, diabetic neuropathy pain, PTSD and a variety of other conditions. Herpes zoster pain and post-herpetic neuralgia (PHN) is the most likely condition where an optometrist would consider prescribing gabapentin.

Gabapentin at the federal level is not listed as a controlled drug, is considered a non-addictive medication and is considered by the CDC a substitute for opiates for chronic pain. However, there are growing concerns about its potential for misuse. Several states have moved gabapentin to a schedule V drug. A benefit of gabapentin use is its relatively mild side-effect profile. The most common side effects are fatigue, dizziness and headache but can increase to euphoria when combined with an opioid.

Initial treatment with gabapentin is usually started with one dose of 300mg/day in the evening and later increases the frequency to three times a day and dosage up to 1800mg/day. The effects are apparent in the first week of treatment but sometimes take about a month for significant improvement. Taper the dose over more than seven days to discontinue the medication.<sup>43</sup> Both gabapentinoids (*i.e.*, gabapentin and pregabalin) and tricyclic antidepressants (TCAs) have been found to be effective and generally well tolerated for PHN.<sup>43</sup> Pregabalin (Lyrica, Pfizer) can also be used for patients with PHN.

## Takeaways

There are many cases in which using oral medications strengthens patient care. To ensure care is maintained along the process, check in with your patient and discuss any anticipated effects and what the patient should do if those occur. Education regarding drug choice and treatment initiation, being up-to-date on legislative changes to controlled substances and monitoring an individual patient's use will be the best way to meet a patient's needs. ■

- Chaudhry SB, Veve MP, Wagner JL. Cephalosporins: a focus on side chains and  $\beta$ -lactam cross-reactivity. *Pharmacy (Basel)*. 2019;7(3):103.
- National Center for Emerging and Zoonotic Infectious Diseases. Is it really a penicillin allergy? Division of Healthcare Quality Promotion. [stacks.cdc.gov/view/cdc/82752](https://stacks.cdc.gov/view/cdc/82752). October 31, 2017. Accessed January 15, 2024.
- Khan DA, Banerji A, Blumenthal KG, et al. Drug allergy: a 2022 practice parameter update. *J Allergy Clin Immunol*. 2022;150(6):1333-93.
- Garza AZ, Park SB, Kocz R. Drug elimination. In: StatPearls [Internet]. Treasure Island (FL): StatPearls Publishing. [www.ncbi.nlm.nih.gov/books/NBK547662/](https://www.ncbi.nlm.nih.gov/books/NBK547662/). Last updated July 4, 2023. Accessed January 15, 2024.
- Sub Laban T, Saadabadi A. Monoamine Oxidase Inhibitors (MAOI) In: StatPearls [Internet]. Treasure Island (FL): StatPearls Publishing. [www.ncbi.nlm.nih.gov/books/NBK539848/](https://www.ncbi.nlm.nih.gov/books/NBK539848/). July 17, 2023. Accessed January 15, 2024.
- Edwards F, MacGowan A, Macnaughton E. Antimicrobial therapy: principles of use. *Medicine (Abingdon)*. 2021;49(10):624-31.
- Mohammed AA, Ali MM, Zenebe MH. Bacterial etiology of ocular and periocular infections, antimicrobial susceptibility profile and associated factors among patients attending eye unit of Shashemene comprehensive specialized hospital, Shashemene, Ethiopia. *BMC Ophthalmol*. 2020;20(1):124.
- Siddiqui AH, Koirala J. Methicillin-Resistant *Staphylococcus aureus*. In: StatPearls [Internet]. Treasure Island (FL): StatPearls Publishing. [www.ncbi.nlm.nih.gov/books/NBK482221/](https://www.ncbi.nlm.nih.gov/books/NBK482221/). Last updated April 2, 2023. Accessed January 15, 2024.
- Sarkar P, Yarlagadda V, Ghosh C, Haldar J. A review on cell wall synthesis inhibitors with an emphasis on glycopeptide antibiotics. *Medchemcomm*. 2017;8(3):516-33.
- Pandey N, Cascella M. Beta-Lactam Antibiotics. In: StatPearls [Internet]. Treasure Island (FL): StatPearls Publishing. [www.ncbi.nlm.nih.gov/books/NBK545311/](https://www.ncbi.nlm.nih.gov/books/NBK545311/). Last updated June 4, 2023. Accessed January 15, 2024.
- Penicillins (2nd generation) In: LiverTox: Clinical and Research Information on Drug-Induced Liver Injury [Internet]. Bethesda (MD): National Institute of Diabetes and Digestive and Kidney Diseases. [www.ncbi.nlm.nih.gov/books/NBK548033/](https://www.ncbi.nlm.nih.gov/books/NBK548033/). Last updated October 20, 2020. Accessed January 15, 2024.
- Kopacz K, Phadtare S. Probiotics for the prevention of antibiotic-associated diarrhea. *Healthcare (Basel)*. 2022;10(8):1450.
- Patel PH, Hashmi MF. Macrolides. In: StatPearls [Internet]. Treasure Island (FL): StatPearls Publishing. [www.ncbi.nlm.nih.gov/books/NBK551495/](https://www.ncbi.nlm.nih.gov/books/NBK551495/). Last updated May 16, 2024. Accessed January 15, 2024.
- Workowski KA, Bachmann LH, Chan PA, et al. Sexually transmitted infections treatment guidelines, 2021. *MMWR Recomm Rep*. 2021;70(4):1-187.
- Kashkoui MB, Fazel AJ, Kiavash V, et al. Oral azithromycin vs. doxycycline in meibomian gland dysfunction: a randomized double-masked open-label clinical trial. *Br J Ophthalmol*. 2015;99(2):199-204.
- Upaphong P, Tangmonkongvoragul C, Phinyo P. Pulsed oral azithromycin vs. six-week oral doxycycline for moderate to severe meibomian gland dysfunction: a randomized clinical trial. *JAMA Ophthalmol*. 2023;141(5):423-9.
- Graziani, Amy. Azithromycin and clarithromycin. UpToDate. Hooper, David (Ed). Wolters Kluwer. Last updated July 12, 2022. Accessed February 11, 2024.
- Shutter MC, Akhondi H. Tetracycline. In: StatPearls [Internet]. Treasure Island (FL): StatPearls Publishing. [www.ncbi.nlm.nih.gov/books/NBK549905/](https://www.ncbi.nlm.nih.gov/books/NBK549905/). Last updated June 5, 2023. Accessed January 15, 2024.
- Brunton LB, Lazo JS, Parker KL (eds.). Goodman & Gilman's The Pharmacological Basis of Therapeutics, 11th ed. Section VII. Chemotherapy of Microbial Diseases, Chapter 55. Protein Synthesis Inhibitors and Miscellaneous Antibacterial Agents. New York: McGraw-Hill; 2005.
- Passi SF, Butcher R, Orme DR, et al. Increased incidence of pseudotumor cerebri syndrome among users of tetracycline antibiotics. *J Neuroophthalmol*. 2022;42(3):323-7.
- Stultz JS, Eiland LS. Doxycycline and tooth discoloration in children: changing of recommendations based on evidence of safety. *Ann Pharmacother*. 2019;53(11):1162-6.
- Lowy F. Methicillin-resistant *Staphylococcus aureus* (MRSA) in adults: Treatment of skin and soft tissue infections. In: UpToDate, Spelman, Denis (Ed), Wolters Kluwer. Last updated November 29, 2023. Accessed February 11, 2024.
- Trimethoprim-sulfamethoxazole (co-trimoxazole): Drug information. In: UpToDate, Wolters Kluwer. Accessed December 28, 2023.
- Sugar A. Herpes simplex keratitis. In: UpToDate, Jacobs, Deborah and Hirsch, Martin (Ed), Wolters Kluwer. Accessed December 28, 2023.
- Albrecht MA. Herpes zoster treatment. In: UpToDate, Hirsch, Martin and Schmadre, Kenneth (Ed), Wolters Kluwer. Accessed December 28, 2023.
- Zachary KC. Acyclovir: an overview. In: UpToDate, Hirsch, Martin (Ed), Wolters Kluwer. Accessed on December 28, 2023.
- Albrecht MA, Levin MJ. Vaccination for prevention of shingles (herpes zoster) In: UpToDate, Hirsch, Martin (Ed), Wolters Kluwer. Accessed December 28, 2023.
- Bartlett JD, Jaanus KE. Clinical Ocular Pharmacology. Butterworth-Heinemann. 2008.
- Fung AT, Tran T, Lim LL, et al. Local delivery of corticosteroids in clinical ophthalmology: a review. *Clin Exp Ophthalmol*. 2020;48(3):366-401.
- Burriss J, Turner M. Know the ins and outs of oral steroids. *Rev Optom*. 2023;160(3):50-4.
- Dinh R and Do BK. Steroids options for treatment of uveitis. *Retinal Physician*. 2023;20:32-6.
- Saag K, Furst D. Major adverse effects of systemic glucocorticoids. In: UpToDate, Hirsch, Martin (Ed), Wolters Kluwer. Accessed on December 28, 2023.
- Rusciano D, Bagnoli P, Gallar J, Galor A. Editorial: eye pain: etiology and therapeutic approaches. *Front Pharmacol*. 2022;13:914809.
- Ventafredda V, Saita L, Ripamonti C, De Conno F. WHO guidelines for the use of analgesics in cancer pain. *Int J Tissue React*. 1985;7(1):93-6.
- Anekar AA, Hendrix JM, Cascella M. WHO analgesic ladder. In: StatPearls [Internet]. Treasure Island (FL): StatPearls Publishing. [www.ncbi.nlm.nih.gov/books/NBK554435/](https://www.ncbi.nlm.nih.gov/books/NBK554435/). Last updated April 23, 2023. Accessed February 11, 2024.
- Gerriets V, Anderson J, Nappe TM. Acetaminophen. In: StatPearls [Internet]. Treasure Island (FL): StatPearls Publishing. [www.ncbi.nlm.nih.gov/books/NBK482369/](https://www.ncbi.nlm.nih.gov/books/NBK482369/). Last updated June 20, 2023. Accessed February 11, 2024.
- Agrawal S, Khazaeni B. Acetaminophen toxicity. In: StatPearls [Internet]. Treasure Island (FL): StatPearls Publishing. [www.ncbi.nlm.nih.gov/books/NBK441917/](https://www.ncbi.nlm.nih.gov/books/NBK441917/). Last updated June 9, 2023. Accessed February 11, 2024.
- Ghlichloo I, Gerriets V. Nonsteroidal anti-inflammatory drugs (NSAIDs). In: StatPearls [Internet]. Treasure Island (FL): StatPearls Publishing. [www.ncbi.nlm.nih.gov/books/NBK547742/](https://www.ncbi.nlm.nih.gov/books/NBK547742/). Last updated May 1, 2023. Accessed February 11, 2024.
- Botting RM. Mechanism of action of acetaminophen: is there a cyclooxygenase 3? *Clin Infect Dis*. 2000;31 Suppl 5:S202-10.
- Lyngstad G, Skjelbred P, Swanson DM, Skoglund LA. Analgesic effect of oral paracetamol 1000mg/ibuprofen 400mg, paracetamol 1000mg/codeine 60mg, paracetamol 1000mg/ibuprofen 400mg/codeine 60mg or placebo on acute postoperative pain: a single-dose, randomized and double-blind study. *Eur J Clin Pharmacol*. 2023;79(8):1131-41.
- Slawson D. Ibuprofen plus acetaminophen equals opioid plus acetaminophen for acute severe extremity pain. *Am Fam Physician*. 2018;97(5):348.
- Schwenk, Eric. Nonopioid pharmacotherapy for acute pain in adults. In: UpToDate, Maniker, Robert (Ed), Wolters Kluwer. Accessed December 29, 2023.
- Yasaei R, Katta S, Saadabadi A. Gabapentin. In: StatPearls [Internet]. Treasure Island (FL): StatPearls Publishing. [www.ncbi.nlm.nih.gov/books/NBK493228/](https://www.ncbi.nlm.nih.gov/books/NBK493228/). Last updated December 19, 2022. Accessed February 11, 2024.

## It's Time to Talk to Your Patients about Digital Eye Strain

Exclusive U.S. consumer research shows screen time is still rising, digital eye strain is prevalent, and opportunity abounds for eye care professionals to help.

By Michele Andrews, OD

In today's world, digital devices are everywhere you turn. Smartphones make it easier than ever to be "on" from anywhere, at any time, and coupled with the regular use of computers, tablets, and e-readers, many people are spending significant portions of their days looking at screens—and their eyes are undoubtedly feeling the strain.<sup>1,2</sup>

A new research report from CooperVision, "A New Look at Digital Eye Strain," provides insights into current trends, the prevalence of digital eye strain, and the awareness of the condition among patients, revealing valuable opportunities for practitioners to help digital device-using patients (almost everyone!) while growing their contact lens practices.<sup>3</sup>

### Latest Trends in Digital Device Use

When asked to quantify their time in front of screens, over half of survey respondents said they spend on average six or more hours a day on digital devices, and one in four said they spend an average of a whopping nine hours or more looking at a screen.<sup>4,5</sup>



Smartphones were shown to be the most used, as 79% of respondents reported spending three hours or more on these devices.<sup>6</sup> **And for many, this behavior continues to rise, with 62% of participants noting their smartphone usage has greatly increased in the past two years.<sup>7</sup>**



While increased time on smartphones was the most prevalent, respondents reported escalating screen time on other devices as well.<sup>8</sup>

### How Common is Digital Eye Strain?

With predominant digital device use, it comes as no surprise that nearly **seven in 10** respondents reported **experiencing symptoms associated with digital eye strain**, with nearly **four in 10** saying they **experience symptoms multiple times per week or more.**<sup>9,10</sup>

While patients in the past may have been unaware that such symptoms were related to their digital device use—writing them off as “normal”—this no longer seems to be the case.<sup>11</sup> When asked to explain what causes their eye tiredness, nearly half of patients believed it was caused by screen time, indicating more substantial awareness of the connection between digital device use and ocular discomfort.<sup>12</sup>

### The Opportunity for ECPs to Help

**Survey results also revealed that today's patients are looking for solutions.** Of the respondents who have digital eye strain, 99% had tried at least one method for reducing symptoms associated with the condition.<sup>13</sup> Yet nearly 60% said they have never talked to an eye care professional about how digital device use affects their eyes.<sup>14</sup>

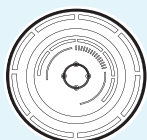Among those who had discussed digital eye strain with their eye care professional, only 19% said that contact lenses designed to help with the symptoms of digital eye strain had been recommended.<sup>15</sup> However, a majority of respondents said that they would be interested in these contact lenses—a well-defined opportunity to grow patient satisfaction and practice success.<sup>16</sup>

Most patients look to their eye care professionals for education and guidance on the latest innovations in eye care, and with so many patients experiencing digital eye strain, there is significant room for improvement. This starts with simply having a conversation and considering prescribing CooperVision **MyDay Energys**® daily disposable and **Biofinity Energys**® monthly replacement contact lenses, the only contact lenses to offer the unique combination of DigitalBoost™ Technology and Aquaform® Technology to help with eye tiredness and dryness associated with digital eye strain.<sup>17</sup>

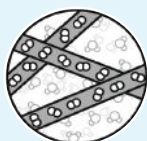


## Breakthrough Contact Lenses Designed to Take on the Challenge

MyDay Energys® and Biofinity Energys® combine an innovative aspheric lens design and advanced material technology to address eye tiredness and dryness associated with digital eye strain.



**DigitalBoost™ Technology** is a single vision aspheric lens design that delivers a +0.3D boost, which may help ease strain on eye muscles so the wearer can shift focus from on screen to off with less effort.<sup>\*18</sup> This design is unique to MyDay Energys® and Biofinity Energys®, making them the only contact lenses with DigitalBoost™ that can help with eye tiredness.



**Aquaform® Technology** retains water from core to surface without the need for surface coating or added wetting agents in the lens material,<sup>17</sup> resulting in incredible comfort, which can help eyes feel less dry, even during times of reduced blinking.

In studies, patients rated MyDay Energys® and Biofinity Energys® nine out of 10 for comfort, and eight out of 10 patients agreed that the lenses help reduce eye tiredness associated with digital eye strain.<sup>\*19-22</sup>

## Conclusion

It is safe to assume that virtually every patient in the chair is a digital device user. Prolific screen time will continue to be the norm in today's "always on" society, and these trends go hand in hand with two common symptoms associated with digital eye strain: tiredness and dryness.<sup>23</sup>

MyDay Energys® and Biofinity Energys® provide eye care professionals with the unique opportunity to prescribe an innovative lens that can help patients with the symptoms of digital eye strain, which the latest research shows they want—and need.



For more information and to download the full research report, visit [coopervision.com/practitioner](https://coopervision.com/practitioner).



\*Based on a statistically significant difference of the mean change in Accommodative Microfluctuations and when compared to a lens without DigitalBoost™/Digital Zone Optics® after reading on an iPhone 5 for 20 minutes held at a distance of 25 cm. Study conducted with Biofinity Energys and sphere.

†MyDay 8.8 vs 9.3 for MyDay Energys, p<0.01.

### References

All figures are from Prodege. Total sample size was 750 vision corrected adults ages 18-44 in the United States. Fieldwork was undertaken October 16-22, 2023. The survey was conducted online.

1. Coles-Brennan C, Sulley A, Young G. Management of digital eye strain. *Clinical and Experimental Optometry*. 2019;102(1):18-29.
2. Vision Council 2016 Digital Eye Strain Report: Eyes overexposed, the digital device dilemma.
3. CooperVision (February 2024). "A New Look at Digital Eye Strain". Report of online survey results (2023): N=750, Vision corrected patients. US Adults Ages 18-44 who wear corrective spectacles and/or contact lenses.
4. CVI data on file 2023. US online survey: N=750, Vision corrected patients. US Adults Ages 18-44 who wear corrective spectacles and/or contact lenses. 52% say they spend 6 hours or more.
5. CVI data on file 2023. US online survey: N=750, Vision corrected patients. US Adults Ages 18-44 who wear corrective spectacles and/or contact lenses. 25% say they send 9 hours or more.
6. CVI data on file 2023. US online survey: N=750, Vision corrected patients. US Adults Ages 18-44 who wear corrective spectacles and/or contact lenses. 62% greatly increased/increased for both work and personal use.
7. CVI data on file 2023. US online survey: N=750, Vision corrected patients. US Adults Ages 18-44 who wear corrective spectacles and/or contact lenses. 62% increased smart phone screen time, 41% increased TV screen time, 39% increased laptop screen time for both work and personal use.
8. CVI data on file 2023. US online survey: N=750, Vision corrected patients. US Adults Ages 18-44 who wear corrective spectacles and/or contact lenses. 31% experience at least once a week or less, 32% experience a few days a week and 6% experience every day.
9. CVI data on file 2023. US online survey: N=750, Vision corrected patients. US Adults Ages 18-44 who wear corrective spectacles and/or contact lenses. 6% experience digital eye strain every day.
10. CVI data on file 2023. US online survey: N=750, Vision corrected patients. US Adults Ages 18-44 who wear corrective spectacles and/or contact lenses. 70 percent of adults report "Digital Eye Strain."
11. Alexander, B. (2014, January 9). Read it and Blink: 70 percent of adults report "Digital Eye Strain." *NBCNews.com*. <https://www.nbcnews.com/health/health-news/read-it-blink-70-percent-adults-report-digital-eye-strain-fna2d11883909>
12. CVI data on file 2023. US online survey: n=586, Vision corrected patients US Adults Ages 18-44 who wear corrective spectacles and/or contact lenses and experience eye tiredness. 48% responded that excessive screen time is what causes their eye tiredness.
13. CVI data on file 2023. US online survey: N=516, Vision corrected patients US Adults Ages 18-44 who have digital eye strain at least once a week or less and who wear corrective spectacles and/or contact lenses.
14. CVI data on file 2023. US online survey: N=750, Vision corrected patients. US Adults Ages 18-44 who wear corrective spectacles and/or contact lenses. 58% haven't talked to their eye doctor.
15. CVI data on file 2023. US online survey: n=294, Vision corrected patients. US Adults Ages 18-44 who wear corrective spectacles and/or contact lenses and talked to their doctor about their digital eye strain.
16. CVI data on file 2023. US online survey: N=750, Vision corrected patients. US Adults Ages 18-44 who wear corrective spectacles and/or contact lenses. Regardless of recommendations from their eye doctor, 56% interested/very interested.
17. CVI data on file 2022.
18. Kajita M et al. Changes in accommodative micro-fluctuations after wearing contact lenses of different optical designs. *Cont Lens Ant Eye* (2020) In Press <https://doi.org/10.1016/j.clae.2020.03.003>.
19. CVI data on file 2018. Prospective, multi-center (5 US sites), open label, bilateral wear, one week dispensing study with MyDay® and MyDay Energys®.
20. CVI data on file 2022. US in market assessment survey conducted by ECPs: N=150, patients wearing Biofinity Energys® contact lenses.
21. CVI data on file 2018. Prospective, multi-center (5 US sites), open label, bilateral wear, one week dispensing study with MyDay Energys®. N=77 habitual soft CL wearers. When asked, "CLs make my eyes feel less tired" (slightly agree/agree/strongly agree).
22. CVI Data on file, 2016. Prospective, multi-center, subject-masked, bilateral, one month dispensing study in USA with Biofinity Energys® in existing Biofinity sphere wearers. N=52. After 2 weeks and after one month of wear.
23. "Computer Vision Syndrome" American Optometric Association.



# Driving Innovation, Defining Excellence: **LEADING THE MARKETPLACE FORWARD**

**W**e take pride in our longstanding commitment to excellence in readership, reach and influence in the vision care field with our print, digital and multi-platform (print/digital/virtual & live) education offerings. Our signature brands deliver a powerful and impactful marketing mix of print and digital marketing opportunities.

Jobson Optical Group brands are readers' most trusted source for news, product information, education, industry trends, research & surveying ECP's, business strategy and practice management insight.

For more information about products, services, and subscriptions, contact us at [info@jobson.com](mailto:info@jobson.com)

**Jobson**  
Optical Group

The vision to help you succeed

**20/20**

**WO**  
WOMEN IN OPTOMETRY®

**REVIEW**  
of OPHTHALMOLOGY

**Frames**  
Data®

**LT**

**Jobson OPTICAL**  
RESEARCH

**RCCL**  
REVIEW OF CORNEA  
& CONTACT LENSES

**my frame**  
GALLERY  
by Frames Data

**20/20**  
**PRO TO PRO**

**Review**  
MYOPIA  
MANAGEMENT

**REVIEW**  
of OPTOMETRY

**EyeRep**®

**Jobson**  
INTERACTIVE

**VM**  
VISION MONDAY

**Jobson**  
**creative**

**REVIEW**  
Education GROUP

**VM** LEADERSHIP  
SUMMIT

**RETINA**  
SPECIALIST

**Review**  
of Optometric  
Business

**Jobson**  
Event Services

**VMAIL**

**REVIEW**  
of PRESBYOPIA  
and the Aging Eye

**U.S. Pharmacist**  
The Pharmacist's Resource for Clinical Excellence

# EASE YOURSELF INTO MYOPIA MANAGEMENT

While it's true that going "all-in" on this new area of care can give you the most control over outcomes, novices can find ways to begin gradually and still see success.



BY ANDREW PUCKER, OD  
MILLEDGEVILLE, GA

The historical norm for treating myopic patients has been to alleviate their visual symptoms with spectacles, contact lenses (CLs) or refractive surgery.<sup>1,2</sup> While these modalities are highly effective at correcting visual blur, they have little to no impact on reducing the likelihood of developing vision-threatening conditions such as retinal detachments, glaucoma or cataracts, which may develop secondary to myopia later in life.<sup>3</sup> Myopic eyes specifically undergo abnormal axial elongation, which results in thinning of the posterior segment.<sup>4</sup> This thinning likely increases susceptibility to these ocular pathologies. Reducing a patient's final refractive error by just 1.00D decreases one's likelihood of developing maculopathies by about 40%.<sup>5</sup> Myopia management, which is the art of reducing myopic progression with pharmacological or optical means, easily has the potential to reduce a treated patient's refractive error by this amount.<sup>6,7</sup> However, it is still too new to



Helping children with contact lens insertion and removal helps ease their anxieties about beginning a myopia intervention.

fully evaluate this prediction.

Myopia management is quickly becoming recognized as the standard of care across the world, and the need for such treatments is ever more urgent as we approach three billion myopes worldwide.<sup>8,9</sup> With myopia being a hot topic in the clinic and laboratory over the past decade, there has been an ever-increasing amount of literature on this topic, which can make clinicians feel overwhelmed and may deter them

from breaking into this space, especially if they have not recently completed their clinical training. While admittedly there are a number of nuances to consider, one can easily begin treating this patient demographic after learning a few basic concepts. You can also start to gradually work myopia management into your practice and expand upon your offerings after you have gained some confidence, while simultaneously developing a new source of income.

#### About the author

**Dr. Pucker** is the senior director of clinical and medical sciences at Lexitas Pharma Services. He earned his OD, MS and PhD degrees from The Ohio State University. His independent research and clinical career have focused on dry eye disease, contact lenses and myopia development. Dr. Pucker is a Fellow and Diplomate of the American Academy of Optometry, Fellow of the Scleral Lens Education Society and Fellow of the British Contact Lens Association.

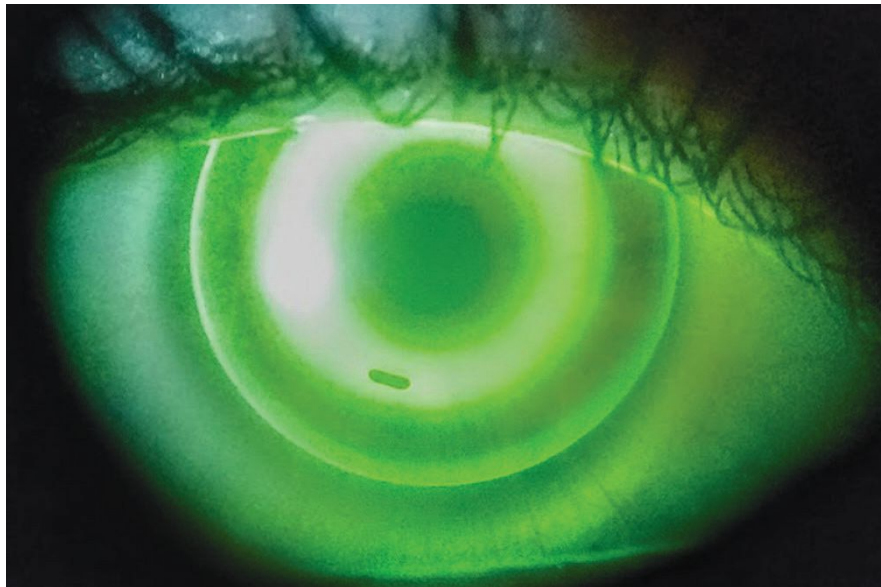
## Myopia Management Options

One of the most important skills to gain as a new myopia management practitioner is to simply understand your patient's treatment options. This section will highlight the options currently available in the United States as well as one option only in other markets, which should be available in the US soon. Armed with this knowledge, you can better treat and educate your patients.

- **Low-dose atropine.** While the community has long been aware that 1.0% atropine can substantially reduce myopic progression, 1.0% atropine typically results in untenable photophobia and accommodative paralysis, which has hampered its use in the US. Nevertheless, the Atropine for the Treatment of Myopia (ATOM) study has determined that while 1.0% atropine is able to better slow myopic progression than 0.01% concentrations over the first two years of treatment, both can significantly reduce myopic progression.<sup>10,11</sup> The ATOM study furthermore determined that 0.01% atropine has a minimal rebound effect after stopping treatment, which was not the case with 1.0% atropine. These data overall suggest that 0.01% atropine is more effective than 1.0% long-term while 0.1% atropine also had minimal side effects.

The Low-concentration Atropine for Myopia Progression (LAMP) study has since determined that 0.025% and 0.05% atropine are more effective at slowing myopic progression than 0.01% atropine. Because of this, many practitioners are now prescribing these higher concentrations.<sup>12,13</sup> While we have substantial research supporting the use of low-dose atropine for myopia management, its mechanism is still unclear.

Low-dose atropine may be the easiest treatment modality to incorporate into your practice because it requires minimal additional chair time and equipment. There is no FDA-approved low-dose atropine option in the US market but several are on the horizon, including NVK-002 (Vyluma), which is expecting FDA action imminently for its 0.01% atropine option.



**In this well-centered ortho-K lens at initial visit, note the small bubble under the return zone inferiorly. These can be ignored and will generally dissipate as the reshaping occurs in the first 24-hour period. You could also instruct the patient to overfill the lens with a viscous artificial tear prior to insertion.**

Myopia management practitioners would historically need to use a compounding pharmacy to prescribe low-dose atropine.<sup>14</sup> Research suggests that atropine concentrations can vary widely from one compounding pharmacy to another; thus, it is worth asking the pharmacist what the most prescribed concentrations are in your area.<sup>14</sup> It may also be worth asking other practitioners in your area about their concentration preferences and why they use the concentration they do. While not scientific, this anecdotal evidence may be useful for determining factors such as if the 0.05% atropine produced by your compounding pharmacy frequently results in side effects or if 0.01% atropine can meaningfully control myopic progression. Concentration variability should be less of an issue with the release of an FDA-approved product.

The community will likewise have data from the Childhood Atropine for Myopia Progression (CHAMP) study, supported by Vyluma, to directly reference.<sup>15</sup> This study furthermore suggests that low-dose atropine can be used in patients who are three years and older, showing that it has wonderful versatility in everyday practice.

- **Multifocal CLs.** This option has long been a mainstay of myopia management. Multifocal CLs are theorized to slow myopic progression by reducing peripheral hyperopic defocus.<sup>16</sup> Studies from investigators such as Smith et al. have determined specifically that the fovea is not essential for regulating myopic growth.<sup>17,18</sup> Related research suggests that providing plus power to the peripheral retina can act as an inhibitor to axial growth, likely by reducing peripheral hyperopic defocus/increasing peripheral myopic defocus.<sup>19</sup> The opposite effect can be observed by providing minus power to the peripheral retina. This theory has been supported by the success of center-distance multifocal CLs, which can simultaneously correct foveal refractive error while also reducing peripheral hyperopic defocus.<sup>16,20</sup>

Although there has been a plethora of multifocal CL studies displaying their effectiveness, the MiSight (daily disposable CLs) and Bifocal Lenses in Nearsighted Kids (BLINK) (monthly CLs) trials may be the best controlled and most important studies in the field.<sup>6,21</sup> Each trial has demonstrated a clinically meaningful reduction in myopic progression. Together, these studies



suggest that a +2.00D or +2.50D add is effective at slowing myopic progression, while contact lenses with an add power less than +2.00D may not produce clinically meaningful results.

Multifocal lenses can also be easily incorporated into a typical clinical practice. Some effective ones are already a part of everyday practice for treating presbyopic patients (*e.g.*, VTI NaturalVue Multifocal 1 Day, CooperVision Biofinity D monthly) and myopia management-specific lenses, such as the MiSight, are also now relatively easy to obtain.<sup>21</sup> Myopia management soft CLs are fitted and managed just like any other soft lens; therefore, you only need to rely upon your past training to start fitting these.

Nevertheless, one potential nuance with soft CLs is that not all practitioners are comfortable with fitting children in CLs. While this could be new territory for some ODs, an important point to keep in mind is that a practitio-

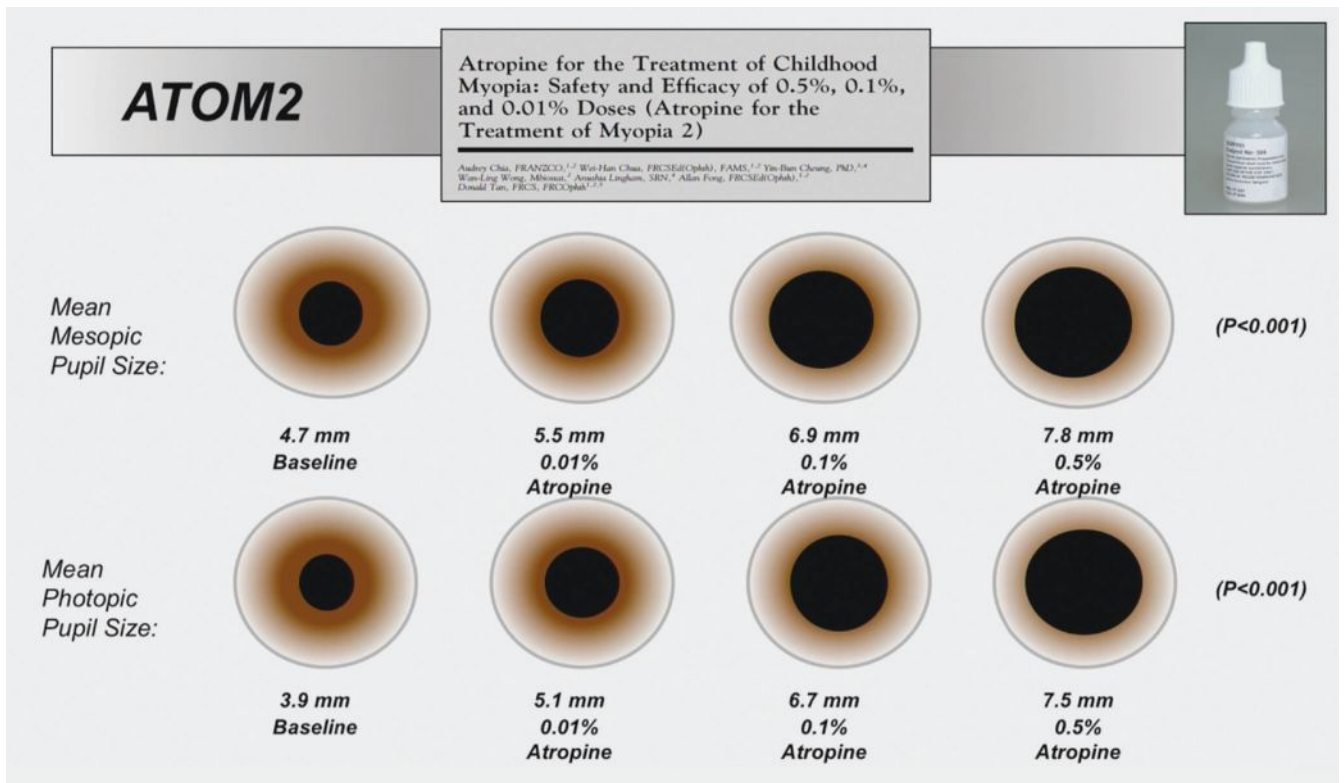
ner's judgement can typically be used to accurately determine if young patients will be good CL candidates (*e.g.*, patient is able to easily follow directions and complete a manifest refraction with a phoropter).<sup>22</sup> Clinical trials further suggest that patients eight years of age and older are good candidates and that, while kids may require more chair time to fit than adults CL wearers, much of this time is related to application and removal training, which can be delegated.<sup>20,22</sup>

Other helpful points to remember is that there are no clinically meaningful benefits to ramping up CL wear times over the first week compared to starting CL wear full-time; therefore, children should be given the choice. While fitting them into CLs may feel odd at first, kids who wear soft CLs are statistically less likely to develop an eye infection than young adults.<sup>23,24</sup>

- *Orthokeratology (ortho-K) lenses.*  
This mainstay of myopia management

is theorized to reduce myopic progression by reducing peripheral hyperopic defocus much like multifocal CLs.<sup>25</sup> Ortho-K likewise has been clinically shown to reduce myopic progression by a clinically meaningful amount.<sup>26,27</sup> Although there have been numerous studies on this topic, two of the most important are from Cho et al., who first demonstrated efficacy with ortho-K compared to spectacles, and later from Walline et al., who corroborated Cho et al.'s results by comparing ortho-K to soft lenses.<sup>26,27</sup> Research suggests that ortho-K can successfully be used in patients six years and older, yet practitioner judgement should again be used for patient selection.

Ortho-K may be the most challenging option to incorporate into a typical clinic because it requires a topographer to monitor lens fit, which would be a capital investment into the practice. Practitioners also need to be highly proficient with advanced



To mitigate the unwanted side effects, ATOM2 explored the nightly binocular treatment of lower concentrations of atropine (0.5%, 0.1%, or 0.01%) for two years. Historical data from ATOM1 was used as the control since it was considered unethical to withhold treatment after showing its efficacy. After two years, the researchers found that axial elongation and myopia progression were greater with lower concentrations (0.27mm, 0.30D with 0.5%; 0.28mm, 0.38D with 0.1%; and 0.41mm, 0.49D with 0.01%).

rigid lens fitting. Other challenges associated with fitting ortho-K are that it requires substantially more chair time (e.g., several follow-up visits, longer sessions) compared with soft CLs and that overnight wear of any contact lens comes with an increased risk of developing microbial keratitis.<sup>28,29</sup> While this increased risk is not dramatically worse than daily wear CLs, it should always be discussed with patients.<sup>28,29</sup>

With these considerations in mind, it may be best to wait to incorporate ortho-K until after the practice is proficient with prescribing other myopia management treatments unless you are already versed on fitting this modality. Nevertheless, if ortho-K does interest you and you need help getting started, you might want to consider contacting a lab who can assist you. The lab may even be willing to send a representative to your practice to help you see your first few patients.

• **Spectacles.** Gaining favor outside the US but not yet available here, new spectacle lens designs are also theorized to reduce myopic progression via the reduction of peripheral hyperopic defocus (e.g., Hoya MiyoSmart, Essilor Stellest).<sup>30</sup> Nevertheless, there is also a lens design that is aimed at slowing myopic progression by altering contrast sensitivity (SightGlass Vision from CooperVision).<sup>31</sup>

Research suggests that spectacles are easily accepted by patients and that they are highly effective at reducing myopic progression.<sup>30,31</sup> Some of the seminal work on myopia management spectacles comes from Lam et al., with their trial indicating about a 60% reduction in both refractive error and axial length over the first two years of treatment (Hoya, MiyoSmart).<sup>30</sup> When spectacles become available in the US, they will likely revolutionize pediatric clinical care. These lenses will specifically not require any additional chair time besides patient education and they will not carry any added risks such as the increased risk of microbial keratitis associated with CLs or the increased risk of photophobia or paralysis of accommodation associated with atropine use.<sup>10,29</sup>

Age (years)	Refractive Change/Year		Axial Length Change/Year	
	Non-Asian	Asian	Non-Asian	Asian
7	-0.98D	-1.12D	0.35mm	0.52mm
8	-0.82D	-0.94D	0.31mm	0.46mm
9	-0.69D	-0.78D	0.28mm	0.41mm
10	-0.56D	-0.66D	0.25mm	0.36mm
11	-0.45D	-0.56D	0.22mm	0.32mm
12	-0.35D	-0.50D	0.20mm	0.28mm

• **Combination treatments.** There is a plethora of research evaluating the combination of atropine with orthokeratology, multifocal CLs and/or spectacles.<sup>32-37</sup> While studies comparing combined atropine with ortho-K to atropine alone are numerous, data overall may suggest that most of the benefit of combination treatment occurs during the first six months of treatment.<sup>32,38,39</sup> It is unclear if there are benefits of combining atropine with other treatment modalities, and because of this, more research is needed on evaluating these combinations, especially with atropine concentrations greater than 0.01%.<sup>34</sup>

Although some patients may inquire about combination treatments, the current data and additional costs associated with using two myopia management interventions should be fully discussed with patients, and one should be well-versed in this literature before making the decision to advocate for this treatment option. With these points in mind, it may be best to avoid offering combination treatments as a first-line option.

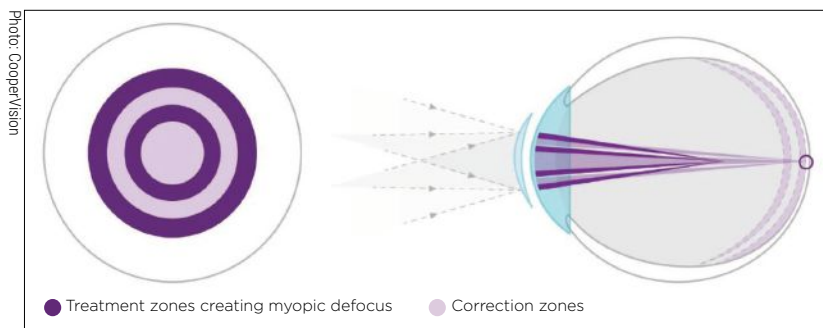
### Tracking Myopic Progression

Many practices use advanced technologies to track myopic progression. The simplest and most accurate method is to use a phoropter to complete a manifest refraction. This is likely the best approach for someone new to prescribing myopia management. It could even be applied to managing ortho-K patients who have had their refractive error negated by the treatment. With these patients, one would specifically complete a patient's ortho-K fit and determine their final refraction in the morning just after adap-

tation and lens removal. Practitioners can then compare refractive error at subsequent visits at a similar time of day to determine if there has been progression. This approach not only spares additional cost to the practitioner, but it will provide the OD with enough information to determine if there is a clinically meaningful change.

Cycloplegic autorefraction can yield an unbiased measure of refractive error and is more repeatable than a manifest refraction, especially when there is more than one practitioner managing a patient. Since most practices have an autorefractor, this information could be easily collected by a new myopia management practitioner and be used as additional data to inform upon if there has been myopic progression.

After practitioners have had some time to incorporate myopia management, they might want to consider adding an optical biometer to monitor axial length progression. Excessive axial length is the primary factor increasing the likelihood of developing ocular comorbidities. Evaluating axial length is attractive because it can help understand the potential risk of developing these ocular comorbidities (>26mm is considered high myopia).<sup>40</sup> This measure could also be helpful because axial length may increase even with a stable refractive error as part of normal emmetropization.<sup>41</sup> In fact, young emmetropes typically have an axial length increase of about 0.1mm/year.<sup>41</sup> Even further, if axial length has stopped changing, this could be an indicator that a patient's eye has stopped growing, which could suggest a potential time to taper or stop myopia management treatment.



**The MiSight 1 Day lens uses what the manufacturer calls “ActivControl technology,” consisting of two discrete rings with a +2.00D add (dark purple) to create myopic defocus on the retina.**

While an optical biometer is nice to have, it is not at all required because change in myopic refractive error and axial length are highly correlated.<sup>42</sup> Said another way, one can use refractive error as a surrogate for axial length if an optical biometer is not available. With this in mind, one can determine if a treatment is successfully working by either evaluating refractive error or axial length. The OD could specifically note the patient’s age and compare their refractive error to norms (*Table 1*) and determine if the treatment is successful (*e.g.*, biometric changes are less than the norms for a given age).<sup>43</sup>

A final point related to progression comes from the Correction of Myopia Evaluation Trial study, which suggests that virtually all patients who are 10 years old or younger are progressing; thus, there is little need to wait to determine if there is progression to treat in this group if they are already myopic.<sup>44</sup>

## Attracting Patients

While there is scant research on myopia management patient recruitment in an everyday clinic, anecdotally it is common practice to begin by recruiting existing patients from one’s own practice. This approach will not require one to make dramatic practice pattern changes or to spend extra money on recruitment campaigns. Once you are more comfortable with myopia management, you may then want to incorporate this offering on your website along with some patient education on this topic, given that the public may not be fully aware of all the options or benefits.

It is the prescribing clinician’s duty to educate patients and their families about all their treatment options; however, the time burden associated with this can be easily shared with trained staff members. Although it may not be realistic to have all staff within a practice well-versed, one could start by educating yourself and subsequently one additional staff member who has an interest in the topic, so they can help recruit patients and educate them on starting a program.

## Patient Burden

There is an unfortunate cost and time burden for the patient and their families. While generally not covered by insurance, there are some aspects that may be. For example, a few rare states cover low-dose atropine under Medicaid. Contact lens

materials can likely be partially covered with many plans. One additional consideration is that it may be best to break up myopia management fees (*e.g.*, materials, contact lens fitting fee) to allow for lens material benefits to be applied while also avoiding an insurance company from discounting the full management fee down to a contact lens fit fee.

Although there is currently limited insurance coverage for myopia management modalities, this will likely change as more data emerges and more treatments are approved by the FDA. Until that changes, clinicians might want to consider developing an internal patient assistant

program to provide an economical myopia management program for those who are unable to afford the full costs of care.

## Takeaways

Myopia management has come of age, and it is time for it to be part and parcel with primary care optometry. It does not require you to be a key opinion leader in the field, have access to every journal article or have extensive capital equipment—it can simply start by taking an interest, making a plan and acting upon it. This simple plan can then grow more elaborate with your skill level and practice while providing your patients with much needed care to improve their visual and ocular health outcomes. ■

1. Remington LA. Clinical anatomy of the visual system. 2nd ed. Boston: Butterworth-Heinemann; 2005.
2. Javitt JC, Chiang YP. The socioeconomic aspects of laser refractive surgery. Arch Ophthalmol. 1994;112(12):1526-30.
3. Flitcroft DI. The complex interactions of retinal, optical and environmental factors in myopia aetiology. Prog Retin Eye Res. 2012;31(6):622-60.
4. Funata M, Tokoro T. Scleral change in experimentally myopic monkeys. Graefes Arch Clin Exp Ophthalmol. 1990;228(2):174-9.
5. Bullimore MA, Brennan NA. Myopia control: Why each diopter matters. Optom Vis Sci. 2019;96(6):463-5.
6. Chamberlain P, Peixoto-de-Matos SC, Logan NS, et al. A three-year randomized clinical trial of MiSight lenses for myopia control. Optom Vis Sci. 2019;96(8):556-67.
7. Chamberlain P, Bradley A, Arumugam B, et al. Long-term effect of dual-focus contact lenses on myopia progression in children: a six-year multicenter clinical trial. Optom Vis Sci. 2022;99(3):204-12.
8. World Council of Optometry. Resolution: the standard of care for myopia management by optometrists. [www.worldcouncilofoptometry.info/resolution-the-standard-of-care-for-myopia-management-by-optometrists](http://www.worldcouncilofoptometry.info/resolution-the-standard-of-care-for-myopia-management-by-optometrists). Accessed January 2, 2024.
9. Holden BA, Fricke TR, Wilson DA, et al. Global prevalence of myopia and high myopia and temporal trends from 2000 through 2050. Ophthalmology. 2016;123(5):1036-42.
10. Chia A, Chua WH, Cheung YB, et al. Atropine for the treatment of childhood myopia: safety and efficacy of 0.5%, 0.1% and 0.01% doses (Atropine for the treatment of Myopia 2). Ophthalmology. 2012;119(2):347-54.
11. Chia A, Chua WH, Wen L, et al. Atropine for the treatment of childhood myopia: changes after stopping atropine 0.01%, 0.1% and 0.5%. Am J Ophthalmol. 2014;157(2):451-7.e1.
12. Yam JC, Jiang Y, Tang SM, et al. Low-concentration atropine for myopia progression (LAMP) study: a randomized, double-blinded, placebo-controlled trial of 0.05%, 0.025% and 0.01% atropine eye drops in myopia control. Ophthalmology. 2019;126(1):113-24.
13. Yam JC, Li FF, Zhang X, et al. Two-year clinical trial of the low-concentration atropine for myopia progression (LAMP) study: phase 2 report. Ophthalmology. 2020;127(7):910-9.
14. Richdale K, Tomiyama ES, Novack GD, Bullimore MA. Compounding of low-concentration atropine for myopia control. Eye Contact Lens. 2022;48(12):489-92.
15. Zadnik S, Schulman E, Flitcroft I, et al. Efficacy and safety of 0.01% and 0.02% atropine for the treatment of pediatric myopia progression over three years: a randomized clinical trial. JAMA Ophthalmol. 2023;141(10):990-9.



16. Berntsen DA, Kramer CE. Peripheral defocus with spherical and multifocal soft contact lenses. *Optom Vis Sci.* 2013;90(11):1215-24.
17. Smith EL 3rd, Hung LF, Huang J. Relative peripheral hyperopic defocus alters central refractive development in infant monkeys. *Vision Res.* 2009;49(19):2386-92.
18. Smith EL 3rd, Ramamirtham R, Qiao-Grider Y, et al. Effects of foveal ablation on emmetropization and form-deprivation myopia. *Invest Ophthalmol Vis Sci.* 2007;48(9):3914-22.
19. Schaeffel F, Glasser A, Howland HC. Accommodation, refractive error and eye growth in chickens. *Vision Res.* 1988;28(5):639-57.
20. Walline JJ, Lindsley KB, Vedula SS, et al. Interventions to slow progression of myopia in children. *Cochrane Database Syst Rev.* 2020;1(1):CD004916.
21. Walline JJ, Walker MK, Mutti DO. Effect of high add power, medium add power or single-vision contact lenses on myopia progression in children: the BLINK randomized clinical trial. *JAMA.* 2020;324(6):571-80.
22. Walline JJ, Jones LA, Rah MJ, et al. Contact lenses in pediatrics (CLIP) study: chair time and ocular health. *Optom Vis Sci.* 2007;84(9):896-902.
23. Pucker AD, Steele S, Rueff E, et al. Contact lens adaption in neophytes. *Optom Vis Sci.* 2021;98(3):266-71.
24. Wagner H, Richdale K, Mitchell GL, et al. Age, behavior, environment and health factors in the soft contact lens risk survey. *Optom Vis Sci.* 2014;91(3):252-61.
25. Nti AN, Berntsen DA. Optical changes and visual performance with orthokeratology. *Clin Exp Optom.* 2020;103(1):44-54.
26. Walline JJ, Jones LA, Sinnott LT. Corneal reshaping and myopia progression. *Br J Ophthalmol.* 2009;93(9):1181-5.
27. Cho P, Cheung SW, Edwards M. The longitudinal orthokeratology research in children (LORIC) in Hong Kong: a pilot study on refractive changes and myopic control. *Curr Eye Res.* 2005;30(1):71-80.
28. Bullimore MA, Sinnott LT, Jones-Jordan LA. The risk of microbial keratitis with overnight corneal reshaping lenses. *Optom Vis Sci.* 2013;90(9):937-44.
29. Stapleton F, Keay L, Edwards K, Holden B. The epidemiology of microbial keratitis with silicone hydrogel contact lenses. *Eye Contact Lens.* 2013;39(1):79-85.
30. Lam CS, Tang WC, Lee PH, et al. Myopia control effect of defocus incorporated multiple segments (DIMS) spectacle lens in Chinese children: results of a three-year follow-up study. *Br J Ophthalmol.* 2022;106(8):1110-4.
31. Rappon J, Chung C, Young G, et al. Control of myopia using diffusion optics spectacle lenses: 12-month results of a randomised controlled, efficacy and safety study (CYPRESS). *Br J Ophthalmol.* 2023;107(11):1709-15.
32. Kinoshita N, Konno Y, Hamada N, et al. Efficacy of combined orthokeratology and 0.01% atropine solution for slowing axial elongation in children with myopia: a two-year randomized trial. *Sci Rep.* 2020;10(1):12750.
33. Zhao Q, Hao Q. Clinical efficacy of 0.01% atropine in retarding the progression of myopia in children. *Int Ophthalmol.* 2021;41(3):1011-7.
34. Jones JH, Mutti DO, Jones-Jordan LA, Walline JJ. Effect of combining 0.01% atropine with soft multifocal contact lenses on myopia progression in children. *Optom Vis Sci.* 2022;99(5):434-42.
35. Erdinest N, London N, Lavy I, et al. Low-concentration atropine monotherapy vs. combined with MiSight 1 Day contact lenses for myopia management. *Vision (Basel)* 2022;6(4):73.
36. Nucci P, Lembo A, Schiavetti I, et al. A comparison of myopia control in European children and adolescents with defocus incorporated multiple segments (DIMS) spectacles, atropine, and combined DIMS/atropine. *PLoS One.* 2023;18(2):e0281816.
37. Huang Z, Chen XF, He T, et al. Synergistic effects of defocus-incorporated multiple segments and atropine in slowing the progression of myopia. *Sci Rep.* 2022;12(1):22311.
38. Yu S, Du L, Ji N, et al. Combination of orthokeratology lens with 0.01% atropine in slowing axial elongation in children with myopia: a randomized double-blinded clinical trial. *BMC Ophthalmol.* 2022;22(1):438.
39. Tan Q, Ng AL, Cheng GP, et al. Combined 0.01% atropine with orthokeratology in childhood myopia control (AOK) study: a two-year randomized clinical trial. *Cont Lens Anterior Eye.* 2023;46(1):101723.
40. Ohno-Matsui K, Wu PC, Yamashiro K, et al. IMI pathologic myopia. *Invest Ophthalmol Vis Sci.* 2021;62(5):5.
41. Chamberlain P, Lazon de la Jara P, Arumugam B, Bullimore MA. Axial length targets for myopia control. *Ophthalmic Physiol Opt.* 2021;41(3):523-31.
42. Mutti DO, Hayes JR, Mitchell GL, et al. Refractive error, axial length and relative peripheral refractive error before and after the onset of myopia. *Invest Ophthalmol Vis Sci.* 2007;48:2510-9.
43. Nixon A, Brennan N. Managing Myopia: A Clinical Response to the Growing Epidemic. Johnson & Johnson Vision 2020. April 13, 2021. Accessed January 2, 2024. [www.jnjvisionpro.com/education-center/resource-library/managing-myopia-clinical-response-growing-epidemic](http://www.jnjvisionpro.com/education-center/resource-library/managing-myopia-clinical-response-growing-epidemic).
44. Group C. Myopia stabilization and associated factors among participants in the Correction of Myopia Evaluation Trial (COMET). *Invest Ophthalmol Vis Sci.* 2013;54(13):7871-84.

# Take Your Practice to the Next Level

Integrate the latest in biomarker technology and proven nutraceutical solutions with the Zx Pro™ and the

 **Zea Performance System™.**



Macular pigment optical density (MPOD) measurement provides valuable risk factor information for eye and overall health. With the Zx Pro™, you can effectively and efficiently measure MPOD levels directly in the eye. You can help patients increase MPOD by prescribing EyePromise® nutraceuticals, remeasuring to track progress along the way.



**Learn how the Zea Performance System elevates your practice.**

**EyePromise**

# OCT BEYOND THE BASICS: UNLOCK THE POWER OF THIS ESSENTIAL TOOL

How to maximize use of this instrument based on the specific pathology at hand.



BY LEE VIEN, OD,  
AND DAVID YANG, OD  
PALO ALTO, CA

Optical coherence tomography (OCT) is an essential imaging test in the diagnosis and management of ocular pathology. It provides us clinicians with quantitative and qualitative information to help detect structural damage and is now used routinely to evaluate a variety of ocular conditions, including glaucoma and retinal disorders. Over the last 20 years, numerous multicenter, prospective clinical trials have employed OCT findings as their study endpoints. Their results have created new practice guidelines including the use of OCT to guide the management of retinal conditions such as diabetic macular edema, vitreomacular interface disorders and screening for hydroxychloroquine maculopathy.<sup>1,2</sup>

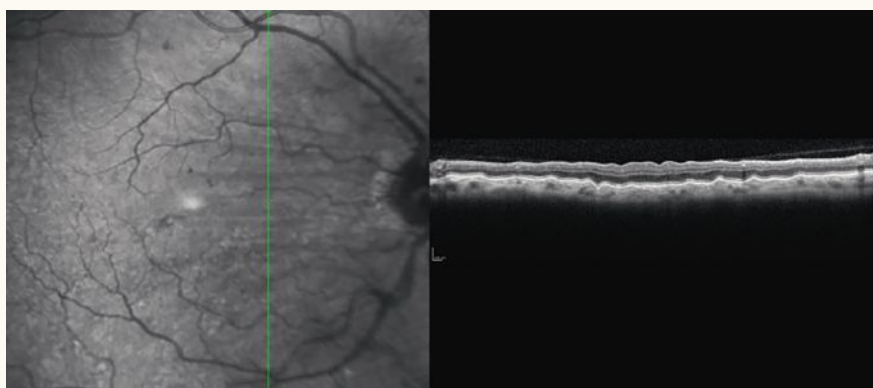
Although many optometric practices have an OCT, clinicians may not fully use their OCT instruments to obtain the best possible data when imaging a patient with ocular pathology. Provid-

ers often rely exclusively on preset scans provided by their instruments. These scans are adequate to screen for most suspected ocular pathologies. However, due to the fast acquisition and often low resolution of these scans, retinal pathology could be missed, particularly if the lesion is located between the displaced line scans or would be better visualized in a different orientation.

This article will walk through various ocular pathologies and discuss how to best use OCT scans and analyses to optimize clinical evaluations.

## Choroidal Folds

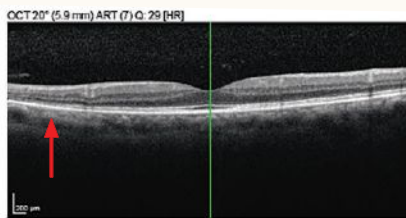
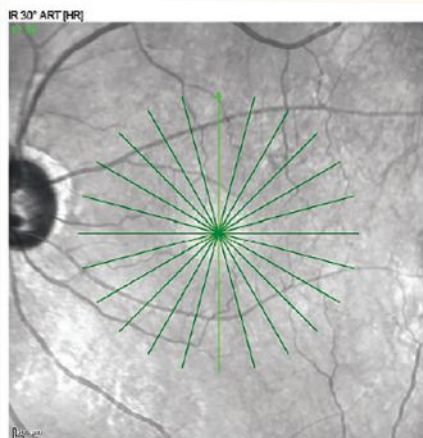
Ocular pathologies present with a specific pattern of damage and using preset OCT scans may miss detection of that disease. An example is using preset scans with horizontal line cuts on a patient with choroidal folds. These phenomena are usually arranged parallel in a horizontal fashion, and therefore, using only OCT horizontal line scans may not detect the folds.<sup>3</sup> To best detect horizontally oriented choroidal folds, multiple vertical high resolution line scans should be used. OCT instruments that generate data for both



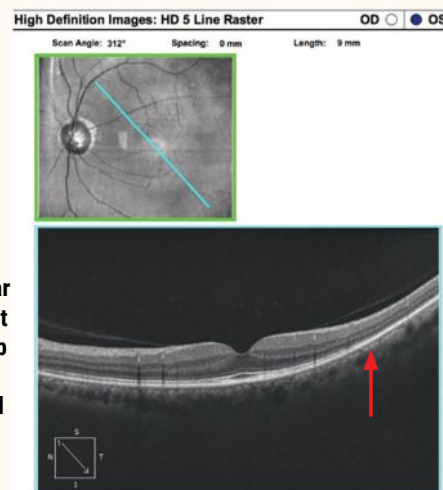
Choroidal folds imaged with high-resolution vertical line scan.

### About the authors

**Dr. Vien** is the director of optometry clinic operations and co-residency coordinator at the VA Palo Alto Healthcare System. He is an assistant clinical professor at Herbert Wertheim School of Optometry & Vision Science at UC Berkeley and Southern California College of Optometry at Marshall B. Ketchum University. Dr. Vien is also an affiliate clinical instructor at the Stanford School of Medicine. **Dr. Yang** is the chief of the optometry section and co-residency coordinator at the VA Palo Alto Healthcare System. He is also a clinical professor at Herbert Wertheim School of Optometry & Vision Science and an affiliated clinical instructor at the Stanford School of Medicine. They have no financial disclosures.



**Hydroxychloroquine maculopathy with pericentral retinopathy. Spectralis SD-OCT Star scan (left image). Mild EZ disruption is present at the edge of the 6mm line scan inferiorly (top image). In the Cirrus HD 9mm line scan, note the loss of EZ inferotemporal in the pericentral retina (right images).**



horizontal and vertical scans in a single acquisition can detect choroidal folds in different orientations. The folds can also be visualized on OCT instruments that provide a retinal pigment epithelium (RPE) layer map.

## Hydroxychloroquine Maculopathy

High-definition scans are the top choice when detecting hydroxychloroquine toxicity to best visualize the interdigitation zone and ellipsoid zone. The initial paracentral area of involvement in hydroxychloroquine maculopathy may not be strictly nasal, temporal, superior or inferior. In a small study of hydroxychloroquine maculopathy

eyes, it was found that the first area of parafoveal damage on SD-OCT was most often the inferotemporal quadrant.<sup>4</sup> Therefore, horizontal or vertical line scans through the paracentral retina may miss early damage. Instead, a combination of horizontal, vertical and radial scans should be completed to screen for hydroxychloroquine maculopathy.

In a large multi-provider analysis on patients diagnosed with hydroxychloroquine maculopathy, more than 50% of Asian patients in the study had pericentral retinopathy without parafoveal involvement.<sup>5</sup> To screen for pericentral retinopathy on OCT,

wide-angle scans—such as 9mm or 12mm HD line scans in different orientations, especially out to the vascular arcades—should be used when accessible. If widefield imaging cannot be performed, scans can also be moved to accommodate pericentral lesions.

## Pachychoroid Diseases

Enhanced-depth imaging (EDI) technology may not be a preset setting, but it is easily obtained using HD scans of the choroid. This type of imaging improves visualization of the choroidal structures and the sclerochoroidal junction. EDI is especially important in

### OCT Beyond the Basics: Unlocking the Power of This Essential Tool

Jointly provided by Postgraduate Institute for Medicine (PIM) and Review Education Group

**Release Date:** March 15, 2024

**Expiration Date:** March 15, 2027

**Estimated Time to Complete Activity:** two hours

**Target Audience:** This activity is intended for optometrists who want to learn how to maximize use of this instrument based on the specific pathology at hand.

**Educational Objectives:** After completing this activity, participants should be better able to:

- Effectively use OCT scans and analyses in clinical practice.
- Recognize the strengths and limitations of various OCT options.
- Determine which type of OCT is the best option for various ocular pathologies.
- Distinguish between newer technologies and understand the role of each.

**Faculty:** Lee Vien, OD, and David Yang, OD

**Disclosure of Conflicts of Interest:** PIM requires faculty, planners and others in control of educational content to disclose all their financial relationships with ineligible companies. All identified conflicts of interest are thoroughly vetted and mitigated according to PIM policy. PIM is committed to providing its learners with high-quality, accredited CE activities and related materials that promote improvements or quality in health care and not a specific proprietary business interest of an ineligible company.

Those involved reported the following relevant financial relationships with ineligible entities related to the educational content of this CE activity: *Faculty* – Drs. Vien and

Yang do not have nothing to disclose. *Planners and Editorial Staff* – PIM has nothing to disclose. The Review Education Group has nothing to disclose.

**Accreditation Statement:** In support of improving patient care, this activity has been planned and implemented by PIM and the Review Education Group. PIM is jointly accredited by the Accreditation Council for Continuing Medical Education, the Accreditation Council for Pharmacy Education and the American Nurses Credentialing Center to provide CE for the healthcare team. PIM is accredited by COPE to provide CE to optometrists.

**Credit Statement:** This course is COPE-approved for two hours of CE credit. Activity #127833 and course ID 89897-GO. Check with your local state licensing board to see if this counts toward your CE requirement for relicensure.

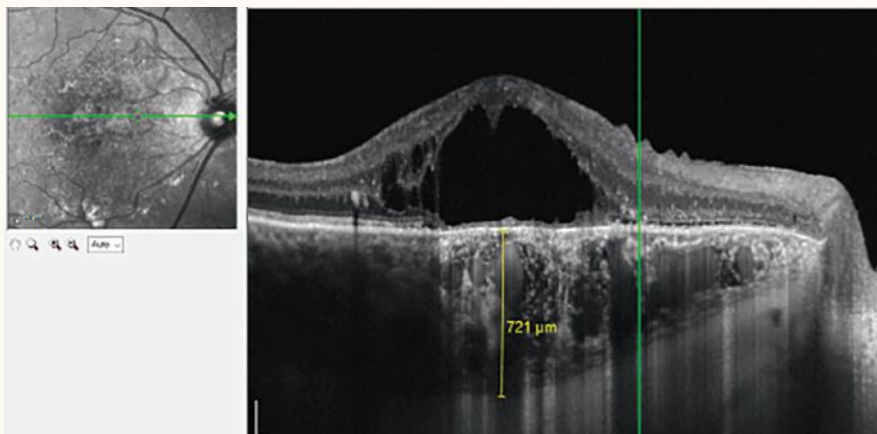
**Disclosure of Unlabeled Use:** This educational activity may contain discussion of published and/or investigational uses of agents that are not indicated by the FDA. The planners of this activity do not recommend the use of any agent outside of the labeled indications. The opinions expressed in the educational activity are those of the faculty and do not necessarily represent the views of the planners. Refer to the official prescribing information for each product for discussion of approved indications, contraindications and warnings.

**Disclaimer:** Participants have an implied responsibility to use the newly acquired information to enhance patient outcomes and their own professional development. The information presented in this activity is not meant to serve as a guideline for patient management. Any procedures, medications or other courses of diagnosis or treatment discussed or suggested in this activity should not be used by clinicians without evaluation of their patient's condition(s) and possible contraindications and/or dangers in use, review of any applicable manufacturer's product information and comparison with recommendations of other authorities.



JOINTLY ACCREDITED PROVIDER  
INTERPROFESSIONAL CONTINUING EDUCATION





**Chronic central serous chorioretinopathy with pachychoroid imaged with EDI OCT. There is a thin choriocapillaris and Sattler's layer overlying the dilated Haller's layer.**

diagnosing pachychoroid diseases, such as central serous chorioretinopathy and polypoidal choroidal vasculopathy.<sup>6</sup> Often, this feature is not turned on when running OCT scans and clinicians miss valuable choroidal details that can support the diagnosis.

The importance of differentiating pachychoroid diseases from age-related macular degeneration (AMD) is essential as the disease course and management differs between the two conditions. In pathologies such as

adult-onset vitelliform macular dystrophy, a thicker choroid can help differentiate between this condition and AMD.<sup>7</sup> In OCT devices without EDI, visualization of the choroid can be improved via a standard high-definition scan focused closer to the eye until the image is inverted or a scan done higher than the recommended reference lines.

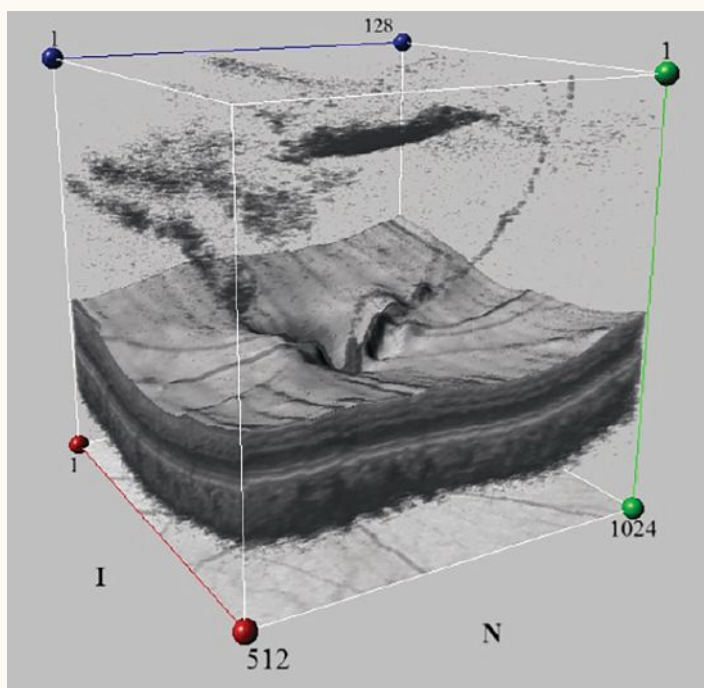
### Optic Nerve Imaging

When evaluating optic nerve disorders, clinicians often rely on the peripap-

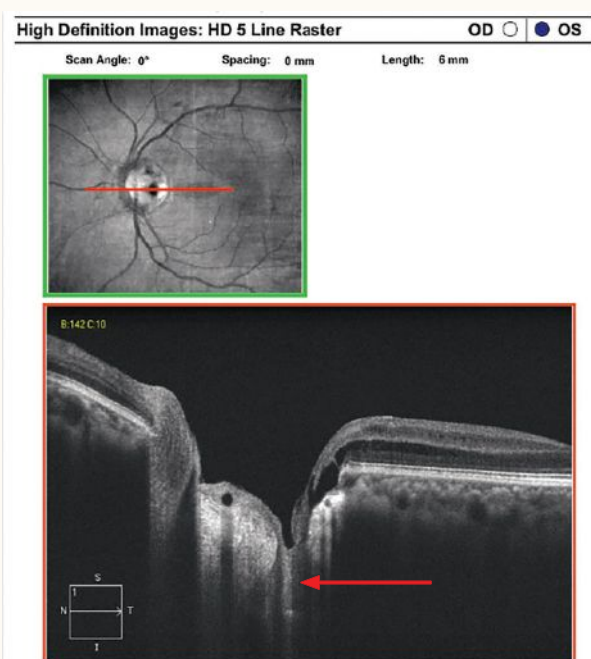
illary retinal nerve fiber thickness (pRNFL), which is based on a set scan circle diameter that varies depending on the OCT instrument. The pRNFL provides valuable data. However, it can miss pathology that falls outside the scan circle. Some OCT instruments, provide not only pRNFL thickness but also a thickness map of the optic nerve and peripapillary area to aid in the detection of pathology outside the pRNFL scan circle. In addition, three-dimensional (3D) views of the optic nerve head (ONH) can be generated to image pathology that cause elevation or view the contour of the optic cup. OCT macula or volume scans can be placed over the optic nerve if specific optic nerve analysis software is not available. These 3D views and OCT B-scans over the optic nerve can highlight vitreopapillary adhesion when determining if a patient has a complete vitreous detachment.

### Optic Disc Pit and Lamina Cribrosa

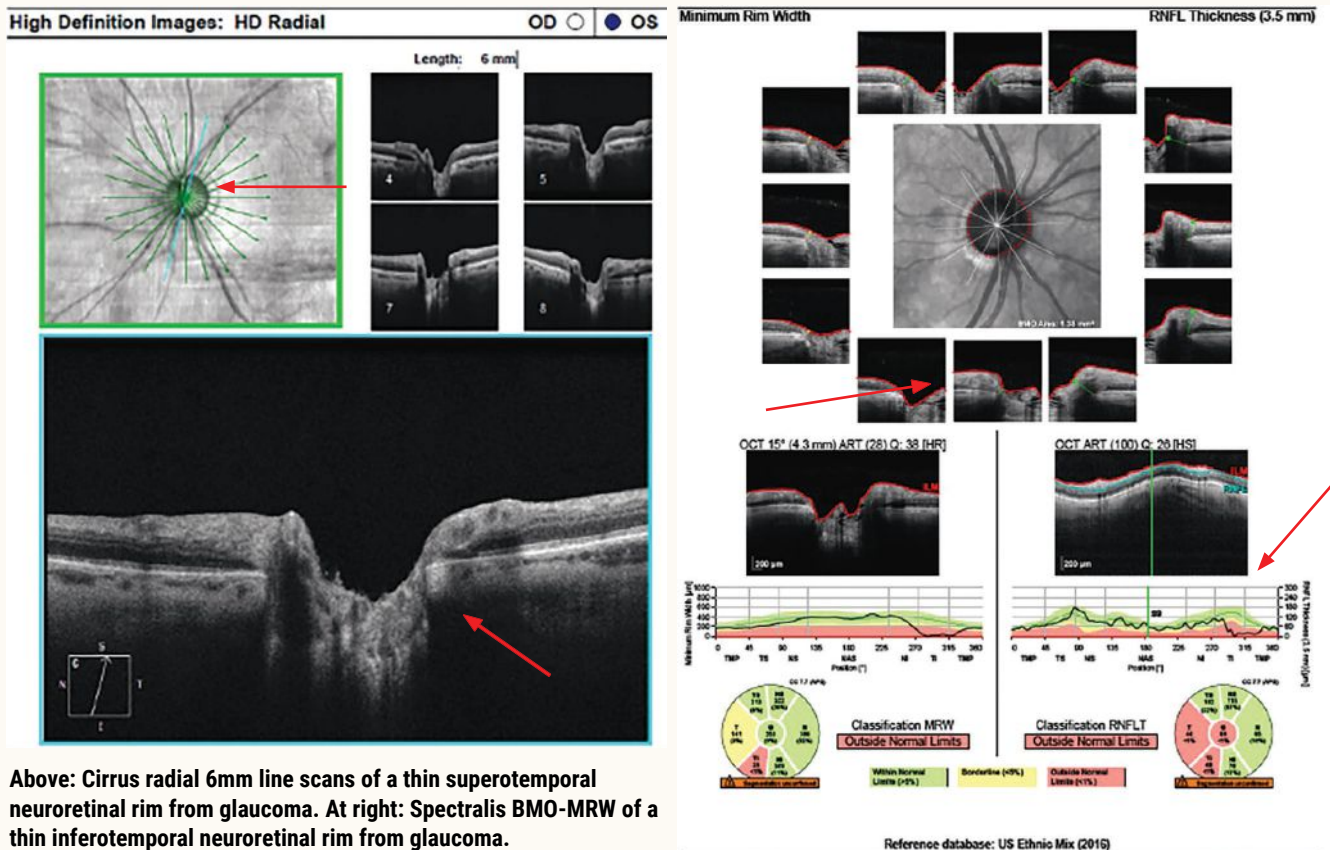
The 3D views of the optic disc cube scan can also highlight the depth of the optic cup and reveal areas of suspected



**Vitreopapillary adhesion imaged with Cirrus Optic Disc Cube in 3D analysis.**



**Optic disc pit imaged with EDI OCT. There is a defect in the lamina cribrosa in the temporal optic disc with associated peripapillary retinoschisis.**



**Above: Cirrus radial 6mm line scans of a thin superotemporal neuroretinal rim from glaucoma. At right: Spectralis BMO-MRW of a thin inferotemporal neuroretinal rim from glaucoma.**

optic disc pits. Both congenital and acquired optic disc pits have a defect in the lamina cribrosa and the 3D scans will exhibit a deep optic disc cup over the area of the lamina cribrosa defect. High-definition line scans over the ONH with EDI or swept-source (SS)-OCT can improve visualization of the lamina cribrosa defect in optic disc pits. It is important to recognize optic disc pits because this condition can cause RNFL loss and visual field defects. It may lead to maculopathy from serous retinal detachment, retinoschisis and cystoid macular edema.<sup>8</sup>

Using EDI and SS-OCT, the lamina cribrosa has been studied extensively in glaucoma. Lamina cribrosa thickness has been found to have an association with glaucoma severity and is thinner in pseudoexfoliation glaucoma compared to primary open-angle glaucoma (POAG) with the same visual field mean deviation.<sup>9</sup> Focal lamina cribrosa defects have also been found to be associated with glaucomatous damage and increase the rate of RNFL loss.<sup>10</sup>

## Neuroretinal Rim Thickness Assessment

In addition to pRNFL scans, the neuroretinal rim thickness can be evaluated with OCT scans over the ONH. OCT line scans in different orientations, especially aligned superotemporally and inferotemporally, can provide objective visualization of the neuroretinal rim thickness in glaucomatous eyes. A visibly thin neuroretinal rim thickness can be used to support an abnormal pRNFL thickness and clinical assessment of the ONH. This technique is helpful in eyes with obliquely inserted ONHs and tilted discs.

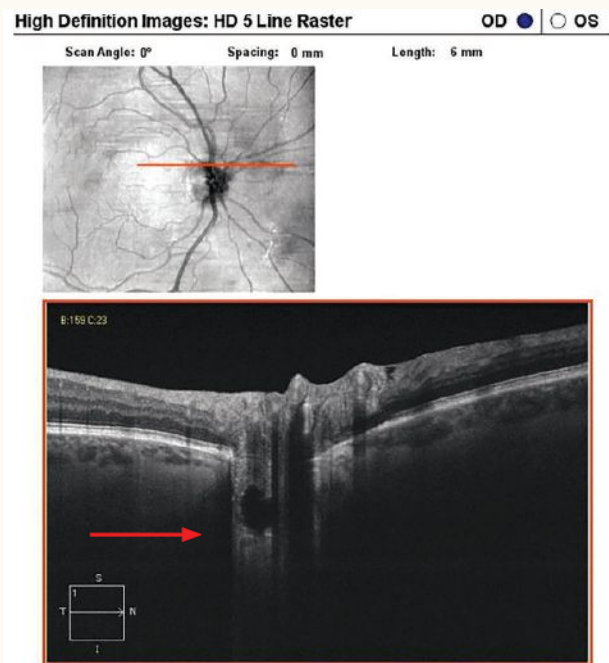
The Bruch's membrane opening (BMO) and minimum rim width (MRW) analysis provides quantitative and qualitative data of the neuroretinal rim tissue. The MRW is defined as the shortest distance between the BMO and the internal limiting membrane.<sup>11</sup> Multiple radial line scans centered on the ONH are used to calculate the BMO-MRW, but note that each slice must be manually confirmed by the

doctor to ensure the device accurately captured the BMO-MRW.

When comparing BMO-MRW to pRNFL thickness, some studies have found that BMO-MRW has better diagnostic accuracy than pRNFL, while others have reported no significant difference.<sup>12,13</sup> Studies have also suggested that BMO-MRW is more sensitive for early detection of glaucomatous damage, but pRNFL may be more sensitive at monitoring glaucomatous progression.<sup>14</sup> The best method to detect glaucoma and progression may possibly be the combination of BMO-MRW and pRNFL measures.<sup>15</sup>

## Optic Disc Drusen (ODD)

It is important to differentiate between pseudo disc edema secondary to ODD vs. true disc edema, as the latter could be life-threatening. When imaging patients suspected of ODD, it is essential to acquire line scans with EDI SD-OCT or SS-OCT over the ONH. The latter uses a wavelength of 1300nm, longer than that used in posterior-segment



**Buried ODD imaged with EDI OCT.**

SD-OCT and better for visualizing buried ODD.

On OCT, ODD has a hyperreflective margin with a hyporeflective core. Recent studies have also described peripapillary hyperreflective ovoid mass-like structures (PHOMS) that were previously considered to be a subtype of ODD. However, PHOMS is now believed to be axoplasmic stasis and nerve fiber herniation in the peripapillary region. These structures have been found to be associated with ODD, papilledema, anterior ischemic optic neuropathy, central retinal vein occlusion, optic neuritis and tilted disc syndrome.<sup>16</sup>

## Peripheral Retina

OCT imaging of the mid-peripheral and peripheral retina is now accessible with widefield imaging instruments and ultra-widefield (UWF) SS-OCT. Although these instruments provide high-resolution images of mid-peripheral and peripheral pathologies, they offer only line scans with no additional analyses, such as retinal thickness measurements.

The good news is that even without widefield capabilities, standard SD-OCT 6mm line scans can assess mid-peripheral and peripheral lesions with the correct head positioning. In

some OCT systems, these line scans can be extended to 9mm and 12mm. OCT imaging of the periphery has increased our understanding of peripheral retinal and choroidal lesions. It can help differentiate a retinoschisis from a retinal detachment and confirm shallow subretinal fluid in retinal tears and holes.

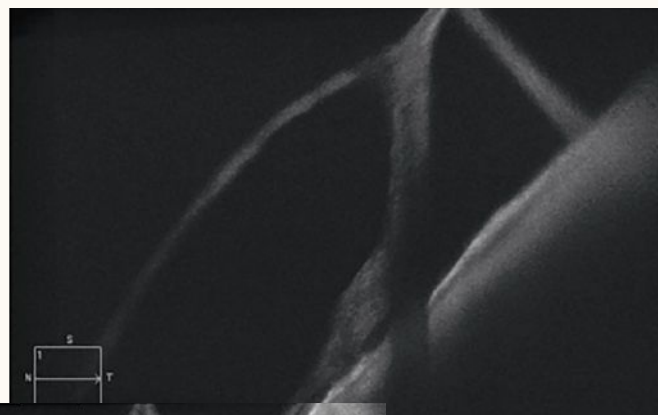
## Anterior Segment

This imaging modality can provide identification and sequential evaluation of anterior-segment pathologies by capturing the

anterior-chamber angle structures, cornea, conjunctiva, iris and lens. Anterior-segment OCT (AS-OCT) is now available on many SD-OCT instruments, so you likely won't need to purchase a separate system. Many clinicians don't take advantage of all their AS-OCT has to offer; for example, the technology can be used to image narrow angles, generate pachymetry maps, image ocular surface squamous cell neoplasia (OSSN) and most other anterior segment pathology, evaluate cells and flare in uveitis and assist in contact lens fits.

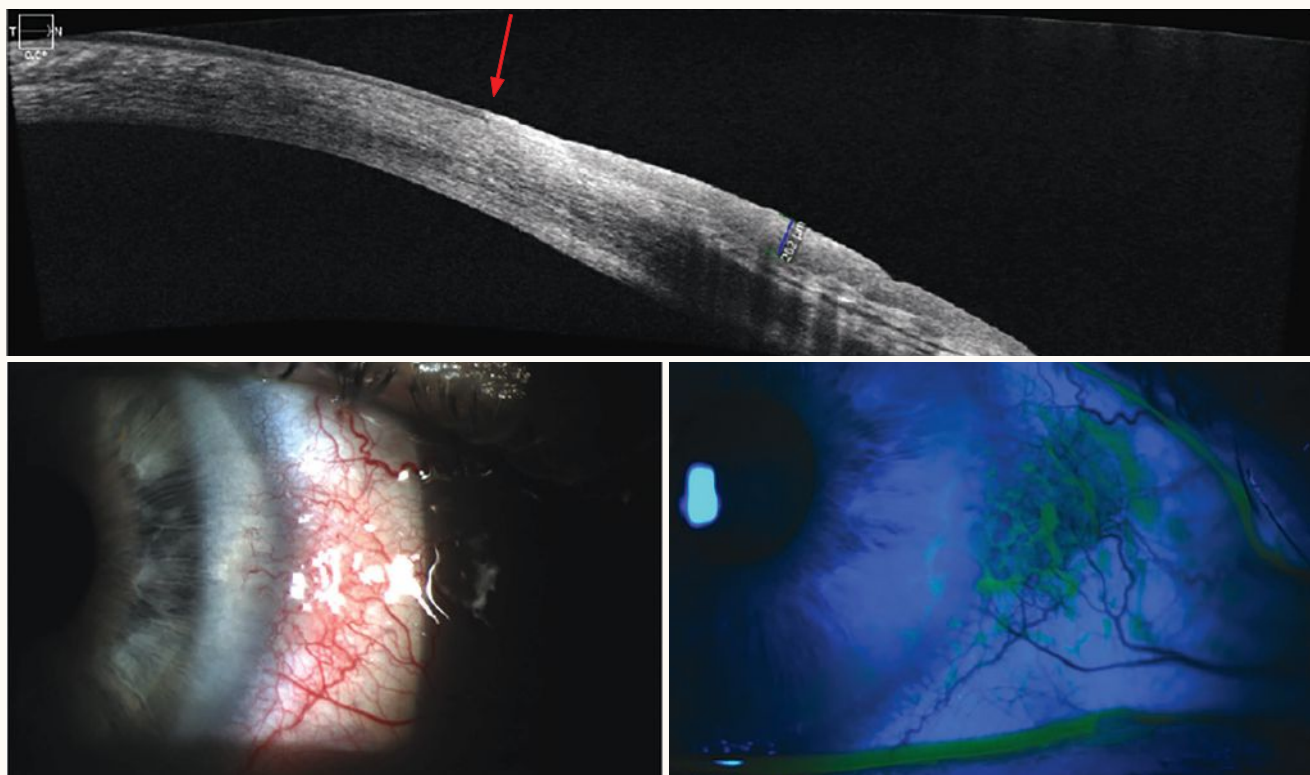
AS-OCT imaging of the iridocorneal angle requires no contact with the eye, can be performed by a technician and allows visualization of the angle under dark conditions. This is especially helpful in providing a quick evaluation of the iridocorneal angle in patients who cannot tolerate gonioscopy. It can also provide objective anterior-chamber angle parameter measurements using built-in tools. AS-OCT has been incorporated in large clinical studies, such as the Zhongshan Angle Closure Prevention (ZAP) trial. The ZAP trial found that AS-OCT biometric parameters of narrower horizontal angle opening distance from the scleral spur and flatter horizontal iris curvature were significantly associated with progression to primary angle closure (PAC) and acute angle closure.<sup>17</sup>

While AS-OCT can capture precise images of the iridocorneal angle, the technology does not replace gonioscopy. Limitations of AS-OCT compared to gonioscopy include poor visibility of the scleral spur in a number of eyes, static images of only certain quadrants in most AS-OCT instruments, inability to indent to assess for peripheral anterior synechiae or plateau iris and inability to assess the pigment in the



**Peripheral retinoschisis with outer retinal break and detachment imaged with HD line scan.**





**OSSN on AS-OCT. There is a thickened and hyperreflective epithelial layer with an abrupt transition from normal to abnormal epithelium.**

angle. AS-OCT also has a high rate of false positives in the diagnosis of angle closure compared to gonioscopy.<sup>18</sup>

AS-OCT pachymetry maps provide non-contact central corneal thickness and topographical thickness maps to detect irregular corneal pathologies as well as aid in dry eye assessment. Pachymetry maps highlight areas of corneal thinning and can aid in the diagnosis of corneal pathology when a corneal topographer is not available. Epithelial thickness maps on AS-OCT have been shown to detect early keratoconus better than anterior corneal topography. This is due to the masking of the early ectasia from compensatory epithelial remodeling with thinning over the location of corneal steepening.<sup>19</sup> On epithelial thickness maps, the epithelium will be thinnest over the area of the corneal steepening.<sup>20,21</sup>

Another clinical advantage of AS-OCT is that it can provide an optical biopsy of abnormal conjunctival and corneal lesions. In OSSN, AS-OCT has distinctive features including a thickened and hyperreflective epithelial

layer with an abrupt transition from normal to abnormal epithelium.<sup>22</sup> AS-OCT attachments can also be used to discern between scleritis and episcleritis.

### Newer Technology

Although most optometry practices have an SD-OCT, newer technology is continually being developed. It can be difficult to determine which upgrades are worth the cost. The upgrade could be software, but at other times may require a hardware upgrade or even a new OCT instrument if the technology is very different. Some of the newer technologies include AS-OCT, OCT-angiography (OCT-A) and SS-OCT.

AS-OCT has many applications in imaging anterior segment pathology. In SD-OCT instruments that have a built-in lens, a license upgrade is all that is needed to gain access to image the cornea and iridocorneal angle. Using a dedicated AS-OCT instrument may not be cost-effective in a primary care practice. Some disadvantages of AS-OCT are its limitation in penetrat-

ing the iris pigment epithelium and its lack of tracking and progression analysis. Furthermore, AS-OCT provides a static image, unlike gonioscopy that is dynamic and allows assessment of the pigmentation in the trabecular meshwork.

OCT-A provides noninvasive imaging of the retinal and choroidal vasculature. Since its introduction to clinical eyecare in 2014, there have been extensive studies evaluating its application in conditions such as diabetic retinopathy, AMD and glaucoma. In diabetic retinopathy, vascular changes in the foveal avascular zone can be detected on OCT-A before clinical findings of diabetic retinopathy are clinically detected.<sup>23</sup> Details of the size and characteristics of macular neovascularization (MNV) from AMD have been studied on OCT-A, including nonexudative MNV.<sup>24</sup> Peripapillary vessel density have been found to be lower in pseudoexfoliation glaucoma compared to POAG, suggesting a separate ischemic mechanism other than intraocular pressure.<sup>25</sup>

Although OCT-A provides valuable information, there are limitations. For example, it does not image leakage as seen on fluorescein angiography (FA) and is susceptible to artifacts such as motion. There is also a range of OCT-A instruments; some scan a wider area than others, some have faster scan acquisitions and only a few provide vascular density measurements.<sup>26</sup> Without vascular density measurements, there is no quantitative data, making it difficult to track progression.

Even without OCT-A, structural OCT scans can map areas of poor perfusion due to retinal conditions. Areas of reduced capillary density on OCT-A in the superficial capillary plexus will correspond to areas of thin inner retinal layers on structural OCT scans. In exudative MNV seen on OCT-A, structural OCT will show subretinal or sub-RPE hyperreflectivity with subretinal and/or intraretinal fluid. In non-exudative MNV, structural OCT will exhibit a shallow irregular RPE elevation with a greatest transverse linear dimension of  $\geq 1000\mu\text{m}$ , height of predominately less than  $100\mu\text{m}$  and a nonhomogenous internal reflectivity.<sup>27</sup>

In clinical practice, the decision to treat using anti-VEGF in MNV from exudative AMD is often based on structural OCT due to its high sensitivity and specificity when compared to FA because not all practices have an OCT-A.<sup>28,29</sup> Instruments with OCT-A also tend to be more expensive than those without it, and the purchase may be easier for optometry practices to justify if they see a large volume of posterior-segment diseases.

SS-OCT offers high-resolution imaging with fast image acquisition, allowing imaging of the choroid and vitreous simultaneously. The modality can penetrate lens opacities, choroid, pigment and blood better than SD-OCT due to its longer wavelength. Commercially approved SS-OCT instruments include the Optos Silverstone, Topcon DRI Triton, Zeiss Plex Elite 9000 and Heidelberg Anterior AS-OCT. Although the Topcon Triton has been FDA-approved since 2018, it has yet to be widely

adopted in clinical practice compared to SD-OCT instruments. Currently, the Zeiss Plex Elite 9000 is mainly used in clinical research. The Optos Silverstone provides UWF OCT images but does not have capabilities for retinal thickness or pRNFL thickness analyses as do SD-OCT instruments. With newer advanced technologies (*i.e.*, improved scanning speeds of 125 KHz on the Spectralis OCT-A module, analysis software and EDI), this modality still has a lot to offer, making an upgrade to SS-OCT less of a necessity.

## Takeaways

OCT is a powerful tool that assists clinicians in diagnosing and managing ocular pathologies affecting the anterior and posterior segments of the eye. Using the appropriate testing strategies for the pathology of interest will allow for maximum utility of your instrument. Potential upgrades to OCT software and hardware that augment current features can also be considered to enhance patient care. ■

1. Baker CW, Glassman AR, Beaulieu WT, et al. Effect of initial management with aflibercept vs laser photocoagulation vs observation on vision loss among patients with diabetic macular edema involving the center of the macula and good visual acuity: a randomized clinical trial. *JAMA Ophthalmol*. 2019;321:1880-94.

2. Marmor MF, Kellner U, Lai TY, et al. American Academy of Ophthalmology recommendations on screening for chloroquine and hydroxychloroquine retinopathy (2016 revision). *Ophthalmology*. 2016;123:1386-94.

3. Cangemi FE, Trempe CL, Walsh JB. Choroidal folds. *Am J Ophthalmol*. 1978;86(3):380-7.

4. Marmor MA. Comparison of screening procedures in hydroxychloroquine toxicity. *Arch Ophthalmol*. 2012;130:461-9.

5. Melles RB, Marmor MF. Pericentral retinopathy and racial differences in hydroxychloroquine toxicity. *Ophthalmology*. 2015;122:110-6.

6. Castro-Navarro V, Behar-Cohen F, Chang Woohyok, et al. Pachychoroid: current concepts on clinical features and pathogenesis. *Graefes Arch Clin Exp Ophthalmol*. 2021;259:1385-1400.

7. Coscas F, Puche N, Coscas G, et al. Comparison of macular choroidal thickness in adult onset foveomacular vitelliform dystrophy and age-related macular degeneration. *Invest Ophthalmol Vis Sci*. 2014;55:64-69.

8. Georgalas I, Ladas I, Georgopoulos G, Petrou P. Optic disc pit: a review. *Graefes Arch Clin Exp Ophthalmol*. 2011;249:1113-22.

9. Moghimi S, Nekoozadeh S, Motamed-Gorji N, et al. Lamina cribrosa and choroid features and their relationship to stage of pseudoexfoliation glaucoma. *Invest Ophthalmol Vis Sci*. 2018;59:5355-65.

10. Moghimi S, Zangwill LM, et al. Association between lamina cribrosa defects and progressive retinal nerve fiber layer loss in glaucoma. *JAMA Ophthalmol*. 2019;137(4):425-33.

11. Povazay B, Hofer B, Hermann B, et al. Minimum distance mapping using three-dimensional OCT for glaucoma diagnosis. *J Biomed Opt*. 2007;12:041204-8.

12. Torres LA, Sharpe GP, Hutchison DM, et al. Influence of Bruch's Membrane opening area in diagnosing glaucoma with neuroretinal parameters from OCT. *Am J Ophthalmol*. 2019;208:94-102.

13. Wu Z, Vianna JR, Reis ASC, et al. Qualitative evaluation of neuroretinal rim and retinal nerve fibre layer on OCT to detect glaucomatous damage. *Br J Ophthalmol*. 2020;104:980-4.

14. Gardiner SK, Boey PY, Yang H, et al. Structural measurements for monitoring change in glaucoma: comparing retinal nerve fiber layer thickness with minimum rim width and area. *Invest Ophthalmol Vis Sci*. 2015;56: 6886-91.

15. Yang H, Luo H, Hardin C, et al. OCT structural abnormality detection in glaucoma using topographically correspondent rim and retinal nerve fiber layer criteria. *Am J Ophthalmol*. 2020;213:203-16.

16. Malmqvist L, Sibony PA, Fraser CL, et al. Optic Disc Drusen Studies Consortium. Peripapillary ovoid hyperreflectivity in optic disc edema and pseudopapilledema. *Ophthalmology*. 2018;125(10):1662-4.

17. Xu BY, Friedman DS, Foster PJ, et al. Ocular biometric risk factors for progression of primary angle closure disease. The Zhongshan angle closure prevention trial. *Ophthalmology*. 2021;129:267-75.

18. Desmond T, Tran V, Maharaj M, et al. Diagnostic accuracy of AS-OCT vs gonioscopy for detecting angle closure: a systemic review and meta-analysis. *Graefes Arch Clin Exp Ophthalmol*. 2022;260:1-23.

19. Silverman RH, Urs R, Roychoudhury A, et al. Epithelial remodeling as basis for machine-based identification of keratoconus. *Invest Ophthalmol Vis Sci*. 2014;55: 1580-7.

20. Reinstein DZ, Archer TJ, Gobbe M. Corneal epithelial thickness profile in the diagnosis of keratoconus. *J Refract Surg*. 2009;25:604-10.

21. Kanellopoulos AJ, Asimellis G. Anterior segment OCT: assisted topographic corneal epithelial thickness distribution imaging of a keratoconus patient. *Case Rep Ophthalmol*. 2013;4:74-8.

22. Thomas BJ, Galor A, Nanji AA, et al. Ultra high-resolution anterior segment OCT in the diagnosis and management of ocular surface squamous neoplasia. *Ocul Surf*. 2014;12:46-58.

23. Lu Y, Simonett JM, Wang J, et al. Evaluation of automatically quantified foveal avascular zone metrics for diagnosis of diabetic retinopathy using OCT angiography. *Invest Ophthalmol Vis Sci*. 2018;59:2212-21.

24. Laiginhas R, Yang J, Rosenfeld et al. Nonexudative macular neovascularization-A systemic review of prevalence, natural history, and recent insights from OCT angiography. *Ophthalmol Retina*. 2020;4:651-61.

25. Park JH, Yoo C, Girard MJ, et al. Peripapillary vessel density in glaucomatous eyes: comparison between pseudoexfoliation glaucoma and primary open-angle glaucoma. *J Glaucoma*. 2018;27:1009-16.

26. Spaide RF, Fujimoto JG, Waheed NK, et al. Optical coherence tomography angiography. *Pro Retin Eye Res*. 2018;64:1-55.

27. Narita C, Wu Z, Rosenfeld P, et al. Structural OCT signs suggestive of subclinical nonexudative macular neovascularization in eyes with large drusen. *Ophthalmology*. 2020;127:637-47.

28. Parekh PK, Folk JC, Gupta P, et al. Fluorescein angiography does not alter the initial clinical management of choroidal neovascularization in age-related macular degeneration. *Ophthalmology Retina*. 2018;2:659-66.

29. Gualino V, Tadayoni R, Cohen S, et al. Optical coherence tomography, fluorescein angiography, and diagnosis of choroidal neovascularization in age-related macular degeneration. *Retina*. 2019;39:1664-71.

## OPTOMETRIC STUDY CENTER QUIZ

To obtain CE credit through the Optometric Study Center, complete the test form on the following page and return it with the \$35 fee to: Jobson Healthcare Information, Attn.: CE Processing, Jobson Healthcare Information, LLC/WebMD, 283-299 Market Street, 2 Gateway Center, 4th Floor, Newark, NJ 07102. To be eligible, please return the card within three years of publication. You can also access the test form and submit your answers and payment via credit card online at [revieweducationgroup.com](http://revieweducationgroup.com). You must achieve a score of 70 or higher to receive credit. Allow four weeks for processing. For each Optometric Study Center course you pass, you earn two hours of credit. Please check with your state licensing board to see if this approval counts toward your CE requirement for relicensure.

**1. Optometrists should use multiple vertical high resolution line scans to detect which of the following conditions?**

- a. Diabetic macular edema.
- b. Hydroxychloroquine maculopathy.
- c. Choroidal folds.
- d. None of the above.

**2. To screen for hydroxychloroquine maculopathy, which of the following should be used?**

- a. Horizontal scans.
- b. Vertical scans.
- c. Radial scans.
- d. A combination of horizontal, vertical and radial scans.

**3. Which of the following improves visualization of the choroidal structures and the sclerochoroidal junction?**

- a. Enhanced depth imaging (EDI).
- b. Optic nerve imaging.
- c. Neuroretinal rim thickness assessment.
- d. None of the above.

**4. In a large multi-provider analysis on patients diagnosed with hydroxychloroquine maculopathy, \_\_\_\_\_ of Asian patients had pericentral retinopathy without parafoveal involvement.**

- a. Less than 50%.
- b. More than 50%.
- c. 10%.
- d. 40%.

**5. Which of the following statements is TRUE?**

- a. To screen for pericentral retinopathy on OCT, wide-angle scans should be used when accessible.
- b. Wide-angle scans should not be used when screening for pericentral retinopathy on OCT.
- c. If widefield imaging cannot be performed, scans can also be moved to accommodate pericentral lesions.
- d. Both A and C.

**6. Which of the following is important for the diagnosis of pachychoroid diseases, such as central serous chorioretinopathy and polypoidal choroidal vasculopathy?**

- a. Optic nerve imaging.
- b. Neuroretinal rim thickness assessment.
- c. Enhanced depth imaging (EDI).
- d. Minimum rim width.

**7. Why is it important to recognize optic disc pits?**

- a. This condition can cause RNFL loss.
- b. It can cause visual field defects.
- c. It may lead to maculopathy from serous retinal detachment, retinoschisis and cystoid macular edema.
- d. All of the above.

**8. Which of the following may be the best method to detect glaucoma and progression?**

- a. BMO-MRW.
- b. pRNFL thickness.
- c. A combination of BMO-MRW and pRNFL.
- d. None of the above.

**9. Which of the following are limitations of OCT-A?**

- a. It does not image leakage as seen on fluorescein angiography (FA).
- b. It is susceptible to artifacts such as motion.
- c. It is a more invasive imaging approach.
- d. Both A and B.

**10. Which of the following is TRUE about AS-OCT imaging of the iridocorneal angle?**

- a. It requires no contact with the eye.
- b. It can be performed by a technician.
- c. It allows visualization of the angle under dark conditions.
- d. All of the above.

**11. Which technology can penetrate lens opacities, choroid, pigment and blood better than SD-OCT due to its longer wavelength?**

- a. AS-OCT.
- b. SS-OCT.
- c. OCT-A.
- d. Both AS-OCT and OCT-A.

**12. Which technology can be used to image narrow angles, generate pachymetry maps, and image OSSN as well as most other anterior segment pathology?**

- a. AS-OCT.
- b. SS-OCT.
- c. OCT-A.
- d. Both B and C.

**13. Peripapillary hyperreflective ovoid mass-like structures (PHOMS) have been found to be associated with which of the following:**

- a. Optic disc drusen.
- b. Anterior ischemic optic neuropathy.
- c. Tilted disc syndrome.
- d. All of the above.

**14. Which of the following statements is FALSE?**

- a. AS-OCT has a high rate of false positive in the diagnosis of angle closure when compared to gonioscopy.
- b. Epithelial thickness maps on AS-OCT have been shown to detect early keratoconus better than anterior corneal topography.
- c. AS-OCT does not provide an optical biopsy of abnormal conjunctival and corneal lesions.
- d. AS-OCT attachments can be used to discern between scleritis and episcleritis.

**15. Which of the following scans can assist in determining if there is a complete posterior vitreous detachment?**

- a. AS-OCT scan of the anterior chamber.
- b. EDI OCT scan to image the choroid.
- c. OCT scans with three-dimensional views of the optic nerve head.
- d. OCT scans over the fovea and parafovea.

**16. Which of the following statements are TRUE?**

- a. MRW is defined as the longest distance between the BMO and the internal limiting membrane (ILM).
- b. Multiple radial line scans centered on the ONH are used to calculate the BMO-MRW.
- c. When comparing BMO-MRW to pRNFL thickness, some studies have found that BMO-MRW has better diagnostic accuracy than pRNFL, while others have reported no significant difference.
- d. Both B and C.

**17. Even without widefield capabilities, standard SD-OCT \_\_\_\_ line scans can assess mid-peripheral and peripheral lesions with the correct head positioning; in some OCT systems, these line scans can be extended to \_\_\_\_ and \_\_\_\_.**

- a. 6mm; 9mm; 12mm.
- b. 4mm; 9mm; 12mm.
- c. 6mm; 10mm; 14mm.
- d. 6mm; 8mm; 15mm.

**18. In non-exudative macular neovascularization, structural OCT will exhibit which of the following?**

- a. A shallow irregular RPE elevation with a greatest transverse linear dimension of  $\geq 1000\mu\text{m}$ .
- b. A height of predominately less than  $100\mu\text{m}$ .
- c. A nonhomogenous internal reflectivity.
- d. All of the above.

**19. When imaging patients suspected of ODD, it is essential to acquire line scans with \_\_\_\_\_ over the ONH.**

- a. EDI SD-OCT and SS-OCT.
- b. SD-OCT and SS-OCT.
- c. EDI SD-OCT or SS-OCT.
- d. EDI SD-OCT or AS-OCT.

**20. In OSSN, which of the following has distinctive features, including a thickened and hyperreflective epithelial layer with an abrupt transition from normal to abnormal epithelium?**

- a. SD-OCT.
- b. AS-OCT.
- c. SS-OCT.
- d. None of the above.



## Examination Answer Sheet

### OCT Beyond the Basics: Unlock the Power of This Essential Tool

Valid for credit through March 15, 2027

**Online:** This exam can be taken online at [revieweducationgroup.com](http://revieweducationgroup.com). Upon passing the exam, you can view your results immediately and download a real-time CE certificate. You can also view your test history at any time from the website.

**Directions:** Select one answer for each question in the exam and completely darken the appropriate circle. A minimum score of 70% is required to earn credit.

**Mail to:** Jobson Healthcare Information, LLC/WebMD, 283-299 Market Street, 2 Gateway Center, 4th Floor, Newark, NJ 07102.

**Payment:** Remit \$35 with this exam. Make check payable to Jobson Healthcare Information, LLC.

**Credit:** This course is COPE-approved for two hours of CE credit. Course ID 89897-GO.

**Processing:** There is a four-week processing time for this exam.

Jointly provided by PIM and the Review Education Group.

#### Answers to CE exam:

1. (A) (B) (C) (D)
2. (A) (B) (C) (D)
3. (A) (B) (C) (D)
4. (A) (B) (C) (D)
5. (A) (B) (C) (D)
6. (A) (B) (C) (D)
7. (A) (B) (C) (D)
8. (A) (B) (C) (D)
9. (A) (B) (C) (D)
10. (A) (B) (C) (D)
11. (A) (B) (C) (D)
12. (A) (B) (C) (D)
13. (A) (B) (C) (D)
14. (A) (B) (C) (D)
15. (A) (B) (C) (D)
16. (A) (B) (C) (D)
17. (A) (B) (C) (D)
18. (A) (B) (C) (D)
19. (A) (B) (C) (D)
20. (A) (B) (C) (D)

#### Post-activity evaluation questions:

Rate how well the activity supported your achievement of these learning objectives. 1=Poor, 2=Fair, 3=Neutral, 4=Good, 5=Excellent

21. Effectively use OCT scans and analyses in clinical practice. (1) (2) (3) (4) (5)
22. Recognize the strengths and limitations of various OCT options. (1) (2) (3) (4) (5)
23. Determine which type of OCT is the best option for various ocular pathologies. (1) (2) (3) (4) (5)
24. Distinguish between newer technologies and understand the role of each. (1) (2) (3) (4) (5)
25. Based upon your participation in this activity, do you intend to change your practice behavior? (Choose only one of the following options.)  
(A) I do plan to implement changes in my practice based on the information presented.  
(B) My current practice has been reinforced by the information presented.  
(C) I need more information before I will change my practice.
26. Thinking about how your participation in this activity will influence your patient care, how many of your patients are likely to benefit? (please use a number):
27. If you plan to change your practice behavior, what type of changes do you plan to implement? (Check all that apply.)  
(A) Apply latest guidelines (D) Change in current practice for referral (G) More active monitoring and counseling  
(B) Change in diagnostic methods (E) Change in vision correction offerings (H) Other, please specify: \_\_\_\_\_  
(C) Choice of management approach (F) Change in differential diagnosis
28. How confident are you that you will be able to make your intended changes?  
(A) Very confident (B) Somewhat confident (C) Unsure (D) Not confident
29. Which of the following do you anticipate will be the primary barrier to implementing these changes?  
(A) Formulary restrictions (D) Insurance/financial issues (G) Patient adherence/compliance  
(B) Time constraints (E) Lack of interprofessional team support (H) Other, please specify: \_\_\_\_\_  
(C) System constraints (F) Treatment related adverse events
30. Additional comments on this course: \_\_\_\_\_

Please retain a copy for your records. Please print clearly.

First Name

Last Name

E-Mail

The following is your: ☐ Home Address ☐ Business Address

Business Name

Address

City  State

ZIP

Telephone #  -  -

Fax #  -  -

OE Tracker Number

#### Rate the quality of the material provided:

1=Strongly disagree, 2=Somewhat disagree, 3=Neutral, 4=Somewhat agree, 5=Strongly agree

31. The content was evidence-based.

(1) (2) (3) (4) (5)

32. The content was balanced and free of bias.

(1) (2) (3) (4) (5)

33. The presentation was clear and effective.

(1) (2) (3) (4) (5)

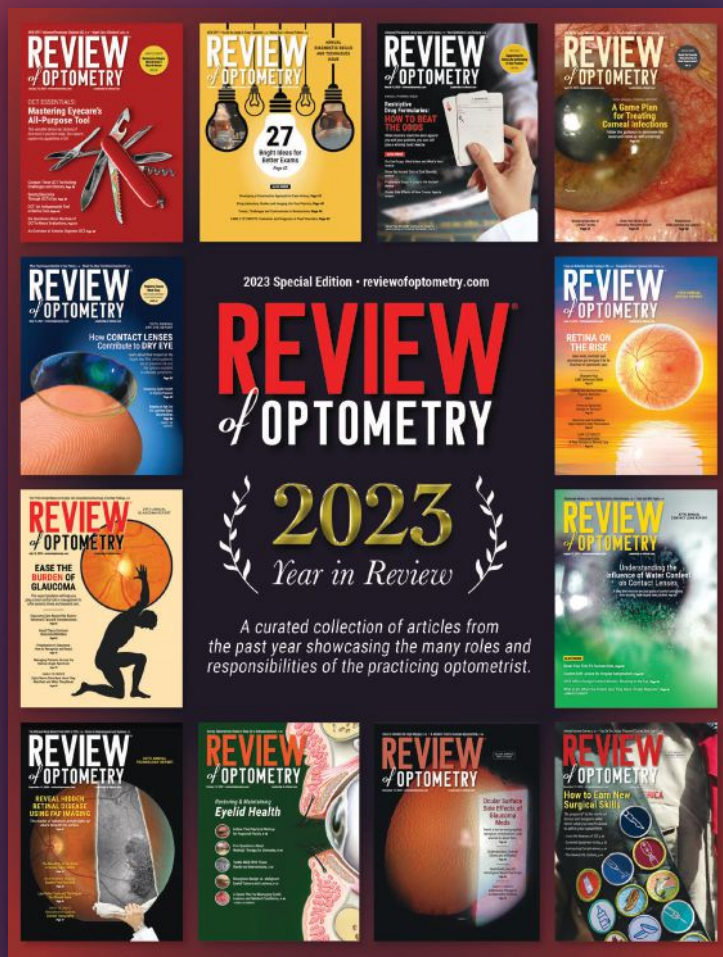By submitting this answer sheet, I certify that I have read the lesson in its entirety and completed the self-assessment exam personally based on the material presented. I have not obtained the answers to this exam by any fraudulent or improper means.

Signature \_\_\_\_\_

Date \_\_\_\_\_

Lesson 124738 RO-OSC-0324

# A Year in the Making.



Our 2023 recap delivers:

- “How-to” guidance on dozens of clinical techniques
- Timely insights from the scientific literature
- The year’s biggest legislative news stories
- Commentary from trusted voices in the profession

...all in one place!

Available now at [reviewofoptometry.com](https://reviewofoptometry.com)





# Not So Nerve-ous

*Know the signs of this frequently misdiagnosed condition.*

**A** 57-year-old male presented for decreased vision in his right eye for one month. He was also experiencing floaters and a general haze over the vision in that eye. Visual acuity was 20/40 OD and 20/25 OS. Intraocular pressures were 14mm Hg bilaterally, and pupils were equal and reactive without an afferent pupillary defect. His extraocular motilities were within normal limits, and he denied pain on eye movement. Color vision testing was unremarkable, as was the anterior segment exam.

In the right eye, there were four clock-hours of sectoral optic disc elevation superonasally with blurred margins (*Figure 1*). There was also a vitreous hemorrhage from the disc extending inferiorly. Unilateral optic disc edema was suspected.

## Edema or Not?

Optic nerve head elevation has a broad differential diagnosis usually including etiologies that result in edema, such as anterior optic neuritis, anterior ischemic optic neuropathy, increased intracranial pressure (if bilateral), diabetic papillopathy, and any condition that increases orbital congestion such as a tumor or inflammation. Buried optic disc drusen, crowded nerves and anomalous discs may also cause optic nerves to appear elevated, leading us to believe they may be edematous. These “pseudo” edema cases often pose interesting diagnostic dilemmas, as they may be difficult to differentiate from true edema.

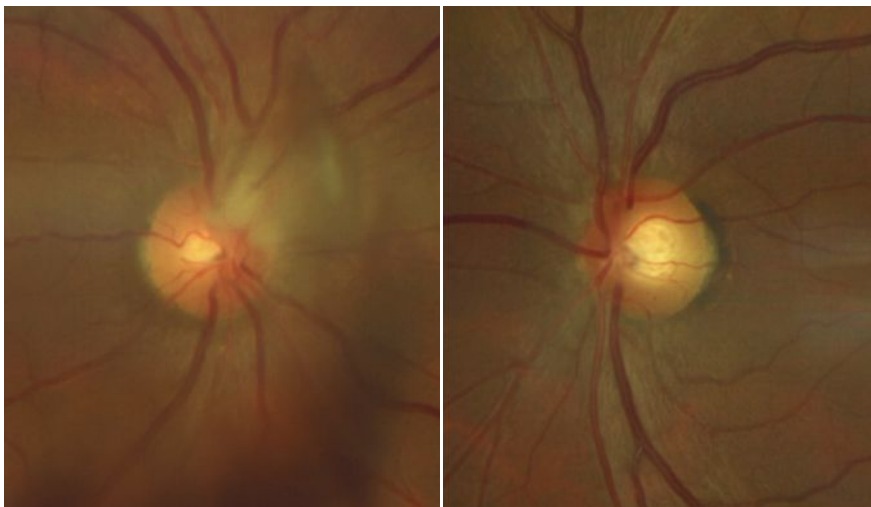
Our patient had an initial suspected diagnosis of unilateral sectoral disc edema with hemorrhage, but how can we confirm the etiology? In this case, OCT

was conducted to allow for better visualization of the optic nerve head. Both RNFL and raster studies were completed and reviewed. The RNFL study revealed thickening in the superior and nasal quadrants, as was seen clinically (*Figure 2*). The raster study, however, gave better insight into the morphology of the optic disc. In particular, the relationship between the vitreous and the disc was visualized. *Figure 3* captures the presence of adhesion between the posterior hyaloid and the optic nerve head. This was consistent with a diagnosis of vitreopapillary traction syndrome (VPT).

In VPT, the posterior hyaloid of the vitreous body remains attached to the optic nerve head, exerting anterior traction on the disc. Clinically, this appears as optic nerve elevation and may be circumferential or partial. If it involves only part of the optic nerve head, it is usually noted superiorly.<sup>1</sup> VPT may be seen concurrently with vitreomacular traction (VMT) or peripapillary hemorrhages and is generally unilateral, though instances of bilateral involvement have been reported. One such case involves a 47-year-old woman who was prescribed acetazolamide for one year due to an erroneous diagnosis of papilledema. She had unremarkable neuroimaging and a normal opening pressure. Eventually, OCT imaging was performed and reviewed in detail, revealing the true diagnosis of bilateral VPT.<sup>2</sup>

## Pathogenesis and Controversy

VPT is thought to occur, in most cases, during a posterior vitreous detachment (PVD). Recall that the vitreous has its strongest posterior pole attachments at the optic disc and macula. As the posterior hyaloid separates from the posterior pole, it often pulls away from the fovea and optic nerve head last. This leads to focal adhesion causing VMT and/or

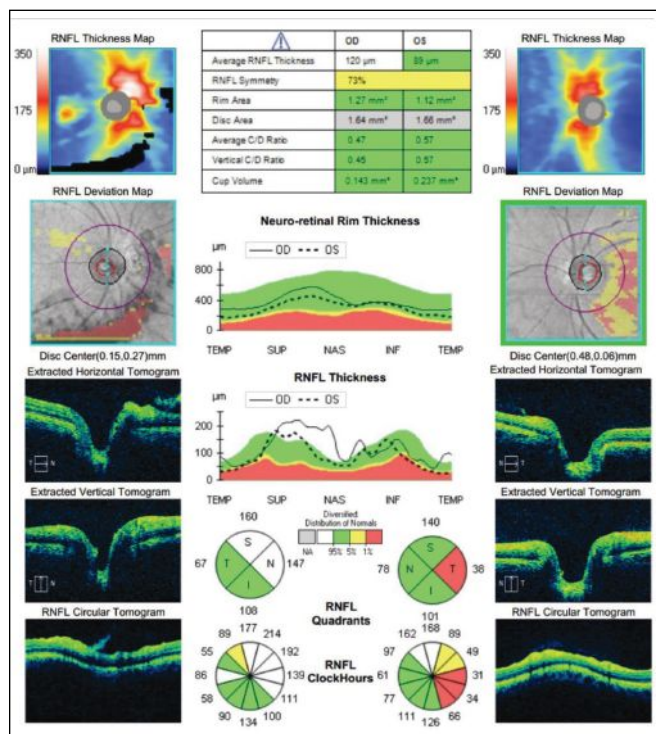


**Fig. 1. Right and left optic nerves. The right optic nerve (left image) is seen with blurred and elevated disc margin superonasally. There is also vitreous hemorrhage causing shadowing inferiorly.**

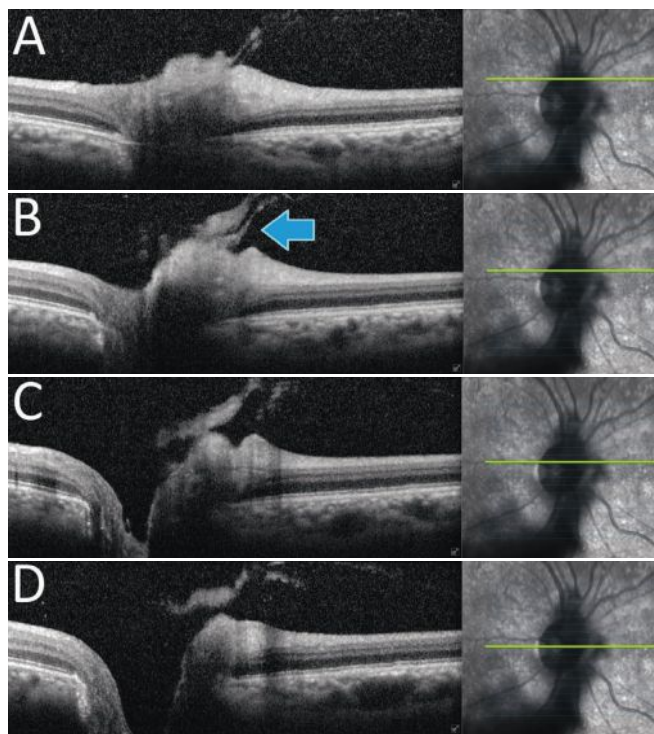
### About Dr. Bozung

**Dr. Bozung** currently practices at Bascom Palmer where she primarily sees patients in the hospital's 24/7 ophthalmic emergency department. She also serves as the optometry residency program coordinator. Dr. Bozung is a fellow of the American Academy of Optometry and a member of the Florida and American Optometric Associations. She is a founding board member of Young OD Connect and serves on the editorial board for *Review of Optometry*. She has no financial interests to disclose.





**Fig. 2.** The OCT of the RNFL is provided. The right optic nerve study reveals thickening of the superior and nasal RNFL. There is some data absent due to hemorrhage blocking signal. The left optic nerve is not elevated; there is unrelated temporal thinning.



**Fig. 3.** The raster OCT over the right optic nerve head exhibits vitreous attachment and traction on the superonasal disc margin (arrow). The hyperreflective nature of the posterior hyaloid is likely due to presence of vitreal condensation and/or blood accumulation.

VPT. Intraretinal, subretinal or vitreous hemorrhage may also be present, as the shearing force of vitreous separation may rupture small vessels.<sup>1</sup> Visual symptoms reported in VPT may include blurred vision, scotomas, gaze-evoked amaurosis, altitudinal defects and photopsias.<sup>3,4</sup>

Interestingly, there is discussion regarding VPT and its plausible role in the development of nonarteritic anterior ischemic optic neuropathy (NAION). Many articles suggest tractional forces on the optic disc vasculature and nerve fibers are what cause elevation of the disc, predisposing the eye to what we classically term an “ischemic” optic neuropathy. Authors suggest that maybe this “NAION” is less about ischemia and more about anatomic axonal distortion and axoplasmic flow reduction.<sup>5</sup> A small study (n=82) found that incomplete vitreopapillary separation was present in 100% of acute NAION eyes and 92% of non-acute NAION eyes. Its authors didn’t provide the percentage of control eyes with incomplete vitreopapillary sep-

aration but cited other studies supporting that only about 68% “normal” eyes have incomplete vitreopapillary separation.<sup>6</sup> It is something worth studying in more detail.

## Treatment

Most patients with VPT are monitored with serial OCT imaging and possibly visual field testing. The condition is not generally considered to lead to prolonged visual impairment.<sup>1,7</sup> Some cases, however, have suggested that pars plana vitrectomy may improve visual function in VPT, even with presumed NAION, but this approach is far from mainstream.<sup>8-11</sup>

## Takeaways

Vitreopapillary traction syndrome has been described frequently in the literature, yet it is often misdiagnosed. Most other causes of optic nerve conditions require extensive neuroimaging and/or laboratory studies that can be costly and wasteful if done for the wrong reason. Accurate diagnosis of VPT can prevent

unnecessary testing, reduce medical errors and avoid needless treatment. ■

1. Katz B, Hoyt WF. Intrapapillary and peripapillary hemorrhage in young patients with incomplete posterior vitreous detachment. Signs of vitreopapillary traction. *Ophthalmology*. 1995;102(2):349-54.
2. Houle E, Miller NR. Bilateral vitreopapillary traction demonstrated by optical coherence tomography mistaken for papilledema. *Case Rep Ophthalmol Med*. 2012;682659.
3. Nomura Y, Tamaki Y, Yanagi Y. Vitreopapillary traction diagnosed by spectral domain optical coherence tomography. *Ophthalmic Surg Lasers Imaging*. 2010;41:74-6.
4. Katz B, Hoyt WF. Gaze-evoked amaurosis from vitreopapillary traction. *Am J Ophthalmol*. 2005;139(4):631-7.
5. Parsa CF, Hoyt WF. Nonarteritic anterior ischemic optic neuropathy (NAION): a misnomer. Rearranging pieces of a puzzle to reveal a nonischemic papillopathy caused by vitreous separation. *Ophthalmology*. 2015;122(3):439-42.
6. Li D, Sun S, Liang J, et al. Papillary vitreous detachment as a possible accomplice in non-arteritic anterior ischaemic optic neuropathy. *Br J Ophthalmol*. 2023;322726.
7. Hedges TR, Flattum NL, Bagga A. Vitreopapillary traction confirmed by optical coherence tomography. *Arch Ophthalmol*. 2006;124(2):279-81.
8. Modarres M, Sanjari MS, Falavarjani KG. Vitrectomy and release of presumed epipapillary vitreous traction for treatment of nonarteritic anterior ischemic optic neuropathy associated with partial posterior vitreous detachment. *Ophthalmology*. 2007;114(2):340-4.
9. Weng CY, Khimani KS, Foroosan R, Gospe SM 3rd, Bhatti MT. A sticky situation. *Surv Ophthalmol*. 2018;63(5):736-44.
10. Meyer CH, Schmidt JC, Mennel S, Kroll P. Functional and anatomical results of vitreopapillary traction after vitrectomy. *Acta Ophthalmol Scand*. 2007;85(2):221-2.
11. Nagesha CK, Rishi P, Rishi E. Vitrectomy for vitreopapillary traction in a nondiabetic 16-year-old girl. *Oman J Ophthalmol*. 2017;10(1):38-9.



BY PAUL M. KARPECKI, OD  
CHIEF CLINICAL EDITOR

## OCULAR SURFACE REVIEW

# Shining the Slit Lamp on ADCs

*ODs can greatly help ovarian cancer patients who are taking this advanced therapeutic agent, specifically Elahere.*

Oncology has seen tremendous advancements in a few short years, including multiple FDA approvals in a rapidly expanding class of targeted therapies known as antibody-drug conjugates, or ADCs. These cancer-targeting “smart bombs” consist of a monoclonal antibody bound to an anti-cancer payload using a chemical linker. While the tolerability of ADCs is generally favorable compared to conventional chemotherapy, several ADCs are associated with adverse ocular surface reactions that are managed by adjusting the medication schedule and dosage.<sup>1</sup> These patients are often seen in optometry offices because the ocular signs indicate an adjustment in dosing concentration is required.

Elahere (mirvetuximab soravtansine-gynx), a new targeted cancer therapy, has been shown to improve overall survival in patients with recurrent ovarian cancer, and optometrists can help significantly.

## Elahere and Ovarian Cancer

Elahere is the third ADC to launch with an eyecare management plan that requires patients to undergo monitoring by an eyecare

professional while on the medication.<sup>1</sup> Ovarian cancer is a difficult-to-treat malignancy, with most patients presenting with late-stage disease and typically will undergo surgery followed by platinum-based chemotherapy. Unfortunately, about 80% experience recurrence and go on to develop platinum-resistant ovarian cancer.<sup>2,3</sup> The monitoring for Elahere falls well within the expertise of optometry, allowing us to help oncologists respond to the characteristic corneal epithelial changes, and in doing so, help patients receive the full benefit of their cancer therapy

by enabling intervention before drug discontinuation becomes necessary.

The MIRASOL confirmatory trial, designed to support conversion to full approval, demonstrated clinically significant improvements in key efficacy endpoints (progression-free survival, objective response rate and overall survival) compared to standard-of-care chemotherapy, making Elahere the first novel therapy to show an overall survival benefit in recurrent ovarian cancer.<sup>4</sup> The most common adverse reactions were low-grade gastrointestinal, neurosensory and a keratopathy known as microcyst-like epithelial changes (MECs).<sup>2</sup>

## MECs and Dry Eye Symptoms

In a pooled safety analysis of 464 patients treated across three clinical trials of Elahere, this keratopathy was observed in 36% of patients. It was generally characterized by MECs with or without punctate epithelial erosions. Furthermore, 26% of the patients reported dry eye sensation.<sup>1</sup>

On slit lamp exam, MECs appear as fine, non-staining punctate epithelial opacities. On retroillumination, MECs may take on a water droplet-like appearance (*Figure 1*). They may be numerous and are often observed in a circumferential pattern in the mid-peripheral epithelium with or without central involvement.<sup>1,5,6</sup>

MECs may cause changes in vision, as half of affected patients reported impairment, which included blurred vision associated with changes in refraction and temporary reductions in visual acuity.<sup>2</sup> Published case reports show an association between the location of MECs, refractive shifts and changes in corneal topography that are hypothesized to result from transient changes in the corneal epithelial thickness profile.<sup>6,7</sup>




Photo: Amadeu Carceller, MD

**Fig. 1. Paracentral non-confluent MECs.**

About  
Dr. Karpecki

**Dr. Karpecki** is the director of Cornea and External Disease for Kentucky Eye Institute and an associate professor at KYCO. He is the Chief Clinical Editor for *Review of Optometry* and chair of the New Technologies & Treatments conferences. A fixture in optometric clinical education, he consults for a wide array of ophthalmic clients, including ones discussed in this article. Dr. Karpecki's full disclosure list can be found in the online version of this article at [www.reviewofoptometry.com](http://www.reviewofoptometry.com).

## Mitigation, Management and Modifications

The recommended eyecare management plan for Elahere keratopathy includes three components: prophylactic use of topical steroids, ocular surface disease management, including use of preservative-free artificial tears, and baseline and monitoring eye exams.<sup>8</sup>

It's important to note that each ADC carries differing toxicities and therefore eyecare management plans may also differ (*Table 1*). The pre-Elahere exam is used to establish baseline refractive and ocular health status as a reference point for later evaluation of treatment-related changes, as well as to clear the patient to start topical steroids. This is a great time to offer the patient education on how and when to use their eye drops and to offer pre-treatment of any existing ocular surface disorders. Follow-up exams should include an assessment of BCVA with refraction performed as clinically indicated, along with a slit lamp examination of the anterior segment, paying close attention to the cornea and ocular surface.

Elahere is administered by IV infusion at three-week intervals. The relationship between the extent of exposure to Elahere in the plasma and the development of MECs allows the oncologist to apply dose modifications in response to the development of adverse reactions. The term "dose modification" refers to delaying the next infusion, reducing the dosage level, or, in the case of high-grade events, discontinuation of the treatment. This is primarily determined by the ocular findings. MEC keratopathy would indicate that too much drug is present. The aim is to allow time for the resolution of clinically significant adverse reactions before the next infusion and potentially reduce the severity of subsequent occurrences.<sup>1</sup>

The dose modification criteria for Elahere includes classification of

**TABLE 1. ELAHERE EYECARE MANAGEMENT PLAN<sup>1,8</sup>**

REGIMEN	RECOMMENDATION
Ophthalmic examination (at a minimum, assessment of BCVA and slit lamp exam)	Conducted prior to initiation of therapy, every other treatment cycle for the first eight cycles and as clinically indicated.  A typical treatment cycle is three weeks; therefore, the approximate timing for eye exams is at six-week intervals for the first six months of treatment for a total of four scheduled exams.
Ophthalmic topical steroids (initial Rx and all renewals after examination with slit lamp; prednisolone acetate 1% ophthalmic suspension used in clinical trials)	<b>Day before infusion:</b> one drop in each eye six times daily <b>Days one through four of each cycle (starting on the day of infusion):</b> one drop in each eye six times daily <b>Days five through eight of each cycle:</b> one drop in each eye four times daily
Preservative-free lubricating eye drops (artificial tears)	Four times daily and as needed (wait at least 10 minutes after administration of ophthalmic topical steroids)
Implement best practices for ocular surface health	Practice good eyelid margin hygiene, use sunglasses during full sunlight, avoid contact lenses during treatment period (unless medically necessary)

MECs as confluent or non-confluent. Generally, confluent keratopathy is described as multiple macro-punctate lesions in the corneal epithelium that have coalesced or appear patchy, while non-confluent superficial keratopathy may consist of multiple, distinct micro-punctate lesions in the corneal epithelium that may be numerous or dense, but have not coalesced. Non-confluent keratopathy without a clinically meaningful reduction in vision may require only monitoring and symptom management without requiring delay of the next infusion.

Keratopathy with significant reduction in BCVA ( $\geq$  three lines) or confluent keratopathy may warrant dose modification by the oncologist, including holding the next dose until it has resolved to the level of non-confluence. In addition to providing the oncologist with information to guide dose modifications, ODs should manage any concomitant ocular surface disorders.<sup>1,8</sup>

In the pooled safety analysis, more than half of ocular adverse reactions resolved to grade 1 or better within 14 days without requiring dose modification. Dose modifications were effective

in managing these events, with <1% of patients discontinuing Elahere due to ocular adverse events. There were no corneal ulcers, perforations or permanent ocular sequelae reported.<sup>1</sup>

## Building Bridges

Oncologists need our help to assess adverse events that may occur related to the use of ADC's and to prescribe and monitor prophylactic steroid drops, including evaluating BCVA, IOP and corneal findings observed on slit lamp exam and assessing changes.

Ophthalmic exam findings are used by the oncologist to determine the need for dose modifications in the context of the patient's overall health status, and ultimately, help to find the best balance between

the patient's vision-related quality of life and their cancer treatment.

Getting involved in the care of women with ovarian cancer is an opportunity to network with oncology teams during a time when the number of novel cancer therapies requiring ophthalmic monitoring is steadily growing, and more importantly, an opportunity to ease a patient's cancer burden by ensuring that her vision is in good hands. ■

*Thanks to Grace Lytle, OD, for her contributions to this column.*

1. Hendershot A, Slabaugh M, Riaz KM, et al. Strategies for prevention and management of ocular events occurring with mirvetuximab soravtansine. *Gynecol Oncol Rep.* 2023;47:101155.

2. Siegel RL, Miller KD, Wagle NS, Jemal A. Cancer statistics. *CA Cancer J Clin.* 2023;73(1):17-48.

3. Armstrong DK, Alvarez RD, Backes FJ, et al. NCCN Guidelines insights: ovarian cancer, version 3. *J Natl Compr Canc Netw.* 2022;20(9):972-80.

4. Moore KM, Angelerques A, Konecny GE, et al. Mirvetuximab soravtansine in FRa positive, platinum-resistant ovarian cancer. *N Engl J Med.* 2023;389(23):2162-74.

5. Kunkler AL, Binkley EM, Mantopoulos D, et al. Known and novel ocular toxicities of biologics, targeted agents and traditional chemotherapeutics. *Graefes Arch Clin Exp Ophthalmol.* 2019;257(8):1771-81.

6. Corbelli E, Miserocchi E, Marchese A, et al. Ocular toxicity of mirvetuximab. *Cornea.* 2019;38(2):229-32.

7. Canestraro J, Hultcrantz M, Modi S, et al. Refractive shifts and changes in corneal curvature associated with antibody-drug conjugates. *Cornea.* 2022;41(6):792-801.

8. Elahere, 2022. Prescribing information. ImmunoGen, Inc.





EDITED BY NATE LIGHTHIZER, OD

## ADVANCED PROCEDURES

# Uprooting Misdirected Lashes

*Trichiasis ablation with radiofrequency can be a more permanent treatment option.*

BY KOMAL PATEL, OD  
TAHLEQUAH, OK

**T**richiasis is a condition characterized by misdirected eyelashes toward the globe. It may result in corneal or conjunctival abrasion, chronic ocular surface disease and ulceration in more severe cases.<sup>1</sup> Patient symptoms may include pain, irritation, epiphora and foreign body sensation.<sup>2</sup> It can be classified as primary trichiasis or secondary trichiasis.

In primary trichiasis, the eyelid margin is normally positioned but the eyelash follicles are misaligned. Primary trichiasis may occur due to severe blepharitis, recurrent chalazia,

tumors, herpes zoster ophthalmicus, eyelid trauma or previous surgery.<sup>3</sup>

In secondary trichiasis, the eyelash follicles are aligned normally, but the eyelid margin is rotated inward, causing lashes to contact the globe.<sup>1</sup> Secondary trichiasis is caused by entropion associated with eyelid laxity, retractor disinsertion or posterior lamellar contraction, as seen in conditions such as cicatricial ocular pemphigoid, Stevens-Johnson syndrome, trachoma and chemical burns.<sup>1,2</sup> When associated with entropion, efforts should be made to correct the underlying condition before performing eyelash ablation. If entropion surgery cannot be performed or trichiasis

remains after surgery, perform radiofrequency ablation.

Distichiasis is characterized by one or more extra rows of eyelashes located within the tarsus and growing behind the normal row of eyelashes at the meibomian gland orifices.<sup>1,4</sup> This condition may be congenital or acquired. The cilia, although aligned normally, commonly result in globe touch due to their more posterior origination.

A permanent treatment method for trichiasis and

distichiasis involves the use of electro-surgery to cause follicular destruction, termed *trichiasis ablation*. Radiofrequency is used to selectively ablate the root of eyelash follicles without side effects caused by electrocautery on the eyelid.

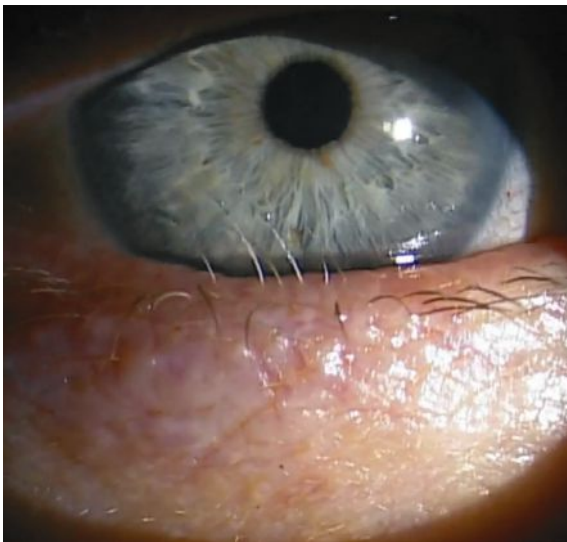
## Contraindications

These involve the cautionary approach exercised when using radiofrequency devices. Patients with cardiac pacemakers or defibrillators and use of flammable fumes such as oxygen are contraindicated with radiofrequency. If alternative treatments are not an option, the grounding plate can be placed away from the heart and the lowest power setting can be used. Trichiasis ablation can be a timely procedure depending on the number of eyelashes that need to be removed, thus patients should be comfortable lying on their back for at least 15 to 30 minutes. Any active herpetic infection should be treated prior to surgery.

## Procedural Technique

Let's review how to perform trichiasis ablation with radiofrequency.

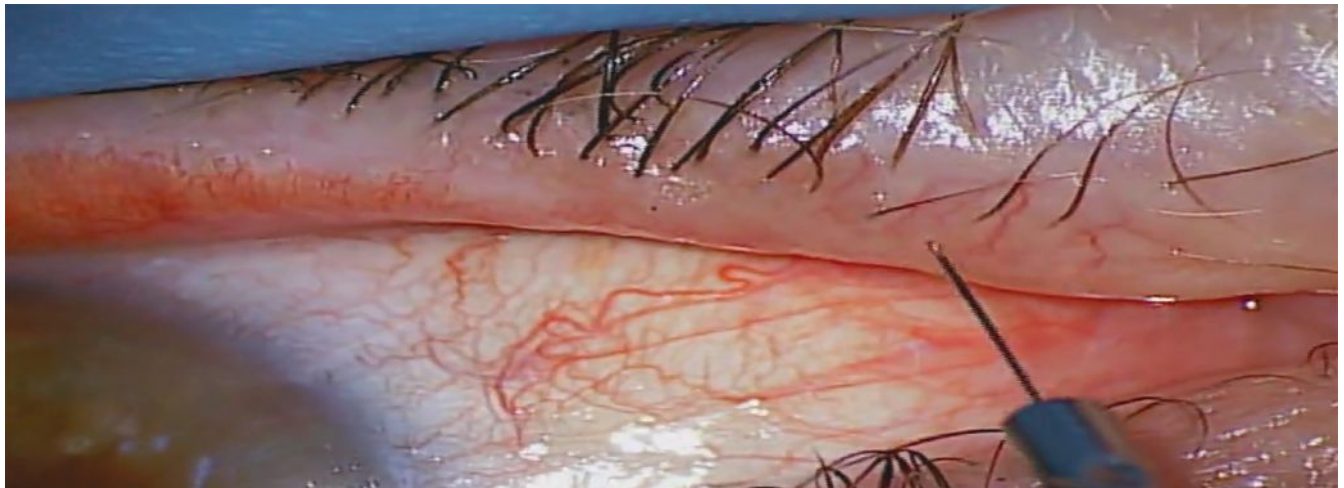
1. Place the patient in supine position, with the grounding plate/passive electrode of the radiofrequency unit underneath the patient's back or shoulder area.
2. Set up the surgical microscope or loupes.
3. Instill topical anesthetic (proparacaine, tetracaine) into both eyes to minimize reflex lacrimation, the blink reflex and keep the patient comfortable during the procedure.
4. Use an alcohol prep pad to clean around the skin and eyelashes where anesthetic will be injected.
5. Use a 30-gauge needle, bevel up, to inject anesthesia (0.5%, 1% or 2%



**Distichiasis with six offending lashes rubbing on the globe.**

### About Dr. Lighthizer

Dr. Lighthizer is the associate dean, director of continuing education and chief of specialty care clinics at the NSU Oklahoma College of Optometry. He is a founding member and immediate past president of the Intrepid Eye Society. Dr. Lighthizer's full disclosure list can be found in the online version of this article at [www.reviewofoptometry.com](http://www.reviewofoptometry.com).



**Micro-insulated electrode shown in this photo. The electrode should be inserted adjacent to the eyelash to the base of the follicle.**

lidocaine with epinephrine 1:100,000 or 1:200,000) subcutaneously at a 10° to 15° angle adjacent to the eyelid margin where eyelashes will be treated. Avoid injecting toward the globe or directly into the eyelid margin. Continue to inject as the needle is withdrawn to form a small bolus of anesthetic either directly below the offending lashes (if on the lower eyelid) or directly above the offending lashes (if on the upper eyelid).

6. A gauze pad or cotton-tipped applicator can be used to massage the anesthesia into the area.

7. Use a 10% povidone-iodine (betadine) swabstick to clean the ocular adnexal area and eyelashes to maintain asepsis. Povidone-iodine should remain on the skin for three minutes. This step is optional, depending on treating clinician preference.

8. Use a piece of gauze to remove any excess povidone-iodine if needed.

9. Use forceps to test the area for proper anesthesia. Ask the patient if they feel any pain or pinching. Pressure sensation is expected.

10. If inadequate anesthesia is present on the eyelid margin, which commonly occurs, apply a few Weck-Cel sponges soaked in 4% topical lidocaine directly onto the offending eyelashes and eyelid margin. Hold each sponge on the eyelid for approximately 30 to 60 seconds. Always ensure the patient is fully anesthetized

before performing the procedure.

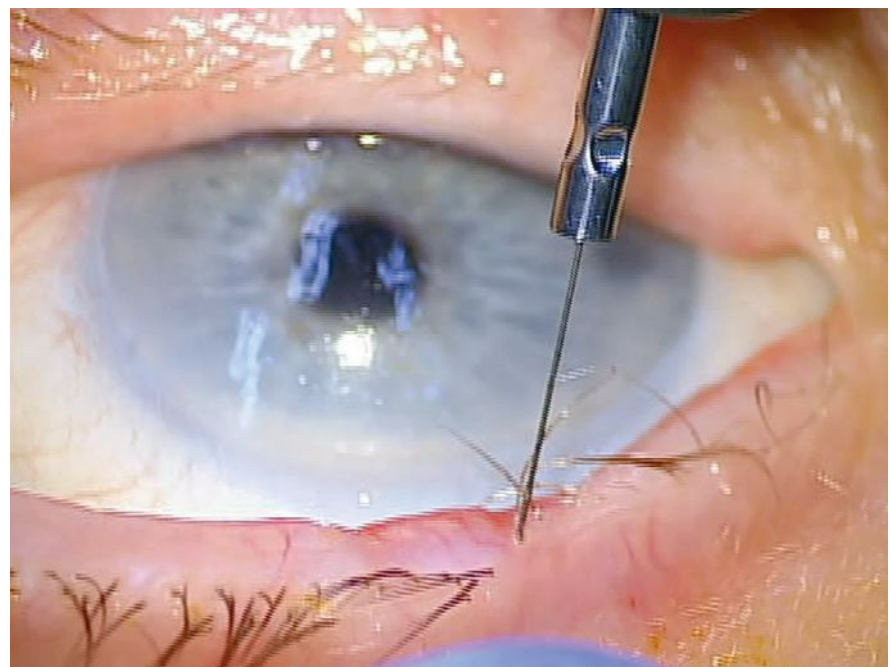
11. Turn on the smoke evacuator that comes with the radiofrequency unit and place it as close to the operative site as possible; no further than 2cm.

12. Partially evert the eyelid to visualize the offending eyelashes and to keep the eyelid margin away from the globe.

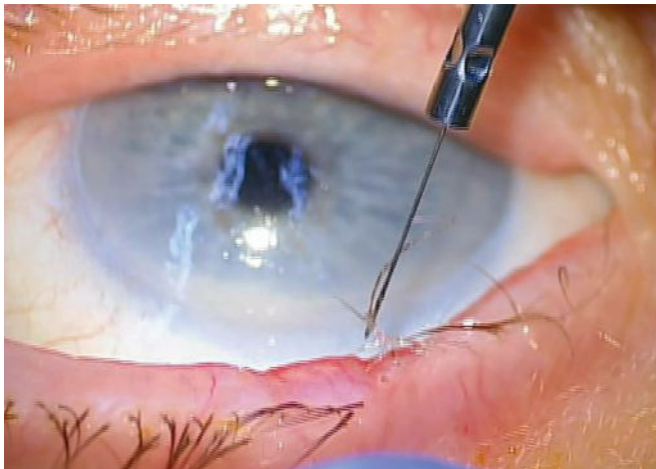13. Align the micro-insulated needle electrode or fine wire electrode down the shaft of the offending eyelash. The electrode should be inserted adjacent to the eyelash to the base

of the follicle. This is approximately 2.4mm for the upper eyelid and 1.4mm for the lower eyelid. It is important to match the orientation of the electrode with the orientation of the offending eyelash.

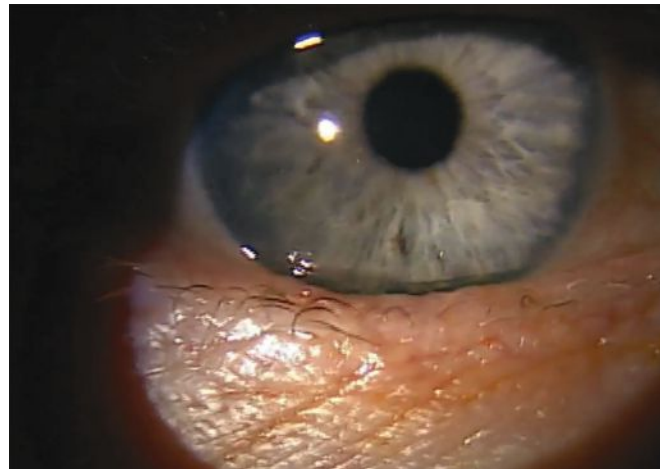
14. Once in the hair follicle, the foot pedal is pressed for one to two seconds on setting 3 (coagulate/hemostasis) at a starting power of 3. A successful removal is when the eyelash comes out on the electrode. Multiple attempts are often required to successfully get the eyelash to stick to the electrode.



**Perfect orientation of the radiofrequency electrode down the shaft of the lash.**



The ideal endpoint of radiofrequency ablation of lashes is the lash being coagulated and sticking to the electrode.



An eight-week follow-up showing the same patient in the first image with all lashes completely gone without regrowth.

If multiple attempts are required, it is encouraged to go around the lash when treating. For example, if the electrode is on the right side of the eyelash and multiple attempts fail to coagulate the follicle and remove the lash, subsequent attempts should position the electrode to the left side of the lash, on the top or on the bottom of it.

**Radiofrequency settings.** Setting 3: coagulate/hemostasis (10% cutting, 90% coagulation)— power 3 to 6.

15. If the eyelash is not sticking to the electrode after several attempts (five to 10), use forceps to gently pull on the eyelash to see if it removes with ease. If a tugging sensation is felt, coagulate again. No resistance should be felt upon removing the eyelash, indicating a successful ablation.

16. Repeat this process until all offending eyelashes have been removed.

17. Apply erythromycin 0.5% ophthalmic ointment to the eyelid margin.

18. No bandages or patches are needed at the conclusion of the procedure.

19. Measure blood pressure and pulse.

## Follow-up

An operative report should be completed after every procedure that describes the steps taken to perform the

procedure. Blood pressure and pulse are measured after the procedure due to the injection of epinephrine. An antibiotic ointment is used three times a day for seven days to prevent infection and aid healing. A one- to two-month follow-up appointment is typically booked to assess treatment success and to determine whether re-treatment is needed. The patient is advised to return sooner if signs and symptoms of infection arise.

Redness and bruising are temporary during the postoperative phase and will self-resolve once completely healed. Bruising may occur from injection of anesthesia and typically resolves within a week. Infection is rare and prevented with the antibiotic ointment that is prescribed postoperatively. If infection were to occur, use topical or oral antibiotics.

Eyelid complications including notching and scarring are more common with electrocautery than radiofrequency, but can occur if the depth of the electrode is excessive or if the radiofrequency power setting is too high.<sup>2</sup> Due to the proximity of the eyelid margin to the globe, accidental injury to the eye may occur.<sup>5</sup> One study found a complication rate of 14% after radiofrequency ablation.<sup>6</sup> These complications included eyelid notching, madarosis, progressive entropion and hyperpigmentation. Another study, using a smaller group size, found faint hypopigmentation in

8.3% of patients and eyelid notching in 16.6% of patients.<sup>7</sup>

## Takeaways

Trichiasis ablation with radiofrequency is a more long-lasting treatment option to offer patients over eyelash epilation. Recurrence of eyelash growth is possible with radiofrequency ablation; however, the procedure can be repeated two to three months after initial treatment with success. This simple and effective in-office, surgical procedure can yield tremendous improvement in patient symptoms. ■

1. Dutton JJ and Waldrop TG. Atlas of Oculoplastic and Orbital Surgery. 2nd ed. Wolters Kluwer; 2019.

2. Fowler G. Pfenninger and Fowler's Procedures for Primary Care. Elsevier; 2020.

3. Bowling B and Kanski JJ. Kanski's Clinical Ophthalmology: A Systematic Approach. 8th ed. Elsevier; 2016: 135-6.

4. Onofrey BE, Skorn L, Jr. and Holdeman NR. Ocular Therapeutics Handbook: A Clinical Manual. 3rd ed. Lippincott Williams & Wilkins; 2012.

5. Hainer BL. Electrosurgery for the skin. Am Fam Physician. 2002;66(7):1259-66.

6. Al-Fakey YH. Treatment of trichiasis with high-frequency radiowave electrosurgery. Saudi J Ophthalmol. 2006;20(2):119-23.

7. Sakarya Y, Sakarya R and Yildirim A. Electrolysis treatment of trichiasis by using ultra-fine needle. Eur J Ophthalmol. 2010;20(4):664-8.


## ABOUT THE AUTHOR



**Dr. Patel** is an assistant professor at the Oklahoma College of Optometry (NSUOCO). She completed a primary care residency at NSUOCO specializing in ocular disease and advanced procedures. Dr. Patel is a diplomate of the American Board of Optometry and a fellow of the American Academy of Optometry. She has no financial disclosures.



# Bringing You the Best in Class of Diagnostic Visual Testing Systems and Dry Eye Solutions



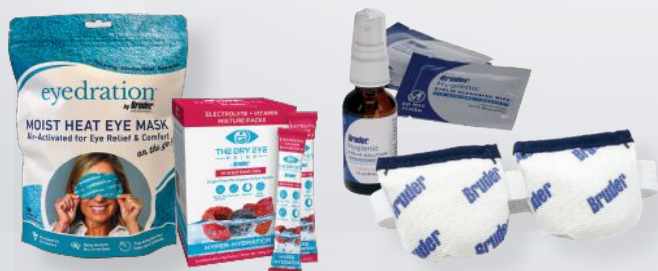Discover the power of collaboration, with eye care solutions that work together. Hilco Vision companies **Bruder Healthcare** and **M&S Technologies** bring Vision Care Solutions to optometrists and ophthalmologists alike.

Join us at VEE  
Booth P2027

## Bruder

### Open Your Eyes to Bruder™

HYGIENE | HEAT | HYDRATION



## M&S TECHNOLOGIES



### Setting the Standard in Computerized Vision Testing

ACCURACY | PRECISION | RELIABILITY



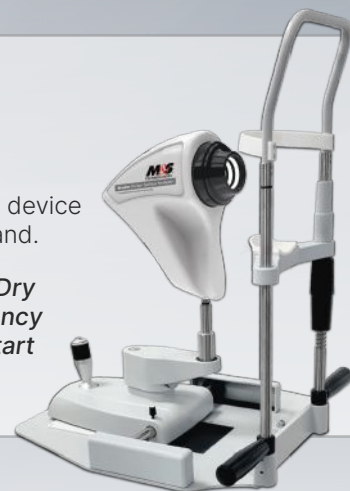SPEED | ACCURACY | EASE OF USE

## Assess Ocular Surface Disease (OSD) in 15 Seconds

Introducing the new M&S Bruder Ocular Surface Analyzer™ (BOSA), an all-in-one, easy-to-use device for dry eye testing, delivering speed, accuracy, and results that patients can see and understand.

*"BOSA provides a ready-made hub to help identify, quantify, and rectify OSD, with recommended treatments tailored to each patient's test results." —Paul Karpecki, OD, FAAO*

*"The answer for both the established Dry Eye practice looking to improve efficiency and the eye care practice looking to start a Dry Eye clinic." —Darrell White, MD*



Want to know more? Contact your Bruder Healthcare or M&S Technologies account representative or visit either website.

[BruderPro.com](http://BruderPro.com) | [MSTech-eyes.com](http://MSTech-eyes.com)



Bruder

HILCO VISION  
VISION CARE SOLUTIONS

M&S  
TECHNOLOGIES



## Faculty



### Assistant Professor- AZ- Pediatrics/Vision Therapy

#### Full-time non-tenure track faculty position for the Arizona College of Optometry

**Responsibilities:** Candidates are expected to be highly knowledgeable in the field of Primary Eye Care, Pediatrics and Vision Therapy who can teach courses and/or laboratories in the subject area. The candidate must also provide clinical instruction to professional students as well as residents and be involved in interdisciplinary practice with other educational professionals.

Candidates expressing interest in practice areas of Strabismus, Vision Therapy, Acquired Brain Injury and/or Sports Vision are desired. Candidates must be willing to actively participate in curricular assessment, professional development, student counseling and service activities within the college, university and the scientific community. Successful candidates are also expected to be involved in research and scholarly activities, and have a sincere commitment to optometric education, community service and patient care. Primary duties include, but are not limited to:

#### a) Teaching

- Developing and delivering lectures and/or laboratories for primary eye care, pediatrics/vision therapy and other related areas, as assigned;
- Embracing and enhancing the didactic philosophies in the O.D. program;
- Maintaining and expanding the high quality clinical practice environment for optometry students on rotation;
- Precepting students on clinical rotation at the Midwestern University Eye Institute; Therapy Institute

#### b) Service

- Helping to maintain and grow the state of the art primary eye care service with a strong interdisciplinary focus that meets the needs of patients in the surrounding community; is efficient, patient friendly, and cost-effective;
- Working closely together with all optometry and ophthalmology faculty to provide a complete range of eye and vision care services;
- Participating in leadership roles in state, regional, and national optometry organizations;
- Participating on College and University committees,

as assigned;

- Participating in College and University service activities

#### c) Scholarly activity

- Engaging in scholarly activity, including presentations at scientific meetings, research, and publication in peer-reviewed journals

**Qualifications:** Candidates must possess a Doctor of Optometry (O.D.) degree from an ACOE accredited institution, must have completed an ACOE-accredited residency in Pediatrics/Vision Therapy or related fields, and must be eligible for an Arizona optometric license. Primary eye care clinic expertise is also required.

**Salary:** Salary will be commensurate with qualifications and experience.

**Contact Information:** Inquires may be directed to:  
Alicia Feis, O.D. Dean, Arizona College of Optometry  
Midwestern University  
19555 North 59th Avenue  
Glendale, AZ 85308  
By Email: [afeis@midwestern.edu](mailto:afeis@midwestern.edu)

**Application:** Please submit your application packet through Midwestern University's online job board:

1. Visit <https://www.midwestern.edu/>
2. Select 'Careers at MWU' scroll to the bottom of the page under Resources
3. Select 'View Current Job Openings'
4. Select 'faculty' for job category and click 'search'. The online profile should include a letter of interest (uploaded as an attachment), curriculum vitae (uploaded as an attachment).

Midwestern University is an Equal Opportunity/Affirmative Action employer that does not discriminate against an employee or applicant based upon race; color; religion; creed; national origin or ancestry; ethnicity; sex (including pregnancy); gender (including gender expressions, gender identity, and sexual orientation); marital status; age; disability; citizenship; past, current, or prospective service in the uniformed services; genetic information; or any other protected class, in accord with all federal, state and local laws, including 41 C.F.R. 60-1.4(a), 250.5(a), 300.5(a) and 741.5(a). Midwestern University complies with the Smoke-Free Arizona Act (A.R.S. 36-601.01) and the Smoke Free Illinois Act (410 ILCS 82/). Midwestern University complies with the Illinois Equal Pay Act of 2003 and Arizona Equal Pay Acts.

### Practice For Sale



Practice Sales • Appraisals • Consulting  
[www.PracticeConsultants.com](http://www.PracticeConsultants.com)

#### PRACTICES FOR SALE NATIONWIDE

Visit us on the Web or call us to learn more about our company and the practices we have available.

[info@PracticeConsultants.com](mailto:info@PracticeConsultants.com)

925-820-6758

[www.PracticeConsultants.com](http://www.PracticeConsultants.com)

#### Targeting Optometrists?

##### CLASSIFIED ADVERTISING WORKS

- JOB OPENINGS • CME PROGRAMS
- PRODUCTS & SERVICES • AND MORE...

Contact us today for classified advertising:

Toll free: 888-498-1460

E-mail: [sales@kerhgroup.com](mailto:sales@kerhgroup.com)

#### Optometric practice in Del Norte Ca is selling a very potentially profitable practice.

There are no other optometry, ophthalmology or optical offices in the city or county. The office is 5 blocks from an amazing coastline with beautiful forest, beaches and rivers. 1250 sf office with a wonderful staff.

Any reasonable offer will be seriously appreciated.


If interested, please contact  
[sinouye7@gmail.com](mailto:sinouye7@gmail.com)

### Do you have CE Programs?

#### CONTACT US TODAY FOR CLASSIFIED ADVERTISING

Toll free:  
888-498-1460

E-mail:  
[sales@kerhgroup.com](mailto:sales@kerhgroup.com)



Contact us today for  
classified advertising:  
Toll free: 888-498-1460  
E-mail: [sales@kerhgroup.com](mailto:sales@kerhgroup.com)

# REVIEW<sup>®</sup> of OPTOMETRY

**Merchandise Offered**

## FRAME DISPLAYS & OPTICAL INTERIORS

FrameDisplays.com is the one-stop-shop for all your optical displays, furniture, and design needs.



Wall Mount



Counter Top



Locking Rods



Trays & Frame Bags



Custom Frame Rods



Optical Cabinets



1-877-274-9300 • [www.framedisplays.com](http://www.framedisplays.com)



Trusted by more than 40,000 eye care professionals worldwide.

### COMPLIMENTARY DESIGN SERVICES



**Complimentary  
Zoom Design  
Session**



**0% Financing  
& Interest for  
36 Months\***

**FREE SHIPPING**

**\$100+ Orders\***

\*) Excludes Freight Shipments

Code: **FREESHIPROOF**

# REVIEW of OPTOMETRY

## Targeting Optometrists?

**CLASSIFIED ADVERTISING WORKS**

- JOB OPENINGS
- CME PROGRAMS
- PRODUCTS & SERVICES
- AND MORE...

Contact us today for classified advertising:

Toll free: **888-498-1460**

E-mail: [sales@kerhgroup.com](mailto:sales@kerhgroup.com)

**KERHGROUP**





# Well, This is Odd

*Do you know the clinical features of this disease?*

**A** 22-year Hispanic female was referred with concern for optic nerve edema in both eyes (OU). She was symptomatic to left-sided headache for one week with ipsilateral transient visual obscuration (TVO) and a “pressure” sensation behind her left eye (OS). She denied prior history of headaches or similar episodes, recent fluctuations in weight and pulsatile tinnitus. Her BMI was 22.1 and she was on oral contraceptive for two years.

Best-corrected visual acuity was 20/20 OU, Ishihara color plates were full OU, there was no relative afferent pupillary defect, confrontation visual fields were full OU and there were no extraocular motility deficits. Anterior segment examination was unremarkable OU.

## Take the Retina Quiz:

1. What is true of the imaging scans?
  - a. B-scan shows hyperechoic lesions within the optic nerve head OU.
  - b. The optic disc is flat with sharp margins.
  - c. Fundus autofluorescence (FAF) shows leakage.
  - d. There is obscuration of the peripapillary blood vessels.
2. What is the most likely diagnosis?
  - a. Central retinal vein occlusion.
  - b. Myelinated nerve fiber.
  - c. Optic disc drusen.
  - d. Optic disc edema.
3. Which is the gold standard for diagnosis?
  - a. B-scan ultrasonography.
  - b. Computed tomography.
  - c. Enhanced-depth imaging OCT.
  - d. FAF.

4. Which of the following is a complication?

- a. Anterior ischemic optic neuropathy.
- b. Cataract.
- c. Cystoid macular edema.
- d. Retinal detachment.

5. All of the following are typical fundus findings, except:

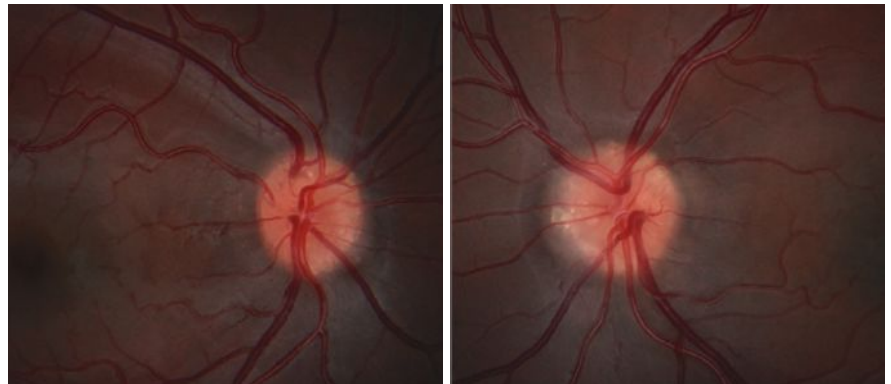
- a. Collateral disc vessels.
- b. Presence of cilioretinal artery.
- c. Vascular tortuosity.
- d. All of the above.

*For answers to the quiz, see page 90.*

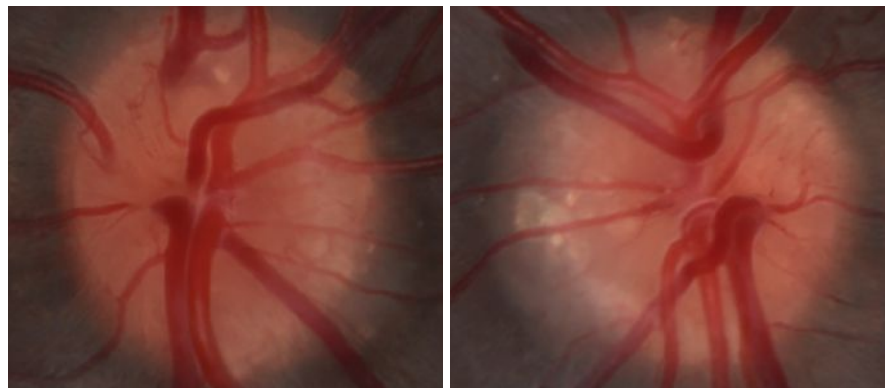
## Diagnosis

Stereoscopic fundus examination revealed bilateral optic nerve elevation with a lumpy and irregular contour (Figures 1 and 2). The disc margins appeared sharp without visible spontaneous venous pulsation present (Figures 1 and 2). FAF identified hyperAF lesions present within the optic nerve head OU (Figure 3). Further investigation with B-scan ultrasonography confirmed the presence of hyperechoic lesions buried within the optic nerve head OU (Figure 4).

While the imaging was consistent with optic disc drusen (ODD) OU, the new-onset headache with TVO raised concern for superimposed true optic nerve edema. For this reason, an MRI was obtained of the brain and orbits with and without contrast, as well as



**Fig. 1. Fundus photos of OD (left) and OS (right).**



**Fig. 2. High magnification optic nerve photos of OD (left) and OS (right).**

magnetic resonance venogram of the brain, to rule out intracranial mass or other etiologies of intracranial hypertension.

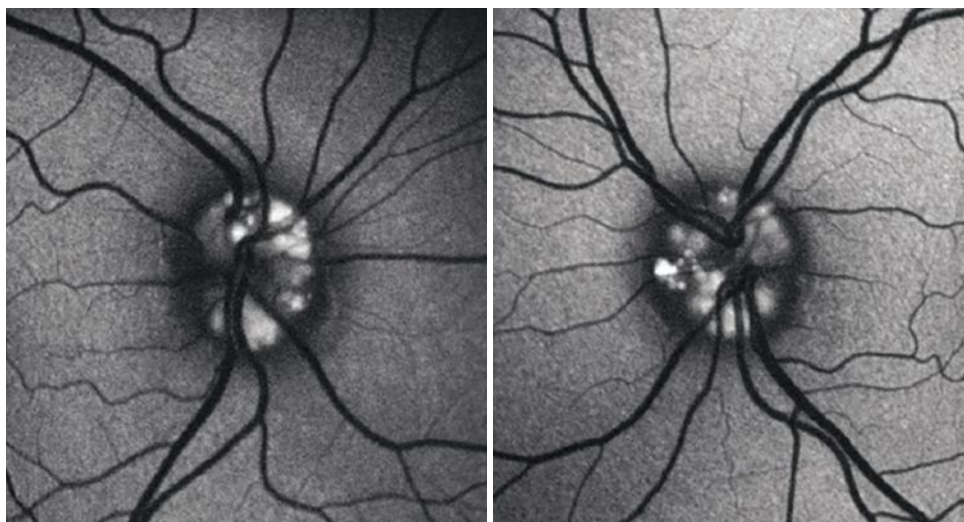
## Discussion

ODD has a clinical prevalence of approximately one in 500 and histopathologic prevalence as high as one in 40.<sup>1</sup> Histopathologic studies suggest a higher subclinical prevalence based on the deeper location of many clinically undiagnosed drusen due to limitations in diagnostic techniques.<sup>1-3</sup> ODD tends to be bilateral (69% to 91%), though asymmetric, with a slight predilection toward females and Caucasians.<sup>1,2</sup>

While the exact pathophysiology is debated, the leading theory is that ODD are accumulations of metabolic byproducts due to impaired axoplasmic transport.<sup>3,4</sup> Thus, ODD are comprised calcium phosphate, mucopolysaccharides, amino acids and nucleic acids.<sup>3-5</sup> A small portion of ODD shows an autosomal dominant inheritance pattern with a positive family history portending a 10 times higher risk of ODD.<sup>5-7</sup>

Clinically, ODD are either classified as visible/superficial (nodular and elevated optic nerve appearance) or buried/deep (undetectable by ophthalmoscopic examination).<sup>3-5</sup> Buried ODD tend to be more common in children due to the natural history of these lesions to acquire calcium and eventually erupt to the surface with age, often during teenage years.<sup>3-5</sup> While ODD may obscure the optic disc margins, they rarely induce peripapillary blood vessel obscurations due to their anatomic location.<sup>1,3,8</sup>

ODD are rarely symptomatic and most commonly found incidentally on exam as the most frequent cause of pseudopapilledema.<sup>1,3</sup> This highlights the importance of a careful review of systems and evaluating the peripapillary vasculature for slight blood vessel obscurations as pseudopapilledema may be superimposed with true papilledema.<sup>1,8</sup> A pediatric case series of patients with



**Fig. 3.** FAF of OD (left) and OS (right).

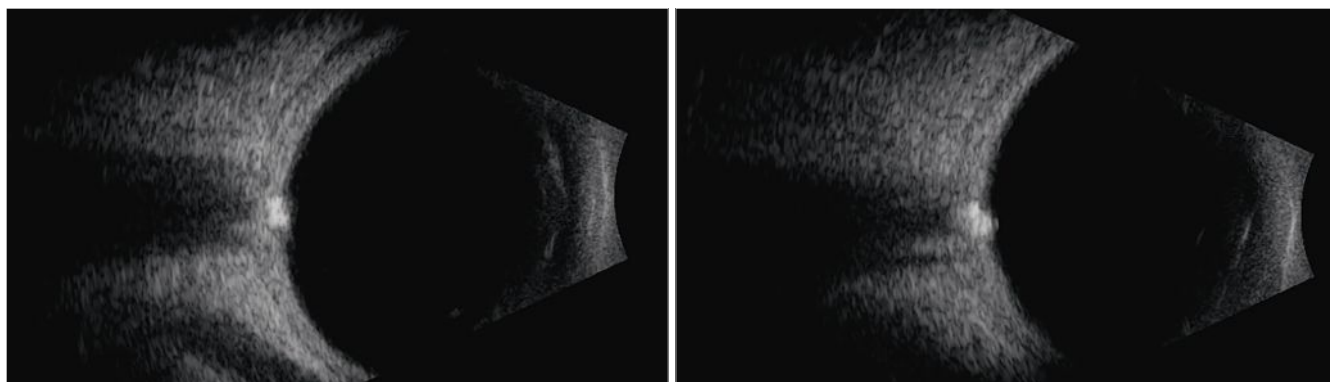
idiopathic intracranial hypertension showed a high concomitant ODD prevalence of 15%, with 72% of patients affected by headache followed by 45% with TVO.<sup>8</sup>

Ophthalmoscopic examination is enhanced by ancillary testing such as B-scan ultrasonography, FAF and fluorescein angiography (FA). B-scan ultrasound is the diagnostic gold standard with the highest sensitivity at detecting calcific lesions present within the optic nerve head substance, though it is less effective at identifying buried ODD due to lack of calcification.<sup>1,3,4,6</sup> While less sensitive than B-scan, FAF similarly shows hyperautofluorescence of superficial ODD better than with buried ODD.<sup>1,3,4,6</sup> Combining FAF with FA is useful to assess for true optic nerve edema as FA will demonstrate leakage of the optic nerve whereas ODD will demonstrate nodular staining of the lesions.<sup>1,4</sup>

There are emerging bodies of evidence attempting to validate enhanced-depth imaging OCT, though it has not yet been shown to outperform B-scan ultrasound as the diagnostic gold standard.<sup>9</sup> It is worth commenting that ODD appear as hyperintense foci on computed tomography due to their calcific nature, but it can be easily missed with slices 1.5mm or greater and ODD alone is not an indication for CT imaging due to radiation exposure.<sup>1,5</sup>

Nearly half of eyes with ODD have normal visual field testing, and approximately one in three eyes will show an enlarged blind spot.<sup>3</sup> Less commonly, there may be arcuate defects or concentric narrowing of the visual field.<sup>3,5</sup> There is a greater incidence of visual field deficits in eyes with superficial ODD as compared in eyes with buried drusen; these patients should be monitored closely with serial retinal nerve fiber layer scans as an objective measure of progression.<sup>3</sup>

Found coincidentally in patients with ODD are increased vascular tortuosity, abnormal vascular branching, collateral disc vessels and a higher incidence of cilioretinal artery presence.<sup>1,6</sup> The most frequent cause of visual loss in eyes with ODD is non-arteritic anterior ischemic optic neuropathy due to crowding of the optic canal similar to what occurs in patients with a physiologic “disc at risk.” Other causes of vision loss include retinal vascular occlusions (venous > arterial), progressive visual field loss and peripapillary subretinal neovascular membranes (treatment only required when foveal-threatening).<sup>1,3</sup> Progressive visual field loss or concomitant glaucoma are managed similarly with topical ocular hypotensives to preserve as much visual function as possible; it may be difficult to subjectively detect progression by disc assessment alone, so objective metrics are often the best indicator for



**Fig. 4. B-scan ultrasound horizontal axial scans over the nerve OD (left) and OS (right).**

when to treat or escalate treatment.<sup>1,3,4</sup> There are no recommended surgical interventions for ODD. Prognosis is generally good, and vascular events are managed as they would be in the absence of ODD.

On retrospective evaluation, one can appreciate the presence of cilioretinal artery OU and a slit defect OD without a corresponding visual field defect. Although our patient had no apparent peripapillary blood vessel obscurations, a complete neuroimaging work-up was indicated due to the new onset headache and TVO. Fortunately, there was

no mass or other radiographic evidence suggestive of intracranial hypertension. This patient has been followed with stable visual fields for the last 18 months.

In summary, the presence of optic disc drusen alone does not preclude the possibility of superimposed true optic disc edema. In cases with a positive review of systems, a complete work-up is indicated to exclude concomitant disease. While the majority of eyes with ODD carry a favorable diagnosis, there are no effective therapeutic options to reverse any incurred vision loss. ■

1. Ryan SJ, Davis JL, Flynn HW, et al. Retina, Fifth ed. London; New York: Saunders/Elsevier, 2013.
2. Friedman AH, Beckerman B, Gold DH, et al. Drusen of the optic disc. *Surv Ophthalmol.* 1977;21(5):373-90.
3. Allegrini D, Pagano L, Ferrara M, et al. Optic disc drusen: a systematic review: up-to-date and future perspective. *Int Ophthalmol.* 2020;40(8):2119-27.
4. Auw-Haendrich C, Staubach F, Witschel H. Optic disc drusen. *Surv Ophthalmol.* 2002;47(6):515-32.
5. Bowling B, Kanski JJ. Kanski's Clinical Ophthalmology: A Systematic Approach. Elsevier, 2016.
6. Chang MY, Pineles SL. Optic disc drusen in children. *Surv Ophthalmol.* 2016;61(6):745-58.
7. Antcliff RJ, Spalton DJ. Are optic disc drusen inherited? *Ophthalmology.* 1999;106(7):1278-81.
8. Genizi J, Meiselles D, Arnowitz E, et al. Optic nerve drusen is highly prevalent among children with pseudotumor cerebri syndrome. *Front Neurol.* 2021;12:789673.
9. Rosa N, De Bernardo M, Abbinante G, et al. Optic nerve drusen evaluation: a comparison between ultrasound and OCT. *J Clin Med.* 2022;11(13).

## ADVERTISER INDEX

*This index is published as a convenience and not as part of the advertising contract. Every care will be taken to index correctly. No allowance will be made for errors due to spelling, incorrect page number, or failure to insert.*

Acuity Pro.....	35
.....(580) 243-1301	
..... <a href="http://www.acuitypro.com">www.acuitypro.com</a>	
..... <a href="mailto:info@acuitypro.com">info@acuitypro.com</a>	
Alcon.....	Covertip
..... <a href="http://www.alcon.com">www.alcon.com</a>	
Alcon.....	7
..... <a href="http://www.alcon.com">www.alcon.com</a>	
Alcon.....	Cover 4
..... <a href="http://www.alcon.com">www.alcon.com</a>	
Apellis.....	47
..... <a href="http://www.apellis.com">www.apellis.com</a>	
Bausch + Lomb.....	15
.....(800) 323-0000	
..... <a href="https://www.bausch.com/">https://www.bausch.com/</a>	
Bruder Healthcare Company.....	83
.....(888) 827-8337	
..... <a href="http://www.brunder.com">www.brunder.com</a>	
CooperVision.....	19
.....800-341-2020	

..... <a href="https://coopervision.com/">https://coopervision.com/</a>	
CooperVision.....	Insert
.....800-341-2020	
..... <a href="https://coopervision.com/">https://coopervision.com/</a>	
First Insight.....	31
.....(800) 233-5469	
..... <a href="http://first-insight.com">first-insight.com</a>	
Glaukos.....	9
.....(800) 452-8567	
..... <a href="http://www.glaukos.com">www.glaukos.com</a>	
Icare USA.....	Insert
.....(888) 422-7313	
..... <a href="http://www.icare-world.com/USA">www.icare-world.com/USA</a>	
..... <a href="mailto:infoUSA@icare-world.com">infoUSA@icare-world.com</a>	
Keeler Instruments.....	11
.....(800) 523-5620	
..... <a href="http://www.keelerusa.com">www.keelerusa.com</a>	
..... <a href="mailto:customerservice@keelerusa.com">customerservice@keelerusa.com</a>	
Nanodropper.....	13
.....(507) 405-5676	
..... <a href="http://www.nanodropper.com/ReviewOpt">www.nanodropper.com/ReviewOpt</a>	
..... <a href="mailto:pro@nanodropper.com">pro@nanodropper.com</a>	
Nextgen.....	Cover 3
..... <a href="http://www.nextgen.com/I-ophth">www.nextgen.com/I-ophth</a>	
Oasis Medical.....	39
.....(844) 820-8940	
..... <a href="http://www.oasismedical.com">www.oasismedical.com</a>	

..... <a href="mailto:customerservice@oasismedical.com">customerservice@oasismedical.com</a>	
Olleyes.....	25
.....(855) 655-3937	
..... <a href="http://www.olleyes.com">www.olleyes.com</a>	
..... <a href="mailto:info@olleyes.com">info@olleyes.com</a>	
Oyster Point.....	42, 43
..... <a href="https://oysterpointrx.com/">https://oysterpointrx.com/</a>	
Reichert Technologies.....	Cover 2, 3
.....(888) 849-8955	
..... <a href="http://www.reichert.com">www.reichert.com</a>	
Thea Pharma.....	23
.....781-832-3664	
..... <a href="https://www.tvizia.com/">https://www.tvizia.com/</a>	
Topcon.....	21
.....201-599-5100	
..... <a href="http://www.topconhealthcare.com">www.topconhealthcare.com</a>	
X-Cel Specialty.....	31
.....800-241-9312	
..... <a href="http://www.xcelspecialtycontacts.com/">www.xcelspecialtycontacts.com/</a>	
Zeavision.....	65
..... <a href="http://eyepromise.com">eyepromise.com</a>	



Find out first from

**REVIEW**  
of OPTOMETRY

### The News Feed

Published July 28, 2023 • By Staff  
CORNEA, NEWS

### PACK-CXL Found Effective Against Bacterial Keratitis

This promising, noninvasive treatment option may help with standard antimicrobial treatment.

A concern in infectious keratitis management is multi-resistant bacterial strains. If your first-line antibiotic drug isn't effective, most clinicians would add another to increase the chances of halting ulcer during a critical period.

## THE NEWS FEED

Updated every weekday

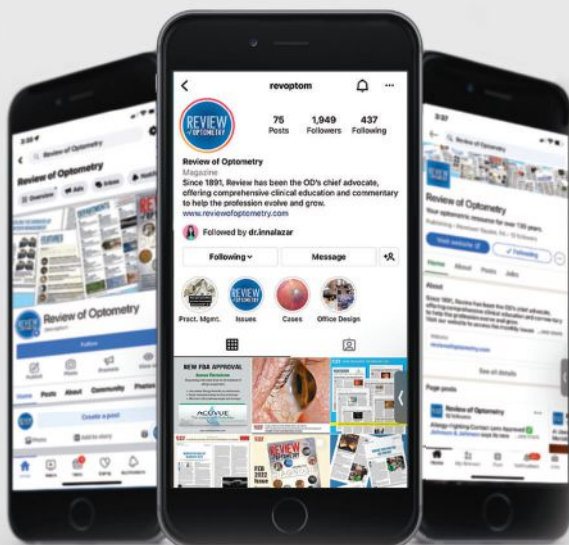[www.reviewofoptometry.com/news](http://www.reviewofoptometry.com/news)

OVER 60 NEWS STORIES PUBLISHED EVERY MONTH

Read the latest news as it happens—prior to print!

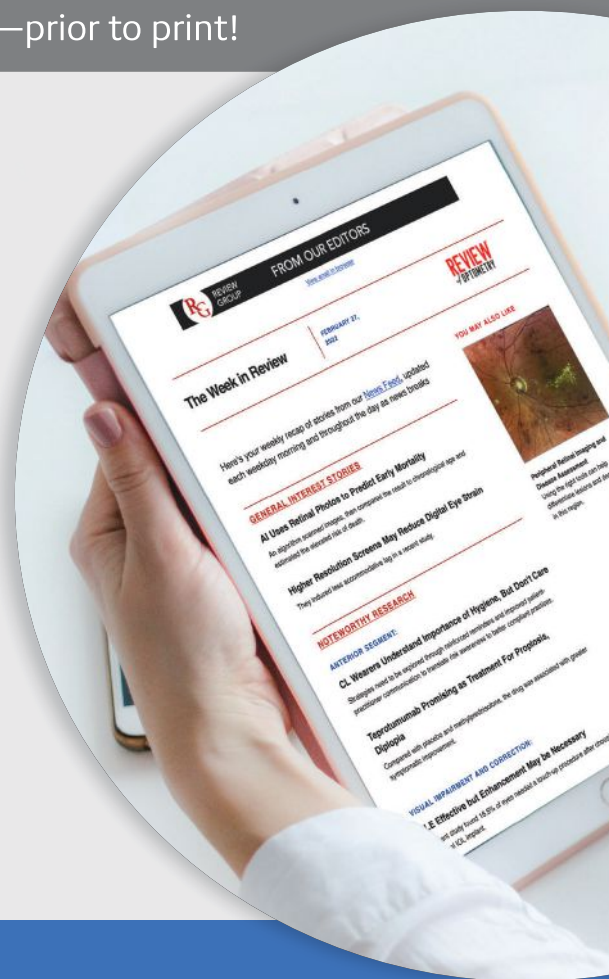
### Three ways to keep up with current events:

- 1 on the website
- 2 through social media
- 3 in your inbox



FACEBOOK: /revoptom  
INSTAGRAM: @revoptom

TWITTER: @revoptom  
LINKEDIN: review-of-optometry





# The Ol' Switcheroo

*Blurring of central vision indicated to the patient—and us—that something was amiss. Do you know what happened?*

**A** 78-year-old woman presented for an emergency visit with a chief complaint of “dimming” vision in both eyes of five days’ duration. She explained that things didn’t go black, just blurred, and now she required a handheld magnifier to see small print.

Her ocular history was positive for bilateral pseudophakia with bilateral YAG capsulotomies and open-angle glaucoma, surgically controlled via a combination of lens extraction and stent insertion. Her systemic history was positive for well-controlled

hypertension and anemia. She was not diabetic. She denied trauma or allergies of any kind.

## Clinical Findings

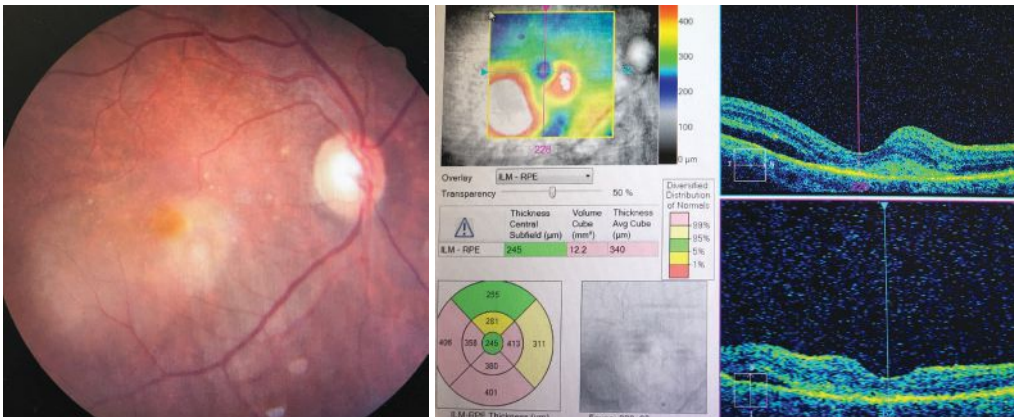
The patient’s best uncorrected entering visual acuities were 20/30 OD and 20/200 OS at distance and near with no improvement upon pinhole. A refraction of +0.50/+3.50 improved visual acuity to 20/25 OD and there was no improvement OS. Her external examination was normal OD and there was no afferent defect. Confrontation visual field OS revealed a

central distortion covering the central 5-7 degrees.

Biomicroscopic examination of the anterior segment found normal tissues and open angles. Her intraocular lenses were well centered and stable. Her intraocular pressures measured 12mm Hg OD and 16mm Hg OS using Goldmann applanation tonometry. The pertinent dilated fundus examination findings are demonstrated in the photo.

## Additional Testing

Amsler grid testing was completed, demonstrating central blur and distortion. Brightness testing and color testing were completed, demonstrating no loss of either. Ocular photography was completed along with OCT. Carotid auscultation and blood pressure were also completed.



## Your Diagnosis

What would be your diagnosis in this case based on the presentation? What’s the likely prognosis? What’s an appropriate intervention? To find out, read the online version of this article at [www.reviewofoptometry.com](http://www.reviewofoptometry.com). ■

*Dr. Gurwood thanks Nick Karbach, OD and Denise Gurwood, OD, for their contributions to this case.*

**This is the patient’s presentation and OCT. Are there any key findings that align with the patient’s report?**

### About Dr. Gurwood

Dr. Gurwood is a professor of clinical sciences at The Eye Institute of the Pennsylvania College of Optometry at Salus University. He is a co-chief of Primary Care Suite 3. He is attending medical staff in the department of ophthalmology at Albert Einstein Medical Center, Philadelphia. He has no financial interests to disclose.

## Retina Quiz Answers (from page 86)—Q1: a, Q2: c, Q3: a, Q4: a, Q5: d

### NEXT MONTH IN THE MAG

In April, we present our annual issue devoted to corneal disease care. Articles will include:

- Equip Your Practice—and Yourself—to Tackle Keratoconus
- Corneal Care: When to Refer and When to Manage

- Advances in Endothelial Surgery: An Update for ODs
- Managing Corneal Neuropathic Pain [Earn 2 CE credits]

*Also in this issue:*

- How to Find, Train and Retain Good Staff Members



# “NextGen® Ambient Assist is the greatest improvement in technology since X-rays went digital.”

Chris Wixon, MD, Cardiovascular | Savannah Vascular Institute

Integrated ambient listening technology securely converts the natural patient-provider conversation into a structured note that can quickly be reviewed and sent into the patient's chart—all in seconds.

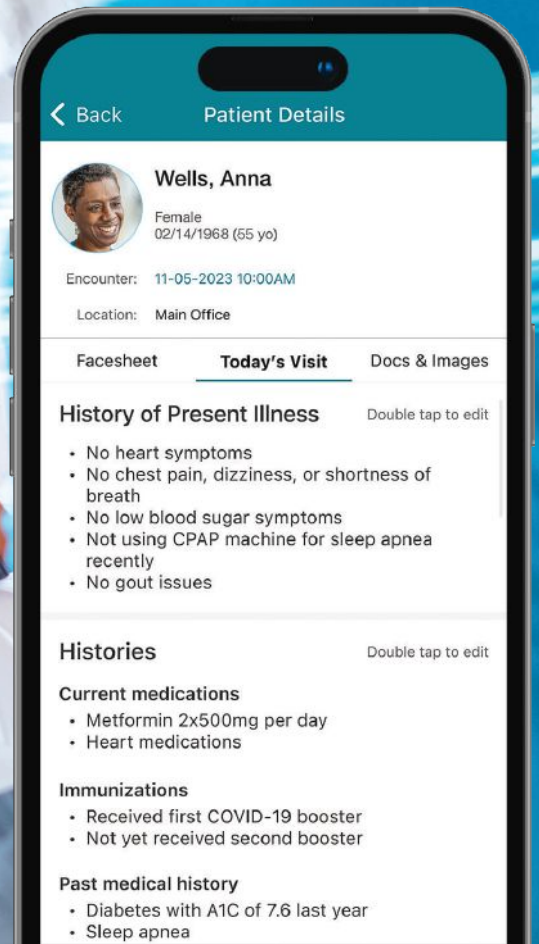
## Schedule a Demo

Call us at 855-346-1528  
or visit [nextgen.com/ambient](https://nextgen.com/ambient)



The product images shown are for illustration purposes only. The actual product may vary.

© 2024 NXGN Management, LLC. All Rights Reserved. NextGen is a registered trademark of NXGN Management, LLC. All other names and marks are the property of their respective owners.





OFFER YOUR PRESBYOPIC PATIENTS

# SEAMLESS VISION<sup>1</sup> WITH A LENS THAT FEELS LIKE NOTHING, EVEN AT DAY 30<sup>2</sup>



**96%**  
FIT SUCCESS<sup>1,3,4\*</sup>

Recommend TOTAL30<sup>®</sup> Multifocal contact lenses for  
**TOTAL comfort<sup>2</sup> and seamless vision near through far<sup>1</sup>**



#### #1 Selling Multifocal Lens Design

In the U.S.<sup>5\*\*</sup> with Proven Fit Success<sup>1,3,4\*</sup>



#### Water Gradient

Nearly 100% water at the outermost surface, so all that touches the eye is a gentle cushion of moisture.



#### Blue-Violet Light Filtering<sup>6,7†</sup> and UV Blocking<sup>6,7†</sup>

Total30<sup>®</sup> Multifocal contact lenses filter 34% of blue-violet light rays (BVL) while blocking more than 90% of UVA and 99% of UVB rays.


\*With two lenses or less per eye, at the initial fitting visit.

\*\*Internal estimates based on internal and third-party data.

<sup>1</sup>There is no demonstrated clinical benefit to a 34% reduction in visible light at wavelengths below 450 nm.

<sup>†</sup>UV absorbing contact lenses are NOT substitutes for protective UV absorbing eyewear, such as UV absorbing goggles or sunglasses because they do not completely cover the eye and surrounding area. The patient should continue to use UV absorbing eyewear as directed.

**References:** 1. Alcon data on file, 2022. 2. In a clinical study wherein patients used CLEAR CARE<sup>®</sup> solution for nightly cleaning, disinfecting, and storing; Alcon data on file, 2021. 3. Merchea M, Evans D, Kannarr S, Miller J, Kaplan M, Nixon L. Assessing a modified fitting approach for improved multifocal contact lens fitting success. Paper presented at Optometry's Meeting, the 121st Congress of the American Optometric Association; June 20-24, 2018; Denver, CO. 4. Bauman E, Lemp J, Kern J. Material effect on multifocal contact lens fitting of lenses of the same optical design with the same fitting guide. Poster presented at: British Contact Lens Association Clinical Conference & Exhibition; June 9-11, 2017; Liverpool, UK. 5. Alcon data on file, 2023. 6. ISO 18369-2:2017 Ophthalmic optics - Contact lenses Part 2: Tolerances. 7. ANSI Z80.20-2016 ophthalmic contact lens UV transmittance.

See product instructions for complete wear, care and safety information. 

©2023 Alcon Inc. US-T3M-2300064

Scan to learn more



**Alcon**