

OBITUARY: Frank D. Fontana, Optometric Luminary, p. 4

REVIEW[®] OF OPTOMETRY

October 15, 2018

www.reviewofoptometry.com

OPTOMETRY TODAY
AND TOMORROW

Growth: Strategies, Setbacks and Successes

Optometry put down roots a century ago and has flourished ever since. Stronger than ever, the profession and its practitioners look to their futures.

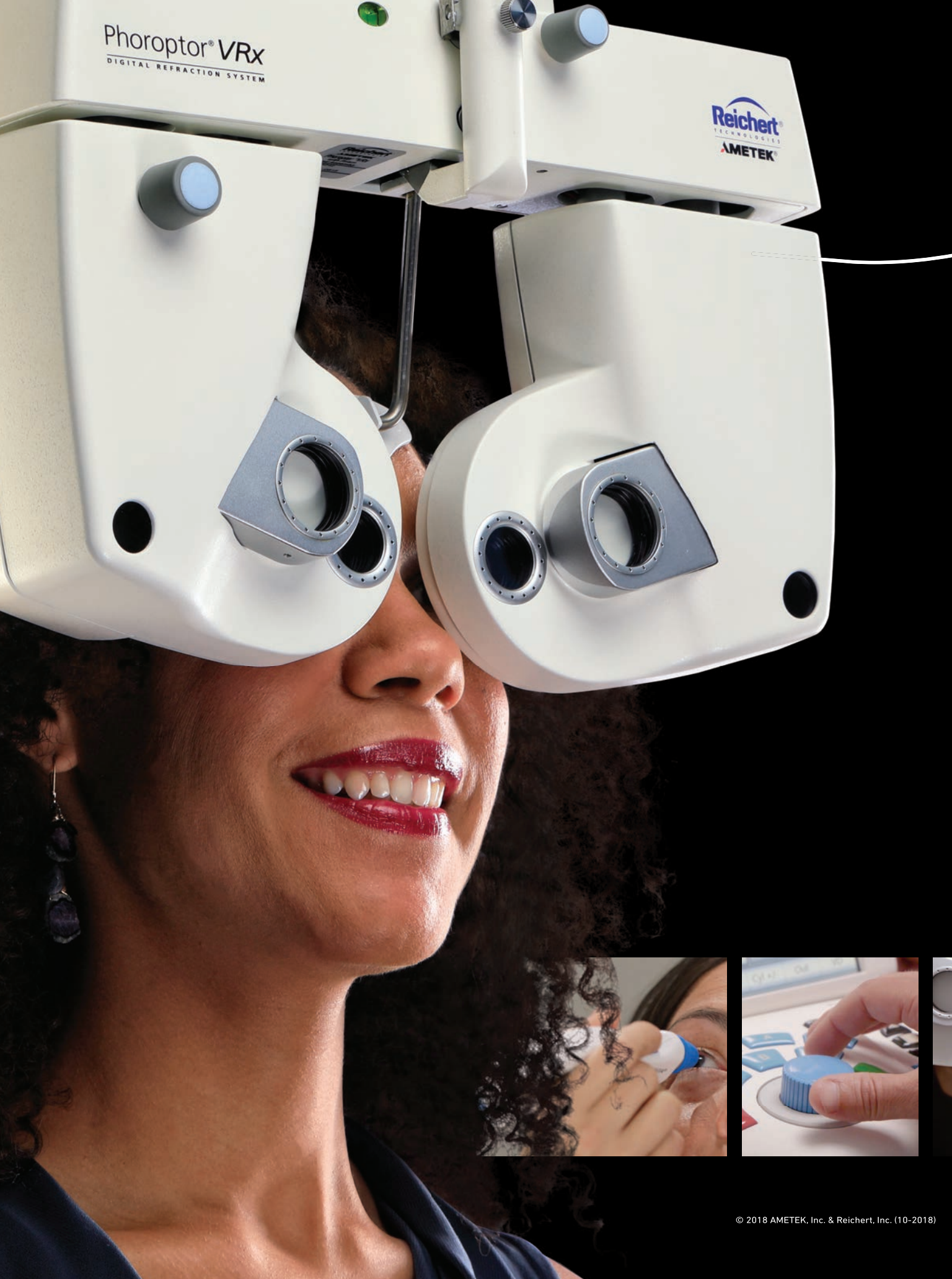
- Expanding Scope of Practice, p. 34
- Embracing Telemedicine, p. 56
- Gaining Hospital Privileges, p. 64
- Selling Your Practice, p. 48

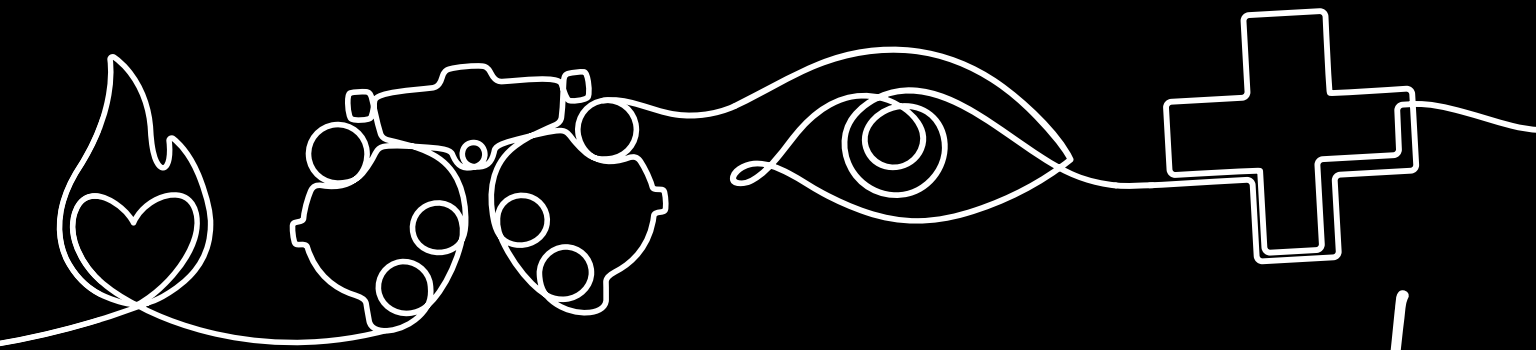
ALSO: Landmark Glaucoma Studies: Still Relevant?, p. 70

Radiologic Testing for ODs, p. 78

Phoroptor® VRx
DIGITAL REFRACTION SYSTEM

Reichert®
TECHNOLOGIES
AMETEK®





Passionate About Eye Care!

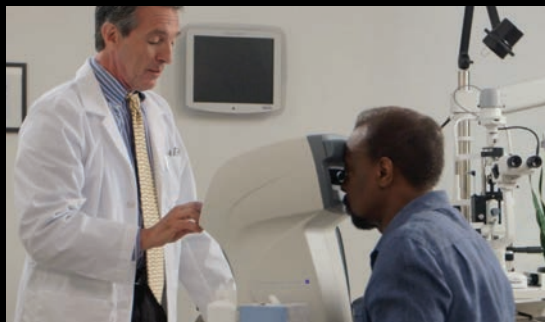
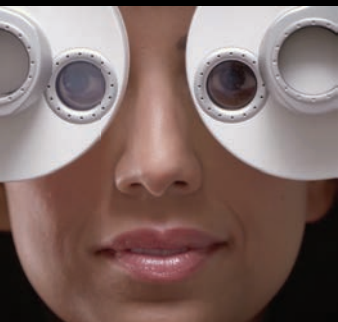We share your **passion for patient experience** with our complete line of digital refraction devices, featuring Phoroptor® VRx.

We also share your **passion for patient care** with our innovative glaucoma diagnostics, featuring Ocular Response Analyzer® G3 with Corneal Hysteresis.

SEE AMERICAN INNOVATION AT
AMERICAN ACADEMY OF OPTOMETRY #1720



reichert.com



Frank D. Fontana, Optometric Luminary

St. Louis native Frank Fontana, OD—called “Uncle Frank” by hundreds of peers and friends throughout optometry—earned his nickname by acting as a mentor to countless optometrists. Through advocacy and his own cutting-edge practice, he sculpted the very model of the modern-day optometrist: a new breed simultaneously skilled in vision correction, contact lens fitting, disease diagnosis and treatment. He died in Las Vegas on October 3 at age 96, after suffering a stroke a few days earlier while in town for the Vision Expo West conference.

In his youth, he served in World War II, spending 35 months in the Army, 28 of those stationed in Europe. When he returned to St. Louis, his father introduced him to an optometrist and he was inspired to join the profession. Dr. Fontana graduated from Illinois College of Optometry in 1949 and opened his practice the following year.

“Contact lenses as we know them now didn’t really exist yet,” he recounted in a 2016 interview with *Review of Optometry*. He may not have known it at the time, but he would soon become one of optometry’s most knowledgeable professionals on the devices, sought out by doctors and manufacturers alike.

Dr. Fontana took on leadership positions in several groups, including the Missouri Optometric Association and the American Optometric Association (AOA). He founded the Contact Lens & Cornea Section of the AOA and co-founded the Heart of America Contact Lens Society.



Dr. Fontana’s war service entitled him to a college education under the GI Bill. He studied at Illinois College of Optometry.

He established a nationally known study group, The Eyecare Marketing and Management Group (commonly known as “The Nephews and Nieces”). In a long and distinguished career, he worked alongside optometric publications, manufacturers and educators, and attended industry conferences until the day he died.

Outreach and Optimism

Several optometrists tell a familiar story of encountering Dr. Fontana for the first time at a conference and being instantly invited to dinner.

Jack Schaeffer, OD, of Alabama met him 35 years ago and was immediately given a helping hand. “When I began practicing,” says Dr. Schaeffer, “Uncle Frank sent me a package that included all his contact lens fees and a recording of how to become a contact lens specialty practice. What a wonderful act of

kindness. It became my practice guidelines.”

John Schachet, OD, of Colorado recalls being berated by a more established OD in his early days on the speaking circuit, only to have Dr. Fontana take him out for a conciliatory drink. After that, the pair remained close for 42 years, even vacationing with their families together.

Rosenberg School of Optometry’s Joseph Pizzimenti, OD, says that once after a lecture, he was approached by Dr. Fontana, who told him, “Wow, I didn’t realize someone could talk for two hours about the choroid. I learned something.” For him to say he learned something from me, that blew me away.”

Dr. Fontana was outgoing, avuncular and a good listener who rarely interrupted. When asked about his personality, his many ‘nieces and nephews’ almost unanimously land on the same word: optimistic.

“In all my conversations with him, I never once heard him say a foul word about anybody. That’s a rare characteristic,” says friend Kirk Smick, OD, of Georgia.

In addition to his noteworthy kindness, “Frank was the best at networking,” explains Dr. Schachet. “He got to know people in research and development departments of the contact lens manufacturers, and would use that to open the door and connect doctors to study opportunities.”

He was also known to advocate for up-and-comers on the lecture circuit. A word from him could go a long way, and he was generous with his support, optometrists say.

The World War II veteran practiced optometry for 68 years.

Everybody's Uncle

Dr. Fontana and his wife Dorris (who died in 2007) had two sons, Donnie and Frankie, but his colleagues say he viewed optometry itself as another member of the family. Uncle Frank could never make his way through an exhibit hall at a convention, his friends say. Too many people stopped to greet him, and he'd speak to each one. "Our meetings will never be the same with his absence," says Dr. Schaeffer.

At *Review of Optometry* editorial board meetings, he routinely requested everyone introduce themselves to each other. Those are the kinds of moments that made him 'everybody's uncle.' He was brimming with positivity and knew everyone's name, and their spouse's and children's names. "As passionate as he was about the profession, he realized there was life beyond optometry and was always careful to keep track of us personally, like we were truly were all his nieces and nephews," adds Dr. Pizzimenti.

"We'll miss the kindness and gentle manner of our beloved friend and colleague, but his impact on us will always remain," says James Henne, *Review of Optometry's* publisher. Dr. Fontana was a contributor to *Review* for decades and someone Mr. Henne frequently consulted. Calling him "one of the most inspiring leaders and icons in optometry for almost 70 years," Mr. Henne notes that Dr. Fontana changed the profession for the better and touched every individual he was associated with. "Uncle Frank's last days were

spent with the industry and people he loved. He's with Dorris now looking down on us and watching over all of us." Mr. Henne also notes with admiration the devotion showed by his son, Frankie Fontana, who "took such good care of him and adored him."

The honors he received have been countless, including a call out on the floor of the Missouri Statehouse, where the governor—a patient of his—told officials Dr. Fontana was the reason he could see at all.

To memorialize Dr. Fontana's influence, *Review of Optometry* will name its annual career achievement award in his honor. Begun in 2014—with Dr. Fontana himself as the first recipient—the award "recognizes individuals who made it their life's work to improve and strengthen the profession," Mr. Henne says. Given out each year during the SECO conference, it will now be called the Dr. Frank Fontana Career Achievement Award.



Dr. Fontana photographed at Vision Expo West 2018, his last public appearance.

The profession will spend the next few months honoring his legacy, but "he wouldn't want anybody to grieve," Dr. Schachet says. "He'd want them to think about the good things he did."

A Friendly Phone Call When I Needed It

By Jim Sluck, Director—Optometric Market Development, Shire Ophthalmics

People say that when you're in eye care, you never leave for good, and perhaps that's so as I find myself back after a two-year detour into dermatology. During those first weeks in an unfamiliar world, there were moments when I wondered what I was doing in such a foreign place surrounded by people and doctors I didn't know... and then the phone rang.

Uncle Frank was the first call I received in my new position. He wanted to know about my work and my reasons for moving to dermatology, and he encouraged me in my new life. It was one of the few calls I got from my eye care family.

At the end of that call, Uncle Frank—same as any blood relative would do—congratulated me on the big new job and wished me continued success in my career. But as only Uncle Frank could do, he also said, "Well, Jimmy, maybe you'll come back to optometry some day," in the tone a relative might use when hearing you've moved out of your home town: proud but wistful, hoping this wasn't truly goodbye. When I decided to come back to eye care, he was one of the first to welcome me with open arms and a warm, knowing smile.

He called me 'nephew' after our first meeting 16 years ago, and today we are all poorer for the passing of our Uncle Frank.

IN THE NEWS

Researchers recently found that **pain sensitivity may play a role in influencing how patients perceive ocular discomfort**. They evaluated 42 patients with the Pain Sensitivity Questionnaire to quantify pain sensitivity levels and then asked them to refrain from blinking until they felt discomfort—a period termed the “maximum interblink period” (MIBP). A longer MIBP was associated with decreased pain sensitivity, a lower ocular surface cooling rate and Asian ethnicity.

Li W, Lin MC. Pain sensitivity associated with the length of the maximum interblink period. *Invest Ophthalmol Vis Sci*. 2018;59:238-45.

Visual field loss can be restored when some patients undergo rehabilitative measures, a new study shows. Researchers looked at seven patients with severe, chronic hemianopia with post-chiasmatic lesions who had five weeks of visual rehabilitation. Imaging revealed that, following the training, the connectivities between the right temporoparietal junction to the insula and the anterior cingulate cortex were strengthened, leading to significant improvements.

Lu Q, Wang X, Lin L, et al. Visual rehabilitation training alters attentional networks in hemianopia: An fMRI study. *Clin Neuro*. 2018;129(9):1832-41.

A new report shows **males and older patients bear the brunt of glaucoma's impact**. Other significant variables include employment, profession and marital status. The study reviewed the records of 3,227 patients and found that Glaucoma Symptom Scale questionnaire scores went up for each 10-year increase in age. It also found that anxiety and depression can add to glaucoma severity.

Riva I, Legramandi L, Katsanos A, et al. Influence of sociodemographic factors on disease characteristics and vision-related quality of life in primary open-angle glaucoma patients: The Italian Primary Open Angle Glaucoma Study (IPOAGS). *Glaucoma*. 2018;27(9):776-84.

Breakthroughs in Eye Augmentation

Artificial retinas and 3D-printed optoelectronics show promise. **By Mark De Leon, Associate Editor**

The future of vision prosthetics has gained momentum thanks to several new technological developments, including an artificial retina and what researchers are calling a “bionic eye.”¹⁻⁴

New Retinas in the Pipeline

Nanshu Lu, PhD, of the University of Texas at Austin, and her collaborator Dae-Hyeong Kim, PhD, of the Seoul National University, have successfully tested a so-called ‘ultrathin’ artificial retina and presented it at the 256th National Meeting & Exposition of the American Chemical Society.

Their team engineered the human eye-inspired soft implantable optoelectronic device using graphene structures (thin sheets of carbon) that conform to the retina. The curved image sensor array exhibits infrared blindness and successfully acquires pixelated optical signals.¹ The researchers see the sensor array as a promising imaging element for use in a soft implant that adds minimal mechanical loading to the retina.

“Although this research is still in its infancy, it is a very exciting starting point for the use of these materials to restore vision,” Dr. Lu said in a statement.² The researchers hope the device will someday restore sight to the millions of people with retinal diseases.²

3D Printing on a Curve

Another display of technological prowess comes from a research team at the University of Minnesota. Michael McAlpine, PhD, and his team successfully 3D printed an array of light receptors on a hemispherical surface using a semi-conducting polymer ink capable of energy-efficient photodetection. Considered by research team to be the first steps toward a “bionic eye,” the devices are integrated into image-sensing arrays with high sensitivity and wide field of view by 3D printing interconnected photodetectors directly onto flexible materials.³

Dr. McAlpine says the next steps are to create a prototype with more light receptors that are even more efficient.⁴ The team would also like to find a way to print on a soft hemispherical material that can be implanted into the eye. They hope the technology will someday help blind people see or visually impaired people see better.⁴

1. EurekAlert. A new generation of artificial retinas based on 2D materials. www.eurekalert.org/pub_releases/2018-08/acs-ang071718.php. August 20, 2018. Accessed August 31, 2018.

2. American Chemical Society. A new generation of artificial retinas based on 2D materials. www.acs.org/content/acs/en/pressroom/newsreleases/2018/august/new-generation-of-artificial-retinas-based-on-2d-materials.html. August 20, 2018. Accessed August 31, 2018.

3. Park SH, Su R, Jeong J, et al. 3D printed polymer photodetectors. *Adv Mater*. August 28, 2018. [Epub ahead of print].

4. University of Minnesota. Research brief: researchers 3D print prototype for ‘bionic eye’. <https://twin-cities.umn.edu/news-events/research-brief-researchers-3d-print-prototype-bionic-eye>. August 28, 2018. Accessed August 31, 2018.

NEWS STORIES POST EVERY WEEKDAY MORNING AT www.reviewofoptometry.com/news

THE JOURNEY TO **IMPROVED VISION** STARTS WITH *YOU*

Successful cataract surgery often depends on strong collaboration between patients, optometrists, and surgeons. **Alcon is here to support YOU** in building those partnerships.

Alcon Surgical Offerings

- The AcrySof® family of IOLs has been implanted over **100 MILLION TIMES**¹ – more than any other brand – and provides exceptional quality, clarity, and stability.²⁻⁴
- Our full range of products helps you meet each individual's needs, including astigmatic and presbyopic patients.
- We provide resources to support collaborative care between the optometrist and ophthalmologist.

Visit myalcon.com/cataractresources to order resources for your patients and your practice.

Alcon A Novartis
Division

 AcrySof® IQ IOL Family

References: 1. Alcon sales data on file. 2. Wirtitsch MG, Findl O, Menapace R, et al. Effect of haptic design on change in axial position after cataract surgery. *J Cataract Refract Surg.* 2004;30(1):45-51. 3. Visser N, Bauer NJ, Nuijts RM. Toric intraocular lenses: Historical overview, patient selection, IOL calculation, surgical techniques, clinical outcomes, and complications. *J Cataract Refract Surg.* 2013;39(4):624-637. 4. Potvin R, Kramer BA, Hardten DR, Berdahl JP. Toric intraocular lens orientation and residual refractive astigmatism: An analysis. *Clin Ophthalmol.* 2016;10:1829-1836.

© 2018 Novartis 04/18 US-ODE-18-E-0547a

AcrySof® Family of Single-Piece IOLs Important Product Information

(AcrySof® UV, AcrySof® IQ, AcrySof® IQ Toric, AcrySof® IQ ReSTOR®, and AcrySof® IQ ReSTOR® Toric IOLs)

CAUTION: Federal law restricts these devices to sale by or on the order of a physician. **INDICATION:**

The family of AcrySof® single-piece intraocular lenses (IOLs) includes AcrySof® UV-absorbing IOLs ("AcrySof® UV"), AcrySof® IQ, AcrySof® IQ Toric and AcrySof® IQ ReSTOR® and AcrySof® IQ ReSTOR® Toric IOLs. Each of these IOLs is indicated for visual correction of aphakia in adult patients following cataract surgery. In addition, the AcrySof Toric IOLs are indicated to correct pre-existing corneal astigmatism at the time of cataract surgery. The AcrySof IQ ReSTOR IOLs are for cataract patients with or without presbyopia, who desire increased spectacle independence with a multifocal vision. All of these IOLs are intended for placement in the capsular bag. **WARNINGS/PRECAUTIONS:**

General cautions for all AcrySof® and AcrySof® UV IOLs:

Careful preoperative evaluation and sound clinical judgment should be used by the surgeon to decide the risk/benefit ratio before implanting any IOL in a patient with any of the conditions described in the Directions for Use that accompany each IOL. Caution should be used prior to lens encapsulation to avoid lens decentration or dislocation. Viscoelastic should be removed from the eye at the close of surgery. **Additional Cautions associated with AcrySof® IQ ReSTOR® IOLs:**

Some patients may experience visual disturbances and/or discomfort due to multifocality, especially under dim light conditions. A reduction in contrast sensitivity may occur in low light conditions. Visual symptoms may be significant enough that the patient will request explant of the multifocal IOL. Spectacle independence rates vary with all multifocal IOLs; as such, some patients may need glasses when reading small print or looking at small objects. Clinical studies indicate that posterior capsule opacification (PCO), when present, may develop earlier into clinically significant PCO with multifocal IOLs. **Additional Cautions associated with AcrySof® IQ Toric, AcrySof® UV Toric and ReSTOR® Toric IOLs:**

Optical theory suggests that, high astigmatic patients (i.e. > 2.5 D) may experience spatial distortions. Possible toric IOL related factors may include residual cylindrical error or axis misalignments. Toric IOLs should not be implanted if the posterior capsule is ruptured, if the zonules are damaged, or if a primary posterior capsulotomy is planned. Rotation can reduce astigmatic correction; if necessary lens repositioning should occur as early as possible prior to lens encapsulation. Prior to surgery, physicians should provide prospective patients with a copy of the appropriate Patient Information Brochure available from Alcon informing them of possible risks and benefits associated with the AcrySof® IQ Toric, AcrySof® IQ ReSTOR® and AcrySof® IQ ReSTOR® Toric IOLs. Do not resterilize. Do not store at temperatures over 45° C. Use only sterile irrigating solutions to rinse or soak IOLs.

ATTENTION: Refer to the Directions for Use labeling for the specific IOL for a complete list of indications, warnings and precautions.



AcrySof.IQ IOL Family

Alcon A Novartis
Division

© 2018 Novartis 04/18 US-ODE-18-E-0547a

News Review

For more, visit www.reviewofoptometry.com/news

High Cost of Glaucoma

Researchers recently crunched the numbers and discovered glaucoma care—whether pharmaceutical, laser or incisional—is not affordable for most patients, in both developed and developing countries.

After studying data from 38 nations, 21 of which were developing countries, and comparing glaucoma intervention costs with the median annual household income, the team designated a price tag of 2.5% of income or below as an affordable intervention. While considerable variability existed from country to country—trabeculectomy was anywhere from 0.3% to 42%—timolol came out on top as the most affordable, registering above the affordable line in only two countries. However, latanoprost was deemed affordable in all developed countries

and even six developing ones.

Trabeculectomy was the most expensive for most countries, above the affordability threshold in 95% of developing countries and just shy of 60% in developed countries.

Laser trabeculectomy sat somewhere in the middle and was unaffordable in 65% of developing countries and 24% of developed countries. Still, this intervention was more affordable than a three-year supply of latanoprost in 53% of countries included in the study.

“Successfully reducing global blindness from glaucoma requires addressing multiple contributing factors, including making glaucoma interventions more affordable,” the study authors conclude.

Zhao PY, Rahmathullah R, Stagg BC, et al. A worldwide price comparison of glaucoma medications, laser trabeculectomy, and trabeculectomy surgery. JAMA Ophthalmol. August 30, 2018. [Epub ahead of print].

OK a Boon for QoL

As myopia hits epidemic levels in some countries, researchers are spending more time evaluating various treatments, including the long-trusted orthokeratology (OK). A new study adds even more weight to its benefits beyond simply slowing myopia progression.

The researchers surveyed 100 children wearing OK lenses—at baseline and after three months of lens wear—using a 20-question survey related to symptoms, entertainment, studies and psychology. The study revealed a significant difference in the children’s answers three months after starting lens wear.

Although symptoms of discomfort were higher, OK provided daytime

freedom from corrective lens wear that proved “very powerful and potentially life-changing,” according to the study. Those wearing OK lenses had a tendency to be more active in sports and recreation, prolonging their outdoor activity time.


The survey showed OK wear boosted the children’s daily activities by eliminating the inconvenience of eyeglasses. It also made them more confident about their academic performance. While the psychological scores were not statistically significant, those wearing OK tended to be more confident and willing to try new things. ■

Zhao F, Zhao G, Zhao Z. Investigation of the effect of orthokeratology lenses on quality of life and behaviors of children. Eye Cont Lens. 2018;44(5):335-8.

Are axial length measurements part of your myopia control program?

The DGH 6000 **SCANMATE**

**A Portable USB A-Scan
for Axial Length Measurements**



*Contact us to learn how
you can incorporate
the Scanmate A
into your practice at
an affordable price.*

(800) 722-3883 • www.dghtechnology.com

Periodic axial length measurements have been identified as an essential procedure for monitoring the effectiveness of any myopia control program.

Proven Performance. The Scanmate A is a portable, USB connected ultrasound A-Scan biometer used to obtain axial length measurements. The Scanmate A utilizes unique alignment and compression detection algorithms which provide audible feedback to the user. These exclusive features give real-time guidance for optimizing alignment and minimizing compression. You can be confident that your axial length measurements will be consistent, accurate and reliable.

Visit us at AAO 2018 Booth 2043

DGH TECHNOLOGY, INC.

THE ULTRASOUND SPECIALIST

Serving Eye Care Professionals since 1982

All DGH products are made in the USA.

ASCRS Releases Guidelines on CyPass

In the wake of Alcon's voluntary recall of the CyPass micro-stent following the high rate of endothelial adverse events in the COMPASS-XT study, the American Society of Cataract and Refractive Surgery (ASCRS) formed a task force of glaucoma and cornea specialists to evaluate the data and provide clinical recommendations.

The Preliminary ASCRS CyPass Withdrawal Consensus Statement, released in late September, advises patients who received the CyPass to continue following up with their eye care providers at appropriate intervals and possibly consider more frequent corneal evaluations.

For practitioners, clinical examination alone may be appropriate for monitoring patients with the CyPass in the absence of clinically significant corneal decompensation; intervention should be limited to instances

when clinically apparent or functionally significant changes occur, the statement says.

When performing gonioscopy on patients, ASCRS says, practitioners should be vigilant for the presence or absence of contact between the corneal endothelium and the CyPass device, the position of the device lumen anterior to Schwalbe's line and the number of retention rings visible in the anterior chamber.

The statement noted the apparent correlation between CyPass implantation depth and the rate of endothelial cell loss. The task force also employs the COMPASS study's use of the number of visible retention rings to grade implantation depth. If only one ring of the CyPass, or none at all, is visible in the anterior chamber by gonioscopy and no clear evidence of corneal decompensation exists, continue to monitor patients

in lieu of intervention, according to ASCRS. If more rings are visible, a greater risk of corneal endothelial cell loss exists.

If corneal decompensation has developed and more than one retention ring is visible, consider recommending surgery to reposition the CyPass or trim the proximal end; however, the expert panel says that repositioning or deeper implantation is safest only within seven to 10 days of initial implantation. The group expressed concern over the potential for fibrosis around and possibly through the filtration holes of the micro-stent, and recommended trimming the proximal end of the device as the preferred procedure if the physician and the patient should desire intervention.

American Society of Cataract and Refractive Surgery. Preliminary ASCRS CyPass withdrawal consensus statement. http://ascrs.org/cypass_statement. September 25, 2018.

Disparities Exist in Low Vision Services

Survey responses from 3,058 Medicare beneficiaries revealed that only 26.1% use low vision devices and 3.5% use low vision rehabilitation.

Photo: Richard J. Shuliner, OD



Not all visually impaired patients are lucky enough to have access to low vision devices, new data suggests.

Because so little is known about whether sociodemographic disparities exist in the use of low vision services by Medicare beneficiaries, researchers designed a study to better understand the possible connections. Their cross-sectional population-based study evaluated if sociodemographic or economic factors were associated with self-reported use of low vision devices or rehabilitation among Medicare beneficiaries with self-reported vision impairment.

In a model adjusted for ocular diagnoses, Hispanic individuals and individuals from other races or ethnicities—but not blacks—were significantly less likely to report using low vision devices than white

individuals. In another model not adjusted for ocular diagnoses, blacks were also significantly less likely to report low vision device use. The study found no significant racial or ethnic disparities for reported use of low vision rehabilitation.

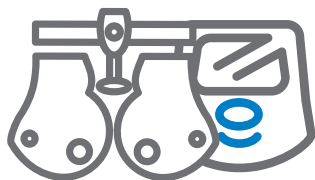
They concluded that additional research is needed to clarify the association between sociodemographics and use of low vision services in the Medicare population. If that association is confirmed, it may suggest that policy makers should consider coverage of low vision devices under Medicare to address disparities.

Choi S, Stagg BC, Ehrlich JR. Disparities in low-vision device use among older US Medicare recipients. *JAMA Ophthalmol*. September 6, 2018. [Epub ahead of print].

GOLD STANDARD ON BOARD NOW

M&S
TECHNOLOGIES

+



=



M&S software is **Exclusive** to the Topcon CV-5000S

» Contrast Sensitivity Testing

» Color Vision Testing

» LEA SYMBOLS® and LEA NUMBERS®

» Threshold Distance Stereo Testing

» Peer-Reviewed and Science-Based Tests

» Dual Working Distance

TOPCON MEDICAL SYSTEMS, INC.

111 Bauer Drive, Oakland, NJ 07436 | Phone: 800.223.1130 | Fax: 201.599.5248 | topconmedical.com

Please visit <https://bit.ly/2fv1zrV>

 **TOPCON**

YOUR VISION. OUR FOCUS.

Imaging Tech Reveals Early FECD

Thanks to Scheimpflug tomography imaging, clinicians can detect Fuchs' endothelial corneal dystrophy (FECD) when it's still in its subclinical phase, according to new findings—and this discovery may just change how doctors evaluate corneas.

Scheimpflug technology, which is noninvasive and requires no anesthesia, keeps the cornea and the anterior segment in focus, providing images of both the front and back surfaces of the cornea, as well as other anterior segment structures. This technology can help evaluate corneal curvature, central corneal thickness and corneal opacities. These measurements are often used in the workup for cataract surgery or other surgical procedures, such as



Image: Karen K. Yeung, OD

Scheimpflug imaging, here of a healthy eye, can help clinicians properly classify Fuchs' endothelial corneal dystrophy.

endothelial keratoplasty (EK).

Armed with this new evidence, researchers out of the Mayo Clinic in Minnesota's Ophthalmology Department are recommending a reclassification of FECD.

To make this determination, the investigators evaluated 93 eyes with and 74 without FECD, each using a slit-lamp and Scheimpflug tomography. The evaluation focused on three points: (1) loss of parallel contours within the cornea, (2) displacement of the thin-

nest point of the cornea and (3) focal posterior corneal surface depression.

The researchers found those features in more than 80% of eyes suspicious for subclinical edema on Scheimpflug tomography, as well as many of those not suspicious but later developed FECD following EK.

The researchers' recommendations on classification protocols are as follows: "FECD corneas as having clinically definite edema (based on slit-lamp examination), subclinical edema (based on tomographic features without clinically definite edema) or no edema (no tomographic or slit-lamp features of edema)."

Sun S, Wacker K, Baratz K, Patel S. Determining subclinical edema in Fuchs endothelial corneal dystrophy. Revised classification using Scheimpflug tomography for preoperative assessment. *Ophthalmology*. August 25, 2018. [Epub ahead of print].

Kids' Macular Thickness Tied to DR

Children with Type I diabetes are at risk of proliferative retinopathy at any time, and the best way to preserve their visual health is to diagnose it at the earliest signs, in the nonproliferative phase or even earlier.

Turkish investigators show that macular and retinal nerve fiber layer (RNFL) thickness measurements on SD-OCT might reveal early stages of diabetic retinopathy (DR). These changes may be present in diabetic eyes before clinically detectable vasculopathy presents, the study says.

"The novelty of this study is the finding that both diabetes duration and HbA1c are inversely associated

with retinal neurodegeneration," says A. Paul Chous, OD, author of the book *Diabetic Eye Disease: Lessons From A Diabetic Eye Doctor*. He adds that the report "makes biologic sense and suggests a common pathophysiologic link between vascular and neural damage caused by diabetes in the retina."

The study looked at 73 children with Type I diabetes and 62 controls. The diabetes cohort had significantly thinner macular findings and thinner RNFLs than their non-diabetic counterparts. The mean HbA1c values were inversely correlated with the mean temporal outer macular thickness and global

RNFL thickness measurements in the patients with diabetes.

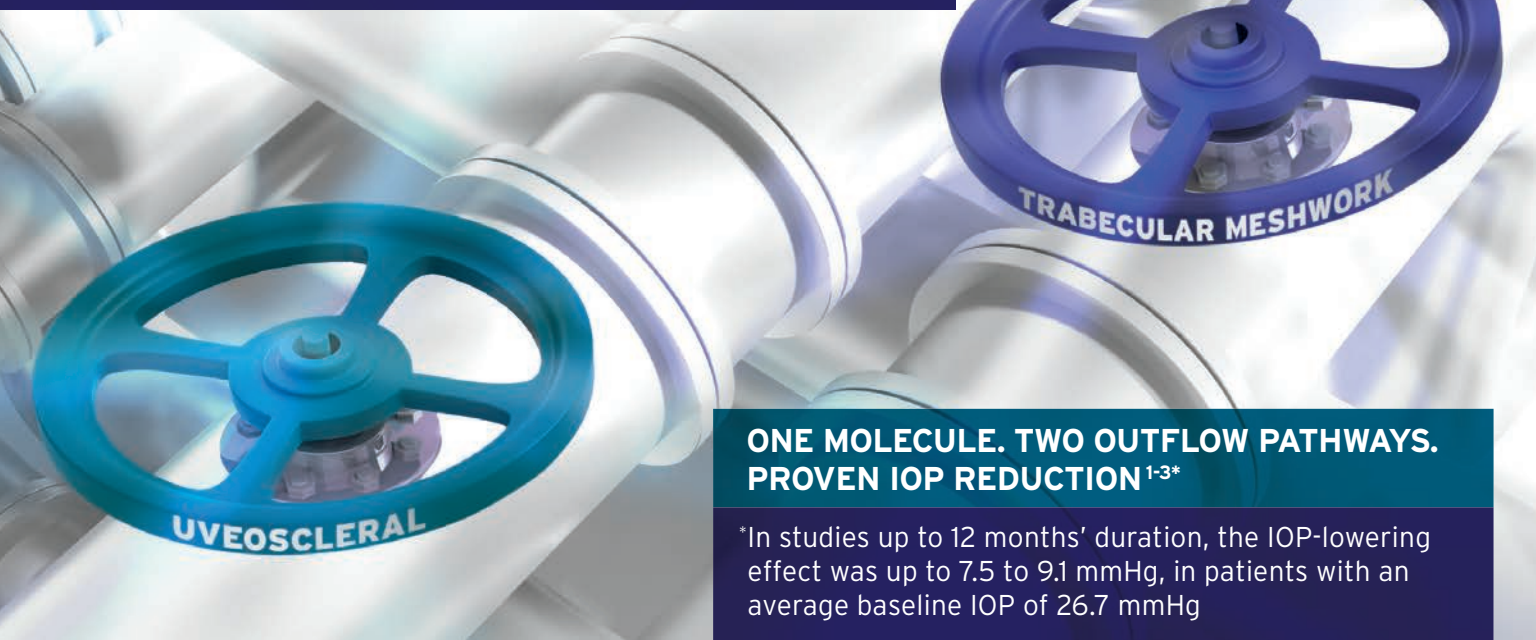
"DR is, in fact, a neurovascular disease that frequently manifests as thinning of neural retinal layers (nerve fiber layer, ganglion cells and inner plexiform layer) in parallel with and, as this study shows, preceding clinically observable microvascular insult," Dr. Chous says.

"Macular and RNFL thickness measurements might be useful indicators for early detection of diabetic retinopathy in the future," the report concludes.

Tekin K, Inanc M, Kurnaz E, et al. Quantitative evaluation of early retinal changes in children with type 1 diabetes mellitus without retinopathy. *Clin Exp Ophthalmol*. 2018;101(5):680-5.

VYZULTA DELIVERS A DUAL MECHANISM OF ACTION

FOR THE REDUCTION OF IOP IN GLAUCOMA PATIENTS¹



**ONE MOLECULE. TWO OUTFLOW PATHWAYS.
PROVEN IOP REDUCTION^{1-3*}**

*In studies up to 12 months' duration, the IOP-lowering effect was up to 7.5 to 9.1 mmHg, in patients with an average baseline IOP of 26.7 mmHg

INDICATION

VYZULTA™ (latanoprostene bunod ophthalmic solution), 0.024% is indicated for the reduction of intraocular pressure (IOP) in patients with open-angle glaucoma or ocular hypertension.

IMPORTANT SAFETY INFORMATION

- Increased pigmentation of the iris and periorbital tissue (eyelid) can occur. Iris pigmentation is likely to be permanent
- Gradual changes to eyelashes, including increased length, increased thickness, and number of eyelashes, may occur. These changes are usually reversible upon treatment discontinuation
- Use with caution in patients with a history of intraocular inflammation (iritis/uveitis). VYZULTA should generally not be used in patients with active intraocular inflammation
- Macular edema, including cystoid macular edema, has been reported during treatment with prostaglandin analogs. Use with caution in aphakic patients, in pseudophakic patients with a torn posterior lens capsule, or in patients with known risk factors for macular edema

IMPORTANT SAFETY INFORMATION (CONTINUED)

- There have been reports of bacterial keratitis associated with the use of multiple-dose containers of topical ophthalmic products that were inadvertently contaminated by patients
- Contact lenses should be removed prior to the administration of VYZULTA and may be reinserted 15 minutes after administration
- Most common ocular adverse reactions with incidence $\geq 2\%$ are conjunctival hyperemia (6%), eye irritation (4%), eye pain (3%), and instillation site pain (2%)

For more information, please see Brief Summary of Prescribing Information on next page.

References:

1. VYZULTA Prescribing Information. Bausch & Lomb Incorporated. 2017.
2. Weinreb RN, Sforzolini BS, Vittitow J, Liebmann J. Latanoprostene bunod 0.024% versus timolol maleate 0.5% in subjects with open-angle glaucoma or ocular hypertension: the APOLLO study. *Ophthalmology*. 2016;123(5):965-973.
3. Medeiros FA, Martin KR, Peace J, Sforzolini BS, Vittitow JL, Weinreb RN. Comparison of latanoprostene bunod 0.024% and timolol maleate 0.5% in open-angle glaucoma or ocular hypertension: the LUNAR study. *Am J Ophthalmol*. 2016;168:250-259.

For more information about VYZULTA and how it works, visit vyzultanow.com

BAUSCH+LOMB

VYZULTA and the V design are trademarks of Bausch & Lomb Incorporated or its affiliates.
©2018 Bausch & Lomb Incorporated. All rights reserved. VYZ.0118.USA.18


VYZULTA™
(latanoprostene
bunod ophthalmic
solution), 0.024%

BRIEF SUMMARY OF PRESCRIBING INFORMATION

This Brief Summary does not include all the information needed to use VYZULTA safely and effectively. See full Prescribing Information for VYZULTA.

VYZULTA™ (latanoprostene bunod ophthalmic solution), 0.024%, for topical ophthalmic use.

Initial U.S. Approval: 2017

1 INDICATIONS AND USAGE

VYZULTA™ (latanoprostene bunod ophthalmic solution) 0.024% is indicated for the reduction of intraocular pressure (IOP) in patients with open-angle glaucoma or ocular hypertension.

4 CONTRAINDICATIONS

None

5 WARNINGS AND PRECAUTIONS

5.1 Pigmentation

VYZULTA™ (latanoprostene bunod ophthalmic solution), 0.024% may cause changes to pigmented tissues. The most frequently reported changes with prostaglandin analogs have been increased pigmentation of the iris and periorbital tissue (eyelid).

Pigmentation is expected to increase as long as latanoprostene bunod ophthalmic solution is administered. The pigmentation change is due to increased melanin content in the melanocytes rather than to an increase in the number of melanocytes. After discontinuation of VYZULTA, pigmentation of the iris is likely to be permanent, while pigmentation of the periorbital tissue and eyelash changes are likely to be reversible in most patients. Patients who receive prostaglandin analogs, including VYZULTA, should be informed of the possibility of increased pigmentation, including permanent changes. The long-term effects of increased pigmentation are not known.

Iris color change may not be noticeable for several months to years. Typically, the brown pigmentation around the pupil spreads concentrically towards the periphery of the iris and the entire iris or parts of the iris become more brownish. Neither nevi nor freckles of the iris appear to be affected by treatment. While treatment with VYZULTA™ (latanoprostene bunod ophthalmic solution), 0.024% can be continued in patients who develop noticeably increased iris pigmentation, these patients should be examined regularly [see Patient Counseling Information (17) in full Prescribing Information].

5.2 Eyelash Changes

VYZULTA may gradually change eyelashes and vellus hair in the treated eye. These changes include increased length, thickness, and the number of lashes or hairs. Eyelash changes are usually reversible upon discontinuation of treatment.

5.3 Intraocular Inflammation

VYZULTA should be used with caution in patients with a history of intraocular inflammation (iritis/uveitis) and should generally not be used in patients with active intraocular inflammation as it may exacerbate this condition.

5.4 Macular Edema

Macular edema, including cystoid macular edema, has been reported during treatment with prostaglandin analogs. VYZULTA should be used with caution in aphakic patients, in pseudophakic patients with a torn posterior lens capsule, or in patients with known risk factors for macular edema.

5.5 Bacterial Keratitis

There have been reports of bacterial keratitis associated with the use of multiple-dose containers of topical ophthalmic products. These containers had been inadvertently contaminated by patients who, in most cases, had a concurrent corneal disease or a disruption of the ocular epithelial surface.

5.6 Use with Contact Lens

Contact lenses should be removed prior to the administration of VYZULTA because this product contains benzalkonium chloride. Lenses may be reinserted 15 minutes after administration.

6 ADVERSE REACTIONS

The following adverse reactions are described in the Warnings and Precautions section: pigmentation (5.1), eyelash changes (5.2), intraocular inflammation (5.3), macular edema (5.4), bacterial keratitis (5.5), use with contact lens (5.6).

6.1 Clinical Trials Experience

Because clinical trials are conducted under widely varying conditions, adverse reaction rates observed in the clinical trials of a drug cannot be directly compared to rates in the clinical trials of another drug and may not reflect the rates observed in practice.

VYZULTA was evaluated in 811 patients in 2 controlled clinical trials of up to 12 months duration. The most common ocular adverse reactions observed in patients treated with latanoprostene bunod were: conjunctival hyperemia (6%), eye irritation (4%), eye pain (3%), and instillation site pain (2%). Approximately 0.6% of patients discontinued therapy due to ocular adverse reactions including ocular hyperemia, conjunctival irritation, eye irritation, eye pain, conjunctival edema, vision blurred, punctate keratitis and foreign body sensation.

8 USE IN SPECIFIC POPULATIONS

8.1 Pregnancy

Risk Summary

There are no available human data for the use of VYZULTA during pregnancy to inform any drug associated risks.

Latanoprostene bunod has caused miscarriages, abortion, and fetal harm in rabbits. Latanoprostene bunod was shown to be abortifacient and teratogenic when administered intravenously (IV) to pregnant rabbits at exposures ≥ 0.28 times the clinical dose.

Doses ≥ 20 $\mu\text{g}/\text{kg}/\text{day}$ (23 times the clinical dose) produced 100% embryofetal lethality. Structural abnormalities observed in rabbit fetuses included anomalies of the great vessels and aortic arch vessels, domed head, sternebral and vertebral skeletal anomalies, limb hyperextension and malrotation, abdominal distension and edema. Latanoprostene bunod was not teratogenic in the rat when administered IV at 150 $\text{mcg}/\text{kg}/\text{day}$ (87 times the clinical dose) [see Data].

The background risk of major birth defects and miscarriage for the indicated population is unknown. However, the background risk in the U.S. general population of major birth defects is 2 to 4%, and of miscarriage is 15 to 20%, of clinically recognized pregnancies.

Data

Animal Data

Embryofetal studies were conducted in pregnant rabbits administered latanoprostene bunod daily by intravenous injection on gestation days 7 through 19, to target the period of organogenesis. The doses administered ranged from 0.24 to 80 $\text{mcg}/\text{kg}/\text{day}$. Abortion occurred at doses ≥ 0.24 $\text{mcg}/\text{kg}/\text{day}$ latanoprostene bunod (0.28 times the clinical dose, on a body surface area basis, assuming 100% absorption). Embryofetal lethality (resorption) was increased in latanoprostene bunod treatment groups, as evidenced by increases in early resorptions at doses ≥ 0.24 $\text{mcg}/\text{kg}/\text{day}$ and late resorptions at doses ≥ 6 $\text{mcg}/\text{kg}/\text{day}$ (approximately 7 times the clinical dose). No fetuses survived in any rabbit pregnancy at doses of 20 $\text{mcg}/\text{kg}/\text{day}$ (23 times the clinical dose) or greater. Latanoprostene bunod produced structural abnormalities at doses ≥ 0.24 $\text{mcg}/\text{kg}/\text{day}$ (0.28 times the clinical dose). Malformations included anomalies of sternum, coarctation of the aorta with pulmonary trunk dilation, retroesophageal subclavian artery with absent brachiocephalic artery, domed head, forepaw hyperextension and hindlimb malrotation, abdominal distention/edema, and missing/fused caudal vertebrae.

An embryofetal study was conducted in pregnant rats administered latanoprostene bunod daily by intravenous injection on gestation days 7 through 17, to target the period of organogenesis. The doses administered ranged from 150 to 1500 $\text{mcg}/\text{kg}/\text{day}$. Maternal toxicity was produced at 1500 $\text{mcg}/\text{kg}/\text{day}$ (870 times the clinical dose, on a body surface area basis, assuming 100% absorption), as evidenced by reduced maternal weight gain. Embryofetal lethality (resorption and fetal death) and structural anomalies were produced at doses ≥ 300 $\text{mcg}/\text{kg}/\text{day}$ (174 times the clinical dose). Malformations included anomalies of the sternum, domed head, forepaw hyperextension and hindlimb malrotation, vertebral anomalies and delayed ossification of distal limb bones. A no observed adverse effect level (NOAEL) was established at 150 $\text{mcg}/\text{kg}/\text{day}$ (87 times the clinical dose) in this study.

8.2 Lactation

Risk Summary

There are no data on the presence of VYZULTA in human milk, the effects on the breastfed infant, or the effects on milk production. The developmental and health benefits of breastfeeding should be considered, along with the mother's clinical need for VYZULTA, and any potential adverse effects on the breastfed infant from VYZULTA.

8.4 Pediatric Use

Use in pediatric patients aged 16 years and younger is not recommended because of potential safety concerns related to increased pigmentation following long-term chronic use.

8.5 Geriatric Use

No overall clinical differences in safety or effectiveness have been observed between elderly and other adult patients.

13 NONCLINICAL TOXICOLOGY

13.1 Carcinogenesis, Mutagenesis, Impairment of Fertility

Latanoprostene bunod was not mutagenic in bacteria and did not induce micronuclei formation in the *in vivo* rat bone marrow micronucleus assay. Chromosomal aberrations were observed *in vitro* with human lymphocytes in the absence of metabolic activation.

Latanoprostene bunod has not been tested for carcinogenic activity in long-term animal studies. Latanoprost acid is a main metabolite of latanoprostene bunod. Exposure of rats and mice to latanoprost acid, resulting from oral dosing with latanoprost in lifetime rodent bioassays, was not carcinogenic.

Fertility studies have not been conducted with latanoprostene bunod. The potential to impact fertility can be partially characterized by exposure to latanoprost acid, a common metabolite of both latanoprostene bunod and latanoprost. Latanoprost acid has not been found to have any effect on male or female fertility in animal studies.

13.2 Animal Toxicology and/or Pharmacology

A 9-month toxicology study administered topical ocular doses of latanoprostene bunod to one eye of cynomolgus monkeys: control (vehicle only), one drop of 0.024% bid, one drop of 0.04% bid and two drops of 0.04% per dose, bid. The systemic exposures are equivalent to 4.2-fold, 7.9-fold, and 13.5-fold the clinical dose, respectively, on a body surface area basis (assuming 100% absorption). Microscopic evaluation of the lungs after 9 months observed pleural/subpleural chronic fibrosis/inflammation in the 0.04% dose male groups, with increasing incidence and severity compared to controls. Lung toxicity was not observed at the 0.024% dose.

Distributed by:

Bausch + Lomb, a division of

Valeant Pharmaceuticals North America LLC

Bridgewater, NJ 08807 USA

U.S. Patent Numbers: 6,211,233; 7,273,946; 7,629,345; 7,910,767; 8,058,467.

VYZULTA is a trademark of Bausch & Lomb Incorporated or its affiliates.

© Bausch & Lomb Incorporated

Based on 9464800 11/2017 VZ.0055.USA.16 Issued: 11/2017



34 Expanding Scope of Practice: Lessons and Leverage

With 20 years of success to tout, the tactics—and the results—are changing. BY BILL KEKEVIAN, SENIOR EDITOR

48 Should You Sell to Private Equity?

With an upward trend in buyouts, private practice ODs have even more to consider when planning for their futures. BY JANE COLE, CONTRIBUTING EDITOR

56 Will Remote Refraction Tarnish Telemedicine?

Competitive efforts risk alienating ODs from a new mode of care that holds much potential for good. BY MARK DE LEON, ASSOCIATE EDITOR

64 The Why and How of Hospital Privileges

Don't shy away from this patient care—and practice boosting—opportunity. BY GLENN S. CORBIN, OD, AND AMANDA S. LEGGE, OD

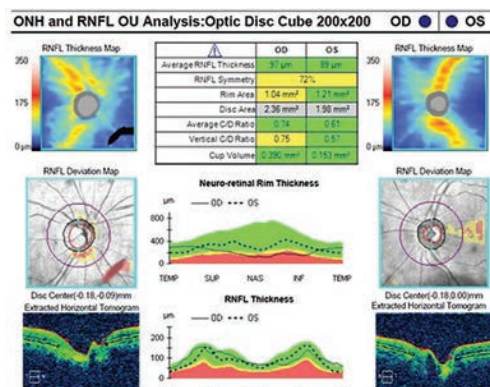
Contents

Review of Optometry October 15, 2018

Glaucoma: From Landmark Studies to Modern-day Care

While it's important to remember where you come from, it's also important to embrace where you're going.

BY JILLIAN JANES, OD, AND CHRISTOPHER KRUTHOFF, OD • PAGE 70



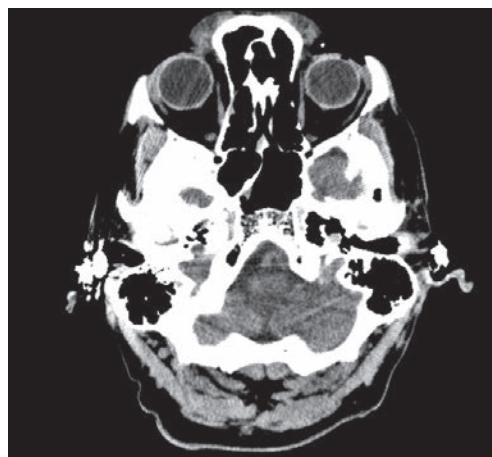
Earn 2 CE Credits:



The ABCs of Radiologic Testing

Clinicians should be prepared to order CT and MRI should the need arise. Patients' lives may count on it.

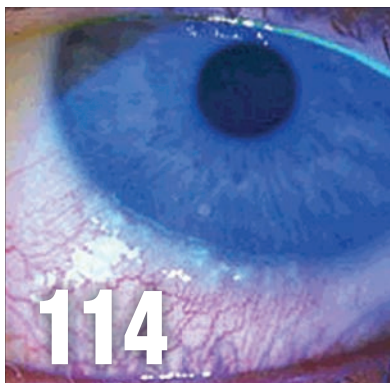
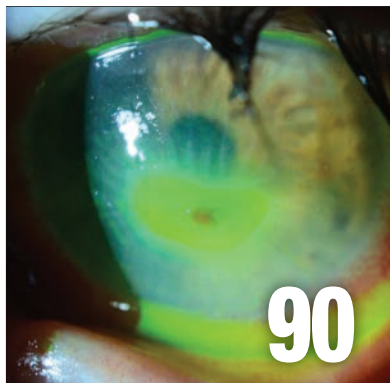
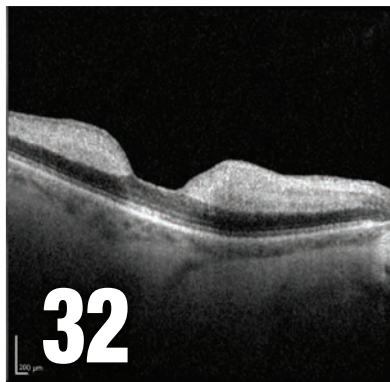
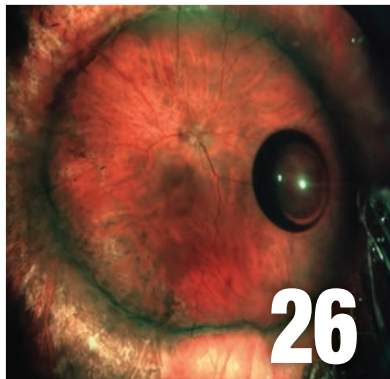BY JASON FLIEGEL, OD, TRACI SENG, OD, SARA WEIDMAYER, OD, AND KATHY LEWIS, OD • PAGE 78



Departments

Review of Optometry October 15, 2018

- 4** **News Review**
- 20** **Outlook**
A Death in the Family
JACK PERSICO
- 22** **Through My Eyes**
The Lesson of Online Refraction
PAUL M. KARPECKI, OD
- 24** **Chairside**
Trust Your Intuition
MONTGOMERY VICKERS, OD
- 26** **Clinical Quandaries**
Buckle Down
PAUL C. AJAMIAN, OD
- 28** **Coding Connection**
In Your Practice... and Wallet
JOHN RUMPAKIS, OD, MBA,
CLINICAL CODING EDITOR
- 30** **Focus on Refraction**
It's a Small World After All
MARC B. TAUB, OD, MS, AND
PAUL HARRIS, OD
- 32** **Retina Dilemmas**
RAO: Stay Calm and Refer On
DIANA SHECHTMAN, OD,
J. WILFREDO LARA, MD, AND
JAY M. HAYNIE, OD
- 90** **Cornea + Contact Lens Q&A**
Delaying the Inevitable
JOSEPH P. SHOWLIN, OD
- 92** **Ocular Surface Review**
Re-think Autologous Serum
PAUL M. KARPECKI, OD
- 94** **Glaucoma Grand Rounds**
Customize Your Steroid Choice
JAMES L. FANELLI, OD
- 98** **Retina Quiz**
Light at the End of the Tunnel
SHREYA JAYASIMHA, OD, AND
MARK T. DUNBAR, OD
- 103** **Therapeutic Review**
Stressed Out
JOSEPH W. SOWKA, OD
- 109** **Surgical Minute**
Break Up With Your Lid Bumps
DEREK N. CUNNINGHAM, OD, AND
WALTER O. WHITLEY, OD, MBA
- 110** **Classifieds**
- 112** **Products**
- 113** **Advertisers Index**
- 114** **Diagnostic Quiz**
A Red Eye Fight
ANDREW S. GURWOOD, OD



REVIEW[®] OF OPTOMETRY

BUSINESS OFFICES
11 CAMPUS BLVD., SUITE 100
NEWTOWN SQUARE, PA 19073

CEO, INFORMATION SERVICES GROUP
MARC FERRARA
(212) 274-7062 • MFERRARA@JOBSON.COM

PUBLISHER
JAMES HENNE
(610) 492-1017 • JHENNE@JOBSON.COM

REGIONAL SALES MANAGER
MICHELE BARRETT
(610) 492-1014 • MBARRETT@JOBSON.COM

REGIONAL SALES MANAGER
MICHAEL HOSTER
(610) 492-1028 • MHOSTER@JOBSON.COM

VICE PRESIDENT, OPERATIONS
CASEY FOSTER
(610) 492-1007 • CFOSTER@JOBSON.COM

VICE PRESIDENT, CLINICAL CONTENT
PAUL M. KARPECKI, OD, FAAO
PKARPECKI@JOBSON.COM

PRODUCTION MANAGER
SCOTT TOBIN
(610) 492-1011 • STOBIN@JOBSON.COM

SENIOR CIRCULATION MANAGER
HAMILTON MAHER
(212) 219-7870 • HMAHER@JHIHEALTH.COM

CLASSIFIED ADVERTISING
(888) 498-1460

SUBSCRIPTIONS
\$56 A YEAR, \$88 (US) IN CANADA,
\$209 (US) IN ALL OTHER COUNTRIES.

SUBSCRIPTION INQUIRIES
(877) 529-1746 (US ONLY)
OUTSIDE US CALL: (845) 267-3065

CIRCULATION
PO Box 81
CONGERS, NY 10920
TEL: (TOLL FREE): (877) 529-1746
OUTSIDE US: (845) 267-3065



CEO, INFORMATION SERVICES GROUP
MARC FERRARA

SENIOR VICE PRESIDENT, OPERATIONS
JEFF LEVITZ

VICE PRESIDENT, HUMAN RESOURCES
TAMMY GARCIA

VICE PRESIDENT, CREATIVE SERVICES & PRODUCTION
MONICA TETTAMANZI

CORPORATE PRODUCTION DIRECTOR
JOHN ANTHONY CAGGIANO

VICE PRESIDENT, CIRCULATION
EMELDA BAREA



LET'S TAKE THE LONG VIEW TOGETHER.

The trail is clear.

Weaving along Hawaii's Na Pali Coast is the breathtaking Kalalau Trail. The trail is demanding...but in the end, its beauty is worth every step. Kalalau was early inspiration for us, today representing our innovative spirit and deep commitment to advancing the treatment of eye diseases. This is the journey we're all on at Kala and the one we can take together.

The technology in sight.

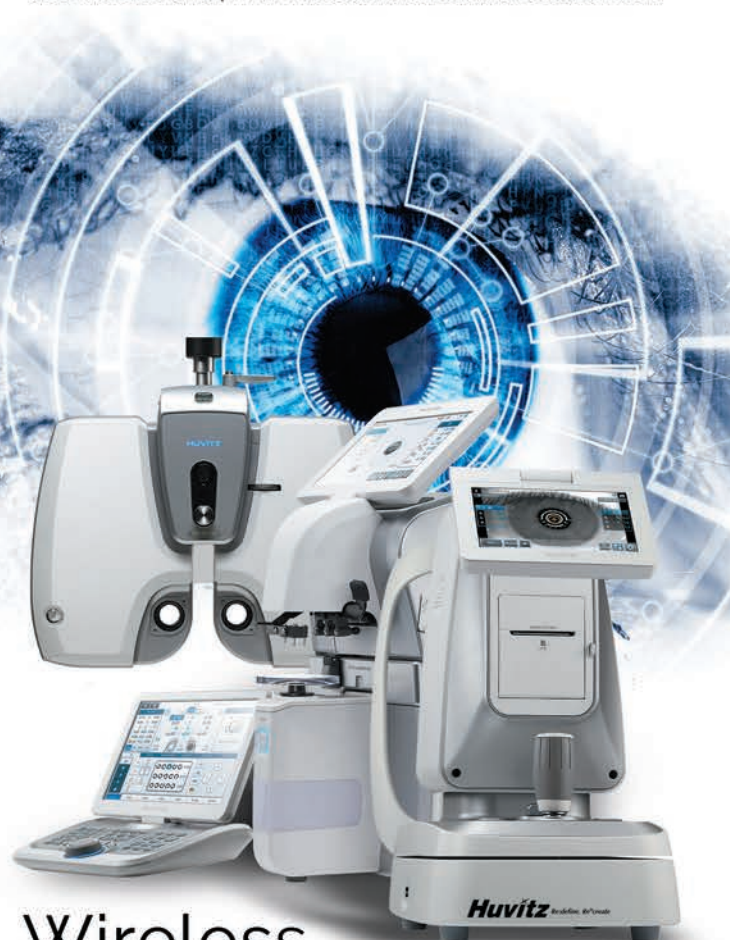Our proprietary and barrier-breaking **AMPPLIFY™** Drug Delivery Technology is designed to help us keep improving what's possible for eye care.

The vista awaits us.

Visit kalarx.com and let's get our journey underway.

kala 
PHARMACEUTICALS

© 2018 Kala Pharmaceuticals
All rights reserved. AMPPLIFY™ is a trademark of Kala Pharmaceuticals. Printed in the USA.
US-INV-1800002 August 2018



Wireless Diagnostic Line

Lensmeter | Digital Refractor | Auto Ref/Keratometer

Increase total practice efficiency with enhanced features such as **wireless communication** and **Hartmann sensor wavefront analysis technology**. The 9000 series is **fully compatible with all EMR systems** and equipped with a **full three year warranty**.

HRK-9000A AUTO REF/KERATOMETER

Enhanced with top-of-the-line features, the HRK-9000A offers **meibomian gland analysis** and **tear film break up time measurement**. Eliminating the need to use a slit lamp, the HRK-9000A is also **anterior segment capable**.

HDR-9000 DIGITAL REFRACTOR

Equipped with a **21 point exam package**, the HDR-9000 eliminates difficulty by displaying results for easy reading for examiners and patients. Features include **fast and silent lens loading**, as well as **enhanced functions in program modules, such as chart customization**.

HLM-9000 AUTO LENSMETER

One of a kind, the HLM-9000 measures the harmful effects of LED screens by utilizing the **blue light filtration measurement** function. Features also include **auto recognition** and **multi-focal lens measurement**.



BOOTH 1522

CONTRIBUTING EDITORS

- PAUL C. AJAMIAN, OD, ATLANTA
 AARON BRONNER, OD, KENNEWICK, WASH.
 MILE BRUJIC, OD, BOWLING GREEN, OHIO
 DEREK N. CUNNINGHAM, OD, AUSTIN, TEXAS
 MARK T. DUNBAR, OD, MIAMI
 ARTHUR B. EPSTEIN, OD, PHOENIX
 JAMES L. FANELLI, OD, WILMINGTON, NC
 FRANK FONTANA, OD, ST. LOUIS
 GARY S. GERBER, OD, HAWTHORNE, NJ
 ANDREW S. GURWOOD, OD, PHILADELPHIA
 ALAN G. KABAT, OD, MEMPHIS, TENN.
 DAVID KADING, OD, SEATTLE
 PAUL M. KARPECKI, OD, LEXINGTON, KY.
 JEROME A. LEGERTON, OD, MBA, SAN DIEGO
 JASON R. MILLER, OD, MBA, POWELL, OHIO
 CHERYL G. MURPHY, OD, BABYLON, NY
 CARLO J. PELINO, OD, JENKINTOWN, PA.
 JOSEPH PIZZIMENTI, OD, FORT LAUDERDALE, FLA.
 JOHN RUMPAKIS, OD, MBA, PORTLAND, ORE.
 DIANA L. SHECHTMAN, OD, FORT LAUDERDALE, FLA.
 JEROME SHERMAN, OD, NEW YORK
 JOSEPH P. SHOVLIN, OD, SCRANTON, PA.
 JOSEPH W. SOWKA, OD, FORT LAUDERDALE, FLA.
 MONTGOMERY VICKERS, OD, ST. ALBANS, W.VA.
 WALTER O. WHITLEY, OD, MBA, VIRGINIA BEACH, VA.

EDITORIAL REVIEW BOARD

- JEFFREY R. ANSHEL, OD, ENCINITAS, CALIF.
 JILL AUTRY, OD, RPH, HOUSTON
 SHERRY J. BASS, OD, NEW YORK
 EDWARD S. BENNETT, OD, ST. LOUIS
 MARC R. BLOOMENSTEIN, OD, SCOTTSDALE, ARIZ.
 CHRIS J. CAKANAC, OD, MURRYSVILLE, PA.
 JERRY CAVALLERANO, OD, PHD, BOSTON
 WALTER L. CHOATE, OD, MADISON, TENN.
 BRIAN CHOU, OD, SAN DIEGO
 A. PAUL CHOUS, MA, OD, TACOMA, WASH.
 ROBERT M. COLE, III, OD, BRIDGETON, NJ
 GLENN S. CORBIN, OD, WYOMISSING, PA.
 ANTHONY S. DIECIDUE, OD, STROUDSBURG, PA.
 S. BARRY EIDEN, OD, DEERFIELD, ILL.
 STEVEN FERRUCCI, OD, SEPULVEDA, CALIF.
 MURRAY FINGERET, OD, HEWLETT, NY
 IAN BEN GADDIE, OD, LOUISVILLE, KY.
 PAUL HARRIS, OD, MEMPHIS, TN
 MILTON HOM, OD, AZUSA, CALIF.
 BLAIR B. LONSBERRY, MS, OD, MED, PORTLAND, ORE.
 THOMAS L. LEWIS, OD, PHD, PHILADELPHIA
 DOMINICK MAINO, OD, MED, CHICAGO
 KELLY A. MALLOY, OD, PHILADELPHIA
 RICHARD B. MANGAN, OD, LEXINGTON, KY.
 RON MELTON, OD, CHARLOTTE, NC
 PAMELA J. MILLER, OD, JD, HIGHLAND, CALIF.
 BRUCE MUCHNICK, OD, COATESVILLE, PA.
 MARC MYERS, OD, COATESVILLE, PA.
 WILLIAM B. POTTER, OD, FREEHOLD, NJ
 CHRISTOPHER J. QUINN, OD, ISELIN, NJ
 MICHAEL C. RADOIU, OD, STAUNTON, VA.
 MOHAMMAD RAFIETARY, OD, MEMPHIS, TN
 JOHN L. SCHACHET, OD, ENGLEWOOD, COLO.
 JACK SCHAEFFER, OD, BIRMINGHAM, ALA.
 LEO P. SEMES, OD, BIRMINGHAM, ALA.
 LEONID SKORIN, JR., OD, DO, ROCHESTER, MINN.
 JOSEPH W. SOWKA, OD, FORT LAUDERDALE, FLA.
 SRUTHI SRINIVASAN, PHD, BS OPTOM, WATERLOO, ONT.
 BRAD M. SUTTON, OD, INDIANAPOLIS
 LORETTA B. SZCZOTKA, OD, PHD, CLEVELAND
 MARC TAUB, OD, MEMPHIS, TN
 TAMMY P. THAN, MS, OD, BIRMINGHAM, ALA.
 RANDALL THOMAS, OD, CONCORD, NC
 SARA WEIDMAYER, OD, ANN ARBOR, MI
 KATHY C. WILLIAMS, OD, SEATTLE
 KAREN YEUNG, OD, LOS ANGELES

YOUR CAMPAIGN YOUR SUPPORT



Think About Your Eyes drove **3.4MM incremental eye exams** and **\$752MM in incremental industry revenue** in 2017.

These industry leaders make the campaign a reality, and to keep it going, they need your support. Show them your appreciation, and encourage other companies you do business with to join the campaign.

Think About your Eyes can get even bigger and more impactful with your help.

thinkabout
youreyes.com

Brought to you by the AOA
AMERICAN OPTOMETRIC ASSOCIATION



PRINTED IN USA

FOUNDING EDITOR, FREDERICK BOGER
1891-1913

EDITORIAL OFFICES
11 CAMPUS BLVD., SUITE 100
NEWTOWN SQUARE, PA 19073

SUBSCRIPTION INQUIRIES
1-877-529-1746

CONTINUING EDUCATION INQUIRIES
1-800-825-4696

EDITOR-IN-CHIEF • JACK PERSICO
(610) 492-1006 • JPERSICO@JOBSON.COM

MANAGING EDITOR • REBECCA HEPP
(610) 492-1005 • RHEPP@JOBSON.COM

SENIOR EDITOR • BILL KEKEVIAN
(610) 492-1003 • BKEKEVIAN@JOBSON.COM

ASSOCIATE EDITOR • CATHERINE MANTHORP
(610) 492-1043 • CMANTHORP@JOBSON.COM

ASSOCIATE EDITOR • MARK DE LEON
(610) 492-1021 • MDELEON@JOBSON.COM

SPECIAL PROJECTS MANAGER • JILL HOFFMAN
(610) 492-1037 • JHOFFMAN@JOBSON.COM

ART DIRECTOR • JARED ARAUJO
(610) 492-1032 • JARAUIJO@JOBSON.COM

DIRECTOR OF CE ADMINISTRATION • REGINA COMBS
(212) 274-7160 • RCOMBS@JOBSON.COM

EDITORIAL BOARD

CHIEF CLINICAL EDITOR • PAUL M. KARPECKI, OD

ASSOCIATE CLINICAL EDITORS • JOSEPH P. SHOVLIN, OD;
ALAN G. KABAT, OD; CHRISTINE W. SINDT, OD

DIRECTOR OPTOMETRIC PROGRAMS • ARTHUR EPSTEIN, OD

CLINICAL & EDUCATION CONFERENCE ADVISOR
PAUL M. KARPECKI, OD

CASE REPORTS COORDINATOR • ANDREW S. GURWOOD, OD

CLINICAL CODING EDITOR • JOHN RUMPAKIS, OD, MBA

CONSULTING EDITOR • FRANK FONTANA, OD

COLUMNISTS

CHAIRSIDE • MONTGOMERY VICKERS, OD

CLINICAL QUANDARIES • PAUL C. AJAMIAN, OD

CODING CONNECTION • JOHN RUMPAKIS, OD

CORNEA & CONTACT LENS Q+A • JOSEPH P. SHOVLIN, OD

DIAGNOSTIC QUIZ • ANDREW S. GURWOOD, OD

THE ESSENTIALS • BISANT A. LABIB, OD

FOCUS ON REFRACTION • MARC TAUB, OD;
PAUL HARRIS, OD

GLAUCOMA GRAND ROUNDS • JAMES L. FANELLI, OD

NEURO CLINIC • MICHAEL TROTTINI, OD;
MICHAEL DELGIODICE, OD

OCULAR SURFACE REVIEW • PAUL M. KARPECKI, OD

RETINA DILEMMAS • DIANA L. SHECHTMAN, OD;

JAY M. HAYNIE, OD

RETINA QUIZ • MARK T. DUNBAR, OD

REVIEW OF SYSTEMS • CARLO J. PELINO, OD;
JOSEPH J. PIZZIMENTI, OD

SURGICAL MINUTE • DEREK N. CUNNINGHAM, OD;
WALTER O. WHITLEY, OD, MBA

THERAPEUTIC REVIEW • JOSEPH W. SOWKA, OD;
ALAN G. KABAT, OD

THROUGH MY EYES • PAUL M. KARPECKI, OD

URGENT CARE • RICHARD B. MANGAN, OD

JOBSON MEDICAL INFORMATION LLC



Outlook

By Jack Persico, Editor-in-Chief



A Death in the Family

Everyone who knew Frank Fontana was enriched by our connection to him. We're all going to miss him dearly.

By now you've heard about the death of Frank Fontana, universally known as 'Uncle Frank' throughout optometry. Many of us who were close to him—and that's hundreds of people at least—are taking it pretty hard. Because Uncle Frank truly did feel like a member of the family.

To give just one example, Uncle Frank used to call me every month when he received his copy of *Review of Optometry*. We'd chat about the topics in the issue, and sometimes he would recommend new authors for us to try. But mostly he was calling just to tell me I was doing a good job. Honestly, that was the reason for his call. I've been a professional medical editor for 27 years, so I'm pretty well settled into the career by now. But Uncle Frank wanted to make sure I felt good about myself. That's what close relatives do, if you're lucky enough to have them in your life. Optometry certainly did.

People who don't have good relationships with their families often comment that you can pick your friends but not your relatives. The wonderful thing about Uncle Frank is that he *did* pick his relatives. He made so many people feel like we were a part of a vast, extended family—and it was entirely his choice to make that a priority in his life. That speaks volumes about his character, and is a big part of why we'll miss him.

He was also indefatigable about being involved in the optometry profession. Uncle Frank continued to see patients a few mornings a week, and he attended all the major conferences. People half his age start

to weary of the travel grind and try to cut back. Not Uncle Frank. He needed to be a part of it, always. He even made it a point to always attend this magazine's editorial board meetings—a two-hour session that starts at 7am. As someone who had already made his mark before most of the others had been born, he cast a long shadow over our discussions.

It seems fitting that Frank Fontana passed away at Vision Expo West, in effect dying on the job. Because the job—being an optometrist—*was* his life. You may even notice that he is quoted in this very issue of the magazine, in the article about private equity buyouts beginning on page 48. He was interviewed for the article about three weeks before his death. He truly never stopped working for optometry.

Those monthly phone conversations I had with Uncle Frank were a welcome relief from the day-to-day stresses of a busy job. I would see a St. Louis phone number come up on my office phone and it would make me smile. One of the toughest things for me to accept since the news of his passing is realizing that'll never happen again. Everyone whose lives were touched by Frank Fontana will have holes like that from now on. After this issue mails and readers start receiving copies, I'll probably feel a little anxious for a few days, not knowing what to do.

Maybe I'll call my own nephew. It's been too long. Uncle Frank would appreciate that. The best way to honor someone is to be changed for the better by having known them. ■

Technology in balance



Health




Vision



Comfort

Miru 1 month: a unique family of silicone hydrogel monthly lenses.

MeniSilk™ and Nanogloss™ technologies designed to meet the demands of today's contact lens wearer.*



Material and surface technologies

MeniSilk™

- Ultra high Dk/t - 161 @ -3.00D
- Exceptional hydration
- Optimized transparency

Nanogloss™

- Super smooth surface
- Resistance to bacteria
- Excellent wettability



www.meniconamerica.com

*Menicon data on file April 2016





The Lesson of Online Refraction

It may be convenient, but it leaves our patients at risk. With new technologies, we can beat it at its own game. **By Paul M. Karpecki, OD, Chief Clinical Editor**

Many patients may believe online refraction would suffice for a comprehensive eye exam. But we have all seen too many cases of malignant melanomas with 20/20 vision, systemic diseases, retinal tears and glaucomatous nerves this technology would miss. Still, if convenience is what our patients want, we need to adjust our practice management to ensure patients get the care they need in our offices. These two steps can help:

1. Educate

Every patient needs to understand the importance of a comprehensive eye examination and refraction. We must convey how we can diagnose everything from diabetes to cancers via a comprehensive eye exam—something a refraction alone can't determine.

2. Enhance

ODs need to incorporate more advanced technology, making it impossible for online services to compete with our accuracy. For example, patients need to know that you use an advanced or electronic phoropter, all of which are ergonomically beneficial and impressive to patients.

One way to differentiate ourselves might be through the eventual use of robotics in clinical practice. For example, a recent research paper suggests the da Vinci robot, with modified software, could perform vitrectomy procedures. Other subtle changes to the software could lead

to its use in intraocular procedures, causing less tremors than surgeons, according to an ARVO poster. But ODs don't need to wait for these advances to incorporate robotics into their practice today. Two new technologies that have robotics at their core and are much more optometry focused have hit the market recently: Nexy, a robotic retinal imaging system (Konan Medical) and the VASR autorefractor by VMax Vision.

Nexy is a fully automated, small footprint retinal or fundus imaging machine. The patient puts their head onto the band at the top and the operator presses a green "go" button. Automatically, the robot guides 3-axis positioning for each eye, capturing polarization-clarified images. The information is sent wirelessly to the electronic health record or a reading center, often for diabetes screening.

The VASR (voice-activated subjective refraction) autorefractor was equally or more accurate to that of manual refraction in 97% of cases in an OD-led clinical study. It included 50 patients who were examined by the VASR autorefractor, with a masked investigator using a standard autorefractor followed by a traditional subjective refinement using a manual phoropter including binocular balance and all the usual steps of subjective refraction.

The phoropter measurements were conducted by clinicians with decades of combined experience, while the VASR subjective measurements were conducted by an optom-

etry student with little to none.

Results revealed there was no statistically significant difference between the VASR and the manual phoropter refractions. What was most impressive was that 14% of patients had better acuity with the VASR system (>1 line Snellen compared with the phoropter refraction), 3% of subjects had worse acuity with VASR (>1 line Snellen worse refraction) and 83% had less than 1 line Snellen line difference compared with a clinician's traditional refraction.

The VASR autorefraction system uses wavefront aberrometry, and the subjective refraction component uses proprietary point-spread-function (PSF) technology. The VASR exam is voice-guided during the entire refraction, and it incorporates artificial intelligence to optimize refraction outcomes. The only time the manual phoropter in the hands of a clinician beat VASR was in being about 20 to 30 seconds quicker to complete the refraction compared with a fully voice-activated system that took the patient from start to finish.

As these advances make clear, robotics are already affecting eye care. They belong in the hands of the eye care practitioner and may one day make our clinical practice—and the lives of our patients—easier. They can increase our efficiency and accuracy and leave online refraction systems in the dust. ■

Dr. Karpecki is a consultant/ advisor to Konan Medical and Vmax.

The all new Katena.com



EXPLORE • LEARN • ORDER

All customers establishing a validated account on the new site will receive a Katena Diamond series 90D reusable lens.*

**Offer ends 12/31/2018 (one lens per account)*



www.katena.com

Trust Your Intuition

Patients can be confusing; but if you know what to look and listen for, you'll know what's up. **By Montgomery Vickers, OD**

After enough patient encounters, you'll suddenly realize you can easily, intuitively and instantly connect with the patient's wants, needs and favorite foods. OK, the food part probably comes from the faint smell of barbecue they should have avoided yesterday, but the wants and needs are what're important anyway.

Playing your part in the critical doctor-patient relationship means listening, observing and, of course, accepting the patient's crappy vision plan. That relationship (with vision plans, not patients, usually) is always somewhere between symbiotic and vampiric; some days you suck their blood, but most days *they* suck yours.

An OD's Sixth Sense

Here's what you can do to hone your patient intuition:

First, and above all else, *listen*. This does not mean simply letting sound waves enter your ears. What does the patient (or parent) really mean? Here are some examples:

If a patient says, "There's nothing more important than our eyes," they don't mean, "There's nothing more important than our eyes." They mean, "I haven't had my eyes checked since I got LASIK in 2004." Obviously.

What if they say, "I just want what my insurance covers"? They mean, "I want to buy a 1964 Corvair Monza, but it had better be as fast as a Ferrari 488 Pista or I will give you a crappy review."

Try this one: "I tried contact lenses once, and they didn't work, but now I want to try them again." You guessed it. They really mean, "I am 53 years old, had LASIK in 2002 and my prescription is plano -0.50 x 162 with a +2.00 add." See how much time listening saved you on the refraction?

What if the mom says, "Billy gets his eyes from me. His father has perfect vision"? What she is really saying is, "Billy's father has never had an eye exam and wears my old glasses to watch TV."

Next, you must *observe*. Does the mom stay on the phone the whole time you are checking her daughter's eyes? By observation, you have just accurately diagnosed the daughter's presenting symptom: her eyes roll around all the time. Case solved.

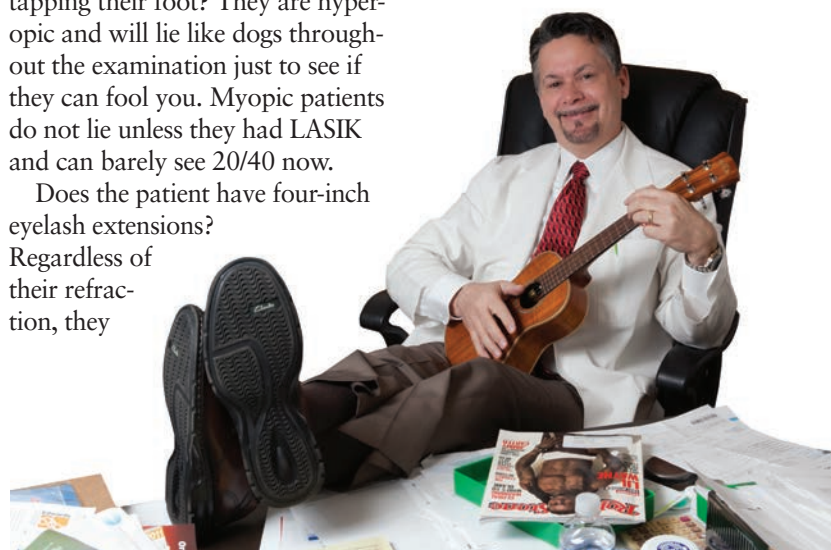When you enter the room, is the patient sitting with arms crossed, tapping their foot? They are hyperopic and will lie like dogs throughout the examination just to see if they can fool you. Myopic patients do not lie unless they had LASIK and can barely see 20/40 now.

Does the patient have four-inch eyelash extensions? Regardless of their refraction, they

will insist you declare them legally disabled because they "can't wear glasses." And if they drive a late-model Mustang, they will also need a letter to get their windows tinted.

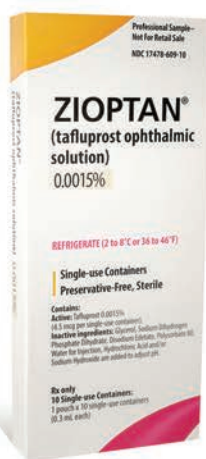Some very successful doctors assure me that patients respond best to *patience*. You know they are now 48 and can't see their computer, but they want to actually tell everyone their story. Sometimes I get the best patient history from the UPS guy who holds the front door for them. So, you absolutely must pretend you care that they can't see their spaghetti unless they wear their readers.

Try to stick to observation and not intervention. I'm 65, and when a 44-year-old tells me their eyes are "old," it's all I can do to not laugh and remind them my shoes are 44 years old. Try to nod and smile and make 'em see better. ■



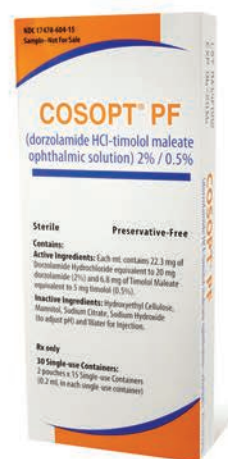

100% PRESERVATIVE FREE



If you're attending
AAO 2018, visit us at

**AKORN BOOTH
#3700**





ZIOPTAN[®]
(tafluprost ophthalmic
solution) 0.0015%

www.ZIOPTAN.com


Cosopt[®] PF
(dorzolamide HCl - timolol maleate
ophthalmic solution) 2% / 0.5%

www.CosoptPF.com

COSOPT is a registered trademark of Merck Sharp & Dohme Corp and is used under license. ZIOPTAN is a registered trademark of Merck Sharp & Dohme Corp and is used under license.

 ZIOPTAN is licensed by Santen Pharmaceutical Co., Ltd.



©2018 Akorn, Inc. All rights reserved. E089 Rev 07/18



Buckle Down

Recognize the situations when a surgeon would consider using scleral buckle procedures. **Edited by Paul C. Ajamian, OD**

Q I have a patient with a history of a scleral buckle procedure in 2004. I haven't seen one in a while and was wondering if they are still done.

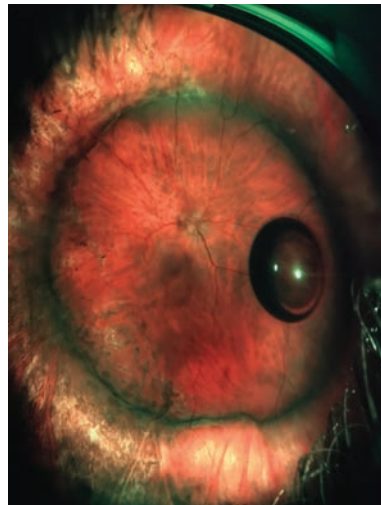
A "The short answer is 'yes'," explains Tanuj Banker, MD, a Bascom Palmer-trained retina surgeon who now works at the Center for Sight in Florida.

First described for the repair of a rhegmatogenous retinal detachment (RRD) more than 60 years ago, the principles of scleral buckling (SB) are: (1) physically support a retinal break by creating an indentation by the buckle and (2) use cryotherapy or laser photocoagulation to create an adhesion between the neurosensory retina and the retinal pigment epithelium, closing off the retinal break. The SB remains in place permanently, helping to mitigate forces such as vitreous traction or proliferative vitreoretinopathy (PVR) that can create a recurrent retinal detachment.

The use of SB for RRD repair has declined steadily over the past 30 years due to increased use of pars plana vitrectomy (PPV), Dr. Banker says, due to improved PPV technology, economic factors and surgeons' preferences. Unfortunately, many vitreoretinal surgical fellowship programs no longer teach scleral buckle placement. Firm believers in the efficacy of the technique at Bascom Palmer begin teaching fellows how to properly place an SB "on the first day of fellowship."

Best Case Scenarios

Scleral buckle placement can be either primary, in which the buckle



Combined scleral buckle and pars plana vitrectomy improved vision in this patient with a total retinal detachment.

alone is used to treat the retinal detachment, or combined with vitrectomy. Dr. Banker says that SB placement is optimal in these scenarios:

1. *A young phakic patient with a traumatic RRD.* A primary SB would avoid the need for a PPV, thus preventing cataract formation. As PPV removes the vitreous, significant cataract formation would occur in 90% of patients within two years.

2. *A patient with high myopia (-10D), extensive lattice and numerous retinal breaks with a total RRD.* In this case, the SB would support the vitreous base entirely, preventing future tears and reinforcing areas of lattice. Additionally, there are often multiple microscopic breaks in high myopia that the buckle would also support.

3. *A chronic inferior RRD with*

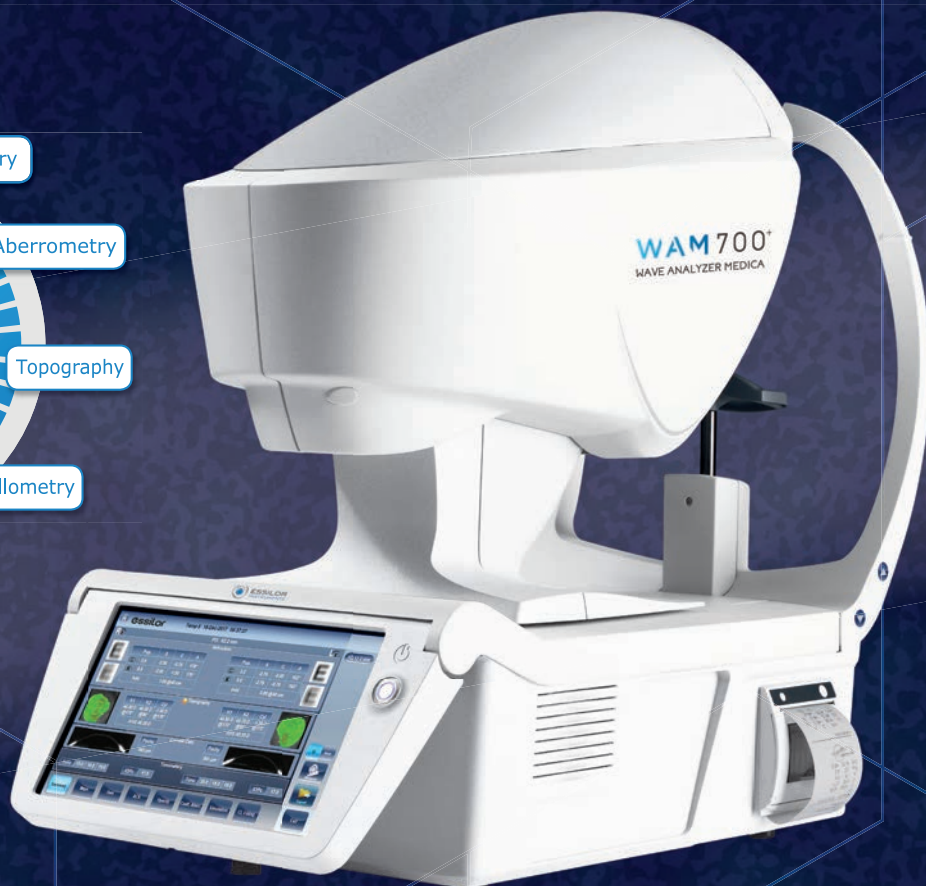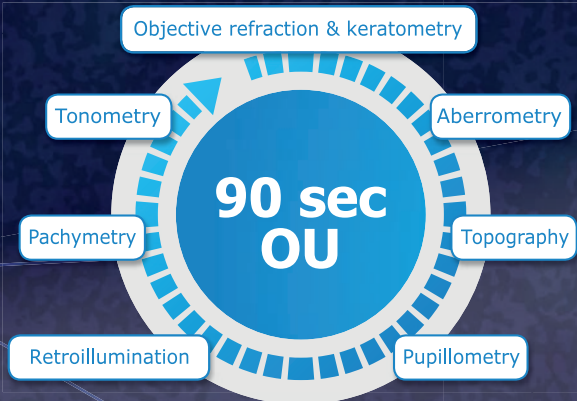
extensive proliferative vitreoretinopathy. In this scenario, a combination vitrectomy/scleral buckle would provide the best outcome. The PPV would allow a surgeon to flatten the retina, remove the PVR and use a gas or oil tamponade. The buckle would provide long-term support to the inferior breaks and help counter any tractional forces created by residual PVR or new PVR formation.

4. *A recurrent RRD after a primary vitrectomy.* Here, the patient had PPV with gas placement as the first surgery to repair the RRD. However, in the postoperative period after the gas has evaporated, the patient developed a recurrent RRD due to vitreous traction on the break or PVR formation. Scleral buckle would provide physical, long-term reinforcement to the break. This is especially important in cases of retinal dialysis or anterior breaks, both of which are difficult to treat with vitrectomy alone due to location.

Despite these virtues, complications such as diplopia, buckle extrusions and postoperative discomfort remain associated with SB. Fortunately, these are rare and can be avoided with proper surgical technique, according to Dr. Banker.

Repairing a complex retinal detachment is similar to going into battle. The more techniques and tools a surgeon has in their armamentarium, the better. "Old is gold; when placed properly in the correct scenarios, a scleral buckle is priceless," Dr. Banker says. ■

AUTOMATIC SCREENING SOLUTION TO STREAMLINE YOUR PRACTICE



WAM 700⁺

WAVE ANALYZER MEDICA

New from Essilor Instruments, the Wave Analyzer Medica 700+ is a very intuitive, rapid, and fully-automatic solution for complete anterior chamber analysis and vision need assessment.

- Fast, effective, and space-saving automatic wavefront aberrometer
- Seven detailed tests in 90 seconds; both eyes
- Key measurements: Wavefront aberrations, pachymetry, NCT, topography, ARK and more
- Simple to navigate with large touch screen



855-393-4647



essilorinstrumentsusa.com



info@essilorinstrumentsusa.com



In Your Practice... and Wallet

How you make your money now affects your practice value long-term.

By John Rumpakis, OD, MBA, Clinical Coding Editor

Normally writing this column doesn't require the use of the MBA side of my brain, but since a large portion of what I do is practice appraisals, I thought it would be useful to discuss the way your net income can impact your practice value.

Map Out a Strategy

Business planning can be a tedious process, but one that can yield great results if you identify strengths, weaknesses, opportunities and threats to your business model and set an appropriate timeline for achieving performance milestones along the way. Most independent practitioners want to successfully transition their practice ownership at some point in their career and, hopefully with proper planning, they look at what maximizes value long before they plan on selling.

Many factors can affect practice value, but one of the most significant is your free cash flow, or adjusted net income. You can certainly grow this number by recommending and prescribing premium optical products and the often-overlooked area of coding and pricing your professional services properly.

The average optometric practice still generates approximately 61% of its gross income from retail sales and 39% from professional services (and 2% from other sources).¹ Thus, barring outside Rx's being filled in your optical, for each dollar of gross income generated, professional services would generally have a higher net percentage, provided chair costs

remain constant since there really isn't a separate cost of goods sold component associated with professional services. With so much riding on your professional services, it's imperative that you handle the economics of them appropriately.

One of the purposes of this column has been to help clinicians navigate the CPT system and understand the value of properly diagnosing and treating ocular conditions that frequently present in your practice; understanding not only the short-term but also the long-term impact on value is critical.

Short-term = Long-term

While it is crucial to your success to understand the prevalence of common ocular conditions and the clinical care protocols surrounding them, you must also know the proper CPT codes for the type and level of office visit and know how to properly price your services. Understanding the time value of money is a basic economic principle that all of us should be familiar with. Making it work to your advantage by tying together all of these principles should be part of your business plan.

As an example, let's discuss incorporating dry eye diagnosis and treatment into your practice. This condition, conservatively, affects 25% of the US population, and the average practitioner sees a dry eye patient three times a year, in addition to their annual comprehensive eye exam.²⁻⁴ Each of those additional visits will bring in approximately \$74, which can generate approxi-

mately \$172,500 annually in office visits.⁵ That's not bad for a short-term return in exchange for your professional services, but that's not the whole story.

The significance of that additional \$172,500 in net income per year could increase your practice value by more than \$1,000,000 in the long-term. Yes, you read that correctly. Even small increases in your net income can add significantly to the value of a practice. The important thing is to recognize these opportunities and act on them during all phases of your practice lifetime.

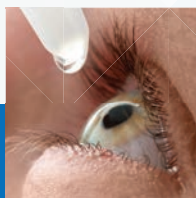
Your practice value is ultimately a multiple of your adjusted net income. Incorporating strategies to increase this value can come from many sources, including simple additions to your professional services. Understanding the prevalence of common ocular conditions and their proper coding, proper pricing for your services and the time value of money are some of the simplest ways to execute on this very important, but often overlooked, approach to maximize your practice value. ■

Send questions and comments to rocodingconnection@gmail.com.

1. Management and Business Academy for Eye Care Professionals. Key metrics: assessing optometric practice performance 2015. Essilor. http://ecpu.com/media/wysiwyg/docs/paa_keymetrics_0415.pdf. Accessed August 29, 2018.
2. Stapleton FJ, Alves M, Bunya V, et al. TFOS DEWS II epidemiology report. *Ocular Surf*. 2017;15(3):334-65.
3. Yen JC, Hsu CA, Li YC, Hsu MH. The prevalence of dry eye syndrome's and the likelihood to develop Sjögren's syndrome in Taiwan: a population-based study. *Int J Environ Res Public Health*. 2015;12(7):7647-55.
4. Shah S, Jani H. Prevalence and associated factors of dry eye: Our experience in patients above 40 years of age at a Tertiary Care Center. *Oman J Ophthalmol*. 2015;8(3):151-6.
5. Centers for Medicare and Medicaid Services. Current CMS national average maximum allowable for CPT code 99213.

VISIT US AT AAO
BOOTH 3503

Autologous serum eye drops **made easy.**



Simple.

Vital Tears eye drops are easy to order and even easier to use.



Precise.

Available in your choice of dilution options in a 3 or 6 month supply.



Accessible.


300+ outpatient blood collection facilities. Direct delivery to your patient.

LEARN MORE AT vitaltears.org OR CALL (800) 360-9592



10560 N Ambassador Dr Suite 210
Kansas City MO 64153

© 2018 Vital Tears LLC. All rights reserved.



It's a Small World After All

Prolonged near-point tasks shrink a patient's visual horizon to their immediate surroundings, overtaxing vergence and accommodation. **By Marc B. Taub, OD, MS, and Paul Harris, OD**

Everyone experiences stress and deals with their stressors—whether they are psychological or physiological—in different ways. Some learn to minimize and live with the stress they face. Some do not.

Our bodies also experience stress. Many people spend hours, if not entire days, on computers. Their backs, shoulders and necks are under a tremendous amount of physical pressure to keep their heads and bodies upright and their eyes pointed at the desired target. Their eyes are put to the test daily and must maintain a state of heightened, stimulated accommodation and convergence for extended periods of time.

To successfully perform a task without experiencing visual side effects, vergence and accommodative systems must meet at the same plane of regard. The majority of these systems, however, cannot satisfy this requirement, which is why our offices flood with patients complaining of headaches, eyestrain and other near-point problems. These poor adapters make up a large percentage of our patients. Understanding the stresses your patients deal with and recognizing the opportunity to meet their needs will greatly improve the quality of care you can provide.

Stressed-out Eyes

A mismatch between vergence and accommodation takes place when a patient cannot sustain near-point demand. Without a compensatory mechanism, the patient is then led down a different adaptation pathway where dysfunctions, such as convergence insufficiency and accommodative excess, occur.

So, why do some people develop near-point stress-induced dysfunctions while others do not? Exophoria and low hyperopia protect the vergence and accommodative systems, essentially acting as buffers to combat the stresses of today's ocular demands. Losing either buffer can have serious implications.



Spending countless hours on computers puts our bodies and eyes under more stress.

Demand Overload

As near-point stress builds up, our patients bring their reading materials, computers or cell phones closer to their eyes. A patient's reaction to the stress causes visual adaptations, such as blur or diplopia. Blur adaptations induce ametropia and may eventually lead to more permanent adaptations, such as myopia.

When the planes of regard for vergence and accommodation misalign during activities requiring sustained concentration, there is a desire for convergence to localize

closer in space than accommodation. This manifests as esophoria at near and encourages the accommodative system to compensate for blur to maintain homeostasis. The theory addresses why some myopic patients develop the condition later in life, long after their eyes have stopped growing.

The continued intense near-point demand can also lead to diplopia. Compensating for diplopia by manipulating convergence causes the patient to develop orthophoria and esophoria. Similar to the development of myopia, this is by no means a quick or smooth process. A patient may attempt to compensate for this change over a period of months, or even years, only to ultimately succumb to a visual efficiency disorder.

Upon becoming orthophoric or esophoric, patients may attempt to rebuild their exophoric buffer and overcompensate (by building a larger buffer) to produce a greater amount of protection. If the exophoric buffer is large enough, convergence insufficiency or suppression or even exotropia (intermittent leading to constant) could develop and high exophoria could become the primary cause of visual dysfunction.

Buffer Management

Low-plus glasses aim to reduce the effects of near-point stress on the visual system, improve posture and normalize the near-point working distance. Low-plus lenses at

Signs of Near-point Stress

Exophoria (>6X') or Esophoria (<1X')

- Exo: fighting the stress
- Eso: losing the exo buffer

Low (<+0.25) or high (<+1.00) MEM or fused cross-cylinder

- Low: absorbing the hyperopic buffer
- High: building up the hyperopic buffer

NRA and PRA both <1.75

Myopia, emmetropia or higher amounts of hyperopia

- Myopia/emmetropia: losing the hyperopic buffer, reducing both the accommodation required to maintain clarity at near and the associated over-convergence
- Hyperopia: building a stronger buffer

Low blur, break or recoveries on vergences

- Low blur: newer problem
- Low break: more embedded
- Low recoveries: poor stability

near are designed to help rebuild the buffer that had previously dissipated as a result of convergence localizing closer than accommodation. They also allow for relaxation of accommodation, putting a halt to, or reducing the need for, over-convergence. This enables the vergence and accommodative systems to overcome, or correct, the mismatch that has developed.

Several methods can help determine the most appropriate low-plus lenses for a patient. Some ODs simply balance the negative relative accommodation and the positive relative accommodation, while others use various forms of near-point retinoscopy, such as the monocular estimation method (MEM) or the stress point, bell or book tests. Clinicians should also consider phoric posture.

Choosing the most appropriate prescription should be a negotiation between the patient and the clinician. When prescribing and attempting to understand how patients benefit from low-plus lenses, we must keep in mind three numbers: +0.50 and ½ exophoria at distance and 6 exophoria at near. These numbers are close to the expected results found by the MEM and phoria at near, both of which can quickly assess the state of the buffer system.

Refractively, the worst thing you can do to your patients is prescribe away their buffers. By doing so, you are setting the stage for future myopia or binocular vision and accommodative dysfunctions. Because the majority of patients do not take buffers into consideration, let alone know what they are, we must educate them on the importance of buffers and guide them through the process of strengthening their buffers to prevent further visual impairment. ■



NuLids™ transformational dry eye therapy

Transforms your patients' lives



Finally... A doctor-directed at-home treatment for dry eye disease that is safe, effective and easy to use.

A multi-center study¹ showed:

- 50% decrease in dry eye symptoms
- 65% improvement in TBUT
- 80% increase in meibomian glands yielding liquid secretions.

For more information visit
www.NuSightMedical.com/ropt10
or call us at 833-368-5437




¹ Schanzlin, Olkowski, Coble, Gross. NuLids II Study, April 2018



NuLids™

Doctor prescribed, at-home dry eye relief



RAO: Keep Calm and Refer On

Blockages are an emergency, but some in-office therapies might help if you see patients in time. **By Diana Shechtman, OD, Jay M. Haynie, OD, and J. Wilfredo Lara, MD**

Retinal artery occlusion (RAO), characterized by acute vision loss due to an arterial blockage, is considered an ocular emergency, as permanent vision loss will ensue in many cases. The blockage manifests as inner retinal swelling associated with a cherry-red spot. In addition, attenuated arterioles, optic nerve atrophy, arterial segmentation ('box-carring') and the presence of an arterial embolus may be noted.

Since retinal emboli are the most common cause, conventional therapies focus on vasodilation in hopes of dislodging the associated embolus. Anecdotal therapy modalities used in our office include hyperbaric chamber, paracentesis, antihypertensive medications, ocular massage and transluminal YAG laser embolysis. Although a few of these measures show anecdotal success, given the limited timeline for retinal reperfusion, the prognosis is often grim.

The key to management is the prevention of secondary complications. Thus, traditional evaluation includes testing blood pressure, fasting glucose/HbA1c, fasting lipids, carotid ultrasound, complete blood count with differentials and echocardiography. Because giant cell arteritis may play a role in elderly patients, clinicians should also evaluate erythrocyte sedimentation rate, C-reactive protein and platelet count in any patient older than age 60. Younger patients should have a hypercoagulable and vasculitis workup as well.

Too Little, Too Late

Case by Drs. Shechtman and Lara

A 72-year-old Caribbean male was referred for evaluation of severe painless acute vision loss of the right eye. Although the patient was initially referred as a STAT

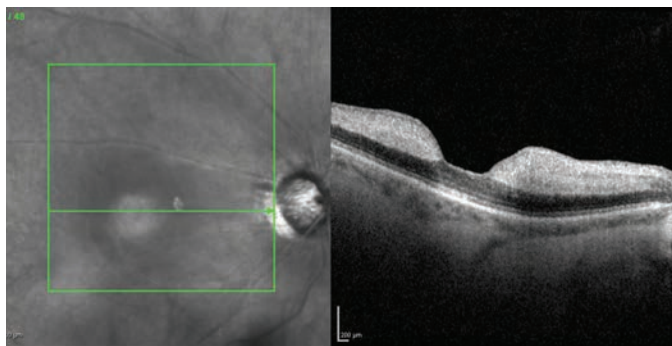


Fig. 1. OCT is an invaluable diagnostic tool to assess possible retinal thickening, as seen here in another acute CRAO patient.

consult by a local ophthalmologist, he did not present to our clinic until two weeks later because he had been hospitalized for a stroke shortly after the onset of vision loss.

His best-corrected visual acuity measured 20/400 in the right eye with an associated afferent pupillary defect.

Dilated examination revealed a mottled retina,

attenuated arterioles and optic atrophy of right eye. Evaluation of his optical coherence tomography (OCT) scans obtained at the initial ophthalmology consult demonstrated inner retinal thickening with associated shadowing of the underlying outer retinal layers. The patient was advised to continue follow-up with his primary care physician and cardiologist and scheduled for a follow-up in four weeks.

Is RAO Akin to Ischemic Stroke?

This case brings to light the realization that RAO and stroke share a common pathophysiological mechanism associated with thromboembolism; they also have similar risk factors. Although the most common cause of RAO stems from an embolic event, other etiologies can stem from thrombosis, spasms, vasculitis or trauma. Confounding risk factors include diabetes, hypertension, hypercoagulability factors and cardiac or carotid disease.

Recent studies suggest RAO is linked to an increased incidence of stroke and mortality-associated complications, considering as many as 25% of patients with an RAO have concurrent brain infarction. Even silent brain infarctions bear a high risk for future stroke, and patients with RAO have more than double the chances of developing subsequent strokes. The magnitude of such strokes is often higher in younger patients, while the increased risk of multiple strokes is often higher

among older patients. Researchers suspect the risk of stroke dramatically increases within the first week after the RAO and remains a possibility a month following the event.

In our practice, it is standard of care to immediately refer any patient with an acute RAO to an emergency department with a stroke center with an order for a neuro consult and a diffusion-weighted magnetic resonance imaging.

Additionally, because transient ischemic attack (TIA)/atrial fibrillation (AF) and retinal emboli share the same cause and mechanism as a cerebral ischemia, we customarily employ the same management protocol for patients presenting with TIA/AF and retinal emboli.

Time is of the Essence

Commentary by Dr. Haynie

I concur regarding the management of a patient with an RAO; however, it should be noted that irreversible vision loss from an acute RAO is often permanent after 90 to 120 minutes from the onset of visual symptoms. Unfortunately, many patients do not present to the clinic in time.

In my practice, our MDs will consider an anterior chamber paracentesis to rapidly lower the intraocular pressure, resulting in vasodilation and potential dislodging of the embolism if the symptoms are less than 24 hours old and the patient has a central RAO. If the embolism is in a branch retinal artery, such a procedure is rarely done, as these patients tend to have, and keep, intact central vision.

Regardless, it is important to attempt to lower the intraocular pressure in the office through digital ocular massage, instillation of topical and oral hypotensive agents, breathing into a paper bag and similar interventions if the symptoms are within 90 to 120 minutes. Patients need access to ophthalmology for a consult if management is not readily available and your state license does not permit you to perform a surgical procedure such as an anterior chamber paracentesis.

I also concur on the referral for appropriate diagnostic studies, keeping in mind that time may be of the essence, as the risk of a secondary event (i.e., cerebral stroke) is much higher in patients with a primary RAO. I will generate a summary and urgent referral for the patient and send them directly from my office to the emergency department in the hopes that this urgent request will expedite the ancillary testing and assessment of associated risk factors that may be amenable to treatment, ultimately reducing the morbidity of embolic complications. ■

NuLids™ transformational dry eye therapy

Transforms your practice

The NuLids System helps reduce patient out-of-pocket expenses while creating an additional revenue stream for the practice – all without impacting overhead costs or disrupting other in-office treatments.

A multi-center study¹ showed 95% were satisfied or very satisfied with the treatment.

For more information visit
www.NuSightMedical.com/ropt10
or call us at 833-368-5437

¹ Schanzlin, Olkowski, Coble, Gross. NuLids II Study, April 2018



NuLids™

Doctor prescribed, at-home dry eye relief





With 20 years of success to tout, the tactics —and the results—are changing. **By Bill Kekevia, Senior Editor**

EXPANDING

SCOPE OF PRACTICE: Lessons and Leverage

Optometry is a legislated profession” is a refrain ODs hear over and over throughout their education and into their careers. The entire scope of practice is dependent on the passage of statewide bills. As a result, optometry has become 50 slightly different professions throughout the country, with 50 different menus of procedures and indications available. These variations are decided by lawmakers, but often reflect the whims of a powerful medical lobby that pushes skepticism about optometry.

That means optometrists who consider employment opportunities across state lines need to consider what *optometry* will even mean in their new home. This is a quandary unique to optometry. Doctors of other stripes, once licensed, are free to operate comparatively uninhibited. A DO or an MD in Oregon has the same rights as one in Florida.

However, due to a perfect storm of economics, demographics, education and technology, optometry is primed to look a lot more like traditional medical practice, if it can finally face down an age-old rivalry (see *Eight*

Decades of Chicanery, p. 36).

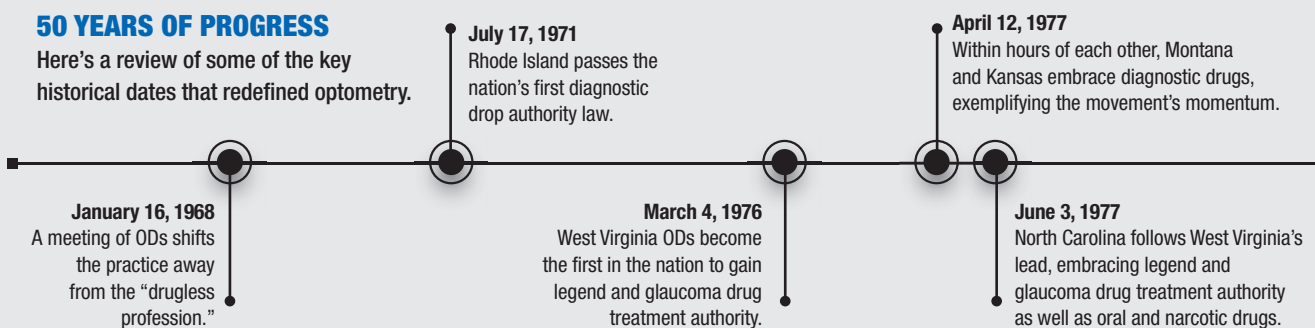
“The whole concept of optometrists moving from a nontherapeutic profession to a therapeutic profession has taken a decade or two, but it’s slowly, steadily still catching on,” says Randall Thomas, OD, of Concord, NC.

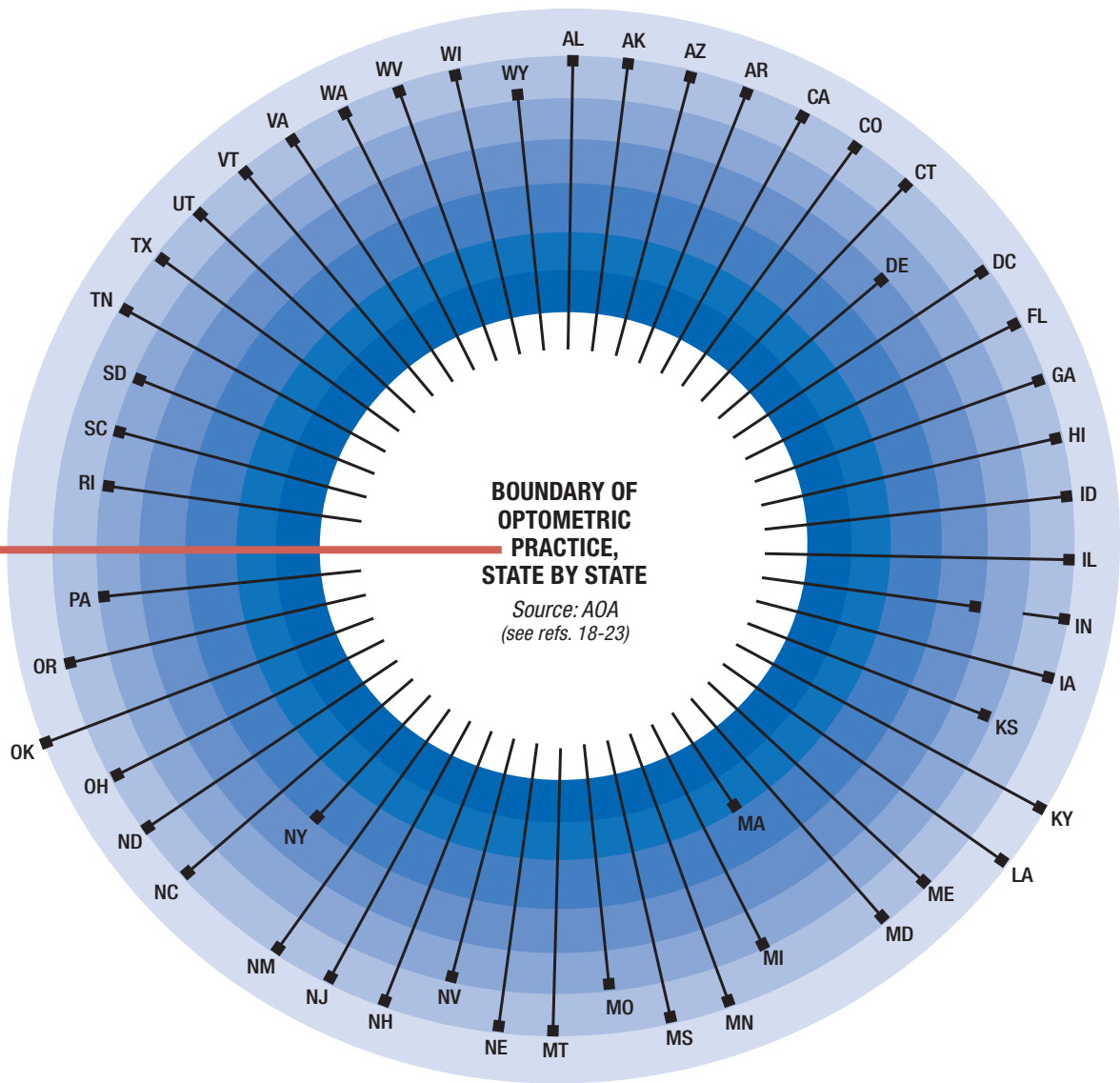
From the Front Lines

Oklahoma is rounding out its second decade with lasers, Kentucky is approaching its 10-year anniversary and Louisiana enters year five. This gives the profession’s advocates a prized resource: empirical data.

50 YEARS OF PROGRESS

Here’s a review of some of the key historical dates that redefined optometry.





BOUNDARY OF OPTOMETRIC PRACTICE, STATE BY STATE

Source: AOA
(see refs. 18-23)

- DIAGNOSTIC AGENTS
- LEGEND Rx THERAPEUTICS
- GLAUCOMA DRUGS
- ORAL MEDICATIONS
- ORAL NARCOTICS
- INJECTABLE DRUGS
- LASER PROCEDURES

Due to optometry’s unique nature, state scope of practice laws vary widely. This graph gives a sense of the broad techniques OD can perform in each state, but even within each concentric circle, subtle nuances exist. For instance, in several states—Minnesota is one—optometrists can prescribe oral drugs, but not oral steroids; and for antiviral drugs in Minnesota, ODs are limited to a 10-day course and oral carbonic anhydrase inhibitors are limited to seven. In Delaware, oral steroids are limited to a six-day course. Another example: in Alaska, optometrists can legally perform anterior segment laser procedures including YAG capsulotomy, SLT and LPI, but its state board hasn’t yet implemented the guidelines to do so. Pennsylvania and Wyoming optometrists can only prescribe Schedule III-V drugs.

- February 14, 1980**
Georgia ODs celebrate Valentine’s Day by becoming the 26th state in the nation to embrace diagnostic drugs.
- March 2, 1987 – June 25, 1987**
Optometry sees an eight-state run of legend drug authority laws passing, increasing the total from 12 to 21 in a few months.
- January 13, 1989**
Maryland becomes the 50th state to achieve diagnostic drug authority.
- March 22, 1984**
Seven years after North Carolina, Oklahoma reignites the fire under glaucoma drug legislation, a trend that would continue steadily for 20 years.
- April 10, 1987**
A decade after North Carolina’s broad expansion, North Dakota passes injectable agent authority.
- August 3, 1989**
With the diagnostic battle won, organized optometry shifts focus to legend, oral and glaucoma drug legislation. Wisconsin sets the standard by passing a law for all three in one day. That law also included narcotic drugs and injectable agents.



Eight Decades of Chicanery

Optometrists have had a target on their backs for decades. In 1937, Albert Fitch, who founded Pennsylvania College of Optometry, tried to pass a diagnostic and therapeutic drops bill. It was defeated in a razor thin 90-88 vote, through what Dr. Fitch would later write was nothing short of “chicanery.” According to Dr. Fitch’s biography, a member of Pennsylvania’s Health and Sanitation Committee, who happened to be a physician, posed as the committee’s chairman and “made a sobbing appeal to have the bill referred to his committee.”

“The physician made a solemn promise that if the bill was referred to his committee, it would be reported back the next day with a recommendation for its passage. He said all this knowing full well that his committee, which contained more physicians than any other committee in the legislature, was not in favor of the bill and that his promise would never be kept.”^{1,2}

1. Fitch A. My fifty years in optometry. 1959;2:337-55.
2. Bennett I. Improving the scope of practice for optometry. Optometry Cares—the AOA Foundation. www.aoafoundation.org/ohs/hindsight/improving-the-scope-of-practice-for-optometry. Accessed October 1, 2018.

Optometric groups are using this track record to show that ODs can provide safe and effective treatments with lasers. “We’re going to have very good data to show that we’re not blinding people and patients are getting improved access to care, so as each state looks at the data moving forward, it’ll be hard for ophthalmology to object,” says Richard Mangan, OD, of Aurora, CO.

Organized optometry has seen a number of successes lately, both in scope expansion and legislation to protect optometrists and their patients.

In recent years, Florida, Missouri, West Virginia and Colorado are among several states that have taken on noncovered services legislation.¹ While these measures lay the groundwork for scope expansion by elevating the profession, legislative changes are being seen in other states such as Virginia, California and Alaska.

It’s all part of the American Optometric Association’s (AOA) and its state affiliates’ strategy, which is less focused on individual indications and more on “making sure the state boards of optometry have the authority to regulate the profession,” says Samuel Pierce, OD, president of the AOA. “That’s important, because you want the state boards to determine what is and isn’t allowed for an OD, and you want a state law that supports the profession by allowing doctors to incorporate new technologies into their practice rather than go back and ask permission time and again.”

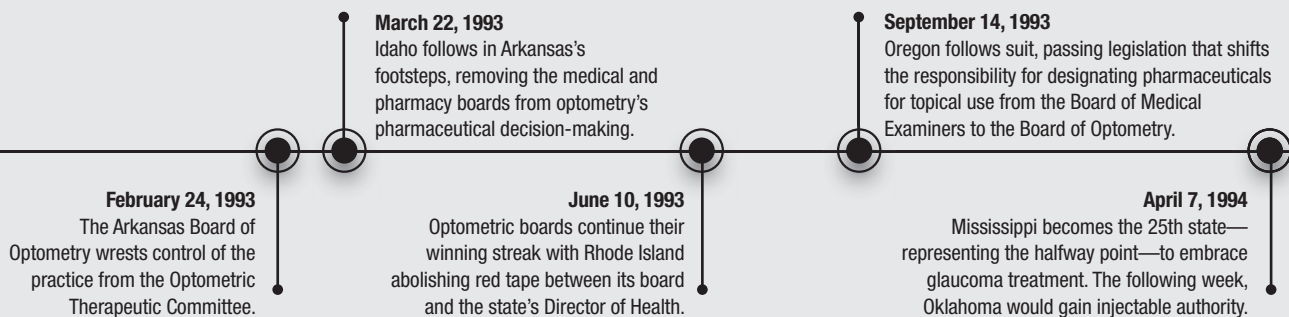
California, under its Optometry Practice Act, did just that by allowing ODs to completely restructure their regulatory system.² Now, any non-controlled medication, device or technology that is FDA approved for an eye condition that optometrists treat is automatically approved

for optometry.² Similarly, off-label medications, devices and technologies need only be approved by California’s licensing board. Before this expansion, ODs also weren’t permitted to administer flu or shingles vaccinations. Now, they can.

But sometimes listing specific procedures has worked too, as was the case this year in Virginia when legislation enacted on July 1 included the right to perform corneal crosslinking, intense pulsed light and chalazian injections with steroids, as well as six other lump and bump removal techniques, explains Dr. Pierce.

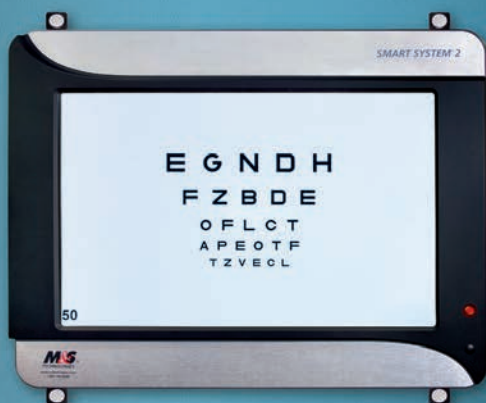In Alaska, the board of examiners in optometry will soon have the authority to write regulations allowing ODs to practice to the highest level of their education.³ That will almost certainly include YAG capsulotomy, SLT and laser peripheral iridotomy as well as foreign body and lump-and-bump removal. However, “just because you pass a law doesn’t mean everybody can start doing it,” explains Dr. Pierce. “The state board has to create a regulatory process.” Once Alaska irons out those last few kinks, they’re likely to become the fourth laser state in the nation.

Optometry is making inroads anywhere that seems amenable to its growth. At the top of that list, it seems, are states neighboring those with the most indications. It’s a reasonable strategy. If a patient lives close enough to the border of Louisiana or Oklahoma—say, perhaps,



**Stop by
for a Demo!**

AAO-OD
Booth 1543



Give your
patients
the best

Call today
1/847-763-0500



Learn more about the Visual Acuity Testing System which includes the best USA-based customer service and technical support in the industry!

Learn more at:
mstech-eyes.com/ebook/ssebook.pdf

M&S
TECHNOLOGIES

The First Choice in Vision Testing Systems



Toll Free: 877-225-6101
mstech-eyes.com



M&S holds US Patents 7,354,155; 7,926,948; 8,425,040; 8,167,429; 8,419,184 & 8,550,631. Other Patents Pending.

SMART SYSTEM[®] 2 | 2020

ACCURACY • RELIABILITY • REPEATABILITY

See how the **Smart System[®] 2** technology enables increased quality of care, streamlines exams and improves engagement with your patients at every level.

Over 50 different Vision Tests, including VA, contrast, stereopsis, binocular balance and color vision.

Near, Intermediate and Distance Testing

DVD Functionality allows the user to play DVDs directly providing immediate fixation on retinoscopies.

Patient Education includes 26 pre-loaded patient education images with the flexibility for additional images and videos

Internal Marketing allows you to load PowerPoint slides, images or videos to promote your practice and educate your patients.

LEA SYMBOLS[®] & LEA NUMBERS[®] is the standard in pediatric vision testing.



One Giant Leap

It took nearly 30 years after the failure of Albert Fitch's historic 1937 attempt at optometric expansion before the modern era of optometry finally began. On January 16, 1968, A. Norman Haffner, OD, finally put his foot down and settled a debate that had been essentially splitting the profession down the middle for decades.

His words at a meeting of optometric leaders that day—"The optometrist is a primary care provider and the optometrist has a role in the diagnosis and treatment of ocular pathology"—seem a simple statement of fact today, but at the time, it was radical. The previous self-definition of a "drugless profession" was out.¹

Within three years, Rhode Island would pass the first diagnostic drug bill and optometry was off to the races. Therapeutic drops followed a similar path, with the first bill past in West Virginia in 1976. Before this run, a mere conjunctivitis patient had to choose between trying to book an eye surgeon for treatment or relying on a family practitioner who wouldn't have particular training in eye care. The primary care role specifically for eyes—the biological structure that most informs humans' perception of the world and most influences quality of life—simply didn't exist.

As optometry enters its next phase, its advocates will have to look to this history to guide how to best serve patients in need.

1. Eger M. The Airlie House Conference. *Journal of the American Optometric Association*. 1969;40(4):429-31.

in Arkansas, which borders both—nothing is stopping them from getting the procedure done across state lines by an optometrist rather than an in-state ophthalmologist.

Lawmakers may even be convinced from a business standpoint, explains one scope expansion advocate. If they think optometrists are likely to pack up shop and move to where they can practice to the fullest extent of their education, they may not want to be responsible for a dearth of primary eye care providers. As such, those southeastern states are inching ever closer to passing OD-friendly bills. Just take a look at Florida, where, last year, news of a bill merely passing a subcommittee vote spooked organized

medicine enough to warrant a media campaign against it.⁴ That bill ultimately died in another subcommittee.⁵ But it represents progress.

In nearby North Carolina, a group called North Carolina Citizens for Clear Action targeted a particular state legislator who co-sponsored a scope expansion bill, funneling at least \$100,000 to confront the state senator with flyers, mailers and television ads.^{6,7} The three-term incumbent—David Curtis, OD—lost his May primary and resigned in June.^{7,8} Local reporting shows that the group North Carolina Citizens for Clear Action was funded by another group: the North Carolina Society of Eye Physicians and Surgeons.⁶

What ODs are Up Against

Organized optometry is replete with complaints about interventions from ophthalmology lobbyists. Nowhere is this truer than in Massachusetts, the last state in the nation that doesn't permit optometrists to prescribe any glaucoma medications. With the might of nearby Massachusetts Eye and Ear at its disposal, organized medicine has become a powerhouse lobby in the Bay State.

"Any time you've got a really strong research eye hospital" with robust state support, "they've built up a huge lobbying network over the years," explains David Damari, OD, who serves as both dean of Michigan College of Optometry at Ferris State University and as president of ASCO.

And it's not just Massachusetts. Other states with prominent eye hospitals—Pennsylvania (Wills Eye), Maryland and Washington DC (Wilmer) and Florida (Bascom Palmer) have all lagged in scope expansion. Pennsylvania didn't get glaucoma drug authority until 2002. Florida didn't have oral drug authority until 2013. The final three legend drug bills for optometry (barring the US Virgin Islands) were passed in Pennsylvania, Massachusetts and Washington, DC. On no issue do they fight harder than glaucoma care—which can bring in Medicare and Medicaid patients who will visit every three to six months.

"They fight to make sure that optometrists don't gain confidence

May 22, 1997

Optometrists in North Carolina amplify their scope of practice by end the requirement to communicate and collaborate with another physician when prescribing TPAs.

March 16, 1998

Oklahoma crafts legislation that expands on language presented a decade earlier. This act would give optometrists the ability to use lasers and remove stitches and foreign bodies.

July 31, 1997

Massachusetts becomes the final state in the nation to embrace legend drug authority for ODs. Glaucoma drugs are still off limits there to this day.

May 18, 1999

Arizona adds specific oral antibiotics, oral antihistamines and prescription strength OTC oral NSAIDs, injectables for anaphylactic reaction, Schedule III controlled narcotic oral analgesics and lab test authority.



TEST.



RESULTS.

Include The Bruder Moist Heat Eye Compress In Your Dry Eye Treatment Protocol

It's a fact. More and more doctors are testing their patients for evidence of dry eye. Not surprising. With the incidence of this chronic disease on the rise, early treatment is important.

Whatever treatment strategy you plan for your patient, it should include the Bruder Moist Heat Eye Compress – recommended by more doctors than any other heat compress.

The patented compress provides a clinically proven treatment that helps relieve dry eye symptoms while improving overall ocular surface health.

The Bruder compress is an effective dry eye treatment that your patient takes home between visits to your office. It's easily incorporated into your patient's daily routine, increases compliance, and provides quick relief.



#1 DOCTOR RECOMMENDED MOIST HEAT COMPRESS

Go to www.bruder.com/getresults-now to learn why more and more doctors are making dry eye an integral part of their practice. And why the 'Bruder Mask' is an important part of their treatment protocol.

VISIT BOOTH #1227 AT ACADEMY 2018 IN SAN ANTONIO TO LEARN MORE.



in glaucoma,” Dr. Damari adds, by insinuating that optometric inexperience might leave patients blind. “It’s not that we can’t treat, it’s that it’s the one thing ophthalmology holds on to because of reimbursements.”

The disparity, optometric advocates report, is apolitical. It’s not about red vs. blue; it’s about the green.

Medical Muckraking

One of the medical lobby’s weapons of choice has been publishing in mainstream news, trade publications and even peer-reviewed journals. You can practically track the status of any one optometric bill by uncovering a typical anti-optometry headline (usually something like “Leave Eye Surgery to the Surgeons”).

Dr. Pierce says the AOA doesn’t really engage in those battles. “We don’t get into tit-for-tat arguments in the press with ophthalmology. The truth of the matter is, since 1998 when Oklahoma first passed legislation to allow lasers, doctors of optometry have done so safely and effectively. We look at facts, and the fact is optometry is doing an excellent job of taking care of their patients,” he says, adding that there has been no rash of lawsuits, nor reports of patients losing their vision due to negligence or other documented problems in states where ODs have gained broader scope.

Within ophthalmology, fear-mongering has reached the peer-

reviewed journals, too. Take for instance, a piece—which left Dr. Thomas apoplectic—from a February 2018 *American Journal of Ophthalmology*, arguing to establish an American Academy of Ophthalmic Associates.⁹ “The idea has merit for physician assistants, nurse practitioners, ophthalmic technicians, and ophthalmic photographers, but ophthalmologists should recognize the limited power it would have over optometrists, were it to be implemented,” wrote David Browning, MD, an ophthalmologist from Charlotte, NC. “It is easy to imagine a scenario in which an optometrist learns to administer intravitreal injections working as part of an ophthalmology-led team, and then leaves to practice without ophthalmic supervision in a state in which the right for optometrists to perform intravitreal injections has been legislated.”

To Dr. Thomas, this is both an example of how optometry is talked about when no ODs are in the room and a classic case of the medical establishment prioritizing itself over its patients. “Ophthalmologists are thinking more and more of recruiting PAs to do intraocular injections—who have had something like two to three weeks of training, whereas optometrists have had four years. But they’d rather have a PA they can control than an OD who is independent,” Dr. Thomas says.

In a *JAMA Ophthalmology* piece that’s been heavily circulated for the past couple of years, a researcher team with representatives from Michigan, Pennsylvania and Oklahoma delivered what some optometrists have since called a scare-tactic in the form of an article finding laser trabeculoplasties performed by optometrists had a 189% “increased risk” of requiring additional laser trabeculoplasty.¹⁰

Glaucoma specialist Murray Fingeret, OD, in a letter to the journal, called the study misleading and noted it isn’t even supported by the authors’ own data.¹¹ “It is hard to understand the meaning of their conclusions without knowing whether treatments were performed in more than one session with 180° treatments or a single session with 360° treatments,” he wrote.¹¹

A good deal of that retreatment rate might stem from the natural history of the disease rather than any optometric shortcomings. The study looked into the performance of 27 optometrists, all trained at Northwestern University, a program which recommends performing the 180° procedure first and only considering treatment of the other half if intraocular pressure doesn’t sufficiently come down.^{10,11} The *JAMA* study said nothing in terms of pressure reduction or complications. It appears the authors used a somewhat flexible definition of “risk.”

In other words, chicanery.

March 15, 2001

North Dakota removes requirement to consult and develop a treatment plan with an ophthalmologist when treating patients with glaucoma. ND also removed the reference to treating “open angle” glaucoma only.

New Hampshire adds treatment of glaucoma with topical agents (and orals in an emergency) as well as topical steroids, topical antivirals and oral antihistamines. Removed the prohibition on treating the lacrimal drainage system.

May 18, 2002

May 29, 1999

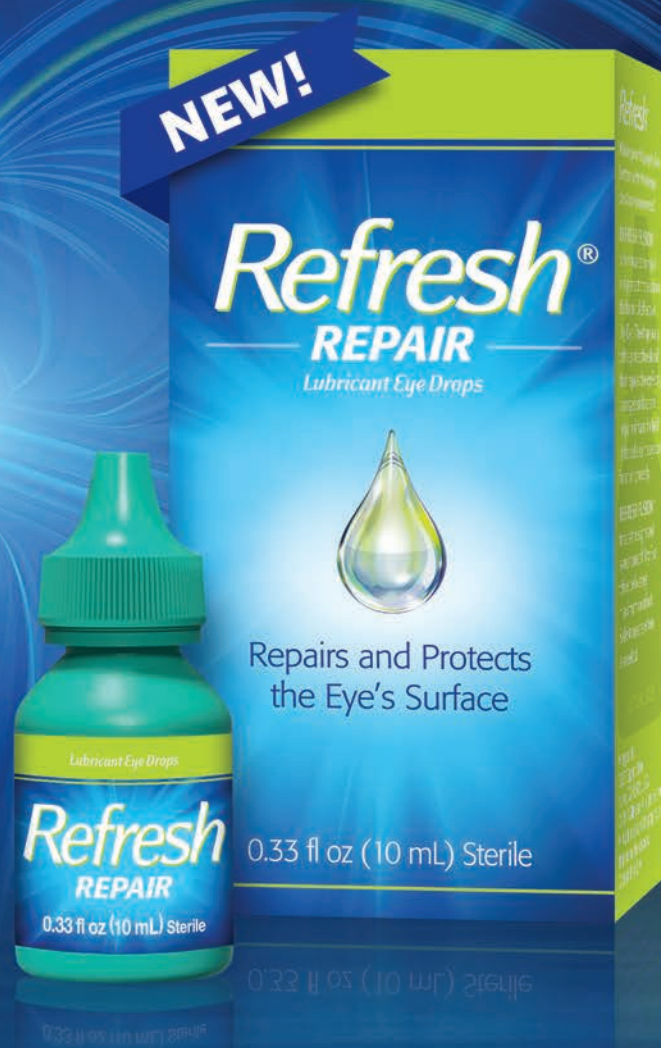Nevada scraps legislation prohibiting ODs from treating glaucoma with topical and oral drugs and added lab testing to their armamentarium.


August 8, 2001

South Carolina removes requirement to consult an ophthalmologist when prescribing beta blockers and extends from seven to 21 days the length of treatment with topical steroids before communication with an ophthalmologist is required.

INTRODUCING
REFRESH[®] REPAIR

The first and only artificial tear in the U.S.
formulated with CMC, HA*, and Osmoprotectants.



REFRESH[®] REPAIR helps promote healing of the cornea and conjunctival epithelia and improves visual performance in Dry Eye patients. Safe to use with contacts. 

refreshbrand.com/doc | 

 **Allergan.**

*HA is an inactive ingredient.

© 2018 Allergan. All rights reserved. All trademarks are the property of their respective owners. REF115212 05/18

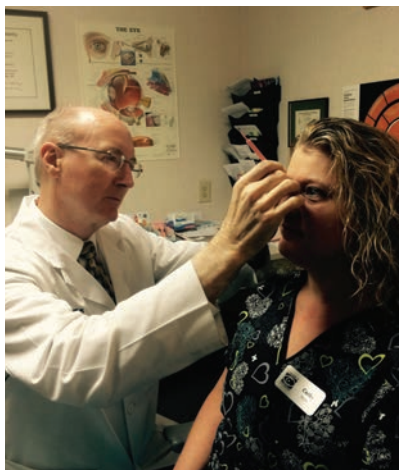

It's the Economy, Doc

Baby boomers are at least 65 million strong, and living long.¹² As people age into their 60s and beyond, pathology starts to increase. “That means more cataract patients, more posterior capsular opacification patients and more glaucoma patients,” explains Nate Lighthizer, OD, an educator out of Northeastern State University Oklahoma College of Optometry, who takes a special interest in laser procedures. With this demographic shift, “ophthalmologists are going to have their hands full keeping up with cataracts and the wet form of macular degeneration” among other things, says Dr. Thomas.

There's been another shift, too. Optometry's numbers are increasing while ophthalmology's remain flat—and may even be decreasing, if you consider that nearly half of American ophthalmologists are older than 55 and optometry is graduating more students than ever.¹³ While optometry is trying to find ways to expand its residency programs, ophthalmology's have stayed relatively flat for nearly a decade and its total number of applicants has decreased over that timespan by more than 100.¹⁴

For patients, these trends mean ophthalmologists are fewer and farther between. This fact has worked in optometry's favor, helping it achieve its broadest scopes of practice in the rural states Kentucky,



Dr. Thomas, seen here demonstrating how he examines a patient, is a vocal advocate for allowing optometrists to use steroids in their treatments when necessary. Approximately 15 states still bar optometrists from doing so, but that may soon change as demographic realities make optometric scope expansion a priority.

Oklahoma and Louisiana. Dr. Mangan—who, until recently, practiced in Kentucky—mentions that while he lived there, he'd have patients who'd walk to his practice, sometimes even with urgent presentations. “I've had patients who didn't drive. For them, it's important that there's access,” he says. Without the expansions in optometry's scope over the years, he might have to send them to another office, which could compromise the patient if their need was timely. Besides, Dr. Mangan says, optometrists “have more training

and expertise in eye disease than any family physician or emergency room doctor could. We typically have better diagnostic equipment, too.”

It doesn't take a sociologist to see optometry is primed to fill a need, and a handful of the roles ophthalmology has traditionally filled are primed to migrate to optometry. “We are often the first encounter a patient will have with the health care provider. Last year, we diagnosed hundreds of thousands of previously undiagnosed diabetes, we are definitely an entry point into the health care system—that doesn't need to be hampered by outdated optometry acts,” notes Dr. Pierce.

For the most part, these roles include the kind of work optometry doesn't need any new indications for, but of those items that do necessitate legislative change—chief among them involving laser, minor surgical procedures and amniotic membranes—organized optometry is taking the fight to the statehouses, just as it did in the 1970s and 1980s for diagnostic drugs and 1980s and 1990s for therapeutic drugs.

They're appealing to lawmakers by explaining how, as Dr. Lighthizer puts it, “a two- to five-minute in-office procedure can restore a 20/40 or 20/50 patient's vision back to 20/20 within hours to days.”

“I envision, in the next 10 to 20 years, more and more states will embrace scope expansion,” he adds.

Part of that will be chalked up

December 16, 2002

Pennsylvania gives optometrists the ability to prescribe steroids and to treat glaucoma with oral and topical drugs.

December 1, 2002

Michigan removes requirement for optometrists to consult with an MD prior to initiating glaucoma treatment. Added narcotics and oral excluding steroids.

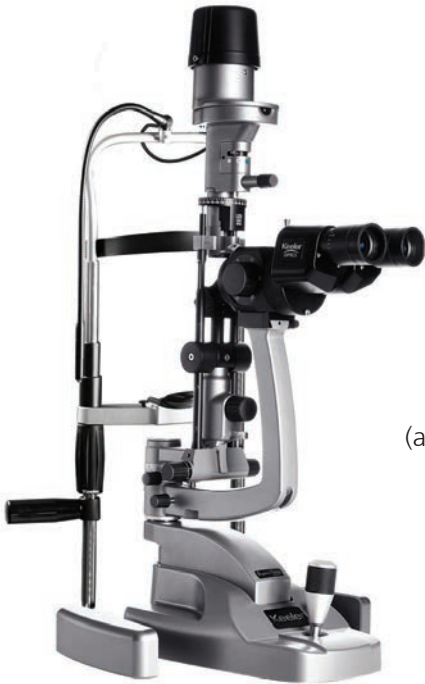March 14, 2003

Washington state adds injectables for anaphylaxis and Schedule III, IV and V narcotic substances, and specifically references the removal of foreign bodies and treatment of the lacrimal system.

The Keeler³ Trade In Program

Buy 3 // Trade 3 // Get 1 Free

The Power of 3. Purchase any 3 Keeler Slit Lamps and trade in 3 of your old Slit Lamps and we'll send you a 4th Keeler Slit Lamp absolutely free of charge.



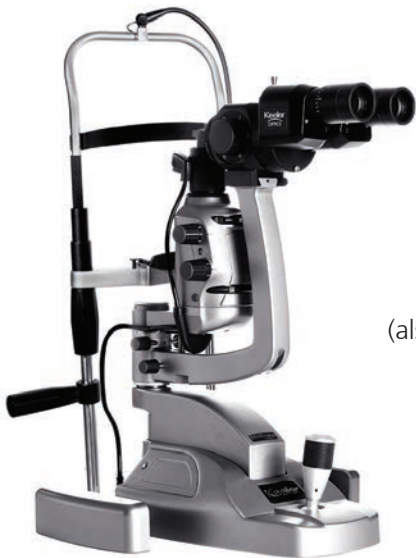KSL-H

(also in Digital Ready)



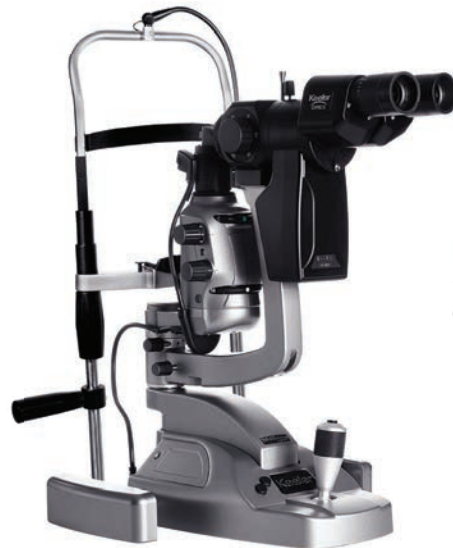KSL-H-D

(full Digital)



KSL-Z

(also in Digital Ready)



KSL-H-D

(full Digital)

Keeler
OPTICS

Keeler Instruments, Inc. • 3222 Phoenixville Pike, bldg. 50 • Malvern, PA 19355
Tel: (800) 523-5620 • Fax: (610) 353-7814 • email: keeler@keelerusa.com

Offer valid until December 31, 2018.

Contact Keeler or one of our authorized dealers for more information.



to appeals to legislators, but the impact technology has on redefining what an OD can do shouldn't be ignored either.

We Have the Technology

"If you're a refraction-centric optometrist, you're going to be replaced by technology," predicts Dr. Thomas. "But if you're a medically oriented optometrist, there's nothing out there to replace solid cerebral clinical judgment." This is a common sentiment among optometrists and it's driven many changes in both legislation and education, both of which are facilitated by technological advances that are making it possible for ophthalmologists and optometrists alike to function more precisely, with more robust data and, ultimately, practice at higher levels.

In fact, technology is inextricably wrapped around optometric scope of practice laws. This is the part that's unique to optometry. When a new surgical technique enters into cardiology or oncology, the surgeon may have to be certified by an independent, non-governmental body, but its application is not legislated. The government doesn't say that a dermatologist but not a family physician can use liquid nitrogen to freeze off a wart. However, most optometric regulations are guided by laws of "inclusion" rather than "exclusion."¹⁵ Inclusive laws define the limits of what optometrists can do; exclusive laws list what optom-

etrists cannot do. In other words, the law in most states must explicitly include particular procedures in optometry's scope.¹⁵

This is where Oklahoma, the first state to gain laser authority (in 1998) and the tenth to gain authority to use injectable agents (in 1994), is so well positioned. The state has an exclusionary law. "The nice thing about that," explains Dr. Lighthizer, "is that when a new procedure comes out, it isn't on the exclusionary list, so ODs don't have to go back to the legislature and ask for permission." For instance, when SLT was approved for use in glaucoma patients in 2001, optometrists in Oklahoma could start using it the moment they were certified and set up for it. Today, SLT is beginning to be recognized as a first-line therapeutic option.¹⁶ That means, if more states permit optometrists to use lasers, patients could have the option of seeing the eye doctor they've been visiting their whole lives for a non-invasive, in-office procedure before they ever see an ophthalmologist. This is precisely the kind of structure California's bill is aiming for.²

Education

The argument against optometry's scope expansion often portrays ODs as lacking the educational background to capably perform certain tasks. But technology is leveling the playing field to the point where the argument is frequently

more about equipment access than actual medicine. "Every optometrist trained on a slit lamp can do a YAG," explains Dr. Lighthizer. "It's the same technique. If you can do gonioscopy, you can do an SLT—it is a very similar skill set."

And if it's the OD's residency training that's being questioned, Dr. Damari, points out that ophthalmology is facing a similar problem. "There just aren't enough patients who need these procedures in the United States," he says. "Removing chalazia, minor suturing, laser procedures for angle closure—there's barely enough for residency training in ophthalmology to do them, let alone for the 1,500 to 1,700 optometry students who graduate every year to get enough experience that would make us comfortable to say they've had enough experience."

That doesn't mean that optometry students aren't learning the ropes; it only means that, like ophthalmology, most of the experience is developed outside of residency programs. Every optometry student, regardless of institution, is trained as though they're going to practice in a state that permits them to perform laser and lid lesion procedures. In fact, nearly every school signs and submits to the optometric boards in Kentucky and Louisiana an affidavit to that effect.

Don't Fight, Adapt

Optometry has always been a

May 19, 2003

Minnesota becomes the 25th state to permit optometrists to use injectable agents, marking the halfway point.

May 11, 2004

Vermont becomes the 49th state in the nation to give ODs glaucoma treatment authority, leaving Massachusetts the only remaining outlier today.

March 25, 2004

The Ohio Board of Optometry's new rule authorizing oral antiviral drugs and oral antihistamine drugs is enacted.

May 25, 2006

New Hampshire repeals comanagement provisions, adds oral antivirals, places approval of topical drugs under the state's Board of Optometry.

TONOMETRY REDEFINED

THE INTELLIGENT TONOMETER THE ACCURATE TONOMETER THE CONSISTENT TONOMETER THE OBJECTIVE TONOMETER THE REPEATABLE TONOMETER THE INTELLIGENT TONOMETER THE ACCURATE TONOMETER THE CONSISTENT TONOMETER THE OBJECTIVE TONOMETER THE REPEATABLE TONOMETER THE INTELLIGENT TONOMETER THE ACCURATE TONOMETER THE CONSISTENT TONOMETER THE OBJECTIVE TONOMETER THE REPEATABLE TONOMETER THE INTELLIGENT TONOMETER THE ACCURATE TONOMETER THE CONSISTENT TONOMETER THE OBJECTIVE TONOMETER THE REPEATABLE TONOMETER THE INTELLIGENT TONOMETER THE ACCURATE TONOMETER THE CONSISTENT TONOMETER THE OBJECTIVE TONOMETER THE REPEATABLE TONOMETER THE INTELLIGENT TONOMETER

icare
HOME

THE PATIENT
CHOICE



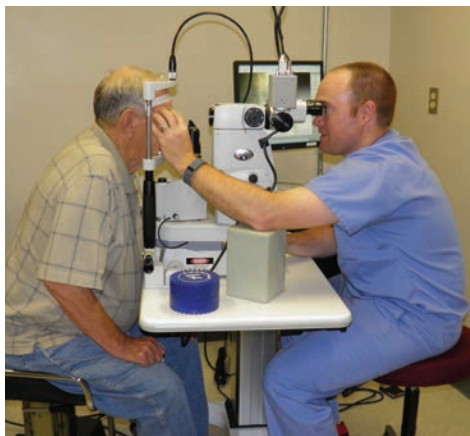icare
ic100

THE PROFESSIONAL
CHOICE



VISIT AAO 2018 **BOOTH #1524** AND MENTION **ALAMO**
FOR SHOW SPECIAL!

Learn more: info@icare-usa.com or www.icare-usa.com



Dr. Lighthizer performs a YAG capsulotomy. This non-invasive laser procedure represents the highest rung of optometry's current scope of practice.

self-defined profession and legislation has always been the mechanism, however imperfect, to broaden that definition. But what if optometry no longer needs legislative action to enable growth? Consider the changing demographics, advanced technologies and the general shift toward medical optometry.

“I don’t believe that our future will be much bolstered by any procedure,” as many become supplanted by newer ones in time, offers Dr. Damari.

Why bother fighting for procedures that may not even exist in a few years instead of refocusing optometry’s efforts towards the more “high-touch” aspects of health care?¹⁷

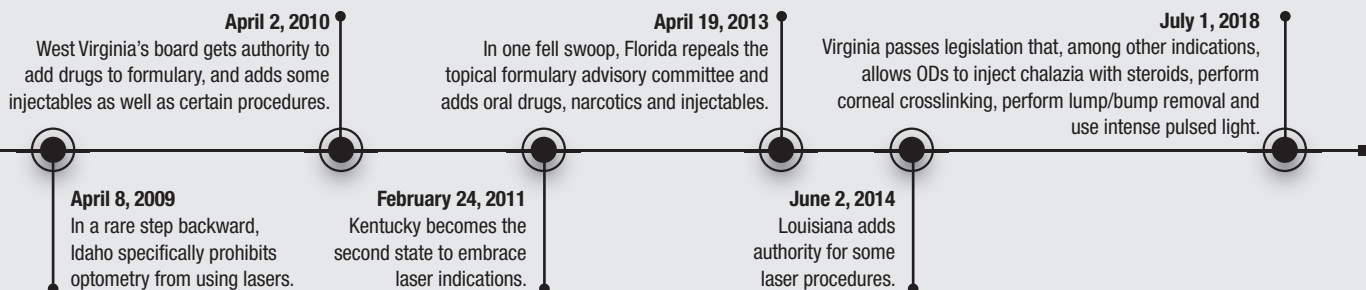
“If we limit our imagination to

only training on procedures, it’s not going to benefit our profession the most” says Dr. Damani, who points to tele-medicine, home diagnostics and quality of life improvement as some of the biggest changes to practice on the horizon. These will include patient management techniques that optometrists are already skilled at, with the possible addition of helping patients understand the kinds of wellness data gathered by wearable diagnostic tools and visual therapy techniques that can protect the eyes of an increasingly near-working population.

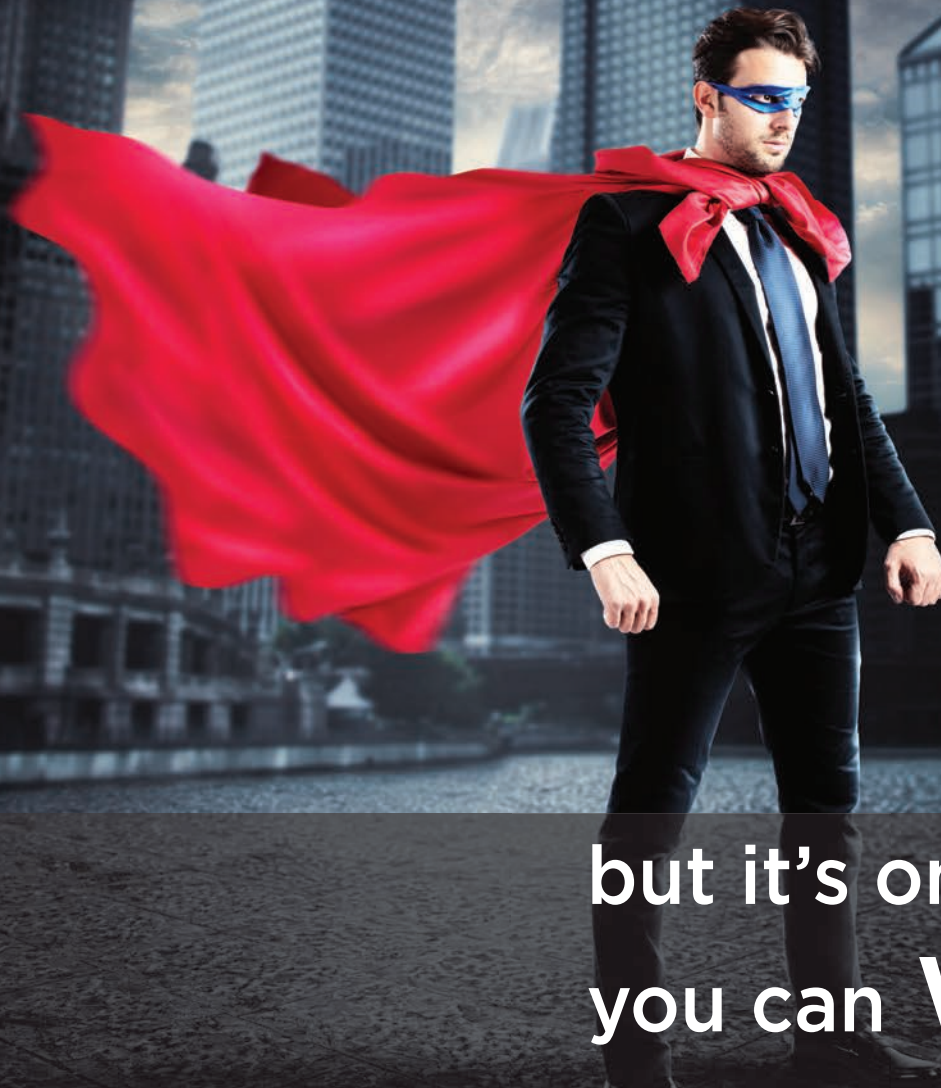As ophthalmology eschews medical management in favor of surgery, optometry will catch all those patients. As refraction either becomes automated or the primary domain of big box retailers and their optical departments, maybe the time for optometry to split is here again—just as it was in 1968. ■

1. American Optometric Association. AOA alerts states to NAVCP-backed noncovered services bill. www.aoa.org/news/advocacy/aoa-alerts-states-to-navcp-backed-noncovered-services-bill. March 10, 2017. Accessed October 1, 2018.
2. California legislative information. AB-443 Optometry: scope of practice. leginfo.ca.gov/faces/billTextClient.xhtml?bill_id=201720180AB443. October 9, 2017. Accessed October 1, 2018.
3. Alaska Optometric Association. Governor Bill Walker signs HB 103 into law. www.aoa.org/news_manager.php?page=14408. Accessed October 1, 2018.
4. Miller N. Florida optometry bill clears House subcommittee. Orlando Sentinel. March 15, 2017. Accessed October 1, 2018.
5. Florida Senate. CS/HB 1037: Optometry. www.flsenate.gov/Session/Bill/2017/1037/ByVersion. Accessed October 1, 2018.
6. Morrill J. ‘Classic dirty politics’: This deep-pocketed group

- is trying to sway an NC election. The Charlotte Observer. www.charlotteobserver.com/news/politics-government/election/article209898514.html. May 1, 2018. Accessed October 1, 2018.
7. Horsch L. These 5 NC Republicans won't get another term in the legislature. News Observer. www.newsobserver.com/news/politics-government/article210721329.html. May 9, 2018. Accessed October 1, 2018.
8. North Carolina General Assembly. Biography, Senator David L. Curtis. www.ncleg.net/gascripts/members/viewMember.pl?Chamber=S&nUserID=378. June 30, 2018. Accessed October 1, 2018.
9. Browning D. Correspondence: Physician assistants and nurse practitioners in ophthalmology—has the time come? JAMA Ophthalmol. 2018;191(7):166-7.
10. Stein J, Zhao P, Andrews C. Comparison of outcomes of laser trabeculoplasty performed by optometrists vs ophthalmologists in Oklahoma. JAMA Ophthalmol. 2016;134(10):1095–1101.
11. Pollard K, Scommegna P. Just how many baby boomers are there? Population Reference Bureau. www.prb.org/justhowmanybabyboomersarethere. April 16, 2014. Accessed October 1, 2018.
12. Association of American Medical Colleges. 2014 Physician Specialty Data Book. members.aamc.org/eweb/upload/14-086%20Specialty%20DataBook%202014_7111.pdf. November 2014. Accessed October 1, 2018.
13. Association of University Professors of Ophthalmology. Ophthalmology residency match summary report 2018. sfnmatch.org/PDF/FilesDisplay/Ophthalmology_Residency_Stats_2018.pdf. Accessed October 1, 2018.
14. Raji J. Louisiana optometry: an exclusive law. Optometry Students. www.optometrystudents.com/louisiana-optometry-an-exclusive-law. July 11, 2017. Accessed October 1, 2018.
15. de Leon J, Latina M. Selective Laser Trabeculoplasty. Quantel Medical. www.quantel-medical.com/upload/products/product-9/download_file_en_Selective_laser_trabeculoplasty_-_JM_DE_LEON_M_LATINA_-_09.2015.pdf. Accessed October 1, 2018.
16. Realini T. First-line selective laser trabeculoplasty: Has its time arrived? Eyeworld. www.eyeworld.org/article-first-line-selective-laser-trabeculoplasty-has-its-time-arrived. August 2013. Accessed October 1, 2018.
17. Menton M. Getting high-tech to remain high-touch. Health Tech Magazines. www.healthtechmagazines.com/getting-high-tech-to-remain-high-touch. Accessed October 1, 2018.
18. American Optometric Association. Optometric prescriptive authority/scope of practice chronology. August 15, 2014.
19. American Optometric Association. Scope of practice enactments – timeline. July 2018.
20. American Optometric Association. Scope of practice amplification laws. January 6, 2018.
21. Nguyen Q. Optometry scope of practice in each state. New Grad Optometry. newgradoptometry.com/optometry-scope-of-practice-united-states. April 20, 2018. Accessed August 1, 2018.
22. Alaska Optometric Association. Governor Bill Walker signs HB 103 into law. http://www.aoa.org/news_manager.php?page=14408. July 26, 2018. Accessed September 4, 2018.
23. Chan J. What is the scope of practice in my state? Optometry Students. www.optometrystudents.com/legislative-list. November 20, 2016. Accessed September 4, 2018.



It may seem like a war...



but it's one
you can **WIN.**

7

Ways to Protect Your Contact Lens Practice

Every time you dispense a "one size fits all" disposable, you create a patient who can shop anywhere for a replacement lens. It could be a competitor, a discount online operation, or a company that promotes directly to patients.

Extreme H2O® disposable lenses are special because they provide unique fitting solutions that are not available from other companies. And by "fitting" your patients in lenses that are designed for their individual needs, there's a better chance they come back to YOU for their specialty disposable lenses.

Learn More at: www.7-Ways-CL.com

877.336.2482 | www.xcelspecialtycontacts.com





Should You Sell to Private Equity?

With an upward trend in buyouts, private practice ODs have even more to consider when planning for their futures. **By Jane Cole, Contributing Editor**

It was time.

Jack Schaeffer, OD, of Birmingham, AL, built the Schaeffer Eye Center to encompass more than 18 locations in Birmingham. After practicing optometry for more than 30 years, Dr. Schaeffer was faced with deciding what would come next for his practice. He had to consider what was best for his family—his three children were also practicing with him—and for him, both personally and professionally.

“I wanted the Schaeffer Eye Center and my children to be part of something that had a larger organizational platform to handle day-to-day operations and negotiate with vision care and managed care companies,” he says. “I wanted a social media platform that was more robust. And I wanted a company that understood how to be profitable in optical in an environment dominated by managed vision care.”

After extensively researching his options, Dr. Schaeffer ultimately decided to sell his fleet of practices to a private equity (PE) company.



Photo: Jack Schaeffer, OD

Dr. Schaeffer is enjoying a year-long sabbatical following the sale of his practice.

“People had been trying to buy the Schaeffer Eye Center for the past 10 years,” he says. “It was time. There was enough initiative on my part that this may be the best route for everybody.”

For some private practice ODs, the once-traditional route of bringing on an associate who would one

day buy the practice is becoming outdated. Instead, the field is experiencing a shift; many younger ODs prefer the freedom of being an employee to the responsibility and cost of owning a practice.

Adding to this equation are a decline in reimbursement rates, the explosion of the telemedicine platform and a surge in electronic health record and staff management demands, all of which leave private practice ODs with even more to consider as they plan ahead and look toward retirement.

“The threats are greater on the profession today,” says Paul Karpecki, OD, of Lexington, KY. “There are a lot more regulations and headaches than there were 15 years ago.”

More and more ODs are finding themselves at a crossroads. Who better to help direct them than their fellow colleagues? This article presents advice a few ODs have to offer on the best path forward when strategically planning for the future and considering PE options.

Biotrue

#31

Dryness is the #1 problem for contact lens wearers¹



The solution? Biotrue[®] MPS contains hyaluronan to help provide up to 20 hours of moisture²

Look at the feedback from contact lens wearers who self-report dryness. They're pretty happy with Biotrue[®] MPS.



96% agree it helps prevent dryness³



97% agree lenses stay moist and comfortable all day long³



97% agree lenses stay comfortable when using digital devices³

No wonder Biotrue[®] is the #1 multi-purpose solution used in more households.* **Recommend Biotrue[®]—for up to 20 hours of moisture.²**

#1

MULTI-PURPOSE SOLUTION*



*Highest household penetration among multi-purpose solutions; IRI Data MULO 52 weeks ending 08/12/18.

REFERENCES: 1. The Multi-sponsors Survey's 2017 study of the US consumer contact lens market, December 2017. 2. In vitro studies evaluated the rate of release of sodium hyaluronate (HA), a conditioning agent in the Biotrue[®] multi-purpose solution, from both conventional and silicone hydrogel contact lenses over a twenty-hour time period. HA was adsorbed on all traditional and silicone hydrogel contact lenses tested upon soaking in the solution overnight. HA is then released from the lenses throughout at least a twenty-hour time period when rinsed with Hank's balanced salt solution at a rate mimicking tear secretions. The in-vitro performance of Biotrue[®] multi-purpose solution suggests that it will provide lens conditioning throughout a twenty-hour time period. 3. Results of an online survey of contact lens wearers with self-reported dryness on a regular basis who completed an evaluation program for Biotrue[®] multi-purpose solution (n=348). Survey results include patients who strongly agreed, agreed, or slightly agreed (on a 6-point agreement scale).

*TM are trademarks of Bausch & Lomb Incorporated or its affiliates. Any other products/brand names and/or logos are trademarks of the respective owner.

©2018 Bausch & Lomb Incorporated, BIO.0130.USA.18

BAUSCH + LOMB
See better. Live better.



PE Made This Doctor's "Legacy Exit" Possible

When private equity came calling, Dr. Glazier was sure of one thing: he had to retain the legacy of his family's second-generation practice. Dr. Glazier had merged his private practice with his father's, and together they had worked hard to build a loyal patient base that they were not willing to give up.

At 51, Dr. Glazier was far from ready to retire. Nonetheless, he was starting to think about an exit strategy, and his young associates could not afford to buy his practice. Based on where he practiced in Maryland, this left him with one unappealing but viable option: sell to a chain, something he wanted to avoid at all costs.

"I did not want to rebrand," he says. "Chains come in and change the software and throw things into the office, and it is hard for staff." Longtime patients also find the transition jarring when they enter a now-unfamiliar practice, and don't always stay. "The main reason people come to see me is because I am an independent. And in the marketplace, there are a lot of what I call 'independent, loyalist patients.' These are people who do not want to go to a chain."

The PE option piqued Dr. Glazier's interest because he knew his practice would, for the most part, remain the same and he could stay on as a clinician and a consultant.

"It sounded like I could remain in my practice and join something bigger," he says. "I call it a 'legacy exit' because the practice name, vision and purpose is kept intact. The look and feel is kept intact. The medical side is improved, and the optical side does not have to be low-end to be profitable."

Dr. Glazier did not know if an opportunity like this would present itself again, so he decided to go for it. He sold his practice on a Friday. The following Monday, he went into his office, and for the first time in his 25-year career, he was just an OD. It has been almost six months, and so far, so good.

"What I have noticed from my new sale now that I am only a clinician is, wow, it is kind of cool to just see patients and have my head fully in the exam lane," he says. "As a business owner, I had one foot out the door during the exam, thinking about my business, and one foot in the room, thinking about the patient."

Dr. Glazier was able to trade in his business responsibilities and focus solely on patient care.

"It took a while for the weight to be lifted off my shoulders, but even on day one, I realized, 'I think I am going to get used to this,'" he says.

Since the sale, Dr. Glazier has taken on a business development role to ensure he plays a part in the continued success of the practice. He says the office now has more resources and runs more efficiently. Best of all, the PE company came through with all the promises they made. From this experience, Dr. Glazier has learned that PE is not bad for private practice optometry like many believe.

"I remember when people thought the autorefractor was a threat to optometry, that it was going to refract everyone and there would be no use for ODs," he says. "These things get blown up, and people tend to see the worst and get scared. Since then, I have seen many of these so-called 'threats' come and go, and optometry has survived, even thrived."

Plan Your Exit Strategy

The day an optometrist decides to open a practice is also the day they should decide how to sell it, says practice management consultant Gary Gerber, OD, of Franklin Lakes, NJ.

"It is Business 101 but not commonly considered in optometry," he says. "The best businesses are built with the owner having a plan of how to leave them."

Under this mindset, ODs have more options and better chances of leaving on their own terms, Dr. Gerber notes. They may be able to sell their practice to another OD or a PE company, but their spectrum of choices only becomes visible when they plan early enough to see it, Dr. Gerber adds.

Alan Glazier, OD, of Rockville, MD, says if an optometrist is considering selling, they need to decide on the best time to sell and take advantage of sale opportunities.

"Positioning yourself to sell can take from five years on up, and that can depend on where you are in the maturity of your practice," he says.

PE as a Major Player

When the time is right, ODs should not shy away from taking the PE route, as it has become much more popular in the last three to five years for several reasons, according to Dr. Gerber.

"I believe it is because the demographics of practitioners have changed; more are looking to sell their practices," he says. "Private

equity has also discovered there is a tremendous upside in the retail optical side of our industry, partially due to us shifting our focus to medical eye care."

The rise of PE buyouts in optometry is also due, in part, to the fact that too much money is sitting on the sidelines with PE funds, causing those companies to look for other areas to invest in that are growing at annual rates of 5% to 7% (e.g., eye care), Dr. Karpecki notes.

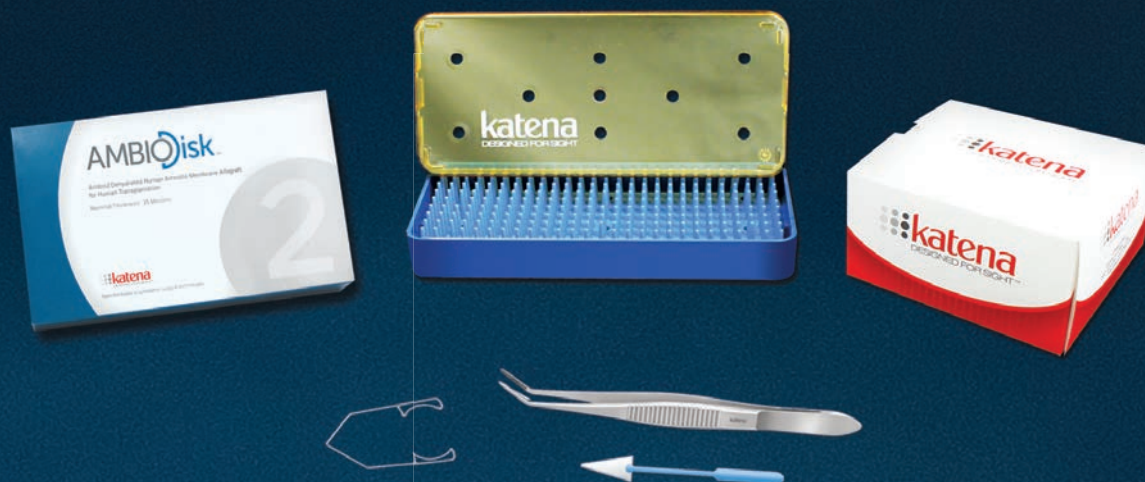"If you look at PE, this has already been done in veterinarian medicine and dentistry," he says. "If you think about eye care, it is not too far from other medical areas."

Fear is another reason for the rise in private equity, says Bill Potter, OD, of Freehold, NJ.

HIT THE DRY EYE MARK WITH AMBIOisk.



Launch your adoption of amniotic membrane
with the **Jump Start Kit**. *Call Katena for details!*



Amniotic membrane is considered an appropriate end stage treatment option to address conditions outlined in the DEWS II step 4 guidelines for severe dry eye.*



800.225.1195 • info@katena.com • www.katena.com

*Physicians may choose to use amniotic membrane at their discretion.
REFERENCE: Craig JP, et al., TFOS DEWS II Report Executive Summary,
The Ocular Surface (2017), <http://dx.doi.org/10.1016/j.jtos.2017.08.003>

KB-Adv-011518-Rev0



“Even successful practices wonder what the future may hold,” he says. “If you take a doctor who is 50 or older, PE offers a chance to take care of their family and retirement. But there are obviously some risks there.”

Practitioners who are selling risk their quality of life and work schedule, but Dr. Potter says if a deal is done properly, the doctor should have nothing to worry about.

Dr. Karpecki calls the rise of PE a “serendipity,” with PE companies looking for good investments at one end and private practitioners who are dealing with additional regulations and staff management demands at the other.

What to Consider When PE Comes Calling

Dr. Gerber says the PE model encompasses buying a practice that presents significant opportunities, building it up and selling it for a profit, all of which could take about five years, he notes.

“If the opportunities exist for PE, they certainly exist for the current doctor/owner, who is usually too close to the practice to see them,” Dr. Gerber says. “So, if doctors have, or can access, business acumen, they can do the same things PE would do by themselves, keep the revenue from the five extra years of working and then sell the practice at a higher multiple. At that point, regardless of the buyer, doctors now have a practice that is worth more and five extra years of income.”

In this scenario, the only downside is that doctors will need to commit more time and resources to their practices rather than to their retirements. Dr. Gerber says this may be worth it for those who are ready to focus more on the business side of their practices.

The timing of a doctor’s deci-

Is PE Right For You?

Dr. Schaeffer offers these tips to help decide whether PE makes sense for *you*:

- Make sure the PE company has a proven and experienced management team and the financial backing to help maintain the business side of the practice and cover all bases.
- Make sure the offer fits *your* needs because PE agreements come in many shapes and sizes, and one size does not fit all.
- Make sure the PE company has the same philosophical outlook about eye care today and in the future and the same vision for your practice as *you* do.
- Make sure the PE company stays true to its word, lives up to your expectations and delivers on its promises.

sion to sell is important, Dr. Gerber says. He recommends doctors first consult with a certified public accountant, tax attorney and financial planner. Generally, the closer a doctor is to retirement, the more sense selling their practice makes, Dr. Gerber adds.

“That being said, not all PE companies are the same, and of course, not all deals are the same,” he says.

For ODs considering a PE option, Dr. Gerber says the decision is no different than any other business deal: you need to do your homework and ask the right experts for help.

A big positive of PE is that offers are often significantly more than young optometry school graduates are willing to pay for buy-ins, Dr. Potter says.

“The corporate resources could completely blow away what the young graduate is capable of,” he says. “The young graduate wants to put up some money and maybe work for a few years and be a partner, whereas a venture capital company may come in with seven figures, and that is hard to turn down.”

Dr. Gerber warns doctors who opt to sell and stay on as employees that they must recognize they are no longer calling the shots and working for themselves; they now have a boss. For this to work, doctors must get along with their new boss and feel comfortable with the direction

the PE company takes their practice, Dr. Gerber says.

Doctors who sell to PE companies and continue to practice, however, do relinquish some control. Dr. Potter admits.


“The doctor who has built up this wonderful private practice, who has been a pioneer, is now going to give some of that up,” he says. “They are going to give up control to the corporate office. Some doctors can do that, and some cannot.”

Those optometrists who are willing to change gears and accommodate new arrangements must be prepared for whatever a private equity company may impose, whether it be different materials, work hours or patient care regulations, Dr. Potter says.

Other doctors, however, may not be comfortable with the adjustments a PE company is interested in making. While some companies may embrace and cultivate the unique aspects of the practices they acquire, others may make changes by incorporating less personalized care or changing the name, Dr. Karpecki notes.

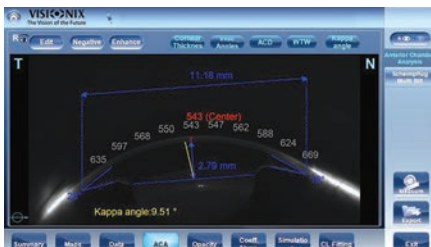
On the flip side, some changes may be welcome. Dr. Karpecki says doctors will often still have a seat at the table and may be able to do away with unwanted duties—such as hiring, firing, paying employees, managing accounts receivable, insurance credentialing, billing and coding—and con-

FOCUS ON EFFICIENT ANTERIOR SEGMENT ANALYSIS



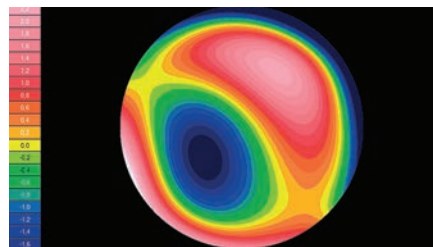
THE POWER OF 3

The Visionix VX130+ is the only instrument combining multi-slit Scheimpflug imaging, Shack-Hartmann wavefront aberrometry and Placido Ring corneal topography in a single instrument. This power gives you the most accurate and efficient anterior segment analysis available, in just 90 seconds, so you can focus on providing the best patient experience.



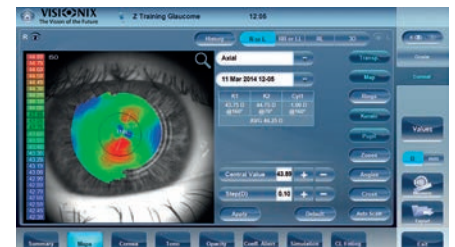SCHEIMPFLUG

- ✓ Assess corneal ectasia and edema
- ✓ Early keratoconus detection on posterior corneal surface
- ✓ Angle kappa for multifocal contact lens fitting



SHACK-HARTMANN

- ✓ Objective over refraction
- ✓ Corneal and internal astigmatism and wavefront error
- ✓ Vision quality simulation



PLACIDO RING

- ✓ Keratoconus
- ✓ Irregular astigmatism
- ✓ Custom contact lens designs

DEMO AT AAO BOOTH #2119

1-800-729-1959 | VISIONIXUSA.COM/VX130



centrate on being doctors.

The key is determining what role you will play if you choose to stay on as an employee rather than an employer.

“You need to consider the question, ‘Can I participate in the future growth of the PE company, or is it just a sale?’” Dr. Karpecki says.

Fear of the Unknown

Some ODs are selling to private equity now, thinking buyers will be more scarce in the future. This trend, however, may not bode well for the future of independent, private practice optometry.

“Doctors think if they sell their practice, they may get more for it than it is worth, but there are always drawbacks and strings attached,” says veteran optometrist

Frank Fontana, of Saint Louis, MO, who at 96, says his lengthy curriculum vitae is a written history of the evolution of private practice. “I have seen more and more unhappy faces after they sell to PE. It is different than selling to an OD or a group practice.”

On the other hand, other health-care modalities were warned that PE would come in and kill the industry, but that has not happened, Dr. Glazier says.

“I think it is just fearmongering and people scared of the unknown, and they tend to want to think of the worst case scenarios,” he says. “But if it was bad for optometry, I would not have done it.”

Dr. Glazier believes PE is valuable for optometry because the ventures create medical positions

and opportunities for students and young ODs—who may otherwise have to take positions at companies that offer free eye exams, are more optical than medical or are run by front office managers rather than practitioners—to practice to the full extent of their education and licensure.

The biggest changes Dr. Schaeffer has seen after selling his practice to a PE company are a new management team, a more effective and efficient software system and a larger focus on training.

“Our doctors are practicing optometry as they always have,” Dr. Schaeffer says. “I do not think they are seeing any difference in the mode of a true primary care practice. That is the key.” ■

PE is a Choice, But Not the First

The disadvantages of a private equity buyout outweighed the advantages for Chad Fleming, OD of Wichita, Kansas, who says the many drawbacks have deterred him from accepting several PE offers. Dr. Fleming shared his views in a recent *Review of Optometric Business* article, “Why (So Far) I’ve Said No to Private Equity,” the content of which is summarized here.¹

While proposed deals are financially attractive upfront, they lack holistic benefits, says Dr. Fleming, who runs a four-location, seven-doctor, 40-staff member practice that has been around for more than 70 years. He adds that he is not just concerned about the financial side; he does not want the quality of patient care to suffer by handing the reins over to a large conglomerate that operates like a chain.

PE Pitches Come in Many Forms

Dr. Fleming has been approached twice to sell to PE. He says offers often highlight how much more money owners could receive for their practices by taking the PE route. This, however, is only true if a practice already has a high profit margin, Dr. Fleming notes.

Dr. Fleming says that some private equity offers may even play up a sale as an opportunity for network marketing or a pyramid structure, meaning you could have the chance to buy out other offices to build a stronger foundation and acquire more money. Other offers may aim to trap sellers by making them feel like PE is their only option when they want to sell, according to Dr. Fleming.

The Cons Outweigh the Pros

Some PE companies prefer having current practice owners stay on to continue running the offices they acquire. Dr. Fleming takes issue with this because if he was asked to occupy a leadership role of any type, he says he would want OD shareholders and himself to be the beneficiaries. He adds that he would also want to make decisions based on what is best for his patients, which may not always be what is best for the company’s bottom line.

By selling to PE, Dr. Fleming says practices lose the profitability of a dividend-paying investment. But the biggest disadvantage is losing the freedom of being your own boss and making your own decisions for the betterment of your practice and your patients.

While selling to PE does not necessarily mean patients will receive lower quality of care, Dr. Fleming says, “it is much more difficult to organically grow the practice through patient care when the leaders of the practice are not personally involved day in and day out.”

Dr. Fleming goes on to note that the only cases in which he would consider selling to PE are if he found a trusted buyer who would treat patients first and profits second or if he was ready to retire and could not find anyone else to buy his practice.

There are doctors who would rather sell their practices for less to fellow ODs in an effort to maintain quality care, according to Dr. Fleming, who believes decisions like these say a lot about a doctor and prove that money is not the only thing that matters.

1. Fleming C. Review of Optometric Business. Why (so far) I’ve said no to private equity. reviewob.com/why-so-far-ive-said-no-to-private-equity/. Accessed September 25, 2018. Published September 19, 2018.

Earn up to
19 CE
Credits*

NEW TECHNOLOGIES
& TREATMENTS IN
2018 EYE CARE



REVIEW OF OPTOMETRY®
EDUCATIONAL MEETINGS OF CLINICAL EXCELLENCE

ARLINGTON, VIRGINIA NOVEMBER 2-4, 2018

Join *Review of Optometry's* New Technologies & Treatments in Eye Care
November 2-4, 2018, at The Westin Arlington Gateway.

The Westin Arlington Gateway

801 N Glebe Road
Arlington, VA 22203
Phone: (703) 717-6200



Program Chair:
Paul Karpecki, OD, FAAO

Faculty:
Doug Devries, OD
Jeffry Gerson, OD
Justin Schweitzer, OD

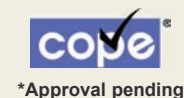A limited number of rooms have been reserved at the rate of **\$159/night**. Please book with the hotel directly by calling the number above. Mention "Review of Optometry" for group rate.

REGISTRATION COST: \$495

REGISTER ONLINE: www.reviewsce.com/arlington2018
EMAIL: reviewmeetings@jhihealth.com or CALL: 866-658-1772

REGISTER ONLINE: WWW.REVIEWSCE.COM/ARLINGTON2018

Administered by
Review of Optometry®



Partially supported by an unrestricted
educational grant from
Alcon



Review of Optometry® partners with Salus University for those ODs who are licensed in states that require university credit. See event website for up-to-date information.



Will Remote Refraction Tarnish Telemedicine?

Competitive efforts risk alienating ODs from a new mode of care that holds much potential for good. **By Mark De Leon, Associate Editor**

Information technology has put medical tools and knowledge in the hands of the public in ways that allow for greater autonomy in healthcare, and the results are decidedly mixed. The current generation is more inquisitive and health-conscious, prioritizing medical care more than the previous ones. This trend could help steer behaviors toward health-promoting habits. But the assimilation of online services into the norms of daily life drives a culture that values convenience, and, in so doing, paints in-person medical care as tedium to be avoided.

Remote refraction services and other self-administered device-based systems are the most obvious example. Understandably, these irk optometrists. But, experts say, it's short-sighted to equate online refraction with the totality of telehealth, a sprawling field that encompasses, in essence, any digital-based delivery of medical care, education or communication—from EHR to AI and everything in between.

Online fulfillment of contact lens orders certainly fares no better. Abuse in this sector disparages clinical care and commodifies medical devices, leaving patients with misperceptions and bad habits that optometrists labor to correct.

Can telehealth's virtues be protected from unsavory forces that don't necessarily have optometrists' best interest at heart? The battle over remote refraction is an early and defining test of optometry's appetite for bringing technology into the doctor-patient relationship.

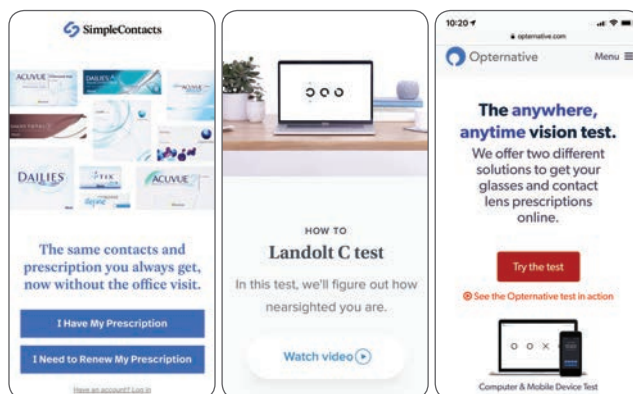
Troubled Beginnings

Optometry soured on telemedicine before the nascent field even had a chance. It's easy to see why. The 2015 launch of Opternative—its brazen name flouting the role of the optometrist—was a warning shot across the bow. Why view it as anything other than a threat to their patients and their practices?

The past year has been an eventful one for Opternative. Last October, the FDA advised it to cease activities because its app constitutes a medical device, which

requires regulatory medical device clearance. Continued marketing is said to violate the Federal Food, Drug and Cosmetic Act.¹

In May, the California Optometric Association asked the state's attorney general to take action against self-administered vision tests that come with significant safety concerns; it also urged investigation into the joint venture of Opternative and 1-800-Contacts.²



Online refraction, prescription renewal and other retail services continue to draw patients away from cautious practitioners. Left to right: SimpleContacts, Prescription Check and Opternative.

MGD can cause the lipid layer to break down.

RESTORE

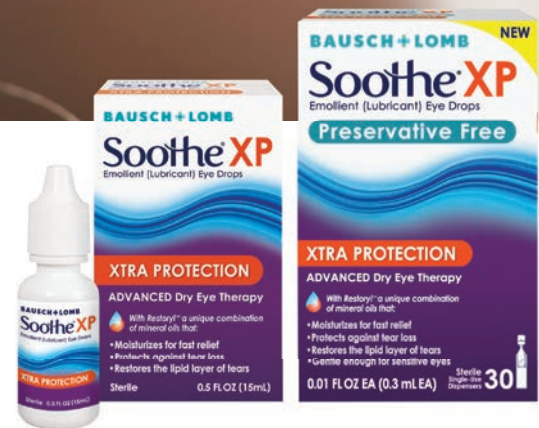SEAL

PROTECT

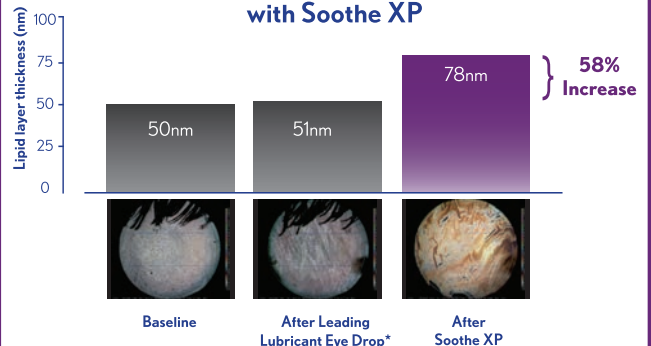
Now Available:
Preservative Free!

Soothe[®] XP helps replenish this layer.

- Up to 86% of patients reporting dry eye symptoms have Meibomian Gland Dysfunction (MGD).¹
- MGD can cause the lipid layer to break down, which may lead to a compromised tear film.²
- Soothe XP contains Restoryl[®] mineral oils that may benefit MGD patients by helping to restore the lipid layer, seal in moisture, and protect against tear loss.



Improved lipid layer thickness after treatment with Soothe XP



¹ Lemp MA et al. Distribution of Aqueous-Deficient and Evaporative Dry Eye in a Clinic-Based Patient Cohort: A Retrospective Study. *Cornea*. 2012; 31:472-478.

² Horwath-Winter J. Prevalence of MGD in a clinical dry eye population. *Acta Ophthalmol* 2011; 89 (s248):2334.

©/TM are trademarks of Bausch & Lomb Incorporated or its affiliates.
© 2018 Bausch & Lomb Incorporated. PN08785_SXP0028_USA.18

*Non-lipid containing eye drop (Systane Ultra)

Lipid layer thickness (LLT) prior to and 15 minutes following a single drop of emollient or non-emollient eye drop in dry eyes with meibomian gland dysfunction. Data are the mean (±SD) LLT based on stroboscopic video color microscope (SVCM) measurements in study eyes (qualifying eye in subjects with only one qualifying eye, or the eye with the lowest LLT at baseline in subjects with two qualifying eyes). p<0.001 paired t-test for the change from baseline. p<0.001, n=35, following a single drop.



In July, Opternative began international expansion, starting in Mexico, with Australia, Canada, Germany, South Africa and the UK also planned.³

In August, the online eye test provider also fanned the flames when it listed ODs on its “Find a Doctor” website without their consent. Concerned doctors reached out to the American Optometric Association (AOA), worried that this would imply an affiliation with Opternative.⁴ The company stated that if it were unable to service a patient because of ineligibility, the locator website could guide that patient to a doctor in their area.

Other entrants into the field also sideline optometrists by marketing directly to consumers or opticians. Among the former are Simple Contacts for contact lens sales and Warby Parker’s Prescription Check, an app that directs customers to its mail order eyeglass business. Among the latter, Smart Vision Labs targets optical shops with inducements of increased eyeglass sales through in-store refractions remotely verified by a doctor, while 2020Now also adds diagnostic tests run by techs with

Defining Terms

The World Health Organization defines *telemedicine* as using information technology to deliver health care services for diagnosis, treatment and prevention and for research and continuing education, particularly when geographical barriers are an obstacle to traditional methods.¹ If the defining feature of telemedicine is provision of care, the concept of *telehealth* goes further, including all telemedicine efforts plus administrative concerns like appointment booking, electronic health records, online training and much more.

An AOA position statement categorizes telehealth as follows:²

Live interactive eye and vision telehealth services use videoconferencing as a core technology. Participants are separated by distance but interact in real-time.

Store-and-forward eye and vision telehealth services refers to methods of providing asynchronous consultations to referring providers or patients.

Eye and vision remote patient monitoring services refer to personal health and medical data collected from an individual in one location via electronic communication, which is then transmitted to a provider in a different location for use in care coordination and related support.

The AOA also states that direct-to-patient applications, including online vision tests and other mobile eye and vision-related applications, must also comply with their requirements for high quality care.

1. World Health Organization. Telemedicine: opportunities and developments in member states: report on the second global survey on eHealth 2009. Geneva: WHO Press. www.who.int/goe/publications/goe_telemedicine_2010.pdf. Accessed October 1, 2018.

2. American Optometric Association. Position statement regarding eye and vision telehealth services. www.aoa.org/Documents/Legal/Position%20Statement%20Regarding%20Eye%20and%20Vision%20Telehealth%20Services%20-%20Referenced%20in%20HOD%20Resolution%201989.pdf. Accessed October 1, 2018.

a doctor available remotely to review results. Yet more players offering variations on the theme include EyeQue, EyeNetra, GlassesOn, Pupil and MyVisionPod.

Proponents say remote vision testing reminds the public of the importance of good vision and expand access to screenings. Detractors worry they diminish the value of in-person eye exams and the importance of eye health.

Can ODs Regain Control?

As new companies emerge and continue to compete for people’s attention online, the efforts to regulate online medical devices have reached certain milestones.

In April 2018, Kentucky Governor Matt Bevin signed the Consumer Protection in Eye Care Act, which allowed telehealth and online eye exams in the state and established provisions to ensure appropriate use. The law requires all patients be at least 18 and complete an in-person eye exam at least once every two years. Technology cannot be used for an initial contact lens Rx.⁵

These safeguards are a start, but are they enough? How do optometrists currently feel as the technology develops and patients become curious about the different services marketed to help direct their healthcare management?

A study conducted in 2017 by Jobson Optical Research found that 66% of optometrists cite online sales and exams as the biggest threat to an optometric practice; alarmingly, it also found that 54% of ODs say that they do not have the tools to prepare them to meet the challenge of remote eye exams.⁶ Most ODs in the survey viewed eye exams as a prime factor in growing their practices as a business. Naturally, they also viewed online sales of optical goods and online eye exams as major challenges to practice success.

Brian Chou, OD, of San Diego, believes the trend currently appeals to those with a strong self-directed mentality. However, he says as technology improves and gains greater acceptance, it will expand to the masses. This may leave patients with insufficient skilled assistance. “If refraction is decoupled from an eye health examination, many patients will neglect or significantly delay the eye health examination,” Dr. Chou says.

Increasingly, patients continue to become aware of products that could accommodate self-tests but prioritize less-vetted information. Dr. Chou is wary and observes that the existing technologies using digital devices are not yet easy, fast nor accurate enough to create new optical prescriptions without an existing one. “That’s why the services place an emphasis on renewing existing and prescriptions for glasses and contact lenses,” says Dr. Chou.

According to Dr. Chou, until the day that phoropter-based refraction is toppled, prescription renewal and

extension will likely get the most play. However, emerging refraction technology may eventually reduce the frequency that patients seek professional eye exams.

How can a practice compete, or co-exist, with the convenience that online services tout?

Cory Collier, OD, of Lakewood Ranch, FL, believes the onus is on practices to provide an exemplary experience that exceeds expectations and reminds patients of the service and satisfaction that comes with in-person interactions. "We have to make it easy to work with our office," which includes using up-to-date technology, making offices "somewhere patients want to interact" and emphasizing "personal care and relationship building that is simply not available online," he explains. "If a patient is taking their time to come to your office, they are looking for an interaction, looking for guidance."

Practice management consultant Gary Gerber, OD, points out that the overall in-office experience is often currently out-of-sync with standards patients derive from their experiences in other realms. "Like it or not, deserved or not, the patient experience in our offices is not only gauged against other healthcare and eye care experiences but also against other retail experiences," Dr. Gerber says. "If the check out process in an office is more complex than an Amazon shopping cart, we've got problems."

Telemedicine, including artificial intelligence-assisted screenings and other tools, will continue to become more common and routine. Optometrists who resist engaging with these trends could give up valuable leverage in determining their appropriate role.

Howard Purcell, OD, former senior vice president of customer development for Essilor of America and president and CEO of the New England College of Optometry, believes that by staying out of the discussion and hoping online refraction will go away, optometrists will disenfranchise themselves from the shaping of the services' future—and their own. "Ultimately, as a profession, we have to try to figure out how to use these tools in a positive way," says Dr. Purcell.

He believes the defensive posture optometrists take in response to online refraction, though often justified, has hindered progress in paving a way for both ODs and companies to collaborate and develop such technology. "I don't believe that the current models are necessarily the answer but I do believe that we should stay as close to these groups as we possibly can, learn what they're doing and identify ways to implement it responsibly," he adds.

Consider a scenario, Dr. Purcell suggests, wherein practitioners could employ online refraction and provide beneficial services to their patients. Suppose a 10-year-old with progressive myopia has a comprehensive eye exam



The Future Is **Now** The Ophthalmic Industry Is Going Digital And for **Good Reason.**

1. Greater Efficiency & Accuracy.
2. Large Return on Investment.
3. Increased Capabilities, Integration and Connectivity.

Focus on the Patient, Not Repetitive Data Entries

- Dual cross cylinder
- Programmable sequences
- Wireless interface with pre-test equipment.

Don't Get Left Behind

IT'S TIME TO GO DIGITAL

Contact Us Today

Veatch Ophthalmic Instruments

www.VOI2020.com | 800.447.7511



and receives a pair of glasses at your office. Six months later, the child loses his glasses at the beach while on vacation and requires a new pair, ideally without curtailing the trip or seeking out a doctor away from home. Dr. Purcell says with appropriate remote refraction technology in practitioners' hands, the boy's family could contact your office for an Rx check to ensure the prescription is still valid, or adjust as needed. This way, you could ensure your patient gets the most accurate prescription for his visual needs that day, not what his prescription was six months ago. "Could an encounter like that be a way we could use some of these technologies to actually improve optometric care?" asks Dr. Purcell.

With appropriate safeguards, remote refraction could become one of those improvements that strengthens the doctor-patient relationship.

See the Big Picture

Although telemedicine has the potential to assist optometry in accomplishing its goals to improve health outcomes, inappropriate uses have more potential to thwart them. Dr. Gerber notes that refraction and telemedicine get put into the same 'convenience' bucket in a patient's brain. Some practitioners "might not like that, but that is our new reality," Dr. Gerber says.

These companies and others who behave similarly are providing partial, arbitrarily segmented care based on a test or a product category without regard to the overall health care needs of the consumer. They market themselves as alternatives to licensed medical providers who use those tests or products within the context of their patients' broader health care needs.⁷

A DeepMind is a Terrible Thing to Waste

London-based AI firm DeepMind, acquired by Google in 2014, has worked with Moorfields Eye Hospital to develop algorithms for a system that can analyze retinal scans and spot symptoms of sight-threatening eye diseases, such as early detection of diabetic retinopathy and age-related macular degeneration. The findings, published in *Nature Medicine*, demonstrate performance in making a referral recommendation that reaches or exceeds that of experts for a range of sight-threatening retinal diseases after training on only 14,884 scans.¹

The AI firm's ultimate objective is to develop and implement a system that can assist the UK's National Health Service with its ever-growing workload.

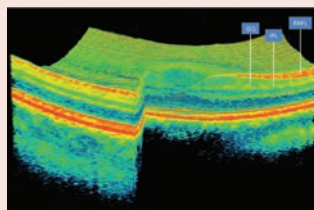


Image: Peter Calabresi, MD

The system can convert a raw OCT scan into a 3D-tissue map to aid treatment decisions.

David Geffen, OD, of San Diego believes it is important for optometrists to separate the battle over online refractions from the larger trend of using telemedicine to help improve care among the patient population.

Dr. Purcell mentions that whenever he lectures on the practice of the future, he has to quickly define what he means when he mentions telemedicine or else he risks losing the crowd. "I find it extremely interesting that we have not done a good enough job of defining what telehealth is," he notes, explaining that it encompasses both professional and consumer components.

The professional side involves education, communication and connection among health care practitioners. In addition to allowing ODs to compare notes with each other, telemedicine gives practitioners access to experts in related fields. "Can I communicate with the world-renowned leader in cornea, retina or glaucoma to help guide my path through an unfamiliar diagnosis and treatment of that patient?" asks Dr. Purcell. This advance goes unremarked by many but radically improves care with only minimal effort or alteration of conventional modes of practice.

Consumer applications of telemedicine are even more vast and disruptive. Along with remote refraction's spotty record, there are more encouraging applications.

Dr. Purcell presents a hypothetical patient interaction over a subconjunctival hemorrhage. A patient calls the office and says their eye is bleeding. Faced with a potential emergency in which response time is precious, the patient could pick up their phone, take a photo of their eye and send it to the office for a quick consult. The doctor could then ask a series of questions to triage the case,

Accurate AI judgments would lead to faster diagnoses and, in theory, treatment that could save patients' vision.²

DeepMind's system consists of two separate networks: a segmentation network that converts the raw optical coherence tomography (OCT) scan data into a 3D tissue map of defined and color-coded slices and a classification network that analyzes the tissue map in order to make decisions about possible diseases and judge the urgency of referral and treatment. The separate networks allow clinicians to check tissue maps and see how the AI came to its final conclusion.

The system needs to pass clinical trials and regulatory approval before it can be used on the frontlines of the NHS. DeepMind also wants to validate its results with further testing and refinements to the underlying algorithms, which could take another three to five years.


1. De Faux J, Ledsam JR, Romero-Paredes B, et al. Clinically applicable deep learning for diagnosis and referral in retinal disease. *Nat Med*. 2018; 24:1342-1350

2. Ghosh S. Google's DeepMind AI can accurately detect 50 types of eye disease just by looking at scans. *Business Insider*. www.businessinsider.com/google-deepmind-ai-detects-eye-disease-2018-8. Accessed October 1, 2018.



Looking Back and Moving Forward

Optometrists have always been a little wary of disruptive technology. In the March 1978 issue, *Review of Optometry* published results of a survey on readers' perception of automation as a threat—autorefraction in particular. A third of over 250 optometrists who responded opposed greater use of automation in optometry and vision care. Nevertheless, "the majority were willing to admit that automation may be the only way to handle future patient loads." Those opposing automation cited its potential to erode the doctor/patient relationship as a primary reason. They were also concerned with the idea of relying wholly on computer results without checking them further.



Overall, the survey did show that ODs were willing to give new technology a fighting chance—if it delivered on its promises. Interestingly, the survey may provide some guidance regarding the comfort level of today's ODs amid modern worries over telemedicine. When polled about their approach to buying a new instrument, doctors in 1978 looked first for quality and whether the instrument can do what it was designed for.

The autorefractor stopped being an object of fear and derision once practitioners had hands-on experience with it and confidence in its merits. It didn't obsolete the doctor; rather, it extended the clinic's capabilities and efficiencies.

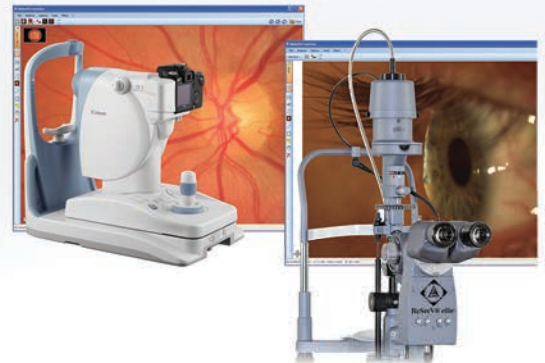
Blake B. Automation: will it click with today's O.D.? *Review of Optometry*, 1978:65-68.

based on patient history and relevant health factors. Over the phone, the doctor could tell the patient exactly what to do before they are able to see them in their office in the next two to three days unless something changes.

"Are we comfortable with a scenario like that?" Dr. Purcell asks. "That needs to come from the profession and I fear that today some of those decisions are being made without our input."

One company following such a model is Eyecare Live, based in California and founded by optometrists. It aims to enhance relationships between doctors and patients and improve collaboration with other health professionals. The company provides HIPAA-compliant communication services for patients with chronic eye conditions, contact lens follow up, and support and triage non-urgent conditions remotely via technology.

"Our present system can enhance the level of care and give you a support system of a network of doctors and professionals that will help you and simplify the



Imaging Solutions:

Serve Your Patients Further

**ReSeeVit: The latest technology,
Built specifically for ophthalmic
professionals**

Leaders of Our Industry

Choose from our suite of imaging solutions, including:

- Anterior segment imaging
- Endothelium cell imaging
- Corneal topography
- Retinal imaging

**Imaging Solutions:
Providing For Your Patients.**

Don't Get Left Behind

IT'S TIME TO GO DIGITAL

Contact Us Today

Veatch Ophthalmic Instruments

www.VOI2020.com | 800.447.7511



process,” says Paul Super, OD, of Los Angeles, a cofounder of Eyecare Live. The OD would be extending the boundaries of the care they provide in the office.

Remote screenings of patients unable to travel is another fertile area for growth. In recent years, communication networks among providers have allowed, for instance, pediatric retina specialists—who are few in number—to screen newborns with retinopathy of prematurity while they’re still in the neonatal intensive care unit. Addressing the epidemic of diabetic retinopathy among rural populations is another instance where telemedicine technology is bringing the clinic to the patient when the converse simply isn’t possible.

It seems inevitable that artificial intelligence will play a role in disease screening in ways that could bring more patients under the umbrella of care, simplify the process of monitoring existing patients, or both (*see, “A Deep Mind is a Terrible Thing to Waste”).* Telehealth provider 20/20Now recently announced incorporation of retinal AI into its ocular exams to enhance images and allow for early detection of disease like diabetic retinopathy.⁸

A Jazz Age Vision, Finally Realized

Technology may finally be bringing telemedicine to doctors’ doorsteps, but the idea itself is almost a century old. Hugo Gernsback, a pioneer of radio and science publishing—the Hugo award for outstanding science fiction is named after him—first laid out a concept for it in a 1925 article, “The Radio Teledactyl,” published in his magazine *Science and Invention*.

Gernsback, pondering the science of medicine 50 years hence, envisioned a device that doctors would use to tend to their patients remotely in the year 1975.¹ The physician of the future would visually examine their patient through a viewscreen while using remote controls and radio waves to manipulate robotic arms (i.e., teledactyls) that had been previously set up at the patient’s bedside. The arms would be sensitive to sound and heat and also could relay that information as well as any tactile response back to the doctor’s controls. Gernsback believed that a good doctor of the future would be able to diagnose a range of ailments using the instrument.²

Commenting on the society and culture of 1925, Gernsback viewed telephone, radio and television as tools for solving innumerable problems. “As we progress, we find our duties are multiplied and we have less and less time to transport our physical bodies in order to transact business, to amuse ourselves and so on,” he observed in the article. In particular, Gernsback noted that doctors in that distant year of 1975 would be too busy to leave their office and visit their patients or, conversely, the patients would not be able to visit the doctor.

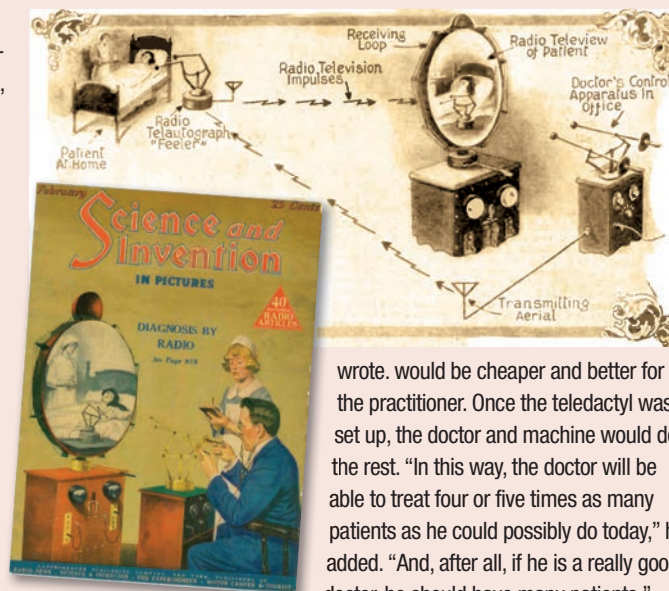
Sending the instrument over to the patient’s location, Gernsback

Talk it Out

Maybe it comes down to comfort level and familiarity. Still, practitioners remain determined to uphold patient safety and quality of care regardless of the increase in patients who seek a more virtual and convenient experience for all their visits. That day hasn’t come, as not all cases are yet amenable to a telehealth model.

The use of telemedicine as it now exists may be appropriate for basic interactions (nonemergency triage), standard data acquisition, confirming therapeutic results or disease stability and notifying clinicians of changes in chronic conditions. Telemedicine would not be appropriate for initial diagnosis as a replacement for in-person visits and exams.⁷

Still, there are optometrists out there like Dr. Purcell who believe that having this telemedicine conversation is time well-spent. “I think the first thing we really have to come to grips with is where we are comfortable using remote technology to assist—but not usurp—our role as doctors in patient intake, assessment, triage and management,” Dr. Purcell says. Not every application will be



wrote. would be cheaper and better for the practitioner. Once the teledactyl was set up, the doctor and machine would do the rest. “In this way, the doctor will be able to treat four or five times as many patients as he could possibly do today,” he added. “And, after all, if he is a really good doctor, he should have many patients.”

One year after this article appeared, Hugo Gernsback launched *Amazing Stories*, the first science fiction magazine (and the inspiration for two Steven Spielberg TV shows of the same name). Gernsback continued to be a lifelong advocate for both science fact and fiction, often using fictional concepts to help inventors and the public envision a better life that might await them.

1. Novak M. Telemedicine predicted in 1925. *Smithsonian*. Published March 14, 2012. www.smithsonianmag.com/history/telemedicine-predicted-in-1925-124140942/?no-ist. Accessed October 1, 2018.

2. Gernsback H. The radio teledactyl. *Science and Innovation*. 1925;(142):978,1036.

appropriate, but it's incumbent on the profession to work through it and find its best uses.

Dr. Chou agrees that no one can escape having that realization. "There is an increasing digitization of eye care—movement toward data-driven diagnosis instead of doctor-driven diagnosis," says Dr. Chou. "It's happening elsewhere in healthcare as well, not just with our field."

Dr. Super also believes that this change will eventually involve all of medicine regardless of one's interest in and aptitude for technology. "The consumer is demanding certain things, and we're trying to ensure that we protect patients by modeling our efforts in their best interest, not in ours, so that we can provide the best level of care."

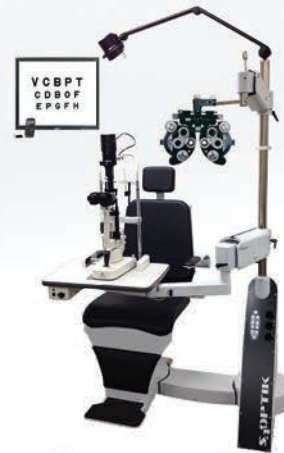The drive for telemedicine adds a consumer-driven element that has to be reckoned with. "Clinical accuracy aside—and not to minimize that very important aspect—if consumers want it, it will happen," Dr. Gerber says.

Dr. Purcell remains optimistic. "I see artificial intelligence, virtual reality, 3D printing and telemedicine all falling into a very similar category of things that will change the profession in a positive way, but without our evaluation or ability to guide that path to some extent, the risks will be greater," Dr. Purcell says.

Dr. Gerber agrees that practitioners should remain engaged in the process. "Doctors would be smart to stay on top of what's coming and find ways to embrace it instead of trying to avoid it," he says. Viewing them as a threat rather than an opportunity "is the heart of the problem," he says. "The smart play for ODs is to keep their minds open and find ways to leverage the buzz, and when they're personally, clinically happy with the technology, to use the tech in their own practices."

Dr. Geffen agrees with this call to action. "Instead of spending our time complaining about this competitive environment, we need to take what is good and enhance it," he says. ■

1. Food and Drug Administration. Inspections, compliance, enforcement, and criminal investigations. Opternative Inc. warning letter. Issued October 30, 2017. www.fda.gov/iceci/enforcementactions/warningletters/2017/ucm600029.htm. Accessed October 1, 2018.
 2. California Optometric Association. California optometrists caution patients about unapproved, online 'vision tests' after FDA warning. COAVision. www.coavision.org/files/05%2009%2018%20Opternative%20Release%20FINAL.pdf. Accessed October 1, 2018.
 3. Opternative announces international expansion [press release]. Chicago, IL: Newswire; Published July 19, 2018. www.newswire.com/news/opternative-announces-international-expansion-20568242. Accessed October 1, 2018.
 4. Vision Monday. Opternative's doctor locator tool draws fire from some ODs. Published August 13, 2018. www.visionmonday.com/latest-news/article/opternatives-doctor-locator-tool-draws-fire-from-some-ods. Accessed October 1, 2018.
 5. Kentucky Legislative Research Commission. 18RS HB 191. www.lrc.ky.gov/record/18RS/HB191.htm. Accessed October 1, 2018.
 6. Wright, M. Defining the future of optometry. Oral presentation at: American Optometric Association Optometry's Meeting, June 2018; Denver, CO. reviewob.com/wp-content/uploads/2017/10/6-13-18futurepdf.pdf. Accessed October 1, 2018.
 7. Petito GT. The evolution of telemedicine in eye care. *Adv Ophthalmol Optom*. 2017;2(1):1-14.
 8. 20/20Now implements retinal AI in all of its ocular telehealth exams. 20/20NOW. Published September 18, 2018. www.for2020now.com/20-20now-incorporates-retinal-ai-into-its-ocular-telehealth-exam-to-provide-early-diagnosis-of-diabetic-retinopathy. Accessed October 5, 2018.



Exam Lane Packages

*Opening a new practice?
Looking to upgrade your equipment?*

**Veatch exam lanes are an investment
in your patients, your equipment
and your business.**

Bundled Packages: Save Time and Money

- Visual acuity system
- Manual or Digital Refractor
- Exam chair & stand

The Quality Tools You Need At A Price You Can Afford

Don't Get Left Behind

IT'S TIME TO GO DIGITAL

Contact Us Today

Veatch Ophthalmic Instruments

www.VOI2020.com | 800.447.7511



The Why and How of Hospital Privileges

Don't shy away from this patient care—and practice boosting—opportunity.

By Glenn S. Corbin, OD, and Amanda S. Legge, OD

Health care continues to trend toward outpatient services and specialty inpatient consults to best serve patients with more efficient diagnoses and treatments. By adding optometry to the list of outpatient services, both hospital physicians and patients benefit from the continuity of medical eye care, networking and referral opportunities; they also benefit from the specialized ocular knowledge that most general hospitalists and emergency department (ED) physicians often lack confidence in.

Unfortunately, few ODs go through the hassle of obtaining hospital privileges to serve this patient population—and miss out on a significant practice builder. These tips, and our practice's unique experience, can prepare you to delve into hospital-based care and boost patient loyalty and your practice's bottom line.

ODs in Hospitals: A Good Fit

Private optometrists and optometry practices have a lot to gain from hospital privileges. Optometrists



Drs. Legge (left) and Corbin (right) are a welcome sight at Penn State Health St. Joseph Medical Center, where they provide much-needed eye care to ED and admitted patients alike.

perform nearly 70% of the primary eye care examinations in the United States, making us the most appropriate eye care provider for this setting.¹ Most ED or inpatient cases for which a hospital seeks an eye care physician consult include problems optometrists see routinely in private practice: flashes and floaters, diplopia, corneal foreign bodies

and abrasions, headaches, eye pain and irritation, blurred vision and loss of vision, to name only a few. In our practice's experience, approximately 98% of cases we consult on are within optometry's scope of practice. Cases that we cannot manage often involve ocular trauma for which sutures or surgeries are necessary. Hospital privileges increase patient access to your practice and help broaden your scope of practice to include significantly more medical eye emergencies, urgencies and examinations. Here are just a few of the benefits our practice has enjoyed:

Revenue booster. The most apparent benefit to having hospital privileges is an increase in patient census. As consulting optometrists, we bill insurances directly for the services we provide in the ED or for inpatient consults. Each patient we see contributes direct revenue to our practice. However, we do not participate with every medical insurance that the hospital does, so in some cases we write off the charges as a courtesy because of our hospital staff status.



ADVANCING OCULAR HEALTH



eyevance pharmaceuticals

We share your vision of optimal ocular health

From impactful therapies that enhance everyday lives to innovative products that meet unique needs, Eyevance is committed to providing better ophthalmic care.



Does your vision align with ours?

To learn more about us and our company's vision, please visit us at **Academy 2018 San Antonio-Booth #1020.**

eyevance.com



We provide care in the ED when contacted outside of our normal office hours, and the ED sends patients to our office during regular hours. Furthermore, many hospitals have urgent care facilities that also act as direct sources of referral for our practice, as urgent care providers almost always refer to a hospital-credentialed doctor when specialty referrals are required. Because many of these patients have chronic eye conditions, the number of exams per year per patient increases, as does in-office diagnostic testing frequency.

Patients seeking urgent care greatly appreciate our services, whether provided after hours or during an inpatient consult. Often, our prompt response to an inpatient consult request leads to a quicker discharge. Taking care of these patients in desperate need builds an immediate doctor-patient relationship, and we estimate more than 70% of these patients return to us for routine care and become loyal to our practice.

Profession elevator. An unexpected benefit was the enhanced perception of optometry within our local medical community. We had some initial hesitation about how our directives would be followed by hospital physicians educated alongside ophthalmologists. Luckily, we have yet to encounter a case where the hospitalist or ED physician knows more about an eye condition than we do. It has been an excellent opportunity to educate the doctors, hospital staff and medical and nursing students at each patient encounter. With limited ophthalmic knowledge, they appreciate our services and immediate response to their patient's needs. Because we have been so well received, we now have regular rotations of med students and residents, as well as physicians asking to observe and learn from us during clinical encounters.

As we continue to gain respect at the hospital, a significant percentage of the doctors, nurses and staff have become patients at our practice. This has furthered our opportunity to educate the medical community about optometry by exposing them to our advanced diagnostic instruments and specialty testing and services that are not visible in the hospital setting. In addition to gaining new patients, we have become widely recognized in the medical community as an integral part of the health care team. Our names and practice information are listed as Accountable Care Organization (ACO) affiliates and Allied Professional Staff on the hospital website and in advertisements, which provides additional avenues for new patients to find our practice.

Procedural enhancements. Once we became affiliated with the hospital, we quickly recognized opportunities to improve the overall quality of care for patients. The most important initial change we helped implement was to the hospital's surgical procedure protocol. Because we were seeing so many inpatient emergencies for exposure keratitis after lengthy surgical procedures, we helped the Dept. of Anesthesia modify the pre-surgical protocol to include the application of ophthalmic ointment for any patient undergoing general anesthesia. We also helped educate the medical staff on lagophthalmos during prolonged procedures and the importance of taping the eyelids shut if necessary.

Since initiating these changes, we rarely encounter patients with eye pain and blurred vision after recovering from a general anesthesia procedure.

Improved comanagement. Our personal interactions with general physicians and specialists have created an easy inter-office referral system for rheumatology, neurology, infectious disease, endocrinology, primary care and any number of other specialties. We provide prompt appointments for patients they refer to us with well-received reports and communication. Hospital privileges also give us easy access to our own patients who need hospital admission, as well as the ability to continue to comanage their care while they are there. We can place STAT orders and view results of imaging, labs and other physician reports through remote access to the hospital's electronic medical records.

Our Story

In 2007, the CEO of our hospital was a patient at our practice. He expressed concern over not having reliable eye care physicians for emergency calls and inpatient consults because the local ophthalmologists were already providing on-call care for another hospital.

We quickly recognized the opportunity for optometry and our practice and began evaluating the hospital bylaws, which categorize and specifically define staff sections or levels. Each type of physician

Beware the Pitfalls

A few obstacles and perceived downsides exist to obtaining hospital privileges. It may be challenging to achieve if your local hospital does not have the bylaws in place for optometry. Without these in place, the credentialing process may seem intimidating, but it is not impossible and is well worth the investment.

The two most obvious drawbacks once your practice has hospital privileges include: (1) the need to provide on-call care after hours and on weekends and (2) writing off examinations or procedures for insurances the hospital participates with that you don't. But, as our practice demonstrates, the pros greatly outweigh the cons.

ONLY

AzaSITE[®]

(azithromycin ophthalmic solution) 1%

Now Available

If you're attending
AAO 2018, visit us at
**AKORN BOOTH
#3700**





must be defined and included in a specific category to have privileges. Our local hospital did not include credentialing optometrists for staff privileges. This then required us, along with a sponsor, to request a bylaw amendment to allow optometrists to seek hospital privileges—a process that took us approximately nine months.² Then, we were eligible to apply for comprehensive privileges consistent with our full scope of optometric practice.

The application process can be time consuming and requires submission of your CV, licenses and references. Our local hospital has a Section of Ophthalmology under the Dept. of Surgery, and optometry fell under the category of allied health professional staff within the Dept. of Surgery, similar to ophthalmology. Thus, we filed formal applications for each of the doctors at our practice to obtain privileges. The change to the hospital bylaws to include optometry was not specific to our practice, and any OD in the area

Hospital Bylaw Options

Several possible categories of hospital privileges exist. *Medical staff* includes full voting privileges and the ability to serve as an officer on certain committees. Slightly more restricting options include *courtesy* and *consulting privileges*, the definitions of which vary depending on the hospital but are generally similar to one another.

Optometrists can also consider becoming a member of the *allied health professional staff*. However, this group generally needs to act under the supervision of another provider whereas optometrists are independently licensed and provide independent patient care. This is often the easiest category to change in a hospital's bylaws to include optometry, and as long as the bylaws allow optometrists to practice at full scope, you can act independently without supervision. The important part is becoming appointed to the hospital with your full scope of practice, not necessarily the category under which optometry falls. The disadvantages of the allied health professional category are that it typically does not have direct admitting or discharge privileges and is limited in its choice of committees.

who desired to obtain hospital privileges could apply.

Once we were approved as hospital affiliates, we were assigned a physician liaison who educated us on hospital procedures and protocols, gave us a tour of the facilities and provided ongoing assistance.

The first few times we were called to the ED to see patients were challenging because we hadn't worked in direct coordination with the full team in a hospital setting. To our surprise, we were welcomed by the physicians and staff without bias. The ED physicians had limited knowledge of ocular disease and were even less confident in managing eye emergencies—and they welcomed our expertise. Initially, the hospital staff often referred to us as ophthalmologists, but with the right education, everyone has come to recognize and respect us as optometrists—a significant advancement for our profession.

Recognizing our hard work, dedication and commitment to the hospital, the Board of Directors approved a Section of Optometry, also under the Department of Surgery, which not only recognizes our profession independent of ophthalmology, but also differentiates us as a unique provider among all other specialists.

Mastering the Hospital Consult

We are called upon for patient care in a variety of ways. We are consulted for inpatient care



As part of their hospital privileges, Drs. Legge and Corbin have access to the hospital's EMR, which makes it easy to view imaging and lab results, as well as other physician reports.

if a patient has a visual or ocular complaint upon admission or develops one during their hospital stay. We are consulted if the hospitalist has any concern for an underlying ocular or neuro-ophthalmic diagnosis or if a patient is diagnosed with a systemic fungal or bacterial infection that might lead to endophthalmitis.

We typically make a phone call immediately after being consulted and respond in less than 24 hours to see the patient. If ED physicians have an eye emergency they are comfortable initiating treatment for, they will schedule the patient to see us the following day in our office for follow-up care. If they are not comfortable treating, they call us for a phone consult to discuss the case. They then initiate treatment, refer the patient to our office during working hours or request that we see the patient immediately—meaning off-hour and weekend ED visits.

Hospital-owned urgent care centers use the same referral protocols as the hospital itself, and the private practicing doctors all have referral forms to fax to our practice that indicate the level of urgency to help us directly contact their patients to schedule.

Once we obtained privileges, we also helped the hospital purchase

the basic equipment we need such as a slit lamp, Goldmann tonometer and minor surgical instruments for foreign body removal. We bring our own handheld equipment, indirect lenses, bandage contact lenses or other portable instruments as needed. In the hospital setting, our care is comprehensive and includes performing minor procedures, prescribing medications for ocular infection or inflammation, coordinating care to prescribe intravenous steroids, antibiotics or acetazolamide and recommending and coordinating patient admission to the hospital. If a patient needs surgical intervention, we coordinate with ophthalmology.

Pleasant Practice Surprises

As our relationship has grown, hospital staff have asked that we become more involved with their family practice resident and medical student training programs. We now provide lectures for the residents on topics relevant to primary and emergency eye care, have residents and students shadow us when we come to the hospital to examine patients and have residents and students come to our office to shadow our specialty services.

We also coordinate with the hospital to host a free monthly diabetic eye clinic for patients who are uninsured or lack transportation. We also educate diabetes patients about ocular risks as part of the hospital's diabetes education program.

We have garnered numerous referral sources from hospital-owned facilities, as well as from hospital physicians in private practice, including internal medicine, family practice, rheumatology and neurology referrals. An added bonus is our access to ACOs and other affiliations through the hospital.

Obtaining optometric privileges in a hospital setting is mutually ben-

eficial to all parties involved—the hospital, you, your practice and the patients. Both obvious and unpredictable benefits of hospital privileges exist—with few negatives. Our practice is booming, in part because of our hospital affiliation, and yours can be too. ■

Dr. Corbin is in private practice in Wyomissing, PA, and is chief of the

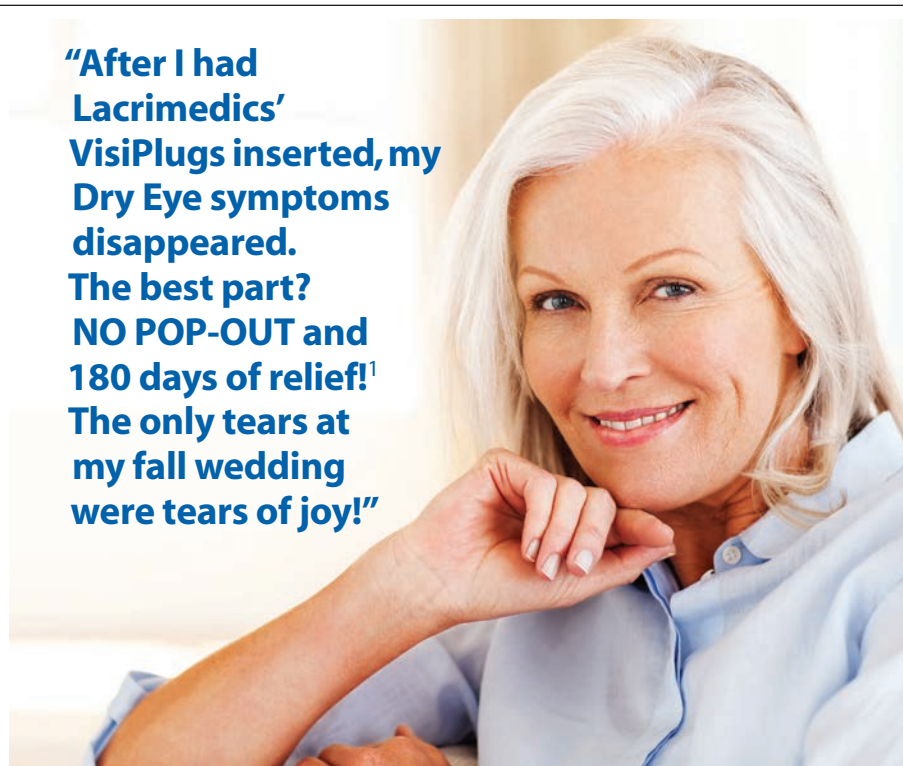Section of Optometry at the Penn State Health St. Joseph Medical Center.

Dr. Legge is in private practice in Wyomissing, PA.

1. American Optometric Association. The State of the Optometric Profession: 2013. www.aoa.org/Documents/news/state_of_optometry.pdf. Accessed August 8, 2018.

2. American Optometric Association. Optometric Hospital Privileges Manual. 2016. <http://aoa.uberflip.com/1/612738-aoa-hospital-privileges-manual-2015>. Accessed August 8, 2018.

**“After I had
Lacrimedics’
VisiPlugs inserted, my
Dry Eye symptoms
disappeared.
The best part?
NO POP-OUT and
180 days of relief!¹
The only tears at
my fall wedding
were tears of joy!”**



**VisiPlug®: A visibly better plug to treat Dry Eye with
no reportable instances since market release in 2003!**

Available in
both 0.4mm
and
0.5mm

To order call 1-800-367-8327
Learn more at www.lacrimedics.com



Lacrimedics®

(800) 367-8327

E-mail: info@lacrimedics.com

www.lacrimedics.com

2620 Williamson Place, Ste. 113, DuPont, WA 98327

¹Dramatization. Not a real patient. Actual results may vary. ©2018 Lacrimedics, Inc.

Glaucoma: From Landmark Studies to Modern-day Care

While it's important to remember where you come from, it's also important to embrace where you're going.

By Jillian Janes, OD, and Christopher Kruthoff, OD

Glaucoma management requires optometrists stay up-to-date on the latest diagnostic tools, protocols and treatment regimens. New medications, technologies and surgical interventions are quickly becoming integral to the care paradigm.

While clinicians cannot forget the evidence-based findings that have shaped how we diagnose, treat and follow glaucoma patients, many may question the relevance of the landmark studies with the advent of new treatments and technologies. Would the studies have different treatment recommendations if topical rho-kinase inhibitors and nitric oxide (NO)-donating molecules had been available? Would opti-

cal coherence tomography (OCT) have changed the outcomes? And, with the boom in minimally invasive glaucoma surgeries (MIGS), is information about filtration surgery even significant? This article revisits several landmark studies and incorporates today's advances to answer these kinds of questions.

The Ocular Hypertension Treatment Study (OHTS)

This study from 2002 is one of the first to highlight central corneal thickness (CCT) as a significant structural risk factor for glaucoma.¹ The study evaluated 1,636 participants with ocular hypertension, defined as an intraocular pressure (IOP) of 24mm Hg to 32mm Hg

in one eye and 21mm Hg to 34mm Hg in the other and no visual field (VF) loss or glaucomatous optic nerve damage.² The study's main objectives were to determine the effectiveness of topical treatment in preventing the onset of primary open-angle glaucoma (POAG) in patients with ocular hypertension and to establish baseline demographic and clinical risk factors for the development of POAG in patients with ocular hypertension.²

After five years, researchers found that the incidence of POAG development was 4.4% in the treated group and 9.5% in the untreated group.² IOP was reduced by 22.5% in the treated group and only 4% in the untreated group,

DAILIES TOTAL1® MULTIFOCAL CONTACT LENSES

DESIGNED FOR SUCCESS



Katie Gilbert-Spear, OD, MPH

Sight and Sun Eyeworks, Pensacola, FL

Dr. Gilbert-Spear was compensated by Alcon for her participation in this testimonial

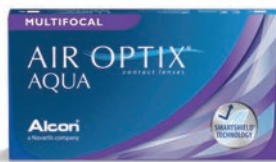Helping patients experience the benefits of contact lenses throughout their lives can be an important building block for practice success.^{1,2} Unfortunately, for patients in their 40s and beyond, their growing near vision correction needs combined with the challenges of monovision or early-generation multifocal contact lenses can lead to a greater dependence on glasses, and—eventually—to contact lens dropout.³ Today's presbyopes are active, image-conscious and have demanding lives.^{4,5} Many of them have grown to love wearing contact lenses, and so want excellent vision without depending on glasses—but they may not be aware of their options. The good news is that DAILIES TOTAL1® Multifocal contact lenses make it easier than ever to meet presbyopic patients' unique needs.

DAILIES TOTAL1® Multifocal contact lenses offer the flexibility and convenience of a daily disposable wear schedule,^{6,7} an innovative multifocal design for seamless vision,^{8,10} and Alcon's unique Water Gradient and SmartTears® Technologies for truly remarkable comfort.¹¹ Also, Alcon's simple 2-step fitting process makes fitting DAILIES TOTAL1® Multifocal lenses (and all Alcon multifocal lenses) easy,^{12,13} so I can get patients the right fit without taking up a large amount of chair time, helping the efficiency of my practice. Data show 80% fit success with a single lens per eye, and 96% success with two lenses or fewer per eye, when the Alcon multifocal contact lens fitting guide is followed.^{12,13} In addition, my contact lens-wearing patients return for exams more frequently than those who wear only glasses, meaning more opportunities to educate them and provide comprehensive care.

Embracing DAILIES TOTAL1® Multifocal contact lenses has been key to differentiating my practice

Beyond offering technologically advanced multifocal lenses, there are several ways that my staff and I can help position patients for success with DAILIES TOTAL1® Multifocal contact lenses. First, we start the conversation early. I begin discussing presbyopia with my patients while they are in their 30s, letting them know that—when the time comes—we can meet their vision and lifestyle needs with multifocal contact lenses. Then, when presbyopia does emerge, I am quick to share the benefits of DAILIES TOTAL1® Multifocal contact lenses. It is also imperative that I explain to patients beginning their trial with DAILIES TOTAL1® Multifocal contact lenses that a short adaptation period will be needed. My office staff also have an important role in setting patients up for success, by collecting information about presbyopic patients' visual expectations and lifestyle demands. For example, my staff ask patients what, if anything, they would change about their current vision correction. This open-ended questioning helps identify patients' needs, and provides an opening for my staff to introduce the exciting opportunity that DAILIES TOTAL1® Multifocal contact lenses represent. Active engagement between staff and patients helps make my discussions with them more efficient. In many cases, patients have decided that they want to try DAILIES TOTAL1® before even walking into the exam room! Once they are properly positioned for success, even my more skeptical patients are amazed by their experience with DAILIES TOTAL1® Multifocal contact lenses.

Embracing DAILIES TOTAL1® Multifocal lenses has been key to differentiating my practice, and one of my priorities is to give as many presbyopic patients as possible an opportunity to enjoy them. In my experience, a focus on active engagement and patient education—in addition to a commitment to offering DAILIES TOTAL1® Multifocal contact lenses—can be an important driver of success for today's practitioners.



References 1. Rumpakis J. New data on contact lens dropouts: an international perspective. *Rev Optom*. 2010;147:37-42. 2. Anderson D. Growth opportunity: move patients into multifocal CLs. *Rev Optom Bus*. June 19, 2017. 3. Dzurinko V, Quinn TG, Woods J. Today's multifocal opportunity. *Contact Lens Spectrum*. February 2012:2-3. 4. Alcon data on file, 2015. Age Perception Impact Survey of 1,067 US adults. 5. Alcon data on file, 2013. 6. Cho P, Boost MV. Daily disposable lenses: the better alternative. *Contact Lens Anterior Eye*. 2013;36:4-12. 7. Efron N, Morgan PB, Helland M, et al. Daily disposable contact lens prescribing around the world. *Contact Lens Anterior Eye*. 2010;33:225-227. 8. Alcon data on file, 2008. 9. Alcon data on file, 2016. 10. Lemp J, Kern J. Alcon multifocal contact lenses for presbyopia correction. Presented at the Canadian Association of Optometrists Congress, June 28-30, 2017. Ottawa, ON. 11. Merchea M, Akerman DH, Mathew J, Mack C. Patient and ECP satisfaction in the United States with a novel water gradient daily disposable multifocal contact lens. Presented at the annual meeting of the American Optometric Association, June 21-26, 2017, Washington, DC. 12. Alcon data on file, 2017. 13. Bauman E, Lemp J, Kern J. Material effect on multifocal contact lens fitting of lenses of the same optical design with the same fitting guide. Presented at the British Contact Lens Association Clinical Conference & Exhibition, June 9-11, 2017. Liverpool, UK.

Important information for AIR OPTIX® AQUA Multifocal (lotrafilcon B) contact lenses: For daily wear or extended wear up to 6 nights for near/far-sightedness and/or presbyopia. Risk of serious eye problems (i.e., corneal ulcer) is greater for extended wear. In rare cases, loss of vision may result. Side effects like discomfort, mild burning or stinging may occur.

See product instructions for complete wear, care and safety information. 

© 2018 Novartis 03/18 US-DTM-18-E0272

Our passion is to help your patients see, look and feel their best.



Sponsored by

Alcon A Novartis Division

they note.² The baseline factors associated with a higher risk of developing POAG include older age, elevated IOP, a larger vertical cup-to-disc (C/D) ratio and a thinner CCT.¹ Being of African descent was associated with a 59% increased risk of developing POAG; however, the study did not find this to be statistically significant.¹ The researchers did note that, at baseline, black participants had a larger mean vertical C/D ratio and a thinner mean CCT compared with other participants.¹

The study concludes that the risk of POAG development in ocular hypertensive patients is reduced by almost 50% at five years when treatment is initiated, and some individuals have a higher risk than others.² Risk assessment is critical in deciding which patients need to be offered treatment.

In a 13-year follow up to OHTS, medication was provided to the

original observation group, and their incidence of POAG reached that of the original medication group—suggesting there may not be a significant detriment in delaying treatment in those at lower risk.³

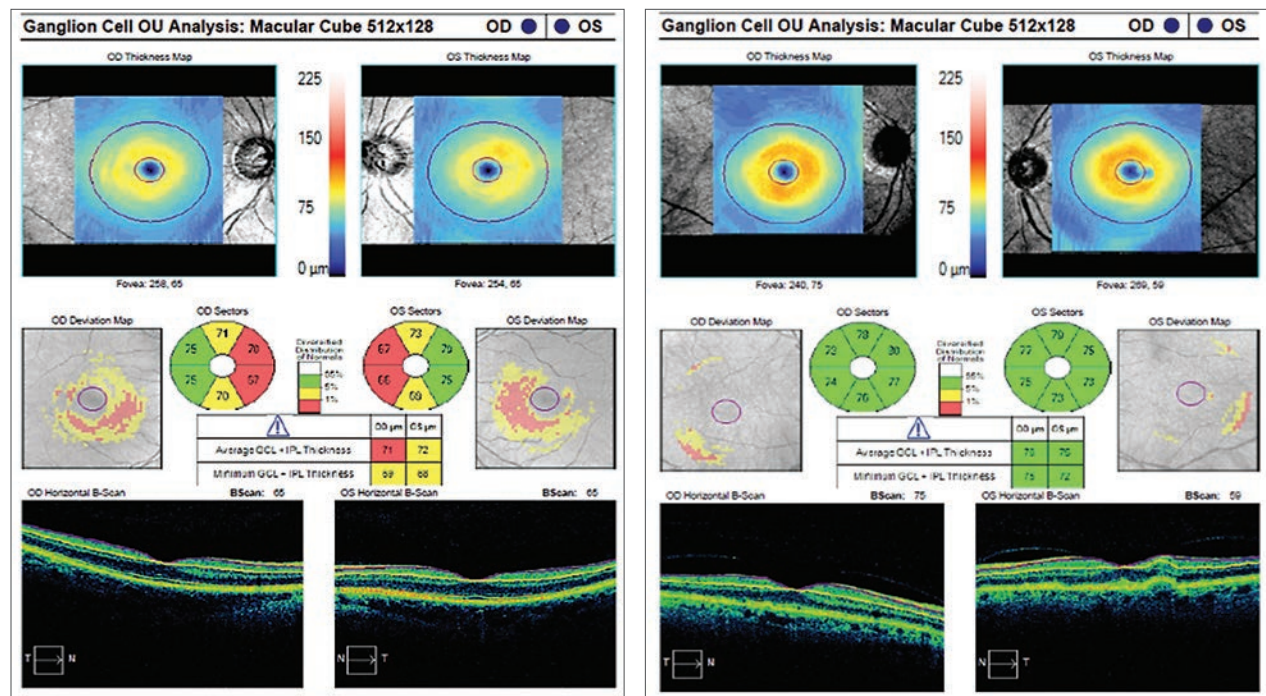
The Early Manifest Glaucoma Trial (EMGT)

This trial, also from 2002, evaluated 255 participants with early-stage glaucoma in at least one eye and a median IOP of 20mm Hg.⁴ The study objective was to observe the progression of glaucoma after early treatment and after delayed treatment (once progression was observed).⁴

The group of participants treated with a topical beta-blocker and 360° argon laser trabeculoplasty (ALT) experienced an average IOP reduction of 5.1mm Hg, approximately 25% from baseline, while the control group that received no treatment experienced minimal

to no changes in IOP from baseline.⁴ The researchers found that glaucoma progressed slower in the treated group, and when progression did occur, it occurred 18 months later than it did in the control group.⁴ The trial concludes that a higher baseline IOP, pseudo-exfoliation, bilateral disease, older age, lower ocular perfusion pressure and cardiovascular disease are all risk factors for progression and that with every 1mm Hg reduction in IOP, the risk of progression was minimized by 10%.⁵

A more recent trial, the Canadian Glaucoma Study, explored this association again and found that every 1mm Hg reduction in IOP reduces the risk of progression by 19%.⁶ Whether the relationship between IOP and disease progression is completely linear is a topic of debate, but what is clear is that reducing IOP, even by 1mm Hg, is critical to limit progression.



The ganglion cell analysis on the left shows a thinned ganglion cell layer secondary to glaucoma, while the right shows a normal ganglion cell layer.

A Surgeon's Perspective

Constance O. Okeke, MD, MSCE, a glaucoma specialist and cataract surgeon at Virginia Eye Consultants and assistant professor at Eastern Virginia Medical School in Norfolk, shared her thoughts about the two most recent novel classes of topical medications, NO-releasing agents and ROCK inhibitors.

As the trabecular meshwork (TM) ages in glaucoma, resistance to outflow increases, she says. This is the most common pathway manipulated or bypassed in surgical interventions. If these new medications, in their mechanisms of cytoskeletal relaxation of the TM fibers, are started earlier in the disease progression, they may prevent further structural disease of the TM. She adds that they may actually have a positive impact on how certain surgical treatments are used, such as MIGS, since many of those procedures are directed at the TM tissue and work better in patients who have good TM outflow systems that are still intact.

"We have evidence that every point matters, that starting prevention early matters and that lowering pressures can relatively halt disease progression," she says. "But we also know that glaucoma will progress despite a low pressure. I am really excited to see how our newer drugs, the ROCK inhibitors and NO-releasing agents, not only affect the pressure but also affect change in the structure in the outflow pathways. We may find that their impact is much more than IOP reduction, but may have a lasting effect that impacts how we are able to treat glaucoma better with the additional technologies and modalities that we have to offer."

The Collaborative Initial Glaucoma Treatment Study (CIGTS)

This study, which began enrolling patients in 1999, evaluated 607 participants with newly diagnosed open-angle glaucoma (OAG) and an IOP of at least 20mm Hg to determine whether patients benefit more from initial treatment with topical therapy or trabeculectomy.⁷

The topically treated group experienced a post-treatment average IOP of 17mm Hg to 18mm Hg compared with 14mm Hg to 15mm Hg in the surgical group.⁷ At the five-year mark, however, both groups had similar low rates of VF progression.⁸ The researchers found that patients who have advanced VF loss at baseline, are of older age, are of African descent or have diabetes are more likely to experience VF progression.⁸

After eight years of follow-up, the study concludes that patients with more advanced VF loss at baseline experience less VF deterioration if they undergo initial

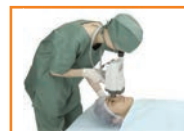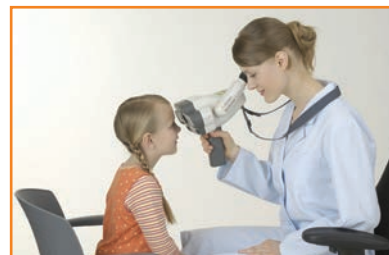treatment with trabeculectomy, supporting the need for early surgical intervention in these patients.⁹

The Collaborative Normal-Tension Glaucoma Study (CNTGS)

In 1998, researchers evaluated 260 participants with normal-tension glaucoma (NTG), defined as having an IOP of 20mm Hg or less after washout and a VF defect that has not advanced to the point where progression is easily detectable.¹⁰ The researchers sought to determine if IOP plays a role in NTG progression and to evaluate the natural tendency of NTG as a disease process.¹⁰ Treatment included a combination of topical pilocarpine, systemic carbonic anhydrase inhibitors, ALT and filtering surgery and aimed to reduce IOP by at least 30% from baseline.¹⁰

At the five-year mark, 35% of untreated eyes had experienced VF loss progression compared with only 12% of eyes that received treatment.¹⁰ Of the untreated eyes,

Precise Measurements Anytime, Anywhere



THE SERIES 3
HAND-HELD AUTOREFRACTOR
RETINOMAX
Righton



- ✓ Fast
- ✓ Lightweight
- ✓ Ergonomically Balanced
- NEW Auto Quick Measurement
- NEW Auto Pupil Measurement
- ✓ Small Pupil 2.3mm Measurement Acquisition
- ✓ Flexible Positioning—Sitting, Standing, Supine

S4OPTIK

www.s4optik.com | 888-224-6012

Sensible equipment. Well made, well priced.
For today's modern office.

one third had progressed within three years and half within five to seven years.¹⁰ The researchers found that those at risk of aggressive progression include women, migraine-sufferers and patients with disc hemorrhages.¹¹

The study concludes that while lowering IOP by 30% slows progression, some NTG cases progress quicker than others, highlighting the importance of identifying patients with aggressive disease and initiating treatment to lower IOP and slow the rate of progression.¹²

The Advanced Glaucoma Intervention Study (AGIS)

This study, also from the '90s, evaluated 591 participants with advanced OAG who were undergoing maximum medical therapy, had VF loss and were failing to achieve adequate IOP levels.¹³

The study aimed to examine the long-term clinical course and prognosis of advanced OAG and compare the outcomes of two sequences of surgical treatments.¹³ The first treatment arm included a trabeculectomy, followed by an ALT and another trabeculectomy, if necessary (TAT).¹³ The second treatment arm began with an ALT, followed by a trabeculectomy and a second, if necessary (ATT).¹³

After seven years, the researchers found that IOP was lower in eyes assigned to the TAT sequence, and those assigned to the ATT sequence suffered from a higher rate of initial therapy failure.¹³ While African American patients experienced better preservation of visual field and visual acuity with the ATT sequence, Caucasian patients had better preservation with the TAT sequence, suggesting a

patient's race should be taken into account when designing a surgical treatment plan involving trabeculectomy.¹⁴

They add that eyes with an initial IOP greater than 17.5mm Hg had statistically significant VF loss compared with eyes that had an IOP less than 14mm Hg, regardless of which surgical treatment course they followed.¹⁵ The study concludes that lowering IOP plays a critical role in reducing the progression of VF deterioration in patients with advanced OAG.¹³⁻¹⁵

That Was Then, This Is Now

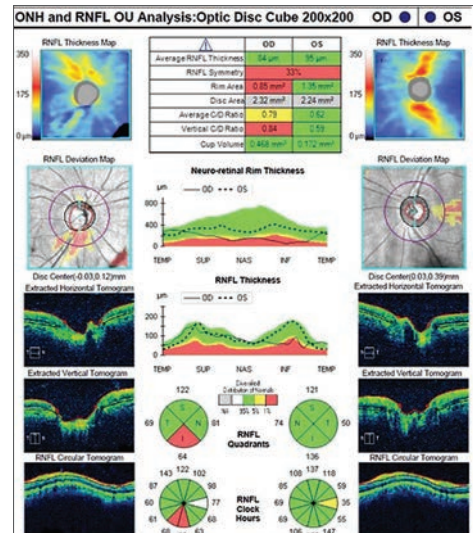
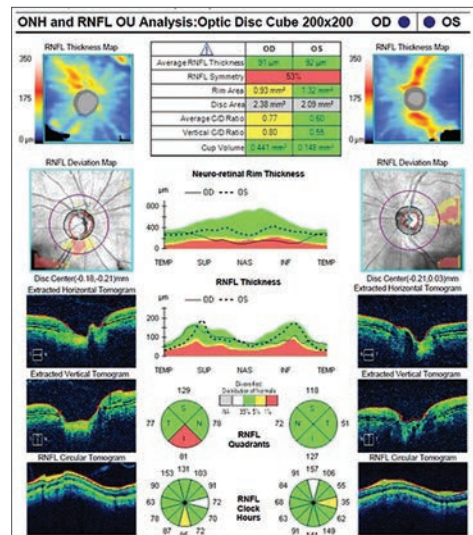
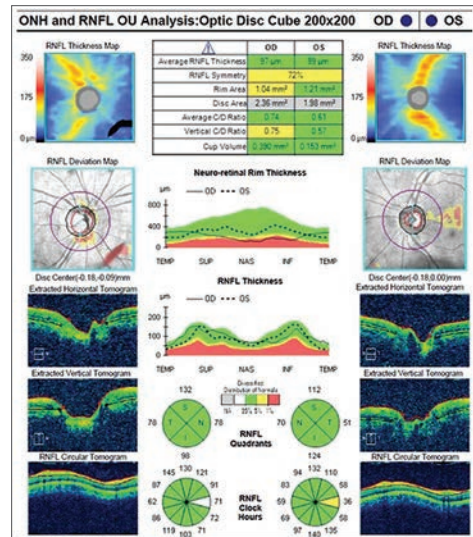
While much has changed since these studies shaped our treatment regimens, many of them are still incredibly important for our clinical decision-making process today.

They tell us that only a portion of patients with ocular hypertension go on to develop OAG without any treatment, and treatment reduces this rate significantly. They help us understand which patients are at a higher risk of progression based on clinical risk factors and that early initial treatment to lower IOP is beneficial in preventing or delaying progression.

What If?

These studies, however, come with some pitfalls, especially in light of the tests and treatments available today. The OHTS defined glaucoma progression, similarly to most of the other studies, as VF loss progression measured by Humphrey visual

Three years of RNFL OCT scans of a patient with unilateral glaucoma show thinning progression in the inferior quadrant of the right eye.



fields or optic disc deterioration noted on photographs. But, if the researchers had included retinal nerve fiber layer (RNFL) loss progression by OCT or OCT ganglion cell analysis as part of their definition of glaucoma progression, the criteria might be different. They may have found more than 9.5% of ocular hypertensive patients experienced progression.

VF testing is the only way to quantify functional loss from glaucoma, but research now shows that up to 50% of the RNFL may deteriorate before a defect is apparent on the visual field.¹⁶ RNFL scanning by OCT measures the thickness of the ganglion cell axons around the optic nerve and is now a well-established measurement for detecting early-stage glaucoma and monitoring progression in early to moderate stages.^{17,18} The macula contains the majority of retinal ganglion cells and, therefore, is primarily where damage takes place during the earliest stage of glaucoma.

OCT analysis has advanced to quantify this layer; ganglion cell analysis can detect glaucomatous damage before a VF defect is observed and can even be beneficial as a parameter for advanced disease detection when RNFL analysis is no longer helpful.^{19,20}

Today, clinicians must fit serial OCT readings into the clinical definition of progression and determine how to administer appropriate treatment when progression is noted on OCT.

The EMGT found that every 1mm Hg matters and that early intervention does slow progression, both of which are still relevant. The standard treatment in the trial, however, was 360° ALT and a topical beta-blocker, which is far from the standard of care today. Although selective laser trabecu-

loplasty (SLT) and ALT are comparable in their abilities to lower IOP initially, once 360° ALT has been performed, no research shows repeated ALT is as efficacious the second time, while repeated 360° SLT has proven effective.²¹⁻²³ Thus, the study may have been more successful and achieved a lower percentage of progression had 360° SLT been performed initially and repeated over follow-ups as needed to maintain target IOP instead of one-time 360° ALT and a topical beta-blocker.

Newer topical medications are also a game-changer and are now being used as first-line therapies ahead of the medications used in these studies. Research shows prostaglandin analogs administered once daily are comparable with and even superior in efficacy to timolol taken twice daily.²⁴

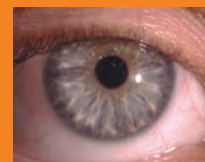
Vyzulta (latanoprostene bunod ophthalmic solution 0.024%, Bausch + Lomb) is a combination of prostaglandins and NO-donating molecules that increases aqueous outflow via both the uveoscleral and trabecular meshwork pathways. It can lower IOP by about 1.2mm Hg more than latanoprost and has shown superiority to timolol after three months.^{25,26} A 1.2mm Hg reduction may seem like a small advantage, but for most patients every 1mm Hg counts.

Rhopressa (netarsudil ophthalmic solution 0.02%, Aerie Pharmaceuticals) is a rho-kinase inhibitor and a norepinephrine transporter inhibitor that increases aqueous outflow through the trabecular meshwork and decreases aqueous fluid production in the ciliary body. While studies have not shown Rhopressa to be superior to latanoprost, it is non-inferior to timolol at baseline IOPs of 21mm Hg to 24mm Hg at three and six months.^{27,28}

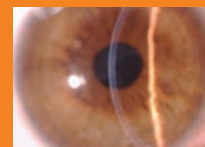

LED SLIT LAMP **MW50D** Righton

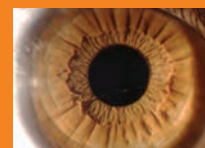Clean, ergonomic design
combined with exceptional
50X Hig-Mag Optics



- 5 Magnification steps from 5X to 50X



- True color LED illumination
- High-Res Digital imaging capable



- Clean cable-free design

S4OPTIK

www.s4optik.com | 888-224-6012

Sensible equipment. Well made, well priced.
For today's modern office.

Glaucoma

This may be a prospective adjunct therapy when secondary agents are needed with a different mechanism of action. This can be especially important for patients with aggressive NTG whose IOP cannot be lowered enough to be beneficial.

Roclatan (netarsudil/latanoprost ophthalmic solution 0.02/0.005%, Aerie Pharmaceuticals) is a combination drop that is pending FDA approval. Researchers suggest that the drop reduces IOP by an average of 1mm Hg to 3mm Hg more than each of its components.²⁹

All of these new treatment options are equal or superior in efficacy to those used in the landmark studies and are becoming more widespread in their use for all stages of glaucoma.

The CIGTS and AGIS found that while filtration surgery can be successful in some patients, associated risk factors exist that clinicians

must consider. Today, we have a growing number of MIGS that can be performed before external incision surgery is required. Some MIGS target the conventional outflow pathway, suprachoroidal space and subconjunctival space, providing multiple surgical options for early- to moderate-stage glaucoma patients. While a place still exists for trabeculectomy and tube shunts in surgical glaucoma management, many patients classified as early to moderate stage undergo MIGS and see a reduction in IOP.

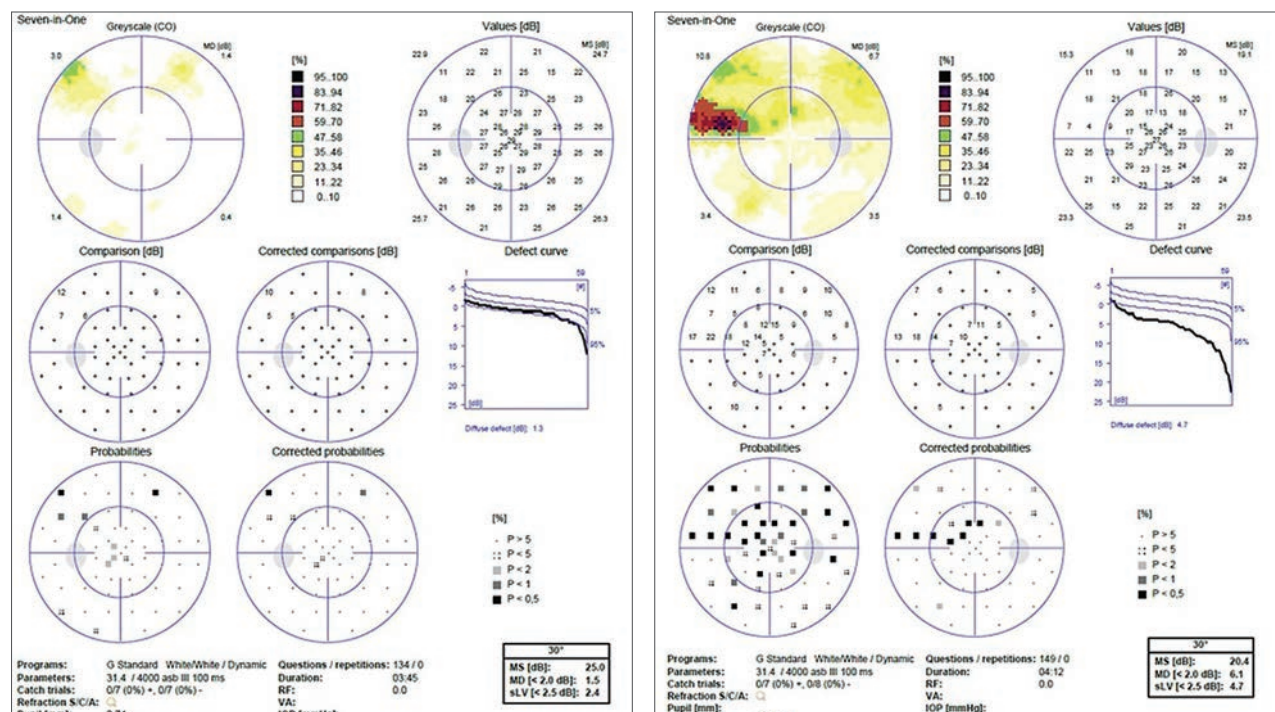
These procedures provide a new avenue of surgical intervention with fewer risk factors. As MIGS surgeons become more comfortable with these procedures and their expected outcomes, their use will likely expand into more advanced forms of glaucoma.

Given the significant advancements in topical, laser and surgical

options, it is worth questioning whether updating the AGIS would provide more insight into which patients can benefit from initial and repeatable SLT and which may need surgery earlier in the process. For the latter group of patients, MIGS may be an option.

Updating the CIGTS to compare topical treatments with various MIGS options would help clinicians understand when and how to offer these procedures to prevent further glaucomatous damage. Incorporating MIGS into this algorithm, as it creates its own tier in the glaucoma treatment hierarchy, would prove beneficial in providing patients with appropriate options depending on their stage of glaucoma.

Though much has changed in the diagnosis and management of glaucoma in the last two to three decades, landmark studies still pro-



This is the visual field of the patient in the RNFL OCTs. The defect correlates with the structural damage seen on OCT scans of the right eye. However, this defect was not present in previous years and was only detected during the most recent RNFL scan. This example showcases the modern definition of progression with OCT.

vide important evidence to support and guide clinicians. These studies all illustrate the importance of aggressive IOP-lowering to prevent progressive damage to the optic nerve and have driven innovation within the field of glaucoma to what we see today.

Early diagnosis is key to successful long-term management, and diligent IOP-lowering is critical. As technological, pharmacological and surgical advancements continue, we are obligated to stay informed on the newest studies and treatments and combine them with the knowledge we've gleaned from these foundational studies to provide the best care for our patients. ■

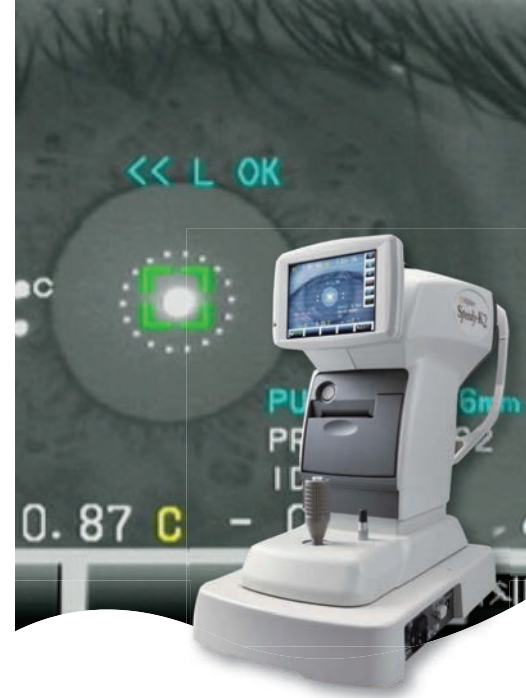Dr. Janes practices at Atlee Gleaton Eye Care in Augusta, ME. She completed her residency training in ocular disease and ocular and refractive surgery at Virginia Eye Consultants.

Dr. Kruthoff is a staff optometrist at Virginia Eye Consultants in Norfolk, VA.

- Gordon MO, Beiser JA, Brandt JD, et al. The Ocular Hypertension Treatment Study: baseline factors that predict the onset of primary open-angle glaucoma. Arch Ophthalmol. 2002;120(6):714-20.
- Kass MA, Heuer DK, Higginbotham EJ, et al. The Ocular Hypertension Treatment Study: a randomized trial determines that topical ocular hypotensive medication delays or prevents the onset of primary open-angle glaucoma. Arch Ophthalmol. 2002;120(6):701-13.
- Kass MA, Gordon MO, Gao F, et al. Delaying treatment of ocular hypertension. Arch Ophthalmol. 2010;128(3):276-87.
- Heijl A, Leske MC, Bengtsson B, et al. Reduction of intraocular pressure and glaucoma progression: results from the early manifest glaucoma trial. Arch Ophthalmol. 2002;120(10):1268-79.
- Leske MC, Heijl A, Hussein M, et al. Factors for glaucoma progression and the effect of treatment: the early manifest glaucoma trial. Arch Ophthalmol. 2003;121(1):48-56.
- Chauhan BC, Mikelberg FS, Balazsi AG, et al. Canadian Glaucoma Study: 2. Risk factors for the progression of open-angle glaucoma. Arch Ophthalmol. 2008;126(8):1030-6.
- Musch DC, Lichter PR, Guire KE, et al. The Collaborative Initial Glaucoma Treatment Study: study design, methods and baseline characteristics of enrolled patients. Ophthalmology. 1999;106(4):653-62.
- Lichter PR, Musch DC, Gillespie BW, et al. Interim clinical outcomes in the Collaborative Initial Glaucoma Treatment Study comparing initial treatment randomized to medications or surgery. Ophthalmology. 2001;108(11):1943-53.
- Musch DC, Gillespie BW, Lichter PR, et al. Visual field progression in the Collaborative Initial Glaucoma Treatment Study: the impact of treatment and other baseline factors. Ophthalmology. 2009;116(2):200-7.
- Comparison of glaucomatous progression between

untreated patients with normal-tension glaucoma and patients with therapeutically reduced intraocular pressures. Am J Ophthalmol. 1998;126(4):487-97.

- Drance S, Anderson DR, Schulzer M. Risk factors for progression of visual field abnormalities in normal-tension glaucoma. Am J Ophthalmol. 2001;131(6):699-708.
- Anderson DR, Drance SM, Schulzer M. Natural history of normal-tension glaucoma. Ophthalmology. 2001;108(2):247-53.
- Ederer F, Gassterland DE, Sullivan EK. The Advanced Glaucoma Intervention Study (AGIS): 1. Study design and methods and baseline characteristics of study patients. Control Clin Trials. 1994;15(4):299-325.
- The Advanced Glaucoma Intervention Study (AGIS): 4. Comparison of treatment outcomes within race. Seven-year results. Ophthalmology. 1998;105(7):1146-64.
- The Advanced Glaucoma Intervention Study (AGIS): 7. The relationship between control of intraocular pressure and visual field deterioration. Am J Ophthalmol. 2000;130(4):429-40.
- Quigley HA, Addicks EM, Green WR. Optic nerve damage in human glaucoma. III. Quantitative correlation of nerve fiber loss and visual field defect in glaucoma, ischemic neuropathy, papilledema and toxic neuropathy. Arch Ophthalmol. 1982;100(1):135-46.
- Schuman JS, Hee MR, Puliafito CA, et al. Quantification of nerve fiber layer thickness in normal and glaucomatous eyes using optical coherence tomography. Arch Ophthalmol. 1995;113(5):586-96.
- Kim NR, Lee ES, Seong GJ, et al. Spectral-domain optical coherence tomography for detection of localized retinal nerve fiber layer defects in patients with open-angle glaucoma. Arch Ophthalmol. 2010;128(9):1121-8.
- Zhang X, Dastiridou A, Francis BA, et al. Comparison of glaucoma progression detection by optical coherence tomography and visual field. Am J Ophthalmol. 2017;184:63-74.
- Bhagat P, Deshpande K, Natu B. Utility of ganglion cell complex analysis in early diagnosis and monitoring of glaucoma using a different spectral domain optical coherence tomography. J Curr Glaucoma Practice. 2014;8(3):101-6.
- Damji KF, Bovell AM, Hodge WG, et al. Selective laser trabeculoplasty versus argon laser trabeculoplasty: results from a 1-year randomised clinical trial. Br J Ophthalmol. 2006;90:1490-4.
- Richter CU, Shingleton BJ, Bellows AR, et al. Retreatment with argon laser trabeculoplasty. Ophthalmology. 1987;94:1085-9.
- Hong BK, Winer JC, Martone JF, et al. Repeat selective laser trabeculoplasty. J Glaucoma. 2009;18(3):180-3.
- Mishima HK, Masuda K, Kitazawa Y, et al. A comparison of latanoprost and timolol in primary open-angle glaucoma and ocular hypertension. A 12-week study. Arch Ophthalmol. 1996;114(8):929-32.
- Weinreb RN, Ong T, Scassellati Sforzolini B, et al. A randomized, controlled comparison of latanoprostene bunod and latanoprost 0.005% in the treatment of ocular hypertension and open-angle glaucoma: the VOYAGER Study. Br J Ophthalmol. 2015;99(6):738-45.
- Medeiros FA, Martin KR, Peace J, et al. Comparison of latanoprostene bunod 0.024% and timolol maleate 0.5% in open-angle glaucoma or ocular hypertension: the LUNAR Study. Am J Ophthalmol. 2016;168:250-9.
- Aerie Pharmaceuticals reports initial Rhopressa phase 3 efficacy results. Aerie Pharmaceuticals. April 23, 2015. investors.aeriepharma.com/news-releases/news-release-details/aerie-pharmaceuticals-reports-initial-rhpressatm-phase-3. Accessed October 15, 2018.
- Aerie Pharmaceuticals reports positive rocket 4 six-month topline safety and efficacy results for Rhopressa (netarsudil ophthalmic solution) 0.02%. Aerie Pharmaceuticals. April 12, 2017. investors.aeriepharma.com/news-releases/news-release-details/aerie-pharmaceuticals-reports-positive-rocket-4-six-month. Accessed October 15, 2018.
- Aerie Pharma (AERI) announces statistically significant data from Roclatan phase 3 mercury 1 trial. Street Insider. September 14, 2016. www.streetinsider.com/Corporate+News/Aerie+Pharma+%28AERI%29+Announces+Statistically+Significant+Data+from+Roclatan+Phase+3+Mercury+1+Trial/12032805.html. Accessed October 15, 2018.



THE NEW
AUTO-REFRACTOR KERATOMETER
SPEEDY-K2
Righton

- ✓ Extremely Fast with Accurate Measurements
- ✓ Variable Target Illumination with Automatic Dimming for Small Pupil
- ✓ Central and Peripheral Keratometry (3.2 and 6.8)
- ✓ 5.7" Touch Panel with 45° Tilt Function
- ✓ Cornea Diameter Measurement (0-16mm)
- ✓ Retro Illumination for Cataract Observation

S4 OPTIK

www.s4optik.com | 888-224-6012

Sensible equipment. Well made, well priced.
For today's modern office.



THE ABCs OF RADIOLOGIC TESTING

Clinicians should be prepared to order CT and MRI should the need arise.
Patients' lives may count on it.

By Jason Fliegel, OD, Traci Seng, OD, Sara Weidmayer, OD, and Kathy Lewis, OD

The pursuit of diagnostic imaging during the course of optometric patient care can be an intimidating clinical decision. Optometrists often face several roadblocks, including unfamiliarity with available imaging options, uncertainty as to what type of modality is appropriate for a certain case and even the possibility of unwanted adverse effects.

Nonetheless, common radiological procedures such as computed tomography (CT) and magnetic resonance imaging (MRI) are often

necessary to obtain the appropriate diagnosis and guide treatment. Here, we discuss the indications for, and precautions associated with, specific types of imaging to help clarify several common concerns that often hinder their use in optometric practice.

Conventional Radiography

The x-ray, a type of electromagnetic energy and source of ionizing radiation, can pass through substances, such as bone, that are typically impenetrable to light.^{1,2} In con-

ventional radiography, x-rays are passed through the area of focus.^{1,2} The amount of x-ray attenuation reflects the various densities of the involved structures and is typically captured in a film or digital format, resulting in the familiar two-dimensional image.¹ Structural densities that can be visualized with x-ray include air, bone, fat, soft tissue and metal.³

A common concern and disadvantage of undergoing x-ray imaging is the exposure to ionizing radiation. However, the amount

Release Date: October 15, 2018

Expiration Date: October 15, 2021

Goal Statement: Clinicians often face several roadblocks when considering radiologic imaging, including unfamiliarity with the available tests, uncertainty as to what type of modality is appropriate and even the possibility of unwanted adverse effects. However, CT and MRI are often valuable to help uncover the appropriate diagnosis and guide treatment—and ODs need to be prepared to order these tests to improve their diagnostic accuracy.

Faculty/Editorial Board: Jason Fliegel, OD, Traci Seng, OD, Sara Weidmayer, OD, and Kathy Lewis, OD

Credit Statement: This course is COPE approved for 2 hours of CE credit. Course ID is **59487-PD**. Check with your local state licensing board to see if this counts toward your CE requirement for relicensure.

Disclosure Statements:

Authors: The authors have no relationships to disclose.

Editorial staff: Jack Persico, Rebecca Hepp, William Kekevan, Catherine Manthorp and Mark De Leon all have no relationships to disclose.

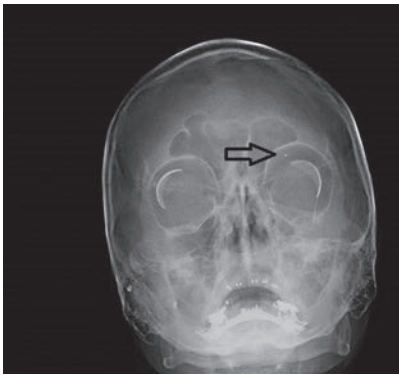
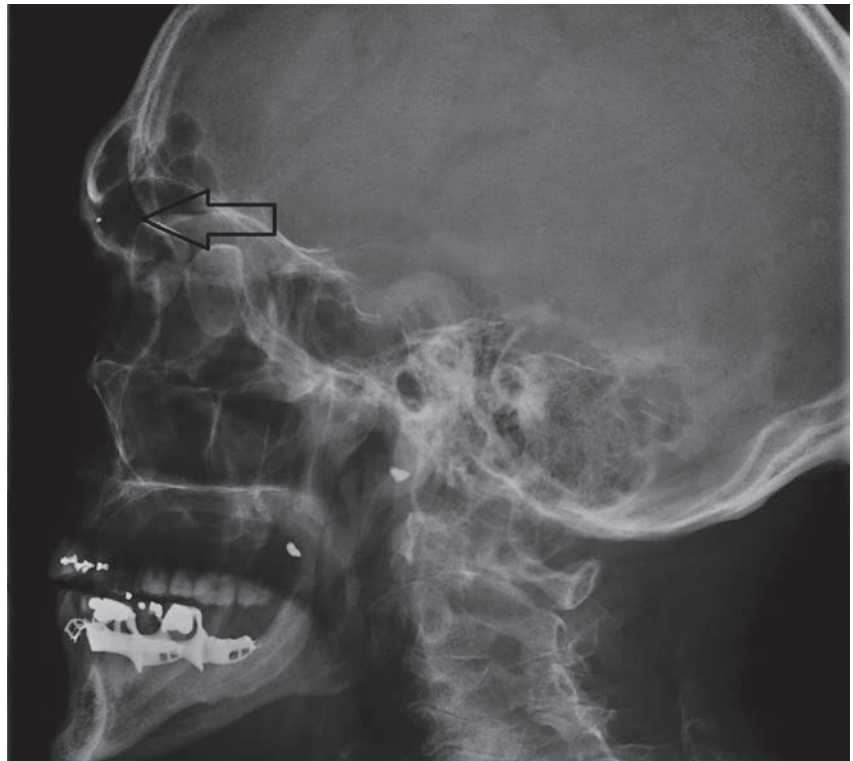


Fig. 1. These radiographic x-ray coronal (above) and sagittal (right) images demonstrate two small metallic shrapnel fragments overlying the right mandible and a smaller shrapnel fragment within the left orbit.



of radiation used in conventional radiography is significantly less than that of CT, which also uses x-ray, and therefore carries less risk for developing a radiation-related disease such as cancer.⁴

In eye care, the use for conventional radiography is limited. Orbital radiographs are mainly used to screen patients who have a history or possible history of intraocular or intraorbital foreign bodies prior to undergoing MRI due to the potential risk for mobilization of ferromagnetic foreign bodies (*Figure 1*).^{5,6} One study suggests 0.27% of the population has intraorbital metallic foreign bodies, compared with 2.5% of those with an occupational history of metalworking or prior metallic foreign body trauma.⁷ Furthermore, the American College of Radiology recommends “all patients who have a history of orbit trauma by a potential ferromagnetic foreign body for which they sought medical attention are to have their orbits cleared by either plain x-ray orbit films (two views) or by a radiologist’s review and assessment of contiguous cut prior CT or MR images (obtained since the suspected traumatic event) if possible.”⁸

Conventional radiography, however, should not be used to fully exclude a potential foreign body if highly suspected or in cases of recent ocular or orbital trauma; CT is recommended for these clinical situations (*Figure 2*).^{6,9}

Conventional x-ray may also assist in the diagnosis of systemic conditions that often present with ocular manifestations. For example, in patients presenting with uveitis, chest radiography may reveal bilateral hilar lymphadenopathy consistent with sarcoidosis, whereas the presence of erosion and sclerosis of the sacroiliac joint are common radiographic findings with ankylosing spondylitis (*Figure 3*).^{10,11}

Computed Tomography

With this modality, an x-ray tube is rotated around the area of focus, after which the amount of x-ray attenuation is measured by opposing detectors.¹²⁻¹⁴ The degree of attenuation, dependent on the den-

sity of the tissues or materials in question, is represented as a numerical value known as Hounsfield Unit (HU).^{12,13} Scan density is then visualized as a 2D or 3D cross-sectional image after Hounsfield Units are assigned to corresponding pixels, each of which have individual grayscale values ranging from 1 (black) to 256 (white).^{12,13,15,16}

The advantages of CT over other imaging modalities include widespread availability, relative cost effectiveness and timely scan completion.^{12,15} Clinically, CT’s ability to provide superior detail of bone abnormalities, calcification, bony involvement from a soft tissue mass and metallic foreign bodies is outstanding.^{6,15,17} CT is especially sensitive at detecting fresh blood, thus making it the preferred imaging option for suspected acute intracranial hemorrhagic conditions.^{6,13,15,18} When iodinated contrast medium is used in conjunction with CT, both specificity and sensitivity of the

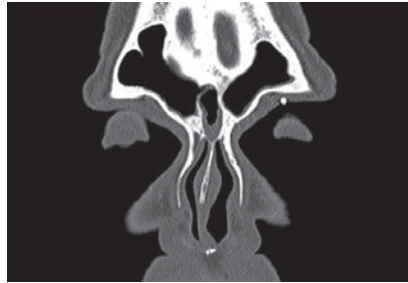
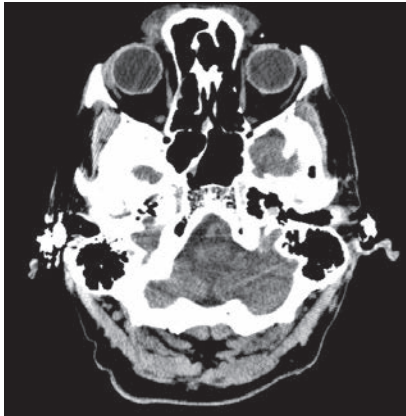


Fig. 2. These axial (left) and coronal (above) CT images demonstrate the same shrapnel fragment in *Figure 1* at the margin of the left superior orbital rim.

scan for various pathologic conditions can increase.^{12,13,15} Improved visualization of a breakdown of the blood-brain barrier, as well as infectious, inflammatory and neoplastic conditions are a few indications that may warrant the use of contrast.^{6,18}

As with conventional radiography, exposure to ionizing radiation is a common concern with CT, which could potentially cause damage at a cellular level and increase the risk for cancer.^{4,19} The millisievert (mSv) is the unit of measurement used to quantify the effective dose of radiation and risk associated with exposure.⁴ In the United States, individuals typically encounter an annual effective dose of around 3.1mSv from naturally-occurring background radiation exposure.²⁰ By comparison, CT of the head reveals an effective dose of 2mSv when done without contrast and 4mSv when done with and without contrast, which is approximately equivalent to eight and 16 months, respectively, of background radiation exposure.²¹

An x-ray of the chest has an effective dose

of only 0.1mSv.²¹ Regardless, the lifetime risk of death from cancer following a single head CT remains low (less than 0.08%), although the risk is much higher when the scan is completed from birth through age 15.²² Cumulative radiation dose is important, as research shows CT could increase the lifetime risk of cancer in patients who have received multiple scans.²³

Given these common concerns, clinicians should take special precautions when considering imaging for certain patient populations:

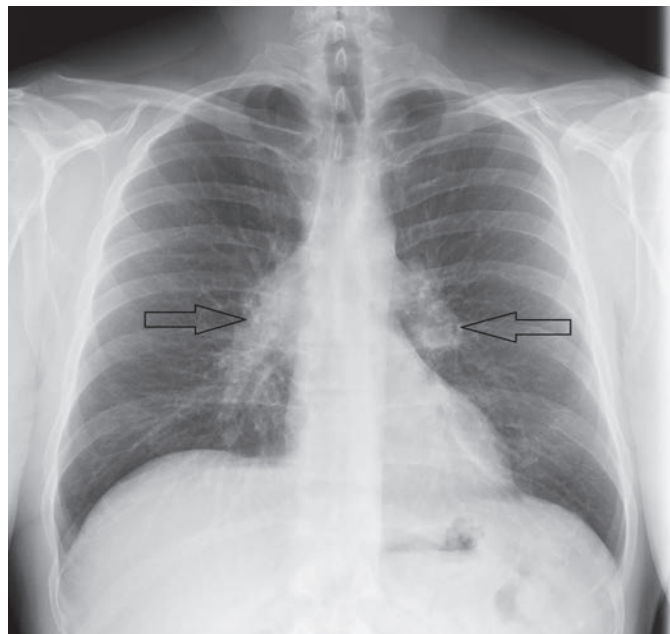


Fig. 3. A chest x-ray reveals sarcoid-associated bilateral hilar lymphadenopathy (arrows).

Pregnancy. CT should be deferred if at all possible in pregnant women, as studies suggest that exposing a developing fetus to ionizing radiation may increase the risk of developing childhood cancers and possibly lead to malformations, developmental disturbances and even loss of pregnancy.^{17,24-27}

Characteristics that influence the amount of fetal radiation exposure include scan location (e.g., head vs. abdomen) and slice thickness.²⁸ A pregnancy test should be considered prior to CT for women of child-bearing age.⁶

Children. Increased organ radiosensitivity, smaller body size and longer lifespan may increase the risk for radiation-related cancers in children.^{4,29} CT is generally avoided unless absolutely indicated, such as in cases of orbital or head trauma where CT remains the preferred method of imaging.⁶

Adding Contrast

The use of iodinated contrast media is not without the possibility of complication; adverse reactions can be mild to severe and include nausea, vomiting, urticaria, bronchospasm, hypotension, anaphylactic shock and even cardiac arrest.¹⁴ Risk factors for an adverse effect include a prior allergic reaction to contrast, asthma, severe cardiac disease, renal insufficiency and procedural anxiety.³⁰ Clinicians should consider these four precautions prior to ordering CT with contrast:

1. Contrast may be contraindicated in patients who have exhibited an allergic or physiologic reaction to

the use of a previous contrast agent. However, in those patients where CT with contrast is a necessity and other imaging modalities are not the preferred option, medications such as corticosteroids (e.g., “steroid prep”) and diphenhydramine are typically given

prior to the use of contrast to reduce the risk of a possible adverse reaction.^{14,15,31}

2. Contrast-induced nephropathy is a concern for those with a prior history of impaired renal function or acute kidney injury.³¹ Therefore, the use of iodinated contrast should be discussed with the appropriate specialties to decide if it is appropriate and to ensure the proper hydration protocol can take place prior to the procedure.^{14,31} Additionally, patients taking metformin with a prior history of renal dysfunction may be asked to discontinue the medication 48 hours prior to the use of contrast media due to the increased risk for lactic acidosis.^{14,30,31}

3. While children and women who are pregnant or breastfeeding have no absolute contraindications with iodinated contrast, adverse events such as allergic-like reactions and nephrotoxicity can also occur; its use is generally avoided if possible.³⁰⁻³²

4. Patients with untreated hyperthyroidism are contraindicated from receiving iodinated contrast due to the risk for thyrotoxicosis.^{14,32}

Order and Interpret CT

Clinicians should clearly communicate the patient’s clinical history, suspected diagnoses and potential contraindications or precautions to

Imaging Variations

While conventional catheter cerebral angiography via the femoral artery remains the standard, magnetic resonance angiography (MRA) and computed tomographic angiography (CTA) are typically initially used to assist in the detection of suspected intracranial vascular conditions, such as aneurysms or dissections.^{6,18,42} MRA and CTA can be advantageous in comparison with catheter angiography due to their availability, timeliness of completion and their noninvasiveness.^{18,42} While CTA allows for more expedient and generally more sensitive results, iodinated contrast medium and exposure to radiation may make MRA necessary in certain clinical situations.^{6,13,18}

Suspicion of cerebral venous sinus thrombosis may warrant magnetic resonance venography (MRV) or computed tomographic venography (CTV) to exclude it as causal for papilledema.⁴² Advantages and disadvantages similar to that of MRA and CTA remain with both MRV and CTV, and clinicians must use their discretion when deciding which imaging modality would best serve the patient.^{15,42}

the radiology department in the CT order.¹⁷

Within eye care, CT is typically used for conditions involving the orbit and ordered accordingly; however, additional views (e.g., head, neck or both) may be necessary depending on the clinical situation. Scans involving the orbit are typically ordered without contrast or with and without contrast in the axial and coronal planes with a slice thickness of between 1mm and 3mm, depending on recommended protocol for the suspected condition.^{6,9,18,33} Clinicians who are uncertain of the proper protocol should consult with the radiologist.

Although the radiologist will complete the CT interpretation and report, optometrists should have a familiar knowledge of normal vs.

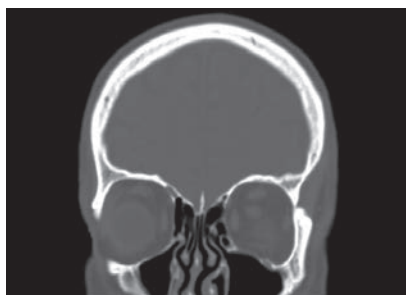

Fig. 4. Radiologists often use bone window settings to improve bony detail when evaluating conditions such as suspected orbital fractures or bony erosion from metastatic tumors.

abnormal anatomy for additional review. The first step in interpreting the results is understanding the units of measure. An HU of 0 is equal to water, -1,000 is equal to air and bone approaches +1,000.^{12,14} Following conversion of all HUs to the corresponding greyscale image, denser tissues such as bone will appear white, while air will appear black.^{12,15}

Tissue or substances such as fat, muscle, blood and contrast medium typically exhibit a range of HU values and are represented accordingly on the greyscale image.^{14,34}

Abnormalities are typically described in comparison with surrounding structures as isodense (comparable with the brain), hyperdense (bone, acute blood, calcification), hypodense (edema, infarction) or enhanced with contrast (inflammation, neoplasms).³⁵ The report should also include a description of how the area of concern is impacting any surrounding structures (e.g., producing midline shift, mass effect, etc.).¹⁴ Radiologists will also often use bone windows to further isolate areas of bony detail concern, rather than using the standard soft tissue setting (*Figure 4*).^{6,36}

The When and Why of CT

Clinicians can use this imaging technique to better assess pertinent structures in any number of clinical presentations:

Orbital trauma. Clinical signs and symptoms that indicate the need for CT following recent orbital trauma include decreased visual acuity or field of vision, new-onset afferent pupillary defect, diplopia, restricted extraocular motility, pain on eye movement, proptosis, lid edema, ecchymosis, severe subconjunctival

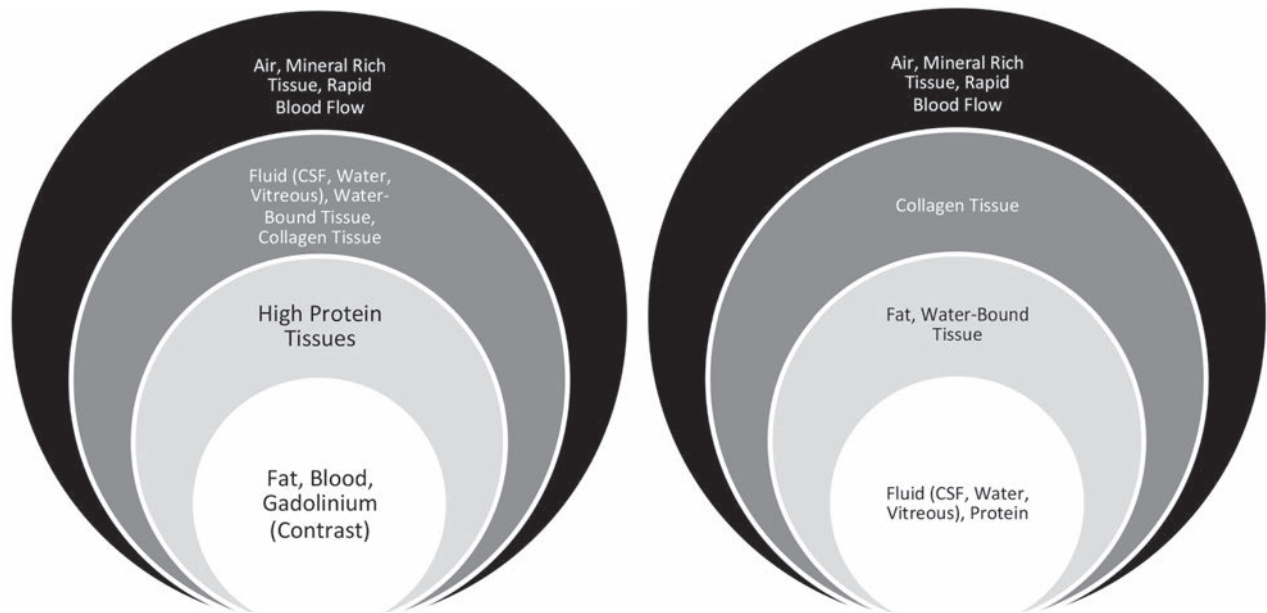


Fig 5. These schematics show general color representations of various T1W (left) and T2W (right) image densities.⁴⁹

hemorrhage and optic disc edema.^{6,9} Any concern for conditions such as an orbital wall fracture, orbital hemorrhage or traumatic optic neuropathy warrant CT of the orbit and possibly the head, face or both, typically without contrast with a thin slice thickness (1mm to 3mm, depending on the recommended protocol) in the axial and coronal planes.^{6,9,37}

Extraocular muscles. Proptosis, ocular motility restriction, eyelid retraction, periorbital edema and ocular surface involvement are signs of Graves' ophthalmopathy.^{6,9,37} While MRI with gadolinium contrast may also be used to evaluate orbital involvement from Graves', axial and coronal views of the orbit using CT without contrast is generally appropriate to visualize enlargement of the extraocular muscles without tendon involvement, which is typical of this condition.^{6,9} While iodinated contrast with CT may allow for enhancement of the involved muscles, it is usually not recommended out of concern for contrast-related thyrotoxicosis.^{13,17,38}

Orbital disease. Proptosis, diplo-

pia, swelling of the eyelids, pain and visual decrease may present in cases of orbital disease such as inflammatory orbital pseudotumor, orbital cellulitis or orbital abscess, meningiomas, mucoceles, orbital lymphoma and orbital varix.^{6,9,15,33}

While MRI may be preferred in certain instances, CT may still provide valuable insight. CT of the orbit (possibly with specified inclusion of the paranasal sinuses) and other pertinent structures such as the brain, with and without contrast in the axial and coronal planes is appropriate for suspected inflammatory, infectious or neoplastic orbital conditions.^{6,9,33,37} CT is especially useful in detecting bony erosion associated with tumors such as metastatic neuroblastoma in children or metastatic and lymphoid tumors in adults.^{6,9,15} The modality is also exceptional at detecting calcification within a tumor.^{6,15,18} This is particularly important in children with retinoblastoma, as 95% of those cases reveal calcification and can assist in diagnosis of this life-threatening condition.^{15,39}

Intraocular, intraorbital foreign

bodies. CT is recommended when concern exists for a penetrating injury following a history of high-speed projectile foreign body trauma to or around the eye. Clinicians should obtain axial and coronal views without contrast of the orbit and, possibly, the brain with a slice thickness of less than 1mm, if possible.^{6,9,33} Objects composed of metal and glass are best observed with CT, whereas wood or vegetative matter may be better detected with B-scan, provided there are no contraindications for the procedure.^{6,9,35}

Magnetic Resonance Imaging

This technique is based on the principle that the nuclei of atoms containing an odd number of protons, neutrons or both become polarized or aligned when placed in a static magnetic field.⁴⁰⁻⁴² For imaging human tissue, the hydrogen atom is primarily responsible for these magnetic properties.^{40,42} In addition to a strong static magnetic field, a transitory oscillating radiofrequency field (RF) is generated that, when switched off, causes the magnetic nuclei to emit nuclear magnetic res-

onance signals, which are then processed to form an MRI image.^{40,41}

MRI techniques and images are characterized according to time, specifically T1-weighted (T1W) and T2-weighted (T2W). These time constants correspond to the behavior of protons responding to the magnetic field and RF. The RF field causes excitation of the protons, and after the RF field is terminated, the protons realign to their original location, known as relaxation. Longitudinal relaxation, or spin-lattice, is referred to as T1W, while transverse relaxation, or spin-spin, is referred to as T2W. T1W and T2W relaxation occur simultaneously; however, T2W relaxation is completed much more rapidly.⁴⁰⁻⁴² Unlike CT, there is no radiation exposure with MRI.

Image appearance of tissues with MRI depends on the proton density of the structures being imaged, timing of the RF pulse and sampling, fluid flow and electron clouds surrounding the nuclei, which may shield the atom from the applied magnetic field.⁴⁰ T1W images of tissues with shorter T1W relaxation times, such as fat and blood, appear hyperintense (brighter) compared with those with longer times such as water, vitreous and cerebrospinal fluid (CSF).^{15,41}

In T2W images, tissues with longer T2W relaxation appear hyperintense compared with those with shorter times such as blood products (Figure 5).^{15,40,41} In general, normal anatomy is best demonstrated on T1W images, whereas intracranial pathology is better imaged with T2W (Figure 6).⁴³ Both are included as part

of a standard MRI examination.⁴³

Although CT neuroimaging is more common, MRI is typically more appropriate for assessment of neuro-ophthalmic diseases. In general, MRI is superior to CT except for visualization of acute hemorrhage or bone abnormalities.^{17,40,42} When referring a patient for MRI, clinicians should determine what area of focus will best demonstrate the suspected pathology (often the brain or orbit) and if gadolinium contrast or any special image processing techniques such as fat suppression, fluid attenuation inversion recovery (FLAIR) or diffusion-weighted imaging (DWI) should be included to maximize the likelihood of correct diagnosis (Figure 7).

Gadolinium contrast is used with T1W scans to enhance areas of a possible compromised blood-brain barrier, blood vessel abnormalities, inflammation and lesions.^{15,40,42,43} Contrast should be included for most neuro-ophthalmic conditions, barring a significant contraindication.^{17,43} Although gadolinium contrast is rarely contraindicated, the literature shows some reported cases of nephrogenic systemic fibrosis developing after use in patients with renal disease.^{30,43} Overall, the rate of adverse effects from the use of gadolinium is significantly less than that of the iodinated contrast medium used with CT.⁴⁴

FLAIR is used with T2W imaging and when used, CSF will appear

dark, whereas nearby areas of edema are bright.^{15,42} This allows demyelinating lesions to be more easily visualized.⁴¹⁻⁴³

DWI is a sequence that can help reveal suspected acute ischemic changes—often within minutes—allowing for earlier detection compared with CT or conventional MRI.^{13,18,41-43}

Fat suppression is used to suppress the hyperintense signal from substances such as fat and water, which can improve visualization of pathology and may be particularly useful for optic neuropathies and orbital lesions.⁴³

When to Order

Possible indications for MRI include unilateral or bilateral vision loss, efferent or afferent pupillary defects, diplopia, external ophthalmoplegia, lid abnormalities, ophthalmoscopic abnormalities indicative of intracranial disease and orbital trauma.⁴⁵

Acute monocular vision loss. In these cases, pupil findings, appearance of the optic nerve, associated visual field involvement, patient symptoms and demographics may help narrow the diagnosis. Many causes of acute monocular vision loss can be diagnosed clinically or with additional lab or radiologic testing; however, if optic neuritis is suspected, MRI of the brain and orbit with gadolinium contrast, fat suppression (to show nerve enhancement) and FLAIR (which highlights demyelination lesions) would be indicated.^{13,17} Research shows that 95% of patients with optic neuritis demonstrate an enhanced optic nerve on MRI, and a single demyelinating

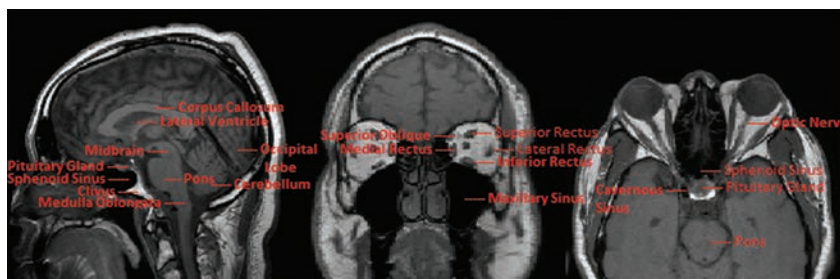


Fig. 6. This figure shows normal MRI T1W images in (left to right) sagittal, coronal and axial cuts. Some major anatomic landmarks are indicated in red.

brain lesion on MRI increases the risk for developing multiple sclerosis from 25% to 72% within 15 years.^{46,47}

If progressive monocular vision loss is more chronic in duration, clinicians should suspect compressive, inflammatory or infiltrative lesions involving the optic nerve anterior to or at the optic chiasm.^{13,45} MRI of the orbit and brain with contrast and fat suppression would be suggested in this circumstance.^{13,17,45}

Binocular vision loss. Particularly when presenting with visual field defects consistent with a suspected neurologic abnormality, this would typically indicate a lesion at or posterior to the optic chiasm.¹⁷

A bitemporal hemianopsia often presents as a result of a lesion that is causing chiasmal compression, most often a pituitary adenoma. For these cases, experts recommend MRI of the brain with contrast, and clinicians should communicate with the radiology department to ensure adequate focus on the chiasmal area (Figure 8).^{13,17,43} Urgent MRI or CT of the sella may also be indicated to rule out aneurysm or pituitary apoplexy, as they are important differential diagnoses when acute bitemporal field loss is detected.^{13,45}

The appearance of a homonymous hemianopsia is typical of conditions involving the retrochiasmal visual pathway.^{13,43} In younger patients, MRI of the brain with contrast can help exclude a mass

or demyelinating lesion as the suspected cause.^{13,17} Acute-onset homonymous hemianopsia in an elderly patient, however, is typically a result of an ischemic stroke; therefore, DWI should be included if symptoms are acute.^{17,45}

Transient visual changes, early visual field disturbances (such as an enlarged blind spot) and headaches in the presence of bilateral disc edema are findings suggestive of increased intracranial pressure (ICP) and warrant expedient neuroimaging.^{6,17} An intracranial mass, meningitis, idiopathic intracranial hypertension (IIH) and cerebral venous sinus thrombosis are all among the possible etiologies.⁶ MRI of the brain with contrast would be indicated; however, magnetic resonance venography (MRV) may also be warranted when clinicians suspect venous sinus thrombosis.^{6,45}

Mandatory neuroimaging must be completed prior to lumbar puncture in suspected cases of IIH.^{6,48} MRI findings typical of IIH include the appearance of an “empty sella” and a flattened appearance of the posterior globes.³⁴

Horner’s syndrome. Ipsilateral ptosis, miosis and possibly anhidrosis are findings consistent with this condition, which can result from carotid dissection, apical lung tumor or any defect along the sympathetic innervation pathway to the eye.¹⁷ In the acute presence of head or neck pain, clinicians should rule out a

carotid dissection.^{6,13,42,45} MRI of the head and neck with contrast and magnetic resonance angiography (MRA) or CTA of the head and neck is recommended in cases of Horner’s syndrome.^{6,13,45} Concern for an apical lung tumor (also known as Pancoast tumor) also warrants imaging of the chest, typically by CT with contrast.^{6,17}

Ocular motility dysfunction. Clinicians should suspect a third nerve palsy with pupillary involvement is caused by a life-threatening aneurysm until proven otherwise.^{6,13,43} Emergent neuroimaging using contrast-enhanced CT/CTA or MRI/MRA is required.^{6,45} CT/CT angiography (CTA) are currently the techniques of choice due to better sensitivity and timeliness; however, MRI/MRA may be necessary should CT be contraindicated.^{6,43} Importantly, if initial neuroimaging does not reveal an aneurysmal cause and strong suspicion is still present, conventional catheter angiography should be considered.^{6,17,42}

Isolated fourth or sixth cranial nerve palsies may or may not need imaging, since they are most commonly associated with an ischemic etiology.^{6,17,42} If a palsy presents acutely in a patient older than 50 who has vasculopathic risk factors (such as diabetes and hypertension), imaging may often be deferred as long as there are not accompanying neurologic signs or involvement, a history of cancer, and resolution occurs within 90 days.^{6,17,42} Otherwise, MRI of the brain with contrast would be indicated.

Non-cranial nerve ocular motility disorders such as skew deviation, nystagmus, supranuclear or internuclear ophthalmoplegia often also require imaging with MRI, typically with contrast and FLAIR.^{13,17,45} If acute transient ischemic attack or stroke is the suspected etiology, then DWI is also included.¹⁷

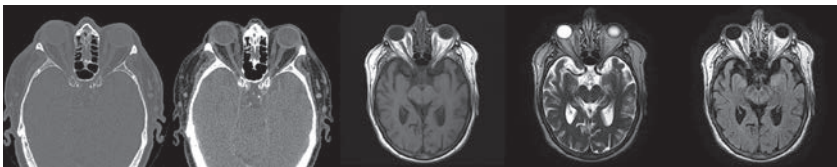


Fig. 7. This patient has thyroid eye disease, including proptosis OD>OS, secondary exposure keratopathy, extraocular muscle movement restrictions and diplopia. He has no clinical or radiologic evidence of optic nerve compression. Imaging includes (left to right, all axial cuts) CT with bone windows, standard CT, MRI T1W, MRI T2W and MRI FLAIR sequence. They reveal proptosis OD>OS, enlarged extraocular muscle bellies and mild prominence of the intraconal fat bilaterally.

When Not to Order

Although MRI may be the most clinically appropriate option, clinicians may forego ordering it due to absolute or relative contraindications. These include patients with magnetic metal in their body, such as cochlear implants and older generation aneurysm clips.¹⁷ A history of any metal in the body overall would at a minimum warrant a discussion with the radiology department to determine if MRI is advisable or if CT would be the preferred method of imaging.^{6,17}

Cardiac pacemakers or implanted cardiac defibrillators are contraindications for MRI, since it can result in programming alterations and even failure.⁴¹

Claustrophobia is a relative contraindication, for which anxiolytic medications can help or, in some instances, open MRI testing can be substituted, although image quality may suffer as a result of poorer resolution.¹⁷ Significant obesity may also warrant the use of open MRI if the machine's bore is too small for the patient.¹⁷

The decision to acquire diagnostic imaging may seem daunting for some clinicians, but it is crucial for the patient—and can be a life-saving decision for some. Clinicians who are familiar with the advantages, disadvantages and indications for the appropriate imaging modality won't hesitate to order the right imaging when encountering these important clinical situations—and will reach a diagnosis in time to initiate appropriate treatment or refer to the correct care provider. ■

Drs. Fliegel, Seng, Weidmayer, and Lewis are staff optometrists in the VISN 10: VA Healthcare System—US Department of Veteran Affairs.

Contents in this publication do not represent the views of the US

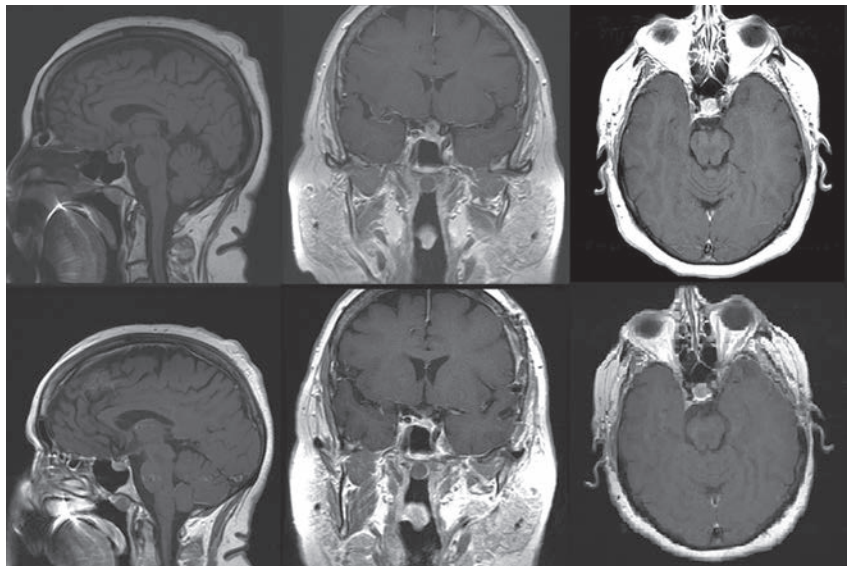


Fig. 8. This patient had a pituitary macroadenoma, which was resected via left pterional craniotomy. Preoperative (above) and postoperative (below) MRI T1W imaging shows (left to right) sagittal, coronal and axial cuts. Preoperatively, notice the pituitary fossa with a heterogeneously enhancing and enlarged pituitary extending to the left optic chiasm, which was displacing the left optic nerve's course superiorly. Postoperatively, notice the hypo-enhancement in the sella turcica and removal of the suprasellar component of the pituitary lesion with minimal residual soft tissue and the decrease in the left optic nerve and chiasmatal mass effect. The MRI images also show post-surgical encephalomalacia/gliosis in the opercular region of the left frontal lobe and in the anterior left temporal lobe, subadjacent to a left pterional craniotomy defect.

Department of Veterans Affairs or the United States Government.

1. Brant WE. Diagnostic imaging methods. In: Brant WE, Helms CE, eds. *Fundamentals of Diagnostic Radiology*. 3rd ed. New York: Lippincott; 2007:3-25.
2. Bushong SC. Essential concepts of radiologic science. In: Bushong SC, ed. *Radiologic Science for Technologists Physics, Biology, and Protection*. 10th Ed. Philadelphia: Elsevier; 2013:3-25.
3. Radiology Masterclass. Basics of x-ray physics. www.radiologymasterclass.co.uk/tutorials/physics/x-ray_physics_densities. Accessed May 23, 2018.
4. Lee CI, Elmore JG. Radiation-related risks of imaging. In: Aronson MD, Lee SI, eds. *UpToDate*. Waltham, MA.
5. Lawrence DA, Lipman AT, Gupta SK, Nacey NC. Undetected intraocular metallic foreign body causing hyphema in a patient undergoing MRI: a rare occurrence demonstrating the limitations of pre-MRI safety screening. *Magnetic Resonance Imaging*. 2015;33(3):358-61.
6. Bagheri N, Wajda BN, Calvo CM, et al. *Wills Eye Manual: Office and Emergency Room Diagnosis and Treatment of Eye Disease*, 7th ed. Philadelphia: Lippincott Williams & Wilkins; 2017.
7. Williamson MR, Espinosa MC, Boutin RD, et al. Metallic foreign bodies in the orbits of patients undergoing MR imaging: Prevalence and value of radiography and CT before MR. *Am J Roentgenology*. 1994;162(4):981-6.
8. Kanal E, Brogstedte JP, Barkovich AJ, et al. American College of Radiology White Paper on MR Safety. *AJR Am J Roentgenol*. 2002;178:1335-47.
9. Kaiser PK, Friedman NJ, Pineda R. *The Massachusetts Eye and Ear Infirmary Illustrated Manual of Ophthalmology*. 4th ed. Philadelphia: Saunders; 2014.
10. West SG. Sarcoidosis. In: Hochberg MC, Gravallese EM, Silman AJ, et al., eds. *Rheumatology*. 7th ed. Philadelphia: Elsevier; 2019:175, 1470-79.
11. Braun J, Baraliakos X. Imaging of spondyloarthritis. In: Hochberg MC, Gravallese EM, Silman AJ, Smolen JS, Weinblatt ME, Weisman

- MH eds. *Rheumatology*. 7th ed. Elsevier; 2019:125, 1024-32.
12. Tawfik HA, Abdelhalim A, Elkafrawy MH. Computed tomography of the orbit - A review and update. *Saudi J Ophthalmol*. 2012;26:409-18.
13. Kim JD, Hashemi N, Gelman R, et al. Neuroimaging in ophthalmology. *Saudi J Ophthalmol*. 2012;26:401-7.
14. Shaw AS, Prokop M. Computed tomography. In: Adam A, Dixon A, Gillard J, et al. *Granger and Allison's Diagnostic Radiology*. 6th ed. Philadelphia: Elsevier; 2015:76-89.
15. Bowling B. Neuro-ophthalmology. In: Bowling B, ed. *Kanski's Clinical Ophthalmology* 8th ed. Philadelphia: Elsevier; 2017:773-849.
16. Gücük A, Üyetürk U. Usefulness of hounsfield unit and density in the assessment and treatment of urinary stones. *World J Nephrol*. 2014;3(4):282-6
17. Kruger JM, Lessell S, Cestari DM. Neuro-imaging: A review for the general ophthalmologist. *Sem Ophthalmol*. 2012;27;(5-6):192-6.
18. Bose S. Principles of imaging in neuro-ophthalmology. In: Yanoff M, Duker JS. *Ophthalmology*. 4th ed. Philadelphia: Elsevier; 2014:851-857.e1.
19. The 2007 Recommendations of the International Commission on Radiological Protection. ICRP publication 103. *Ann ICRP*. 2007;37(2-4):1.
20. United States Nuclear Regulatory Commission. Background on biological effects of radiation. www.nrc.gov/reading-rm/doc-collections/fact-sheets/bio-effects-radiation.html. Accessed July 30, 2018.
21. American College of Radiology. Radiation dose to adults from common imaging examinations. www.acr.org/-/media/ACR/Files/Radiology-Safety/Radiation-Dose-Reference-Card.pdf?la=en. Accessed July 30, 2018.
22. Brenner DJ, Hall EJ. Computed tomography - an increasing source of radiation exposure. *N Engl J Med*. 2007;357:2277-84.
23. Task Group on Control of Radiation Dose in Computed Tomography. Managing patient dose in computed tomography. A report of the International Commission on Radiological Protection. *Ann ICRP*. 2000;30(4):7.
24. Wakeford R, Little MP. Risk coefficients for childhood cancer after intrauterine irradiation: a review. *Int J Radiat Biol*. 2003;79(5):293.
25. Preston DL, Cullings H, Suyama A, et al. Solid cancer incidence in atomic bomb survivors exposed in utero or as young children. *J Natl*

Cancer Inst. 2008;100(6):428.

26. Yamazaki JN, Schull WJ. Perinatal loss and neurological abnormalities among children of the atomic bomb. Nagasaki and Hiroshima revisited, 1949 to 1989. *JAMA*. 1990;264(5):605.
27. Brent RL. Saving lives and changing family histories: appropriate counseling of pregnant women and men and women of reproductive age, concerning the risk of diagnostic radiation exposures during and before pregnancy. *Am J Obstet Gynecol*. 2009;200(1):4-24.
28. Kruskal JB. Diagnostic imaging procedures in pregnant and nursing women. In: Levine D, Barss VA, eds. *UpToDate*, Waltham, MA.
29. Linet MS, Kim KP, Rajaraman P. Children's exposure to diagnostic medical radiation and cancer risk: epidemiologic and dosimetric considerations. *Pediatr Radiol*. 2009;39 Suppl 1:S4.
30. American College of Radiology ACR Committee on Drugs and Contrast Media. ACR manual on contrast media. www.acr.org/-/media/ACR/Files/Clinical-Resources/Contrast_Media.pdf. Accessed July 30, 2018.
31. Davenport MS, Newhouse JH. Patient evaluation prior to oral or iodinated intravenous contrast for computed tomography. In: Bhalla S, Soto JA, Lee SI, eds. *UpToDate*, Waltham, MA.
32. Thomsen HS, Reimer P. Intravascular contrast media for radiography, MRI, and ultrasound. In: Adam A, Dixon A, Gillard J, et al. *Grainger and Allison's Diagnostic Radiology*, 6th ed. Philadelphia:

Elsevier; 2015;(2):26-51.e1.

33. Thust SC, Miskiel K, Davagnanam I. Orbit. In: Adam A, Dixon A, Gillard J, et al. *Grainger and Allison's Diagnostic Radiology*, 6th ed. Philadelphia: Elsevier; 2014:1556-89.e1.
34. Radgray.com. Hounsfield scale. www.radgray.com/ct/general-ct/hounsfield-scale. Accessed July 30, 2018.
35. Biouesse V, Newman NJ. *Neuro-ophthalmology Illustrated*, 2nd ed. New York: Thieme; 2015.
36. Costelloe CM, Chuang HH, Chasen BA, et al. Bone windows for distinguishing malignant from benign primary bone tumors on FDG PET/CT. *J Cancer*. 2013;4(7):524-30.
37. Shindler KS. Orbital disease in neuro-ophthalmology. In: Liu GT, Volpe NJ, Galetta SL, Liu, Volpe, and Galetta's *Neuro-Ophthalmology*, 3rd ed. Philadelphia: Elsevier; 2019.
38. Kruger JM, Cestari DM, Cunnane MB. Systemic approaches for reviewing neuro-imaging scans in ophthalmology. *Digit J Ophthalmol*. 2017;19;23(3):50-59.
39. Barkovich AJ, Raybaud C. *Pediatric Neuroimaging*, 5th ed. Philadelphia: Lippincott & Williams; 2005.
40. Johnson MC, Policeni BA, Lee AG, Smoker WRK, eds. *Neuroimaging in Ophthalmology*, 2nd ed. Oxford, NY: Oxford University Press; 2011.
41. Simha A, Irodi A, Davis S. Magnetic resonance imaging for the

- ophthalmologist: a primer. *Indian J Ophthalmol*. 2012;60(4):301-10.
42. Woods AD, Caputo MK. Essential uses of radiologic testing in eye care. *Rev Optom*. 2014;151(1):52-9.
43. Lee AG, Johnson MC, Policeni BA, Smoker WRK. Imaging for neuro-ophthalmic and orbital disease—a review. *Clin Exper Ophthalmol*. 2009;37:30-53.
44. Hunt CH, Hartman RP, Hesley GK. Frequency and severity of adverse effects of iodinated and gadolinium contrast materials: Retrospective view of 456,930 doses. *AJR App J Roentgenol*. 2009;193(4):1124-7.
45. Lee AG, Brazis PW, Garrity JA, White M. Imaging for neuro-ophthalmic and orbital disease. *Am J Ophthalmol*. 2004;138:852-62.
46. Rizzo JF, Andreoli CM, Rabinov JD. Use of magnetic resonance imaging to differentiate optic neuritis and nonarteritic anterior ischemic optic neuropathy. *Ophthalmology*. 2002;109(9):1679-84.
47. Optic Neuritis Study Group. Multiple sclerosis risk after optic neuritis: Final optic neuritis treatment trial follow-up. *Arch Neurol*. 2008;65(6):727-32.
48. Gower DJ, Baker AL, Bell WO, Ball MR. Contraindications to lumbar puncture as defined by computed cranial tomography. *J Neurol Neurosurg Psychiatry*. 1987;50(8):1071-4.
49. MRI technique. www.startradiology.com/the-basics/mri-technique. Accessed August 8, 2018.

OSC QUIZ

You can obtain transcript-quality continuing education credit through the Optometric Study Center. Complete the test form and return it with the \$35 fee to: Jobson Medical Information, Dept.: Optometric CE, 440 9th Avenue, 14th Floor, New York, NY 10001. To be eligible, please return the card within one year of publication. You can also access the test form and submit your answers and payment via credit card at *Review of Optometry* online, www.reviewofoptometry.com/ce.

You must achieve a score of 70 or higher to receive credit. Allow four weeks for processing. For each Optometric Study Center course you pass, you earn 2 hours of transcript-quality credit from Pennsylvania College of Optometry and double credit toward the AOA Optometric Recognition Award—Category 1.

Please check with your state licensing board to see if this approval counts toward your CE requirement for relicensure.

1. Conventional radiography uses what source of energy?
 - a. Electromagnetic.
 - b. Thermal.
 - c. Kinetic.
 - d. Rotational.
2. What is a common use for conventional x-ray in eye care?
 - a. Horner syndrome.
 - b. Cranial nerve palsies.
 - c. Screen for possible intraocular/intraorbital foreign bodies.
 - d. Transient monocular vision loss.
3. In select patients with a pertinent history, a minimum of how many radiographic views should be obtained to screen for possible

facial, orbital or intraocular foreign bodies prior to ordering MRI?

- a. One.
- b. Two.
- c. Three.
- d. Four.

4. What unit of measurement is used in CT to describe the degree of x-ray attenuation?

- a. Hounsfield.
- b. Microns.
- c. Millisievert.
- d. Parts per million

5. What materials does CT image particularly well?

- a. Bone abnormalities.
- b. Calcification.
- c. Metallic foreign bodies.
- d. All of the above.

6. What imaging modality is especially sensitive for detecting fresh blood/bleeding?

- a. X-ray.
- b. MRI T1W.
- c. CT.
- d. MRI T2W.

7. What imaging modality delivers the highest effective dose of radiation?

- a. Conventional radiography.
- b. CT without contrast.
- c. CT with and without contrast.
- d. MRI.

8. What is the approximate effective dose of radiation exposure for a head CT without contrast?

- a. 0.1mSv.
- b. 2.0mSv.
- c. 3.1mSv.
- d. 4.0mSv.

9. What is the approximate effective dose of radiation exposure for a chest x-ray?

- a. 0.1mSv.
- b. 2.0mSv.
- c. 3.1mSv.
- d. 4.0mSv.

10. Possible adverse reactions to iodinated contrast media include all of the following, except:

- a. Nausea.
- b. Bronchospasm.
- c. Anaphylaxis.
- d. Conjunctivitis.

11. Patients who have had an allergic reaction to iodinated contrast media may be able to subsequently have iodinated contrast media:

- a. Without any concern for another allergic reaction.
- b. If pre-treated with corticosteroids and/or diphenhydramine.
- c. If pre-treated with antibiotics.
- d. If iodinated contrast media is needed to image a different area of the body.

12. On CT, dense materials appear on grayscale as:

- a. Black.
- b. Dark gray.
- c. Light gray.
- d. White.

13. Compared with the brain, bone appears _____ on CT.

- a. Isodense.
- b. Hyperdense.
- c. Hypodense.
- d. Absent.

14. On MRI, longitudinal relaxation is also known as:

OSC QUIZ

- a. Spin-lattice.
- b. T1W.
- c. T2W.
- d. Both a and b.

15. Which imaging modality is not a source of ionizing radiation?

- a. MRI.
- b. CT without contrast.
- c. CT with contrast.
- d. X-ray.

16. In T1 imaging, which of the following would appear the most hyperintense?

- a. Cerebrospinal fluid.
- b. Vitreous.
- c. Blood.
- d. Water.

17. What type of contrast is used for MRI imaging?

- a. Iodinated contrast media.
- b. Gadolinium.
- c. Iodine.
- d. Barium.

18. What is one benefit of the FLAIR imaging technique?

- a. CSF appears hypointense/dark and edema appears hyperintense/bright.
- b. CSF appears hyperintense/bright and edema appears hypointense/dark.
- c. The fat signal is enhanced.
- d. Demyelinating lesions appear hypointense/dark.

19. What MRI imaging sequence is best to detect acute ischemic changes?

- a. T1W.
- b. DWI.
- c. T2W.
- d. FLAIR.

20. Which of the following is not a contraindication for MRI imaging?

- a. Magnetic metal foreign body.
- b. Cochlear implants.
- c. Cardiac pacemakers or defibrillators.
- d. Anxiety.



TAKE THE TEST ONLINE TODAY!
www.reviewofoptometry.com/continuing_education/

Examination Answer Sheet

The ABCs of Radiologic Testing

Valid for credit through October 15, 2021

Online: This exam can be taken online at www.reviewofoptometry.com/ce. Upon passing the exam, you can view your results immediately and download a real-time CE certificate. You can also view your test history at any time from the website.

Directions: Select one answer for each question in the exam and completely darken the appropriate circle. A minimum score of 70% is required to earn credit.

Mail to: Jobson Medical Information, Dept.: Optometric CE, 440 9th Avenue, 14th Floor, New York, NY 10001.

Payment: Remit \$35 with this exam. Make check payable to Jobson Medical Information LLC.

Credit: This course is COPE approved for 2 hours of CE credit. Course ID is 59487-PD.

Sponsorship: This course is joint-sponsored by the Pennsylvania College of Optometry.

Processing: There is a four-week processing time for this exam.

Answers to CE exam:

1. (A) (B) (C) (D)
2. (A) (B) (C) (D)
3. (A) (B) (C) (D)
4. (A) (B) (C) (D)
5. (A) (B) (C) (D)
6. (A) (B) (C) (D)
7. (A) (B) (C) (D)
8. (A) (B) (C) (D)
9. (A) (B) (C) (D)
10. (A) (B) (C) (D)
11. (A) (B) (C) (D)
12. (A) (B) (C) (D)
13. (A) (B) (C) (D)
14. (A) (B) (C) (D)
15. (A) (B) (C) (D)
16. (A) (B) (C) (D)
17. (A) (B) (C) (D)
18. (A) (B) (C) (D)
19. (A) (B) (C) (D)
20. (A) (B) (C) (D)

Post-activity evaluation questions:

Rate how well the activity supported your achievement of these learning objectives:
 1=Poor, 2=Fair, 3=Neutral, 4=Good, 5=Excellent

21. Improve my understanding of the indications for radiologic imaging. (1) (2) (3) (4) (5)

22. Better recognize precautions associated with CT and MRI imaging. (1) (2) (3) (4) (5)

23. Identify common concerns that hinder my use of radiologic testing. (1) (2) (3) (4) (5)

24. Improve my ability to order radiologic imaging such as CT and MRI. (1) (2) (3) (4) (5)

25. Increase my knowledge of the interpretation protocols associate with CT and MRI. (1) (2) (3) (4) (5)

26. Clarify the various image processing techniques necessary for certain conditions. (1) (2) (3) (4) (5)

Rate the quality of the material provided:
 1=Strongly disagree, 2=Somewhat disagree, 3=Neutral, 4=Somewhat agree, 5=Strongly agree

27. The content was evidence-based. (1) (2) (3) (4) (5)

28. The content was balanced and free of bias. (1) (2) (3) (4) (5)

29. The presentation was clear and effective. (1) (2) (3) (4) (5)

30. Additional comments on this course:

Please retain a copy for your records. Please print clearly.

First Name

Last Name

E-Mail

The following is your: Home Address Business Address

Business Name

Address

City State

ZIP

Telephone # - -

Fax # - -

By submitting this answer sheet, I certify that I have read the lesson in its entirety and completed the self-assessment exam personally based on the material presented. I have not obtained the answers to this exam by any fraudulent or improper means.

Signature _____ Date _____

Lesson 117095

RO-OSC-1018

10TH ANNUAL
2018

WEST COAST Optometric Glaucoma Symposium

Earn up to
**12 CE
Credits***

DECEMBER 14-15, 2018

Join our faculty of renowned ODs and MDs for a highly interactive meeting covering the most up-to-date information in glaucoma care. Up to 12 CE credits for only \$325.

MONARCH HOTEL

1 Monarch Beach Resort
Dana Point, CA 92629
949-234-3900

MEETING CO-CHAIRS:



Murray Fingeret, OD



Robert Weinreb, MD

SPEAKERS: Andrew Camp, MD
Ben Gaddie, OD

Alex Huang, MD, PhD
Richard Madonna, OD

THREE WAYS TO REGISTER

www.reviewsce.com/WCOGS2018

Email: reviewmeetings@jhihealth.com

Call Lois DiDomenico: 877-451-6514

Administered by

Review Group Vision Care Education, LLC



*Approval pending



SALUS
UNIVERSITY

Pennsylvania College of Optometry

Partially supported by
unrestricted educational grants from

Bausch + Lomb
Novartis

Aerie

Earn up to
**12 CE
Credits***

WEST COAST Optometric Glaucoma Symposium

DECEMBER 14-15, 2018 • DANA POINT, CA

Registration Information

Name	Title	NPI # (NPI numbers will only be used for HCP reporting purposes)	
Practice Affiliation	License #/State	OE Tracker #	
Work Mailing Address	City	State	Zip Code
Work Telephone	Cell	E-mail	Fax

Name Badge Information (please print clearly)

My Name	My Guest	Additional Guests
---------	----------	-------------------

Payment Information

OD Registration: \$325	Rate per person	No. in party	Subtotal
	\$325	x _____	= \$ _____

Call 866-685-1772 or visit event website for daily rates.

Check enclosed (make checks payable to Jobson Healthcare, LLC)

Charge my: American Express Mastercard Visa

Credit Card Number _____ Exp Date _____

Cardholder (print name) _____

Signature _____

CONFERENCE CANCELLATION POLICY

Please refer to the "Fees" page on www.reviewsce.com/WCOGS2018 for cancellation policy details.

For more information or to register,
contact Lois DiDomenico at 866-658-1772
or at reviewmeetings@jhihealth.com.

Mail Form: Review Group c/o Jobson
11 Campus Blvd, Ste. 100
Newtown Square, PA 19073

Fax Form: Review Group
610-492-1039

Administered by

Review Group Vision Care Education, LLC



*Approval pending



Partially supported by
unrestricted educational grants from
Bausch + Lomb **Aerie**
Novartis

See website for up-to-date information.



Delaying the Inevitable

With persistent epithelial defects, referring to a specialist may ultimately be the best option. **Edited by Joseph P. Shovlin, OD**

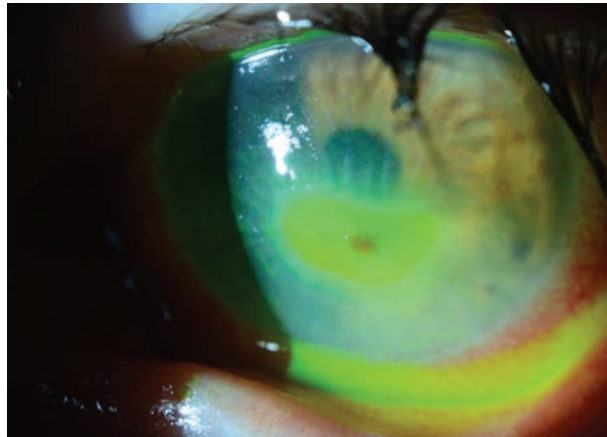
Q I have a patient who recently had neurosurgery for an acoustic neuroma and now has facial nerve palsy and a persistent epithelial defect. Until he sees an oculoplastic specialist, how can I preserve the corneal surface and help the persistent defect heal to prevent infection?

A These patients can be problematic because they usually have a neurotrophic cornea and an exposed ocular surface, according to Christopher J. Rapuano, MD, chief of the cornea service at Wills Eye Hospital. He says the goal is to keep the corneal epithelium intact in an effort to prevent ulceration, infection, scarring, melting and perforation. Though doctors can accomplish this task in several ways, Dr. Rapuano notes that “the specific approach usually depends on the health of the corneal surface.”

A Case-by-case Basis

While Dr. Rapuano says mild cases may respond to simple solutions, such as preservative-free tears four to six times per day and tear gel at night, most cases require more aggressive treatment. He suggests using a viscous lubricant during the day—such as a thick, preservative-free artificial tear—and an artificial tear ointment at night.

In the case of an epithelial defect, Dr. Rapuano recommends



This corneal melt developed in an eye with a neurotrophic cornea after undergoing acoustic neuroma treatment.

using a broad-spectrum antibiotic drop three to four times per day and an artificial tear ointment or an antibiotic ointment every two hours while the patient is awake.

If a patient has a persistent epithelial defect like this patient, Dr. Rapuano notes that a bandage soft contact lens (BSCL) may be necessary but could increase the risk of infectious keratitis. He says the next step is to apply a self-retained amniotic membrane, which can be attached to a plastic ring or placed under a BSCL. The amniotic membrane tends to be quite successful in treating persistent epithelial defects and eventually dissolves over a period of days or weeks, Dr. Rapuano adds.

The doctor’s course of action following treatment for the persistent epithelial defect depends on whether the defect responds positively. If it only responds partially

to treatment, Dr. Rapuano recommends applying another amniotic membrane. However, if the defect does not respond, and especially if the cornea begins to thin, he suggests referring to a corneal specialist for more aggressive treatment.

An additional option includes securing the amniotic membrane tissue to the cornea with sutures and/or fibrin glue. He adds that using cyanoacrylate glue may be

helpful when trying to avoid an urgent corneal transplant if severe corneal thinning, a descemetocele or a small corneal perforation is present.

Prior to a more permanent eye closure by an oculoplastic surgeon, Dr. Rapuano suggests simply taping the eye closed at night using external aides, such as nasal strips, which are gentle on the patient’s skin. He says some doctors go as far as applying superglue to the eyelashes to glue the eye shut. This can be dangerous, however, and he encourages doctors to exercise caution and carefully use the glue to avoid touching the globe and causing significant corneal and conjunctival damage.

While doctors can attempt to heal the defect, Dr. Rapuano says at the end of the day, “the best solution is closure of the eyelids by an oculoplastic surgeon.” ■

Earn up to
18-28 CE
Credits*

REVIEW GROUP
VISION CARE EDUCATION, LLC

NEW TECHNOLOGIES
& TREATMENTS IN
2019 EYE CARE



Join us for our
2019 MEETINGS



FEBRUARY 15-19, 2019 - ASPEN, CO

Annual Winter Ophthalmic Conference

Westin Snowmass Conference Center

Program Co-chairs: Murray Fingeret, OD, and Leo Semes, OD

REGISTER ONLINE: www.skivision.com



MARCH 7-10, 2019 - ORLANDO, FL

Disney Yacht & Beach Club

Program Chair: Paul Karpecki, OD, FAAO



APRIL 11-14, 2019 - SAN DIEGO, CA**

Manchester Grand Hyatt

Program Chair: Paul Karpecki, OD, FAAO



May 17-19, 2019 - NASHVILLE, TN

Gaylord Opryland

Program Chair: Paul Karpecki, OD, FAAO



NOVEMBER 1-3, 2019 - BALTIMORE, MD

Renaissance Baltimore Harborplace

Program Chair: Paul Karpecki, OD, FAAO

Visit our website for the latest information: www.reviewsce.com/events
e-mail: reviewmeetings@jhihealth.com or call: 866-658-1772

Administered by

Review Group Vision Care Education, LLC



*Approval pending



Pennsylvania College of Optometry



**16th Annual Education Symposium
Joint Meeting with NT&T in Eye Care

Review Group Vision Care Education, LLC partners with Salus University for those ODs who are licensed in states that require university credit.
See www.reviewsce.com/events for any meeting schedule changes or updates.



Re-think Autologous Serum

Clinicians are turning to this therapy earlier and more frequently, as new products make serum-derived tears easier to obtain and use. **By Paul M. Karpecki, OD**

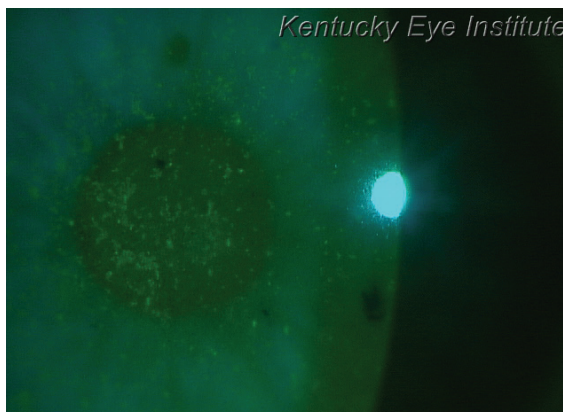
Autologous serum (AS) tears or autologous serum eye drops (ASEDs) are customized drops made from a patient's own blood diluted in sterile saline or hyaluronic acid. Because serum is composed of a complex mix of growth factors, proteins, antioxidants and lipids, it is more akin to the components of human tears and may provide a more effective replacement than manufactured tears. The lacrimal gland uses serum components to generate tear fluid, so it

makes intuitive sense that, in patients with malfunctioning lacrimal glands, we might be able to mimic that function by using serum in topical form.

The first use of AS tears was reported in 1975, and for the next 25 years or so, they were considered a last resort and used only by corneal specialists.¹ However, with today's advancements, they have been embraced by a wider range of clinicians and are being used earlier in the course of dry eye disease.

Evidence for AS tears

Research shows AS tears are more effective than conventional tears for improving tear film stability and subjective comfort in patients with severe dry eye.² They also provide statistically significant improvements in Schirmer's scores, tear film debris and goblet and epithelial cell density.³ In a California Kaiser Permanente population of mostly recal-



New autologous serum options make it more feasible for treating conditions such as superficial punctate keratitis, seen here in a patient with keratoconjunctivitis sicca.

citrant dry eye patients treated with AS tears as an insurance-covered benefit, patients had improved corneal staining and reduced dependence on artificial tears.⁴

AS tears are also effective at improving both the signs and symptoms of ocular surface disorders associated with systemic autoimmune diseases. In about 80% of patients with conditions such as Sjögren's syndrome (SS), mucous membrane pemphigoid, graft-vs.-host disease (GVHD), rheumatoid arthritis and other autoimmune disorders, the researchers demonstrated improvement in corneal staining, reduction in punctate epithelial erosions and persistent epithelial defects and improvements in subjective symptoms.⁵

This treatment modality can also accelerate corneal epithelial healing after surface ablation corneal refractive surgery and pterygium surgery.^{6,7}

Adoption Hurdles

Historically, challenges with AS tears have hindered their use. A recent Cochrane review of randomized controlled trials in which AS tears were used to treat patients with SS, non-SS dry eye and postoperative dry eye found inconsistencies in the literature and concluded that current evidence did not necessarily support a benefit; but the study data was based on only two weeks of treatment.⁸ Limited studies were available for review, and the

authors acknowledged that much more research is still needed.

Beyond scarce support, the modality poses patient-specific concerns. Patients must not have any blood-borne infectious conditions and have their blood drawn regularly. Once compounded, ASED vials must be kept frozen or refrigerated to avoid contamination, degradation of the components or both. Additionally, AS tears can be expensive and are not always covered by insurance.

Changing Paradigms

But as optometrists become more effective and more aggressive in treating ocular surface conditions, AS tears are rising in popularity. The International Task Force Delphi Panel on Dry Eye identified ASEAs as a recommended treatment for patients with level three disease, as opposed to only for level four (the most severe cases).⁹

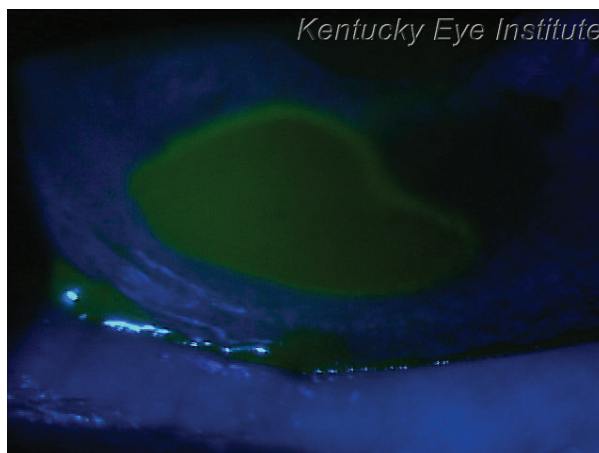
Beyond the therapy's clinical benefits, advances in the technology have been another major driver to the increased use of ASEs. The advent of self-retained cryopreserved amniotic membrane (Prokera, BioTissue) has put ASEs in a far more accessible package for in-office use. In my practice, for example, we move quickly to amniotic membrane for patients with persistent superficial punctate keratitis, recalcitrant recurrent corneal erosion, neurotrophic keratitis and neuropathic keratitis. We have even use it in earlier stages of dry eye with decreased vision, and almost always prescribe ASEs long-term in conjunction with amniotic membrane.

Additionally, AS tears have become much more accessible through compounding pharmacies and eye banks. Recently, Vital Tears in Kansas City, Mo., has become a nationwide source for ASEs. The company works with a network of facilities for local blood collection and coordinates production, quick delivery and billing. The drops are made to clinician specifications and available to patients on a short-term or ongoing subscription basis.

Other new approaches are in the pipeline as well. A biologic eye drop (Elate Ocular, Cambium Medical Technologies) for dry eye is currently in Phase II clinical trials. These are allogeneic, rather than autologous, human platelet-derived topical drops expected to be shelf-stable, eliminating the need for refrigeration. Sourcing serum from healthy young donors for these allogeneic serum tears may avoid elevated proinflammatory cytokine levels in the serum of patients with active autoimmune diseases.

Drops derived from umbilical cord serum—avoiding issues with donation of autologous serum—is also under investigation.¹⁰ Anecdotally, many patients with advanced ocular surface disease and dry eye disease have achieved significant relief with the use of commercially available amniotic cytokine extract (ACE) eye drops. Genesis drops (Ocular Science) BID have the potential to modulate corneal and conjunctival epithelial healing, as well as inflammation. Other researchers are investigating the use of platelet-rich plasma AS, which uses a portion of the patient's own blood that has a higher-than-normal platelet concentration, with the goal of creating a prolonged release of growth factors that are involved in the wound healing process.¹¹

Serum-derived and biologic-based eye drops are poised to make waves in our clinical approach to dry eye patients, and new options continue to crop up. In patients who can't make enough of their own tears because of advanced keratoconjunctivitis sicca, GVHD, SS and numerous other ocular surface diseases, the current therapies are essential—and are getting better by the day. ■



A neurotrophic ulcer, such as this one, can be treated quickly with an amniotic membrane to help promote healing.

ASE Facts

The serum concentration is most commonly 20% for dry eye disease patients, although higher concentrations of 40% or even 50% are often used in advanced conditions such as neurotrophic corneal ulcers. The drops are usually dosed anywhere from two to eight times per day, with six or Q2H being the most common, for the treatment of aqueous-deficient dry eye, neurotrophic keratitis or ocular surface disease secondary to systemic autoimmune syndromes.

Dr. Karpecki is a consultant/ advisor to: BioTissue, Cambium Medical Technologies, Vital Tears and Ocular Science.

1. Fox RI, Chan R, Michelson JB, et al. Beneficial effect of artificial tears made with autologous serum in patients with keratoconjunctivitis sicca. *Arthritis Rheum.* 1984;27(4):459-61.
2. Celebi AR, Ulusoy C, Mirza GE. The efficacy of autologous serum eye drops for severe dry eye syndrome: A randomized double-blink crossover study. *Graefes Arch Clin Exp Ophthalmol* 2014;252(4):619-26.
3. Jirsova K, Brejchova K, Krabцова I, et al. The application of autologous serum eye drops in severe dry eye patients; subjective and objective parameters before and after treatment. *Curr Eye Res* 2014;39(1):21-30.
4. Dalmon CA, Chandra NS, Jeng BH. Use of autologous serum eyedrops for the treatment of ocular surface disease: First US experience in a large population as an insurance-covered benefit. *Arch Ophthalmol.* 2012;130(12):1612-3.
5. Ali TK, Gibbons A, Cartes C, et al. Use of autologous serum tears for the treatment of ocular surface disease from patients with systemic autoimmune diseases. *Am J Ophthalmol.* 2018;189:65-70.
6. Akcam HT, Unlu M, Karaca EE, et al. Autologous serum eye-drops and enhanced epithelial healing time after photorefractive keratectomy. *Clin Exp Optom.* 2018;101(1):34-7.
7. Sul S, Korkmaz S, Alacamli G, et al. Application of autologous serum eye drops after pterygium surgery: A prospective study. *Graefes Arch Clin Exp Ophthalmol.* July 18, 2018. [Epub ahead of print].
8. Pan Q, Angelina A, Marrone M, et al. Autologous serum eye drops for dry eye. *Cochrane Database Syst Rev.* February 28, 2017.
9. Behrens A, Doyle JJ, Stern L, et al; Dysfunctional tear syndrome study group. Dysfunctional tear syndrome: A Delphi approach to treatment recommendations. *Cornea.* 2006;25:900-7.
10. Yoon KC, Heo H, Im SK, et al. Comparison of autologous serum and umbilical cord serum eye drops for dry eye syndrome. *Am J Ophthalmol* 2007;144(1):86-92.
11. Alio JL, Rodriguez AE, Wrobel Dudzinska D. Eye platelet-rich plasma in the treatment of ocular surface disorders. *Curr Opin Ophthalmol.* 2015;26(4):325-32.



Customize Your Steroid Choice

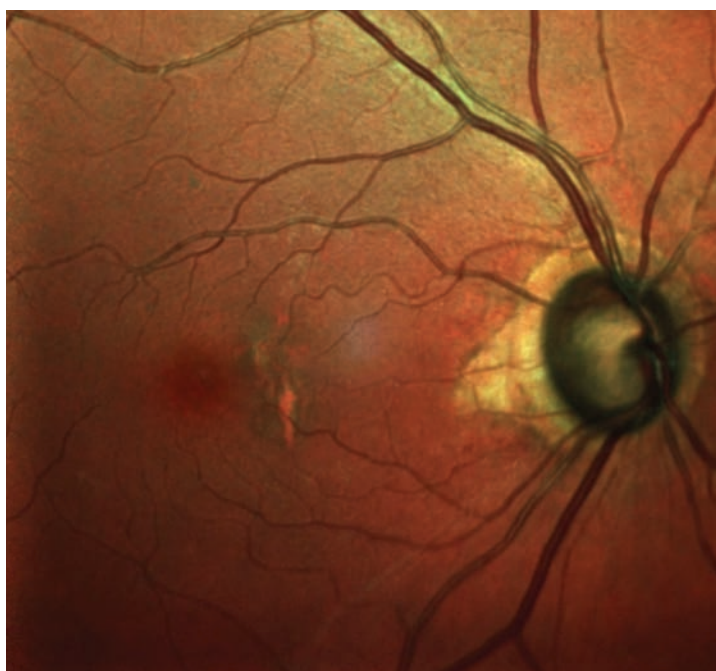
A glaucoma patient undergoes cataract surgery and develops elevated intraocular pressure. What is the best way to manage this situation?. **By James L. Fanelli, OD**

A 77-year-old Caucasian female glaucoma patient presented with complaints of gradually decreased visual clarity secondary to cataracts over the past two years. It was starting to negatively impact her quality of life, and it was time to proceed with cataract surgery.

This patient presented to me more than a decade earlier with advanced glaucoma as a new patient. She has been an ideal patient over the years, vigilant and compliant with her medications. As is the case with many long-standing glaucoma patients, she has had varied issues with ocular surface disease, exacerbated by topical anti-glaucoma medications. Following the pattern for such cases, we've modified medications over the years to provide her with reasonable comfort, as well as therapeutic efficacy in stemming the progression of the glaucoma.

Evaluation

During her preoperative work up, we first had to establish that her glaucoma was stable, and her ocu-



The patient's right eye, shows advanced glaucomatous damage and macular changes consistent with her age.

lar surface in good enough shape to undergo the planned bilateral cataract extractions. At this time, her systemic medications included only lisinopril and Prilosec (omeprazole, Procter & Gamble). Also at this time, best-corrected visual acuities were 20/50-OD and 20/40-2 OS, both decreasing significantly under glare conditions. The anterior segment was characterized by mild inferior superficial punctate keratitis (SPK), mild episcleral injection and a thin tear prism OU. This presentation was consistent with her anterior segment characteristics for the past

several years and was deemed acceptable for cataract surgery.

Applanation tensions at this visit were 12mm Hg OD and 13mm Hg OS, which were consistent long-term with her target pressures and at a level where there had been no progression of her glaucoma. Treated intraocular pressures (IOPs) were achieved by using Travatan Z (travoprost, Novartis) HS OU and 0.5% timolol QAM OU. She had been on this regimen for the past four and a half years.

Gonioscopy demonstrated open angles in both eyes with the scleral spur visible in most quadrants, and previous ultrasonic biomicroscopy demonstrated a slight plateau approach in both eyes.

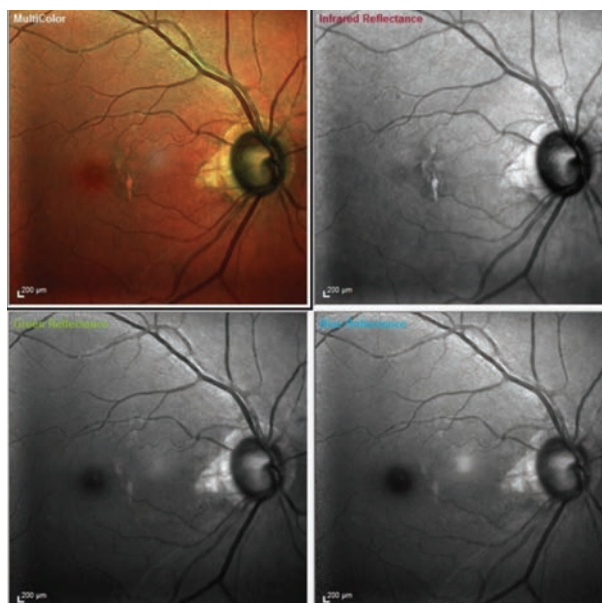
Through dilated pupils, her crystalline lenses were characterized by 2+ cortical spoking OU, mostly off the visual axis, as well as 2+ nuclear sclerosis OU and early PSC formation in the right eye more than the left. The onset of the posterior subcapsular cataracts in the previous six months contributed greatly to her decreased quality of life.

Her optic nerves were average sized and characterized by 0.8 x 0.9 cupping OD and 0.85 x 0.9 cupping OS. The temporal neuroretinal rims were thinned OU, and there was associated zone beta peripapillary atrophy temporally in both eyes.

In the past decade, the peripapillary atrophy had gradually increased, but fortunately we were able to stave off further neuroretinal rim damage by constant vigilance and medication modification when warranted. These optic nerve appearances were consistent with what she initially presented with as a new patient many years ago.

Previous visual fields demonstrated bilateral arcuate field defects encroaching fixation in the left eye more than the right, and were last completed six months prior. Heidelberg retina tomography and optical coherence tomography performed on the preoperative visit demonstrated no change as compared with previous scans in three important areas: the neuroretinal rim, the peripapillary retinal nerve fiber layer circle scans, and the macular ganglion cell analyses. Structurally, these images showed she was stable, and previous field studies demonstrated her functional stability.

Her macular evaluations were characterized by mild retinal pigment epithelium mottling in both eyes, consistent with her age, and no evidence of subretinal neovascular membrane formation. Her retinal vasculature was essentially unremarkable, as were the findings of her peripheral retinal evaluations.



A multi color composite image of the patients right eye is obtained through the use of three different wavelength laser images stacked on top of each other to provide a composite of the fundus. Each image highlights different layers of the retina. Infrared laser highlights the choroid, the green laser highlights the intraretinal layers and blue highlights the retinal nerve fiber layer. These help us see structural nuances that occur structurally in the retina in these various diseases.

Discussion

In evaluating preoperative cataract patients, make sure glaucoma patients are as well controlled as possible—and that ocular surface issues are addressed preoperatively. This patient was stable. The fact that she has been a compliant patient helps, as the addition of postoperative medications can complicate an already full regimen.

Post-cataract surgery medications will vary depending upon the surgeon, but typically include an antibiotic, nonsteroidal anti-inflammatory drugs (NSAIDs), and a steroid. For the particular surgeon this patient was sent to, the standard postoperative regimen includes Besivance (besifloxacin, Bausch + Lomb) BID x 2 weeks, Prolensa (bromfenac, Bausch + Lomb) QD x 4 weeks and Durezol (difuprednate, Novartis) BID for two weeks and tapered as inflammation subsides. With the use of fluoroquinolones and NSAIDs postoperatively, the course of care is pretty much the same whichever drugs are used. However, steroids can have significant, and

problematic, postoperative differences. In general, the postoperative steroid regimen will vary in one of three ways, and typically include Durezol, Pred Forte (prednisolone, Allergan) or Lotemax (loteprednol etabonate, Bausch + Lomb). They each have good and bad qualities for glaucoma patient undergoing cataract extraction.

Therapeutic Nuances

Glaucoma patients have a higher tendency to develop IOP spikes following the administration of topical steroids, and this must be kept in mind when seeing these patients postoperatively. In general, those steroids that are most likely to reduce inflammation are more likely to elevate IOP, especially in glaucoma patients. So, the dichotomy between side effects of IOP elevation, and anti-inflammatory effects, must be taken into consideration when managing glaucoma patients postoperatively.

Postoperative steroid dosing varies; with Durezol typically being dosed BID, Pred Forte QID and Lotemax QID. Given the tendency

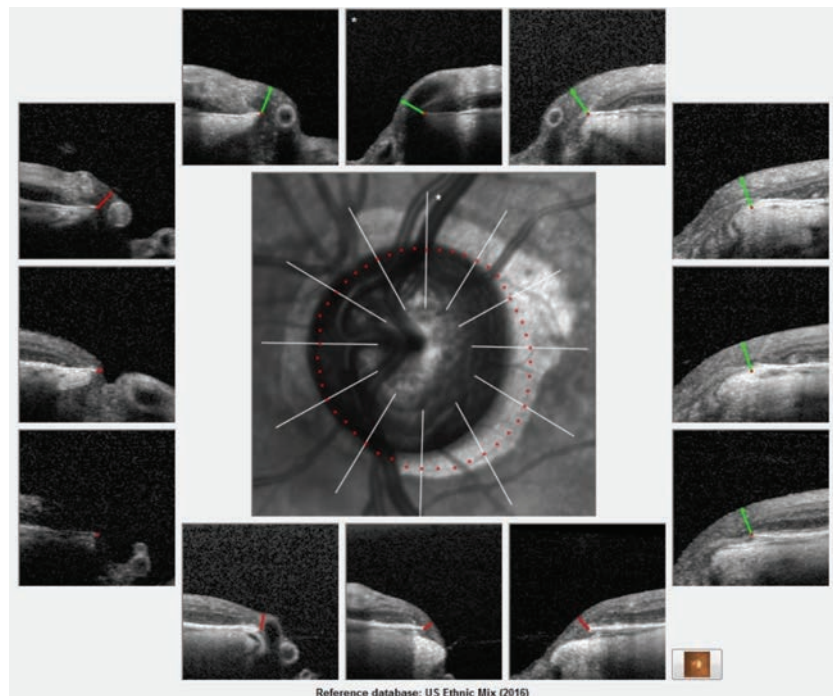
for Durezol to elevate IOP, this particular patient was given the following postoperative regimen: Besivance BID, Pred Forte QID, and Prolensa (bromfenac, Bausch + Lomb) QD. However, the patient was unable to obtain the Pred Forte, and was told to pick up a sample at the surgeon's office. When she arrived, she was given Durezol and her instruction sheet was not adjusted accordingly and so she took the steroid QID in the operated eye.

On her day five postoperative follow up visit, her visual acuity uncorrected was 20/30+, with minimal central corneal edema, negative Siedel sign, mild incisional bullous keratopathy, a quiet chamber with trace particle and trace cell only, and an IOP of 31mm Hg. She was using the all her medications appropriately.

When IOP spikes develop postoperatively in glaucoma patients, especially in patients with advanced disease (such as this patient), it is imperative to reduce IOP to prevent further damage to the already fragile neuroretinal rim. This can be accomplished by adding more pressure-reducing agents or reducing the offending steroid's dosing. Keep in mind, too, the postoperative inflammation must also be managed, which does require a steroid.

How can an optometrist balance these somewhat contradictory needs? In general, I prefer to use the fewest medications possible, so I would reduce the steroid.

By choosing the best steroid for the job initially, optometrists can mitigate steroids' postoperative side effects (assuming proper compliance and dosing). Personally, I insist the patient use Pred Forte, partially because it has less IOP elevation potential than some steroids and more anti-inflammatory effects



The Bruch's membrane overview printout for this patient shows advanced glaucomatous damage. This image helps get a 'global' picture of the neuroretinal rim. The actual scanning of the optic nerve obtains many more images and is more clinically detailed. Each scan measures the ganglion cells inside the optic nerve, specifically in the neuroretinal rim. A reduction in the thickness reading is consistent with progressive ganglion cell loss.

than others. But I also have a more important, more practical reason.

With Durezol (on a BID dosing schedule) if the patient experiences an IOP spike, you really only have two options to titrate down the dosage; either use the Durezol QD or stop it completely. Usually, cutting down the Durezol to once daily has minimal effect in reducing IOP, as even the QD dosing can keep pressure elevated. And stopping it in the immediate postoperative period is not a good idea either when considering inflammatory control.

On the other end of the spectrum is the option of Lotemax QID. While it won't usually elevate IOP as much as Durezol, it is a weak anti-inflammatory agent, and, in my experience, tapering Lotemax

too quickly can result in protracted anterior segment inflammation.

Pred Forte is my preferred postoperative steroid because it has good anti-inflammatory efficacy when dosed QID and can be decreased to TID, BID or QD to mitigate any intraocular pressure rises. In other words, clinicians have three options before discontinuing the medication, whereas with Durezol they only have a QD option, with minimal effect on lowering IOP.

Doctors can quickly find themselves painted into a corner, trying to manage inflammation and IOP spikes secondary to topical steroids. By choosing a steroid that supports numerous dosing schedules, you have more options at hand to control both issues. ■

Clinical Applications of the TFOS DEWS II Diagnostic Section

One of the best opportunities for any eye care practice is the effective management of dry eye disease (DED). It is estimated that as many as 90 million people suffer from symptoms of DED; yet, just 16 million individuals have been diagnosed, and only about 1.5 million of them are actively being managed with prescription agents.¹⁻³

Ask the Right Questions

If there are 90 million potential DED patients in the US, and we're diagnosing fewer than 20% of them, then we're not asking the right questions. My favorite four questions to ask of any patient over age 14—or any individual who spends more than two hours per day on a digital device—are:

- Do your eyes ever burn, or feel dry and irritated?
- Are your eyes red?
- Do you experience blurred and/or fluctuating vision?
- Do you use, or have the urge to use, artificial tears?

Asking these triaging questions on an intake form, or while patients wait in the reception area, certainly will help you identify those with DED.

The next step is to measure such responses against denotative risk factors for dry eye. Primary risk factors include—but are not limited to—smoking, contact lens wear, a history of refractive surgery, extensive daily screen time or the use of certain medications (e.g., anti-histamines). Between the subjective patient responses to the aforementioned questions and an evaluation of concurrent risk factors, you should have a clear indication of which patients are likely to have DED.

Diagnostic Testing

The next course of action is diagnostic testing for symptoms and signs. Dry eye disease symptoms can be measured and scored using a validated questionnaire, such as SPEED or DQ5. Signs, on the other hand, can be measured using tear film break-up time (TFBUT), ocular surface staining or tear film osmolarity testing. The subcommittee strongly recommended the use of non-invasive TFBUT, which can be performed using the OCULUS Keratograph® 5M, over use of vital dye. The Keratograph® 5M is also highly effective for evaluating ocular surface staining.

Differentiating Dry Eye Subtype

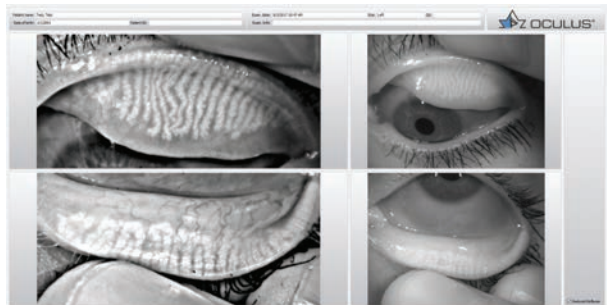
While TFBUT, ocular surface staining and tear film osmolarity are highly valuable, these tests do not help the clinician differentiate

I was honored to serve on the TFOS DEWS II Diagnostic Methodology Subcommittee. Here is a brief synopsis of clinical applications gleaned from that subcommittee section, with a specific focus on the incorporation of existing diagnostic technologies.



between evaporative and aqueous-deficient dry eye. To evaluate for evaporative DED, consider performing meibography using the Keratograph® 5M's Meibo-Scan function. Meibography should show all rows of glands present, without signs of atrophy or stress.

If necessary, mechanical gland expression can help improve ocular surface health. Healthy meibum should be clear and exhibit the



Meibography images of the top and bottom lids captured via the Keratograph® 5M's Meibo-Scan software.

viscosity of olive oil. In patients with significant gland obstruction, however, meibum typically is thick, off-color or granular.

To test for aqueous-deficient DED, perform an evaluation that assesses tear volume, such as tear meniscus height. This also can be measured using the Keratograph® 5M (as a baseline reference, normal tear meniscus height is greater than 0.2mm).

Once you've assessed the subtype of DED, you'll be able to more effectively tailor your treatment paradigm. I find this schematic to be logical, efficient, clinically applicable and highly effective. Diagnostic technologies like OCULUS' Keratograph® 5M can adequately address nearly every aspect of the TFOS DEWS II diagnostic algorithm.

Dr. Karpecki is Director of Cornea at the Kentucky Eye Institute, and is the Chief Medical Consultant for Review of Optometry. He is a paid consultant to OCULUS, Inc.

References

1. Wolffsohn JS1, Arita R2, Chalmers R, et al. TFOS DEWS II Diagnostic Methodology report. *Ocul Surf.* 2017 Jul;15(3):539-74.
2. Nichols KK1, Bacharach J2, Holland E, et al. Impact of Dry Eye Disease on Work Productivity, and Patients' Satisfaction With Over-the-Counter Dry Eye Treatments. *Invest Ophthalmol Vis Sci.* 2016 Jun 1;57(7):2975-82.
3. Paulsen AJ1, Cruickshanks KJ2, Fischer ME, et al. Dry eye in the beaver dam offspring study: prevalence, risk factors, and health-related quality of life. *Am J Ophthalmol.* 2014 Apr;157(4):799-806.



Light at the End of the Tunnel

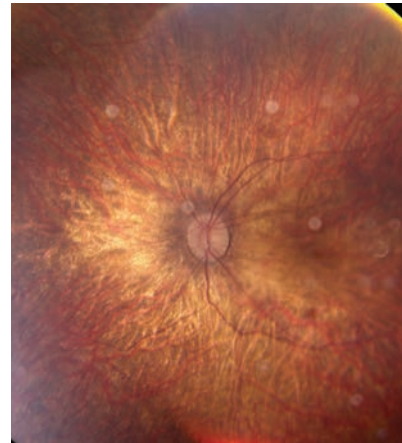
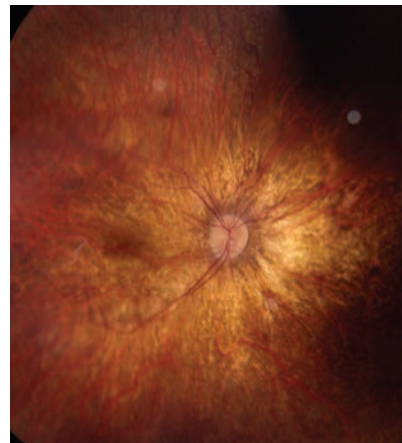
How can this pediatric patient's family history inform his diagnosis?

By Shreya Jayasimha, OD, and Mark T. Dunbar, OD

An eight-year-old Caucasian male presented with gradually progressive blurry vision in both eyes and the added difficulty seeing at night since early childhood. The patient reported that four of his maternal uncles experienced similar visual difficulties, which progressed with age. His ocular history is positive for a high myopic prescription, which began at age two and has progressed drastically every year. His medical history is positive for B-cell acute lymphoblastic leukemia in 2016, for which he received chemotherapy for two years. He is currently in medical remission and is closely monitored by his oncologist every three months. His social history is unremarkable.

On examination, best-corrected visual acuities were 20/60 OD, 20/80 OS with a prescription of -11.25 +3.00 x 107 OD, -9.25 +2.75 x 0975 OS. The patient's extraocular motility was full and smooth. Confrontation visual fields revealed a 360° peripheral constriction in both eyes. Pupils were equal, round and slowly reactive to light with no afferent pupillary defect in either eye.

Color vision, measured with Ishihara plates, was reduced for both eyes (7/10 OD, 8/10 OS). Intraocular pressures (IOPs) were 20mm Hg OD and 21mm Hg OS. Anterior segment health was unremarkable for both eyes. A dilated fundus examination revealed changes. Optical coherence tomog-



Right and left eyes of our young patient showing an ultra-widefield view of the posterior pole and periphery. What pathology could explain his blurry vision?

raphy (OCT) and visual fields were also performed.

Take the Retina Quiz

- Which statement best describes the fundus appearance of our patient?
 - Blonde fundus with a loss of the retinal pigment epithelium and choroid.
 - Vascular attenuation with disc pallor and increased choroidal show.
 - Diffuse outer retinal atrophy with exposed sclera, sparing the macula.
 - Vascular attenuation with surrounding angioid streaks.
- What is the likely diagnosis for this patient?
 - Fundus albipunctatus.
 - Retinitis pigmentosa.
 - Choroideremia.
 - Gyrate atrophy.

3. What is the underlying etiology of this condition?

- Infectious.
- Congenital.
- Inflammatory.
- Hereditary.

4. What is the most common first symptom of this condition?

- Progressive blurry vision.
- Nyctalopia.
- Reduced color vision.
- Loss of peripheral vision.

5. Based on the presentation, what is the appropriate next step?

- Monitor annually.
- Refer for an electroretinograph and genetic testing.
- Treatment with vitamin E supplements.
- Refer the patient to a low vision specialist.

For answers, see page 114.

Diagnosis

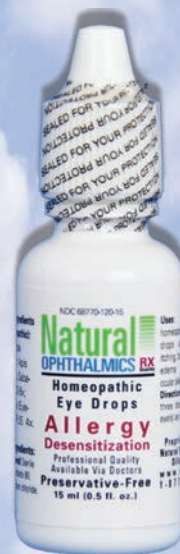Based on the history and clinical presentation, the patient was tentatively diagnosed with retinitis pigmentosa (RP) and sent for a full-field electroretinogram (ERG) as well as genetic testing to confirm the diagnosis. We also considered the possibility of choroideremia based on the fundus appearance; however, the ERG results revealed diffuse flattening of both the A and B waveforms, indicating reduced functioning of the photoreceptors and inner retinal cells (i.e., bipolar and Mueller cells) more consistent with RP.¹ In addition, genetic testing came back positive for a mutation in the RP2 gene. Based on the ERG findings and genetic testing, along with a strong family history of RP, we confirmed that our patient has x-linked recessive retinitis pigmentosa.

Retinitis pigmentosa is a group of genetic disorders with varying modes of inheritance, from autosomal dominant to x-linked recessive. It is a familial condition that causes bilateral, progressive vision loss typically in individuals between nine and 19 years old with no sex or race predilection.² Symptoms of RP include night blindness (most common), loss of peripheral vision, reduced color vision and blurred vision.^{3,4} Clinical signs of RP include a triad of a waxy optic disc pallor, vessel attenuation and perivascular bone-spicule pigmentation in the mid-periphery.³ Additional signs include diffuse RPE atrophy, cystoid macular edema, optic disc drusen (10% of cases), epiretinal membrane, vitreous condensation, keratoconus and posterior subcapsular cataracts (35% to 51% of cases).³ To date, this patient has presented with optic disc pallor and vessel attenuation with diffuse thinning of the retina secondary to myopic degeneration.

Discussion

An estimated 100,000 Americans have RP as a result of several genetic mutations.⁵ More than 60 mutated genes may cause RP, 20 of which are associated with the autosomal dominant form of this disorder.⁵ In contrast, mutations in about six genes contribute to the x-linked form of this condition. In fact, mutations in the RPGR and RP2 genes account for a majority of X-linked RP individuals, as is the case with this patient.⁵ The RP2 gene product mimics the human cofactor C-protein

Show me a better Allergy Eye Drop!!!



Allergy Desensitization Eye Drops

NatO drops vs Other drops

- Desensitization vs Suppression**
- Tear stimulation ingredient vs Dries out eyes**
- Great with contacts vs No contacts**
- Feel great/work fast vs Stings/burns**
- Non preserved Eye Drops vs Preserved**
- Inexpensive vs Expensive**
- No side effects vs Side effects**
- Safe for children vs Not for children**
- No contraindications vs Contraindications**
- No rebound vs Rebound**

Try a dozen bottles on your toughest allergy patients.

Call today 877-220-9710



Natural
OPHTHALMICS **RX**
Quality

www.NaturalEyeDrops.com

877-220-9710

AIR OPTIX® PLUS HYDRAGLYDE® CONTACT LENSES AND HYDRAGLYDE® LENS CARE*: GREAT COMFORT AND VISION FOR DIGITALLY CONNECTED STUDENTS AND YOUNG PROFESSIONALS



Dr. Chandra Mickles, OD, MS, FAAO, FSLs
Fort Lauderdale, FL

Dr. Mickles was compensated by Alcon for her participation in this advertorial.



One of my patients, a 20-something nurse who works long hours in a cool, dry assisted living facility, complained to me that, long before the end of her shift, her contact lenses grow too uncomfortable to continue wearing. I asked if she wanted to switch to daily disposables, but she preferred to continue with a monthly replacement schedule, having worn monthly replacement lenses most of her life. Another patient—a 17-year-old young man new to contact lenses—only stopped using his smartphone long enough for me to examine his eyes, telling me he needed to finish his homework before basketball practice later that evening. When I asked how much time he spent using the phone each day, he barely hesitated before telling me, “Almost all the time, except during practice.”

I often hear of similar patient experiences. A large percentage of my patients are students and young professionals who lead very active lives, often involving intense, prolonged concentration on digital devices, long hours working or studying, extra-curricular sports/exercise, and full social schedules. Demanding visual activities, though, can stress the contact-lens-wearing eye by destabilizing the tear film, which in turn can contribute to contact-lens-related dryness and discomfort.¹ My nurse patient was already complaining of limited comfortable wear time, and I knew that the student’s digital device use could lead to a poor experience if not in the right lenses. Both cost-conscious patients wanted a monthly replacement lens that provides exceptional comfort and vision throughout the day, each day for the full wearing period.

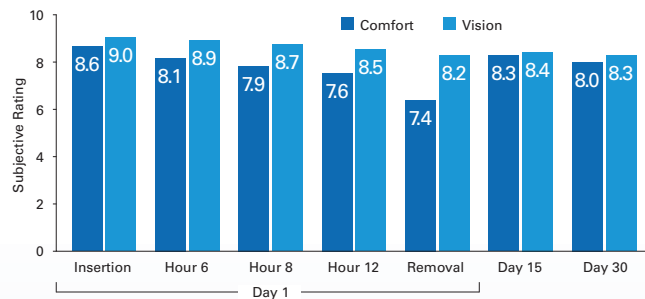
The solution for both was AIR OPTIX® plus HydraGlyde® contact lenses, my go-to choice for patients who prefer a monthly-replacement schedule. These lenses incorporate two unique technologies—SmartShield® for excellent deposit resistance^{2,4} and the HydraGlyde® Moisture Matrix wetting agent—into one outstanding lens. AIR OPTIX® plus HydraGlyde® contact lenses have demonstrated excellent lens-surface wettability and tear film stability in laboratory and clinical studies.^{4,8}

Additionally, HydraGlyde® Moisture Matrix technology is also found in CLEAR CARE® PLUS Cleaning & Disinfecting Solution and OPTI-FREE® PureMoist® Multi-Purpose Disinfecting Solution. Using either of these solutions daily can maintain the lens surface-moisture benefits of AIR OPTIX® plus HydraGlyde® contact lenses^{5,8}—

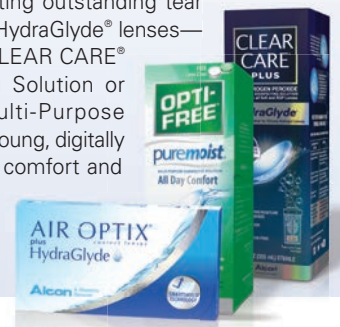supporting outstanding comfort and excellent vision from Day 1 to Day 30 (Figure 1).⁹ And the nurse, who needed more comfortable wear time during her long work shifts, was pleased to hear that these HydraGlyde®-containing lens care solutions increased hours of comfortable wear in symptomatic AIR OPTIX® lens wearers, compared to habitual multipurpose solutions.⁹⁻¹¹

Figure 1: Average subjective comfort and vision ratings of AIR OPTIX® plus HydraGlyde® contact lenses⁹

(1=poor, 10=excellent; n = 75)⁹



Patient preference plays a strong role in lens choice, and in another recent survey, 4X as many patients preferred AIR OPTIX® plus HydraGlyde® versus their habitual lenses after trying them for 1 month.¹² Since the cost of premium daily disposable lenses may be prohibitive to cost-conscious patients like students and young professionals, the trick is to find a monthly replacement lens that can offer them that “Wow!” factor. For my patients, that monthly replacement lens is AIR OPTIX® plus HydraGlyde®. With excellent lens surface wettability supporting outstanding tear film stability,^{4,8} AIR OPTIX® plus HydraGlyde® lenses—paired with daily use of either CLEAR CARE® PLUS Cleaning & Disinfecting Solution or OPTI-FREE® PureMoist® Multi-Purpose Disinfecting Solution—offer my young, digitally connected patients month-long comfort and vision that keeps up with their active lifestyles,⁹ helping them to see, look and feel their best!



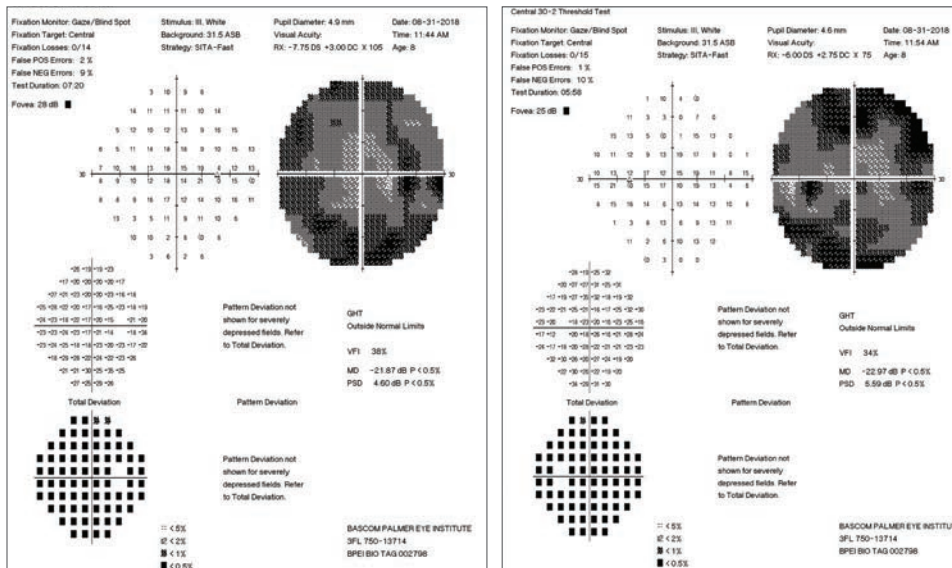
[†] The surveyed patients used OPTI-FREE® PureMoist® or CLEAR CARE® Plus with HydraGlyde® lens care solutions throughout the survey period.

*AIR OPTIX® plus HydraGlyde® lenses cleaned and disinfected daily with either CLEAR CARE® PLUS Cleaning & Disinfecting Solution or OPTI-FREE® PureMoist® Multi-Purpose Disinfecting Solution.

Important information for AIR OPTIX® plus HydraGlyde® (lotrafilcon B) contact lenses: For daily wear or extended wear up to 6 nights for near/far-sightedness, presbyopia and/or astigmatism. Risk of serious eye problems (i.e., corneal ulcer) is greater for extended wear. In rare cases, loss of vision may result. Side effects like discomfort, mild burning or stinging may occur.

References 1. Nichols JJ, Willcox MD, Bron AJ, et al; members of the TFOS International Workshop on Contact Lens Discomfort. The TFOS International Workshop on Contact Lens Discomfort: executive summary. *Invest Ophthalmol Vis Sci.* 2013;54:TFOS7-TFOS13. 2. Nash W, Gabriel M. Ex vivo analysis of cholesterol deposition for commercially available silicone hydrogel contact lenses using a fluorometric enzymatic assay. *Eye Contact Lens.* 2014;40:277-282. 3. Nash W, Gabriel M, Mowrey-McKee. A comparison of various silicone hydrogel lenses; lipid and protein deposition as a result of daily wear. *Optom Vis Sci.* 2010;87:E-abstract 105110. 4. Lemp J, Kern J. On-eye performance of lotrafilcon B lenses packaged with a substantive wetting agent. Poster presented at Optometry’s Meeting, the Annual Meeting of the American Optometric Association; June 21-25, 2017; Washington, D.C. 5. Lemp J, Muya L, Driver-Scott A, Alvord L. A comparison of two methods for assessing wetting substantivity. Poster presented at: 2016 Global Specialty Lens Symposium (GSLs); January 21-24, 2016; Las Vegas, NV. 6. Marx S, Sickenberger V. Wettability of different silicone hydrogel lens materials and blister solutions measured using non-invasive keratographic drying up time (NIK-DUT). *Optom Vis Sci.* 2016;93:E-abstract 165113. 7. Tucker R, Lemp J, Guillon M. In vitro and on eye wettability of lotrafilcon B lenses packaged with a substantive wetting agent. *Invest Ophthalmol Vis Sci.* 2017;58:ARVO E-Abstract 3070. 8. Alcon data on file, 2017. 9. Garofalo R, Lemp J. Clinical trial experience with OPTI-FREE PUREMOIST MPDS. *Contact Lens Spectrum.* 2011; 26:Part SPI 44-48. 10. Alcon data on file, 2011. 11. Alcon data on file, 2016. 12. Merchea M, Matthew J, Mack C. Assessing satisfaction with lotrafilcon B packaged with an EOBO wetting agent combined with EOBO-based lens care solutions. Poster presented at American Academy of Optometry annual meeting, 11-14 October 2017; Chicago, IL. Poster 143.





These 30-2 visual fields showing significant loss of the peripheral fields in each eye.

involved in beta-tubulin folding.^{3,5} Mutations in this gene result in an accumulation of incorrectly folded tubulin isoforms resulting in subsequent cellular death and progressive retinal degeneration.^{3,5}

Imaging

Multimodal imaging can help diagnosis. In RP patients, fundus autofluorescence typically displays an abnormal hyperautofluorescence as a result of lipofuscin accumulation from increased phagocytosis of photoreceptor outer segments.² The presence of a hyperautofluorescent macular ring is classic in RP patients and represents the transitional zone between healthy and dying photoreceptors.^{2,3} Over time, this ring constricts with the advancement of this disorder and can be used as an indicator of progression. OCT can also help to identify signs of RP. With the progression of this disorder, OCT shows a disruption of the ellipsoid band and a thinning of the outer nuclear layer due to photoreceptor cell loss.^{2,6} This, in conjunction with full-field ERG as well as

genetic testing, contributes pieces to the puzzle and allows for a more comprehensive diagnosis.

For a majority of cases, RP is an isolated disorder (simple or non-syndromic). However, it can be associated with systemic conditions, such as Usher's syndrome, Bardet-Biedl syndrome, Cockayne's syndrome, Alstrom's disease abetalipoproteinemia and more.⁶ In this case, the patient only had an isolated form of this disorder with no evidence of systemic associations.

Treatment

RP presently has no cure. In 2012, three peer-reviewed clinical studies reported that a combined regimen of 15,000 IU of vitamin A palmitate, oily fish and lutein can help slow the rate of visual acuity lost per year by RP patients by preserving retinal function.^{2,3} Oily fish contributes a rich omega-3 diet, of which docosahexaenoic acid (DHA) is a major constituent. This treatment method, however, is controversial in children and no specific studies focus on the more-aggressive x-linked RP.³ Nevertheless, a

clinical trial evaluating the benefits of DHA in people with x-linked RP is currently underway.⁶

For advanced cases of RP, the Argus II retinal prosthesis, a surgically implanted device, is being used to deliver electrical stimulation to the retina to restore visual perception.^{2,3} However, the effectiveness of this device is yet to be demonstrated. Retinal stem cell treatment for RP patients is in its Phase I/IIa safety trial.⁶ The basis of this treatment is to inject retinal progenitors (similar to stem cells) into the vitreous with the hopes of rescuing and reactivating the recipient's photoreceptors before they die.⁶ However, this study is still in its nascency and has yet to be tested for all forms of RP.

Our patient was referred to the Miami Lighthouse for the Blind for solutions to optimize visual performance and is being monitored on an annual basis with visual fields and OCT imaging. ■

Our patient was referred to the Miami Lighthouse for the Blind for solutions to optimize visual performance and is being monitored on an annual basis with visual fields and OCT imaging. ■

Dr. Jayasimha is doing a residency in ocular disease at Bascom Palmer Eye Institute in Miami.

- Creel D. The electroretinogram and electro-oculogram: clinical applications. Webvision: The Organization of the Retina and Visual System. webvision.med.utah.edu/book/electro-physiology/the-electroretinogram-clinical-applications. July 14 2015. Accessed September 9, 2018.
- Fahim A, Daiger S, Weleber R. Retinitis pigmentosa overview. Gene Reviews. www.ncbi.nlm.nih.gov/books/NBK1417/. March 21, 2013. Accessed September 9, 2018.
- Hamel C. Retinitis pigmentosa. OJRD. ojrd.biomedcentral.com/articles/10.1186/1750-1172-1-40. October 11 2006. Accessed Sept. 9, 2018.
- Iannaccone A, Berdia J. Retinitis pigmentosa. National Organization of Rare Disorders. rarediseases.org/rare-diseases/retinitis-pigmentosa. July 05, 2016. Accessed Sept. 9, 2018.
- Ferrari S, Di Iorio E, Barbaro V, et al. Retinitis pigmentosa: genes and disease mechanisms. *Curr Genomics*. 2011 Jun;12(4):238-49.
- Klassen H. Groundbreaking stem cell treatment for retinitis pigmentosa. JCyte. icyte.com/our-mission. July 01, 2018. Accessed September 9, 2018.

Optometry CE Study Center



The CE You Need In 2018!

As low as
\$17.50
per Credit Hour

Buy just one 2-hour course for \$35 or buy as many as you need

Choose from over 50 individual CE courses

Includes the hard to find topics that fulfill your state requirements

All available in a convenient online format

Purchase Now!

www.reviewsce.com

The CE Study Center courses have been developed in conjunction with expert faculty from leading schools of optometry and are oriented toward clinical practice issues that are designed to assist eye care professionals in serving their patient's healthcare needs. CE Courses also appear in print monthly in Review of Optometry.

1-800-825-4696 • INFO@REVIEWSCE.COM

These COPE-Accredited CE courses are administered in partnership with an accredited school of optometry.





Stressed Out

When “type A” patients come under pressure, their eyes can pay the price.

By Joseph W. Sowka, OD

A 28-year-old male presented to the office complaining of painless vision loss in his left eye for the past week. He can still see, but notices distortions in his vision. At first, he attributed his problem to extreme amounts of reading and other near work leading to “eye strain.” He thought that things would get better on their own, but when he noticed the doorframe in his home appeared ballooned out “like a pincushion,” he immediately sought care.

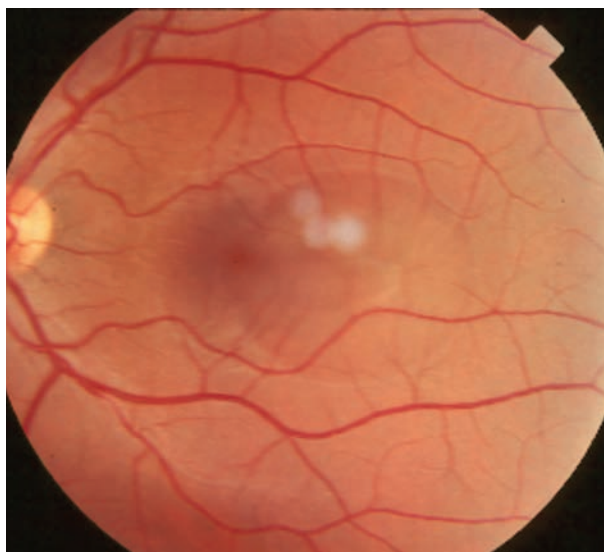
Examination

His entering uncorrected visual acuities were 20/25 OD and 20/40 OS, with both eyes improving to 20/20 with pinhole. Subsequent refraction also yielded 20/20 acuity in each eye, but with a -0.50 DS lens for the right eye and a +0.1.00 DS for the left.

The remainder of his external examination was normal and a dilated fundus examination showed all his right eye’s structures were normal; however, a large, bullous sensory macular detachment was visible in the left eye. He was subsequently diagnosed with central serous chorioretinopathy (CSC).

With a diagnosis in hand, he was further questioned regarding possible etiologies.

He denied use of any type of steroid but, when asked about his vocation, he explained that he was a law school graduate under tremendous anxiety as he studied for the bar exam.



This patient’s fundus photo shows a large paracentral central serous chorioretinopathy. This pathology can cause sudden-onset blurred vision and decreased color perception in addition to other complaints.

Discussion

Patients with CSC usually present with complaints of sudden onset distortion or blurring of central vision. They may report metamorphopsia, decreased color perception or even a relative central scotoma.¹⁻³ Patients often report a history of using corticosteroids (topical, injectable or oral), sympathomimetic agents or medications for erectile dysfunction.¹⁻⁹ If such a history is not offered, it is crucial to specifically ask about these associations. Other contributory elements may include antibiotics, uncontrolled hypertension, alcohol, allergic respiratory disease and obstructive sleep apnea.^{2,10} However, steroids are the greatest exogenous precipitating factor.²

Patients with CSC are typically between the ages of 25 and 50.^{11,12} Men are afflicted far more frequent-

ly than women, with an incidence ratio of about 6:1.^{1,2,12-15} Perhaps the most well-known association with CSC is the psychological profile known as “type A” personality. These individuals, who are described as exhibiting the characteristics of time urgency, aggressiveness, hostility and competitiveness, seem to be particularly predisposed to developing CSC.¹⁶⁻¹⁹

Mild hyperopic refractive shift (+1.25D or less) is often noted in the affected eye. Funduscopic exam shows a distinct, round or oval serous elevation of the macula with a loss of the foveal light reflex. An underlying area of retinal pigment epithelium (RPE) detachment may be seen concurrently in about 10% of patients, and this may easily be missed without optical coherence tomography (OCT).^{20,21} The possibility of choroidal neovascularization

(CNV) exists as well, and these cases are typically associated with a poor visual outcome.^{22,23}

CSC appears to have a multifactorial etiology, with various systemic associations and a complex pathogenesis. The primary dysfunction appears to be localized ischemia or inflammation at the level of the choriocapillaris, which leads to hyperpermeability; this in turn results in decompensation of the RPE, causing a focal detachment of the overlying neurosensory retina.^{19,20} Biochemical changes are likely at the root of this process. In patients with CSC, serum levels of catecholamines and glucocorticoids appear elevated, directly influencing the integrity of Bruch's membrane.^{17-19,24} Stimulation of adrenergic receptors often results in release of secondary messengers (e.g., cyclic adenosine monophosphate), and this may produce the vascular or RPE changes that result in CSC.²⁵

Therapies

Most cases of CSC are fortunately self-limiting over a period of three to 12 months.^{1,11} The prognosis for visual recovery is excellent, with most regaining their pre-event acuity. Upon diagnosing the condition, any corticosteroid therapy should be immediately discontinued, if possible, as 90% of CSC cases resolve spontaneously following the cessation of steroids.²⁶ While the acute phase of CSC is usually self-limiting, the condition may be recurrent in as many as 50% of affected individuals.²⁷

In non-remitting or recurrent cases, focal laser photocoagulation has been used in an attempt to arrest the leakage.²⁸ However, focal laser therapy does not necessarily ensure improvement in visual acuity; it merely hastens recovery and possibly diminishes the likelihood of

recurrence.^{1,28} There are risks associated with this treatment, most notably laser damage to the fovea and subsequent CNV formation.^{1,23,24}

For these reasons, most will employ laser therapy only in cases that fail to respond within a reasonable period of time, recurrent cases or cases in which the patients are overtly symptomatic and insist on definitive treatment. Others will avoid laser for fear of further disrupting the RPE/Bruch's complex and have felt that this treatment is like "putting fertilizer on a weed."

Photodynamic therapy (PDT) with Visudyne (verteporfin, Bausch + Lomb) has also been used successfully in the treatment of CSC; research shows it improves visual acuity, reduces leakage on fluorescein angiography, reduces subretinal fluid as demonstrated by OCT, and fosters choroidal remodeling with decreased choroidal permeability.^{29,30} While PDT has promising results, this treatment has limitations. First, CSC is not an approved use for PDT; thus, most insurances will not cover a treatment costing approximately \$2,000. Also, the laser used is no longer sold or readily available. No compelling evidence at this time shows intravitreal injections of anti-VEGF drugs improves outcomes in CSC.³¹

Future Therapy

A potential therapy in the pipeline is the potassium-sparing diuretic Aldactone (spironolactone, Pfizer), a mineralocorticoid receptor antagonist. Aldactone is used to treat primary hyperaldosteronism, in which the body produces excess amounts of the hormone aldosterone, regulating sodium and water levels. Aldactone treats fluid retention in people with congestive heart failure, cirrhosis of the liver and nephrotic syndrome. This medication is also used

to treat or prevent hypokalemia.

In a study of acute CSC patients treated with spironolactone (40mg orally, twice daily) for two months compared with an observational group, investigators saw a faster resolution in the orally treated group.³² Additionally, in eyes with persistent CSC, Aldactone therapy was associated with a statistically significant improvement in subretinal fluid as well as visual acuity.³³ Another report confirmed a positive effect of spironolactone in non-resolving CSC and good results in patients with recurrent CSC who responded to spironolactone initially.³⁴

It appears that a good clinical response and low cost makes Aldactone a reasonable option for patients with CSC. There are, however, some adverse effects including decreased libido and male gynecomastia. In that CSC often has a good prognosis for spontaneous recovery, these effects must be considered.

The patient presented here, once educated on his treatment options, elected to be observed only. The good news was that over several weeks, the CSC lesion resolved without complications commensurate with his passing the bar. The bad news was that he plans to specialize in malpractice litigation. Sigh. ■

1. Ross A, Ross AH, Mohamed Q. Review and update of central serous chorioretinopathy. *Curr Opin Ophthalmol*. 2011;22(3):166-73.
2. Haimovici R, Koh S, Gagnon DR, et al. Risk factors for central serous chorioretinopathy: a case-control study. *Ophthalmology*. 2004;111(2):244-9.
3. Kleinberger AJ, Patel C, Lieberman RM, Malkin BD. Bilateral central serous chorioretinopathy caused by intranasal corticosteroids: a case report and review of the literature. *Laryngoscope*. 2011;121(9):2034-7.
4. Baurnal CR, Martidis A, Truong SN. Central serous chorioretinopathy associated with periocular corticosteroid injection treatment for HLA-B27-associated iritis. *Arch Ophthalmol*. 2004;122(6):926-8.
5. Fernandez CF, Mendoza AJ, Arevalo JF. Central serous chorioretinopathy associated with topical dermal corticosteroids. *Retina*. 2004;24(3):471-4.
6. Koyama M, Mizota A, Igarashi Y, et al. Seventeen cases of central serous chorioretinopathy associated with systemic corticosteroid therapy. *Ophthalmologica*. 2004;218(2):107-10.
7. Fraunfelder FW, Fraunfelder FT. Central serous chorioretinopathy associated with sildenafil. *Retina*. 2008;28(4):606-9.
8. Gordon-Bennett P, Rimmer T. Central serous chorioretinopathy following oral tadalafil. *Eye (Lond)*. 2012;26(1):168-9.



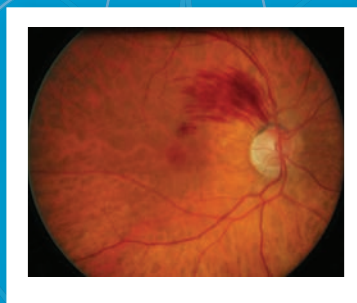
**“All of our doctors love Acuity Pro.
Fantastic Product!”**

- Dan McQueen, OD



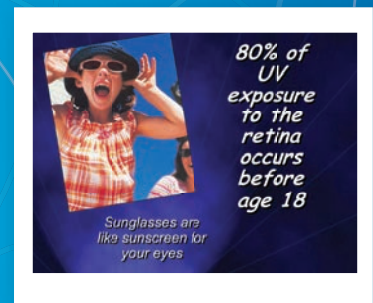
**INCREASE REFRACTION
SPEED AND ACCURACY**

- Instantly change charts and randomize optotypes.
- Instantly switch from multi-row to single row to shorter single row.
- Create macros to customize sequences.



**INCREASE SPEED OF
PATIENT EDUCATION**

Acuity Pro was the first digital chart to incorporate patient education libraries for rapidly switching from acuity testing to patient education. We include 50 common pathology images. You can add as many as you wish.



**BRAND & MARKET YOUR
PRACTICE FROM THE CHAIR**

Educate while they wait. Our 200 included practice and product promotion slides are just the beginning. Create custom slides that speak to your patient population and promote your specialties and social media presence.

SLOAN / SNELLEN / NUMBERS / CONTRAST SENSITIVITY / HOTV / ALL ETRDS CHARTS / WHITE ON BLACK OPTION / VIDEO LIBRARY / SINGLE LETTER - SINGLE LINE - MULTI-LINE / 56 KEY CUSTOM REMOTE / MARCO INTEGRATION / INFINITE OR LIMITED RANDOMIZATION OPTIONS / ALL IN ONE SYSTEMS OR SOFTWARE ONLY / FREE SUPPORT/ NO ANNUAL FEES

DISASTER PROOF BY DESIGN - 580.243.1301 / ACUITYPRO.COM



USED ON BOARD THE INTERNATIONAL SPACE STATION AND IN OVER 20 COUNTRIES ON EARTH

VISIT US AT AMERICAN ACADEMY OF OPHTHALMOLOGY OCT 27-30 BOOTH #3167 CHICAGO
AMERICAN ACADEMY OF OPTOMETRY NOVEMBER 7-9 BOOTH #1823 SAN ANTONIO

Therapeutic Review

9. Michael JC, Pak J, Pulido J, et al. Central serous chorioretinopathy associated with administration of sympathomimetic agents. *Am J Ophthalmol.* 2003;136(1):182-5.
10. Kloos P, Laube I, Thoelen A. Obstructive sleep apnea in patients with central serous chorioretinopathy. *Graefes Arch Clin Exp Ophthalmol.* 2008;246(9):1225-8.
11. Marcuson J, Riley T. Central serous chorioretinopathy. *Optometry.* 2008;79(5):241-51.
12. Kitzmann AS, Pulido JS, Diehl NN, et al. The incidence of central serous chorioretinopathy in Olmsted County, Minnesota, 1980-2002. *Ophthalmology.* 2008;115(1):169-73.
13. Todd KC, Hainsworth DP, Lee LR, et al. Longitudinal analysis of central serous chorioretinopathy and sex. *Can J Ophthalmol.* 2002;37(7):405-8.
14. How AC, Koh AH. Angiographic characteristics of acute central serous chorioretinopathy in an Asian population. *Ann Acad Med Singapore.* 2006;35(2):77-9.
15. Desai UR, Alhalel AA, Campen TJ, et al. Central serous chorioretinopathy in African Americans. *J Natl Med Assoc.* 2003;95(7):553-9.
16. Yannuzzi LA. Type A behavior and central serous chorioretinopathy. *Trans Am Ophthalmol Soc.* 1986;84:799-845.
17. Wynn PA. Idiopathic central serous chorioretinopathy—a physical complication of stress? *Occup Med (Lond).* 2001;51(2):139-40.
18. Zakir SM, Shukla M, Simi ZU, et al. Serum cortisol and testosterone levels in idiopathic central serous chorioretinopathy. *Indian J Ophthalmol.* 2009;57(6):419-22.
19. Gemenetzi M, De Salvo G, Lotery AJ. Central serous chorioretinopathy: an update on pathogenesis and treatment. *Eye (Lond).* 2010;24(12):1743-56.
20. Mudvari SS, Goff MJ, Fu AD, et al. The natural history of pigment epithelial detachment associated with central serous chorioretinopathy. *Retina.* 2007;27(9):1168-73.
21. Chang MA, Bressler SB. Photodynamic therapy for chronic pigment epithelial detachment in central serous chorioretinopathy. *Can J Ophthalmol.* 2009;44(2):221-2.
22. Shanmugam MP, Bhende M. Retinal pigment epithelial tears associated with idiopathic central serous chorioretinopathy. *Indian J Ophthalmol.* 2000;48(4):315-7.
23. Konstantinidis L, Mantel I, Zografos L, Ambresin A. Intravitreal ranibizumab in the treatment of choroidal neovascularization associated with idiopathic central serous chorioretinopathy. *Eur J Ophthalmol.* 2010;20(5):955-8.
24. Chan WM, Lai TY, Liu DT, Lam DS. Intravitreal bevacizumab (avastin) for choroidal neovascularization secondary to central serous chorioretinopathy, secondary to punctate inner choroidopathy, or of idiopathic origin. *Am J Ophthalmol.* 2007;143(6):977-983.
25. Sun J, Tan J, Wang Z, et al. Effect of catecholamine on central serous chorioretinopathy. *J Huazhong Univ Sci Technolog Med Sci.* 2003;23(3):313-6.
26. Sharma T, Shah N, Rao M, et al. Visual outcome after discontinuation of corticosteroids in atypical severe central serous chorioretinopathy. *Ophthalmology.* 2004;111(9):1708-14.
27. Wong R, Chopdar A, Brown M. Five to 15 year follow-up of resolved idiopathic central serous chorioretinopathy. *Eye (Lond).* 2004;18(3):262-8.
28. Lim JW, Kang SW, Kim YT, et al. Comparative study of patients with central serous chorioretinopathy undergoing focal laser photocoagulation or photodynamic therapy. *Br J Ophthalmol.* 2011;95(4):514-7.
29. Taban M, Boyer DS, Thomas EL, et al. Chronic central serous chorioretinopathy: photodynamic therapy. *Am J Ophthalmol.* 2004;137(6):1073-80.
30. Chan WM, Lam DS, Lai TY, et al. Choroidal vascular remodelling in central serous chorioretinopathy after indocyanine green guided photodynamic therapy with verteporfin: a novel treatment at the primary disease level. *Br J Ophthalmol.* 2003;87(12):1453-8.
31. Salehi M, Wenick AS, Law HA, et al. Interventions for central serous chorioretinopathy: a network meta-analysis. *Cochrane Database Syst Rev.* 2015 Dec 22;(12):CD011841.
32. Sun X, Shuai Y, Fang W, et al. Spironolactone versus observation in the treatment of acute central serous chorioretinopathy. *Br J Ophthalmol.* 2018;102(8):1060-5.
33. Falavarjani KG, Amirsardari A, Habibi A, et al. Visual and Anatomical Outcomes of Spironolactone Therapy in Patients with Chronic Central Serous Chorioretinopathy. *J Ophthalmic Vis Res.* 2017;12(3):281-9.
34. Herold TR, Rist K, Priglinger SG, et al. Long-term results and recurrence rates after spironolactone treatment in non-resolving central serous chorioretinopathy (CSCR). *Graefes Arch Clin Exp Ophthalmol.* 2017;255(2):221-9.

Hiring Optical Staff?

More Opticians, Insurance Specialists, and other optical staff find jobs on Local Eye Site than anywhere else.

Save 20% on your job listing with coupon code **REVOPT**

localeyesite.com



Local Eye Site
JOBS IN EYE CARE

Earn up to
**20 CE
Credits***

ANNUAL • EST. 1976

WINTER OPHTHALMIC CONFERENCE

A REVIEW GROUP VISION CARE EDUCATION, LLC MEETING OF CLINICAL EXCELLENCE

THE LONGEST RUNNING WINTER CE MEETING IN EYE CARE!

FEBRUARY 15-19, 2019

Join Review Group Vision Care Education, LLC in Aspen, CO, for the 2019 Winter Ophthalmic Conference. This meeting features relevant topics in glaucoma, dry eye, external disease and retina.

WESTIN SNOWMASS CONFERENCE CENTER

100 Elbert Lane
Snowmass Village, CO 81615
Phone: 970-923-8200

CONTINUING EDUCATION:

- Earn up to 20 hours of COPE CE* credits
- **Registration cost: \$575**
- **Single day registration is available**
- Visit www.skivision.com for meeting agenda

THREE WAYS TO REGISTER

online: www.skivision.com
e-mail: reviewmeetings@jhihealth.com
call: 866-730-9257

See event website for all accommodations and rates.

MEETING CO-CHAIRS:



Murray Fingeret, OD, FAAO



Leo Semes, OD, FACMO, FAAO

SPEAKERS:

Jack Cioffi, MD
Mark Dunbar, OD, FAAO
Ben Gaddie, OD, FAAO
Elise Kramer, OD, FAAO
Ron Melton, OD, FAAO
Andrew Morgenstern, OD, FAAO
Jack Schaeffer, OD, FAAO
Randall Thomas, OD, MPH, FAAO

Administered by
Review Group Vision Care Education, LLC



Review Group Vision Care Education, LLC partners with Salus University for those ODs who are licensed in states that require university credit.

Earn up to
11 CE
Credits*

SAVE THE DATE!

The Optometric Retina Society &
Review Group Vision Care Education Present

RETINAUPDATE 2018

November 30 - December 1 • Scottsdale, AZ



FAIRMONT SCOTTSDALE

7575 E Princess Drive
Scottsdale, AZ 85255
480-585-4848

A limited number of rooms have been reserved at \$259/night plus applicable taxes. Make your reservations with the hotel at 1-800-344-4758, mention "Review's Optometric Retina Society Meeting" for group rate.

REGISTRATION COST:

ORS Member: \$405 Non-member: \$450

PROGRAM CHAIRS: Steven Ferrucci, OD, FAAO
Mohammad Rafieetary, OD, FAAO

FACULTY: Mark Barakat, MD; Jeffry Gerson, OD, FAAO;
Leo Semes, OD, FAAO; Brad Sutton, OD, FAAO

ORS MISSION STATEMENT

The mission of the Optometric Retina Society (ORS) is to promote the advancement of vitreoretinal knowledge for clinicians, ophthalmic educators, residents, and students. The ORS is dedicated to posterior segment disease prevention, diagnosis, management and co-management.

THREE WAYS TO REGISTER

email: reviewmeetings@jhihealth.com | call: 800-999-0975

online: www.reviewsce.com/orsretupdate2018

Administered by
Review Group Vision Care Education, LLC



Partially supported by an unrestricted
educational grant from
REGENERON

Review Group Vision Care Education, LLC partners with Salus University for those ODs who are licensed in states that require university credit. See event website for up-to-date information.



Break Up With Your Lid Bumps

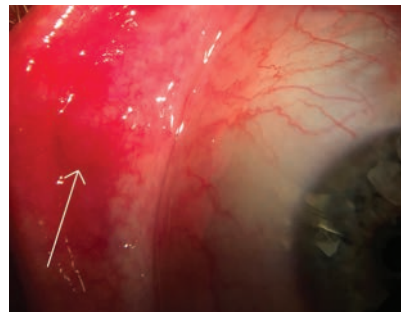
With a chalazion and a concurrent pyogenic granuloma, conservative therapy will not provide relief. **By Marisa Asheim, BS, and Leonid Skorin, Jr., OD, DO, MS**

Patients with a chalazion are often frustrated by the unsightly eyelid bump that may linger for weeks or months. If warm compresses aren't doing the trick, clinicians should look for concurrent pyogenic granulomas, as they shift the treatment from simple compresses to surgery. This provides patients the results they are looking for with less chance of recurrence.

The First Problem

Chalazia are sterile lesions caused by chronic lipogranulomatous inflammation of the meibomian glands and are associated with rosacea or meibomitis.^{1,2} Histopathological study shows multinucleated giant cells, lymphocytes, extracellular fat deposits and lipid-laden epithelioid cells.² These lesions may get larger over time, and patients usually have no pain but may have irritation due to the size or location of the lesion.

Because at least one third of chalazia resolve spontaneously, initial observation is advised.² When treatment is indicated, hot compresses several times daily is the most common approach. Expression can be effective for fresh lesions near the lid margin.² Lesions located near structures such as the puncta may warrant triamcinolone acetonide injection into and around the lesion. Unfortunately, intralesional corticosteroid injection has a lower



Palpebral view of a chalazion near the lid margin and pyogenic granuloma (arrow).

resolution rate than surgery.³ If a concurrent pyogenic granuloma exists, surgery is indicated.⁴

The Second Problem

The term *pyogenic granuloma* is a misnomer; it's neither pyogenic nor granulomatous. It's a vascularized lesion, often pedunculated and red in color, with inflammatory cells and lobular capillary proliferation.⁵ Pyogenic granulomas usually occur in locations previously affected by surgery, trauma or infection.²

Usually, intervention is required for pyogenic granulomas, as spontaneous resolution is rare. Topical corticosteroids may have some success, but most require surgical excision for complete resolution.^{2,5}

Two Bumps, One Surgery

Prior to excision, the eyelid is anesthetized with 2.0% lidocaine and 1:100,000 epinephrine. This also induces vasoconstriction, which reduces bleeding during and after the procedure. The surgeon passes a traction suture through the eyelid adjacent to the lesion to more easily

evert the eyelid and then places and tightens a chalazion clamp into position. Using a trephine, the surgeon opens the chalazion and loosens and removes granulomatous tissue from the chalazion with a curette. The surgeon then uses scissors to widen the tunnel between the pyogenic granuloma and the chalazion and excise the pyogenic granuloma. After removing the clamp, pressure is applied to achieve hemostasis.

Post-op Considerations

After the procedure, patients will be instructed to apply an antibiotic ointment to the incision site three times per day for five days. The patient should return to the clinic if they notice any signs of infection such as discharge, swelling, redness, fever or changes in vision. If desired, a follow-up appointment can be set at the discretion of the optometrist one week post-excision. ■

Ms. Asheim is a fourth-year student at Pacific University College of Optometry.

Dr. Skorin is a consultant in the Department of Surgery, Community Division of Ophthalmology in the Mayo Clinic Health System in Albert Lea, MN.



To see a video of this procedure, visit www.reviewofoptometry.com, or scan the QR code.

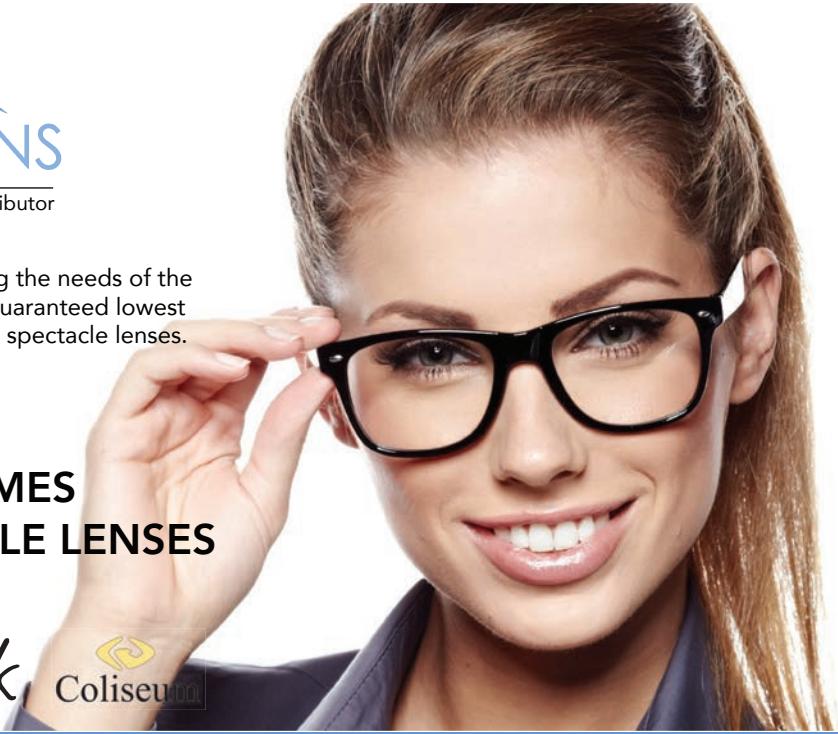
1. Kaiser PK, Friedman NJ. Eyelid Inflammations. In: Massachusetts Eye and Ear Infirmary Illustrated Manual of Ophthalmology. 4th ed. Philadelphia: Elsevier; 2014:77-83.
2. Bowling B, Kanski JJ. Eyelids. In: Kanski's Clinical Ophthalmology. 8th ed. Philadelphia: Elsevier; 2016:2-62.
3. Aycinena AR, Achiron A, Paul M, Burgansky-Eliash Z. Incision and curettage versus steroid injection for the treatment of chalazia: A meta-analysis. *Ophthalmic Plastic Reconstructive Surg.* 2016;32:220-4.
4. Bagheri N, Wajda B. Chalazion/Hordeolum. In: The Wills Eye Manual: Office and Emergency Room Diagnosis and Treatment of Eye Disease. 7th ed. Philadelphia: Wolters Kluwer; 2017:132-3.
5. Tan IJ, Turner AW. Pyogenic granuloma of the conjunctiva. *New Engl J Med.* 2017;376:1667.

Merchandise Offered



National Lens is dedicated to fulfilling the needs of the optical profession by providing the guaranteed lowest prices on contact lenses, frames, and spectacle lenses.

CONTACT LENSES
100% ITALIAN FRAMES
FINISHED SPECTACLE LENSES



GUARANTEED LOWEST PRICES | FREE FIRST CLASS SHIPPING*

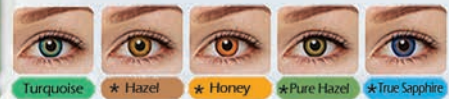
*in stock products (when available)

Contact Lenses

Impressions

Color Contact Lens

Unleash your true color!



Impressions colored contacts blend naturally with your patients eyes to create a beautiful look. Available in nine dazzling opaque colors of which Brown, Grey, Green, Hazel, Honey, Pure Hazel and True Sapphire are available in RX PL to -8.00.

Impressions are fun, hip, fashionable and very competitively priced to help your bottom line. POP materials and posters are available upon request.

Available Exclusively at



Equipment and Supplies

WHY PAY RETAIL???



Pretesting Tables of all shapes and sizes at Wholesale Prices.

Search the word PRETESTING at EBAY

Save hundreds even thousands on all your pretesting needs.

Or call: 316-734-4265

Place Your Ad Here!

Toll free: 888-498-1460

E-mail: sales@kerhgroup.com

Practice For Sale

ARE YOU IN CONTROL?

Don't buy a job...acquire a business.

Select clients have larger practices available for outright purchase. Positive cash flow and 100% financing available. America's leading optometry business development consultancy provides support before, during and after closure.

We'll help you acquire the optometry practice of your dreams with no cost to you. See our current offerings at:

<http://www.cleinman.com/buy>

800-331-5536



Practice Consultants
 Practice Sales • Appraisals • Consulting
www.PracticeConsultants.com

PRACTICES FOR SALE NATIONWIDE

Visit us on the Web or call us to learn more about our company and the practices we have available.

info@PracticeConsultants.com
800-576-6935

www.PracticeConsultants.com

Career Opportunities

Staff Optometrist Wanted

Bard Optical is a family owned full-service retail optometric practice with 22 offices (and growing) throughout Central Illinois. Bard Optical prides itself on having a progressive optometric staff whose foundation is based on one-on-one patient service. We are currently accepting CV/resumes for Optometrists to join our medical model optometric practice that includes extended testing. The practice includes but is not limited to general optometry, contact lenses and geriatric care. Salaried, full-time positions are available with excellent base compensation and incentive programs and benefits. Some part-time opportunities may also be available.

Current positions are available in Bloomington/Normal, Decatur/Forsyth, Peoria, Sterling and Canton as we continue to grow with new and established offices.

Please email your information to mhall@bardoptical.com or call Mick at 309-693-9540 ext 225. Mailing address if more convenient is:
Bard Optical
 Attn: Mick Hall, Vice President
 8309 N Knoxville Avenue
 Peoria, IL 61615

Bard Optical is a proud Associate Member of the Illinois Optometric Association.



www.bardoptical.com

REVIEW OF OPTOMETRY

Targeting Optometrists?

CLASSIFIED ADVERTISING WORKS

- JOB OPENINGS
- CME PROGRAMS
- PRODUCTS & SERVICES
- AND MORE...

Contact us today for classified advertising:

Toll free: 888-498-1460

E-mail: sales@kerhgroup.com



30 year private optometry practice opportunity

in Fairbanks, Alaska.

See patients of all ages.

Excellent leased location on busy thoroughfare.

907-978-7481

or [email virginalind@yahoo.com](mailto:virginalind@yahoo.com)

Product Review

Pharmaceuticals

BAK-free Latanoprost Approved

Glaucoma patients and suspects now have a new non-preserved treatment option thanks to the recent approval of Xelpros (latanoprost ophthalmic emulsion 0.005%, Sun Pharma). Xelpros is formulated with what the manufacturer calls 'swollen micelle microemulsion' technology that Sun says "helps to solubilize drugs that have limited or no solubility, thus eliminating the need for benzalkonium chloride."

Xelpros is approved for once-daily dosing.

Visit www.myxelpros.com.

Novel Neurotrophic Keratitis Therapy

Patients who experience loss of corneal sensation from damage to the trigeminal nerve finally have a potential remedy that doesn't require surgery, with the recent approval of Oxervate (cenegermin). The drug is manufactured by Dompé Farmaceutici, based in Milan. Safety and efficacy were demonstrated in 151 patients in two randomized controlled trials of eight weeks' duration, each using a 6x/day dosing regimen. Complete corneal healing was demonstrated in 70% of patients treated with Oxervate vs. 28% in controls, according to the FDA. The most common adverse reactions were pain, hyperemia, inflammation and increased lacrimation.

Visit www.dompe.com/en.

Higher Concentration Therapy

Sun Pharma's Cequa (cyclosporine ophthalmic solution 0.09%), indicated to increase tear production in dry eye patients, joins the ranks of Restasis and Xiidra (lifitegrast) as only the third Rx product approved for this patient population in 19 years. Cequa's 0.09% concentration of cyclosporine A is the highest on the market. Cequa is dosed twice daily and will be available as a single-use vial.

Visit www.sunpharma.com.

New Topical Steroid Hits the Market

The FDA recently approved a 1% formulation of loteprednol etabonate, under the brand name Inveltys (Kala Pharmaceuticals), with an indication for treatment of inflammation and pain following ocular surgery. The company says this is the first twice-daily topical corticosteroid approved for this indication, as others are dosed QID. That distinction "may improve compliance and prove less burdensome for patients," according to a company press release.

Visit inveltys.com.

Diagnostic Technology

OCT-A Comes to Spectralis

Clinicians eager to incorporate the latest retinal diagnostic technology now have another option for optical coherence tomography angiography (OCT-A), especially those who already have the Heidelberg Spectralis OCT device. The company recently announced the FDA has cleared its OCT-A module for the Spectralis portfolio. Doctors in the market for a new OCT and those with existing Spectralis upgradeable devices can incorporate this diagnostic tool into their practice. OCT-A allows for noninvasive evaluation of retinal and choroidal vascular abnormalities using three-dimensional visualization of perfused vasculature structures, the company says.

Visit www.heidelbergengineering.com.

Ocular Surface Therapy

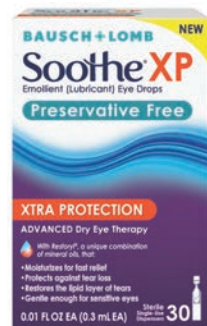Scleral Lens Gains New Indication

If you use scleral contact lenses to treat advanced ocular surface disease, note that the Onefit line from Blanchard Contact Lenses has been cleared by the FDA for that indication, the company recently announced. The approval is contingent on use of the Optimum Extra, Optimum Extreme or Hexa 100 materials from Contamac, however. Blanchard cites dry eye, Sjögren's syndrome, graft-vs.-host disease and keratitis as some of the potential diseases amenable to therapy with this modality.

Visit www.blanchardlab.com.

Extra Protection with New Eye Drop

Clinicians seeking a preservative-free artificial tear for patients with dry eye symptoms can now suggest Bausch + Lomb's Soothe Xtra Protection (XP) Preservative Free lubricant eye drops, the latest addition to its portfolio. The eye drops use a unique combination of mineral oils as active ingredients, which are designed to restore the lipid layer, seal in moisture and protect against further irritation, according to the company.



Soothe XP Preservative Free eye drops are now available at many major retailers nationwide, including Walmart, Target, Walgreens, Rite Aid and Meijer.

Visit www.sootheeyedrops.com. ■



Statement of Ownership, Management, and Circulation (Requester Publications Only)

1. Publication Title: Review of Optometry
2. Publication Number: 087-350
3. Filing Date: 09/14/18
4. Issue Frequency: Monthly
5. Number of Issues Published Annually: 12
6. Annual Subscription Price: \$56.00
7. Complete Mailing Address of Known Office of Publication: Jobson Medical Information LLC, 440 Ninth Ave, 14th Floor, New York, NY 10001
8. Complete Mailing Address of Headquarters or General Business Office of Publisher: Jobson Medical Information LLC, 440 Ninth Ave, 14th Floor, New York, NY 10001
9. Full Names and Complete Mailing Addresses of Publisher, Editor, and Managing Editor: James Henne, Publisher, Reviews Group; Jobson Medical Information LLC, 11 Campus Drive, Suite 100, Newtown Square, PA 19073; Jack Persico, Editor-in-Chief; Jobson Medical Information LLC, 11 Campus Drive, Suite 100, Newtown Square, PA 19073; Rebecca Hepp, Managing Editor; Jobson Medical Information LLC, 11 Campus Drive, Suite 100, Newtown Square, PA 19073

10. Owner: Jobson Medical Information LLC, 440 Ninth Avenue, 14th Floor, New York, NY 10001
11. Known Bondholders, Mortgagees, and Other Security Holders: None
12. Tax Status: For completion by nonprofit organizations authorized to mail at nonprofit rates. (Check one)
PS Form 3526-R, July 2014 (Page 1 of 4) (See instructions page 4) PSN: 7530-09-000-8855 PRIVACY NOTICE: See our privacy policy on www.usps.com

Table with 2 columns: Full Name, Complete Mailing Address. Row 1: Jobson Medical Information LLC, 440 Ninth Avenue, 14th Floor, New York, NY 10001

Table with 2 columns: Full Name, Complete Mailing Address. Row 1: Jobson Medical Information LLC, 440 Ninth Avenue, 14th Floor, New York, NY 10001

13. Publication Title: Review of Optometry
14. Issue Date for Circulation Data Below: August 15, 2018
15. Extent and Nature of Circulation: Total Number of Copies (Net press run): 43,817
Average No. Copies Each Issue During Preceding 12 Months: 40,372
No. Copies of Single Issue Published Nearest to Filing Date: 40,913

Table with 4 columns: Description, Average No. Copies Each Issue During Preceding 12 Months, No. Copies of Single Issue Published Nearest to Filing Date, Percent Paid and/or Requested Circulation. Rows include Total Number of Copies, Legitimate Paid and/or Requested Distribution, Total Paid and/or Requested Circulation, Non-requested Distribution, Total Non-requested Distribution, Total Distribution, Copies not Distributed, Total (Sum of 15f and g), Percent Paid and/or Requested Circulation (15c divided by 15f times 100).

* If you are claiming electronic copies, go to line 16 on page 3. If you are not claiming electronic copies, skip to line 17 on page 3.



Statement of Ownership, Management, and Circulation (Requester Publications Only)

16. Electronic Copy Circulation: a. Requested and Paid Electronic Copies; b. Total Requested and Paid Print Copies (Line 15c) + Requested/Paid Electronic Copies (Line 16a); c. Total Requested Copy Distribution (Line 15f) + Requested/Paid Electronic Copies (Line 16a); d. Percent Paid and/or Requested Circulation (Both Print & Electronic Copies) (16b divided by 15c x 100)

I certify that 50% of all my distributed copies (electronic and print) are legitimate requests or paid copies.

17. Publication of Statement of Ownership for a Requester Publication is required and will be printed in the issue of this publication: October 15, 2018

18. Signature and Title of Editor, Publisher, Business Manager, or Owner: James Henne, Publisher; Date: 9/18/2018

I certify that all information furnished on this form is true and complete. I understand that anyone who furnishes false or misleading information on this form or who omits material or information requested on the form may be subject to criminal sanctions (including fines and imprisonment) and/or civil sanctions (including civil penalties).

Advertisers Index

Acuity Pro/VisionScience Software, Inc. 105
Phone (877) 228-4890
or (580) 243-1301
Fax (580) 243-1377
info@acuitypro.com

Akorn Pharmaceuticals 25, 67
Phone (800) 932-5676
www.akorn.com

Alcon Laboratories 7, 8, 71
100, 116
Phone (800) 451-3937
Fax (817) 551-4352

Allergan, Inc. 41
Phone (800) 347-4500

Bausch + Lomb 13, 14, 49, 57
Phone (800) 323-0000
Fax (813) 975-7762

Bruder Ophthalmic Products 39
Phone (888) 827-8337
eyes@bruderophthalmic.com

Coburn Technologies 18
Phone (800) 262-8761
www.coburntechnologies.com

CooperVision 115
Phone (800) 341-2020

DGH Technology, Inc. 9
Phone (800) 722-3883
Fax (610) 594-0390
info@dghkoi.com
www.dghkoi.com

Essilor of America 27
www.essilorusa.com

Eye Vance Pharmaceuticals 65
Phone (817) 677-6120
www.eyevance.com

Icare USA 45
Phone (888) 389-4022
www.icare-usa.com

Kala Pharmaceuticals 17
Phone (781) 996-5252
Fax (781) 642-0399
info@kalarx.com
www.kalarx.com

Katena 23, 51
Phone (800) 225-1195
www.katena.com

Keeler Instruments 43
Phone (800) 523-5620
Fax (610) 353-7814

Lacrimedics, Inc 69
Phone (800) 367-8327
Fax (253) 964-2699
info@lacrimedics.com
www.lacrimedics.com

Luneau Technology USA, Inc. 53
Phone (800) 729-1959
www.visionixusa.com

M&S Technologies 37
Phone (877) 225-6101
Fax (847) 763-9170

Menicon 21
Phone (800) MENICON
information@menicon.com
www.meniconamerica.com

Natural Ophthalmics, Inc. 99
Phone (877) 220-9710
Info@NaturalEyeDrops.com
www.NaturalEyeDrops.com

NuSight Medical Operations 31, 33
Phone (833) 468-5437
www.NuSightMedical.com

Oculus, Inc. 97
Phone (888) 284-8004
Fax (425) 867-1881

Reichert Technologies 2-3
Phone (888) 849-8955
Fax (716) 686-4545
www.reichert.com

S4OPTIK 73, 75, 77
Phone (888) 224-6012

Topcon Medical Systems 11
Phone (800) 223-1130
Fax (201) 599-5250

Veatch 59, 61, 63
Phone (800) 447-7511
Fax (602) 838-4934

Vital Tears 29
Phone (800) 360-9592
Fax (816) 255-1395
info@vitaltears.org
www.vitaltears.org

X-Cel Speciality Contacts 47
Phone (877) 336-2482
www.xcelspecialitycontacts.com

This advertiser index is published as a convenience and not as part of the advertising contract. Every care will be taken to index correctly. No allowance will be made for errors due to spelling, incorrect page number or failure to insert.



A Red Eye Fight

By Andrew S. Gurwood, OD

History

A 27-year-old female patient reported to the office with a chief complaint of red, itchy eyes for three months. She explained that she had been placed on Pataday (olopatadine hydrochloride ophthalmic solution, Novartis) QD, PRN by her internal medicine doctor but did not get sustained relief. Her ocular history was non-contributory.

Her systemic disease history was positive for rheumatoid arthritis, for which she medicated with Enbrel (etanercept, Amgen) 50mg/week. She denied allergies to medications and foods.

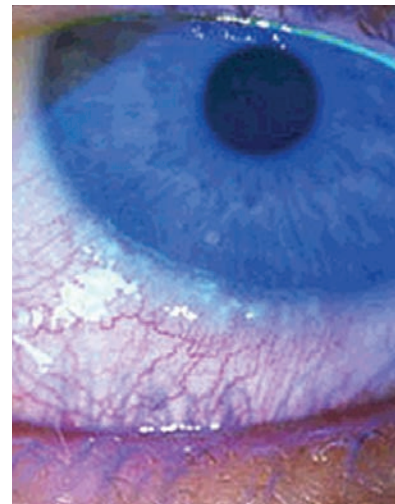
Diagnostic Data

Her best-corrected entering visual acuities were 20/15 OD and

20/15 OS at distance and near. Her external examination was normal with no evidence of afferent pupillary defect. The pertinent biomicroscopic examination of the anterior segment findings are demonstrated in the photo. Goldmann applanation tonometry measured 14mm Hg OU. The dilated fundus examination revealed no peripheral pathologies in either eye.

Your Diagnosis

Does the case presented require any additional tests, history or information? What steps would you take to manage this patient? Based on the information provided, what would be your diagnosis? What is the patient's most likely prognosis? To find out, visit www.reviewofoptometry.com. ■



This 27-year-old patient's red, itchy eyes have been causing her trouble for the previous three months. Consider her medical history plus this image to help you uncover the cause behind her discomfort.

Retina Quiz Answers (from page 98): 1) b; 2) b; 3) d; 4) b; 5) b.

Next Month in the Mag

In our November issue, *Review of Optometry* will take a special look at the health of the ocular surface. Topics for this issue will include:

- *Point-of-care Diagnostic Testing for Ocular Surface Compromises*
- *Performing a Thorough Lid and Ocular Surface Evaluation*

- *Artificial Tears: Which Drop to Recommend?*
- *Simple Strategies to Help Your Dry Eye Patients*
- *Diagnosing and Managing Comorbidities in Dry Eye Disease* (Earn 2 CE credits)

Also in this issue:

- *The Annual Dilated Exam: Has Widefield Imaging Changed Your Protocols?*

REVIEW OF OPTOMETRY (ISSN 0147-7633) IS PUBLISHED MONTHLY, 12 TIMES A YEAR BY JOBSON MEDICAL INFORMATION LLC, 440 9TH AVENUE, 14TH FLOOR, NEW YORK, NY 10013-1678. PERIODICALS POSTAGE PAID AT NEW YORK, NY AND ADDITIONAL MAILING OFFICES. POSTMASTER: SEND ADDRESS CHANGES TO REVIEW OF OPTOMETRY, PO BOX 81, CONGERS, NY 10920-0081. SUBSCRIPTION PRICES: US: ONE YEAR \$56; TWO YEARS \$97, CANADA: ONE YEAR \$88, TWO YEARS \$160, INT'L: ONE YEAR \$209, TWO YEARS \$299. FOR SUBSCRIPTION INFORMATION CALL TOLL-FREE (877) 529-1746 (USA); OUTSIDE USA, CALL (845) 267-3065. OREMAIL US AT REVIEWOPTOMETRY@CAMBEYWEST.COM. PUBLICATIONS MAIL AGREEMENT NO: 40612608. CANADA RETURNS TO BE SENT TO BLEUCHIP INTERNATIONAL, P.O. BOX 25542, LONDON, ON N6C 6B2.

**the contact lens choice
for future leaders, busy mamas
& joy seekers alike.**



It's a great, big, beautiful world out there. Upgrade your 2-week and monthly patients to the convenience of clariti® 1 day, a high-oxygen silicone hydrogel 1-day lens at the price of a hydrogel. Plus, with a full family of lenses, there's a clariti® 1 day to fit virtually all patients. To which we say, Oh, happy day. [Prescribecleariti.com](https://www.Prescribecleariti.com)

clariti® 1 day

GIVE YOUR PATIENTS OUTSTANDING COMFORT FROM DAY 1 TO DAY 30^{1-3*}



Excellent Deposit Protection^{4,5}



Lasting Lens Surface Moisture^{6,7}

AIR OPTIX[®]
plus
HydraGlyde
contact lenses
Alcon A Novartis
Division

FOR A LIMITED TIME, PATIENTS CAN
SAVE UP TO \$50

ON AN ANNUAL SUPPLY VIA MAIL-IN OR ONLINE REBATE**
WITH THE AIR OPTIX[®] CHOICE PROGRAM!

Visit AIROPTIXCHOICE.com to learn more

*Based on clinical studies with AIR OPTIX[®] AQUA contact lenses.

**Savings via mail-in (or online) rebate in the form of an Alcon VISA[®] pre-paid card. Valid on an annual supply purchase (four 6-ct boxes) of AIR OPTIX[®] brand lenses from your eye care professional or participating retailer between 5/1/18 and 12/31/18. An eye exam or lens fitting is required and must occur within 90 days prior to your contact lens purchase. Rebate claim must be submitted within sixty (60) days of your purchase. Additional Restrictions apply. Visit AIROPTIXCHOICE.com for full Terms and Conditions. Questions? Call 1-855-344-6871.

References: 1. Eiden SB, Davis R, Bergenske P. Prospective study of lotrafilcon B lenses comparing 2 versus 4 weeks of wear for objective and subjective measures of health, comfort, and vision. *Eye Contact Lens*. 2013;39(4):290-294. 2. Lemp J, Kern J. A comparison of real time and recall comfort assessments. *Optom Vis Sci*. 2016;93:Eabstract 165256. 3. Merchea M, Mathew J, Mack C. Assessing Satisfaction with lotrafilcon B Packaged with an EOBO Wetting Agent Combined with EOBO-Based Lens Care Solutions. Poster presented at the Annual Meeting of the American Academy of Optometry, October 11-14, 2017, Chicago, IL. 4. Nash W, Gabriel M, Mowrey-McKee M. A comparison of various silicone hydrogel lenses; lipid and protein deposition as a result of daily wear. *Optom Vis Sci*. 2010;87:Eabstract 105110. 5. Nash WL, Gabriel MM. Ex vivo analysis of cholesterol deposition for commercially available silicone hydrogel contact lenses using a fluorometric enzymatic assay. *Eye Contact Lens*. 2014;40(5):277-282. 6. In vitro study over 16 hours to measure wetting substantivity, Alcon data on file, 2015. 7. Muya L, Lemp J, Kern JR, Sentell KB, Lane J, Perry SS. Impact of packaging saline wetting agents on wetting substantivity and lubricity. *Invest Ophthalmol Vis Sci* 2016;57:E-abstract 1463.

Important information for AIR OPTIX[®] plus HydraGlyde[®] (lotrafilcon B): For daily wear or extended wear up to 6 nights for near/farsightedness, presbyopia and/or astigmatism. Risk of serious eye problems (i.e. corneal ulcer) is greater for extended wear. In rare cases, loss of vision may result. Side effects like discomfort, mild burning or stinging may occur.



Recommend CLEAR CARE[®] PLUS
or OPTI-FREE[®] Puremoist[®]
as the perfect combination
with AIR OPTIX[®] lenses.

Alcon A Novartis
Division

See product instructions for complete wear, care and safety information.

Rx only

© 2018 Novartis 08/18 US-AOH-18-E-0424(2)