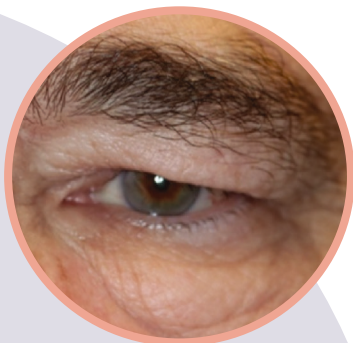


BEYOND AESTHETIC CONCERNS:

THE IMPORTANCE OF RECOGNIZING AND MANAGING BLEPHAROPTOSIS

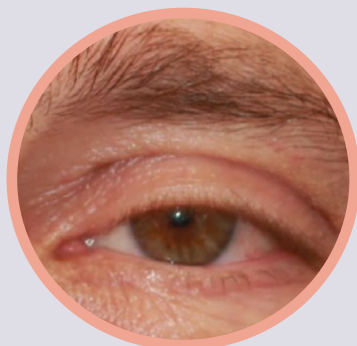
▶ **DERMATOCHALASIS**

Dermatochalasis of the upper eyelid refers to redundant skin.



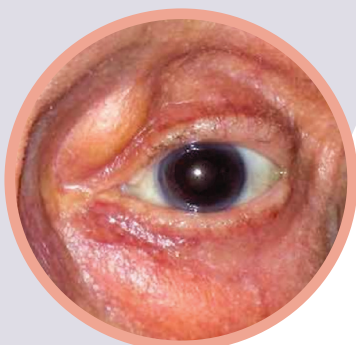
▶ **PTOSIS**

Ptosis indicates a low upper eyelid position.



▶ **STEATOBLEPHARON**

Steatoblepharon is anterior herniation of the orbital fat.



The eyes serve as a crucial focal point during social interactions. The skin surrounding the eyes is the thinnest on the body and often exhibits the initial signs of aging and fatigue. As individuals age, fine lines and deeper creases (rhytids) develop on the face due to sun damage and collagen remodeling, transforming lines of facial expression into permanent static creases. The eyelid skin loses its elasticity, leading to redundant upper lid skin that may overhang the eyelashes (dermatochalasis). The brows lose volume and descend, particularly laterally, contributing to “lateral hooding.” Progressive attenuation of the orbital septum permits orbital fat to herniate into the eyelids (steatoblepharon), causing the eyelids to appear puffier, especially medially, where the nasal fat pads may become quite prominent. Eyelid laxity develops, predisposing individuals to lower

SPONSORED BY

RVL
PHARMACEUTICALS

This educational material was developed with Mednetrin, LLC, “Educating and empowering patients and providers”.

Sponsored supplement published in the October 2023 issue of Review of Ophthalmology

Table of Contents

3. Evaluating Ptosis in the Clinic

5. Ptosis Classification

8. Eyelid Metrics

10. Addressing An Often-Overlooked Condition

11. Ptosis Visual Field Loss Can Be Additive to Visual Field Loss from Other Conditions

11. Ptosis and Visual Field Loss

eyelid malposition (e.g., retraction, ectropion, or entropion). Thinning or stretching of the levator aponeurosis or separation from the tarsal plate results in ptosis (aponeurotic ptosis). Consequently, many individuals seek eyelid plastic surgeons to enhance their appearance and improve their vision by addressing issues such as overhanging skin (dermatochalasis) and low-lying upper eyelids (ptosis).¹

“Blepharoptosis, or “ptosis,” is a prevalent eyelid disorder characterized by the abnormal drooping of the upper eyelid in primary gaze. Ptosis typically arises when the levator muscle detaches from its eyelid insertion and can manifest as unilateral or bilateral, congenital or acquired.¹ With a reported prevalence ranging from 4.7% to 13.5% in adults, its incidence increases with age.¹ Although acquired ptosis is frequently observed in clinical settings, it is crucial to conduct a differential diagnosis during patient evaluation to rule out severe neurologic or orbital diseases. If left unaddressed, ptosis can result in appearance-related anxiety, depression, and deficits in the superior visual field.^{2,3}

Assessments of the superior visual field using static perimetry testing, such as the Humphrey visual field test, demonstrate that even mild ptosis can lead to significant impairment, which exacerbates with moderate ptosis.⁴ This impairment can heighten the func-

tional burden for patients with glaucoma or geographic atrophy and potentially confound visual field findings. Additionally, ptosis patients experiencing visual field impairment may face a decline in health-related quality of life due to reduced independence and increased difficulty in driving and performing everyday tasks.²

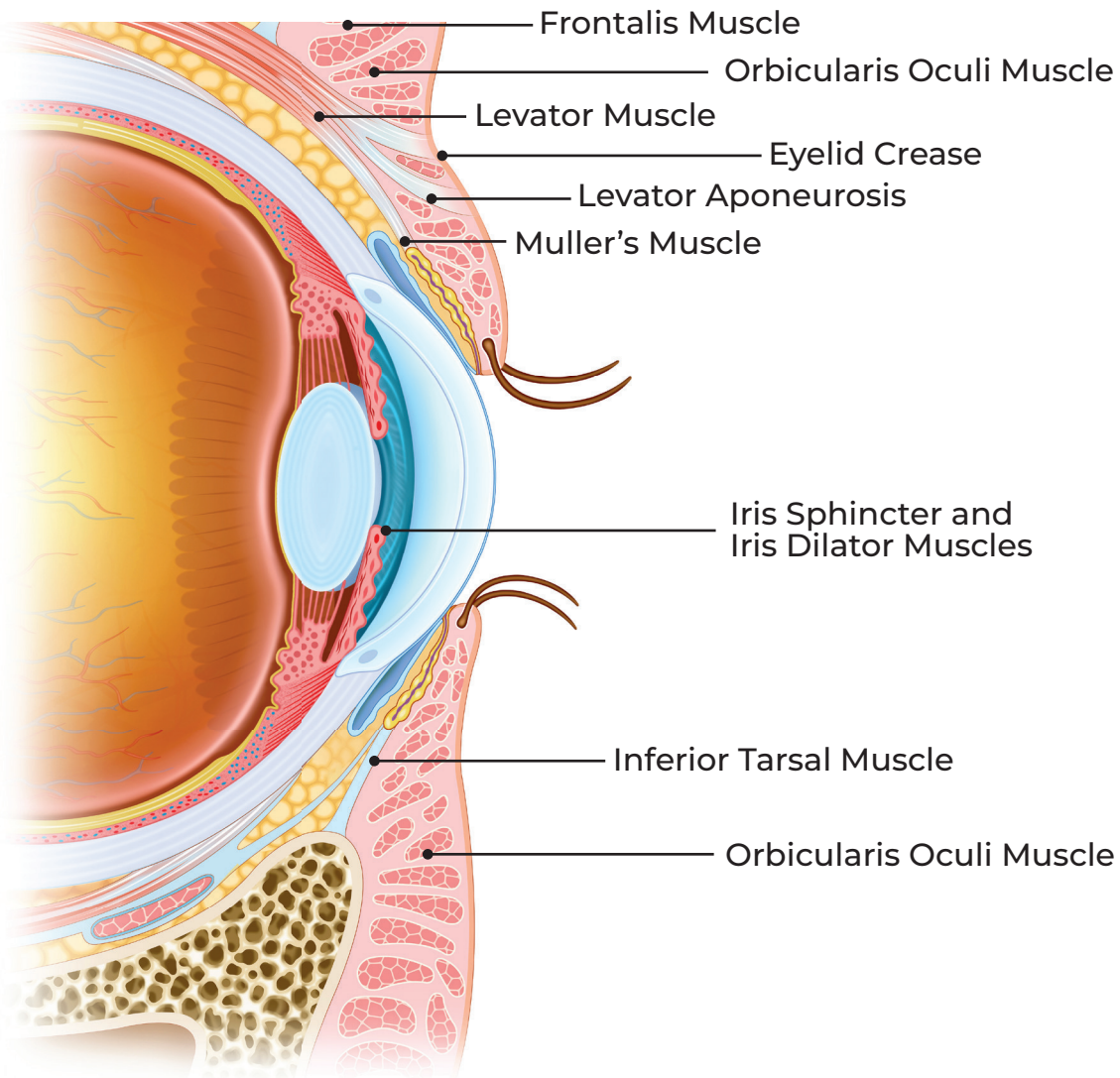
As individuals age, fine lines and deeper creases (rhytids) develop on the face due to sun damage and collagen remodeling, transforming lines of facial expression into permanent static creases.

Fortunately, eye care professionals can easily recognize and evaluate ptosis by understanding basic anatomy and employing simple evaluation strategies.¹ This knowledge equips clinicians to more effectively explain the condition to patients and identify those who may benefit from medical therapy or referral to an oculoplastic surgeon. This monograph focuses on the clinical assessment of the eye zone, with an emphasis on adult ptosis. The images and tables provided present multiple complementary perspectives on periocular anatomy. Designed for efficient review, it is intended to serve as a valuable future reference.

EVALUATING PTOSIS IN THE CLINIC

To effectively evaluate and manage ptosis, it is crucial to possess a comprehensive understanding of the regional eyelid anatomy, not only the protractors (elevators) of the eyelid. The primary protractor of the eyelid is the orbicularis oculi muscle, which is divided into orbital and palpebral components. The orbital component assists in voluntary forced lid closure, while the palpebral component aids in involuntary lid closure.

► EYELID ANATOMY



The following table serves as a useful reference to identify the periocular muscles.

EYELID ANATOMY						
Periocular Muscle	Innervation	Receptors	Type of Muscle	Action	Disorders Involving This Muscle	Comments
Levator Muscle	3rd cranial (oculomotor) nerve—superior division	Nicotinic cholinergic and beta 1 adrenergic	Striated	Elevates and retracts upper eyelid	3rd nerve palsy, aponeurotic ptosis, botulinum toxin injection, myasthenia gravis, various myopathies	Primary lid elevator, under volitional control
Müller's (Superior Tarsal) Muscle	Sympathetic nervous system	Alpha 1D > beta 1 > alpha 2C > beta 2 adrenergic	Smooth	Elevates and retracts the upper eyelid	Horner syndrome	Secondary lid elevator, autonomically innervated, typically only contributes 1-2mm to upper lid elevation.
Inferior Tarsal Muscle	Sympathetic nervous system	Alpha 2 and beta 1 adrenergic receptors	Smooth	Retracts the lower eyelid	Horner syndrome	
Frontalis Muscle	7th cranial (facial) nerve—frontal (temporal) branch	Nicotinic cholinergic receptors	Striated	Elevates the eyebrows	Facial nerve palsy, myasthenia gravis, botulinum toxin injection, myopathies	This muscle is often involuntarily activated to compensate for upper lid ptosis or dermatochalasis.
Orbicularis Oculi Muscle	7th cranial (facial) nerve	Nicotinic cholinergic receptors	Striated	Closes the eyes	Facial nerve palsy, myasthenia gravis, botulinum toxin injection, myopathies	Orbicularis oculi weakness may result in lagophthalmos or a deficient blink reflex.
Rectus and Oblique Muscles	3rd, 4th, and 6th cranial nerves	Nicotinic cholinergic receptors	Striated	Moves the eyes in all directions	Cranial nerve palsy, myasthenia gravis, orbital myositis, CPEO, etc.	4 rectus and 2 oblique muscles, each paired (yoked) with another in the opposite orbit. EOM dysfunction generally leads to incomitant strabismus with binocular diplopia.
Iris Sphincter Muscle	Parasympathetic nervous system (nerve fibers travel with inferior division of CN3 in the orbit)	Muscarinic cholinergic receptors (M3 > M2 subtype)	Smooth	Constricts the pupil	Pupil-involving 3rd nerve palsy, Adie's tonic pupil	Segmental pupillary paralysis with vermiform (worm-like) constriction is highly suggestive of an Adie tonic pupil.
Iris Dilator Muscle	Sympathetic nervous system (nerve fibers enter orbit with V1 (first division of CN5))	Alpha 1A > alpha 1B > alpha 1D adrenergic	Smooth	Dilates the pupil	Horner syndrome	
Conjunctival and Episcleral Vessel Wall	Sympathetic and parasympathetic nervous system	Alpha adrenergic and muscarinic cholinergic	Smooth	Constricts blood vessels	Horner syndrome	

PTOSIS HISTORY

A comprehensive patient history is crucial, as it can offer numerous clues about whether a patient presents with isolated ptosis or a more concerning condition.¹ The most common type of ptosis, involutional ptosis, is typically bilateral (although it can be asymmetric) and has a gradual onset, progressing over months to years. It is essential to assess the entire face and obtain an overall gestalt before focusing on the periocular region, as this can prevent overlooking important nearby pathology that warrants attention or may impact ptosis management, such as brow droop or facial weakness.

When providing the best care for patients, it is critical to first rule out any serious conditions. The most common serious neurological or muscular conditions encountered in clinical practice include Horner syndrome, 3rd cranial (oculomotor) nerve palsy, myasthenia gravis, and chronic progressive external ophthalmoplegia (CPEO).¹ A thorough review of a patient's history can help determine the timing of ptosis onset, as a sudden onset may signal serious underlying pathology.¹

Patient Presentation

The following questions can assist clinicians in gathering relevant information that may further clarify a patient's presentation of ptosis:

- Does the patient have diabetes or hypertension?
- Is the ptosis new onset or longstanding?
- Do functional changes occur during the day (e.g., complete closure)?
- Does the patient experience double vision?
- Are the extraocular muscle movements (EOMs) equal and full?
- When assessing levator function while holding the eyebrows, what is the excursion of the upper eyelid from downgaze to upgaze? (It should be equal to and more than 12mm).
- Are pupil sizes equal in both light and dark conditions?

PTOSIS CLASSIFICATION

Acquired ptosis, the most common form of ptosis, can be categorized by etiology, including aponeurotic, myogenic, neurogenic, mechanical, or traumatic origins. The following table serves as a useful reference to better understand these classifications. (See pages 6-7.)

PTOSIS CLASSIFICATION			
Mechanism of Ptosis	Related Diagnoses (green = common diagnosis) (red = more serious diagnosis)	Etiology	Typical Clinical Features
Aponeurotic	Involuntal	Levator dehiscence or disinsertion	Bilateral ptosis (not uncommonly asymmetric) with good to excellent LF, high upper lid crease
Mechanical	Lid edema; lid or orbital mass; fibrosis	Increased upper lid weight or restriction of lid movement	Visible or palpable pathology
Myogenic	Chronic progressive external ophthalmoplegia (CPEO)	Mitochondrial or nuclear DNA mutation	Bilateral, symmetric, slowly progressive ptosis with reduced LF and generalized ophthalmoparesis; often features orbicularis oculi weakness
	Oculopharyngeal muscular dystrophy (OPMD)	Mutation of the PABPN1 (polyadenylate-binding protein nuclear 1) gene on chromosome 14	Gradually progressive ptosis with reduced LF, +/-generalized ophthalmoparesis with reduced saccadic velocity; often features orbicularis oculi muscle weakness
	Myotonic dystrophy	Nuclear DNA mutation; type 1 (abnormal repeats in DMPK gene on chromosome 19); more often displays facial and ocular features	Progressive muscle wasting and weakness; bilateral ptosis with reduced levator function, generalized ophthalmoparesis, possible orbicularis oculi and facial weakness; prolonged muscle contraction with inability to relax (myotonia), e.g., hand grip; cataracts; cardiac conduction abnormalities
	Myasthenia gravis	Autoantibodies interfering with neuromuscular transmission at the neuromuscular junction	Any of the following: ptosis (unilateral or bilateral), diplopia strabismus, or ocular motility impairment; facial or orbicularis oculi muscle weakness; bulbar, limb, or respiratory muscle weakness if generalized condition; variability and fatigability; no pupil involvement
	Chemodenervation	Diffusion of botulinum toxin injected nearby	Transient ptosis with reduced levator function
Neurogenic	Third nerve palsy	Various causes of CN3 dysfunction (aneurysm, tumor, infarct, diabetes, trauma, etc.)	Ptosis; anisocoria with larger, sluggish pupil ipsilateral to ptosis (if pupil involvement); impaired supraduction, adduction, and infraduction, unless superior or inferior divisional CN3 palsy
	Horner syndrome	Various causes of a sympathetic pathway lesion (e.g., carotid dissection, neck trauma or surgery, Pancoast tumor (apical lung cancer))	Ptosis; anisocoria with ipsilateral miosis; dilation lag with anisocoria greater in dim lighting; possible anhidrosis, possible pain
Traumatic	Blunt or penetrating injury	Levator muscle or aponeurosis injury	Ptosis; possible visible wound site
Pseudoptosis	Non-Levator / Mullers-induced ptosis	Globe, eyelid, or brow malposition; or strabismus, mimicking ptosis	Breadth of entities: dermatochalasis, brow ptosis , lash ptosis, enophthalmos, contralateral upper eyelid retraction, orbicularis spasm (blepharospasm, hemifacial spasm, or synkinetic spasm due to aberrant facial nerve regeneration)
Congenital	Levator muscle dysgenesis ("simple congenital ptosis")	Maldevelopment of levator muscle	Unilateral or bilateral ptosis with reduced levator function; lid lag, possible poor lid crease; increased risk of amblyopia, strabismus, and refractive error
	Marcus Gunn jaw winking syndrome (congenital synkinetic ptosis)(2-13% of cases of congenital ptosis)	Abnormal innervation of the levator by a motor branch of CNS, with external pterygoid-levator muscle synkinesis	Unilateral ptosis; upper eyelid elevation with various movements of the mouth and jaw
	Blepharophimosis syndrome	Mutation in FOXL2 gene or cytogenetic rearrangements involving chromosome 3	Bilateral ptosis with poor levator function, epicanthus inversus, blepharophimosis (horizontal narrowing of palpebral fissure), and telecanthus; possible amblyopia, refractive error, and strabismus; possible ovarian dysfunction in women
	Double elevator palsy	Ptosis or pseudoptosis with impaired supraduction due to inferior rectus restriction, superior rectus paresis, or supranuclear palsy (3 types)(sporadic)	Unilateral ptosis and impaired supraduction

Making the Diagnosis	Comments
Typical clinical features, gradual onset and progression, possible history of CL wear	Most common form of ptosis, along with mechanical. May be exacerbated by contact lens wear or eye surgery using a lid speculum.
Exam findings (e.g., lid swelling, hematoma, mass, symblepharon, etc.); history (e.g., prior eye trauma or surgery, etc.)	Treatment depends on the underlying condition, e.g., observation for resolution of lid swelling or resection of an eyelid or orbital mass.
Typical clinical features; muscle biopsy showing “ragged red fibers”; genetic testing	Surgery should be conservative due to risk of corneal exposure secondary to lagophthalmos (orbicularis muscle weakness) and deficient Bell’s phenomenon.
Typical clinical features; usually strong family history; ancestry: French Canadian, New Mexican Hispanics, Bukharan Jews in central Asia; genetic testing	Dysphagia may need to be addressed, e.g., cricopharyngeal myotomy or botulinum toxin injection, to prevent malnutrition and aspiration pneumonia.
Typical clinical features, strong family history, EMG, genetic testing	Surgery should be conservative due to risk of corneal exposure secondary to lagophthalmos (orbicularis muscle weakness) and deficient Bell’s phenomenon.
Positive ice test, decremental response on RNS, jitter on SFEMG, positive acetylcholine receptor or MuSK antibodies	Treatment with pyridostigmine (acetylcholinesterase inhibitor) and often systemic immunomodulatory therapy. Neurology consult to assess whether the condition is ocular or generalized. CT or MRI of chest to rule out thymic disorders, e.g., thymoma.
History of botulinum toxin injections in or near the eyelids within the past 3 months	May treat pharmacologically (oxymetazoline or apraclonidine) or observe until it spontaneously resolves.
Typical clinical features	Urgent neuroimaging with contrast (MRI or CT) and cerebral angiography (MRA, CTA, or conventional) to rule out cerebral aneurysm, if pupil is involved. Treatment is directed toward the underlying etiology.
Typical clinical features, positive apraclonidine test (replaced the cocaine test)	Imaging (CT or MRI) of the head/neck/upper chest, cerebral angiography (usually CTA or MRA). Urgent imaging to rule out carotid dissection if acute onset Horner syndrome, especially if there’s neck, facial, or head pain.
Onset of ptosis following orbital trauma	Ptosis may spontaneously improve, so typically ptosis repair is delayed at least 3-4 months for observation, unless levator is transected.
Eye exam	Treatment depends on the underlying condition, e.g., upper blepharoplasty for dermatochalasis or botulinum toxin injections for orbicularis spasm.
Isolated congenital ptosis (unilateral or bilateral) with decreased levator function; possible congenital ptosis	Represents ~75% of congenital ptosis cases.
Typical clinical features; no findings of aberrant regeneration of CN7 (facial nerve synkinesis)	Synkinesis refers to co-contraction of unrelated muscles due to nerve “miswiring”; this is a congenital cranial dysinnervation syndrome.
Typical clinical features; +FH, genetic testing, and chromosome analysis	May have other associated anomalies
Typical clinical features; no other findings to suggest a CN3 palsy	May be difficult to distinguish from congenital CN3 palsy. Strabismus surgery may be required for hypotropia.

EYELID METRICS

After ruling out any serious conditions and determining that the patient has acquired ptosis, it is crucial to employ evaluation strategies to assess the degree and severity of the condition.⁵ Accurate documentation of normal upper eyelid position plays a significant role in evaluating blepharoptosis and eyelid retraction.⁵ Although palpebral fissure measurements were once considered the primary index for eyelid position, recent recommendations caution against relying solely on these measurements, as they depend on both upper and lower eyelid positions.⁵ Instead, upper and lower eyelid positions should be recorded individually.⁵

The following table offers a review of eyelid measurements. Note that these measurements vary by race, age, and ethnicity.

Eyelid Metrics	Details	Normal Range (mm)	Comments
Primary Measurements			
Palpebral fissure height (PF_v)	Vertical dimension	11-12	MRD1 + MRD2 = PFh; Malposition of the upper and lower eyelid may impact PFh, so this is not an optimal measure of upper lid height for ptosis.
Margin-reflex distance 1 (MRD1)	Corneal light reflex to upper lid margin	4-5	Measurement of upper lid margin position relative to the central corneal apex visualized with a penlight or flash. Alternatively, it's possible to qualitatively assess upper lid position relative to superior limbus using clock hours, i.e., where the upper lid intersects the limbus nasally and temporally.
Levator function (LF)	Maximal vertical excursion of upper lid margin from downgaze to upgaze	13-17	Tests strength and functionality of the levator muscle. Hold the brow in place to neutralize any frontalis muscle contribution. >15mm (supranormal) is seen in some involuntional cases due to greater descent of upper lid in downgaze. This metric helps determine nature of the ptosis and the type of corrective surgery.
Lid crease height (LC_n)	Distance from lash line to upper lid crease	6-8 (men) 8-10 (women)	Lid crease is site of attachment of levator aponeurosis to skin. It is best measured in downgaze. Lid crease height is measured in the plane of pretarsal platform, and is typically higher with involuntional ptosis and lower in Asians.
Pre-tarsal platform (PTP)	Distance from upper lid fold to upper lid margin	1-8	Typically redundant skin hinges at the upper lid crease, termed the upper lid fold (ULF), which descends toward the upper lid margin. The visible portion of pre-tarsal skin (PTP) is a potential cause of upper eyelid asymmetry.
Margin-reflex distance 2 (MRD2)	Corneal light reflex to lower lid margin	5-6	Measurement of lower lid margin position to quantify lower lid retraction or reverse ptosis (elevation of the lower lid). The lower lid margin normally rests at or just above the inferior limbus.
Scleral show (SS)	Scleral show	< 0	In the setting of lid retraction (widening), this is a measure of the exposed "white" (sclera) above or below the 12 (upper) or 6 (lower) clock-hour positions.
Brow	Brow position and shape often assessed relative to the superior orbital rim	Peak above lateral limbus	According to the classic aesthetic ideal, the brows (in men) are horizontal and positioned along the superior orbital rim, while the brows (in women) are more arched, with the apex over the lateral limbus and lateral brow 1cm over the superior orbital rim.
Secondary Measurements			
Effective margin-reflex distance (eMRD1)	Light reflex to inferior edge of overhanging skin or ptotic lashes	4-5	Method of documenting visual impact of dermatochalasis or lash ptosis when skin or lashes are lower than the upper lid margin. Thus, when applicable, eMRD1 will always be less than MRD1.
Palpebral fissure width (PF_w)	Horizontal dimension	29-31	Lateral canthal dehiscence results in shortening of palpebral fissure width, rounding of the lateral canthal angle (LCA), and increasing the distance from the LCA to the lateral orbital rim (normal ~2-3mm).
Canthal tilt	Angle between a line through the medial and lateral canthal angles and an imaginary horizontal line	+5-8 degrees (lateral canthal angle ~1-2mm above medial)	May also measure vertical discrepancy between lateral to the medial canthal angle. Positive canthal tilt, with the lateral canthal angle a bit higher than the medial, is often considered more attractive. Negative canthal tilt (lateral canthal dystopia) may contribute to lower eyelid retraction and less favorable lacrimal drainage mechanics.
Tarsal height	Measurement of vertical dimension of the tarsal plate	upper lid 8-10mm, lower lid 4mm	Reduced superior tarsal height may result from prior surgery in which superior tarsectomy was performed, e.g., prior Hughes tarsoconjunctival flap or Fasanella Servat ptosis repair, which can make subsequent ptosis surgery more challenging.

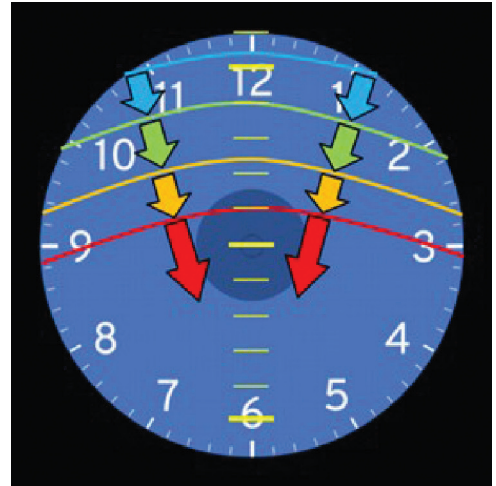
PRACTICAL EVALUATION STRATEGIES

During the evaluation of patients with ptosis, envisioning the iris as a clock face can serve as a useful mental guide for clinicians when applying different eyelid measurements to assess the surface anatomy.

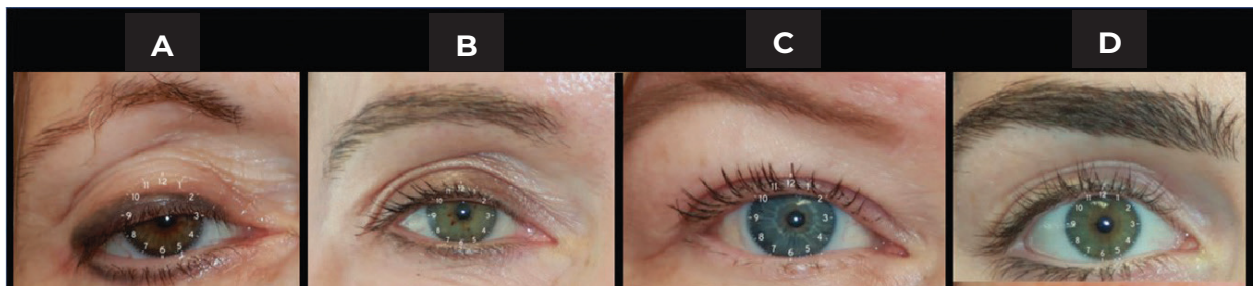	Degree of Ptosis	MRD1 Range
	Severe	<1mm
	Moderate	1.0-2.5mm
	Mild	2.5-4.0mm
	Normal	4.0-5.5mm

Table (above): MRD1 ranges (mm) of ptosis by severity.

Figure (right): Depicts clockface positions of degrees of ptosis with color codings depicted in above Table. Yellow dashes centrally represent mm increments. Central circle represents 3mm pupil.



Using this method to visually assess the degree of ptosis in these clinical images, the below ratings can be assigned:



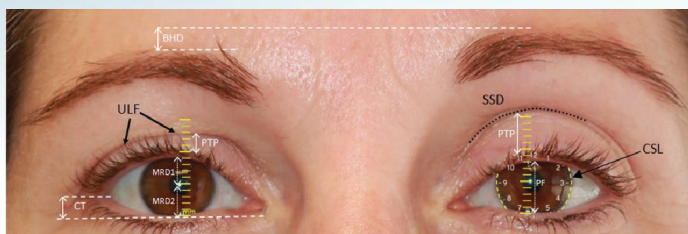A. Severe Ptosis

B. Moderate Ptosis

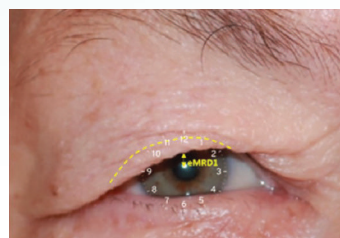C. Mild Ptosis

D. Normal Eyelid

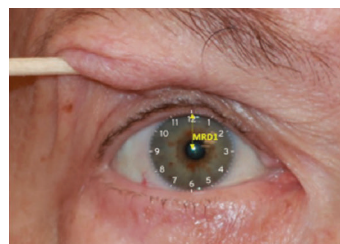
In the below left photo (*see page 10*), note the mild ptosis in the left upper lid accompanied by a compensatory deep superior sulcus. PF refers to the palpebral fissure height, with a graded yellow millimeter ruler shown for measurement. MRD1 represents Marginal Reflex Distance 1, and MRD2 stands for Marginal Reflex Distance 2. To accurately measure the MRD, an excellent light reflex on the corneal apex is necessary. Alternatively, a more qualitative assessment of eyelid position can be made by observing the intersection of the lid margin with the CSL (Corneal-Scleral Limbus), as seen in the left eye (~9.6 to 2.1 clock hours). PTP denotes the Pre-Tarsal Platform, ULF refers to the Upper Lid Fold, SSD signifies the Superior Sulcus Depression or Defect, BHD represents the Brow Height Difference, and CT stands for Canthal Tilt.



Distinguishing between dermatochalasis and blepharoptosis can be challenging, as both



eMRD1



MRD1

conditions present with drooping eyelids and may appear similar, making precise diagnosis crucial for appropriate treatment. The effective margin-reflex distance (eMRD) aids in differentiating these conditions by evaluating functional eyelid obstruction. To assess eMRD, measure the standard margin-reflex distance (MRD1) in primary gaze, then manually lift the overhanging skin and measure again. A notable discrepancy between MRD1 and eMRD implies dermatochalasis, where the visual axis clears as the overhanging skin is lifted, while a minimal difference suggests true blepharoptosis.

ADDRESSING AN OFTEN-OVERLOOKED CONDITION

The term “ptosis,” which originates from the Greek word meaning “falling” or “sinking,” intriguingly illustrates the drooping appearance of the affected body part. Blepharoptosis, or low-lying eyelids, is a widespread issue, primarily caused by age-related changes, but occasionally it may signal a more severe underlying concern. A comprehensive patient history and systematic examination are essential for determining the nature of ptosis, informing the need for ancillary testing and guiding the development of treatment plans.

It is important for clinicians to assess the entire face and consider the overall context before focusing on the periorbital region. This approach helps prevent overlooking related pathologies, such as brow droop or facial weakness, which may impact ptosis management. In some cases, ptosis can lead to a significant impact on a patient’s field of vision, making it vital for clinicians to address the issue to improve visual function and overall quality of life.

By gaining a thorough understanding of acquired ptosis and its potential treatments, clinicians can address this often-overlooked condition more effectively and expand their eye care services. This knowledge empowers them to guide patients with ptosis through the eye care continuum, providing tailored care to meet their unique needs.

References:

1. Bacharach J, Lee WW, Harrison AR, et al. A review of acquired blepharoptosis: prevalence, diagnosis, and current treatment options. *Eye (Lond)*. 2021; Apr 29. [Epub ahead of print].
2. McKean-Cowdin R, Varma R, Wu J, Hays RD, Azen SP, Los Angeles Latino Eye Study Group. Severity of visual field loss and health-related quality of life. *Am J Ophthalmol*. 2007;143: 1013-23.
3. Richards HS, Jenkinson E, Rumsey N, et al. The psychological well-being and appearance concerns of patients presenting with ptosis. *Eye*. 2014;28:296-302.
4. Meyer DR, Stern JH, Jarvis JM, Lininger LL. Evaluating the visual field effects of blepharoptosis using automated static perimetry. *Ophthalmology*. 1993;100:651-8.
5. Small RG, Meyer DR. Eyelid metrics. *Ophthalmic Plast Reconstr Surg*. 2004 Jul;20(4):266-7.

PTOSIS VISUAL FIELD LOSS CAN BE ADDITIVE TO VISUAL FIELD LOSS FROM OTHER CONDITIONS

Ptosis-related visual field loss can worsen the overall impact on a patient's vision when combined with visual field loss from other conditions, such as glaucoma or retinal disorders. Assessing upper eyelid position before performing visual field testing is crucial to avoid misleading results that may affect treatment decisions. In cases of significant ptosis (e.g., MRD1 < 3), taping the upper eyelid up during testing is recommended. Although ptosis alone may cause considerable visual field impairment, the combined visual field loss from ptosis and another coexisting disorder could lead to even greater visual disability. Treating ptosis in patients with concurrent disorders affecting the visual field can substantially enhance their quality of life.

PTOSIS AND VISUAL FIELD LOSS

A 73-year-old woman was referred for glaucoma surgery due to worsening visual fields attributed to low tension glaucoma in both eyes, despite well-controlled eye pressures and stable optic nerve cupping.

Surprisingly, her most recent visual field showed significant progression of superior visual field loss (*Figure 1*). The patient reported frequently bumping her head on overhead cabinets, particularly on the left side.

External examination revealed upper eyelid ptosis, worse in the left eye, with an MRD1 of 2.5mm in the right eye and 1mm in the left eye (*Figure 2*). Intraocular pressures were 11 mmHg in the right eye and 10 mmHg in the left eye. Fundus exam showed enlarged optic nerve cupping in both eyes, similar to optic disc photos from a year prior, except for a new small optic disc hemorrhage in the left eye (*Figure 3*), and OCT appeared unchanged.

Repeat automated perimetry with the left upper eyelid taped revealed a significant improvement in superior visual field loss, now displaying a discrete superior arcuate visual field defect close to fixation (*Figure 4*), similar to previous visual fields. This finding confirmed that glaucoma was stable, and glaucoma surgery was unnecessary.

The patient and referring clinician were advised that the superior visual loss OS could be improved by treatment of the ptosis.

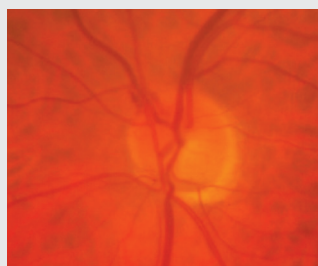


Figure 3. Increased left optic nerve cupping with loss of the inferior neural rim. Despite the small superonasal disc hemorrhage, there was no discernible change in the optic nerve cupping.

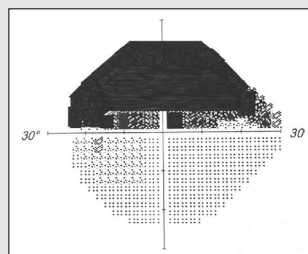


Figure 1. Threshold perimetry of left eye displaying severe diffuse superior visual field loss.

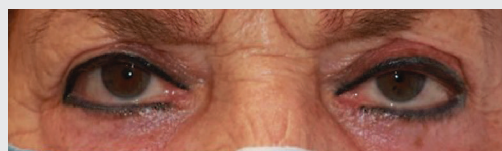


Figure 2. Bilateral upper eyelid ptosis, greater on the left.

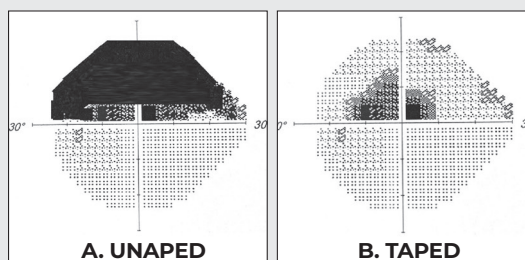


Figure 4. Threshold perimetry, left eye. A. Previous untaped visual field. B. Repeat visual field with the upper eyelid taped showed a discrete superior arcuate visual field defect close to fixation, with elimination of the ptosis contribution to the severe superior visual field impairment.

SPONSORED BY

R V L
PHARMACEUTICALS