

The Wild and Woolly World of Anti-VEGF in 2023, p. 36 • Botox for Blepharospasm and Dystonia, p. 92

# REVIEW<sup>®</sup> *of* OPTOMETRY

46TH ANNUAL  
TECHNOLOGY REPORT

September 15, 2023 • reviewofoptometry.com

Leadership in clinical care

REVEAL HIDDEN  
RETINAL DISEASE  
USING FAF IMAGING

# Times Change

Address the dynamic vision needs of today's  
presbyopes with **INFUSE<sup>®</sup> Multifocal**.



FIND OUT HOW



<sup>®/™</sup> are trademarks of Bausch & Lomb Incorporated or its affiliates.  
©2023 Bausch & Lomb Incorporated or its affiliates. IMF.0019.USA.23

**BAUSCH+LOMB**

REVIEW OF OPTOMETRY • VOL. 160, NO. 9 • SEPTEMBER 15, 2023 • Anti-VEGF Agents • Visual Field



The Wild and Woolly World of Anti-VEGF in 2023, p. 36 • Botox for Blepharospasm and Dystonia, p. 92

# REVIEW<sup>®</sup> *of* OPTOMETRY

46TH ANNUAL  
TECHNOLOGY REPORT

September 15, 2023 • reviewofoptometry.com

Leadership in clinical care

## REVEAL HIDDEN RETINAL DISEASE USING FAF IMAGING

*This marker of metabolic activity lights up  
what's beneath the surface.*

Page 50

### The New Kids on the Block in Visual Field Testing

Page 44

### Ultra-Widefield Imaging: Expand Your Horizons

Page 58

### Low Vision Tools and Techniques You Should Know

Page 66

### EARN 2 CE CREDITS The Definitive Guide to Corneal Topography

Page 72



When Selecting a Prescription  
Dry Eye Treatment

**DON'T**

**MAKE  
HER  
WAIT.**



Not an actual patient.

### **Indication**

Xiidra® (lifitegrast ophthalmic solution) 5% is indicated for the treatment of signs and symptoms of dry eye disease (DED).

### **Important Safety Information**

- Xiidra is contraindicated in patients with known hypersensitivity to lifitegrast or to any of the other ingredients.
- In clinical trials, the most common adverse reactions reported in 5-25% of patients were instillation site irritation, dysgeusia and reduced visual acuity. Other adverse reactions reported in 1% to 5% of the patients were blurred vision, conjunctival hyperemia, eye irritation, headache, increased lacrimation, eye discharge, eye discomfort, eye pruritus and sinusitis.
- To avoid the potential for eye injury or contamination of the solution, patients should not touch the tip of the single-use container to their eye or to any surface.



**Novartis Pharmaceuticals Corporation**  
East Hanover, New Jersey 07936-1080





**CHOOSE XIIDRA**  
Because lasting symptom  
relief can start as early as  
**2 WEEKS<sup>1\*</sup>**



Access to Xiidra is  
better than ever<sup>2</sup>

\*Xiidra reduced symptoms of eye dryness at 2 weeks (based on Eye Dryness Score compared to vehicle) in 2 out of 4 studies, with improvements observed at 6 and 12 weeks in all 4 studies.<sup>1†</sup>

### Important Safety Information (cont)

- Contact lenses should be removed prior to the administration of Xiidra and may be reinserted 15 minutes following administration.
- Safety and efficacy in pediatric patients below the age of 17 years have not been established.

**Please see Brief Summary of Important Product Information on adjacent page.**

#### <sup>†</sup>Pivotal trial data

The safety and efficacy of Xiidra were assessed in four 12-week, randomized, multicenter, double-masked, vehicle-controlled studies (N=2133). Patients were dosed twice daily. **Use of artificial tears was not allowed during the studies.** The study end points included assessment of signs (based on Inferior fluorescein Corneal Staining Score [ICSS] on a scale of 0-4) and symptoms (based on patient-reported Eye Dryness Score [EDS] on a visual analogue scale of 0-100).<sup>1</sup>

Effects on symptoms of dry eye disease: A larger reduction in EDS favoring Xiidra was observed in all studies at day 42 and day 84. Xiidra reduced symptoms of eye dryness at 2 weeks (based on EDS) compared to vehicle in 2 out of 4 clinical trials.<sup>1</sup>

Effects on signs of dry eye disease: At day 84, a larger reduction in ICSS favoring Xiidra was observed in 3 of the 4 studies.<sup>1</sup>

**References:** 1. Xiidra [package insert]. East Hanover, NJ: Novartis Pharmaceuticals Corp. 2. Data on file. DRF Fingertip Formulary<sup>®</sup> Novartis Pharmaceuticals Corp; July 2022.

**XIIDRA, the XIIDRA logo and ii are registered trademarks of Novartis AG.**

## **Xiidra® (lifitegrast ophthalmic solution), for topical ophthalmic use**

**Initial U.S. Approval: 2016**

**BRIEF SUMMARY: Please see package insert for full prescribing information.**

### **1 INDICATIONS AND USAGE**

Xiidra® (lifitegrast ophthalmic solution) 5% is indicated for the treatment of the signs and symptoms of dry eye disease (DED).

### **4 CONTRAINDICATIONS**

Xiidra is contraindicated in patients with known hypersensitivity to lifitegrast or to any of the other ingredients in the formulation [see *Adverse Reactions (6.2)*].

### **6 ADVERSE REACTIONS**

The following serious adverse reactions are described elsewhere in the labeling:

- Hypersensitivity [see *Contraindications (4)*]

#### **6.1 Clinical Trials Experience**

Because clinical trials are conducted under widely varying conditions, adverse reaction rates observed in clinical trials of a drug cannot be directly compared to rates in the clinical trials of another drug and may not reflect the rates observed in practice.

In five clinical trials of DED conducted with lifitegrast ophthalmic solution, 1401 patients received at least one dose of lifitegrast (1287 of which received lifitegrast 5%). The majority of patients (84%) had less than or equal to 3 months of treatment exposure. One hundred-seventy patients were exposed to lifitegrast for approximately 12 months. The majority of the treated patients were female (77%). The most common adverse reactions reported in 5%-25% of patients were instillation-site irritation, dysgeusia, and reduced visual acuity.

Other adverse reactions reported in 1%-5% of the patients were blurred vision, conjunctival hyperemia, eye irritation, headache, increased lacrimation, eye discharge, eye discomfort, eye pruritus, and sinusitis.

#### **6.2 Postmarketing Experience**

The following adverse reactions have been identified during post-approval use of Xiidra. Because these reactions are reported voluntarily from a population of uncertain size, it is not always possible to reliably estimate their frequency or establish a causal relationship to drug exposure.

Rare serious cases of hypersensitivity, including anaphylactic reaction, bronchospasm, respiratory distress, pharyngeal edema, swollen tongue, urticaria, allergic conjunctivitis, dyspnea, angioedema, and allergic dermatitis have been reported. Eye swelling and rash have also been reported [see *Contraindications (4)*].

### **8 USE IN SPECIFIC POPULATIONS**

#### **8.1 Pregnancy**

##### Risk Summary

There are no available data on Xiidra use in pregnant women to inform any drug-associated risks. Intravenous (IV) administration of lifitegrast to pregnant rats, from pre-mating through gestation day 17, did not produce

teratogenicity at clinically relevant systemic exposures. Intravenous administration of lifitegrast to pregnant rabbits during organogenesis produced an increased incidence of omphalocele at the lowest dose tested, 3 mg/kg/day (400-fold the human plasma exposure at the recommended human ophthalmic dose [RHOD], based on the area under the curve [AUC] level). Since human systemic exposure to lifitegrast following ocular administration of Xiidra at the RHOD is low, the applicability of animal findings to the risk of Xiidra use in humans during pregnancy is unclear [see *Clinical Pharmacology (12.3) in the full prescribing information*].

##### Data

##### Animal Data

Lifitegrast administered daily by IV injection to rats, from pre-mating through gestation day 17, caused an increase in mean pre-implantation loss and an increased incidence of several minor skeletal anomalies at 30 mg/kg/day, representing 5,400-fold the human plasma exposure at the RHOD of Xiidra, based on AUC. No teratogenicity was observed in the rat at 10 mg/kg/day (460-fold the human plasma exposure at the RHOD, based on AUC). In the rabbit, an increased incidence of omphalocele was observed at the lowest dose tested, 3 mg/kg/day (400-fold the human plasma exposure at the RHOD, based on AUC), when administered by IV injection daily from gestation days 7 through 19. A fetal no observed adverse effect level (NOAEL) was not identified in the rabbit.

#### **8.2 Lactation**

##### Risk Summary

There are no data on the presence of lifitegrast in human milk, the effects on the breastfed infant, or the effects on milk production. However, systemic exposure to lifitegrast from ocular administration is low [see *Clinical Pharmacology (12.3) in the full prescribing information*]. The developmental and health benefits of breastfeeding should be considered, along with the mother's clinical need for Xiidra and any potential adverse effects on the breastfed child from Xiidra.

#### **8.4 Pediatric Use**

Safety and efficacy in pediatric patients below the age of 17 years have not been established.

#### **8.5 Geriatric Use**

No overall differences in safety or effectiveness have been observed between elderly and younger adult patients.

Distributed by:  
Novartis Pharmaceuticals Corporation  
One Health Plaza  
East Hanover, NJ 07936  
T2020-87



## New Hampshire Governor Signs Bill Allowing ODs to Administer Vaccines

*This includes shots for influenza, COVID-19 and shingles. The law takes effect next month.*

The number of healthcare providers in New Hampshire who can administer FDA-approved vaccinations to patients shot up (no pun intended) by several hundred in early August when Governor Chris Sununu signed Senate Bill 200, authorizing optometrists in the state to administer vaccines to adults aged 18 and older for influenza, COVID-19 and shingles.

“The ability for licensed optometrists to provide vaccines means more choice for patients, and possibly more convenience, as optometrists often have patients who have their regular eye exam but do not have or don’t see a primary care physician,” comments Erica Griffin, OD, president of the New Hampshire Optometric Association (NHOA).

The bipartisan legislation was first introduced in January of this year, and by June, it had passed both the state House and Senate with strong advocacy efforts led by the NHOA and optometrists across the state.

“Our ask was logical; we stuck to the facts and addressed OD training and patient access,” notes Dr. Griffin. “We pointed out that due to an anomaly in our statute, someone with only a high school education could administer vaccines but an independently-practicing doctorate-level health provider cannot,” she adds. “There was no disagreement among the legislators.”

An amendment introduced in the state House in May threatened to delay the bill’s inclusion of mRNA vaccines by two years while research continues to be conducted on the new drug; however, a majority vote opposing the amendment ensured that the newly enacted law will still permit New Hampshire optometrists to administer these vaccines for COVID-19.

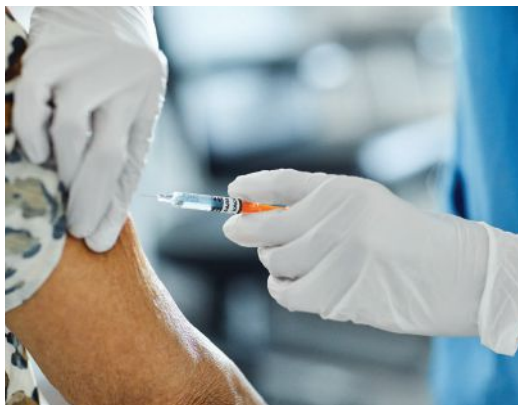legislative process; however, these were minor and related to the qualifications of optometrists who wish to administer these vaccines to their patients. For example, unlike the introduced bill, the signed document states that optometrists must have at least \$1,000,000 of professional liability insurance coverage and have active certification in basic cardiopulmonary resuscitation, along with other requirements.

Similar to other professions’ vaccination guidelines, ODs will also be required to review the patient’s vaccine history prior to administration, record the vaccination in the state registry and submit reports of any adverse reactions to the CDC Vaccine Adverse Event Reporting System.

American Optometric Association president, Ronald L. Benner, OD, offers his praise to all of those who played a hand in the passage of SB 200. “After tireless dedication and fortitude, the NHOA and New Hampshire doctors of optometry should be proud of this important step forward for the profession and patients across the state,” he says. “This win is a clear example of the expanding recognition of our primary eye health and vision care role and demonstrates the common sense progress we can accomplish when we come together to fight for what is best for our patients.”

The new law goes into effect 60 days from the governor’s signature, which will land in the first week of October. ◀

Photo: Getty Images



**Once the new law goes into effect, optometrists in New Hampshire will be able to provide approved vaccines to patients who may not have or see a PCP.**

“It was very frustrating for me and other optometrists on the frontline during the pandemic being underused during the COVID-19 vaccination pushes, particularly when President Biden gave the go-ahead at the federal level for optometrists to administer vaccines,” says Dr. Griffin. “This new law is progress toward being allowed to use our skills and training for the greater benefit of our patients.”

The House and Senate did adopt several other amendments throughout the



# Female Sex Hormone Changes Impact the Cornea Throughout a Woman's Life

Several features vary pre- vs. postmenopause and during pregnancy, including thickness, IOP and dry eye symptoms.

Women experience fluctuating sex hormone levels throughout the stages of their life. As a hormone-responsive tissue, the cornea's structure and function are directly impacted by these changes. The shifting balance of sex hormones in women over time has been shown to affect central corneal thickness (CCT), intraocular pressure (IOP) and tear film quality.

Recently, researchers conducted a systematic review of 55 articles from multiple databases to take a closer look at the corneal changes presenting in women during the three hormonal milestones: menarche, pregnancy and menopause.

The team identified several studies that present evidence of the effect of sex hormones on CCT at menarche and during the menstrual cycle. One study “demonstrated that the central cornea tends to be thinnest at the start of the menstrual cycle (542 $\mu$ m) and thickest at mid-cycle (*i.e.*, during ovulation; 559 $\mu$ m),” the researchers cited in their paper in *BMC Ophthalmology*. Several other studies agreed with this finding, but not all; for instance, one found CCT was greatest at ovulation (556 $\mu$ m) and thinnest at the end—rather than the beginning—of the cycle (536 $\mu$ m).

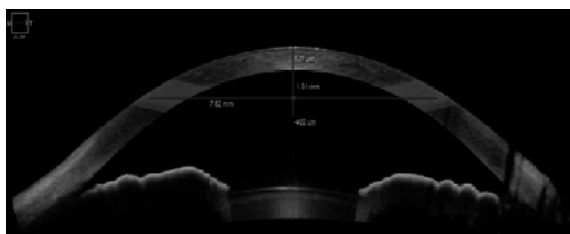
The consensus surrounding the impact of sex hormones on IOP was more straightforward; numerous studies identified higher IOP levels at ovulation vs. at the end of the menstrual cycle (in one study, the difference was 1mm Hg). Like age, race and gender, sex hormones are among the factors that govern IOP level by influencing aqueous production rate, the function of outflow pathways through the trabecular meshwork and episcleral venous system, as well as corneal curvature and thickness, the researchers explained.

Several discrepancies existed between studies regarding the influence of sex hormone changes on the ocular surface at menarche and during menstruation. For example, one study observed no significant changes in TBUT during the menstrual cycles of 17 premenopausal females, while another found a statistical difference in tear stability between several phases of menstruation, except in patients with preexisting dry eye disease.

Next, the review authors reported on corneal changes in patients during pregnancy. Most studies noted that CCT increases by an average of 3.1% while IOP decreases by 9.5% between the first and third trimesters.

“Given the presence of estrogen, progesterone and androgen receptors within corneal epithelial cells, it is plausible that changes in female sex hormone levels could directly cause CCT changes,” the authors noted. Regarding the observed decrease in IOP during pregnancy, they cite one proposed mechanism that “hypothesizes a relationship between female sex hormones and an increase in aqueous humor outflow capacity.” They added, “Peak levels of progesterone, estrogen and relaxin at the end of pregnancy correlate inversely with IOP.”

Hormonal shifts during menopause oppose those during pregnancy (characterized by a drop, rather than an increase, in both estrogen and progesterone); likewise, the corneal changes seen during this milestone are also opposite of those seen during pregnancy. Postmenopausal women typically have decreased CCT and increased IOP levels when compared with premenopausal women.



The cornea is directly affected by sex hormone changes, shown in this literature review by altered corneal features in women during menarche, pregnancy and menopause.

Photo: Carl Zeiss Meditec

Postmenopausal women were also shown in numerous studies to have a higher incidence of dry eye disease, worse OSDI scores and worse tear stability than premenopausal women. “The literature suggests inflammation of the lacrimal gland, diminished meibomian gland tissue and reduced lipid production secondary to androgen deficiency as the possible underlying mechanisms,” the researchers wrote in their review.

External hormonal treatments (*i.e.*, hormone replacement therapy) were shown to affect corneal features to varying degrees in each hormonal milestone. In some cases, hormonal treatment had a positive effect on the cornea, leading several authors to consider its therapeutic potential. However, the review concluded that it remains inconclusive whether systemic or topical estrogen supplementation benefits ocular surface health.

Based on current research, it's evident that female sex hormones impact corneal structure and function throughout a woman's life. As knowledge on this subject grows, clinicians can better understand the ocular symptoms women experience as they age, improve surgical risk assessment and use an informed approach to tailor interventions and procedures to patients. ◀

Kelly DS, Sabharwal S, Ramsey DJ, Morkin MI. The effects of female sex hormones on the human cornea across a woman's life cycle. *BMC Ophthalmol.* 23(1):358.

# Emergency Depts. Strained by Neuro-ophth Referrals

Study finds patients are flocking to hospitals due to the subspecialty's shortage of providers nationwide.

The suggested workforce-to-population ratio required for adequate delivery of neuro-ophthalmology services has been estimated to be one specialist per 1.2 million people. However, in 2022 only eight US states meet this threshold; in the worst-served regions, six had no neuro-ophthalmologists in the entire state. With increasing outpatient demand, and the subspecialty's scarcity, one new study wanted to determine what the typical presentations to the emergency department (ED) for related issues look like.

The prospective study published in *Ophthalmology* included one academic care institution's ED and inpatient neuro-ophthalmology consultation patterns and patient outcomes over one year. Of the 494 adult consultations, 49% took place at night or on week-ends. Of the emergency consults (65%), 39% occurred during weekdays, 39% on weeknights and 22% on weekends/holidays. Of 322 ED consultations, 70% presented with a chief neuro-ophthal-mic complaint.

Referrals to the ED by healthcare professionals were primarily made by eyecare specialists (76%). Most commonly encountered questions for emergency referral were due to papilledema at 23% and vision loss at 22%. A sizable 68% had a final active neuro-ophthal-mic diagnosis, 69% had high or very high complexity and 44% needed admission.

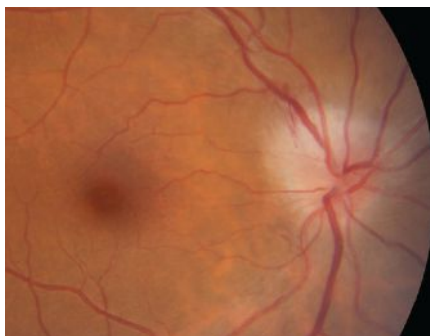


Photo: Christine Smith, OD

**Creating hospital protocols for neuro-ophthalmologic conditions like TIA-related transient vision loss, acute central retinal artery occlusion, papilledema and optic neuritis (pictured) could streamline management of complex patients.**

Of the remaining 172 inpatient consultations, most were requested by hospitalists, including neurologists (41%) and oncologists (12%) for vision loss (25%) and eye movement disorders (20%), as well as neurosurgery (33%) to examine for mass or pre-op evaluation (11%). Active neuro-ophthalmic diagnosis was confirmed in 67% of patients, and a striking 90% of cases found neuro-ophthalmic assessment appropriate to make a diagnosis or evaluate for ophthalmic manifestations of disease.

The authors note that, overall, 61% of patients were diagnosed with a life- or vision-threatening pathology. Of the 49% of consultations occurring during off-hours, only 25% of these were urgent—highlighting “the paradoxical relationship between the additional

burden generated by these unscheduled urgent neuro-ophthalmology consults and the genuine need for these patients to be examined by a neuro-ophthalmologist, to whom limited access generates more such consultations.”

Driving the spikes in neuro-ophthalmology referrals or consultations are factors of delayed consultations resulting in diagnostic errors, increased cost and worse outcomes, made worse by associated litigation risk for the provider if not done promptly. Further motivation for patient referral to hospitals rather than outpatient clinics is that ED or hospital evaluation is more time efficient, allowing for immediate multidisciplinary care and testing.

To deal with the rising rates, the authors propose that increasing the number of available outpatient neuro-ophthalmologists may be one solution. They also propose that “there is a need for expanded development and utilization of technological and diagnostic aids such as nonmydriatic fundus cameras in EDs as well as telehealth delivery processes for integration into healthcare settings. Finally, creating and implementing standardized neuro-ophthalmology ED and hospital protocols for common presentations and diseases should facilitate rapid diagnosis and treatment of common neuro-ophthalmologic disorders.”

Smolar ALQ, Ray HJ, Dattilo M, et al. Neuro-ophthalmology emergency department and inpatient consultations at a large academic referral center. *Ophthalmology*. August 4, 2023. [Epub ahead of print].

## IN BRIEF

■ **Macular Atrophy Differs Significantly in Wet vs. Dry AMD.** A new retrospective study evaluated 124 anti-VEGF-treated patients with wet AMD in one eye and dry AMD in the fellow eye. The researchers reported that the first detection of macular atrophy in wet AMD eyes without macular atrophy at baseline increased significantly between years two and six, compared with dry AMD eyes.

Significantly more wet AMD eyes (45%) developed macular atrophy during the study's follow-up period, compared with 16.5% of dry AMD fellow eyes. Comparing both eyes' macular atrophy progression in a synchronous paired manner over four years showed that wet AMD eyes had an average macular atrophy progression rate of 0.275mm/year compared with 0.11mm/year in the dry AMD fellow eye.

However, when they compared progression between the two eyes in

an asynchronous manner, they found that when macular atrophy developed in dry AMD eyes, it progressed significantly faster than wet AMD eyes (0.295 mm/year in dry AMD vs. 0.176mm/year in wet AMD) with a significant time-eye interaction.

Overall, the researchers conclude that treated wet AMD eyes demonstrate more macular atrophy compared with fellow dry AMD eyes. “This indicates that in patients that, for a certain time period, maintain asymmetry between their two

eyes in regard to neovascularization presence, this asymmetry tends to exist for the atrophic component of their disease too, during this period.” However, they added, when macular atrophy does appear in dry AMD eyes, “it has a significantly higher growth rate” compared to wet AMD eyes.

Blazaki S, Blavakis E, Chlouverakis G, et al. Evolution of macular atrophy in eyes with neovascular age-related macular degeneration compared to fellow non-neovascular eyes. *Graefes Arch Clin Exp Ophthalmol*. August 11, 2023. [Epub ahead of print].

# Pregnancy-related Weight Gain Carries Lower Papilledema Risk in IIH

Research suggests this may be related to a difference in weight distribution or hormonal changes.

While research has shown that weight gain is likely a risk factor for recurrent papilledema in idiopathic intracranial hypertension (IIH), this may not apply to pregnancy-related weight gain, as suggested by the findings of a recent small study. When the researchers examined the clinical data of 13 pregnant women with IIH, they noted that the risk presented by weight gain was not as significant as it is in non-IIH patients. Rather, the cohort demonstrated a high rate of stable or even decreased disc edema despite medication discontinuation and excess pregnancy weight gain.

The retrospective chart review analyzed OCT findings and Humphrey visual field data, determined excess pregnancy weight gain using body mass index-adjusted weight gain goals and correlated IIH symptom worsening to changes in papilledema. The 13 patients included had at least two visits with neuro-ophthalmology during pregnancy, and data were compared from clinic visits before, during and after pregnancy.

At the baseline visit, three patients had low-grade disc edema and 10 had none. During pregnancy, three patients had increased papilledema, two of which developed new peripheral visual field defects that persisted after delivery. The other 10 patients had either stable

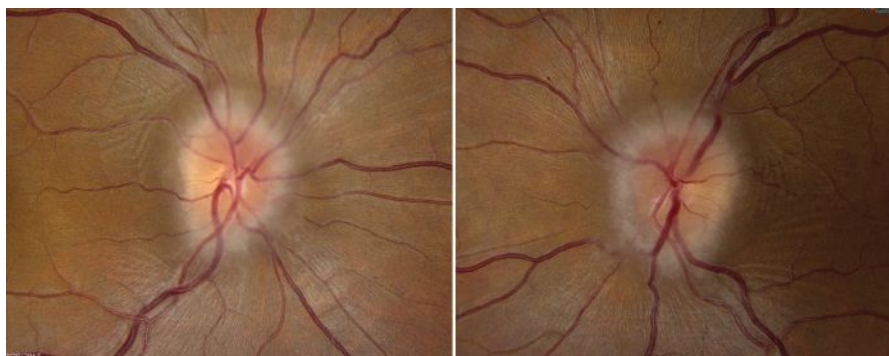


Photo: Mark Dunbar, OD

**In a small study of 13 pregnant women with IIH, most remained stable without developing disc edema from pre- to post-pregnancy despite having gained weight—a known risk factor for papilledema in IIH.**

or improved disc edema during pregnancy, despite the fact that all patients showed more than the 6% weight gain that is typically observed in recurrent IIH, 11 gained more than their weight from initial diagnosis and eight had excess pregnancy weight gain. Six patients had also discontinued their medication for IIH.

Of the seven patients who attended post-pregnancy clinic visits, one had increased disc edema ( $>100\mu\text{m}$ ), one had improved disc edema and five were stable without any disc edema.

The researchers suggest the reduced risk of weight gain on IIH in expectant mothers may be related to weight distribution or endocrine changes during pregnancy. They elaborate on

this hypothesis in their study, published in *Journal of Neuro-Ophthalmology*:

“Potential explanations may include a different distribution of weight (abdomen rather than neck and therefore less reduction in venous return from the brain), pregnancy hormonal changes, ‘lean body weight gain’ of the fetus and placenta rather than additional adipose tissue, or other less obvious causes.”

Due to this study’s small sample size, further research will need to be conducted before using this data to counsel IIH patients who are or plan to become pregnant. ◀

Lambert-Cheatham NA, Nagia L, Pasmanter NR, et al. Impact of pregnancy on papilledema and vision loss in idiopathic intracranial hypertension patients: a chart review and case series of 13 patients. *J Neuroophthalmol*. August 4, 2023. [Epub ahead of print].

## IN BRIEF

■ **White Blood Cells May Be Useful DME Biomarkers.** Diabetes and its complications are closely associated with chronic inflammation, and retinal inflammation is also thought to contribute to diabetic macular edema (DME). In a paper recently published in *Frontiers in Endocrinology*, researchers pointed out that complete blood count is “an affordable and readily available test” for assessing inflammation,

since white blood cells (WBC) are considered inflammatory response biomarkers. They investigated the potential relationship between peripheral blood biomarkers and DME, and found that they may hold clues to disease pathogenesis. “Compelling evidence suggests that the elevated physiological WBC count is associated with the presence and severity of diabetic retinopathy (DR) as well as DME,” the researchers noted in their paper.

The team’s cross-sectional, hospital-based study included the

contralateral eyes of 239 inpatients (mean age 55) with type 2 diabetes who underwent vitrectomy for proliferative DR. Patients’ average central macular thickness was  $284.23\mu\text{m}$ . Models showed a significantly negative association between central macular thickness and both WBC and neutrophil count. For eyes with DME, there was an inverse association between DME and WBC, monocyte count and eosinophil count.

“This clinical study demonstrated that lower physiological WBC levels

are associated with increased central macular thickness as well as the odds of DME in Chinese patients with proliferative DR,” the researchers wrote. “Our results show that WBC and its subtypes in circulation may play an important role in the pathogenesis of DME in proliferative DR patients.”

Lei C, Gu J, Liu L, et al. The correlation between peripheral complete blood count parameters and diabetic macular edema in proliferative diabetic retinopathy patients: a cross-sectional study. *Front Endocrinol* 2023;14:1190239.



# The Sky is the Limit



## OCULUS Easyfield®

The OCULUS Easyfield® is not only a screener but also designed for use as a threshold perimeter for immediate re-examination of any abnormal findings. One of the most striking features is its small footprint! Its compact design and light protected bowl enable examinations to be performed in rooms with normal lighting conditions. The perimeter is robust and light-weight, making it well-suited for portable use.

Your compact device for affordable and fast automated perimetry.

Learn more: [www.oculususa.com/easyfield](http://www.oculususa.com/easyfield).



Scan here or visit  
[www.oculususa.com](http://www.oculususa.com)

Toll free 888-519-5375  
[ads@oculususa.com](mailto:ads@oculususa.com)

 OCULUS®

# Should Accommodative Spasm in Kids Be a Concern?

As rates of myopia continue to increase, researchers are looking for ways to identify and prevent the condition earlier. One study out of China's Shangdong province contributed to this by investigating whether pseudomyopia is an independent risk factor for myopia onset. They found that an alarming 21.2% of pseudomyopia eyes converted to myopia by six months.

A total of 2,328 non-myopic children aged four to 17 were recruited from schools in the province and underwent baseline exams and six-month follow-

ups. Pseudomyopia was defined as SE of  $\leq -0.50D$  before cycloplegia and  $> -0.50D$  after cycloplegia. Myopia was defined as cycloplegic SE of  $\leq -0.50D$ . At the six-month follow-up, 21.1% pseudomyopic eyes developed myopia, while only 3.8% of non-myopic and non-pseudomyopic eyes developed myopia. Pseudomyopia was common, existing at a rate of 37.2%.

Pseudomyopia was identified as an independent risk factor for myopia onset after adjusting for known risk factors. Higher risk was seen in pseudomyopic kids with more myopic cycloplegic SE, smaller difference between cycloplegic and non-cycloplegic SE and higher binocular amplitude of accommodation.

The study authors urge that "clinicians should envisage that children, once they are in premyopia status, are at significantly increased risk of developing myopia, and thus all prophylactic measures should be adopted (*i.e.*, outdoor time intervention)."

A prior study found that hyperopic kids with more near work-induced tran-

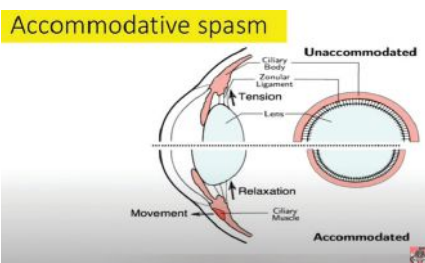
sient myopia experienced more relative myopic refraction progression. Another found the conflicting result that pseudomyopia was not associated with myopia progression.

However, the authors point out that the current study aimed to clarify if pseudomyopia is associated with myopia onset, not myopia progression. The increased prevalence of the pseudomyopia rate in this research may be caused by increased near work and electronic device use with homeschooling during the COVID-19 pandemic, as baseline examinations occurred in September 2020.

Although future research is needed to fully understand the underlying reasons for the phenomenon, the authors contend that "our study findings provide important evidences that children with pseudomyopia are more likely to develop myopia than those without." ◀

Sun W, Yu M, Wu J, et al. Pseudomyopia as an independent risk factor for myopia onset: a prospective cohort study among school-aged children. *Br J Ophthalmol*. August 4, 2023. [Epub ahead of print].

Photo: OptometristLepKSNHAYouTube



**The ubiquity of digital device usage is increasingly taxing the accommodative system and contributing to the rise in myopia cases worldwide.**

# Corneal Plus Conjunctival Staining Most Definitive for DED Dx

Accurate diagnosis of dry eye disease can be difficult. Many of the tests require significant time and skill to interpret and synthesize, often making it impractical to conduct the full battery.

The TFOS DEWS II report put forth a set of standard test procedures for diagnosis. To establish the utility of each diagnostic measure, researcher Eric Papas, MCOptom, PhD, calculated the probability of a correct dry eye diagnosis given a positive result for a range of standard tests. His analysis showed that at an assumed prevalence of 11.6%, corneal staining had the highest probability of a correct diagnosis (0.28), and OSDI had the lowest probability (0.14).

Dr. Papas also found that the best combination of symptoms with a single test of tear film homeostasis was

## BEST AND WORST CHANCES OF CORRECT DX (GIVEN A POSITIVE RESULT)

Best	Worst
Corneal staining alone [28%]	OSDI alone [14%]
DEQ5 + corneal staining with symptoms + a single test of TF homeostasis [42%]	OSDI + TBUT with symptoms + a single test of TF homeostasis [23%]
Conjunctival + corneal staining [49%]	Any single test alone

the five-item Dry Eye Questionnaire (DEQ5) + corneal staining (0.42). The worst was OSDI + tear film break-up time (TBUT) results (0.23). Simultaneous observation of both conjunctival and corneal staining was associated with a probability of 0.49.

He also reported a greater chance of a correct diagnosis with more positive tests, up to a maximum of 0.9 when DEQ5, conjunctival and corneal staining, osmolarity and TBUT were positive.

He concluded, in his article for *Contact Lens & Anterior Eye*, that corneal staining is the single most useful test, but added, "the likelihood of correct diagnosis is considerably improved by considering the simultaneous occurrence of conjunctival AND corneal staining as the key positive outcome. It's recommended that this criterion be specified in diagnostic guidelines for dry eye disease." ◀

Papas EB. Diagnosing dry-eye: which tests are most accurate? *Contact Lens and Anterior Eye*. 2023. [Epub ahead of print].






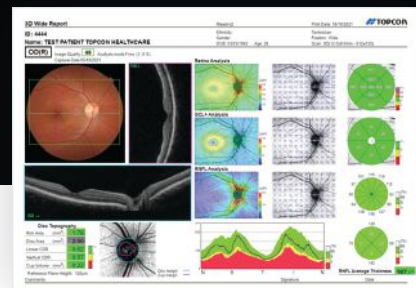
# MAESTRO2

## Fully Featured OCT + Fundus Camera

- Rich analysis of the retina, optic nerve and anterior segment using easy-to-interpret reports
- 12x9mm widefield OCT scan encompasses both the macula and disc for a comprehensive and efficient evaluation of eye health
- Easy to operate robotic OCT

Comprehensive Reporting in Just One Click

### 3D Wide Scan Report



## MAESTRO2 OCT CERTIFICATION COURSE

With the purchase of a Maestro2, your staff will receive comprehensive training by enrolling in our **Maestro2 OCT Certification Course** and earn **FREE CE Credits**.

[Scan to Learn More](#)





# Evidence Lacking for Blue-Light Blocking Lens Claims

*A systematic review determines that this modality may not reduce short-term eye strain associated with computer work.*

There remains significant debate surrounding whether blue-light filtering or blocking spectacle lenses have merit in ophthalmic practice. These lenses are frequently prescribed (sometimes in preference to standard spectacles lenses) in eyecare practice and a range of marketing claims exist surrounding their potential benefits to reduce visual fatigue from digital device use, protect the macula and improve sleep quality. The mechanisms by which these lenses might impart at least some of these effects remains unclear.

To gain some clarity on the matter and help answer the increasingly common question asked by patients, “Do blue-light glasses actually work?”, a recent Cochrane Review investigated the possible advantages and safety of blue-light filtering spectacle lenses. Their analysis determined that there may be no short-term advantages with using blue-light filtering lenses to reduce visual fatigue with computer use. No obvious harmful effects appeared to result from short-term wear, either. However, the authors cautioned that there is limited information about the potential positive or negative effects of these lenses on visual acuity and sleep-related measures.

The systematic review included 17 studies that recruited 619 people aged 18 and older and took place in six countries. Sample sizes ranged from five to 156 participants, and intervention follow-up periods ranged from less than one day to five weeks. A variety of participant characteristics was represented across the studies, includ-

ing healthy adults as well as individuals with mental health and sleep disorders.

The researchers judged 65% of the studies to have a high risk of bias due to outcome assessors not being masked (detection bias) and 59% to be at high risk of bias of performance bias as participants and personnel were not masked.



Photo: Joshua Kettle on Unsplash

**Some evidence that harmful effects may be related to using blue-light blocking lenses include headache, increased depressive symptoms, lowered mood and discomfort during wear. However, similar adverse effects were also reported with non-blue-light blocking lenses, and there was not enough data to accurately measure or determine possible harmful effects with certainty.**

The systematic review found that blue-light filtering spectacle lenses may not reduce symptoms of eye strain with computer use over a short-term follow-up period, compared with non-blue-light filtering lenses. Further, the researchers found no clinically meaningful difference in changes to critical fusion frequency with blue-light filtering lenses compared with non-blue-light filtering lenses.

Also, potential harmful effects were temporary and mostly mild, and thought to be related to the glasses more generally rather than specifically to the lenses themselves.

The researchers additionally noted that there were no clear associations

found between the type of device used and patient outcomes, though future research on a potential relationship might be beneficial.

Because none of the included studies investigated contrast sensitivity, color discrimination, discomfort glare, macular health, serum melatonin levels or overall patient visual satisfaction, the

review could not draw any conclusions regarding these measures.

“Based on the current best available evidence, there is probably little or no effect of blue-light filtering lenses on best-corrected visual acuity compared with non-blue-light filtering lenses,” the authors of the paper wrote.


“Our ability to draw conclusions about the effect of blue-light filtering spectacle lenses on many of the prespecified secondary outcomes was limited by the available evidence, with most trials not reporting quantitative data, having

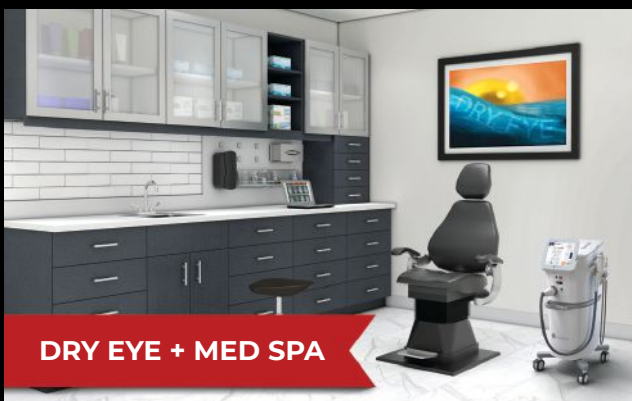shorter follow-up periods than the period of interest defined in our systematic review protocol or heterogeneous study populations that limited our capacity for quantitative syntheses,” the team added.

“Overall, the results of this review indicate that future high-quality research is required to more clearly define the potential effects of blue-light filtering lenses on visual performance, sleep and macular health, including whether efficacy and safety outcomes are distinct in different study populations,” the authors concluded. ◀


Singh S, Keller PR, Busija L, et al. Blue-light filtering spectacle lenses for visual performance, sleep and macular health in adults. *Cochrane Database Syst Rev.* 2023;8(8):CD013244.

# Your Complete Resource.

MERCHANDISING · SPACE PLANNING · DESIGN · 



DRY EYE + MED SPA



PROJECT LOCATION:  
PRELIMINARY

CREATE  
BUILD  
INSPIRE

**EYEDESIGNS**  
CUSTOM INTERIORS + FURNITURE *group*

800-346-8890 · [www.eyedesigns.com](http://www.eyedesigns.com)



DESIGN  
STARTS  
HERE!

VIEW BOOTH 14065

EXAM LANES · LIGHTING · SEATING · OPTICAL ART · & MORE

# OCT Artifacts Present in Half of Patients with Both High Myopia and Glaucoma

Predictive factors included a longer axial length, a higher pattern standard deviation and thinner RNFL.

While OCT is a useful and often reliable tool for diagnosing and monitoring glaucoma, it's important that clinicians recognize the presence of imaging artifacts to avoid inaccurate scan interpretation. A new study in *Journal of Glaucoma* suggests this may be especially crucial when assessing glaucoma patients who also have high myopia, as it noted a higher prevalence of imaging artifacts among these patients compared with non-myopes.

The prospective study enrolled 226 patients with glaucoma and/or high myopia divided into four groups based on their refractive status and which condition(s) they had: non-high myope controls, non-high myope glaucoma patients, highly myopic patients and highly myopic patients with glaucoma. For each patient, peripapillary retinal nerve fiber layer (RNFL) scan images were inspected for artifacts.

The prevalence of OCT artifacts among the cohort was significantly higher in high myopes (51.9%) than in non-high myopes (18.6%), though the most common type of artifact differed between the two; in high myopes, retinal pathology-related artifact was the most common type (23%; 4% in non-high myopes), and in non-myopes, this was outer RNFL border misidentification (11%; 19.4% in high myopes).

The researchers also determined three prominent predictive factors for the presence of OCT artifacts: a longer axial length (odds ratio [OR]: 1.82), a higher pattern standard deviation (OR: 1.19) and thinner RNFL (OR: 0.95).

“Overall, OCT artifact is relatively uncommon in a non-highly myopic normal population (4.9%),” the researchers wrote in their study. “However, the prevalence of OCT artifacts becomes much higher

with a patient having glaucoma (33.3%), high myopia (43.5%) or both (63.0%).”

They go on to explain a few reasons why artifacts are more common in these patients. For example, regarding outer RNFL border misidentification in high myopes, the study authors note that “extreme elongation of the globe may result in an inadequately captured image due to exceeding the diopter compensation of the device or from insufficiently reflected image signals.” They add, “Distortion of the posterior pole may also result in a highly curved peripapillary retinal image on OCT and could hinder the segmentation algorithm from accurately identifying the outer RNFL border.” The authors also note that in high myopes, irregularity in the contour of the peripapillary region can lead to a variable focusing effect and irregular light scattering, increasing the likelihood of segmentation errors.

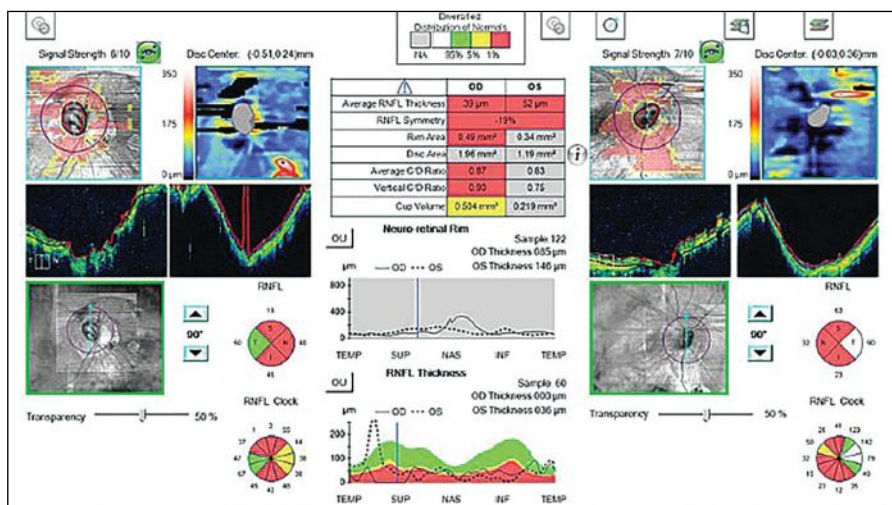
Retinal pathology-related artifact, the most common observed in highly myopic patients in this study, may

appear as the loss or disruption of the retinal pigment epithelium layer, RNFL plaques, retinal thinning or abnormal retinal sloping.

Imaging acquisition artifact was among the less common types observed and can often be reduced through more technician training and experience, the authors noted. However, they did find that motion artifact had a prevalence of 9.3% in high myopes vs. 0.8% in non-myopes, which they hypothesized “could reflect the difficulties in reaching an adequate focal plane, needing frequent adjustments to obtain an OCT image in high myopes as their eyeballs are more elongated than normal eyes.”

In light of these findings, the researchers advise that special care should be taken when interpreting OCT scans of patients with glaucoma, high myopia or both to ensure accurate assessment and informed clinical decision-making. ◀

Poon LYC, Wang CH, Lin PW, et al. The prevalence of optical coherence tomography artifacts in high myopia and its influence on glaucoma diagnosis. *J Glaucoma*. 2023;32:7.

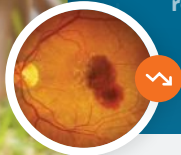

This study found a much higher rate of imaging artifacts in high myopes vs. non-myopes, which researchers suggest may be due to various factors such as globe elongation and posterior pole disruption. This abnormal OCT shows poor segmentation in both the heat maps and tomograms in a high myope.

Photo: Andrew Rouse, OD



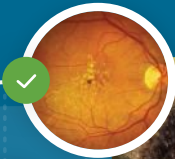# Prevent AMD Vision Loss with Digital Healthcare



IRIS REGISTRY

**20/83 VA**

Average at wet AMD diagnosis according to IRIS Registry real-world data<sup>1</sup>



ALOFT STUDY

**≥20/40 VA**

Average at wet AMD diagnosis with ForeseeHome<sup>2</sup>



**ForeseeHOME™**  
AMD Monitoring Program

## Early Detection Helps Preserve Vision

ForeseeHome is a **remote monitoring** program for at-risk dry AMD patients that helps **detect wet AMD earlier** and alerts you of changes.


## Remote patient monitoring leads to better outcomes and stronger optometric practices

✓ FDA Cleared    ✓ Medicare Covered

- Plug and play digital health solution for your patients
- Solidify long-term relationships with your patients
- No cost to your practice
- Strengthen your referral relationships with qualified wet AMD referrals

## The Key to Successful Home Monitoring

**NOTAL VISION MONITORING CENTER**



Engagement & Education

Benefits Verification & Authorization

Continuous Monitoring



Practice Workflow Implementation

Remote Patient Management

Vision Alert Management



ForeseeHome is a registered trademark, and the ForeseeHome AMD Monitoring Program and logo and the Notal Vision logo are trademarks of Notal Vision. © 2023 Notal Vision, Inc. All rights reserved.

References: 1. Rao P et al. *Ophthalmology*. 2018;125(4):522-528. 2. Mathai M, Reddy S, Elman MJ, Garfinkel RA, Ladd B, Wagner A, Sanborn GE, Jacobs J, Busquets M, Chew EY; ALOFT study group. Analysis of the Long-term visual Outcomes of ForeseeHome Remote Telemonitoring - The ALOFT study. *Ophthalmology Retina*. 2022;6:922-929.

See website for FDA Indication for Use.

SM-169.3



**GET STARTED TODAY**

**1-855-600-3112**

Mon-Fri, 8 AM to 6 PM EST

[notalvision.info/revopt](https://notalvision.info/revopt)

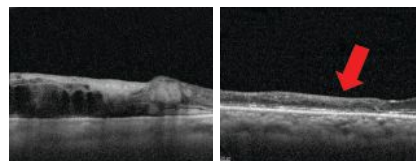
# FEATURES

REVIEW OF OPTOMETRY • Vol. 160, No. 9 • SEPTEMBER 15, 2023

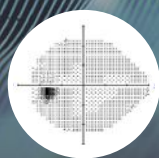
## 36 The Wild and Woolly World of Anti-VEGF in 2023

A once-simple treatment protocol has gotten more sophisticated—and complicated—by novel drug compounds, varied dosing regimens and sustained-release delivery methods. Here's the current state of affairs.

By Jessica Haynes, OD, and Mohammad Rafieetary, OD



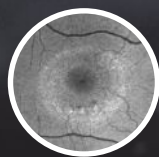
## 46TH ANNUAL TECHNOLOGY REPORT



### 44 The New Kids on the Block in Visual Field Testing

Move over, SAP machines—updated technologies available today provide a more accurate and clearer diagnosis in glaucoma and optic neuropathy.


By Elyse Banister, OD, Shaun Brennan, OD, Brian Fisher, OD, Michelle Nguyen, OD, and Nirmani Karunathilake, OD



### 50 Reveal Hidden Retinal Disease With FAF Imaging

This marker of metabolic activity lights up what's beneath the surface.

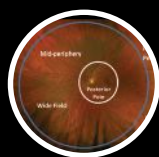By Steve Njeru, OD, MS, and Daniel Grangaard, OD



### 66 Low Vision Tools and Techniques You Should Know

An overview of concepts and resources used by primary eyecare providers and appropriate specialists to ease patient's impairments.

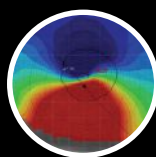
By Jessica Capri, OD



### 58 Ultra-widefield Imaging: Expand Your Horizons

Several instruments are available today. Here, we guide you through the technologies to help you obtain optimal results for many common retinal conditions.

By Brad Sutton, OD, and Julie Torbit, OD



EARN 2 CE CREDITS

### 72 The Definitive Guide to Corneal Topography

Understanding when and how to use this tool is a critical component of optometric practice.

By Becky Su, OD, Marcus Noyes, OD, and John Gelles, OD


On the cover: Fundus and FAF images of central serous chorioretinopathy courtesy of Anna Bedwell, OD, and Brad Sutton, OD; stock images by Getty

**THE FUTURE IS  
CLOSING IN**

**iyuzeh<sup>TM</sup>**

(latanoprost ophthalmic solution) 0.005%

Prepare now at [iyuzeh.com](https://iyuzeh.com)





# DEPARTMENTS

REVIEW OF OPTOMETRY • SEPTEMBER 15, 2023

VISIT US ON SOCIAL MEDIA

Facebook: revoptom

Twitter: revoptom

Instagram: revoptom

Threads: revoptom

LinkedIn: company/review-of-optometry

5

## NEWS REVIEW

Clinical, legislative and practice updates for optometrists.

20

## OUTLOOK

### Baby Boom

The next generation of optometrists is transforming the profession—and our publication.

**Jack Persico, Editor-in-Chief**

22

## THROUGH MY EYES

### Why Didn't I Think of That?

Some inventions come from the most simple ideas.

**Paul M. Karpecki, OD**

24

## CHAIRSIDE

### Stress Less, YAWMAO More

Use this catchphrase in your next crazy encounter.

**Montgomery Vickers, OD**


26

## CLINICAL QUANDARIES

### Hard Knocks

Pay special attention to a patient's ocular health after they experience a head injury.

**Paul C. Ajamian, OD**



28

## THE ESSENTIALS

### Electrify Your Exams

ERGs document neuronal function—and dysfunction—to aid differential diagnosis and monitoring.

**Bisant A. Labib, OD**

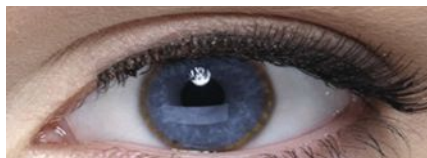
33

## YOU BE THE JUDGE

### Stuck on Third

Getting the correct diagnosis is like a triple in baseball; it doesn't always score a run.

**Jerome Sherman, OD, and Sherry Bass, OD**



84

## OCULAR SURFACE REVIEW

### Call the Exterminator

A new eye drop, Xdemvy, shows positive results in wiping out the unusually common condition known as Demodex blepharitis.

**Paul M. Karpecki, OD**

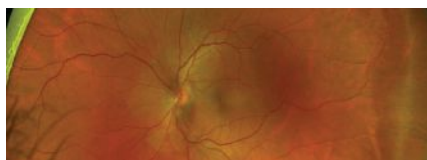
86

## URGENT CARE

### The Great Masquerader

Due to its widely varying presentation, syphilis often flies beneath the radar.

**Evelyn Mechias, OD**



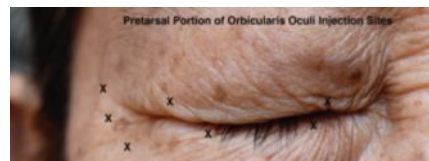
92

## ADVANCED PROCEDURES

### Spasms, Twitches and Other Eyelid Glitches

Botox can be a safe and effective option for facial muscle contractions.

**Leonid Skorin, Jr., DO, OD, MS**



96

## RETINA QUIZ

### You've Got Some Nerve

A hospital visit identified alarming signs.

**Rami Aboumourad, OD**

100

## CORNEA AND CONTACT LENS Q + A

### Herpes Helper

Oral antivirals are safe and resistance is low, but immuno-suppressed patients may need IV therapy.

**Joseph P. Shovlin, OD**

102

## PRODUCT REVIEW

New items to improve clinical care.

106

## DIAGNOSTIC QUIZ

### Split the Difference

Should you worry about the current or future status of an eye that presents like this?

**Andrew S. Gurwood, OD**

REVIEW OF OPTOMETRY (ISSN 0147-7633) IS PUBLISHED MONTHLY, 12 TIMES A YEAR BY JOBSON MEDICAL INFORMATION LLC/WebMD, 283-299 MARKET STREET, 2 GATEWAY CENTER, 4TH FLOOR, NEWARK, NJ 07102. PERIODICALS POSTAGE PAID AT NEWARK, NJ AND ADDITIONAL MAILING OFFICES. POSTMASTER: SEND ADDRESS CHANGES TO REVIEW OF OPTOMETRY, PO BOX 81, CONGERS, NY 10920-0081. SUBSCRIPTION PRICES: US: ONE YEAR \$56; TWO YEARS \$97, CANADA: ONE YEAR \$88, TWO YEARS \$160, INT'L: ONE YEAR \$209, TWO YEARS \$299. FOR SUBSCRIPTION INFORMATION CALL TOLL-FREE (877) 529-1746 (USA); OUTSIDE USA, CALL (845) 267-3065. OR EMAIL US AT REVOPOTOMETRY@CAMBEYWEST.COM. PUBLICATIONS MAIL AGREEMENT NO: 40612608. CANADA RETURNS TO BE SENT TO BLEUCHIP INTERNATIONAL, P.O. BOX 25542, LONDON, ON N6C 6B2.

# Look for choroidal hypertransmission, a marker of Geographic Atrophy (GA) on OCT<sup>1\*</sup>

- While BCVA is poorly correlated to lesion size, visual function continues to decline as lesions grow<sup>2,3</sup>
- It is critical to recognize GA and refer patients in a timely manner, as disease progression is relentless and irreversible<sup>1,3-7</sup>

Learn more about identifying GA  
at [RecognizeAndReferGA.com](https://www.recognizeandreferga.com)



**RECOGNIZE  
AND REFER**

\*GA is defined by atrophic lesions, resulting from loss of photoreceptors, RPE, and underlying choriocapillaris. This results in a choroidal hypertransmission defect on OCT.<sup>1,8,9</sup>  
BCVA=best-corrected visual acuity; OCT=optical coherence tomography; RPE=retinal pigment epithelium.

**References:** **1.** Fleckenstein M, Mitchell P, Freund KB, et al. The progression of geographic atrophy secondary to age-related macular degeneration. *Ophthalmology*. 2018;125(3):369-390. doi:10.1016/j.ophtha.2017.08.038. **2.** Heier JS, Pieramici D, Chakravarthy U, et al. Visual function decline resulting from geographic atrophy: results from the chroma and spectri phase 3 trials. *Ophthalmol Retina*. 2020;4(7):673-688. doi:10.1016/j.oret.2020.01.019. **3.** Sunness JS, Margalit E, Srikumaran D, et al. The long-term natural history of geographic atrophy from age-related macular degeneration: enlargement of atrophy and implications for interventional clinical trials. *Ophthalmology*. 2007;114(2):271-277. **4.** Boyer DS, Schmidt-Erfurth U, van Lookeren Campagne M, Henry EC, Brittain C. The pathophysiology of geographic atrophy secondary to age-related macular degeneration and the complement pathway as a therapeutic target. *Retina*. 2017;37(5):819-835. doi:10.1097/iae.0000000000001392. **5.** American Optometric Association. AOA Comprehensive adult eye and vision examination. *Quick Reference Guide: Evidence-Based Clinical Practice Guideline*. 1st ed. Accessed July 13, 2023. [https://www.aoa.org/documents/EBO/Comprehensive\\_Adult\\_Eye\\_and\\_Vision\\_20QRG.pdf](https://www.aoa.org/documents/EBO/Comprehensive_Adult_Eye_and_Vision_20QRG.pdf). **6.** Holz FG, Strauss EC, Schmitz-Valckenberg S, van Lookeren Campagne M. Geographic atrophy: clinical features and potential therapeutic approaches. *Ophthalmology*. 2014;121(5):1079-1091. doi:10.1016/j.ophtha.2013.11.023. **7.** Lindblad AS, Lloyd PC, Clemons TE, et al; Age-Related Eye Disease Study Research Group. Change in area of geographic atrophy in the age-related eye disease study: AREDS report number 26. *Arch Ophthalmol*. 2009;127(9):1168-1174. doi:10.1001/archophthalmol.2009.198. **8.** van Lookeren Campagne M, LeCouter J, Yaspan BL, Ye W. Mechanisms of age-related macular degeneration and therapeutic opportunities. *J Pathol*. 2014;232(2):151-164. doi:10.1002/path.4266. **9.** Chakravarthy U, Bailey CC, Scanlon PH, et al. Progression from early/intermediate to advanced forms of age-related macular degeneration in a large UK cohort: rates and risk factors. *Ophthalmol Retina*. 2020;4(7):662-672.

Apellis

The APELLIS® name and logo is a registered trademark of Apellis Pharmaceuticals, Inc.  
©2023 Apellis Pharmaceuticals, Inc. 8/23 US-GA-2300089 v1.0

## EDITOR-IN-CHIEF

**JACK PERSICO**

(610) 492-1006 • jpersico@jobson.com

## SENIOR EDITOR

**JULIE SHANNON**

(610) 492-1005 • jshannon@jobson.com

## SENIOR ASSOCIATE EDITOR

**MARK DE LEON**

(610) 492-1021 • mdeleon@jobson.com

## ASSOCIATE EDITOR

**LEANNE SPIEGLE**

(610) 492-1026 • lspiegle@jobson.com

## ASSOCIATE EDITOR

**RACHEL RITA**

(610) 492-1000 • rrita@jobson.com

## SENIOR SPECIAL PROJECTS MANAGER

**JILL GALLAGHER**

(610) 492-1037 • jgallagher@jobson.com

## SENIOR ART DIRECTOR

**JARED ARAUJO**

jaraujo@jobson.com

## GRAPHIC DESIGNER

**LYNNE O'CONNOR**

lyconnor@jobson.com

## DIRECTOR OF CE ADMINISTRATION

**REGINA COMBS**

(212) 274-7160 • rcombs@jobson.com

**Clinical Editors**

Chief Clinical Editor • Paul M. Karpecki, OD

## Associate Clinical Editors

Joseph P. Shovlin, OD, Christine W. Sindt, OD

Clinical &amp; Education Conference Advisor

Paul M. Karpecki, OD

Case Reports Coordinator • Andrew S. Gurwood, OD

**Columnists***Advanced Procedures* – Nate Lighthizer, OD*Chairside* – Montgomery Vickers, OD*Clinical Quandaries* – Paul C. Ajamian, OD*Cornea and Contact Lens Q+A* – Joseph P. Shovlin, OD*Diagnostic Quiz* – Andrew S. Gurwood, OD*The Essentials* – Bisant A. Labib, OD*Focus on Refraction* – Marc Taub, OD, Pamela Schnell, OD*Glaucoma Grand Rounds* – James L. Fanelli, OD*Ocular Surface Review* – Paul M. Karpecki, OD*Retina Quiz* – Rami Aboumourad, OD*Surgical Minute* – Derek Cunningham, OD, Walter Whitley, OD*Therapeutic Review* – Jessica Steen, OD*Through My Eyes* – Paul M. Karpecki, OD*Urgent Care* – Alison Bozung, OD*You Be The Judge* – Jerome Sherman, OD, Sherry Bass, OD**Editorial Offices**

19 Campus Blvd., Suite 101 • Newtown Square, PA 19073

Jobson Medical Information/WebMD

283-299 Market Street, 2 Gateway Center, 4th Floor  
Newark, NJ 07102

Subscription inquiries: (877) 529-1746

Continuing Education inquiries: (800) 825-4696

Printed in USA

BY JACK PERSICO  
EDITOR-IN-CHIEF**OUTLOOK**

# Baby Boom

*The next generation of optometrists is transforming the profession—and our publication.*

This magazine is fortunate to have long-standing ties with ODs who've been prominent in the field for decades and have, along the way, become fixtures of our monthly editorial slate. Joe Shovlin, Paul Ajamian and Monty Vickers have each been *Review of Optometry* columnists for over 30 years. More than a dozen of our editorial board members also have been active in the field at least as long, and a few have an even more distinguished tenure—Jerry Sherman and Sherry Bass, the venerable SUNY professors who write our popular new malpractice column *You Be The Judge*, have a combined 94 years of experience. Yes, you read that right.

These thought leaders and countless others of their generations have been a consistent engine of progress for optometry, innovators who retooled a glasses-and-contacts profession into the premier venue for primary eye care in America.

The wide array of ODs who write and review articles for *Review* make themselves available to our staff day and night. Many times I've reached out at odd hours, with odd requests, and found willing volunteers happy to assist. But lately in my interactions with authors, I've noticed something that doesn't come up much in conversations with the senior optometrists in our stable.

Babies. Lots of them.

This month alone, we have contributions from five ODs who've welcomed new babies into their families: Erin Tomiyama, Stephanie Ramdass, Trevor Fosso, Alison Bozung and Suzanne Sherman. Two other recent authors who managed to fit in contributions for *Review* around diaper changes and feeding schedules are Lindsay Sicks and Christina Cherny. These busy doctors

were all kind enough to give us—and, by extension, you—some of their precious new-parent time, and I thank them all.

This tracks with a decision we made a few years back to make sure the next generation of experts also finds a home for their views in *Review of Optometry*. In the past five years, the average age of our authors has dropped significantly. These days most people you'll see on the bylines haven't even developed presbyopia yet. With no disrespect aimed at our indispensable senior contributors, I find it exciting that this magazine is experiencing an injection of new blood.

Those optometrists who entered the profession after about 2010 have notably different ambitions, attitudes and personalities than previous generations of ODs. "Medical optometry" is not aspirational to them—it's the table stakes. Performing minor surgical procedures isn't some radical notion but rather the next logical step for them. And relations with MDs are far more collaborative and cooperative for this new breed of OD. Many work side by side with ophthalmologists, and a handful even teach in their educational institutions!

We're also at the time of year when many optometry schools do their white coat ceremonies to welcome students into the clinical portion of their training. The social media feeds we interact with these days are filled with fresh-faced optometrists-to-be in their new lab coats.

For students anticipating the road ahead, young ODs finding their way and veterans looking to stay sharp, this publication has guidance to offer. We pride ourselves on *Review* being the nexus of all these varied experiences of optometry.

And to those new parents: Congrats! Get some rest. ■




# SPEED. EASE. RANGE.

**MyDay® daily disposable multifocal with CooperVision Binocular Progressive System® is a game-changer.<sup>1</sup>**



Micaela Crowley, O.D.  
Lexington, MA



MyDay® multifocal leverages the latest innovation in multifocal contact lens technology with **CooperVision Binocular Progressive System®** to optimize vision for all levels of presbyopia and visual acuity at all distances.<sup>2</sup> With its speed and ease of fit using OptiExpert™, you can **successfully fit 98% of the time** with two pairs or fewer.<sup>3,4</sup> Plus, with the **incredible comfort of Aquaform® Technology** that patients' eyes deserve<sup>5</sup>, MyDay® multifocal has changed the game.

**If you haven't fit MyDay® multifocal, what are you waiting for? Get in the game.**

1. CVI data on file as of May 2023 vs. leading manufacturers. 2. CVI data on file 2020. Prospective, double-masked, bilateral, one-week dispensing study UK with MyDay daily disposable multifocal; n=104 habitual MFCL wearers. 3. CVI data on file 2020. Prospective, double-masked, bilateral, one-week dispensing study UK with MyDay multifocal; n=104 habitual multifocal contact lens wearers. 4. CVI data on file 2021. Prospective, subject-masked, randomized, bilateral, two-week dispensing study at 5 US sites with MyDay multifocal; n=58 habitual multifocal contact lens wearers. 5. CVI Data on file 2022. Based on global product sales and internal estimates of products using Aquaform® Technology over 12 months in 2022. ©2023 CooperVision 14777ROO 9/23



BY PAUL M. KARPECKI, OD  
CHIEF CLINICAL EDITOR

## THROUGH MY EYES

# Why Didn't I Think of That?

*Some truly original inventions come from the most simple ideas.*

The greatest ideas are often so simple that one's response is, "Why didn't I think of that?" Simple doesn't mean lack of innovation, though. Just look at Post-it Notes and Spanx; both made billions. It got me thinking, do we have similar innovations in eyecare?

### Bruder Moist Heat Eye Compress

It took an optometrist in primary care practice to recognize this technology belonged in dry eye. He was using a Bruder Sinus Compress with MediBeads on his dry eye patients. After witnessing impressive success in dry eye, he inquired as to the possibility of a half-sized version that would only cover the eyelids. Today, it is known as the Bruder Moist Heat Eye Compress (Bruder Healthcare). The uniquely designed MediBeads allow for just the right amount of moisture, lasting eight to 10 minutes after 20 to 22 seconds in the microwave. It's not too hot to cause excess steam, nor do the beads become mushy with exposure to moisture over time. This turned out to be far more valuable for dry eye management than any other clinical application.

### SleepTite/SleepRite

Who knew the No. 1 cause of nonresponsive dry eye would be inadequate lid closure at night? Publications by one of our most gifted researchers, Donald Korb, OD, identified this condition early. He developed tests to con-

firm it and understood its significant role in nocturnal evaporative stress, resulting in symptoms upon waking.

“**Creating a complex technology is often easier than a “Why didn't I think of that?” invention.**”

SleepTite/SleepRite (Eye Sleep-Tite) is a hypoallergenic, latex-free, disposable eye cover that has the ideal level of adhesive to anatomically seal the eyelids but not stick to lashes. Patients discover that all of their symptoms, including dry eyes, are resolved. **Contoured Prism**

If more than 90% of patients have greater prismatic need at near than far, why wouldn't someone come up with a “progressive prism”?<sup>1</sup> Well, that is exactly what Neurolens offers—a lens that often starts with base-in (and sometimes vertical prism correction) that increases inferiorly to resolve headaches, neck stiffness and asthenopia. I can see this option being a common upgrade for patients suffering from headaches or wanting less eye strain, just like transition lenses or anti-reflective coatings.

### Ocular Response Analyzer and CATS Tonometer

We've known that inaccurate IOP measurements occur with Goldmann tonometry, especially post-LASIK,

in high or low hysteresis or in thin corneas. The Correcting Applanation Tonometry Surface (CATS) tonometer prism adjusts for surface irregularities and hysteresis, and provides the exact IOP of that patient.

I've seen glaucoma patients with Goldmann IOP of 17mm Hg continue to progress only to find out that when measured with the Ocular Response Analyzer (Reichert Technologies) were 20mm Hg. The upside was hysteresis, which turned out to be the single most predictable measurement for visual field loss progression.<sup>2</sup> A high hysteresis is protective but a low one signals concern, especially if other subtle signs of glaucoma are present.

### Lumify

Before Lumify (Bausch + Lomb) came to market, doctors had observed glaucoma patients on Alphagan P eye drops presenting with white eyes. Those who realized this incredible need, given the number of people using harmful products like tetrahydrozoline, did extremely well. Today, it works by constricting venules (not restricting oxygen/arteries) and results in three times more whitening effects.<sup>3</sup>

Creating a complex technology is often easier than a “Why didn't I think of that?” invention. Hopefully as you read this, you, too, will come up with fresh, simple ideas that have a profound effect on millions of patients' lives. ■

1. Association of American Medical Colleges. 2021 Physician Specialty Data Report. <https://www.aamc.org/data-reports/workforce/data/number-people-active-physician-specialty-2021>. Accessed June 21, 2023.

2. Rothman AL, Stoler JB, Vu DM, et al. A geodemographic service coverage analysis of travel time to glaucoma specialists in Florida. *Glaucoma*. 2020;29(12):1147-51.

3. Congdon N, Azuara-Blanco A, Solberg Y, et al. Direct selective laser trabeculoplasty in open angle glaucoma study design: a multicentre, randomised, controlled, investigator-masked trial (GLAUrious). *Br J Ophthalmol*. 2023 Jan;107(1):62-65. doi: 10.1136/bjophthalmol-2021-319379. Epub 2021 Aug 25.

#### About Dr. Karpecki

**Dr. Karpecki** is the director of Cornea and External Disease for Kentucky Eye Institute, associate professor at KYCO and medical director for the Dry Eye Institutes of Kentucky and Indiana. He is the Chief Clinical Editor for Review of Optometry and chair of the New Technologies & Treatments conferences. A fixture in optometric clinical education, he consults for a wide array of ophthalmic clients, including ones discussed in this article. Dr. Karpecki's full disclosure list can be found in the online version of this article at [www.reviewofoptometry.com](http://www.reviewofoptometry.com).

# ALL THOSE IN FAVOR OF PRESERVATIVE FREEDOM, **SAY EYE**

As eye care professionals, eye drops play a central role in the care we provide for our patients. Many prescription and OTC eye drops continue to include preservatives—compounds that are proven deleterious to the ocular surface.

Preservative Freedom is a commitment to preserve patient eye health.

**We're pledging to break through our indifference and old habits,  
and to do so while keeping our patients' eye care as the highest priority.**



**PRESERVATIVE  
FREEDOM**

Learn more, and join the movement at  
[PreservativeFreedom.com](https://www.PreservativeFreedom.com)

 **Théa**  
let's open our eyes



# Stress Less, YAWMAO More

*Use this catchphrase in your next crazy encounter.*

**H**ave you ever invented something? An idea no one has used before? In my experiences with ODs I would say we, as a rule, are hesitant when it comes to, well, sticking our necks out. That makes perfect sense, as we can easily feel like our profession has a target on our collective backs with the requirements to be held to the same practice responsibility as ophthalmologists while those folks often battle to make sure we cannot legally provide the care that meets our level of responsibility in the courts.

Then, we see our so-called colleagues offering “free examinations” or “online, offsite virtual care” where no doctor at all is required for ordering corrective lenses, lowering the bar on quality of care so Generation Lazy doesn’t have to put on pants to get eyecare and eyewear.

Looming over all is the almighty government, which seems to be doing all it can to convince us that all we have is theirs and that, like Vikings, we will die a glorious death and end up in Valhalla as long as we continue to follow orders.

My wife and I have stopped grumbling and groveling. Instead, we have created a slogan for our lives. Now, we replace our angst by using the phrase, philosophy and humor of (wait for it!)... YAWMAO.

I feel better already. Now, this trademarked image is indeed pronounced just the way it looks above: YAW + MAO (as in Chairman Mao), but it actually looks a little different than it is spelled. Think of this sequence of letters (and one symbol): “Y A W M (INSERT PICTURE OF A DONKEY) O.”

ODs are very educated and although our minds may be more filled with math and science than Shakespeare, we all had to take that dreaded freshman English Lit class, so what is another word for “donkey”? No, not “state legislator.” Try again! Get it? Take your time. It will come to you. Speaking of “you,” the first letter in YAWMAO stands for “you” and the last word is “out.” Run with that! Oh, and there’s an “are wearing my” in there somewhere.

Once you get it, you will see how just grinning and saying YAWMAO out loud can be used to lighten your mood in any crazy encounter, whether it be with your patient who tells you in October they never could wear the glasses they got somewhere else in January, with your spouse, your kids, your kid’s kids, etc.

In my family, this catchphrase has morphed into a verb, as in “My kids are YAWMAOing me!” It has become a noun... “Life is full of surprises, so get your YAWMAO on!” It’s a call to action... “Don’t let life get you down. YAWMAO more!”

Here are some examples of how YAWMAO can help:

1. That patient who gave you a one-star review because you were running 15 minutes behind last year when she came in... well, she’s coming in again this year. YAWMAO!

2. The staff waited until Monday to order a supply of multipacks that would put you into the bonus level with your contact lens lab had she ordered them on Friday. YAWMAO!

3. The last patient of the week shows up 20 minutes late and opts for dilation instead of widefield photography. YAWMAO!

4. That patient who comes in for a glaucoma evaluation brings her screaming four-year-old twins along. YAWMAO!

5. Your wife surprises you on the warmest, sunniest Saturday of the winter by telling you she has you signed up for a Be a Great Husband all day event at the church. (Once I get through the aforementioned great husband training, I will

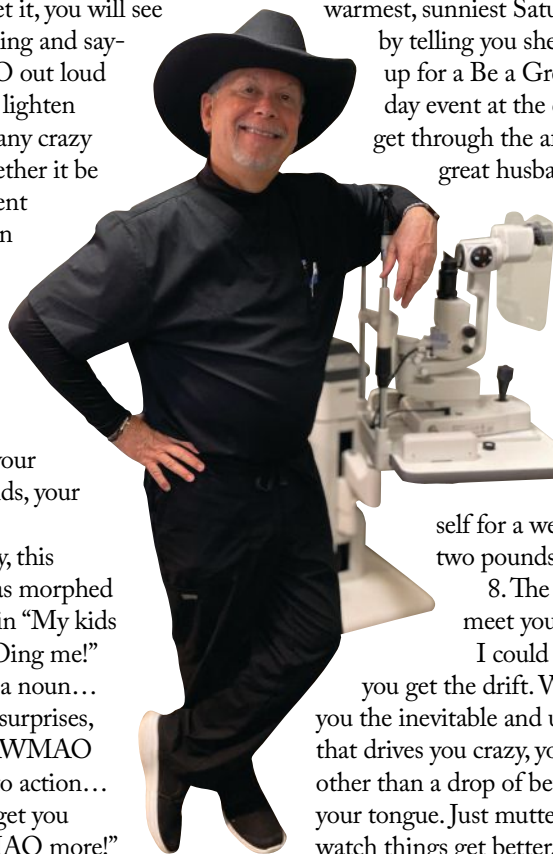
get her back.) YAWMAO!

6. The computers are down. YAWMAO YAWMAO YAWMAO!!!!

7. After starving yourself for a week, you gained two pounds. YAWMAO!

8. The IRS would like to meet you. YAWMAO!

I could go on and on, but you get the drift. When life throws you the inevitable and unavoidable crap that drives you crazy, you need something other than a drop of beta-blocker under your tongue. Just mutter YAWMAO and watch things get better. ■



**About  
Dr. Vickers**

**Dr. Vickers** received his optometry degree from the Pennsylvania College of Optometry in 1979 and was clinical director at Vision Associates in St. Albans, WV, for 36 years. He is now in private practice in Dallas, where he continues to practice full-scope optometry. He has no financial interests to disclose.

From the makers of the #1-prescribed dry eye brand in Europe\*

## Covering the spectrum of

# Dry Eye Relief

Over-the-counter iVIZIA® lubricant eye drops deliver a unique combination of immediate and long-lasting relief and ocular surface protection in a preservative-free formulation.

- Advanced formulation offers a combination of povidone (active), hyaluronic acid (HA), and trehalose
- HA and trehalose increased tear film thickness for up to 240 minutes
- Proprietary, multi-dose bottle

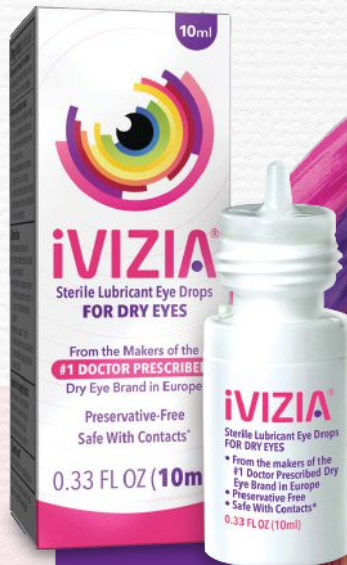### Chronic Dry Eye Patient Usage Study†:

Up to  
**8 hours**  
of relief

as well as improved comfort during computer work, reading, and driving<sup>1</sup>

**84%**

of users reported iVIZIA worked better than their previous eye drops<sup>1</sup>



Safe for use with contact lenses‡



Scan here.

Recommend iVIZIA and request samples by visiting [iVIZIA.com/ECP](https://www.ivizia.com/ECP).

\*Prescription market data, Dec. 2022 – S01K without cyclosporine.

†In a chronic dry eye patient usage study, participants from a variety of socioeconomic backgrounds answered questions about iVIZIA. There were 203 chronic dry eye patients, ranging from ages 28-80, who used their current eye drops before switching to iVIZIA for 30 days.<sup>1</sup>

‡To limit blurriness when using contact lenses, remove contacts, apply drops, then insert contacts.

Reference: 1. Data on file.

Copyright ©2023 Thea Pharma Inc. | Similasan | All Rights Reserved. | PRC-IED-1030-v2 04.2023

Made by  
**Thea**  
let's open our eyes

Distributed by  
**Similasan**  
EVIDENCE-BASED EYE CARE





EDITED BY PAUL C. AJAMIAN, OD

## CLINICAL QUANDARIES

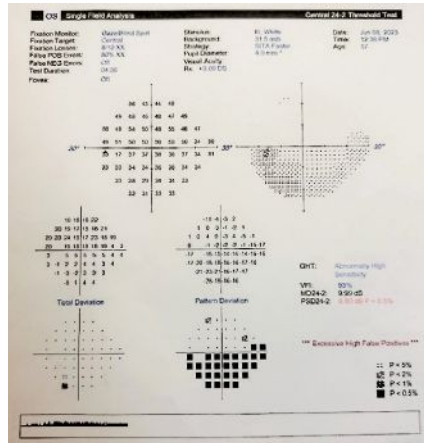
# Hard Knocks

Pay special attention to a patient's ocular health after they experience a head injury.

**Q** A patient reported left-sided head trauma and headaches after a recent motor vehicle accident. The referring provider indicated there was an inferior altitudinal defect in the left eye. The patient is under the care of a neurologist. What are the next steps?

**A** Visual field defects are present in about 38% of patients with traumatic brain injuries (TBI), based upon a retrospective study.<sup>1</sup> A recent meta-analysis stated that the prevalence was 6.6% in mild TBI cases and 39.8% in moderate to severe cases for visual fields of post-chiasmal origin.<sup>2</sup> The severity of a TBI is defined using the following characteristics (Table 1).<sup>3</sup>

“Important case history elements to ask before evaluating functional vision symptoms include the onset of the injury, location of the injury and neurological status,” says Esther Han, OD, associate clinical professor and residency program supervisor of the vision rehabilitation residency with an emphasis on brain injuries at SUNY. If the accident was recent, either imaging or monitoring of any headache symptoms over a 24-to-72-hour period should be done to rule out a slow bleeding intracranial hemorrhage.<sup>3,4</sup>



The left eye visual field of the patient with a left-sided head trauma secondary to a motor vehicle accident.

This patient may appear clumsier than before and/or may bump into or trip over things on the left side. Some additional visual field-related symptoms include experiencing restriction in their peripheral vision, loss of balance, dizziness, not feeling grounded and veering off to one side when walking.

Given the *coup-contrecoup* nature of the motor vehicle accident, where the patient's brain jostles back and forth in the skull due to the force of the accident, the patient may additionally

experience vision symptoms related to deficits in vergence, oculomotor and/or accommodative function, according to Dr. Han. She recommends performing the Convergence Insufficiency Symptom Survey (CISS), such as the one in the American Optometric Association's Clinical Practical Guidelines, as a quick way to monitor symptoms. A score of greater than 21 for adults indicates the patient should be referred to a neuro-optometric rehabilitation/optometric vision therapy provider.

### Neuro Evaluation

Typically, visual acuities will not be reduced, but there may be fluctuations in acuity and single letter acuities may need to be measured. Given that the patient in this case was hit on the left side of their head, Dr. Han notes that speech may be slower and less coherent during the recovery stage. “Perform a comprehensive ocular health assessment, including careful pupillary testing, motility, confrontation fields and a dilated exam, to determine the presence of any retinal, optic nerve or visual pathway abnormalities that require immediate referral and management,” she adds. “Since only one eye depicted visual field abnormalities, monocular color vision should also be performed as a baseline to monitor optic nerve function.”

In acute cases, light sensitivity will be a major symptom. Wearing a hat, visor or even sunglasses can help decrease this. During the examination, turning off the fluorescent lighting will significantly increase patient comfort.

### Management

In acute cases, the patient should be re-assessed in one to two weeks depending on the severity of symptoms. Repeat visual fields and other indicated baseline tests to monitor for change.

TABLE 1. CLASSIFICATION OF TBI SEVERITY<sup>3</sup>

Parameters	Mild	Moderate or Severe
Loss of consciousness (LOC)	Zero to 30 minutes	Greater than 30 minutes
Alteration of consciousness (AOC)	One minute to 24 hours	Greater than 24 hours
Post-traumatic amnesia (PTA)	Zero to 24 hours	Greater than 24 hours, up to seven days
Glasgow Coma Scale (GCS) score	13 to 15	Less than 13, after 30 minutes

About Dr. Ajamian

Dr. Ajamian is board certified by the American Board of Optometry and serves as Center Director of Omni Eye Services of Atlanta. He is vice president of the Georgia State Board of Optometry and general CE chairman of SECO International. He has no financial interests to disclose.



NEW  
TECHNOLOGIES  
& TREATMENTS IN  
EYE CARE



SEPTEMBER 22–24, 2023  
THE WESTIN PHILADELPHIA  
PHILADELPHIA, PENNSYLVANIA

CONFERENCE CHAIR



**Paul M. Karpecki, OD, FAAO**

Director of Cornea Services  
Kentucky Eye Institute  
Medical Director  
Keplr Vision  
Lexington, Kentucky

FACULTY



**Doug Devries, OD**

Co-Founder  
Eye Care Associates of Nevada  
Associate Clinical Professor of Optometry  
Sparks, Nevada



**Ben Gaddie, OD, FAAO**

Co-Founder and Chief Medical Officer  
Keplr Vision  
Gaddie Eye Centers  
Louisville, Kentucky



**Carolyn Majcher, OD, FAAO**

Associate Professor and Director  
Residency Programs  
Northeastern State University  
Oklahoma College of Optometry



For more information and to register,  
scan the QR code or visit:

[www.reviewedu.com/nttphiladelphia](http://www.reviewedu.com/nttphiladelphia)

Earn up to 22 COPE credits\*



Postgraduate Institute  
for Medicine

\*COPE Accreditation Pending  
Partially supported by an independent educational  
grant from Johnson & Johnson Vision, Inc.

**REVIEW**  
Education GROUP

Because this patient experienced a mild TBI after the accident, the recovery period should be about two to four weeks. Should the patient report persistent symptoms, Dr. Han suggests that a referral to a psychiatrist or rehabilitative medicine provider specializing in concussions would be indicated to manage any post-concussive syndrome-related issues. This provider will team with neuropsychology/cognitive therapy, physical/vestibular therapy, speech therapy and neurology to address persistent symptoms.

Ongoing visual symptoms such as light sensitivity or a CISS score that remains above 21 are indications that further treatment is required.

“Ophthalmic tints should be trialed should the patient report persistent indoor light sensitivity,” she notes. “Typically, 10% to 25% (absorption) blue, gray, brown tints are well-tolerated for indoor use.” Post-injury patients also report greater comfort with polarized lens sunglasses.

A referral for optometric vision therapy is indicated if the patient’s symptoms are interfering with their activities of daily living. “Should the visual field defects remain in the left eye, about 2PD to 5PD base-down yoked prism should be trialed for near work or as reading glasses to move images into the intact visual field,” Dr. Han says. “This will decrease the patient’s awareness of the relative field defect.”

Accurate charting is very important in motor vehicle accident cases with symptomatic patients, as records will be requested by various agencies such as no-fault insurance, short-term disability and attorneys. ■

1. Merezhinskaya, N, Mallia RK, Park D, et al. Visual deficits and dysfunctions associated with traumatic brain injury: a systematic review and meta-analysis. *Optom Vis Sci.* 2019;96(8):542-55.

2. Suchoff IB, Kapoor N, Ciuffreda KJ, et al. The frequency of occurrence, types and characteristics of visual field defects in acquired brain injury: a retrospective analysis. *Optometry.* 2008;79(5):59-65.

3. Silverberg ND, Iverson GL, Cogan A, et al. The American Congress of Rehabilitation medicine diagnostic criteria for mild traumatic brain injury. *Arch Phys Med Rehabil.* May 19, 2023. [Epub ahead of print].

4. Homnick A, Sifri Z, Yonclas P, et al. The temporal course of intracranial hemorrhage progression: how long is observation necessary? *Injury.* 2012;4(12)3:2122-5.



BY BISANT A. LABIB, OD

## THE ESSENTIALS

# Electrify Your Exams

*ERGs document neuronal function—and dysfunction—in retinal conditions to aid differential diagnosis and monitor progression.*

**A**s eyecare practitioners, we are always in search of new tools that help elucidate a diagnosis, particularly in the case of retinal diseases. As many conditions present with overlapping clinical features, it is often necessary to distinguish between them to provide the most optimal management. One important area of assessment is in electrophysiology.

Electrophysiological testing can be a valuable tool in ophthalmic practice because it provides information about the electrical activity of the eye that cannot be obtained from a standard eye exam. First, it can provide objective, quantifiable data about retinal function that can be used to help diagnose retinal diseases, monitor disease progression and assess the effectiveness of treatment. These tests may also help in diagnosing retinal diseases in infants and young children who may not be able to cooperate with other diagnostic methods. Electrophysiological testing is also frequently used in research to identify new therapeutic targets.

## Electrophysiological Tests

The most common of these tools used in the ophthalmic setting are visual evoked potentials (VEPs), electro-oculography (EOG) and electroretinography (ERG). Generally, the VEP measures the electrical activity of the brain in response to a visual stimulus. EOG measures the

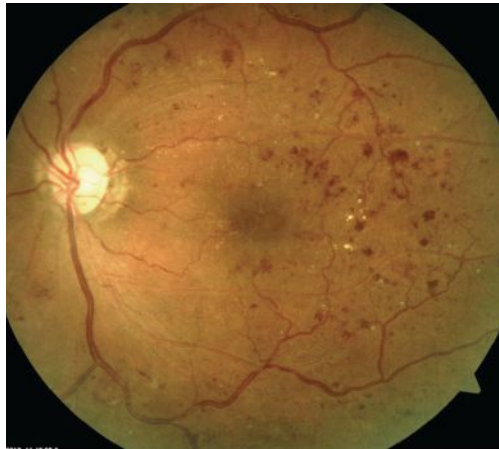

Photo: Julie Toth, OD

**An example of moderately severe non-proliferative diabetic retinopathy. Using ERG testing in such a patient, neural damage may be detectable.**

electrical activity of the eye muscles in response to eye movements, and the ERG, which will be our main focus, measures the electrical activity of the retina in response to light.<sup>1-8</sup>

ERG is an important tool in eye care because it provides objective and quantifiable data about retinal function while also being a noninvasive and painless procedure. Its use in the diagnosis of retinal conditions is becoming increasingly important, as it offers a great degree of information regarding the neuroretinal response to disease, treatment, genetics, age and environmental exposures.

The assessment involves placing electrodes on the surface of the eye, followed by flashing a series of bright lights in front of the eye. These electrodes measure the electrical activity of the retina in response to the light flashes.

To understand how the ERG works, a refresher about the electric potential of the eye and the intricate neuronal network of the retina is due.<sup>1,2</sup>

## Retinal Electrical Activity

The electric potential of the human eye ranges from 0.4mV to 1.0mV. The cornea is electrically positive in relation to the retina; this potential difference is not generated by excitable tissue but rather is attributed to the higher metabolic rate of the retina. This electric potential changes rapidly when the eye is exposed to light, which is the basis of the ERG. An ERG is a waveform consisting of data from two processes: the receptor potential, or a-wave, which is the early negative phase arising from the retinal photoreceptors, and the positive b-wave arising from the inner nuclear layer.<sup>3</sup>

The retina is the only photosensitive tissue in the eye and is composed of over 50 neurons, including photoreceptors, bipolar cells, ganglion cells, horizontal cells and amacrine cells. For a phototransduction to occur, this precise neural network throughout the outer and inner retinal layers must be maintained. The process begins when the photoreceptors synapse with bipolar cells and transmit signals to the ganglion cells. Ultimately, the signal travels through the optic nerve to the brain for vision.<sup>4</sup> This function of retinal neuronal and non-neuronal cells is assessed through ERG testing, which measures ion transport and the change in membrane potential using the eye's response to a light stimulus.<sup>4,6</sup>

## Types of ERGs

Each kind of ERG test provides unique information. A *full-field ERG*

About  
Dr. Labib

**Dr. Labib** graduated from Pennsylvania College of Optometry, where she now works as an associate professor. She completed her residency in primary care/ocular disease and is a fellow of the American Academy of Optometry and a diplomate in the Comprehensive Eye Care section. She has no financial interests to disclose.

(ffERG) measures the total electrical activity in the retina in response to diffuse light stimulus. Typically, this is performed and recorded twice under light conditions and twice under dark conditions. The *light-adapted ffERG* is performed under lighting conditions that suppress rod photoreceptor function. The initial a-wave is a result of primarily cone photoreceptors and, to a lesser degree, OFF bipolar cells. The light-adapted b-wave is a function of both ON and OFF bipolar cells as well as retinal ganglion cells.

In contrast to the light-adapted procedure, the *dark-adapted ffERG* is performed under dark-adapted conditions in response to a brief low and moderate luminance flash. The b-wave is generated by ON bipolar cells in this case, and the moderate flash produces an a-wave consisting of a mixed rod and cone response. Overall, this type of ERG provides general information about the retina's light response under light and dark conditions.<sup>4</sup> A limitation to this form is that it does not localize loss of function and instead averages it over the entirety of the retina and macula.<sup>6</sup>

In contrast to the full-field, the *multifocal ERG* (mfERG) allows recordings from various points of the retina, including the macula and periphery under photopic conditions. Given this ability, it is useful in assessing localized areas of neural dysfunction in retinal disease. Finally, the *pattern ERG* (pERG) evaluates macular ganglion cell activity, which is otherwise difficult to assess with the other types.<sup>5</sup>

## Clinical Role

The use of ERG testing has long been recognized in the differentiation of inherited retinal disorders, as many have overlapping signs and symptoms. Testing can determine photoreceptor function for cone-rod or rod-cone dystrophies, since the principal use of ERG is in the assessment of neurons. In addition to aiding in diagnosis, the ffERG is used

**TABLE 1. DIFFERENT TYPES OF ERGs AND THEIR CLINICAL USES**

ERG Type	Test Features	Clinical Conditions
Full-field (ffERG)	Light-adapted and dark-adapted sum of photoreceptor and bipolar function	<ul style="list-style-type: none"> <li>• Diabetic retinopathy</li> <li>• Inherited retinal disorders</li> <li>• Refractive error</li> </ul>
Multifocal (mfERG)	Localized information on outer retinal function	<ul style="list-style-type: none"> <li>• Diabetic retinopathy</li> <li>• Drug-induced retinal toxicity</li> </ul>
Pattern (pERG)	Information on retinal ganglion cell function	<ul style="list-style-type: none"> <li>• Glaucoma</li> </ul>

specifically to measure progression of disease. An example is with retinitis pigmentosa, where measuring cone degeneration is a way to elucidate the disease's progression.<sup>6</sup>

More recently, ERG testing has found use in other retinal conditions. Although diabetic retinopathy is readily visible through clinical examination and is a known vascular disorder, evidence suggests there is a component of neural damage associated with the condition that can be uncovered using ERG testing. Light-adapted ffERG with high luminance has been able to detect cone sensitivity loss even before the clinical manifestation of retinopathy. This is likely a result of retinal hypoxia associated with diabetes. Additionally, mfERG can be helpful in measuring the extent of neurodegenerative disease in diabetes due to its ability to localize abnormalities, which may predict the progression of vascular abnormalities.<sup>5</sup>

Emerging studies about the role of ERG in glaucoma suggest the potential of using pERG to stratify risk of disease, since this is ERG type most sensitive to the retinal ganglion cells affected by glaucoma.<sup>7</sup>

Another area for ERG testing is drug-induced retinopathy. mfERG specifically is of great benefit due to its ability to evaluate toxicity limited to the central retina. This objective assessment can help aid the clinician in assessing the location and degree of retinal toxicity in response to chloroquine, hydroxychloroquine, VGB, interferon-alpha, ethambutol

and sildenafil therapy. Moreover, it can monitor the return of function following drug cessation.<sup>8</sup>

Beyond diseases and drug toxicities, ERG has been studied in refractive errors such as myopia. For example, studies have shown that for every 1mm increase in axial length, dark-adapted ERG responses subsequently decrease, even in the absence of myopic retinal degeneration.<sup>3</sup>

These conditions are just some examples of how ERG testing has become more useful over time. Further studies are certainly needed, as this overview does not begin to cover the extent of its use. Overall, electrophysiological testing is an important tool in eye care that provides valuable information about retinal function. It is a versatile, noninvasive and objective test that has a wide range of applications in diagnosis, monitoring and research of retinal diseases. ■

1. Charles S, ed. RE Records. Electrical signals of the retinal microcircuitry. In Physiology of the Human Eye and Visual System. Harper & Row, Hagerstown. 1979:319-27.

2. Clark JW, ed. JG Webster. The electroretinogram. In Medical Instrumentation. Houghton Mifflin, Boston. 1978:177-84.

3. Kelsey JH. Clinical electroretinography. 1. Br J Ophthalmol. 1967;51(5):356-7.

4. Gupta SK, Chakraborty R, Verkicharla PK. Electroretinogram responses in myopia: a review. Doc Ophthalmol. 2022;145(2):77-95.

5. McAnany JJ, Persidina OS, Park JC. Clinical electroretinography in diabetic retinopathy: a review. Surv Ophthalmol. 2022;67(3):712-22.

6. Cornish EE, Vaze A, Jamieson RV, Grigg JR. The electroretinogram in the genomics era: outer retinal disorders. Eye (Lond). 2021;35(9):2406-18.

7. Wilsey LJ, Fortune B. Electroretinography in glaucoma diagnosis. Curr Opin Ophthalmol. 2016;27(2):118-24.

8. Dettoraki M, Moschos MM. The role of multifocal electroretinography in the assessment of drug-induced retinopathy: a review of the literature. Ophthalmic Res. 2016;56(4):169-77.





**izervay**<sup>™</sup>  
(avacincaptad pegol  
intravitreal solution) 2 mg

#### **INDICATION**

IZERVAY<sup>™</sup> (avacincaptad pegol intravitreal solution) is indicated for the treatment of geographic atrophy (GA) secondary to age-related macular degeneration (AMD)

#### **IMPORTANT SAFETY INFORMATION**

##### **CONTRAINDICATIONS**

- IZERVAY is contraindicated in patients with ocular or periocular infections and in patients with active intraocular inflammation.

##### **WARNINGS AND PRECAUTIONS**

- Endophthalmitis and Retinal Detachments
  - Intravitreal injections, including those with IZERVAY, may be associated with endophthalmitis and retinal detachments. Proper aseptic injection technique must always be used when administering IZERVAY in order to minimize the risk of endophthalmitis. Patients should be instructed to report any symptoms suggestive of endophthalmitis or retinal detachment without delay and should be managed appropriately.

# NOW APPROVED

for the treatment of geographic atrophy (GA) secondary to age-related macular degeneration (AMD).



To learn more and stay up to date,  
visit [IZERVAYecp.com](https://www.izervayecp.com)

- Neovascular AMD
  - In clinical trials, use of IZERVAY was associated with increased rates of neovascular (wet) AMD or choroidal neovascularization (7% when administered monthly and 4% in the sham group) by Month 12. Patients receiving IZERVAY should be monitored for signs of neovascular AMD.
- Increase in Intraocular Pressure
  - Transient increases in intraocular pressure (IOP) may occur after any intravitreal injection, including with IZERVAY. Perfusion of the optic nerve head should be monitored following the injection and managed appropriately.

## ADVERSE REACTIONS

- Most common adverse reactions (incidence  $\geq 5\%$ ) reported in patients receiving IZERVAY were conjunctival hemorrhage, increased IOP, blurred vision, and neovascular age-related macular degeneration.

**Please see Brief Summary of Prescribing Information for IZERVAY on the following page.**

## IZERVAY™ (avacincaptad pegol intravitreal solution)

Rx only

**Brief Summary:** This information is not comprehensive. Visit IZERVAYecp.com to obtain the FDA-approved product labeling or call 609-474-6755.

### 1 INDICATIONS AND USAGE

IZERVAY is indicated for the treatment of geographic atrophy (GA) secondary to age-related macular degeneration (AMD).

### 2 DOSAGE AND ADMINISTRATION

#### 2.1 General Dosing Information

IZERVAY must be administered by a qualified physician.

#### 2.2 Recommended Dosage

The recommended dose for IZERVAY is 2 mg (0.1 mL of 20 mg/mL solution) administered by intravitreal injection to each affected eye once monthly (approximately every 28 ± 7 days) for up to 12 months.

#### 2.4 Injection Procedure

Only 0.1 mL (2 mg) should be administered to deliver a single dose. Any excess volume should be disposed.

Prior to the intravitreal injection, patients should be monitored for elevated intraocular pressure (IOP) using tonometry. If necessary, ocular hypotensive medication can be given to lower the IOP.

The intravitreal injection procedure must be carried out under controlled aseptic conditions, which includes the use of surgical hand disinfection, sterile gloves, a sterile drape, and a sterile eyelid speculum (or equivalent). Adequate anesthesia and a broad-spectrum topical microbicide should be given prior to the injection.

Inject slowly until the rubber stopper reaches the end of the syringe to deliver the volume of 0.1 mL. Confirm delivery of the full dose by checking that the rubber stopper has reached the end of the syringe barrel.

Immediately following the intravitreal injection, patients should be monitored for elevation in intraocular pressure (IOP). Appropriate monitoring may consist of a check for perfusion of the optic nerve head or tonometry.

Following intravitreal injection, patients should be instructed to report any symptoms suggestive of endophthalmitis (e.g., eye pain, redness of the eye, photophobia, blurring of vision) without delay.

Each vial and syringe should only be used for the treatment of a single eye. If the contralateral eye requires treatment, a new vial and syringe should be used and the sterile field, syringe, gloves, drapes, eyelid speculum, filter needle, and injection needle should be changed before IZERVAY is administered to the other eye. Repeat the same procedure steps as above.

Any unused medicinal product or waste material should be disposed of in accordance with local regulations.

### 3 DOSAGE FORMS AND STRENGTHS

Intravitreal solution: 20 mg/mL clear to slightly opalescent, colorless to slightly yellow solution in a single-dose vial.

### 4 CONTRAINDICATIONS

#### 4.1 Ocular or Periocular Infections

IZERVAY is contraindicated in patients with ocular or periocular infections.

#### 4.2 Active Intraocular Inflammation

IZERVAY is contraindicated in patients with active intraocular inflammation.

### 5 WARNINGS AND PRECAUTIONS

#### 5.1 Endophthalmitis and Retinal Detachments

Intravitreal injections may be associated with endophthalmitis and retinal detachments. Proper aseptic injection techniques must always be used when administering IZERVAY in order to minimize the risk of endophthalmitis. Patients should be instructed to report any symptoms suggestive of endophthalmitis or retinal detachment without delay, to permit prompt and appropriate management.

#### 5.2 Neovascular AMD

In clinical trials, use of IZERVAY was associated with increased rates of neovascular (wet) AMD or choroidal neovascularization (7% when administered monthly and 4% in the sham group) by Month 12. Patients receiving IZERVAY should be monitored for signs of neovascular AMD.

#### 5.3 Increase in Intraocular Pressure

Transient increases in intraocular pressure (IOP) have been observed after an intravitreal injection, including with IZERVAY. Perfusion of the optic nerve head should be monitored following the injection and managed as needed.

### 6 ADVERSE REACTIONS

The following potentially serious adverse reactions are described elsewhere in the labeling:

- Ocular and periocular infections
- Neovascular AMD
- Active intraocular inflammation
- Increase in intraocular pressure
- Endophthalmitis and retinal detachments

#### 6.1 Clinical Trials Experience

Because clinical trials are conducted under widely varying conditions, adverse reaction rates observed in the clinical trials of a drug cannot be directly compared to rates in the clinical trials of another drug and may not reflect the rates observed in practice.

The safety of avacincaptad pegol was evaluated in 733 patients with AMD in two sham-controlled studies (GATHER1 and GATHER2). Of these patients,

292 were treated with intravitreal IZERVAY 2 mg (0.1 mL of 20 mg/mL solution). Three hundred thirty-two (332) patients were assigned to sham.

Adverse reactions reported in ≥2% of patients who received treatment with IZERVAY pooled across GATHER1 and GATHER2, are listed below in Table 1.

**Table 1: Common Ocular Adverse Reactions (≥2%) and greater than Sham in Study Eye**

Adverse Drug Reactions	IZERVAY N=292	Sham N=332
Conjunctival hemorrhage	13%	9%
Increased IOP	9%	1%
Choroidal neovascularization	7%	4%
Blurred Vision*	8%	5%
Eye pain	4%	3%
Vitreous floaters	2%	<1%
Blepharitis	2%	<1%

\* Blurred vision includes visual impairment, vision blurred, visual acuity reduced, visual acuity reduced transiently.

### 8 USE IN SPECIFIC POPULATIONS

#### 8.1 Pregnancy

##### Risk Summary

There are no adequate and well-controlled studies of IZERVAY administration in pregnant women. The use of IZERVAY may be considered following an assessment of the risks and benefits.

Administration of avacincaptad pegol to pregnant rats and rabbits throughout the period of organogenesis resulted in no evidence of adverse effects to the fetus or pregnant female at intravenous (IV) doses 5.1 times and 3.2 times the human exposure (based on AUC) at the maximum recommended human dose (MRHD) of 2 mg once monthly, respectively.

In the U.S. general population, the estimated background risks of major birth defects and miscarriage in clinically recognized pregnancies is 2-4% and 15%-20%, respectively.

#### Animal Data

An embryo fetal developmental toxicity study was conducted with pregnant rats. Pregnant rats received daily intravenous (IV) injections of avacincaptad pegol from day 6 to day 17 of gestation at 0.1, 0.4, 1.2 mg/kg/day. No maternal or embryofetal adverse effects were observed at any dose evaluated. An increase in the incidence of a non-adverse skeletal variation, described as short thoracolumbar (ossification site without distal cartilage) supernumerary ribs, was observed at all doses evaluated. The clinical relevance of this finding is unknown. Plasma exposures at the high dose were 5.1 times the MRHD, based on Area Under the Curve (AUC).

An embryo fetal developmental toxicity study was conducted with pregnant rabbits. Pregnant rabbits received daily IV injections of avacincaptad pegol from day 7 to day 19 of gestation at 0.12, 0.4, 1.2 mg/kg/day. No maternal or embryofetal adverse effects were observed at any dose evaluated. Plasma exposure in pregnant rabbits at the highest dose of 1.2 mg/kg/day was 3.2 times the human exposure at the MRHD, based on AUC.

#### 8.2 Lactation

There is no information regarding the presence of avacincaptad pegol in human milk, the effects of the drug on the breastfed infant or on milk production.

The developmental and health benefits of breastfeeding should be considered along with the mother's clinical need for IZERVAY and any potential adverse effects on the breastfed infant from IZERVAY.

#### 8.4 Pediatric Use

Safety and effectiveness of IZERVAY in pediatric patients have not been established.

#### 8.5 Geriatric Use

Of the total number of patients who received IZERVAY in the two clinical trials, 90% (263/292) were ≥65 years and 61% (178/292) were ≥75 years of age. No significant differences in efficacy or safety of avacincaptad pegol were seen with increasing age in these studies. No dose adjustment is required in patients 65 years and above.

### 17 PATIENT COUNSELING INFORMATION

Advise patients that following IZERVAY administration, patients are at risk of developing neovascular AMD, endophthalmitis, elevated intraocular pressure and retinal detachments. If the eye becomes red, sensitive to light, painful, or if a patient develops a change in vision, instruct the patient to seek immediate care from an ophthalmologist.

Patients may experience temporary visual disturbances and blurring after an intravitreal injection with IZERVAY and the associated eye examinations. Advise patients not to drive or use machinery until visual function has recovered sufficiently.

Manufactured by:

IVERIC bio, Inc., An Astellas Company. Parsippany, NJ 07054

©2023 IVERIC bio, Inc., An Astellas Company. IZERVAY is a trademark of IVERIC bio, Inc., An Astellas Company.





BY JEROME SHERMAN, OD, AND SHERRY BASS, OD

## YOU BE THE JUDGE

# Stuck on Third

*Getting the correct diagnosis is like a triple in baseball; it doesn't always score a run.*

It is well known that the eyes can exhibit signs of systemic diseases and that an eye examination can alert the practitioner to further investigate whether their patient may have a suspected systemic condition. Early detection potentiates the likelihood of early treatment, which can not only save vision but can also save lives. However, there may be times when the best intentions go awry and the ultimate devastating result, which might have been avoided, inevitably occurs.

## Case

A college-educated 25-year-old Caucasian female presented with the chief complaint of a foreign body sensation in the right eye. The patient wore soft contact lenses for several years without significant problems. No detailed general health history was obtained on this exam.

Best-corrected visual acuity measured 20/20 in each eye with contact lenses. A slit lamp evaluation revealed a misdirected lash, which had contact with the inferior conjunctiva. While performing the slit lamp exam, the eye doctor observed a “limbal iridescence” in each eye. Lash removal appeared to alleviate the patient’s symptoms, but the eye doctor requested that the patient return in two days. When she did, she was evaluated by a different eye doctor in the same office. The patient was asymptomatic, and visual acu-

ity was 20/20 in each eye. The second eye doctor also performed a slit lamp exam and noted “crocodile shagreen” and suggested a consultation with a cornea specialist. However, it appeared that the patient never bothered to see a specialist.

## Follow-up

Six months later, the patient presented again to the first eye doctor for a routine contact lens check-up. Visual acuity was correctable to better than 20/20 in each eye. A slit lamp exam again revealed a large iridescent ring deep in the cornea near the limbus (*Figure 1*). At this visit, the eye doctor decided to pursue the unusual slit lamp obser-

vation. He consulted *The Wills Eye Manual* in his office and discovered that the observed rings fit the description of a Kayser-Fleischer ring, which is most often due to abnormal copper deposits in Wilson’s disease (WD), also known as Wilson’s hepatolenticular disease. He then asked the patient about any history of liver problems, and the patient responded that some of her liver enzymes had been noted to be mildly abnormal. She mentioned that her physician believed the liver enzyme disorder was due to the Accutane (isotretinoin, Roche) that the patient was taking for acne, and perhaps due to a prior mononucleosis infection caused by the Epstein-Barr virus.

The eye doctor decided to fax a single-page interprofessional report to the patient’s internist. It listed his observation and the possible association with WD. In his deposition many months later, that doctor testified that he faxed the report and gave the original to the patient, then he told the patient to follow up on it with her internist and he

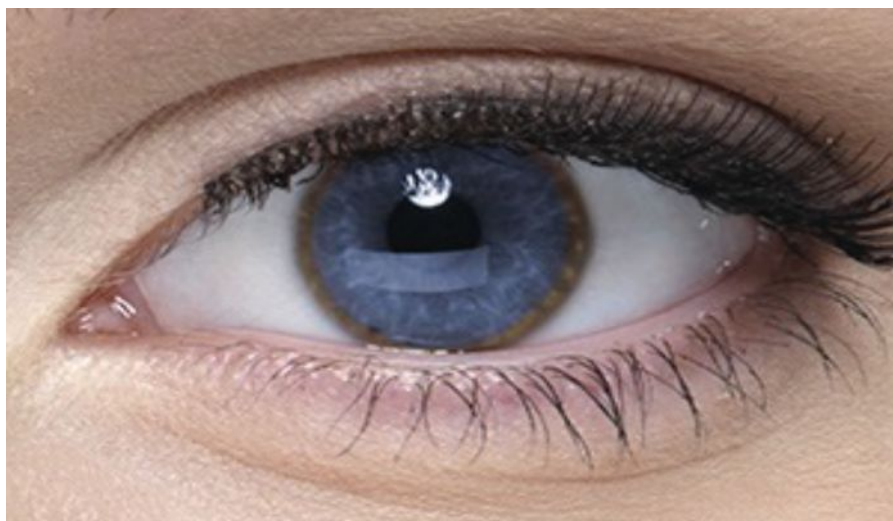

Photo: Wilson Disease Association

**Fig. 1. Kayser-Fleischer brownish-yellow ring in the corneal-scleral limbal junction of a patient with Wilson’s disease (not the one described in this case).**

### About Drs. Sherman and Bass

**Dr. Sherman** is a Distinguished Teaching Professor at the SUNY State College of Optometry and editor-in-chief of *Retina Revealed* at [www.retinarevealed.com](http://www.retinarevealed.com). During his 53 years at SUNY, Dr. Sherman has published about 750 various manuscripts. He has also served as an expert witness in 400 malpractice cases, approximately equally split between plaintiff and defendant. Dr. Sherman has received support for *Retina Revealed* from Carl Zeiss Meditec, MacuHealth and Konan. **Dr. Bass** is a Distinguished Teaching Professor at the SUNY College of Optometry and is an attending in the Retina Clinic of the University Eye Center. She has served as an expert witness in a significant number of malpractice cases, the majority in support of the defendant. She serves as a consultant for ProQR Therapeutics.

**TABLE 1. MANIFESTATIONS OF COPPER DEPOSITION IN THE BASAL GANGLIA**

Neurological Impairment	Psychiatric Impairment
<ul style="list-style-type: none"> <li>· Movement disorders</li> <li>· Speech disorders</li> <li>· Cognitive impairment</li> </ul>	<ul style="list-style-type: none"> <li>· Psychosis</li> <li>· Personality changes</li> <li>· Mood changes</li> </ul>

retained a copy for his records. A week later, the patient returned because of a lost contact lens, and the eye doctor asked whether she had seen her internist. The patient had not. On the chart, the eye doctor wrote under the plan section to call the internist.

He never did.

Over the next year, the patient was seen several times by her internist for various problems, including a marked weight gain, but apparently never mentioned the eye doctor’s concern about WD. It appeared that the internist’s staff buried the fax in the patient’s record and never informed the internist that a fax was received. So, the internist was unaware of the eye doctor’s concern. Over this period, the patient began to develop psychiatric symptoms. Two psychiatrists she consulted attributed the problems to her parents’ recent divorce. But as the disorder worsened over many months, one psychiatrist noted increasing tremors and referred the patient to a neurologist to rule out Parkinson’s disease.

Slurred speech and involuntary hand movements were noted. An MRI revealed copper deposition in the basal ganglia at the base of the brain that resulted in neurological and psychiatric abnormalities (*Table 1*). Blood and urine testing confirmed the abnormal copper levels, a diagnosis of WD was finally confirmed and treatment initiated. The diagnosis was made about one and a half years after the first eye doctor noted the iridescent corneal rings. Although the patient improved somewhat with treatment, she still suffered from what some doctors have labeled as severe neurological dysfunction.

### You Be the Judge

In light of the facts presented here, consider the following questions:

- Did the eye doctor meet the standard of care when he faxed a report to the internist’s office?
- Did the eye doctor meet the standard of care when he informed the patient of his concerns, gave the patient a copy of his report and told her to follow up with the internist?
- The eye doctor said he was going to follow up with a telephone call to the patient’s internist, but never did. Was the eye doctor culpable?
- Did the eye doctor’s responsibility in this case end when he informed the patient of his suspicion, and was it the patient’s responsibility to follow up with her internist?

### Malpractice Allegation

Numerous doctors were named in the lawsuit: the two eye doctors from the same practice, three physicians in the patient’s medical group and two psychiatrists were all served. None of the doctors in the medical group who had evaluated the patient over the past five years ever considered a diagnosis of WD.

I (JS) was an expert witness who defended the two optometrists. It struck me when one of the lead attorneys, who was wearing cowboy boots, had his feet on the conference room table. He was far more interested in speed-reading a stack of magazines than in any of the depositions. I chatted with him about why he appeared to have little interest in the contents of the expert testimonies. His response surprised me. To paraphrase: With seven defendants, all with excellent malpractice insurance, there was no reason for the case to go to trial. He predicted that each insurance carrier would prefer to contribute several hundred thousand dollars to the total settlement than risk the uncertainty of a trial.

**Outcome:** The attorney with the cowboy boots was right. The insurance companies for all the defendants contributed to the final global award, about \$2 million for the plaintiff as a result of the delayed diagnosis of WD and about \$1 million for the law firm representing the patient.

### Not Yet Home

Wilson’s disease is a rare, autosomal recessive genetic disorder that affects the metabolism of copper.<sup>1</sup> It is believed to affect between one in 30,000 to one in 100,000 individuals. Signs and symptoms begin early in life, up to age 35. It is primarily characterized by hepatic and neurologic disease. The liver does not excrete copper in the bile, and copper accumulates in several organs, including the eye and brain. Because of copper manifesting in the cornea, eye doctors are in a perfect position to detect this deadly disease early, before the onset of major organ damage.

Neither eye doctor recognized the unusual corneal observation as a Kayser-Fleischer ring at first. This alone does not constitute malpractice because most eye doctors might similarly fail to recognize this rare and subtle observation. The eye doctor who used the term “crocodile shagreen” had the wrong diagnosis but did attempt to refer the patient. The eye doctor who consulted *The Wills Eye Manual* arrived at the correct diagnosis. He referred the patient back to her internist to confirm his suspicions, but his astute diagnosis and attempt at referral never benefited the patient. In baseball terms, this eye doctor struck out when he first saw the patient but hit a triple months later.

NOTE: This article is one of a series based on actual lawsuits in which the author served as an expert witness or rendered an expert opinion. These cases are factual, but some details have been altered to preserve confidentiality. The article represents the authors’ opinion of acceptable standards of care and do not give legal or medical advice. Laws, standards and the outcome of cases can vary from place to place. Others’ opinions may differ; we welcome yours.

However, he never scored a run (in the sense of a benefit to the patient).

But what is the standard of care with regards to referral? Is informing the patient and faxing a report adequate when one uncovers a systemic disease-related finding with significant morbidity and, eventually, mortality if undiagnosed and untreated? Very little is written in the optometric literature concerning the appropriate standard. In his book *Legal Aspects of Optometry*, John Classe, OD, JD, suggested making the appointment while the patient is in your office and setting up a system to make certain that the appointment is kept.<sup>2</sup>

What about the patient's responsibility in this case? The patient was told about the corneal rings and likely connection with WD. She was also given the original referral form and knew that it was faxed to the internist. In her deposition, the patient claimed that she did not think it was a serious problem because the eye doctors who examined her failed to convey a sense of urgency.

As the patient began to gain weight and developed psychiatric and neurological symptoms, she never mentioned the eye doctor's findings to any of the specialists she was consulting.

“ **What is the standard of care with regards to referral? Is informing the patient and faxing a report adequate when one uncovers a systemic disease-related finding with significant morbidity?** ”

This supports the contention that the patient was at least partly to blame for the outcome. Others will argue that, since the condition was already causing psychiatric problems, the patient could not be held culpable in any way.

To avoid malpractice in this case would have meant going beyond the standard. In retrospect, it appeared the

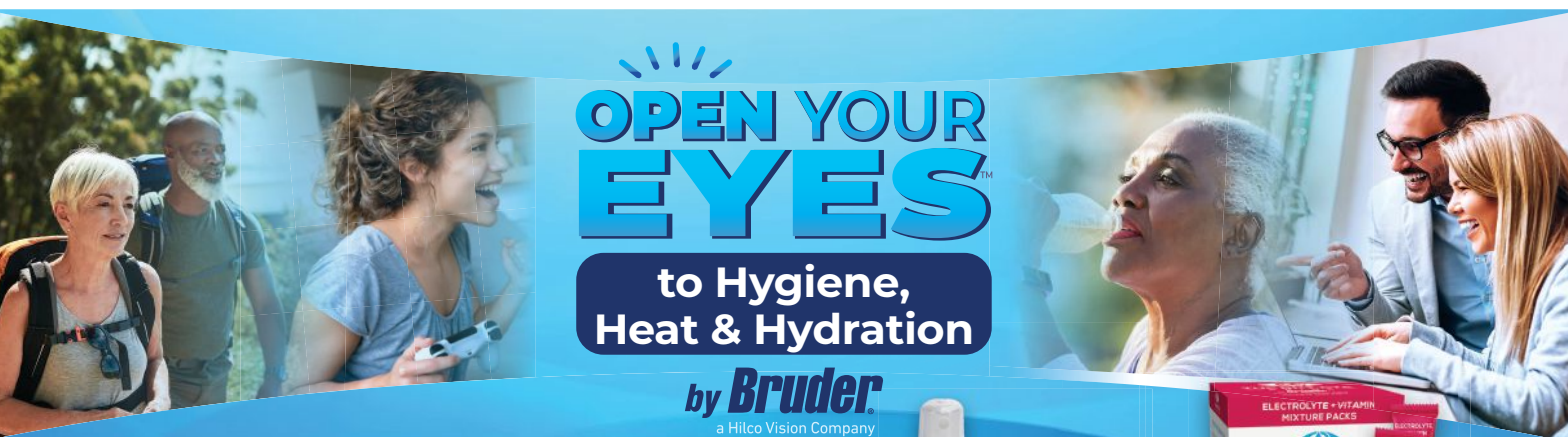OD should have picked up a phone to relay his suspicion of WD directly with the internist. Fax reports (or even scanned or mailed reports) can be easily misplaced in a busy practice, and even if the document was put in the patient's chart, it could get buried by other documents and never be seen by the treating doctor. This case also points out that relying on the patient to convey important information may not be justified.

Although it is debatable as to whether the OD met the existing standard of care, it is highly recommended in such a case to go beyond the standard and ensure the right information gets into the right hands, especially when suspecting a disease with high morbidity. Decrease the risk of malpractice litigations dramatically by taking the extra step.

With no one on base, ballgames cannot be won with a triple. ■

1. Ala A, Walker AP, Ashkan K, et al. Wilson's disease. *Lancet* 2007;369(9559):397-408.

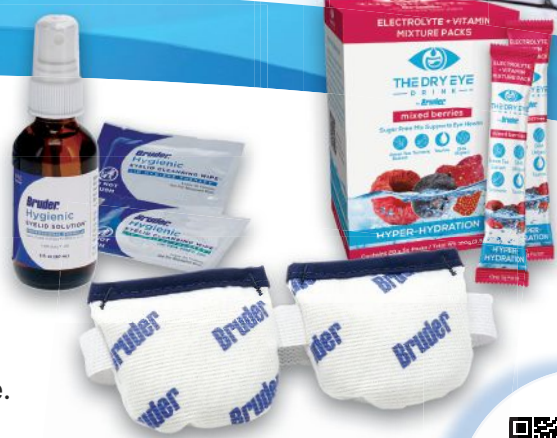2. Classe J. *Legal Aspects of Optometry*. 1st ed. Butterworth-Heinemann; 1989.



# OPEN YOUR EYES™

to Hygiene, Heat & Hydration

by **Bruder**  
a Hilco Vision Company



**Open your eyes to Bruder.™** You know us for our #1 doctor-recommended moist heat mask. But did you know we also offer science-based products for lid hygiene and hydration?

Help your patients alleviate dry eye symptoms while also improving comfort by encouraging daily lid hygiene and lid warming. And don't forget to hydrate with Dry Eye Drink™ by Bruder, specially formulated to help improve the ocular surface.

Stock up now on eye care essentials at [order.bruder.com](http://order.bruder.com), [eyes@bruder.com](mailto:eyes@bruder.com) or 888-827-8337. Learn about the science behind Bruder products at [bruder.com/pro](http://bruder.com/pro).





# THE WILD AND WOOLLY WORLD OF ANTI-VEGF IN 2023

A once-simple treatment protocol has gotten more sophisticated—and complicated—by novel drug compounds, varied dosing regimens and sustained-release delivery methods. Here's the current state of affairs.



BY JESSICA HAYNES, OD,  
AND MOHAMMAD RAFIEETARY, OD  
GERMANTOWN, TN

**A**nti-vascular endothelial growth factor (anti-VEGF) agents have been used in ophthalmic care for nearly two decades since the first approval in 2004. Their development revolutionized the management of posterior segment diseases such as neovascular age-related macular degeneration (nAMD), diabetic retinopathy (DR), diabetic macular edema (DME), macular edema secondary to retinal vein occlusion (RVO) and choroidal neovascularization (CNV) from any source, among others (as depicted in *Figures 1 to 3*).

However, after a long period of dominance by the familiar triumvirate of Avastin, Lucentis and Eylea, the medication landscape in 2023 is far more varied. Optometrists would do well to keep up with recent anti-VEGF advances in order to have more accurate and fruitful discussions with patients prior to referral and during monitoring visits for those engaged in comanagement.

## A Brief History

The first selective anti-VEGF molecule used for ophthalmic purposes was pegaptanib (Macugen), though its reign was short-lived; treated patients maintained but did not regain visual acuity. While that agent was on the market, bevacizumab (Avastin), originally designed to treat colon cancer, was soon found to help control neovascularization and vascular permeability in the aforementioned conditions when injected intravitreally into the eye. Numerous other medications have since been developed for ocular use with the goal to improve efficacy and durability of treatment.<sup>1</sup>

## Drawbacks

Intravitreal anti-VEGF agents provide highly effective and low-risk treatment for conditions that were previously very difficult or impossible to manage, but they are not without downsides. One difficulty that remains is known as treatment burden. Though advances in molecular design have led to longer-acting agents, these medications often require repeat injections over long periods of time. The original regimens required monthly or bimonthly visits.

For patients, this can mean lost productivity with more days off work, time away from family and friends, financial burdens, long travel distances, many hours spent each year in the office of a retina specialist and even an incrementally higher risk of endophthalmitis with each additional injection. In some cases, this burden is placed not only on the patient but also on those they rely on for support and transportation.

Another downside: While anti-VEGF agents target a key factor in the pathophysiology of a wide variety of vascular and angiogenic posterior segment conditions, some patients still have less than optimal response to treatment. For example, patients battling DME may suffer from persistent edema even after numerous treatments with the best available agents.<sup>2</sup> In addition, anti-VEGF injections do not treat every aspect of these conditions, such as macular ischemia in DR or geographic atrophy (GA) in AMD, driving the need for different therapeutic options to be used in addition to or in place of anti-VEGF.

No matter how effective the agent, early detection and intervention is also key to achieving positive outcomes.

### About the authors

**Dr. Haynes** is a consultative optometrist at the Charles Retina Institute in Germantown, TN, and consulting faculty at Southern College of Optometry in Memphis. She is a fellow of the American Academy of Optometry (AAO). She is a paid speaker for Heidelberg Engineering and a consultant for Notal Vision. **Dr. Rafieetary** is also a consultative optometric physician at the Charles Retina Institute and a fellow of the AAO. He is on advisory boards for Heidelberg Engineering, Optos, Regeneron, Notal Vision and Cardinal Health.

Patients with nAMD, for example, can quickly develop submacular scarring and photoreceptor atrophy if intervention is not initiated promptly. Another consideration of anti-VEGF therapy is the potential of adverse events associated with any intravitreally delivered medication, which even includes severe complications like endophthalmitis.

While these pitfalls exist, use of anti-VEGF in the eye has saved the vision of countless patients, and innovation continues to improve the therapy over time. In the remainder of this article, we provide a review of the current tried-and-true anti-VEGF agents along with the newcomers in this space.

### Anti-VEGF Classics

Though the landscape of anti-VEGF therapy is always evolving, the following three medications have historically been used most in the United States:

- Bevacizumab (Avastin), although off-label in eye care, is still commonly used intravitreally for the conditions described above. Its greatest advantage is that it is cost-effective.

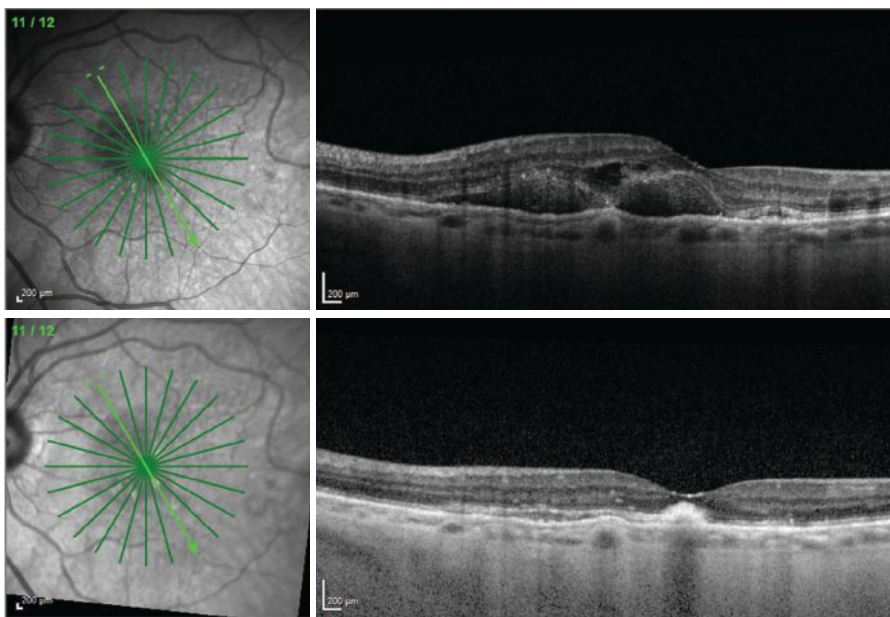
- Ranibizumab (Lucentis, Genentech) is FDA-approved for nAMD, all forms of DR, macular edema secondary to RVO and myopic CNV.<sup>3</sup>

- Aflibercept (Eylea, Regeneron) is FDA-approved for nAMD, all forms of DR and macular edema secondary to RVO.<sup>4</sup>

### New-generation Compounds

Development of novel drugs continues to provide greater efficacy and durability with goals of improving visual outcomes and decreasing burden of treatment. Two examples of more recently approved medications follow:

- **Brolucizumab-dbil (Beovu, Novartis).** This agent was FDA approved in 2019 for the treatment of nAMD and later for DME. Since its approval, concerns surrounding its increased risk of intraocular inflammation have stunted its integration into clinical practice. Post-approval analysis suggests about 4% risk of intraocular inflammation with some being severe occlusive vasculitic events.<sup>5</sup> A chief advantage of Beovu is durability,



**Fig. 1.** An 83-year-old female presented with nAMD and 20/400 visual acuity (top). She received an injection of Eylea and returned four weeks later with significant improvement in macular thickness (bottom). Her visual acuity was still 20/200 at this visit. The patient will continue to receive injections, and the visual outcome will depend on how much submacular scarring and photoreceptor atrophy is present once the macula stabilizes.

with about 50% of patients in both the nAMD and DME trials being able to maintain a q12 week dosing schedule.<sup>6,7</sup>

- **Faricimab-svoa (Vabysmo, Genentech).** Vabysmo received FDA approval in 2022 for the treatment of nAMD and DME. The drug targets not only VEGF but also angiopoietin-2, another pro-angiogenic molecule, making it the first biphasic intravitreal anti-VEGF molecule. A major advantage of Vabysmo is its durability, with about 50% of patients in clinical trials able to maintain q16 week dosing for nAMD and DME.<sup>8,9</sup>

### High-dose Aflibercept

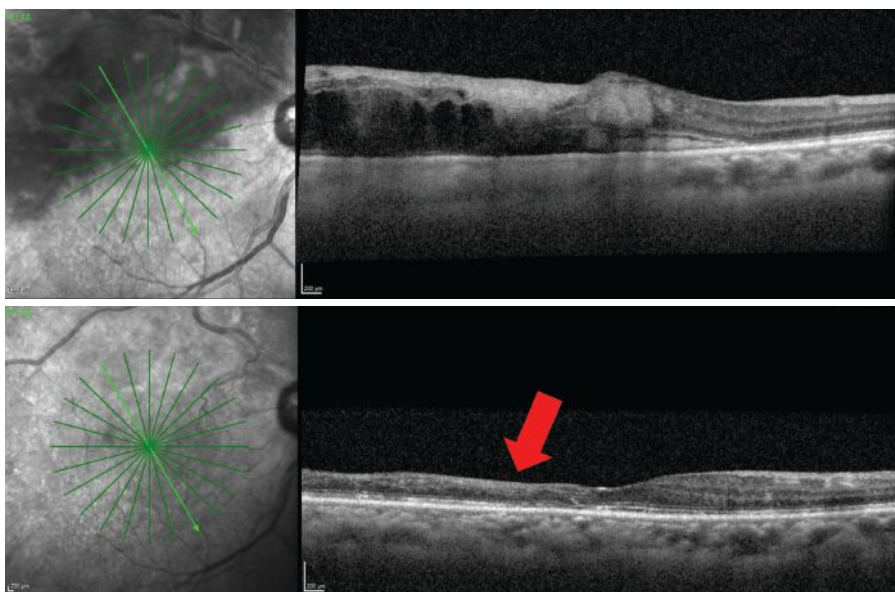
Eylea was previously only approved at a dose of 2mg per injection; however, last month the FDA gave its stamp of approval to a higher aflibercept dose of 8mg for the treatment of wet AMD, DME and DR, allowing for extended intervals between treatments of up to 16 weeks. The recommended regimen for Eylea HD—the brand name of the high-dose form—is monthly injections for the first three months followed by treatments every eight to 16 weeks in wet AMD and DME and every eight to 12 weeks for DR.

The drug's approval was sparked by the positive results of two clinical trials, Pulsar and Photon, which demonstrated non-inferiority and clinically equivalent vision gains at 48 weeks with eight-, 12- and 16-week dosing regimens after the three initial monthly doses. The Pulsar study, which evaluated the efficacy of Eylea HD on patients with nAMD, showed that the high-dose formulation provided longer dosing intervals and improved drying of fluid.<sup>10</sup> The Photon study for DME also showed the benefit of longer treatment intervals.<sup>11</sup>

Adverse reactions, while only occurring in 3% or fewer of patients, included cataract, conjunctival hemorrhage, increased intraocular pressure, ocular discomfort, eye pain or irritation, blurry vision, floaters, vitreous detachment, corneal epithelium defect and retinal hemorrhage.

### Step Therapy

With all these new treatment options, which are doctors most likely to choose? The current reality is that treatment decisions depend not only on doctor preferences, but logistical considerations and insurance coverage. Most



**Fig. 2.** A 68-year-old male patient presented with macular edema secondary to branch RVO and visual acuity of 20/80 (top). The patient had four monthly Avastin injections, which resulted in complete resolution of the macular edema (bottom). The patient's visual acuity improved to 20/50 but was limited by the severity of macular ischemia that is evident from the significant inner retinal thinning (red arrow).

insurances require some variety of “step therapy” where more affordable options like Avastin must be tried first, and then changed in a stepwise approach if response is suboptimal.

There is obvious concern that delaying treatment with more efficacious drugs could result in worse visual outcomes. DRCR Network Protocol AC evaluated the response of DME with initial Eylea treatment vs. initial Avastin followed by Eylea if response was suboptimal with Avastin. It found that the two arms had similar visual outcomes.<sup>12</sup> While there are many struggles on an individual patient basis navigating the requirements of step therapy, these results were at least reassuring that, on average, patients will not be harmed by step therapy.

## Biosimilars

In addition to the creation of novel medications, a class of drugs called biosimilars is being created to reduce costs and increase access to care. Anti-VEGF molecules are biological compounds created through complex and expensive manufacturing processes using living material. When their patents expire, biosimilars of the reference drug can be produced. Biosimilars have been

described as the “generic versions” of biological compounds, but it is important to consider the difference between a traditional drug and a biological compound. Traditional drugs are smaller molecules whose known composition can be replicated exactly through chemical synthesis. Biological compounds, or biologics, are large-complex molecules. They cannot be precisely replicated due to their large size and complicated manufacturing processes. A biosimilar is a compound that is not identical to its reference drug but has been shown to be similar in structure, function, safety and efficacy.<sup>13</sup>

There are currently two FDA-approved biosimilars of Lucentis available for use in the United States: Byooviz (ranibizumab-nuna, Biogen/Samsung Bioepis) and Cimerli (ranibizumab-eqrn, Coherus BioSciences). Byooviz was the first to receive FDA approval in 2021 for the treatment of nAMD, macular edema following RVO and myopic CNV.<sup>14</sup> The following year, in 2022, Cimerli became approved as an interchangeable biosimilar for the treatment of all prior indications of Lucentis (nAMD, DR, DME, myopic CNV and macular edema following RVO).<sup>15</sup>

Not all biosimilars are considered interchangeable. While interchangeable biosimilars must meet additional requirements by the FDA, this designation does not necessarily mean that they are safer or more effective.<sup>18</sup>

There is particular concern that the FDA approval of Avastin biosimilars could ultimately *increase* the cost of care. With such a biosimilar FDA-approved for ophthalmic use, pharmacies may no longer be able to compound off-label bevacizumab, thus removing the lowest-cost option from the market. At this year's American Society of Retina Specialists meeting, Ravi Parikh, MD, of the NYU Grossman School of Medicine and Manhattan Retina and Eye Consultants in New York City, noted that “switching from Lucentis and Eylea to biosimilars would offset only 30% of the increase resulting from the higher cost of the bevacizumab biosimilar.”<sup>17</sup>

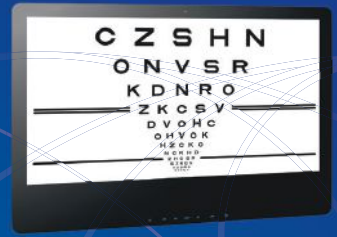
Nonetheless, in general, production of anti-VEGF biosimilars has the potential to decrease the cost of care and increase accessibility of more effective treatment options. However, it is unclear how well these medications will be accepted by physicians. Use of biosimilars throughout all fields of medicine in the US is fairly new, with the first FDA biosimilar being approved only in 2015.<sup>18</sup> This is particularly novel in the retina space with the first FDA approval of an anti-VEGF biosimilar occurring in 2021.

Concerns stem from the complicated manufacturing process of these compounds, where seemingly benign changes could lead to increased adverse reactions, with particular concern for immunological responses.<sup>13</sup> Expanded use on a broader scale will help to uncover if these concerns have merit or not. At present, it is encouraging to have these additional and more affordable options with numerous other biosimilars for Lucentis and Eylea in clinical trials.

## Novel Delivery Methods

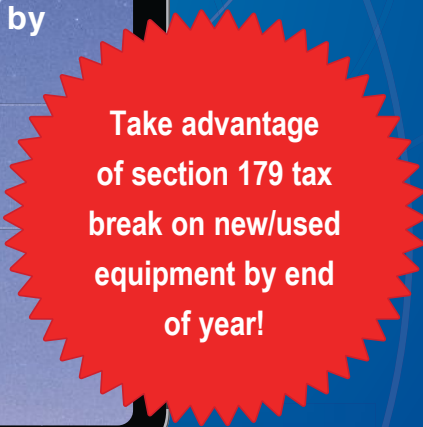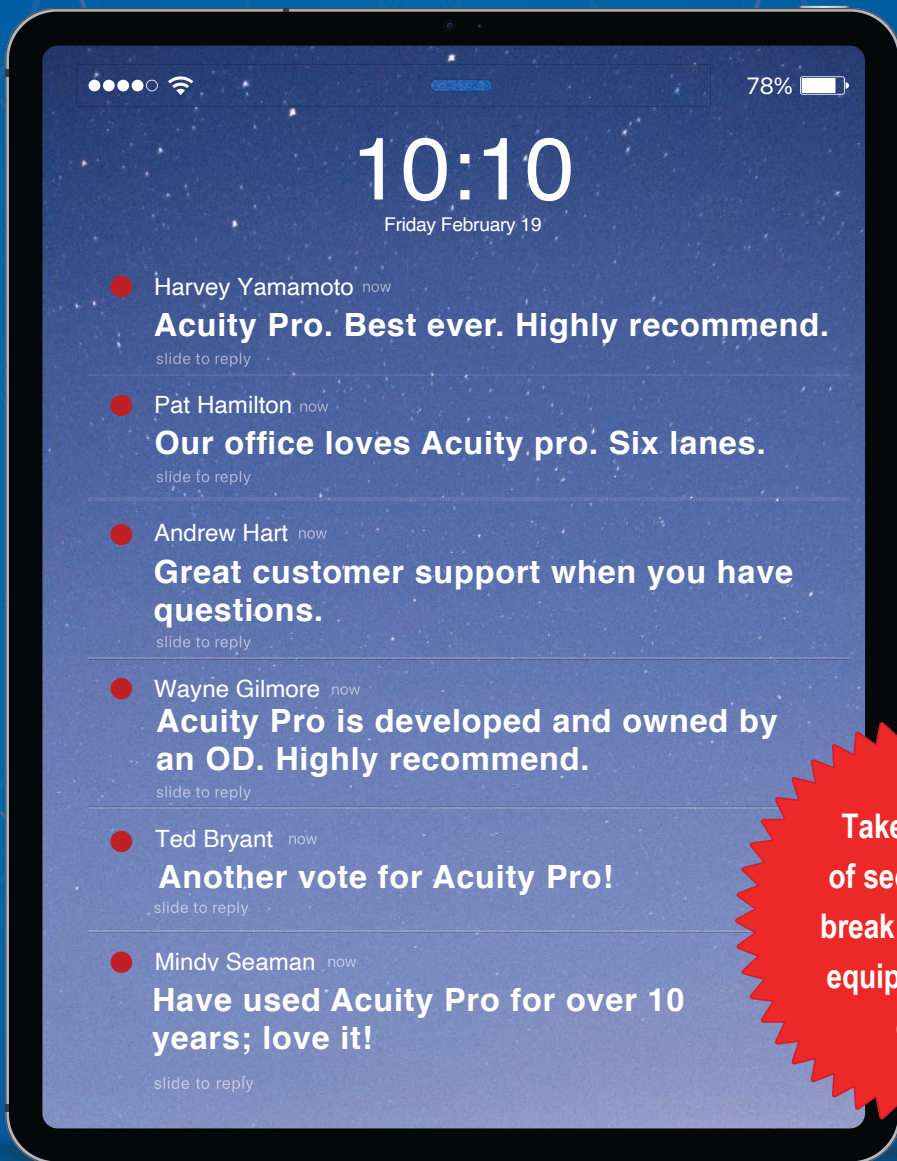
Given the burden and barriers in the care of chronic conditions such as nAMD and DME—caused by factors such as injection frequency, anxiety and fatigue—exploration of alternative





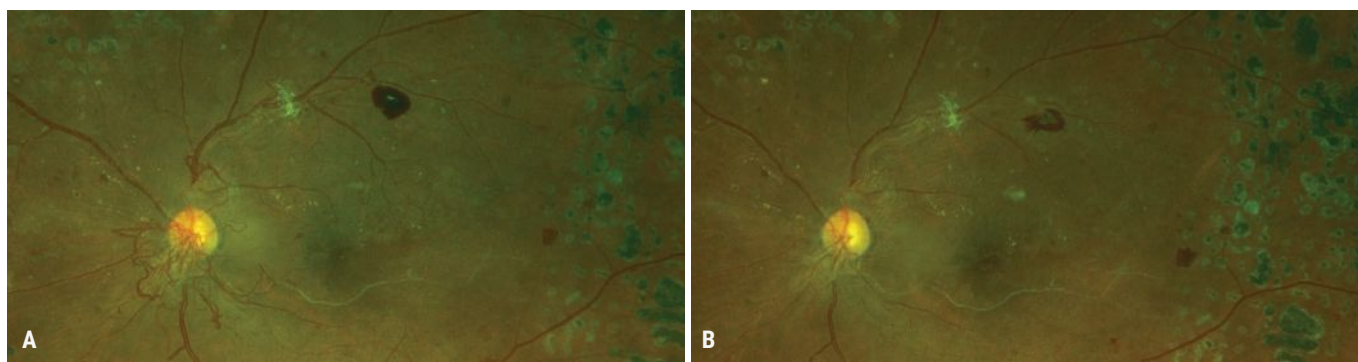
Over 20 years of 👍 and ❤️ !

I'm looking for a reputable solution for a digital acuity system – any suggestions?



Disaster proof by design | [acuitypro.com](http://acuitypro.com) / 580-243-1301

Sloan / Snellen / Numbers / Contrast / ETDRS / White On Black Option / Randomize Custom Remote / Marco Integration / Free Support / No Annual Fees



**Fig. 3. (A)** A 40-year-old Black female presented after noncompliance with significant neovascularization at the disc (NVD). She has previously been treated with panretinal photocoagulation. She received an Avastin injection and returned one month later with resolution of the NVD **(B)**. The patient must be compliant with follow-ups, as the neovascularization can return and require the need for more injections.

dosing strategies to overcome these concerns has surged. One of these innovations includes permanent implantable devices such as the port delivery system (PDS; Susvimo implant, Genentech).<sup>19,20</sup> This device received FDA approval for nAMD in 2021 and was in clinical trials for DME and DR.

Following surgical implantation of the device, patients had the port refilled every six months, which was more tolerable than frequent intravitreal injections. However, in October 2022, Genentech voluntarily recalled Susvimo due to a mechanical failure of the device during the refill procedure, and the company suspended the DR and DME clinical trials.<sup>21</sup> Currently, there are no updates on the device's status. As for patients who received the PDS during clinical trials or post-FDA approval, as long as the device is intact, they can continue receiving the appropriate interval refills.

Other delivery alternatives under investigation include bioerodible implants, such as depot formulations of sunitinib malate GB-102 (Graybug Vision) and genetic therapies that introduce genetic material through subretinal or suprachoroidal injection of adeno-associated virus vectors.<sup>22</sup> These genes alter the ocular tissue to produce endogenous anti-VEGF with the hope to seize or reduce the need for intravitreal injections. Several are in various stages of clinical trials for AMD, DR and even GA. Examples include RGX-314 (RegenxBio), 4D-150 (4D Molecular Therapeutics), EXG102-031 (Exegenesis Bio), GEM103 (Disc Medicine) and SK0106

(Skyline Therapeutics), the last which recently received its investigational new drug application for nAMD.<sup>23</sup>

### Alternatives to Injections

In addition to all these possibilities of longer-acting agents, combination strategies, sustained-release and genetic therapies, there is potential for topical and oral agents in the treatment of these conditions. OTT166 (OcuTerra Therapeutics), an integrin inhibitor, is a proposed engineered molecule that has shown safety and efficiency via topical application for treatment of DR in early-phase trials. Currently, the DREAM (Diabetic Retinopathy Early Active Management) study is in Phase II trials for further investigation.<sup>24</sup>

APX3330 (Ocuphore Pharma) is an oral agent that—despite failing to meet its primary endpoint of reversal of moderately severe to severe DR (ETDRS severity levels 47 and 53) in its Phase II trial, ZETA-1—did demonstrate good systemic and ocular safety. In addition, it was announced recently that ZETA-1 showed a statistically significant reduction in the progression of DR to more advanced stages in those taking APX3330.<sup>25</sup>

Xiflam (InflamX) is also an oral agent that inhibits inflammasomes. It is currently under investigation for treatment of DR and DME.

### Future Possibilities

These are definitely exciting times for research and development. Currently, there are nearly 90 investigational novel

agents in the pipeline for various retinal diseases, primarily targeting wet and dry AMD, DR, DME and inherited retinal disorders. A comprehensive review of these can be found in the January/February 2023 issue of *Retina Specialist*.

### Non-Anti-VEGF Interventions

As mentioned previously, while anti-VEGF medications have revolutionized care of the posterior segment, they do not treat every aspect of posterior segment disease. In the treatment of AMD, for example, anti-VEGF medications are used to manage the complication of CNV but they do not treat the degenerative process of AMD itself. Novel targets are needed to treat other aspects of disease such as complement inhibition for GA.

In February 2023, a new class of drug was released for the treatment of GA secondary to AMD. Pegcetacoplan (Syfovre, Appellis) inhibits complement factor C, stopping a vital step in the complement cascade, which promotes inflammation. Syfovre is an intravitreal injection with recommended dosing between 25 and 60 days. While Syfovre does not reverse GA or stop it entirely, it reduces GA growth between 17% and 22% at two years depending on the dosage.<sup>26</sup> It is meant to be a long-term ongoing treatment and not a cure.

In clinical trials, Syfovre did increase the risk of CNV, with 12% occurrence in those treated monthly, 7% in those treated bimonthly and 3% in the sham group. Those who develop CNV will then require anti-VEGF injections.<sup>27</sup>

In mid-July, the American Society of Retina Specialists announced reports of retinal vasculitis in a handful of patients receiving injections of Syfovre, though this side effect was not reported in clinical trials.<sup>28</sup> The ASRS statement noted that all occurrences took place between seven and 13 days after drug administration, and the etiology of the events remains unclear. At the time of that announcement, the outcomes of affected patients were still evolving.

While the situation continues to unfold, eyecare practitioners must stay vigilant for any updates that emerge and decide individually whether they plan to adjust their intervention protocols based on the new information.

Last month, a second drug for GA became FDA-approved: an intravitreally dosed complement factor V inhibitor, avacincaptad pegol (Izervay), from Iveric Bio. In its Phase III trials, slowing of disease progression was observed after as few as six injections; after 12 injections, patients experienced up to a 35% reduction in GA progression rate compared with sham. The most common adverse reactions reported by patients during trials included conjunctival hemorrhage (13%), increased intraocular pressure (9%) and blurry vision (8%).<sup>29</sup>

Other intravitreal injectable treatment options include intravitreal steroids. While this approach can have the well-known side effects of cataract formation and increased intraocular pressure, it continues to have a role in treating posterior segment disease. Kenalog can be used off-label intravitreally or via sub-Tenon delivery. In addition, sustained-release intravitreal steroid injections include Ozurdex, Yutiq and Iluvien. While each has a unique list of approvals, this drug category can be helpful in treating conditions such as DME, macular edema from RVO, cystoid macular edema and non-infectious posterior uveitis. Though anti-VEGF is considered the first-line treatment for DME, DRCR Network Protocol U showed that persistent DME despite multiple Lucentis injections may have improvement of macular thickness when supplemented with Ozurdex.<sup>30</sup>

## Takeaways

Intravitreal anti-VEGF injections have revolutionized posterior segment care, providing vision-saving treatments for a variety of conditions. Longer-acting and more efficacious medications as well as biosimilars continue to be developed to improve cost and patient access. Sustained delivery systems and alternate delivery methods are also a likely possibility in the near future. Drugs with new mechanisms of action will continue to advance as well, providing new delivery methods and treating aspects of disease that do not respond to anti-VEGF.

The trade-off between the simplicity of yesterday and the complexity of today is our much more robust capability to fight posterior segment disease at present. Both the complexity and the capability will no doubt continue to increase over time. ■

1. Kim LA, D'Amore PA. A brief history of anti-VEGF for the treatment of ocular angiogenesis. *Am J Pathol.* 2012;181(2):376-9.

2. Kuroiwa DAK, Malerbi FK, Regatieri CVS. New insights in resistant diabetic macular edema. *Ophthalmologica.* 2021;244(6):485-94.

3. Lucentis. [package insert]. San Francisco, CA: Genentech, Inc. 2014.

4. Eylea. [package insert]. Tarrytown, NY: Regeneron Pharmaceuticals, Inc. 2023.

5. Monés J, Srivastava SK, Jaffe GJ, et al. Risk of inflammation, retinal vasculitis, and retinal occlusion-related events with brolicizumab: post hoc review of HAWK and HARRIER. *Ophthalmology.* 2021;128:1050-9.

6. Dugel PU, Koh A, Ogura Y, et al. HAWK and HARRIER: Phase 3, multicenter, randomized, double-masked trials of brolicizumab for neovascular age-related macular degeneration. *Ophthalmology.* 2020;127(1):72-84.

7. Brown DM, Emanuelli A, Bandello F, et al. KESTREL & KITE: 52-week results from two phase III pivotal trials of brolicizumab for diabetic macular edema. *Am J Ophthalmol.* 2022;238:157-72.

8. Heier JS, Khanani AM, Quezada Ruiz C, et al. Efficacy, durability, and safety of intravitreal faricimab up to every 16 weeks for neovascular age-related macular degeneration (TENAYA and LUCERNE): two randomised, double-masked, phase 3, non-inferiority trials. *Lancet (London, England).* 2022;399(10326):729-40.

9. Wykoff CC, Abreu F, Adamis AP, et al. Efficacy, durability, and safety of intravitreal faricimab with extended dosing up to every 16 weeks in patients with diabetic macular oedema (YOSEMITE and RHINE): two randomised, double-masked, phase 3 trials. *Lancet (London, England).* 2022;399(10326):741-55.

10. Lanzetta P. Intravitreal aflibercept injection 8 mg for nAMD: 48-week results from the phase 3 PULSAR trial. Presented at American Academy of Ophthalmology 2022 annual meeting, September 30 to October 3, 2022. [investor.regeneron.com/static-files/e3307e7d-d495-438c-b8bb-c62cdacdb37](https://investor.regeneron.com/static-files/e3307e7d-d495-438c-b8bb-c62cdacdb37). Accessed July 9, 2023.

11. Brown DM. Intravitreal aflibercept injection 8 mg for DME: 48-week results from the phase 2/3 PHOTON trial. Presented at American Academy of Ophthalmology 2022 annual meeting, September 30 to October 3, 2022. [investor.regeneron.com/static-files/da20405e-b843-402e-855b-d824a15dec60](https://investor.regeneron.com/static-files/da20405e-b843-402e-855b-d824a15dec60). Accessed July 9, 2023.

12. Jhaveri CD, Glassman AR, Ferris FL, et al. Aflibercept monotherapy or bevacizumab first for diabetic macular edema. *N Engl J Med.* 2022;387(8):692-703.

13. Biosimilars. US FDA. Updated March 1, 2023. [www.fda.gov/drugs/therapeutic-biologics-applications-bla/biosimilars](https://www.fda.gov/drugs/therapeutic-biologics-applications-bla/biosimilars). Accessed July 9, 2023.

14. FDA Approves First Biosimilar to Treat Macular Degeneration Disease and Other Eye Conditions. US FDA. Published September 17, 2021. [www.fda.gov/news-events/press-announcements/fda-approves-first-biosimilar-treat-macular-degeneration-disease-and-other-eye-conditions](https://www.fda.gov/news-events/press-announcements/fda-approves-first-biosimilar-treat-macular-degeneration-disease-and-other-eye-conditions). Accessed July 1, 2023.

15. CIMERLI™ (ranibizumab-eqrn) U.S. Prescribing Information, August 2022. [www.accessdata.fda.gov/drugsatfda\\_docs/label/2022/761165s000lbl.pdf](https://www.accessdata.fda.gov/drugsatfda_docs/label/2022/761165s000lbl.pdf).

16. Interchangeable Biological Products. US FDA. Updated March 1, 2023. [www.fda.gov/biosimilars](https://www.fda.gov/biosimilars). Accessed July 9, 2023.

17. Bankhead C. Sticker shock: ophthalmic bevacizumab biosimilar could drive up costs. *MedPage Today.* Published August 1, 2023. [www.medpagetoday.com/meetingcoverage/asrs/105715#:~:text=The%20analysis%20showed%20that%20an%20would%20increase%20by%20about%2015%25](https://www.medpagetoday.com/meetingcoverage/asrs/105715#:~:text=The%20analysis%20showed%20that%20an%20would%20increase%20by%20about%2015%25). Accessed August 17, 2023.

18. Biosimilars approved in the US. Generics And Biosimilars Initiative. Updated May 19, 2023. [www.gabionline.net/biosimilars/general/biosimilars-approved-in-the-us](https://www.gabionline.net/biosimilars/general/biosimilars-approved-in-the-us). Accessed June 30, 2023.

19. Ranade S V, Wieland MR, Tam T, Rea JC, et al. The Port Delivery System with ranibizumab: a new paradigm for long-acting retinal drug delivery. *Drug Deliv.* 2022;29(1):1326-34.

20. Holekamp NM, Campochiaro PA, Chang MA, et al. Archway randomized phase 3 trial of the port delivery system with ranibizumab for neovascular age-related macular degeneration. *Ophthalmology.* 2022;129(3):295-307.

21. Hutton D, Charters L. Genentech recalling ranibizumab injection ocular implant in US. *Ophthalmology Times.* Published October 17, 2022. [www.opthalmologytimes.com/view/genentech-recalling-ranibizumab-injection-ocular-implant-in-us](https://www.opthalmologytimes.com/view/genentech-recalling-ranibizumab-injection-ocular-implant-in-us). Accessed July 9, 2023.

22. Patel P, Sheth V. New and innovative treatments for neovascular age-related macular degeneration (nAMD). *J Clin Med.* 2021;10(11).

23. Crago SM. FDA Gives Clearance of IND for SK0106, Skyline Therapeutics AAV gene therapy candidate for nAMD. *Modern Retina.* Published July 6, 2023. [www.modernretina.com/view/fda-gives-clearance-of-ind-for-sk0106-skyline-therapeutics-aaav-gene-therapy-candidate-for-namd](https://www.modernretina.com/view/fda-gives-clearance-of-ind-for-sk0106-skyline-therapeutics-aaav-gene-therapy-candidate-for-namd). Accessed July 9, 2023.

24. OTT166 in Diabetic Retinopathy (DR). *Clinicaltrials.gov.* Updated July 17, 2023. [classic.clinicaltrials.gov/ct2/show/NCT05409235](https://clinicaltrials.gov/ct2/show/NCT05409235). Accessed July 9, 2023.

25. Hutton D. Efficacy and safety results of the ZETA-1 Phase 2 trial in diabetic retinopathy at the 83rd Scientific Sessions of the ADA. *Modern Retina.* Published July 3, 2023. [www.modernretina.com/view/efficacy-and-safety-results-of-the-zeta-1-phase-2-trial-in-diabetic-retinopathy-at-the-83rd-scientific-sessions-of-the-ada](https://www.modernretina.com/view/efficacy-and-safety-results-of-the-zeta-1-phase-2-trial-in-diabetic-retinopathy-at-the-83rd-scientific-sessions-of-the-ada). Accessed July 9, 2023.

26. Syfovre Efficacy. Syfovre. [syfovreecp.com/oaks-and-derby-efficacy](https://syfovreecp.com/oaks-and-derby-efficacy). Accessed July 9, 2023.

27. Syfovre Safety. Syfovre. [syfovreecp.com/safety](https://syfovreecp.com/safety). Accessed July 9, 2023.

28. Apellis shares sink on reports of rare side effects with new vision loss drug. *Fidler B. Biopharma Dive.* Published July 17, 2023. [www.biopharmadive.com/news/apellis-syfovre-inflammation-side-effects-geographic-atrophy/687989](https://www.biopharmadive.com/news/apellis-syfovre-inflammation-side-effects-geographic-atrophy/687989). Accessed August 22, 2023.

29. Innovations for Tomorrow's Retinal Disease Patients: Therapeutic Pipeline. Iveric Bio. 2023. [ivericbio.com/our-science/#pipeline](https://ivericbio.com/our-science/#pipeline). Accessed July 9, 2023.

30. Maturi RK, Glassman AR, Liu D, et al. Effect of adding dexamethasone to continued ranibizumab treatment in patients with persistent diabetic macular edema: a DRCR network phase 2 randomized clinical trial. *JAMA Ophthalmol.* 2018;136(1):29-38.

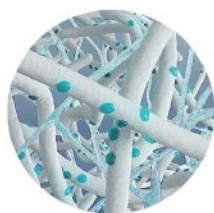


# ACUVUE® OASYS MAX 1-Day Lenses: Designed to Help Meet the Demands of Today

## Today's eyes demand more from a contact lens

If your patients are like most digital device users, their current contact lenses might not be able to handle today's new demands. With screen use up 35% since 2019,<sup>1</sup> their eyes may be impacted by 60% less blinking, which can compromise the tear film and cause discomfort.<sup>2,3</sup> Blue light—which is a shorter wavelength—scatters more, and blue-violet light scatter can impact visual clarity.<sup>4</sup>

ACUVUE® OASYS MAX 1-Day lenses with an unprecedented combination of two technologies<sup>5</sup>—TearStable™ Technology and OptiBlue™ Light Filter\*—are designed to help meet today's digital demands and help your patients navigate comfortably through their day.



### TearStable™ Technology

- Optimizes wetting agent distribution throughout the lens and on the surface<sup>5,6,7</sup>
- Prolongs tear film stability<sup>\*,5,6</sup>



### OptiBlue™ Light Filter\*

With the capability to filter 60% of blue light,<sup>\*,5,7</sup> ACUVUE® OASYS MAX 1-Day lenses offer the highest level blue-violet light filter in the industry.<sup>\*,5,7</sup>

## Meeting patient needs with ACUVUE® OASYS MAX 1-Day



Patricia  
Poma, OD



Whether on video calls, using digital devices at home or at work, or driving in the evening, my patients appreciate the ability of MAX lenses to filter blue-violet light,<sup>\*,5</sup>” said Patricia Poma, OD, who has been practicing in Michigan for the past 17 years.

With a combination of two technologies<sup>5</sup>—TearStable™ Technology and OptiBlue™ Light Filter\*—ACUVUE® OASYS MAX 1-Day lenses can help deliver the performance that today's patients expect. In a survey of 470 patients, 75% agreed they wanted more from their contact lenses, including increased comfort and clarity.<sup>8</sup>

\*Filtering of HEV light by contact lenses has not been demonstrated to confer any health benefit to the user, including but not limited to retinal protection, protection from cataract progression, reduced eye strain, improved contrast, improved acuity, reduced glare, improved low light vision, or improved circadian rhythm/sleep cycle. The Eye Care Professional should be consulted for more information.

\*More wearers achieved a visual tear break up time  $\geq 10$  seconds versus ACUVUE® OASYS 1-Day.

^Versus publicly available information for standard daily use contact lenses as of June 2023.

#### References:

1. Eyesafe estimate based upon Nielsen Q3 2019 Total Audience Report.
2. Tsubota K, Nakamori K. Dry eyes and video display terminals. *N Engl J Med.* 1993;328(8):584
3. Patel S, Henderson R, Bradley L, et al. Effect of visual display unit use on blink rate and tear stability. *Optom Vis Sci* 1991;68(11):888-89.
4. JJV Data on File 2022. Blue-Violet Filter Utilized in ACUVUE® OASYS MAX 1-Day contact lenses.
5. JJV Data on File 2022. TearStable™ Technology Definition.
6. JJV Data on File 2022. Effect on Tear Film and Evaluation of Visual Artifacts of ACUVUE® OASYS MAX 1-Day Family with TearStable™ Technology.
7. JJV Data on File 2022. Material Properties: 1-DAY ACUVUE® MOIST, 1-DAY ACUVUE® TruEye®, ACUVUE® OASYS 1-Day with HydraLuxe™ Technology and ACUVUE® OASYS MAX 1-Day with TearStable™ Technology. Brand Contact Lenses and other daily disposable contact lens brands.
8. JJV data on file, survey fielded to 468 contact lens wearing patients in the US in April 2022.
9. JJV Data on File, 2022. CSM Subjective Responses ACUVUE® OASYS MAX 1-Day Contact Lenses-Retrospective Meta-analysis.





Also Available in Multifocal



### Baley Petersen, OD

who has been practicing in South Carolina for the last decade has experienced this first-hand with patients asking about blue-light filtering contact lenses.



For my patients looking for lenses that can filter blue-violet light, whether that's my digital device users who are spending a lot of time on screens, or my patients working or playing outside, spending ample time out in the sun, I finally have a lens I can offer these patients—a lens with the highest level of blue-light filtering in the industry,<sup>\*\*5,7</sup> she said.

## Proven on-eye performance<sup>##9</sup> enables practice success

Dr. Petersen had a patient struggling so much with vision and comfort that he had given up on contact lenses entirely. "I told him the ACUVUE<sup>®</sup> OASYS MAX 1-Day lenses provide all-day comfort<sup>9</sup> and that he should give them a try," said Dr. Peterson. "Well, he's back wearing lenses again and says the ACUVUE<sup>®</sup> OASYS MAX 1-Day lenses are meeting his needs, allowing him to wear them comfortably all day.<sup>9</sup>

The ACUVUE<sup>®</sup> OASYS MAX 1-Day lens has made a real difference in my practice and for many of my patients. Offering patients innovative products only helps build stronger relationships with them and tells them you embrace the latest technology and understand their needs. This lens has been an absolute game changer in my practice and has put many of my patients who had given up on lenses back into them."

### Sean Coughlin, OD

who has been practicing for almost 20 years in Orlando, Florida, sees that his patients' lenses are drying out because his patients aren't blinking as they should when engaged with digital screens.<sup>2,3</sup>



ACUVUE<sup>®</sup> OASYS MAX 1-Day lenses utilize an unprecedented combination of technologies to help meet the demands of today's digitally intense lifestyle,<sup>5</sup> he said. "Now it's become my go-to lens for current and new contact lens wearers because it provides my patients with increased visual clarity and superior comfort.<sup>19</sup> As a result, this lens has been great for my patients, and ultimately great for my practice."

\*Filtering of HEV light by contact lenses has not been demonstrated to confer any health benefit to the user, including but not limited to retinal protection, protection from cataract progression, reduced eye strain, improved contrast, improved acuity, reduced glare, improved low light vision, or improved circadian rhythm/sleep cycle. The Eye Care Professional should be consulted for more information.

<sup>9</sup>Versus publicly available information for standard daily use contact lenses as of June 2023.

<sup>##</sup>Descriptive data from 4 clinical studies.

<sup>19</sup>Versus ACUVUE<sup>®</sup> OASYS 1-Day

# ACUVUE<sup>®</sup>

Scan to  
see the **MAX**  
difference



**Important safety information:** ACUVUE<sup>®</sup> Contact Lenses are indicated for vision correction. As with any contact lens, eye problems, including corneal ulcers, can develop. Some wearers may experience mild irritation, itching or discomfort. Lenses should not be prescribed if patients have any eye infection, or experience eye discomfort, excessive tearing, vision changes, redness or other eye problems. Consult the package insert for complete information. Complete information is also available from Johnson & Johnson Vision Care, Inc. by calling 1-800-843-2020, or by visiting [www.jnjvisionpro.com](http://www.jnjvisionpro.com).

# THE NEW KIDS ON THE BLOCK IN VISUAL FIELD TESTING

Move over, SAP machines—updated technologies available today provide a more accurate and clearer diagnosis in glaucoma and optic neuropathy.



BY ELYSE BANISTER, OD<sup>1</sup>, SHAUN BRENNAN, OD<sup>2</sup>,  
BRIAN FISHER, OD<sup>1</sup>, MICHELLE NGUYEN, OD<sup>4</sup> AND NIRMANI  
KARUNATHILAKE, OD<sup>1</sup>

<sup>1</sup>THE VILLAGES, FL; <sup>2</sup>TUSCON; <sup>3</sup>PHOENIX

In an era where new technology is quickly evolving, choosing the right visual field techniques and devices is essential for diagnosing and managing optic neuropathies. New algorithms within the Humphrey Visual Field Analyzer deserve a chance in the spotlight. Reducing patient chair time, clinical footprint and technician load while maintaining reliable results is crucial. Many glaucoma providers still prefer using the 24-2 or 10-2 SITA Standard, but there is a benefit to patients and schedules without sacrificing accuracy with the SITA Fast, Faster and 24-2C algorithms. Below, we will look at how the new SITA Faster differs from the SITA Fast. More importantly,

is the Humphrey (or Octopus) becoming obsolete? Virtual reality perimetry (VRP) may edge out the Humphrey in a head-to-head comparison, as it offers numerous advantages over our standard automated perimetry (SAP) machines.

## Humphrey Visual Field 24-2C

For many years, the Humphrey 24-2 has been the mainstay of optometric glaucoma care. Likewise, the 10-2 confirms early glaucomatous defects visualized structurally within the ganglion cell layer (GCL) when using OCT instruments that offer ganglion cell analysis, such as the ganglion cell analysis (GCA).

In recent years, the Humphrey 24-2C has been introduced and essentially marries the two tests together in one convenient package. Although the 10-2 continues to be the gold standard for detecting defects corresponding to a loss in the GCL, we often need to choose between the 24-2 and the 10-2 for time and billing purposes. The GCA scans can often show anomalous loss that

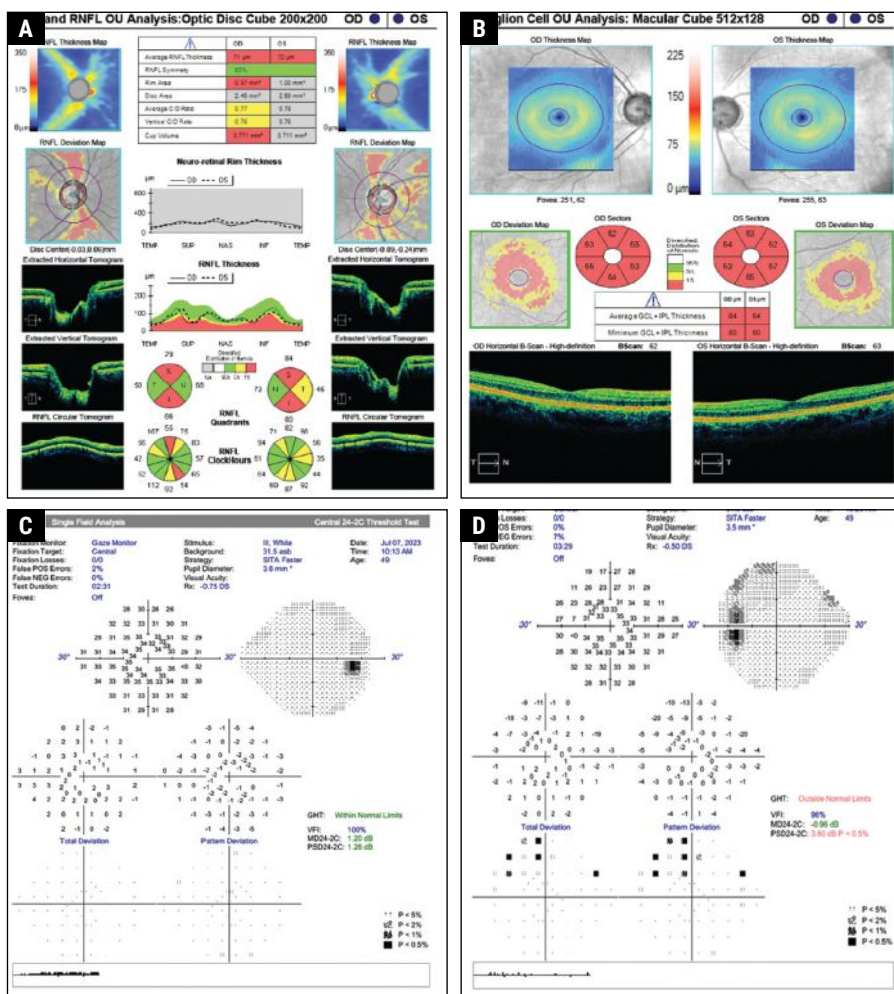
can be attributed to macular pathologies unrelated to glaucomatous changes. For those with an underlying macular disease, running a 10-2 based on an abnormal GCA can lead to false-positive glaucomatous centralized deficits. In this case, the 24-2C becomes advantageous, as it contains 10 extra data points within the central field that lie just outside areas where macular defects can occur. When performed reliably, the new 24-2C strategy becomes more useful than a standalone 24-2 or 10-2 for early glaucoma and optic neuropathy.

In a case study looking at the 10-2 vs. the 24-2C in optic neuropathies, there were no perceptible differences between the two—the 24-2C picked up the same defects as the 10-2.<sup>1</sup> In this patient, there is considerable loss of the retinal nerve fiber layer (RNFL) with polar thinning and a corresponding loss on the GCA in both eyes at the initial exam (*Figure 1*). However, when performing a baseline 24-2C SITA Faster, only the left eye was confirmed to have a

### About the authors

**Dr. Banister** is an optometrist at The Villages VA Outpatient Clinic in The Villages, FL. She is a graduate of Pennsylvania College of Optometry at Salus University and completed her residency at the Bay Pines VA Healthcare Center in Bay Pines, FL. **Dr. Brennan** is an optometrist at the Tucson VAMC and an adjunct clinical professor at Ohio State College of Optometry and Marshall B. Ketchum University. He received his undergraduate degree at the University of Utah and optometric degree at Western University College of Optometry. Dr. Brennan completed his residency at the Malcolm Randall VAMC in Gainesville, FL. **Dr. Fisher** is an optometrist and supervisor at The Villages VA Outpatient Clinic in The Villages, FL. He is a graduate of Midwestern University Arizona College of Optometry and completed his residency in primary care and low vision at the Lake City VA Medical Center in Lake City, FL. **Dr. Nguyen** is an optometrist at the Phoenix VA Healthcare System. She is a graduate of Midwestern University Arizona College of Optometry and completed her residency at the Malcolm Randall VAMC in Gainesville, FL. **Dr. Karunathilake** is an optometrist at the Lake City VAMC in Lake City, FL, where she serves as the residency coordinator and low vision clinic director. She maintains five adjunct faculty appointments at various colleges of optometry throughout the country. They have no financial disclosures.





**Fig. 1. A 49-year-old Caucasian male with no prior diagnosis of glaucoma or family history, IOP 17mm Hg OU with thinner than average pachymetry. (A) OCT RNFL shows an average thickness of 71µm OD and 70µm OS with superior and inferior thinning OU. (B) OCT GCA shows 360° of cell loss OU. (C) Baseline visual field 24-2C SITA Faster OD shows excellent reliability with no glaucomatous depressions. (D) Baseline field 24-2C SITA Faster OS shows excellent reliability and confirms a glaucomatous defect in the superior temporal quadrant forming an early arcuate with no central involvement despite abnormal GCA.**

glaucomatous defect that corresponded with the detected area of loss on ocular computed tomography. In this case, if one of the central data points showed up with a quantifiable depression, the next step could be to order a 10-2 at a follow-up exam, as the functional defects are not correlating to the structural defects in the right eye, despite testing reliability.

To further confirm the extent of central ganglion loss, a 10-2 can be performed but is not necessary, as it would not detect any additional glaucomatous defects that were not visualized on a 24-2C and will not alter the course of treatment.<sup>1</sup> A 24-2 SITA Fast would

likely correlate with the 24-2C superior temporal defect in OS (Figure 1C and D). However, a 24-2 SITA Fast is not able to test the central area for early glaucomatous defects within the GCL. In those with pre-perimetric or early-stage glaucoma, the 24-2C has shown to be as reliable as the 10-2 for initiating treatment based on a baseline field due to the improved reliability, while reducing the testing time and including central data points.<sup>2</sup> This means that we can reliably diagnose and initiate treatment almost three to six months sooner when using a 24-2C than when using a 24-2 as the baseline field.

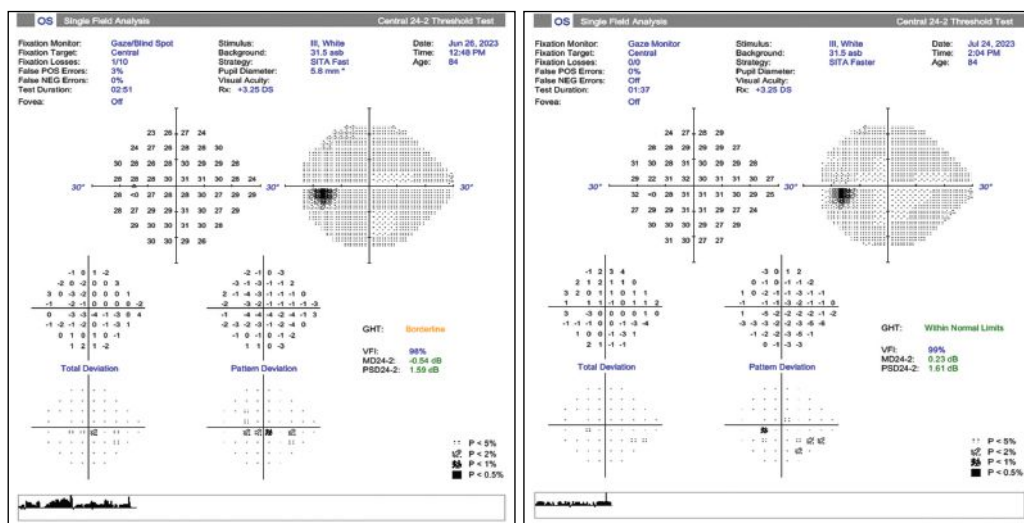
## SITA Fast vs. Faster 24-2

The SITA Standard has been the gold standard for glaucoma visual field testing since its introduction. To reduce patient fatigue, increase reliability and reduce chair time, the SITA Fast was later introduced. Much like how the SITA Standard replaced Full Threshold by reducing the testing time by 50%, the SITA Faster is intended to replace the SITA Fast.<sup>3</sup> SITA Fast has also replaced the Fastpac. Eventually, the only option that will be available for the 24-2 test will be the SITA Standard and the new SITA Faster.

To create the SITA Faster, several minor changes were made to the SITA Fast algorithm. Unlike the Full Threshold, SITA Standard and SITA Fast, which use a stimulus of 25dB in the first stimuli of each quadrant, the SITA Faster reduces the brightness to correlate with the patient's age.<sup>4</sup> Because of this, the number of stimuli presented to an older patient is reduced and results in a lower test duration. A patient with mild to moderate optic nerve disease will have an average test time of two minutes, while those with more advanced defects will be longer but less than a SITA Standard. The new algorithm uses the gaze tracker to check the blind spot rather than presenting stimuli. False-negative catch trials were eliminated.

The SITA Faster also saves time by eliminating the time between unseen stimuli, and it no longer retests areas of initial non-response.<sup>4</sup> However, these factors should be considered when testing those with conditions that would result in a limited reaction time.

In a study comparing the SITA Faster and SITA Fast with the SITA Standard, the only quantifiable difference observed was a small change in the false-positive rates.<sup>3</sup> The SITA Standard has slightly lower false-positive rates than both due to its positive start bias, which involves showing easier stimuli first to help promote a patient's willingness to engage positively with the test. In contrast, the SITA Fast and Faster are more likely to result in both eyes having equal reliability for interpretation than the Standard. This is in large part due to the observation



**Fig. 2.** Two examples of 24-2 visual fields of a patient with ocular hypertension *Left:* SITA Fast field shows good reliability with low fixations losses, low false-positives and a borderline glaucoma hemifield test. There is a small inferior central cluster defect questionable for early glaucoma. *Right:* One-month follow-up using SITA Faster shows no fixations losses, no false-positives and a glaucoma hemifield test within normal limits. The field does not confirm the previous central defect but reveals a shallow inferior nasal cluster defect.

that patients will usually do well on the first tested eye, only to become less reliable due to testing fatigue on the second eye when using SITA Standard.

Another study observed that SITA Fast and Standard gave similar results when compared with SITA Faster, finding that the visual field index between all three stayed the same, aiding the reliability, but concluded that the algorithms are not interchangeable for following advanced disease progression between examinations.<sup>5</sup> As a result, when comparing previously obtained SITA Fast results with the newer SITA Faster, we see that the testing time reduces by nearly 50% and the reliability of the test further improves with the Faster (*Figure 2*). However, the defects between the two fields are not comparable or repeatable despite being performed a month apart. The pattern standard deviation values are roughly the same, suggesting high reliability of the test taker.

Based on this example, we can see evidence to support one study’s observation that the SITA Faster tends to show a similar yet smaller-sized field deficits than the SITA Fast, suggesting the two testing modalities are likely not interchangeable for those with advanced glaucoma.<sup>4</sup>

SITA Faster is a viable option when testing glaucoma suspects up to moderate stages of glaucoma, but the SITA Standard should be used for those with more significant field loss. The Standard allows the patient more response time, which helps detect smaller changes in the field that may signal progression on current therapy. When paired with the 24-2C modality, the SITA Faster is a great option to screen those who have risk factors for glaucoma or are showing pre-perimetric thinning on nerve fiber analysis and/or ganglion cell analysis.

### Virtual Reality Perimetry vs. the Gold Standard (Humphrey)

The use of VRP in the detection of visual field defects was first introduced in 2018. During the COVID-19 pandemic, VRP gained significant traction in managing glaucoma patients due to its portability, convenience, lower entry price point and space-saving capabilities when compared with SAP.

Studies have shown that frequent field testing is essential in the detection and management of rapidly progressing individuals in the initial stages of glaucoma diagnosis.<sup>6</sup> One study recommended performing an average of six visual field tests within the first two years

of diagnosis to establish a baseline.<sup>7</sup> This follow-up schedule can be a burden to both the patient and clinic if performed using SAP. In these circumstances, VRP becomes an attractive testing modality for the patient and provider.

VRP uses head-mounted devices to administer fields to patients in-office and eventually in the convenience of their home. These devices provide more reliable and repeatable data compared with similarly used tablet-based visual fields for at-home testing, as the lighting and gaze tracking is more accurate.<sup>8</sup>

Numerous studies have shown VRP produces comparable results with high correlations to SAP testing when diagnosing and managing glaucoma patients.<sup>6,8-12</sup> A study evaluating the VisuAll (Oleyes) head-mounted perimetry device in glaucoma patients showed significant correlation in the mean sensitivity when compared to Humphrey Field Analyzer.<sup>9</sup> Another study evaluating the Advanced Vision Analyzer (Elisar Vision) head-mounted perimetry device showed similar threshold values to the HVF, suggesting high reliability for detecting defects.<sup>10</sup> A different study comparing the Vivid Vision Perimetry with the Humphrey Field Analyzer in those with open angle glaucoma and glaucoma suspects also compared favorably.

Other products on the market include the Smart System VR Headset (M&S Technologies) and VF2000 (Micro Medical Devices). The newest device is the Heru VR, which uses immersive augmented reality. According to a study comparing Heru’s visual field to SITA Standard, the Heru field results were repeatable and comparable with those obtained with SAP Humphrey.<sup>13,14</sup>

A similarity between all currently available VRP devices is their ability to export results to electronic health records systems using PDFs, making



Catch us at  
**VEW Booth #F10035**

**Marco #F11059 and  
Lombart #F6035**

# The future of visual testing is here.



## VisuALL VRP

We bring you unparalleled office efficiency, seamless integration, and the new era of patient comfort, in just one device.

### Dynamic Matrix

Our proprietary eye tracking algorithm can reduce fixation loss to zero.

### Meet Annie - your new virtual assistant

Annie can increase office efficiency, monitor patients, speak over 35+ languages and so much more.

One comprehensive efficiency tool that does it all, including testing for:



Pupillometry



Extraocular  
Motility



Visual Acuity



Visual Field



Color Vision



Contrast  
Sensitivity



Experience the  
future today.

 **olleyes**  
watch this

Exclusive Distributors



**LOMBART**  
YOUR OPHTHALMIC PARTNER

Scan code to know more or visit [www.olleyes.com](http://www.olleyes.com)



### The Emerging Role of AI in Optometry

Artificial intelligence (AI) is something both feared and embraced in society today. According to one study, roughly 64% of ODs are willing to incorporate AI into their practice.<sup>15</sup> The FDA has approved two autonomous AI systems that will impact optometry: LumineticsCore (formerly IDx-DR) by Digital Diagnostics and EyeArt by Eyenuk. Both aim to diagnose diabetic retinopathy, glaucoma and macular degeneration in the setting of a primary care visit rather than using an eye provider to further evaluate the images. As with any new technology, AI has its inherent benefits and limitations, and is only as good as the information that we feed it, as it

relies heavily on the internet database for diagnosis. AI will aid a provider in efficiency, but there are several retinal and optic neuropathy presentations that are red herrings of other systemic diseases that only a trained provider can piece together. Many VR perimeters use cloud-based AI-powered software.

As for the future of visual field testing, the iCare Compass combines visual field perimetry with retinal photographs. With this new technology, it is likely that one day soon AI may be able to reliably depict the visual field of a patient solely by retinal imaging. We should remain cognizant of optometric AI, as we do not want to make ourselves a target for replacement by advanced technology.

it easy to compare prior results from SAP to VRP. With any visual field test, the reliability of the patient is only part of the equation. Comparing subjective results to objective results is still reliant on the providers interpretation.

Despite the inherent advantages of VR technology, headset devices are not without their disadvantages. Most of the research studies currently available are preliminary in nature, sponsored by the developers of the devices and use small sample sizes.<sup>6-8</sup> Moreover, there are multiple VRP devices with different features and algorithms in the current market, making it more challenging to perform large-scale studies comparing these systems with each other, as well as with SAP. Another limitation to VRP is the observance of low sensitivity in screening for early glaucoma, though relatively high sensitivity is noted when screening those with moderate to severe glaucoma.<sup>8</sup> In time, large-scale prospective studies with progression analysis will be important to confidently validate the accuracy and reproducibility of VRP systems in comparison with SAP.

There are several benefits that outweigh any disadvantage to VRP that are not as easily recognized from the exterior of these petite technology-packed packages. An appealing aspect includes higher quality user experience compared to SAP, even though certain devices have longer test durations.<sup>8-10</sup> VRP allows patients to use more comfortable positioning when performing the test compared with SAP, where patients must maintain a stable head position throughout the duration of the test. Most VRP devices offer accurate

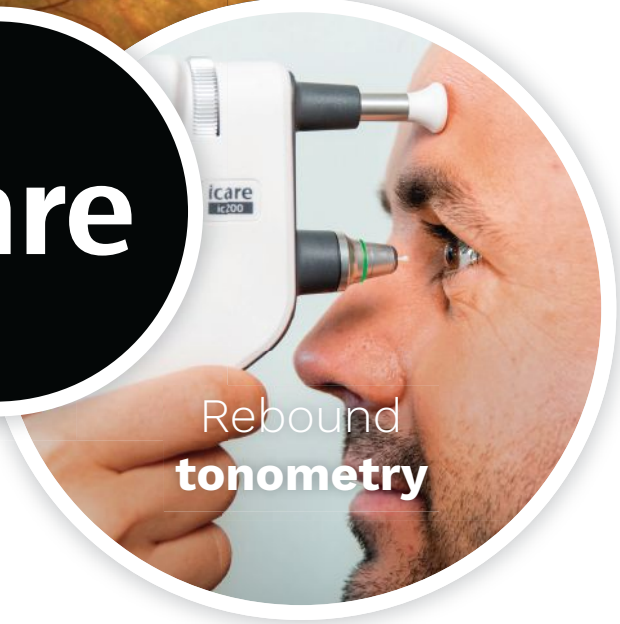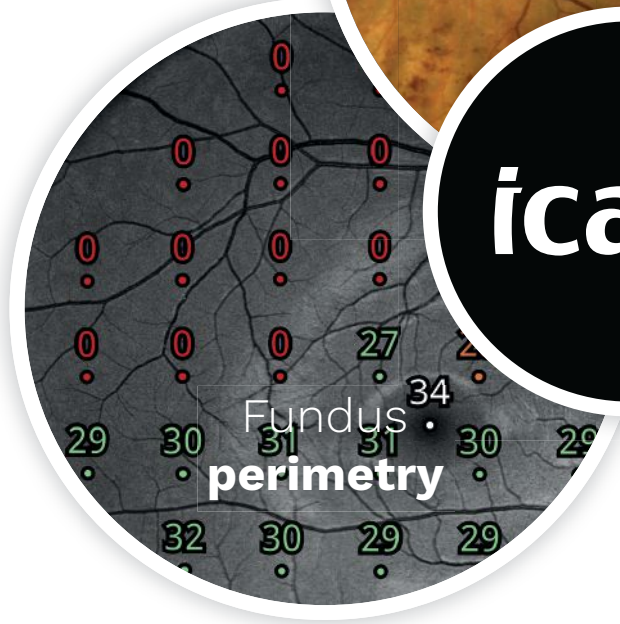
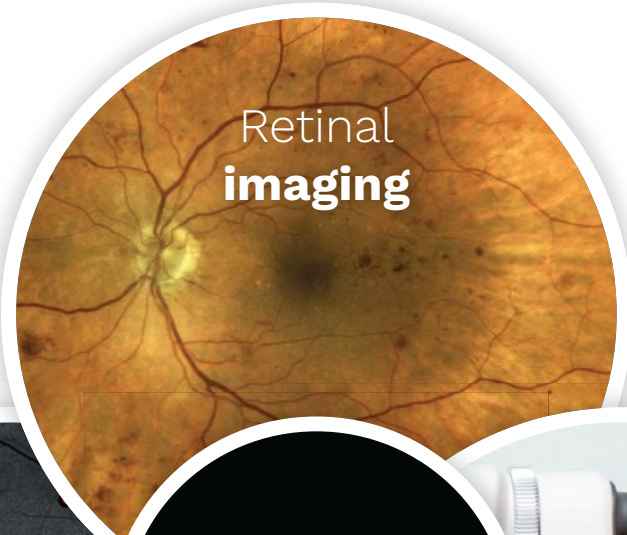
gaze tracking using infrared lighting and standard background illumination comparable to that of SAP, which can increase the reliability of the results.<sup>6,8</sup>

Headset perimetry is an excellent testing method for patients with a history of previously unreliable SAP results, particularly those who have physical limitations that were unable to be tested in the past. VRP can also reduce the clinical burden to practices by reducing technician monitoring time required for each patient when using SAP devices. These devices are also more portable and cost-effective compared to SAP. The average price found for currently available devices started around \$10,000, nearly half the cost of SAP. VRP is also ideal for mobile optometric clinicians who care for nonambulatory communities, such as those in nursing homes.

### Takeaways

When looking at current research, the 24-C SITA Faster has proven to be as reliable as the 10-2 for diagnosing early glaucomatous centralized deficits in the ganglion cell layer, but the 10-2 should still be used for monitoring those with advanced glaucoma. The SITA Fast or Faster technique is better for patients who have been unreliable on the SITA Standard, or have had a history of being unable to sit for the duration of the test. VRP shows promise for patients with compromised mobility, clinics with small footprints and mobile optometric physicians. Ultimately, it remains up to the provider to determine their own diagnostic comfort level with new field strategies and decide if a VRP device is beneficial to their mode of practice. ■

1. Yamane M, Odel J. Introducing the 24-2C visual field test in neuro-ophthalmology. *J Neuroophthalmol.* 2021;41(4):e606-11.
2. Chakravarti T, Moghadam M, Proudfoot JA, et al. Agreement between 10-2 and 24-2C visual field test protocols for detecting glaucomatous central visual field defects. *J Glaucoma.* 2021;30(6):e285-91.
3. Heijl A, Patella VM, Chong LX, et al. A New SITA perimetric threshold testing algorithm: construction and a multicenter clinical study. *Am J Ophthalmol.* 2019;198:154-65.
4. Qian CX, Chen Q, Cun Q, et al. Comparison of the SITA Faster-a new visual field strategy with SITA Fast strategy. *Int J Ophthalmol.* 2021;14(8):1185-91.
5. Thulasidas M, Patyal S. Comparison of 24-2 Faster, Fast and Standard Programs of Swedish interactive threshold algorithm of Humphrey Field Analyzer for perimetry in patients with manifest and suspect glaucoma. *J Glaucoma.* 2020;29(11):1070-6.
6. Prager AJ, Kang JM, Tanna AP. Advances in perimetry for glaucoma. *Curr Opin Ophthalmol.* 2021;32(2):92-7.
7. Chauhan BC, Garway-Heath DF, Goñi FJ, et al. Practical recommendations for measuring rates of visual field change in glaucoma. *Br J Ophthalmol.* 2008;92(4):569-73.
8. Ma MKI, Saha C, Poon SHL, et al. Virtual reality and augmented reality-emerging screening and diagnostic techniques in ophthalmology: a systematic review. *Surv Ophthalmol.* 2022;67(5):1516-30.
9. Razeghinejad R, Gonzalez-Garcia A, Myers JS, Katz LJ. Preliminary report on a novel virtual reality perimeter compared with standard automated perimetry. *J Glaucoma.* 2021;30(1):17-23.
10. Narang P, Agarwal A, Srinivasan M, Agarwal A. Advanced vision analyzer-virtual reality perimeter: device validation, functional correlation and comparison with Humphrey Field Analyzer. *Ophthalmol Sci.* 2021;1(2):100035.
11. Greenfield JA, Deiner M, Nguyen A, et al. Virtual reality oculokinetic perimetry test reproducibility and relationship to conventional perimetry and OCT. *Ophthalmol Sci.* 2021;2(1):100105.
12. Stapelfeldt J, Kucur SS, Huber N, et al. Virtual reality-based and conventional visual field examination comparison in healthy and glaucoma patients. *Transl Vis Sci Technol.* 2021;10(12):10.
13. Johnson C, Sayed A, McSoley J, et al. Comparison of visual field test measurements with a novel approach on a wearable headset to standard automated perimetry. *J Glaucoma.* 2023;32(8):647-57.
14. Video: Heru visual field app measurements show strong correlations to Humphrey analyzer. <https://www.healio.com/news/ophthalmology/20210506/video-heru-visual-field-app-measurements-show-strong-correlation-to-humphrey-analyzer>. May 8, 2021. Accessed August 24, 2023.
15. Scanzera AC, Shorter E, Kinnaird C, et al. Optometrists perspectives of artificial intelligence in eye care. *J Optom.* 2022;15 Suppl 1(Suppl 1):S91-7.



**You know us for tonometry.**  
**Get to know iCare for**  
**imaging and perimetry.**



Discover the next level of eye care  
with our full line of devices.

Scan or visit [www.icare-world.com/USA](http://www.icare-world.com/USA)



# REVEAL HIDDEN RETINAL DISEASE USING FAF IMAGING

This marker of metabolic activity lights up what's beneath the surface.



BY STEVE NJERU, OD, MS,  
AND DANIEL GRANGAARD, OD  
CHILLICOTHE, OH

**F**undus autofluorescence (FAF) was first described in the 1980s as a means to evaluate and monitor retinal metabolic function. Over time, this testing method has increasingly become important to better understand ocular diseases and the visual function of patients by providing information on the structure and function of the retinal pigment epithelium (RPE).

By exposing the natural fluorophores of the retina to blue or green light, FAF will cause an autofluorescence response that will appear as *hyper*fluorescence (an increased signal) or *hypo*fluorescence (a decreased signal). This noninvasive imaging method does not require an injection of a dye to take advantage of the autofluorescent qualities of ocular fluorophores to detect early changes and monitor for progression of retinal diseases.<sup>1</sup>

## Retinal Fluorescence

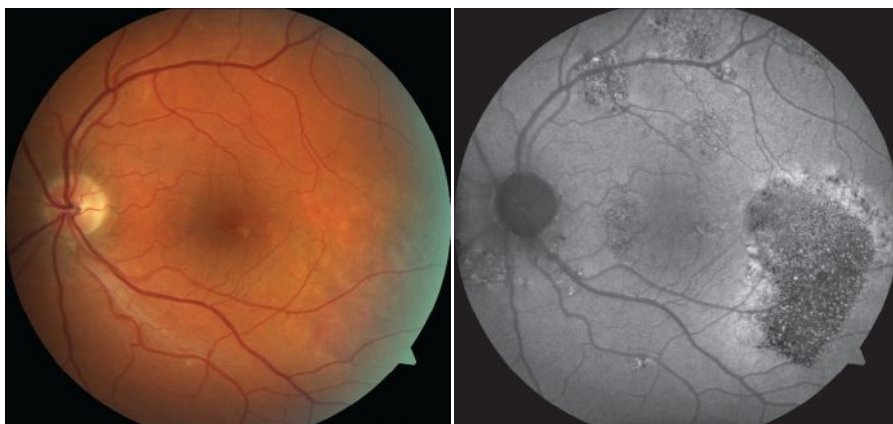Fluorophores are compounds that absorb light at a certain wavelength and release light in an excited state to become auto-

fluorescent.<sup>1</sup> There are several structures of the eye that have fluorophores, including the cornea, lens and retina; however, primarily what will be discussed in this article are those located in the RPE.

The most abundant ocular fluorophore in the retina is lipofuscin. It possesses a mixture of autofluorescent properties that are waste products capable of absorbing blue light at an excitation wavelength of 470nm.<sup>1</sup> These waste products are bisretinoid compounds formed in the outer segments of the photoreceptor as byproducts of the visual cycle. They are then deposited in the RPE to be

broken down.<sup>1</sup> However, in the presence of RPE dysfunction, from conditions such as Stargardt's disease or age-related macular degeneration (AMD), lipofuscin will accumulate and act as a marker for metabolic activity, providing an early indication for inherited retinal diseases or degeneration of the retina.

Melanin is another ocular fluorophore in the RPE that protects the retina from light-induced damage such as ultraviolet radiation.<sup>1</sup> The compound also acts as an antioxidant to protect against free radicals, photo-oxidation and even lipofuscin accumulation. Unlike lipofuscin, melanin



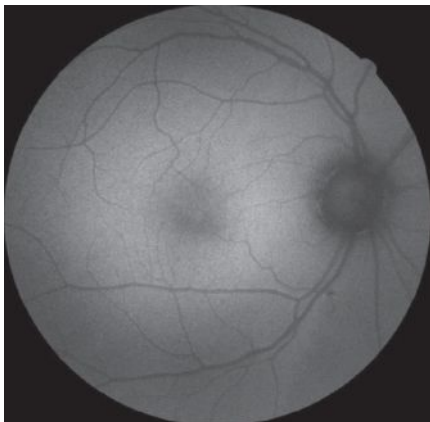FAF dramatically reveals clinical evidence of central serous chorioretinopathy in this case.

Photos: Anna Bedwell, OD, and Brad Sutton, OD

### About the authors

**Dr. Njeru** is a staff optometrist at the Chillicothe VA Medical Center. He graduated from the Ohio State University College of Optometry and completed his ocular disease residency at the Chillicothe and Columbus VA. **Dr. Grangaard** is staff optometrist and serves as the co-residency director at the Chillicothe VA Medical Center. He graduated from the Ohio State University College of Optometry and completed his ocular disease residency at the Chillicothe and Columbus VA. He is a fellow of the American Academy of Optometry and board-certified in medical optometry. They have no financial interests to disclose.





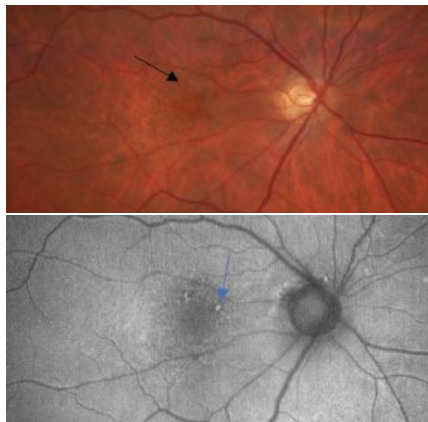**A normal FAF using blue light.**

has a higher peak of excitation at a longer wavelength of 787nm, so it absorbs the shorter wavelengths of blue (488nm) and green (514nm) light used by FAF and decreases the autofluorescent signal.

### Imaging Modalities

Confocal scanning laser ophthalmoscopy (cSLO) uses a system of mirrors to focus a low-powered laser beam to map the retina in a raster-like pattern.<sup>1</sup> It uses blue light excitation at a wavelength of 488nm. This generates autofluorescence while at the same time eliminates interference from scattered light due to other ocular structures like the crystalline lens, through confocal optics.<sup>1</sup> What's more, cSLO can capture multiple images and average the quality in real-time to produce high-contrast and high-resolution images. Challenges with using cSLO include a lack of ability to take color photos and the inability to perform testing after fluorescein angiography (FA) since both cSLO and FA use similar excitation wavelengths of 488nm.

Fundus photography is one of the most common imaging modalities due to its simple functionality and cost-effectiveness when compared with other diagnostic devices. The camera uses a single flash of light to capture color photos and autofluorescence through using both blue and green light at an excitation wavelength between 488nm and 585nm, depending on the imaging system and if a red-shifted wavelength filter is used.<sup>1</sup> With additional red-shifted wavelength filters, fundus photography can avoid scattered light from crystalline lenses



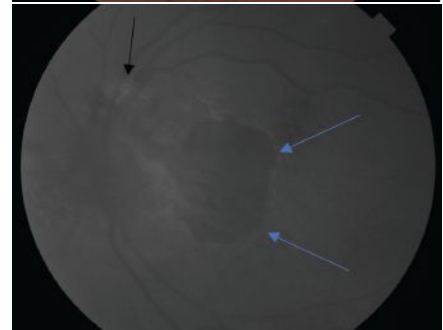
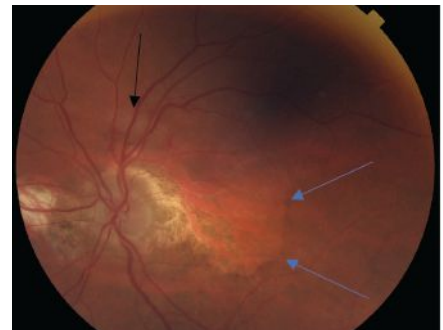
**At top, a color photo of early, dry AMD with a few small drusen (<63µm) and mild RPE changes as defined by the Age-Related Eye Disease Study (black arrow). At bottom, an FAF photo that shows small areas of hyperfluorescence and highlights the RPE changes caused by an increase of drusen (blue arrow).**

and decrease the absorption of the signal by the natural macular pigments.<sup>1</sup> Other advantages of fundus photography include better visualization of exudative retinal diseases, color imaging, enhanced comfort for the patient during testing and that it can still be performed before or after FA.<sup>1</sup> Disadvantages of this option include poor image quality if there is interference from media opacities without a red wavelength and a higher chance of pseudo-autofluorescence.

Ultrawide imaging, such as with an Optos, combines confocal scanning and an ellipsoid mirror to create a wide color image and/or FAF photo at up to 200° of view.<sup>1</sup> It uses either a 532nm or 633nm wavelength of excitation to capture the autofluorescent properties of the retina, providing a quick capture time, even with an undilated pupil.<sup>1</sup> Due to its wide field of view, there is better detection and evaluation for peripheral findings with FAF. The disadvantages include poor views of the superior and inferior retina due to lid and eyelash artifacts, as well as distortion at the peripheral retina due to the ellipsoid mirror.

### FAF Interpretation

A healthy FAF should demonstrate a diffuse hyperfluorescent signal because of the natural levels of lipofuscin in the



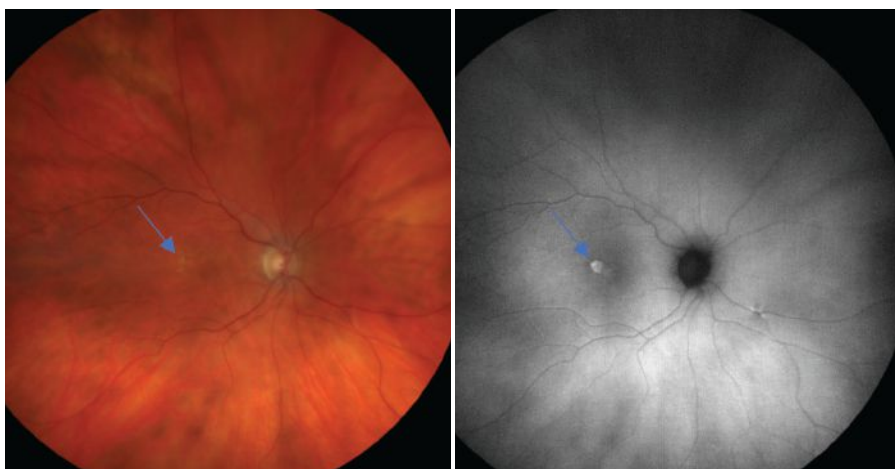**At top, a color photo of advanced AMD with extensive, central geographic atrophy (blue arrows) and a peripheral choroidal neovascular membrane located superiorly to the optic nerve (black arrow). At bottom, an FAF photo that shows an extensive amount of central hypofluorescence due to RPE loss and a small area of hyperfluorescence superior to the optic nerve caused by increased metabolic activity from the neovascular membrane.**

RPE cells, so the posterior pole may appear as a light gray. Depending on the excitation wavelength, the optic nerve will appear as a darker gray when using blue light or a lighter gray when using green light since it lacks RPE or lipofuscin. The fovea will appear as a hypofluorescent spot due to the high amounts of xanthophyll, which naturally absorbs light. Lastly, blood vessels will appear dark, since blood strongly absorbs wavelengths of green and blue light.

### FAF and Disease Detection

There are many retinal diseases that can be evaluated with FAF, which in turn can help clinicians better understand a patient's visual function and predict risk of progression. Below, we will describe a few retinal diseases that may be adequately monitored by using FAF.

**AMD.** One of the most common causes of permanent vision loss in those



On the left is a color photo of early AMD with a few soft drusen (~63µm), mild RPE changes (as defined by the Age-Related Eye Disease Study) and a new, elevated lesion temporal to the macula (blue arrow). On the right is an FAF photo that shows a significant amount of hyperfluorescence associated at the site of this new lesion, suggesting the presence of a choroidal neovascular membrane from increased metabolic activity.

over 65 is AMD, accounting for roughly 9% of all causes of blindness worldwide.<sup>2</sup> Described as either non-exudative or exudative, this AMD classification depends on the level of changes noted within the RPE and/or the presence of choroidal neovascularization.

Often, many patients during the early stages are asymptomatic but will slowly begin to notice central visual changes as the condition progresses over time. This is especially so in the presence of geographic atrophy as it encroaches into the fovea. In these cases, FAF can be used to map RPE loss and presence of retinal changes that can go unnoticed with funduscopy. An increase in the FAF signal, or hyperfluorescence, marks an area of abnormal metabolic activity from an excess amount of lipofuscin caused by RPE cell death. Conversely, a decrease in the FAF signal, or hypofluorescence, will indicate areas of cellular atrophy or a lack of lipofuscin. It can also be a sign of increased hyperpigmentation of the RPE or new hemorrhaging.

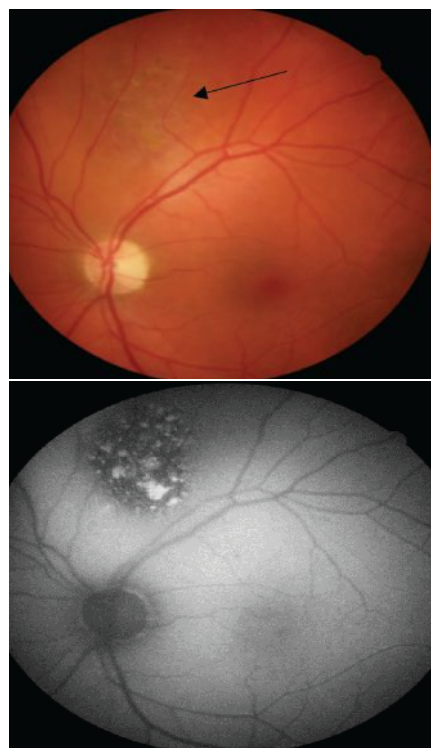Both autofluorescent qualities can be appreciated in retinal pathologies such as exudative AMD, which can cause an increase in hyperfluorescence from an abnormal amount of lipofuscin as well as leading to areas of hypofluorescence from exudative material and/or hemorrhaging. These can be used to predict the development of a choroidal neovascular

membrane.<sup>2</sup> However, unlike fluorescein angiography, FAF cannot be used to confirm the presence of a choroidal neovascular membrane.

**Choroidal lesion.** Choroidal melanomas are the most common type of intraocular tumors, but the risk for a nevus to convert to a malignant melanoma is low, at roughly 0.025%.<sup>3</sup> Although it is a rare condition, it can become both sight- and life-threatening. This malignancy of choroidal melanocytes leads to the destruction of the RPE and may lead to areas of overlying lipofuscin, atrophy and/or hyperpigmentation.<sup>3</sup>

There are six main risk factors for tumor growth: thickness (>2mm); subretinal fluid; symptoms of flashes, floaters and vision loss; orange pigment (lipofuscin); acoustic hollowness; and lesion diameter (>5mm).<sup>4</sup> In recent studies, FAF has proven to be an essential method for determining the presence of overlying lipofuscin, which relieves the pressure of clinicians having to rely on funduscopy views alone when monitoring for such an important risk factor.

In general, drusen are a hallmark sign for chronicity and increase the likelihood that the lesion is benign in nature, like a choroidal nevus. Presence of lipofuscin, by contrast, is a concern for a malignant lesion, as a lesion causes damage to the overlying RPE, compromising the ability of the RPE to remove excess lipofus-



The top color photo reveals a faint, elevated and non-pigmented choroidal lesion (black arrow) that has overlying pigment changes due to RPE changes. On the bottom, the FAF helps to showcase the level of increased metabolic activity with multiple focal areas of hyperfluorescence from an accumulation of lipofuscin and hypofluorescence from RPE atrophy.

cin. This in turn leads to an overlying lipofuscin accumulation. With FAF, both drusen and lipofuscin will cause hyperautofluorescence, but lipofuscin will show a much greater intensity. When evaluating an FAF of malignant lesions, clinicians will notice an overlying mix of autofluorescence, which may appear as a leopard-like pattern. This is caused by multiple focal areas of overlying lipofuscin and increased areas of hyperpigmentation or cellular atrophy from malfunction of the overlying RPE.

**Drug toxicity.** Hydroxychloroquine is an anti-inflammatory drug that has a risk of causing ocular toxicity. Likelihood of toxicity is increased with a cumulative dosage and long-term usage. Hydroxychloroquine toxicity leads to a loss of parafoveal photoreceptors with foveal sparing and permanent visual changes.<sup>1</sup>

This presentation will appear as a hyperfluorescent parafoveal ring from



# Got Mites?

Demodex Mites Live on the Eyelids!

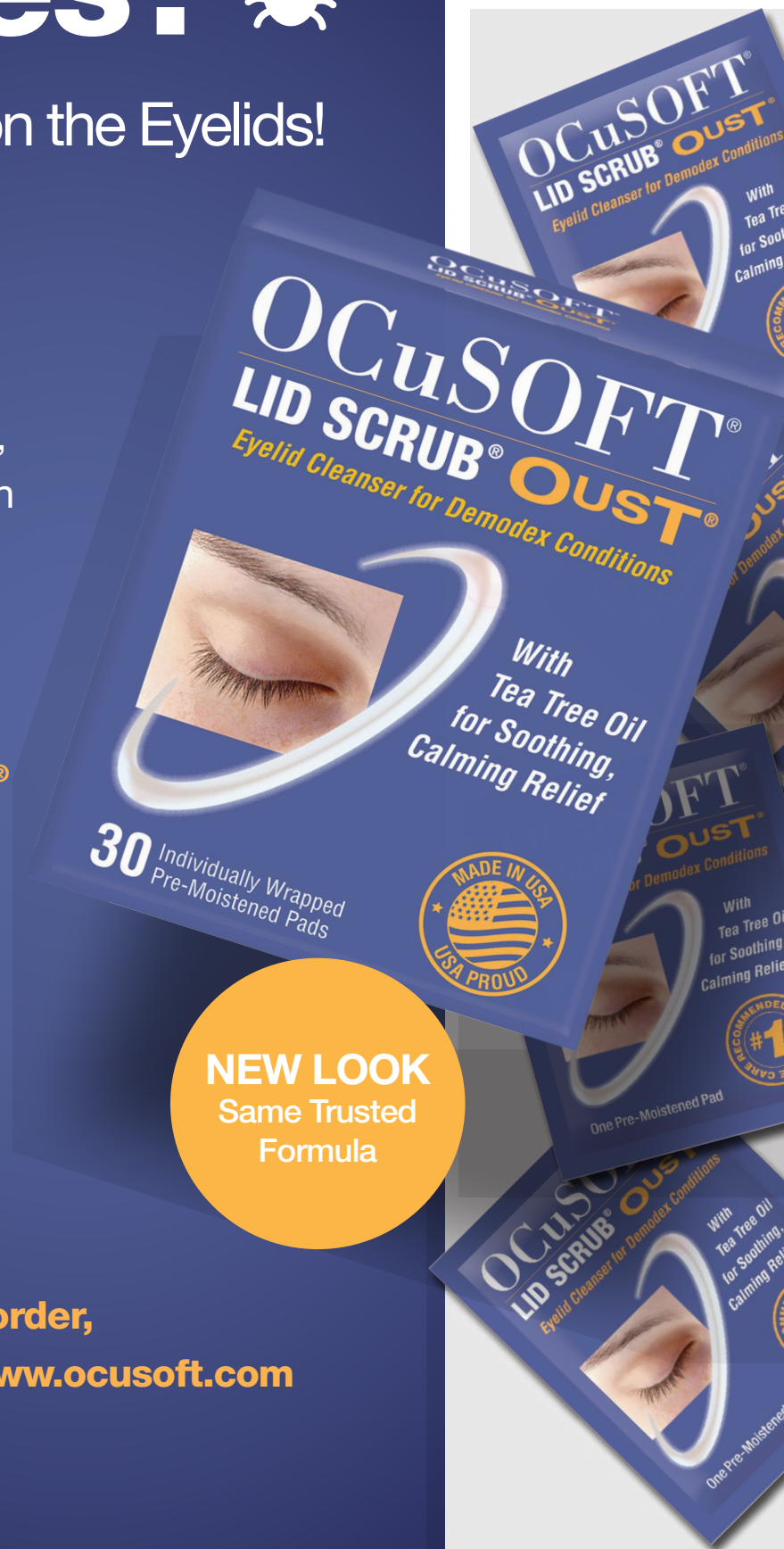**Demodex mites** are a part of our environment and live on our faces, usually without problems. When an overpopulation occurs, resulting eye/eyelid irritations can arise. OCuSOFT® Lid Scrub® Oust® effectively addresses these problems.

**OCuSOFT® Lid Scrub® Oust® Eyelid Cleanser is an extra strength cleanser** with tea tree oil that effectively relieves irritation from the eyelashes, eyelids, brow, and face. It also contains a moisturizer to help soothe eyelid discomfort.

**For more information and to order, call (800) 233-5469 or visit [www.ocusoft.com](http://www.ocusoft.com)**

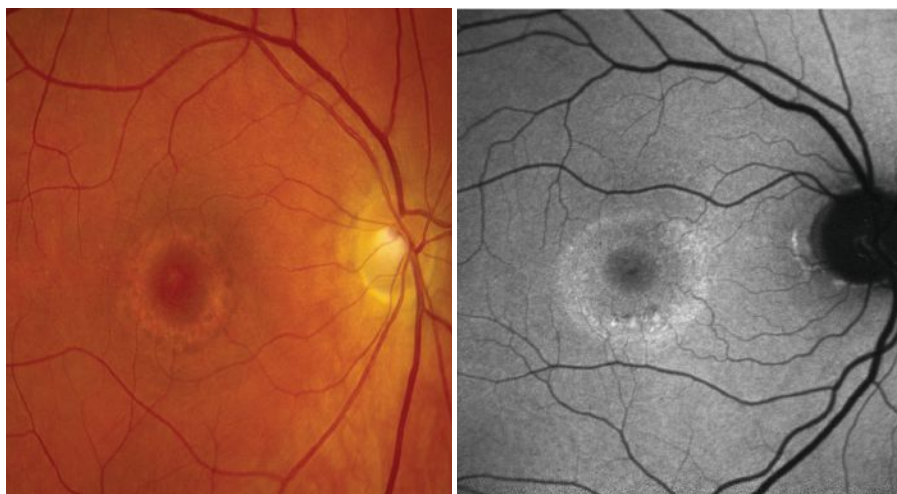**OCuSOFT®**

©2023 OCuSOFT Inc., Rosenberg, TX 77471



**NEW LOOK**  
Same Trusted  
Formula





**On the left, a color photo showing parafoveal pigmentary changes in a bull's eye pattern. On the right, FAF shows a large ring of hyperfluorescence surrounding the macula, indicative of active cell death.**

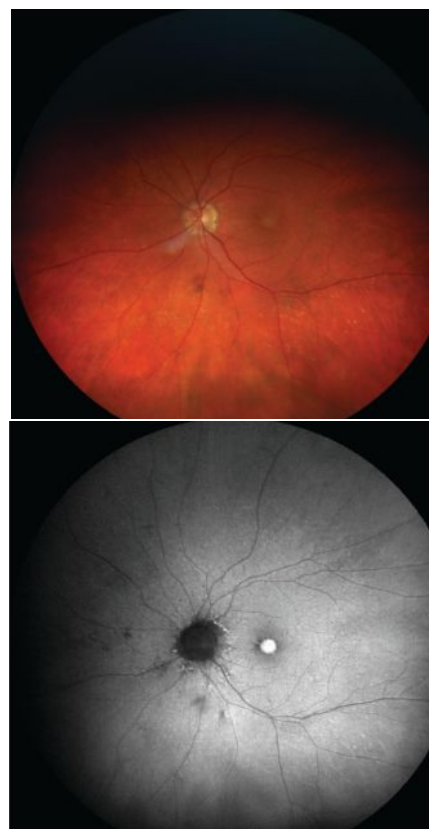photoreceptor damage in the early stages when viewed on FAF. Subsequently, the damage will cause a decrease in FAF signal from RPE cell loss if the medication is not stopped. This late stage is known as bull's eye maculopathy. Typically, additional testing such as FAF may be used per screening guidelines, since it has a sensitivity of about 73.7% when monitoring for hydroxychloroquine toxicity.<sup>1</sup>

**Pattern dystrophies.** This collection of late-onset macular dystrophies tend to be bilateral and symmetric. There are different subtypes, including adult-onset vitelliform dystrophy, butterfly pattern dystrophy, reticular dystrophy and fundus pulverulentus. These conditions are associated with an autosomal dominant mutation in the PRPH2 gene, which helps to code for a membrane glycoprotein on cone and rod photoreceptor outer segments.<sup>1</sup> This leads to yellow- or gray-like material that accumulates subretinally or at the level of the RPE that gives a hyperfluorescent response on FAF.<sup>1</sup>

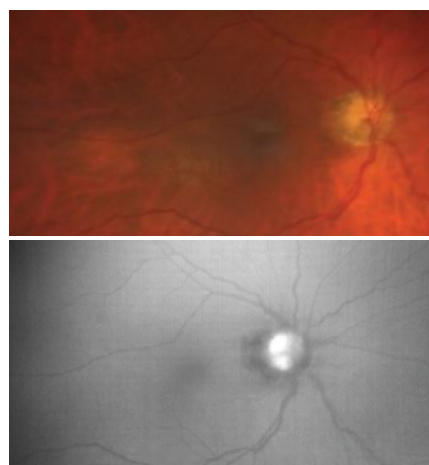
Adult-onset vitelliform dystrophy presents as bilateral subfoveal lesions that consist of outer segment debris because of RPE dysfunction. These vitelliform lesions represent a loss of apposition between photoreceptor tips, and the RPE and will appear egg yolk-like. The lesions cause an increase in the FAF signal during early stages but will become hypo-fluorescent over time, due to subsequent RPE atrophy.<sup>1</sup>

Other pattern dystrophies currently do not have as well-documented findings with autofluorescence, but FAF imaging has still been found useful in these conditions. For example, butterfly pattern dystrophy will appear as bilateral pigmented deposits in a butterfly-like shape with central RPE atrophy. When evaluated with FAF, this condition will show areas of hypofluorescence from the deposits and RPE loss causing hyperpigmentation, along with areas of hyperfluorescence caused by increased accumulation of lipofuscin.<sup>5</sup> Another pattern dystrophy—reticular dystrophy—will feature a network of pigment lines and knots in a fishnet-like pattern from RPE disruptions, but these lesions will typically fade away with age and lead to atrophic changes. With FAF, there will be increased areas of hypofluorescence from atrophy over time, surrounded by excess lipofuscin-induced areas of hyperfluorescence.<sup>5</sup>

**Optic nerve head drusen (ODD).** This is a benign and congenital condition of the optic nerve, identified by hyaline-like nodules that may be described as either buried or erupted drusen. These hyaline-like deposits develop because of an abnormal axonal metabolism and continue to change in size over time, hardening with age from calcification.<sup>6</sup> As the drusen become more superficial, and thus more visible, they have the ability to cause neural tissue loss



**On top, a color photo captures a large, central yellow-ish lesion consistent with the appearance of a vitelliform lesion. On the bottom, the FAF photo captures a large area of hyperfluorescence at the site of the lesion from highly concentrated lipofuscin.**



**The top color photo captures an optic nerve head with indistinct margins and is suspected for visible ODD. On the bottom, the FAF photo reveals multiple ODD as highlighted by the increased FAF signal overlying the optic nerve head.**

that can lead to visual field defects. In cases of buried drusen, FAF is unable



# Changing SIGHT Overnight.

Overnight Orthokeratology

1.

NCLE certified consultation experts to guide you through the entire fitting process

2.

Highly adjustable parameters with an online lens design calculator

3.

Dynamic Edge Profile™ delivers remarkable comfort

4.

Diameter & optic zone options for myopia management patients, along with standard Orthokeratology patients



Scan to learn more about REMLens®.

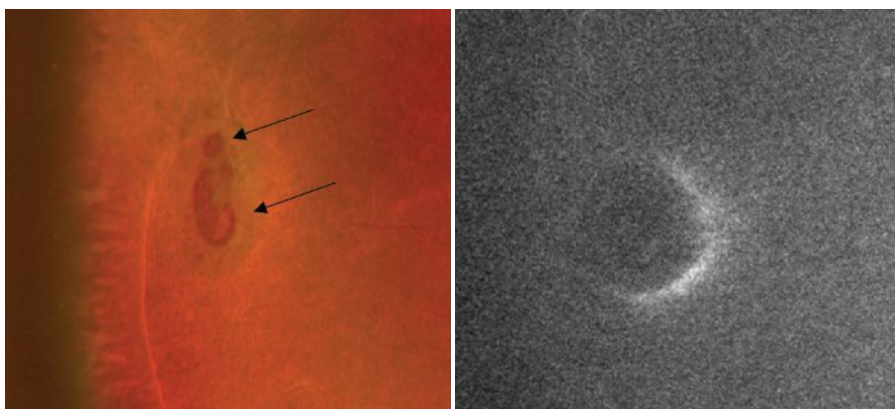


**X-CEL**  
SPECIALTY CONTACTS

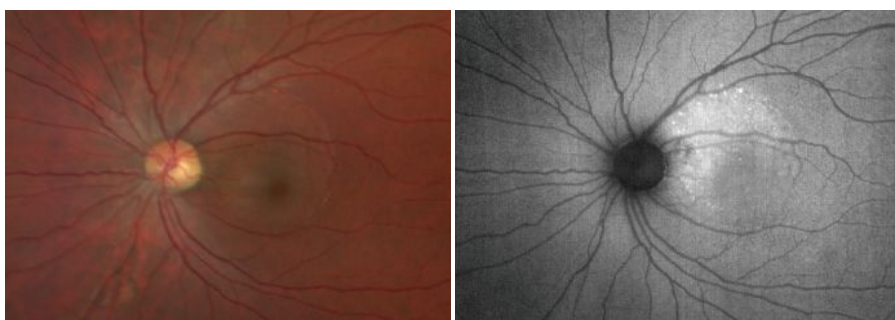
800.241.9312  
[xcel specialtycontacts.com/remlens](https://xcel specialtycontacts.com/remlens)

Vision Shaping  
Treatment VST®

MADE EXCLUSIVELY WITH  
BOSTON® EQUALENS® II  
LENS MATERIALS



The color photo on the left captures two atrophic holes that are suspected to have a cuff of fluid due to the elevated edges (black arrows). On the right, the FAF photo reveals a crescent-shaped area of hyperfluorescence anterior to the atrophic holes and confirms the presence of a cuff of edema.



On the left, the color photo captures a large, round area of edema that is consistent with CSCR. On the right, the FAF photo highlights an increased area of hyperfluorescence caused by photoreceptor debris from subretinal fluid accumulation.

to detect the structures due to overlying tissue, but as the drusen become more superficial, they will appear as round or oval-like hyperfluorescent lesions.<sup>7</sup> Therefore, FAF can be useful in monitoring for changes in ODD as patients age.

**Retinal breaks.** Described as holes or tears in the retina, retinal breaks are generally caused by aging or vitreal traction.<sup>6</sup> In both scenarios, FAF can monitor for the presence of fluid with retinal breaks, which is a factor considered to increase the risk for a retinal detachment. In cases where patients are asymptomatic but have an atrophic hole, FAF can help through characterizing the presence of a cuff of fluid, which will appear as a hyperfluorescent area near the edges of the hole caused by subretinal fluid. This additional information helps clinicians determine the level of urgency for referrals and prompt treatment with a retina specialist.

**Central serous chorioretinopathy (CSCR).** This is the fourth most common retinopathy, is caused by choroidal dysfunction and leads to fluid leakage from the RPE into the subretinal space, resulting in serous detachment.<sup>1</sup> During initial presentation, roughly 72% to 96% of cases present with an area of hypofluorescence on FAF, which corresponds to the focal leakage sites that would appear on FA.<sup>1</sup> As acute cases of CSCR resolve, FAF images will capture granular-like hyperfluorescence from photoreceptor debris, which accumulates in the subretinal space at the border of the serous detachment; this gives the appearance of hyperautofluorescent gravitational tracks. Chronic cases will instead most commonly present a teardrop-like appearance of hypofluorescence due to gravity, marking a sign of atrophy from RPE loss and previous history of subretinal fluid. This is commonly known as hypoautofluorescent atrophic gravitational tracks.<sup>1</sup>

## Takeaways

Common etiologies that can lead to an increased FAF signal or hyperfluorescence and subsequent accumulation of fluorophores include an accumulation of lipofuscin, subretinal autofluorescent material (such as vitelliform lesions), ODD and loss of macular photopigment and photoreceptor attenuation.

Hypofluorescence can be just as important on FAF, with common etiologies resulting in RPE loss or blockage causing a decreased FAF signal to occur. These are indicated by a decrease in the natural amount of retinal lipofuscin, the presence of naturally occurring macular pigments (such as xanthophyll), acute retinal hemorrhages, fibrosis or scar tissue and media opacities such as cataracts.

Lastly, FAF has been a valuable method of imaging to characterize the metabolic function of the retina. It is widely available on a variety of diagnostic machines, such as a fundus camera, ultrawide imaging and confocal scanning laser ophthalmoscopy. These options can easily be incorporated into a clinician's management of retinal pathology. Integrating FAF into your practice strategy can help you detect early changes and monitor for progression with a variety of retinal conditions. This is especially important when regarding preventative care and helping patients to better understand their vision changes as they relate to daily activities such as driving, reading, watching TV and their hobbies. Take that extra step and use FAF on your next eligible patient—you won't regret it! ■

1. Yung M, Klufas MA, Sarraf D. Clinical applications of fundus autofluorescence in retinal disease. *Int J Retin Vit.* 2016;2:12.

2. Stahl A. The diagnosis and treatment of age-related macular degeneration. *Dtsch Arztebl Int.* 2020;117(29-30):513-20.

3. Bindewald-Wittich A, Holz FG, Ach T, et al. Fundus autofluorescence imaging in patients with choroidal melanoma. *Cancers.* 2022;14(7):1809.

4. Shields CL, Dalvin LA, Ancona-Lezama D, et al. Choroidal nevus imaging features in 3,806 cases and risk factors for transformation into melanoma in 2,355 cases: the 2020 Taylor R. Smith and Victor T. Curtin Lecture. *Retina.* 2019;39(10):1840-51.

5. Ahmed H, Sierpina DI, Khasaeni L. Retinal pattern dystrophy. In: StatPearls [Internet]. Treasure Island (FL): StatPearls Publishing. Updated January 7, 2023.

6. Friedman NJ, Kaiser PK, Pineda II R. The Massachusetts Eye and Ear Infirmary illustrated manual of ophthalmology. 5th ed. St. Louis, MO: Elsevier. 2021.

7. Tuğcu B, Özdemir H. Imaging methods in the diagnosis of optic disc drusen. *Turk J Ophthalmol.* 2016;46(5):232-6.



UNCOVER MORE >

# MAP AND TRACK DRY AMD

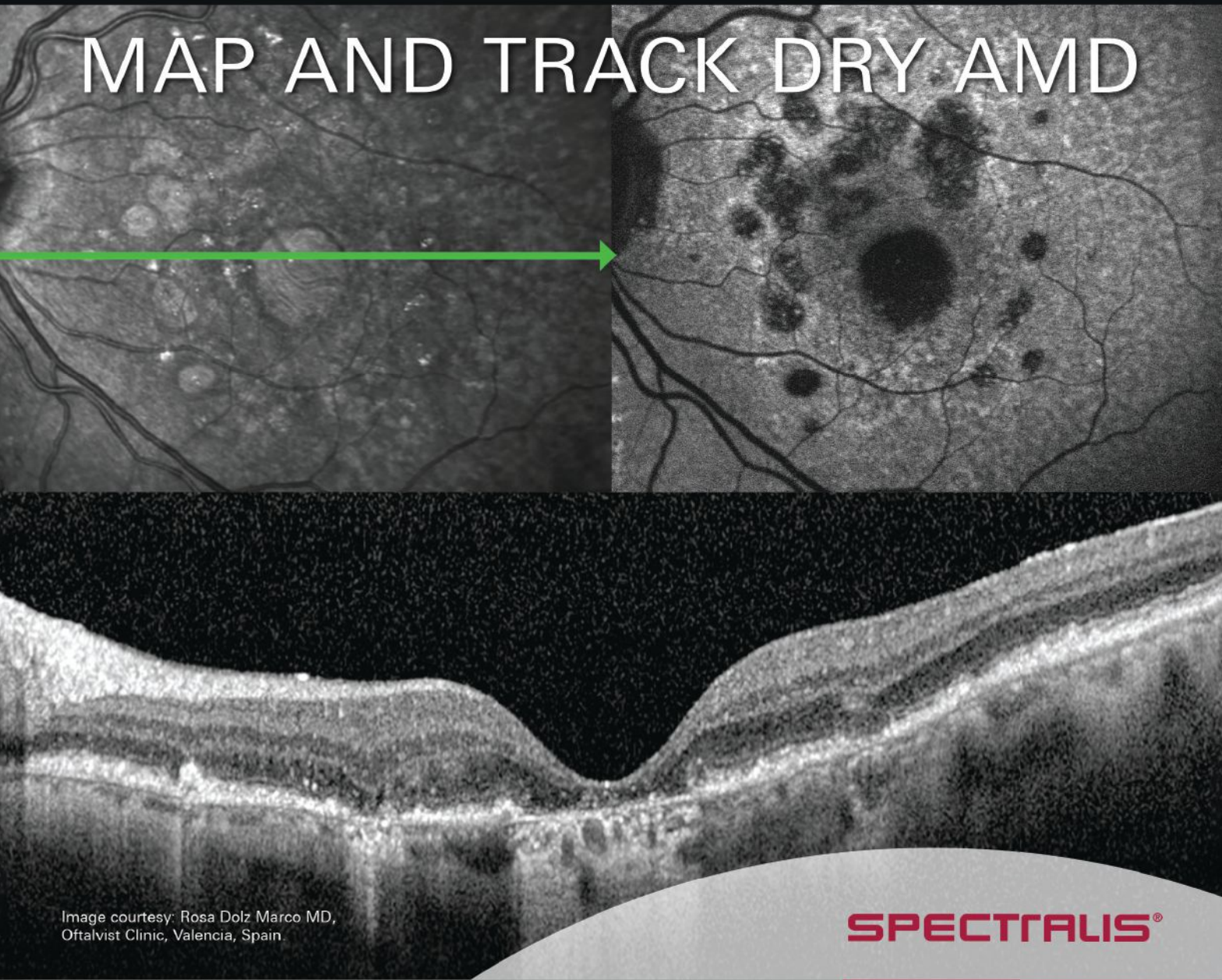


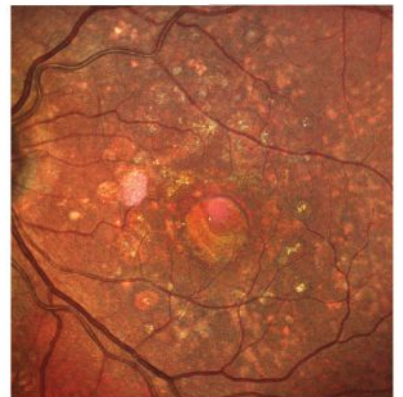
Image courtesy: Rosa Dolz Marco MD,  
Oftalvist Clinic, Valencia, Spain

**SPECTRALIS®**

## Emerging treatments for geographic atrophy demand advanced multimodal diagnostics

Quickly classify disease and monitor progression, by combining the metabolic insight of BluePeak autofluorescence, structural visualization of OCT, fundus imaging at different depths with MultiColor and fine vascular details of OCTA colocalized with TruTrack Active Eye Tracking. Map and track changes with SPECTRALIS®.

Visit us at VEW (#F13044) for a hands-on demonstration of SPECTRALIS.



> Uncover more: [www.SPECTRALIS-platform.com](http://www.SPECTRALIS-platform.com) | 800-931-2230

**HEIDELBERG  
ENGINEERING**

# ULTRA-WIDEFIELD IMAGING: EXPAND YOUR HORIZONS

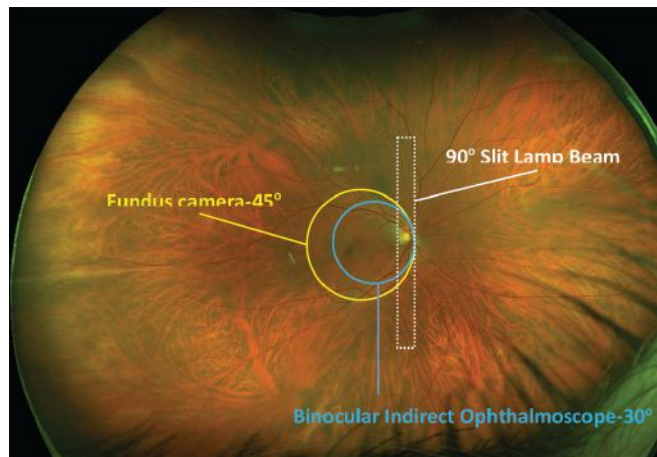
Several instruments are available today. Here, we guide you through the technologies to help you obtain optimal results for many common retinal conditions.



BY BRAD SUTTON, OD,  
AND JULIE TORBIT, OD  
INDIANAPOLIS

Retinal imaging has evolved significantly, from the first black and white picture of the retina captured in 1886 to 40 years later when the first commercially available camera was developed by Carl Zeiss in 1926 with a 20° field of view.<sup>1</sup> By the end of 20th century, retinal cameras could routinely capture a 45° image of the posterior pole; with montaging of multiple photographs, a 96° view of the fundus was possible (*Figure 1*).<sup>2</sup>

Today, modern widefield (WF) and ultra-widefield (UWF) imaging devices provide digital images that have the capability to capture over 200° of the retina. These cameras are very useful for screening, diagnosing and managing a wide array of retinal diseases. Many peripheral imaging systems now offer features such as color fundus photography, fluorescein angiography (FA), indocyanine green angiography, fundus autofluorescence (FAF) and spectral domain or swept-source OCT.



**Fig. 1. Comparisons of fields of view from different fundus imaging devices overlaid on an Optos photo.**

## UWF Imaging Definitions

These were formalized for various fundus imaging modalities in 2019 and are based on anatomic landmarks.<sup>3</sup> The posterior pole is defined as the central 50° of the retina, which extends just beyond the vascular arcades. WF photography is defined as images with a field of view of approximately 60° to 100°, capturing the mid-peripheral retina from the anterior aspect of the vascular arcades to the posterior edge of the vortex vein ampullae. UWF imaging captures the far peripheral fundus, which includes the retina from the anterior edge of the vortex vein ampulla to the pars plana with a 110° to 220° field of view (*Figure 2*). The term *panretinal* describes an

image that includes the entire retina to the ora serrata 360° around.

## Types of Cameras

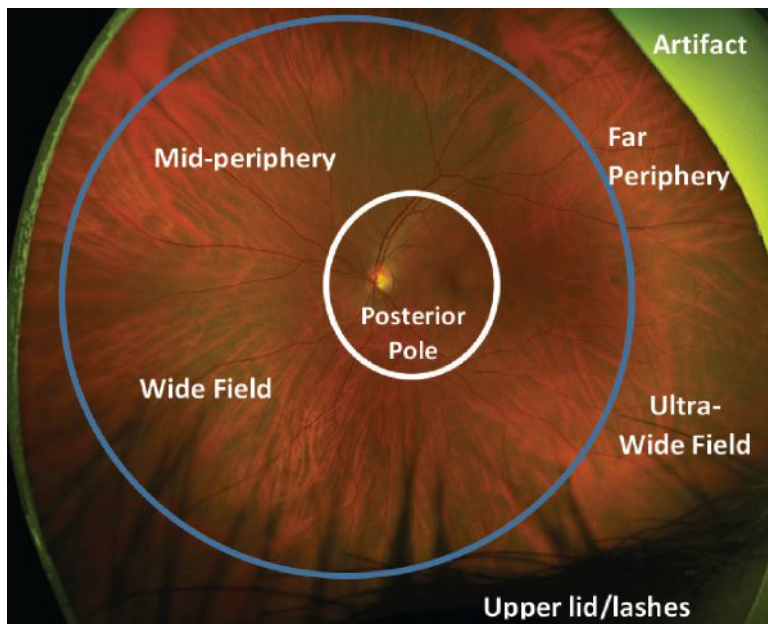
There are several widefield instruments currently in use, including the following: Optos (Optos), Heidelberg Spectralis, (Heidelberg Engineering), Clarus 700 (Carl Zeiss Meditec), Eidon (CenterVue) and RetCam (Clarity Medical Systems).

UWF imaging systems that use confocal laser ophthalmoscopy include Optos,

### About the authors

**Dr. Sutton** is a clinical professor at Indiana University School of Optometry and Service Chief of the Indianapolis Eye Care Center. He is a Fellow of the American Academy of Optometry, the Optometric Retina Society and the Optometric Glaucoma Society, as well as a member of the American Optometric Association. **Dr. Torbit** is an associate clinical professor at Indiana University School of Optometry. She is a Fellow of the American Academy of Optometry, the Optometric Retina Society and the Optometric Glaucoma Society. They have no financial disclosures.





**Fig. 2. Defining widefield and ultra-widefield on an Optos photo. The white circle represents the posterior pole of the fundus. The retina inside the blue circle represents widefield imaging and mid peripheral retina. The retina outside the blue circle represents ultra-widefield imaging and the far periphery.**

Heidelberg Spectralis and Eidon. Optos combines a confocal scanning laser ophthalmoscope (cSLO) with an ellipsoid mirror and is capable of capturing 200° images (approximately 82%) of the retina in less than half a second with 11µm to 14µm/pixel resolution.<sup>1</sup> Using the auto-montage feature on the machine, which combines up, down, left and right gaze steered images, Optos can photograph 220° (approximately 97%) of the retina.<sup>4</sup> Optos uses low-powered red and green lasers to produce pseudocolor images, blue laser for FA, green laser for FAF and infrared laser for indocyanine green angiography.

Heidelberg Spectralis also uses cSLO imaging and is capable of taking UWF photos with a resolution of 10µm/pixel.<sup>1</sup> The Heidelberg system can take non-contact images up to 105° (with the HRA 2 model) with considerably less lash artifacts compared to Optos. With the addition of a contact Staurenghi lens (Ocular Staurenghi 230 SLO Retina Lens, Ocular Instruments), the Heidelberg system can produce a 150° image of the retina.

The main disadvantages of an imaging system that requires contact with the ocular surface are the need for a skilled photographer and a highly cooperative patient. The Eidon system uses cSLO and white LED light to take a 90° true color photo in a single capture and can image up to 160° with a montage of multiple photographs.<sup>5</sup>

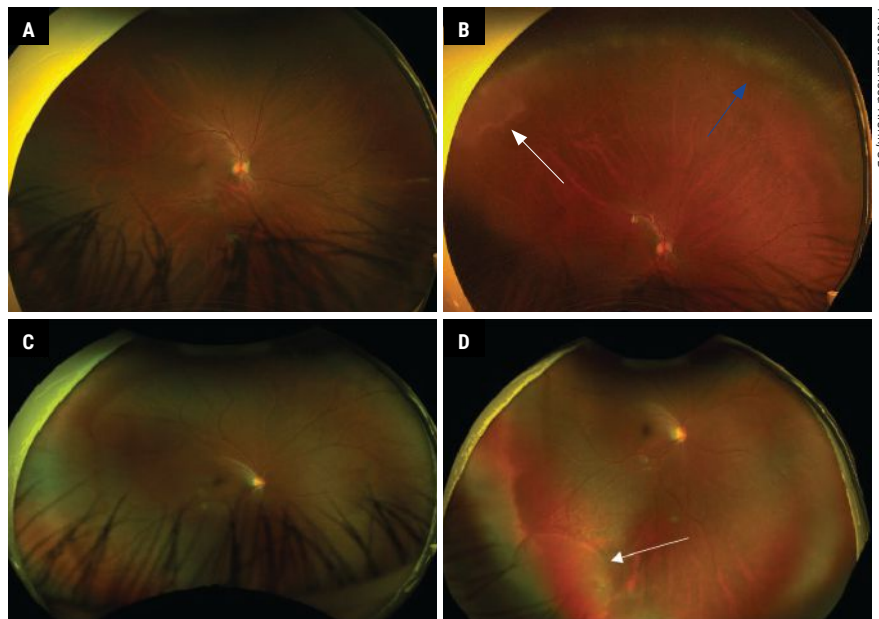
Other ultrawide imaging systems available are the Clarus 700 and RetCam. Clarus is a non-contact camera with partially confocal optics that reduces lash and lid artifacts. This camera provides true color images with a resolution of 7µm/pixel, capturing 133° in a single image and 200° with two combined images.<sup>1</sup> RetCam also has a similar 130° field of view and is most commonly used in the pediatric population. It's portable and can take images in the supine position, which is advantageous for newborns and bedridden adults, but does require dilation.

### Avoiding Artifacts

Proper patient and camera positioning is key to capturing any good quality retinal image. Far peripheral lesions can be difficult to image, even for experienced ophthalmic photographers. Having the patient look in the direction of the lesion and using the “steering” feature on the camera (if available) often allows for the peripheral lesion to come into view and will provide an improved quality photo (Figure 3). It may also be helpful to have the clinician present when taking a peripheral image to

help the technician locate the area in question.

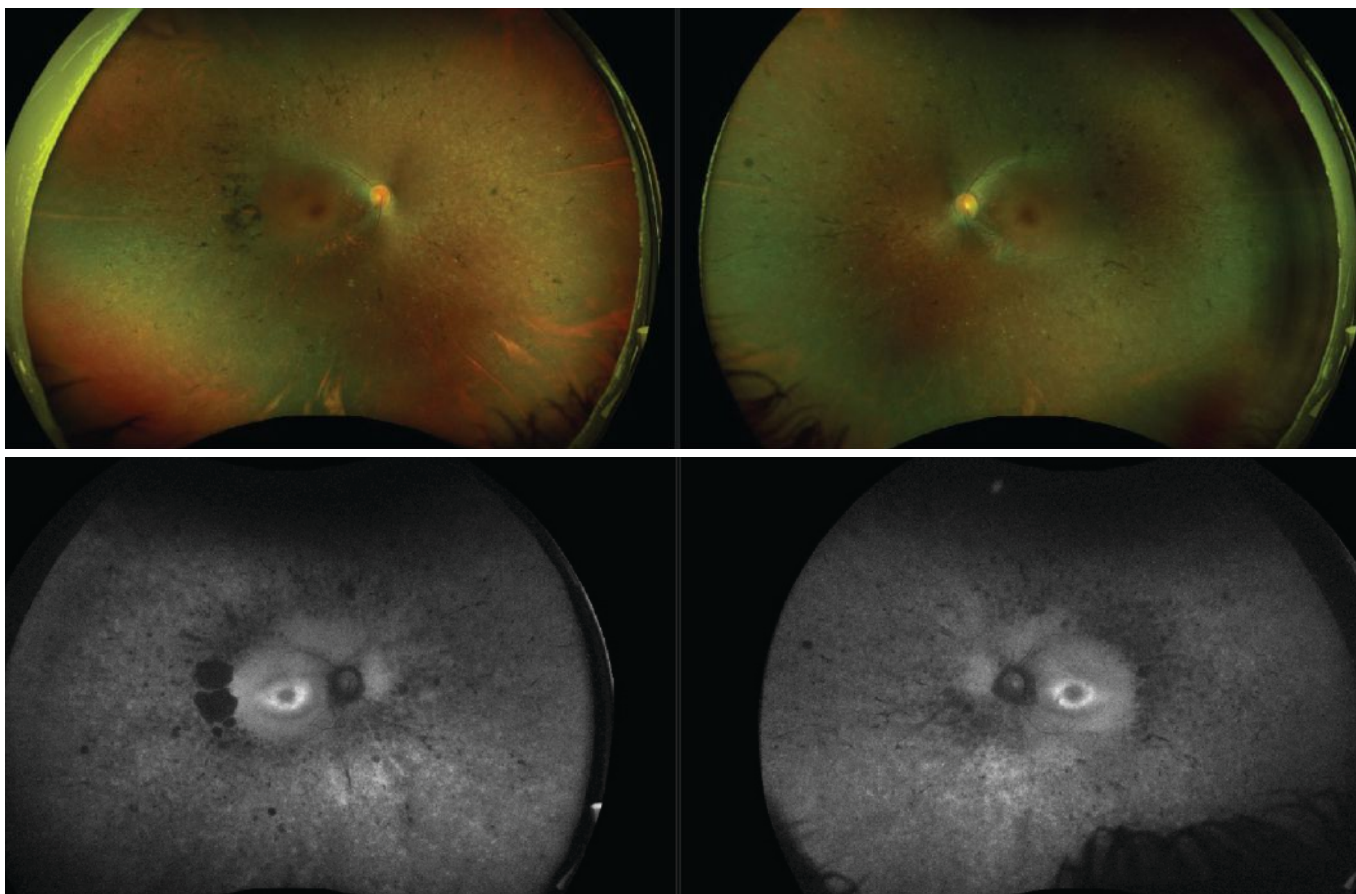
The patient can also help align themselves for optimal results by moving their head in or out depending on the location and/or the color of the target that they see in the instrument. Common artifacts in UWF imaging occur from the eyelashes, eyelids and nose. To minimize the amount of



**Fig. 3. (A) Normal-appearing Optos fundus photo in straight-ahead gaze. (B) Steered photo of patient A, looking up to reveal peripheral cystoid degeneration (blue arrow) and white without pressure (white arrow). (C) Normal-appearing Optos fundus photo in straight-ahead gaze. (D) Steered photo of patient C, looking down and out to reveal a shallow inferior temporal retinal detachment (white arrow).**

Photos: Larissa Kreinik, OD





**Fig. 4. Color Optos photos of retinitis pigmentosa (top). FAF Optos images of the same patient (bottom).**

lid and lash artifacts in an image, ask the patient to open their eye as wide as possible. Lifting the patient’s eyebrow or raising the height of the table may also reduce upper eyelid artifacts that appear at the bottom of the photo. With some imaging systems, such as the Optos, the patient’s head needs to be turned so that the nose remains out of the picture.

Often, it is helpful to tell the patient to position their head as if they were looking through a keyhole in a door, as poor head positioning can lead to a bright reflex of light that can be mistaken for a retinal lesion. Vitreous floaters often cast shadows that masquerade as dark lesions on the retina, mimicking conditions such as blood or a choroidal nevus. Examining additional UWF images of a presumed lesion for a change in position on the retina is beneficial in identifying such an anomaly. As with any potential artifact found on photography, suspicious findings should be confirmed with a dilated eye exam.

### **UWF Imaging vs. Dilation**

While WF imaging has come a long way, there are no retinal imaging systems currently capable of taking a panretinal photograph and capturing an image of the entire retina in a single click of a button. Therefore, UWF imaging does not replace a dilated fundus exam, but can certainly enhance the ability to locate and document retinal abnormalities. Small

lesions that are seen with binocular indirect ophthalmoscopy can be photographed and then digitally magnified to aid in differential diagnosis.

Advantages to UWF imaging are that it is safe, fast, painless and does not require mydriasis. However, it can miss subtle retinal pathology, especially beyond 200° in the far periphery. Pseudo coloration and magnification distortions of images can allow retinal findings to go undiagnosed in the absence of a dilated fundus exam. Imaging systems that use cSLO technology combine monochromatic red and green light rather than full color spectrum white light. The two-tone, semi-realistic coloration of the fundus produced by scanning ophthalmoscopes makes detecting subtle retinal changes more difficult.

Magnification distortions occur when a three-dimensional image is placed onto a two-dimensional flat surface. Projecting a curved surface like the retina onto a flat screen can lead to peripheral lesions appearing larger than if they were located more centrally. An example of this phenomenon would be how a two-dimensional map representing our three-dimensional world distorts the size of land masses near the poles, known as the “Greenland effect.”<sup>6</sup> Fortunately, there is stereoscopic projection software incorporated into some UWF imaging systems that attempts to remedy these peripheral distortions.<sup>1,2</sup>

## Screening Tool

UWF imaging lends itself well to telemedicine, as it can be an effective tool for in-office or off-site screenings by aiding in the detection of retinal disease in high-risk populations such as diabetic retinopathy (DR) or retinopathy of prematurity. UWF cameras can provide quick, comfortable and convenient high-resolution images, even in those patients who dilate poorly, resist dilation or have medial opacities.<sup>6</sup>

Some doctors have UWF images taken in-office prior to examining the patient, which allows them to be more precise and effective with their dilated retinal examinations. Other practices offer retinal imaging and detailed evaluation of those images as a screening prior to the patient being seen for a dilated eye exam. Clinicians have found that these screening images aid in patient education. Patients also appreciate having their fundus photos sent directly to them electronically via Bluetooth on their phone or later via e-mail.<sup>7</sup>

An out-of-pocket fee is charged for these services, thus enhancing practice revenue. Medically necessary UWF photos to document retinal pathology are billable to insurance with a written physician's order and associated ICD-10 diagnosis using the standard 99250 fundus photography code.

## Diagnosis and Management of Disease

UWF imaging has led to a better understanding of the peripheral retina and its role in a wide array of retinal vascular conditions and inherited retinal diseases. With inherited retinal diseases, UWF imaging is excellent for documenting the level of involvement in nearly the entire retina. In these patients, UWF-FAF can be invaluable in helping to differentially diagnose various disorders (*Figure 4*).

Retinal conditions with areas of peripheral capillary nonperfusion such as diabetic retinopathy, retinal vein occlusion (RVO), sickle cell retinopathy and ocular ischemic syndrome can be more effectively diagnosed and managed with UWF images, particularly incorporating UWF angiography.<sup>2,6</sup> UWF imaging can also be very helpful in diagnosing posterior uveitis, retinal vasculitis and posterior ocular tumors. Research also continues to study the clinical significance of the peripheral retina in macular conditions such as age-related macular degeneration and edema associated with DR and RVO.

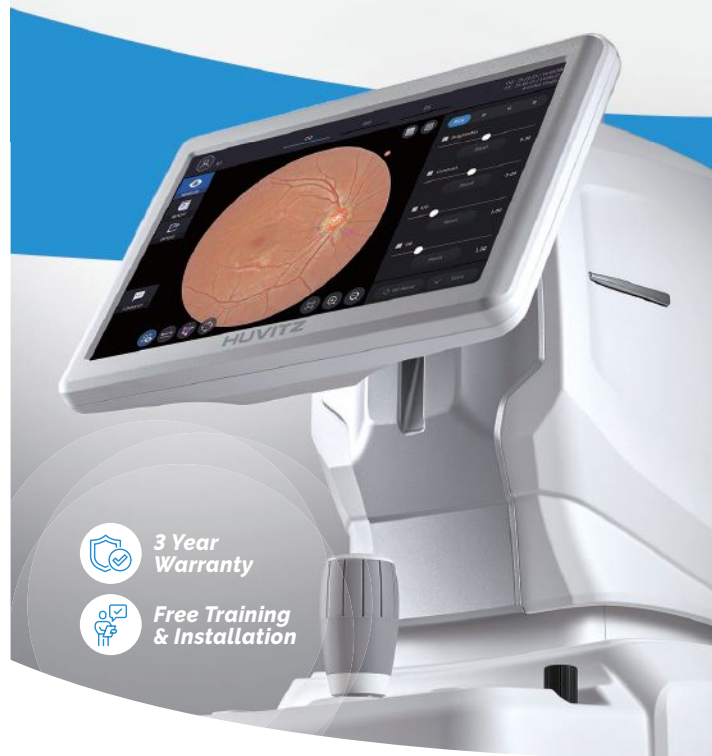## Diabetic Retinopathy

Traditional diagnosis, classification and management of DR has centered on vascular changes seen in the posterior pole, not fully considering the role peripheral nonperfusion and ischemia play in the overall progression of the disease. The gold standard for the assessment and grading of DR severity has been the seven-standard field (SSF) photographs as defined by the Early Treatment Diabetic Retinopathy Study (ETDRS). However, SSF imaging can only capture about 75° of the fundus with a montage of seven 30° photos,

# High quality, automatic digital retinal imaging.

Experience the  
**HFC-1 Non-Mydriatic Fundus Camera.**

- Quick and stable auto tracking and auto shooting
- Adjust fixation target position
- Enhanced Visualization Technology captures fine pathological variation
- Full color digital image acquisition

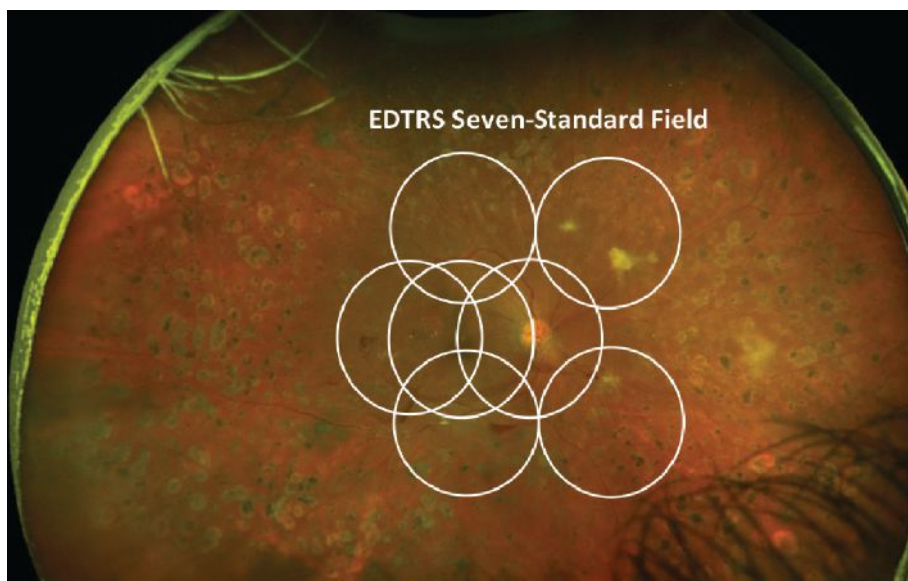


**COBURN  
TECHNOLOGIES** 

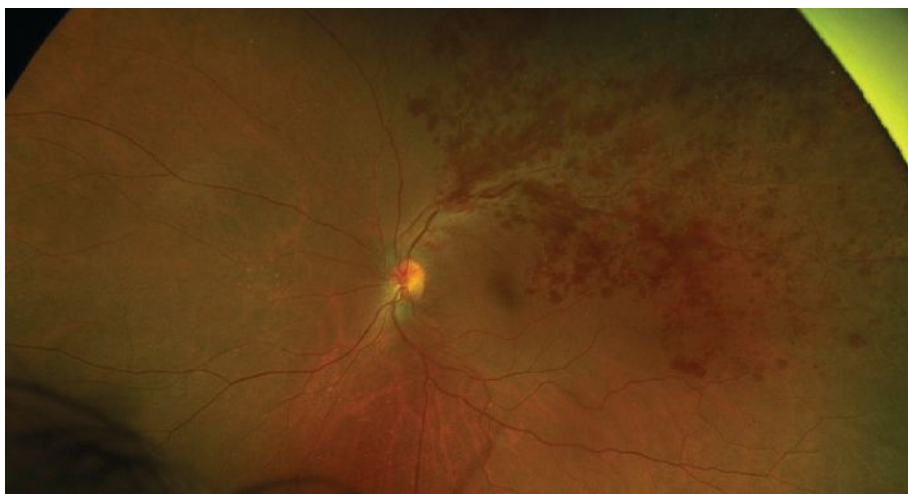
1-800-COBURN-1  
See our full line of products  
at [coburntechnologies.com](http://coburntechnologies.com)

  
**VISION  
EXPO**  
Booth F6065





**Fig. 5.** EDTRS seven-standard field images laid over an Optos proliferative diabetic retinopathy photograph.



**Fig. 6.** Optos photo of a large branch retinal vein occlusion.

which encompasses approximately 34% of the retina (*Figure 5*).<sup>2,6</sup> By contrast, UWF imaging can capture over 80% of the retina and better assess the full extent of nonperfusion.

UWF has been found to be at least as sensitive (84% to 94%) and specific (90% to 100%) as the ETDRS SSF montage images for screening and staging DR.<sup>6,8-10</sup> In fact, studies show that 40% of DR-related changes occur outside the conventional SSF field of view, resulting in higher levels of DR detected in 9% to 15% of eyes imaged with UWF technology.<sup>6,11-15</sup>

Using ultra-widefield fluorescein angiography is useful for identifying, quantifying and monitoring areas of peripheral capillary nonperfusion and ischemia in retinal vascular diseases. Research has found DR that is predominately located in the periphery to be four times more likely to progress to proliferative DR over a four-year period.<sup>16-18</sup> In fact, when DR was located mainly in the periphery, UWF-FA was

found to be better at predicting future DR worsening than UWF color photos alone.<sup>18-20</sup> Another study using UWF-FA found that proliferative DR developed with a threshold of 118 disc areas of retinal capillary nonperfusion.<sup>6-21</sup> UWF-FA also allows clinicians to follow areas of retinal nonperfusion and target laser photocoagulation treatment if necessary.<sup>22-24</sup>

UWF-OCT is also available and capable of producing fast, high-resolution, dye-free angiographic images. The parameters of this modality are not solidified in the literature. In general, experts in the field consider OCT to be UWF when the field of vision is equal to or greater than 90°, which can only be reached using a composite of several pictures.<sup>25,26</sup> One drawback to imaging the retina with OCT is a much smaller field of view compared to dye-based angiography. An OCT field of 12mm x 12mm covers 50° of the retina compared to UWF-FA which can photograph 110° to 220° in a single image.<sup>27</sup>

## RVO

This is another vascular disorder where areas of peripheral retinal nonperfusion extensively contribute to the disease process (*Figure 6*). Capillary dropout and ischemia are believed to cause the upregulation of pro-inflammatory cytokines such as vascular endothelial growth factor (VEGF). Presumably, larger areas of non-perfused retina extending into the periphery are

thought to be associated with elevated levels of intraocular VEGF.<sup>28,29</sup>

Capillary nonperfusion can be graded using an ischemic index or judging the anatomical extent (in mm<sup>2</sup>) of the involved retina. The ischemic index is a ratio that compares the number of pixels within the area of capillary nonperfusion to the total number of pixels within the entire visible retina.<sup>30</sup> In contrast, judging the anatomical extent of nonperfusion in mm<sup>2</sup> often identifies a larger area of nonperfusion.<sup>6</sup>

Although there is no strict definition, ischemic RVO has often historically been defined as greater than 10 disc areas of nonperfusion on SSF-FA.<sup>1,31</sup> With continued adoption of UWF-FA and OCT-A imaging, definitions of peripheral nonperfusion are rapidly evolving. Research using ultra-widefield FA suggests that most nonperfusion in a central RVO occurs in the temporal retina and that a total of 30 disc



areas of nonperfusion—rather than 10—may be a better threshold for considering a central RVO to be ischemic.<sup>32,33</sup> Research with widefield OCT-A suggests defining ischemic RVO as having >30% decreased flow area throughout the entire extent of the imaged retina.<sup>26</sup>

### Far Peripheral Lesions

UWF photography allows for imaging a host of peripheral retina lesions such as retinal detachments, holes, tears, lattice degeneration and retinoschisis. For example, imaging can have a role in detecting and managing rhegmatogenous retinal detachment (RRD). The ability to image the rhegmatogenous detachment allows for better patient education, surgical planning and monitoring of the condition (*Figure 7*). Also, UWF-FAF imaging may reveal a more accurate demarcation line, thus better evaluating the extent of the RRD.<sup>34</sup>

Obtaining a cross-sectional view of far peripheral lesions using UWF-OCT can provide detailed information on the extent of vitreal traction, subretinal fluid, relative retinal thinning, attenuation of choroidal vessels and cystoid degeneration of peripheral pathologies.<sup>35</sup>

### Pediatrics

Diagnosing and managing vitreoretinal disorders in the pediatric population can be challenging and often requires exams to be done under sedation with contact-based imaging systems. The RetCam has been used for many years in the neonatal population to screen for retinopathy of prematurity.<sup>36</sup> This camera is especially useful because it can perform FA on these children, which aids in the diagnosis and management of this and other peripheral retinal diseases.<sup>37</sup> Other contact-based imaging systems used in the pediatric population include Heidelberg Spectralis, PanoCam LT (Visunex Medical Systems) and 3nethra Classic (Forus Health).<sup>2</sup>

Capturing non-contact retinal images on neonates is difficult but possible by holding the newborn in the “flying baby” position.<sup>6</sup> With this technique, the infant is held face down on the parent’s inner forearm, supporting the chest and chin, while the other hand supports the baby’s head. The newborn is then held up to the camera and positioned properly by the parent to allow a technician to capture an image.

### Takeaways

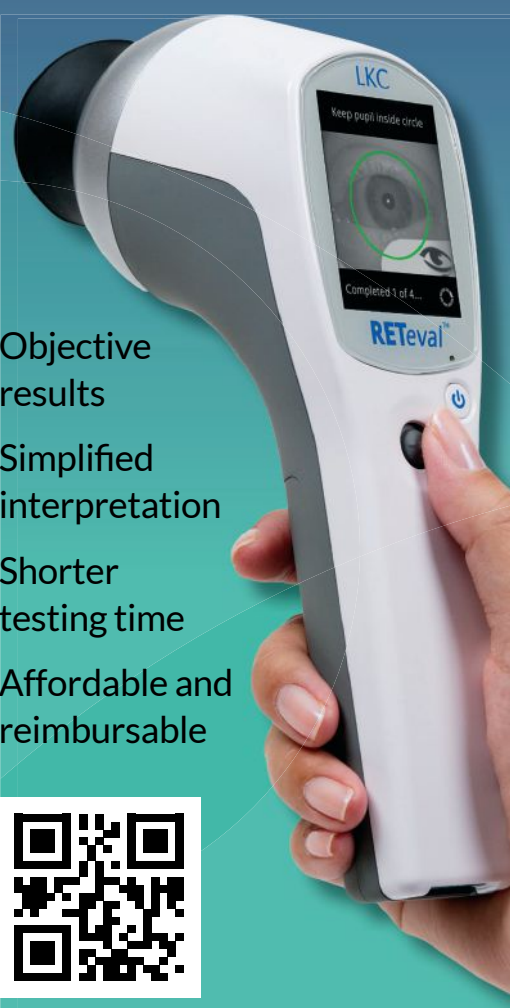When used properly, UWF imaging does not routinely replace dilation, but instead augments our ability to fully evaluate the peripheral fundus. It has brought new insights into the importance of the peripheral retina in various retinal disorders. Not only can UWF imaging allow detailed documentation of peripheral retinal findings, it can also improve diagnosis, staging classifications, monitoring and management of many common retinal conditions. The future of UWF imaging will likely include smartphone-based,

# RETeval<sup>®</sup>


ERG SIMPLIFIED

## THINK YOU KNOW ERG?

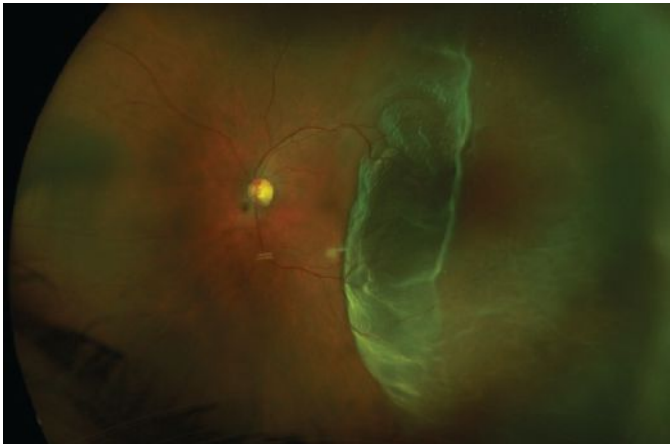*Think again*



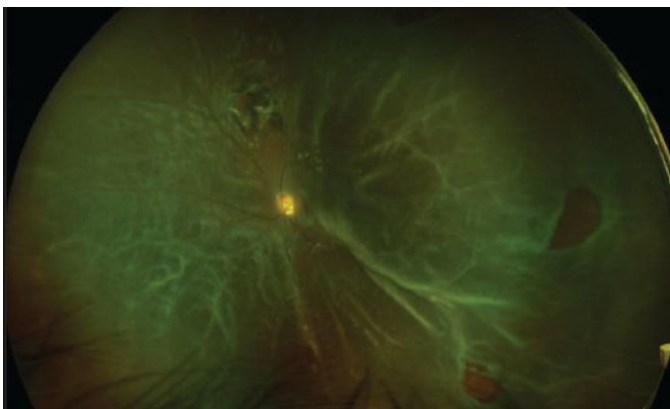- ✔ Objective results
- ✔ Simplified interpretation
- ✔ Shorter testing time
- ✔ Affordable and reimbursable



 **LKC**  
TECHNOLOGIES  
[LKC.COM](http://LKC.COM)



**Fig. 7. Optos photo of a macula-off retinal detachment (top). Optos photo of a total retinal detachment (bottom).**



portable devices to virtually screen the retina and the development of artificial intelligence-based software to improve the analysis of peripheral retinal pathology.<sup>37-40</sup>

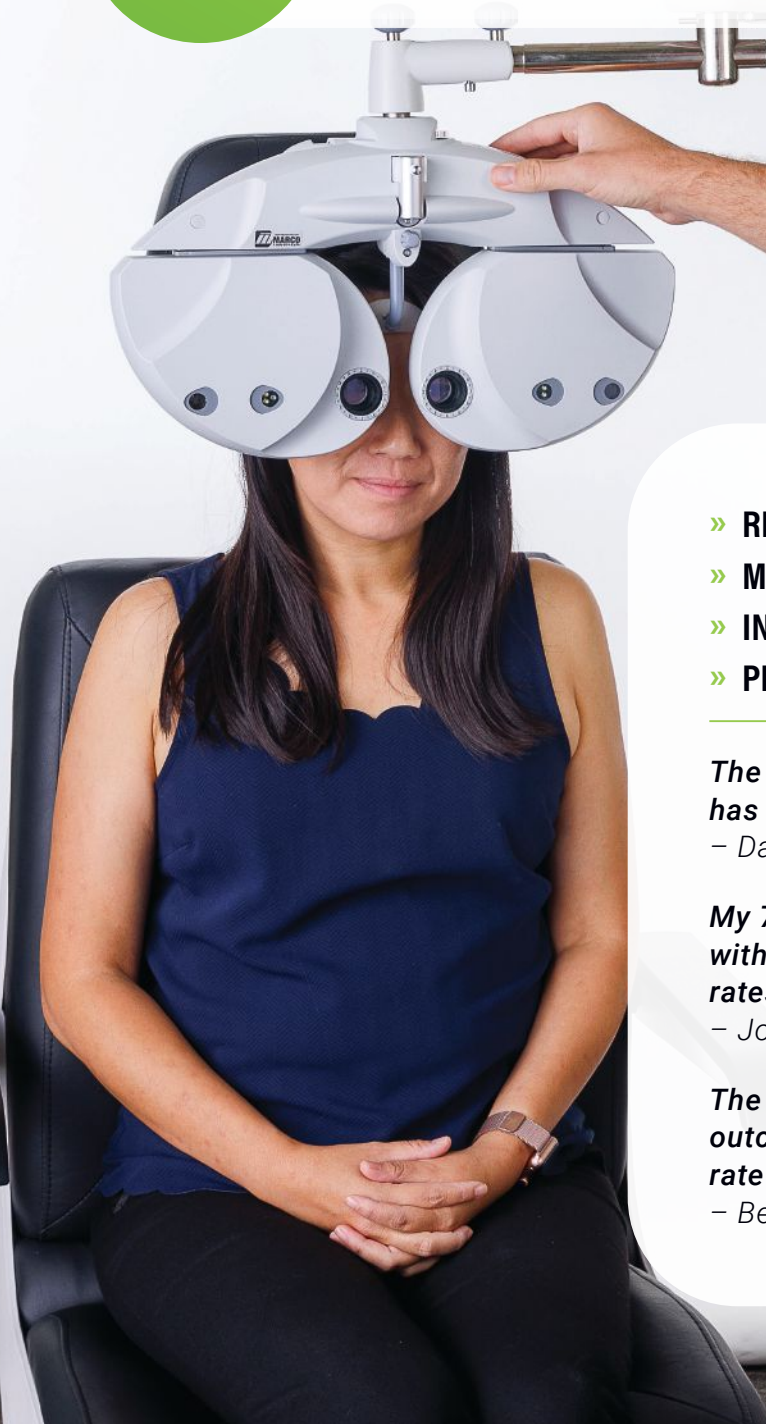As UWF imaging technology evolves, expanding our field of view, we will likely continue to gain new insights into the role the peripheral fundus plays in ocular disease. ■

1. Haner NU, Dysli C, Muck MR. Imaging in retinal vascular disease: A review. *Clin Experiment Ophthalmol.* 2023;51:217-28.
2. Patel SN, Shi A, Wibbelsman TD, Klufas MA. Ultra-widefield retinal imaging: an update on recent advances. *Ther Adv Ophthalmol.* 2020;(12):1-12.
3. Choudhry N, Duker JS, Freund KB, et al. Classification and guidelines for widefield imaging: recommendations from the International Widefield Imaging Study Group. *Ophthalmol Retina.* 2019;3:10:843-9.
4. Calvo CM., Hartnett ME. The utility of ultra-widefield fluorescein angiography in pediatric retinal diseases. *Int J Retin Vit.* 2018;4(21).
5. Midena E., Marchione G, Digiorgio S, et al. Ultra-wide-field fundus photography compared to ophthalmoscopy in diagnosing and classifying major retinal diseases. *Sci Rep.* 2022;12:19287.
6. Kumar V, Surve A, Kumawat D, et al. Ultra-wide field retinal imaging: a wider clinical perspective. *Indian J Ophthalmol.* 2021;69:824-35.
7. Salz JJ, Seibel BS. Screening with widefield fundus photography. Widefield technology has value for a practice's patients, efficiency and bottom line. *Ophthalmology Management.* June 1, 2019. Accessed August 16, 2023.
8. Purbick RM, Izadi S, Gupta A, Chong NV. Comparison of Optomap ultrawide-field imaging versus slit-lamp biomicroscopy for the assessment of diabetic retinopathy. *Clin Ophthalmol.* 2014;8:1413-7.
9. Wilson PJ, Ellis JD, MacEwen CJ, et al. Screening for diabetic retinopathy: a comparative trial of photograph and scanning laser ophthalmoscopy. *Ophthalmologica.* 2010;224:251-7.
10. Neubauer AS, Kernt M, Haritoglou C, et al. Nonmydriatic screening laser ophthalmoscopy (optomap). *Graefes Arch Clin Exp Ophthalmol.* 2008; 246:229-35.
11. Wessel MM, Aaker GD, Parilitis G, et al. Ultra-wide field angiography improves the detection and classification of diabetic retinopathy. *Retina.* 2012;32(4):785-91

12. Silva PS, Cavallerano JD, Sun JK, et al. Peripheral lesions identified by mydriatic ultrawide field imaging: distribution and potential impact on diabetic retinopathy severity. *Ophthalmology.* 2013;120(12):2587-95.
13. Silva PS, Cavallerano JD, Tolls D, et al. Potential efficiency benefits of nonmydriatic ultrawide field retinal imaging in an ocular telehealth diabetic retinopathy program. *Diabetes Care.* 2014;37(1):50-5.
14. Price LD, Au S, Chong NV. Optomap ultrawide field imaging identifies additional retinal abnormalities in patients with diabetic retinopathy. *Clin Ophthalmol.* 2015;9:527-31.
15. Aiello LP, Odia I, Glassman AR, et al. Comparison of early treatment diabetic retinopathy study standard 7-field imaging with ultrawide-field imaging for determining severity of diabetic retinopathy. *JAMA Ophthalmol.* 2019;137(1):65-73.
16. Silva PS, Cavallerano JD, Haddad MN, et al. Peripheral lesions identified on ultrawide field imaging predict increased risk of diabetic retinopathy progression over four years. *Ophthalmology.* 2015;122:949-56.
17. Hirano T, Imai A, Kasamatsu H, et al. Assessment of diabetic retinopathy using two ultra-wide-field fundus imaging systems, the Clarus and Optos systems. *BMC Ophthalmol.* 2018;18(1):332.
18. Marcus DM, Silva PS, Liu D, et al. Association of predominantly peripheral lesions on ultra-widefield imaging and the risk of diabetic retinopathy worsening over time. *JAMA Ophthalmol.* 2022;140(10):946-54.
19. Silva PS, Liu D, Glassman AR, et al. Assessment of fluorescein angiography nonperfusion in eyes with diabetic retinopathy using ultrawide field retinal imaging. *Retina.* 2022;42:1302-10.
20. Yusuf IH, Lotery AJ. Thinking outside the circle-the potential value of ultra-widefield imaging. *JAMA Ophthalmol* 2022;140(10):955-6.
21. Nicholson L, Ramu J, Chan EW, et al. Retinal nonperfusion characteristics on ultra-wide field angiography in eyes with severe nonproliferative diabetic retinopathy and proliferative diabetic retinopathy. *JAMA Ophthalmol.* 2019;137:626-31.
22. Lasave AF, Shoughy SS, Kozak I, Arefalo, JF. When ultra-widefield retinal imaging is most useful. *Retina Today.* 2019;36-40.
23. Wykoff CC, Nittala MG, Zhou B et al. Intravitreal aflibercept for retinal nonperfusion in proliferative diabetic retinopathy: outcomes from the randomized recovery trial *Ophthalmol Retina.* 2019;3:1076-86.
24. Campochiaro PA. Low risk to retina from sustained suppression of VEGF. *J Clin Invest.* 2019;129(8):3029-31.
25. Pichi F, Carreño E, Pavesio C, et al. Consensus-based recommendations for OCT angiography reporting in uveitis. *Br J Ophthalmol.* 2023;107(7):959-65.
26. Munk MR, Kashani AH, Tadayoni R, et al. Recommendation for OCT angiography reporting in retinal vascular disease. A Delphi approach by international experts. *Ophthalmol Retina.* 2022;6(9):753-61.
27. Li M, Mao M, Wei D, et al. Different scan areas affect the detection rates of diabetic retinopathy lesions by high-speed ultra-widefield swept-source optical coherence tomography angiography. *Front Endocrinol (Lausanne).* 2023;14:1111360.
28. Singer M, Tan CS, Bell D, Sadda SR. Area of peripheral retinal nonperfusion and treatment response in branch and central retinal vein occlusion. *Retina.* 2014;34(9):1736-42.
29. Campochiaro PA, Bhistkul RB, Shapiro H, Rubio RG. Vascular endothelial growth factor promotes progressive retinal nonperfusion in patients with retinal vein occlusion. *Ophthalmology.* 2013;120(4):795-802.
30. Tan TE, Ibrahim F, Chandrasekaran PR, Teo KYC. Clinical utility of ultra-widefield fluorescein angiography and OCT angiography for retinal vein occlusions. *Front Med (Lausanne).* 2023;10:110166.
31. Sivaprasad S, Amoaku WM, Hykin P. The Royal College of Ophthalmologist Guidelines on retinal vein occlusions: executive summary. *Eye (Lond).* 2015;29(12):1633-8.
32. Nicholson L, Vazquez AC, Patrao NV, et al. Retinal nonperfusion in the posterior pole is associated with increased risk of neovascularization in central retinal vein occlusion. *Am J Ophthalmol.* 2017;182:118-25.
33. Nicholson L, Vazquez-Alfageme C, Sen P, et al. The clinical relevance of ultra-widefield angiography findings in patients with central retinal vein occlusion and macular oedema receiving anti-VEGF therapy. *Eye (Lond).* 2022;36(5):1086-93.
34. Witmer MT, Cho M, Favarone G, et al. Ultra-wide field autofluorescence imaging in non-traumatic rhegmatogenous retinal detachment. *Eye (Lond).* 2012;26(9):1209-16.
35. Choudhry N, Golding J, Manry MW, Rao RC. Ultra-widefield steering-based spectral-domain optical coherence tomography imaging of the retinal periphery. *Ophthalmology.* 2016;123:1368-74.
36. Alone A, Chandra K, Chhablani J. Wide-field imaging-an update. *Indian J Ophthalmol.* 2021;69(4):788-9.
37. Temkar S, Azad SV, Chawla R, et al. Ultra-widefield fundus fluorescein angiography in pediatric retinal vascular diseases. *Indian J Ophthalmol.* 2019;67(6):788-94.
38. Lee SJ, Yang KM, Lee KB, Park NC. Design of illumination system using characterized illuminances for smartphone-based fundus camera. *Opt Lasers Eng.* 2023;168:107664.
39. Iqbal, U. Smartphone fundus photography: a narrative review. *Int J Retin Vit.* 2021;7(44).
40. Sedova A, Hajdu D, Datlinger G, et al. Comparison of early diabetic retinopathy staging in asymptomatic patients between autonomous AI-based screening and human-graded ultra-widefield color fundus images. *Eye.* 2022;36:510-6.



## DISCOVER THE POWER OF AUTOMATION



- » REDUCE REFRACTION TIME
- » MAXIMIZE STAFF RESOURCES
- » INCREASE OPTICAL SALES
- » PROVIDE A HIGH-TECH EXAM

*The TRS has not only improved my efficiency, but has enhanced my patients' experience.*

– David Mills, OD, Boston, MA

*My 7+ minute refractions are now around 3 minutes with TRS, and they are more accurate too. Our redo rates have dropped to near zero.*

– Joel Hayden, OD, Mansfield, MA,

*The TRS allows me to compare patients' refractive outcomes with their current glasses. My conversion rate and multiple pair metrics have never been higher.*

– Ben Gaddie, OD, Louisville, KY

**VISIT MARCO AT VEV FOR SPECIAL SHOW SAVINGS | BOOTH F6035**

**NOT ATTENDING VEV 2023?**

Contact Marco Healthcare to learn how you can access our exclusive show promotions.

**MARCO.COM | 904.997.4131**



# LOW VISION TOOLS AND TECHNIQUES YOU SHOULD KNOW

An overview of concepts and resources used by primary eyecare providers and appropriate specialists to ease patients' visual impairments.



BY JESSICA CAPRI, OD  
BOSTON

Optometrists are often the first providers to see patients experiencing vision loss, whether new, progressive or long-standing. Although it is the duty of the provider to diagnose and manage the underlying cause of the worsening vision, we cannot overlook how irreversible vision loss impacts quality of life for our patients. It is crucial as eyecare professionals and experts in our field to fully understand the needs of this patient population beyond the exam chair, which may be as simple as having an in-office conversation.

It is also important to remember that there is no “acuity cutoff” necessary for a low vision rehabilitation referral. Any patient with a history of ocular disease whose activities of daily living are not being met should be promptly referred to a low vision rehabilitation (LVR) specialist. LVR aims to use resources and tools in order to help patients adapt to lifestyle changes as a result of vision loss. In this article, not only will the importance of LVR referral be high-

lighted, but also the need for primary eyecare practitioners to become aware of possible tools and resources so their affected patients may benefit from these services, especially if an LVR provider is not in their area.

## Where to Start?

It is the duty of every eye doctor to promptly and accurately refer patients to specialists when needed, and low vision rehabilitation is no exception. At a minimum, our profession must be familiar with state agencies and organizations for the visually impaired and how to register a patient when necessary as legally blind, which will allow patients to access available resources. These resources can often be found online by searching your state's government websites.

For example, at the time this article was written, to register in Massachusetts for legal blindness, an online form can be completed and submitted to the Massachusetts Commission for the Blind. In many states, eye doctors have a legal duty to register their patients promptly in order to provide them with resources they have a right to receive. Following registration, patients are

usually connected with a case manager, generally a social worker, who will act as their liaison. This may vary state to state, but it is crucial to connect patients with accurate resources, and to do so requires the first step of registration.

Even when a patient does not qualify for legal blindness but does have vision loss, it is imperative that eye doctors are aware of alternative options to help meet the needs of their patients. Such important resources include grief counseling and support groups. This is incredibly vital not to overlook, as many patients struggle with progressive or sudden vision loss. There are groups specific to veterans through local Veterans Hospitals that patients may get involved with, but many local programs exist as well. Reaching out to your state's commission for blindness or foundation for blindness is a great way to learn about these groups and how to connect them with your patients.

When any patient has experienced impact to their daily activities because of vision changes, thorough consideration should also be given to an LVR referral. Having a knowledgeable conversation with patients about the potential

### About the author

Dr. Capri currently works at Tufts Medical Center, where she specializes in low vision rehabilitation and traumatic brain injury. She also teaches clinical education at the Massachusetts College of Pharmacy and Health Sciences School of Optometry and New England College of Optometry. Additionally, she has an interest in health law and is completing her law degree at Suffolk University Law School. She has no financial interests to disclose.



**Fig. 1. Top: Optivisor with light for intermediate tasks. Middle: Spectacle-mounted telescope for distance enhancement. Bottom: Optelec illuminated handheld magnifier for spot reading.**

advantages these referrals offer is crucial to determine if the patient is motivated and will actually benefit from a referral. Searching online and asking others in the field are some ways to find an LVR provider, but reaching out to the nearest optometry school is another productive option that can be overlooked. Additionally, many large ophthalmology programs have optometrists (and less frequently ophthalmologists) practicing LVR that are affiliated with their hospitals.

Remember, LVR examinations are goal-specific. Providers listen carefully to the needs of their patients and identify areas in which low vision technology and resources may be of adequate assistance. To accurately identify these resources and complete a comprehensive



**Fig. 2. Left to right: Binocular telescope, monocular telescope and MaxTV glasses for distance enhancement.**



**Fig. 3. Left to right: Distance-enhancement interfaces corresponding to the aforementioned binocular telescope, monocular telescope and Max TV glasses of Fig. 2, respectively.**

LVR examination, understanding the connection between the disease process and a patient's functional vision loss is key. Although not all-inclusive, this article provides a brief overview of common causes of vision loss and the impact these conditions may commonly play in quality of life. Also discussed are recommendations an LVR provider may consider in an effort to encourage primary eyecare providers to begin the conversation about low vision and its resources to further understand why LVR referral is key.

### Central Scotomas and Metamorphopsia

A central scotoma is a blind spot or area of decreased vision impacting central vision, while metamorphopsia is

described as vision distortion. Both are often experienced by patients suffering from conditions like age-related macular degeneration and Stargardt's disease.

Many patients with central scotomas and metamorphopsia may have trouble reading, especially continuous text, as the distortion or blind spot may cause letters to appear jumbled or missing. Central scotomas may also reduce the amount of saccadic eye movements during reading, greatly impairing reading speed and efficiency.<sup>1</sup> This form of vision loss may also significantly impact one's ability to drive confidently or recognize faces, as central vision is impaired or missing entirely.

Patients with central scotomas are often very successful with eccentric viewing, magnification and additional

goal-specific strategies. Eccentric viewing is a method of vision training that works to move the viewed image into the patient's preferred retinal locus (PRL).<sup>2,3</sup> Patients may learn to use their PRL to improve visual clarity by using a less damaged or healthy part of their retina.<sup>4,5</sup>

This training can be completed in-office by the OD, but is often completed by a referred specialist, such as a low vision-trained occupational therapist, certified low vision therapist or vision rehabilitation therapist. Eye doctors should be familiar with vision rehabilitation specialists like these in their area. Aside from a quick Google search or word-of-mouth recommendations, using the following website can direct your efforts: [www.acvrep.org/index](http://www.acvrep.org/index).

As for task-specific goals, this is where referral to a low vision rehabilitation provider may be necessary. Most eye doctors have some (albeit varying) level of experience with LVR. As the field has grown extensively beyond high-powered adds and magnifiers, a full LVR exam is difficult to complete in a primary care setting.

During the LVR examination, specialists will thoroughly review the patient's needs and determine which potential devices and resources they may benefit from. These may range from optical devices such as handheld magnifiers, stand magnifiers, microscopes and telescopes to electronic devices and assistive technology on phones and computers, either built into the software or through third-party applications. Electronic devices to consider include desktop magnifiers, electronic magnifiers and head-mounted devices. Many of these allow for adjustable magnification, reverse polarity and audibility.<sup>6</sup>

### Peripheral Vision Loss

This type of loss constitutes a gradual reduction of vision moving from peripheral to central regions. It is often experienced by patients suffering from conditions such as glaucoma and retinitis pigmentosa.

Many patients with peripheral vision loss may have difficulty with mobility

and express this in the form of bumping into objects or missing objects as they come towards them.<sup>7</sup> This may result in an increased risk of falling and lack of confidence when traveling independently. Although not all states have a visual field requirement for legal driving, this difficulty with peripheral vision loss may make it difficult or impossible to drive. Additionally, smaller fields of vision may hinder reading abilities, as the patient may find it difficult to localize words on a page or it may be harder to read efficiently with fewer words in their field of view.<sup>8</sup>

Tools such as reverse telescopes prove successful with patients experiencing peripheral vision loss. The use of a monocular telescope in the reverse direction minifies objects and expands the patient's field of view, therefore allowing a greater number of smaller images within the field of vision.<sup>9</sup> This can be especially beneficial for mobility purposes. Following evaluation and recommendation from an LVR provider of which type of reverse telescope to use, a qualified rehabilitation specialist is useful for possible in-home training with the device.

Another important resource for referrals is a certified orientation and mobility specialist (COMS). These specialists work to train patients with vision loss so they are able to travel and freely move about their home, work and public environments.<sup>10</sup> This is often the best way to provide patients with white cane training and broaden their independence regarding mobility concerns.

### Hemianopsia and Quadrantopsia

Vision loss of this type is the loss of half or a quarter of the patient's vision bilaterally. This form of vision loss is often experienced by patients suffering from conditions such as trauma and stroke.

Like patients with full peripheral vision loss, patients with partial loss also have trouble with mobility, object localization, driving and reading.<sup>11</sup> Especially in cases of right-sided loss, the patient may be reading into their scotoma and have trouble discerning where the end of the page is located.

Outside of an LVR consultation, referral to a COMS and any other applicable rehabilitation specialist (as determined by the patient's goals) is best practice for many patients with hemianopsia field loss. A prism evaluation may be extremely useful for these patients. Use of prisms, including but not limited to Peli prism, yoked prism and Fresnel prism may require additional training that can be provided either in-office or by these specialists.<sup>12,13</sup>

### Contrast Sensitivity and Glare

These factors are arguably two of the most overlooked aspects of vision reduction. A thorough evaluation may be completed using a Pelli-Robson or Mars chart, along with questions related to glare sensitivity. Most patients with vision loss do experience some form of glare or contrast sensitivity loss.<sup>14</sup>

Reduced contrast sensitivity and glare can impact driving by reducing the distinction and clarity of sight in low-light environments or instances where exposure to bright lights is frequent, such



**Tinted fit-over glasses for improved contrast and glare management.**



as with bright headlights. Additionally, trouble with contrast may hinder mobility by causing difficulty seeing or stepping around objects, while trouble with adaptation to glare may also make independent travel difficult.<sup>14</sup> Other tasks such as reading may be impaired as many forms of reading material, such as newspaper, is printed on poorly contrasted material.

To counteract these issues, a thorough tint trial can assist patients immensely. Although the use of tints for LVR is an under-researched area, their use may help improve contrast sensitivity thresholds and cut glare without any impairment of visual acuity.<sup>15</sup> If tints are to be recommended for use, LVR specialists will connect with vendors such as Chadwick Optical and Eschenbach Optik to request a tint trial set, which is one of the best ways to complete this evaluation.

Providers should also consider recommendations regarding the patient's environment. This may include suggesting hats or visors to minimize glare and the amount of light a patient is exposed to. Providing samples of different task lighting may also be useful to enhance contrast. A recommendation may also be made for patients to adopt the use of LED smart bulbs with voice command options. These bulbs often allow for brightness adjustment and can be easy to use for patients once set up in the home.<sup>16</sup>

Rehabilitation specialists can also be a helpful resource when recommending environmental changes to improve contrast and minimize glare. For example, a lighting evaluation may be completed in the home to provide suggestions to enhance light in certain areas, offer options for better lighting and suggest best locations for reading or completing other visually difficult tasks. Other recommendations can be discussed, such as using dark or light backgrounds on a table to enhance an item's contrast, making it easier to see.

## Diplopia

Occurring when an image is split, usually into two parts, diplopia is generally



**Tinted trial rings can show patients different potential tinted lenses for continual wear to enhance contrast and manage glare.**

horizontal, vertical or diagonal. There is a wide range of neurologic causes for diplopia, but common reasons include stroke and muscle palsy.<sup>17</sup> Binocular vision disorders such as decompensated phorias may also be a cause.

Diplopia patients may also benefit from a thorough prism trial, as with hemianopsia, which can often be completed in-office. Vision therapy (VT) may be another consideration for patients experiencing diplopia. Like LVR, VT specialists comprise another crucial referral system that primary eyecare providers should be aware of. Provider directory use and reaching out to the nearest optometry school are two possible ways to locate VT providers.

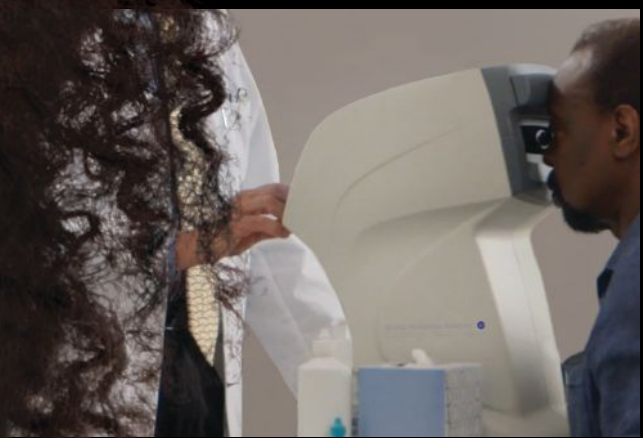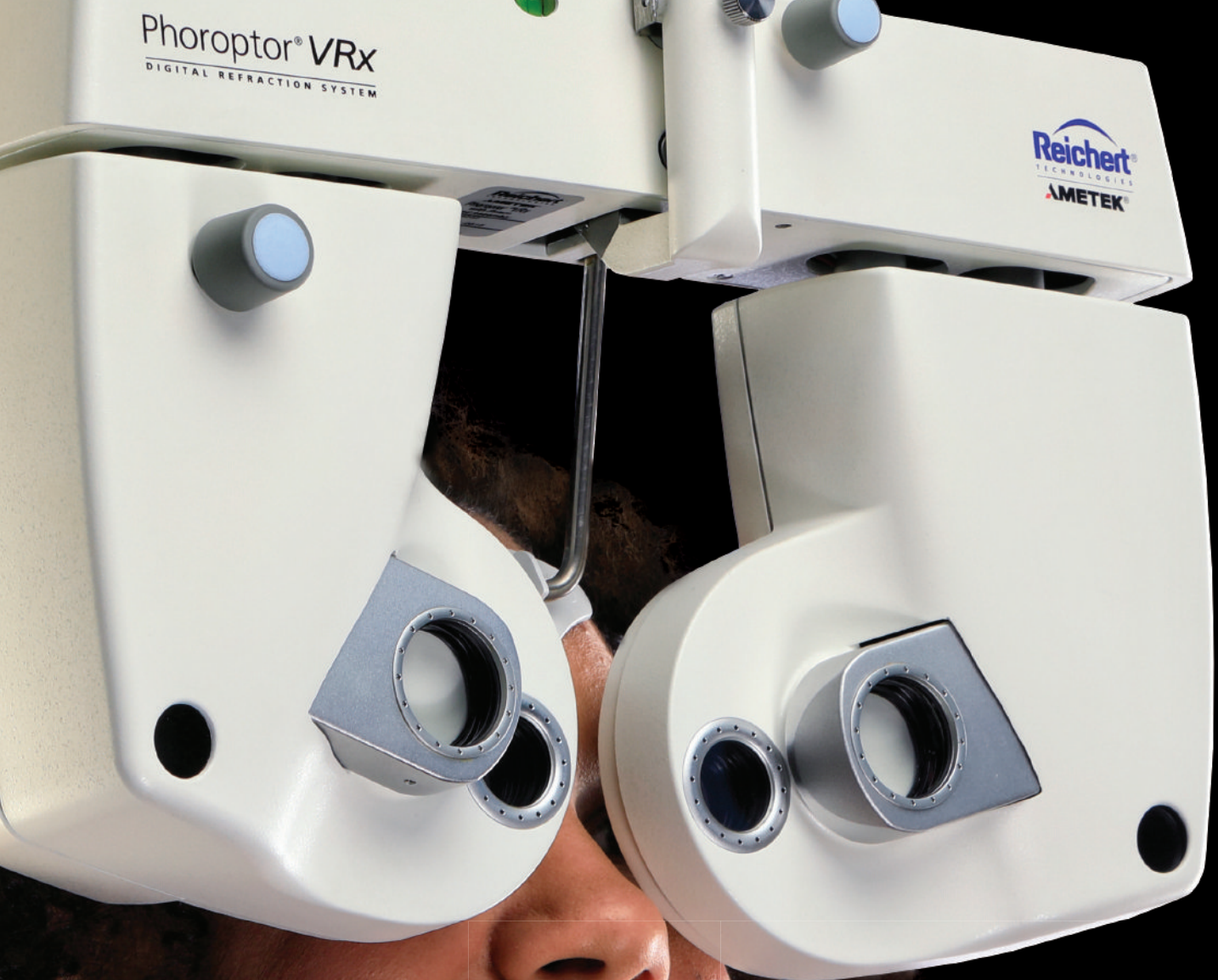## Takeaways

As most eye doctors do not practice low vision and many areas have limited services, it is imperative that providers at a minimum discuss with their patients their quality of life related to their vision loss. Practitioners should also understand which resources are available in their area to refer patients to. More research is needed to determine which services and practices can benefit patients with low vision, but in the meantime, optometrists must not overlook the importance of connecting the dots between visual function and daily activity impact. ■

1. Song Y, Ouchene L, Khan AZ. Saccadic adaptation in the presence of artificial central scotomas. *J Vis.* 2021;21(1):8.
2. "Eccentric viewing" to improve vision. Lighthouse Guild. Published July 16, 2021. [lighthouseguild.org/eccentric-viewing-to-improve-vision](https://lighthouseguild.org/eccentric-viewing-to-improve-vision). Accessed August 7, 2023.
3. Swinton DJ, Thomas AG. The visual pathway—functional anatomy and pathology. *Semin Ultrasound CT MR.* 2014;35(5):487-503.
4. Gaffney AJ, Margrain TH, Bunce CV, Binns AM. How effective is eccentric viewing training? A systematic literature review. *Ophthalmic Physiol Opt.* 2014;34(4):427-37.
5. Cheung SH, Legge GE. Functional and cortical adaptations to central vision loss. *Vis Neurosci.* 2005;22(2):187-201.
6. Vasconcelos G, Fernandes LC. Low-vision aids. *American Academy of Ophthalmology.* Published November 4, 2015. [aao.org/eye-health/diseases/low-vision-aids](https://www.aao.org/eye-health/diseases/low-vision-aids). Updated March 4, 2021.
7. Swenor BK, Muñoz B, West SK. Does visual impairment affect mobility over time? The Salisbury Eye Evaluation Study. *Invest Ophthalmol Vis Sci.* 2013;54(12):7683-90.
8. Chung STL, Legge GE, Cheung S. Letter-recognition and reading speed in peripheral vision benefit from perceptual learning. *Vision Res.* 2004;44(7):695-709.
9. Monirittilaki M, Badakhsh M, Ehsaei A, Daneshvar R. The effect of contact lens-spectacle reversed Galilean telescope on the visual field of patients with open-angle glaucoma. *J Ophthalmic Vis Res.* 2020;15(4):502-8.
10. Orientation & mobility (O&M). Commonwealth of Massachusetts. [mass.gov/service-details/orientation-mobility-om](https://www.mass.gov/service-details/orientation-mobility-om). Accessed August 7, 2023.
11. Costela FM, Sheldon SS, Walker B, Woods RL. People with hemianopia report difficulty with TV, computer, cinema use, and photography. *Optom Vis Sci.* 2018;95(5):428-34.
12. Taub MB, Harris P. Fresnel prism to the rescue. *Review of Optometry.* Published April 15, 2018. [reviewofoptometry.com/article/fresnel-prism-to-the-rescue](https://www.reviewofoptometry.com/article/fresnel-prism-to-the-rescue). Accessed August 7, 2023.
13. Peil E. 2017 Charles F. Prentice Award Lecture: peripheral prisms for visual field expansion: a translational journey. *Optom Vis Sci.* 2020;97(10):833-46.
14. Colenbrander A, Fletcher DC. Contrast sensitivity and visual hallucinations in patients referred to a low vision rehabilitation clinic. *Br J Ophthalmol.* 2007;91(3):272.
15. de Fez MD, Luque MJ, Viqueira V. Enhancement of contrast sensitivity and losses of chromatic discrimination with tinted lenses. *Optom Vis Sci.* 2002;79(9):590-7.
16. Lighting and low vision. Perkins School for the Blind. Published December 7, 2022. [perkins.org/resource/lighting-and-low-vision](https://www.perkins.org/resource/lighting-and-low-vision). Accessed August 7, 2023.
17. Uzdrowska M, Crossland M, Broniarczyk-Loba A. Is binocular vision worth considering in people with low vision? *Klin Oczna.* 2014;116(1):49-51.

Phoroptor® VRx  
DIGITAL REFRACTION SYSTEM

Reichert®  
TECHNOLOGIES  
AMETEK



Ocular Response Analyzer® G3 with Corneal Hysteresis + IOPcc



# RELIABLE REFRACTION. TRUSTED TONOMOMETRY.

We share your passion for personalizing and improving vision testing and glaucoma care. For nearly two centuries, we've delivered innovative, precise, and efficient diagnostic devices to help you provide better patient care.


LEARN MORE



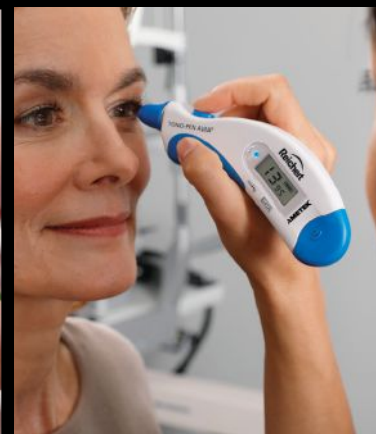VISIT US AT VISION EXPO WEST #F9037!  
SHOW PROMOS FOR ALL: [REICHERT.COM/PROMOS](https://www.reichert.com/promos)



Tono-Vera® Tonometer\* - Coming Soon



Phoropter® - Digital or Traditional featuring Phoropter® VRx with ClearChart®









Tono-Pen AVIA® Tonometer

**Reichert**  
AMETEK®

*passionate about eye care*

© 2023 AMETEK, Inc. & Reichert, Inc. (08-2023) Phoropter, ClearChart, Ocular Response Analyzer, Tono-Pen AVIA, and Tono-Vera are all registered trademarks of Reichert, Inc.

\*Pending FDA Clearance · Designed & assembled in USA      



Earn 2 CE Credits  
(COPE APPROVED)

# THE DEFINITIVE GUIDE TO CORNEAL TOPOGRAPHY

Understanding when and how to use this tool is a critical component of optometric practice.



BY BECKY SU, OD,<sup>1</sup> MARCUS NOYES, OD,<sup>2</sup>  
AND JOHN GELLES, OD<sup>1</sup>

<sup>1</sup> TEANECK, NJ; <sup>2</sup> IOWA CITY, IA

As eyecare practitioners, we understand the crucial role diagnostic tools play in patient care. They allow us to make the invisible visible and quantifiable. Corneal topography is a vital instrument that offers valuable insights into the state of the corneal surface. Due to its applicability and benefits, corneal topography should be a ubiquitous tool used frequently in our daily practice to facilitate informed decisions about vision and eye health. This article tells you everything you need to know about how to succeed with corneal topography.

## Understanding the Technology

Corneal topography visually represents the corneal surface curvature and provides quantitative and qualitative data. Over the years, it has evolved to include evaluations beyond typical curvature maps.

One of the earliest forms of corneal topography, and still the most commonly used today, is Placido disc-based systems. These systems rely on the reflection of a series of illuminated concentric rings projected onto the corneal surface and a centrally located camera to capture an image of the reflection. The cornea's curvature is then calculated by analyzing the shape and spacing between the reflected mires. Widely spaced mires indicate a flatter corneal curvature and closely spaced rings indicate a steeper curvature. These systems heavily depend on the tear film to reflect the illuminated ring image.

Placido disc topographers can be categorized as either small-cone or large-cone systems. Small-cone topographers can achieve near-limbus-to-limbus scan coverage. Large-cone topographers capture images of the central 7mm to 8mm.

Ring spacing is another differentiating factor. Denser, more tightly spaced rings can capture more detailed curvature data, whereas wider-spaced rings tend to have fewer issues with ring overlap-related artifacts.

Other reflection-based technologies for deriving corneal topography include raster stereography, in which raster grids are projected onto the ocular surface instead of concentric rings after applying sodium fluorescein. This technology is no longer available in the form of a corneal topographer; however, it has been successfully applied to corneal scleral profilometry to map the ocular surface, primarily for scleral

### About the authors

**Dr. Su** is the cornea and contact lens fellow at the Cornea and Laser Eye Institute (CLEI) Center for Keratoconus in Teaneck, NJ. **Dr. Noyes** is a clinical assistant professor at the University of Iowa department of ophthalmology, specialty contact lens department in Iowa City, IA. He graduated from University of Houston College of Optometry and went on to complete a dual residency in cornea/contact lens and ocular disease at Havener Eye Institute, department of ophthalmology and visual science at The Ohio State University Wexner Medical Center. As part of the faculty at College Carver of Medicine at the University of Iowa, he is involved in teaching ophthalmology residents and medical students ophthalmological skills in both a lecture-based and clinical-based setting. He is a fellow of the American Academy of Optometry as well as the Scleral Lens Society. **Dr. Gelles** is the director of the specialty contact lens division at the CLEI and the CLEI Center for Keratoconus. He is an assistant clinical professor at Rutgers New Jersey Medical School within the department of ophthalmology and visual science. He is an adjunct clinical professor at the State University of New York College of Optometry, Illinois College of Optometry and New England College of Optometry. They have no financial disclosures.

shape analysis and device-driven scleral lens design.

Another technology uses a large series of multi-color LED lights in a dot grid pattern that capture the image as it is projected onto the cornea. Its software uses the spacing between the dots to derive the corneal surface and infrared LED lights to measure second Purkinje images, providing simplified information about the posterior cornea.

## Differentiating the Maps

The data captured during corneal topography can be presented in different types of corneal maps, such as axial, tangential and elevation.

**Axial (sagittal) maps.** This is the classic standard representation on all topography devices. It shows the corneal power and shape at a glance, facilitating the diagnosis and monitoring of corneal conditions such as keratoconus. It also assesses corneal power changes caused by corneal treatments such as corneal refractive surgery or orthokeratology (ortho-K). In this map, the corneas' curvature is calculated using the corneal apex as a reference point, and the data is averaged, creating a "smooth" map, thereby losing minute details of the peripheral cornea.

**TABLE 1. TOPOGRAPHY TRICKS AND TIPS**

<b>Nasal Scan Defects</b>	Typically caused by the bridge of the nose blocking the projected rings. Turn the head about 20° to 30° in the opposite direction of the eye being scanned; this will open the orbit eliminating nose defects.
<b>Superior Scan Defects</b>	Caused by strong brows and deep orbits. Overcome this problem by keeping the forehead against the forehead rest and jut the chin forward to create a backward tilt; this will open the orbit more.
<b>Brow or Nose Contact</b>	Typically only a problem in small-cone topographers and can be remedied by using the above techniques.
<b>Holding Lids</b>	Superior defects caused by lash and upper lid position is common. Lids stick or cotton swabs can be used. Don't be afraid to ask a patient to hold a lower lid while you hold the upper. Avoid pressure on the globe as it will deform and may alter the corneal shape.
<b>Poor Mire Quality</b>	This is most commonly due to poor tear film stability. Blinking between captures is important to keep mires sharp so data is accurate. In patients with ocular surface disease, using saline can significantly help. High viscosity artificial tears can alter topography; however, for those with significant corneal staining, it may be the only way to obtain an adequate scan. Depending on the intended use of the scan, this can be sufficient as a starting point for diagnostic contact lens fitting, for example. However, for a device-driven contact lens design, this may lead to inaccurate data.

### *Tangential (instantaneous) maps.*

Unlike axial maps, tangential maps are more sensitive and do not use a single point as a reference. They enable a more precise depiction of local curvature changes, particularly in the peripheral cornea. These maps are ideal for measurements where fine detail is

important, such as the assessment of ortho-K treatment, specifically treatment zone centration.

**Elevation maps.** These maps show the "height" or "elevation" of the cornea at any given point relative to a reference shape. A "best-fit sphere" is calculated and extrapolated through the

#### The Definitive Guide to Corneal Topography

Jointly provided by Postgraduate Institute for Medicine (PIM) and Review Education Group

**Release Date:** September 15, 2023

**Expiration Date:** September 15, 2026

**Estimated Time to Complete Activity:** two hours

**Target Audience:** This activity is intended for optometrists engaged in optic nerve disorder management.

**Educational Objectives:** After completing this activity, participants should be better able to:

- Recognize the role of corneal topography in optometric practice.
- Effectively use this tool in contact lens management.
- Employ corneal topography for the detection of corneal disease.
- Correctly use corneal topography for pre- and postoperative management.

**Faculty:** Becky Su, OD, Marcus Noyes, OD, and John Gelles, OD

**Disclosure of Conflicts of Interest:** PIM requires faculty, planners and others in control of educational content to disclose all their financial relationships with ineligible companies. All identified conflicts of interest are thoroughly vetted and mitigated according to PIM policy. PIM is committed to providing its learners with high-quality, accredited CE activities and related materials that promote improvements or quality in health care and not a specific proprietary business interest of an ineligible company.

Those involved reported the following relevant financial relationships with ineligible entities related to the educational content of this CE activity: *Faculty* – Drs. Su, Noyes



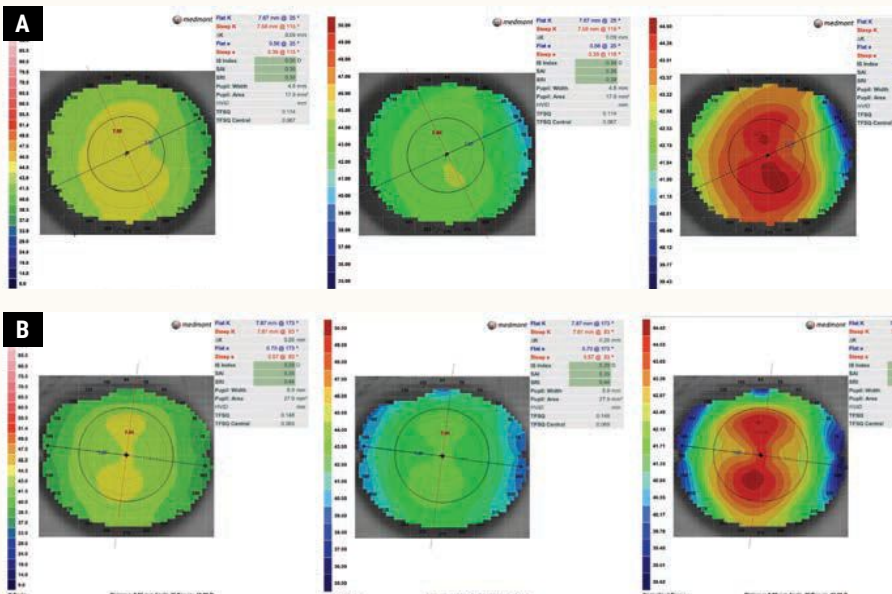
and Gelles have nothing to disclose. *Planners and Editorial Staff* – PIM has nothing to disclose. The Review Education Group has nothing to disclose.

**Accreditation Statement:** In support of improving patient care, this activity has been planned and implemented by PIM and the Review Education Group. PIM is jointly accredited by the Accreditation Council for Continuing Medical Education, the Accreditation Council for Pharmacy Education and the American Nurses Credentialing Center to provide CE for the healthcare team. PIM is accredited by COPE to provide CE to optometrists.

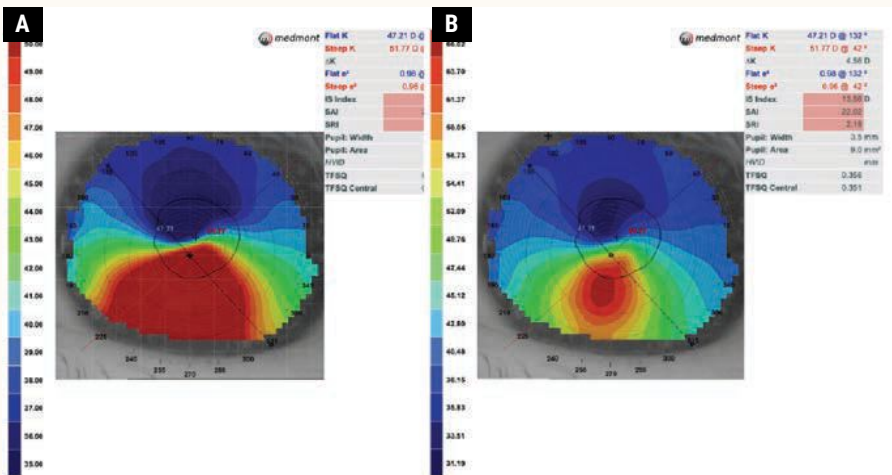
**Credit Statement:** This course is COPE-approved for two hours of CE credit. Activity #126680 and course ID 86588-GO. Check with your local state licensing board to see if this counts toward your CE requirement for relicensure.

**Disclosure of Unlabeled Use:** This educational activity may contain discussion of published and/or investigational uses of agents that are not indicated by the FDA. The planners of this activity do not recommend the use of any agent outside of the labeled indications. The opinions expressed in the educational activity are those of the faculty and do not necessarily represent the views of the planners. Refer to the official prescribing information for each product for discussion of approved indications, contraindications and warnings.

**Disclaimer:** Participants have an implied responsibility to use the newly acquired information to enhance patient outcomes and their own professional development. The information presented in this activity is not meant to serve as a guideline for patient management. Any procedures, medications or other courses of diagnosis or treatment discussed or suggested in this activity should not be used by clinicians without evaluation of their patient's condition(s) and possible contraindications and/or dangers in use, review of any applicable manufacturer's product information and comparison with recommendations of other authorities.



**Fig. 1.** Same axial map scan of (A) normal, spherical cornea and (B) regular astigmatic cornea with different scaling: The color scale represents the power in Diopters at each particular point. In (A), the K Scale and Standard Power color maps show a uniform green/yellow pattern compared to a Normalized Power scale, which shows a gradient with multiple colors and a large red area. At first glance, it may be easy to assume that the third topography map is irregular and steep due to the predominantly red presentation. However, the scale setting used maxes out at 44.60 diopters which correlates with the dark red color. In (B), the K scale shows a mild classic, with-the-rule topography pattern but appears spherical in the standard power. The astigmatic pattern is much more pronounced in the Normalized scaling. It is thus important to take note of the scaling range as it is much broader in the standard scale compared to the normalized scale.



**Fig. 2.** Same axial map with different scaling in an irregular cornea: Initially using the default Standard Power scaling (a), it is apparent that the patient has keratoconus, but the scale only goes up to 50.00D, while the steep K-reading itself exceeds this value at 51.77D. Once the scale is adjusted to Normalized Power (b), the map reveals a steeper and more condensed cone compared with the Standard Power scale.

cornea as a reference. The best-fit sphere on an elevation map may be centered on the corneal apex, shifted to the line of sight, tilted, in contact with, or floating through the measured corneal surface.

Some corneal topography devices allow other modifications to the best-fit shape, such as choosing sphere diameter or even selecting a non-spherical shape such as a torus. Deviation values from

the best-fit sphere are measured and displayed in microns, allowing areas of relative elevation or depression to be identified.

### Importance of Scaling

Color scales in corneal topography represent different measurements (e.g., curvature, elevation, power). The color spectrum used varies by brand and model but generally ranges from cool to warm colors, each corresponding to a specific value range.

Warmer colors (orange/red) tend to indicate higher values, while cooler colors (indigo/blue) indicate lower ones. Values are selected from each map, such as diopters and mm of curvature for Axial and Tangential, and microns for Elevation. The maps are color-coded, and even customizable: “fine scaling” shows color changes in 0.5 D steps, whereas “rough scaling” can be  $\geq 2.0$  D per step.

The main scales are as follows:

- *Absolute Scale:* uses fixed color-coding that is the same for all patients and exams, allowing for consistent comparison between different exams or different patients.

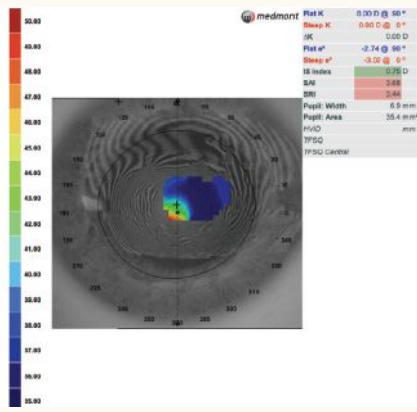
- *Normalized (Relative or Adaptive) Scale:* matches color coding to a specific patient’s measurements, helping to highlight subtle differences in that patient’s cornea. However, this scale makes comparisons between patients, and even the same patient, at different time points more difficult.

- *User-Defined Scale:* some topographers allow users to define their color scale, thus customizing it to specific needs or preferences.

- *Standardized Scale:* recommended by organizations like the American National Standards Institute (ANSI) and commonly used for scientific research.

Pro tip: Normalized scales often overemphasize the blue/green or orange/red colors on the corneal topography, depending on the condition diagnosed. Failure to carefully review this information can lead to an incorrect diagnosis. Achieving an accurate representation relies on selecting the appropriate scale (Figures 1 and 2).





**Fig. 3. Poor scan quality due to an unstable tear film. Irregularities of the mires and area with incomplete data collection do not allow a reliable diagnosis.**

### Evaluating Scan Quality

The corneal topography's precision depends on image quality. High-quality scans have full coverage of the cornea (dependent on topographer cone size), are well-centered and have no missing or extrapolated data.

Artifacts such as eyelashes, reflections or tear film abnormalities can lead to inaccurate data interpretation. Poor fixation leading to decentered images, patient motion causing smearing of mires and incomplete data capture can also degrade scan quality. If the mires—particularly near the center—are distorted, the data is unreliable (Figure 3).

Furthermore, it is important to ensure the patient blinks sufficiently between scans to maintain the tear film, as a dry ocular surface can significantly impact the measurements. Although this tear film dependency may be the cause of variability, it allows for non-invasive measurement of tear film quality. Many topographers have quality score metrics, indicating errors due to acquisition, position, blinking, and fixation. However, severe corneal irregularities can deform the cornea so much that high-quality scans are no longer possible.

### Corneal Topography in Contact Lens Management

Corneal topography is the cornerstone of contact lens management, particularly for fitting complex corneas and specialty contact lenses, but it is also valuable for

any contact lens. Its maps help determine the appropriate lens design, base curve, diameter and power. Axial maps are ideal for base curve selection of a corneal GP, hybrid or soft contact lens as it portrays the average central curvature.

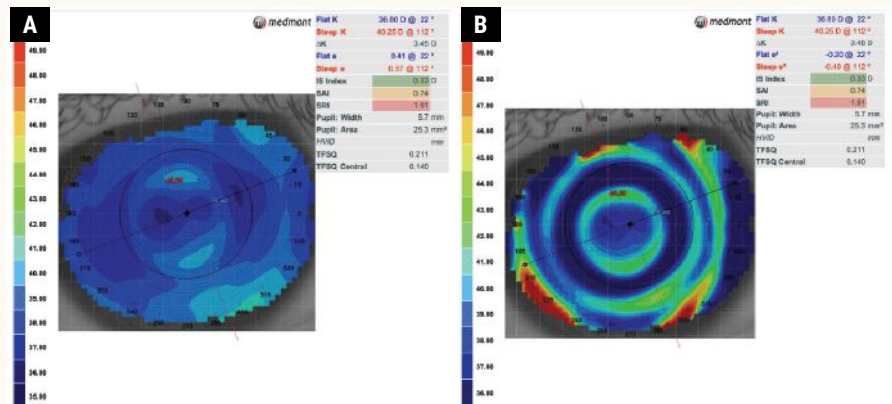
Contact lens optics can be evaluated using tangential map displays while the lens is on the eye, which is particularly useful for patients wearing a multifocal lens to assess the exact optics position in the line of sight. The display shows the lens power over the cornea, allowing the examiner to closely monitor the optics position to get a better clinical idea of optical performance (Figure 4). This map is also sensitive to changes in corneal curvature caused by contact lens warpage.

Comparative, difference or subtractive maps can be used to identify corneal effects and correlate complaints such as

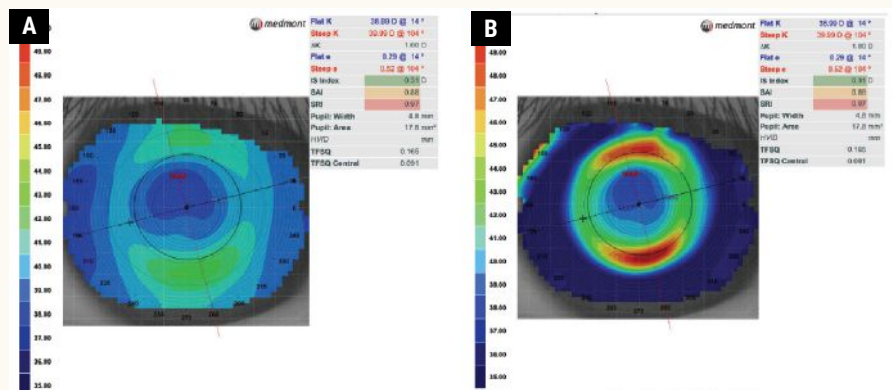
optical blurring after contact lens wear. Flattening of the corneal topography occurs in patients with hyperopic shifts after wearing a contact lens. With this data, the lens can be modified with a steeper base curve to reduce corneal deformation and the associated blurring of the glasses.

Additionally, tangential maps are beneficial in ortho-K, especially when evaluating the peripheral corneal shape (Figure 5). It also guides post-wear centration analysis. Difference maps can be used to compare a baseline scan to the treatment map and show accurate lens positioning (Figure 6). The lens's position and fit are accurately displayed by resetting the scale proportionately to the amount of myopia corrected.

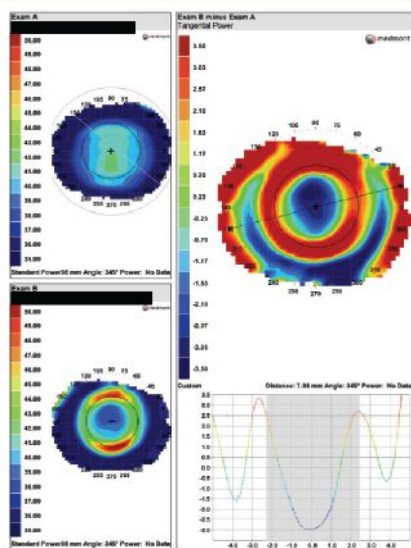
The elevation display map helps selecting the optimal ortho-K lens design. When there is an elevation difference



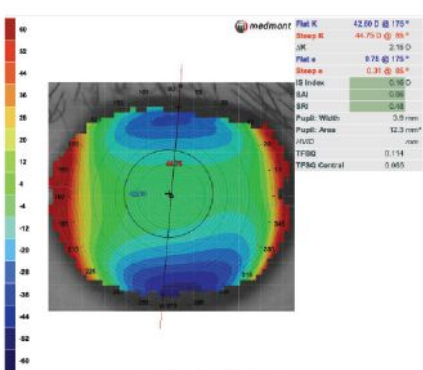
**Fig. 4. Axial (A) and tangential (B) power maps of a patient wearing a multifocal soft lens for myopia control. The tangential map provides a detailed overview of the lens centration.**



**Fig. 5. Axial power map (A) and tangential power map (B) of a patient treated with orthokeratology. The axial map provides data on the corneal astigmatism type and corneal curvature power. A tangential map allows the visualization of the corneal curvature in one place relative to neighboring tangential points. This is most helpful when analyzing orthokeratology lens centration.**



**Fig. 6. Comparison of post and pre-wear topography scans to highlight changes in corneal shape caused by orthokeratology lenses. The scale was reset for this -3.50D myope's tangential difference map. The lens is centered and there is -3.50D of treatment.**



**Fig. 7. In this case, the patient exhibits a limbus-to-limbus astigmatic pattern with a corneal cylinder exceeding 2.00D and an average elevation difference greater than 30µm between the steep and flat meridians. These findings indicate that a toric ortho-K lens design would yield a more favorable outcome for this patient.**

of 30µm or greater at the 8mm chord between the principal meridians, it indicates that a toric lens is better suited for correct lens alignment and centering (Figure 7).<sup>1</sup> It can also be used for an irregular cornea, especially when deciding between a corneal or scleral lens.

As corneal irregularities increase, the surface will likely become more asymmetrical, preventing symmetric lenses

from conforming to the surface. Individuals with an elevation difference between the highest and lowest point of elevation greater than 350µm will likely need a scleral lens since the level of difference causes the corneal gas permeable (GP) lens to be unstable on the eye (Figure 8).<sup>2</sup> In this way, corneal topography can guide lens selection. In this case, scleral lenses will be used to vault the cornea and achieve a successful fit.

Lens fitting software allows simulation of a contact lens on the ocular surface and to facilitate empirical lens orders. More advanced software can allow this surface data to be used to create freeform lenses incorporating the corneal shape.

### Dry Eye Disease

Before initiating contact lens wear, the noninvasive tear break-up test, available on many Placido disc topographers, can assess tear film stability, a vital metric as successful contact lens wear relies on a healthy tear film.

When performing topography over the contact lens, the tear break-up display can determine the surface wettability of the lens. This display provides a quantitative score to monitor tear film stability while wearing contact lenses.

### Detecting Corneal Disease

By capturing detailed measurements of the corneal surface, topography goes beyond traditional clinical examinations. Advanced imaging enables precise analysis of the cornea's shape, curvature and regularity, allowing for early detection and diagnosis of various corneal diseases.

A quintessential example is keratoconus. Patient history may give warning signs, such as complaints of ghosting, frequent prescriptions changes, difficulty with contact lens wear, asymmetric vision, and glare, flare, streaks, halos, and vision that is worse at night, or they may suffer from diseases or conditions that put them at higher risk for developing keratoconus such as floppy eyelid syndrome, sleep apnea, or Down, Marfan or Ehlers-Danlos syndrome.

Other warning signs include patients who frequently rub their eyes and those with a family history of keratoconus.<sup>3,4</sup>

Clinically, several signs can help determine if topography is warranted. Autorefraction and autokeratometry may reveal high astigmatism and steep keratometry readings on an oblique or against-the-rule axis due to corneal irregularities. Retinoscopy may show a scissor reflex, and manifest refraction may be challenging with reduced visual acuity.

Slit lamp examination may appear normal, but in moderate to severe keratoconus, the presence of Vogt's striae, Fleischer's ring or Munson's sign may be evident. When any of these clinical findings and medical history are present, topography is necessary to confirm the suspicion of disease.

### Early Detection in Pediatric Patients

Keratoconus has been observed in children as young as age four and progresses significantly faster than in adults.<sup>5</sup> Studies suggest that children with keratoconus have more severe disease at diagnosis, with 27.8% classified as stage 4 as opposed to 7.8% in adults.<sup>6</sup> This may be attributed to the early onset, rapid progression and the challenges associated with conducting comprehensive eye exams in children.

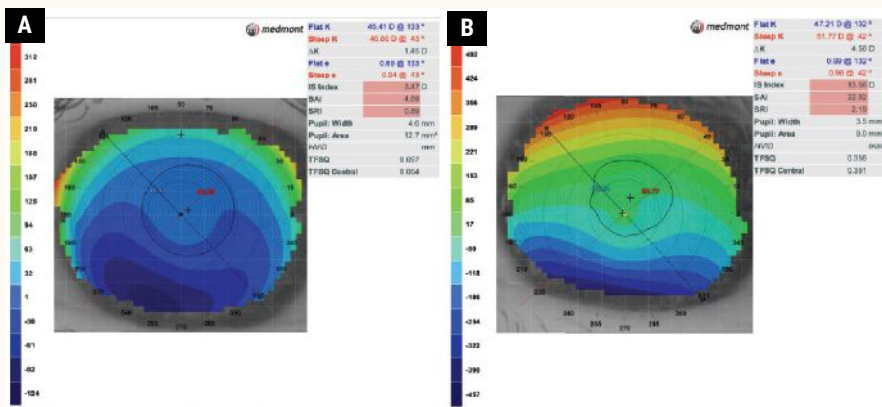
Patients with early-stage keratoconus, particularly children, often exhibit anisometropia and a high degree of cylinder and asymmetric astigmatism. Given these factors and the information discussed above, corneal topography screening may be helpful in all pediatric patients.

Topography reveals the cornea's shape, curvature and regularity, which aids in the early detection of subtle corneal irregularities and allows for timely intervention, thereby mitigating the impact of keratoconus on a child's vision. For pediatric patients not correctable to 20/20, amblyopia cannot be diagnosed without corneal topography. Only in the absence of corneal pathology can amblyopia be confirmed.

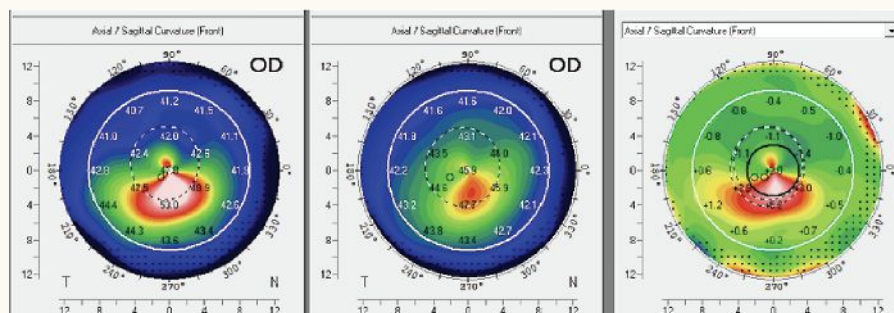
### Indices and Monitoring

Corneal topography has demonstrated remarkable sensitivity in detecting ectatic disease even before the loss of vision





**Fig. 8. Elevation maps of two corneas with keratoconus: (A) shows an elevation difference of ~150µm from the highest to lowest elevation point vs. (B) an elevation difference of over 600µm. This suggests that a GP is much more likely to be successful in (A), whereas a scleral lens is more likely to be successful in (B).**



**Fig. 9. Scheimpflug-based imaging system to generate an axial map of a 14-year-old female patient who underwent CXL in her right eye. Following a 10-month post-CXL evaluation, the difference map reveals a significant increase of 5D in Kmax, indicating corneal steepening and progression. Consequently, the patient underwent a subsequent round of CXL treatment to enhance corneal stability.**

and significant slit-lamp exam findings manifest. While keratoconus is identified by the distinctive topographical pattern of inferior steepening, other signs may also raise suspicion.

Topography metrics for the diagnosis of keratoconus have been studied extensively. Much of the early work was performed by Rabinowitz and Klyce.<sup>7,8</sup> Various indices, such as Rabinowitz and McDonnell's inferior-superior asymmetry, are commonly used for keratoconus detection. Indicators raising suspicion of keratoconus include corneal curvature greater than 47.2D and greater than 1.4D asymmetry between the 3mm radius values of the superior and inferior corneal regions.<sup>7,9</sup>

Close monitoring of these parameters at regular follow-up visits every one to three months is critical in pediatric patients, as rapid disease progression

may occur in this age group. Early detection of keratoconus allows for timely treatments, such as corneal collagen crosslinking (CXL), halting the disease progression. CXL is currently FDA-approved for patients with unstable keratoconus.

Regular topographic monitoring in keratoconus patients and post-CXL follow-up visits is essential for several reasons. It helps identify signs of disease progression that may require additional interventions to prevent further vision deterioration. It also aids in assessing the effectiveness of interventions such as CXL by providing objective measurements of corneal changes. Additionally, it helps optimize visual outcomes by guiding the selection of appropriate corrective measures, such as contact lenses or refractive surgeries, based on the evolving corneal topographic patterns.

In the long-term management of keratoconus, topography allows for precise monitoring of disease progression, assessment of treatment outcomes and timely implementation of appropriate interventions (Figure 9).

## Pre- and Post-op Management of Refractive and Cataract Surgery

Preoperatively, corneal topography helps identify patients with subtle irregular astigmatism who may be at higher risk of postoperative complications. Used this way, clinicians can determine if a patient is not a suitable candidate for corneal refractive surgery.

It is important to note that though topography can provide information about the anterior cornea, it is inadequate for determining the candidacy for or planning of a cornea refractive procedure. In this way, topography is only used to screen out obvious non-candidates. Corneal tomography is considered the standard of care for refractive surgery evaluation, and the differences will be explained in the next section.

Topography also detects ocular surface irregularities due to dry eye or epithelial basement membrane disease, indicating that the surface may need to be normalized or optimized to obtain the best vision post-surgery.

Postoperatively, corneal topography can assess a procedure's success by comparing pre- and post-operative maps, which show changes in corneal shape, regularity and astigmatism. Additionally, it supports the diagnosis of possible complications such as post-operative ectasia or decentered ablation after refractive surgery.

## Advances in Corneal Assessment and Combo Devices

The first commercial topographer was introduced over 30 years ago, and its value has stood the test of time. Combined with other technologies, its capabilities expanded, resulting in more powerful diagnostic devices. The following technologies are frequently combined with topography.

Color imaging with variable color illumination expands the possibilities for



**TABLE 2. CONSIDERATIONS FOR TOPOGRAPHY TO SCREEN FOR KERATOCONUS**

<b>Refractive asymmetry</b>	Differences in the amount and orientation of astigmatism between eyes
<b>Retinoscopy</b>	Irregular reflex
<b>Refraction</b>	Against the rule, or oblique axis, monocular diplopia, refractive cyl of 2.00D or more, increase in astigmatism or myopic shift over time, reduced best-corrected visual acuity
<b>Autorefraction</b>	Against the rule or oblique axis, cylinder >2.00D, error messages
<b>Autokeratometry</b>	Difference >2.00D between K1 and K2, error messages
<b>Slit lamp</b>	Apical thinning, Fleischer’s ring, warped beam
<b>History</b>	Aggressive eye rubbing, family history, medical history of connective tissue disorders

anterior segment photography where diffuse white light illumination can serve general purposes. Cobalt blue helps assess sodium fluorescence and infrared illumination captures images of the meibomian glands. This may include video modes, and with sophisticated software, there are objective metrics to quantify bulbar injection, pupil size, tear meniscus height and more.

Another popular combined device is a wavefront aberrometer, which measures the objective optics of the total eye. When combined with topography, the source of aberration can be located by differentiating the corneal surface from the internal eye. Another increasingly relevant combination is optical biometry. The growing adoption of myopia management has made measuring axial length a necessity and many of the treatments, soft lenses and ortho-K require corneal topography to be successful.

The next evolution of corneal evaluation provides more comprehensive metrics. Corneal tomography, emphasis on the “M,” is the new gold standard for corneal evaluation, with device availability for over 20 years. It was predominantly adopted by corneal and refractive surgeons but is commonly used today due to its utility.

Corneal topography measures only the anterior surface of the cornea, while tomography systems enable measurement of anterior, posterior and global corneal thickness. Various technologies are used to capture corneal tomography. Scheimpflug imaging involves a rotating Scheimpflug camera that captures

cross-sectional images of the cornea. By analyzing these images, Scheimpflug imaging provides a three-dimensional evaluation of the corneal surfaces, both anterior and posterior, enabling precise measurements of curvature, elevation, and global pachymetry distribution.

Combined with sophisticated multi-metric analysis software and normative databases, exceptionally sensitive and specific analyses can be performed for refractive surgery screening or keratoconus progression analysis.

Initially developed for retinal imaging, optical coherence tomography (OCT) technology has been adapted for corneal evaluation. By employing low-coherence interferometry, OCT provides high-resolution cross-sectional images of the cornea, allowing visualization of the corneal layers and precise measurement of their thickness.

An underused technology, high-resolution ultrasound, has the advantage of deep tissue penetration facilitating assessment of the posterior sulcus, helpful in refractive surgery planning for phakic IOL implantations such as the Evo ICL. These advanced imaging techniques have greatly improved our understanding of corneal pathologies and our ability to assess corneal and refractive surgery.

Corneal tomography systems provide much more comprehensive corneal analysis. However, cost is a significant barrier to adoption. While they offer significantly more, making a comparison of the two systems inappropriate, they tend to be more expensive than their Placido ring-based counterparts.

That said, multiple systems are combined with Placido-based corneal topographers to provide even more data that cannot be obtained with tomography alone, such as mire imaging and tear film analysis. Topography is still and may always be relevant as it is inexpensive, extremely useful and easy to apply, making it a must have for every clinic.

**Takeaways**

Corneal topography provides a wealth of information about the anterior cornea and tear film. With a clear understanding of its capabilities and limitations, clinicians can use corneal topography to guide them in providing superior patient care. Since its introduction nearly 30 years ago, prices have become so affordable that every doctor should have access to this technology and, more importantly, use it frequently. ■

1. Kojima R, Caroline P, et al. Should all orthokeratology lenses be toric? Poster presented at the 2016 GSLS, Jan. 2016, Las Vegas.
2. Zheng F, Caroline P, Kojima R, et al. Corneal elevation differences and the initial selection of corneal and scleral contact lens. Poster presented at the 2015 Global Specialty Lens Symposium, January 2015, Las Vegas.
3. Woodward MA, Blachley TS, Stein JD. The association between sociodemographic factors, common systemic diseases, and keratoconus: an analysis of a nationwide health care claims database. *Ophthalmology*. 2016;123(3):457-65.
4. Merdlar I, Hassidim A, Sorkin N, et al. Keratoconus and allergic diseases among Israeli adolescents between 2005 and 2013. *Cornea*. 2015;34(5):525-9.
5. Mukhtar S, Ambati BK. Pediatric keratoconus: a review of the literature. *Int Ophthalmol*. 2018;38(5):2257-66.
6. Léoni-Mesplé S, Mortemousque B, Touboul D, et al. Scalability and severity of keratoconus in Children. *Am J Ophthalmol*. 2012;154(1):56-62.e1.
7. Rabinowitz YS, McDonnell PJ. Computer-assisted corneal topography in keratoconus. *Refract Corneal Surg*. 1989;5(6):400-8.
8. Wilson SE, Klyce SD. Advances in the analysis of corneal topography. *Surv Ophthalmol*. 1991;35(4):269-77.
9. Maeda N, Klyce SD, Smolek MK. Comparison of methods for detecting keratoconus using videokeratography. *Arch Ophthalmol*. 1995;113(7):870-4.

## OPTOMETRIC STUDY CENTER QUIZ

To obtain CE credit through the Optometric Study Center, complete the test form on the following page and return it with the \$35 fee to: Jobson Healthcare Information, Attn.: CE Processing, Jobson Healthcare Information, LLC/WebMD, 283-299 Market Street, 2 Gateway Center, 4th Floor, Newark, NJ 07102. To be eligible, please return the card within three years of publication. You can also access the test form and submit your answers and payment via credit card online at [revieweducationgroup.com](http://revieweducationgroup.com). You must achieve a score of 70 or higher to receive credit. Allow four weeks for processing. For each Optometric Study Center course you pass, you earn two hours of credit. Please check with your state licensing board to see if this approval counts toward your CE requirement for relicensure.

- 1. Placido disc-based systems used in corneal topography rely on the reflection of which of the following?**
  - a. Concentric rings.
  - b. Slit beam of light.
  - c. Scattered light.
  - d. Infrared waves.
- 2. Which of the following techniques captures images of both the anterior and posterior surfaces of the cornea?**
  - a. Placido disc-based systems.
  - b. Scheimpflug imaging.
  - c. Slit scanning.
  - d. All of the above.
- 3. The accuracy of axial maps in corneal topography may be compromised compared with other power maps because they:**
  - a. Overestimate the degree of steepening in the peripheral cornea.
  - b. Underestimate the degree of steepening in the central cornea.
  - c. Average out data to create a "smooth" map.
  - d. Provide distorted reflections of the corneal surface.
- 4. Tangential maps in corneal topography are useful for evaluating which of the following?**
  - a. Corneal thickness.
  - b. Corneal curvature at various points.
  - c. Tear film quality.
  - d. Corneal irregularities in peripheral regions.
- 5. The accuracy of axial maps in placido-based corneal topography may be compromised when measuring corneal power and shape due to their reliance on which of the following?**
  - a. Tear film quality.
  - b. Iris structure.
  - c. Pupil size.
  - d. Lens position.
- 6. Corneal topography can be used to monitor the success and detect complications following which surgical procedure?**
  - a. LASIK.
  - b. Cataract surgery.
  - c. Retinal detachment surgery.
  - d. Glaucoma surgery.
- 7. Regular topographic monitoring is important in patients with keratoconus to:**
  - a. Detect retinal abnormalities.
  - b. Assess ocular surface irregularities.
  - c. Monitor disease progression.
  - d. Evaluate tear film stability.
- 8. Corneal topography provides a comprehensive evaluation of the cornea, including measurements of which of the following?**
  - a. Shape.
  - b. Curvature.
  - c. Elevation.
  - d. All of the above.
- 9. Monitoring corneal curvature exceeding 47D, axis skew greater than 20°, and asymmetry in the upper and lower corneal regions can raise suspicion for which of the following?**
  - a. Dry eye syndrome.
  - b. Keratoconus.
  - c. Retinal detachment.
  - d. Glaucoma.
- 10. Which of the following can cause an artifact on corneal topography?**
  - a. Lashes.
  - b. Nose bridge.
  - c. Poor tear film.
  - d. All of the above.
- 11. What type of corneal map is valuable in detecting corneal protrusions or depressions?**
  - a. Axial maps.
  - b. Tangential maps.
  - c. Elevation maps.
  - d. Refractive asymmetry maps.
- 12. Corneal topography plays a role in the detection and diagnosis of various corneal conditions at their \_\_\_\_ stages.**
  - a. Latest.
  - b. Earliest.
  - c. Final.
  - d. Intermediate.
- 13. What is the significance of regular topographic monitoring in keratoconus patients?**
  - a. To assess tear film quality.
  - b. To determine contact lens powers.
  - c. To detect changes in disease progression.
  - d. All of the above.
- 14. Which type of map is most beneficial in monitoring the treatment zone and centration of ortho-K?**
  - a. Axial map.
  - b. Tangential map.
  - c. Elevation map.
  - d. Tear break-up display.
- 15. How does topography contribute to the long-term management of post-CXL treatment?**
  - a. It helps identify the effectiveness of CXL.
  - b. Guides the selection of appropriate corrective measures such as contact lenses or refractive surgeries.
  - c. It enables precise monitoring of disease progression.
  - d. All of the above.
- 16. Which of the following is a limitation of Placido ring-based corneal topography?**
  - a. Inability to measure the posterior corneal surface.
  - b. Limited coverage of the peripheral cornea.
  - c. Inconsistent measurements in patients with irregular cornea.
  - d. All of the above.
- 17. Why is measuring the posterior corneal surface important in corneal topography?**
  - a. It helps in detecting tear film abnormalities.
  - b. It aids in identifying subtle changes in the anterior cornea.
  - c. It can help diagnose conditions like corneal ectasia and early signs of keratoconus.
  - d. It provides information about global corneal thickness.
- 18. Which of the following keratoconus signs is visible with the naked eye (i.e., no additional instrumentation)?**
  - a. Munson's sign.
  - b. Vogt's striae.
  - c. Scissoring reflex.
  - d. Higher order aberrations.
- 19. Corneal topography is capable of measuring which of the following?**
  - a. Anterior corneal surface.
  - b. Posterior corneal surface.
  - c. Global corneal thickness.
  - d. All of the above.
- 20. Collagen crosslinking is FDA-approved in which of the following patients?**
  - a. Myopic progression.
  - b. Stable keratoconus.
  - c. Unstable keratoconus.
  - d. Pediatric keratoconus.

### Examination Answer Sheet

*The Definitive Guide to Corneal Topography*

Valid for credit through September 15, 2026

**Online:** This exam can be taken online at [revieweducationgroup.com](http://revieweducationgroup.com). Upon passing the exam, you can view your results immediately and download a real-time CE certificate. You can also view your test history at any time from the website.

**Directions:** Select one answer for each question in the exam and completely darken the appropriate circle. A minimum score of 70% is required to earn credit.

**Mail to:** Jobson Healthcare Information, LLC/WebMD, 283-299 Market Street, 2 Gateway Center, 4th Floor, Newark, NJ 07102.

**Payment:** Remit \$35 with this exam. Make check payable to Jobson Healthcare Information, LLC.

**Credit:** This course is COPE-approved for two hours of CE credit. Course ID 86588-GO.

**Processing:** There is a four-week processing time for this exam.

Jointly provided by PIM and the Review Education Group.

**Answers to CE exam:**

**Post-activity evaluation questions:**

1. (A) (B) (C) (D)
2. (A) (B) (C) (D)
3. (A) (B) (C) (D)
4. (A) (B) (C) (D)
5. (A) (B) (C) (D)
6. (A) (B) (C) (D)
7. (A) (B) (C) (D)
8. (A) (B) (C) (D)
9. (A) (B) (C) (D)
10. (A) (B) (C) (D)
11. (A) (B) (C) (D)
12. (A) (B) (C) (D)
13. (A) (B) (C) (D)
14. (A) (B) (C) (D)
15. (A) (B) (C) (D)
16. (A) (B) (C) (D)
17. (A) (B) (C) (D)
18. (A) (B) (C) (D)
19. (A) (B) (C) (D)
20. (A) (B) (C) (D)

Rate how well the activity supported your achievement of these learning objectives. 1=Poor, 2=Fair, 3=Neutral, 4=Good, 5=Excellent

21. Recognize the role of corneal topography in optometric practice. (1) (2) (3) (4) (5)
22. Effectively use this tool in contact lens management. (1) (2) (3) (4) (5)
23. Employ corneal topography for the detection of corneal disease. (1) (2) (3) (4) (5)
24. Correctly use corneal topography for pre- and postoperative management. (1) (2) (3) (4) (5)
25. Based upon your participation in this activity, do you intend to change your practice behavior? (Choose only one of the following options.)
  - (A) I do plan to implement changes in my practice based on the information presented.
  - (B) My current practice has been reinforced by the information presented.
  - (C) I need more information before I will change my practice.
26. Thinking about how your participation in this activity will influence your patient care, how many of your patients are likely to benefit? (please use a number):
27. If you plan to change your practice behavior, what type of changes do you plan to implement? (Check all that apply.)
 

(A) Apply latest guidelines	(D) Change in current practice for referral	(G) More active monitoring and counseling
(B) Change in diagnostic methods	(E) Change in vision correction offerings	(H) Other, please specify: _____
(C) Choice of management approach	(F) Change in differential diagnosis	
28. How confident are you that you will be able to make your intended changes?
  - (A) Very confident
  - (B) Somewhat confident
  - (C) Unsure
  - (D) Not confident
29. Which of the following do you anticipate will be the primary barrier to implementing these changes?
 

(A) Formulary restrictions	(D) Insurance/financial issues	(G) Patient adherence/compliance
(B) Time constraints	(E) Lack of interprofessional team support	(H) Other, please specify: _____
(C) System constraints	(F) Treatment related adverse events	
30. Additional comments on this course: \_\_\_\_\_

**Please retain a copy for your records. Please print clearly.**

First Name

Last Name

E-Mail

The following is your:  Home Address  Business Address

Business Name

Address

City  State

ZIP

Telephone #  -  -

Fax #  -  -

OE Tracker Number

**Rate the quality of the material provided:**  
 1=Strongly disagree, 2=Somewhat disagree,  
 3=Neutral, 4=Somewhat agree, 5=Strongly agree

31. The content was evidence-based.  
 (1) (2) (3) (4) (5)

32. The content was balanced and free of bias.  
 (1) (2) (3) (4) (5)

33. The presentation was clear and effective.  
 (1) (2) (3) (4) (5)

By submitting this answer sheet, I certify that I have read the lesson in its entirety and completed the self-assessment exam personally based on the material presented. I have not obtained the answers to this exam by any fraudulent or improper means.

Signature \_\_\_\_\_ Date \_\_\_\_\_ Lesson 124121 RO-OSC-0923





Rue des Français  
**Frenchmen Street**

*laissez les bon  
 temps rouler*

**ACADEMY**  
**NEW 23**  
**ORLEANS**  
**OCTOBER 11-14**



# MEET US IN THE BIG EASY

*Online registration ends October 7.*



# ALWAYS ON

CooperVision® **MyDay Energys®** and **Biofinity Energys®** contact lenses offer extraordinary comfort for today's lifestyles<sup>1</sup>

As Americans spend a significant portion of their days fixated on digital devices,<sup>2</sup> they are frequently experiencing digital eye strain.<sup>3</sup> Today, there are contact lenses specifically designed to address eye tiredness and dryness, providing incredible comfort in an "always on" world.

CooperVision® **MyDay Energys®** and **Biofinity Energys®** are the first and only contact lenses combining an innovative aspheric design and material technology to help with eye tiredness

and dryness associated with digital eye strain. The **DigitalBoost™** single vision aspheric design delivers a +0.3D boost of power that may help ease strain on eye muscles so the wearer can shift focus from on screen to off screen with less effort.<sup>4+</sup> **Aquaform® Technology** hydrates contact lenses to twice their weight in water for natural wettability<sup>5</sup> and incredible comfort, which can help eyes feel less dry, even during times of reduced blinking.



CooperVision® **MyDay Energys®** and **Biofinity Energys®** are ideal go-to choices for high-performing contact lenses, designed for what your patients need today.<sup>1,2</sup>

LEARN MORE



SPONSORED CONTENT



## THE RESULTS ARE IN

### MyDay Energys®



Wearers rated MyDay Energys® **4.5 out of 5** for all-day comfort<sup>6</sup>



**9 out of 10** wearers agreed that they experienced clear, reliable vision while wearing MyDay Energys®<sup>6†</sup>



More than **8 out of 10** contact lens wearers agreed that they experienced an improvement in eye tiredness while wearing MyDay Energys®<sup>6∞</sup>



**99.5%** of wearers experienced an acceptable fit with MyDay Energys®<sup>6</sup>



*“MyDay Energys® is definitely a game-changing lens.<sup>7</sup> DigitalBoost™ helps with eye tiredness and Aquaform® Technology can help eyes feel less dry when using digital devices, giving them the relief they deserve to have all day, every day.”*

– Nikki Iravani, OD



Dr. Nikki Iravani

### Biofinity Energys®



Wearers rated Biofinity Energys® **9 out of 10** for overall comfort<sup>8</sup>



Patients experiencing symptoms of digital eye strain had high **overall satisfaction** with their level of eye tiredness<sup>±</sup> and dryness<sup>§</sup> when wearing Biofinity Energys®<sup>9</sup>



**4 out of 5** patients experiencing symptoms of digital eye strain would recommend Biofinity Energys® to friends or family after trialing the lens<sup>9#</sup>



**3 out of 4** patients who were new to Biofinity Energys® went on to purchase the lens after trial<sup>10</sup>



*“Biofinity Energys® is our go-to monthly spherical contact lens.<sup>11</sup> We are fitting all patients who prefer the monthly modality into this lens whether they are complaining of digital eye strain or not.”*

– Andrew Neukirch, OD



Dr. Andrew Neukirch

\* US monthly single vision lens. †Based on a statistically significant difference of the mean change in Accommodative Microfluctuations and when compared to a lens without DigitalBoost™/ Digital Zone Optics® after reading on an iPhone 5 for 20 minutes held at a distance of 25 cm. Study conducted with Biofinity Energys and sphere. ‡ Top 2 Box: 90%. ∞ Top 2 Box: 82%. ± Average Rate 8.7/10. § Average Rate 8.5/10. #84% went on to recommend to family and friends. 1. CVI data on file 2023. US in market assessment survey conducted by 23 ECPs: n=207 habitual contact lens patients refit into MyDay Energys® contact lenses after one week of daily wear. ECPs Top 2 Box: 100%. 2. The Nielsen Company, The Nielsen Total Audience Report, Time Flies: U.S. Adults Now Spend Nearly Half a Day Interacting with Media (nielsen.com). 3. 2017 YouGov Digital Device Usage and Your Eyes Report, self-reported findings from the US, UK, and Australia. 4. Kajita M et al. Changes in accommodative micro-fluctuations after wearing contact lenses of different optical designs. Cont Lens Ant Eye (2020) In Press <https://doi.org/10.1016/j.clae.2020.03.003>. 5. CVI data on file 2022. 6. CVI data on file 2023. US in market assessment survey conducted by ECPs: n=207 habitual contact lens patients refit into MyDay Energys® contact lenses after one week of daily wear. 7. CVI data on file 2021. US in market assessment survey conducted by 15 ECPs: fitting 10 patients each into Biofinity Energys®. Response to “How would having the Biofinity Energys® technology available in a 1-day contact lens impact your practice?” 8. CVI data on file 2022. US in market assessment survey conducted by ECPs: N=150, patients wearing Biofinity Energys® contact lenses. 9. CVI data on file 2022. US in market assessment survey conducted by ECPs: N=62, habitual contact lens patients refit and new contact lens patients fit into Biofinity Energys® contact lenses after one week of wear and currently experiencing digital eye strain. 10. CVI data on file 2022. US in market assessment survey conducted by ECPs: N=83, habitual contact lens patients refit and new contact lens patients fit into Biofinity Energys® contact lenses after one week of wear. 11. CVI data on file 2022. US in market assessment survey conducted by 15 ECPs: N=150, Patients wearing Biofinity Energys® contact lenses. New wearers wore contact lenses for one week. ECPs post-IMA Top 2 Box: 87%. 12. CooperVision data on file 2019. Randomized, double-masked, crossover study, habitual CL wearers fitted with Biofinity for 1/12 then MyDay for 1/52. N=55. ©2023 CooperVision 14808 6/23





BY PAUL M. KARPECKI, OD  
CHIEF CLINICAL EDITOR

## OCULAR SURFACE REVIEW

# Call the Exterminator

A new eye drop, Xdemvy, shows positive results in wiping out the unusually common condition known as *Demodex* blepharitis.

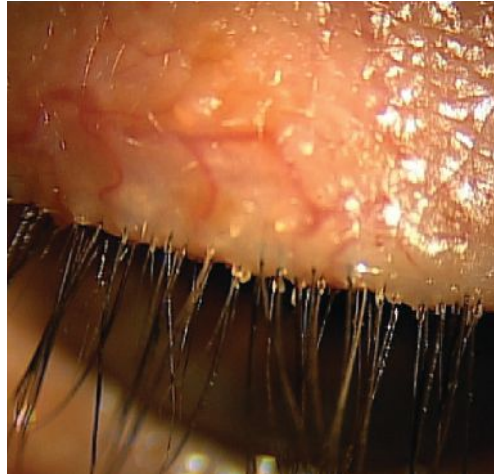
**W**e're in the early days of the rollout of Xdemvy (lotilaner ophthalmic solution 0.25% Tarsus), the first FDA-approved prescription medication for *Demodex* blepharitis, a condition that affects at least 25 million Americans.<sup>1</sup> Despite its pervasive nature, *Demodex* blepharitis is an underdiagnosed disease, but fortunately with easy to identify pathognomonic clinical signs and a host of symptoms.

Let's dive into this condition, what signs to look for and the new treatment poised to wipe out *Demodex*.

### What is *Demodex* Blepharitis?

*Demodex* is the most common ectoparasite found in humans, with prevalence rates as high as 58% of all patients.<sup>1</sup> It is also the cause of about seven out of 10 cases of blepharitis.<sup>1-3</sup> The *Demodex* mite has two forms: *Demodex folliculorum* and *Demodex brevis*. The first, *D. folliculorum*, tends to involve the lashes and particularly within the lash follicle itself, while *D. brevis* affects the sebaceous glands of the skin, as well as the meibomian glands of the eyelid. *D. brevis* has been implicated as a contributor to ocular rosacea.<sup>4</sup>

Studies show that 59% of all patients presenting with facial rosacea have *Demodex* blepharitis.<sup>5</sup> The condition occurs more often in contact lens wearers, with research showing that 90% are positive for *Demodex* blepharitis.<sup>6</sup> Even more startling is the fact that 93% of contact



Debris at the base of the lashes is a hallmark sign of *Demodex* blepharitis.

lens-intolerant patients were positive for *Demodex* blepharitis.<sup>1</sup>

### Diagnosis

Collarettes, or a sleeve or debris at the base of the lashes, is the hallmark sign of *Demodex* blepharitis. They are composed of mite waste products, digestive enzymes and eggs, resulting in red, irritated and itchy eyelids.<sup>3</sup> Patients might also experience dryness, grittiness and foreign body sensation. A clinician doesn't require extra tools or equipment to make the diagnosis. Simply have the patient look down while at the slit lamp and increase the magnification, as it helps you scan the base of the upper lashes.

Because it affects the meibomian glands, *Demodex* can also be associated with meibomian gland dysfunction, frequent or recurring hordeola/chalazia and evaporative DED.<sup>3,8-9</sup>

### Unique Properties

Lotilaner, the active ingredient in Xdemvy, has been used in veterinary medicine for the treatment of parasites in canines. Lotilaner is a non-competitive antagonist of parasitic gamma-aminobutyric acid-gated chloride channels; blocking these channels results in paralysis and death of the *Demodex* mite.

### FDA Approval

In the pivotal FDA clinical trials of Xdemvy, efficacy and safety was met with 415 patients in the treatment arm, with significant reductions in collarettes and erythema improvement observed as early as two weeks and at the primary endpoint, day 43. The most common adverse event was burning upon instillation in about 10% of patients.

All Xdemvy therapy takes is one drop, twice a day over a six-week period. This covers the entire lifecycle of the mite and eggs and will ensure high levels of eradication as well as enhance our patients' ocular health and quality of life. ■

1. Trattler W, Karpecki P, Rapoport Y, et al. The prevalence of *Demodex* blepharitis in US eye care clinic patients as determined by collarettes: a pathognomonic sign. *Clin Ophthalmol*. 2022;16:1153-64.

2. Zhang AC, Muntz A, Wang MTM, et al. Ocular *Demodex*: a systematic review of the clinical literature. *Ophthalmic Physiol Opt*. 2020;40(4):389-432.

3. Fromstein SR, Harthan JS, Jaymeni P, Optiz DL. *Demodex* blepharitis: clinical perspectives. *Clin Optom (Auckl)*. 2018;10:57-63.

4. Forton FMN. Rosacea, an infectious disease: why rosacea with papulopustules should be considered a demodocosis: a narrative review. *J Eur Acad Dermatol Venereol*. 2022;36(7):987-1002.

5. Gonzalez-Hinojosa D, Jaime-Villalonga A, Aguilar-Montes G, Lammoglia-Ordiales L. *Demodex* and rosacea: is there a relationship? *Ind J Ophthalmol*. 2018;66(1):36-8.

6. Jalbert I, Rejab S. Increased numbers of *Demodex* in contact lens wearers. *Optom Vis Sci*. 2015;92:671-8.

7. Tarkowski W, Moneta-Wielgos J, Mlocicki D. *Demodex* Sp. as a potential cause of the abandonment of soft contact lenses by their existing users. *Biomed Res Int*. 2015;2015:259109.

8. Liu J, Sheha H, Tseng, SCG. Pathogenic role of *Demodex* mites in blepharitis. *Curr Opin Allergy Clin Immunol*. 2010;10(5):505-10.

9. Cheng AM, Sheha H, Tseng SCG. Recent advances on ocular *Demodex* infestation. *Curr Opin Ophthalmol*. 2015;26(4):295-300.

About  
Dr. Karpecki

Dr. Karpecki is medical director for Keplr Vision and the Dry Eye Institutes of Kentucky and Indiana. He is the Chief Clinical Editor for *Review of Optometry* and chair of the New Technologies & Treatments conferences. A fixture in optometric clinical education, he consults for a wide array of ophthalmic clients, including ones discussed in this article. Dr. Karpecki's full disclosure list can be found in the online version of this article at [www.reviewofoptometry.com](http://www.reviewofoptometry.com).

# SEE WHAT LEADING DRY EYE SPECIALISTS ARE SAYING ABOUT



**Marc Bloomenstein OD, FAAO-Arizona**

"I love SleepTite/SleepRite for my office and for my patients! When I need a safe, comfortable way to keep my patient's eye(s) sealed overnight I reach for SleepTite/SleepRite. My patients with ILS issues regardless of the cause can't believe the difference SleepTite/SleepRite makes for them."

**Mile Brujic OD, FAAO- Ohio**

"Incomplete lid seal (ILS) has become an important characteristic to assess in our dry eye patients. Identifying this anatomical anomaly is critical because it is often the answer to alleviating the signs and symptoms our patients experience. SleepTite/SleepRite provides us a simple solution for these patients and provides a seal that fosters a more normal environment for these patients."



**Doug Devries OD-Nevada**

"It's shocking how many patients have morning symptoms as a result of inadequate lid seal (ILS) as a root cause of their dry eye. I've found that SleepTite/SleepRite not only dramatically reduces their symptoms, but it makes all other conventional treatments much more efficacious."

**Tracy Doll OD,FAAO-Oregon**

"SleepTite/ SleepRite is my first choice to combat morning dryness from CPAP machines in those with Obstructive Sleep Apnea. STSR does not interfere with the fit of CPAP and protects the ocular surface while the patient sleeps."



**Jackie Garlich OD, FAAO- Massachusetts**

"Incomplete lid seal is one of the easiest diagnoses to make and requires no extra equipment. When a patient experiences morning dry eye, this alerts me to look for the presence of ILS. Careful observation of this seemingly small detail can have a profound impact on the outcome of dry eye patients."

**Josh Johnston OD, FAAO-Georgia**

"Dry eye is a multifactorial and complex disease that can be challenging to treat. Incomplete lid closure is a common risk factor for dry eye patients, and it must be treated if diagnosed. SleepTite/SleepRite offers a simple and efficacious treatment option to help patients that suffer from incomplete lid seal issues."



**Paul Karpecki OD, FAAO-Kentucky**

"I have found that the number one cause of non-responsive dry eye is inadequate lid seal (ILS). The diagnosis is easy because patients have morning symptoms rather than late in the day symptoms like most dry eye. Thanks to SleepTite/SleepRite we have an extremely effective treatment that has finally relieved patient symptoms and prevents further damage to their meibomian glands."

**Jacob Lang-OD, FAAO-Minnesota**

"My patient's feedback and the improvement in their ocular health has made SleepTite/SleepRite my go to when addressing incomplete lid closure. It is safe, easy and effective."



**Walt Whitley OD, FAAO-Virginia**

"I've made the evaluation for incomplete lid seal (ILS) a part of my standard dry eye work up! Asking patients when their symptoms are worse helps me with the diagnosis. Morning symptoms are usually an indicator of ILS. SleepTite/SleepRite has become my go to treatment and has improved the quality of life for many of my OSD patients."



**SLEEPTITE/SLEEPRITE™  
ADDRESSING INADEQUATE LID SEAL (ILS)  
AND THE NOCTURNAL EVAPORATIVE  
STRESS DUE TO LID CLOSURE ISSUES.**

[www.eyesleeptite.com](http://www.eyesleeptite.com)





# The Great Masquerader

*Due to its widely varying presentation, syphilis often flies beneath the radar.*

BY EVELYNE MECHAS, OD  
CINCINNATI, OH

**A** 53-year-old male presented to the ophthalmic emergency department with flashes and painless decreased vision in the left eye for two days. He had an ocular history of lattice degeneration and an atrophic hole in the right eye. Pertinent medical history includes type 2 diabetes mellitus, for which he takes metformin 1000mg twice daily. He also disclosed occasional use of tadalafil 10mg. He reported no recent viral prodromal symptoms and had no other neurological symptoms such as headache, diplopia, numbness or weakness.

On presentation, his visual acuity was 20/20 OD and 20/70 OS. Intraocular pressures (IOPs) were 18mm Hg OD and 16mm Hg OS. The pupils

reacted briskly, but there was an afferent pupillary defect in the left eye. Color vision was full at 14/14 in the right eye and decreased to 1/14 in the left eye with Ishihara testing. Extraocular motility testing was normal without pain. Fundus exam was unremarkable OD and revealed grade 2 optic nerve edema with flame hemorrhage OS. The retina was attached in both eyes.

Currently, differentials for a painless unilateral decrease in vision with disc edema and no signs of intraocular inflammation include an ischemic event, such as anterior ischemic optic neuropathy (non-arteritic vs. arteritic), compressive optic neuropathy, diabetic papillitis, demyelinating disease or an infectious or inflammatory-related etiology.

Arteritic anterior ischemic optic neuropathy (AION), as seen in giant

cell arteritis, was considered less likely due to his age and lack of suggestive symptoms such as new headache, temporal pain, jaw claudication, weight or appetite loss, fever and pain seen in polymyalgia rheumatica. Despite being less likely, laboratory testing was ordered—including complete blood count, c-reactive protein and erythrocyte sedimentation rate—and returned unremarkable, thereby ruling out AION.

Magnetic resonance imaging (MRI) of the brain and orbit was completed with and without contrast to look for any lesions or enhancement of the optic nerve. The MRI yielded normal results, making conditions such as compressive optic neuropathy and optic neuritis unlikely. The differential diagnosis list at this point was narrowed to non-arteritic ischemic optic neuropathy (NAION), diabetic papillitis or an inflammatory or infectious etiology.

Visual field testing on a short-interval return visit to the neuro-ophthalmology clinic revealed a full field OD and an enlarged blind spot with an inferior scotoma OS (*Figure*

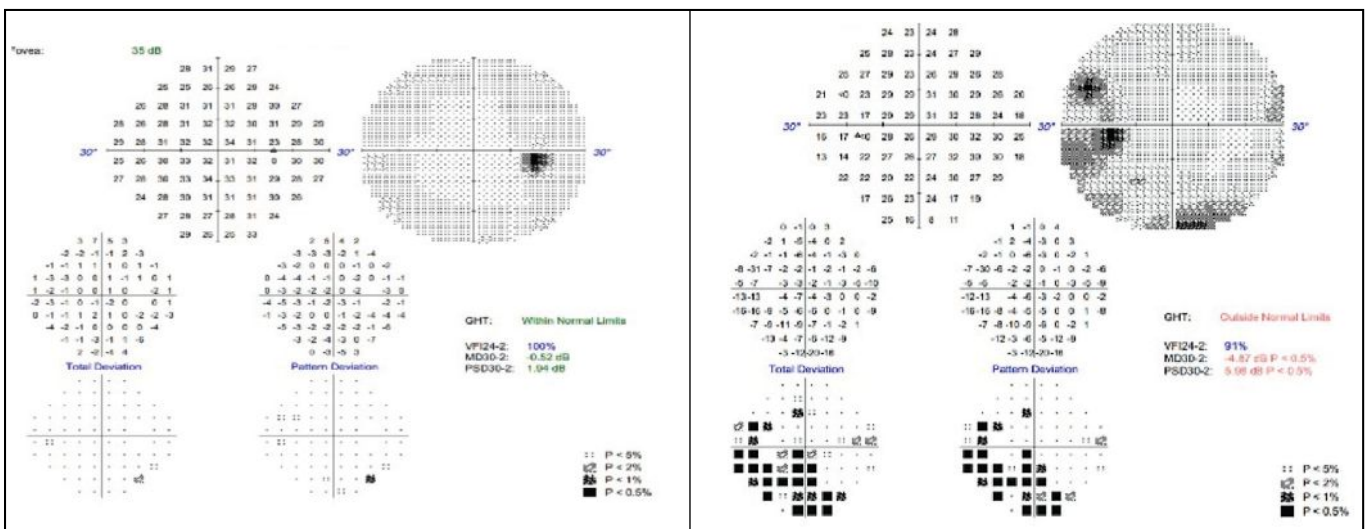


Fig. 1. 30-2 Humphrey visual field of the right eye (left) and left eye (right).

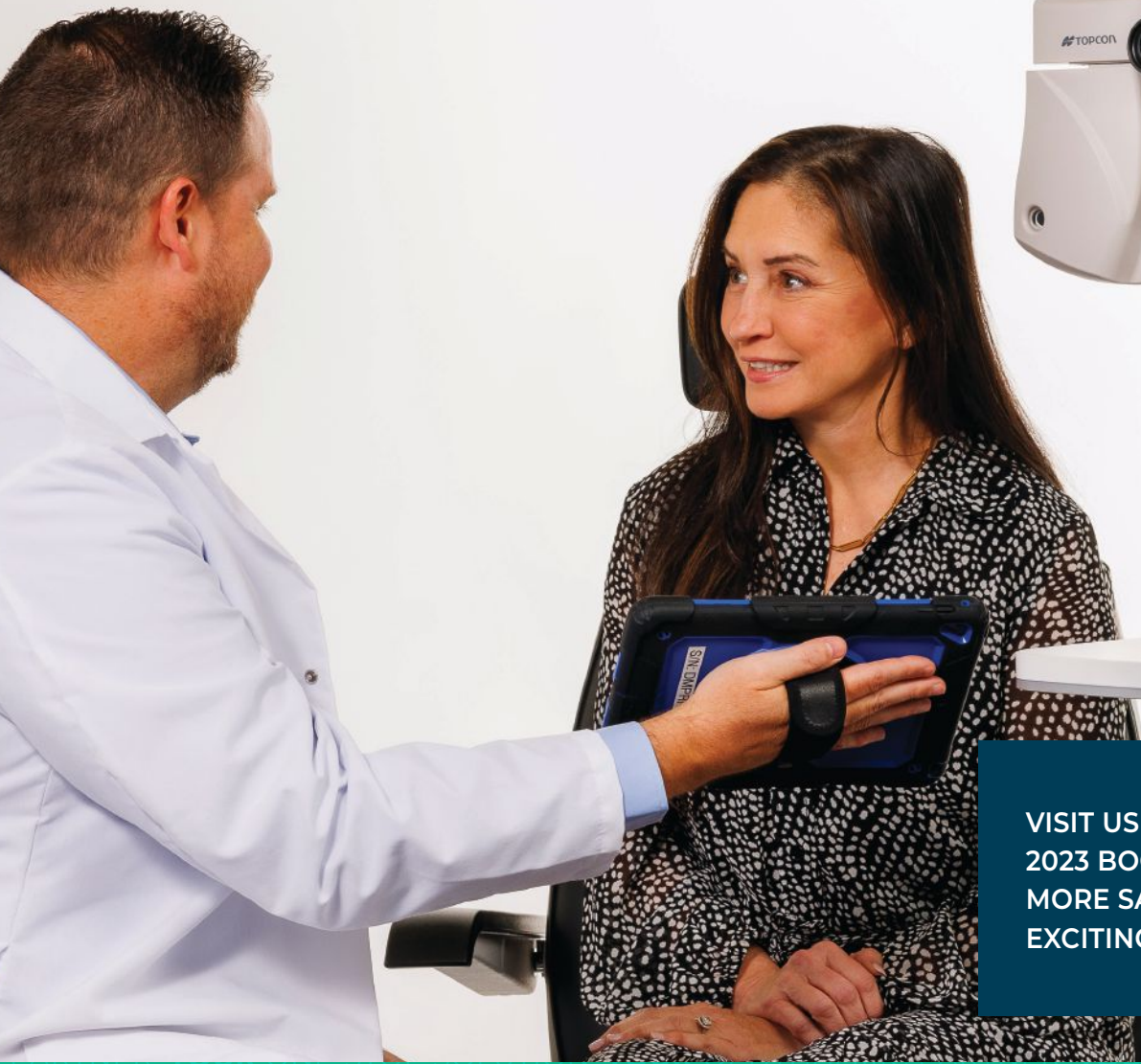**About Dr. Bozung**

Dr. Bozung works in the Ophthalmic Emergency Department of the Bascom Palmer Eye Institute (BPEI) in Miami and serves as the clinical site director of the Optometric Student Externship Program as well as the associate director of the Optometric Residence Program at BPEI. She has no financial interests to disclose.



WHEN YOU NEED QUALITY OPHTHALMIC EQUIPMENT,  
**THINK LOMBART**

LANE PACKAGES  
STARTING AT \$16,995



VISIT US AT VISION EXPO WEST  
2023 BOOTH #F11059 FOR  
MORE SAVINGS & TO DEMO  
EXCITING NEW EQUIPMENT.



**SAVE WITH LOMBART HEALTHCARE!**

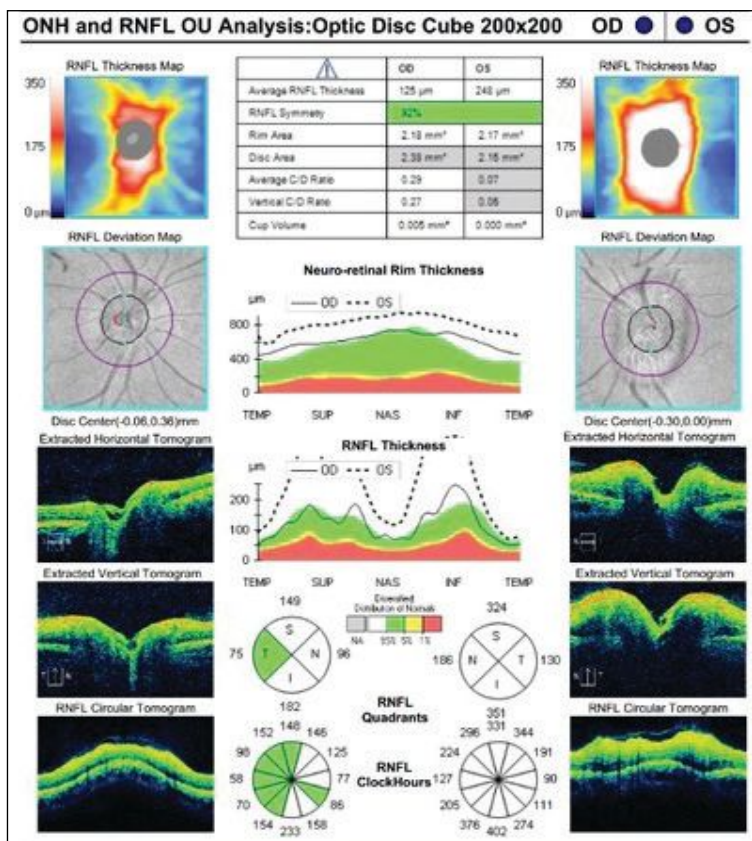
Missing the show? You can still take advantage of our show promotions. Contact us for more information.

800-LOMBART | [LOMBARTINSTRUMENT.COM](http://LOMBARTINSTRUMENT.COM)

LOMBART HEALTHCARE IS A DIVISION OF ADVANCING EYECARE™

1). There was notably diffuse thickening of the OS retinal nerve fiber layer (RNFL) on OCT (Figure 2). The same day, fundus photos revealed an unremarkable right eye (Figure 3A). However, in addition to the optic nerve edema and flame hemorrhage initially seen in the left eye, a new, large, faintly yellowish placoid lesion was seen circumventing the optic nerve (Figure 3B-C). An OCT of the left macula can also be reviewed in Figure 4.

Although NAION was the presumed diagnosis initially based on the patient's age, acute loss of vision and history of using PDE-5, the retinal findings were not consistent with NAION. Therefore, to investigate infectious and inflammatory etiologies, the patient was sent for labs, including *Bartonella* antibody titers, Lyme antibody titers, angiotensin converting enzyme, serum lysozyme, antineutrophil cytoplasmic antibodies, rapid plasminogen reagin (RPR), fluorescent treponemal antibody absorption (FTA-ABS), toxoplasmosis antibody titers, toxocara antibody titers, compre-



**Fig. 2. OCT of the RNFL of both eyes. The right eye is unremarkable and the left eye presents with 360 degrees of RNFL thickening.**

hensive metabolic panel and complete blood count with differential. The labs were unremarkable aside from a reactive FTA-ABS and elevated RPR, supporting a diagnosis of syphilis.

### Verdict and Outcome

Our patient was diagnosed with acute syphilitic posterior placoid chorio-

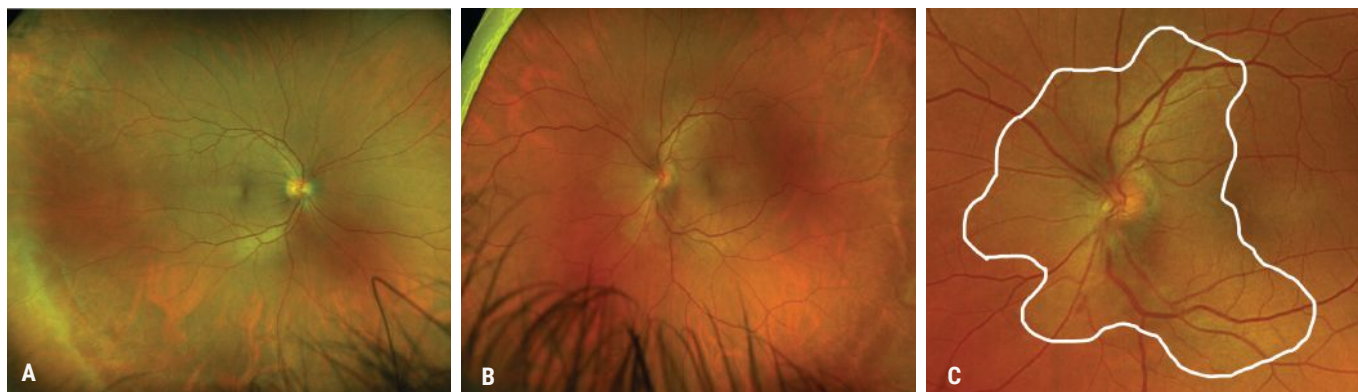
retinitis with optic nerve edema and was admitted to the hospital for intravenous (IV) penicillin treatment and an infectious disease consult. After completing a five-day course of treatment, the patient was seen in clinic for a follow-up, where his vision had improved to 20/20 in both eyes, and there was complete resolution of both the optic nerve edema and visual field defects.

### Discussion

Syphilis is known as “the great masquerader” because its clinical presentation can vary widely. The infectious disease is caused by the spirochete *Treponema pallidum* and can be transmitted during sexual contact or via congenital transmission *in utero*, either across the

placenta or less commonly by contact with an active genital lesion during delivery.<sup>2</sup>

Syphilitic infection progresses through four stages and can affect many organ systems. Primary syphilis manifests as a painless ulcer or chancre at the site of inoculation. These lesions are often overlooked and will resolve



**Fig. 3. (A) Fundus photo of the right eye with mild peripheral pigmentary changes, but otherwise unremarkable. (B) Fundus photo of the left eye demonstrates a large, faintly yellowish placoid lesion circumventing the optic nerve, along with blurred optic disc margins and a small inferior hemorrhage. (C) Enlarged fundus photo of the left eye allows for better visualization of the yellowish placoid lesion circumventing the optic nerve (outlined in white) along with blurred optic disc margins and a small inferior hemorrhage.**

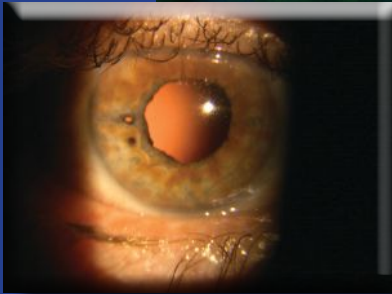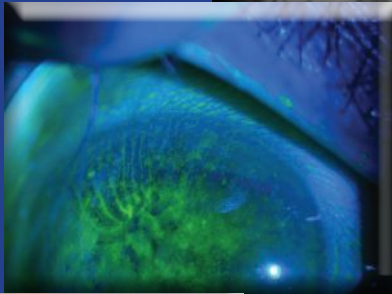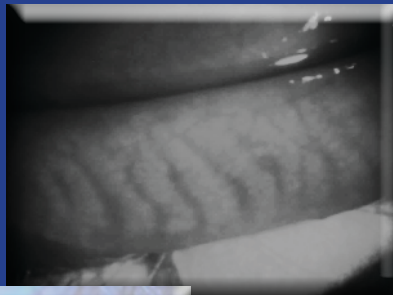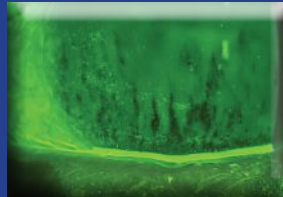



# EyeRes™

Digital Imaging Systems

by **TelScreen**

Slit Lamps • Digital Imaging Systems for Lasers and Slit Lamps • Functional Meibography



Gold

Platinum

Diamond



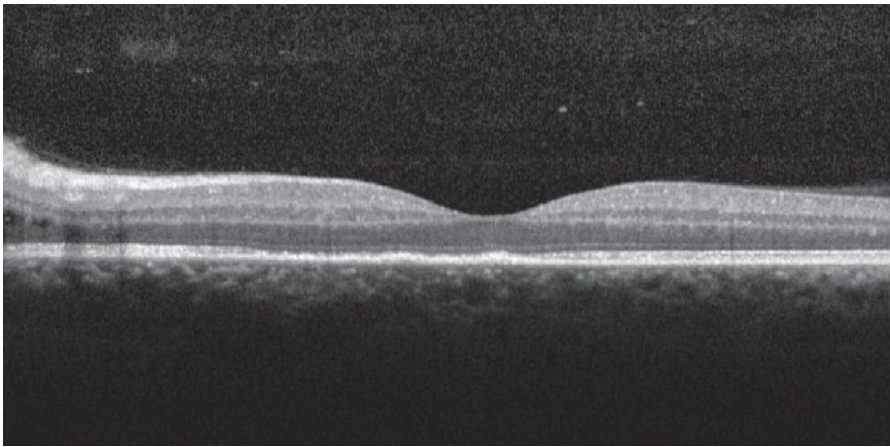
info@TelScreen.com



Come see for yourself at **Booth F3038**

Vision Expo West  
Las Vegas, NV  
September 28-30, 2023





**Fig. 4. OCT of the macula of the left eye showing loss of ellipsoid zone and intraretinal edema adjacent to the optic nerve.**

spontaneously. If untreated, primary syphilis can progress to secondary syphilis roughly six to eight weeks later and presents with generalized symptoms such as fever and malaise, as well as a generalized rash, but may also involve ocular, gastrointestinal, musculoskeletal, renal and neurological symptoms.<sup>3</sup> Primary and secondary syphilis will resolve without treatment and enter a latent phase with no clinical manifestations. Approximately 15% to 40% of untreated patients in this stage will progress to the tertiary stage, characterized by the presence of gummas, which are tumors of granulation tissue containing *T. pallidum* that can affect any body organ, commonly involving the cardiovascular and nervous systems.<sup>3</sup>

Syphilis can cause inflammation in most areas of the eye at any stage of disease. The anterior segment can present with conjunctivitis, episcleritis, scleritis and syphilitic keratitis. The condition can also manifest in the posterior segment as necrotizing or non-necrotizing retinitis in the macula, midperiphery and peripheral retina and can be associated with vasculitis and vascular occlusion. This case presented with a syphilitic posterior placoid chorioretinitis, which is a yellow inflammatory lesion near the level of the RPE, resulting from invasion of the choriocapillaris.<sup>4</sup> These lesions are rare and best viewed with fundus autofluorescence.

“**The most common ophthalmologic presentation of syphilis is uveitis, which can vary widely in presentation.**”

The most common ophthalmologic presentation of syphilis is uveitis, which can vary widely in presentation. The inflammation can be granulomatous iridocyclitis (46%), non-granulomatous iridocyclitis (25%), panuveitis (13%), posterior uveitis (8%) or keratouveitis (8%).<sup>4</sup> Optic nerve is appreciable in about 20% of cases and presents as perineuritis, optic neuritis, neuroretinitis, papilledema and optic atrophy (late stage).<sup>3</sup> Optic nerve edema is thought to be secondary to ischemic or inflammatory processes. Argyll Robertson pupil is a classic finding in syphilis and may result from damage to the ciliary nucleus or to the neuronal connections between the Edinger-Westphal nuclei and the pretectal nuclei. This damage causes the pupils to be miotic and unable to constrict in response to light, but they will constrict in response to near vision phenomenon, termed light-near dissociation.<sup>4</sup>

The oculomotor pathway can also be affected: in the early stages of syphilis, saccade velocity and accuracy of smooth pursuit movements may be abnormal, and in late stages, a cranial nerve palsy may develop.<sup>4</sup>

## Testing and Treatment

Venereal disease research laboratory and RPR tests are useful in screening for active disease and antibody quantification as a titer level. These tests are sensitive, but not specific, and a positive result should be confirmed with treponemal tests such as FTA-ABS, microhemagglutination assay for *Treponema pallidum* or *T. pallidum*-particle agglutination.<sup>4</sup> Ocular syphilis may be considered a finding of neurosyphilis; therefore, neurosyphilis protocol may be considered for treatment of all cases. This includes brain imaging and possible lumbar puncture with cerebrospinal fluid analysis, as well as consultation of infectious service.<sup>1</sup> The recommended adult regimen for treatment of neurosyphilis is IV aqueous crystalline penicillin G 18 to 24 million units per day (either as continuous infusion or three to four million units every four hours) for 10 to 14 days.<sup>1</sup>

In conclusion, it is important to always consider less-common etiologies for common clinical presentations, especially if the clinical phenotype morphs or doesn't fit into the diagnostic box as we expect. Syphilis should remain in the back of our minds often, given its clinically variable presentations, stealthy progression and rise in incidence across the United States. ■

1. Jones-Vanderleest JG. Neurosyphilis, ocular syphilis, and otosyphilis: detection and treatment. American Family Physician. Published July 31, 2022. [www.aafp.org/pubs/afp/issues/2022/0800/editorial-syphilis.html](http://www.aafp.org/pubs/afp/issues/2022/0800/editorial-syphilis.html). Accessed August 1, 2023.

2. Tudor ME, Al Aboud AM, Leslie SW, et al. Syphilis. In: StatPearls. Treasure Island (FL): StatPearls Publishing; May 30, 2023.

3. Kabanovskii A, Donaldson L, Jeeva-Patel T, Margolin EA. Optic disc edema in syphilis. J Neuro-Ophthalmol. 2022;42(1):e173-e180.

4. Lee AG, Bindiganavile SH, Wiley Z, et al. Ophthalmologic manifestations of syphilis. EyeWiki. Updated July 30, 2022. [eyewiki.aao.org/Ophthalmologic\\_Manifestations\\_of\\_Syphilis](http://eyewiki.aao.org/Ophthalmologic_Manifestations_of_Syphilis). Accessed August 1, 2023. Accessed August 1, 2023.

## ABOUT THE AUTHOR

**Dr. Mechas** received her doctorate of optometry at Ohio State University. Recently, she completed a residency in Ocular Disease at Bascom Palmer Eye Institute in Miami and is happy to announce she will be continuing her optometric career at Cincinnati Eye Institute.

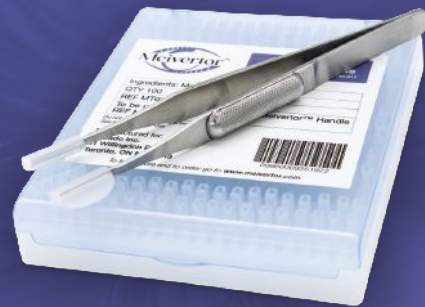
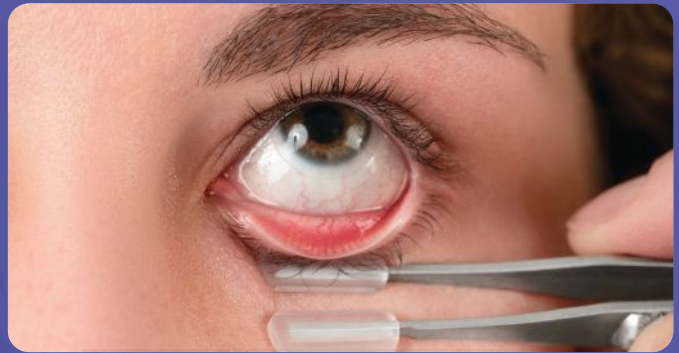
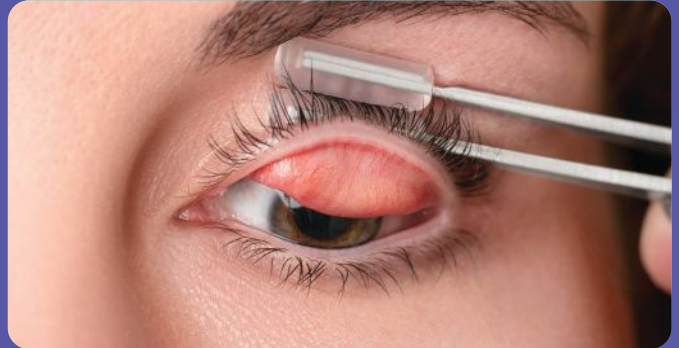

US Patent 11,446,017

# The ONLY SINGLE-HANDED UPPER and lower eyelid EVERSION TOOL

- Optimize the functionality of your meibographer
- Empower your technician to take the images you need – flipping a lid has never been easier
- Whenever you evert an upper eyelid – AND need a free hand – use your Meivertor



“Amazingly well designed, incredible balance to the instrument, and ease of use. I would recommend every technician who does meibography have one.”

-Dr. Paul Karpecki, OD, FAAO

“Love the Meivertor. First true game changer in the meibography game in my opinion.”

-Dr. Bradley Barnett, MD

“The Meivertor is a terrific product that has become one of my staff’s favourite in a very short time!”

-Dr. Kimberly K. Friedman, OD, FAAO

“Anyone struggle with lid eversion for meibomian gland imaging? Try using the Meivertor. Teaching techs has been a breeze and we can image both the upper and lower lids with ease!”

-Dr. Preeya Gupta, MD



For more information and to purchase go to [meivertor.com](http://meivertor.com)



BY NATE LIGHTHIZER, OD

## ADVANCED PROCEDURES

# Spasms, Twitches and Other Eyelid Glitches

*Botox can be a safe and effective option for facial muscle contractions.*

BY LEONID SKORIN, JR., DO, OD, MS  
ALBERT LEA, MN

**B**otulinum toxin is best known as a cosmetic agent used to treat facial wrinkles, yet its origins and current application for our purposes is more importantly that of a therapeutic agent.<sup>1</sup> Its use in the treatment of neuro-ophthalmic disorders, especially those in which traditional therapies are of limited benefit, has had a decades-long positive track record.<sup>2</sup> Botulinum toxin has emerged as a safe and effective treatment for a number of previously refractive conditions associated with excessive muscle activity.<sup>3</sup>

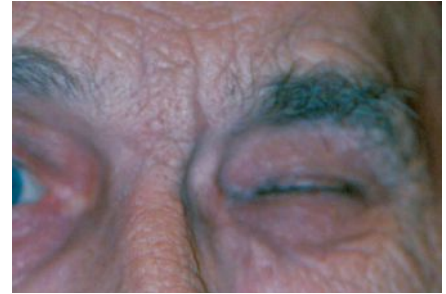It has been used to treat numerous types of strabismus in children and adults as both an adjunctive and alternative surgical therapy, as well as for various dystonias of the facial muscles.<sup>4</sup> Dystonia

is a syndrome dominated by involuntary sustained (tonic) or spasmodic (rapid or clonic) repetitive muscle contraction patterns, frequently causing twisting, flexing or extending and squeezing movements or abnormal postures.<sup>5-9</sup> The most common facial dystonias are benign essential blepharospasm, Meige syndrome and hemifacial spasm.

### Background

Botulinum toxin is the most potent biologic neurotoxin known to man. It can cause botulism, a potentially fatal condition that causes neuromuscular paralysis. All botulinum toxins are produced by the anaerobic gram-negative bacterium, *Clostridium botulinum*.<sup>9</sup> These neurotoxins are grouped into eight serotypes based on their immunologic properties. Of these eight, only three (A, B and E) cause flaccid paralysis in humans.<sup>9,10</sup>

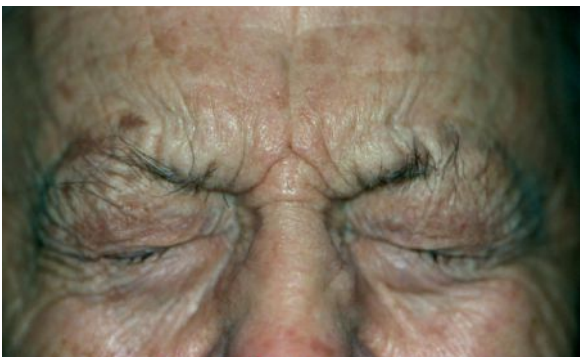Following intramuscular injection, botulinum toxin inhibits the release of acetylcholine from the motor nerve terminals, resulting in a temporary reduction in muscle contractions. Once injected, the toxin rapidly and firmly binds at receptor sites on the acetylcholine-related nerve terminals. Neuromuscular transmission ceases, and the target muscle atro-



**Fig. 2. Hemifacial spasm is characterized by unilateral, periodic, tonic contractions of the facial muscles used in expression.**

phies. This chemical denervation effect is seen within five days with peak effect at two to three weeks and duration of action of three months.<sup>2</sup> Since the nerve terminals recover their normal functions, the effects of botulinum toxin are not permanent.<sup>11</sup> This reactivation of muscle activity may be considered both an advantage and a disadvantage when using botulinum toxin in a clinical setting. This is an advantage because, if there were any overtreatment of a muscle or even involvement of the incorrect muscle, the error resolves on its own with no long-term untoward effects. The disadvantage with this therapy is that it is not permanent and needs to be repeated approximately every three months.

There are currently six FDA-approved neurotoxins (*Table 1*). All these agents can be used interchangeably, but it is important that the unit dosing is adjusted accordingly if the clinician uses various neurotoxins. It is probably most prudent for the clinician to get familiar with one or two of these agents and build proficiency with these before trying to mix and match multiple agents. Not all the agents are unit-to-unit equivalent and some have other subtleties that would affect patient outcome. For instance, abobotulinumtoxin A has a faster onset of action with a median time of onset of two or three days.<sup>12</sup> On the other hand,



**Fig. 1. BEB, a common bilateral facial dystonia, involves the orbicularis oculi, procerus and corrugator musculature.**

About  
Dr. Lighthizer

Dr. Lighthizer is the associate dean, director of continuing education and chief of specialty care clinics at the NSU Oklahoma College of Optometry. He is a founding member and immediate past president of the Intrepid Eye Society. Dr. Lighthizer's full disclosure list can be found in the online version of this article at [www.reviewofoptometry.com](http://www.reviewofoptometry.com).



daxibotulinumtoxin A has a longer duration of action with a median duration of 24 weeks. Therefore, dilution, dosage and injection points are the most critical considerations for the final clinical outcome.

## Facial Dystonias

Benign essential blepharospasm (BEB) are bilateral involuntary spasms of the orbicularis oculi, procerus and corrugator musculature (Figure 1). BEB usually begins in individuals aged 50 to 70 with a mean age of onset of 56 years.<sup>5</sup> Almost two-thirds are women. The spasms are so frequent and severe that they can result in functional blindness in up to 12% of patients.<sup>10</sup> Meige syndrome (idiopathic orofacial dystonia) is when BEB is associated with intermittent lower facial movement. It can affect the patient's speech and may cause involuntary chewing, lip pursing and trismus (lockjaw).<sup>5</sup> Hemifacial spasm is characterized by unilateral, periodic, tonic contractions of the facial muscles of expression (Figure 2). Hemifacial spasm may be caused by a cerebellopontine tumor, or more commonly by microvascular compression or irritation of the facial nerve by an aberrant artery in the posterior fossa. All these patients must undergo neuroimaging.

## Procedural Technique

Prior to the procedure, educate the patient and explain that botulinum toxin is a natural substance that, when used in the standard medical dosage, does not cause botulism or poisoning. Let them know it is administered via a few tiny injections and the treatment is simple,

quick and minimally invasive. There is no downtime for the patient and, although the effect is not permanent, any overtreatment wears off, and future injections can be adjusted to obtain a more desirable clinical result.

The equipment needed includes:

- Topical anesthetic drops (*i.e.*, tetracaine or proparacaine).
- Alcohol pads for cleaning the tops of the vials and for the patient's skin.
- Gauze for any potential bleeding.
- A sharps container.
- A 1mL tuberculin syringe with a 30-gauge needle for the intramuscular injections.
- A 3mL syringe with an 18- or 20-gauge needle for reconstitution of botulinum toxin.
- A vial of sterile preservative-free 0.9% sodium chloride to reconstitute the botulinum toxin powder.

Except for rimabotulinumtoxin B, which comes prepackaged as a solution, all the other neurotoxins come in a powder form. Therefore, they will need to be reconstituted by the clinician before they can be used. The neurotoxin agent being used and the reconstitution volume will provide the specific dilution. Always follow the manufacturer's recommended dilution rates. As an example, for onabotulinumtoxin A, to obtain a dosage of 4.0 units for every 0.1mL to be injected intramuscularly, 2.5mL of 0.9% sodium chloride will need to be injected into the 100-unit vial of this neurotoxin.

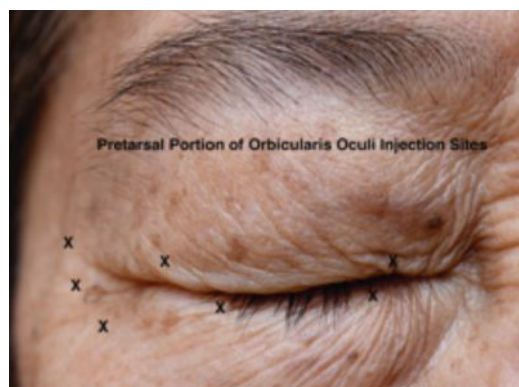

Photo: Selina McGee, OD

**Fig. 3. Injection sites (depicted as an "X") for benign essential blepharospasm—always done bilaterally. Procerus and corrugator musculature not labeled.**

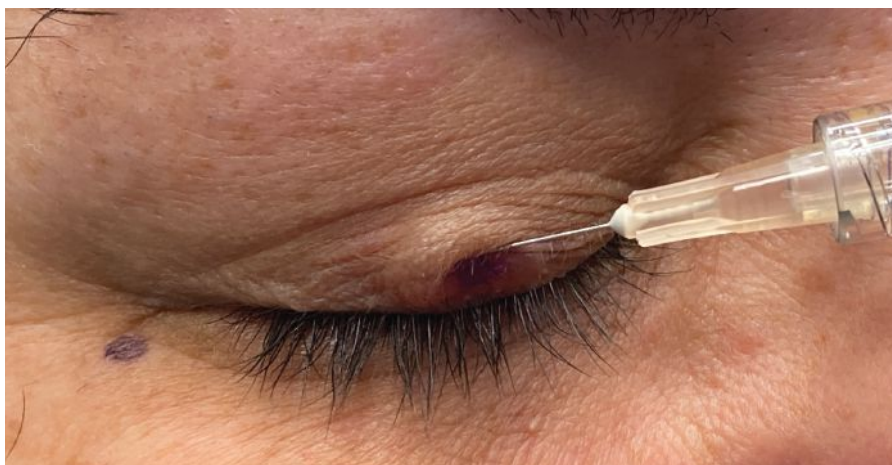Do not agitate the reconstituted neurotoxin either while injecting the sodium chloride into the neurotoxin-containing vial or after the injection is completed. It is recommended that the diluted neurotoxin be used within seven hours of reconstitution; however, studies have shown that the medication can be stored in a refrigerator between 2° C to 8° C for up to four weeks and still maintain up to 87% potency.<sup>15</sup>

After the topical anesthetic eye drops have been applied, the patient is positioned and slightly reclined. This allows the clinician to adjust the height and angle of the patient. For BEB, injections should be given bilaterally, using the reconstituted neurotoxin that has been drawn up into the tuberculin syringe and using the 30-gauge needle. The initial injection sites should include the medial and lateral pretarsal orbicularis oculi of the upper eyelid and the lateral pretarsal orbicularis oculi of the lower eyelid (Figure 3). From 2.0

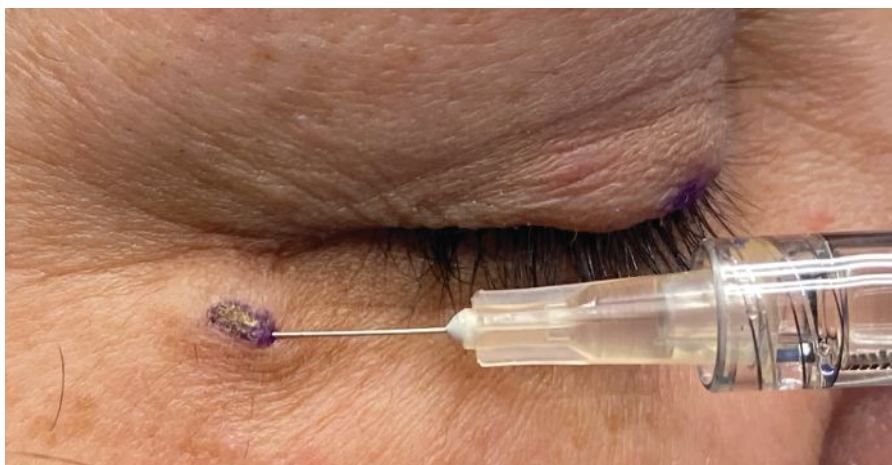**TABLE 1. FDA-APPROVED BOTULINUM TOXIN AGENTS**

Agent	US Trade Name	Company	Active Ingredient	Units per vial	Drug Form
Onabotulinumtoxin A	Botox, Botox Cosmetic	Allergan	BoNT-A Complex	50, 100, 200	Powder
Abobotulinumtoxin A	Dysport	Galderma	BoNT-A Complex	300, 500	Powder
Incobotulinumtoxin A	Xeomin	Merz	BoNT-A free from complexing proteins	50, 100, 200	Powder
Daxibotulinumtoxin A	Daxxify	Revance	BoNT-A complex	50, 100	Powder
Prabotulinumtoxin A	Jeveau	Evolus	BoNT-A complex	100	Powder
Rimabotulinumtoxin B	Myobloc	Solstice Neurosciences	BoNT-B complex	2,500; 5,000; 10,000	Solution

BoNT: botulinum toxin type



**Fig. 4. Injection of botox in the central upper lid in the pretarsal portion of the orbicularis. A 30-gauge needle on a 1cc syringe is being used.**



**Fig. 5. Injection of botox along the temporal aspect of the orbicular muscle. Notice the shallow approach of the needle to the injection site and the wheal of medication being injected very superficially just below the skin.**

units (0.05mL) to 4.0 units (0.1mL) is administered in each injection site depending on the severity of the spasms. Since the skin in this location is very thin, insert the needle just below the skin surface and administer this injection subcutaneously in order to avoid inactivating the levator muscle, which lies immediately beneath the orbicularis oculi muscle and septum.

Injecting the levator muscle will cause blepharoptosis. The lateral canthal aspect of the orbicularis oculi muscle is also treated with one to three injections at or just lateral to the orbital rim.<sup>14</sup> The procerus and corrugator/depressor supercillii muscle complex make up the glabella. Inject 4.0 units (0.1mL) intramuscularly centrally into the procerus muscle and

two injections in each corrugator/depressor supercillii complex. One injection is given in the medial (body) aspect of this muscle complex, and the other in the lateral (tail) aspect. Lateral corrugator injections should be placed at least 1cm above the bony supraorbital ridge.

In hemifacial spasm patients, all injections are administered only on the involved side. The same injection sites as would be administered for BEB are used. In addition, injection into the zygomaticus major, zygomaticus minor and risorius would also need to be performed. Document the specific neurotoxin and dilution used.

The treatment form should have a facial diagram where a pictorial account of the injection pattern and dosing can be

recorded. This can then be referred to on subsequent visits to adjust the location and dosage of the injections to obtain the desired result.<sup>6</sup>

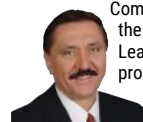### Post-op and Follow-Up

Instruct the patient not to lie down for several hours following treatment and to avoid manipulation of the injection sites. A potential side effect is post-injection blepharoptosis. It lasts for about two to three weeks. The patient can use either apraclonidine 0.5% or oxymetazoline 0.1% to activate Müller's muscle. Since the blepharoptosis will resolve on its own, these medications can be used as a temporizing measure. Schedule the patient to return for repeat treatment in three months. ■

1. Small R. Botulinum toxin injection for facial wrinkles. *Am Fam Physician*. 2014;90(3):168-75.
2. Ahuero AE, Gross MP. Botulinum toxin and filler agents. In: Onofrey BE, Skorin L, Holdeman NR, (eds.). *Ocular Therapeutics Handbook: A Clinical Manual*, 4th Ed. Philadelphia: Wolters Kluwer, 2020:660-3.
3. Hughes AJ. Botulinum toxin in clinical practice. *Drugs* 1994;48(6):888-93.
4. Binenbaum G, Chang MY, Heidary G, et al. Botulinum toxin injection for the treatment of strabismus, a report by the American Academy of Ophthalmology. *Ophthalmology*. 2021;128(2):1766-76.
5. Skorin L. Blepharospasm and hemifacial spasm. In: Onofrey BE, Skorin L, Holdeman NR, (eds.). *Ocular Therapeutics Handbook: A Clinical Manual*, 4th Edition. Philadelphia: Wolters-Kluwer, 2020:617-9.
6. Berry MG. *Botulinum Toxin in Clinical Practice*. Cham, Switzerland: Springer, 2021.
7. McCann JD, Saulny S, Goldberg RA, Anderson RL. Essential blepharospasm. In: Chen WP, (ed). *Oculoplastic Surgery: The Essentials*. New York: Thieme, 2001:113-24.
8. Gallagher CJ. Basic science of Botox Cosmetic. In: Carruthers A, Carruthers J, (eds). *Botulinum Toxin*, 4th Edit. Edinburgh: Elsevier, 2018:21-9.
9. Nestor M, Cohen JL, Landau M, et al. Onset and duration of abobotulinumtoxin A for aesthetic use in the upper face: a systematic literature review. *J Clin Aesthet Dermatol*. 2020;13(12):E56-83.
10. Salish N, Carruthers J, Kaufman J, et al. Overview of daxibotulinumtoxin A for injection: a novel formulation of botulinum toxin type A. *Drugs*. 2021;81(18):2091-102.
11. Lipham WJ. Treatment of blepharospasm, Meige's syndrome and hemifacial spasm. In: Lipham WJ, (ed). *Cosmetic and Clinical Applications of Botulinum Toxin*. Thorofare NJ: Slack Incorp., 2004:37-45.
12. Carruthers J, Fagien S, Matarasso SL; Botox Consensus Group. Consensus recommendations on the use of botulinum toxin type A in facial aesthetics. *Plast Reconstr Surg*. 2004;114(6 Suppl):1S-22S.

### ABOUT THE AUTHOR

**Dr. Skorin** is a consultant in the Department of Surgery, Community Division of Ophthalmology at the Mayo Clinic Health System in Albert Lea, MN. In addition, he is an assistant professor of Ophthalmology at the Mayo Clinic College of Medicine in Rochester, MN.



# SECO2024

THE EDUCATION DESTINATION™

FEBRUARY 28 – MARCH 3, 2024  
ATLANTA, GEORGIA

## SAVE THE DATE

REGISTRATION OPENS NOVEMBER 1<sup>ST</sup>



### ADVANCING EYE CARE WORLDWIDE

SECO International is dedicated to providing world-class educational opportunities to eye care professionals, helping them enhance their skills, expand their networks, and grow their practices. Experience the future of eye care at our flagship event - where groundbreaking technology meets leading-edge education.



### EMPOWERING EYE CARE PROFESSIONALS


SECO International is passionate about empowering eye care professionals through top-tier educational content and networking opportunities. Our flagship event, SECO 2024, will bring together the global optometry community, fostering collaboration, knowledge sharing, and the advancement of eye care.



### YOUR PARTNER IN EYE CARE EXCELLENCE

SECO International is committed to promoting excellence in eye care through cutting-edge educational offerings, robust networking platforms, and strategic partnerships. At our premier event, SECO 2024, you'll gain access to a global community of optometry professionals and industry leaders, ready to inspire and be inspired.

SCAN HERE TO BE NOTIFIED ABOUT  
SECO 2024 REGISTRATION



LEARN MORE AT  
[attendseco.com](https://attendseco.com)





# You've Got Some Nerve

*A hospital visit identified alarming signs for this patient.*

**A** 22-year-old Caucasian female was referred for ophthalmic evaluation following discharge from a hospital where she was admitted for workup due to four days of a right-sided headache, horizontal double vision, ringing in her ears and transient visual obscurations. She was taking an oral contraceptive and was allergic to heparin. Prior to this episode, her past medical, ocular and family histories were all unremarkable.

Visual acuity was 20/25 OD and 20/30 OS. There was -1 abduction OD and -4 abduction OS. Confrontation visual field testing was full to finger counting OU, pupils were equal in size and reactivity without relative APD. IOP was 12mm Hg OD and 15mm Hg OS, and Ishihara color plates were full OU.

## Take the Retina Quiz

1. According to the Frisén classification of optic nerve edema, how would you grade

*the optic nerves seen in Figures 1 and 2?*

- a. Grade 2.
- b. Grade 3.
- c. Grade 4.
- d. Grade 5.

2. Which of the following is NOT a risk factor for bilateral optic nerve edema?

- a. Blood dyscrasias.
- b. Brain tumor.
- c. Systemic hypertension.
- d. Overhydration.

3. Which of the following is NOT indicated in the workup for this patient?

- a. Measuring blood pressure.
- b. MRI of the brain and orbits with and without contrast.
- c. MRV of the brain without contrast.
- d. All of the above are indicated.

4. According to the Idiopathic Intracranial Hypertension Treatment Trial, what is the maximum recommended dose of oral acetazolamide that is considered safe?

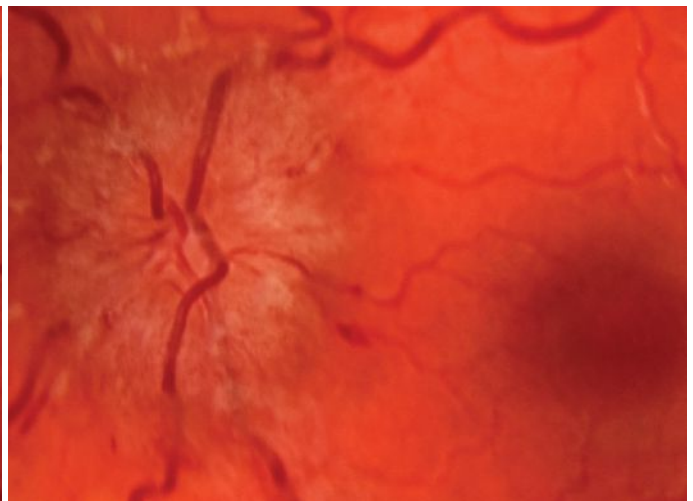
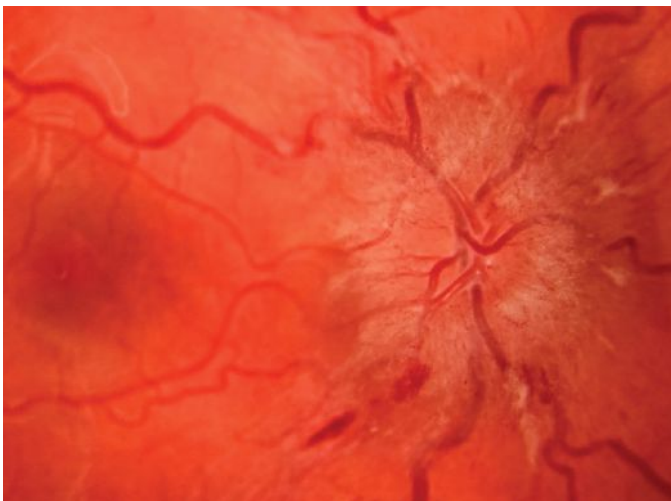
- a. 250mg PO BID.
- b. 500mg PO BID.
- c. 1,000mg PO BID.
- d. 2,000mg PO BID.

5. Which of the following is required to make a diagnosis of idiopathic intracranial hypertension (IIH)?

- a. Absence of spontaneous venous pulsation.
- b. Negative MRI brain and orbits, and MRV brain.
- c. Lumbar puncture opening pressure <20cm H<sub>2</sub>O.
- d. Transverse sinus thrombosis.

## Diagnosis

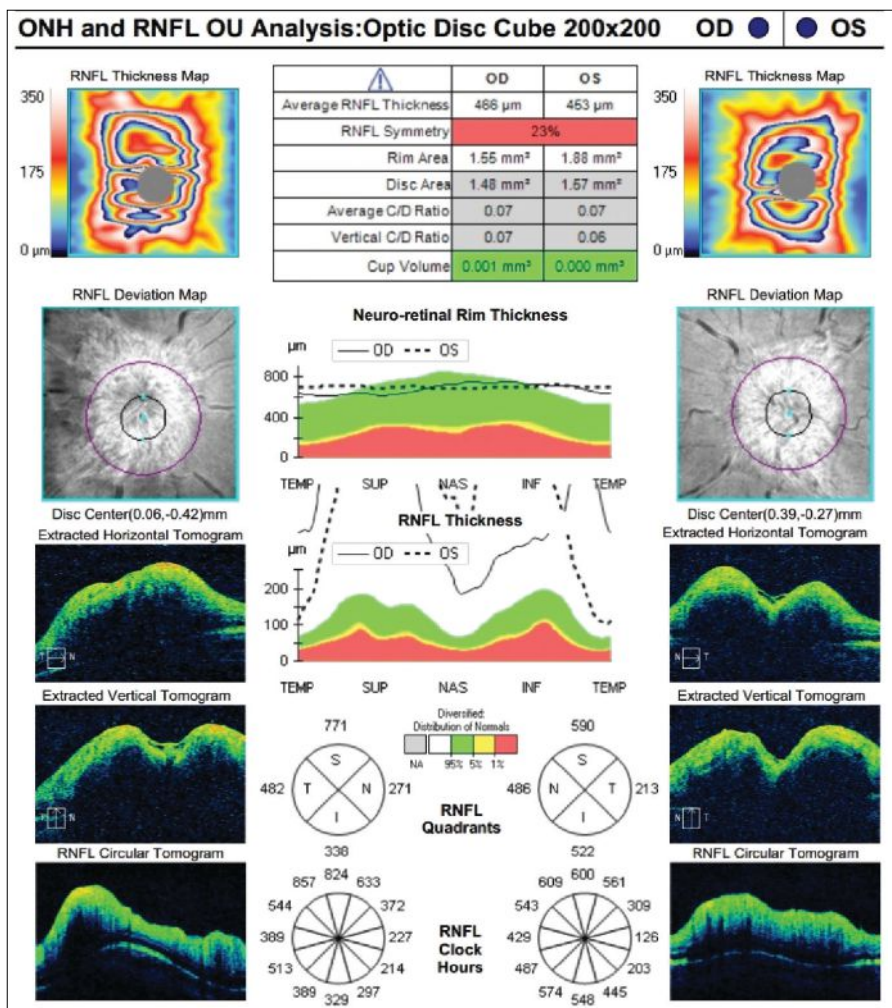
While in the hospital, the patient underwent neuroimaging that identified cerebral venous thromboses (CVT) present on magnetic resonance venogram (MRV) in the upper right internal jugular vein, as well as the right superior sagittal, transverse and sigmoid sinuses. Serologies to investigate for blood dyscrasias uncovered a previously undiagnosed Factor V Leiden heterozygous mutation and elevated Factor VIII (antihemophilic factor A) activity of 238% (reference range 60% to 150%).



**Topcon fundus photo of optic nerve OD at presentation (left). Topcon fundus photo of optic nerve OS at presentation (right).**

About  
**Dr. Aboumourad**

Dr. Aboumourad currently practices at Bascom Palmer Eye Institute in Miami. He has no financial disclosures.



**Zeiss Cirrus RNFL OU at presentation.**

It was felt that the Factor V Leiden positivity in the setting of oral contraceptive use put her at an increased risk for developing the CVTs and secondary intracranial hypertension. She was treated acutely with tissue plasminogen activator and systemic anticoagulation, and her birth control pill was discontinued. She was discharged on warfarin 5mg PO BID and acetazolamide 250mg PO BID.

Upon presentation to our institute, she was found to have bilateral (left >> right) cranial nerve VI palsies and grade 4 optic disc edema OU. Her headache improved, but she still had pulsatile tinnitus, horizontal diplopia worse in left gaze and transient visual obscurations varying with positional changes.

*For answers to the quiz, see page 106.*

## Discussion

Papilledema is defined as optic nerve edema in the setting of intracranial hypertension (*e.g.*, space-occupying lesion, infection, malignant hypertension, idiopathic).<sup>1,2</sup> When there is no elevated intracranial pressure (ICP) as the underlying etiology, the term *optic nerve edema* is more appropriate, defined as swelling of the optic nerve head secondary to local or systemic etiologies (*e.g.*, optic neuritis, ischemic optic neuropathy, uveitis, retinal vein occlusion, radiation, medication use).<sup>1</sup>

The pathophysiology underlying optic nerve edema is based on stasis or obstruction of axoplasmic transport and secondary accumulation of fluid within the retinal nerve fiber layer (RNFL).<sup>1</sup> Such edema appears opaque and can blur the appearance of the optic nerve and its vasculature.<sup>1</sup>

Papilledema is graded on the Frisén scale from 0 to 5, with grade 0 being a normal optic nerve without edema.<sup>1,3</sup> Grade 1 is defined as a “c-shaped” halo of blurring along the nasal border of the optic nerve, and grade 2 is characterized by a circumferential halo of optic nerve obscuration.<sup>1,3</sup> Grades 3 to 5 are determined by degree of blood vessel obscuration; grades 3 and 4 are defined by partial obscuration of a major blood vessel leaving and on the disc, respectively, and grade 5 is characterized by obscuration of all vessels leaving and on the disc with obliteration of the cup.<sup>1,3</sup>

While the absence of spontaneous venous pulsations is an early and subtle indicator of elevated ICP, it may be absent in up to 10% of normal patients.<sup>4</sup>

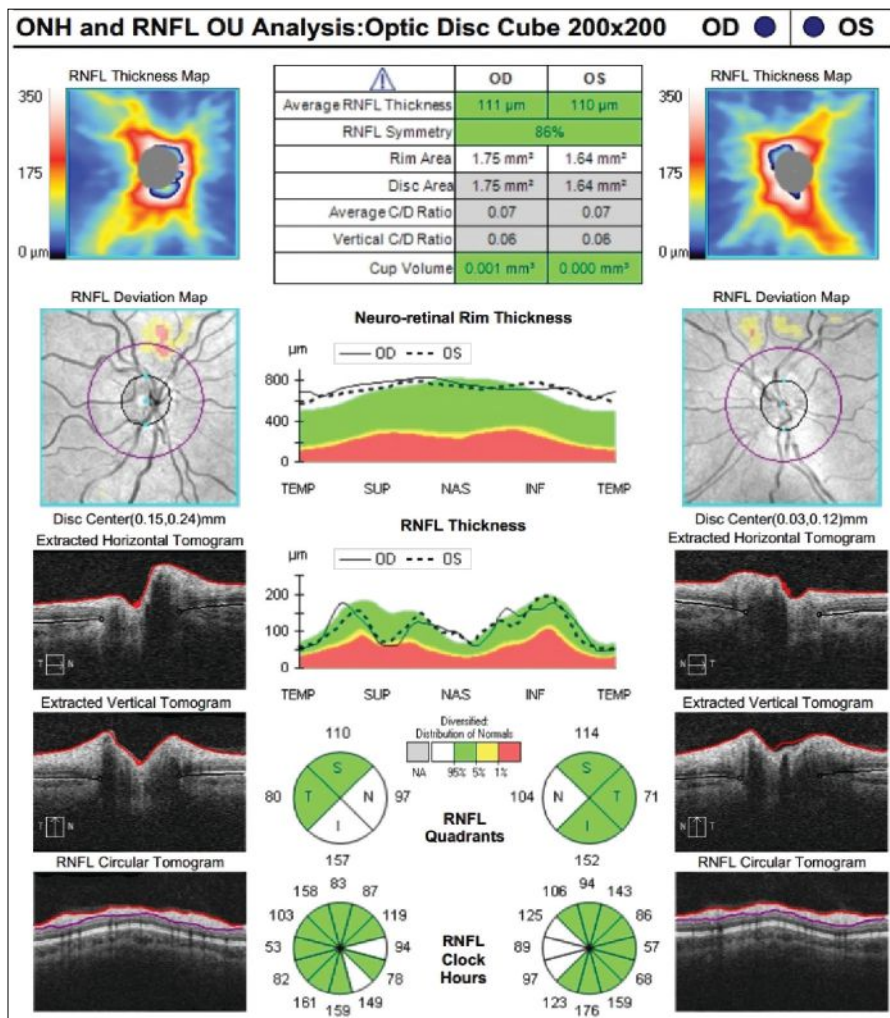
## Workup

A thorough and careful history is required to elicit symptoms of blurry vision, pulsatile tinnitus, intermittent or constant horizontal binocular diplopia, transient visual obscurations, neck stiffness, headache, nausea and altered states of consciousness. Pertinent medication history includes hormone-containing contraception, tetracycline antibiotics, vitamin A, lithium and systemic steroid use—all of which can elevate intracranial pressure or are risk factors for venous thrombosis.<sup>1</sup>

Additional history should include smoking status, presence of metabolic syndrome (measuring blood pressure and BMI calculation) and recent weight gain.<sup>1</sup>

Idiopathic intracranial hypertension is a diagnosis of exclusion that requires a completely negative work-up to rule out primary etiologies for elevated ICP, including MRI and MRV of brain and orbits with/without contrast.<sup>1</sup> Once space-occupying lesions have been ruled out, lumbar puncture can be diagnostic to measure the opening pressure and confirm elevated ICP; typical opening pressure in an adult is <20cm H<sub>2</sub>O.<sup>5</sup> Positive neuroimaging findings warrant consultation with appropriate subspecialties and further investigative studies as indicated.





Zeiss Cirrus RNFL OU at follow-up.

**Management**

Primary etiologies for papilledema, when present, must be addressed directly. IIH may be treated with weight

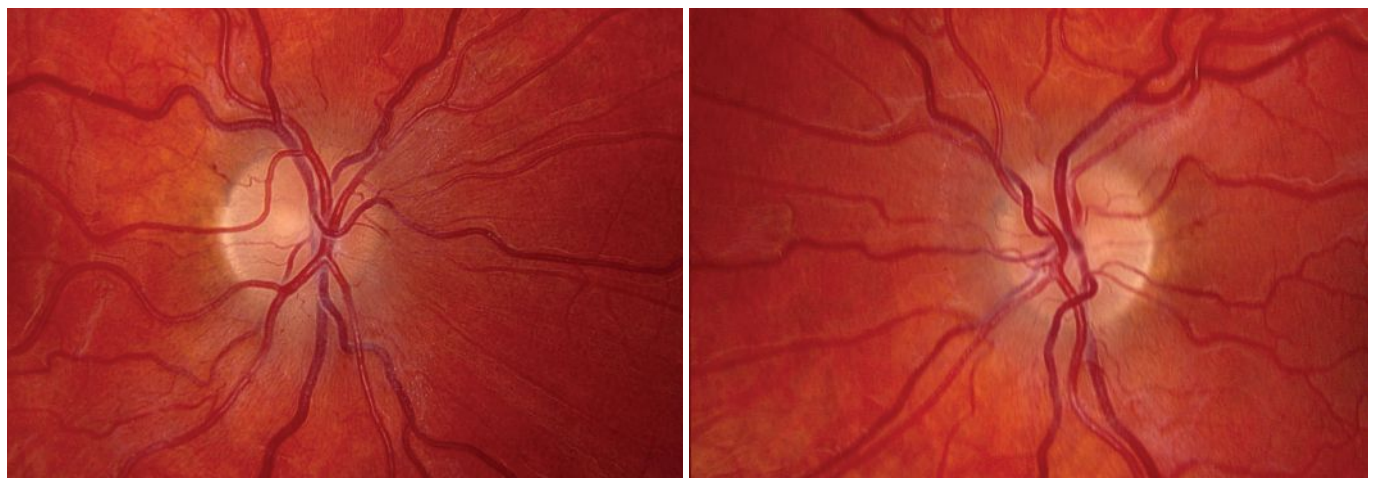
loss and oral acetazolamide.<sup>6</sup> The Idiopathic Intracranial Hypertension Treatment Trial demonstrated safety, tolerability and efficacy of oral acet-

azolamide titrated to a maximum daily dose of 4g (divided into two doses).<sup>6</sup>

Our patient's CVTs were addressed with acute and long-term systemic anticoagulation, cessation of her oral contraceptive and initiation of acetazolamide. Acetazolamide was titrated to 3g daily (1,500mg PO BID) and she achieved complete resolution of her cranial nerve VI palsies and optic nerve edema within three and nine months, respectively, with a final visual acuity of 20/20 OU. The patient was ultimately tapered off acetazolamide and maintained systemic anticoagulation with warfarin 5mg PO QD indefinitely.

CVTs are a rare but life-threatening cause of optic nerve edema. This case underscores the significance of including MRV in the work-up of all patients presenting with bilateral optic nerve edema. Furthermore, even when there are known risk factors for hypercoagulability such as oral contraceptive use, blood dyscrasias must be ruled out with thorough serological studies. ■

1. Yanoff M, Duker JS, Ausburger JJ, et al. *Ophthalmology*, 5th ed. Philadelphia: Elsevier Saunders, 2019.
2. Ryan SJ, Davis JL, Flynn HW, et al. *Retina*, 5th ed. London; New York: Saunders/Elsevier, 2013.
3. Frisén L. Swelling of the optic nerve head: a staging scheme. *J Neurol Neurosurg Psychiatry*. 1982;45(1):13-8.
4. Jacks AS, Miller NR. Spontaneous retinal venous pulsation: aetiology and significance. *J Neurol Neurosurg Psychiatry*. 2003;74(1):7-9.
5. Bowling B, Kanski JJ. Kanski's clinical ophthalmology a systematic approach. [Erscheinungsort nicht ermittelbar: Elsevier, 2016.
6. Smith SV, Friedman DI. The Idiopathic Intracranial Hypertension Treatment Trial: a review of the outcomes. *Headache* 2017;57(8):1303-10.



Topcon fundus photo of optic nerve OD at presentation (left). Topcon fundus photo of optic nerve OS at presentation (right).





# TARSUS

## Join us this October for An Experience to Remember

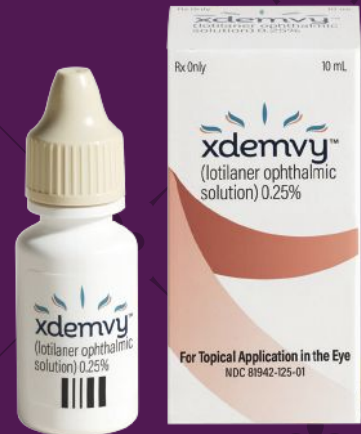Friday, October 13, 2023

6:00 PM – 8:00 PM CT

*The Sugar Mill*

1021 Convention Center Blvd., New Orleans, LA 70130

Enjoy a New Orleans-style reception and dinner while hearing about real-world patient and physician experiences with newly approved XDEMZY™ (lotilaner ophthalmic solution) 0.25%.



### FACULTY



**Paul M. Karpecki, OD**  
**Moderator**

Director of Cornea  
Kentucky Eye Institute  
Lexington, KY



**Ben Gaddie, OD**  
**Presenter**

Owner and Director  
Gaddie Eye Centers  
Louisville, KY



**Joshua Davidson, OD**  
**Guest Speaker**

Williamson Eye  
Baton Rouge, LA



**Selina McGee, OD**  
**Guest Speaker**

Owner  
CEO BeSpoke Vision  
Edmond, OK



**REGISTER NOW**

[www.reviewofoptometry.com/tarsus-nola](http://www.reviewofoptometry.com/tarsus-nola)

This is an approved affiliate event in conjunction with the American Academy of Optometry. We encourage all participants to register for Academy 2023 New Orleans by visiting [www.aaopt.org](http://www.aaopt.org). US—2300348 8/23

Sponsored by



Brought to you by





EDITED BY JOSEPH P. SHOVLIN, OD

# Herpes Helper

*Oral antivirals are safe and resistance is low, but immunosuppressed patients may need IV versions in severe cases.*

**Q I have a patient who requires oral antiviral prophylaxis for recurrent herpes simplex keratitis. Are there any significant risks for viral resistance with chronic antiviral use?**

**A** “Antiviral prophylaxis has been used for decades in patients with herpes simplex keratitis. Prior to the availability of oral antivirals, topical antivirals were used,” explains Christopher J. Rapuano, MD, of Wills Eye Hospital in Philadelphia. It was common practice to use topical trifluridine the same number of times a day as the topical steroid. When oral acyclovir was FDA-approved in the 1980s, physicians began using it instead of the topical antiviral medications. When valacyclovir and famciclovir were later FDA-approved in the 1990s, the use of oral antivirals increased, Dr. Rapuano elaborates.

But it wasn’t until 1998, with publication of the Herpes Eye Disease Study (HEDS) that looked at the prophylactic use of oral acyclovir in eyes with herpes simplex ocular disease, when it became essentially the standard of care. The study found an approximate 50% decrease in recurrence of ocular herpes with the one year of 400mg acyclovir used twice daily, and with no rebound effect when it was stopped for six months.

## Current Guidelines

While the dosages vary per patient, the current standard prophylactic dose of acyclovir is 400mg BID, valacyclovir 500mg QD and famciclovir 250mg one to two times a day; however, the

length of prophylaxis has not been fully established. “HEDS showed effectiveness for one year, but many doctors will keep their patients on for much longer. Most surgeons who perform a corneal graft in an eye with herpes simplex keratitis will continue their prophylaxis for many years, if not for life,” declares Dr. Rapuano.

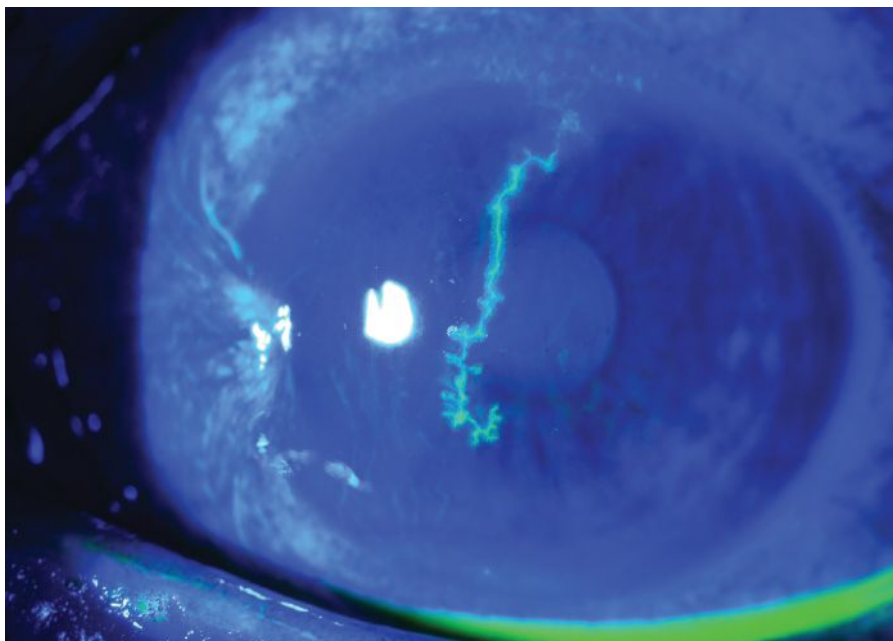
Clinicians must remember that while oral antiviral prophylaxis is effective, breakthrough herpes keratitis can still occur. HEDS demonstrated a 50% decrease in ocular herpes, not 100% elimination, Dr. Rapuano reminds. Having said that, when a patient on

oral antiviral prophylaxis is either not responding to the antiviral medication or is getting frequent recurrences, the questions of compliance with medication use and of antiviral resistance should be considered.

## Viral Resistance

Just like prolonged antibiotic use can promote resistance, so can prolonged antiviral use. Resistance of the herpes simplex virus (HSV) to oral acyclovir is thought to be rather low, with reports of 0.6% in immunocompetent patients. However, in immunosuppressed patients, the resistance rate jumps anywhere from 3% to 6%.

Resistance is usually due to a mutation of the thymidine kinase gene, which is needed to convert acyclovir, valacyclovir, famciclovir and ganciclovir in order to inhibit viral replication. “In such cases,” Dr. Rapuano advises, “one can



**A 54-year-old man with a history of a pterygium in this eye presented with a large central HSV dendrite. It was treated with oral valacyclovir and resolved. He has been maintained on prophylactic oral valacyclovir to prevent recurrences, especially as this dendrite was so large and central.**

About Dr. Shovlin

Dr. Shovlin, a senior optometrist at Northeastern Eye Institute in Scranton, PA, is a fellow and past president of the American Academy of Optometry. He consults for Kala, Aerie, AbbVie, Novartis, Hubble and Bausch + Lomb and is on the medical advisory panel for Lentechs.

# ADVERTISER INDEX

This index is published as a convenience and not as part of the advertising contract. Every care will be taken to index correctly. No allowance will be made for errors due to spelling, incorrect page number, or failure to insert.

consider using high-dose IV acyclovir to overcome the resistance, but that can induce renal toxicity.” Interestingly, he notes, studies have not looked at alternating regimens of chronic antiviral medications to reduce resistance, but as these medications all have a similar mechanism of action, this approach may not be promising.

There are some antiviral drugs that do not rely on thymidine kinase phosphorylation, including foscarnet and cidofovir, Dr. Rapuano adds. Foscarnet is currently indicated for cytomegalovirus (CMV) retinitis and mucocutaneous acyclovir-resistant HSV. It is only available as an IV medication and has numerous side effects, including renal abnormalities. Cidofovir, typically used for CMV retinitis, is also an IV medication that can be used when foscarnet is unsuccessful in acyclovir-resistant patients. Unfortunately, it has even more side effects than foscarnet, reportedly including renal failure after just one or two doses. Consequently, these drugs are generally reserved for severe herpes simplex infections. One can consider using topical trifluridine (but this is quite toxic to the corneal surface) to vidarabine (not commonly available), which may be effective.

Dr. Rapuano summarizes that resistance to the commonly used prophylactic antiviral medications for HSV keratitis is rare in immunocompetent patients, but not as rare in immunosuppressed patients, so antiviral resistance should be kept in mind when considering this population. High-dose IV acyclovir, IV foscarnet or IV cidofovir can be considered in severe cases. “The good news is that new therapies, including RNA peptides, cationic peptide therapy and interferon alpha-2b, are being investigated to treat acyclovir resistant HSV,” he says. ■

1. Acyclovir for the prevention of recurrent herpes simplex virus eye disease. Herpetic Eye Disease Study Group. N Engl J Med. 1998;339(5):300-6.

2. Esra N, Hollhumer R. Herpes simplex virus-related conjunctivitis resistant to aciclovir: a case report and review of the literature. Cornea. 2021;40(8):1055-8.

3. Moshirfar M, Kelkar N, Peterson T, et al. The impact of antiviral resistance on herpetic keratitis. Eye Contact Lens. 2023;49(3):127-34.

<b>Acuity Pro</b> .....	<b>39</b>	<b>Notal Vision</b> .....	<b>15</b>
.....(580) 243-1301		.....1-855-600-3112	
..... <a href="mailto:info@acuitypro.com">info@acuitypro.com</a>		..... <a href="http://www.notalvision.com">www.notalvision.com</a>	
..... <a href="http://www.acuitypro.com">www.acuitypro.com</a>			
<b>Apellis</b> .....	<b>19</b>	<b>Novartis Pharmaceuticals</b> .....	<b>Cover 2-4</b>
..... <a href="http://www.apellis.com">www.apellis.com</a>		.....862 778 21 00	
		..... <a href="http://www.novartis.com">www.novartis.com</a>	
<b>Bausch + Lomb</b> .....	<b>Cover Tip</b>	<b>Oculus, Inc.</b> .....	<b>9</b>
.....866-246-8245		.....(888) 519-5375	
..... <a href="http://www.bauschcontactlenses.com/contacts/infuse-one-day">www.bauschcontactlenses.com/contacts/infuse-one-day</a>		..... <a href="mailto:ads@oculususa.com">ads@oculususa.com</a>	
		..... <a href="http://en.oculus.de">en.oculus.de</a>	
<b>Bruder Healthcare Company</b> .....	<b>35</b>	<b>Ocusoft</b> .....	<b>53</b>
.....(888) 827-8337		.....(800) 233-5469	
..... <a href="mailto:eyes@bruder.com">eyes@bruder.com</a>		..... <a href="http://www.ocusoft.com">www.ocusoft.com</a>	
..... <a href="http://www.bruder.com">www.bruder.com</a>			
<b>Coburn Technologies</b> .....	<b>61</b>	<b>Olleyes</b> .....	<b>47</b>
.....(800) COBURN-1		.....(855) 655-3937	
..... <a href="http://www.coburntechnologies.com">www.coburntechnologies.com</a>		..... <a href="mailto:info@olleyes.com">info@olleyes.com</a>	
		..... <a href="http://www.olleyes.com">www.olleyes.com</a>	
<b>CooperVision</b> .....	<b>Cover 3</b>	<b>Reichert Technologies</b> .....	<b>70, 71</b>
.....800-341-2020		.....(888) 849-8955	
..... <a href="http://www.coopervision.com">www.coopervision.com</a>		..... <a href="http://www.reichert.com">www.reichert.com</a>	
<b>CooperVision</b> .....	<b>21</b>	<b>SleepTite</b> .....	<b>85</b>
.....800-341-2020		..... <a href="http://www.eyesleeptite.com">www.eyesleeptite.com</a>	
..... <a href="http://www.coopervision.com">www.coopervision.com</a>			
<b>CooperVision</b> .....	<b>82, 83</b>	<b>Tarsus</b> .....	<b>COVER 4</b>
.....800-341-2020		..... <a href="http://www.tarsusrx.com">www.tarsusrx.com</a>	
..... <a href="http://www.coopervision.com">www.coopervision.com</a>			
<b>Eye Designs</b> .....	<b>13</b>	<b>TelScreen</b> .....	<b>89</b>
.....(800) 346-8890		.....502-515-1806	
..... <a href="http://www.eyedesigns.com">www.eyedesigns.com</a>		..... <a href="http://www.TelScreen.com">www.TelScreen.com</a>	
<b>Heidelberg Engineering</b> .....	<b>57</b>	<b>Thea Pharma</b> .....	<b>17</b>
.....(508) 530-7900		.....781-832-3664	
..... <a href="http://www.heidelbergengineering.com/us">www.heidelbergengineering.com/us</a>		..... <a href="http://www.ijuzeh.com">www.ijuzeh.com</a>	
<b>Icare USA</b> .....	<b>49</b>	<b>Thea Pharma</b> .....	<b>23</b>
.....(888) 422-7313		.....781-832-3664	
..... <a href="mailto:infoUSA@icare-world.com">infoUSA@icare-world.com</a>		..... <a href="http://www.theapharmainc.com/preservative-free">www.theapharmainc.com/preservative-free</a>	
..... <a href="http://www.icare-world.com/USA">www.icare-world.com/USA</a>			
<b>Iveric Bio</b> .....	<b>30-32</b>	<b>Thea Pharma</b> .....	<b>25</b>
..... <a href="http://www.IvericBio.com">www.IvericBio.com</a>		.....781-832-3664	
		..... <a href="http://www.www.ivizia.com">www.www.ivizia.com</a>	
<b>Johnson &amp; Johnson</b> .....	<b>42, 43</b>	<b>Topcon</b> .....	<b>11</b>
.....800-874-5278		.....201-599-5100	
..... <a href="http://www.jnjvisionpro.com">www.jnjvisionpro.com</a>		..... <a href="http://www.topconhealthcare.com">www.topconhealthcare.com</a>	
<b>LKC</b> .....	<b>63</b>	<b>X-Cel</b> .....	<b>55</b>
.....301 840 1992		.....800-241-9312	
..... <a href="http://www.lkc.com">www.lkc.com</a>		..... <a href="http://www.xcelspecialtycontacts.com">www.xcelspecialtycontacts.com</a>	
<b>Lombart</b> .....	<b>87</b>		
.....800-LOMBART			
..... <a href="http://www.lombartinstrument.com">www.lombartinstrument.com</a>			
<b>Marco</b> .....	<b>65</b>		
.....(800) 874-5274			
..... <a href="http://www.marco.com">www.marco.com</a>			
<b>Meivertor</b> .....	<b>91</b>		
..... <a href="http://www.Meivertor.com">www.Meivertor.com</a>			



# PRODUCT REVIEW

New items to improve clinical care and strengthen your practice.



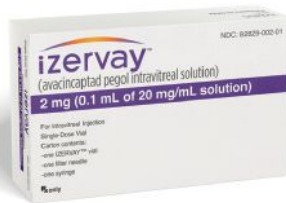
**ONLINE FIRST:**  
GET THE LATEST  
PRODUCT NEWS AT  
[www.reviewofoptometry.com](http://www.reviewofoptometry.com)

## ► PHARMACEUTICALS

### **New GA Drug from Iveric Bio Approved**

Last month, the FDA approved the second drug in the emerging market for geographic atrophy treatment: Izervay (avacincaptad pegol intravitreal solution, 2mg). The complement C5 inhibitor from Iveric Bio demonstrated an ability to significantly reduce the rate of disease progression at 12 months in both of its Phase III clinical trials, Gather1 and Gather2.

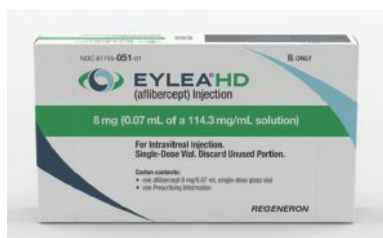The drug is intended to be administered monthly via intravitreal injection to patients with GA secondary to AMD. In Phase III trials, slowing of disease progression was observed after as few as six injections; after 12 injections, patients experienced up to a 35% reduction in GA progression rate compared with sham.



Iveric Bio reports the most common adverse reactions at 12 months were conjunctival hemorrhage (13%), increased IOP (9%) and blurry vision (8%).

### **Eylea HD 8mg Injection for Wet AMD, DME, DR**

Anti-VEGF therapy revolutionized the treatment of many intractable retinal problems, but burdened patients and practices with a busy schedule of office visits for injections, initially administered monthly. When Eylea launched over a decade ago at a 2mg dose, the drug was able to push the maintenance interval to bimonthly in many cases. Now, a newly approved high-dose formulation may extend that to 16 weeks in some clinical scenarios, according to manufacturer Regeneron. The positive results of two clinical trials, Photon and Pulsar, sparked the drug's approval, demonstrating non-inferiority and clinically equivalent vision gains at 48 weeks with eight-, 12- and 16-week dosing regimens after the three initial monthly doses.



The new formulation—called Eylea HD—is approved to treat wet AMD, diabetic macular edema and diabetic retinopathy. The recommended regimen is monthly injections for the first three months followed by treatments every eight to 16 weeks in wet AMD and DME and every eight to 12 weeks for DR.

Regeneron reported that adverse reactions, occurring in 3% or fewer patients, included cataract, conjunctival hemorrhage, increased IOP, ocular discomfort, eye pain or irritation, blurry

vision, floaters, vitreous detachment, corneal epithelium defect and retinal hemorrhage.

## ► CORRECTIVE LENSES

### **Spectacle Lens To Improve Day/Night Vision for Drivers**

Certain spectacle lenses designed to sharpen vision, reduce glare and widen the visual field may benefit those who want to see clearer on the road during the day and at night. One option for these patients to recently hit the market is Shamir Insight's Driver Intelligence lens. The lenses come in a pack of two: one lens for daytime ("Sun"), and one for nighttime ("Moon").



The company says it used some high-tech tools, including artificial intelligence and eye tracking, to develop the lenses. After testing them on a racetrack, Shamir reported the following statistics on their performance in that setting:

- 16% reduction in visual information processing effort vs. regular lenses
- 33% wider horizontal visual field and 18% longer vertical visual field
- 15% faster reaction time at night and 11% faster reaction time during the day
- Improved nighttime vision using myopic shift compensation and low-reflection coating

The "Sun" lens features a coating intended to reduce sun glare and improve its durability, while the anti-reflective coating on the "Moon" lens provides a 25% increase in contrast sensitivity, visual noise reduction and improved reaction time, the company reports.

### **Scleral Lens 'Microvault' Option for Hard-to-fit Eyes**

In patients with scleral abnormalities such as pingueculae or filtering blebs, adding a microvault to their scleral lenses can help to avoid compression on the elevated area of the conjunctiva. Art Optical recently announced the addition of this feature to the company's Ampleye scleral lens. The new option allows the microvault to be customized and placed at any point along the 360° edge of the lens based on the estimated width and height of the scleral elevation.

Beyond the new microvault capability, Art Optical says that practitioners will also have full control of the following lens parameters: all four independent fitting zones, lens size between 15mm and 17mm, front surface toricity, quadrant-specific peripheral adjustments and multifocal optics with near zone decentration, among others. ■

# Find qualified opticians fast

Finding a qualified optician for your practice can be difficult. That's why private practices and large employers alike trust Eyes On Eyecare® for specialized job posting and recruiting services.

## SOURCE TALENT MORE EFFICIENTLY WITH OUR:



Large talent pool of active and passive job seekers



Syndication to major job platforms and cross-promotion to our affiliate network



Dedicated recruiting team with years of eyecare experience sourcing talent for specialized positions



*"I had such a wonderful experience using Eyes On Eyecare. It was so easy to post a job and they walk you through the entire process. I recommend them to everyone I know."*

*- Ashley Wojcik*

PROUD PARTNER OF JOBSON OPTICAL GROUP

Learn more at [eyesoneyecare.com/hire-now](https://eyesoneyecare.com/hire-now)

Contact Lenses

**INDUSTRY LEADING SERVICE | LOWEST PRICES | SAME DAY SHIPPING \***

**JOHNSON & JOHNSON**

Acuvue 1 Day Oasys (90 Pack)  
Acuvue Oasys (12 Pack)  
Acuvue Vita (6 Pack)

AS LOW AS  
\$69.95  
\$48.95  
\$36.95

**COOPERVISION**

Biofinity (6 Pack)  
Biofinity Toric (6 Pack)  
Biofinity Energy (6 Pack)

AS LOW AS  
\$29.50  
\$40.50  
\$31.95

**BAUSCH & LOMB**

Biotrue (90 Pack)  
Ultra (6 Pack)  
Ultra Presbyopia (6 Pack)

AS LOW AS  
\$41.95  
\$29.95  
\$51.95



**National-Lens.com**

Call for our current price list  
or visit our website to register  
**866.923.5600**

\*Some restrictions apply, contact us for details

**Practice For Sale**



Practice Sales • Appraisals • Consulting  
[www.PracticeConsultants.com](http://www.PracticeConsultants.com)

**PRACTICES FOR SALE  
NATIONWIDE**

Visit us on the Web or call us to learn  
more about our company and the  
practices we have available.

[info@PracticeConsultants.com](mailto:info@PracticeConsultants.com)

**925-820-6758**

[www.PracticeConsultants.com](http://www.PracticeConsultants.com)

Targeting Optometrists?

**CLASSIFIED ADVERTISING WORKS**

- JOB OPENINGS
- CME PROGRAMS
- PRODUCTS & SERVICES
- AND MORE...

Contact us today for classified advertising:  
Toll free: **888-498-1460**

E-mail: [sales@kerhgroup.com](mailto:sales@kerhgroup.com)

Contact us today for  
classified advertising:  
Toll free: **888-498-1460**  
E-mail: [sales@kerhgroup.com](mailto:sales@kerhgroup.com)

**REVIEW**  
of OPTOMETRY

**Grow Your Practice**



**Low Vision Intensive  
Training 4-day Course**

We teach how to:

- create a consistent flow of qualified patients
- conduct the *Shuldiner 12-Step Low Vision Evaluation* in less than an hour
- make low vision in private practice *professionally and financially rewarding*

**TURNKEY** | Low Financial Risk  
20+ Years of Success with 50+ Practices

Learn how to profitably incorporate  
Low Vision Care into your practice at:  
[ShuldinerLowVisionTrainingInstitute.org](http://ShuldinerLowVisionTrainingInstitute.org)

Or contact

**Richard J. Shuldiner, OD, FAAO**  
Low Vision Diplomate, AAO

Founder, Shuldiner Low Vision Training Institute  
(951) 286-2020 | [doctor@lowvisioncare.com](mailto:doctor@lowvisioncare.com)



Contact Lenses

# Impressions

Color Contact Lens

*Unleash your true color!*

Impressions colored contacts blend naturally with your patients eyes to create a beautiful look. Available in nine dazzling opaque colors.



★ Brown   ★ Grey   ★ Green   Turquoise   ★ Hazel   ★ Honey   ★ Pure Hazel   ★ True Sapphire  
 \* Available in RX PL to -8.00

Impressions are fun, hip, fashionable, comparable to other color contact lenses and very competitively priced to help your bottom line.  
 - Free Trial Kit and P.O.P. Materials with Purchase -



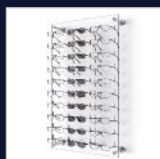
866.923.5600  
 National-Lens.com



Merchandise Offered

## FRAME DISPLAYS & OPTICAL INTERIORS


FrameDisplays.com is the one-stop-shop for all your optical displays, furniture, and design needs.



Wall Mount



Counter Top



Locking Rods



Trays & Frame Bags



Custom Frame Rods



Optical Cabinets

Trusted by more than 40,000 eye care professionals worldwide.

### COMPLIMENTARY DESIGN SERVICES



1-877-274-9300 • www.framedisplays.com



Complimentary Zoom Design Session



0% Financing & Interest for 36 Months\*



# Split the Difference

*Should you worry about the current or future status of an eye that presents like this?*

**A**n 85-year-old Hispanic female presented to the office for a routine eye examination with a chief complaint of blurry vision. She had been told by another eye care practitioner that she had cataracts in both eyes, was a glaucoma suspect because her optic nerves were big and

that she had a “birthmark” in the back of the right eye, which did not require treatment. Her systemic history was remarkable for hypertension and dyslipidemia, for which she was properly medicated. She denied ocular trauma and had no allergies to medications or environmental factors.

## Clinical Findings

Her best-corrected entering visual acuities were 20/25 OD and 20/25 OS at distance and near with no improvement upon the use of pinhole or refraction. Her external examination was remarkable for metamorphopsia and constriction of the superior nasal periphery of the right eye upon facial Amsler, confirmed with Amsler grid. The left eye was normal. All other external findings were normal and there was no afferent pupillary defect.

Biomicroscopy of both eyes found normal anterior segment structures and nuclear sclerotic cataracts OU. Her intraocular pressures measured 13mm Hg in both eyes by Goldmann applanation. The pertinent posterior segment finding OD is demonstrated in the photograph.

Her cup-to-disc ratios measured 0.5/0.5 OU with distinct pink rims. The retinal periphery of the left eye was unremarkable.

## Your Diagnosis

What would be your diagnosis in this case based on the findings presented? What’s the likely prognosis? Which interventions, if any, would you recommend? To find out, read the online version of this article at [www.reviewofoptometry.com](http://www.reviewofoptometry.com). ■

*Dr. Gurwood thanks Dr. Korey Patrizi for contributing this case.*

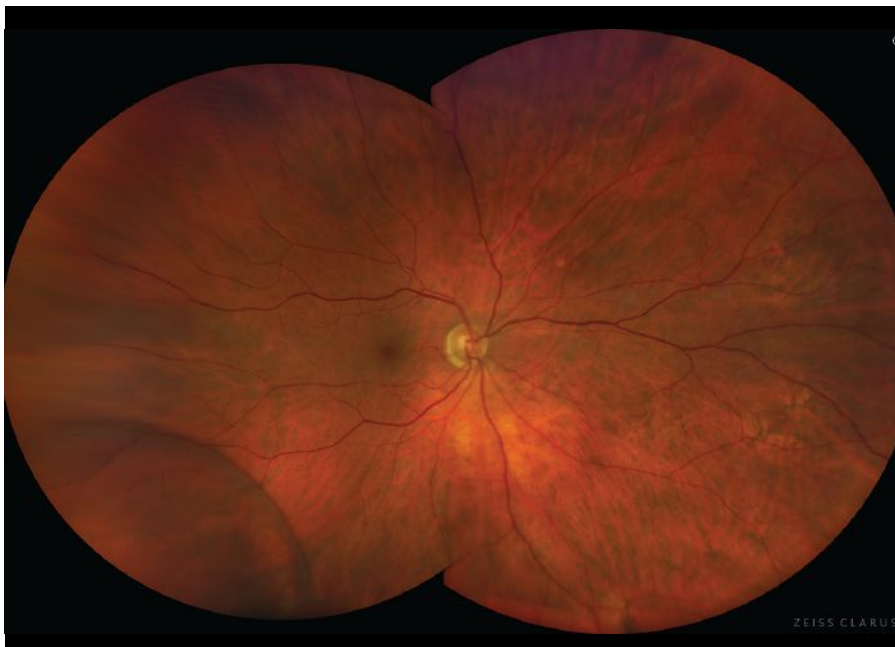

Photo: Jay M. Haynie, OD

This photo of a different patient with the same condition shows a comparable presentation.

### About Dr. Gurwood

Dr. Gurwood is a professor of clinical sciences at The Eye Institute of the Pennsylvania College of Optometry at Salus University. He is a co-chief of Primary Care Suite 3. He is attending medical staff in the department of ophthalmology at Albert Einstein Medical Center, Philadelphia. He has no financial interests to disclose.

## Retina Quiz Answers (from page 96)—Q1: c, Q2: d, Q3: d, Q4: d, Q5: b

### NEXT MONTH IN THE MAG

In October, we present an issue devoted to topics in eyelid health. Articles will include:

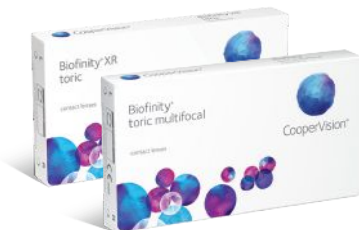- Follow This Practical Ptosis Workup
- Differentiating Benign vs. Malignant Eyelid Tumors and Lesions
- Are You Ready to Add Meibomian Gland Expression and Blepharoxfoliation?
- Common Eyelid Surgeries: Indications and Complications
- Five Questions About How the New *Demodex* Therapy Works in Practice



Want to fit more patients than ever before?

# YOU'RE GOLDEN

You're a hero to your patients—especially those who thought they could never wear contacts. Biofinity® XR toric and toric multifocal are available in more than **238,000 unique prescriptions**<sup>1</sup>—more than 7x the parameter options of all other monthly brands combined<sup>2</sup>. Which means you can give virtually all of your patients incredible comfort thanks to Aquaform® Technology and grow your business at the same time.<sup>3,4</sup> With Biofinity®, you're golden.




Biofinity® | CooperVision®  
XR toric | toric multifocal

NOW  
AVAILABLE  
FASTER




1. CVI data on file, 2023. Based on total number of prescription option combinations (for sphere, cylinder, axis and add - including D & N combinations) manufactured.
  2. CVI data on file, 2020. Based on number of parameter options available in the USA across all so lenses from the 4 main manufacturers as reported by Tylers Quarterly Sept 2020.
  3. CVI data on file 2021. Rx coverage database; 14-70 years.
  4. CVI data on file 2022. Based on global product sales and internal estimates of products using Aquaform® Technology over 12 months in 2022.
- ©2023 CooperVision 18156ROO 8/23





**xdemvy**<sup>TM</sup>  
(lotilaner ophthalmic  
solution) 0.25%

**NOW AVAILABLE TO PRESCRIBE**



Learn more at [XDEMYYHCP.com](https://www.XDEMYYHCP.com)



Tarsus, XDEMYY, and the associated logos are trademarks of Tarsus Pharmaceuticals, Inc.

© 2023 Tarsus Pharmaceuticals, Inc. US--2300350 9/23