

# REVIEW<sup>®</sup> of OPTOMETRY

September 15, 2022 • reviewofoptometry.com

Leadership in clinical care

EARN 2 CE CREDITS  
**Take Control of the  
Nutrition Conversation**  
PAGE 73

45th Annual TECHNOLOGY REPORT

## WHAT'S POWERING THE NEXT WAVE

### OFFER PATIENTS AN **EXCEPTIONAL LENS EXPERIENCE**

Eye Care Professionals across the nation are sharing their success with Bausch + Lomb INFUSE<sup>®</sup>. See the impact it can have on your practice and patients, too.



SCAN CODE TO WATCH  
PEER TESTIMONIALS



HERE'S A SNEAK  
PEEK AT WHAT  
YOUR PEERS  
ARE SAYING:

"INFUSE<sup>®</sup> has great comfort, vision, and oxygen transmissibility."

- Dr Michelle Mumford

"The lens speaks for itself."


- Dr Scott Moscow

"INFUSE<sup>®</sup> helps address symptoms of contact lens dryness."

- Dr Kevin Nehaul

"INFUSE<sup>®</sup> has what I call 'the WOW factor.'"

- Dr Richard Goellner



# REVIEW<sup>®</sup> *of* OPTOMETRY

September 15, 2022 • reviewofoptometry.com

Leadership in clinical care

EARN 2 CE CREDITS

Take Control of the  
Nutrition Conversation

PAGE 73

45th Annual **TECHNOLOGY REPORT**

## WHAT'S POWERING THE NEXT WAVE?

*Find out how AI, telehealth, OCT and other new clinical devices are helping ODs build out their practice for the future.*

---

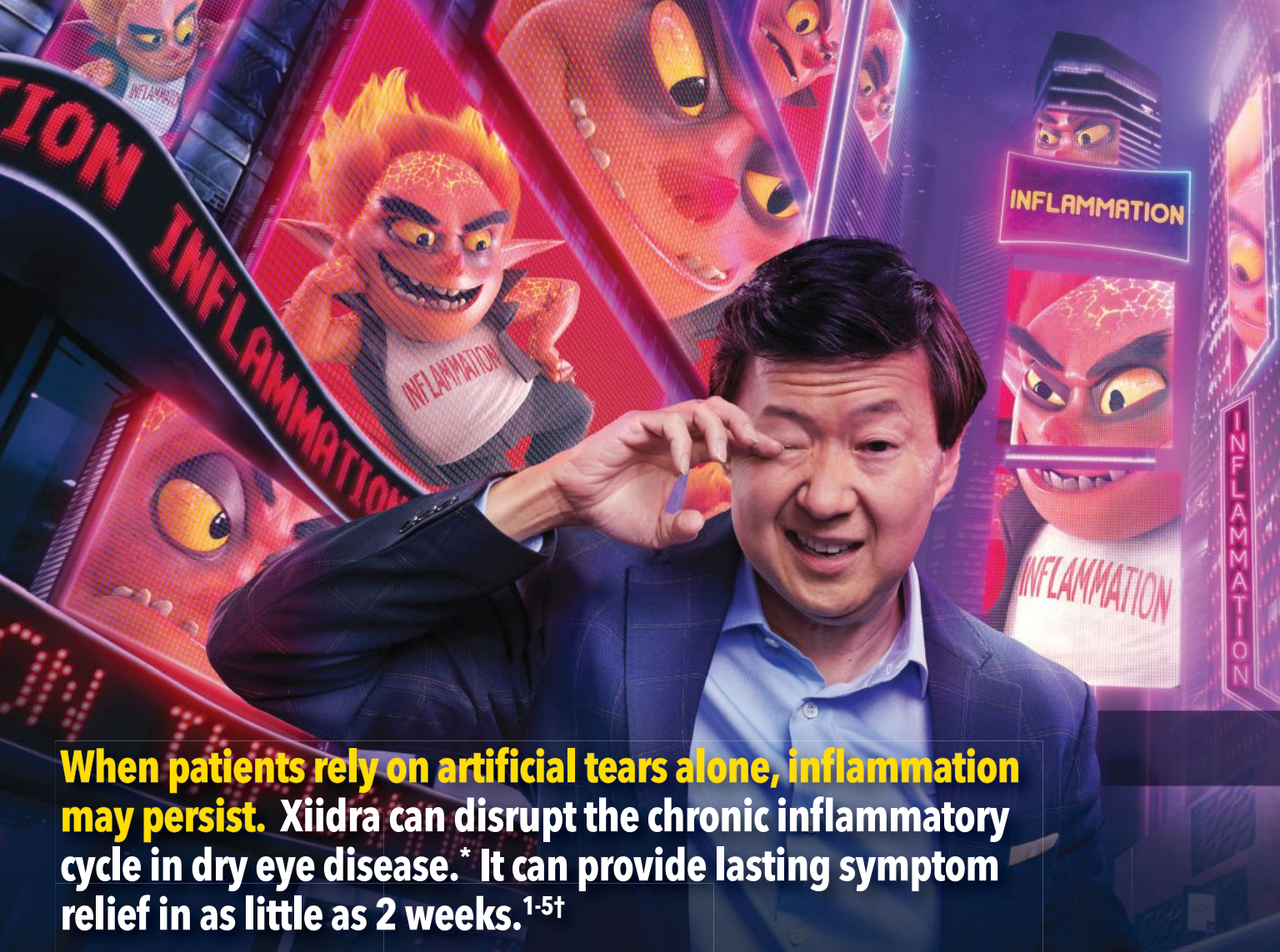New Technology Purchases:  
How and Why ODs Buy  
**Page 38**

OCT: What's Under the Hood?  
**Page 44**

Telemedicine:  
What We've Learned and What's to Come  
**Page 54**

Is Artificial Intelligence  
Smart Enough Yet to Help Us?  
**Page 62**





**When patients rely on artificial tears alone, inflammation may persist. Xiidra can disrupt the chronic inflammatory cycle in dry eye disease.\* It can provide lasting symptom relief in as little as 2 weeks.<sup>1-5†</sup>**

\*Xiidra blocks LFA-1 on T cells from binding with ICAM-1 that may be overexpressed on the ocular surface in dry eye disease and may prevent formation of an immunologic synapse which, based on in vitro studies, may inhibit T-cell activation, migration of activated T cells to the ocular surface, and reduce cytokine release. The exact mechanism of action of Xiidra in DED is not known.<sup>1,2,5</sup>

†The safety and efficacy of Xiidra were assessed in four 12-week, randomized, multicenter, double-masked, vehicle controlled studies (N=2133). Patients were dosed twice daily. The mean age was 59 years (range, 19-97 years). The majority of patients were female (76%). Use of artificial tears was not allowed during the studies. The study end points included assessment of signs (based on Inferior fluorescein Corneal Staining Score [ICSS] on a scale of 0 to 4) and symptoms (based on patient-reported EDS on a visual analogue scale of 0 to 100). Effects on symptoms of dry eye disease: a larger reduction in EDS favoring Xiidra was observed in all studies at day 42 and day 84. Xiidra reduced symptoms of eye dryness at 2 weeks (based on EDS) compared to vehicle in 2 out of 4 clinical trials. Effects on signs of dry eye disease: at day 84, a larger reduction in ICSS favoring Xiidra was observed in 3 out of the 4 studies.<sup>1</sup>

## Indication

Xiidra® (lifitegrast ophthalmic solution) 5% is indicated for the treatment of signs and symptoms of dry eye disease (DED).

## Important Safety Information

- Xiidra is contraindicated in patients with known hypersensitivity to lifitegrast or to any of the other ingredients.



**Novartis Pharmaceuticals Corporation**  
East Hanover, New Jersey 07936-1080



**KEN JEONG,**  
REAL DRY EYE PATIENT.

### Important Safety Information (cont)

- In clinical trials, the most common adverse reactions reported in 5-25% of patients were instillation site irritation, dysgeusia and reduced visual acuity. Other adverse reactions reported in 1% to 5% of the patients were blurred vision, conjunctival hyperemia, eye irritation, headache, increased lacrimation, eye discharge, eye discomfort, eye pruritus and sinusitis.
- To avoid the potential for eye injury or contamination of the solution, patients should not touch the tip of the single-use container to their eye or to any surface.
- Contact lenses should be removed prior to the administration of Xiidra and may be reinserted 15 minutes following administration.
- Safety and efficacy in pediatric patients below the age of 17 years have not been established.

**For additional safety information about XIIDRA<sup>®</sup>, please refer to the brief summary of Full Prescribing Information on adjacent page.**

**References:** **1.** Xiidra [package insert]. East Hanover, NJ: Novartis Pharmaceuticals Corp; June 2020. **2.** Bron AJ, de Paiva CS, Chauhan SK, et al. TFOS DEWS II Pathophysiology Report. *Ocul Surf.* 2017;15(3):438-510. **3.** US Food and Drug Administration. Code of Federal Regulations, Title 21, Volume 5 (21CFR349). Accessed May 25, 2021. <https://www.accessdata.fda.gov/scripts/cdrh/cfdocs/cfcfr/CFRSearch.cfm?CFRPart=349&showFR=1> **4.** Jones L, Downie LE, Korb D, et al. TFOS DEWS II Management and Therapy Report. *Ocul Surf.* 2017;15(3):575-628. **5.** Pflugfelder SC, Stern M, Zhang S, Shojaei A. LFA-1/ICAM-1 interaction as a therapeutic target in dry eye disease. *J Ocul Pharmacol Ther.* 2017;33(1):5-12.

**XIIDRA, the XIIDRA logo and ii are registered trademarks of Novartis AG.**

## **Xiidra® (lifitegrast ophthalmic solution), for topical ophthalmic use**

**Initial U.S. Approval: 2016**

**BRIEF SUMMARY: Please see package insert for full prescribing information.**

### **1 INDICATIONS AND USAGE**

Xiidra® (lifitegrast ophthalmic solution) 5% is indicated for the treatment of the signs and symptoms of dry eye disease (DED).

### **4 CONTRAINDICATIONS**

Xiidra is contraindicated in patients with known hypersensitivity to lifitegrast or to any of the other ingredients in the formulation [see *Adverse Reactions (6.2)*].

### **6 ADVERSE REACTIONS**

The following serious adverse reactions are described elsewhere in the labeling:

- Hypersensitivity [see *Contraindications (4)*]

#### **6.1 Clinical Trials Experience**

Because clinical trials are conducted under widely varying conditions, adverse reaction rates observed in clinical trials of a drug cannot be directly compared to rates in the clinical trials of another drug and may not reflect the rates observed in practice.

In five clinical trials of DED conducted with lifitegrast ophthalmic solution, 1401 patients received at least one dose of lifitegrast (1287 of which received lifitegrast 5%). The majority of patients (84%) had less than or equal to 3 months of treatment exposure. One hundred-seventy patients were exposed to lifitegrast for approximately 12 months. The majority of the treated patients were female (77%). The most common adverse reactions reported in 5%-25% of patients were instillation-site irritation, dysgeusia, and reduced visual acuity.

Other adverse reactions reported in 1%-5% of the patients were blurred vision, conjunctival hyperemia, eye irritation, headache, increased lacrimation, eye discharge, eye discomfort, eye pruritus, and sinusitis.

#### **6.2 Postmarketing Experience**

The following adverse reactions have been identified during post-approval use of Xiidra. Because these reactions are reported voluntarily from a population of uncertain size, it is not always possible to reliably estimate their frequency or establish a causal relationship to drug exposure.

Rare serious cases of hypersensitivity, including anaphylactic reaction, bronchospasm, respiratory distress, pharyngeal edema, swollen tongue, urticaria, allergic conjunctivitis, dyspnea, angioedema, and allergic dermatitis have been reported. Eye swelling and rash have also been reported [see *Contraindications (4)*].

### **8 USE IN SPECIFIC POPULATIONS**

#### **8.1 Pregnancy**

##### Risk Summary

There are no available data on Xiidra use in pregnant women to inform any drug-associated risks. Intravenous (IV) administration of lifitegrast to pregnant rats, from pre-mating through gestation day 17, did not produce

teratogenicity at clinically relevant systemic exposures. Intravenous administration of lifitegrast to pregnant rabbits during organogenesis produced an increased incidence of omphalocele at the lowest dose tested, 3 mg/kg/day (400-fold the human plasma exposure at the recommended human ophthalmic dose [RHOD], based on the area under the curve [AUC] level). Since human systemic exposure to lifitegrast following ocular administration of Xiidra at the RHOD is low, the applicability of animal findings to the risk of Xiidra use in humans during pregnancy is unclear [see *Clinical Pharmacology (12.3) in the full prescribing information*].

##### Data

##### Animal Data

Lifitegrast administered daily by IV injection to rats, from pre-mating through gestation day 17, caused an increase in mean pre-implantation loss and an increased incidence of several minor skeletal anomalies at 30 mg/kg/day, representing 5,400-fold the human plasma exposure at the RHOD of Xiidra, based on AUC. No teratogenicity was observed in the rat at 10 mg/kg/day (460-fold the human plasma exposure at the RHOD, based on AUC). In the rabbit, an increased incidence of omphalocele was observed at the lowest dose tested, 3 mg/kg/day (400-fold the human plasma exposure at the RHOD, based on AUC), when administered by IV injection daily from gestation days 7 through 19. A fetal no observed adverse effect level (NOAEL) was not identified in the rabbit.

#### **8.2 Lactation**

##### Risk Summary

There are no data on the presence of lifitegrast in human milk, the effects on the breastfed infant, or the effects on milk production. However, systemic exposure to lifitegrast from ocular administration is low [see *Clinical Pharmacology (12.3) in the full prescribing information*]. The developmental and health benefits of breastfeeding should be considered, along with the mother's clinical need for Xiidra and any potential adverse effects on the breastfed child from Xiidra.

#### **8.4 Pediatric Use**

Safety and efficacy in pediatric patients below the age of 17 years have not been established.

#### **8.5 Geriatric Use**

No overall differences in safety or effectiveness have been observed between elderly and younger adult patients.

Distributed by:  
Novartis Pharmaceuticals Corporation  
One Health Plaza  
East Hanover, NJ 07936  
T2020-87

## CLINICAL EDITORS

**CHIEF CLINICAL EDITOR** ~ PAUL M. KARPECKI, OD

**ASSOCIATE CLINICAL EDITORS** ~ JOSEPH P. SHOVLIN, OD, CHRISTINE SINDT, OD

## CONTRIBUTING EDITORS

**PAUL C. AJAMIAN, OD, ATLANTA**

**ALISON BOZUNG, OD, MIAMI**

**DEREK N. CUNNINGHAM, OD, AUSTIN, TEX.**

**MARK T. DUNBAR, OD, MIAMI**

**JAMES L. FANELLI, OD, WILMINGTON, NC**

**ANDREW S. GURWOOD, OD, PHILADELPHIA**

**PAUL M. KARPECKI, OD, LEXINGTON, KY.**

**BISANT LABIB, OD, ELKINS PARK, PA**

**PAMELA H. SCHNELL, OD, MEMPHIS, TENN.**

**JOSEPH P. SHOVLIN, OD, SCRANTON, PA**

**JOSEPH W. SOWKA, OD, FORT LAUDERDALE, FLA.**

**MARC TAUB, OD, MEMPHIS, TENN.**

**MONTGOMERY VICKERS, OD, DALLAS**

**WALTER O. WHITLEY, OD, MBA, VIRGINIA BEACH, VA.**

## EDITORIAL ADVISORY BOARD

**JEFFREY R. ANSHEL, OD, ENCINITAS, CALIF.**

**JILL AUTRY, OD, RPH, HOUSTON**

**SHERRY J. BASS, OD, NEW YORK**

**EDWARD S. BENNETT, OD, ST. LOUIS**

**MARC R. BLOOMENSTEIN, OD, SCOTTSDALE, ARIZ.**

**ALISON BOZUNG, OD, MIAMI**

**AARON BRONNER, OD, KENNEWICK, WASH.**

**MILE BRUJIC, OD, BOWLING GREEN, OHIO**

**CHRIS J. CAKANAC, OD, MURRYSVILLE, PA**

**JERRY CAVALLERANO, OD, PhD, BOSTON**

**BRIAN CHOU, OD, SAN DIEGO**

**MICHAEL CHAGLASIAN, OD, CHICAGO**

**A. PAUL CHOUS, MA, OD, TACOMA, WASH.**

**GLENN S. CORBIN, OD, WYOMISSING, PA**

**MICHAEL DELGIODICE, OD, CLIFTON, NJ**

**S. BARRY EIDEN, OD, DEERFIELD, ILL.**

**ARTHUR B. EPSTEIN, OD, PHOENIX**

**STEVEN FERRUCCI, OD, SEPULVEDA, CALIF.**

**MURRAY FINGERET, OD, HEWLETT, NY**

**IAN BEN GADDIE, OD, LOUISVILLE, KY**

**GARY S. GERBER, OD, HAWTHORNE, NJ**

**JESSICA HAYNES, OD, MEMPHIS, TENN.**

**MILTON HOM, OD, AZUSA, CALIF.**

**DAVID KADING, OD, SEATTLE**

**JEROME A. LEGERTON, OD, MBA, SAN DIEGO**

**THOMAS L. LEWIS, OD, PhD, PHILADELPHIA**

**BLAIR B. LONSBERRY, MS, OD, MED, PORTLAND, OR**

**KELLY A. MALLOY, OD, PHILADELPHIA**

**DANICA MARRELLI, OD, HOUSTON, TEX.**

**RON MELTON, OD, CHARLOTTE, NC**

**PAMELA J. MILLER, OD, JD, HIGHLAND, CALIF.**

**MARC MYERS, OD, COATESVILLE, PA**

**CARLO J. PELINO, OD, JENKINTOWN, PA**

**JOSEPH PIZZIMENTI, OD, FORT LAUDERDALE, FLA.**

**CHRISTOPHER J. QUINN, OD, ISELIN, NJ**

**MOHAMMAD RAFIEETARY, OD, MEMPHIS, TENN.**

**JOHN L. SCHACHET, OD, ENGLEWOOD, COLO.**

**JACK SCHAEFFER, OD, BIRMINGHAM, ALA.**

**PAMELA H. SCHNELL, OD, MEMPHIS, TENN.**

**LEO P. SEMES, OD, BIRMINGHAM, ALA.**

**DIANA L. SHECHTMAN, OD, FORT LAUDERDALE, FLA.**

**JEROME SHERMAN, OD, NEW YORK, NY**

**LEONID SKORIN, JR., OD, DO, ROCHESTER, MINN.**

**JOSEPH W. SOWKA, OD, FORT LAUDERDALE, FLA.**

**JESSICA STEEN, OD, DAVIE, FLA.**

**BRAD M. SUTTON, OD, INDIANAPOLIS**

**LORETTA B. SZCZOTKA, OD, PhD, CLEVELAND**

**MARC TAUB, OD, MEMPHIS, TENN.**

**TAMMY P. THAN, MS, OD, BIRMINGHAM, ALA.**

**RANDALL THOMAS, OD, CONCORD, NC**

**SARA WEIDMAYER, OD, ANN ARBOR, MICH.**

**KAREN YEUNG, OD, LOS ANGELES**



### Business Offices

19 Campus Boulevard, Suite 101

Newtown Square, PA 19073

Subscription inquiries (877) 529-1746 (USA only)  
outside USA, call (847) 763-9630

### PUBLISHER

**MICHAEL HOSTER**

(610) 492-1028

mhoster@jobson.com

SENIOR MANAGER, STRATEGIC ACCOUNTS

**MICHELE BARRETT**

(610) 492-1014

mbarrett@jobson.com

REGIONAL SALES MANAGER

**JONATHAN DARDINE**

(610) 492-1030

jdardine@jobson.com

PRODUCTION MANAGER

**FARRAH APONTE**

(212) 274-7057

faponte@jobson.com

PRODUCTION MANAGER

**KAREN LALLONE**

(610) 492-1010

klallone@jobson.com

DIGITAL MARKETING MANAGER

**MATT EGGER**

(610) 492-1029

megger@jobson.com

### CLASSIFIED ADVERTISING

(888) 498-1460

### SUBSCRIPTIONS

\$63 PER YEAR, \$99 (US) IN CANADA,

\$158 (US) IN ALL OTHER COUNTRIES

revoptometry@cambeywest.com

### CIRCULATION

PO BOX 71, CONGERS, NY 10920-0071

(877) 529-1746

OUTSIDE USA: (845) 267-3065

SENIOR CIRCULATION MANAGER

**HAMILTON MAHER**

(212) 219-7870

hmaher@jhihealth.com

CEO, INFORMATION GROUP SERVICES

**MARC FERRARA**

SENIOR VICE PRESIDENT, OPERATIONS

**JEFF LEVITZ**

VICE PRESIDENT, HUMAN RESOURCES

**TAMMY GARCIA**

VICE PRESIDENT, CREATIVE SERVICES & PRODUCTION

**MONICA TETTAMANZI**

CORPORATE PRODUCTION DIRECTOR

**JOHN ANTHONY CAGGIANO**

VICE PRESIDENT, CIRCULATION

**JARED SONNERS**

Jobson Health Information/WebMD  
395 Hudson Street, 3rd Floor, New York, NY 10014

Phoroptor® VRx  
DIGITAL REFRACTION SYSTEM

Reichert®  
TECHNOLOGIES  
AMETEK®





# MORE EFFICIENT. BETTER CARE.

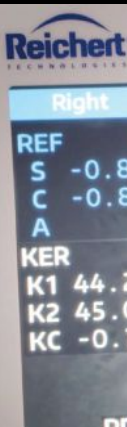
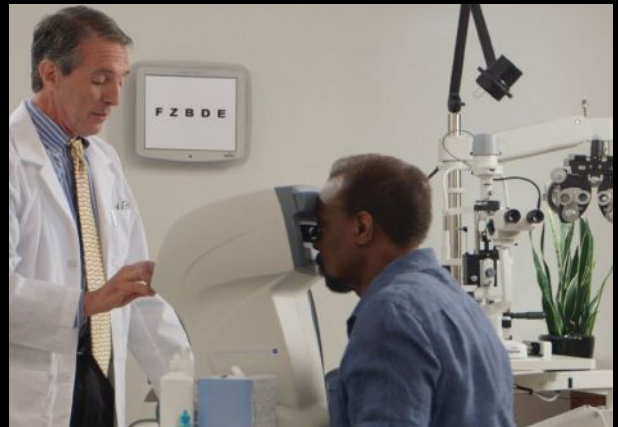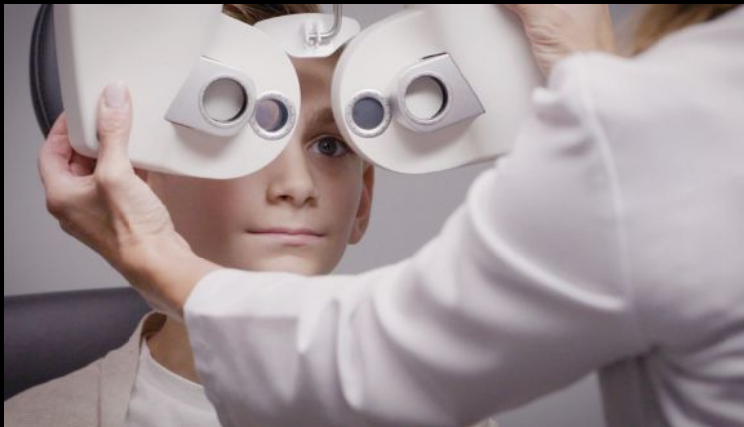Refract safely from across the room or across the Internet with Reichert's complete line of digital refraction devices, featuring **Phoroptor® VRx**, the most advanced Phoroptor® and **ClearChart® 4**, the pixel-perfect Digital Acuity System.

Improve glaucoma care with **Ocular Response Analyzer® G3** featuring Corneal Hysteresis + IOPcc and **Tono-Pen AVIA®**, the most trusted handheld tonometer.

LEARN MORE



LEARN MORE AT REICHERT.COM OR DEMO AT **VEW #F9043** FOR YOUR CHANCE TO WIN UP TO **\$1,500!**



*passionate about eye care*

# NEWS REVIEW

Clinical, legislative and practice development updates for ODs.



Get the latest at  
[www.reviewofoptometry.com/news](http://www.reviewofoptometry.com/news)  
Stories post every weekday

REUSABLE CONTACTS UP AT RISK, P.10 >> CATARACT SURGERY AND NAION, P.12 >> HEART AND EYE HEALTH CONNECTION, P.12 >> MYOPIA CONTROL GLASSES, P.14 >> NEGO TACKLES STUDENT DEBT, P.16 >> EXERCISE IMPROVES VISION IN CHILDREN, P.18

## Calif. Passes Historic Bill Allowing Optometric Surgery

*If signed into law, the state's nearly 7,000 ODs will have the opportunity to pursue laser procedures, lesion removal, several types of injections and corneal crosslinking.*

It's a watershed moment for optometrists in California—and their colleagues across the country. On August 31st, the state Assembly gave its final approval to bill AB 2236, which would expand the profession's scope of practice in California to include several advanced procedures, including lasers and some incisional surgeries. The victory came at 11:50pm Pacific time on the last day of the legislative calendar, after strident opposition nearly sunk the bill earlier in the session.

AB 2236, introduced in February by Assemblymember Evan Low, needed 41 votes to pass after a successful vote in the Senate earlier that week sent it back to the Assembly for concurrence with several amendments. The governor's signature, expected within 30 days, is the final step to California becoming the 11th state to include lasers in optometry's scope of practice.

If signed, ODs in California will be allowed to perform the following:

- Three types of laser procedures: selective laser trabeculoplasty, pe-

ripheral iridotomy for prophylactic treatment of angle-closure glaucoma and posterior capsulotomy secondary to cataract surgery.

- Lesion removal—skin tags, cysts and other non-cancerous growths.
- Injections to treat eye conditions (subcutaneous, intramuscular, subconjunctival and intraslesional).
- Corneal collagen crosslinking in keratoconus.

A few amendments had been made to the bill since its introduction, which is what the Assembly approved with their vote. Kristina Shultz, executive director of the California Optometric Association (COA), says one of these amendments addresses continued competency. "At every two-year license renewal, an optometrist is required to perform at least one of each procedure (rather than two in each category)," she explains. "This was intended to address the opposition's concern that all procedures may not be performed regularly." None of the other amendments significantly altered the bill, Ms. Shultz says.

Leading the opposition in the floor vote was Assemblymember Akilah Weber, MD, an OB/GYN, who rose to speak against it. "This is not the bill that we voted off the Assembly floor," she



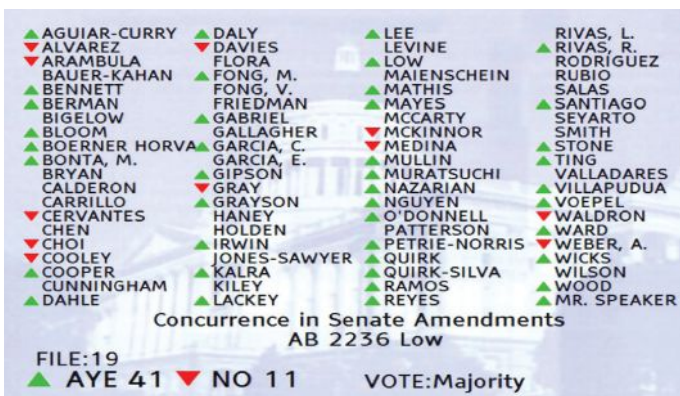
**Asm. Low, sponsor of the bill, mounted a spirited defense of the legislation late into the session in the face of opposition from Asm. Weber and an initial vote that didn't measure up for passage.**

opened with, citing the recent amendments. "This bill is much more dangerous than the original one," she asserted in the legislative session.

"It's not a question about scope of practice. It's not a question for me if optometrists should do surgical procedures—they should," Asm. Weber stated. "But it's a question about the amount of training—hands-on, live training—that someone should do before we allow them to go out and practice independently."

In light of these objections from Asm. Weber and others, the initial vote on the measure fell short by six votes. After some last-minute politicking on the floor, the bill received more rounds of voting and ended with 41 votes in its favor.

Those directly involved in optometric training for advanced procedures paint a different picture than the one offered by Asm. Weber of an OD's suitability for these responsibilities.



The final tally, which came at 11:50pm on the last day of the legislative calendar, gave the bill 41 votes in favor—exactly that needed for passage.

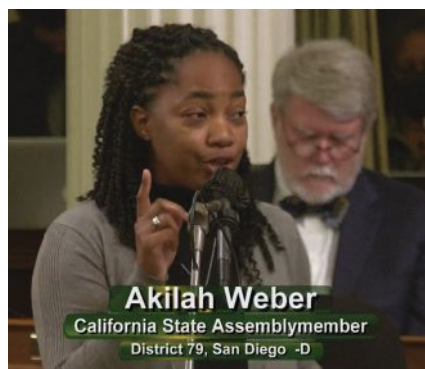“Students across all optometry schools, and doctors of optometry in post-doctoral education, are incredibly well trained on these procedures both didactically as well as with hands-on laboratory training and have successfully been performing laser and in-office surgical procedures for many years in 10 states,” explains Nathan Lighthizer, OD, associate dean of NSU Oklahoma College of Optometry and a champion of optometric surgery, who has been training ODs for many years on these responsibilities.

“I have personally witnessed thousands of doctors go through post-doctoral laser and surgical training courses and have seen nothing but success stories from classroom training to laboratory training to implementation in their practice,” Dr. Lighthizer says. “I’ve received countless emails and phone calls from doctors expressing how satisfied their patients have been” after optometric implementation of laser and other minor surgical procedures.

“I congratulate the COA, and I commend the California legislature for recognizing the current training and education of ODs across the country,” Dr. Lighthizer says.

## Anticipated Impact

A multitude of benefits are anticipated to stem from this legislation. “This is an important step forward to increase access and care to patients in California,” says Melissa Barnett, OD,



**Asm. Weber, an OB/GYN, led the opposition, claiming the bill’s insufficient training requirements would put CA citizens at risk if ODs were allowed to perform minor surgeries.**

principal optometrist at UC Davis Eye Center. “It’s also significant for doctors of optometry to be able to practice to their fullest scope in California.”

The most populous US state, California is home to more practicing optometrists than any other. In May 2021, the US Bureau of Labor Statistics (BLS) reported that there were 6,730 practicing optometrists in California.<sup>1</sup> Also using BLS figures, the number of ODs who currently have the right to pursue laser privileges in the existing 10 states with such laws is 4,570, meaning that this bill would more than double the number of ODs who can offer advanced procedures to their patients if they choose to undergo the necessary training regimen.

If ODs in the state pursue the opportunity, thousands of California residents will be able to receive more comprehensive care from their trusted primary eyecare provider without having to travel far, see an unfamiliar doctor or tolerate the longer wait times for an appointment typical of ophthalmic practices.

One compelling argument in favor of the bill came from Asm. Jim Wood, DDS, a dentist familiar with scope expansion battles in other areas of care.

“Back up for a second and understand why we’re even here having these kinds of discussions,” Asm. Wood encouraged the legislators. “People have a hard time accessing services like this.” He then explained that a third of California residents rely on Medi-Cal, the state’s assistance program for low-income citizens. “About 85% of optometrists accept Medi-Cal. I’m pretty sure that number is way smaller for ophthalmologists—way smaller.”

The COA’s president, Amanda Dexter, OD, who practices in San Diego, says, “This bill allows optometrists to practice to the fullest extent of their license. There is additional training and testing to make sure optometrists are competent to perform these procedures,” she explains. “It will mean my patients will get the right care at the right time and don’t have to wait



**Asm. Jim Wood, a dentist who previously supported scope expansion efforts, gave an impassioned defense of the bill that cited its positive impact on low-income residents in the Medi-Cal insurance plan. “About 85% of ODs accept Medi-Cal. I’m pretty sure that number is way smaller for ophthalmologists—way smaller,” he said.**

months to see an ophthalmologist for something that I can do for them while they are in my chair.”

The victory also sets a high-profile precedent for other states in their legal battles to expand the optometric scope. Unfortunately, some regions are more accepting of this scope expansion than others, Dr. Dexter points out.

“Where I practice, ophthalmologists generally agree with us on the proper division of labor, and politics don’t come into play,” she says. “It’s not controversial to have optometrists that are trained and competent doing the lower-level procedures that have low complication rates and free up physicians to perform more complex surgeries in tremendous demand right now like cataract surgery and retinal detachment related to diabetes,” Dr. Dexter explains, adding that this view is unfortunately not shared statewide.

Although the opposition will always put up a fight, optometry won this time—its biggest win yet—adding to the growing national momentum to increase the field’s practice rights.

If signed by Gov. Newsom, the bill would go into effect on January 1, 2023, and is expected to take roughly two years to implement. ◀

US Bureau of Labor Statistics. Occupational employment and wages. May 2021: 29-1041 Optometrists. Updated March 31, 2022. [www.bls.gov/oes/current/oes291041.htm](https://www.bls.gov/oes/current/oes291041.htm). Accessed August 31, 2022.

# Reusable CLs Increase AK Risk Threefold

Leaving lenses on while showering or sleeping and having fewer follow-up appointments were also factors in this study.

**N**early half of patients who develop *Acanthamoeba* keratitis—typically caused by poor contact lens handling—will end up losing some of their vision. In fact, a new study published in *Ophthalmology* on risk factors for this type of microbial keratitis noted that for “*Acanthamoeba* keratitis, unlike bacterial keratitis in contact lens users, 90% of cases are associated with avoidable risks.”

Though the condition is rare (0.31 to 0.48 cases per 10,000 people based on data from the United Kingdom and the Netherlands), its visual impact is often devastating, so researchers set out to identify modifiable risk factors that may help reduce its incidence.

The study observed a total of 83 contact lens wearers who developed *Acanthamoeba* keratitis. They compared the clinical data and self-administered questionnaires of patients who used daily disposable contact lenses with those who wore reusable lenses. They found that the latter increased the risk of infection threefold.

Several modifiable risk factors were identified in both types of lens users. For those who wore daily disposable lenses, *Acanthamoeba* keratitis was associated with the following: less frequent professional follow-up (odds ratio [OR]: 10.12), showering in lenses

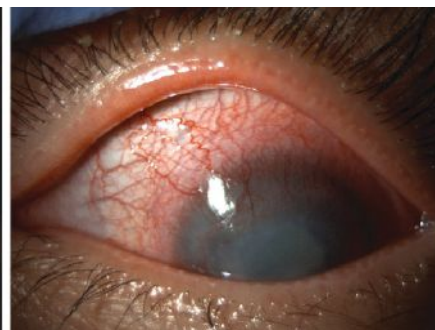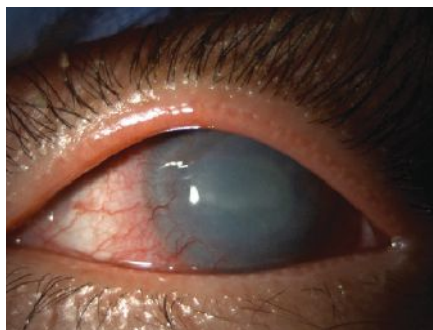


Photo: Suzanne Sherman, OD

**Patients who wore daily disposable contact lenses were three times less likely to develop *Acanthamoeba* keratitis than those who wore reusable lenses in this study.**

(OR: 3.29), lens reuse (OR: 5.41) and overnight wear (OR: 3.93).

“This study is the first to show a substantial three-times lower risk of severe corneal infections in daily disposable lenses compared with reusables,” says Nicole Carnt, PhD, of the University of New South Wales, lead author of the study. The analysis estimated that 30% to 62% of cases could have been prevented if patients were using daily disposable instead of reusable soft lenses. “However, daily disposables are not without risk, which we demonstrate can be minimized by more frequent optometry consultations and eliminating daily disposable reuse,” she points out.

Showering in lenses and leaving lenses on during sleep were also two significant risk factors observed among both daily disposable and reusable

contact lens users, the former resulting in a 3.3-fold increased risk of infection. Dr. Carnt adds, “This is the first time that overnight wear, a major risk factor for bacterial corneal infection, has been significantly associated with *Acanthamoeba* keratitis.” Reuse of lenses and less frequent follow-up visits still topped the list as the most influential risk factors.

“Optometrists are in a powerful position to mitigate the risk of *Acanthamoeba* keratitis and ensure healthier contact lens wear,” concludes Dr. Carnt. Advising patients to remove lenses while showering and at night and avoid reusing them may help prevent more cases of this vision-threatening infection, she suggests. ◀

Carnt N, Minassian DC, Dart JKG. *Acanthamoeba* keratitis risk factors for daily wear contact lens users: a case control study. *Ophthalmology*. Sept. 9, 2022. [Epub ahead of print].

## IN BRIEF

**Alterations in MG Morphology May Cause Contact Lens Discomfort.** In an effort to more precisely pinpoint the relationship between contact lens wear and the meibomian glands, researchers recently investigated the use of this modality in conjunction with meibomian gland morphology.

The study included 19 symptomatic (CLDEQ-8 score ≥12) contact lens wearers, 19 as-

ymptomatic (CLDEQ-8 score <12) contact lens wearers and 22 non-contact lens wearers. Upper and lower eyelid meibography images were taken, and the following parameters were analyzed using semi-objective software in the central two-thirds of each eyelid: number of meibomian glands, number of partial meibomian glands, percentage of meibomian gland loss and percentage of tortuosity. The relationship between CLDEQ-8 and meibomian gland morphology was then explored.

No significant differences were found between groups in the meibomian gland morphology of the upper or lower eyelids. In all contact lens wearers, a significant correlation with CLDEQ-8 was found in the upper eyelid for the number of meibomian glands. In symptomatic wearers, significant correlations with CLDEQ-8 were found in the lower eyelid for the number and percentage of partial meibomian glands.

**“Alterations in meibomian gland morphology, without clini-**

**cally apparent alteration in meibomian gland function, can be involved in causing contact lens discomfort and influence the degree of symptoms,”** the study authors wrote in their paper. “The differences in findings between eyelids indicate the need to monitor both eyelids, especially the lower one, in contact lens wearers.”

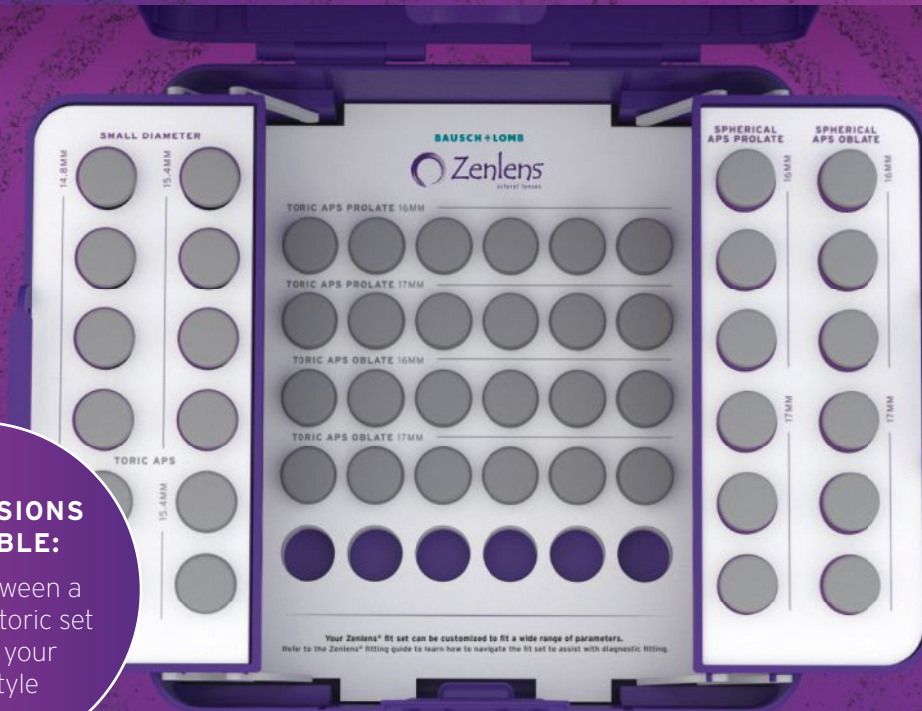Blanco-Vázquez M, Arroyo-Del-Arroyo C, Novo-Diez A, et al. Is contact lens discomfort related to meibomian gland morphology? *Cont Lens Anterior Eye*. August 24, 2022. [Epub ahead of print].

BAUSCH+LOMB



# ENLIGHTEN YOUR FITTING EXPERIENCE

The new all-in-one Zenlens® fit set combines a comprehensive range of lens features and customizations, so you can fit more scleral lens patients than ever before.



**TWO VERSIONS AVAILABLE:**  
Choose between a spherical or toric set based on your fitting style



**SPHERICAL AND TORIC PERIPHERAL CURVES** to further customize your set



**48 LENSES IN 4 DIAMETERS** for small and large corneas



**6 CUSTOMIZABLE LENS SLOTS\*** to fill with diagnostic lenses of your choice

\*Additional diagnostic lenses available for purchase.

**START YOUR ZENLENS® FIT SET JOURNEY TODAY**

Visit [bauschsvp.com](https://bauschsvp.com) for Important Safety Information.

Zenlens is a trademark of Bausch & Lomb Incorporated or its affiliates.  
©2022 Bausch & Lomb Incorporated or its affiliates. ALZN.0039.USA.22

# Can Cataract Surgery Induce Optic Neuropathy?

*It may occur due to negative perfusion pressure caused by elevated IOP. The fellow eye is also at risk.*

Cataract surgery is very safe and low-risk; however, in a small number of patients, minor and major complications still occur. These include post-surgical optic neuropathy (PCSON), which may arise within hours to days or even weeks to months after surgery. PCSON has many of the same

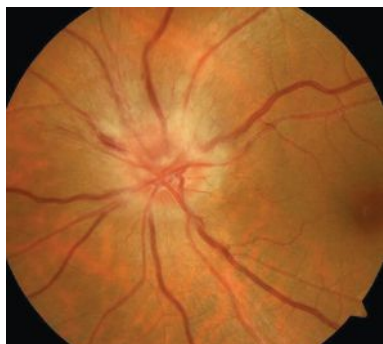

Photo: Neil Miller, MD

**PCSON or NAION may increase the risk of PCSON in the fellow eye.**

clinical characteristics as spontaneous nonarteritic anterior ischemic optic neuropathy (NAION), making it difficult to determine whether PCSON is a direct effect of cataract surgery or if these patients just happen to develop spontaneous NAION after the procedure. Researchers recently performed a literature review to better understand

this rare complication's pathogenesis and made several observations.

"Immediate PCSON appears to be related to negative perfusion pressure at the level of the optic disc due to increased IOP," the researchers noted in their paper. "The pathogenesis of delayed PCSON is unknown but likely multifactorial." Additionally, patients who experienced spontaneous NAION or PCSON in one eye appeared to have an increased risk of PCSON in the fellow eye. One study found that in patients who experienced spontaneous NAION in one eye and had not had

subsequent cataract surgery in the fellow eye, the frequency of subsequent spontaneous fellow eye NAION was 19%. However, in the small cohort that developed spontaneous NAION in one eye and then underwent cataract surgery in the fellow eye, the incidence of fellow eye acute optic neuropathy was 53%. The researchers noted this strongly suggests PCSON is indeed a form of NAION, but no current pathological evidence supports this speculation.

The team concluded, "Patients who have experienced either spontaneous NAION or PCSON in one eye and who are being considered for cataract surgery in the fellow eye should be counseled on the possible increased risk of developing PCSON." ◀

Bhatta MT, Miller NR. Post-cataract surgery optic neuropathy: a chronological narrative review of the literature and speculation on pathogenesis. *Curr Opin Ophthalmol*. August 18, 2022. [Epub ahead of print].

# Cardiovascular Health May Predict Ocular Health

*Some modifiable risk factors were associated with thinning of the retina and glaucoma likelihood.*

Recent research on the intersection of cardiovascular and eye health provides evidence that systemic risk factors may contribute to glaucomatous and retinal diseases. A group recently found that blood pressure and weight explained 12.6% of the variance in the ganglion cell complex-inner plexiform layer (GCIPL).<sup>1</sup> Similarly, a multicohort study reported that BMI was correlated with glaucomatous outcomes.<sup>2</sup>

The population-based Tromsø Study consisted of longitudinal and cross-sectional analyses of OCT images of patients with diabetes and glaucoma in Norway.<sup>1</sup> The researchers reported:

- GCIPL was negatively associated with age.
- Females had a thicker GCIPL than males at an older age and

thinner outer retinal layers at all ages.

- Systolic blood pressure was negatively associated with GCIPL and retinal nerve fiber layer (RNFL).
- There was a U-shaped relationship with the GCIPL in females.
- Males had a stronger negative association than women with BMI and RNFL/GCIPL/outer retinal layer thickness.
- Higher baseline BMI was associated with a reduction in GCIPL over eight years.

Findings of the second study, a multicohort analysis, included:

- In the retrospective longitudinal analysis of the PROGRESSA study, a lower BMI was associated with a faster rate of visual field progression.

- In the UK Biobank study, a one standard deviation-lower BMI was associated with worse cross-sectional vertical c/d ratio and a 10% greater risk of glaucoma. BMI was positively correlated with IOP.
- In the Canadian Longitudinal Study of Aging, a lower BMI was associated with a greater vertical cup-to-disc ratio change.

Overall, both studies concluded that studying cardiovascular risk factors in relation to retinal diseases and glaucoma may provide more insight into disease mechanisms. ◀

1. von Hanno T, Hareide LL, Småbrekke L, et al. Macular layer thickness and effect of BMI, body fat, and traditional cardiovascular risk factors: the Tromsø Study. *Invest Ophthalmol Vis Sci*. 2022;63(9):16.

2. Marshall H, Berry EC, Diaz Torres S, et al. Association between body mass index and primary open-angle glaucoma in three cohorts. *Am J Ophthalmol*. August 4, 2022. [Epub ahead of print].

HYDRUS<sup>®</sup>  
MICROSTENT

Let every nation know, whether it wishes us well or ill, that we shall pay any price, bear any burden, meet any hardship, support our friends, and defeat our foe, in order to assure the survival and the success of liberty.  
*John F. Kennedy*

Visas

INTERNATIONAL AIRPORT  
23 JUN 2012  
VISIT PASS  
PERMITTED TO ENTER AND REMAIN IN BRUNEI DARUSSALAM FOR THIRTY DAYS FROM SECOND VISIT UNTIL FIFTEEN THE DATE SHOWN ABOVE

IMMIGRATION ARRIVED  
24 SEP 2013  
SYDNEY AIRPORT  
617 P  
AUSTRALIA

26 ENE 2016

06. 3. 2013  
JKIA - NAIROBI  
2-31-31-31-31

FLUGHAFEN MÜNCHEN  
F 140

IMMIGRATION  
23 APR 2013  
KEULUAR  
KUALA LUMPUR

ONE DAY VISIT  
15 JUN 2013  
IMMIGRATION  
ONE DAY VISIT

14

ONLY MIGS DEVICE WITH  
**5-YEAR DATA**  
FROM A PIVOTAL TRIAL  
TO DELIVER:

**66%**  
of patients  
medication-free  
at 5 years<sup>1</sup>

**>50%** ↓ relative reduction in  
incisional SSIs\*  
vs. cataract  
surgery alone<sup>2†</sup>  
\* 2.4% in Hydrus vs. 5.3% in CS only

Established  
**LONG-TERM SAFETY**  
at 60-months<sup>2</sup>


**YOUR MIGS CHOICE MATTERS**  
BECAUSE THERE'S SO  
MUCH MORE TO SEE

Your adult Primary Open-Angle Glaucoma patients have seen tremendous things, and plan to see a whole lot more.

**Choose the MIGS device built to enable life's biggest experiences.**

\*SSI = Secondary Surgical Intervention

† includes trabeculectomy, tube shunt, gel stent, ECP/TSCP, non-penetrating; (9/369 Hydrus and 10/187 CS)



#### IMPORTANT PRODUCT INFORMATION

**CAUTION: Federal law restricts this device to sale by or on the order of a physician.**

**INDICATIONS FOR USE:** The Hydrus Microstent is indicated for use in conjunction with cataract surgery for the reduction of intraocular pressure (IOP) in adult patients with mild to moderate primary open-angle glaucoma (POAG). **CONTRAINDICATIONS:** The Hydrus Microstent is contraindicated under the following circumstances or conditions: (1) In eyes with angle closure glaucoma; and (2) In eyes with traumatic, malignant, uveitic, or neovascular glaucoma or discernible congenital anomalies of the anterior chamber (AC) angle. **WARNINGS:** Clear media for adequate visualization is required. Conditions such as corneal haze, corneal opacity or other conditions may inhibit gonioscopic view of the intended implant location. Gonioscopy should be performed prior to surgery to exclude congenital anomalies of the angle, peripheral anterior synechiae (PAS), angle closure, rubeosis and any other angle abnormalities that could lead to improper placement of the stent and pose a hazard. The surgeon should monitor the patient postoperatively for proper maintenance of intraocular pressure. The surgeon should periodically monitor the status of the microstent with gonioscopy to assess for the development of PAS, obstruction of the inlet, migration, or device-iris or device-cornea touch. The Hydrus Microstent is intended for implantation in conjunction with cataract surgery, which may impact corneal health. Therefore, caution is indicated in eyes with evidence of corneal compromise or with risk factors for corneal compromise following cataract surgery. Prior to implantation, patients with history of allergic reactions to nitinol, nickel or titanium should be counseled on the materials contained in the device, as well as potential for allergy/hypersensitivity to these materials. **PRECAUTIONS:** If excessive resistance is encountered during the insertion of the microstent at any time during the procedure, discontinue use of the device. The safety and effectiveness of use of more than a single Hydrus Microstent has not been established. The safety and effectiveness of the Hydrus Microstent has not been established as an alternative to the primary treatment of glaucoma with medications, in patients 21 years or younger, eyes with significant prior trauma, eyes with abnormal anterior segment, eyes with chronic inflammation, eyes with glaucoma associated with vascular disorders, eyes with preexisting pseudophakia, eyes with pseudoexfoliative or pigmentary glaucoma, and when implantation is without concomitant cataract surgery with IOL implantation. Please see a complete list of Precautions in the Instructions for use. **ADVERSE EVENTS:** The most frequently reported finding in the randomized pivotal trial was peripheral anterior synechiae (PAS), with the cumulative rate at 5 years (14.6% vs 3.7% for cataract surgery alone). Other Hydrus postoperative adverse events reported at 5 years included partial or complete device obstruction (8.4%) and device malposition (1.4%). Additionally, there were no new reports of persistent anterior uveitis (2/369, 0.5% at 2 years) from 2 to 5 years postoperative. There were no reports of explanted Hydrus implants over the 5-year follow-up. For additional adverse event information, please refer to the Instructions for Use. **MRI INFORMATION:** The Hydrus Microstent is MR-Conditional meaning that the device is safe for use in a specified MR environment under specified conditions. **Please see the Instructions for Use for complete product information.**

**References:** 1. Ahmed I, et al; HORIZON Investigators. Long-term Outcomes from the HORIZON Randomized Trial for a Schlemm's Canal Microstent in Combination Cataract and Glaucoma Surgery. [https://www.aaojournal.org/article/S0161-6420\(22\)00160-9/fulltext](https://www.aaojournal.org/article/S0161-6420(22)00160-9/fulltext)  
2. Hydrus Microstent Instructions for Use

# Alcon

## Study Supports Pediatric Use of Myopia Control Glasses

A recent study explored the efficacy of spectacle lenses designed for myopia management (incorporating either “highly aspherical lenslets” or “slightly aspherical lenslets”) vs. conventional single-vision spectacle lenses for myopia control. The data revealed that both highly aspherical and slightly aspherical lenslets reduced the rate of myopia progression and axial elongation over a two-year period, with a greater efficacy for highly aspherical lenslets.

In this double-masked, randomized clinical trial, children ages eight to 13 with a cycloplegic spherical equivalent refraction of  $-0.75D$  to  $-4.75D$  and astigmatism of less than  $-1.50D$  were recruited. Participants were randomly assigned in a 1:1:1 ratio to receive spectacle lenses with highly aspherical lenslets, spectacle lenses with slightly aspherical lenslets or single-vision spectacle lenses.

Of the participants who completed each visit ( $n=157$ ), the researchers analyzed 54 in the highly aspherical lenslets group, 53 in the slightly aspherical lenslets group and 50 in the single-vision spectacle lenses group. They reported the mean two-year myopia progression in the single-vision lens group to be  $-1.46D$  compared with  $-0.66D$  and  $-1.04D$  for the highly aspherical and slightly aspherical lenslet groups, respectively.

Compared with single-vision spectacle lenses, the mean change in

spherical equivalent refraction was less for children who received highly aspherical or slightly aspherical lenslets. They reported a mean increase in axial length of  $0.69mm$  for single-vision spectacle lenses. The data showed that, in comparison with single-vision lenses, increase in axial length was slowed by a mean of  $0.35mm$  for highly aspherical lenslets and  $0.18mm$  for slightly aspherical lenslets.

Additionally, the researchers observed that, when compared with those in the single-vision spectacle lens group, the mean change in spherical equivalent refraction was slowed by  $0.99D$  and the mean increase in axial length was slowed by  $0.41mm$  among children who wore highly aspherical lenslets at least 12 hours every day.

“In children with myopia, wearing highly aspherical lenslets significantly reduced the rate of myopia progression and eye growth over two years compared with slightly aspherical lenslets and single-vision spectacle lenses. This study demonstrated a dose-dependent effect, with higher lenslet asphericity having greater myopia control efficacy,” the authors concluded in their paper. “The full-time wearing of highly aspherical lenslets increased myopia control efficacy to  $0.99D$  (67%) for spherical equivalent refraction and  $0.41mm$  (60%) for axial length.” ◀

Bao J, Huang Y, Li X, et al. Spectacle lenses with aspherical lenslets for myopia control vs single-vision spectacle lenses. *JAMA Ophthalmology*. 2022;140(5):472-8.



Photo: Essilor

Essilor's Stellest lenses are an emerging treatment option for myopia management.





# VisuALL VRP

VISION TESTING MADE EASY

Visual Field  
+  
Color Vision  
+  
Visual Acuity  
+  
Pupillometry  
+  
Extraocular  
Motility

# *Join the Virtual Reality Revolution!*

Increase patient flow  
**AND**  
satisfaction



*Schedule a  
demo today!*



**Visit us at Academy San Diego  
Booth #508 and #300**

# NECO Tackles Student Debt, Access to Education

*A tuition reimbursement program just launched, and a hybrid curriculum is ramping up with a goal of bringing remote learning to underserved areas of the country.*

Interesting things are afoot at New England College of Optometry. The venerable college is addressing two big issues in optometric education: reducing student debt and expanding the applicant pool.

At an on-campus event in late August, President and CEO Howard Purcell, OD, announced an opportunity for tuition coverage wherein students who commit to work for five years after graduation for a participating company will have their education expenses paid by their employer, finding themselves debt-free at the end of the employment term. They can then choose to stay employed there or move on. Students already enrolled at NECO can make a three-year employment commitment in exchange for having their last two years of tuition covered. Dr. Purcell said that about 20% of NECO's current third-year students have taken the option.

Dr. Purcell likened the initiative to the GI Bill program that gave World War II veterans tuition coverage in exchange for their service. Addressing the employers in the audience, Dr. Purcell said, "Look at the benefits on the other side that you get when our students graduate and what they generate in terms of revenue for companies. It's important that [employers] have some skin in the game."

The first wave of employers are FYidoctors, Vision Source and Warby Parker. Four more potential employers are in discussions with NECO, Dr. Purcell said.

Explaining that about 75% of the revenue at schools and colleges of optometry comes from students' tuition, Dr. Purcell expressed the view that such a funding mechanism is untenable for educational institutions long-term. "Any spend we make, it's students' money," he reminded the audience, adding that "we cannot al-



**Dr. Purcell discussed challenges in optometric education and efforts NECO is putting forth to make the institution more responsive to the needs of the student body.**



**A panel discussion at the same event allowed several current NECO students to talk frankly about their career goals—and the obstacles in their way.**

low our students and graduates to continue to accrue this incredible debt." The employer-funded tuition program can help alleviate NECO's reliance on its student body as a revenue base.

The second program, a hybrid online/in-person educational curriculum, aims to bring new optometry candidates into the student pool from regions of the country with no local optometry college (33 states do not have one, Dr. Purcell noted). Students who travel out of state for their education tend to not return after graduation, Dr. Purcell said. The program hopes to address the dire need for eye care in many underserved communities by creating opportunities for new ODs to be trained locally, and remain there upon graduating, but still gain the advantages conferred by the NECO curriculum.

Students will perform their hands-on clinic learning in their local areas but will have the didactic portion of their education take place online. This, Dr. Purcell explained, is in line with the usage patterns of existing optometry students in traditional programs. Many students already choose to access lectures online now rather than in person, reflecting changes in habits borne by the pandemic and a greater desire for flexibility in their daily schedules. "We have to be more creative in the way we're delivering education," Dr. Purcell said. "Not everybody learns in the same way."

The hybrid curriculum is currently being reviewed by ACOE to achieve the milestones needed for accreditation, Dr. Purcell noted, and is contingent on such approval

before proceeding. Once those criteria are met, he hopes to launch the program in 2023 or 2024. Additional details will be announced as they are finalized.

Dr. Purcell's presentation was part of a think-tank of sorts called the Industry Collaborative that he is spearheading at NECO. The annual event brings together stakeholders from education, industry, research, clinical practice and other facets of eye care to address challenges the profession faces today and tomorrow. This year's event began with a panel discussion about the evolving role of telehealth services and online vision testing. Other talks included a student panel addressing the goals and priorities of new entrants to the field and a conversation with industry leaders about their support for students and recent graduates. ◀

# ENOUGH IS ENOUGH

*There's a better way.*

Providing the best care and achieving professional fulfillment—that's what matters. *We know these days it's hard.* Between rising costs, declining reimbursements, staffing challenges, regulations, and billing complexity—seems like there's just not enough time. But the right technology can help. Imagine a single EHR and PM platform with mobile transcription, easier ophthalmic-specific workflows, and efficient billing. Plus, a better way to engage patients. All from a partner who'll be there for the long-haul.

Make it better:  
[nextgen.com/better-OP](https://nextgen.com/better-OP)

**BELIEVE IN BETTER.®**

© 2022 NXGN Management, LLC. All Rights Reserved. NextGen is a registered trademark of NXGN Management, LLC. All other names and marks are the property of their respective owners.

**nextgen**  
healthcare

# Physical Activity in Children Correlates to Better Eyesight

*Researchers found that kids who were regularly engaged in sports every week had better visual and stereoacuity and were less likely to need glasses.*

Exercise is important to maintain health, and new analysis found these benefits extend into the eye health of children. The review, named the Ireland Eye Study, examined schoolchildren for different aspects of sight, comparing these to their fitness levels.

Participants—1,626 children aged six to seven and 12 to 13 years—were randomly selected across schools in Ireland. Parents and guardians were given a questionnaire to fill out detailing their child’s level of physical activity per week, with four options available to select: no activity, light activity, moderate activity or regular activity. No activity was defined as being mostly on screens, light activity as occasional walking or cycling, moderate activity as less than three hours a week of sports and regular activity as more than three hours a week of sports.

The researchers found better distance and near visual acuity (VA), as well as stereoacuity, in children who exercised regularly compared with other activity levels, and this was consistent with both the six to seven and 12 to 13 age groups. Regular physical activity was also associated with an absence of clinically significant refractive error (defined here as less than -0.50D of myopia or 2.00D of hyperopia).

Overall, children with better VA and stereoacuity who do not need glasses are more likely to engage in regular

physical activity compared to children with reduced VA and stereoacuity who wear glasses. Conversely, children reported to engage in no physical activity were more likely to be visually impaired. One in three visually impaired children reported no activity, compared to the overall one in 10. Lack of activity extended to include children with amblyopia, myopia and astigmatism.

Prior research reflects similar findings in myopic children, with one dataset finding myopic children aged 12 to 13 spent less time outdoors being physically active and more time on screens than their emmetropic counterparts. Yet, in another study, emmetropes, though associated with spending more time outside, were not associated with greater physical activity, indicating that being outside may be just as important for eye development as exercise.

Similarly, prior research in amblyopic children found they possess lower athletic competence, like catching and aiming, mapping onto this study’s finding that amblyopic children were almost six-times more likely to report no physical activity. Further, children treated for amblyopia were five-times more likely than amblyopic children to be regularly engaged in physical activity.




Photo: Getty Images

**Playing sports and exercising regularly may benefit the visual health of children, study finds.**

Socioeconomically, physical inactivity was associated with disadvantaged and minority children. Parents’ education and occupation mattered too, with lower education levels and social class contributing to overall inactivity and visually impaired children.

The researchers concluded that the study highlights the importance of physical activity in relation to eyesight, although whether the relationship begins as physical inactivity resulting in reduced VA or vice-versa is unclear. They do suggest, however, that “eyecare clinicians should incorporate an assessment of physical activity engagement into consultations, include physical activity advice and plans in managing children’s eye care and assess the benefits during follow-up.” ◀

Harrington S, Kearney J, O’Dwyer V. Visual factors associated with physical activity in schoolchildren. *Clinical and Experimental Optometry*. August 11, 2022. [Epub ahead of print].

## IN BRIEF

**Placebo Effect May Influence Visual Function in Exams.** Mind-over-matter mentalities, beliefs and expectations are not to be trifled with, as the placebo effect shows us. Studies have proven that our minds can unconsciously influence our own behavior and physiological responses. Researchers recently investigated whether the placebo effect had any influence on the dynamics of accommodative response

and stereoacuity, and, indeed, they found that **expectations can modulate visual function.** In the study, 19 healthy university students performed three experimental sessions in randomized order: experimentally induced placebo, “nocebo” (an expectation of negative outcomes) and control. The researchers measured accommodative response, stereoacuity and subjective measures. The experimentally induced placebo was an inert capsule said to have posi-

tive effects on human physiology. The control group did not ingest a capsule. The researchers reported that **the variability of accommodation was sensitive to the placebo and nocebo effects. The students had a more stable accommodative response to the placebo vs. nocebo exam. During the placebo exam, the students also exhibited better stereoacuity vs. the nocebo and control groups.** The researchers’ analysis of students’ subjective

perceptions confirmed the success of the experimental manipulation. **“These results indicate that manipulating expectations regarding the efficacy of an inert treatment can influence visual functioning in the short term,** which may be of relevance in both clinical and laboratory settings,” the researchers concluded in their paper. Vera J, Redondo B, Ocaso E, et al. Manipulating expectancies in optometry practice: ocular accommodation and stereoacuity are sensitive to placebo and nocebo effects. *Ophthalmic Physiol Opt*. August 12, 2022. [Epub ahead of print].

# What about our future?



## OCULUS Myopia Master®

The all-in-one-device for Myopia Management.

The new OCULUS Myopia Master® features the unique combination of axial length, autorefractometry and corneal curvature. The software features including: normative growth curves, lifestyle questionnaire, and trend analysis deliver a customized myopia report for patient education and comprehensive parental consultation.

**Master myopia management today and for the future!**

The availability of products and features may vary by country. OCULUS reserves the right to change product specifications and design.



[www.myopia-master.com/us](http://www.myopia-master.com/us)

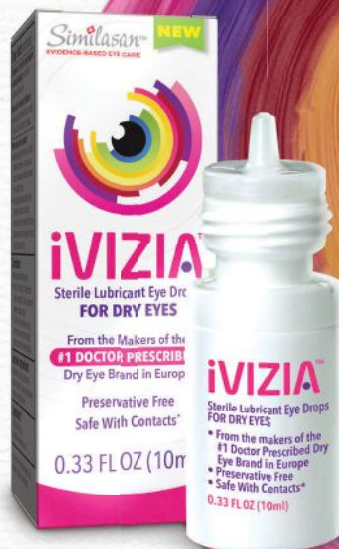

New from the makers of the #1-prescribed dry eye brand in Europe\*

# Covering the spectrum of Dry Eye Relief

Introducing preservative-free iVIZIA™ lubricant eye drops for the comprehensive combination of lasting relief and ocular surface protection.<sup>1-6</sup>

- Trehalose provides bioprotection, osmoprotection, and rehydration<sup>1-4</sup>
- Hyaluronic acid (HA) and povidone deliver lubrication with long-lasting relief<sup>5-6</sup>
- Increased tear film thickness for up to 240 minutes<sup>7</sup>
- Preservative free
- Proprietary multi-dose bottle design for calibrated dosing and contamination protection
- Suitable for all dry eye sufferers, including contact lens wearers†



Help patients see dry eye relief differently. Recommend iVIZIA OTC.

Request samples and learn more by scanning the QR code or visiting [iVIZIA.com/ECP](https://www.iVIZIA.com/ECP).



\*Prescription market data, Sept. 2021 – S01K without cyclosporine.

†To limit blurriness when using contact lenses, remove contacts, apply drops, then insert contacts.

**References:** **1.** Chen W, Zhang X, Liu M, et al. Trehalose protects against ocular surface disorders in experimental murine dry eye through suppression of apoptosis. *Exp Eye Res.* 2009;89(3):311-318. **2.** Aragona P, Colosi P, Rania L, et al. Protective effects of trehalose on the corneal epithelial cells. *ScientificWorldJournal.* 2014;2014:717835. **3.** Chiambaretta F, Doan S, Labetoulle M, et al. A randomized, controlled study of the efficacy and safety of a new eyedrop formulation for moderate to severe dry eye syndrome. *Eur J Ophthalmol.* 2017;27(1):1-9. **4.** Liu Z, Chen D, Chen X, et al. Trehalose induces autophagy against inflammation by activating TFEB signaling pathway in human corneal epithelial cells exposed to hyperosmotic stress. *Invest Ophthalmol Vis Sci.* 2020;61(10):26. **5.** US FDA Department of Health and Human Services. Ophthalmic drug products for over-the-counter human use. Updated October 21, 2021. Accessed January 19, 2022. <https://www.accessdata.fda.gov/scripts/cdrh/cfdocs/cfcfr/CFRSearch.cfm?CFRPart=349>. **6.** Jones L, Downie LE, Korb D, et al. TFOS DEWS II management and therapy report. *Ocul Surf.* 2017;15(3):575-628. **7.** Schmidl D, Schmetterer L, Witkowska KJ, et al. Tear film thickness after treatment with artificial tears in patients with moderate dry eye disease. *Cornea.* 2015;34(4):421-426.

# FEATURES

REVIEW OF OPTOMETRY • Vol. 159, No. 9 • SEPTEMBER 15, 2022



## 45th Annual TECHNOLOGY REPORT

### 38 New Technology Purchases: How and Why ODs Buy

This reader survey reveals the preferences and priorities that guide optometrists when adding tools and techniques to their practices.

*By Catherine Manthorp, Senior Associate Editor*

### 44 OCT: What's Under the Hood?

This essential guide will help you understand the technology and how it supports clinical practice.

*By Lori Mandy Pennington, OD, and Brooke Smith, OD*

### 54 Telemedicine: What We've Learned and What's to Come

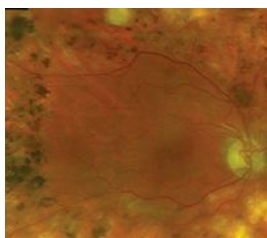
Reflecting on the present and preparing for the future of virtual eye care.

*By Marta O'Grady, OD*

### 62 Is Artificial Intelligence Smart Enough Yet to Help Us?

Learn the current state of this technology and what might be coming soon to support optometry's efforts to fight diabetic retinopathy.

*By Lauren White, OD*



EARN 2 CE CREDITS

### 73 Take Control of the Nutrition Conversation

Comprehensive optometric care includes discerning the role evidence-based nutrition plays in eye health.

*By Cecelia Koetting, OD*



**We Welcome  
Your Comments**

[editor@reviewofoptometry.com](mailto:editor@reviewofoptometry.com)



**Follow Us!**

Enjoy our content on  
Instagram at [@revoptom](https://www.instagram.com/revoptom)

# DEPARTMENTS

REVIEW OF OPTOMETRY • SEPTEMBER 15, 2022



VISIT US ON SOCIAL MEDIA

Facebook: revoptom

Twitter: revoptom

Instagram: revoptom

LinkedIn: company/review-of-optometry

## 8

### NEWS REVIEW

Clinical, legislative and practice development updates.



## 26

### OUTLOOK

#### Don't Fear Digital Disruptors

Technologies that change the delivery of eye care are maturing. Optometrists should act—rather than react.

*Jack Persico, Editor-in-Chief*

## 28

### THROUGH MY EYES

#### The Best-Kept Secret

Optometry's role in health care is crucial. Time to spread the word.

*Paul M. Karpecki, OD*

## 30

### CHAIRSIDE

#### Words From the Wise

I'm referring to me and my advice. Take it or leave it.

*Montgomery Vickers, OD*

## 32

### CLINICAL QUANDARIES

#### Giving Up the Ghost

Don't provide a cataract referral without first considering corneal rehabilitation.

*Paul C. Ajamian, OD*

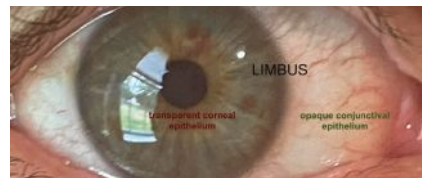## 34

### THE ESSENTIALS

#### Limbal Landmarks

Explore the inner workings of a region essential to the cornea.

*Bisant A. Labib, OD*



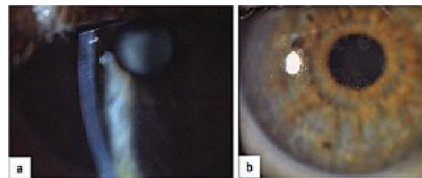
## 82

### CORNEA AND CONTACT LENS Q&A

#### Talkin' Toxicity

Consider the potential adverse effects associated with Blenrep before initiating use for myeloma treatment.

*Joseph P. Shovlin, OD*



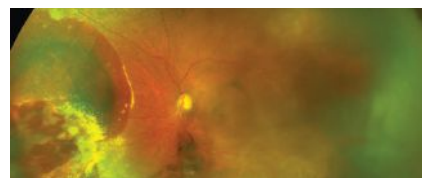
## 84

### URGENT CARE

#### Pecking Away at Differentials

Are you familiar with this choroidal lesion?

*Alison Bozung, OD*



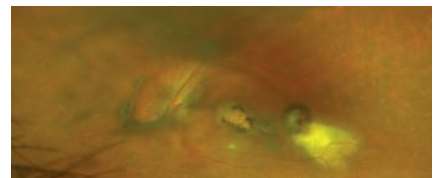
## 88

### RETINA QUIZ

#### Lights in the Fog

This patient's hypopigmented lesion led to the diagnosis.

*Rami Aboumourad, OD, and Alberta Pengo, BS*



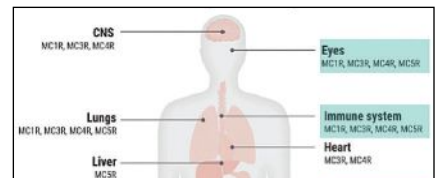
## 92

### OCULAR SURFACE REVIEW

#### Revisit a Steroid Alternative

Acthar Gel, an injectable therapy that activates melanocortin pathways, may be a saving grace for some of your patients.

*Paul M. Karpecki, OD*



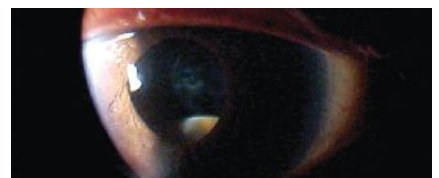
## 98

### DIAGNOSTIC QUIZ

#### That Sinking Feeling

A patient's vision has been blurry ever since a fall.

*Andrew S. Gurwood, OD*







# PLAN PERFORM PROFIT

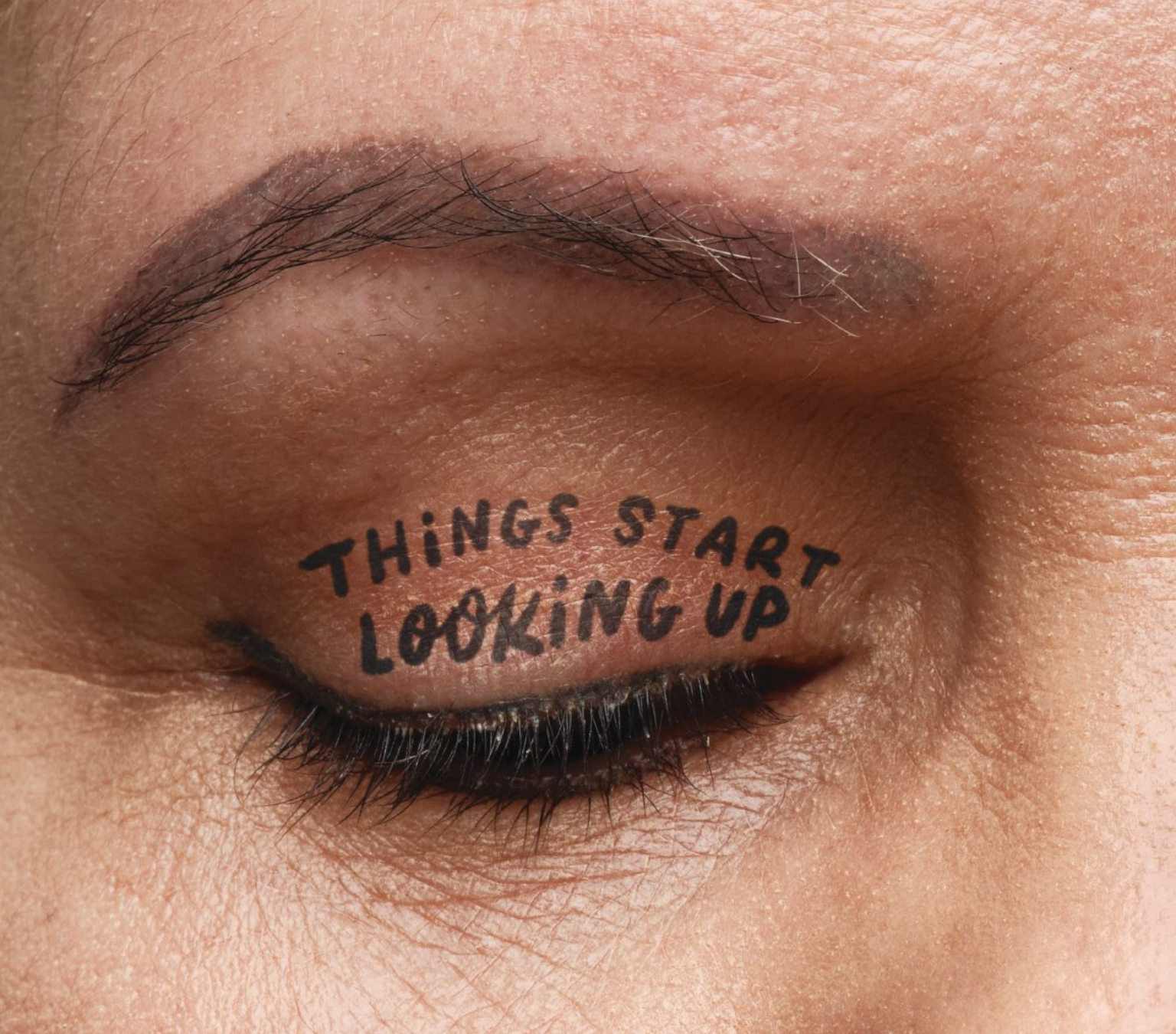CUSTOM INTERIORS + FURNITURE

- Enhance the Patient Experience
- Build Practice Equity
- Attract New Associates

EYEDESIGNS  
CUSTOM INTERIORS + FURNITURE *group*  
www.eyedesigns.com  
800-346-8890

VISIT OUR  
SHOWROOMS



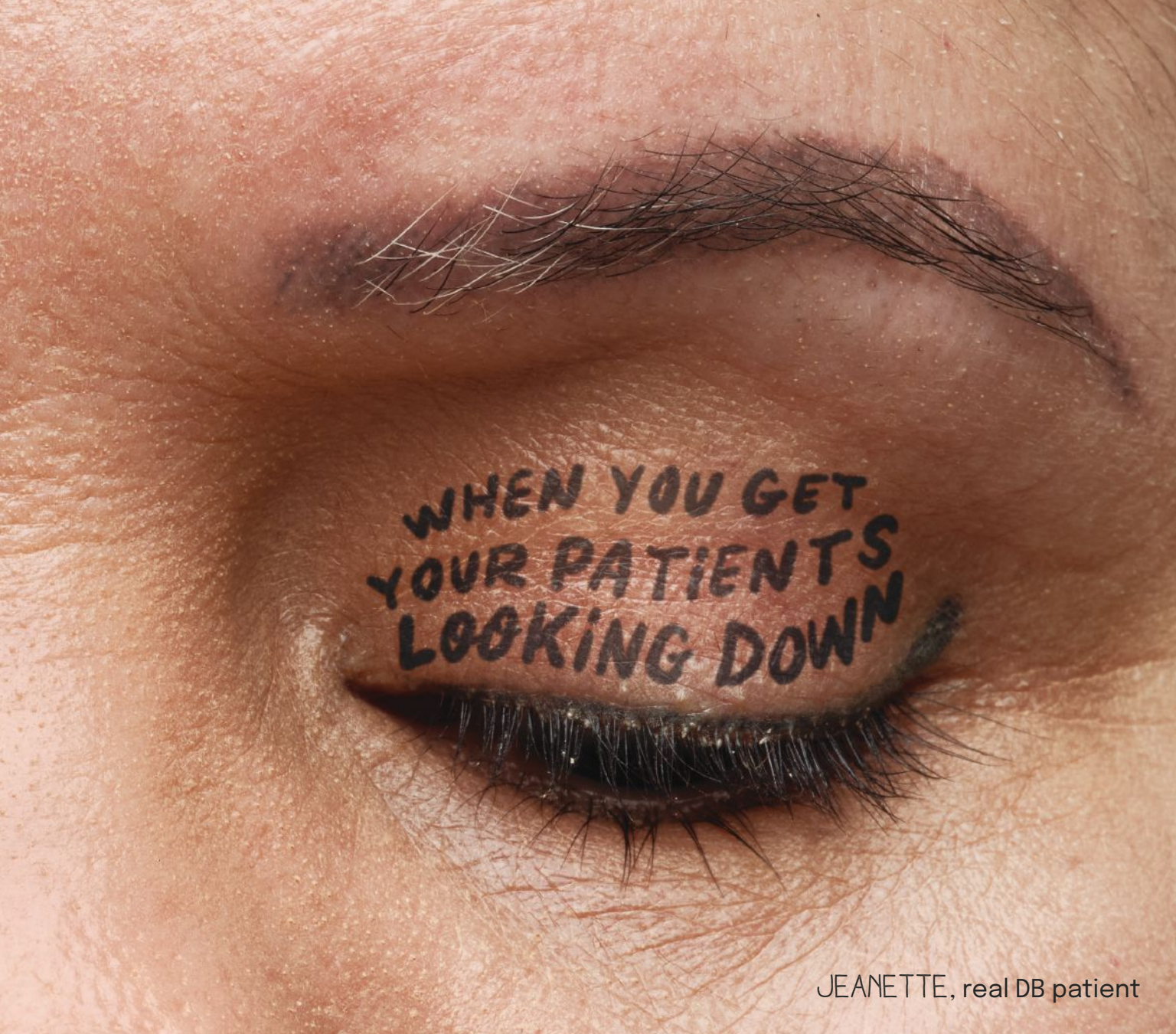

**We're willing to bet** most eye care professionals don't realize just how prevalent *Demodex* blepharitis is.<sup>1</sup>

In fact, **~25 million eye care patients** are affected by *Demodex* blepharitis (DB).<sup>2,3</sup>

---

**References:** 1. Data on file, Tarsus Pharmaceuticals, Inc. June 2022. 2. Trattler W, Karpecki P, Rapoport Y, et al. The prevalence of *Demodex* blepharitis in US eye care clinic patients as determined by collarettes: a pathognomonic sign. *Clin Ophthalmol.* 2022;16:1153-1164. 3. Saydah SH, Gerzoff RB, Saaddine JB, Zhang X, Cotch MF. Eye care among US adults at high risk for vision loss in the United States in 2002 and 2017. *JAMA Ophthalmol.* 2020;138(5):479-489.



JEANETTE, real DB patient

DON'T BELIEVE US?  
LEARN HOW EASILY DB CAN FLY UNDER THE RADAR AT

LOOK *at the* LIDS.COM



@LookAtTheLids



## EDITOR-IN-CHIEF

**JACK PERSICO**  
(610) 492-1006 • jpersico@jobson.com

## SENIOR EDITOR

**JULIE SHANNON**  
(610) 492-1005 • jshannon@jobson.com

## SENIOR ASSOCIATE EDITOR

**CATHERINE MANTHORP**  
(610) 492-1043 • cmanthorp@jobson.com

## SENIOR ASSOCIATE EDITOR

**MARK DE LEON**  
(610) 492-1021 • mdeleon@jobson.com

## ASSOCIATE EDITOR

**LEANNE SPIEGLE**  
(610) 492-1026 • lspiegle@jobson.com

## ASSOCIATE EDITOR

**RACHEL RITA**  
(610) 492-1000 • rrita@jobson.com

## SENIOR SPECIAL PROJECTS MANAGER

**JILL GALLAGHER**  
(610) 492-1037 • jgallagher@jobson.com

## SENIOR ART DIRECTOR

**JARED ARAUJO**  
jaraujo@jobson.com

## GRAPHIC DESIGNER

**LYNNE O'CONNOR**  
lyoconnor@jobson.com

## DIRECTOR OF CE ADMINISTRATION

**REGINA COMBS**  
(212) 274-7160 • rcombs@jobson.com**Clinical Editors**

Chief Clinical Editor • Paul M. Karpecki, OD

## Associate Clinical Editors

Joseph P. Shovlin, OD, Christine W. Sindt, OD

## Clinical &amp; Education Conference Advisor

Paul M. Karpecki, OD

Case Reports Coordinator • Andrew S. Gurwood, OD

**Columnists***Chairside* – Montgomery Vickers, OD*Clinical Quandaries* – Paul C. Ajamian, OD*Cornea and Contact Lens Q+A* – Joseph P. Shovlin, OD*Diagnostic Quiz* – Andrew S. Gurwood, OD*The Essentials* – Bisant A. Labib, OD*Focus on Refraction* – Marc Taub, OD, Pamela Schnell, OD*Glaucoma Grand Rounds* – James L. Fanelli, OD*Ocular Surface Review* – Paul M. Karpecki, OD*Retina Quiz* – Mark T. Dunbar, OD*Surgical Minute* – Derek Cunningham, OD, Walter Whitley, OD*Therapeutic Review* – Joseph W. Sowka, OD*Through My Eyes* – Paul M. Karpecki, OD*Urgent Care* – Alison Bozong, OD**Editorial Offices**

19 Campus Blvd., Suite 101 • Newtown Square, PA 19073

Jobson Medical Information/WebMD  
395 Hudson Street, 3rd Floor, New York, NY 10014Subscription inquiries: (877) 529-1746  
Continuing Education inquiries: (800) 825-4696

Printed in USA

BY JACK PERSICO  
EDITOR-IN-CHIEF  
**OUTLOOK**

# Don't Fear Digital Disruptors

*Technologies that change the delivery of eye care are maturing. Optometrists should act—rather than react.*

It wasn't too long ago that providing eye care was the near-exclusive province of optometry and ophthalmology. Aside from a few simple vision screening techniques used by pediatricians and other family practitioners, if you wanted your eyes checked out, you got in a car and drove to see an OD or an OMD. That model isn't going away any time soon, and it remains the gold standard, but we'd all be remiss if we ignored the growth of alternative modes of eyecare delivery.

The pandemic accelerated some trends that were already in motion, notably the desire or need to provide some semblance of care virtually. Many observers see in the Millennial and Gen Z cohorts a generational shift toward viewing eye care as just one more product to purchase online. That's an easy overgeneralization to make, but when you grow up conducting much of your day-to-day life online, you see it as the default experience, not an outlier.

Online refraction services get a lot of flak from optometrists—rightly so, they're terrible—but they do at least show that a market is there for it. It stands to reason that these will evolve and eventually achieve a level of respectability such that ODs themselves might even employ them for limited uses, like doing a contact lens Rx refill on a pre-existing patient who does also periodically come in for an exam.

Telehealth services, after being the only game in town during the 2020 lockdown, looks to maintain an ongoing presence too in optometry. In this month's 45th annual Technology Report, Marta O'Grady, OD, weighs in on lessons learned and where the experience is heading.

Most ODs think of telehealth as a half-a-loaf-is-better-than-none method of maintaining contact with their patients, and there's something to be said for that view, but it can also expand optometry's reach. "As optometry historically moves towards more systemic treatment and collaborative work with other medical subspecialties, virtual visits may accelerate this pursuit by allowing us to virtually consult in emergency departments without leaving our offices as well as collaborate with primary care practitioners, internists, nutritionists and neurologists," writes Dr. O'Grady in her article.

Artificial intelligence—covered this month by Lauren White, OD—is another way technology is disrupting the delivery of eye care. AI-powered cameras that screen for diabetic retinopathy in GP offices and drug stores may not yet be commonplace, but there's every reason to expect that's coming. These tools can also come in handy for optometrists, serving as sort of an instant consult with a digital retina specialist. As Dr. White writes, "AI can democratize fundus photo interpretation by leveling the playing field for providers with varying clinical expertise."

These technology and market-driven changes were part of a wide-ranging discussion held last month at New England College of Optometry. For me, the take-home message was this: even if these trends and tools aren't ready for prime time, it behooves us to reckon with them now so they can support optometry's general ethos and commitment to patient care. Otherwise, we stand vulnerable to outside forces that see only profit and conquest in the disruptive power of new tech. ■

# Business (and Life) Partners

## A Couple's Approach to Co-Owning a Practice



**Kathy Solum, OD | Art Wong, OD**  
Edmonds Vision Center  
Edmonds, Wash.

There are many benefits (and challenges) that come with co-owning an optometry practice—especially if the co-owner is not only a partner in business, but in life. 2022 Best Practices Honorees Kathy Solum, OD, and Art Wong, OD, are married and co-own Edmonds Vision Center in Edmonds, Wash. In a recent interview, the couple explains the benefits of co-ownership, how they navigate the challenges, and their approach to making joint decisions for their practice.

### What are the biggest benefits of co-owning your practice?

**Dr. Wong:** Dr. Solum's strengths and skillset are completely different than mine. For example, I attract an older crowd and treat conditions like glaucoma and macular degeneration, whereas Dr. Solum performs a lot of pediatric exams and specializes in myopia management. Having different areas of expertise enables us to self-refer within our practice and better serve a broader range of patients.

**Dr. Solum:** From my perspective, one of the biggest benefits has been work-life balance. Our ability to "job share," if you will, has made it much easier for us to not only run a business, but raise our family. We've taken turns being in the office and staying home with our children. Even if your business partner is not your spouse, there are certainly benefits to being able to divide and conquer.

### How does being a married couple change the dynamics of your partnership?

**Dr. Solum:** It's important for us to always be mindful about keeping our work life and home life separate. People always say to leave your work at the office and your personal life at home, but as a married couple, we can't. If there's a non-work-related disagreement, we have to be cognizant about not bringing that into the office with us. We make sure to talk through and resolve those issues prior to coming into the office.


### What are some other challenges of co-ownership?

**Dr. Solum:** As you might expect, it can be difficult to handle differences in ideas and opinions. I remember when we first started out, I set up the office exactly how I envisioned it would be. When Dr. Wong returned home from a trip, he wanted to change everything around to how he had pictured it. If we were just business partners, I'm sure we would have collaborated on it from the beginning. But as a married couple, sometimes it's easy to feel like you can make choices without necessarily running every little detail by your partner. It was a good reminder early in the process that communication is key—and ensuring each partner has the chance to be heard will make your practice thrive.

### How does that communication come into play when making joint decisions for your practice?

**Dr. Wong:** We divide responsibilities between the two of us to help streamline bigger decisions, like purchasing a new piece of equipment, for example. My job is to research new instruments and evaluate the benefits they will offer to our patients and practice. Dr. Solum is responsible for the financial side of things and looks at the return on investment. We both bring our findings to the table to discuss and decide together what makes the most sense for the success of our practice.

**Dr. Solum:** We also make sure to look beyond the two of us, as we value the opinions of others as well. Sometimes hearing a third-party perspective—from another doctor, associate, or colleague—helps guide our decisions. Our staff always has the opportunity to provide input as well, since it's imperative that we have buy-in from the entire team.



## 3 TIPS FOR SUCCESSFUL CO-OWNERSHIP:

- 1 Communication is Key.**  
Be open to your partner's ideas and concerns. An open line of communication is essential for a co-owned practice's success.
- 2 Play to Your Strengths.**  
It's impossible for one doctor to excel at every specialty. Focusing on your strengths and allowing your co-owner to focus on theirs is a win for your patients—and your practice.
- 3 Compromise.**  
As with any partnership, it can be difficult to find successful models for decision-making—especially when opinions may clash. Be open to a cooperative mindset and compromise whenever possible.



BY PAUL M. KARPECKI, OD  
CHIEF CLINICAL EDITOR

## THROUGH MY EYES

# The Best-Kept Secret

*Optometry's role in health care is crucial. Time to spread the word.*

**O**ur profession sees around 85% of all comprehensive eye exams.<sup>1</sup> We are the ideal providers of primary eye care, from the treatment of refractive error to the diagnosis and management of hundreds of ocular conditions.

Today's ODs live in an exciting time of growth in the field. In 10 states and counting, the optometric scope of practice now includes noninvasive surgical procedures and lasers, such as YAG capsulotomy and SLT. Being known as the "go-to" doctor for all eyecare needs—from emergencies to red eyes, glaucoma to dry eye and cataract and refractive surgery care to glasses and contact lens prescriptions—is an enviable position. Plus, it makes a 30- to 40-year career far more interesting and enjoyable.

Here's the catch, though: patients don't know all that optometrists do—and how would they if we're not educating them? It's estimated that more than 80% of pediatric conjunctivitis goes to a pediatrician, Urgent Care doctor or other primary care provider rather than to an eyecare provider.<sup>2</sup> Many patients are also unaware that we perform diabetic eye exams or that systemic illness ranging from hypertension and autoimmune disease to brain tumors and even pending aneurysms can be diagnosed with an annual eye exam. We perform the majority of these exams, giving us a fantastic opportunity to educate patients and their families.

## Comanagement Contributions

Payment in comanagement arrangements must be reasonable and abide by

rulings from the Centers for Medicare and Medicaid Services (CMS), meaning they make up about 20% of the comprehensive fee. Fortunately, many surgical practices apply this to premium intraocular lenses (IOLs) as well, but not all. If optometrists provide four perioperative exams per cataract surgery plus the other aspects of care for premium IOL patients—education, follow-up, adjustments—it becomes necessary to work with the surgeon to ensure that compensation meets CMS guidelines and isn't equal to that of a standard monofocal IOL surgery. Find a talented surgeon who understands the expertise, time and care optometrists provide.

“Patients don't know all that optometrists do—and how would they if we're not educating them?”

## Working with Outside Providers

I have a large dry eye practice, with over 800 diagnosed Sjögren's syndrome patients. It would've been impossible to see and manage this many cases without rheumatologists having the largest growth in referring physicians this past year. When managing Sjögren's, these physicians know what to ask patients but, frankly, they don't have the capacity, equipment, desire or ability to manage this level of dry eye disease. These referrals help patients receive necessary care from the most suitable doctor (you), as well as help

you gain the trust of patients and outside providers.

Many similar opportunities exist in optometry, such as working with endocrinology to provide diabetic eye exams, retinal surgeons for low vision care or corneal specialists for scleral lens referrals.

## Insurance Carriers

If we do all of these effectively—co-manage with ophthalmologists, educate patients on optometry's role in primary eye care and work with providers outside our field—there is a huge potential reward: turning the tables on insurance companies. These entities wouldn't exist if patients didn't sign up, and patients won't sign up if no providers are willing to accept absurd compensation amounts. As consolidation continues in eye care via private equity or simply via the understanding that ODs perform nearly nine of 10 exams, this will put providers in a position of leverage. It's a matter of time and organization before we optometrists can dictate fair terms.

## Strength in Numbers

Individual state scope laws abiding, there are numerous ways to embrace the power of this 85% statistic and take steps to help primary eye care improve. Pathways to success include working with subspecialties, such as retinal specialists and cataract surgeons, and caring for systemic disease patients referred for ocular exams. This will allow the healthcare system to be most efficient and enable every physician, from surgeons to optometrists, to do what they do best. ■

1. Wilson FA, Stimpson JP, Wang Y. Inconsistencies exist in national estimates of eye care services utilization in the United States. *J Ophthalmol.* 2015;43:5606.

2. Shekhawat NS, Shtein RM, Blachley TS, Stein JD. Antibiotic prescription fills for acute conjunctivitis among enrollees in a large United States managed care network. *American Academy of Ophthalmol.* 2017;124(8):1099-107.

About  
Dr. Karpecki

**Dr. Karpecki** is the director of Cornea and External Disease for Kentucky Eye Institute, associate professor at KYCO and medical director for the Dry Eye Institutes of Kentucky and Indiana. He is also chair of the New Technologies & Treatments conferences. He consults for a wide array of ophthalmic clients, including ones discussed in this article. Dr. Karpecki's full disclosure list can be found in the online version of this article at [www.reviewofoptometry.com](http://www.reviewofoptometry.com).



IVERIC  
BIO

DEVELOPING  
TRANSFORMATIVE  
THERAPIES  
FOR RETINAL DISEASES

---

We are focused on developing treatments for patients suffering from retinal diseases with significant unmet medical needs.

**Geographic Atrophy | Stargardt Disease | Inherited Retinal Diseases**

Learn more at [IvericBio.com](https://IvericBio.com)



# Words From the Wise

*Yeah, I'm referring to me and my advice. Take it or leave it.*

**T**his is about the time of year when suddenly I morph into every new optometry graduate's weird Uncle Monty. If you are a recent grad, all doctor-hooded and so forth, the chances are that you already have a game plan for your next move.

Maybe you'll move right in with mom's established practice. Maybe you'll just go hardcore corporate for "a couple of years" (sure) to pay off some student debt or, if our wonderful government forgives your debt, take my tax donations to buy a cool car while you live in daddy's attic. Maybe you'll go right into a residency so you can stay a student for as long as you can as an excuse to continue weekend kegers.

And maybe, just maybe, you few hardy souls will find a great place to start the long, but thrilling, process of being your own boss in private practice. Goals for this shrinking subgroup, of course, includes getting in with some old docs and figuring out how to run them off, sooner or later.

Oh, I almost forgot. Some of you will think it's okay to work in one of those "free eye exam if you buy cheap glasses" places. Other than the fact that this feeds into the propaganda that optometrists are not "real doctors," I send you my love (as required by my personal religion)... for now.

Let's pretend that your family is throwing a graduation party and, unfortunately, I get wind of it despite the lack of an invitation and just show up. You can run to the bathroom and hide all you want, but I will not

be deterred. Dr. Newbie, here's the *Cliffs Notes* of my standard four-plus-hour speech.

## Six Simple Rules

Without further ado, my pearls of wisdom:

1. Practice where you want to live. Now, when I say "practice where you want to live," I don't actually mean "practice where you want to live" because all the cool places are already taken and there's a decent OD on every street corner. Do you really want to practice optometry against these seasoned and successful veterans? You may do just fine...in 20 years after they all die off. But why wait that long?

Ask mom and dad if they have any old CDs lying around, get out a map, use the CD to trace concentric circles that overlap the cool place you want to live and then practice inside the circle where your services are needed. You don't have to live and practice in the cool place. You just have to be able to get there and back on one charge of your goofy electric car.

2. Don't be the cheapest doctor in town. Do you think for one second that your patients would take a pay cut so

people would like them more? No way. Charge what you need to charge to have a modern office with superhero staff members. You'll be fine.

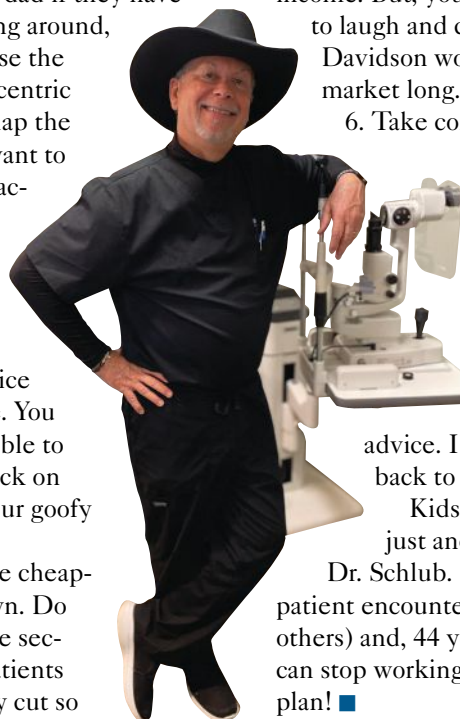
3. If you feel you have to accept every dumb vision plan to get the ball rolling or because the doctor that hires you accepts them, you might be right. However, if you break even or lose money on every visit, you might be stupid. Stupid is not allowed for a doctor.

4. Don't spend all your income. Yes, you are a doctor. Yes, you finally have a real job. No, you are not rich. Yes, you are actually poor right now unless Aunt Tillie left you her untouched Barbie doll collection to sell on eBay. If so, knock yourself out.

5. If you haven't already, please find your soulmate. Optometry is a great profession for anyone who wants to share a life. You can just about make your own hours and have at least some control over your income. But, you need somebody to laugh and cry with, and Pete Davidson won't be back on the market long.

6. Take continuing education seriously. After all, no CE=no license. No license, no career. No career, no income. No income, no TV. No TV, no *The View*. Hmm, I may reconsider this advice. I'll sleep on it and get back to you.

Kids, you are now not just another schlub. You are Dr. Schlub. Enjoy every single patient encounter (some more than others) and, 44 years from now, you can stop working on Fridays. Good plan! ■



### About Dr. Vickers

Dr. Vickers received his optometry degree from the Pennsylvania College of Optometry in 1979 and was clinical director at Vision Associates in St. Albans, WV, for 36 years. He is now in private practice in Dallas, where he continues to practice full-scope optometry. He has no financial interests to disclose.







EDITED BY PAUL C. AJAMIAN, OD

## CLINICAL QUANDARIES

# Giving Up the Ghost

*Don't provide a cataract referral without first considering corneal rehabilitation.*

**Q** A 66-year-old male patient presented for a cataract evaluation, stating that the vision in his left eye was blurred and has been “double” for three months. He is interested in a multifocal lens. How should I proceed?

**A** “Double vision is always a troubling complaint,” says Paul C. Ajamian, OD, center director of Omni Eye Services of Atlanta and editor of this column. Before you panic, have the patient close one eye and see if the diplopia is still present. In this case, the patient described a ghosting of letters above the actual print or signs, only from the left eye. Once we determined that, it was time to find the cause.

“Everything starts with corneal topography,” says Dr. Ajamian. “It is very difficult to make a proper cataract referral without it.” Look at the numbers, color map and keratoscopic rings for any irregularities. In the case of our patient, the topography in that left eye was very irregular, and caused us to take another look at the cornea.

### The Hard Way

The best way to prove that a subtle irregularity of the cornea is the culprit in a case such as this is with a diagnostic hard lens. Dust off your hard lens trial kit and, with a drop of proparacaine, fit the patient with an appropriate base curve lens and do an overrefraction. The results can be very revealing. In the case of our patient, the monocular ghosting totally disappeared with the lens in place, and the vision improved by several lines.

“I have seen this hard lens trick save patients from further testing and time-consuming referrals for unexplained vision loss,” Dr. Ajamian notes. Otherwise, look for other causes such as milky nuclear sclerosis, a subtle epiretinal membrane or perhaps a neurological issue that needs to be investigated with visual fields and radiologic imaging.

### A Closer Look

If you didn't see anything on the slit lamp exam the first time around, look again. The topographic map of our patient showed a steep irregular area superiorly (*Figure 1*). This corresponded to a subtle horizontal band of epithelial basement membrane dystrophy with maps and fingerprints above the visual axis. Before you send

anyone for cataract surgery, be sure to address the lids and ocular surface. “The more pristine the ocular surface, the better the results of standard or premium lens cataract surgery,” Dr. Ajamian notes.

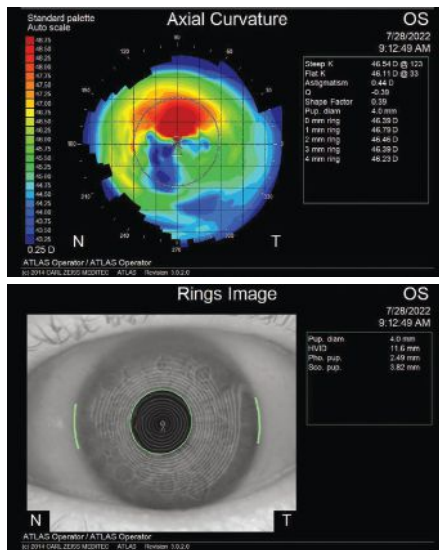
Convey your findings and pre-op plan to the surgeon by writing a letter that clearly outlines the patient's goals as well as your recommendations for type of lens implant, target refraction and/or monovision. The more options discussed ahead of time, the easier the patient can make an informed decision when they see the surgeon.

No one knows your patient better than you, so share your knowledge of your patients with other providers to ensure desired outcomes.

### The Plan, Stan

Our patient was a bit surprised when the talk turned from cataract removal to corneal rehabilitation. A patient with advanced map-dot-fingerprint epithelial dystrophy will not do well after cataract surgery unless the cornea is addressed first. A superficial keratectomy was recommended prior to surgery. This procedure removes the corneal epithelium down to Bowman's membrane, particularly the area of central reduplicated epithelial basement membrane that is causing the irregular astigmatism.

After the procedure, a bandage lens is put on the eye and the patient followed over a few weeks. Several months later, assuming good healing and stable topography readings, the cataract scans can be redone and cataract surgery can be scheduled. However, proceed with caution on a multifocal IOL despite a “new” corneal surface. “A monofocal lens with reading glasses is probably still the safest bet in a case like this,” Dr. Ajamian says. ■



**Fig. 1. Check the cornea for any irregularities before moving forward with cataract patients.**

**About Dr. Ajamian**

**Dr. Ajamian** is board certified by the American Board of Optometry and serves as Center Director of Omni Eye Services of Atlanta. He is vice president of the Georgia State Board of Optometry and general CE chairman of SECO International. He has no financial interests to disclose.

# MAXIVISION<sup>®</sup>

SCIENCE BACKED.  
QUALITY GUARANTEED.



Developed using groundbreaking research and decades of clinical experience



100% satisfaction guarantee



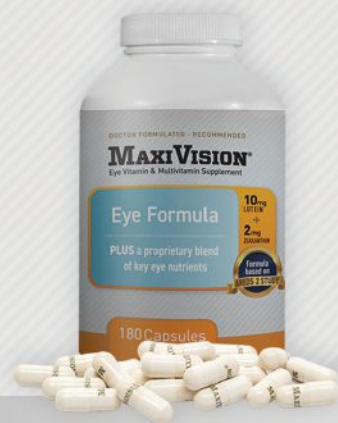Proudly manufactured in FDA Inspected, GMP Compliant Labs in the USA



## CALL TODAY AND SAVE 40% ON MAXIVISION EYE FORMULA!

- ✓ Uniquely formulated to strengthen eye tissues and structures while reducing the risk of age-related conditions like AMD
- ✓ Contains ingredients from groundbreaking AREDS 2 study and decades of clinical experience: Vitamins C and E, Zinc, Copper, and Taurine
- ✓ Antioxidants zeaxanthin and FloraGLO<sup>®</sup> lutein help fortify macular pigment optical density (MPOD)

Call **888-670-7220** today to learn how you can save **40%** on a 3-month supply of our popular Eye Formula — free shipping on orders of 48 bottles or more!



CLAIM YOUR EYE FORMULA  
DISCOUNT TODAY

Scan here or call today:  
**888-670-7220**



LUNOVUS



BY BISANT A. LABIB, OD

## THE ESSENTIALS

# Limbal Landmarks

*Explore the inner workings of a region essential to the cornea.*

**T**he cornea is a unique, immune-privileged ocular structure that requires transparency for the individual to achieve optimal vision. Although it is normally avascular, it is still able to obtain adequate nourishment and efficiently undergo various cell processes, including mitosis and cellular healing/repair. These functions, along with the general integrity of the cornea, are made possible through the essential and adjacent area: the limbus.

The limbus is defined as the transition zone between the opaque sclera and the clear cornea, separating the conjunctival epithelium and the corneal epithelium.<sup>1-3</sup> The diameter is 1mm to 2mm wide and is often measured by the normal, gradual loss of transparency as the cornea extends toward the far periphery.<sup>1,2</sup> This anatomical area in and of itself acts as a barrier prohibiting the invasion of conjunctival epithelial cells onto the cornea.<sup>3</sup> It also, however, houses key components to corneal and ocular health, called limbal stem cells (LSCs).<sup>1-5</sup>

## Cells and Components

LSCs are most concentrated in areas of the limbus called the palisades of Vogt. To a lesser degree, they are also located in limbal epithelial crypts and the limbal epithelial pit. The limbal palisades of Vogt appear as fibrovascular ridges located radially and circumferentially around the peripheral cornea. These are readily viewed on the slit lamp under high magnification, appearing as a blue-gray ring encircling the periphery.<sup>1,2</sup> The area

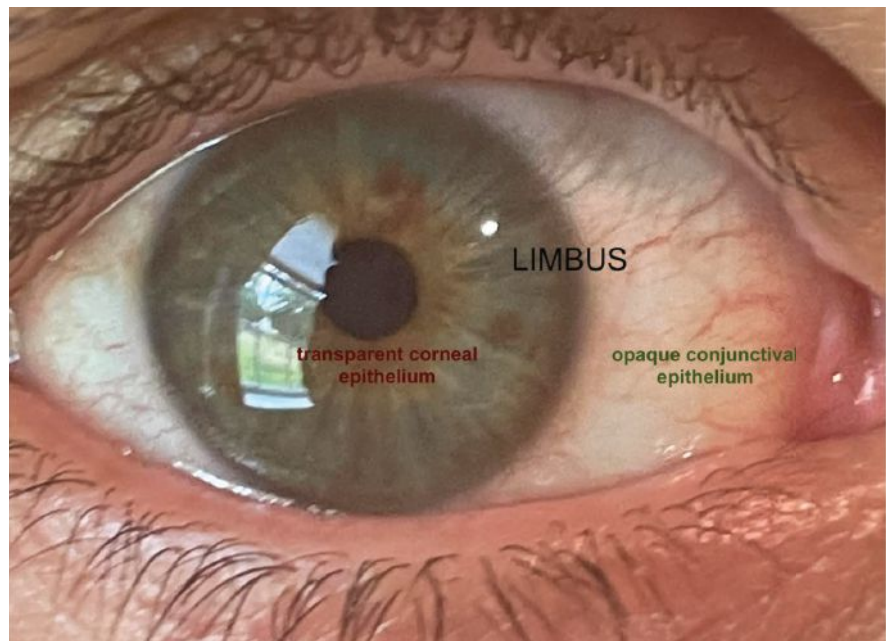
of highest concentration of palisades is within the superior and inferior limbus. More specifically, these LSCs are located within the basal layer of the limbus and possess a higher degree of mitotic ability as compared with the peripheral and central cornea.<sup>4</sup>

The precise homeostasis of the LSC environment is critical in maintaining corneal integrity. It is what allows the cornea to remain transparent and avascular, to proliferate and heal and ultimately to provide the most optimal surface for light rays to be transmitted and focused on the retina for vision.<sup>4</sup> A distinguishing feature of the cornea that would not be possible without the limbus is its avascularity. Unlike other ocular

structures, the cornea is free of blood vessels, which allows for its transparency. The vasculature of the limbus, as well as the tear film, is what nourishes the cornea. The limbus is the zone that prevents the opaque conjunctival epithelium from invading the otherwise clear cornea.<sup>1-5</sup>

## Damage and Disease

When dysfunction arises, as in various pathological conditions, the environment is disrupted. When the limbus, which is rich in stem cells, is injured, this leads to cellular apoptosis. LSCs typically differentiate into corneal epithelial cells, but when they are injured, they are repaired and filled in by the conjunctival epithelium. There is a stark difference between these two types of epithelia, as the conjunctiva contains goblet cells and is highly vascularized. This ultimately leads to blood vessels invading the cornea, which is called neovascularization.



**The limbus is the transition zone preventing the opaque epithelium from invading the clear cornea.**

About  
Dr. Labib

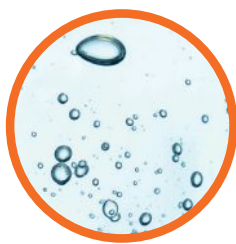
**Dr. Labib** graduated from Pennsylvania College of Optometry, where she now works as an associate professor. She completed her residency in primary care/ocular disease and is a fellow of the American Academy of Optometry and a diplomate in the Comprehensive Eye Care section. She has no financial interests to disclose.

NEW




HELP YOUR PATIENTS GO FROM  
**DRY EYES**  
TO EXTRA LONG-LASTING  
**HYDRATION**<sup>1-8</sup>

Introducing blink® triple care — the first and only over-the-counter eye drop with both hyaluronate and a nano-emulsion lipid within the unique formula.<sup>9-10</sup> Here's how our **DUAL ACTION MOISTURE SEAL TECHNOLOGY**<sup>5-8</sup> works:



**HYALURONIC ACID**  
binds moisture and helps  
boost hydration<sup>3-5</sup>



**LIPID NANO EMULSION**  
helps protect against tear  
evaporation<sup>11</sup> to lock in moisture<sup>5-8</sup>

The result is **3-in-1 Extended Relief**<sup>1-8</sup> for both Aqueous-Deficient and Evaporative Dry Eyes<sup>12</sup>:



**Instantly Soothes**<sup>1-8</sup>



**Extra Long-Lasting Hydration**<sup>1-8</sup>



**Locks in Moisture**<sup>5-8</sup>

**References:** 1. Wasmanski AD and Kislán T. Cross-Over Evaluation of Polyethylene Glycol 400 (PEG-400) 0.4% and 0.25% Artificial Tears in Mild Dry Eye Patients. Invest. Ophthalmol. Vis. Sci. 2010;51(13):6263. 2. Montani G. Intrasubject Tear Osmolarity Changes with Two Different Types of Eye Drops. Optom. Vis. Sci. 2013;90(4): 372-377. doi: 10.1097/OPX.0b013e318288bdbe 3. Laurent TC. Structure of Hyaluronic Acid. In: EA Balazs (Ed.), Chemistry and Molecular Biology of Intracellular Matrix. Academic Press, London. 1970:703-732. 4. Aragona P, Papa V, Micali A, et al. Long Term Treatment with Sodium Hyaluronate-Containing Artificial Tears Reduces Ocular Surface Damage in Patients with Dry Eye. Br. J. Ophthalmol. 2002;86(2):181-184. doi: 10.1136/bjo.86.2.181. 5. Prabhasawat P, Tesavibul N, Kasetsuwan K. Performance Profile of Sodium Hyaluronate in Patients with Lipid Tear Deficiency: Randomised, Double-Blind, Controlled, Exploratory Study. Br. J. Ophthalmol. 2007;91(1):47-50. doi: 10.1136/bjo.2006.097691. 6. Zheng X, Goto T, Shiraishi A, et al. In vitro efficacy of ocular surface lubricants against dehydration. Invest. Ophthalmol. Vis. Sci. 2013;32(9):1260-1264. doi: 10.1097/j.ico.0b013e31829cfd44. 7. Maissa C, Guillon M, Simmons P, et al. Effect of castor oil emulsion eyedrops on tear film composition and stability. Contact Lens Anterior Eye. 2010;33(2):76-82. doi: 10.1016/j.clae.2009.10.005. 8. Craig JP, Nichols KK, Akpek EK, et al. TFOS DEWS II Definition and Classification Report. The Ocular Surface. 2017;15(3):276-283. 9. US Dry Eye OTC Product Comparison. 10. IRI US 2020 Dry Eye Share Competitive Report. 11. JJV Data on File 2020. Blink Triple Care Lubricating Eye Drops - Consolidated, Approved Claims List. 12. 2012. Lemp, Miachael A. Distribution of Aqueous-Deficient and Evaporative Dry Eye in a Clinic-Based Patient Cohort: A Retrospective Study

**Important Safety Information:** Blink® Tears, Blink GelTears® and Blink® Triple Care drops are for the temporary relief of burning, irritation and discomfort due to dryness of the eye or exposure to wind or sun, and may be used as a protectant against further irritation. Patients should stop use and contact their eye care practitioner if they experience eye pain, changes in vision, continued redness or irritation of the eye, or if the condition worsens or persists for more than 72 hours.

© Johnson & Johnson Surgical Vision, Inc. 2022. PP2022CN4045

**Table 1. Overview of LSC Damage**

Staging of LSC Deficiency	Clinical Findings
Stage 1: Mild	Dull corneal reflex Epithelial thinning and pooling Peripheral pannus >50% limbal involvement
Stage 2: Moderate	Vortex keratopathy/whorl-like epitheliopathy Central neovascularization Epithelial erosions >50% limbal involvement
Stage 3: Severe	Corneal melt and/or perforation Stromal scarring and neovascularization Diffuse, severe corneal opacification

Evidence of neovascularization is a clinical indication that key components of the limbus, the LSCs, are damaged.<sup>4,5</sup> Additionally, invasion of the conjunctival epithelium onto the corneal surface leads to an irregular ocular surface, diminished tensile strength and inept barrier function.<sup>5</sup>

Generally speaking, corneal neovascularization affects up to 1.4 million people per year and is a common cause of vision loss.<sup>5</sup> Growth of new blood vessels can occur in various regions of the cornea, including the epithelium and the stroma. Because of the limbal vascularity and the avascularity of the cornea, neovascularization begins peripherally and can progress to the central cornea, leading to opacification and vision loss. Being able to accurately identify and determine the underlying cause of corneal neovascularization is key, as many treatment options are most effective only in the early stages.<sup>3</sup>

**Cause and Chronicity**

LSC deficiency is a gradual process and can occur from primary or secondary causes. Using clinical clues, like neovascularization, is necessary in identifying this dysfunction and preventing vision loss as early and effectively as possible. Primary causes are characterized by genetic

mutations that are often congenital and directly affect the integrity or function of LSCs. Such cases include aniridia, congenital epidermal dysplasia, Turner syndrome, keratitis secondary to endocrine deficiencies and xeroderma pigmentosum.

The other category of LSC deficiency is comprised of secondary conditions that cause damage to

LSCs due to external conditions. Most commonly, these include thermal or chemical injury, chronic inflammation, injury from ocular surgeries, contact lens wear, infection, keratopathies and ocular surface tumors.<sup>3</sup>

Diagnosis of LSC deficiency is made through clinical examination. Symptoms are often nonspecific and may be mild in the early stages, such as conjunctival redness, foreign body sensation, photophobia and tearing. As LSC deficiency advances, delayed epithelial wound healing is evident through symptoms of pain and decreased vision. Clinically, this would manifest as recurrent corneal erosions.<sup>3</sup>

There are three stages of LSC deficiency that depend on clinical clues and examination with slit lamp biomicroscopy. While examination with white light is routinely performed, diagnosing LSC deficiency is easier through the use of fluorescein under cobalt blue light.<sup>3</sup>

**Mild stage.** The first and earliest stage of LSC deficiency is denoted by a dull, irregular corneal reflex. This is due to the combination of conjunctival and corneal epithelial cells, inhibiting optimal transparency of the cornea. Additionally, there may be areas of thinning and pooling of fluorescein because the abnormal epithelium is thinner and lacks tight junctions.

Neovascularization is usually not present in the milder stage, but there may be areas of pannus peripherally, outside the central 5mm of the cornea. There is also less than 50% limbal involvement. To identify loss of the palisades of Vogt, careful examination of LSC location, especially inferiorly and superiorly, is necessary. The limbus may also appear more flat than healthy eyes.<sup>3,4</sup>

**Moderate stage.** As LSC deficiency advances, the corneal epithelium may take on a spiral pattern similar to vortex or whorl-like keratopathy. This area is susceptible to epithelial erosions. Neovascularization or pannus may be seen centrally, and over 50% of the limbus is involved in this stage.<sup>3,4</sup>

**Severe stage.** The third and final stage is the most severe display of LSC deficiency, resulting in corneal melt or perforation from the chronic, poor epithelial wound healing. Opacification takes over the entire cornea, and deeper stromal neovascularization and scarring are often present. Total blindness is a potential and devastating outcome of this condition.<sup>3,4</sup>

Treatment is most effective in the early stages of LSC deficiency. As such, a timely and accurate diagnosis is vital for the best visual outcome. Treatment is also variable and related to the underlying etiology. While we routinely examine both the conjunctiva and the cornea, we need to pay closer attention to the important transitory zone of the limbus, which houses the most important cells for corneal function. ■

- Peraza Nieves J, Rocha de Lossada C, Sabater Cruz N, Torras Sanvicens J. Human corneo-conjunctival limbus anatomy assessed by scanning electron microscopy. *Indian J Ophthalmol.* 2020;68(8):1665.
- Bergmanson JP, Martinez JG. Size does matter: what is the corneo-limbal diameter? *Clin Exp Optom.* 2017;100(5):522-8.
- Le Q, Xu J, Deng SX. The diagnosis of limbal stem cell deficiency. *Ocul Surf.* 2018;16(1):58-69.
- Ruan Y, Jiang S, Musayeva A, et al. Corneal epithelial stem cells-physiology, pathophysiology and therapeutic options. *Cells.* 2021;10(9):2302.
- Sharif Z, Sharif W. Corneal neovascularization: updates on pathophysiology, investigations & management. *Rom J Ophthalmol.* 2019;63(1):15-22.

# Time well spent.

**With Chronos Automated  
Binocular Refraction System,  
spend more time on what  
matters most, your patients.**

Transform the time you spend on refraction into quality time with your patients. Topcon enables stronger patient consultations, conversations, and loyalty. Simply delegate the upfront binocular autorefractometry, keratometry and subjective acuity testing to a technician with the help of the SightPilot guided refraction software.

**Discover the true value of Chronos.  
Visit us at VEW Booth #F11051.  
[topconhealthcare.com/chronos](https://topconhealthcare.com/chronos)**



# NEW TECHNOLOGY PURCHASES: HOW AND WHY ODS BUY

This reader survey reveals the preferences and priorities that guide optometrists when adding tools and techniques to their practices.

BY CATHERINE MANTHORP  
SENIOR ASSOCIATE EDITOR

Seasoned clinicians will tell you that the best tool they have for diagnostic assessment is their own brains, as years of exposure to thousands of clinical puzzles develops finely attuned instincts. But some technology used in optometric practice, most notably OCT, can be transformative, revealing the status of the eye in remarkable detail and opening up entirely new modes of care. OCT has emerged as an essential tool—and it tops the list of new medical equipment optometrists are planning to buy in the next year, according to a reader survey we conducted this summer.

Of course, not everything on someone's wish list ultimately ends up in their shopping cart, however. Especially in a time of financial uncertainty, optometrists need to pick and choose carefully when investing in their practices. Which factors guide this process? We asked, and you answered. Here's what your fellow ODs had to say.

## Invaluable Investing

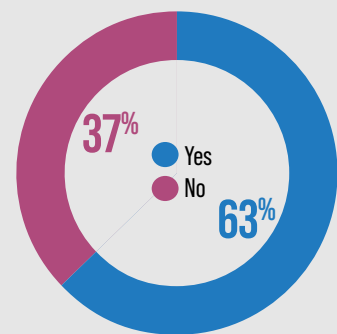
A total of 276 optometrists responded to our survey to keep us in the loop about the latest pieces of equipment

they've invested in and those they have their eye on. This pool of ODs tends to focus on patient care, positive impressions and ease of use when deciding whether to upgrade technologies. Other priorities include adding practice value and revenue, as well as device warranty/service plan.

"Making patient contact easier and safer is a big priority," emphasized one respondent. Another, Marc Ullman, OD, of Pine Beach, NJ, said that his patients appreciate seeing new equipment at his practice and associate these additions with meaningful progress. Along the same lines, Stephen DuBois, OD, of Jacksonville, FL, noted, "We always look for things that can either add patients to the practice or give existing ones something to talk about."

Keeping their priorities in mind, 63% of respondents took the leap and found it worth making new additions to their clinics over the past two years (Figure 1), most commonly including imaging devices such as Optos, OCT and fundus cameras. "Seeing is believing," said survey respondent Duke B. Yoon, OD, of Lakewood, WA, to emphasize the importance of visual data in patient enthusiasm and compliance. "When patients see their retinal artery and vein, or some hemorrhage in the retina, they are excited about the

FIG. 1. HAVE YOU INVESTED IN ANY NEW MEDICAL TECHNOLOGY FOR YOUR PRACTICE IN THE PAST TWO YEARS?

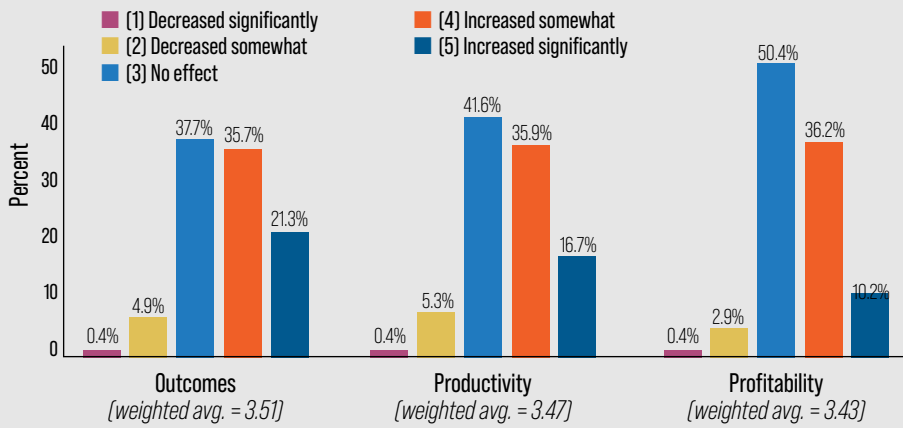


importance of eye care and very enthusiastic" about taking action to protect their vision, he says.

What motivates an OD to invest? The big three goals are typically to improve patient care, streamline office flow and boost practice revenue. We asked readers to rate their most recent purchase in these areas to see if the new tech delivered. It was a decidedly mixed bag. As far as achieving the intended effect, 57%, 53% and 46% of respondents, respectively, noted an increase in clinical outcomes, productivity and profitability (Figure 2). The rest, for the most part, claimed to have seen no effect or even small decreases in each of these measures.



**FIG. 2. HOW HAS THIS RECENT INVESTMENT AFFECTED YOUR PROFITABILITY, PRODUCTIVITY AND CLINICAL OUTCOMES?** *Rated on a 1-5 scale.*



With patient care the guiding principle for new equipment purchases, what specifically does that entail? Given the array of procedures that fall under the umbrella of primary eye care, an optometrist has no shortage of options to pursue. Interestingly, almost as many ODs in our survey reported that they invest to improve existing procedures and services as they do to add new ones (Figure 4).

### To Have and Have Not

With some clinics “all in” on new advancements and others just starting to revamp their office space, it’s worth noting that not every piece

of technology holds the same clinical utility, requiring ODs to weigh each tool’s benefits against their budget.

Most respondents already own the standard battery of primary eyecare equipment. Nine out of 10 ODs have the essential trio of slit lamp, manual phoropter and autoref/keratometer (Figure 5). More specialized tools like scleral topographers and advanced dry eye treatments (IPL and LLLT) have some of the lowest penetration rates to date, though interest in the dry eye tech is high for the near future. Dark adaptometry, however, has yet to find an audience, a proposition complicated

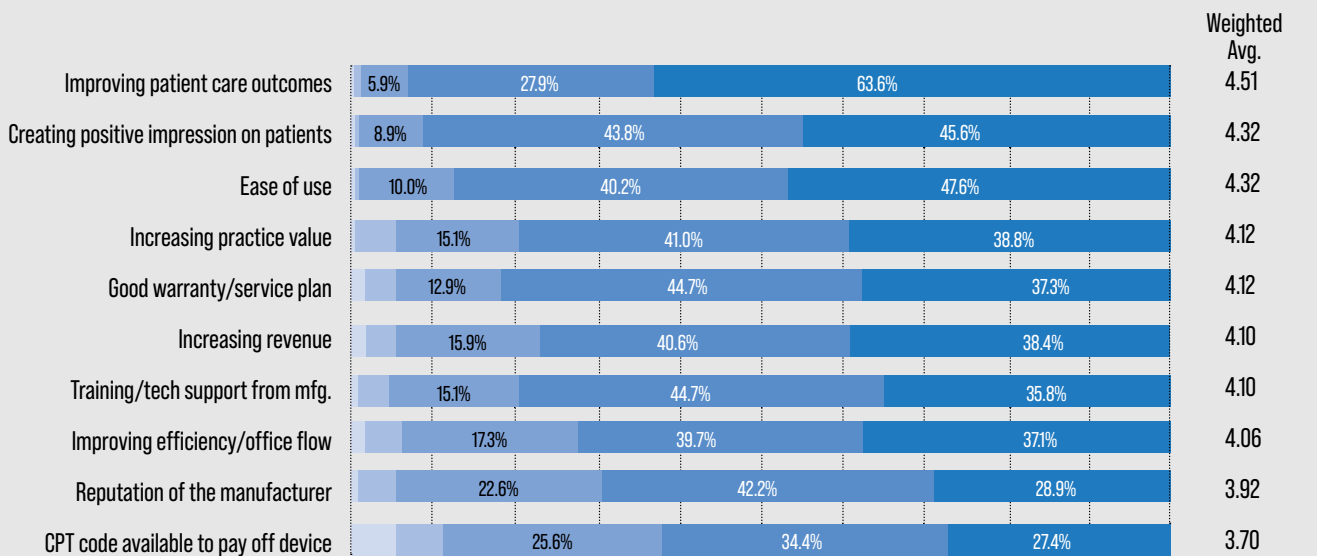
For each of these three factors, the weighted average—a composite score that encapsulates all responses—showed the sentiment to fall squarely between “no effect” and “increased somewhat,” although better clinical outcomes did edge out the other two.

Improving clinical outcomes also topped the list when we asked for ratings of several aspects of the purchasing decision (Figure 3). Here, the weighted average score of 4.51 shows optometrists’ strong commitment to buying equipment with their patients in mind. Tied for second in the rankings were the goals of creating a positive impres-

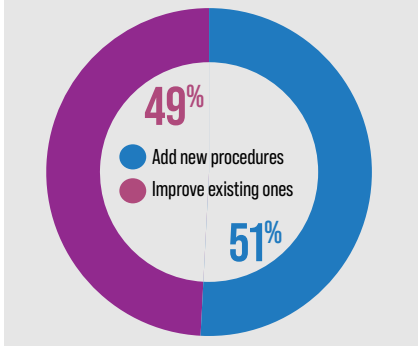
sion on patients and the device’s ease of use. Somewhat surprisingly, reputation of the manufacturer and availability of a CPT code—two elements often touted in product marketing—ranked the lowest in ODs’ priorities.

Several readers pointed out that challenges in hiring and retaining good staff affects equipment purchases, too. “I’m always looking to increase efficiency with equipment,” wrote one OD from South Bend, IN. “Staffing is getting more difficult and more expensive, so I’m looking to efficiencies with technology and equipment to do more with the same or less staff.”

**FIG. 3. RATE THE IMPORTANCE OF EACH WHEN BUYING NEW TECHNOLOGY.** *Rated on 1-5 scale [1 = least impact, 5 = most impact]*



**FIG. 4. FOR YOUR NEXT MAJOR EQUIPMENT PURCHASE, WHAT IS YOUR PRIMARY CLINICAL GOAL?**



by the recent exit of Maculogix from the market.

Turning to wish-list items (Figure 6), OCT already has a healthy adoption

among our readers—two-thirds have such a device—and getting on board with it is the number one goal for those who don't. Of the 32.2% of readers in the market for OCT right now, there's a lack of consensus on whether or not devices with angiography capabilities are worth it for them. It's split pretty evenly, with 16.9% of respondents looking to add OCT-A and another 15.4% opting for the standard OCT models.

Either way, it's a win for them and their patients. Milwaukee's Robert Blankenbeler, OD, raved about his recent OCT purchase. "It is a versatile instrument used at least 10 times a day," he wrote.

"I think the more 'combination' machines are the best—for example,

the OCT can do anterior segment scans and give me a pachymetry reading without having to use a handheld pachymeter," a reader from Detroit offered. "I hope technologically we move towards more combination feature machines for convenience for the patient and doctors alike. It would also remove the burden of time during patient flow."

Also posting strong numbers for intent to purchase were slit lamp camera attachments—ideal for patient education and pathology documentation—and the new virtual reality perimetry headsets that move visual field testing beyond traditional SAP.

With so many products, naturally there are plenty that ODs just can't justify even if they do seem cool (Figure 7).

**FIG. 5. WHICH OF THESE TOOLS DO YOU ALREADY HAVE?**

Slit lamp	92.6%
Autorefractor/keratometer	89.7%
Phoropter (manual)	89.7%
Diagnostic lenses	87.1%
Tonometer (Goldmann)	86.7%
Tonometer (non-Goldmann)	74.5%
Perimeter (conventional)	69.7%
OCT (with or without angiography)	67.3%
EHR with practice management features	64.7%
Pachymeter	57.8%
Fundus camera (conventional)	56.4%
Corneal topographer	52.8%
Gas permeable/scleral lens fitting sets	47.7%
Fundus camera (ultra-widefield)	42.2%
Phoropter (digital)	40.4%
Fundus autofluorescence	31.0%
Slit lamp camera attachment	27.4%
B-scan ultrasound	17.4%
Wavefront aberrometer	16.3%
Thermal pulsation device for MG expression	13.5%
Optical biometer	12.8%
Lid microexfoliation device	12.6%
Tear osmolarity tester	9.6%
Perimeter (headset)	8.5%
Scleral topographer	8.3%
Dark adaptometry	7.6%
Intense pulsed light	7.3%
Low-level light therapy	5.1%

**FIG. 6. WHICH ARE YOU CONSIDERING BUYING IN THE NEAR FUTURE?**

OCT (with or without angiography)	32.3%
Slit lamp camera attachment	31.6%
Perimeter (headset)	23.9%
Thermal pulsation device for MG expression	21.5%
Intense pulsed light	21.2%
Fundus camera (ultra-widefield)	19.5%
Tear osmolarity tester	18.7%
Corneal topographer	17.5%
Low-level light therapy	16.1%
EHR with practice management features	15.8%
Phoropter (digital)	14.7%
Lid microexfoliation device	14.1%
Optical biometer	13.2%
Tonometer (non-Goldmann)	12.9%
Pachymeter	12.6%
Fundus autofluorescence	11.8%
Fundus camera (conventional)	11.6%
Gas permeable/scleral lens fitting sets	11.2%
Scleral topographer	10.3%
Dark adaptometry	9.6%
B-scan ultrasound	8.7%
Slit lamp	7.4%
Perimeter (conventional)	6.9%
Wavefront aberrometer	6.4%
Tonometer (Goldmann)	5.9%
Autorefractor/keratometer	5.2%
Diagnostic lenses	5.2%
Phoropter (manual)	4.2%

**FIG. 7. WHICH WOULD YOU LOVE TO HAVE BUT JUST CAN'T JUSTIFY RIGHT NOW?**

Dark adaptometry	82.7%
Scleral topographer	81.8%
Low-level light therapy	78.7%
Wavefront aberrometer	77.3%
Optical biometer	74.9%
B-scan ultrasound	74.3%
Lid microexfoliation device	73.3%
Intense pulsed light	72.7%
Tear osmolarity tester	71.7%
Perimeter (headset)	67.6%
OCT (with angiography)	66.5%
Thermal pulsation device for MG expression	66.5%
Fundus autofluorescence	57.7%
Phoropter (digital)	45.7%
Gas permeable/scleral lens fitting sets	41.9%
Slit lamp camera attachment	41.1%
Fundus camera (ultra-widefield)	39.5%
OCT (without angiography)	35.0%
Fundus camera (conventional)	34.0%
Pachymeter	31.1%
Corneal topographer	30.9%
Perimeter (conventional)	24.1%
EHR with practice management features	19.9%
Tonometer (non-Goldmann)	12.6%
Diagnostic lenses	9.2%
Tonometer (Goldmann)	8.5%
Phoropter (manual)	7.2%
Autorefractor/keratometer	6.6%
Slit lamp	3.3%

Note: Figures 5 and 6 combine the figures for OCT and OCT-A into one value while Figure 7 lists each individually.

## Smart System® | VR Headset

Provided by the industry leader  
in vision testing for over 30 years



Vision  
Expo West  
Booth #F11039  
Las Vegas

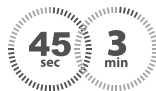### The Only VR Headset with Time-Tested Software

**M&S takes vision testing to new heights.** The programmable VR Headset with Surface Pro 7 Tablet is powered by our trusted M&S Smart System® software for fast and accurate vision testing. Our years of experience and service continue to help your clinic shine.



#### Reliable Results

Trust data accuracy with *Active Eye Tracking* technology that continuously monitors patient fixation and pauses the test when fixation is lost



#### Speed and Efficiency

Our proven testing protocols reduce patient fatigue by providing *QuickScreen* results in 45 seconds and full threshold test results in under 3 minutes per eye



#### Patient and Practice Friendly

Comfortable design with easy set up, audio and visual cues to your technician and patient, the ability to test without a wifi connection and results that can be immediately exported to your EMR

Schedule a demo at: [MSTech-Eyes.com/vr-headset](https://MSTech-Eyes.com/vr-headset)



**M&S**  
TECHNOLOGIES



847-763-0500  
[mstech-eyes.com](https://mstech-eyes.com)

The First Choice in Vision Testing Systems

A HILCOVISION COMPANY

CE ©2022 M&S and Smart System are registered trademarks of the Hilsinger Company Parent LLC. All rights reserved. The Hilsinger Company Parent LLC holds US Patents 7,354,155; 7,926,948; 8,425,040; 8,167,429; 8,419,184; 8,550,631; 8,992,022; 9,433,347; 9,820,644; 10,244,938 and 10,182,713. Other Patents Pending.

Items at the top of that list are too niche for many ODs; products at the bottom more often than not are workhorse devices that rarely need an upgrade.

Many respondents said return on investment, office space and equipment cost are what's holding them back. Others noted that comanagement allows them to take advantage of other colleagues' services—and invest in relationships rather than equipment—while also offering their own.

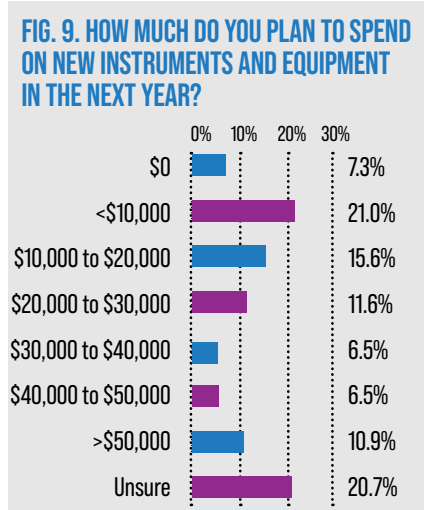
One highlighted the mistake of taking existing tools for granted. “I can buy it, but integration of a product is what scares me most. I don't want to add too much and not be able to use the devices. If I spread myself too thin, I won't be doing anyone any favors, especially my patients. If I focus on what I have and can improve upon it, I would consider adding more.”

### Selling Themselves Short

Sales reps strongly influence the opinions optometrists have about the company and whether or not to do business with them. The impression we got from our readers? Well, maybe reps should cut back on their caffeine intake a bit.

“I dislike pushy sales people,” said Samantha Love, OD, of Clermont, FL. “I value feedback from my fellow colleagues about their experience with the device.”

A reader from Southern California agreed. “The product should sell itself, with testimonials from other professionals who have used it. Reps should be able to feel safe to give references to practices with recent purchase.” This doctor also said they wish sales reps would understand the differ-



ences between small vs. large practices, optometry vs. ophthalmology and other distinctions that affect buying priorities.

Hard-sell tactics backfire, readers told us. “I hate when reps use a short deadline,” said an OD from Wisconsin. “I received a quote yesterday threatening that it's only good for six days, then the price will most definitely increase.”

Sales reps who are too aggressive run the risk of alienating potential customers. “I might be a little too cautious when I approach the purchase of new equipment. I don't enjoy sales reps who brush me off when they find out I financially cannot afford their device at the moment. I still want to learn everything about it even if I am not in the market to purchase at this time,” an OD from Utah commented. “In my situation, it would be beneficial to have more opportunities to interact with the technology through presentations or seminars without the hard sales push.”

Another reader noted that they wished manufacturers would post their

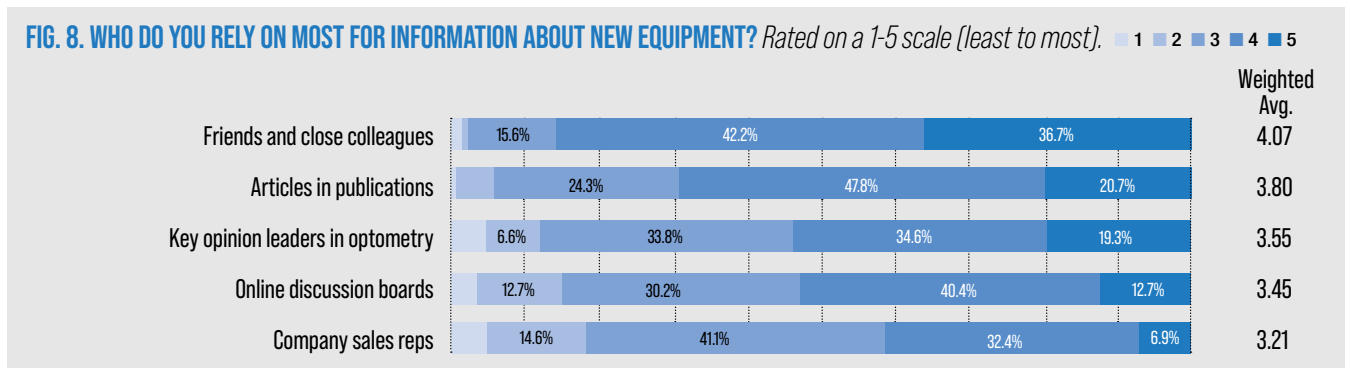
equipment prices online, “rather than saying ‘contact us for price.’ When I'm researching equipment, I don't want to deal with a rep initially.”

Instead, most optometrists in our survey prefer relying on friends and colleagues for advice about new purchases, followed by published articles, optometric opinion leaders, online discussion boards and, least of all, company sales reps (Figure 8).

### Health Care on the Horizon

Looking to future purchases, the more expensive the investment, the more hesitant ODs are to commit (Figure 9). The sweet spot in spending came out to be \$10,000 or less (21%), with 7% of ODs completely against looking into purchasing any dollar amount of equipment in the next year and another 21% unsure. Joette Wisoky, OD, of Lexington, KY, commented that they're not looking to buy the most expensive option on the market; rather, the most practical tool that aims to benefit the most patients is what catches their eye.

“Purchasing equipment is the easy part,” remarked respondent Larry Macapagal, OD, of Los Angeles. The hard part is what comes next: training, maintenance, upgrade and replacement. But it's worth it, with one survey respondent going so far as to say it's part of the OD's job to keep adding to their armamentarium. “Many factors go into device purchasing, but the most important is providing the highest quality care to patients. Being in the healthcare field requires staying up to date on everything including technology; we would be doing patients a disservice if we never updated.” ■



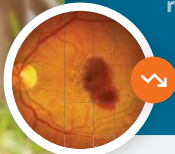# Prevent AMD Vision Loss with Digital Healthcare



IRIS REGISTRY

**20/83 VA**

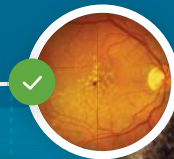Average at wet AMD diagnosis according to IRIS Registry real-world data<sup>1</sup>



HOME STUDY

**≥20/40 VA**

Average at wet AMD diagnosis with ForeseeHome<sup>2</sup>



## Early Detection Helps Preserve Vision

ForeseeHome is a **remote monitoring** program for at-risk dry AMD patients that helps **detect wet AMD earlier** and alerts you of changes.



**ForeseeHOME™**  
AMD Monitoring Program


## Remote patient monitoring leads to better outcomes and stronger optometric practices

✓ FDA Cleared    ✓ Medicare Covered

- Plug and play digital health solution for your patients
- No cost to your practice
- Solidify long-term relationships with your patients
- Strengthen your referral relationships with qualified wet AMD referrals

## The Key to Successful Home Monitoring

**NOTAL VISION MONITORING CENTER**



Engagement & Education  
Benefits Verification & Authorization  
Continuous Monitoring



Practice Workflow Implementation  
Remote Patient Management  
Vision Alert Management



ForeseeHome is a registered trademark, and the ForeseeHome AMD Monitoring Program and logo and the Notal Vision logo are trademarks of Notal Vision. © 2020 Notal Vision, Inc. All rights reserved.

References: 1. Rao P et al. *Ophthalmology*. 2018;125(4):522-528. 2. Domalpally A, Clemons TE, Bressler SB, et al. *Ophthalmol Retina*. 2019;3(4):326-335.

See website for FDA Indication for Use.

SM-169.2



**GET STARTED TODAY**

**1-855-600-3112**

Mon-Fri, 8 AM to 6 PM EST

[www.foreseehome.com/doctor](http://www.foreseehome.com/doctor)

# OCT: WHAT'S UNDER THE HOOD?

This essential guide will help you understand the technology and how it supports clinical practice.



BY LORI MANDY PENNINGTON, OD,  
AND BROOKE SMITH, OD  
HAMPTON, VA

The principles of optical coherence tomography (OCT) were first described just over 30 years ago and the first commercial device came on the market in 1996. This technology offers a noninvasive approach of imaging ocular tissues with high resolution by measuring back-scattered light and producing a cross-section topographic image. With the increase in clinical implementation to manage ocular and systemic disease, optometrists must continue learning how to expand the technology's uses from conventional and common to sophisticated but practical.<sup>1</sup> These now-multimodal imaging devices can help aid in the diagnosis of both ocular and systemic disease.

Clinicians have several commercially available spectral-domain (SD) OCT models to choose from. For this article, four prominent ones will be described: Cirrus HD SD-OCT 5000 (Carl Zeiss Meditec), 3D OCT-1 Maestro2 (Topcon Healthcare), Spectralis SD-OCT (Heidelberg Engineering) and Optovue iVue80 (Visionix). This article outlines the basics of OCT imaging, the newest model updates, a guided data analysis of the different instruments' metrics and how to interpret various measurements using each model.

## OCT Basics: Then and Now

Since its 1991 debut, OCT technology has continually evolved. Now considered primitive, the original time-domain analysis used an infrared light source and was dependent on movement of a mirror to change the optical

path of a reference beam. It could only acquire 400 scans per second with an 840nm wavelength, which limited imaging resolution and sampling density.<sup>2</sup>

Current spectral-domain OCT (SD-OCT) offers a superior resolution with a lessened acquisition time and

**Table 1. Comparison of Four Commercially Available SD-OCT Models**

Model (Manufacturer)	Cirrus HD-OCT 5000 (Carl Zeiss Meditec) <sup>16</sup>	3D OCT-1 Maestro2 (Topcon) <sup>17</sup>	Spectralis 2nd and 3rd Generation (Heidelberg) <sup>19</sup>	iVue80 Optovue (Visionix) <sup>18</sup>
Scanning Speed (A-scans per second)	27,000-68,000*	50,000	85,000**	80,000
Axial Resolution (µm in tissue)	5	6	Optical: 7 Digital: 3.9	5
Minimum Pupil Diameter (mm)	2	>2.5	SLO: 1.5 OCT: 2	2.5

\*Cirrus OCT (5000 model) acquires 68,000 scans per second with OCT-A

\*\*3rd generation Spectralis offers Shift Technology: 20kHz, 125kHz not available in the United States

**Table 2. Comparison of Four Commercially Available SS-OCT and OCT-A Models**

Model (Manufacturer)	Plex Elite (Carl Zeiss Meditec) <sup>16</sup>	Triton (Topcon) <sup>17</sup>	Optovue Avanti with Angiovue (Visionix) <sup>18</sup>	Spectralis OCT-A (Heidelberg) <sup>19</sup>
SD-OCT or SS-OCT	SS-OCT	SS-OCT	SD-OCT	SD-OCT*
Scanning speed (A-scans/sec)	100,000-200,000	100,000	70,000	85,000
Axial resolution (µm in tissue)	6.3	8	5	3.9
Minimum pupil diameter (mm)	2.5	OCT: 2.5 Fundus: 3.3	2.5	SLO: 1.5 OCT: 2
Field of view	56°	45°	12mm x 9mm	up to 30°

\*Swept-source Anterior imaging app available

About the authors

**Dr. Pennington** is a staff optometrist at the Hampton VA Medical Center, where she is adjunct faculty for the Ohio State University College of Optometry. She is the president of the Tidewater Optometric Society and a member of the board of trustees for the Virginia Optometric Association. **Dr. Smith** is a staff optometrist at the Hampton VA Medical Center, where she is the externship director and adjunct faculty for Ohio State University. She is an active fellow of the American Academy of Optometry, where she lectures and currently sits on the fellowship committee advisory board. Neither has any financial disclosures.

can capture between 26,000 and 80,000 axial scans per second, while swept-source OCT (SS-OCT) can achieve upwards of 100,000 to 200,000 axial scans per second (*Tables 1 and 2*).<sup>3</sup> This development allows the clinician to minimize motion artifacts and provides volumetric analysis with three-dimensional imaging capabilities to obtain better quality images.<sup>2</sup>

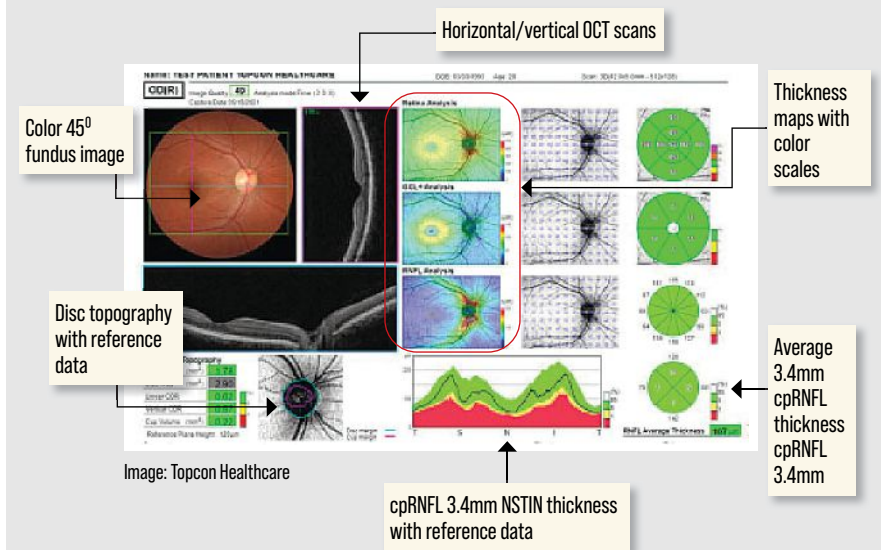
Today, the most common OCT models on the market for eye care are the combination OCT/fundus systems and advanced OCT models. These SD-OCT devices have enhanced fundus camera capabilities, increased field of view and can combine retinal nerve fiber layer (RNFL), macula and ganglion cell layer (GCL) all in one report (*Figures A and B*). Multimodal imaging offers full-color, high-resolution fundus photography, reflectance imaging and fundus autofluorescence.

Many of the newer SD-OCTs have more anterior segment options to better evaluate the cornea and anterior chamber (*Figures I to L*). Most continue to allow image acquisition with miotic pupils, which is advantageous for patients who struggle with dilation due to age or other factors.<sup>4</sup> Furthermore, advancements and upgrades in OCT systems include widefield, swept-source, enhanced-depth imaging (EDI-OCT) and OCT angiography (OCT-A) technologies. These will all be discussed below.

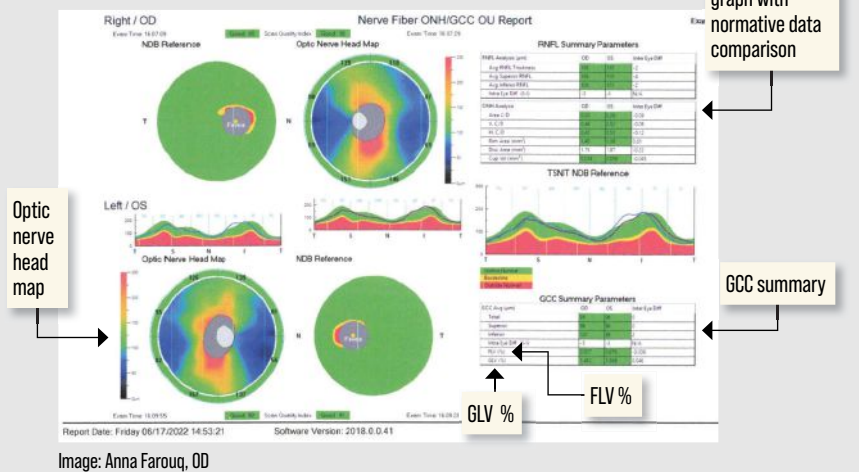
SS-OCT and EDI-OCT allow for deeper retinal imaging that includes the choroid, with faster acquisition speeds.<sup>5</sup> SS-OCT uses longer wavelengths (1050nm vs. 840nm in SD-OCT) to overcome scattering light defects of the RPE and faster scanning times (100,000 to 400,000 A-scans/sec) allow for longer B-scans to help with widefield imaging.<sup>2,3</sup> With these parameters, SS-OCT allows for penetrance to the level of the choroid with a reduced axial resolution.<sup>6</sup>

Two commercially available SS-OCTs today are Topcon's Triton DRI (*Figure H*) and Plex Elite 9000. They offer 12x9mm widefield scans.<sup>7</sup> EDI-OCT penetrates an additional 500µm to 800µm deeper compared with

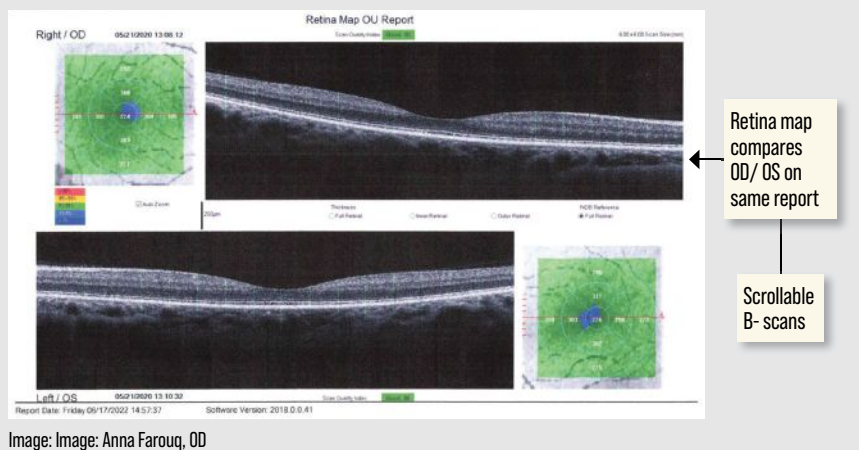**Fig. A. Topcon 3D-1 Maestro2 3D Wide Report**



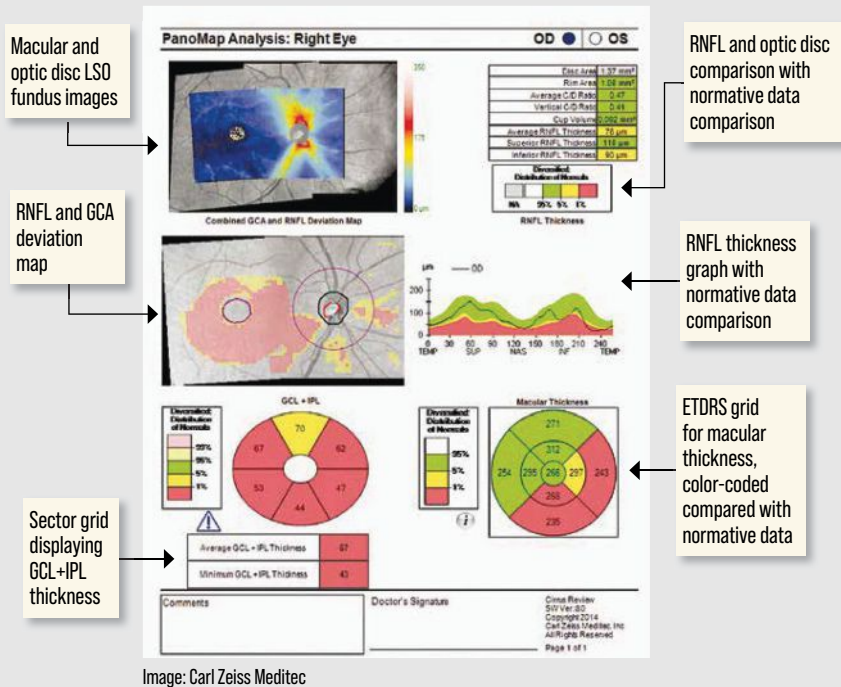
**Fig. B. Optovue iVue80 Nerve Fiber ONH/GCC OU Report**



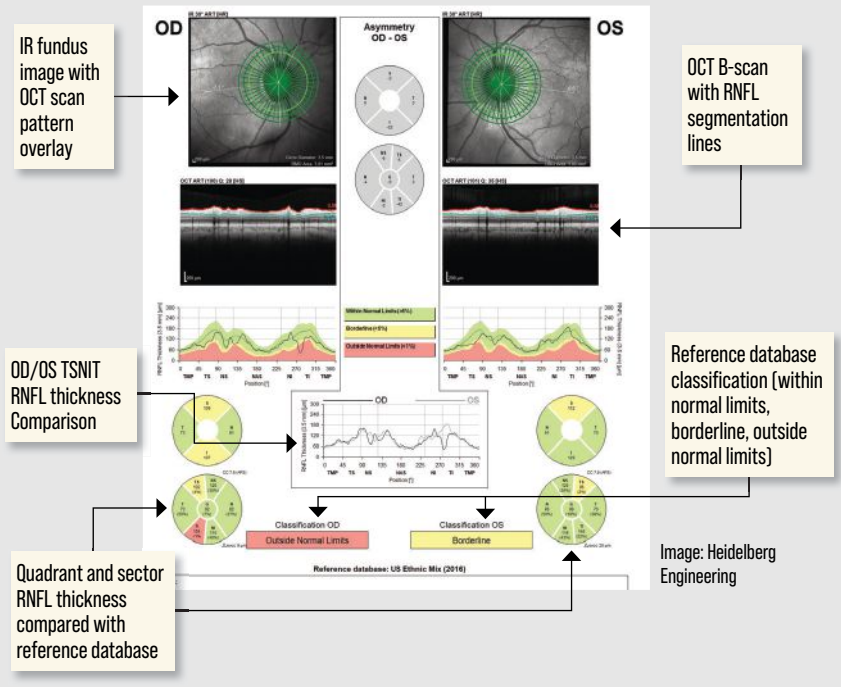
**Fig. C. Optovue iVue80 Retina Map OU Report**



### D. Zeiss Cirrus HD-OCT PanoMap Analysis



### E. Heidelberg Spectralis Glaucoma Report



ovue offers “deep choroidal imaging” (DCI). The EDI option may have to be chosen when taking the scans on SD-OCT. SS-OCTs integrally image the choroid and deeper structures without the need for EDI.

Several of the new SD and SS models have a true color fundus photo with corresponding disc topography, RNFL thickness, GCL thickness with reference data all on the same report (*Figures A and H*). Spectralis has a multicolor imaging platform offered with confocal scanning laser ophthalmoscope (cSLO) fundus imaging (*Table 3*).

Typically thought of as a posterior segment diagnostic instrument, the OCT has offered several different anterior segment options (*Figures I-L*). In addition to aiding in the assessment of the cornea and angle, anterior segment OCT (AS-OCT) can also be used to fit complex specialty contact lens patients. AS-OCT has the capabilities of measuring sagittal height and depth, tear layer clearance, landing zone and thickness alignment for scleral, rigid gas permeable and custom fit lenses.<sup>10</sup>

Phase-variable technology, or OCT-A, combines Doppler analysis and OCT imaging to produce superimposed structural data.<sup>4,6</sup> Its noninvasive technology obtains three-dimensional volumetric images of the retinal and choroidal vascular systems as well as blood flow. These images are dependent on multiple cross-sectional scans, scattering properties and collecting depth-encoded profiles from motion contrast of erythrocytes.<sup>5</sup> OCT-A has improved identification of capillary nonperfusion, microaneurysms and retinal ischemia, as well as delineating the foveal avascular zone.<sup>11</sup>

*Table 2* references the four main commercially available OCT-A devices with their respective angio analytics. While montage OCT-A is useful in detecting small areas of neovascularization and capillary nonperfusion, it is not required to detect small areas of neovascularization and capillary nonperfusion. However, in diabetic retinopathy, many of these areas are going to be outside of the typical 6x6mm or 8x8mm scan;

traditional OCT.<sup>1</sup> The EDI feature has become the gold standard of detection of optic nerve head drusen and very useful in age-related choroidal atrophy, high myopia, central serous chorioretinopathy and choroidal tumors.<sup>8,9</sup>

Currently, EDI scans are available on the 4000 and 5000 Zeiss models as well as the second and third generation Spectralis models. Topcon uses similar technology, called “deep range imaging” (DRI) on its systems, while Opt-



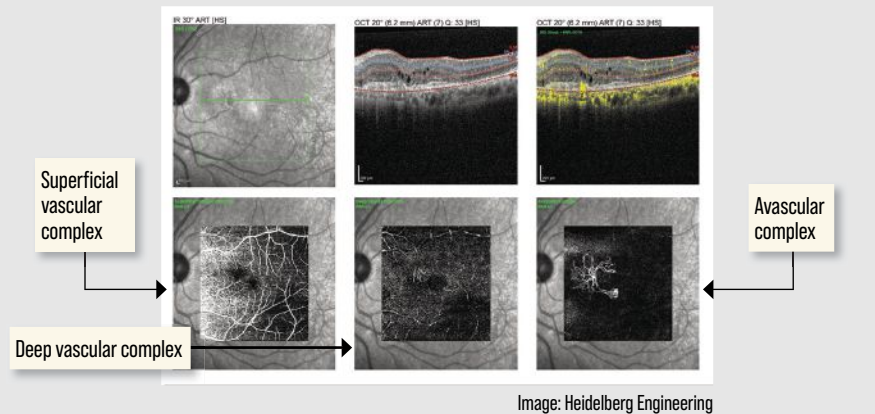
a montage strategy allows for a wider field of view to detect these lesions.<sup>1</sup>

Furthermore, OCT-A imaging blood flow information can be displayed as *en face* and the cross-sectional view. An *en face* view allows blood flow visualization as a top view mode and can separate the inner and outer retinal vascular plexus, the choriocapillaris and the choroid (Figures F and G). It can also be used to look for blood flow in regions where it should not be, such as on the vitreoretinal interface in the situation of retinal neovascularization and in the avascular zone with the development of choroidal neovascularization. Cross-sectional views offer blood flow information displayed over a structural B-scan, allowing detailed correlation of flow signals with structural OCT findings.<sup>12</sup>

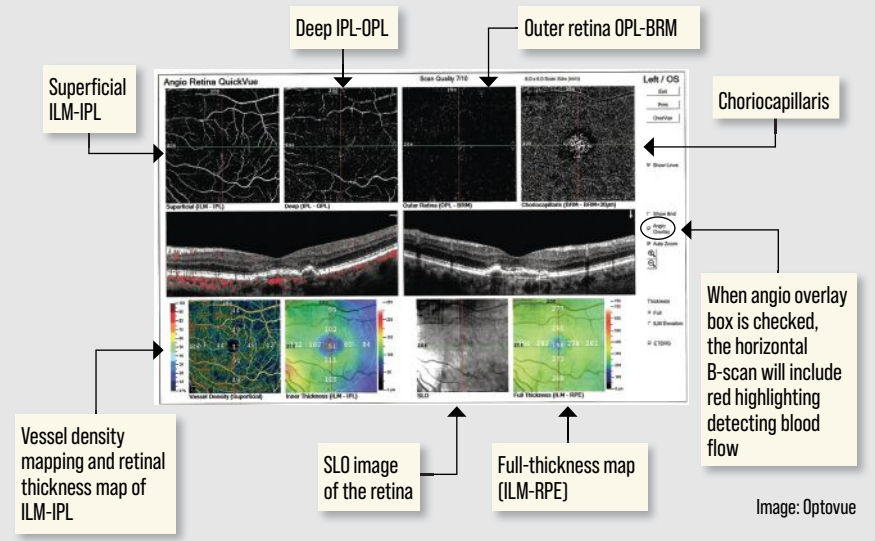
OCT-A was initially developed as an application of SD-OCT but is now being integrated into SS-OCT models. Today's instruments acquire about 70,000 to 100,000 A-scans per second using a light source centered at a wavelength of either 840nm or 1050nm, for SD- or SS-OCT-A, respectively, with an interscan time of 4ms to 5ms, and achieving optical axial resolution of 5µm to 10µm.<sup>5</sup> Blood flow velocity in the retinal circulation can be anywhere in the range 0.2mm/s to 7mm/s.<sup>5</sup> Instruments usually collect between two to four B-scans at the same location. OCT-A's angular field of view covers 10° to 30°, but widefield can extend the raster scanning protocol to achieve much larger fields of view, up to 12x12mm using the montage technique.<sup>5,11</sup>

OCT and OCT-A have the potential to detect optic neuropathies, retrochiasmal visual pathway disorders and systemic diseases.<sup>6</sup> In particular, SD-OCT has revealed diffuse inner retinal thinning that is prominent of the RNFL, GCL/inner plexiform layer (IPL) junction and choroid. These are commonly seen in patients that suffer from neurodegenerative diseases such as Alzheimer's, multiple sclerosis and dementia. (Figure M).<sup>13,14</sup> Alzheimer's disease patients showed a significant thickness reduction in global and temporal superior quadrants in RNFL.<sup>15</sup>

### F. Spectralis OCT-A

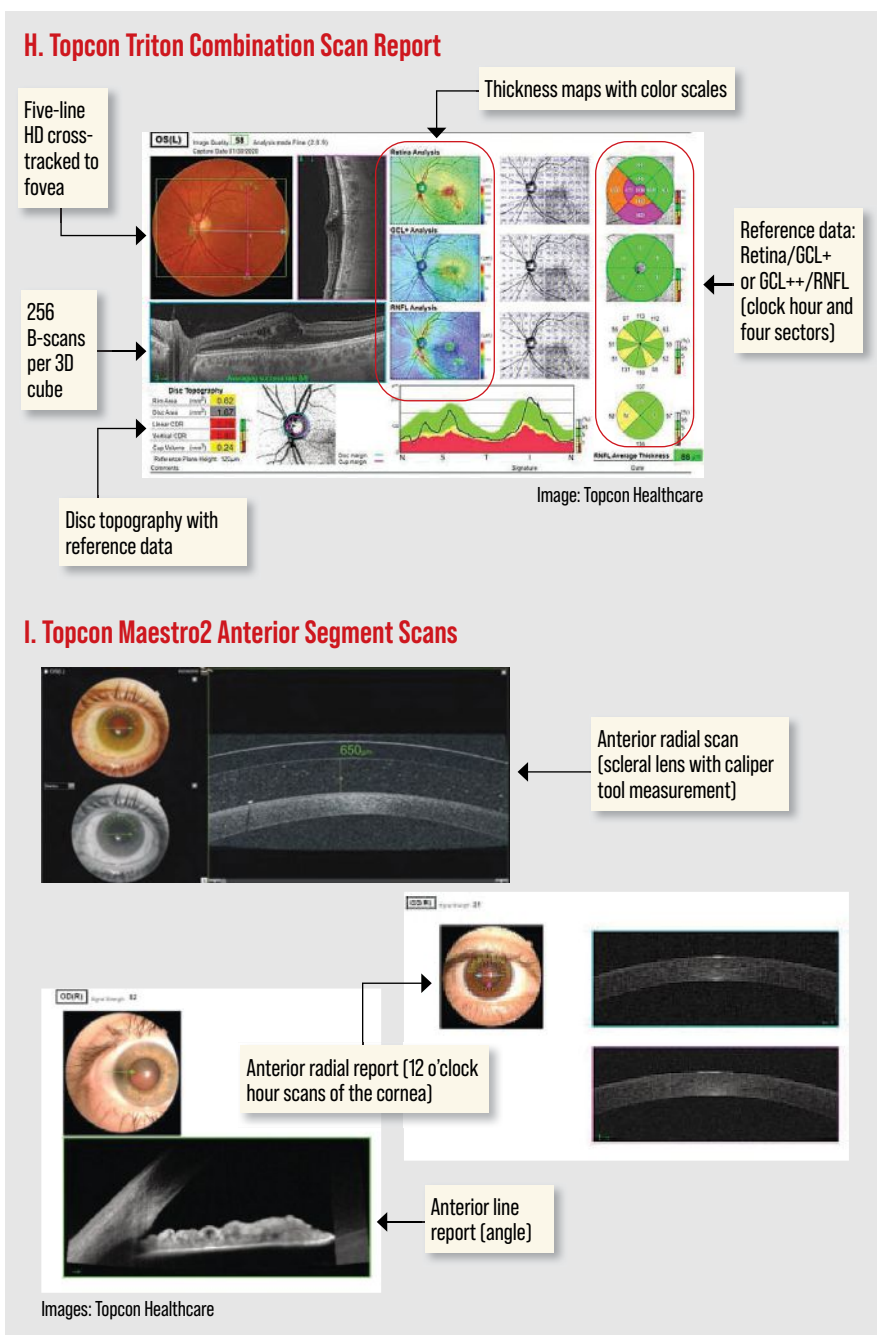


### G. Optovue AngioRetina OCT Angiography QuickVue Report



**Table 3. Comparison of Imaging Modes and Capabilities by Model**

	Cirrus HD-OCT 5000 <sup>1</sup>	3D OCT-1 Maestro <sup>27</sup>	Spectralis 2nd Generation <sup>19</sup>	iVue80 <sup>18</sup>
<b>Imaging Modes</b>	SD-OCT, cSLO	SD-OCT widefield, Color fundus, red-free fundus, IR fundus, enhanced IR fundus and external eye photography	SD-OCT cSLO	SD-OCT widefield
<b>Fundus Photos Scanning Modes</b>	IR	Color, red-free, IR	IR, blue laser FAF, MultiColor, red-free photos, scanning laser angiography includes FFA and ICGA	Live IR iCam12 upgrade: color, red-free
<b>Image Field of View</b>	Fundus photo, 36x30mm	Fundus photo, 45°	SD: 30° (8.9mm), WFO: 55° (16.3mm), UWF: 102° (30.3mm), ASM: 30° (16.6mm), HMM: 8° (2.3mm), panning camera	Varies by scan; maximum is a line scan at 12mm (about 42°)



The 3D OCT-1 Maestro2 offers widefield OCT with color retinal photography. In addition to automated capture, the Maestro2 offers manual/semi-manual options for difficult-to-image patients.<sup>17</sup> The 3D wide report offers simultaneous imaging of the macula and optic nerve in one scan, providing a single report with retinal thickness, RNFL, ganglion cell thickness and optic nerve head (ONH) analysis with reference database comparisons (Figure A). The Maestro2 also has several anterior segment scan options (anterior radial and anterior line; Figure D).

The iVue80 (Optovue) offers 80,000 A-scans per second, which is three times faster than the original iVue OCT. The most current model offers *en face* imaging. Focal loss volume (FLV%) and global loss volume (GLV%) are GCC metrics unique to this system that provide information to aid in glaucoma diagnosis and management.<sup>18</sup> (Figure B) The retina map compares OD/OS on the same report (Figure C).

The third-generation Spectralis SD-OCT offers 85,000 A-scans per second compared to 40,000 in the first-gen device. In addition to EDI, Spectralis second and third generations offer enhanced vitreous imaging. Spectralis has something called shift technology, which the manufacturer says enables you to switch between three OCT scan speeds to find the optimal balance of image quality and clinical workflow. It received the CE Mark for safety in Europe in 2022, but is not yet available in the United States. Spectralis now offers Anterior SS-OCT imaging, which provides high resolution visualization of the entire anterior segment (Figure L).<sup>19</sup>

All OCT instruments possess a retinal thickness scanning mode as well as an optic nerve and RNFL acquisition and analysis. Most have an anterior segment option to evaluate the anterior chamber and cornea (Table 4). Current OCTs also possess recognition software and progression or change functions to track and monitor progression over time based on each model's normative data (Table 5).

OCT-A analysis found a reduction of retinal vessel and perfusion density, with a larger foveal avascular zone.<sup>13</sup>

### Comparing OCT Scan Reports

While all four SD-OCT models are comparable in many ways, each one displays the data differently.

The Cirrus HD-OCT has a Pano-Map Analysis report that combines information from the macular cube and optic disc cube scans, providing an integrated widefield viewpoint

for comprehensive analysis which is particularly useful in monitoring glaucoma progression. (Figure D). The newest software has several anterior segment scan options. The HD angle scan generates a report that is used for the assessment and documentation of the anterior chamber angle. The pachymetry scan uses 24 radial scan lines to generate a color-coded map of the cornea. The Wide Angle-to-Angle scan captures both iridocorneal angles in one scan. (Figures I-J).<sup>16</sup>

# Life demands more of our eyes

An unprecedented combination of technologies designed to help meet the demands of today.<sup>1</sup>

**TearStable™  
Technology**  
**MAX comfort**<sup>\*2</sup>



**OptiBlue™  
Light Filter†**  
**MAX clarity**<sup>\*2</sup>



Also Available in Multifocal

# ACUVUE®

\* Versus ACUVUE® OASYS 1-Day

† Filtering of HEV light by contact lenses has not been demonstrated to confer any health benefit to the user, including but not limited to retinal protection, protection from cataract progression, reduced eye strain, improved contrast, improved acuity, reduced glare, improved low light vision, or improved circadian rhythm/sleep cycle. The Eye Care Professional should be consulted for more information.

1. JJV Data on File 2022. TearStable™ Technology Definition.

2. JJV Data on File. CSM Subjective Responses ACUVUE® OASYS MAX 1-Day Contact Lenses- Retrospective Meta-analysis

**Important safety information:** ACUVUE® Contact Lenses are indicated for vision correction. As with any contact lens, eye problems, including corneal ulcers, can develop. Some wearers may experience mild irritation, itching or discomfort. Lenses should not be prescribed if patients have any eye infection, or experience eye discomfort, excessive tearing, vision changes, redness or other eye problems. Consult the package insert for complete information. Complete information is also available from Johnson & Johnson Vision Care, Inc. by calling 1-800-843-2020, or by visiting [www.jnjvisionpro.com](http://www.jnjvisionpro.com).

© Johnson & Johnson Vision Care, Inc. 2022

PP2022MLT5735



Scan to see the  
**MAX** difference.

**Table 4. Scan Acquisition and Analyzing Options by Model**

Model	Cirrus HD-OCT 5000 <sup>16</sup>	3D OCT-1 Maestro2 <sup>17</sup>	Spectralis 2nd and 3rd Generation <sup>19</sup>	iVue80 Optovue <sup>18</sup>
<b>Scanning Range</b>	Retina/nerve, anterior segment	Retina/nerve, anterior segment, cornea, angle	Retina/nerve/periphery/anterior	Retina/nerve, cornea, angle
<b>Scan Acquisition: Macula</b>	Macular cube (512x128, 200x200), HD 21-line raster, HD radial, HD Cross	3D scan 6mm x 6mm, radial scan, five line horizontal and vertical cross scan	Line, volume (3D), radial	3D Retina (7X7mm), line (12mm), radial lines (six 12mm radial slices)
<b>Scan Acquisition: Nerve</b>	Optic disc cube (200x200)	3D wide scan, 6mm x 6mm	Circle/Radial/Volume (Posterior Pole Scan)	13 concentric rings at the following diameters: 4.9mm, 4.6mm, 4.3mm, 4.0mm, 3.7mm, 3.4mm, 3.1mm, 2.8mm, 2.5mm, 2.2mm, 1.9mm, 1.6mm, 1.3mm  12 radial line scans at 3.4mm length
<b>Scan Acquisition: Anterior Segment</b>	12-line raster, cornea, manual angle	Radial corneal scan, line angle scan	Line, Volume (3D), Radial	Pachymetry, cornea line, cornea crossline, angle, raster, 3D cornea
<b>Posterior Segment Analysis</b>	Macula: macular thickness, macular change, ganglion cell, RPE change  Nerve: RNFL thickness, guided progression  3D imaging	Glaucoma and macula report (12mm x 9mm 3D wide scan)  Macula: 3D macula report analysis  Nerve: 3D disc report, 6mm x 6mm, RNFL trend analysis, glaucoma analysis	Retina: Visualization of 15 structures, segmentation of retinal layers, progression analysis, customizable scan patterns, 3D imaging  Glaucoma: Visualization of 15 structures, segmentation of retinal layers, progression analysis, RNFL/GC/IPL thickness, BMO-MRW, asymmetry, RNFL and MRW reference database	Vessel registration  Focal Loss Volume metric, Global Loss Volume metric  Macula: retinal thickness analysis, retinal trend analysis, ganglion cell complex analysis, ganglion cell trend analysis, multilayers enface report; iWellness report  Nerve: 3D Disc, nerve fiber layer analysis; nerve fiber trend analysis
<b>Anterior Segment Analysis</b>	Cornea: manual thickness  Angle: manual angle measurement	Cornea: thickness map, curvature and radial  Angle: manual angle measurement	Angle to angle view, customizable scan patterns	Cornea: 6mm area, pachymetry and epithelial thickness map, anterior radial map, change analysis report  Angle grading: manual

**COMMON OCT ABBREVIATIONS AND TERMINOLOGY**

**A-scan/B-scan:** axial images allowing for 3D representation/line scan of longitudinal images

**AS-OCT:** anterior segment OCT

**AS-OCT-A:** anterior segment OCT angiography

**BMO-MRW:** Bruch's membrane opening minimum rim width

**cpRNFL:** circumpapillary retinal nerve fiber layer

**cSLO:** confocal scanning laser ophthalmoscopy

**Deviation map:** graph comparing patient to normative age-matched database

**En face OCT:** view of retina or optic nerve as a clinician would view during funduscopy

**EDI:** enhanced-depth imaging

**FLV (%):** focal loss volume (pre-glaucoma) based on normative data

**DRI:** deep range imaging

**GCL+:** GCL and IPL Layers

**GCL++:** RNFL, GCL and IPL layers

**GCL/GCA/GCC:** ganglion cell layer/ganglion cell analysis/ganglion cell complex

**GCL-IPL:** ganglion cell layer-inner plexiform layer

**GLV (%):** ganglion cell loss volume (advanced glaucoma) metric based on normative data

**ILM-IPL:** internal limiting membrane-inner plexiform layer

**ILM-RPE:** internal limiting membrane-retinal pigment epithelium

**ED:** enhanced-depth imaging

**FLV (%):** focal loss volume (pre-glaucoma) based on normative data

**DRI:** deep range imaging

**GCL+:** GCL and IPL Layers

**GCL++:** RNFL, GCL and IPL layers

**GCL/GCA/GCC:** ganglion cell layer/ganglion cell analysis/ganglion cell complex

**GCL-IPL:** ganglion cell layer-inner plexiform layer

**GLV (%):** ganglion cell loss volume (advanced glaucoma) metric based on normative data

**ILM-IPL:** internal limiting membrane-inner plexiform layer

**ILM-RPE:** internal limiting membrane-retinal pigment epithelium

**Line scan:** a scan through a tissue, which can be adjusted to orientation

**LSO:** line scan ophthalmoscope

**NDB:** normative database

**NSTIN:** nasal-superior-temporal-inferior-nasal

**ONH:** optic nerve head

**OCT-A:** OCT angiography

**Raster:** scan generally consisting of five lines that can have various spacing and orientation (customizable)

**OPL-BRM:** outer plexiform layer-Bruch's membrane

**Raster:** scan generally consisting of at least five lines that can have various spacing and orientation (customizable)

**RNFL/prNFL:** retinal nerve fiber layer/paripapillary retinal nerve fiber layer

**SD-OCT:** spectral-domain OCT

**SS-OCT:** swept-source OCT

**SS-OCT-A:** swept-source OCT angiography

**Thickness map:** graph comparing retinal thickness with normative age-matched database

**Tomogram:** a two-dimensional image of a slice through a tissue (e.g., retinal tissue)

**TSNIT:** linear graph of concentric nerve fiber layer thickness in respect to normative database; temporal, superior, nasal, inferior, temporal

**UWF:** ultra-widefield

**Volume scan:** 3D representation formed from the vertical and horizontal line scans, representing a block or cube of retinal tissue

**WFO:** wavefront optimized

**SD-OCT:** spectral-domain OCT

**SS-OCT:** swept-source OCT

**SS-OCT-A:** swept-source OCT angiography

**Thickness map:** graph comparing retinal thickness with normative age-matched database

**Tomogram:** a two-dimensional image of a slice through a tissue (e.g., retinal tissue)

**TSNIT:** linear graph of concentric nerve fiber layer thickness in respect to normative database; temporal, superior, nasal, inferior, temporal

**UWF:** ultra-widefield

**Volume scan:** 3D representation formed from the vertical and horizontal line scans, representing a block or cube of retinal tissue

**WFO:** wavefront optimized

NEW  
TECHNOLOGIES  
& TREATMENTS IN  
EYE CARE



NOVEMBER 11–13, 2022

HILTON ORLANDO BUENA VISTA PALACE | 1900 E. BUENA VISTA DRIVE  
ORLANDO, FLORIDA

 IN-PERSON EVENT

OVERVIEW

NT&T continues to serve as a forum to gain clinical pearls and insights that we know you're going to face in clinical practice routinely and regularly, but even some of the rarer forms of cases and presentations so that the next time you see it, you'll have a new sense of understanding and ability to manage it effectively.

PROGRAM CHAIR



**Paul M. Karpecki, OD, FAAO**  
Kentucky Eye Institute  
Director of Cornea & External Disease  
Associate Professor  
University of Pikeville  
Kentucky College of Optometry  
Lexington, Kentucky

PRESENTING FACULTY



**Douglas Devries, OD**  
Co-founder  
Eye Care Associates of Nevada  
Associate Clinical Professor of Optometry  
Sparks, Nevada



**Mark Dunbar, OD, FAAO**  
Director of Optometry  
University of Miami  
Miami, Florida



**Brianna Rhue, OD**  
West Broward  
Eyecare Associates  
Tamarac, Florida



**Eric Schmidt, OD, FAAO**  
President and Founder  
Omni Eye Specialists  
Wilmington, North Carolina

Earn up to 20 LIVE COPE credits\*  
8 hours of TQ\*\*

For more information and to register, visit:  
[www.reviewedu.com/ntt-orlando](http://www.reviewedu.com/ntt-orlando)



Postgraduate Institute  
for Medicine

\*COPE approval pending

\*Florida Board of Optometry approval pending

\*\*8 hours of TQ approval is pending for optometrists licensed in Florida or other states requiring "Transcript Quality" courses for re-licensure.

Partially supported by an unrestricted educational grant from Bausch + Lomb.

# REGISTER NOW

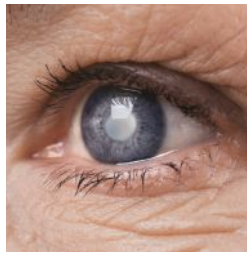

IN-PERSON EVENTS

Join Review Education Group and MedscapeLIVE! this December for the West Coast Optometric Glaucoma Symposium (WCOGS) and Retina Update 2022. The conferences will be co-located at the Hilton La Jolla Torrey Pines in La Jolla, California. Attendees are encouraged to participate in both symposia to greatly enhance their learning experience.

**Early bird special pricing: \$149 single conference | \$250 bundled**

Deadline to register with special rate: October 21, 2022



## WEST COAST OPTOMETRIC GLAUCOMA SYMPOSIUM

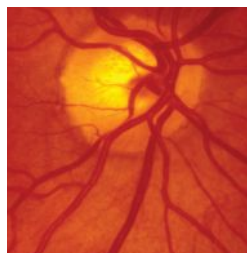
**DECEMBER 9–10, 2022**

LA JOLLA, CALIFORNIA

Program Co-Chairs: Murray Fingeret, OD, FAAO; Robert N. Weinreb, MD

**EARN UP TO 12 LIVE COPE CREDITS\***

WCOGS is a 2-day biannual symposium designed to provide optometrists with exposure to current thinking on evolving standards of care, state-of-the-art technology and breaking research that will guide current and future glaucoma care in the optometric setting. Incorporating cases, clinical pearls, and discussion sessions, the program will maximize the opportunity for participant/faculty engagement.



THE OPTOMETRIC RETINA SOCIETY AND REVIEW EDUCATION GROUP PRESENT

## RETINAUPDATE2022

**DECEMBER 10–11, 2022**

LA JOLLA, CALIFORNIA

Program Co-Chairs: Mohammad Rafieetary, OD, FAAO; Steven Ferrucci, OD, FAAO

**EARN UP TO 11 LIVE COPE CREDITS\***

Retina Update 2022 will help ensure that primary practitioners consider all relevant research so they can practice in an effective and appropriate manner. The program will offer specific direction and practical advice on how to detect and manage a broad range of retinal disease and promote improved retinal health.

**Earn up to 23 LIVE COPE credits\***

[www.reviewedu.com/winteroptometry](http://www.reviewedu.com/winteroptometry)



Postgraduate Institute  
for Medicine



### J. Zeiss Cirrus HD-OCT Wide Angle-to-Angle Analysis

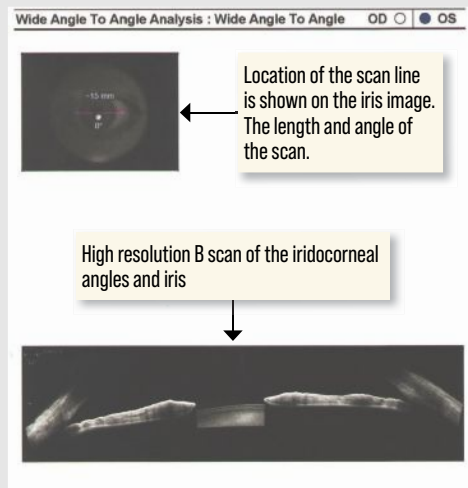


Image: Carl Zeiss Meditec

### K. Zeiss Cirrus HD-OCT Pachymetry Analysis

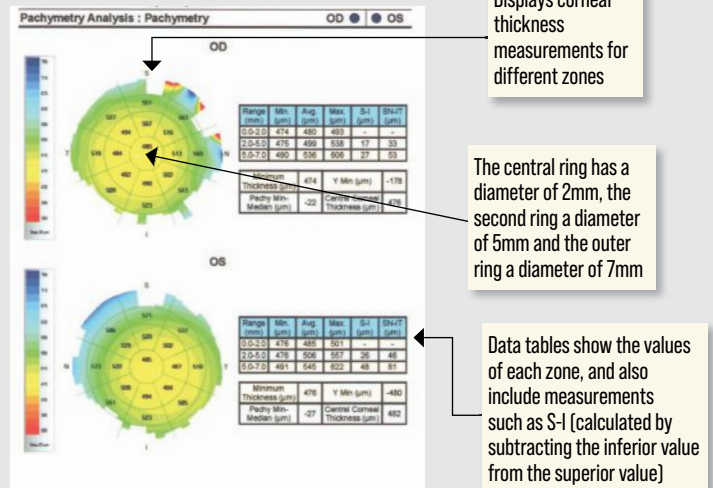


Image: Carl Zeiss Meditec

### L. Heidelberg Engineering Anterior




Image: Heidelberg Engineering

### M. Cirrus HD-OCT results of GCL-IPL thickness in an Alzheimer's patient

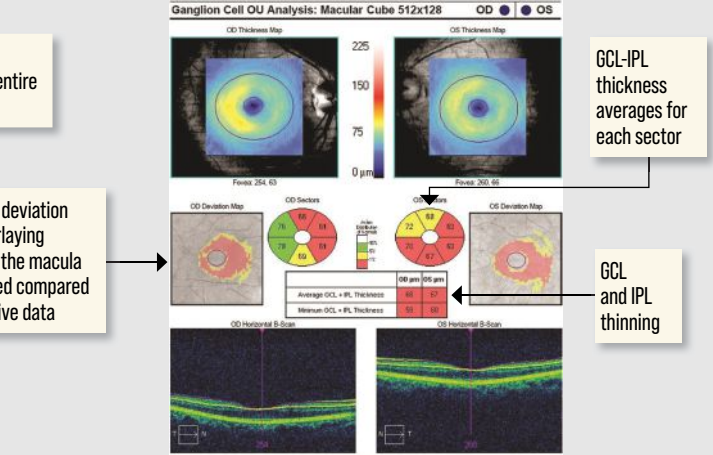


Image: Kim JI, Kang BH. Decreased retinal thickness in patients with Alzheimer's disease is correlated with disease severity. *PLoS One*. 2019 Nov 5;14(11):e0224180.

### OCT-A's Limitations

Despite the technological wonder of better understanding retinal vasculature in a noninvasive approach, several limitations currently exist. These can be divided into technological and uniform standardization deficits. Currently, OCT-A's image quality is impacted by artifacts produced by motion, such as blinking and saccades.<sup>20</sup> Also, OCT-A does not currently provide dynamic information such as velocity of blood flow or the presence of leakages.<sup>21</sup>

In order to increase the visibility and orientation of retinal vessels, reduce

imaging artifacts and improve post image processing, a dual-mode instrument that has standard (20µm) and high transverse resolutions (5µm to 10µm) is beneficial. Working on advancing from 2D projections to 3D will improve volumetric vascular networks and metrics, as well as increasing the angular field of view to more than 100°.

Commercially available instruments currently do not have normative databases from which to compare your individual patients. More comprehensive multi-sourced databases are needed to incorporate this into the instruments.

This will aid in the diagnosis of retinal vascular disease and identify potential biomarkers for a variety of retinal and systemic pathologies. Currently, two OCT-A datasets can be found from the ROSE and PREVENT studies.<sup>5</sup>

### The Future of OCT

After 2020, the global market for OCT in ophthalmology was estimated at \$526.2 million in the United States and is projected to reach approximately \$754.4 million in the US by 2026.<sup>22</sup> Further advancements in macular and extramacular imaging with adaptive

optics are to include indocyanine green angiography and widefield OCT-A with eye motion artifact correction and laser Doppler holography. This technology permits a large field of blood flow imaging and deeper assessment of the retina and choroid anterior to the equator with high resolution.<sup>23</sup>

Additionally, swept-source systems and three-dimensional visualization of choroidal vessels are being evaluated to visualize the choroid vasculature.<sup>24</sup> Promising early-stage lab-based research includes the study of retinal vascular function, including monitoring of pulse wave velocity, blood flow heterogeneity and response to external stimulation.<sup>5</sup> Other widefield OCT devices that use both SD and SS-OCT technologies are under development.

Research on the anterior segment OCT-A remains in its initial phase. With an adaptor lens, anterior segment OCT-A analysis can be used in assessing the conjunctiva, cornea and limbus, ciliary body and iris. OCT-A can also scan the anterior segment for abnormal vasculatures and assess limbal epithelial stem cells and suspicious lesions. Postoperative use of anterior segment OCT-A will help in the early evaluation of blood flow density on filtering blebs after trabeculectomy. Widefield SS-OCT-A shows potential for anterior segment imaging due to its sufficient scanning range and high sensitivity in detecting structures.<sup>11</sup>

Portable, handheld OCT devices with and without angiography are being better refined to offer disease management in pediatric and elderly patients. These devices are becoming smaller with more accurate and detailed results of direct imaging, and manufacturers are creating normative databases.<sup>25</sup> Currently, at-home OCT monitoring is being developed for exudative macular degeneration with the Notal Home OCT by Notal Vision. This device is said to be patient friendly for those with reduced acuities (>20/400) and uses artificial intelligence software to analyze for subretinal fluid. If detected, a report is generated and assigned to a physician at the Notal Vision Diagnostic Clinic for

**Table 5. SD-OCT Normative Databases by Manufacturer for US Models**

	Carl Zeiss Meditec <sup>16</sup>	Topcon <sup>17</sup>	Heidelberg <sup>19</sup>	Optovue Visionix <sup>18</sup>
<b>Number of Subjects</b>	284 RNFL study 282 macula, ganglion cell, ONH study	399	201 (RNFL thickness)	480
<b>Ages</b>	19 to 84	18 to 88	18 to 78	18 to 82
<b>Sex (M/F)</b>	Macula and ganglion cell study: 133/149  RNFL and ONH study: 134/150	173/226	111/90	Retina only
<b>Ethnicity</b>	43% Caucasian 24% Asian 18% African American 12% Hispanic 1% Indian 2% Mixed Ethnicity	59% Caucasian 20% African American 18% Hispanic/Latino 3% Other	European descent	47% Caucasian 19% Asian 10% African 15% Hispanics 8% Indian 1% Other

further interpretation and instructional follow-up recommendation.<sup>26</sup>

Collectively, the recent and upcoming advancements have expanded the utility of OCT, making it an important ancillary test for clinicians. With its multimodal imaging, OCT can offer more than one diagnostic image to help primary eyecare clinicians to understand more about the underlying pathogenesis, disease progression and treatment responses to further improve patient care. ■

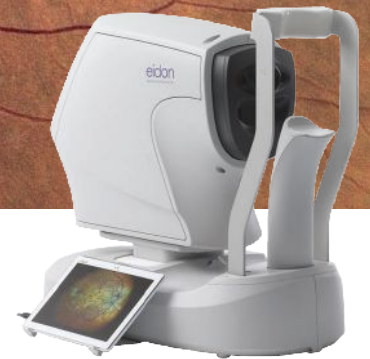1. Majcher C, Cobbina S. Take OCT to the next level. *RevOptom.* 2021;158(9):32-40.
2. Levison A and Ehlers J. "Widefield oct: current and future applications. *Retinal Physician*, April 1, 2014. [www.retinalphysician.com/issues/2014/april-2014/widefield-oct-current-and-future-applications](http://www.retinalphysician.com/issues/2014/april-2014/widefield-oct-current-and-future-applications). Accessed July 15, 2022.
3. Huang D, Swanson EA, Lin CP, et al. Optical coherence tomography. *Science*. 1991;254(5035):1178-81.
4. Mazzarella J, Cole J. The anatomy of an OCT scan. *RevOptom.* 2015;152(9):58-68.
5. Sampson DM, Dubis AM, Chen FK, Zawadzki RJ, Sampson DD. Towards standardizing retinal optical coherence tomography angiography: a review. *Light Sci Appl.* 2022;11(1):63.
6. Lo C, Vuong LN, Micieli JA. Recent advances and future directions on the use of optical coherence tomography in neuro-ophthalmology. *Taiwan J Ophthalmol.* 2021;11(1):3-15.
7. Salsberg K. Swept-source and multimodal OCT technologies offer clinical advantages. *Optometry Times*. June 12, 2020. [www.optometrytimes.com/view/swept-source-and-multimodal-oct-technologies-offer-clinical-advantages](http://www.optometrytimes.com/view/swept-source-and-multimodal-oct-technologies-offer-clinical-advantages). Accessed July 15, 2022.
8. Yan Y, Liao YJ. Updates on ophthalmic imaging features of optic disc drusen, papilledema and optic disc edema. *Curr Opin Neurol.* 2021;34(1):108-15.
9. Yiu G, Chiu SJ, Petrou PA, et al. Relationship of central choroidal thickness with age-related macular degeneration status. *Am J Ophthalmol.* 2015;159(4):617-26.
10. Mickles C. What OCT can offer your specialty lens fits. *RevOptom.* 2020;157(3):80-6.

11. Luo M, Li Y, Zhou Y. Advances and current clinical applications of anterior segment optical coherence tomography angiography. *Front Med (Lausanne)*. 2021;8:721442.
12. Siggel R, Spital C, Lentzsch A, Liakopoulos S. Optical coherence tomography angiography for the detection of macular neovascularization-comparison of *en face* vs. cross-sectional view Eye (Lond). January 6, 2022. [Epub ahead of print].
13. Song A, Johnson N, Ayala A, Thompson AC. Optical coherence tomography in patients with Alzheimer's disease: what can it tell us? *Eye Brain*. 2021;13:1-20.
14. Kim JI, Kang BH. Decreased retinal thickness in patients with Alzheimer's disease is correlated with disease severity. *PLoS One*. 2019;14(11):e0224180.
15. Cunha JP, Proença R, Dias-Santos A, et al. OCT in Alzheimer's disease: thinning of the RNFL and superior hemiretina. *Graefes Arch Clin Exp Ophthalmol.* 2017;255(9):1827-35.
16. Carl Zeiss Meditec. Cirrus HD-OCT. [www.zeiss.com/meditec/en-us/products](http://www.zeiss.com/meditec/en-us/products). Accessed July 15, 2022.
17. Topcon Healthcare. 3D OCT-2000 spectral domain OCT. [www.topconmedical.com/products/3doct2000.htm](http://www.topconmedical.com/products/3doct2000.htm). Accessed July 15, 2022.
18. Visionix. iVue80 Optovue. [www.visionix.com/us/](http://www.visionix.com/us/). Accessed July 15, 2022.
19. Heidelberg Engineering H. Spectralis: Multi-modality diagnostic imaging of the eye. [www.heidelbergengineering.com/us/products/spectralis-models/](http://www.heidelbergengineering.com/us/products/spectralis-models/). Accessed July 15, 2022.
20. Rodman J. Is OCT-A right for my practice? *RevOptom.* 2020;157(9):50-6.
21. Ghasemi Falavarjani K, Tian JJ, Akil H, et al. Swept-source optical coherence tomography angiography of the optic disk in optic neuropathy. *Retina*. 2016;36 Suppl 1:S168-77.
22. PR Newswire. Global industry analysts predicts the world optical coherence tomography (oct) for ophthalmology market to reach \$754.4 million by 2026. March 1, 2022. [www.prnewswire.com/news-releases/global-industry-analysts-predicts-the-world-optical-coherence-tomography-oct-for-ophthalmology-market-to-reach-754-4-million-by-2026-301360428.html](http://www.prnewswire.com/news-releases/global-industry-analysts-predicts-the-world-optical-coherence-tomography-oct-for-ophthalmology-market-to-reach-754-4-million-by-2026-301360428.html). Accessed July 1, 2022.
23. Puyo L, David C, Saad R, et al. Laser Doppler holography of the anterior segment for blood flow imaging, eye tracking, and transparency assessment. *Biomed Opt Express*. 2021;12(7):4478-95.
24. Puyo L, David C, Saad R, et al. Laser Doppler holography of the anterior segment for blood flow imaging, eye tracking, and transparency assessment. *Biomed Opt Express*. 2021;12(7):4478-95.
25. Monroy GL, Won J, Spillman DR, et al. Clinical translation of handheld optical coherence tomography: practical considerations and recent advancements. *J Biomed Opt.* 2017;22(12):1-30.
26. Notal Vision. Notal Home OCT. [notalvision.com/technology/home-oct](http://notalvision.com/technology/home-oct). Accessed July 15, 2022.



Visit VEW  
Booth F5043  
for show  
specials!

# 200° of iCare



## iCare EIDON

Eidon Ultra-Widefield:  
200 degrees of **imaging**

iCare's unique combination of sharpness and TrueColor offers now an even wider view of the retina. From 120° with a single shot, up to 200°, helps detect subtle signs of pathologies in the periphery using a mosaic function.\*

- + Rich in details from center to periphery
- + Imaging through media opacities

\* Ultra-Widefield imaging is available with the optional EIDON UWF Module.



JUST LAUNCHED

## iCare HOME2

24-hour at home  
**tonometry**

- + **NEW!** Supine, reclined & seated positions
- + **NEW!** New smart light guide for easy positioning
- + **NEW!** Interactive display screen
- + **NEW!** Comprehensive IOP reports



For more information, scan,  
call 888.422.7313, or email  
infoUSA@icare-world.com  
[www.icare-world.com/USA](http://www.icare-world.com/USA)

For better perception **icare**

# TELEMEDICINE: WHAT WE'VE LEARNED AND WHAT'S TO COME

Reflecting on the present and preparing for the future of virtual eye care.



BY MARTA O'GRADY  
NEW YORK CITY

**S**huttered offices and international pandemic guidelines curtailed in-person patient care in 2020 but also led to demonstrations of sheer tenacity. Despite the challenges, loss and unsteadiness that COVID-19 brought into all of our lives, we would be remiss not to reflect on the opportunities, invention and hopefully lasting patient care innovation that transpired from the events of the last several years. Between social distancing, periods of mandated quarantine and general caution to remain at home, many patients found great utility in virtual communications with practitioners, and doctors were relieved to keep in touch with their patients' needs.

Immediately upon recognizing the crisis to come, the Centers for Disease Control and Prevention officially began recommending telemedicine in lieu of clinic visits for patients who tested positive for the virus in anticipation of extended periods of social distancing. As a result, practitioners

had to pivot their clinical operations—a process that is, in many ways, ongoing.<sup>1</sup> Telemedicine is defined by The National Institutes of Health as “the use of electronic information and communication technologies to provide and support healthcare when distance separates the participants.”<sup>2</sup> The rapidly evolving modality of care has opened the door to various new doctor-patient interactions

For example, optometrists became able to advise patients on an incipient chalazion from their own home, diagnose follicular conjunctivitis via video conferencing or review posterior blepharitis treatment algorithms from a quiet, empty office. As practitioners, we all learned to leave our comfort zone by being forced to conduct virtual scheduling and examinations and bill for socially distant patient appointments.

After nearly three years since this nationwide shift towards telehealth, we have benefited from, been challenged by and, eventually, duly accepted this new mode of practice. Here, we will review some lessons worth considering as virtual eye care continues to evolve.

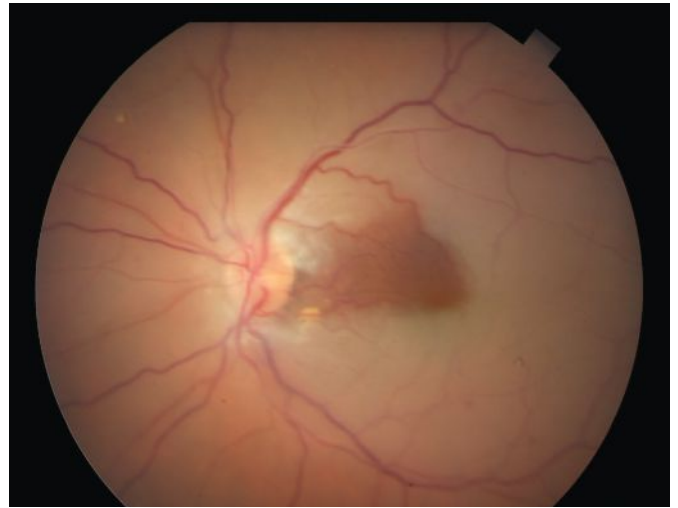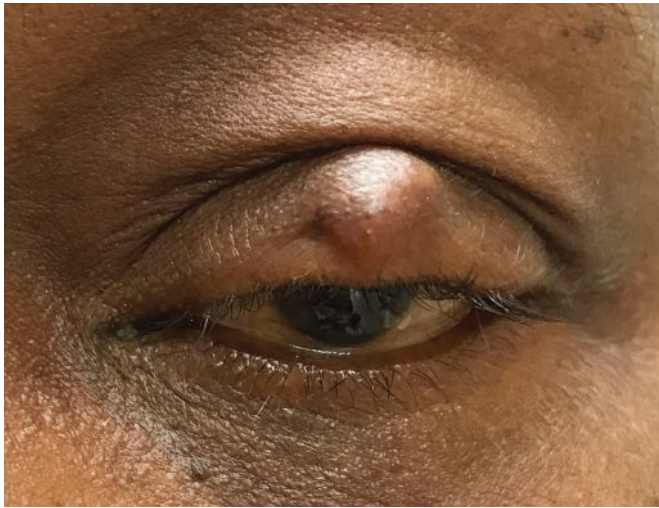## Improving Access to Eye Care

For both patients and doctors, teleoptometry afforded an unparalleled opportunity for patient access. Removing the need for travel allowed more patients to receive direct and expedient access to needed eye care, especially for those in rural locations, with mobility challenges, cost barriers or those who rely on public transportation. During the pandemic, and still now, this was especially vital for patients who were under quarantine, those too nervous to travel and those with comorbidities that more strictly required social distancing. For some physicians, another advantage of this upsurge in telemedicine use was that it helped decrease late and canceled appointments, as well as decreased the number of patients who delayed care, which would potentially worsen their ocular condition.

During this time, it was relieving for practitioners to know that they could still be in touch with their patients and could direct any emergent care, and patients knew that their doctors were never far. One successful example is Northwell Health Physician Partners Ophthalmology Faculty

### About the author

**Dr. O'Grady** recently began a new role as a division administrative director in the Department of Surgery at the University of Colorado School of Medicine. Prior to the move to Denver, Dr. O'Grady practiced at Northwell Health in New York City. She is a Fellow of the American Academy of Optometry and chair of the Membership Committee. She has no financial disclosures.



**A chalazion (at left) that is easily observable via a video consult is amenable to optometric consult using telemedicine services. By contrast, a central retinal artery occlusion with cilioretinal sparing (at right) is one example of a condition where the presumable complaint of vision loss would necessitate an in-office visit for treatment and diagnosis.**

Practice at Manhattan Eye, Ear and Throat Hospital, which allowed for virtual patient care even during the height of the pandemic and in the epicenter of New York City.

Travel aside, virtual visits also removed any potential discomfort during an eye examination from lid eversion, intraocular pressure (IOP) checks or the lasting effects of dilation (not to mention scleral depression or other in-office procedures). The downside, of course, is that these tests, which provide vital information, were not completed. The trade-off for comfort was sometimes bare-bones testing.

Remote telehealth visits at least allowed for basic triage and treatment during a time when access to advanced diagnostics like optical coherence tomography (OCT) or visual field testing was limited. Using even rudimentary examination information, practitioners were able to decide which patients could be managed from afar, or which required in-person follow-up.

Although virtual appointments, for many doctors, vary fiscally in reimbursement from carrier to carrier, it was a massive improvement on an empty schedule and allowed access to funding in order to continue providing care and keep office lights on—literally. Virtual visits also enabled

practices to expand available office hours, which made it so that practitioners could open schedules from the comfort of satellite locations.

### Pitfalls of Technology

New workflows are rarely introduced into a practice without challenges. For patients, teleoptometry requires both reliable internet access and hardware, whether that be a phone, smartphone, tablet or computer. Some existing desktop computers require cameras and/or microphone attachments, in addition to the software needed to sync these devices. Training for both staff and doctors is also a necessity whenever new equipment is added to the office.

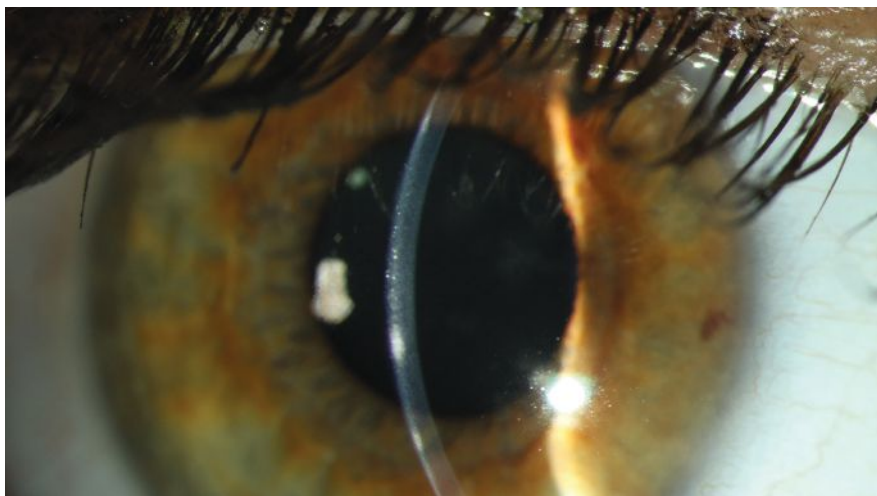
Regarding access to technology, patients over the age of 50 are often less likely to have access to video conferencing capabilities.<sup>3</sup> This is especially pertinent for optometry, as studies have shown that the largest segment of our patient base is between 50 and 64 years old.<sup>4</sup> Luckily, as social distancing protocols have loosened in a majority of the country, caregivers or friends have a greater ability than they did two years ago to assist patients with their telehealth technology challenges at home.

Another challenge is that, presbyopia aside, many eyecare patients may

not have optimal vision to operate a smartphone with small buttons and icons. In fact, a 2021 American Medical Association (AMA) Telehealth Survey Report, which surveyed over 2,000 ophthalmologists from November through December 2021, revealed that 54% of practitioners cared for patients who experienced technological challenges.<sup>5</sup> Notably, 18% of physician respondents reported that they themselves have had to navigate difficulties with telehealth/technology-related workflows and 22% with integrating this new modality of care with electronic medical records (EMR).

If your practice can afford to hire an IT assistant, they could be an asset by ensuring the staff is well-versed in the new equipment, and they can also be a resource for questions or concerns that arise after your team dives into the telehealth workflow. In addition, many academic medical centers offer free online training videos on various topics—*e.g.*, telehealth billing, ethics and risk management, as well as HIPAA compliance—that can serve as an adjunctive method of staff education.

These hurdles on both the patient and practitioner sides—mainly regarding technology access and staff and patient training and education—need to be addressed to keep up with



**This photo shows a patient with a corneal infiltrate, another condition that would not be treatable via telehealth.**

the increasing demand for telehealth services. The AMA survey results showed that 85% of respondents reported using telehealth and 93% of those physicians said they were conducting live, interactive video visits. In order to get those numbers up to 100%, we need to continue to find ways to ensure optometrists can offer effective, universally accessible virtual care to every patient regardless of technological skill. If patients do come to the clinic for occasional in-person appointments, you could take a minute to show them how they can log in for a virtual visit (*i.e.*, via a video conferencing website) and confirm that they know how to do it.

### What About Reimbursement?

Let's talk money. Under the 1135 Centers for Medicare and Medicaid Services (CMS) Waiver Expansion of 2020, many patients, at least at the height of the pandemic, were waived cost-sharing for telehealth visits paid for by federal healthcare programs.<sup>6</sup> To boot, patient copays were often waived up front, which helped during what many experienced as a financially trying time.<sup>7</sup> From a patient standpoint, this helped improve access to care by removing the requirement of an initial cost. From the practitioner's standpoint, while helpful, reimbursement became more of a challenge.

From the previously cited AMA survey, lack of insurer coverage of telehealth services afflicted 76% of respondents and 64% cited low or no reimbursement.<sup>5</sup> Complicating factors were that telemedicine rules and regulations varied both by state and by individual contracted insurance companies, as well as the mode and technology by which it was performed (*i.e.*, voice vs. video). Telehealth Current Procedural Terminology (CPT) codes are based on how care is delivered, which could either be via video calls face-to-face or through technologies that collect and store images to transmit and interpret later (*i.e.*, sending a photo) or simply audio communications. Modifiers that designate the location of the practitioner from 'in-office' to 'virtual' are important, as they are reimbursed differently. The American Academy of Ophthalmology created a succinct coding update summarizing which CPT codes were reimbursable, as well as how to accurately specify a telephonic versus video visit, out-of-office locations, modifier applications and hybrid examination.

Additionally, the CARES Act, effective from March 2020, mandated that telehealth visits be paid for at the same rate as in-person visits for those insured by Medicare. The majority of insurance plans followed CMS recommendations following the 1135

Waiver expansion and the CARES Act.<sup>8</sup> However, as not all insurance plans followed CMS/Medicare billing guidelines, there was a variety of reimbursing rates on the same telemedicine and virtual care codes.

To complicate matters further, the billing requirements for telemedicine can vary within the same payer by individual insurance plan. This saddles the practitioners' office with the burden of determining the specific billing requirements for each contracted insurance plan, and verifying the patient's coverage and benefits.

Luckily, the Telehealth Extension and Evaluation Act was introduced in April 2022, which extends Medicare-enabled telehealth capabilities for two years following the COVID-19 pandemic including continued reimbursement in rural locations, limitations on payments for tests and equipment and remote access to prescriptions.<sup>9</sup> This is all to say that although the reimbursement was a complicated algorithm of regulations and rules, for many it was still income-generating and additive for office function.

Note that it is critically important to stay up to date on your state's reimbursement policies, as these rules are constantly evolving and have already since the beginning of the pandemic.

### Preparing for Telehealth's Future

As a generalization, it could be said that both patients and practitioners are expecting telemedicine to continue as a modality of care, at least in some capacity. Many insurance companies also expect demand for virtual care to remain high post-pandemic. According to Cigna, prior to the pandemic, virtual care made up less than 1% of visits for many subspecialties. At the time of this article, Cigna reported that 25% of visits were completed virtually.<sup>10</sup> This shift is expected to continue, with a recent Evernorth survey finding that 75% of Americans see a future that includes obtaining health care from home.<sup>11</sup> Thus, looking forward, it's safe to say that telehealth is likely here to stay. The American Optometric As-

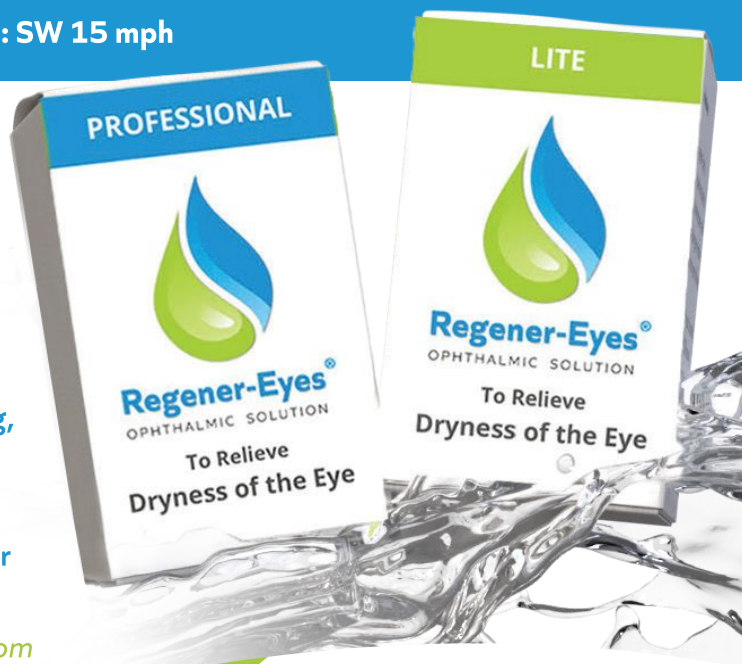

Bike Trail, Cincinnati | Pollen Count: 11.8 ppm<sup>°</sup> | Wind: SW 15 mph

## **Perfect Conditions to Recommend Regener-Eyes<sup>®</sup>**

When the air swirls with pollen and the wind is whipping, it's the perfect time to recommend Regener-Eyes. It's a first-in-class hypotonic, natural, and preservative-free ophthalmic drop To Relieve Dryness of the Eye. Let your patients pedal away from pollen with Regener-Eyes.

Call (877) 206-0706 to register or visit [regenereyes.com](http://regenereyes.com)



The Power of Science, in the Ease of an Eye Drop™

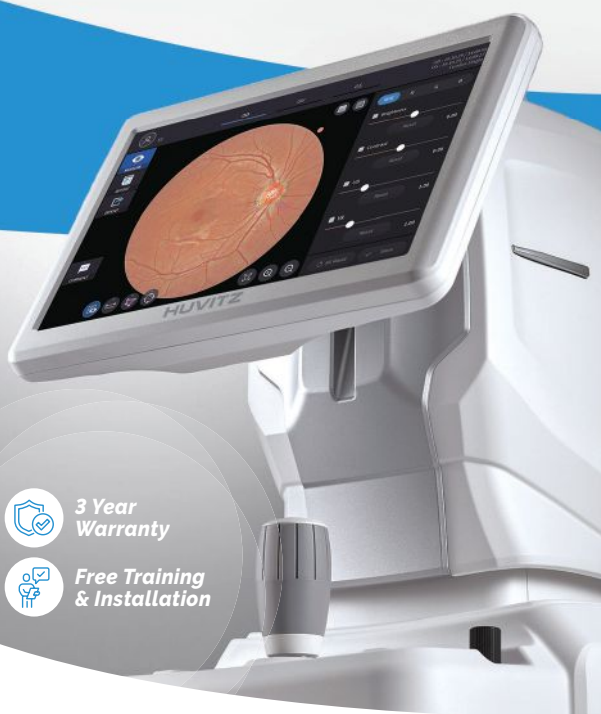

**Regener-Eyes<sup>®</sup>**  
OPHTHALMIC SOLUTION

# High quality, automatic digital retinal imaging.

Experience the  
**HFC-1 Non-Mydriatic  
Fundus Camera.**

- Quick and stable auto tracking and auto shooting
- Adjust fixation target position
- Enhanced Visualization Technology captures fine pathological variation
- Full color digital image acquisition



3 Year  
Warranty



Free Training  
& Installation

**COBURN  
TECHNOLOGIES**

1-800-COBURN-1  
See our full line of products  
at [coburntechnologies.com](http://coburntechnologies.com)

**VISION  
EXPO**

BOOTH F6075

## Feature TELEHEALTH

sociation's 2020 policy statement echoes this position and further posits that, as doctors of optometry, we must take an active and proactive role in the evolution of telemedicine technology and use.<sup>12</sup>

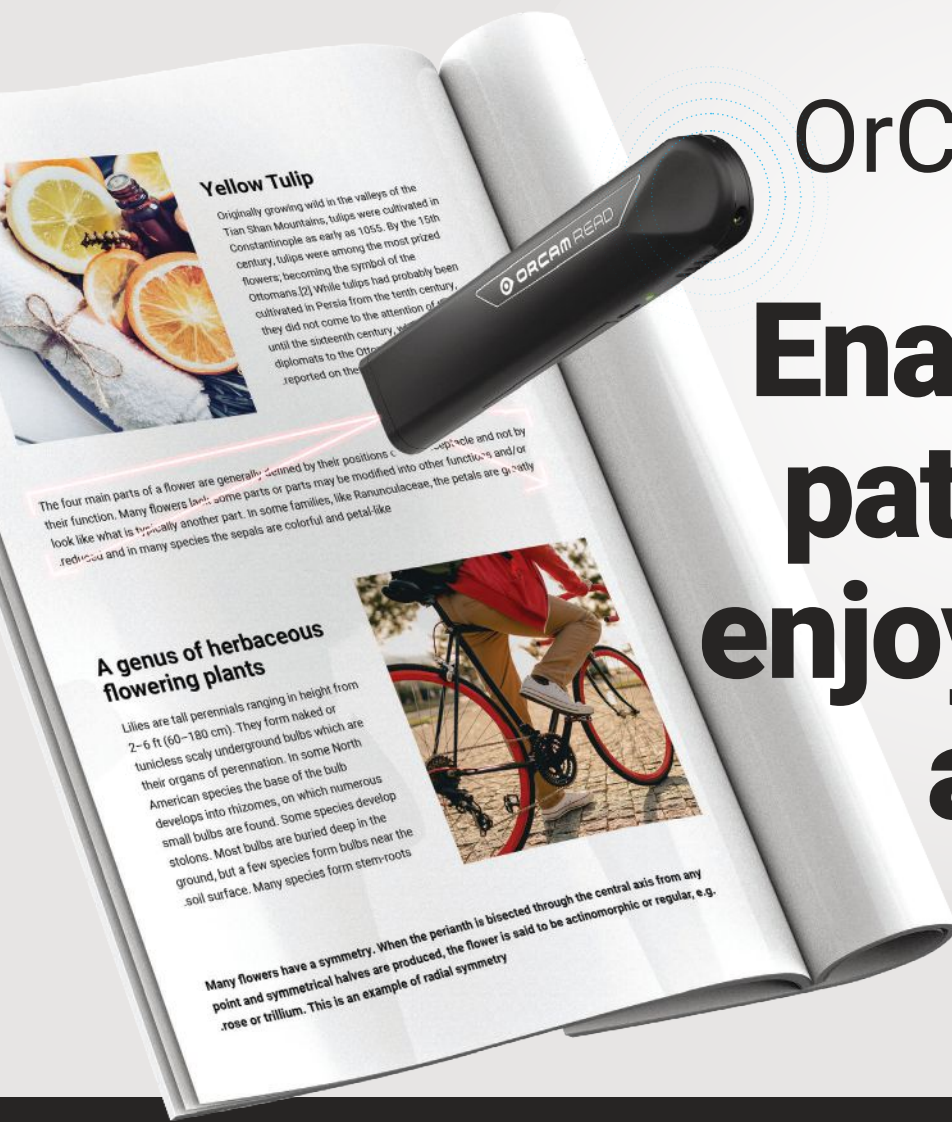Here are four factors to consider for the future of virtual eye care.

**1. New ways to access advanced testing for higher-level diagnosis are being developed.** With regular iPhone and Android photo software updates, as well as a rapidly changing landscape of smartphone camera hardware, there may be improved near-term focus on smartphone cameras or attachments for self-photography for anterior segment pathology documentation.

There are already many applications that allow for patients to check both near and distance vision, as well as color vision, near point convergence and diplopia. Opportunities down the road involve remotely controlled slit-lamp devices, smartphone-driven nonmydriatic fundus cameras and remote-operated OCT machines in public areas. A few already approved by the FDA include two artificial intelligence designs: IDx-DR (Digital Diagnostics) and EyeArt (Eyenuk) for detecting diabetic retinopathy, ForesceHome (NotalVision), an at-home neovascular age-related macular degeneration (AMD) monitoring device and program, and Alleye (Oculocare Medical), a free mobile app for self-monitoring AMD progression. Comparing results using self-monitored technology, as opposed to during an office visit, should be completed for integrity in remote testing, but certainly presents an opportunity for advanced diagnostics. For example, home tonometry has seen exciting innovation in recent years as a tool for remote glaucoma care. With these self-monitoring devices, such as the iCare Home tonometer, doctors are able to more closely observe IOP patterns through more frequent testing, which would otherwise only be performed sporadically during in-person visits.

To address the deficiency of remote high-level testing, some larger hospitals are test-driving mobile units with advanced diagnostics (examples include Rutgers University and Duke Ophthalmology). These modified vans have been equipped to screen patients on various machines, including autorefractors, nonmydriatic fundus cameras and OCTs. It is important to recognize and to remind our patients that these remote screening technologies are considered adjunctive to telemedicine treatment and do not replace services performed by a doctor.

**2. There is a learning curve to new technology.** Incorporating new devices or software efficiently into your practice flow involves consideration of things like schedule rearrangement, office-wide EMR training and designation of hardware devices for data storage. Training technicians and staff to input virtual intake information into the EMR over a secure line and scheduling the practitioner to complete a virtual examination is paramount. Thanks to the capabilities of telehealth, this could be done before, during or after



# OrCam Read

## Enable your patients to enjoy reading again



### Full Page Capture

Unlike all other devices which require word-by-word scanning.



### Smart Reading

Ask the device to read only the text that interests you.



### Easy to Use

An intuitive device - simply point and click to start reading.

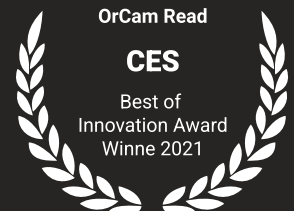
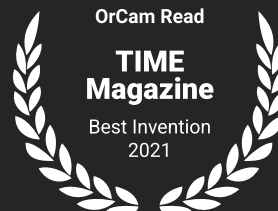
### No Connectivity Required

Offline operation - for use anywhere.



Contact for more information or a demonstration:  
[eyedoc@orcaml.com](mailto:eyedoc@orcaml.com)



hours. Training of advanced clinical providers and special testing professionals to augment the practitioner's schedule would extend the telehealth reach.

A practice may find that they need to build a schedule that allows for flexibility to balance in-person and virtual slots and potentially open up appointments after hours to catch up on patient backlogs. Empowering patients to complete remote testing (e.g., self-checking vision, completing an Amsler grid test, compiling all complaints) prior to the start of their appointment will also help with time efficiency.

**3. Legislators must support and advocate for fair reimbursement.**

There is an increasing call for continuing billing flexibilities afforded by the CARES Act, on a permanent basis. Aside from the relaxation of regulatory restrictions afforded by the Telehealth Extension and Evaluation Act, optometrists need continued reimbursement algorithms that align with in-person care and allow telehealth visits to become an extension of in-person visits. In addition, leniency on interstate

**Seventy-five percent of Americans see a future that includes obtaining health care from home.**

licensure, or at the very least easily understandable policies and compacts, will be integral for patient access. The US Department of Health and Human Services agrees with this notion, as its website states that interstate compacts would simplify cross-state telehealth by expediting the licensing process or allowing members to practice under a single multistate license.<sup>13</sup>

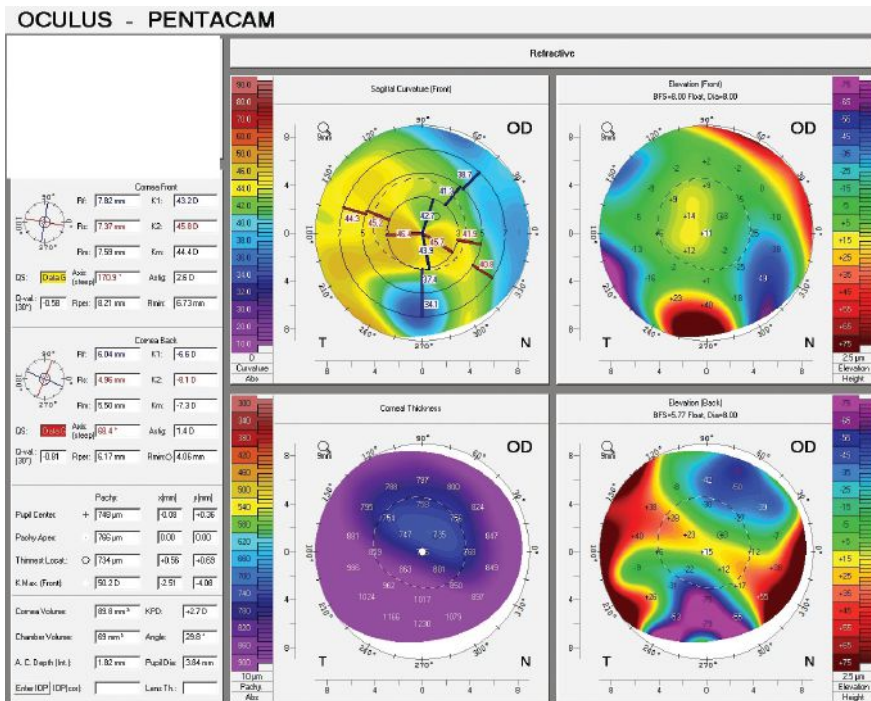
**4. The range of potential applications for telehealth is broad.** As optometry historically moves towards more systemic treatment and collaborative work with other medical subspecialties, virtual visits may accelerate this pursuit by allowing us to virtually consult in emergency departments without leaving our offices as well as collaborate with primary care practitioners, internists, nutritionists and neurologists. In some ways, telehealth is

virtually opening the door for us to add value in innumerable medical spaces, in addition to expanding our ability to see our existing patient base.

In sum, telehealth, in its various forms, is here to stay. We may need to adapt our practices, embrace new technology and re-imagine care models as we once knew them. It will be important to continually analyze and compare remote levels of care to in-person visits to ensure that we are providing the same standard of care.


This rapid evolution of virtual healthcare will afford optometrists new ways to offer high-quality care to innumerable patients—one of the few positive pandemic sequelae. ■

- Centers for Disease Control and Prevention. Get your clinic ready for coronavirus disease 2019 (COVID-19). Updated February 25, 2021. [www.cdc.gov/coronavirus/2019-ncov/hcp/clinic-preparedness.html](http://www.cdc.gov/coronavirus/2019-ncov/hcp/clinic-preparedness.html). Accessed April 18, 2022.
- Medicaid.gov. Telemedicine. 2020. [www.medicaid.gov/medicaid/benefits/telemedicine/index.html](http://www.medicaid.gov/medicaid/benefits/telemedicine/index.html). Accessed April 18, 2022.
- Pasquinelli MM, Patel D, Nguyen R, et al. Age-based disparities in telehealth use in an urban, underserved population in cancer and pulmonary clinics: A need for policy change. *J Am Assoc Nurse Pract.* 2022;34(5):731-37.
- Statista. Share of Americans who visited an optometrist in the last 12 months in 2018, by age. Published October 24, 2018. [www.statista.com/statistics/228528/people-who-used-an-eye-examiner-optometrist-usa](https://www.statista.com/statistics/228528/people-who-used-an-eye-examiner-optometrist-usa). Accessed April 20, 2022.
- American Medical Association. 2021 Telehealth Survey Report. [www.ama-assn.org/system/files/telehealth-survey-report.pdf](http://www.ama-assn.org/system/files/telehealth-survey-report.pdf). Accessed April 20, 2022.
- Centers for Medicare and Medicaid Services. 1135 Waiver. <https://www.cms.gov/Medicare/Provider-Enrollment-and-Certification/SurveyCertEmergPrep/1135-Waivers>. Accessed May 26, 2022.
- AHIP. Health Insurance Providers Respond to Coronavirus (COVID-19). [www.ahip.org/news/articles/health-insurance-providers-respond-to-coronavirus-covid-19](http://www.ahip.org/news/articles/health-insurance-providers-respond-to-coronavirus-covid-19). Accessed June 7, 2022.
- AHIP. Health Insurance Providers Respond to Coronavirus (COVID-19). Published April 27, 2021. [www.ahip.org/news/articles/health-insurance-providers-respond-to-coronavirus-covid-19](http://www.ahip.org/news/articles/health-insurance-providers-respond-to-coronavirus-covid-19). Accessed August 12, 2022.
- United States Congress. H.R.7573 - Telehealth Extension and Evaluation Act. [www.congress.gov/bills/117/congress/117th-congress/house-bill/7573/text?r=1&s=1](http://www.congress.gov/bills/117/congress/117th-congress/house-bill/7573/text?r=1&s=1). Accessed June 7, 2022.
- Cigna. The Four Biggest Health Care Trends of 2022 and How They Impact America's Employers. [newsroom.cigna.com/4-biggest-health-care-trends-2022-impact-on-employers](https://newsroom.cigna.com/4-biggest-health-care-trends-2022-impact-on-employers). Accessed June 29, 2022.
- Evernorth. Virtual Care and Digital Health Are Here to Stay. Published May 4, 2021. [www.evernorth.com/articles/virtual-care-and-digital-health-are-here-to-stay](http://www.evernorth.com/articles/virtual-care-and-digital-health-are-here-to-stay). Accessed June 1, 2022.
- American Optometric Association. AOA spearheads conditions for evolution of telemedicine technology. Published October 22, 2020. [www.aoa.org/news/advocacy/patient-protection/telemedicine-policy?ss=oy](http://www.aoa.org/news/advocacy/patient-protection/telemedicine-policy?ss=oy). Accessed August 12, 2022.
- Department of Health and Human Services. Telehealth Licensure requirements and interstate compacts. Updated March 25, 2022. [telehealth.hhs.gov/providers/policy-changes-during-the-covid-19-public-health-emergency/telehealth-licensing-requirements-and-interstate-compacts](https://telehealth.hhs.gov/providers/policy-changes-during-the-covid-19-public-health-emergency/telehealth-licensing-requirements-and-interstate-compacts). Accessed August 12, 2022.



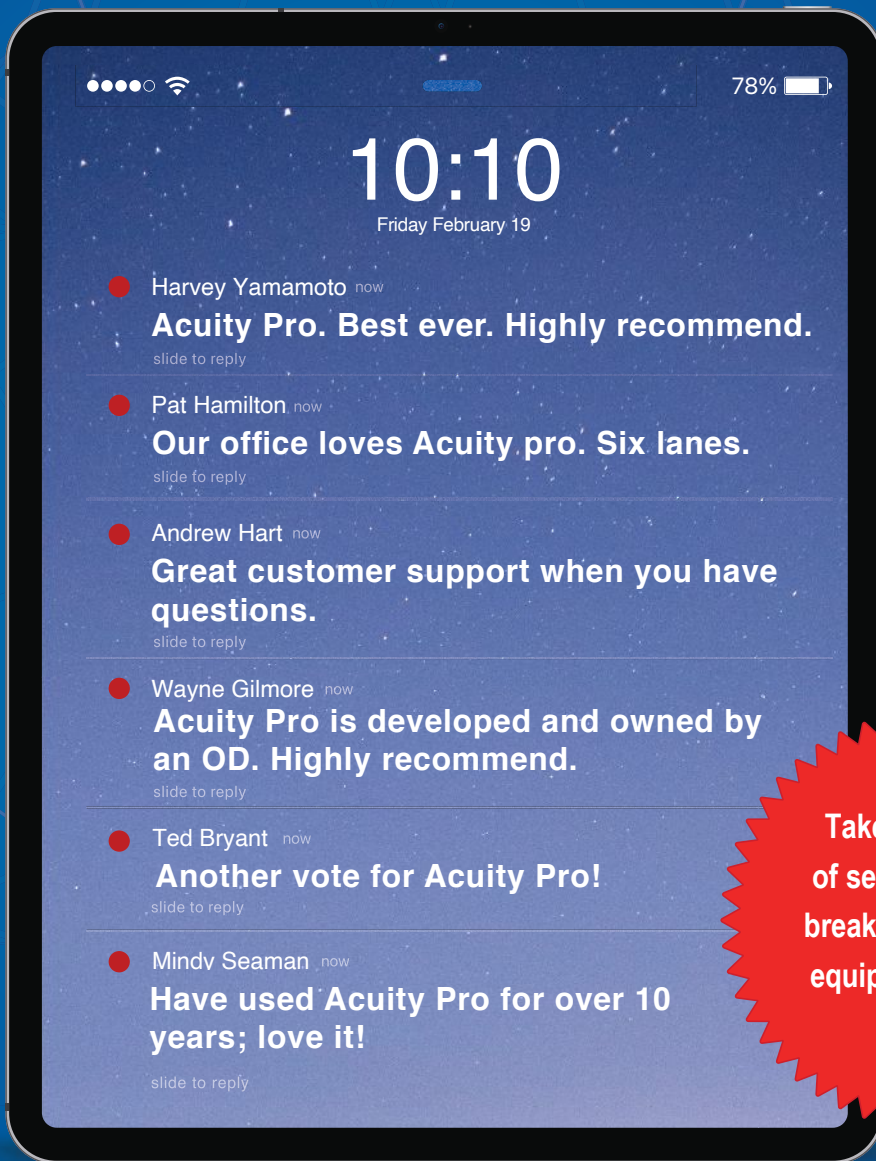
**Pentacam of a post-LASIK inferior Salzmann's nodule, which can only be diagnosed virtually if topography is able to be completed remotely, such as via a mobile testing van.**





Over 20 years of 👍 and ❤️!

I'm looking for a reputable solution for a digital acuity system – any suggestions?



Take advantage of section 179 tax break on new/used equipment by end of year!

Disaster proof by design | [acuitypro.com](http://acuitypro.com) / 580-243-1301

Sloan / Snellen / Numbers / Contrast / ETDRS / White On Black Option / Randomize Custom Remote / Marco Integration / Free Support / No Annual Fees

# IS ARTIFICIAL INTELLIGENCE SMART ENOUGH YET TO HELP US?

Learn the current state of this technology and what might be coming soon to support optometry's efforts to fight diabetic retinopathy.

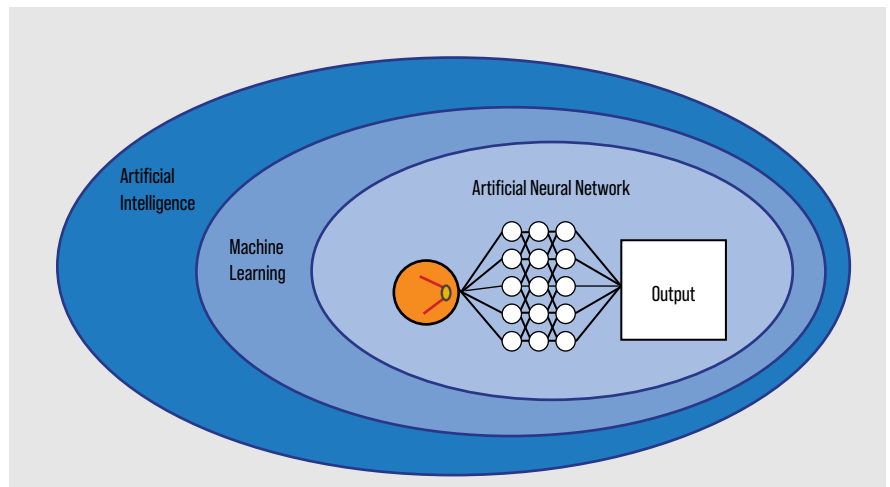


BY LAUREN WHITE, OD  
ELKINS PARK, PA

There are 37.5 million diabetic Americans, and less than half have historically received dilated diabetic eye exams at recommended intervals, leaving the majority without proper care and surveillance.<sup>1-7</sup> Although there are many ideas for how to fill this void, one promising and emerging solution to increase access to diabetic retinopathy (DR) screening is artificial intelligence (AI).<sup>6-8</sup> Will such systems replace optometrists and ophthalmologists or merely augment our capabilities? At which level of care are they the most useful? Let's look at where things currently stand.

## Background

AI is defined by the National Artificial Intelligence Act of 2020 as “a machine-based system that can for a given set of human-defined objectives, make predictions, recommendations or decisions influencing real or virtual environments.”<sup>9</sup> Machine learning is a subset of AI that designs and trains software algorithms to learn from and then make predictions, recommenda-



A depiction of essential AI vocabulary.

tions or decisions on data. Machine learning can incorporate artificial neural networks. In this type of system, a digital input, such as a retinal image, is presented to the first layer of neurons, or nodes. The input in each layer of nodes is processed and converted into outputs, which are then transmitted to the next layer for further processing.

During the algorithm training, the final output is compared with a reference standard to determine if further modification and training is required. After training, the algorithm

is validated with another dataset to verify its ability to produce an accurate outcome.<sup>10</sup> Machine learning algorithms differ in the production time, size of training data, learning method and structure of the artificial neural network and goals of the final output resulting in a wide variety of potential designs.<sup>11</sup>

## AI Today

When deployed clinically, these algorithms can be applied as *assistive AI* or *autonomous AI*. Assistive AI can

About  
the author

Dr. White recently completed her residency in ocular disease at the Dayton VA Medical Center. She is joining the faculty at Salus University's Pennsylvania College of Optometry this fall. She has no financial interests to disclose.

be used in conjunction with a provider to aid in diagnosis and disease severity grading. Autonomous AI works independently of providers to diagnose disease. To date, autonomous AI has two primary ways of detecting DR: detector-based design and deep learning. As with clinicians, detector-based designs identify abnormalities based on various biomarkers indicative of DR, including microaneurysms, hemorrhages, venous anomalies, exudates and neovascularization. Deep learning is often referred to as a black box system because it is less clear how the algorithm learns to identify disease.<sup>13</sup>

There are two AI devices for DR currently available for clinical use in the United States: IDx-Dr by Digital Diagnostics and EyeArt by Eyenuk. Both technologies have been evaluated for their ability to detect DR by quantifying imageability, sensitivity and specificity of their performance and comparing them with human-interpreted images.<sup>13</sup>

**IDx-DR (Digital Diagnostics).** This instrument was FDA *de novo* cleared in 2018 as the first autonomous AI system in medicine.<sup>14</sup> In the IDx-DR pivotal trial, among 900 patients in primary care clinics were evaluated for more-than-mild DR and/or center-involved diabetic macular edema (DME). It had a sensitivity of 87.2% and a specificity of 90.7% when compared with the Wisconsin Fundus Photograph Reading Center analysis of four widefield stereoscopic dilated fundus photographs, anterior segment photography and a macular optical coherence tomography (OCT) scan. There was an imageability rate of 96.1%, with 23.6% of patients requiring dilation.<sup>15</sup> IDx-DR has been installed in hundreds of point-of-care clinics, including primary care physicians, endocrinology, clinical laboratories and retail clinics, with the goal of early detection and intervention of diabetic eye disease.

In practice, a primary care physician orders testing for patients who are 22 and older, have not been previously diagnosed with DR and are not otherwise contraindicated.

Two non-mydratric retinal images of each eye, one disc-centered and one macula-centered, are captured by an operator with guidance from the system and uploaded to a secure cloud-based system. Using a lesion detection algorithm, the device analyzes the images using biomarker-based AI to detect more-than-mild DR and center-involved DME.

The findings and care recommendations are provided on a one-page report that includes a diagnostic output that aligns with the American Academy of Ophthalmology's Preferred Practice Pattern recommendations. Patients with more-than-mild DR and/or DME are referred to optometrists and ophthalmologists for evaluation and proper management; otherwise, IDx-DR generates a recommendation of continued yearly examination.<sup>16</sup>

**EyeArt AI Eye Screening System (Eyenuk).** The manufacturer received 510(k) clearance by the FDA to market the EyeArt AI system for the detection of more-than-mild DR and vision-threatening DR in August 2020.<sup>17</sup> It has many similarities to the IDx-DR.

EyeArt was validated in a prospective, multicenter pivotal clinical trial with 942 participants that demonstrated the system's ability for detecting more-than-mild DR (sensitivity 95.5% and specificity 87.8%) and vision-

threatening DR (sensitivity 97.0% and specificity 90.1%). This too was compared with the Wisconsin Fundus Photograph Reading Center analysis of four widefield stereoscopic dilated fundus photographs and anterior segment photography. Imageability was reported at 87.6% in undilated fundusoscopic images. In patients who required dilation, the imageability rate was 97.7%.<sup>18</sup>

Much like the IDx-DR, the EyeArt is indicated to evaluate individuals 22 and older who have diabetes and have not been previously diagnosed with more-than-mild DR or other contraindications. Eyenuk is working with a few hundred installations deployed in testing locations, including hospitals, primary care offices, independent diabetic clinics, insurance companies, ophthalmology practices and optometry practices.

After obtaining a disc-centered and a macula-centered photo of each eye, the system generates a report of the diagnosed level of disease and an associated plan, also based on the Academy of Ophthalmology's Preferred Practice Pattern recommendations.

Eyenuk also offers diagnostic services in an asynchronous telehealth setting that combines human readers and AI assessment to detect DR and other ocular diseases.

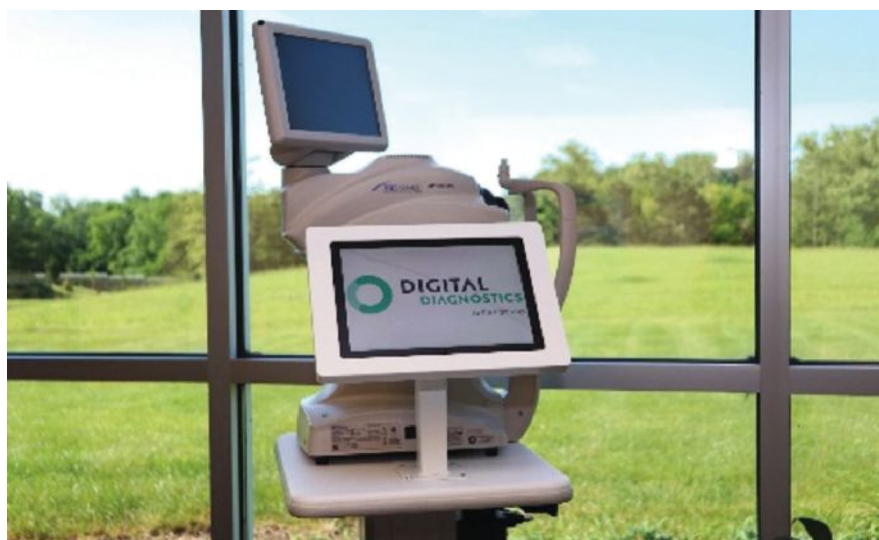

Photo: Digital Diagnostics

**The IDx-DR could be a reliable screening tool that may uncover diabetic eye disease in the primary care office.**

# Permanent Water Surface Contact Lens Technology: Science-Driven Evolution for Outstanding Patient Experience

With technological leaps occurring before our eyes, this is an exciting time to be fitting contact lenses – and to be a contact lens wearer! One of the most remarkable advances has been the arrival and evolution of Alcon’s permanent water surface technology.

The fundamental goal of this technology is to deliver the comfort, vision, and overall experience that patients deserve. Launched in 2013, DAILIES TOTAL1® was a first-of-its-kind product that remains the world’s only daily disposable water gradient lens. Starting with a highly breathable, low water-content, silicone hydrogel (delefilcon A), Alcon’s material science created a water gradient from core to surface, culminating in a 6 µm-thick outer surface composed of nearly 100% water.<sup>1,2</sup> The lubricity of the DAILIES TOTAL1® lens surface remains unchanged over 16-plus hours of wear,<sup>3</sup> resulting in truly outstanding comfort<sup>4\*</sup> and vision.<sup>5\*\*</sup> Known as SmarTears® Technology, the lenses release phosphatidylcholine (PC), an ingredient found naturally in tears that helps stabilize the lipid layer of the tear film.<sup>6,7</sup>

To build on this unique foundation, Alcon set forth to develop a permanent water surface lens to meet the needs of more daily disposable wearers. The result was PRECISION1®, launched in 2019. In contrast to DAILIES TOTAL1®, PRECISION1® lever-

ages a unique material (verofilcon A) and manufacturing process to “step up” from a low water-content core to a microthin outer surface layer that is >80% water.<sup>8</sup> Like DAILIES TOTAL1®, the result is superior lens surface moisture stability.<sup>9†</sup>

PRECISION1® is an outstanding option for daily disposable lens wearers, particularly those who are new to contact lenses and needing a strong start. PRECISION1® wearers report excellent comfort, vision, and handling,<sup>10</sup> effectively addressing the most frequent reasons for new lens wearer dropout.<sup>11</sup>

The addition of TOTAL30® to the permanent water surface lens family in 2021 is excellent news for reusable lens wearers. Monthly replacement lens wearers may experience some discomfort,<sup>12</sup> but they are accustomed to and like this replacement schedule – even when switching lenses, 3 out of 4 patients choose to switch to another monthly replacement lens.<sup>13</sup> With TOTAL30®, patients now have access to

the world’s first and only water gradient monthly replacement lens, which was created to meet the challenges of monthly replacement wear.

TOTAL30®’s development began with lehilcon A, a completely unique, highly breathable silicone hydrogel material. Moving from core to surface, the interpenetrating anchoring zone allows for the creation of a water gradient reaching nearly 100%

**The fundamental goal of Alcon’s permanent water surface technology is to deliver the comfort, vision, and overall experience that patients deserve**

1. Angelini T, Nixon R, Dunn AC, Uruena J, Pruitt J, Sawyer W. Viscoelasticity and mesh-size at the surface of hydrogels characterized with microrheology. *Invest Ophthalmol Vis Sci.* 2013;54:E-abstract 500. 2. Thekveli S, Qui Y, Kapoor Y, Kumi A, Liang W, Pruitt J. Structure-property relationship of delefilcon A lenses. *Cont Lens Anterior Eye.* 2012;35(suppl 1):e14. 3. Maissa C, Martin A, Kramer D, Nelson J, DeCenzo-Verbeten T. Evaluation of the lubricity of DAILIES TOTAL1 contact lenses after wear. Presented at the 2014 American Academy of Optometry Annual Meeting, November 12-15, 2014, Denver, CO. 4. Alcon data on file, 2016. 5. Belda-Salmerón L, Ferrer-Blasco T, Albarrán-Diego C, Madrid-Costa D, Montés-Micó R. Diurnal variations in visual performance for disposable contact lenses. *Optom Vis Sci.* 2013;90:682-690. 6. Greiner JV, Glonek T, Korb DR, Booth R, Leahy CD. Phospholipids in meibomian gland secretion. *Ophthalmic Res.* 1996;28:44-49. 7. Pitt WG, Jack DR, Zhao Y, Nelson JL, Pruitt JD. Transport of phospholipid in silicone hydrogel contact lenses. *J Biomater Sci, Polym Ed.* 2012;23:527-541. 8. In vitro measurement of unworn lenses. Alcon data on file, 2019. 9. Based on in vitro study wherein wettability was measured using the iDDrop System, with lenses soaked in a PBS (phosphate-buffered saline solution) for 16 hours (± 2 hours). Alcon data on file, 2020. 10. Cummings S, Giedd B, Pearson C. Clinical performance of a new daily disposable spherical contact lens. *Optom Vis Sci.* 2019;96:E-abstract 195375. 11. Sulley A, Young G, Hunt C, McCreedy S, Targett MT, Craven R. Retention Rates in New Contact Lens Wearers. *Eye Contact Lens.* 2018;44 Suppl 1:S273-s282. 12. Schnider C. Evaluating monthly replacement CL patient satisfaction. Presented at the 2016 American

## TOTAL30® Contact Lenses Mimic the Dynamic Corneal Surface<sup>19,23-25</sup>




at the outer lens surface.<sup>14‡</sup> Like its daily disposable counterparts, the result is outstanding lens surface moisture stability,<sup>15§</sup> and further, superior lens surface

softness<sup>16§</sup> and lubricity.<sup>17§</sup> Even more impressively, TOTAL30®'s surface chemistry mimics that of the ocular surface (Celligent® Technology),<sup>14,18,19</sup> with polymer nano-fibers that selectively attract water molecules and help resist lipids and bacteria.<sup>18-21‡</sup>

Alcon's permanent water surface lenses – DAILIES TOTAL1®, PRECISION1®, TOTAL30® – are so unique that they make up an exclusive lens category.<sup>22</sup> The growing opportunity to fit patients in these lenses, thanks to the range of replacement schedules in sphere, toric, and multifocal designs, is an exciting one that practitioners cannot ignore. Permanent water surface lenses can help support practice success by giving patients a lens-wearing experience they'll love.

## The Alcon Permanent Water Surface Contact Lens Family



	DAILIES TOTAL1® Water Gradient Technology	PRECISION1® SMARTSURFACE® Technology	TOTAL30® Water Gradient Technology
<b>Replacement</b>	Daily Disposable	Daily Disposable	Monthly Replacement
<b>Sphere</b>	✓	✓	✓
<b>Toric</b>	✓	✓	
<b>Multifocal</b>	✓		
<b>Silicone hydrogel material</b>	delefilcon A	verofilcon A	lehilcon A
<b>Dk/t ≥ 100 (@ -3.00 D)</b>	156 @ -3.00 D	100 @ -3.00 D <sup>§</sup>	154 @ -3.00 D <sup>14</sup>
<b>Outer surface water content</b>	-100% <sup>1,2‡</sup>	>80% <sup>11‡</sup>	-100% <sup>18,19‡</sup>
<b>Additional advanced lens technology</b>	SmarTears®	CLASS 1 UV Absorption <sup>#</sup>	Celligent® Technology CLASS 1 UV Absorption <sup>#</sup> HEVL Filtration <sup>¶</sup>

\* vs. ACUVUE® OASYS 1-Day daily disposable lenses. \*\* p<0.05 vs. clariti® 1-day daily disposable lenses. † p<0.05 vs. 1-Day ACUVUE® Moist, clariti® 1-day, and MyDay® daily disposable lenses. ‡ Based on in vitro studies of unworn lenses. § p<0.05 vs. ACUVUE® Vita, Biofinity®, and ULTRA® monthly replacement lenses. # UV absorbing contact lenses are NOT substitutes for protective UV absorbing eyewear such as UV absorbing goggles or sunglasses because they do not completely cover the eye and surrounding area. The patient should continue to use UV absorbing eyewear as directed. ¶ There is no demonstrated clinical benefit to a 34% reduction in visible light at wavelength below 450 nm. ^ Trademarks are the property of their respective owners.

Academy of Optometry Annual Meeting; Orlando, FL, USA. **13.** GfK Market Intelligence: US CL Fit Tracking 2019. US Fit Market; Alcon data on file. **14.** In vitro analysis of lens oxygen permeability, water content, and surface imaging; Alcon data on file, 2021. **15.** Based on in vitro study wherein wettability was measured using the iDDrop System, with lenses soaked in a PBS (phosphate-buffered saline solution) for 16 hours (± 2 hours). Alcon data on file, 2021. **16.** Laboratory analysis of surface modulus of lehilcon A and commercial lens using atomic force microscope; Alcon data on file, 2020. **17.** Surface lubricity testing of lehilcon A and commercial lenses using nan-tribometer; Alcon data on file, 2020. **18.** Shi X, Cantu-Crouch D, Sharma V, et al. Surface characterization of a silicone hydrogel contact lens having bioinspired 2-methacryloyloxyethyl phosphorylcholine polymer layer in hydrated state. *Colloids Surf B Biointerfaces*. 2021;199:111539. **19.** Ishihara K, Fukazawa K, Sharma V, et al. Antifouling Silicone Hydrogel Contact Lenses with a Bioinspired 2-Methacryloyloxyethyl Phosphorylcholine Polymer Surface. *ACS omega*. 2021;6:7058-7067. **20.** In vitro evaluation of bacterial adherence in commercial lenses; Alcon data on file, 2020. **21.** In vitro evaluation of lipid deposition for lehilcon A and commercial lenses using 3D confocal imaging; Alcon data on file, 2021. **22.** Tyler's Quarterly Soft Contact Lens Parameter Guide. September 2021.

See product instructions for complete wear, care, and safety information.

© 2022 Alcon Inc. US-T30-PRA-2200004

**Alcon**

## The OD's Role Today

Optometrists have a responsibility to understand the capability, benefits and limitations of AI algorithms in diabetic eye care. AI can democratize fundus photo interpretation by leveling the playing field for providers with varying clinical expertise. Increasing access to fundus photography and interpretation also increases access to DR screenings and opportunities for early interventions, especially for patients not currently managed by an eyecare professional. AI does not threaten to replace optometrists; it is a tool to improve patient access and equity.

AI is an emerging technology that is intended to supplement eye care rather than replace a comprehensive eye exam. AI-based DR screenings strive to ensure that the patients most in need—those with more-than-mild DR—have access to care. It does not account for patients who have other retinal diseases, optic nerve disease or ocular comorbidities associated with fluctuating glycemia (e.g. diabetic cataracts and neurotrophic keratitis).

“ AI can democratize fundus photo interpretation by leveling the playing field for providers with varying clinical expertise. ”

Like with most new technologies, there is a level of uncertainty regarding the potential implications and its effect on the future of healthcare. To ensure responsible and efficient implementation of AI for DR detection, conversation should center around current areas of uncertainty: the doctor-patient relationship, referrals and continuum of care, high patient demand and the long-term metrics to indicate positive patient outcomes. These uncertainties are likely to be resolved over time but are a limiting factor in the current confidence of AI. Although there are some clear limitations in the technology today, AI is a tool that could potentially change

**Table 1. Summary of EyeArt Diagnosis, Associated Plan and Study Endpoints<sup>17</sup>**

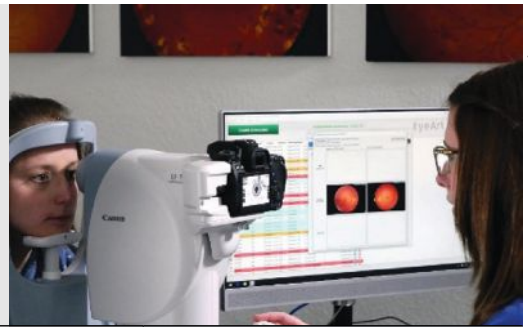


Photo: Evrenk

<b>Diagnosis</b>	More-than-mild DR	Vision-threatening DR
<b>Plan</b>	Refer to an eye professional for evaluation	Refer to an eyecare professional for evaluation (with preferential scheduling if possible)
<b>Sensitivity</b>	95.5%	97.0%
<b>Specificity</b>	87.8%	90.1%
<b>Imageability</b>	87.8% non-mydriatic 97.7% mydriatic (12.6% of the population was dilated when needed)	

recommended exam intervals and other standards of care for diabetic examinations in the future.

AI for DR detection is being implemented in two clinical models: as a screening for healthcare and as an additional clinical tool in eyecare facilities.

One strategy to increase retinal screening is to incorporate it into a point-of-care visit during routinely scheduled diabetic care. Hemoglobin A1c measurements are a screening tool with 60% to 90% adherence among diabetic patients.<sup>3,19</sup> This makes clinics that perform A1c measurements—primary care, endocrinology and clinical laboratories—ideal places to incorporate diabetic eye screening.

Furthermore, those practitioners are incentivized to participate in diabetic eye screenings with the help of clinical quality measurement programs including the Centers for Medicare and Medicaid Services' Merit-Based Incentive Payment System and the National Committee for Quality Assurance's Healthcare Effectiveness Data and Information Set (HEDIS). These quality metrics can be met at the point-of-care using autonomous AI systems that provide quick reports containing findings and recommendations at the point-of-care. This point-of-care model focuses on identifying patients who do

not obtain routine diabetic eye exams to help ensure they receive the eye care required to prevent diabetic-related vision loss.

Point-of-care DR screening will likely increase DR identification and require those patients to seek care with an eyecare professional. Optometrists are essential in this model to build relationships with providers in these other areas of diabetic care, to evaluate the patients flagged at point-of-care and to help medically manage these patients.

EyeArt is used in eyecare settings, where it has been deployed as a screening tool and a confirmation for human diagnosis. AI as a screening tool can be used in high volume clinics or during community screening to allow practitioners to prioritize those with more immediate needs.

It can also be used as a tool for confirmation of DR staging and a method of communicating to retinal specialists. The application of current AI technologies for DR has the potential to increase consistency of diagnosis.<sup>20</sup> AI can also streamline clinical care and add tools for better delivery of diabetic eye care.

## AI Tomorrow

This technology will undoubtedly continue to evolve and expand throughout



# NANO DROPPER

**First we made smaller drops.  
Then we revolutionized  
the standard of care.**

Hundreds of clinics nationwide have improved their standard of care. Are you ready to better serve your patients?

**Use discount code  
ROM10 for 10% off  
your first order!**



The Nanodropper is the only FDA-listed, volume-reducing adaptor for eyedrop bottles designed to deliver precisely the amount of fluid the eye can absorb. Smaller drops have been shown to reduce the waste and cost of in-clinic and Rx formulations while minimizing local and systemic side effects.

[nanodropper.com/ReviewOpt](https://nanodropper.com/ReviewOpt) | [pro@nanodropper.com](mailto:pro@nanodropper.com) | (507) 405-5676

health care and eye care. Looking at the next three to five years, new and upcoming AI technologies can be divided into the hardware in which the algorithm will be incorporated: fundus cameras and OCTs.

**Fundus cameras.** There are dozens of companies designing algorithms that use fundus photography for lesion detection for DR. During the design phase of a multicenter, head-to-head, real-world validation study of seven Automated AI DR screening systems, published in *Diabetes Care*, 23 companies with AI algorithms were invited to participate.<sup>21</sup> The following list of AI algorithms for DR are the ones that were announced to be in FDA trials in 2022 and moving towards FDA clearance:

- AEye (AEye Health) and Aurora (Optomed) are working in collaboration for autonomous detection of more-than-mild DR. In a 2022 press release AEye Health announced the results of the pivotal FDA clinical trial.<sup>22</sup> Using a single photo from a Topcon NW-400 as reference, the system achieved 93% sensitivity, 91.4% specificity and >99% imageability. Using a single photo from a handheld camera (Optomed Aurora), 91.9% sensitivity, 93.6% specificity and >99% imageability was achieved. If FDA cleared, this technology could contribute an AI algorithm that requires a single photo and an algorithm built to work with a handheld fundus camera.

Looking towards the future, AEye released a preprint paper in July 2022 that outlines the potential use of AI to predict future development of DR, which could influence personalized patient prognosis and management.<sup>23</sup>

- Automated Retinal Disease Assessment (ARDA; Verily Life Sciences) is an algorithm currently used in India and across the European Union.<sup>24</sup> Verily Life Sciences and Google are analyzing the ARDA algorithm for more-than-mild DR on both 45° and ultra-widefield fundus imaging.<sup>25</sup> No results have yet been released. If this receives FDA clearance, ARDA could be the first AI algorithm for DR detection in ultra-widefield fundus imaging.

- A company called Retina-AI is developing a DR algorithm known as Galaxy that can work on several different imaging devices. The Retina-AI recently released a study that compared five different fundus cameras in detecting more-than-mild DR and vision-threatening DR. According to company data, there is at least 77.4% sensitivity, 82.4% specificity and 94% imageability between cameras and variable levels of disease.<sup>26,27</sup> Retina-AI initiated another FDA trial in May 2022 focusing on DR detection in three retinal cameras.<sup>28</sup> If FDA cleared, this algorithm could increase availability of AI-powered software across various fundus cameras.

- Zilia Ocular (Zilia) is a hybrid retinal camera that can also incorporate oximetry, a measurement of blood oxygen saturation. The camera has a 24° field of view with fixation targets that allow imaging throughout the retina. The company is investigating the use of computerized neural networks to improve oximetry calculations.<sup>29</sup> In parallel with imaging, machine learning algorithms will be used to quantify oxygen saturation along with other biomarkers. This will help identify early spectral and structural changes for a variety of diseases, including diabetes and DR. Zilia is aiming to receive FDA clearance by 2024.

**OCT.** Currently, FDA-cleared applications of AI algorithms in OCTs are limited to age-related macular degeneration (AMD). However, active research on integrating AI into OCTs for DME detection is likely to impact clinical care. Detecting DME with fundoscopic examination and fundus photography is well documented to result in low sensitivity, making the OCT a crucial tool in preventative care here.<sup>15,30-33</sup>

Integrating AI into this tool can democratize and streamline diabetic eye care. Early research and current clinical applications indicate that AI embedded in the OCT will likely serve as another resource for improving detection and management protocols of DME.

The Notal OCT Analyzer (Notal Vision) is a leader in applications of AI in OCTs. The algorithm was granted FDA breakthrough device designation in 2018 for patients with wet AMD.<sup>34</sup> It was recently featured in the AREDS2 10-year follow-up study, which compared intraretinal and subretinal fluid detection between the Notal OCT Analyzer and human investigators.

Upon comparing intraretinal fluid detection, a relevant biomarker in DME, the Notal OCT Analyzer was

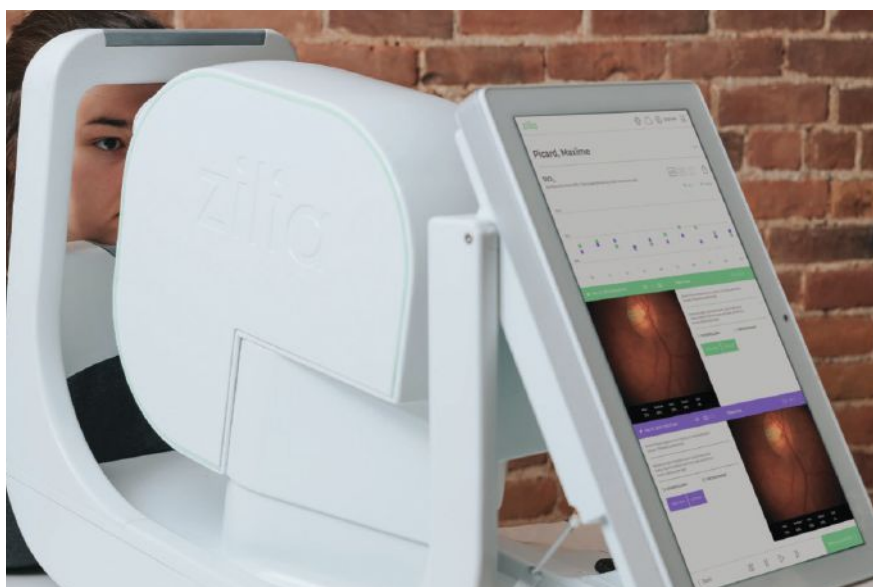

Photo: Zilia

**Zilia has a hybrid retinal camera in development that can potentially incorporate oximetry, a measurement of blood oxygen saturation.**

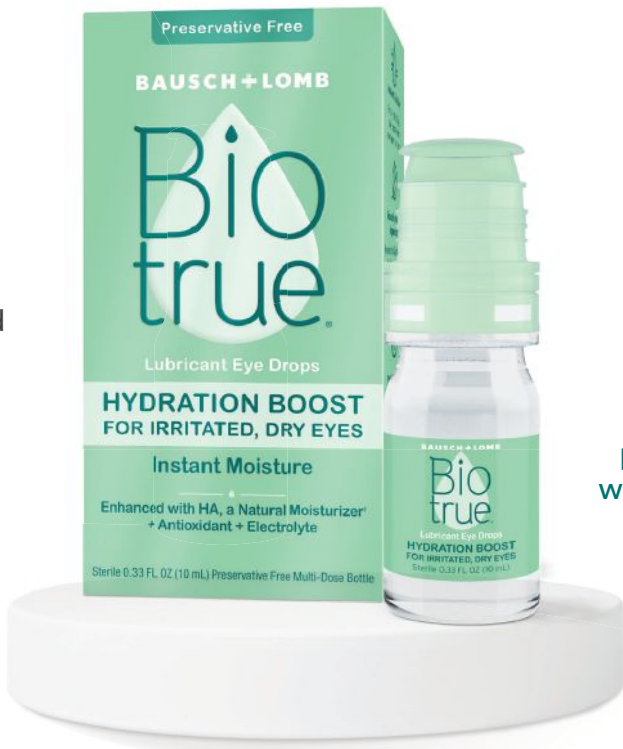

FROM THE  
MAKERS OF  
BIOTRUE®



# Dry eye symptom relief inspired by the biology of the eye

- Helps maintain ocular surface homeostasis
- Soothes eye dryness caused by screen and environmental stressors



Contact lens compatible\*

98%

patient satisfaction with Biotrue® Hydration Boost Eye Drops†



Free from preservatives that can cause irritation



Potassium helps maintain ocular surface homeostasis



Antioxidant protects hyaluronan (HA) against free radicals



HA, a moisturizer found naturally in tears‡



pH balanced

\*Based on standardized testing of soft contact lenses. Not meant to lubricate or rewet lenses.  
†In-Home Use Study: N=728 dry eye sufferers; April 2021. ‡Hyaluronan (HA) is sourced from a large-scale natural fermentation process.

LEARN MORE AT  
[biotrue.com/professional](https://biotrue.com/professional)

# Are Axial Length Measurements a part of your myopia control program ?

## SCANMATE

Periodic axial length measurements have been identified as an essential procedure for monitoring the effectiveness of any myopia control program.

The Scanmate *A* is a portable, USB connected ultrasound A-Scan biometer used to obtain axial length measurements. The Scanmate *A* utilizes unique alignment and compression detection algorithms and provide real time audible feedback to the user. These exclusive features give real-time guidance for optimizing alignment and minimizing compression. You can be confident that your axial measurements will be consistent, accurate and reliable.



**DGH** TECHNOLOGY, INC.

## Feature AI USE IN DR

superior in accuracy (0.877 vs. 0.815) and sensitivity (0.763 vs. 0.403), while investigators were superior in specificity (0.922 vs. 0.978) and precision (0.795 vs. 0.879). The study concluded that this device and equivalent tools may have a future in clinical care for detecting retinal fluid to improve specificity and ultimately better diagnose and manage patients as well as determine prognoses.<sup>35</sup>

As these technologies continue to mature, it is likely that intraretinal fluid detection from OCT will expand to help in the detection and management of other diseases, including DME. Early detection can allow for early intervention and avoid cases of preventable blindness associated with DME.

### Takeaways

Today, autonomous AI is being incorporated into fundus photography to detect DR. It is used to primarily screen patients at the point-of-care to reduce gaps in care and thereby improve health equity. Simultaneously, it has already begun to assist eyecare providers within their clinics. Optometrists should understand the technology's design and real-world validation results to fully evaluate its strengths and weaknesses and understand how it can be implemented appropriately in different clinical care settings.

During this digital revolution, AI is expected to continually become more prominent throughout health care. As it relates to eye care for those with diabetes, autonomous algorithms are expected to further infiltrate retinal cameras and OCT markets. Optometrists will continue to have an increased responsibility to decide how to best incorporate this emerging technology into their practices and patient care. ■

1. Benoit SR, Swenor B, Geiss LS, et al. Eye care utilization among insured people with diabetes in the US, 2010–2014. *Diabetes Care*. 2019;42(3):427-33.
2. Centers for Disease Control and Prevention. National diabetes statistics report. January 18, 2022. [www.cdc.gov/diabetes/data/statistics-report/index.html](http://www.cdc.gov/diabetes/data/statistics-report/index.html). Accessed July 15, 2022.
3. National Committee for Quality Assurance. Comprehensive diabetes care (CDC). NCCA. [www.ncca.org/hedis/measures/comprehensive-diabetes-care/](http://www.ncca.org/hedis/measures/comprehensive-diabetes-care/). Accessed July 15, 2022.
4. Shi Q, Zhao Y, Fonseca V, et al. Racial disparity of eye examinations among the US working-age population with diabetes: 2002-2009. *Diabetes Care*. 2014;37(5):1321-8.
5. Fathy C, Patel S, Sternberg P, Kohanim S. Disparities in adherence to screening guidelines for diabetic retinopathy in the United States: a comprehensive review and guide for future directions. *Semin Ophthalmol*. 2016;31(4):364-77.
6. Lundeen EA, Wittenborn J, Benoit SR, Saaddine J. Disparities in receipt of eye exams among Medicare Part B fee-for-service beneficiaries with diabetes –United States, 2017. *MMWR Morb Mortal Wkly Rep*. 2019;68(45):1020-3.
7. Gibson DM. Estimates of the percentage of US adults with diabetes who could be screened for diabetic retinopathy in primary care settings. *JAMA Ophthalmol*. 2019;137(4):440-4.
8. Fathy C, Patel S, Sternberg P, Kohanim S. Disparities in adherence to screening guidelines for diabetic retinopathy in the United States: a comprehensive review and guide for future directions. *Semin Ophthalmol*. 2016;31(4):364-77.
9. US Food and Drug Administration. artificial intelligence and machine learning in software as a medical device. September 22, 2021. [www.fda.gov/medical-devices/software-medical-device-samd/artificial-intelligence-and-machine-learning-software-medical-device#what-is](http://www.fda.gov/medical-devices/software-medical-device-samd/artificial-intelligence-and-machine-learning-software-medical-device#what-is). Accessed July 15, 2022.
10. Tsiknakis N, Theodoropoulos D, Manikis G, et al. Deep learning for diabetic retinopathy detection and classification based on fundus images: a review. *Computers in Biology and Medicine*. 2021;135:104599.

11. Vizient. TechFlash: artificial intelligence for automated detection of diabetic retinopathy. 2021. [www.vizientinc.com/-/media/documents/sitecorepublishingdocuments/secured/collaboratives/techflash\\_ai\\_diabetic\\_retinopathy\\_aug\\_2021.pdf?RIN2104](http://www.vizientinc.com/-/media/documents/sitecorepublishingdocuments/secured/collaboratives/techflash_ai_diabetic_retinopathy_aug_2021.pdf?RIN2104). Accessed July 15, 2022.
12. Channa R, Wolf R, Abramoff MD. Autonomous artificial intelligence in diabetic retinopathy: from algorithm to clinical application. *J Diabetes Sci Technol*. 2021;15(3):695-8.
13. Schmidt-Erfurth U, Sadeghipour A, Gerendas BS, et al. Artificial intelligence in retina. *Porg Retin Eye Res*. 2018;67:1-29.
14. Chiang MF. artificial intelligence getting smarter! innovations from the vision field. National Eye Institute. February 8, 2022. [directorsblog.nih.gov/tag/idx-dr/](https://directorsblog.nih.gov/tag/idx-dr/). Accessed July 15, 2022.
15. Abràmoff MD, Lavin PT, Birch M, Shah N, Folk JC. Pivotal trial of an autonomous AI-based diagnostic system for detection of diabetic retinopathy in primary care offices. *npj Digit Med*. 2018;1(1):39.
16. US Food and Drug Administration, Center for Drug Evaluation and Research. IDx-DR de novo summary (DEN180001). January 12, 2018. [www.accessdata.fda.gov/cdrh\\_docs/reviews/DEN180001.pdf](https://www.accessdata.fda.gov/cdrh_docs/reviews/DEN180001.pdf). Accessed July 15, 2022.
17. US Food and Drug Administration, Center for Drug Evaluation and Research. EyeArt 501(k) summary (K200667). August 3, 2020. [www.accessdata.fda.gov/cdrh\\_docs/pdf20/K200667.pdf](https://www.accessdata.fda.gov/cdrh_docs/pdf20/K200667.pdf). Accessed July 15, 2022.
18. Ipp E, Liljenquist D, Bode B, et al. Pivotal Evaluation of an artificial intelligence system for autonomous detection of referable and vision-threatening diabetic retinopathy. *JAMA Netw Open*. 2021;4(11):e2134254.
19. Baughman D, Zain A, Waheed A. Patient adherence to hemoglobin a1c testing recommendations in telemedicine and in-office cohorts during COVID-19. *JAMA Netw Open*. 2021;4(9):e2127779.
20. Lin DY, Blumenkranz MS, Brothers RJ, Grosvenor DM. The sensitivity and specificity of single-field nonmydriatic monochromatic digital fundus photography with remote image interpretation for diabetic retinopathy screening: a comparison with ophthalmoscopy and standardized mydriatic color photography. *Am J Ophthalmol*. 2002;134(2):204-13.
21. Lee AY, Yanagihara RT, Lee CS, et al. Multicenter, head-to-head, real-world validation study of seven automated artificial intelligence diabetic retinopathy screening systems. *Diabetes Care*. 2021;44(5):1168-75.
22. James M. AEYE Health Reports Pivotal Clinical Trial Results of its AI Algorithm for the Autonomous Screening and Detection of More-Than-Mild Diabetic Retinopathy. PR Newswire. February 7, 2022. [www.prnewswire.com/news-releases/aeeye-health-reports-pivotal-clinical-trial-results-of-its-ai-algorithm-for-the-autonomous-screening-and-detection-of-more-than-mild-diabetic-retinopathy-301476299.html](https://www.prnewswire.com/news-releases/aeeye-health-reports-pivotal-clinical-trial-results-of-its-ai-algorithm-for-the-autonomous-screening-and-detection-of-more-than-mild-diabetic-retinopathy-301476299.html). Accessed July 15, 2022.
23. Rom Y, Aviv R, Ianchulev S, Dvey-Aharon Z. Predicting the future development of diabetic retinopathy using a deep learning algorithm for the analysis of non-invasive retinal imaging. medRxiv. January 1, 2022. [Epub ahead of print].
24. Google Health. Using AI to prevent blindness. [health.google.com/caregivers/arda/](https://health.google.com/caregivers/arda/). Accessed July 15, 2022.
25. Verily Life Sciences. ARDA Software for the Detection of mtmDR. June 6, 2022. [clinicaltrials.gov/ct2/show/NCT04905459](https://clinicaltrials.gov/ct2/show/NCT04905459). Accessed July 15, 2022.
26. Odaibo S, Imasogie, N, Courtes A, et al. Pivotal study of an autonomous multi-camera compatible artificial intelligence system for diabetic retinopathy screening in primary care. Presented at SIIM Annual Meeting 2021.
27. RETINA-AI Health. Validation study of RETINA-AI Galaxy, an automated diabetic retinopathy screening device. [clinicaltrials.gov/ct2/show/NCT04774822](https://clinicaltrials.gov/ct2/show/NCT04774822). Accessed July 15, 2022.
28. RETINA-AI Health. Validation study of RETINA-AI Galaxy v2.0, an automated diabetic retinopathy screening device. [clinicaltrials.gov/ct2/show/NCT05368623](https://clinicaltrials.gov/ct2/show/NCT05368623). Accessed July 15, 2022.
29. DePaoli DT, Tossou P, Parent M, et al. Convolutional neural networks for spectroscopic analysis in retinal oximetry. *Sci Rep*. 2019;9(1):11387.
30. Ferris FL 3rd, Patz A. Macular edema. A complication of diabetic retinopathy. *Surv Ophthalmol*. 1984;28 Suppl:452-61.
31. Centers for Disease Control and Prevention. Diabetes and vision loss. Published online May 7, 2021. [www.cdc.gov/diabetes/managing/diabetes-vision-loss.html](https://www.cdc.gov/diabetes/managing/diabetes-vision-loss.html). Accessed July 15, 2022.
32. Browning DJ, McOwen MD, Bowen RMJ, O'Marah TL. Comparison of the clinical diagnosis of diabetic macular edema with diagnosis by optical coherence tomography. *Ophthalmology*. 2004;111(4):712-5.
33. Wang YT, Tadarati M, Wolfson Y, et al. Comparison of prevalence of diabetic macular edema based on monocular fundus photography vs. optical coherence tomography. *JAMA Ophthalmology*. 2016;134(2):222-8.
34. Hutton D. Efficacy of Notal Vision OCT device demonstrated by a series of scientific and clinical work. *Ophthalmology Times*. July 1, 2022. [www.opthalmologytimes.com/view/efficacy-of-notal-vision-oct-device-demonstrated-by-a-series-of-scientific-and-clinical-work](https://www.opthalmologytimes.com/view/efficacy-of-notal-vision-oct-device-demonstrated-by-a-series-of-scientific-and-clinical-work). Accessed July 15, 2022.
35. Keenan TDL, Clemons TE, Domalpally A, et al. Retinal specialist vs. artificial intelligence detection of retinal fluid from OCT. *Ophthalmology*. 2021;128(1):100-9.

Can One Device Have It  
All?

# SCANMATE FLEX

The Scanmate Flex, a portable, ophthalmic ultrasound platform, is the perfect product to enhance your practice's diagnostic capabilities. The Flex provides any desired combination of A-Scan, B-Scan, and UBM. It's hall mark is flexibility.

**DGH** TECHNOLOGY, INC.



# NEW TECHNOLOGIES & TREATMENTS IN EYE CARE



**NOVEMBER 11–13, 2022**

HILTON ORLANDO BUENA VISTA PALACE | 1900 E. BUENA VISTA DRIVE  
ORLANDO, FLORIDA

 **IN-PERSON EVENT**

## PROGRAM CHAIR



**Paul M. Karpecki, OD, FAAO**  
Kentucky Eye Institute  
Director of Cornea &  
External Disease  
Associate Professor  
University of Pikeville  
Kentucky College  
of Optometry  
Lexington, Kentucky

## PRESENTING FACULTY



**Douglas Devries, OD**  
Co-founder  
Eye Care Associates of Nevada  
Associate Clinical Professor  
of Optometry  
Sparks, Nevada



**Mark Dunbar, OD, FAAO**  
Director of Optometry  
University of Miami  
Miami, Florida




**Brianna Rhue, OD**  
West Broward  
Eyecare Associates  
Tamarac, Florida



**Eric Schmidt, OD, FAAO**  
President and Founder  
Omni Eye Specialists  
Wilmington, North Carolina

Earn up to **20 LIVE COPE credits\***  
**8 hours of TQ\*\***

For more information and to register, visit:  
[www.reviewedu.com/ntt-orlando](http://www.reviewedu.com/ntt-orlando)



Postgraduate Institute  
for Medicine

\*COPE approval pending

\*Florida Board of Optometry approval pending

\*\*8 hours of TQ approval is pending for optometrists licensed in Florida  
or other states requiring "Transcript Quality" courses for re-licensure.

Partially supported by an unrestricted educational grant from Bausch + Lomb.

Earn 2 CE Credits  
(COPE APPROVED)

# TAKE CONTROL OF THE NUTRITION CONVERSATION

Comprehensive optometric care includes discerning the role evidence-based nutrition plays in eye health.



BY CECELIA KOETTING, OD  
DENVER

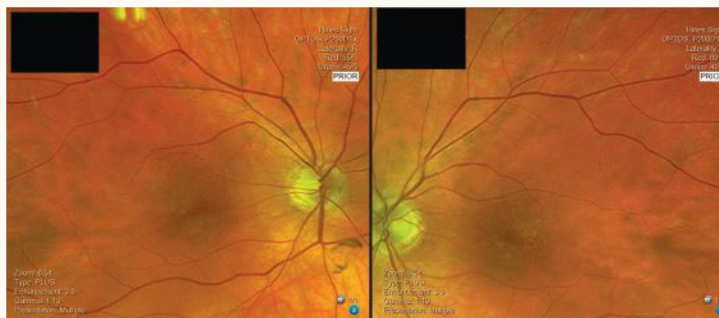For years, there has been discussion around diet and nutrition as it relates to ocular health. Many studies have shown—or suggested—the benefits of certain vitamins and nutrients for a variety of disease states, as well as for overall ocular health. As our patients' primary eyecare providers, it is important to have a comprehensive understanding of the current literature and its impact on clinical care. This will better equip us to discuss the role of dietary supplements. By working in conjunction with a patient's primary care physician and other specialists, we can provide a holistic approach to improve our patients' wellbeing.

The TFOS DEWS II report and the AREDS and AREDS2 studies are three of the larger, well-known efforts that highlight benefits of nutraceutical use in ocular health.<sup>1,2</sup> There are many different vitamins and nutrients that are vital for the correct functionality of our eyes, brain and body. However, it is also important to acknowledge that not all nutraceuticals are equal, and any OD discussing nutrition and supplements with their patients must know which brands should and shouldn't be recommended.

The following is a discussion of the most common ocular disorders, some in relation to systemic disease, where nutraceuticals have been shown by studies to be beneficial. This article will also delve into the role of the OD and how to tackle the nutrition conversation with our patients.

## Age-related Macular Degeneration and Retinal Health

Arguably one of the most well-known applications of nutraceuticals to ocular health is the AREDS2 formula, stemming from the AREDS2 study. In the original AREDS study, over 3,000 participants with age-related macular degeneration (AMD) were in one of four groups receiving antioxidant + zinc + copper, zinc + copper, antioxidant formulation only or placebo. The group receiving antioxidant formulation + zinc



**This patient with intermediate AMD was started on AREDS2 vitamins and ForeseeHome monitoring.**

### About the author

**Dr. Koetting** practices at the MD/OD practice Hines Sight in Denver. Her primary focus is anterior segment and ocular surface disease, neuro-optometry and perioperative care. She is a fellow of the American Academy of Optometry, a diplomate of the American Board of Optometry, an active member of the American Optometric Association (AOA) and has served as both local and state officers of the AOA. She receives consulting fees from Bruder, Tarsus, Oyster Point, Avellino, Alcon, Abbvie, Glaukos, RVL, Dompé, Claris Bio and Aldeyra.

+ copper had the largest reduction in risk for progression from intermediate to advanced AMD and vision loss. Ten years after enrollment, it was found that those who were taking this formula were still 25% to 30% less likely to develop advanced AMD than those in the placebo group.<sup>2</sup>

In 2006, the AREDS2 study was started to test the original formula while adjusting zinc levels and adding either omega-3 fatty acids or lutein + zeaxanthin to see if there was an increase in efficacy.<sup>2,3</sup> At the same time, the study tested the effect of eliminating beta-carotene, which had become a concern for increased risk of lung cancer in smokers.<sup>2,3</sup> Over 4,000 patients with either intermediate or severe AMD (in one eye) were enrolled. No patients without AMD or with early AMD were included in AREDS2 since the original formula was not shown to be beneficial for these patients.

Both the omega-3 and lutein + zeaxanthin arms demonstrated no significant added risk reduction for AMD advancement. It was noteworthy that those in the arm receiving antioxidants with lutein + zeaxanthin but without beta-carotene showed an incremental increase in benefit over those who took the original AREDS formula. This became what we now know as the AREDS2 formula (*Table 1*).<sup>2,3</sup>

In June 2021, the results of the 10-year follow-up study of AREDS2 were released. The study focused on assessing the long-term effect of adding lutein, zeaxanthin and omega-3 fatty acids to the original AREDS on AMD progression and adverse side effects.<sup>4</sup> A total of 6,460 eyes (3,887 participants) were followed, and the study found that 58% of these patients progressed to late AMD.<sup>4</sup> This indicated that the 10-year findings replicated findings of the five-year AREDS2 trial.<sup>4</sup> Both lutein and zeaxanthin had incremental beneficial effect on progression to late AMD compared with beta-carotene, which doubled the risk of lung cancer.<sup>4</sup>

### Diabetes and Ocular Health

The leading global cause of preventable blindness in the working-age population is diabetes, affecting an estimated 425 million adults worldwide in 2019.<sup>5,6</sup> The major causal factors leading to retinal vascular damage and neovascularization in people with diabetes are oxidative stress and inflammation.<sup>6</sup> It is believed that oxidative stress pushes reactive oxygen species into mitochondrial overproduction within the retina. This leads to disruption of cellular signals and cellular damage.<sup>10</sup>

The optometrist's discussion with diabetic patients includes optimizing glycemic control. There is a direct

correlation with poor control in blood sugar and progression of diabetic retinopathy. Many of us feel comfortable discussing diet and changes that can be made, or at the very least referring to a dietician. However, this should not be where the conversation ends.

Another thing that should also be discussed is appropriate dietary supplementation in patients who are known to have poor dietary habits. One supplement that is widely discussed within eye care is omega-3 fatty acids, specifically eicosapentaenoic acid (EPA) and docosahexaenoic acid (DHA). Both of these are long-chain n-3 polyunsaturated fatty acids, which in studies have been used as a therapy for retinal diseases.<sup>6,8,9</sup> This is, in part, due to their pleiotropic effects which include anti-inflammatory, antioxidant, antiproliferative and antiangiogenic properties.<sup>6,8,9</sup> DHA is important for function of the retinal vascular and sensory systems; EPA is converted into DHA within our cells.<sup>6,8,9</sup> Dietary consumption of DHA or oily fish has been shown to have a protective role against diabetic retinopathy.<sup>10</sup>

The PREDIMED trial, a large prospective cohort study, sought to further investigate this association.<sup>10</sup> While the original study was widely criticized due to protocol deviations, it was retracted and republished in June 2018. The trial included 3,482 patients, all of whom at baseline had a

**Release Date:** September 15, 2022

**Expiration Date:** September 15, 2025

**Estimated Time to Complete Activity:** two hours

Jointly provided by the Postgraduate Institute for Medicine (PIM) and Review Education Group

**Educational Objectives:** After completing this activity, the participant should be better able to:

- Discern the role evidence-based nutrition plays in eye health.
- Determine how ODs should be involved in the nutrition conversation.
- Educate patients on nutrition and its connection to eye health.
- Support patients in evidence-based lifestyle changes.

**Target Audience:** This activity is intended for optometrists engaged in nutrition management.

**Accreditation Statement:** In support of improving patient care, this activity has been planned and implemented by PIM and the Review Education Group. PIM is jointly accredited by the Accreditation Council for Continuing Medical Education, the Accreditation Council



JOINTLY ACCREDITED PROVIDER™  
INTERPROFESSIONAL CONTINUING EDUCATION

for Pharmacy Education and the American Nurses Credentialing Center to provide CE for the healthcare team. PIM is accredited by COPE to provide CE to optometrists.

**Reviewed by:** Salus University, Elkins Park, PA



**Faculty/Editorial Board:** Cecelia Koetting, OD

**Credit Statement:** This course is COPE-approved for two hours of CE credit. Activity #124583 and course ID 80387-GO. Check with your local state licensing board to see if this counts toward your CE requirement for relicensure.

**Disclosure Statements:** PIM requires faculty, planners and others in control of educational content to disclose all their financial relationships with ineligible companies. All identified conflicts of interest are thoroughly vetted and mitigated according to PIM policy. PIM is committed to providing its learners with high-quality, accredited CE activities and related materials that promote improvements or quality in healthcare and not a specific proprietary business interest of an ineligible company.

Those involved reported the following relevant financial relationships with ineligible entities related to the educational content of this CE activity: *Author:* Dr. Koetting receives consulting fees from Bruder, Tarsus, Oyster Point, Avellino, Alcon, Abbvie, Glaukos, RVL, Dompé, Claris Bio and Aldeyra. *Managers and Editorial Staff:* The PIM planners and managers have nothing to disclose. The Review Education Group planners, managers and editorial staff have nothing to disclose.

**Table 1. AREDS Vitamin Formulations**

	AREDS1	AREDS2
	Daily Dose	
Vitamin C	500mg	500mg
Vitamin E	273mg (400 IU)	273mg (400 IU)
Beta-Carotene	15mg	-
Lutein	-	10mg
Zeaxanthin	-	2mg
Zinc	80mg	25mg
Copper	2mg	2mg

previous diagnosis of type 2 diabetes. It investigated the risk of diabetic retinopathy in relation to dietary DHA/EPA intake.<sup>10</sup>

At baseline, 75% of the patients were meeting the recommended intake of 500mg per day of DHA/EPA, equivalent to two weekly servings of oily fish, had a lower prevalence of hypertension and were being treated with insulin.<sup>10</sup> After screening, all patients were assigned to either a Mediterranean diet with extra virgin olive oil, a Mediterranean diet with nuts or a control diet reducing all dietary fat.<sup>10</sup>

At the six-year follow-up, those who reported diets with an intake of at least 500mg per day of EPA/DHA at baseline had a 46% decreased risk of sight-threatening diabetic retinopathy.<sup>10</sup> Patients who did not meet that intake at baseline but were assigned to the Mediterranean diet with extra virgin olive oil had a 63% decreased risk of sight-threatening diabetic retinopathy.<sup>10</sup> Overall, these were very interesting outcomes, suggesting that increased dietary DHA/EPA, possibly with extra-virgin olive oil or with two servings of oily fish per week, can decrease the risk of development or worsening of diabetic retinopathy.<sup>10</sup>

Multiple studies have found that omega-3 dietary supplements with both high EPA and DHA provide a higher antioxidant effect on human retinal cells, increasing cell viability and proliferation while also repairing oxidative-induced damage to retinal pigment epithelium cells.<sup>6,8</sup> In diabetic patients, this may help to prevent or

delay diabetic retinopathy.

Omega-3 fatty acids are also helpful for corneal function in diabetic patients. One study found that patients with type 1 diabetes receiving 1,800mg per day of oral omega-3 fatty acid supplements for 180 days exhibited corneal neuro-regenerative effects when compared with placebo.<sup>9</sup> This was measured by an increase in central corneal nerve fiber length and corneal sensitivity at the end of

follow-up compared with baseline.<sup>9</sup>

Another vitamin that is important to retinal function is vitamin D. This fat-soluble vitamin plays a role in the retina as an antioxidant, anti-inflammatory and anti-angiogenic in patients with diabetes.<sup>11</sup> It helps to decrease production of pro-inflammatory cytokines and helper T-cells, cytotoxic T-cells and natural killer cells.<sup>11</sup> Previously it has been found to be involved with vascular endothelial dysfunction leading to compromise of the blood retinal barrier.<sup>11</sup>

DiVFuSS, a small study of 67 patients, investigated the use of a novel multi-component formula in patients with type 1 or 2 diabetes with no retinopathy or mild to moderate nonproliferative retinopathy.<sup>12</sup> Interestingly, patients with diabetic macular edema were also included.<sup>12</sup>

The formula contained vitamin C, D3 and E, zinc oxide, EPA, DHA, alpha lipoic acid, coQ10, mixed tocotrienols/tocopherols, zeaxanthin, lutein, benfotiamine, N-acetyl cysteine, grape seed extract, resveratrol, turmeric root extract, green tea leaf and pycogenol.<sup>12</sup> Patients were given this formula or placebo canola oil soft gel twice a day.<sup>12</sup>

After six months of use, those who had been on the supplement had significantly better visual function as well as an improvement in serum lipid levels and peripheral neuropathy.<sup>12</sup> No significant change was found in retinal nerve fiber layer thickness, total cholesterol or HbA1c.<sup>12</sup> While the study size was small, it supports evidence of improvement in visual function among

other things for patients with and without nonproliferative diabetic retinopathy, warranting further investigation.<sup>12</sup>

## Corneal Disease and Ocular Surface Disease

Vitamin D is also important for corneal function and has been shown to control inflammation in both corneal healing and chronic ocular surface disease. In addition to this, vitamin D also stimulates expression of antimicrobial peptides, which is beneficial in the presence of infection and wound healing.<sup>13</sup> In association with dry eye disease (DED), one study looked at the level of serum vitamin D and tear fluid and found both to be lower in patients with DED.<sup>14</sup> Tear vitamin D levels were more closely associated with DED and ocular surface discomfort, in theory because they regulate the expression of inflammatory cytokines and protect the corneal epithelial barrier function. All of this is in favor of enhancing corneal and tear vitamin D levels.

Vitamins C and A are well-known for their roles in corneal regulation and healing. Vitamin A specifically helps in epithelial growth and limbal stem cell differentiation.<sup>15</sup> Vitamin A ophthalmic ointment or oral supplements can be used to help speed epithelial healing.<sup>15</sup> Improved corneal wound healing and decreased corneal scarring post-surgery have been associated with use of oral vitamin C. This is in part due to the important role vitamin C plays in enhancing collagen synthesis and suppressing corneal neovascularization.<sup>16</sup>

One study looked at reduction of corneal opacity with use of vitamin C supplementation in patients with infectious keratitis.<sup>16</sup> It found that in conjunction to antibiotic therapy both oral and intravenous vitamin C supplementation helped with healing the cornea and reducing the corneal opacity.<sup>16</sup> Additionally, intravenous vitamin C decreased the corneal opacity size more so than oral.<sup>16</sup>

Over the last two decades, the role of omega-3 fatty acid supplementation in DED and meibomian gland

dysfunction has been well discussed. In 2005, the Women's Health Study of over 32,000 women showed an association between DED and diets low in omega-3 fatty acids.<sup>17</sup> Confirmation has been demonstrated in many studies. A meta-analysis in 2019 demonstrated significant improvement in signs and symptoms of DED with omega-3 use.<sup>18</sup>

At this time, omega-3 fatty acids are considered part of first-line therapy for DED with a recommended dosage of 2g of EPA/DHA at a 3:1 ratio.<sup>1,19-22</sup> Not all omega-3 fatty acids are created equal, and most OTC options are synthetic or an unpurified form that is poorly absorbed. This is a partial cause of the fishy taste and odor. Concern for elevated heavy metals such as mercury within supplements has been reported by [consumerlab.com](http://consumerlab.com), an independent nutraceutical quality testing company, to be less than that in fresh fish meat. This is consistent with a 2018 study published that found extracted mercury levels were two to three times lower than that found in fish.<sup>23</sup>

The DREAM study in 2018 had some controversial conclusions, stating that there were no beneficial effects of taking omega-3 supplements over the placebo, which was olive oil. However, what it did show was a statistically significant improvement in the OSDI score in both groups, with no statistically significant difference between the groups.<sup>24</sup> Larger studies looking at the use of olive oil and Mediterranean diet would be worth investigating.

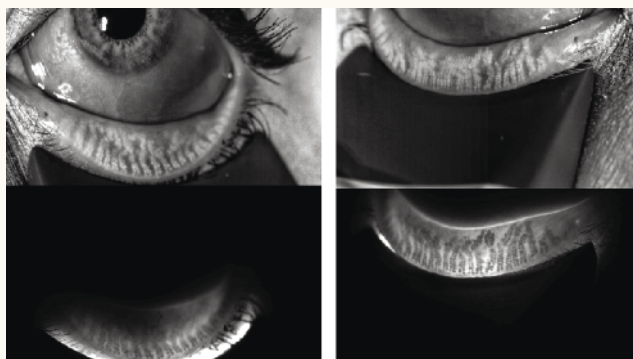
Another study, VITAL, that challenged the use of omega-3 fatty acids for DED was published in *JAMA Ophthalmology* in July 2022.<sup>25</sup> The original study looked at the use of 2,000 IU of vitamin D3 and/or marine omega-3 fatty acids at 1g daily in prevention of cancer and cardiovascular disease in 25,871 adults.<sup>25</sup> The follow-up reviewed the data collected from the original study participants, excluding anyone who previously had a diagnosis of DED or severe symptoms of dry eye based on patient questionnaires.<sup>25</sup> It is important to understand that this

study was specifically looking at preventing DED.<sup>25</sup>

The findings showed that when the group taking marine omega-3 only was compared with the omega-3 placebo group, the same amount of patients developed dry eye.<sup>25</sup> The incidence of DED was 0.7% in the placebo group and 0.7% in the omega-3 group in those 50 to 65 years old and 1.24% in placebo vs. 1.16% in omega-3 in patients over 65.<sup>25</sup> As we know, DED is multifactorial and not solely reliant on one treatment, with incidence increasing with age, so the findings are not necessarily surprising.

Some limitations regarding this study exist. The omega-3 fatty acid used was EPA and DHA in a 1.2:1 ratio, which is significantly lower than that suggested (3:1) for use in DED, and at a lower dosage of 1g vs. the suggested 2g.<sup>1,19-22,25</sup> None of the included patients had DED to start as determined by a questionnaire.<sup>25</sup> Only when symptoms were reported on the follow-up questionnaire one year later were records from the patient's eyecare physician obtained.<sup>25</sup> Lastly, the contents of the placebo omega-3 were not published, so it could be that this was another oil that contains some fatty acid benefits.

Vitamin B12 deficiency has also been evaluated in both causality and treatment among patients with severe DED and neuropathic ocular pain (NOP). In a study of 90 patients, severe DED and ocular pain were divided into two groups. The first included patients with both severe DED and vitamin B12 deficiency receiving parenteral vitamin B12 supplement, topical artificial tears and cyclosporine. The second group, with severe DED and normal vitamin B12 levels, received only topical artificial tears and cyclosporine.<sup>26</sup>



**This patient with minimal atrophy, moderate inspissation and loss of gland structure OD>OS was started on omega-3 fatty acids and had thermal pulsation.**

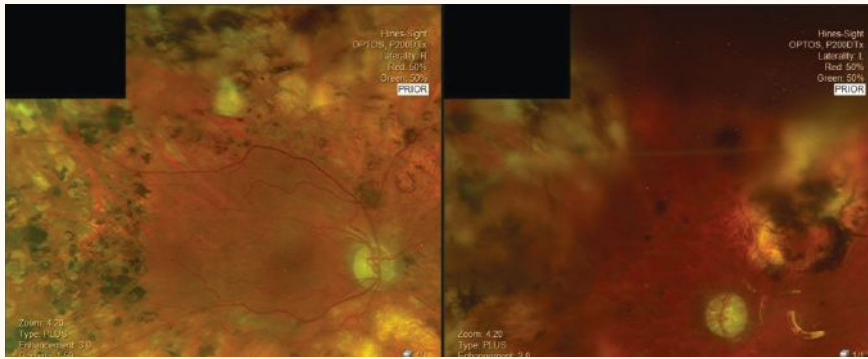
Both arms were evaluated with OSDI, tear breakup time (TBUT) and Schirmer's type 1.<sup>26</sup> The vitamin B12 level increased in group one after 12 weeks of treatment, as did the mean TBUT and Schirmer's score, and the OSDI questionnaire score significantly dropped.<sup>26</sup> Group two also had improvements in these areas; however, it was not as profound.<sup>26</sup> This may indicate that we should be considering vitamin B12 levels in our patients with NOP and severe DED.

### Exercise, BMI and Ocular Health

Regular aerobic exercise and lower BMI are known for their benefits to our body and minds overall but have also been shown to be beneficial for our ocular health. Greater cataract risk has been found in patients with greater inactivity, and vice-versa.<sup>27,28</sup> Decreased risk of progression in patients with primary open-angle glaucoma and lower IOP has been documented.<sup>29</sup>

Exercise has been shown to have a protective effect on progression of dry to wet AMD.<sup>30</sup> Increased risk has been found for progression of dry to wet AMD in those with overall abdominal obesity.<sup>31</sup> In regard to the Mediterranean diet, patients with AMD may benefit from a reduction in their dietary glycemic index, especially those with diabetes.<sup>32,33</sup> This is just one more reason it is important for us as healthcare professionals to discuss a healthy diet and regular exercise with our patients.





**This patient with poorly controlled diabetes and a history of proliferative diabetic retinopathy and panretinal photocoagulation OU initiated omega-3 fatty acid treatment with lutein and zeaxanthin.**

### Eating Habits and Nutraceuticals

Diet is the best source for nutrients and vitamins. Our bodies readily absorb these better than supplements. Non-processed and fresh foods carry more nutrients and vitamins, which are decreased in the milling and storage process.<sup>34</sup> Some of the best sources for dietary vitamin A are in green, orange and yellow vegetables (e.g., carrots and spinach).<sup>35</sup> Vitamin D is not naturally occurring in many foods other than fatty fish like salmon and tuna but has been fortified in most cow milk within the United States.<sup>35</sup>

The same can be said for omega-3 fatty acids. Fatty fish and plant oils are the most common, but products like eggs, milk and yogurt can be found fortified with omega-3 fatty acids.<sup>35</sup> Vitamin B12 is found mainly in animal products and some seafood or shellfish, again with other foods that may be fortified.<sup>35</sup> Lastly, and arguably the easiest, is vitamin C. Found in citrus fruits, juices, red and green peppers, broccoli, kiwi, strawberries, potatoes and tomatoes, there is a little something for everyone.<sup>35</sup>

According to CDC data from the National Health and Nutrition Examination Survey, 57.6% of adults over 20 years of age in the United States were taking dietary supplements in 2017 and 2018.<sup>36</sup> Use was higher among women than men and increased with age, highest among women 60 years and older at 80.2%.<sup>36</sup> The most commonly used dietary supplements were multivitamin mineral supplements,

followed by vitamin D and omega-3 fatty acids.<sup>36</sup>

Use of dietary supplements and vitamins are good ways to help improve our dietary deficits. However, the body's ability to absorb these varies based on chemical composition. This can also be affected by surgeries that alter our digestive system such as ostomies or bariatric surgery.<sup>37</sup> With a decreased surface area for absorption either with the colon or the stomach, the most common vitamin deficiencies are B12, iron, calcium, vitamin D and calcium.<sup>37</sup>

### Which Supplements to Use?

It is important for optometrists to discuss treatment options with patients, including diet, exercise and nutraceuticals. When adapting new knowledge and practice habits, this can take time and research.

There are different approaches and steps that can be taken to help our patients. Initiating discussions around nutrition and eye health should be the bare minimum. From here you can refer the patient to a dietician as needed or provide direction on what exactly they need to add to their diet or supplement intake.

Quality vs. quantity applies when talking about vitamins and supplements. What is on the label may in fact not always be correct when it comes to the true content. Before recommending products, or taking them ourselves, it is important to verify any marketing claims. The FDA does not have the

authority to approve dietary supplements, and companies do not have to provide evidence to substantiate safety of their products, unless they contain a new dietary ingredient.<sup>38</sup> This is defined as a dietary ingredient that was not marketed in the United States in a dietary supplement before October 15, 1994.<sup>38</sup> While companies do not have to submit to the FDA, under the Federal Food, Drug and Cosmetic Act companies are held responsible for ensuring that dietary supplements are not misbranded or providing false claims of function.<sup>38</sup> Companies do not have to submit prior to putting claims on their products such as “supports better vision” or “helps lose that belly fat;” however, if challenged, they are responsible for providing documentation and research backing these claims.

This is why many nutraceutical companies have independent certification labels, such as Natural Products Association (NPA), US Pharmacopeial Convention (USP) and NSF certified. This allows a third party to test for purity and safety of their product. Beyond this, there are independent groups such as [labdoor.com](http://labdoor.com) and [consumerlab.com](http://consumerlab.com) that test the quality and content of products. The ConsumerLab website also provides information on who the FDA has flagged regarding false claims of content and function.

When considering the supplements and vendors that we may use as eyecare professionals, there are many choices. Don't hesitate to ask about independent research or white papers that may help you when deciding which you prefer to recommend. Several eyecare companies have a wide selection of eye health formulas and have taken the time to make sure their research materials are available for both patients and physicians.

### To Sell or Not to Sell?

There are varying opinions among eyecare professionals regarding both use and in-office sales of nutraceuticals. It is important to remember that

these products are not cures but serve as tools or other options to supplement treatment for our patients. The science and benefits have already been discussed but the pros and cons of in-office sales should also be considered.

Carrying supplements in-office or working with different nutraceutical companies for direct-to-patient sales can be beneficial for both the patient and the practitioner. Patients are much more likely to follow through with treatment plans when there is a firm recommendation on which products to use, why and how. When they know that something is being prescribed vs. suggested, it changes compliance.

Recommend one or two specific brands, tell the patient where to find them and the exact dosage they need. Taking it a step further and carrying nutraceuticals in-house or sending in a prescription to the company puts the product in the patient's hand, and they are much more likely to follow through with use. Many companies have auto-renewal and shipment options as well, similar to mail order pharmacies. This ensures the patient will not run out and will be able to continue with treatment.

This can also be financially beneficial for the practice as well as the patient. Selling products within the office can lead to a passive income, and many of companies offer a percentage of online sales when you set up an account to allow your patients to order. This presents an option for those who do not have the footprint to offer products in-house or those who work in a retail setting or partnership where they may not have the ability to make these executive decisions. However, none of these options will work if we as doctors do not take the time to discuss the importance and value of this approach with our patients.

As with any in-office sale, there is a concern that the patient may perceive that we are only trying to make money. This may be reason enough for some to avoid in-office sales, but it should not mean that we don't take an active role in the nutrition conversation.

The correct dietary balance of important nutrients and vitamins is vital for the functionality of our body, including our eyes. Educating our patients regarding both dietary changes and supplements should be part of our exam. As members of the healthcare team, optometrists need to be prepared to aid in the continued discussion regarding diet and exercise with patients as a part of a more holistic approach. ■

- Jones L, Downie LE, Korb D, et al. TFOS DEWS II management and therapy report. *Ocul Surf*. 2017;15(3):575-628.
- National Eye Institute. AREDS/AREDS2 clinical trials. [www.nei.nih.gov/research/clinical-trials/age-related-eye-disease-studies-aredsareds2/about-areds-and-areds2](http://www.nei.nih.gov/research/clinical-trials/age-related-eye-disease-studies-aredsareds2/about-areds-and-areds2). Accessed 7/10/22.
- Chew EY, Clemons TE, Sangiovanni JP, et al. Secondary analyses of the effects of lutein/zeaxanthin on age-related macular degeneration progression: AREDS2 report No. 3. *JAMA Ophthalmology*. 2014;132(2):142-9.
- Chew EY, Clemons TE, Keenan T, et al. The results of the 10 year follow-on study of the age-related eye disease study 2 (AREDS2). *Invest Ophthalmol Vis Sci*. 2021;62(8):1215.
- Flaxman SR, Bourne RRA, Resnikoff S, et al. Global causes of blindness and distance vision impairment 1990-2020: a systematic review and meta-analysis. *Lancet Glob Health*. 2017;5(12):e1221-e1234.
- Saenz de Viteri M, Hernandez M, Bilbao-Malavé V, et al. A higher proportion of eicosapentaenoic acid (EPA) when combined with docosahexaenoic acid (DHA) in omega-3 dietary supplements provides higher antioxidant effects in human retinal cells. *Antioxidants (Basel)*. 2020;9(9):828.
- Valle, Maria Stella, Cristina Russo, and Lucia Malaguarnera. Protective role of vitamin D against oxidative stress in diabetic retinopathy. *Diabetes/Metabolism Research and Reviews* 37.8 (2021): e3447.
- Xiao Y, Zhang Q, Liao X, et al. The effects of omega-3 fatty acids in type 2 diabetes: A systematic review and meta-analysis. *Prostaglandins Leukot Essent Fatty Acids*. 2022;182:102456
- Alexis Britten-Jones AC, Kamel JT, Roberts LJ, et al. Investigating the neuroprotective effect of oral omega-3 fatty acid supplementation in type 1 diabetes (nPROOF1): A Randomized Placebo-Controlled Trial. *Diabetes*. 2021;70(8):1794-1806.
- Sala-Vila A, Díaz-López A, Valls-Pedret C, et al. Dietary marine ω-3 fatty acids and incident sight-threatening retinopathy in middle-aged and older individuals with type 2 diabetes: prospective investigation from the PREDIMED trial. *JAMA Ophthalmol*. 2016;134(10):1142-9.
- Valle MS, Russo C, Malaguarnera L. Protective role of vitamin D against oxidative stress in diabetic retinopathy. *Diabetes Metab Res Rev*. 2021;37(8):e3447
- F Chous AP, Richer SP, Gerson JD, et al. The diabetes visual function supplement study (DiVFuSS). *Br J Ophthalmol*. 2016;100:227-34.
- Reins RY, Hanlon SD, Magadi S, et al. Effects of topically applied vitamin D during corneal wound healing. *PLoS One*. 2016;11(4):e0152889
- Khamar P, Nair AP, Shetty R, et al. Dysregulated tear fluid nociception-associated factors, corneal dendritic cell density, and vitamin D levels in evaporative dry eye. *Invest Ophthalmol Vis Sci*. 2019;60(7):2532-42.
- Chelala E, Dirani A, Fadlallah A, et al. The role of topical vitamin A in promoting healing in surface refractive procedures: a prospective randomized controlled study. *Clin Ophthalmol*. 2013;7:1913-8.
- Cho YW, Yoo WS, Kim SJ, et al. Efficacy of systemic vitamin C supplementation in reducing corneal opacity resulting from infectious keratitis. *Medicine (Baltimore)*. 2014;93(23):e125.
- Ziemanski JF, Wolters LR, Jones-Jordan L, et al. Relation between dietary essential fatty acid intake and dry eye disease and meibomian gland dysfunction in postmenopausal women. *Am J Ophthalmol*. 2018;189:29-40.
- Giannaccare G, Pellegrini M, Sebastiani S, et al. Efficacy of omega-3 fatty acid supplementation for treatment of dry eye disease: a meta-analysis of randomized clinical trials. *Cornea*. 2019;38(5):565-73.
- Lum F, Feder RS, McLeod SD, et al. The preferred practice pattern guidelines in ophthalmology. *Ophthalmology*. 2016;123(5):928-9.
- Milner MS, Beckman KA, Luchs JI, et al. Dysfunctional tear syndrome: dry eye disease and associated tear film disorders - new strategies for diagnosis and treatment. *Curr Opin Ophthalmol*. 2017;27(Suppl 1):3-47.
- Starr CE, Gupta PK, Farid M, et al. An algorithm for the preoperative diagnosis and treatment of ocular surface disorders. *J Cataract Refract Surg*. 2019;45(5):669-84.
- Akpek EK, Amescua G, Farid M, et al. Dry eye syndrome preferred practice pattern. *Ophthalmology*. 2019;126(1):286-P334.
- Mei N, Bunhong L, Liu J, et al. Speciation of trace mercury impurities in fish oil supplements. *Food Control*. 2018;84:221-5.
- Asbell PA, Maguire MG, Peskin E, et al. Dry eye assessment and management (DREAM) study: study design and baseline characteristics. *Contemp Clin Trials*. 2018;71:70-9.
- Christen WG, Cook NR, Manson JE, et al. Efficacy of marine ω-3 fatty acid supplementation vs placebo in reducing incidence of dry eye disease in healthy US adults: a randomized clinical trial. *JAMA Ophthalmol*. 2022;140(7):707-14.
- Ozen S, Ozer MA, Akdemir MO. Vitamin B12 deficiency evaluation and treatment in severe dry eye disease with neuropathic ocular pain. *Graefes Arch Clin Exp Ophthalmol*. 2017;255(6):1173-7.
- Williams PT. Prospective epidemiological cohort study of reduced risk for incident cataract with vigorous physical activity and cardiorespiratory fitness during a 7-year follow-up. *Invest Ophthalmol Vis Sci*. 2009;50:95-100.
- Selin JZ, Orsini N, Lindblad BE, et al. Long-term physical activity and risk of age-related cataract: a population-based prospective study of male and female cohorts. *Ophthalmology*. 2015;122:274-80.
- Tsai JC. Influencing ocular blood flow in glaucoma patients: the cardiovascular system and healthy lifestyle choices. *Can J Ophthalmol*. 2008;43:347-50.
- Knudtson MD, Klein R, Klein BEK. Physical activity and the 15-year cumulative incidence of age-related macular degeneration: the Beaver Dam Eye Study. *Br J Ophthalmol*. 2006;90:1461-3.
- Seddon JM, Cote J, Davis N, et al. Progression of age-related macular degeneration: association with body mass index, waist circumference, and waist-hip ratio. *Arch Ophthalmol*. 2003;121:785-92.
- Merle BMJ, Silver RE, Rosner B, et al. Adherence to a Mediterranean diet, genetic susceptibility, and progression to advanced macular degeneration: a prospective cohort study. *Am J Clin Nutr*. 2015;102:1196-206.
- Chiu C, Milton RC, Gensler G, et al. Association between dietary glycemic index and age-related macular degeneration in nondiabetic participants in the Age-Related Eye Disease Study. *Am J Clin Nutr*. 2007;86:180-8.
- Rock CL. Multivitamin-multimineral supplements: who uses them. *Am J Clin Nutr*. 2007;85(1):2778-95.
- National Institutes of Health. <https://ods.od.nih.gov/factsheets/list-all/#A>. Accessed 7/20/22.
- Centers for Disease Control and Prevention. [www.cdc.gov/nchs/products/databriefs/db399.htm](http://www.cdc.gov/nchs/products/databriefs/db399.htm). Accessed 7/10/22.
- Malinowski SS. Nutritional and metabolic complications of bariatric surgery. *Am J Med Sci*. 2006 Apr;331(4):219-25.
- U.S. Food and Drug Administration. [www.fda.gov/food/information-consumers-using-dietary-supplements/questions-and-answers-dietary-supplements](http://www.fda.gov/food/information-consumers-using-dietary-supplements/questions-and-answers-dietary-supplements).

## OPTOMETRIC STUDY CENTER QUIZ

To obtain CE credit through the Optometric Study Center, complete the test form on the following page and return it with the \$35 fee to: Jobson Healthcare Information, LLC, Attn.: CE Processing, 395 Hudson Street, 3rd Floor New York, New York 10014. To be eligible, please return the card within three years of publication. You can also access the test form and submit your answers and payment via credit card online at [revieweducationgroup.com](http://revieweducationgroup.com). You must achieve a score of 70 or higher to receive credit. Allow four weeks for processing. For each Optometric Study Center course you pass, you earn two hours of credit. Please check with your state licensing board to see if this approval counts toward your CE requirement for relicensure.

- 1. The original AREDS formula contained which of the following?**
  - a. Antioxidant + zinc + copper.
  - b. Zinc + copper only.
  - c. Antioxidants only.
  - d. Antioxidant + copper only.
- 2. AREDS2 removed beta-carotene because it did what?**
  - a. Increased risk of lung cancer to men.
  - b. Increased risk of lung cancer to smokers.
  - c. Increased risk of prostate cancer to smokers.
  - d. Increased risk of prostate cancer to men.
- 3. When compared with the original formula, the AREDS2 study found the addition of omega-3 fatty acids did what?**
  - a. Caused an increased risk of AMD progression.
  - b. Decreased the risk of AMD progression.
  - c. Did not cause a difference in the risk profile.
  - d. The risk profile wasn't studied in AREDS2.
- 4. What percentage of patients in the 10-year follow-up AREDS2 was found to have progressed to late AMD?**
  - a. 58%.
  - b. 15%.
  - c. 25%.
  - d. 78%.
- 5. What omega-3 fatty acids are most beneficial for diabetic patients?**
  - a. DHA + EPA.
  - b. EPA only.
  - c. DHA only.
  - d. BPA + ALA.
- 6. Which is not a part of why omega-3 fatty acids are helpful for diabetic patients?**
  - a. Increasing cell viability and proliferation within the retina.
  - b. Repairing oxidative damage to the retinal pigment epithelium.
  - c. Improving corneal neuro-regeneration.
  - d. Increasing inflammatory markers.
- 7. Which fat-soluble vitamin works in the retina as an antioxidant, anti-inflammatory and anti-angiogenic?**
  - a. Vitamin A.
  - b. Vitamin D.
  - c. Vitamin B9.
  - d. Vitamin E.
- 8. In regard to the cornea, vitamin D is believed to be involved in all of the following except which?**
  - a. Inflammation control.
  - b. Expression of antimicrobial peptides.
  - c. Protection of the corneal epithelial barrier function.
  - d. Endothelial cell destruction.
- 9. Patients who are post-corneal surgery may benefit from which of the following?**
  - a. Decreased levels of vitamin C.
  - b. Increased levels of vitamin C.
  - c. Decreased levels of lutein.
  - d. Increased levels of lutein.
- 10. What is the preferred EPA/DHA ratio of omega-3 fatty acids?**
  - a. 2:1.
  - b. 5:1.
  - c. 3:1.
  - d. 1:1.
- 11. The DREAM Study in 2018 found which of the following true concerning DED?**
  - a. Omega-3 fatty acids were better than olive oil.
  - b. Olive oil was better than omega-3 fatty acids.
  - c. Neither olive oil nor omega-3 fatty acids were beneficial.
  - d. Omega-3 fatty acids and olive oil were beneficial.
- 12. Which vitamin deficiency may be associated with NOP?**
  - a. Vitamin B12.
  - b. Vitamin B6.
  - c. Vitamin D.
  - d. Vitamin C.
- 13. Exercise has been shown to do what?**
  - a. Increase progression of dry AMD to wet AMD.
  - b. Have no effect on progression of AMD.
  - c. Have a protective effect on progression of dry AMD to wet AMD.
  - d. It has not been investigated in relation to AMD.
- 14. Exercise has been linked to benefits in all of the following except which?**
  - a. Diabetic retinopathy.
  - b. Strabismus.
  - c. Cataract risk.
  - d. Primary open-angle glaucoma.
- 15. Our bodies absorb nutrients from our diet \_\_\_\_\_ than from supplements.**
  - a. Better.
  - b. Worse.
  - c. Equal to.
  - d. Unstudied.
- 16. What percentage of US adults take dietary supplements according to 2017 CDC data?**
  - a. 80.2%.
  - b. 57.6%.
  - c. 22.9%.
  - d. 40.5%.
- 17. Dietary vitamin A is found in all of the following except which?**
  - a. Carrots.
  - b. Spinach.
  - c. Eggs.
  - d. Yellow peppers.
- 18. Fatty fish are good sources of all of the following except which?**
  - a. Omega-3.
  - b. Vitamin B12.
  - c. Vitamin D.
  - d. Vitamin A.
- 19. What are the most common vitamin deficiencies in patients who have had bariatric surgery?**
  - a. B12, iron and calcium.
  - b. Vitamin D.
  - c. Vitamin C.
  - d. a and b.
- 20. A new dietary ingredient is defined as:**
  - a. A dietary ingredient that was not marketed in the United States in a dietary supplement before October 15, 1994.
  - b. A dietary ingredient that is not naturally occurring.
  - c. A dietary ingredient that does not require FDA authority.
  - d. A dietary ingredient that was marketed in the United States in a dietary supplement before October 15, 1994.

## Examination Answer Sheet

### Take Control of the Nutrition Conversation

Valid for credit through September 15, 2025

**Online:** This exam can be taken online at [revieweducationgroup.com](http://revieweducationgroup.com). Upon passing the exam, you can view your results immediately and download a real-time CE certificate. You can also view your test history at any time from the website.

**Directions:** Select one answer for each question in the exam and completely darken the appropriate circle. A minimum score of 70% is required to earn credit.

**Mail to:** Jobson Healthcare Information, LLC, Attn.: CE Processing, 395 Hudson Street, 3rd Floor New York, New York 10014.

**Payment:** Remit \$35 with this exam. Make check payable to Jobson Healthcare Information, LLC.

**Credit:** This course is COPE-approved for two hours of CE credit. Course ID 80387-G0.

**Processing:** There is a four-week processing time for this exam.

Jointly provided by PIM and the Review Education Group.  
Salus University has sponsored the review and approval of this activity.

**Answers to CE exam:**

1.  A  B  C  D
2.  A  B  C  D
3.  A  B  C  D
4.  A  B  C  D
5.  A  B  C  D
6.  A  B  C  D
7.  A  B  C  D
8.  A  B  C  D
9.  A  B  C  D
10.  A  B  C  D
11.  A  B  C  D
12.  A  B  C  D
13.  A  B  C  D
14.  A  B  C  D
15.  A  B  C  D
16.  A  B  C  D
17.  A  B  C  D
18.  A  B  C  D
19.  A  B  C  D
20.  A  B  C  D

**Post-activity evaluation questions:**

Rate how well the activity supported your achievement of these learning objectives. 1=Poor, 2=Fair, 3=Neutral, 4=Good, 5=Excellent

21. Discern the role evidence-based nutrition plays in eye health. ① ② ③ ④ ⑤
22. Determine how ODs should be involved in the nutrition conversation. ① ② ③ ④ ⑤
23. Educate patients on nutrition and its connection to eye health. ① ② ③ ④ ⑤
24. Support patients in evidence-based lifestyle changes. ① ② ③ ④ ⑤
25. Based upon your participation in this activity, do you intend to change your practice behavior? (Choose only one of the following options.)
  - A I do plan to implement changes in my practice based on the information presented.
  - B My current practice has been reinforced by the information presented.
  - C I need more information before I will change my practice.
26. Thinking about how your participation in this activity will influence your patient care, how many of your patients are likely to benefit? (please use a number):
27. If you plan to change your practice behavior, what type of changes do you plan to implement? (Check all that apply.)
 

<input type="checkbox"/> A Apply latest guidelines	<input type="checkbox"/> D Change in current practice for referral	<input type="checkbox"/> G More active monitoring and counseling
<input type="checkbox"/> B Change in diagnostic methods	<input type="checkbox"/> E Change in vision correction offerings	<input type="checkbox"/> H Other, please specify: _____
<input type="checkbox"/> C Choice of management approach	<input type="checkbox"/> F Change in differential diagnosis	
28. How confident are you that you will be able to make your intended changes?
  - A Very confident
  - B Somewhat confident
  - C Unsure
  - D Not confident
29. Which of the following do you anticipate will be the primary barrier to implementing these changes?
 

<input type="radio"/> A Formulary restrictions	<input type="radio"/> D Insurance/financial issues	<input type="radio"/> G Patient adherence/compliance
<input type="radio"/> B Time constraints	<input type="radio"/> E Lack of interprofessional team support	<input type="radio"/> H Other, please specify: _____
<input type="radio"/> C System constraints	<input type="radio"/> F Treatment related adverse events	
30. Additional comments on this course: \_\_\_\_\_

**Please retain a copy for your records. Please print clearly.**

First Name

Last Name

E-Mail

The following is your:  Home Address  Business Address

Business Name

Address

City  State

ZIP

Telephone #  -  -

Fax #  -  -

OE Tracker Number

**Rate the quality of the material provided:**

1=Strongly disagree, 2=Somewhat disagree, 3=Neutral, 4=Somewhat agree, 5=Strongly agree

31. The content was evidence-based.

① ② ③ ④ ⑤

32. The content was balanced and free of bias.

① ② ③ ④ ⑤

33. The presentation was clear and effective.

① ② ③ ④ ⑤

By submitting this answer sheet, I certify that I have read the lesson in its entirety and completed the self-assessment exam personally based on the material presented. I have not obtained the answers to this exam by any fraudulent or improper means.

Signature \_\_\_\_\_ Date \_\_\_\_\_ Lesson 123124 RO-OSC-0922

# REGISTER NOW

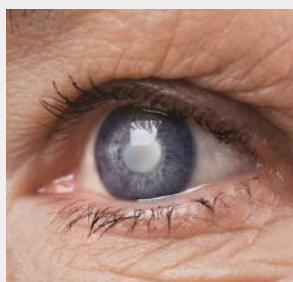

IN-PERSON EVENTS

Join Review Education Group and MedscapeLIVE! this December for the West Coast Optometric Glaucoma Symposium (WCOGS) and Retina Update 2022. The conferences will be co-located at the Hilton La Jolla Torrey Pines in La Jolla, California. Attendees are encouraged to participate in both symposia to greatly enhance their learning experience.

**Early bird special pricing: \$149 single conference | \$250 bundled**

Deadline to register with special rate: October 21, 2022



## WEST COAST OPTOMETRIC GLAUCOMA SYMPOSIUM

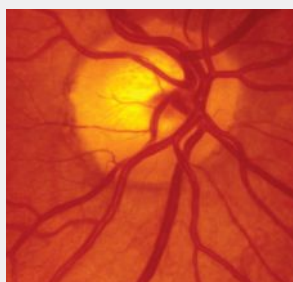**DECEMBER 9–10, 2022**

LA JOLLA, CALIFORNIA

Program Co-chairs: Murray Fingeret, OD, FAAO; Robert N. Weinreb, MD

**EARN UP TO 12 LIVE CE CREDITS\***

WCOGS is a 2-day biannual symposium designed to provide optometrists with exposure to current thinking on evolving standards of care, state-of-the-art technology and breaking research that will guide current and future glaucoma care in the optometric setting. Incorporating cases, clinical pearls, and discussion sessions, the program will maximize the opportunity for participant/faculty engagement.



THE OPTOMETRIC RETINA SOCIETY AND REVIEW EDUCATION GROUP PRESENT

## RETINAUPDATE2022

**DECEMBER 10–11, 2022**

LA JOLLA, CALIFORNIA

Program Co-chairs: Mohammad Rafieetary, OD, FAAO; Steven Ferrucci, OD, FAAO

**EARN UP TO 11 CE CREDITS\***

Retina Update 2022 will help ensure that primary practitioners consider all relevant research so they can practice in an effective and appropriate manner. The program will offer specific direction and practical advice on how to detect and manage a broad range of retinal disease and promote improved retinal health.

**Earn up to 23 LIVE COPE credits\***

For more information and to register

[www.reviewedu.com/winteroptometry](http://www.reviewedu.com/winteroptometry)



Postgraduate Institute  
for Medicine

**REVIEW**  
Education GROUP



EDITED BY JOSEPH P. SHOVLIN, OD

# Talkin' Toxicity

Consider the potential adverse effects associated with Blenrep before initiating use for myeloma treatment.

**Q** I have a patient who recently started treatment for refractory multiple myeloma with Blenrep (belantamab, GlaxoSmithKline). Apparently, there are significant warnings regarding corneal (epithelial) toxicity. Any suggestions on what signs to look for? At what point would the medication have to be stopped? Are the corneal changes reversible?

**A** Blenrep is a drug used in the treatment of relapsed and refractory multiple myeloma, says Manveen Bedi, OD, who practices in Toronto. The DREAMM-1 and DREAMM-2 trials noted several ocular toxicities that required dose adjustments, dose delays and discontinuation of therapy.<sup>1,2</sup> Once the drug reaches the corneal epithelium through the tear film or vascularized limbal region, the cytotoxic component, monomethyl auristatin F (MMAF), is internalized by corneal epithelial cells in an off-target mechanism resulting in apoptosis.<sup>1-3</sup> Subsequently, the cornea reflects signs of keratopathy and microcyst-like corneal epithelial changes.<sup>1-3</sup> The most common ocular impacts were dry eye and blurred vision.<sup>1-3</sup>

who were prescribed a dose of 2.5mg/kg, 72% experienced microcyst-like corneal epithelial changes, 25% had blurred vision and 15% suffered from dry eye.<sup>1,2</sup> In the dosing cohort of 3.4mg/kg, 77% had microcyst-like corneal epithelial changes, 33% had blurred vision and 25% had dry eye.<sup>1,2</sup> Symptom onset usually ranged from nine days to nine months after receiving Blenrep with a median of 36 days.<sup>2</sup>

Previously, the use of corticosteroids to mitigate MMAF-related adverse effects was considered, according to Dr. Bedi. However, the DREAMM-2 sub-study further investigated the role of steroids and increased the treatment duration from four to seven days, concluding that there was no significant effect on corneal change prevention.<sup>2</sup>

Also, long-term follow-up of patients from the DREAMM-1 study showed development of secondary glaucoma and cataracts; therefore, it was recommended to avoid steroids as a mitigation strategy to reduce ocular toxicity.<sup>2</sup>

Corneal changes are overall reversible with dose modification and cessation of therapy; however, in the presence of corneal adverse

effects, recommendations from the DREAMM-2 study should be followed while working in conjunction with a hematologist/oncologist.<sup>1,2</sup>

Suggestions include the following:<sup>1</sup>

1. Conduct a baseline eye examination with visual acuity and slit lamp assessment up to three weeks prior to initiation of Blenrep and monitor patient prior to every cycle of treatment (up to two weeks before) and upon worsening of symptoms.

2. Comanage care with a hematologist/oncologist and provide information about corneal findings and visual acuity changes for dose management, which is based on the worst grade of the most affected eye.

3. Use the Keratopathy and Visual Acuity Scale to determine dosing.<sup>1,2</sup>

4. For patients with a history of dry eye, avoid contact lens wear and initiate use of preservative-free artificial tears four times a day with the first infusion of Blenrep until cessation of therapy, as this population is more likely to develop moderate/severe microcyst-like corneal epithelial changes. ■

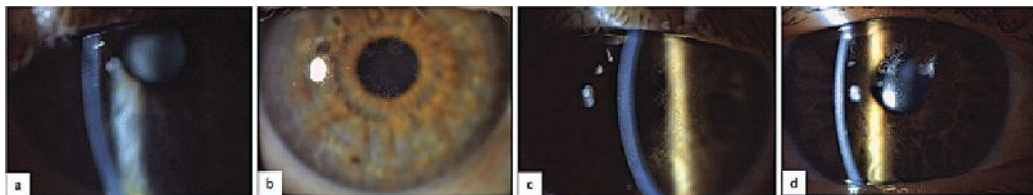
1. Farooq AV, Degli Esposti S, Popat R, et al. Corneal epithelial findings in patients with multiple myeloma treated with antibody-drug conjugate belantamab mafodotin in the pivotal, randomized, DREAMM-2 study. *Ophthalmol Ther*. 2020;9(4):889-911.

2. Wahab A, Rafae A, Mushtaq K, et al. Ocular toxicity of belantamab mafodotin, an oncological perspective of management in relapsed and refractory multiple myeloma. *Front Oncol*. 2021;11:678634.

3. Aschauer J, Donner R, Lammer J, et al. Corneal toxicity associated with belantamab mafodotin is not restricted to the epithelium: neuropathy studied with confocal microscopy. *Am J Ophthalmol*. 2022;242:116-24.

## Discussion

In the DREAMM-2 study, Dr. Bedi noted that in the presence of corneal changes the majority of patients became symptomatic of visual changes. Of those



Slit lamp images of patients with mild (a), moderate (b) and severe (c, d) microcystic epithelial changes.<sup>3</sup>

About Dr. Shovlin

Dr. Shovlin, a senior optometrist at Northeastern Eye Institute in Scranton, PA, is a fellow and past president of the American Academy of Optometry and a clinical editor of *Review of Optometry* and *Review of Cornea & Contact Lenses*. He consults for Kala, Aerie, AbbVie, Novartis, Hubble and Bausch + Lomb and is on the medical advisory panel for Lentechs.

# SOOTHE THE DRY EYES NATURALLY

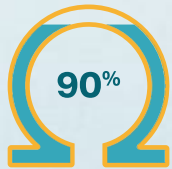Nearly half of all Americans experience dry eye symptoms.<sup>1</sup> Give your patients the best fish oil on the market, and don't let the blurred vision and burning feeling of dry eyes slow them down. Our formula is:



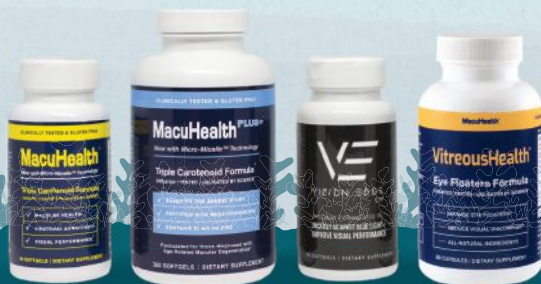**Purified** up to 5 times for optimal purity and no fishy taste



**Traceable** and easily absorbed for optimal health benefits



**Concentrated** 90% with 2,200 mg of EPA and DHA combined per serving



Meet the complete family of products at [MacuHealth.com](https://MacuHealth.com)

**MacuHealth**<sup>®</sup>

Our safe, pharmaceutical grade re-esterified triglyceride (rTG) formula is not only vital for relieving dry eye symptoms but essential for optimal brain and heart health.

Reference: 1 Adler R. Dry eye syndrome: Symptoms and causes. All About Vision, 2017. © 2022 MacuHealth. All rights reserved.



# Pecking Away at Differentials

*Are you familiar with this choroidal lesion?*

An 84-year-old Black female presented to our ophthalmic emergency department for new floaters and decreased vision in her left eye starting the day prior. She denied any flashes of light, pain or recent head or eye trauma.

Her vision was 20/30 OD and 20/200 OS. Her intraocular pressures were measured at 13mm Hg OD and 14mm Hg OS. Examination revealed pupils that were equal in size, with no afferent pupillary defects, and normal extraocular motilities. She was pseudophakic

with centered intraocular lenses in both eyes, and her anterior chambers were quiet. The posterior segment of the right eye was normal and revealed only moderate optic nerve cupping consistent with her history of primary open-angle glaucoma. The left eye's fundus exam was significant for vitreous hemorrhage that was most dense centrally and an interesting retinal lesion located in the nasal periphery that appeared elevated. It was associated with both preretinal and subretinal hemorrhage and had exudates nearby.

The patient's medical history was significant for hypertension, diabetes without retinopathy, hypercholesterolemia, peripheral neuropathy and obstructive sleep apnea. She also had a history of breast cancer, diagnosed and treated seven years prior.

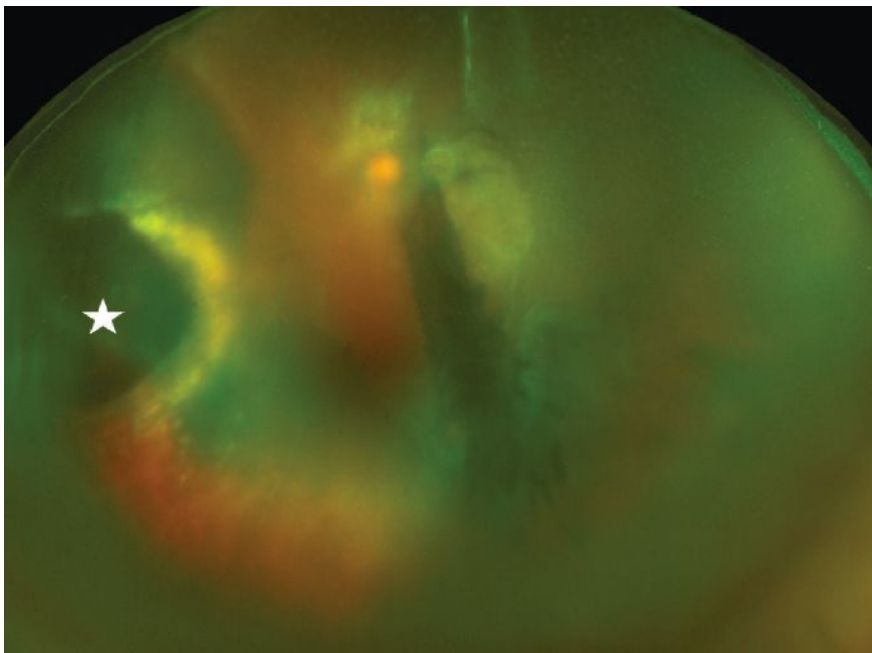
## Working the Case

Given her history of diabetes, a vitreous hemorrhage from proliferative diabetic retinopathy was considered first. However, the fellow eye did not have even mild diabetic retinopathy, making this unlikely.

The hemorrhagic mass in the periphery raised other suspicions, such as a neoplastic choroidal lesion. Choroidal melanoma may present with choroidal and vitreous hemorrhage, making it a differential in this case.<sup>1,2</sup> The patient's history of breast cancer also made a metastatic lesion a definite possibility.

Ultrasonography showed significant vitreous opacities, which corresponded to dispersed vitreous hemorrhage. Additionally, the lesion of concern was hyperechoic and irregularly shaped. There was no internal vascularity appreciable. There was an associated shallow retinal detachment inferior to the lesion, just posterior to the equator. The macula was attached. Due to the irregular, bumpy contour of the lesion and its high internal reflectivity, combined with the clinical examination, a tentative diagnosis of peripheral exudative hemorrhagic chorioretinopathy (PEHCR) was made.

Given the history of breast cancer and the possibility of a metastatic tumor, the patient was referred to an ocular oncologist for further evaluation. The evaluating retina specialist confirmed the likely diagnosis of PEHCR and recommended a trial of anti-VEGF injections. Intravitreal Avastin (bevacizumab, Genentech) was used, and

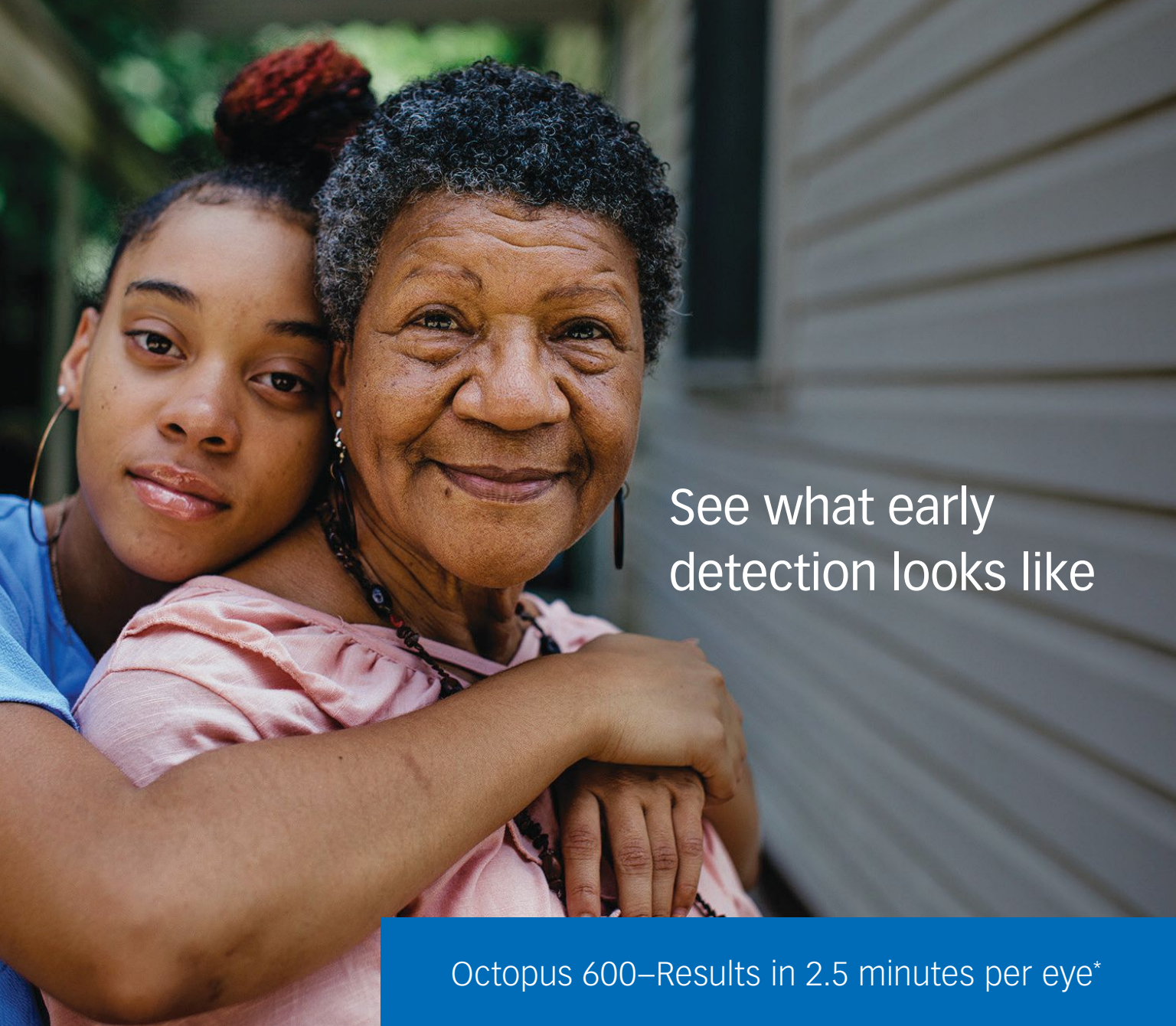


**Widefield fundus photo of the left eye on presentation. There is dispersed vitreous hemorrhage blocking the view partially, but a multilayered hemorrhagic lesion (white star) on the left side of the image can be visualized. There is surrounding exudation seen as a yellowish glow.**

### About Dr. Bozung

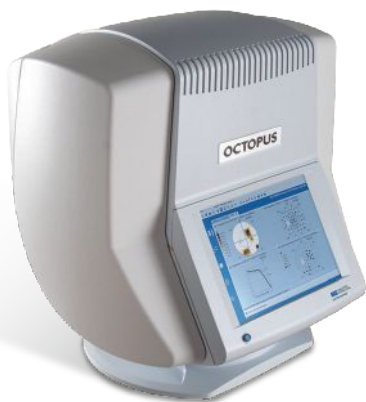Dr. Bozung works in the Ophthalmic Emergency Department of the Bascom Palmer Eye Institute (BPEI) in Miami and serves as the clinical site director of the Optometric Student Externship Program as well as the associate director of the Optometric Residence Program at BPEI. She has no financial interests to disclose.





See what early detection looks like

Octopus 600—Results in 2.5 minutes per eye\*



Affordable early detection, the Octopus 600 offers all your perimetry needs in one easy-to-use device. The 30-degree perimeter, with off-instrument review software and data management, is space-saving, patient-friendly, and delivers 100% fixation static testing for results you can trust. Detect early signs of disease and help your patients live a better quality of life.

**ADVANCED:**

Early detection with both standard white-on-white and the exclusive Pulsar test method

**FAST:**

Reduce patient testing time with TOP threshold strategy, 2.5 minutes per eye\*

**INSTANT:**

Immediately quantify change with EyeSuite Progression Analysis

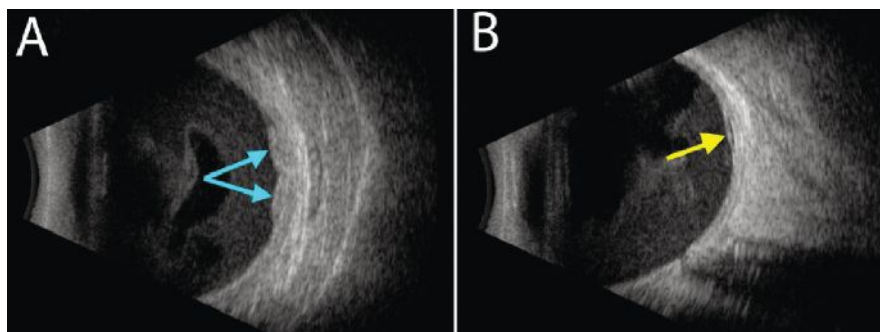


Visit us at Vision Expo West 2022, booth F10043.  
Or schedule a demo online at [hsoctopus.com](https://hsoctopus.com).  
© 2022 Haag-Streit USA. All Rights Reserved.

\* Available on the Octopus 600 Pro



Look closer. See further.



**Ultrasonography shows a hyperechoic, lobular and solid-appearing area of subretinal thickening (A, blue arrows) with an adjacent small pocket of subretinal fluid (B, yellow arrow). Diffuse hemorrhage can be seen in the vitreous cavity in both images.**

during the patient’s one-month return visit, she noted significant improvement in vision, from 20/200 to 20/60. Three additional anti-VEGF injections were administered over the following four months. The lesion shrunk considerably, leaving behind fibrosis and mild exudation. The retina reattached as fluid resolved, and the visual acuity at last follow-up was 20/50, her baseline acuity prior to the hemorrhage.

She continues to be managed by her OD for glaucoma and sees the ocular oncologist/retinal specialist every four to six months to monitor for stability.

### Discussion

A PubMed search for PEHCR reveals the first article with this condition’s name was published in 1980, but the author references other journal entries describing similar entities from as early as 1961.<sup>3</sup> There was then a general paucity of articles discussing PEHCR until the early 2000s, when it began to gain more attention. In 2003, a study determined that PEHCR was the second most common diagnosis for lesions referred to as suspected melanomas, popularizing the term “pseudomelanoma” for PEHCR.<sup>4</sup>

The condition is described as a peripheral retinal disorder leading to pigment epithelial detachment with subretinal and/or sub-RPE hemorrhage and exudation. At times, the degenerative changes are asymptomatic due to their peripheral location. Other times, sight-threatening complications can occur and include breakthrough vitreous hemorrhaging and exudative retinal

detachments. Studies show that the average age at presentation is approximately 77 to 82, and PEHCR is more common in females.<sup>5,6</sup> Furthermore, PEHCR has been associated with systemic hypertension and anticoagulant use.<sup>7</sup>

Hemorrhagic lesions are typically located in the temporal periphery, and they may be dome-shaped, plateau-shaped or multilobular, as was the case with our patient. Ultrasonography is often completed for further characterization of these lesions, which will reveal primarily solid lesions or acoustically hollow lesions, depending on whether the pigment epithelial detachments are filled with hemorrhage or serous fluid.

Intrinsic vascular pulsations are lacking in PEHCR, as this finding would suggest a neoplastic lesion. Fluorescein and indocyanine green angiography can also help evaluate for the presence of pathologic choroidal neovascular networks.<sup>5,8</sup>

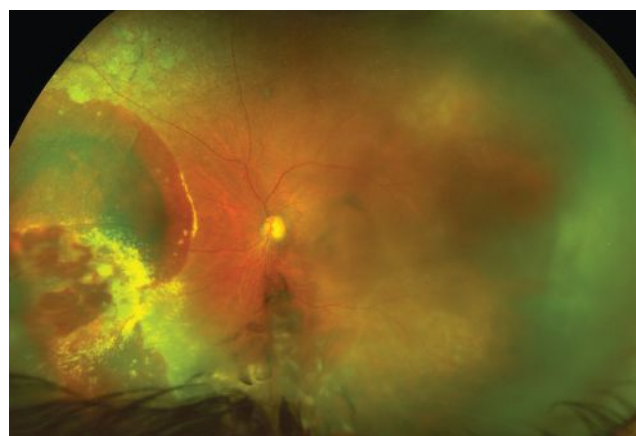
The most commonly employed treatment strategies for patients with PEHCR include monitoring without intervention as most lesions regress on their own, intravitreal anti-VEGF injections, photodynamic therapy, laser photocoagulation or a combination of

therapies.<sup>6,8</sup> There exists no randomized, prospective trial for therapeutic options, but treating patients with high-risk characteristics (e.g., vitreous hemorrhage and exudative macular involvement) more aggressively is highly recommended.<sup>6</sup>

### Takeaways

This case presented an interesting diagnostic challenge, given the patient’s medical history. As optometrists, we should be aware of this disease manifestation and consider it as a differential in cases of hemorrhagic chorioretinal lesions, as it can mimic metastatic or malignant tumors. ■

1. Chee YE, Mudumbai R, Saraf SS, et al. Hemorrhagic choroidal detachment as the presenting sign of uveal melanoma. *Am J Ophthalmol Case Rep.* 2021;23:101173.
2. Fraser DJ Jr., Font RL. Ocular inflammation and hemorrhage as initial manifestations of uveal malignant melanoma. Incidence and prognosis. *Arch Ophthalmol.* 1979;97(7):1311-4.
3. Annesley WH Jr. Peripheral exudative hemorrhagic chorioretinopathy. *Trans Am Ophthalmol Soc.* 1980;78:321-64.
4. Shields JA, Mashayekhi A, Ra S, Shields CL. Pseudomelanomas of the posterior uveal tract: the 2006 Taylor R. Smith Lecture. *Retina.* 2005;25(6):767-71.
5. Mantel I, Uffer S, Zografos L. Peripheral exudative hemorrhagic chorioretinopathy: a clinical, angiographic, and histologic study. *Am J Ophthalmol.* 2009;148(6):932-8.
6. Zicarelli F, Preziosa C, Staurengi G, Pellegrini M. Peripheral exudative haemorrhagic chorioretinopathy: a widefield imaging study. *Br J Ophthalmol.* 2021;105(10):1410-4.
7. Kim YT, Kang SE, Lee JH, Chung SE. Peripheral exudative hemorrhagic chorioretinopathy in Korean patients. *Jpn J Ophthalmol.* 2010;54(3):227-31.
8. Shields CL, Salazar PF, Mashayekhi A, Shields JA. Peripheral exudative hemorrhagic chorioretinopathy simulating choroidal melanoma in 173 eyes. *Ophthalmology.* 2009;116(3):529-35.



**The left eye at the one-month follow-up after a single anti-VEGF intravitreal injection. The vitreous hemorrhage has cleared partially, allowing for better visualization of the nasal retina. You can still make out the extensive hemorrhaging and exudation from the lesion. The vision at this visit improved to 20/60.**

# EXPAND YOUR PRACTICE CAPABILITIES WITH SANTINELLI EDGERS



Cut your lab costs by up to 30%



Deliver quality eyewear faster

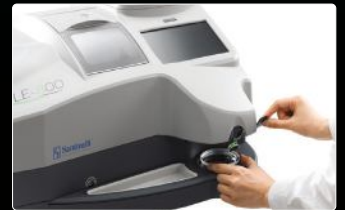

Attract & retain more patients



Control the quality of your finished eyewear

Let our experts provide a FREE customized ROI analysis to see if in-office finishing is right for your practice.



## ATTENDING VISION EXPO WEST?

Visit us at booth #F11087 to demo our award-winning line of lens edging equipment and take advantage of our incredible savings.

LEARN MORE AT [800.644.EDGE \(3343\)](tel:800644EDGE) | [SANTINELLI.COM](http://SANTINELLI.COM)



**Santinelli**<sup>®</sup>  
INTERNATIONAL  
A DIVISION OF ADVANCING EYECARE™

PERFECTING THE ART  
INSIDE THE FRAME™

PROUD WINNER FOR  
13 CONSECUTIVE YEARS

2021 **EYEVOTE** 2020 VM



# Lights in the Fog

*This patient's hypopigmented lesion led to the diagnosis.*

BY RAMI ABOUMOURAD, OD, AND ALBERTA PENGU, BS  
MIAMI

**A** 34-year-old male from Venezuela presented to our tertiary care center with a two-day history of redness, photophobia and worsening vision in his left eye. He was asymptomatic in his right eye. His past ocular history was significant for at least one similar episode in the left eye eight years prior.

His visual acuity was 20/20 OD and 20/150 OS with no pinhole improvement. Pupils were equally round and reactive without a relative afferent pupillary defect. His confrontation visual fields were full to careful finger counting, and there were no extraocular motility restrictions. His intraocular pressures were 18mm Hg OD and 13mm Hg OS.

Fundus photos and OCT images are available for review (Figures 1-4). Slit lamp examination was unremarkable OD; OS, there was 2+ diffuse conjunctival hyperemia with limbal flush and 2+ anterior chamber cell.

There were also trace posterior vitreous cells with mild posterior vitreous haze (Figure 3).

## Take the Retina Quiz

1. Which of the following is false regarding Figures 3 and 4?

- a. There are posterior vitreous cells.
- b. There is papillitis.
- c. There is multifocal outer-retinal and retinal pigment epithelium (RPE) atrophy of the macula.
- d. There are outer-retinal cystic changes of the macula.

2. What is the most likely diagnosis?

- a. Syphilis.
- b. Toxoplasmosis.
- c. Tuberculosis.
- d. Viral retinitis.

3. Which treatment option is most appropriate for this patient?

- a. Oral sulfamethoxazole/trimethoprim and clindamycin.
- b. Triple therapy (oral pyrimethamine, sulfadiazine, prednisone and folic acid supplementation).

- c. Triple therapy plus oral clindamycin.
- d. All of the above are reasonable treatment options.

4. Which of the following is true regarding the diagnosis of this patient?

- a. It must be confirmed with serologic studies.
- b. It is primarily a non-granulomatous anterior uveitis with posterior spillover.
- c. It is the most common cause of posterior uveitis worldwide.
- d. The primary site of infection is the choroid.

5. Which of the following is not a typical feature of the patient's condition?

- a. Dense vitritis.
- b. Papillitis.
- c. Posterior or panuveitis.
- d. Preseptal cellulitis.

*For answers, see page 98.*

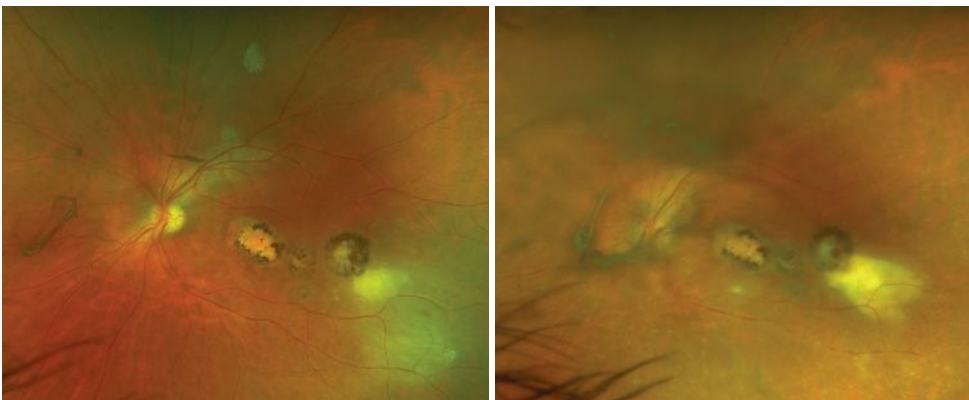
## Diagnosis

Fundus exam OS revealed multifocal pigmented macular scars involving the fovea (Figures 1 and 4). There was a presumably new, hypopigmented lesion in the temporal macula with more prominent overlying vitritis adjacent to the strand of hyperpigmented lesions. There was no retinal vasculitis or papillitis at that time (Figure 1).

His panuveitis was representative of a reactivation of toxoplasmosis. Posterior uveitis serology was obtained, and serum *T. gondii* IgG titers were elevated with PCR confirmation of *T. gondii* DNA, which also ruled out viral causes of necrotizing retinitis.

## Discussion

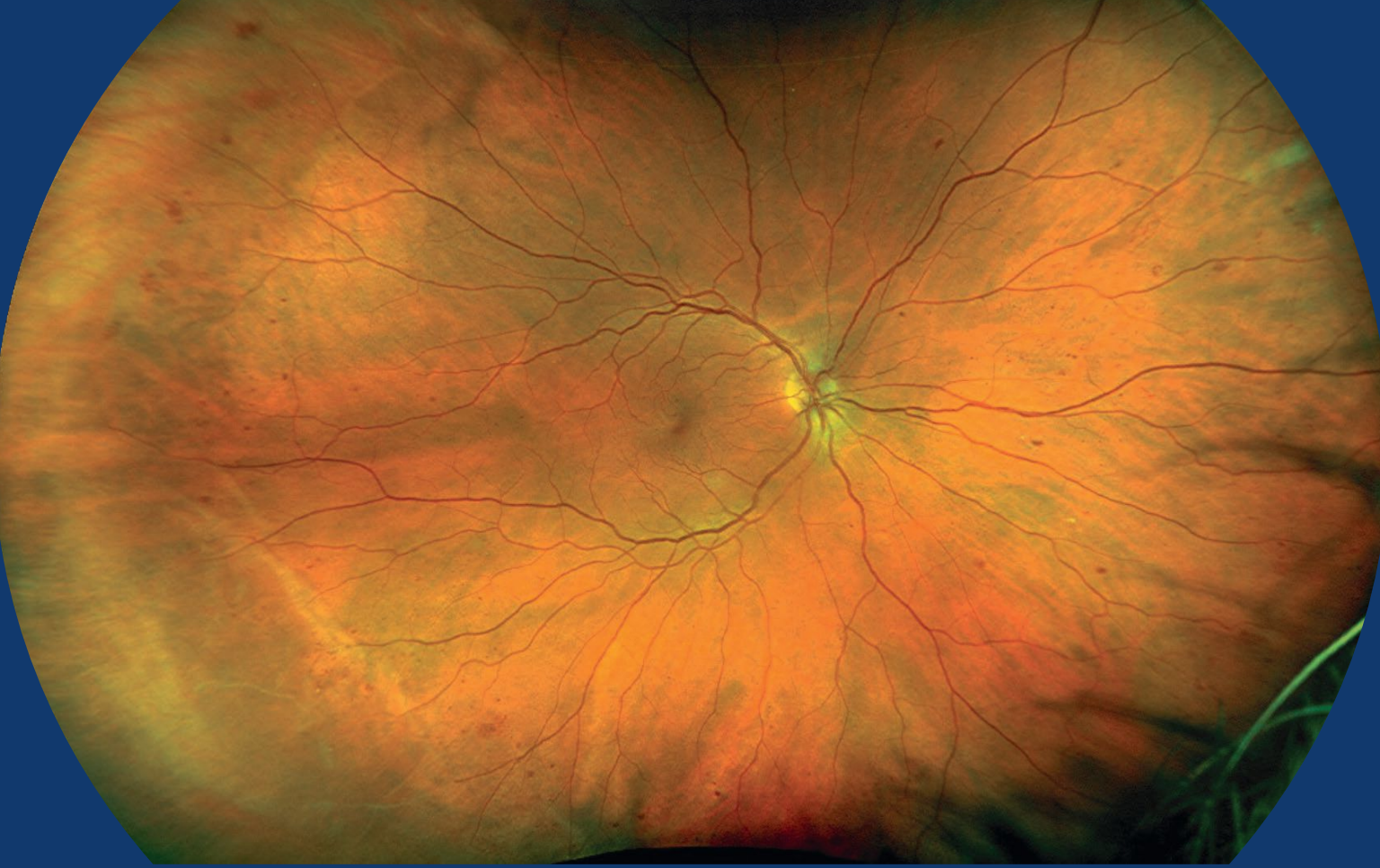Ocular toxoplasmosis is the most common cause of posterior uveitis and is secondary



**Figs. 1 and 2.** Ultra-widefield photo of the left eye on presentation and on follow-up four days later.

### About Dr. Dunbar

Dr. Dunbar is the director of optometric services and optometry residency supervisor at the Bascom Palmer Eye Institute at the University of Miami. He is a founding member of the Optometric Glaucoma Society and the Optometric Retina Society. Dr. Dunbar is a consultant for Carl Zeiss Meditec, Allergan, Regeneron and Genentech.



# optomap<sup>®</sup> Improves Efficiency

The **ONLY** single-capture ultra-widefield retinal image, **optomap** improves practice flow and supports patient engagement.



Decrease patient visit time 33%<sup>1</sup>

**66%**  
MORE

Find 66% more pathology<sup>2</sup>



See 7% more patients<sup>3</sup>

[www.optos.com](http://www.optos.com)

1. Successful interventions to improve efficiency and reduce patient visit duration in a retina practice; Retina, 2021. 2. Comparison of image-assisted versus traditional fundus examination; Eye and Brain, 2013. 3. The Impact of Ultra-widefield Retinal Imaging on Practice Efficiency; US Ophthalmic Review, 2017.



to *T. gondii*, an obligate intracellular protozoan.<sup>1</sup> Patients tend to present with blurred vision, floaters and photophobia.<sup>1</sup> Clinical findings of ocular toxoplasmosis may include a posterior or panuveitis with diffuse or focal vitritis, papillitis, macular edema, retinal hemorrhage and retinal vasculitis/segmental retinal arteritis.<sup>1,2</sup>

Ocular toxoplasmosis is characterized by a unilateral focal area of necrotizing granulomatous retinochoroiditis obscured by overlying vitritis, classically termed as a “headlight in the fog.”<sup>1,2</sup> There may be adjacent hyperpigmented chorioretinal scars.<sup>1,2</sup>

Infection most commonly occurs in the retina and RPE, but tissue cysts (bradyzoites) have also been isolated in other ocular structures, including the choroid, vitreous, iris and optic nerve.<sup>1,2</sup>

Segmental retinal arteritis is characterized as periarterial exudates and intra-arterial plaques that may resemble retinal emboli.<sup>2</sup> It can be present anywhere in the fundus and is otherwise a benign finding. This generally resolves without sequelae but can persist for months even after clinical resolution of intraocular inflammation.<sup>3-5</sup>

As the retinochoroiditis resolves, the disorganization of the retinal layers and hyperpigmentation produces the appearance of an inactive toxoplasmosis scar.<sup>2</sup> The typical presentation of congenital toxoplasmosis is a unilateral macular scar.<sup>2</sup> Reactivation can be seen in up to two-thirds of patients and often occurs adjacent to the site of primary infection due to the rupture of intraretinal cysts and local immune reaction.<sup>1,2,6</sup> Decreased visual function secondary to toxoplasmosis is typically related to macular or optic nerve involvement.<sup>1</sup>

Diagnosis is primarily clinical (no serologic confirmation required) but can be supported by lab testing.<sup>1,2,7</sup> Elevated serum IgG antibodies confirm past exposure but low titers do not rule it out.<sup>1,2</sup> Also, IgM titers may not be elevated at initial presentation.<sup>1,2,7</sup>

### Treatment

Tissue cysts are impenetrable by current anti-toxoplasmic drugs and can

remain viable indefinitely.<sup>1</sup> Still, toxoplasmosis is a self-limiting condition with treatment aimed at minimizing structural damage by modulating the inflammatory response.<sup>1,2,6</sup> Treatment is recommended for all immunocompromised patients as well

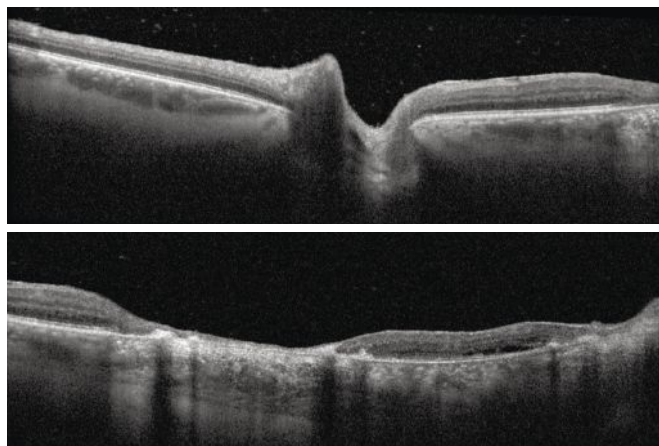
as immunocompetent patients with lesions in the posterior pole, adjacent to the optic disc or larger than two-disc diameters.<sup>6,8</sup>

“Triple therapy” for the treatment of toxoplasmosis includes the use of pyrimethamine, sulfadiazine and oral prednisone. Pyrimethamine requires folic acid supplementation to prevent aplastic anemia.<sup>1,2,6,9</sup> Bactrim DS (sulfamethoxazole 800mg and trimethoprim 160mg, Roche Pharmaceuticals) has a safer side effect profile compared with triple therapy, but its efficacy has been questioned. Long-term systemic prophylaxis with Bactrim DS can be considered in high-risk patients.<sup>10</sup> Clindamycin injections may be useful in recalcitrant cases.<sup>1,6</sup>

### Patient Care

There was macular involvement in our patient, and he was started on oral Bactrim DS two times daily, oral clindamycin 300mg three times daily, topical prednisolone acetate 1% every two hours OS and atropine sulfate 1% two times daily in the left eye.

He returned four days later for follow-up and demonstrated worsening of intraocular inflammation. There was increased vitritis, enlargement of the retinal lesion and new retinal vasculitis/segmental retinal arteritis (*Figure 2*). This prompted anterior chamber paracentesis to send an aqueous humor sample for polymerase chain reaction as well as administration of an intravitreal injection of clindamycin.



**Figs. 3 and 4. Spectralis OCT of the left optic nerve and left macula.**

The patient responded well to the adjuvant treatment and was later started on oral prednisone. He achieved quiescence but was continued on prophylactic Bactrim DS given his history of recurrence with macular involvement. ■

*Special thanks to Alberta Pengo, who helped contribute to this case. Alberta is a fourth-year optometry extern from New England College of Optometry.*

- Schachat AP, Wilkinson CP, Hinton DR, et al. *Ryan's Retina*, 6th Edition. Elsevier. 2018.
- Gass JDM. *Stereoscopic atlas of macular disease: a fundoscopic and angiographic presentation*. Saint Louis: Mosby, 1970.
- Chazalon E, Conrath J, Ridings B, Matonti F. Kyrieleis arteritis: report of two cases and literature review. *J Fr Ophthalmol*. 2013;36(3):191-6.
- Meier PG, Herbot CP, Jr., Wolfensberger TJ. Spectral domain optical coherence tomography for the characterization of kyrieleis exudates involving both the fovea and retinal vessels. *Klin Monbl Augenheilkd*. 2016;233(4):545-6.
- Pichi F, Veronese C, Lembo A, et al. New appraisals of Kyrieleis plaques: a multimodal imaging study. *Br J Ophthalmol* 2017;101(3):316-21.
- Yanoff M, Duker J. *Ophthalmology*, 5th Edition. Elsevier. 2019.
- Fekkar A, Bodaghi B, Touafek F, et al. Comparison of immunoblotting, calculation of the Goldmann-Witmer coefficient and real-time PCR using aqueous humor samples for diagnosis of ocular toxoplasmosis. *J Clin Microbiol*. 2008;46(6):1965-7.
- Holland GN, Lewis KG. An update on current practices in the management of ocular toxoplasmosis. *Am J Ophthalmol*. 2002;134(1):102-14.
- Eyles DE, Coleman N. Antibiotics in the treatment of toxoplasmosis. *Am J Trop Med Hyg*. 1953;2(1):64-9.
- Fernandes Felix JP, Cavalcanti Lira RP, Grupenmacher AT, et al. Long-term results of trimethoprim-sulfamethoxazole vs. placebo to reduce the risk of recurrent toxoplasma gondii retinochoroiditis. *Am J Ophthalmol*. 2020;213:195-202.


### ABOUT THE AUTHOR



**Dr. Aboumourad** currently practices at Bascom Palmer Eye Institute in Miami. He has no financial disclosures.

# IT'S CLEAR

The user-friendly way to get patients to believe your recommendations and follow through.



**EyeRes**<sup>™</sup>  
Digital Imaging Systems  
by **TelScreen**

[www.TelScreen.com](http://www.TelScreen.com)





BY PAUL M. KARPECKI, OD  
CHIEF CLINICAL EDITOR

## OCULAR SURFACE REVIEW

# Revisit a Steroid Alternative

*Acthar Gel, an injectable therapy that activates melanocortin pathways, may be a saving grace for some of your patients.*

In all medical specialties, doctors have long relied on glucocorticoid therapy. However, it's well-known that systemic glucocorticoid treatments (e.g., oral prednisone) affect other cells in the body. In some patients, these drugs can produce side effects that may include diabetes, impaired wound healing, gastric ulcers, weight gain, cardiovascular disease, bone loss, muscle wasting and neuropsychiatric issues.<sup>1-3</sup> We also know that glucocorticoids create additional adverse effects in the eye, including increased intraocular pressure and potential glaucoma, cataract formation, central serous chorioretinopathy, corneal thinning, increased risk of infection and impaired wound healing.<sup>1</sup>

Unlike steroids, the innate melanocortin (MC) pathways help the immune system regulate itself within the ocular microenvironment. For example, aqueous humor suppresses activation of immune cells that mediate hypersensitivity.<sup>1,4</sup> In addition, aqueous humor-treated immune cells suppress hypersensitivity-mediated T-cells.<sup>1,5</sup> Because the  $\alpha$ -melanocyte-stimulating hormone ( $\alpha$ -MSH) is present in the aqueous humor, it helps prevent the potential damages of inflammation.

Beyond the aqueous humor, cells in the iris, ciliary body and retinal pigment epithelium also play a role in immune privilege and inflammation suppression relative to the MC pathways.<sup>1</sup> Given these distinct advantages and the fact that all five MC receptors affect the eyes,  $\alpha$ -MSH-based treatments are a reasonable alternative to glucocorticoid therapy worthy of our consideration.

### The Melanocortin System

This neuronal pathway is made up of a collection of multiple peptides, including the adrenocorticotropic hormone (ACTH), as well as five MC receptors, which are expressed in various cells and tissues throughout the body (Figure 1).<sup>1</sup> The MC system controls inflammation by releasing corticotropin-releasing hormone, which in turn stimulates pro-

opiomelanocortin production, thereby generating the MC peptides.<sup>1</sup> MCs have many functions, which are carried out when they bind to one of five known MC receptors.<sup>1</sup> Each of these receptors is expressed in a specific cell type.<sup>1</sup> The adrenocorticotropic hormone, in particular, stimulates the MC receptor 2 on the adrenal cortex, which thereby produces glucocorticoids. The other four MC receptors are found in the eye (Figure 2). Glucocorticoids have anti-inflammatory effects, but they also act as immune modulators.<sup>1</sup>

### MC Pathway-based Treatment

Repository corticotropin injection (RCI) is a highly purified formulation of ACTH in 16% gelatin that provides sustained release after subcutaneous (or intramuscular) injection.<sup>6</sup> The most common RCI—Acthar Gel (Mallinckrodt Pharmaceuticals)—was first FDA approved in 1952; yet, for decades, it hasn't been commonly used due to potential reasons such as poor marketing, assumptions that the product is outdated and the requirement of self-administered biweekly injections. Given new, promising research on RCI and

considering the known potential adverse effects of traditional steroids, this form of therapy is becoming more frequently used in multiple areas of medicine, including optometry.

Acthar engages MC receptors expressed in immune, organ and tissue cells throughout the body and is thought to produce both an indirect anti-inflammatory effect and a direct cell modulation effect (Figure 3).<sup>6-11</sup> The drug is approved for 19 indications across

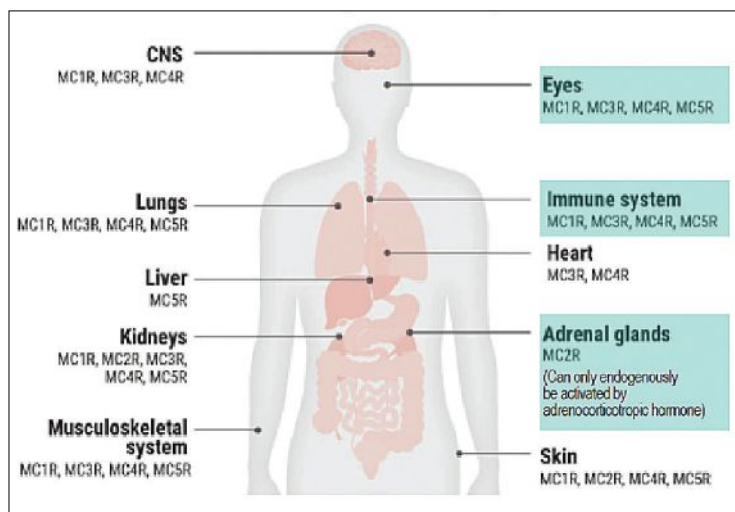


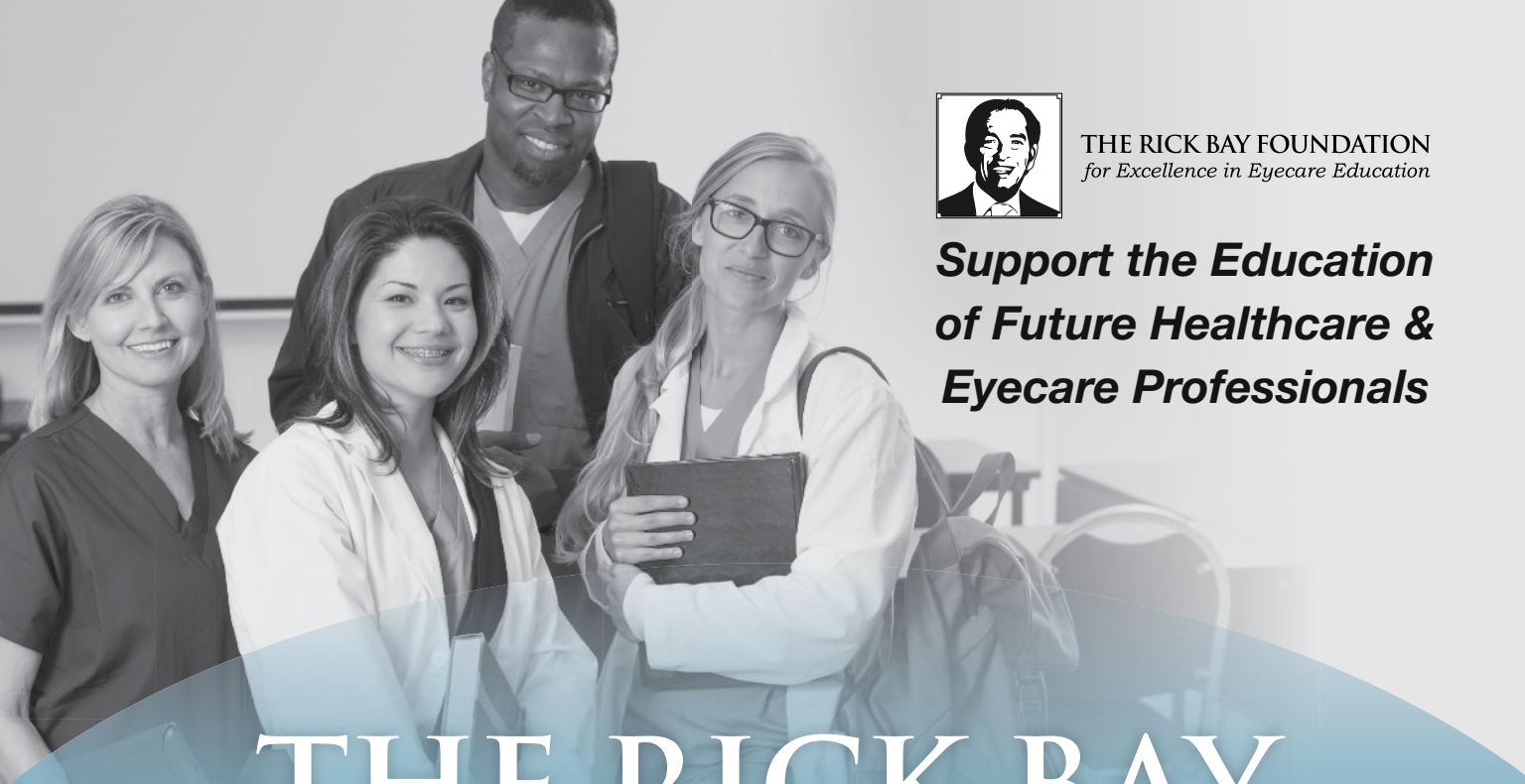
Fig. 1. The various MC receptors throughout the body.

Photo: Taylor/AW et al.

About  
Dr. Karpecki

Dr. Karpecki is the director of Cornea and External Disease for Kentucky Eye Institute, associate professor at KYCO and medical director for the Dry Eye Institutes of Kentucky and Indiana. He is also the Chief Clinical Editor for *Review of Optometry* and chair of the New Technologies & Treatments conferences. He consults for a wide array of ophthalmic clients, including ones discussed in this article. Dr. Karpecki's full disclosure list can be found in the online version of this article at [www.reviewofoptometry.com](http://www.reviewofoptometry.com).





THE RICK BAY FOUNDATION  
*for Excellence in Eyecare Education*

**Support the Education  
of Future Healthcare &  
Eyecare Professionals**

# THE RICK BAY FOUNDATION

*for Excellence in Eyecare Education*

Scholarships are awarded to advance the education of students in both **Optometry** and **Ophthalmology**, and are chosen by their school based on qualities that embody Rick's commitment to the profession, including integrity, compassion, partnership and dedication to the greater good.

## INTERESTED IN BEING A PARTNER WITH US?

[www.rickbayfoundation.org](http://www.rickbayfoundation.org)

*(Contributions are tax-deductible in accordance  
with section 170 of the Internal Revenue Code.)*

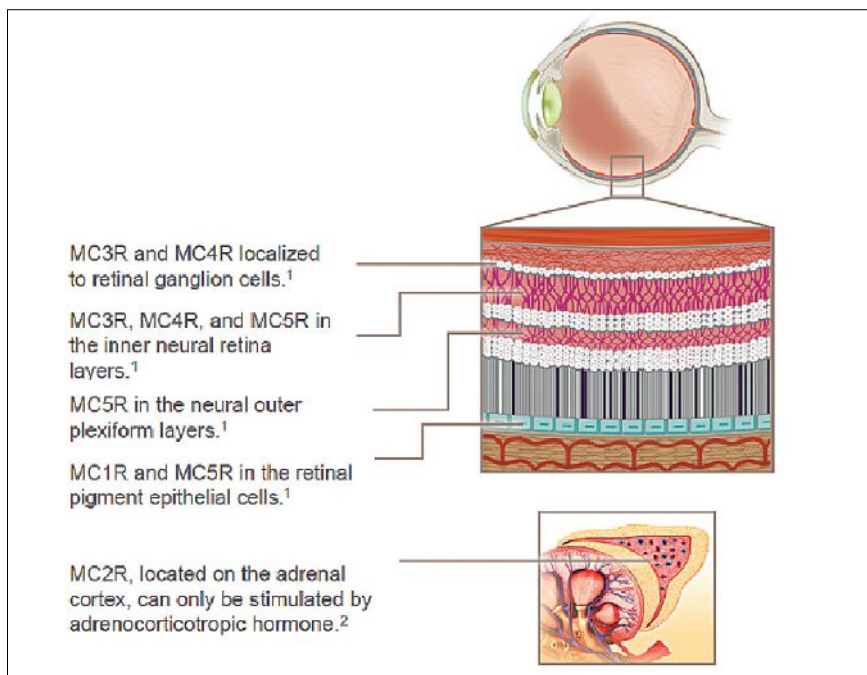
### **ABOUT RICK**

Rick Bay served as the publisher of *The Review Group* for more than 20 years. To those who worked for him, he was a leader whose essence was based in a fierce and boundless loyalty. To those in the industry and the professions he served, he will be remembered for his unique array of skills and for his dedication to exceeding the expectations of his customers, making many of them fast friends.



*(The Rick Bay Foundation for Excellence in Eyecare Education is a nonprofit, tax-exempt organization under section 501(c)(3) of the Internal Revenue Code.)*

Photo: Catania A, et al.



**Fig. 2. MC receptors are expressed by immune cells, as well as in ocular cells, retinal pigment epithelial cells, retinal ganglion cells and the neural outer plexiform layer.**

nine disease categories.<sup>12</sup> For example, in neurology it's used for the treatment of infantile spasms in infants and children under two years of age as well as for acute exacerbations of multiple sclerosis in adults. In pulmonology, it's used to treat symptomatic sarcoidosis. In nephrology, it's used to induce a diuresis or a remission of proteinuria in nephrotic syndrome. In rheumatology, it can help patients who have arthritis or lupus erythematosus.

Importantly, we can also turn to this therapy to treat patients with ocular disease. Currently, Acthar Gel is indicated for the treatment of severe acute and chronic allergic and inflammatory processes involving the eye and its adnexa, such as keratitis, iritis, iridocyclitis, diffuse posterior uveitis and choroiditis, optic neuritis, chorioretinitis and anterior segment inflammation.<sup>6,13-17</sup>

Eye care practitioners don't need to be responsible for administering the injections or teaching patients how to inject themselves. Mallinckrodt offers a service where nurses can provide the initial injections at a patient's home and show them how to do it on their own.






Contraindications include patients with uncontrolled hypertension or uncontrolled diabetes. Patients should be educated regarding the low incidence but potential for insomnia or, alternatively, lethargy. Since patients are typically administering biweekly subcutaneous injections themselves, there is always the potential of injection site irritation. Research shows that Acthar produces about 3% of the systemic cortisol effect compared with systemic prednisone.<sup>18</sup> In my opinion, since it's a combination of ACTH and other natural pituitary peptides, it essentially "resets" the immune system in helping patients with treatment-resistant inflam-

matory eye conditions, including keratitis, uveitis and keratoconjunctivitis sicca (KCS).

### Takeaways for Optometry

In a recent study that observed 91 patients with a several-year history of uveitis that did not adequately respond to previously attempted treatments, most patients showed improvement after initiating Acthar.<sup>6</sup> In another study, 35 patients with severe, treatment-resistant KCS received Acthar twice weekly for 12 weeks and showed significantly reduced corneal and conjunctival staining, improved dry eye symptoms and, most impressively, improved quality-of-life scores at two, four, six and 12 weeks.<sup>19</sup> Few drugs have shown this level of efficacy on quality of life using the 57-item IDEEL questionnaire (Alcon), especially with such minimal side effects.

Given Acthar's safety profile and the challenges we often face in treating many of the conditions for which it is indicated, we should consider it in three circumstances, which I refer to as the "three Rs"—resisters, rebounders and responders. The first group of patients who may be candidates for Acthar Gel include those who are resistant to treatment, meaning you've

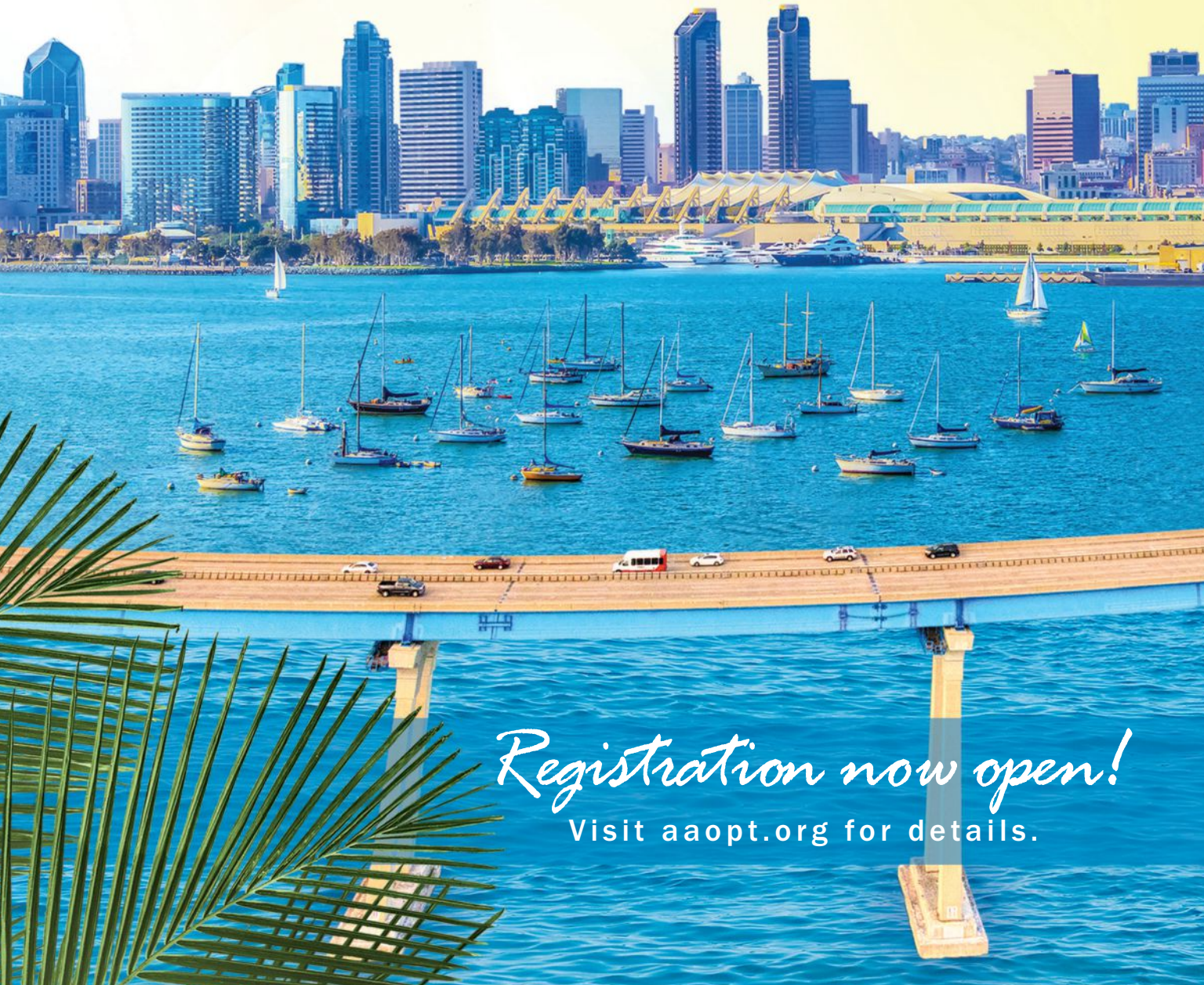	<p><b>T-Regulatory Cells   MC1R, MC5R<sup>3-8</sup></b></p> <ul style="list-style-type: none"> <li>• Reduction in proinflammatory cytokines and mediators.</li> <li>• Increase in anti-inflammatory cytokines and mediators.</li> <li>• Increased conversion of T-helper cells to T-regulatory cells.</li> </ul>
	<p><b>Cytokines   GROWTH FACTORS/ADHESION MOLECULES<sup>4-6,8-13</sup></b></p> <ul style="list-style-type: none"> <li>• Reduction in proinflammatory cytokines and mediators.</li> <li>• Increase in anti-inflammatory cytokines and mediators.</li> <li>• Decrease in adhesion molecules.</li> </ul>
	<p><b>Dendritic Cells   MC1R<sup>3,6,10</sup></b></p> <ul style="list-style-type: none"> <li>• Induction of tolerogenic dendritic cells.</li> <li>• Decrease in costimulatory molecules to decrease T cell stimulation.</li> </ul>
	<p><b>Macrophages   MC1R, MC3R, MC5R<sup>8,10,11,14</sup></b></p> <ul style="list-style-type: none"> <li>• Reduction in proinflammatory cytokines and mediators.</li> <li>• Increase in anti-inflammatory cytokines and mediators.</li> <li>• Inhibits TNF-α release.</li> </ul>
	<p><b>B Cells   MC1R, MC5R<sup>11</sup></b></p> <ul style="list-style-type: none"> <li>• Decreased activity.</li> </ul>

**Fig. 3. Engaging all five MC receptors may have an impact on immune cells and cytokines.**

Photo: Ahmed Tj, et al.

*Centennial Celebration*  
**ACADEMY** **20**  
**san diego** **22**  
OCTOBER 26-29, 2022

Presented by AMERICAN ACADEMY of OPTOMETRY



*Registration now open!*

Visit [aaopt.org](http://aaopt.org) for details.

Practice For Sale



Practice Sales • Appraisals • Consulting  
www.PracticeConsultants.com

PRACTICES FOR SALE  
NATIONWIDE

Visit us on the Web or call us to learn more about our company and the practices we have available.

info@PracticeConsultants.com

925-820-6758

www.PracticeConsultants.com

Targeting Optometrists?

CLASSIFIED ADVERTISING WORKS

- JOB OPENINGS
- CME PROGRAMS
- PRODUCTS & SERVICES
- AND MORE...

Contact us today for classified advertising:  
Toll free: 888-498-1460  
E-mail: sales@kerhgroup.com

# REVIEW of OPTOMETRY

Do you have  
Products and  
Services for sale?

CLASSIFIED  
ADVERTISING WORKS

- JOB OPENINGS
- CME PROGRAMS
- PRODUCTS
- AND MORE...

Contact us today for  
classified advertising:  
Toll free: 888-498-1460  
E-mail: sales@kerhgroup.com

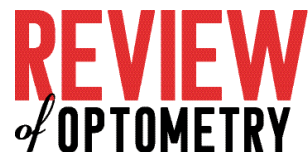

## Do you have CE Programs?

CONTACT US TODAY  
FOR CLASSIFIED  
ADVERTISING

Toll free:  
888-498-1460

E-mail:  
sales@kerhgroup.com



# REVIEW of OPTOMETRY

## Targeting Optometrists?

CLASSIFIED ADVERTISING WORKS

- JOB OPENINGS
- CME PROGRAMS
- PRODUCTS & SERVICES
- AND MORE...

Contact us today for classified advertising:  
Toll free: 888-498-1460  
E-mail: sales@kerhgroup.com



tried multiple treatment options that failed to resolve the keratitis or uveitis. The second group consists of patients who experience rebound keratitis or uveitis after you taper or discontinue their medications, such as topical steroids. The third group of patients who may benefit from treatment with Acthar Gel are steroid responders. In one study, 50% of patients with uveitis were off steroids by six weeks, and 80% no longer required steroids after three months following Acthar initiation.<sup>6,20</sup>

Consider Acthar a later option in your armamentarium for recalcitrant cases of keratitis, including KCS, for uveitis management in steroid responders and for keratitis or uveitis rebounders. Many patients who also suffer from autoimmune conditions seem to do well ocularly and systemically with Acthar. It can be a valuable tool for those patients with few remaining options. ■

- Clemson CM, Yost J, Taylor AW. The role of Alpha-MSH as a Modulator of ocular immunobiology exemplifies mechanistic differences between melanocortins and steroids. *Ocul Immunol Inflamm.* 2017;25(2):179-89.
- Schacke H, Docke WD, Asadullah K. Mechanisms involved in the side effects of glucocorticoids. *Pharmacol Ther.* 2002;96(1):23-43.
- Harris E, Tiganescu A, Tubeuf S, et al. The prediction and monitoring of toxicity associated with long-term systemic glucocorticoid therapy. *Curr Rheumatol Rep.* 2015;17(6):513.
- Kaiser CJ, Ksander BR, Streilein JW. Inhibition of lymphocyte proliferation by aqueous humor. *Regional Immunology.* 1989;2(1):42-9.
- Nishida T, Taylor A. Specific aqueous humor factors induce activation of regulatory T cells. *Investigative Ophthalmology & Visual Science.* 1999;40(10):2268-74.
- Nelson WW, Lima AF, Kranyak J, et al. Retrospective medical record review to describe use of repository corticotropin injection among patients with uveitis in the United States. *J Ocul Pharmacol Ther.* 2019;35(3):182-88.
- Catania A, Lonati C, Sordi A, Carlin A, Leonardi P, Gatti S. The melanocortin system in control of inflammation. *ScientificWorldJournal.* 2010;10:1840-53.
- Wright D, Fitch R. Repository corticotropin injection (H.P. Acthar Gel) enhances remyelination after cuprizone-induced demyelination. *NDM04. Int J MS Care.* 2019a;21(suppl 1):61-62.
- Olsen NJ, Decker DA, Higgins P, et al. Direct effects of HP Acthar Gel on human B lymphocyte activation in vitro. *Arthritis Res Ther.* 2015;17:300.
- Healy LM, Jang JH, Lin YH, Rao V, Antel JP, Wright D. Melanocortin receptor-mediated anti-inflammatory effect of repository corticotropin injection on human monocyte-derived macrophages. *Mult Scler J.* 2017;23(suppl 3):777.
- Wright D, Zweifel B, Sharma P, Galen K, Fitch R. Reduced steroidogenic activity of repository corticotropin injection induces a distinct cytokine response following T cell activation in vivo (EULAR abstract AB0082). *Ann Rheum Dis.* 2019b;78(suppl 2):1504.
- Acthar Gel. Repository corticotropin injection (Prescribing Information). Mallinckrodt ARD LLC.
- H.P. Acthar Gel (repository corticotropin injection) prescribing information. Mallinckrodt Pharmaceuticals. 2017.
- ClinicalTrials.gov. Adrenocorticotropic hormone (ACTH) for post-op inflammation in proliferative vitreoretinopathy (PVR). Updated August 10, 2022. <https://clinicaltrials.gov/ct2/show/NCT03727776>. Accessed July 20, 2022.
- ClinicalTrials.gov. Clinical efficacy of H.P. Acthar Gel 80 U/mL to improve the signs and symptoms in subjects with dry eye disease. January 28, 2021. <https://clinicaltrials.gov/ct2/show/NCT03287635>. Accessed July 20, 2022.
- ClinicalTrials.gov. A clinical study to evaluate the potential role of ACTH Gel in patients with scleritis (ATLAS). Updated July 12, 2022. <https://clinicaltrials.gov/ct2/show/NCT03465111>. Accessed July 20, 2022.
- ClinicalTrials.gov. Efficacy and safety of H.P. Acthar Gel in adults with retinal vasculitis. September 12, 2019. <https://clinicaltrials.gov/ct2/show/NCT03066869>. Accessed July 20, 2022.
- Bomback AS, Tumlin JA, Baranski J, et al. Treatment of nephrotic syndrome with adrenocorticotropic hormone (ACTH) gel. *Drug Des Devel Ther.* 2011;5:147-53.
- Grieco J, McLaurin EB, Ousler GW, et al. Topline results from a multicenter, open-label, phase 4 study of repository corticotropin injection in patients with treatment-resistant severe non-infectious keratitis. *Invest Ophthalmol Vis Sci.* 2021;62(8):1275.
- Madan A, Mijovic-Das S, Stankovic A, et al. Acthar Gel in the treatment of nephrotic syndrome: a multicenter retrospective case series. *BMC Nephrol.* 2016;17:37.

## ADVERTISER INDEX

This index is published as a convenience and not as part of the advertising contract. Every care will be taken to index correctly. No allowance will be made for errors due to spelling, incorrect page number, or failure to insert.

Acuity Pro.....	61
.....(580) 243-1301	
.....info@acuitypro.com	
.....www.acuitypro.com	
Alcon.....	100
.....www.alcon.com	
Alcon.....	13 & 14
.....www.alcon.com	
Alcon.....	64 & 65
.....www.alcon.com	
Bausch + Lomb.....	11
.....www.bausch+lomb.com	
Bausch + Lomb.....	69
.....www.bausch+lomb.com/professional	
Bausch + Lomb.....	Cover Tip
.....www.bausch+lomb.com	
Coburn Technologies.....	58
.....(800) COBURN-1	
.....www.coburntechnologies.com	
CooperVision.....	27
.....www.cooper-vision.com	
CooperVision.....	99
.....www.cooper-vision.com	

DGH Technologies, Inc.....	70 & 71
.....www.dghtechnology.com	
Eye Designs.....	23
.....(800) 346-8890	
.....www.eyedesigns.com	
Haag-Streit USA.....	85
.....www.haag-streit.com	
Icare USA.....	53
.....(888) 422-7313	
.....infoUSA@icare-world.com	
.....www.icare-world.com/USA	
Iveric Bio.....	29
.....www.ivericbio.com	
Johnson & Johnson.....	35
.....www.jnjvisionpro.com	
Johnson & Johnson.....	49
.....www.jnjvisionpro.com	
Lombart.....	31
.....800-LOMBART	
.....www.lombartinstrument.com	
Lunovus.....	33
.....(888) 670-7220	
.....www.lunovus.com	
M&S Technologies.....	41
.....(847) 763-0500	
.....www.mstech-eyes.com/vr-headset	
MacuHealth.....	83
.....www.macuhealth.com	
Nanodropper.....	67
.....(507) 405-5676	
.....pr@nanodropper.com	
.....www.nanodropper.com/ReviewOpt	

Nextgen.....	17
.....www.nextgen.com/better-OP	
Notal Vision.....	43
.....(855) 600-3112	
.....www.inresethome.com/doctor	
Novartis.....	Cover 2, Pages 3 & 4
.....www.novartis.com	
Oculus, Inc.....	19
.....www.myopia-master.com/us	
Olleyes.....	15
.....www.olleyes.com	
Optos.....	89
.....www.optos.com	
Orcam.....	59
.....eyefix@orcama.com	
.....www.orcam.com	
RegenerEyes.....	57
.....(877) 206-0707	
.....www.regenereyes.com	
Reichert Technologies.....	67
.....(888) 849-8955	
.....www.reichert.com	
Santinelli.....	87
.....(800) 644-EDGE	
.....www.santinelli.com	
Tarsus.....	24 & 25
.....www.linkallthelids.com	
TelScreen.....	91
.....www.TelScreen.com	
Thea Pharma.....	20
.....www.thea.com/eng	
Topcon.....	37
.....www.topconhealthcare.com/chronus	



# That Sinking Feeling

*A patient's vision has been blurry ever since a recent fall. You examine her and find this. What's going on?*

**A**n 84-year-old woman presented to the office with a chief complaint of blurry vision in her left eye, which she reported had begun after she encountered a fall about one month prior to her visit. She said the issue had gradually become worse over the ensuing month, making her left eye's vision

poor. She did not report any pain. She denied systemic disease or allergies of any kind.

### Clinical Findings

Her best-corrected entering visual acuities were 20/30 OD and 20/100 OS. Her external examination was unremarkable, with no evidence

of afferent pupillary defect; the pertinent biomicroscopic finding is demonstrated in the photograph. Her Goldmann applanation tonometry measured 17mm Hg OU and her angles were grade 4 using the Van Herick angle estimation method.

### For More Information

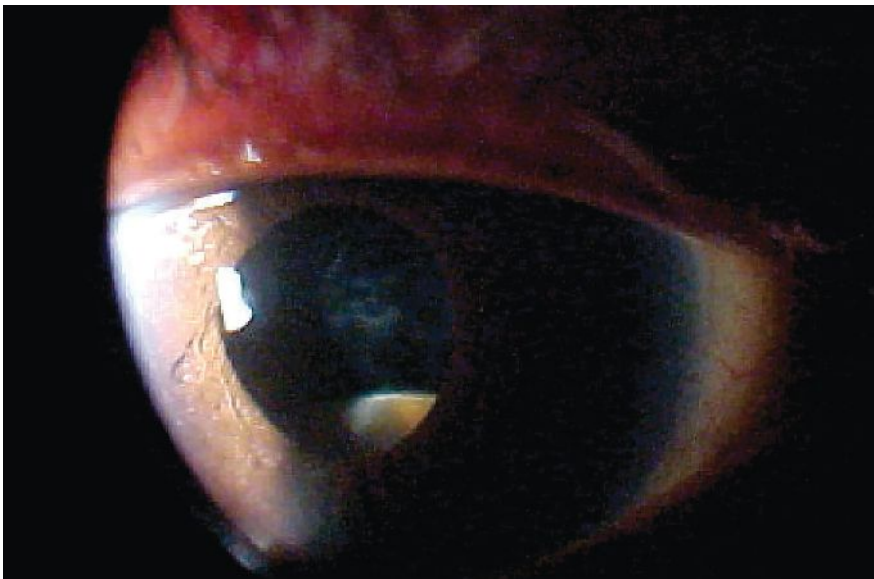
Additional studies ordered in this case included B-scan ultrasonography to image the relevant ocular structures. Anterior segment OCT was helpful in the same way. Laser interferometry was completed to evaluate the foveal potential for acuity.

Additional health history questions were also asked to rule out any potential connection of the issue at hand to undiagnosed systemic disease, of which there were many of concern, chief among them pseudoexfoliation, amyloidosis, Marfan's syndrome and Ehlers-Danlos syndrome.

### Your Diagnosis

What would be your diagnosis in this case? What is the patient's likely prognosis? To find out, please read the online version of this article at [www.reviewofoptometry.com](http://www.reviewofoptometry.com). ■

*Dr. Gurwood thanks Dr. Al Kabat for his contributions to this case.*



**This was the patient's presentation at the slit lamp. Does this explain her symptoms?**

**About Dr. Gurwood** Dr. Gurwood is a professor of clinical sciences at The Eye Institute of the Pennsylvania College of Optometry at Salus University. He is a co-chief of Primary Care Suite 3. He is attending medical staff in the department of ophthalmology at Albert Einstein Medical Center, Philadelphia. He has no financial interests to disclose.

## Retina Quiz Answers (from page 90)—Q1: b, Q2: b, Q3: d, Q4: c, Q5: d

### NEXT MONTH IN THE MAG

In October, we present an issue devoted to systemic diseases and the eye. Articles will include:

- The OD as PCP: Make Yourself a Vital Part of the Healthcare Team
- Thyroid Eye Disease Update: New Meds, New Methods
- The Diabetes Epidemic and Its Implications for DR Care
- How Sleep Disorders Impact Glaucoma, Diabetic Eye Disease and Ocular Surface Health
- Retinal Risks in Hypertensive Disease and Acute Stroke
- COVID's Consequences for the Eye

# MiSight<sup>®</sup> 1 day

is the **FIRST** and **ONLY** one for myopia control  
in age-appropriate children\*†

## The facts about MiSight<sup>®</sup> 1 day:



MiSight<sup>®</sup> 1 day is the **one and only FDA-approved**<sup>\*</sup> soft contact lens to slow the progression of myopia in children aged 8-12 at the initiation of treatment<sup>1†</sup>

**59%**

On average, there was a **59% reduction** in the rate of myopia progression over three years<sup>1‡</sup>



On average, children wearing MiSight<sup>®</sup> 1 day progressed **less than -1.00D** over 6 years<sup>2§</sup>

**NOW AVAILABLE**  
up to  
**-7.00D**



How can myopia control with MiSight<sup>®</sup> 1 day benefit your practice?

Learn more at [CooperVision.com](https://www.CooperVision.com).



CooperVision<sup>®</sup>

**MiSight<sup>®</sup> 1 day**  
for daily wear

**\*Indications for use:** MiSight<sup>®</sup> 1 day (omafilcon A) soft (hydrophilic) contact lenses for daily wear are indicated for the correction of myopic ametropia and for slowing the progression of myopia in children with non-diseased eyes, who at the initiation of treatment are 8-12 years of age and have a refraction of -0.75 to -4.00 diopters (spherical equivalent) with  $\leq 0.75$  diopters of astigmatism. The lens is to be discarded after each removal.

† Soft contact lens designed for myopia control in the U.S.

‡ Compared to a single vision 1 day lens over a 3 year period.

§ Fitted at 8-12 years of age at initiation of treatment.

**References:** 1. Chamberlain P, et al. A 3-year randomized clinical trial of MiSight<sup>®</sup> lenses for myopia control. *Optom Vis Sci.* 2019; 96(8): 556-67. 2. Chamberlain P, Arumugam B, Jones D, et al. Myopia Progression in Children wearing Dual-Focus Contact Lenses: 6-year findings. *Optom Vis Sci.* 2020; 97(E-abstract): 200038.



# Alcon Permanent Water Surface Technology


An exclusive category\* of contact lenses that go beyond SiHy alone



Water Gradient and  
SmarTears® Technologies

**DAILIES TOTAL1®**


Ultimate Comfort<sup>1</sup>  
FEELS LIKE NOTHING™



Water Gradient and  
CELLIGENT® Technologies

**TOTAL30®**

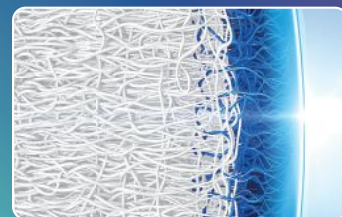
FEELS LIKE NOTHING,  
Even at Day 30<sup>2</sup>



SMARTSURFACE®  
Technology

**PRECISION1®**

Born from  
Water Gradient Technology  
at a Mainstream Price



We've gone beyond SiHy alone and permanently anchored water into our lens surface material for an outstanding lens-wearing experience.



Scan here to learn how Alcon's Permanent Water Surface Technology contact lenses are great for your patients and great for your practice.

\*As defined by Tyler's Quarterly in 2021.

**References:** 1. Maissa C, Nelson J; DeCenzo-Verbeten T, et al. Evaluation of the lubricity of delefilcon A daily disposable contact lenses (DAILIES TOTAL1®) after wear. Poster presented at the American Academy of Optometry Annual Conference; Nov. 2014, Denver, CO. 2. In a clinical study wherein patients (n=66) used CLEAR CARE® solution for nightly cleaning, disinfecting, and storing; Alcon data on file, 2021.

See product instructions for complete wear, care, and safety information. 

©2022 Alcon Inc. US-DT1-2200053

**Alcon**