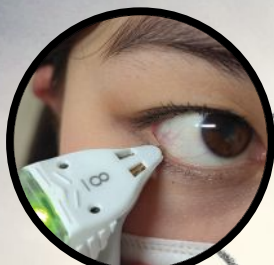
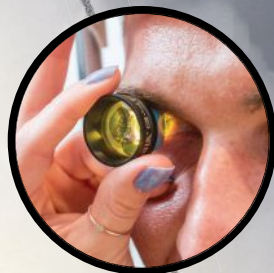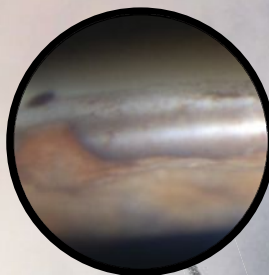


# REVIEW<sup>®</sup> of OPTOMETRY

February 15, 2022 • reviewofoptometry.com

Leadership in clinical care


9th Annual  
Diagnostic Skills  
& Techniques  
Issue



## MAKING THE

## OFFER PATIENTS AN EXCEPTIONAL LENS EXPERIENCE

Eye Care Professionals across the nation are sharing their success with Bausch + Lomb INFUSE<sup>®</sup>. See the impact it can have on your practice and patients, too.



SCAN CODE TO WATCH  
PEER TESTIMONIALS



HERE'S A SNEAK  
PEEK AT WHAT  
YOUR PEERS  
ARE SAYING:

"INFUSE<sup>®</sup> has great comfort, vision, and oxygen transmissibility."

- Dr Michelle Mumford

"The lens speaks for itself."


- Dr Scott Moscow

"INFUSE<sup>®</sup> helps address symptoms of contact lens dryness."

- Dr Kevin Nehaul

"INFUSE<sup>®</sup> has what I call 'the WOW factor.'"

- Dr Richard Goellner



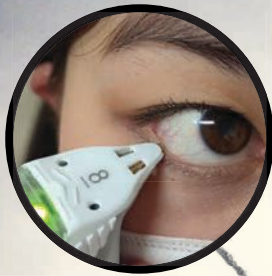
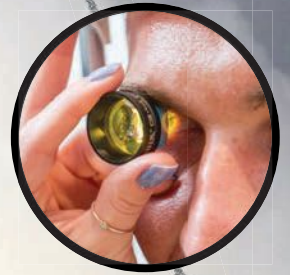Tackling the Barriers of Myopia Management, p. 38 • Retina Quiz: IS/OS in Distress, p. 98

# REVIEW<sup>®</sup> of OPTOMETRY

9th Annual  
Diagnostic Skills  
& Techniques  
Issue

February 15, 2022 • reviewofoptometry.com

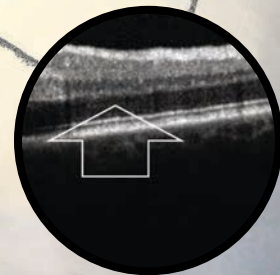
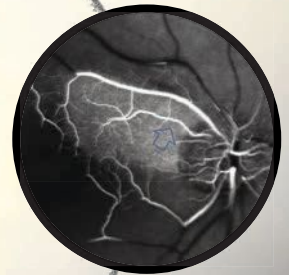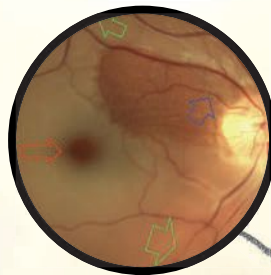
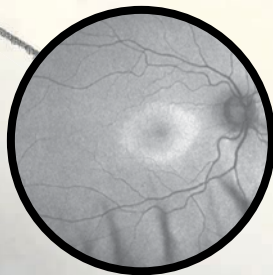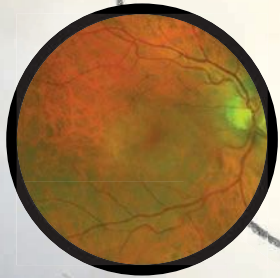
Leadership in clinical care



## MAKING THE

# DIAGNOSIS

*Experts offer their best advice on how to connect the dots.*



- Debating the Value of Diagnostic Tests, p. 46
- Gonioscopy: A Simple Tool, Too Often Forgotten, p. 56
- Elevate Your Dry Eye Practice, p. 64
- How to Triage Non-Traumatic Ocular Emergencies, p. 74
- Peripheral Retinal Imaging and Disease Assessment, p. 84—EARN 2 CE CREDITS



# MOST.

The contact lens with the  
**most moisture** among leading brands.

# MORE.

The toric daily disposable with  
**more parameters** than any leading brand.\*

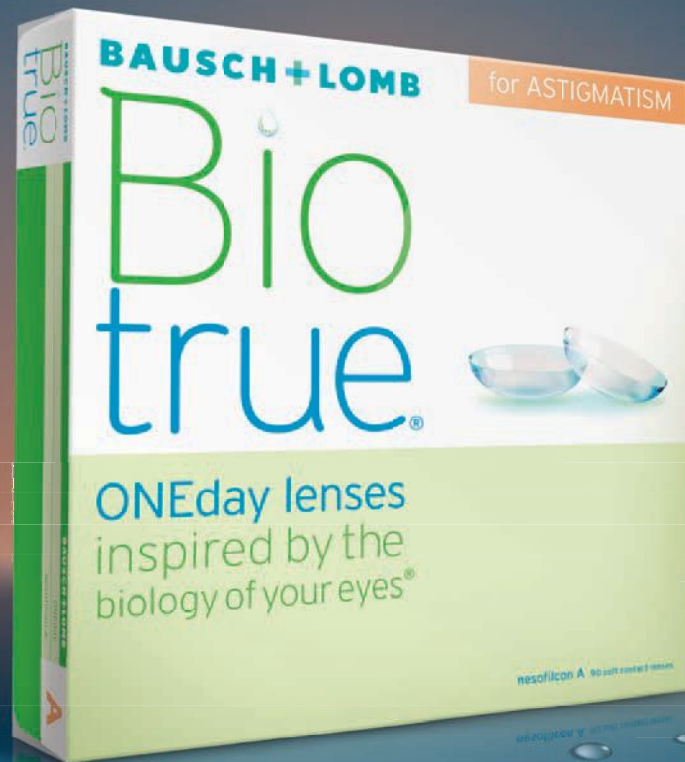# ONLY.

The **first and only** daily disposable with  
**-2.75 Cylinder** available as a standard offering.



# -2.75 CYLINDER

daily disposable available for **same-day fitting.**



Fit the first and only daily disposable with a -2.75 Cylinder offering—Biotrue® ONEday for Astigmatism.



**Most moisture** and **toric parameters** among leading daily disposables\*



**Helps reduce halos and glare** with spherical aberration control<sup>1</sup>



**Fast to fit with excellent centration** at dispensing and follow-up<sup>2</sup>

\*Point of sales data from January to June 2021, sourced from third party.

REFERENCES: 1. Results of an online survey with patients who completed an evaluation program for Biotrue® ONEday for Astigmatism contact lenses and wore their trial lenses for ≥4 days (n=1001). 2. Results from a 7-investigator, multi-site study of Biotrue® ONEday for Astigmatism contact lenses on 123 current non-daily disposable toric soft contact lens wearers. Lenses were worn on a daily wear basis for 1 week.

Biotrue and inspired by the biology of your eyes are trademarks of Bausch & Lomb Incorporated or its affiliates.  
©2021 Bausch & Lomb Incorporated or its affiliates. BFA.0026.USA.21

**BAUSCH + LOMB**  
See better. Live better.



## Vitamin B3 May Lower Risk of Glaucoma

*Increased daily niacin intake was associated with lower odds of developing the disease.*

A recently published population-based study of the National Health and Nutrition Examination Survey suggests daily consumption of niacin may be associated with a lower chance of developing glaucoma.

The study included 5,768 subjects age 40 and older who completed the dietary and vision health portions of the survey. Glaucoma was self-reported and confirmed by fundus imaging and the criteria of the International Society of Geographical and Epidemiological Ophthalmology (ISGEO).

The researchers reported a significant decrease in the odds of self-reported glaucoma in the two highest brackets of daily niacin consumption, representing daily intake of 21mg or more. They noted a similar trend on fundus imaging for the same patients. It was determined that the odds of glaucoma based on fundus imaging remained lower for niacin intake at those levels after adjusting for covariates. However, using ISGEO criteria, no association was found between glaucoma and daily niacin consumption.

"Participants with a daily niacin intake greater than 21mg (quartiles three and four) had a lower glaucoma risk than those with a daily intake less than

15.3mg (quartile one)," the researchers noted.

"Niacin, a form of vitamin B3, includes two vitamers—nicotinamide (NAM) and nicotinic acid—involved in the synthesis pathway of nicotinamide adenine dinucleotide (NAD)," they explained. "The first possible mechanism for protection is related to the mitochondrial energy production pathway. As retinal ganglion cells are responsible for transducing visual information from the retina to the brain, they require a lot of energy. Thus, reduction of NAD, via NAD-consuming enzymes, may limit adenosine triphosphate production and result in the failure to provide sufficient energy for sustaining the health of the cell leading to the degeneration of retinal ganglion cells."

The researchers cited another suspected benefit of NAD—prevention of axonal degeneration—and suggest that restoring NAD precursors, such as NAM, may enhance retinal ganglion cell resistance.

"Our results show the odds of having glaucoma were nearly two-times lower in subjects with a daily intake of niacin in the third and fourth quartiles [*i.e.*,  $\geq 21$ mg], as compared with the first and second quartiles," the researchers wrote.

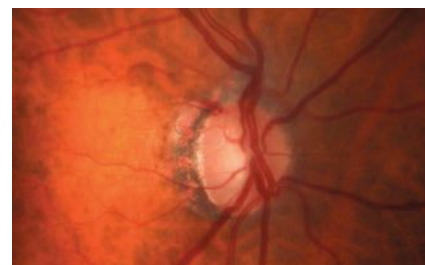


Photo: Michael Chaglassian, OD

### Niacin may boost mitochondrial function to support retinal ganglion cells.

They continued, "The current recommended dietary allowance (RDA) of niacin equivalent is 16mg per day for men and 14mg per day for women. Our results have shown that the mean daily niacin intake of individuals aged 40 and older was 24.18mg per day, which is greater than the RDA dosage. Though possible side effects of niacin include flushing, chills and gastrointestinal issues, studies have shown that intake of nearly 1g (or up to 3g) of NAM daily is well-tolerated even in long-term use."

They concluded that increased daily niacin intake was associated with lower glaucoma likelihood, and that there seems to be a certain threshold of niacin dosage for its prevention effects to be most potent. ◀

Taechameekietichai T, Chansangpetch S, Peerawaranun P, Lin SC. Association between daily niacin intake and glaucoma: National Health and Nutrition Examination Survey. *Nutrients*. 2021;13(12):4263.

### IN BRIEF

#### ■ Dry Eye Patients Misuse Meds.

A survey of patients found that the frequency of DED drop use is incorrect 90% of the time and that most only used them as needed to alleviate symptoms rather than preventively. To help understand the factors at play, a recent web-based patient survey in-

vestigated real-world patterns of use, the reasons behind drop instillation and the relationship between usage patterns and subjective symptoms.

A total of 2,645 participants were enrolled. The study found most did not instill eye drops at the specified frequency, nor were they instructed about the necessary drop frequency by eyecare providers or pharmacists. The most common reason

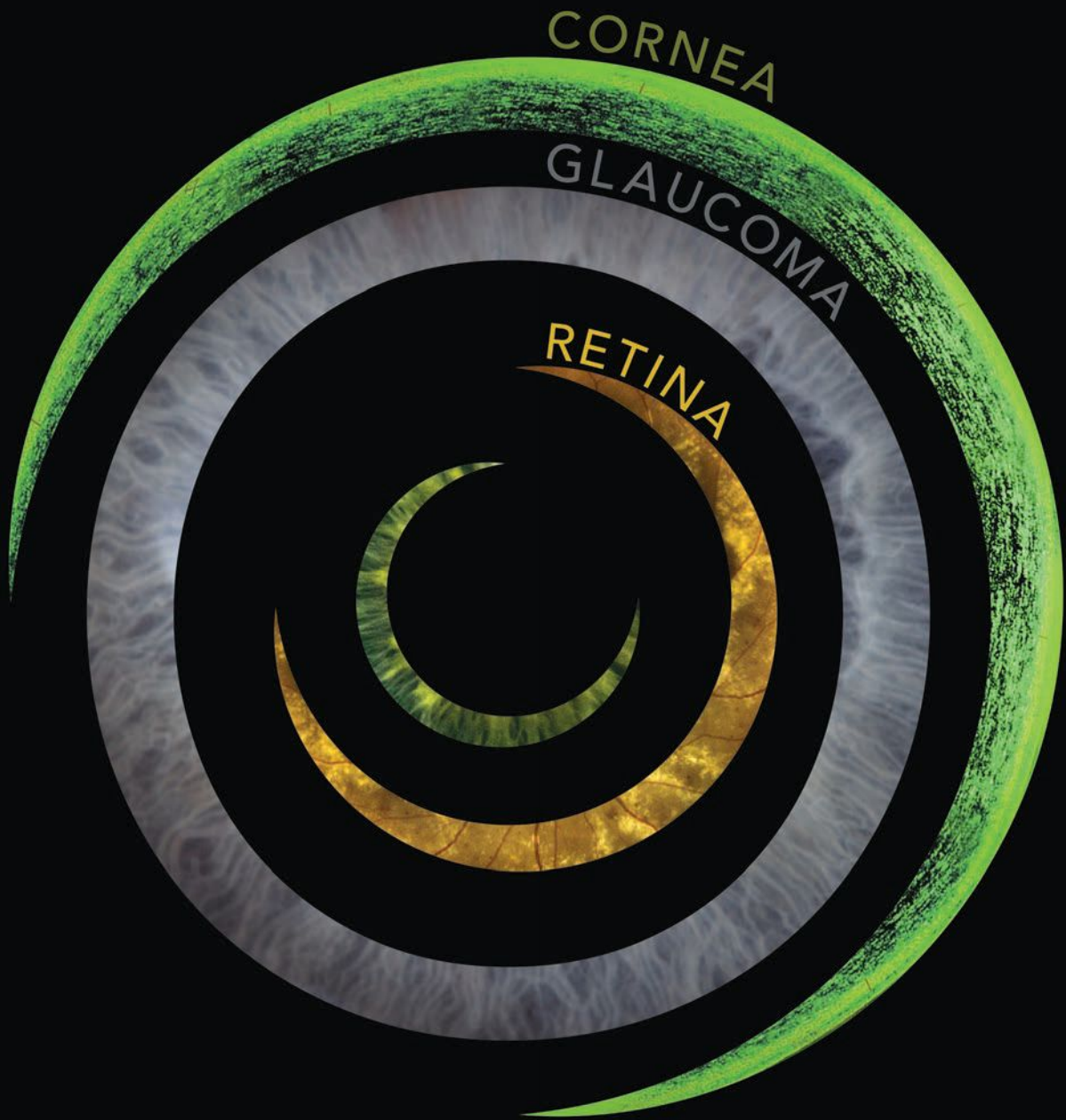
was because patients used them on an as-needed basis only to alleviate subjective symptoms (*e.g.*, dryness, eye fatigue). "More than 60% of participants instilled them when subjective symptoms became apparent," the authors noted.

However, patients may have immediate recurrence of symptoms "because the vicious cycle between the abnormal functioning of the

corneal epithelium and the instability of the tear film layer still exists."

This shows it's important to continue using the drops to prevent the symptoms from appearing, rather than using them to suppress the symptoms once they occur.

Uchino M, Yokoi N, Shimazaki J, et al. Adherence to eye drops usage in dry eye patients and reasons for non-compliance: a web-based survey. *J Clin Med*. January 12, 2022. [Epub ahead of print].



# We'll go first

Innovation is at the core of everything we do. At Glaukos, we push the limits of science and technology to solve unmet needs in chronic eye diseases.

Experience a world of firsts in vision care.  
**Learn more at [Glaukos.com](https://www.Glaukos.com).**

**GLAUKOS**  
TRANSFORMING VISION



# Low Estrogen Ups POAG Risk in Females

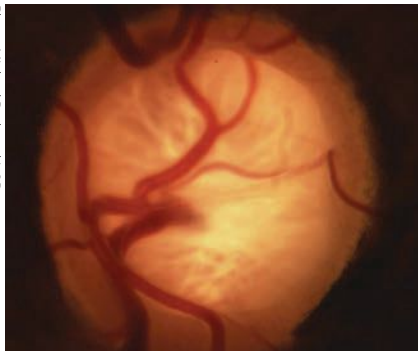
*This association was more significant for pre- rather than postmenopausal women.*

**R**esearch on primary glaucoma, the leading cause of irreversible visual field (VF) defect and blindness, is continually identifying new risk factors associated with the pathogenesis of primary open-angle glaucoma (POAG). Recent literature has suggested women may be more prone to progression and development of POAG, likely due to a hormonal cause. A previous study observed decreased estrogen as a risk factor for POAG. To follow-up on these findings, researchers performed both a cross-sectional and a cohort study on sex hormone levels in women with POAG and found decreased estrogen level was associated with both the condition and VF progression.

The studies enrolled 63 women with POAG and 56 healthy women as controls. Fifty-seven women with POAG followed up for at least two years and were included in the cohort study. Each patient was evaluated for serum concentration of the following sex hormones: prolactin, luteinizing hormone, testosterone, follicle-stimulating hormone, progesterone and estrogen. POAG patients in the cohort study also underwent VF examinations at baseline and during follow-up visits at six, 12, 18 and 24 months.

Results of the cross-sectional study showed that estrogen levels were significantly lower in POAG patients than in healthy controls (136.2pg/

Photo: Michael Dorkowski, OD



**Low estrogen levels may lead to an increased risk of POAG.**

mL vs. 235.9pg/mL). This finding was observed in both the premenopausal group (223.0pg/mL vs. 389.3pg/mL) and the postmenopausal group (27.8pg/mL vs. 31.3pg/mL) compared with healthy controls.

These findings were consistent with the data from the cohort study; there were 29 non-progression subjects and 28 progression subjects, the latter of which were observed to have significantly lower levels of estrogen than those with no progression (27.0pg/mL vs. 211.3pg/mL).

Lower VF non-progression rates were also observed in POAG patients with lower baseline estrogen levels in the cohort study; however, the association was only statistically significant in premenopausal subjects. The researchers also noted that the data suggests estrogen may not be the only sex hormone affecting the risk of progression in primary glaucoma.

The team observed that circulation levels of progesterone, luteinizing hormone follicle-stimulating hormone and testosterone “were also associated with onset and/or development of POAG, indicating sex hormones might jointly influence its pathogenesis.”

They continued, “For the first time, we have shown that an increased [estrogen] level slows the progression of VF loss in POAG,” noting that the hormone “is thought to play an important role in neuroprotection, which has been reported in various central nervous system injuries. One study showed better predicted outcomes and recovery in female patients than in male patients after traumatic brain injury.”

The researchers determined that a decreased estrogen level in women is a risk factor for POAG and has a significant effect on VF progression, especially in premenopausal subjects. They conclude that estrogen “might be a new predictor of POAG onset and VF progression, which is helpful in guiding clinical treatments and evaluating prognosis.” Moreover, the other sex hormones that showed an association might play a role in the pathogenesis and progression of POAG. ◀

Qiu Y, Yu J, Tang L, et al. Association between sex hormones and visual field progression in women with primary open angle glaucoma: a cross-sectional and prospective cohort study. *Front Aging Neurosci.* December 24, 2021. [Epub ahead of print].

## IN BRIEF

■ **Intravitreal Injections Increase PCR Risk.** Cataract surgery and anti-VEGF shots are both very common and, by and large, very safe. However, complications such as **posterior capsule rupture (PCR)** can still occur during cataract surgery, **resulting in a longer and more complex procedure** involving an anterior vitrectomy and a different IOL strategy.

Researchers recently performed a systematic literature review to assess the impact of previous intravitreal injection on the risk of PCR. **They found that each shot increased the chances by 4%, but this only becomes clinically significant after 10 or more cumulative treatments.**

Six studies (n=1,051,097 eyes) were analyzed, all of which evaluated the risk of PCR in eyes undergoing cataract surgery with previous intravitreal injections. A total of 7,034

eyes had a history of previous intravitreal injection (majority anti-VEGF). The meta-analysis showed that any previous intravitreal injection was a risk for PCR (OR: 2.30).

“**The risk from previous intravitreal injections is highly dependent on the number performed,**” the researchers wrote. They list four possible explanations: “(i) iatrogenic physical trauma from the needle, (ii) mechanical changes in lens capsule from exposure to anti-VEGF/cortico-

steroids, (iii) accelerated cataractogenesis from anti-VEGF exposure or corticosteroids resulting in denser cataracts and (iv) denser cataracts.”

They conclude that **previous intravitreal injection raises the risk of PCR in cataract surgery** and should be taken into consideration.

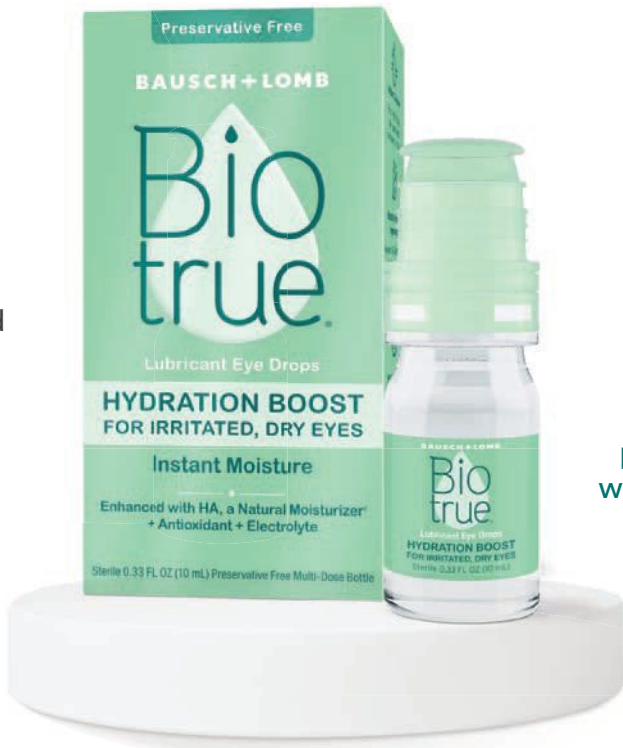Bjerager J, van Dijk EHC, Holm LM, et al. Previous intravitreal injection as a risk factor of posterior capsule rupture in cataract surgery: a systematic review and meta-analysis. *Acta Ophthalmologica.* January 21, 2022. [Epub ahead of print].

FROM THE  
MAKERS OF  
BIOTRUE®



# Dry eye symptom relief inspired by the biology of the eye

- Helps maintain ocular surface homeostasis
- Soothes eye dryness caused by screen and environmental stressors



Contact lens compatible\*

98%

patient satisfaction with Biotrue® Hydration Boost Eye Drops†



Free from preservatives that can cause irritation



Potassium helps maintain ocular surface homeostasis



Antioxidant protects hyaluronan (HA) against free radicals



HA, a moisturizer found naturally in tears‡



pH balanced

\*Based on standardized testing of soft contact lenses. Not meant to lubricate or rewet lenses.  
†In-Home Use Study: N=728 dry eye sufferers; April 2021. ‡Hyaluronan (HA) is sourced from a large-scale natural fermentation process.

LEARN MORE AT  
[biotrue.com/professional](https://biotrue.com/professional)

# Congress, Feds Crack Down on DTC Tactics

*House members call for investigation, citing reports that Hubble Contacts skirted federal regulations of product sales. A separate action hit the company with a \$3.5 million fine.*


A coalition of US Congress members is calling for a federal review of direct-to-consumer (DTC) prescription medical device practices, noting that appropriate regulatory oversight may be lacking in the sale of products such as contact lenses.<sup>1</sup>

In a Dec. 6 letter to the US Comptroller, 21 House members asked the Government Accountability Office (GAO) to launch a study looking into federal regulation of DTC advertising (DTCA) for prescription medical devices.<sup>2</sup> The letter included mentions of media articles that purported Hubble Contacts skirted federal regulations.<sup>2</sup>

Brian Chou, OD, of San Diego said he feels encouraged that members of Congress are looking at this issue, which he says is long overdue. DTCA of drugs is banned in virtually every country except the US and New Zealand because their use without professional supervision can lead to adverse consequences, he explains. “By extension, consumer protections are also a must to safeguard citizens from harm by medical device advertisements,” he says. “The drug and medical device companies have generally failed at self-regulation, so this is where government intervention is welcome.”

While there are regulations currently in place governing DTCA, the fast development of new technology has outpaced the slow process of government regulation, he adds.

On the surface, it seems odd there are advertisements directed to consumers because they are for products people don't have authority to buy on their own, Dr. Chou suggests. “Yet the high return-on-investment for this advertising perpetuates this sales strategy,” he says. “Advertisers know they can get consumers to influence prescribers to give them what they want.”



**Congress has asked to review companies such as Hubble that may not be adhering to regulations on sales of prescription products.**

## Hubble in Trouble

While products advertised directly to consumers have the potential to increase convenience and lower costs, concerns have also been raised about reports of poor quality or adverse events related to these products, the letter states.<sup>2</sup> Additionally, some DTC products allow consumers to bypass evaluation or supervision by a health-care provider entirely, which may be appropriate for some products but not for others, the letter continues.

Case in point: Hubble Contacts. “An online distributor of contact lenses is accused of using older materials and switching prescribed lenses for other brands, which doctors allege affects the safety of the lenses,” Congress members wrote in the letter. “Advocacy groups and other complaints further allege that the company skirts existing prescription verification requirements under the FTC’s Contact Lens Rule.”<sup>2</sup>

On January 28, Hubble was hit with a \$3.5 million fine from the Department of Justice and the Federal Trade Commission in an investigation of such business practices, and required to clean up its act.

Yet, it isn't just Hubble that participates in DTCA. Major soft disposable contact lens manufacturers promote

“free trial lens” coupons to consumers without clearly disclosing that professional services are desirable and necessary, and that they carry a corresponding financial responsibility, Dr. Chou adds. Additionally, he suggests that DTCA seeks to strengthen the patient’s relationship and loyalty with the brand of contact lens, thereby minimizing the importance of the practitioner.

“That’s why I encourage my colleagues to seek partnerships with the drug and medical device companies that understand their products are to enhance the patient-doctor relationship rather than disrupt it,” he says.

Based on the concerns raised in the letter, House members are asking the GAO to investigate the following:<sup>2</sup>

- What are the known advantages and concerns of marketing medical products that require prescriptions or other provider evaluation, such as contact lenses, directly to consumers?
- What actions are federal agencies, such as the FDA and the FTC, taking to address any identified concerns?
- Are there limitations to the FDA or FTC’s ability to enforce existing laws and regulations governing DTCA of prescription medical products and, if so, what are they?

## DTC Weakens Doctor-Patient Relationship

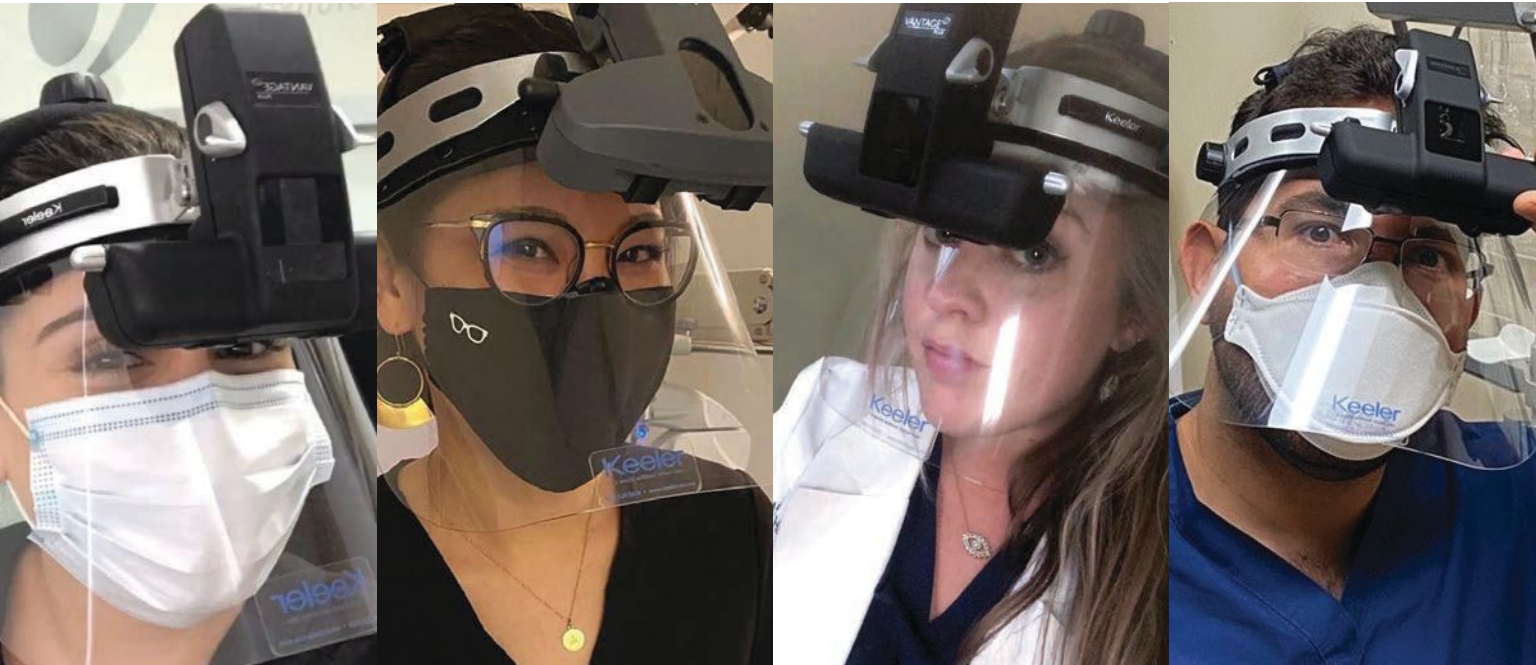The AOA has long spoken out against DTC contact lens sale schemes that seek to disrupt the doctor-patient relationship and other online vendors that circumvent federal contact lens market laws and regulations, placing a greater emphasis on convenience than patients’ vision and eye health.<sup>1</sup>

Even as recently as the FTC’s Contact Lens Rule review, the AOA advocated for the necessity of a reformed contact lens prescription verification

*(Continued on p. 10)*



# Helping Heroes See Clear And Stay Safe



The Vantage BIO is great for ROP screening! It's lightweight, has settings for different pupil sizes, a cool, white LED light and the longest battery ever!!"

**Dra. Paulina Ramirez Neria**



I'm a big fan of the All Pupil BIO. I had issues with other models so when I started [my practice], I knew the All Pupil would be my go-to BIO...I greatly appreciate the new custom fit Keeler BIO shields as an added safety layer."

**Dr. Annie Bacon**



I chose my [Vantage Plus] for the optics and value...with other brands, I had difficulty focusing up close during my dilated fundus exams. [The oculars] made my eyes feel more relaxed, and I felt like my view was better."

**Dr. Michelle Hammond**



[I've] been seeing emergent and urgent cases every day during the COVID19 pandemic. I really like [the Vantage BIO] because [it's a] very good quality and provides a super clear view."

**Dr. Reza Moradi**

Choose option #1 or #2 below when you purchase (or lease) a BIO\*  
**(Expires March 31, 2022)**

\*Valid for wireless indirects: Vantage Plus and/or All Pupil II

1



RECEIVE A

**\$850**

credit towards any PPE

2

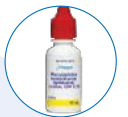24-MONTH

**0%**

lease as low as \$128/month\*

\*All Pupil II: \$127.92/month; Vantage Plus: \$155/month (shipping and taxes not included).

3



RECEIVE

**10 FREE**

bottles of phenylephrine  
2.5%, 15mL

**\*If you lease the BIO, you may also choose the PPE credit OR the phenylephrine option.**

Contact us at 800-523-5620 or customerservice@keelerusa.com to learn more or place your order. This promo cannot be combined with any other Keeler offers.

**Keeler**

— A world without vision loss —

www.keelerusa.com • 3222 Phoenixville Pike - Bldg. #50 • Malvern, PA 19355  
Tel No: 1-610-353-4350 • Toll Free: 1-800-523-5620 • Fax: 1-610-353-7814

A Halma company

# Warmers Reduce Mask-Induced Lens Fogging

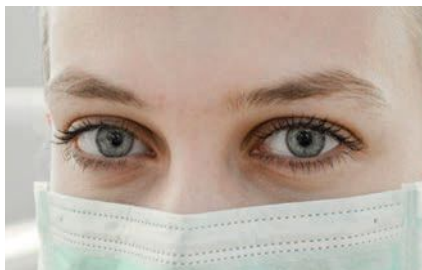Since the onset of the pandemic, many healthcare settings have required mask wear during visits; for optometry specifically, this has led to increased fogging of condensing lenses at the slit lamp during retinal exams, as room-temperature lenses frequently accumulate condensation in mask-wearing patients.

To combat this issue, a recent study published in *Optometry & Vision Science* suggests lens warmers may reduce fogging and, in turn, eliminate potential disruptions.

Lens warming to decrease fogging is not a new idea; in fact, professional photographers have been using this technology for decades, says lead researcher Marta C. Fabrykowski, OD, of the Manhattan Eye, Ear and Throat Hospital ophthalmology department. She adds that professional photography lens warmers are inexpensive and can be easily purchased online for less than \$20.

“Keeping the lenses warm between patients decreases the time needed to warm up lenses for patients who may be heavier breathers. In fact, you can examine all patients with warmed lenses,” Dr. Fabrykowski explains.

Photo: Ani Koleshi on Unsplash



**A \$20 heating device virtually eliminated fogging of 90D lenses in a recent study.**

Dr. Fabrykowski and her team evaluated the degree of lens fogging in mask-wearing patients using ImageJ to measure lens surface areas fogged in slit lamp photos of 90D lenses before and after use of a lens warmer. Additionally, they queried eyecare providers by survey, asking them to rate their experience with diagnostic lens fogging during retinal exams in mask-wearing patients with and without warmers.

Based on the results, the lens warmers were highly effective. For mask-wearing subjects, the percent of the fogged lens area in the 90D lens was roughly 33% with unheated lenses compared with about 1% when a heated lens was used.

The doctors who responded to the survey noted significant less fogging of the 78D and 90D lenses when using the lens warmer and noted this addition helped facilitate the retinal exam.

Practitioners have suggested other methods to reduce fogging, such as requesting patients tape the top of their mask to the bridge of their nose to prevent exhaled breath from traveling upward, pinching the mask to the top of the patient's nose and applying anti-fog solution to the lenses. However, these suggestions are difficult to implement since patients may resist having tape put on their face, complain of difficulty breathing from a tight seal, have skin sensitivities to adhesives or simply not want their face touched, the investigators noted. Using anti-fogging solution may also decrease the integrity of the lens coating, complicate lens cleaning and require frequent reapplication.

One potential improvement the investigators suggested is to develop a lens case with a built-in warmer and temperature gauge. ◀

Fabrykowski MC, Schwarz LA, Gupa RR, Mitchell JR. Technical report: reducing lens fogging associated with patient mask wearing with heated diagnostic funduscopy lenses. *Optom Vis Sci*. January 7, 2022. [Epub ahead of print].

# Congress, Feds Call Out Direct-to-Consumer Practices

(Continued from p. 8)

process with doctors' reports of patients obtaining contact lenses without valid prescriptions or companies substituting doctor-prescribed lenses.<sup>1</sup>

A common argument from drug and medical device companies that advertise directly to consumers is that they are educating the public about better treatments while opening discussions these individuals can have with their doctor, Dr. Chou suggests.

While this is true and helpful in specific cases, these ads can also confuse the public by creating demand for more expensive and unnecessary treatments, he explains. Sometimes

they even make patients believe they have a condition that they don't.

“This sets up the doctor to deliver disappointing news that a particular drug or medical device is not right for them,” Dr. Chou says. “So, despite the narrative by these companies that they are helping patients, they are in fact potentially hindering the relationship between doctors and patients.”

Adding to this argument, he notes that doctors have limited chair time, so inappropriate advertisements can subtract from the doctor's discretionary time by imposing a burden of explaining why a marketed drug or device isn't suitable.

“This is a travesty when doctor time could be allocated in a more fruitful manner for the patient,” Dr. Chou argues. “In other words, the non-specific approach of direct-to-consumer drug and medical device advertising taxes practitioner time, which can ultimately compromise patient care by placing constraints on our time.” ◀

1. US House, consumer groups mull federal action against DTC contact lens sales schemes. American Optometric Association. [www.aoa.org/news/advocacy/federal-advocacy/us-house-consumer-groups-mull-federal-action-against-dtc-contact-lens-sales-schemes?sso=y](http://www.aoa.org/news/advocacy/federal-advocacy/us-house-consumer-groups-mull-federal-action-against-dtc-contact-lens-sales-schemes?sso=y). December 21, 2021. Accessed December 27, 2021.

2. Congress Letter to the Comptroller General. [craig.house.gov/sites/craig.house.gov/files/wysiwyg\\_uploaded/V3Letter%20to%20GAO%20re%20Direct-to-Consumer%20Medical%20Products.pdf](https://www.craig.house.gov/sites/craig.house.gov/files/wysiwyg_uploaded/V3Letter%20to%20GAO%20re%20Direct-to-Consumer%20Medical%20Products.pdf). December 6, 2021. Accessed December 27, 2021.



# GET THERE IN TIME

When you see patients with signs of keratoconus, don't hesitate. Refer them for iLink<sup>™</sup> — the only FDA-approved cross-linking procedure that slows or halts disease progression and is eligible for commercial insurance coverage with over 95% of commercially covered lives.

Connect with an  
iLink<sup>™</sup> expert today.  
Visit [iLinkExpert.com](http://iLinkExpert.com)

#### INDICATIONS

Photrexa<sup>®</sup> Viscous (riboflavin 5'-phosphate in 20% dextran ophthalmic solution) and Photrexa<sup>®</sup> (riboflavin 5'-phosphate ophthalmic solution) are indicated for use with the KXL system in corneal collagen cross-linking for the treatment of progressive keratoconus and corneal ectasia following refractive surgery. Corneal collagen cross-linking should not be performed on pregnant women.

#### IMPORTANT SAFETY INFORMATION

Ulcerative keratitis can occur. Patients should be monitored for resolution of epithelial defects.

The most common ocular adverse reaction was corneal opacity (haze). Other ocular side effects include punctate keratitis, corneal striae, dry eye, corneal epithelium defect, eye pain, light sensitivity, reduced visual acuity, and blurred vision.

These are not all of the side effects of the corneal collagen cross-linking treatment. For more information, go to [www.livingwithkeratoconus.com](http://www.livingwithkeratoconus.com) to obtain the FDA-approved product labeling.

You are encouraged to report all side effects to the FDA. Visit [www.fda.gov/medwatch](http://www.fda.gov/medwatch), or call 1-800-FDA-1088.

\*Photrexa<sup>®</sup> Viscous and Photrexa<sup>®</sup> are manufactured for Avedro. The KXL<sup>®</sup> system is manufactured by Avedro. Avedro is a Glaukos company.

REFERENCE: 1. Photrexa [package insert]. Waltham, MA: Glaukos, Inc; 2016.

MA-02164A  
PM-US-0427

iLink<sup>™</sup> is a trademark of Glaukos Corporation. Photrexa<sup>®</sup>, Photrexa<sup>®</sup> Viscous, and the KXL<sup>®</sup> system are registered trademarks of Avedro, a Glaukos company. All rights reserved. ©2022



**GLAUKOS**



# Scope Expansion Bills Currently in Play

Virginia and Utah are pushing to add laser privileges for their ODs.

Last year, optometry netted some big scope of practice wins. Now, with many states fresh into their 2022 legislative sessions, expansion laws are being molded in Utah, Virginia and others.

In Utah, the state's Optometric Practice Act hasn't been updated for nearly 30 years, says Weston Barney, OD, president of the Utah Optometric Association (UOA). Dr. Barney and other members of the UOA are currently working on the bill to allow ODs in their state to practice at the level being taught in optometry schools.

For example, the current scope law prohibits optometrists from performing surgical procedures. Technically, optometrists in Utah do minor surgical procedures based on Medicare definitions, which can be as simple as eyelash epilation, Dr. Barney explains.

"Since we are updating the bill, we thought, why not bring it to modern times to include training optometrists receive currently? All 23 optometry schools are teaching laser procedures, so we also want to update the law to where it allows optometrists to practice that full scope, including lasers," says Dr. Barney.

Regarding the bill's current status, it should be assigned to a state congressional committee soon, Dr. Barney says. If passed, the bill would ultimately improve patient care, according to its proponents. "Many of our patients in rural Utah are having to travel to ap-

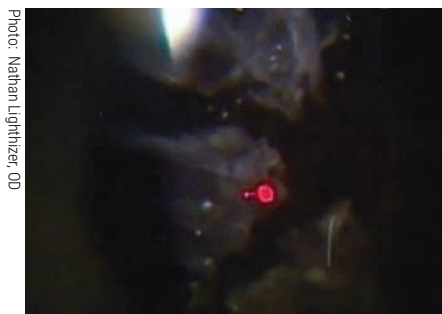


Photo: Nathan Lightizer, OD

**Legislation being debated now in Utah and Virginia aims to allow ODs in those states to perform YAG capsulotomies, among other procedures.**

pointments. The bill would reduce the redundancy of visits," he suggests.

For example, if a rural patient is referred for a YAG procedure by their local OD and the referring ophthalmologist is two hours away, the patient is forced to drive for several hours or have a family member take a day off work to get them to the appointment, Dr. Barney explains. While some ophthalmologists may argue that they do provide care in rural areas, the counterargument is that their coverage is minimal at best, and usually one day a month in a remote office with long wait times for appointments, Dr. Barney says.

One partner in the UOA is a new optometry school, the Rocky Mountain University of Health Professions College of Optometry, slated to open in 2023. In order to attract students to the school, the state shouldn't have scope limitations, Dr. Barney suggests.

In Virginia, two bills are in play: House Bill 213 and Senate Bill 375, which would allow OD to use lasers for glaucoma procedures like SLT, plus YAG capsulotomy following cataract.<sup>1</sup>

In an op-ed published in the *Bristol Herald Courier*, Amanda Umlandt, OD, president-elect of the Virginia Optometric Association (VOA), wrote, "There are now eight states where optometrists are able to perform these laser procedures. There are many more programs training optometrists to perform these procedures and excel in their delivery. These procedures are quick, safe and part of every graduating optometrist's education and experience. Being able to provide this care to my patients isn't about reimbursement; it's about access to care and providing the highest level of care to patients, no matter where they live."<sup>2</sup>

As of press time, the two bills were going before full congressional committees, according to the VOA.

Expanded scope bills are also being pursued in West Virginia, Colorado and Washington, according to the state government relations committee of the AOA. Stay tuned as further details become available. ◀

1. Robertson M. Virginia bill would allow optometrists to perform in-office laser procedures. Becker's Healthcare. [www.beckersasc.com/ophthalmology/virginia-bill-would-allow-optometrists-to-perform-in-office-laser-procedures.html](http://www.beckersasc.com/ophthalmology/virginia-bill-would-allow-optometrists-to-perform-in-office-laser-procedures.html). January 20, 2022. Accessed January 25, 2022.

2. Umlandt A. Bills would help Virginians' access to eye care. Herald Courier. [heraldcourier.com/opinion/columnists/question-view-bills-would-help-virginians-access-to-eye-care/article-fd-bb1c4c-1d9c-56bb-b43c-936671cec613.html](http://heraldcourier.com/opinion/columnists/question-view-bills-would-help-virginians-access-to-eye-care/article-fd-bb1c4c-1d9c-56bb-b43c-936671cec613.html). January 14, 2022. Accessed January 26, 2022.

## IN BRIEF

### ■ Glaucoma Resembles Alzheimer's.

A recent review of glaucoma and Alzheimer's disease (AD) imaging biomarkers suggests the two share a number of pathogenic mechanisms and that glaucoma should be considered a neurodegenerative condition affecting the entire visual system.

"Evidence of a possible connection between AD and glaucoma emerged because patients with AD

showed a significantly higher rate (5x increase) of glaucoma occurrence, despite a lower mean IOP," the authors wrote. They noted the following connections between the two:

- Both glaucoma and AD affect ocular and brain tissue of similar embryological origin.
- Apolipoprotein metabolism alterations may play a significant role in both diseases.
- Both diseases may share an underlying vascular component.

- Vascular deposits of amyloid-beta may be a possible common pathway.

- Significantly lower levels of amyloid-beta and higher levels of tau proteins were found in the vitreous of glaucoma patients compared with non-glaucomatous controls.

- Both glaucoma and mild AD patients demonstrated impaired cognition vs. healthy controls.

- Ocular hypertension may induce amyloid-beta deposition in the retina,

leading to progressive synaptic dysfunction and visual impairment.

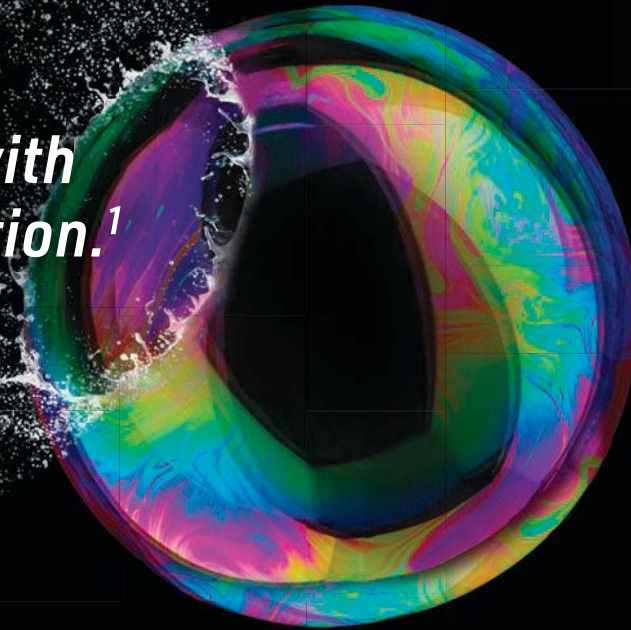
"Overall, these results suggest that the extent of structural and functional alterations extends in areas beyond the visual pathway and are likely connected to abnormalities along white fibers and the brain network."

Martucci A, Picchi E, Di Giuliano F, et al. Imaging biomarkers for Alzheimer's disease and glaucoma: current and future practices. *Curr Opin Pharma* 2022;62:137-44.

**tyrvaya™**  
(varenicline solution)  
nasal spray 0.03 mg

# NOW APPROVED

*Dry eye starts with  
tear film disruption.<sup>1</sup>*




*Treat by activating  
tear film production.<sup>2</sup>*

## INTRODUCING A WHOLE NEW WAY TO TREAT DRY EYE DISEASE.<sup>2</sup>

Tyrvaya™, the first and only nasal spray approved to treat the signs and symptoms of dry eye, is believed to activate the trigeminal parasympathetic pathway via the nose, resulting in increased tear film production.<sup>2</sup> The exact mechanism of action is unknown at this time.

Watch Tyrvaya in action at [Tyrvaya-pro.com](http://Tyrvaya-pro.com).



### INDICATION

Tyrvaya™ (varenicline solution) Nasal Spray is indicated for the treatment of the signs and symptoms of dry eye disease.

**Please see Brief Summary of Prescribing Information on the adjacent page and the full Prescribing Information at [Tyrvaya-pro.com](http://Tyrvaya-pro.com).**

### IMPORTANT SAFETY INFORMATION

#### Adverse Reactions

The most common adverse reaction reported in 82% of patients was sneezing. Events that were reported in 5-16% of patients were cough, throat irritation, and instillation-site (nose) irritation.

**References:** 1. Craig JP, Nelson JD, Azar DT, et al. *Ocul Surf.* 2017;15(4):802-812. 2. Tyrvaya. Prescribing Information. Oyster Point Pharma; 2021.

© 2021 Oyster Point Pharma, Inc. Oyster Point™, the Oyster Point logo, Tyrvaya™ and the Tyrvaya logo are trademarks of Oyster Point Pharma, Inc. All rights reserved. OP-TYR-000867 10/21



**BRIEF SUMMARY:** Consult the full Prescribing Information for complete product information available at [www.tyrvaya-pro.com](http://www.tyrvaya-pro.com).

### INDICATIONS AND USAGE

TYRVAYA™ (varenicline solution) nasal spray is a cholinergic agonist indicated for the treatment of the signs and symptoms of dry eye disease.

### ADVERSE REACTIONS

**Clinical Trials Experience:** Because clinical trials are conducted under widely varying conditions, adverse reaction rates observed in the clinical trials of a drug cannot be directly compared to rates in the clinical trials of another drug and may not reflect the rates observed in practice.

In three clinical trials of dry eye disease conducted with varenicline solution nasal spray, 349 patients received at least 1 dose of TYRVAYA. The majority of patients had 31 days of treatment exposure, with a maximum exposure of 105 days.

The most common adverse reactions reported in 82% of TYRVAYA treated patients was sneezing. Other common adverse reactions that were reported in >5% of patients include cough (16%), throat irritation (13%), and instillation-site (nose) irritation (8%).

### USE IN SPECIFIC POPULATIONS

**Pregnancy: Risk Summary:** There are no available data on TYRVAYA use in pregnant women to inform any drug associated risks. In animal reproduction studies, varenicline did not produce malformations at clinically relevant doses.

All pregnancies have a risk of birth defect, loss, or other adverse outcomes. In the US general population, the estimated background risk of major birth

defects and miscarriage in clinically recognized pregnancies is 2% to 4% and 15% to 20%, respectively.

**Data: Animal Data:** Pregnant rats and rabbits received varenicline succinate during organogenesis at oral doses up to 15 and 30 mg/kg/day, respectively. While no fetal structural abnormalities occurred in either species, maternal toxicity, characterized by reduced body weight gain, and reduced fetal weights occurred in rabbits at the highest dose (4864 times the MRHD on a mg/m<sup>2</sup> basis).

In a pre- and postnatal development study, pregnant rats received up to 15 mg/kg/day of oral varenicline succinate from organogenesis through lactation. Maternal toxicity, characterized by a decrease in body weight gain, was observed at 15 mg/kg/day (1216 times the MRHD on a mg/m<sup>2</sup> basis). Decreased fertility and increased auditory startle response occurred in offspring at the highest maternal dose of 15 mg/kg/day.

**Lactation: Risk summary:** There are no data on the presence of varenicline in human milk, the effects on the breastfed infant, or the effects on milk production. In animal studies varenicline was present in milk of lactating rats. However, due to species-specific differences in lactation physiology, animal data may not reliably predict drug levels in human milk.

The lack of clinical data during lactation precludes a clear determination of the risk of TYRVAYA to an infant during lactation; however, the developmental and health benefits of breastfeeding should be considered along with the mother's clinical need for TYRVAYA and any potential adverse effects on the breastfed child from TYRVAYA.

**Pediatric Use:** Safety and efficacy of TYRVAYA in pediatric patients have not been established.

**Geriatric Use:** No overall differences in safety or effectiveness have been observed between elderly and younger adult patients.

## NEWS REVIEW

### IN BRIEF

■ **Central VF Loss May Indicate Glaucoma Progression.** To better understand glaucoma progression, researchers recently determined the patterns of visual field defects in early, moderate and severe stages of POAG. They found that **defects become more central as disease severity increases and suggest that extra attention be paid to this region in glaucoma patients.**

They analyzed one visual field of each of the 100 patients included in each group based on the location of the 300 visual defects, involved hemifields and connection to the blind spot.

"As the severity of the glaucomatous visual field defects increase, their patterns become more central, connected to the physiological blind spot and involving both hemifields," the authors explained in their paper. **Even in the early stages of glaucomatous visual field defects, 49% already occurred in both hemifields.** When the defect was localized to only one hemifield, 62.6% occurred in the superior hemifield.

As severity increases, the defect deepens and expands, involving the blind spot. In the early group, 27% of defects were connected to the physiological blind spot vs. 64% in the moderate group and 95% in the severe group. Also in the early group, 28% of the defects involved the central 5° of fixation.

Antunes Schiave Germano R, Schiave Germano C, Susanna FN, Junior RS. Patterns of visual field loss in early, moderate and severe stages of open-angle glaucoma. *J Glaucoma*. January 12, 2022. [Epub ahead of print].

■ **Subconj Heme Doesn't Increase Stroke Risk.** Researchers in Korea recently used nationwide general population health data to determine that subconjunctival hemorrhage (SCH) itself is not a risk factor for stroke or acute myocardial infarction (MI). The study included 703,090 individuals aged 20 and older without any history of SCH, cerebrovascular disease or ischemic heart disease. Within that group, the researchers then identified 46,251 cases of SCH.

The hemorrhage group showed slightly higher 10-year incidence probability of stroke or acute MI than the general population (3.17% vs. 2.71%, respectively); however, when compared with matched controls, there was no difference (3.17% vs. 3.03%, respectively). After adjusting for confounders, SCH did not increase the risk of stroke or acute MI.

Patient characteristics the team found associated with an increased risk of both stroke and acute MI included male sex, older age, hypertension, diabetes, congestive heart failure and chronic kidney disease. "We would recommend attentive evaluation of underlying diseases in patients with SCH, in that SCH might share risk factors with stroke or acute MI," they wrote.

Jeon HS, Byun SJ, Hyon JY, et al. Risk of stroke or acute myocardial infarction in subconjunctival hemorrhage: a nationwide cohort study. *Ophthalmic Epidemiol*. November 18, 2021. [Epub ahead of print].



Manufactured for: Oyster Point Pharma, Inc., 202 Carnegie Center, Suite 109, Princeton, NJ 08540  
For more information visit [www.tyrvaya-pro.com](http://www.tyrvaya-pro.com).  
To report an adverse event, contact 1-877-EYE-0123.  
Tyrvaya™, the Tyrvaya logo, Oyster Point™ and the Oyster Point logo are trademarks of Oyster Point Pharma Inc.  
©2021 Oyster Point Pharma, Inc. All Rights Reserved.  
Issued: Oct 2021

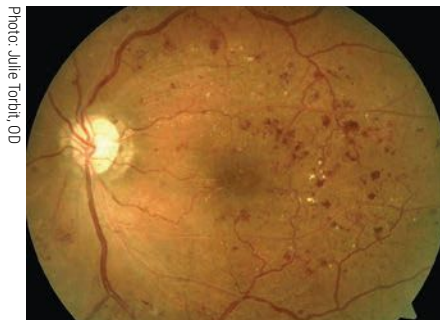
OP-TYR-000867 10/21



# DR May Raise Risk of Cognitive Impairment

**C**urrent research supports the notion that vascular insufficiency and neurodegeneration both contribute to an increased risk of cognitive impairment in patients with diabetes. Because the retina is a brain-derived tissue, its examination may act as an easily accessible and noninvasive way to screen for cerebral structural abnormalities or cognitive decline in diabetic patients. A recent study found that diabetic retinopathy (DR) was associated with both structural abnormalities in the brain and cognitive impairment after adjusting for glycemia, A1c levels and hypertension.

The meta-analysis looked at 27 studies that assessed the association between DR and cerebral small vessel disease or cognitive impairment in a diabetic cohort. Investigators performed four analyses of the association between DR and brain structural abnormalities, as well as DR and cognitive impairment. They calculated a combined odds ratio of 1.75 for the



**DR patients were 1.75x more likely to have cerebral small vessel disease.**

association between DR and cerebral structural change from five studies. The association between DR and cognitive impairment had an odds ratio of 1.43 based on data from 14 studies.

“The present meta-analysis suggests that DR is associated with an increased risk of structural abnormalities in the brain and cognitive impairment, which remained significant after adjusting for blood glucose levels, hemoglobin A1c and the presence of hypertension,” the researchers wrote in their study.

The analysis did not find a relationship between diabetic retinopathy and dementia. Though many of the cohort studies suggested that the dual presence of DR and cognitive impairment could predict dementia risk, the cross-sectional studies overall did not agree.

“The contradiction between cohort and cross-sectional studies may have resulted from the average age of the patients. We believe that the outcome of the cohort studies is more reliable because we can draw causal inferences,” the researchers explained.

In conclusion, the literature review finds that the presence of diabetic retinopathy may signal a potential risk for cerebral disease and compromised cognition. Additional research may help to solidify DR screening as a way to evaluate these conditions in patients with diabetes. ◀

Chai YH, Zhang YP, Qiao YS, et al. Association between diabetic retinopathy, brain structural abnormalities and cognitive impairment for accumulated evidence in observational studies. *Am J Ophthalmol.* January 10, 2022. [Epub ahead of print].

# Aerobic Exercise Improves Dry Eye

**C**ould hitting the gym make your eyes feel better? Possibly, says a new study that looked at the effects of aerobic exercise on tear secretion and tear film stability in dry eye patients.

The study consisted of two parts, and each included three groups: dry eye without aerobic exercise, dry eye with aerobic exercise and preclinical dry eye with aerobic exercise. In part one (34

eyes per group), variations of Schirmer I test and six tear compositions before and after aerobic exercise were tested. In part two (30 eyes per group), variations of tear meniscus height, first and average noninvasive tear breakup time, lipid layer thickness, number of incomplete and complete blinks, partial blink rate (PBR) and visual acuity before and after aerobic exercise were studied.

Results showed an increase in tear secretion at 30 minutes after aerobic exercise. The main cause may be the location of the sympathetic nerves in the lacrimal gland, which are around lacrimal gland acinar blood vessels and “can cause vasodilation and increase secretion of electrolytes and water.”

The authors explained “this might be the main cause of increased tear secretion in dry eye patients after aerobic exercise. The lack of significant change

in tear secretion in preclinical dry eye patients might be due to the limited effect of aerobic exercise on secretory function of healthy lacrimal glands. This suggests dry eye patients are more likely to benefit from aerobic exercise.”

The number of incomplete blinks and PBR at 10 minutes after aerobic exercise decreased significantly compared with baseline, while the number of complete blinks increased significantly.

“This was helpful with tear secretion and more even distribution of the tear film on the ocular surface, thus prolonging the tear breakup time and improving the stability of tear film,” the authors explained. Also, visual acuity improved after exercise and was maintained for at least 30 minutes. ◀

Sun C, Chen X, Huang Y, et al. Effects of aerobic exercise on tear secretion and tear film stability in dry eye patients. *BMC Ophthalmol.* January 4, 2022. [Epub ahead of print].



**Patients had improved tear secretion and VA after 30 minutes of exercise.**

# Screen Burned Eyes?

# TRY REGENER-EYES

THE **POWER** OF A BIOLOGIC IN THE **EASE** OF AN EYEDROP



[regenereyes.com](http://regenereyes.com) | 877-206-0706

© 2021 Regener-Eyes®, All rights reserved



# FEATURES

REVIEW OF OPTOMETRY • Vol. 159, No. 2 • February 15, 2022

Making the

# DIAGNOSIS

9th Annual  
**Diagnostic Skills  
& Techniques**  
Issue

46

## Debating the Value of Diagnostic Tests

Four seasoned pros have a freewheeling conversation about whether or not several tried-and-true tools and concepts have run their course and should be modified or replaced.

*By Christina Hicks-Hubbard, OD, Brad Taylor, OD, Sara Weidmayer, OD, and Traci Seng, OD*

56

## Gonioscopy: A Simple Tool, Too Often Forgotten

Sharpen your skills with this valuable technique.

*By Amila Herbert, OD, Kelly Thompson, OD, and Carly Rose, OD*

64

## Elevate Your Dry Eye Practice

Let's break down every diagnostic test tier by tier to help you decide which ones are best for your patients. *By Lindsay Sicks, OD*

74

## How to Triage Non-Traumatic Ocular Emergencies

These urgent cases rely on early diagnosis and effective treatment and/or referral for successful outcomes. *By Mohammad Rafieetary, OD, Salar Rafieetary, MD, and Blake Briggs, MD*

84

## Peripheral Retinal Imaging and Disease Assessment

Using the right tools can help differentiate lesions and degenerations in this region.

*By Julie Rodman, OD, MSc, Veronica Acuña, OD, and Pooja Alloju, OD*

—EARN 2 CE CREDITS

38

## Tackling the Barriers of Myopia Management

Learn tips to be successful in discussing this topic with patients and their parents.

*By Ariel Cerenzie, OD*



**We Welcome  
Your Comments**

[editor@reviewofoptometry.com](mailto:editor@reviewofoptometry.com)



**Recently added!**

Enjoy our content on  
Instagram at [@revoptom](https://www.instagram.com/revoptom)

# DEPARTMENTS

REVIEW OF OPTOMETRY • FEBRUARY 15, 2022



VISIT US ON SOCIAL MEDIA

Facebook: [www.facebook.com/revoptom](https://www.facebook.com/revoptom)

Twitter: [twitter.com/revoptom](https://twitter.com/revoptom)

Instagram: [www.instagram.com/revoptom](https://www.instagram.com/revoptom)

4

## NEWS REVIEW

Clinical, legislative and practice development updates.

22

## OUTLOOK

### There They Go Again

The anti-optometry lobby is repeating the same old tired arguments that the public never falls for.

*Jack Persico, Editor-in-Chief*

25

## LETTERS TO THE EDITOR

Feedback and ideas from the optometric community.

28

## THROUGH MY EYES

### Spruce Up Your Practice

Focus on additions that can set you up for success.

*Paul M. Karpecki, OD*

30

## CHAIRSIDE

### Word on the Street is Nothing's Easy

If you're in need of convincing, you've come to the right place.

*Montgomery Vickers, OD*

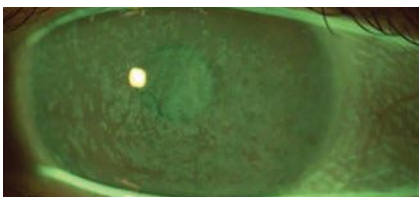
32

## CLINICAL QUANDARIES

### Secret Serum

Restoring the ocular surface after LASIK.

*Paul C. Ajamian, OD*



35

## FOCUS ON REFRACTION

### Double the Glasses, Double the Success

The two-pair approach is a major contributor to the healing process post-brain injury.

*Marc B. Taub, OD, MS, and Pamela H. Schnell, OD*

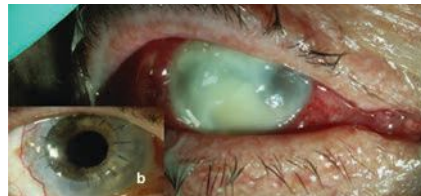92

## CORNEA AND CONTACT LENS Q + A

### Using CXL as 'Bug Killer'

When medications alone don't bring resolution, consider photodynamic therapy with rose bengal and UV-A.

*Joseph P. Showlin, OD*



94

## THERAPEUTIC REVIEW

### Down in the Basement

Numerous options exist to ameliorate symptoms and visually rehabilitate eyes with corneal dystrophies.

*Joseph W. Sowka, OD*

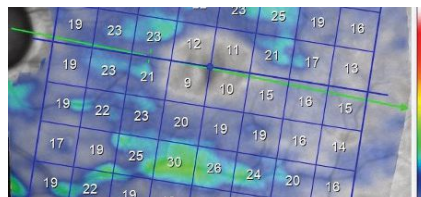
96

## GLAUCOMA GRAND ROUNDS

### That Time of Year

After the holidays come insurance coverage changes.

*James L. Fanelli, OD*



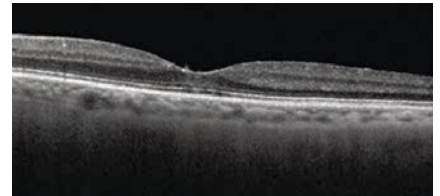
98

## RETINA QUIZ

### Crystal... Not So Clear

Going through this patient's medical history proved to be key in finding the correct diagnosis.

*Mark Dunbar, OD*



100

## SURGICAL MINUTE

### Those Pesky Floaters

Vitrectomy is a safe option to eliminate opacities.

*Derek N. Cunningham, OD, and Walter O. Whitley, OD, MBA*



102

## PRODUCT REVIEW

New items to improve clinical care.

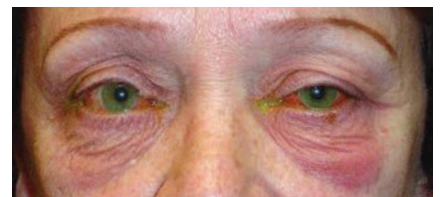
106

## DIAGNOSTIC QUIZ

### Oh, That's Catchy!

Is this red eye something potentially more troubling?

*Andrew S. Gurwood, OD*

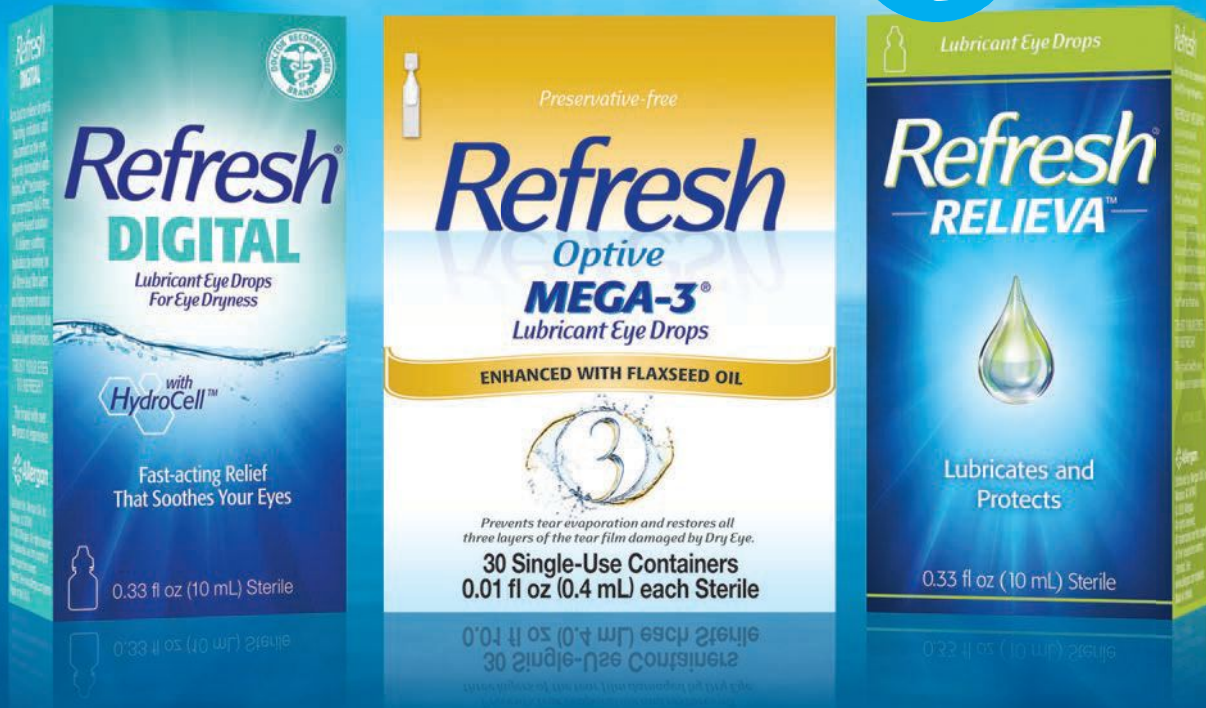



OPEN YOUR EYES TO

# Refresh<sup>®</sup>

## CONCIERGE



DISCOVER EXCLUSIVE ACCESS TO ALL THINGS REFRESH<sup>®</sup>.

Our full-service, dedicated team is here to assist you and your staff with all your REFRESH<sup>®</sup> needs.



REFRESH<sup>®</sup>  
SAMPLES



PATIENT  
COUPONS



PRODUCT  
EDUCATION



REFRESH<sup>®</sup> DIRECT  
ECOMMERCE

Call us and see how REFRESH<sup>®</sup> Concierge can help you bring relief to your patients.

**833-REF-SMPL** 7:30 a.m.–7 p.m. CT, M–F

## CLINICAL EDITORS

**CHIEF CLINICAL EDITOR** ~ PAUL M. KARPECKI, OD

**ASSOCIATE CLINICAL EDITORS** ~ JOSEPH P. SHOVLIN, OD, CHRISTINE SINDT, OD

## CONTRIBUTING EDITORS

**PAUL C. AJAMIAN, OD**, ATLANTA

**ALISON BOZUNG, OD**, MIAMI

**DEREK N. CUNNINGHAM, OD**, AUSTIN, TEX.

**MARK T. DUNBAR, OD**, MIAMI

**JAMES L. FANELLI, OD**, WILMINGTON, NC

**ANDREW S. GURWOOD, OD**, PHILADELPHIA

**PAUL M. KARPECKI, OD**, LEXINGTON, KY.

**BISANT LABIB, OD**, ELKINS PARK, PA

**PAMELA H. SCHNELL, OD**, MEMPHIS, TENN.

**JOSEPH P. SHOVLIN, OD**, SCRANTON, PA

**JOSEPH W. SOWKA, OD**, FORT LAUDERDALE, FLA.

**MARC TAUB, OD**, MEMPHIS, TENN.

**MONTGOMERY VICKERS, OD**, DALLAS

**WALTER O. WHITLEY, OD, MBA**, VIRGINIA BEACH, VA.

## EDITORIAL ADVISORY BOARD

**JEFFREY R. ANSHEL, OD**, ENCINITAS, CALIF.

**JILL AUTRY, OD, RPH**, HOUSTON

**SHERRY J. BASS, OD**, NEW YORK

**EDWARD S. BENNETT, OD**, ST. LOUIS

**MARC R. BLOOMENSTEIN, OD**, SCOTTSDALE, ARIZ.

**ALISON BOZUNG, OD**, MIAMI

**AARON BRONNER, OD**, KENNEWICK, WASH.

**MILE BRUJIC, OD**, BOWLING GREEN, OHIO

**CHRIS J. CAKANAC, OD**, MURRYSVILLE, PA

**JERRY CAVALLERANO, OD, PhD**, BOSTON

**WALTER L. CHOATE, OD**, MADISON, TENN.

**BRIAN CHOU, OD**, SAN DIEGO

**MICHAEL CHAGLASIAN, OD**, CHICAGO

**A. PAUL CHOUS, MA, OD**, TACOMA, WASH.

**GLENN S. CORBIN, OD**, WYOMISSING, PA

**MICHAEL DELGIODICE, OD**, CLIFTON, NJ

**ANTHONY S. DIECIDUE, OD**, STROUDSBURG, PA

**S. BARRY EIDEN, OD**, DEERFIELD, ILL.

**ARTHUR B. EPSTEIN, OD**, PHOENIX

**STEVEN FERRUCCI, OD**, SEPULVEDA, CALIF.

**MURRAY FINGERET, OD**, HEWLETT, NY

**IAN BEN GADDIE, OD**, LOUISVILLE, KY

**GARY S. GERBER, OD**, HAWTHORNE, NJ

**MILTON HOM, OD**, AZUSA, CALIF.

**DAVID KADING, OD**, SEATTLE

**JEROME A. LEGERTON, OD, MBA**, SAN DIEGO

**THOMAS L. LEWIS, OD, PhD**, PHILADELPHIA

**BLAIR B. LONSBERRY, MS, OD, MED**, PORTLAND, OR

**DOMINICK MAINO, OD, MED**, CHICAGO

**KELLY A. MALLOY, OD**, PHILADELPHIA

**DANICA MARRELLI, OD**, HOUSTON, TEX.

**RON MELTON, OD**, CHARLOTTE, NC

**PAMELA J. MILLER, OD, JD**, HIGHLAND, CALIF.

**BRUCE MUCHNICK, OD**, COATESVILLE, PA

**MARC MYERS, OD**, COATESVILLE, PA

**CARLO J. PELINO, OD**, JENKINTOWN, PA

**JOSEPH PIZZIMENTI, OD**, FORT LAUDERDALE, FLA.

**CHRISTOPHER J. QUINN, OD**, ISELIN, NJ

**MICHAEL C. RADOIU, OD**, STAUNTON, VA

**MOHAMMAD RAFIETARY, OD**, MEMPHIS, TENN.

**JOHN L. SCHACHET, OD**, ENGLEWOOD, COLO.

**JACK SCHAEFFER, OD**, BIRMINGHAM, ALA.

**PAMELA H. SCHNELL, OD**, MEMPHIS, TENN.

**LEO P. SEMES, OD**, BIRMINGHAM, ALA.

**DIANA L. SHECHTMAN, OD**, FORT LAUDERDALE, FLA.

**JEROME SHERMAN, OD**, NEW YORK, NY

**LEONID SKORIN, JR., OD, DO**, ROCHESTER, MINN.

**JOSEPH W. SOWKA, OD**, FORT LAUDERDALE, FLA.

**BRAD M. SUTTON, OD**, INDIANAPOLIS

**LORETTA B. SZCZOTKA, OD, PhD**, CLEVELAND

**MARC TAUB, OD**, MEMPHIS, TENN.

**TAMMY P. THAN, MS, OD**, BIRMINGHAM, ALA.

**RANDALL THOMAS, OD**, CONCORD, NC

**SARA WEIDMAYER, OD**, ANN ARBOR, MICH.

**KAREN YEUNG, OD**, LOS ANGELES



### Business Offices

19 Campus Boulevard, Suite 101  
Newtown Square, PA 19073  
Subscription inquiries (877) 529-1746 (USA only)  
outside USA, call (847) 763-9630

### PUBLISHER

**MICHAEL HOSTER**  
(610) 492-1028  
mhoster@jobson.com

### SENIOR MANAGER, STRATEGIC ACCOUNTS

**MICHELE BARRETT**  
(610) 492-1014  
mbarrett@jobson.com

### REGIONAL SALES MANAGER

**JONATHAN DARDINE**  
(610) 492-1030  
jdardine@jobson.com

### PRODUCTION MANAGER

**FARRAH APONTE**  
212-274-7057 faponte@Jobson.com

### PRODUCTION MANAGER

**KAREN LALLONE**  
(610) 492-1010 klallone@Jobson.com

### CLASSIFIED ADVERTISING

(888)-498-1460

### SUBSCRIPTIONS

\$63 PER YEAR, \$99 (US) IN CANADA,  
\$158 (US) IN ALL OTHER COUNTRIES  
revoptometry@cambeywest.com

### CIRCULATION

PO BOX 71, CONGERS, NY 10920-0071  
(877) 529-1746  
OUTSIDE USA: (845) 267-3065

### SENIOR CIRCULATION MANAGER

**HAMILTON MAHER**  
(212) 219-7870  
hmaher@jhihealth.com

### CEO, INFORMATION GROUP SERVICES

**MARC FERRARA**

### SENIOR VICE PRESIDENT, OPERATIONS

**JEFF LEVITZ**

### VICE PRESIDENT, HUMAN RESOURCES

**TAMMY GARCIA**

### VICE PRESIDENT, CREATIVE SERVICES & PRODUCTION

**MONICA TETTAMANZI**

### CORPORATE PRODUCTION DIRECTOR

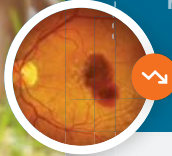**JOHN ANTHONY CAGGIANO**

### VICE PRESIDENT, CIRCULATION

**JARED SONNERS**

Jobson Health Information/WebMD  
395 Hudson Street, 3rd Floor, New York, NY 10014

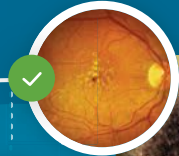# Prevent AMD Vision Loss with Digital Healthcare



IRIS REGISTRY

**20/83 VA**

Average at wet AMD diagnosis according to IRIS Registry real-world data<sup>1</sup>



HOME STUDY

**≥20/40 VA**

Average at wet AMD diagnosis with ForeseeHome<sup>2</sup>



**ForeseeHOME™**  
AMD Monitoring Program

## Early Detection Helps Preserve Vision

ForeseeHome is a **remote monitoring** program for at-risk dry AMD patients that helps **detect wet AMD earlier** and alerts you of changes.


## Remote patient monitoring leads to better outcomes and stronger optometric practices

- ✓ FDA Cleared
- ✓ Medicare Covered

- Plug and play digital health solution for your patients
- Solidify long-term relationships with your patients
- No cost to your practice
- Strengthen your referral relationships with qualified wet AMD referrals

## The Key to Successful Home Monitoring

**NOTAL VISION MONITORING CENTER**



Engagement & Education

Benefits Verification & Authorization

Continuous Monitoring



Practice Workflow Implementation

Remote Patient Management

Vision Alert Management



ForeseeHome is a registered trademark, and the ForeseeHome AMD Monitoring Program and logo and the Notal Vision logo are trademarks of Notal Vision. © 2020 Notal Vision, Inc. All rights reserved.

References: 1. Rao P et al. *Ophthalmology*. 2018;125(4):522-528. 2. Domalpally A, Clemons TE, Bressler SB, et al. *Ophthalmol Retina*. 2019;3(4):326-335.

See website for FDA Indication for Use.

SM-169.2



**GET STARTED TODAY**

**1-855-600-3112**

Mon-Fri, 8 AM to 6 PM EST

[www.foreseehome.com/doctor](http://www.foreseehome.com/doctor)



Founded 1891  
Founding Editor, Frederick Boger

EDITOR-IN-CHIEF  
**JACK PERSICO**  
(610) 492-1006 • jpersico@jobson.com

SENIOR EDITOR  
**JULIE SHANNON**  
(610) 492-1005 • jshannon@jobson.com

SENIOR ASSOCIATE EDITOR  
**CATHERINE MANTHORP**  
(610) 492-1043 • cmanthorp@jobson.com

SENIOR ASSOCIATE EDITOR  
**MARK DE LEON**  
(610) 492-1021 • mdeleon@jobson.com

ASSOCIATE EDITOR  
**LEANNE SPIEGLE**  
(610) 492-1026 • lspiegle@jobson.com

SPECIAL PROJECTS MANAGER  
**JILL GALLAGHER**  
(610) 492-1037 • jgallagher@jobson.com

SENIOR ART DIRECTOR  
**JARED ARAUJO**  
(610) 492-1032 • jaraujo@jobson.com

DIRECTOR OF CE ADMINISTRATION  
**REGINA COMBS**  
(212) 274-7160 • rcombs@jobson.com

#### Clinical Editors

Chief Clinical Editor • Paul M. Karpecki, OD  
Associate Clinical Editors  
Joseph P. Showlin, OD, Christine W. Sindt, OD  
Clinical & Education Conference Advisor  
Paul M. Karpecki, OD  
Case Reports Coordinator • Andrew S. Gurwood, OD

#### Columnists

*Chairside* – Montgomery Vickers, OD  
*Clinical Quandaries* – Paul C. Ajamian, OD  
*Cornea and Contact Lens Q+A* – Joseph P. Showlin, OD  
*Diagnostic Quiz* – Andrew S. Gurwood, OD  
*The Essentials* – Bisant A. Labib, OD  
*Focus on Refraction* – Marc Taub, OD, Pamela Schnell, OD  
*Glaucoma Grand Rounds* – James L. Fanelli, OD  
*Ocular Surface Review* – Paul M. Karpecki, OD  
*Retina Quiz* – Mark T. Dunbar, OD  
*Surgical Minute* – Derek Cunningham, OD, Walter Whitley, OD  
*Therapeutic Review* – Joseph W. Sowka, OD  
*Through My Eyes* – Paul M. Karpecki, OD  
*Urgent Care* – Alison Bozung, OD

#### Editorial Offices

19 Campus Blvd., Suite 101 • Newtown Square, PA 19073



Jobson Medical Information/WebMD  
395 Hudson Street, 3rd Floor, New York, NY 10014

Subscription inquiries: (877) 529-1746  
Continuing Education inquiries: (800) 825-4696

Printed in USA



BY JACK PERSICO  
EDITOR-IN-CHIEF  
**OUTLOOK**

# There They Go Again

*The anti-optometry lobby is repeating the same old tired arguments that the public never falls for.*

In October 1980, an otherwise run-of-the-mill presidential debate between Jimmy Carter and Ronald Reagan yielded an exchange that helped define Reagan's message and, if you believe the pundits, win him the election. After Carter painted Reagan as being opposed to Medicare—which by then had become untouchable, lest a politician risk losing the senior vote—Reagan smiled, shook his head and said, “There you go again.” With those four words, he painted Carter as a hysterical Chicken Little and himself as a level-headed pragmatist.

That long-ago exchange came to mind while reading the latest anti-optometry screed making the rounds. As we report in our news section, Virginia, Utah and several other states are advancing scope expansion laws at the moment, some including laser procedures. This prompted an ophthalmologist in Virginia to trot out all the usual arguments in a local newspaper: optometrists aren't surgeons, they don't even go to medical school (good heavens!) and their job is just to take care of vision problems while referring any patients with eye disease to an MD.

When I see arguments like this, I just want to shake my head and say, “There they go again.”

These arguments never work, even with a glossy coat of sophistry layered on top like in this particular case. In his op-ed, the MD noted that ophthalmologists undergo “at least 12 years of higher education” whereas optometrists “can practice eight or nine years after graduating high school.” Notice how he frames that distinction: MDs get *higher education* while you do some unspecified... stuff... after *high school*.

That's shameful, and shows how bankrupt the anti-optometry arguments are.

Obviously, no one should downplay risks or the need for qualifications. But they also shouldn't be inflated either. This MD has no problem being grandiose in his description of laser procedures in an attempt to raise the stakes: “In essence, we create microscopic explosions in the eye. And like any explosion, both good and bad impacts occur within the blast radius.” Really, the *blast radius*? Come on, dude—it's a YAG laser, not a stealth bomber.

He also likes to drift away from the specific procedures in question and wax philosophical about surgery as a concept, arguing that, “Providing safe surgical care to patients requires rigorous instruction and years of supervised residency training.” For an ILM peel? Absolutely. Same goes for a tube shunt, a DMEK or dozens of other complex eye surgeries that optometrists have no interest in. But SLT and capsulotomy are performed in an office setting, not an OR, without general anesthesia and without exposing patients to risk of intraocular infection. These are a qualitative differences that he conveniently ignores. Because he has to—the fact is that complication rates and malpractice rates are not higher among optometrists who perform such procedures.

When the facts aren't on the ophthalmology lobby's side, they resort to emotional ploys. But the results are always the same in the long run: legislatures look at the data, are reassured of public safety and support scope expansion. Hyperbole and hand-wringing may rile up the base, but they don't win against calm confidence. Just ask Jimmy Carter. ■



# UPNEEQ®

(oxymetazoline hydrochloride ophthalmic solution), 0.1%

## Now available to sell in your practice!\*




Sign up now at  
<https://upneeq.rvlpharma.com/signup>

\*Some states may not participate.

The only FDA-approved prescription eyedrop proven to lift upper eyelids in adults with acquired blepharoptosis (low-lying lids).<sup>1</sup>

## Imagine an EYE-OPENING Lift



Images are of actual patients. Individual results may vary. Average upper eyelid lift with Upneeq in clinical trials was 1 mm.<sup>2</sup>

### INDICATION

Upneeq® (oxymetazoline hydrochloride ophthalmic solution), 0.1% is indicated for the treatment of acquired blepharoptosis in adults.

### IMPORTANT SAFETY INFORMATION

#### WARNINGS AND PRECAUTIONS

- Ptosis may be associated with neurologic or orbital diseases such as stroke and/or cerebral aneurysm, Horner syndrome, myasthenia gravis, external ophthalmoplegia, orbital infection and orbital masses. Consideration should be given to these conditions in the presence of acquired ptosis with decreased levator muscle function and/or other neurologic signs.
- Alpha-adrenergic agonists as a class may impact blood pressure. Advise Upneeq patients with cardiovascular disease, orthostatic hypotension, and/or uncontrolled hypertension or hypotension to seek medical care if their condition worsens.
- Use Upneeq with caution in patients with cerebral or coronary insufficiency or Sjögren's syndrome. Advise patients to seek medical care if signs and symptoms of potentiation of vascular insufficiency develop.
- Upneeq may increase the risk of angle closure glaucoma in patients with untreated narrow-angle glaucoma. Advise patients to seek immediate medical care if signs and symptoms of acute narrow-angle glaucoma develop.
- Patients should not touch the tip of the single patient-use container to their eye or to any surface, in order to avoid eye injury or contamination of the solution.

### ADVERSE REACTIONS

Adverse reactions that occurred in 1-5% of subjects treated with Upneeq were punctate keratitis, conjunctival hyperemia, dry eye, blurred vision, instillation site pain, eye irritation, and headache.

### DRUG INTERACTIONS

- Alpha-adrenergic agonists, as a class, may impact blood pressure. Caution in using drugs such as beta blockers, anti-hypertensives, and/or cardiac glycosides is advised. Caution should also be exercised in patients receiving alpha adrenergic receptor antagonists such as in the treatment of cardiovascular disease, or benign prostatic hypertrophy.
- Caution is advised in patients taking monoamine oxidase inhibitors which can affect the metabolism and uptake of circulating amines.

**To report SUSPECTED ADVERSE REACTIONS or product complaints, contact RVL Pharmaceuticals at 1-877-482-3788. You may also report SUSPECTED ADVERSE REACTIONS to the FDA at 1-800-FDA-1088 or [www.fda.gov/medwatch](http://www.fda.gov/medwatch).**

**Please see next page for Brief Summary of full Prescribing Information.**

**References:** 1. Upneeq® (oxymetazoline hydrochloride ophthalmic solution), 0.1%. [Prescribing Information]. RVL Pharmaceuticals, Inc; 2021. 2. Data on file. RVL Pharmaceuticals, Inc.

**RVL**  
PHARMACEUTICALS, INC.

Distributed by: RVL Pharmaceuticals, Inc.  
Bridgewater, NJ 08807  
Customer Service 1-866-600-4799

Upneeq is a registered trademark of RVL Pharmaceuticals, Inc.  
©2022 RVL Pharmaceuticals, Inc. PM-US-UPN-0789 01/22



**UPNEEQ® (oxymetazoline hydrochloride ophthalmic solution), 0.1%, for topical ophthalmic use**

**BRIEF SUMMARY: The following is a brief summary only; see full Prescribing Information at <https://www.upneeq.com/Upneeq-PI.pdf> for complete information.**

## 1 INDICATIONS AND USAGE

UPNEEQ is indicated for the treatment of acquired blepharoptosis in adults.

## 2 DOSAGE AND ADMINISTRATION

Contact lenses should be removed prior to instillation of UPNEEQ and may be reinserted 15 minutes following its administration.

If more than one topical ophthalmic drug is being used, the drugs should be administered at least 15 minutes between applications.

## 4 CONTRAINDICATIONS

None.

## 5 WARNINGS AND PRECAUTIONS

### 5.1 Ptosis as Presenting Sign of Serious Neurologic Disease

Ptosis may be associated with neurologic or orbital diseases such as stroke and/or cerebral aneurysm, Horner syndrome, myasthenia gravis, external ophthalmoplegia, orbital infection and orbital masses. Consideration should be given to these conditions in the presence of ptosis with decreased levator muscle function and/or other neurologic signs.

### 5.2 Potential Impacts on Cardiovascular Disease

Alpha-adrenergic agonists may impact blood pressure. UPNEEQ should be used with caution in patients with severe or unstable cardiovascular disease, orthostatic hypotension, and uncontrolled hypertension or hypotension. Advise patients with cardiovascular disease, orthostatic hypotension, and/or uncontrolled hypertension/hypotension to seek immediate medical care if their condition worsens.

### 5.3 Potentiation of Vascular Insufficiency

UPNEEQ should be used with caution in patients with cerebral or coronary insufficiency, or Sjögren's syndrome. Advise patients to seek immediate medical care if signs and symptoms of potentiation of vascular insufficiency develop.

### 5.4 Risk of Angle Closure Glaucoma

UPNEEQ may increase the risk of angle closure glaucoma in patients with untreated narrow-angle glaucoma. Advise patients to seek immediate medical care if signs and symptoms of acute angle closure glaucoma develop.

### 5.5 Risk of Contamination

Patients should not touch the tip of the single patient-use container to their eye or to any surface, in order to avoid eye injury or contamination of the solution.

## 6 ADVERSE REACTIONS

### 6.1 Clinical Trials Experience

Because clinical trials are conducted under widely varying conditions, adverse reaction rates observed in the clinical trials of a drug cannot be directly compared to rates in the clinical trials of another drug and may not reflect the rates observed in practice.

A total of 360 subjects with acquired blepharoptosis were treated with UPNEEQ once daily in each eye for at least 6 weeks in three controlled Phase 3 clinical trials, including 203 subjects treated with UPNEEQ for 6 weeks and 157 subjects treated with UPNEEQ for 12 weeks. Adverse reactions that occurred in 1-5% of subjects treated with UPNEEQ were punctate keratitis, conjunctival hyperemia, dry eye, blurred vision, instillation site pain, eye irritation, and headache.

## 7 DRUG INTERACTIONS

### 7.1 Anti-hypertensives/Cardiac Glycosides

Alpha-adrenergic agonists, as a class, may impact blood pressure. Caution in using drugs such as beta-blockers, anti-hypertensives, and/or cardiac glycosides is advised.

Caution should also be exercised in patients receiving alpha adrenergic receptor antagonists such as in the treatment of cardiovascular disease, or benign prostatic hypertrophy.

### 7.2 Monoamine Oxidase Inhibitors

Caution is advised in patients taking MAO inhibitors which can affect the metabolism and uptake of circulating amines.

## 8 USE IN SPECIFIC POPULATIONS

### 8.1 Pregnancy

#### Risk Summary

There are no available data on UPNEEQ use in pregnant women to inform a drug-associated risk for major birth defects and miscarriage. In animal reproduction studies, there were no adverse developmental effects observed after oral administration of oxymetazoline hydrochloride in pregnant rats and rabbits at systemic exposures up to 7 and 278 times the maximum recommended human ophthalmic dose (MRHOD), respectively, based on dose comparison. [see Data]. The estimated background risks of major birth defects and miscarriage for the indicated population are unknown. All pregnancies have a background risk of birth defect, loss, or other adverse outcomes. In the U.S. general population, the estimated background risk of major birth defects and miscarriage in clinically recognized pregnancies is 2-4% and 15-20%, respectively.

#### Data

##### Animal Data

Effects on embryo-fetal development were evaluated in rats and rabbits following oral administration of oxymetazoline hydrochloride during the period of organogenesis. Oxymetazoline hydrochloride did not cause adverse effects to the fetus at oral doses up to 0.2 mg/kg/day in pregnant rats during the period of organogenesis (28 times the MRHOD, on a dose comparison basis). Oxymetazoline hydrochloride did not cause adverse effects to the fetus at oral doses up to 1 mg/kg/day in pregnant rabbits during the period of organogenesis (278 times the MRHOD, on a dose comparison basis). Maternal toxicity, including decreased maternal body weight, was produced at the high dose of 1 mg/kg/day in pregnant rabbits and was associated with findings of delayed skeletal ossification.

In a rat prenatal and postnatal development study, oxymetazoline hydrochloride was orally administered to pregnant rats once daily from gestation day 6 through lactation day 20. Maternal toxicity was produced at the high dose of 0.2 mg/kg/day (28 times the MRHOD, on a dose comparison basis) in pregnant rats and was associated with an increase in pup mortality and reduced pup body weights. Delayed sexual maturation was noted at 0.1 mg/kg/day (14 times the MRHOD, on a dose comparison basis). Oxymetazoline hydrochloride did not have any adverse effects on fetal development at a dose of 0.05 mg/kg/day (7 times the MRHOD, on a dose comparison basis).

### 8.2 Lactation

#### Risk Summary

No clinical data are available to assess the effects of oxymetazoline on the quantity or rate of breast milk production, or to establish the level of oxymetazoline present in human breast milk post-dose. Oxymetazoline was detected in the milk of lactating rats. The developmental and health benefits of breastfeeding should be considered along with the mother's clinical need for UPNEEQ and any potential adverse effects on the breastfed child from UPNEEQ.

### 8.4 Pediatric Use

Safety and effectiveness of UPNEEQ have not been established in pediatric patients under 13 years of age.

### 8.5 Geriatric Use

Three hundred and fifteen subjects aged 65 years and older received treatment with UPNEEQ (n = 216) or vehicle (n = 99) in clinical trials. No overall differences in safety or effectiveness were observed between subjects 65 years of age and older and younger subjects.

## 10 OVERDOSAGE

Accidental oral ingestion of topical intended solutions (including ophthalmic solutions and nasal sprays) containing imidazoline derivatives (e.g., oxymetazoline) in children has resulted in serious adverse events requiring hospitalization, including nausea, vomiting, lethargy, tachycardia, decreased respiration, bradycardia, hypotension, hypertension, sedation, somnolence, mydriasis, stupor, hypothermia, drooling, and coma. Keep UPNEEQ out of reach of children.

## PATIENT COUNSELING INFORMATION

Advise the patient to read the FDA-approved patient labeling (Instructions for Use).

**RVL**  
PHARMACEUTICALS, INC.

Manufactured for: RVL Pharmaceuticals, Inc.  
Bridgewater, New Jersey 08807  
©2021 RVL Pharmaceuticals, Inc.  
UPNEEQ is a registered trademark of RVL Pharmaceuticals, Inc.  
PM-US-UPN-0203 01/21

# LETTERS TO THE EDITOR

Feedback and ideas from the optometric community.

## SHARE YOUR THOUGHTS

Letters are welcome. Write to:  
[editor@reviewofoptometry.com](mailto:editor@reviewofoptometry.com).

Submissions may be edited for length,  
content or clarity.

## Femto Cataract Surgery: Is it Ready for Prime Time?

*Even impressive technology can fall short if it adds an onerous financial burden.*

The lust for money has forever plagued the human condition. As insurance payments for cataract surgery have decreased over the years, this has compelled surgery centers to seek additional revenue streams.

Enter femtosecond cataract surgery and “premium” IOLs, both of which come with large out-of-pocket costs for the patient, who is in almost all cases a senior citizen. While there are indeed many people ecstatic with their vision with so-called premium IOLs, a substantial amount of others are frustrated with their compromised vision from these same lens implants. When outcomes are highly variable and the price tag is high, doctors have a duty to be conservative in our recommendations.

We raised such concerns last year in the 2021 edition of our annual publication, *Clinical Perspectives on Patient Care*—and were taken to task in letters to the editor published in the October 2021 and November 2021 issues. Among other things, it was argued that because we are generalists rather than specialists in surgical comanagement, our impressions matter less than those with direct experience. We wish to delve into the topic some more to share the thoughts of surgeons on the front

lines as well as our take on what these experts have been telling us, anecdotally and in peer-reviewed journals.

Numerous studies have found that femto and traditional phaco yield virtually clinically equivalent outcomes.



**Drs. Melton, Thomas and Vollmer expand on their commentary about FLACS in response to previous letters.**

The enabling reasoning offered by surgeons who promote these products and services is that “premium” IOLs that aim to correct astigmatism or presbyopia are a precise technology and must be placed in the eye with equal precision—thus the “need” for femto-assisted cataract surgery.

A cataract surgeon at a prestigious medical center recently said to an ophthalmologist friend of ours, “femto is a device that prints money!”

The technology of “premium” IOLs may not be in its infancy, but it is still in its adolescence. Postoperative glare, halos and inadequate near vision correction are all so widespread that they require aggressive pre-op counseling of patients just to keep expectations somewhat reasonable. Ultimately, this technology may very well become standard of care, but such is not the case currently. I (Dr. Thomas) recently had a consultation with a lady who had been “sold” a \$4,000-per-eye surcharge from a slick-talking “premium” cataract surgeon in a large city. One of our

surgeons, who performs standard phaco and standard monofocal IOL implantation, was consulted at my request. This lady is now thrilled with her vision and thanked me profusely for saving her \$8,000!

In a point-counterpoint debate that took place at the 2021 American Society of Cataract and Refractive Surgery annual meeting, one surgeon stated that his femto laser broke down after over one thousand cases, forcing a return to manual surgery. “What I found was that we were doing one less eye per hour with femto,” he was quoted as saying. “A little more anesthesia and pre-treatment with NSAIDs also were required for femto. Manual surgery is more efficient and decreases the cost for equivalent outcomes.”<sup>1</sup> In a follow-up personal correspondence with this surgeon, he stated, “Even after doing one thousand consecutive femto cases, I could still find no cogent reason to continue. It’s a costly burden at best, and I haven’t done one in years.”

### Thumbs Down from the Academy

Defenders will argue that, in their centers, results are fantastic and patients are elated. That surely is true in some places, but we think it’s very telling that femto cataract has not yet been endorsed by the largest and most prestigious organization in ophthalmology. In October 2021, the American Academy of Ophthalmology released its latest position paper on cataract surgery, which states:<sup>2</sup>

*“Femtosecond laser-assisted cataract surgery (FLACS) increases the circularity and centration of the capsulorhexis and the precision of the corneal incisions. It may also reduce the amount of ultrasonic energy required to remove a cataract. However, the technology is not yet cost-effective, and the overall risk profile and refractive outcomes have not been shown to be superior to that of standard phacoemulsification.”*



*“New technology in cataract surgery, including the use of advanced technology IOLs and femtosecond lasers, represents an increased out-of-pocket expense for cataract patients. Currently, these technologies are used in a small portion of total cases, but their use is expected to increase over the coming years. Also, [while] some benefits of new technology are clear, others remain ambiguous. Their use does add to the patient’s economic healthcare burden.”*

There you have it: the voice of organized ophthalmology in America says FLACS is not, in fact, ready for prime time.

A previous letter to the editor noted that American journals and surgeons represent the gold standard for outcomes and interpretation of femto’s surgical merit, so let’s look at a few. An article published in *JCRS* in 2020 concludes: “Both femto and phaco are effective and safe. Femto requires less ultrasonic energy and a more precise treatment. However, mid-term visual acuity did not show any difference between both methods.”<sup>3</sup>

In the October 2019 issue of *AJO*, we find the following quote: “Our

study supports the well established similarity between femto and phaco with regard to visual and refractive outcomes in a very large, consecutive cohort. However, our results support the potential role for femto in more difficult cases, although large randomized studies in such cases are needed to further delineate this trend. Surgeon experience and comfort, patient preference and economic considerations remain critical factors of consideration for the choice of cataract surgery modality.”<sup>4</sup>

An article found in the August 2020 issue of *Ophthalmology* offers these conclusions: “The results of this trial with three-month postoperative data found that phaco is as good as femto in terms of vision, patient-reported health and safety outcomes at three months. Longer term outcomes in terms of clinical and cost-effectiveness are awaited. Additional randomized clinical trial data and meta-analysis are required to further investigate possible differences between the surgical methods because of the low complication rates and apparent similar efficacy.”<sup>5</sup>

## Our Take on Femto

According to a preponderance of the literature, the advantage of “premium” IOLs and femtosecond surgery is evolving. FLACS is definitely no worse than conventional phaco and we do see the value it can offer in astigmatism reduction at the time of cataract surgery—corneal incisions can indeed be made very precisely with the laser. For patients with endothelial compromise, the femto laser allows for less ultrasound energy to be used. Dense cataracts can be chopped more easily with the laser. Some premium IOL patients get marginally better visual outcomes.

But none of that addresses FLACS’s added cost, especially in light of its only modest clinical gains. Based on the humanitarian principle of caring for others in a manner in which you would like to be cared for, we feel femto and “premium” IOLs are not delivering a premium experience for most patients.

For many years, there has been a quest for reducing healthcare costs to American citizens. With finite healthcare resources, it is our responsibility to practice cost-effective, evidence-based medicine. Need more be said?

*Randall Thomas, OD, MPH  
Concord, NC*

*Ron Melton, OD  
Charlotte, NC*

*Patrick Vollmer, OD  
Shelby, NC*

## INTERNATIONAL VOICES JOIN THE CHORUS

If the above-quoted papers aren’t enough to document the serious misgivings that many in the ophthalmology community have, there are plenty more available to those who want to look. Here are a few from our colleagues overseas:

- A retrospective study of 50 FLACS and 50 conventional phaco surgeries performed in Egypt concluded: “Femtosecond laser-assisted cataract surgery was a safe and precise procedure, but enhanced visual outcomes only minimally when compared to conventional cataract surgery in experienced hands. Both FLACS and manual surgeries can achieve high efficiency, predictability and safety with slight superior outcomes in FLACS.”<sup>1</sup>

- In a cost effectiveness study conducted in the UK, research found that FLACS is “non-inferior” to phaco cataract surgery (PCS) in terms of vision and safety. While FLACS did clear that rather low bar, it was not considered cost effective enough to recommend. “We did not find evidence for a change in practice to adopt FLACS in preference to PCS,” the authors stated. In a summary intended for the public, they explained it as follows: “We found that the outcomes were almost identical for eyesight, quality of life and complications. Overall, the evidence suggests that the new technique is not worth the additional costs.”<sup>2</sup>

- A study of 704 eyes and 685 PCS eyes conducted for the French Ministry of Social Affairs and Health concluded: “Despite its advanced technology, femtosecond laser was not superior to phacoemulsification in cataract surgery and, with higher costs, did not provide an additional benefit over phacoemulsification for patients or healthcare systems.”<sup>3</sup>

1. Shaheen MS, AbouSamra A, Helaly HA, et al. Comparison Between Refractive Outcomes of Femtosecond Laser-Assisted Cataract Surgery and Standard Phacoemulsification. *BMC Ophthalmology*. 2020;20:1.

2. Day AC, Burr JM, Bennett K, et al. Femtosecond laser-assisted cataract surgery compared with phacoemulsification: the FACT non-inferiority RCT. *Health Technol Assess*. 2021 Jan;25(6):1-68.

3. Schweitzer C, Brezin A, Cochener B, et al. Femtosecond laser-assisted versus phacoemulsification cataract surgery (FEMCAT): a multicentre participant-masked randomised superiority and cost-effectiveness trial. *Lancet*. 2020 Jan 18;395(10219):212-224.

1. 2021 American Society of Cataract and Refractive Surgery, Las Vegas, NV. As quoted in “LACS vs. Manual Surgery,” *EuroTimes*, October 1, 2021. Available at [www.eurotimes.org/lacs-vs-manual-cataract-surgery](http://www.eurotimes.org/lacs-vs-manual-cataract-surgery).

2. Miller KM, Oetting TA, Tweeten JP, Carter K, Lee BS, Lin S, Nanji AA, Shorstein NH, Musch DC; American Academy of Ophthalmology preferred practice pattern cataract/anterior segment panel. Cataract in the Adult Eye Preferred Practice Pattern. *Ophthalmol*. 2022;129(1):1-126.

3. Kolb CM, Shajari M, Mathys L, Herrmann E, Petermann K, Mayer WJ, Priglinger S, Kohnen T. Comparison of femtosecond laser-assisted cataract surgery and conventional cataract surgery: a meta-analysis and systematic review. *J Cataract Refract Surg*. 2020;46(8):1075-85.

4. Nithiandan H, Jegatheeswaran V, Dalal V, et al. Refractive laser-assisted cataract surgery versus conventional manual surgery: comparing efficacy and safety in 3,144 eyes. *Am J Ophthalmol*. 2019;206:32-39.

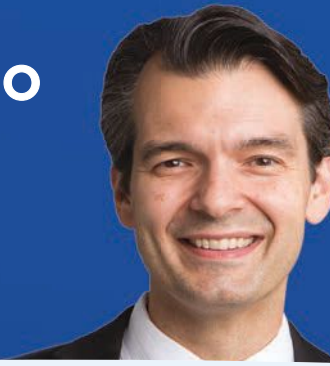5. Day AC, Burr JM, Bennett K, et al. Femtosecond Laser-assisted cataract surgery versus phacoemulsification cataract surgery (FACT). *Ophthalmol*. 2020;127:1012-19.

From the experts

# Why add a compress to your patients' dry eye treatment?

Answered by Dr. Mile Brujic, OD, FAAO

**Bruder**  
Better. By Design.

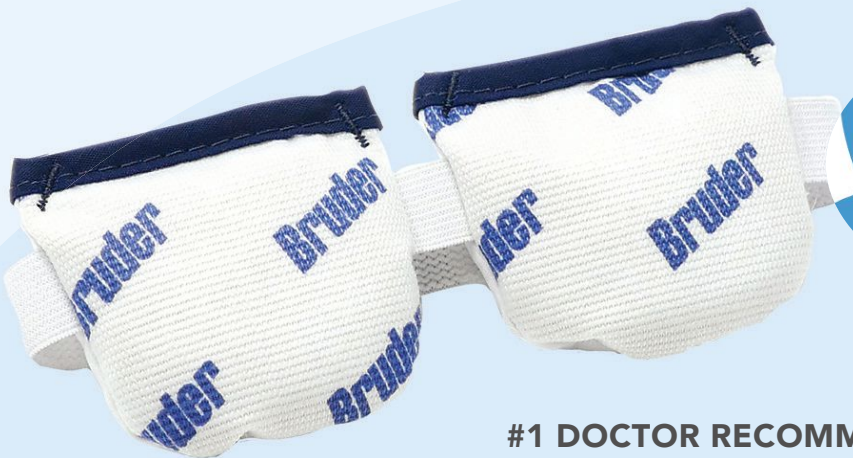

“The Bruder Compress is the centerpiece of an effective ocular wellness routine. It gets the meibum moving and keeps it moving so glands do not remain clogged.”

– Dr. Mile Brujic, Premier Vision Group

The **Bruder Moist Heat Eye Compress** has been clinically proven to meet the target heat and duration needed to unclog meibomian glands without dangerous hot spots.<sup>1</sup>

- ✓ Naturally alleviates dry eye symptoms
- ✓ Hydrates and stabilizes the eye surface
- ✓ Keeps oil glands functioning properly
- ✓ Helps maintain daily eye health
- ✓ A fundamental part of a dry eye treatment strategy



Join us in **SECO Booth 1325** to receive a complimentary sample and learn about our new retail packaging option.

**#1 DOCTOR RECOMMENDED**  
Accept No Substitutes

©2022 Bruder Healthcare Company Alpharetta, GA 30004

1. Tan J, Ho L, Wong K, et al. Cont Lens Anterior Eye. 2018;41(1):83-87.



Learn more

Ready to bring relief to your patients? Visit [order.bruder.com](https://order.bruder.com).

Have a question or want to learn more about our full line of products? Give us a call at 888-827-8337 or email [eyes@bruder.com](mailto:eyes@bruder.com)



BY PAUL M. KARPECKI, OD  
CHIEF CLINICAL EDITOR

## THROUGH MY EYES

# Spruce Up Your Practice

*Focus on new additions that can set you up for further success.*

**A**lthough optometry has succeeded in differentiating itself via ocular disease management, contact lenses and spectacles, adding new areas of expertise can quickly invigorate your practice and create huge growth opportunities for the foreseeable future. This month, we'll look at presbyopia, neuro-optometry and myopia management, and I'll summarize where I believe you can best succeed and find the area that you are most passionate about—and own it.

## Presbyopia

Your success in this area will depend on how well you educate and communicate with your patients. First, recognize that most patients don't understand presbyopia. I often hear this chief complaint: "My LASIK has worn off." My assumption was that they regressed and are slightly myopic, only to find that the patient is 46 years old, plano in both eyes and can no longer read. Use an eye model, animations like Rendia or your best explanation to help patients recognize that the lens in the eye ages like our skin, nails and hair. Describe common symptoms they can relate to, such as night vision problems and having to make lights brighter, followed by difficulty reading and eventually full cataracts that require surgery.

Eye drops are a new development worth exploring, as well as determining the most appropriate candidates. Also, educate patients on the newest progressive spectacle lens option, NeuroLens (eyeBrain Medical), for

those who haven't found success with progressive lenses and presbyopia-correcting contact lenses. For those with cataracts, discuss comanagement intraocular lens (IOL) options, including light-adjustable lenses (RxSight) and trifocal and extended depth-of-focus IOLs.



**Adding new areas of expertise can quickly invigorate your practice and create huge growth opportunities for the foreseeable future.**



## Neurological Conditions

Let's face it, not everyone is accurate at performing the swinging flashlight test for neurological pupil assessment, and that's frightening considering that a missed diagnosis could mean an impending aneurysm or brain tumor. I encourage you to look into new diagnostics like EyeKinetix (Konan Medical) that can objectively perform accurate pupil assessments in less than 40 seconds.

If you don't think there are enough cases of these rare neurological conditions, consider that over 95% of all patients with early glaucoma have a subtle relative afferent pupillary defect that can be detected with this technology. Combine that with hysteresis (and the usual glaucoma tests like IOP, OCT, optic nerve assessment, visual field testing) and you'll have a good idea of which patients should start medication or undergo SLT.

If you haven't been an expert in binocular vision, NeuroLens can help build your skills in this area. This device can accurately and objectively measure heterophorias, vergence conditioning, fixation disparity and accommodative convergence response in 90 seconds. More importantly, it provides information to prescribe the exact prism necessary (customized for near) to solve patients issues, whether it be headaches, dizziness, asthenopia or others.

New visual field testing technology including virtual reality headsets (Hilco Vision, OllEyes) and objective field testing (Konan) are making things easier on patients as well.

## Myopia

What better opportunity can exist than targeting a condition that affects 34% of the US population and is expected to surpass 50% within the next three decades? Get familiar with the various options, as some kids (or parents) won't be able to insert contact lenses, bifocal spectacles may cause falls and low-dose atropine may not be tolerated by all children. Orthokeratology lenses may work better for some kids; in others, soft contact lenses are preferred. New diagnostic devices such as Myopia Master (Oculus) can help with optimizing treatment and monitoring progression. Lastly, educate parents and children on reducing near tasks like using iPads and have children spend at least 90 minutes per day outdoors.

One of the greatest things about optometry is the many choices available in how you want to practice. But to truly be successful in the coming decades, you'll need to find additional areas of focus. This will allow you to practice longer, enjoy your time in clinic more, become more profitable, and most importantly, have a profound impact on your patients' lives. ■

About  
Dr. Karpecki

**Dr. Karpecki** is the director of Cornea and External Disease for Kentucky Eye Institute, associate professor at KYCO and medical director for Keplr Vision and the Dry Eye Institutes of Kentucky and Indiana. He is also chair of the New Technologies & Treatments conferences. He consults for a wide array of ophthalmic clients, including ones discussed in this article. Dr. Karpecki's full disclosure list can be found in the online version of this article at [www.reviewofoptometry.com](http://www.reviewofoptometry.com).



# AMD Awareness Begins with Early Detection

AMD used to be managed almost exclusively by retinologists, but as the American Academy of Ophthalmology notes, “early detection is a critical first step.”<sup>1</sup> Indeed, the focus has shifted from late-stage treatment to strategies aimed at protecting vision from early through intermediate stage disease. In response, optometrists have tightened up their screening, monitoring, and management protocols. As we enter AMD Awareness Month, several ODs answer practical questions about how they’ve adapted to the modern AMD paradigm.

## What is the AMD screening protocol in your practice?



**Dr. Claudio Lagunas:** Dark adaptation testing is the norm in our practice, rather than the exception. Every single patient age 50 or older gets tested and monitored accordingly, which is now an achievable goal thanks to a portable, head-mounted dark adaptometer with a built-in technician.



**Dr. Tammy Tully:** We also screen every patient over age 50 with an AdaptDx Pro<sup>®</sup> Rapid Test and, if their dark adaptation is impaired, we bring them back for an Extended Test and an OCT. Next, based on the results of the Extended Test, we monitor them based on the level of dark adaptation impairment (higher RI score).



**Dr. Frances Bynum:** I strongly maintain that diagnostic and screening standards can and should vary based on practice risk demographics. If your patients are predominantly physically-fit 30-year-olds, your testing protocol might look a little different than mine. Many of my patients are Caucasian and have a little extra around the middle, so I start testing dark adaptation in all patients beginning at age 40.

## How frequently are you diagnosing AMD with your protocol?



**Dr. Gary Kirman:** From 2014 to 2018, we routinely tested patients age 60 and older and found 40% of those tested to have abnormal dark adaptation in one or both eyes. From 2018-2019, we started testing patients 55 and older. Our results showed 7% of patients from ages 55 to 59 had abnormal dark adaptation. We are currently looking at what additional percentage of patients will have abnormal dark adaptation between ages 50 to 54.



**Dr. Amanda Legge:** When we started testing every patient over age 60, we found that we had about a 30% impairment rate among new and established patients who had never before undergone dark adaptation testing.

## How does dark adaptation testing help you monitor AMD patients?



**Dr. Paul Karpecki:** Functional testing complements the structural testing even more profoundly when monitoring AMD than it does in the initial diagnosis. Now that I can see the Rod Intercept<sup>®</sup> time, I can monitor cases very closely and refer for injections as soon as conversion occurs, when the patient’s vision is still very good.



**Dr. Pamela Lowe:** Before dark adaptation testing, I had to rely on my gut a lot more than I do now. It’s a relief to have so much more confidence with such a high-stakes condition. In this regard, the AdaptDx has really made AMD care so much easier in my practice.



**Dr. Tammy Tully:** The RI score helps me decide how soon I need to see the patient back. And I am confident it’s working because even though we’ve had patients convert to CNV, our elevated standard of care with more frequent monitoring gave us the opportunity to ensure that they were promptly referred for injections while their vision was still 20/20.

---

<sup>1</sup> <https://www.aao.org/newsroom/observances>



# Word on the Street is Nothing's Easy

*If you're in need of convincing, you've come to the right place.*

I have always believed that there are only two things you can actually count on in life. No, not death and taxes. Taxes? I pay them, but I don't actually *believe* in them. Death? As a famous comedian once said, "I intend to live forever. So far, so good." The two things: (1) Kohl's is having a sale. (2) Nothing's easy.

Now, (1) we can all agree on. For optometry, (2) has, shall we say, evolved.

"Easy" depends on the situation. I kind of remember the first time I tried a soft contact lens on a patient. I stuck a PMMA hard lens on one eye and that first available soft lens on the other. Guess which one the patient picked? Okay, I am man enough to admit that this was easy.

In those pre-tech days, nobody really cared if they could actually see through contact lenses as long as they did not have to wear glasses, which was, at the time, a sign of weakness until Elton John proved everyone wrong.

But 99% of the time, nothing's easy. When we had one or two soft contact lenses, everyone loved them. Now we have hundreds and hundreds, and even I myself change my contacts a couple of times a day because there is always bound to be one that works better, right? Man, I only wish I knew a good eye doctor.

And what about collecting fees? After years of concentrated effort, I finally changed the policy at my late mentor and partner's office. Patients

now have to pay for their glasses by the time they pick them up instead of paying \$5 every 90 days forever, which was his policy. That's right. He'd send a 30- then a 60- then a 90-day notice, threaten them with collection and, if they sent him five bucks, start over! He told me we'd never be able to get patients to pay in full. I offered a 10% discount if they paid in full at the time of the order. Every old farmer in West Virginia whipped out a wad of hundreds and let them go! For a short while, okay, this too was easy.

Then along came vision insurance. Now, once again, in case you've forgotten, let me remind you that nothing's easy. If you are an optometrist and are breathing, you know what I mean. Let's not pick on anybody. Let's just say that nothing's easy and leave it at that.

Staff? We used to be friends. We used to exchange Christmas cards. They showed up on time. They smiled. They knew and loved every single patient, and every single patient loved them right on back. They loved their doctors and coworkers, too. Ahhh, so easy.

Now, nothing's easy. I can't remember the last time every single one of

my staff members showed up on time. They used to crawl in the door even if they had two broken legs. Not anymore; times have changed, I tell ya.

"I found an ant on my front door and, I'm sorry, but I just can't come in today." Here's what I have to say to that, "Why, that's terrible! Tell you what, my wonderful staffer, take a week. In fact, take 52 weeks a year for the rest of your life. Good luck with your ant problem." Point proven: nothing's easy.

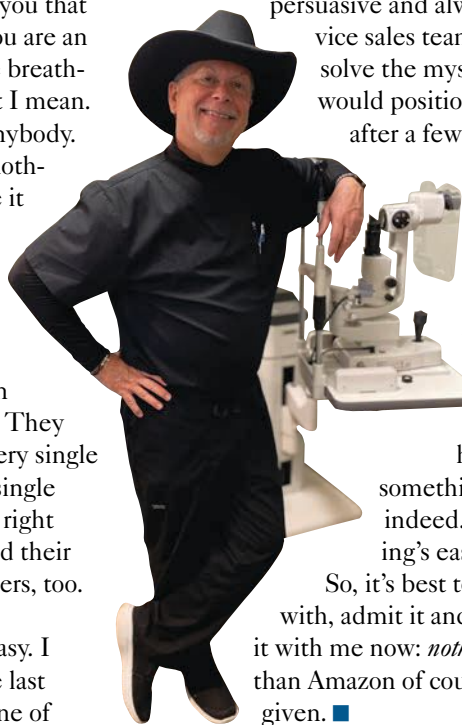
Yes, nothing's easy. For the first three-fourths of my career, I recall time and time again observing something very unusual in a patient's eye and thinking to myself, "Hmm, that's something very unusual." Then, the wonders of technology created elegant ways to scan the details of every single cell. Just by spending a few tens of thousands of dollars and upgrading my office hardware and software, I was convinced (by the delightfully

persuasive and always handsome device sales team) that *this* would solve the mysteries of the eye. I would position the patient and, after a few seconds, immediately witness

the beauty of technicolored, fantastical and utterly endearing multiple images that revealed the truth: that whatever I

had observed was something very unusual indeed. Dare I say, nothing's easy.

So, it's best to just get it over with, admit it and move on. Say it with me now: *nothing's easy*. Other than Amazon of course, but that's a given. ■



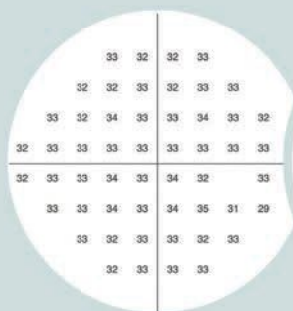
About  
Dr. Vickers

Dr. Vickers received his optometry degree from the Pennsylvania College of Optometry in 1979 and was clinical director at Vision Associates in St. Albans, WV, for 36 years. He is now in private practice in Dallas, where he continues to practice full-scope optometry. He has no financial interests to disclose.


# Increase your practice efficiency and productivity with the **VisuALL VRP**

The **VisuALL Virtual Reality Platform** delivers fast, comfortable, and clinically validated visual field examinations and more.


For more information, visit [olleyes.com](http://olleyes.com)



VISUAL FIELD



VISUAL ACUITY



COLOR VISION

1-855-OLLEYES (1-855-655-3937) / [info@olleyes.com](mailto:info@olleyes.com)  
350 Springfield Ave, Suite 200 Summit, NJ 07901







EDITED BY PAUL C. AJAJIAN, OD

## CLINICAL QUANDARIES

# Secret Serum

*Treating LASIK-induced dry eye requires restoration of the ocular surface.*

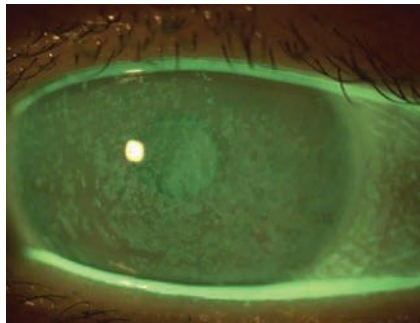**Q** I have a 35-year-old female patient with recalcitrant dry eyes post-LASIK who has not responded to any traditional therapies and is now at her wit's end. Any other options?

**A** "LASIK surgery is the most performed refractive surgical procedure worldwide," says Mahnia Madan, OD, of Vancouver Eye Doctor, in Vancouver, BC." Even though post-op complications are rare, approximately half of all LASIK patients experience dry eye symptoms for up to six months after surgery."<sup>1,2</sup>

In most cases, these symptoms resolve with traditional management, which includes non-preserved lubricating eye drops, punctal plugs, oral supplementation with omega-3 essential fatty acids and/or topical anti-inflammatory agents.<sup>2,3</sup> However, as many as 20% of these patients may develop chronic LASIK-associated dry eye not responsive to traditional therapies.<sup>1,2</sup> The post-LASIK chronic dry eye can vary from mild pain sensation to severe and disabling chronic pain.<sup>2,4</sup>

### Vicious Cycle

Although much is still not understood about LASIK-induced dry eye, current evidence suggests that flap creation during LASIK causes significant damage to corneal nerves and is the most likely cause of dry eye symptoms after refractive surgery.<sup>2,4</sup> Confocal microscopy images of cornea after LASIK have shown structural changes to the corneal nerves and loss of subbasal corneal nerve plexuses.<sup>3,5</sup> Furthermore, alteration in the concentration of neuropep-



**Patients with chronic LASIK-induced dry eye may require advanced therapies.**

tides in tears following LASIK has also been linked to dry eye disease.<sup>2</sup>

According to Dr. Madan, corneal nerves play a key role in maintaining the ocular surface homeostasis. Disruption of these corneal nerves leads to decreased corneal sensitivity, which in turn leads to disruption of corneal/lacrimal gland and corneal/blinking reflex loops.<sup>4,5</sup> A reduced blink rate may further prevent proper meibomian gland secretion and/or excretion, perpetuating the entire dry eye cycle.<sup>4,5</sup>

### Management Options

"For these patients, I recommend using platelet-rich plasma (PRP) eye drops, which are a preservative-free biological product made from the patient's own blood," Dr. Madan says.

Platelets are a major source of growth factors that can aid in proliferation, migration and differentiation of corneal epithelial cells, thus helping to heal the ocular surface of the post-LASIK eye.<sup>1,5</sup> Because PRP contains a higher concentration of growth factors and other platelet-derived factors,

many consider it superior to autologous serum for healing. Studies have also reported an increase in corneal subbasal nerve plexus density due to the action of nerve growth factor (NGF) present in PRP, a possible pathway to managing patients with corneal nerve injury.<sup>5,6</sup>

Although PRP is widely used in medicine and dentistry, its availability in eye care is still limited. Optometrists looking to implement a PRP system in their own practice may find some commercially available companies that provide this (depending on their state's laws) or work with their local compounding pharmacies and labs to make their own drops. Patients can expect to spend \$400 to \$600 for a three-month supply of PRP eye drops.

This patient used PRP eye drops four times a day for three months, and the keratitis improved significantly. Along with using them, Dr. Madan also recommends treating coexisting lid disease aggressively in these patients. Disruption of the corneal-blink reflex loop due to damage to corneal nerves can lead to meibomian gland dysfunction in post-LASIK patients.<sup>6,7</sup> "I also treat these patients with intense pulse light therapy followed by maintenance at-home with lid hygiene," she says. ■

1. Alio JL, Rodriguez AE, Abdelghany AA, Oliveira RF. Autologous platelet-rich plasma eye drops for the treatment of post-LASIK chronic ocular surface syndrome. *J Ophthalmol.* 2017;2017:2457620.
2. Chao C, Golebiowski B, Stapleton F. The role of corneal innervation in LASIK-induced neuropathic dry eye. *Ocul Surf.* 2014;12(1):32-45.
3. Labetoulle M, Baudouin C, Calonge M, et al. Role of corneal nerves in ocular surface homeostasis and disease. *Acta Ophthalmol.* 2019;97(2):137-45.
4. Yang AY, Chow J, Liu J. Corneal innervation and sensation: the eye and beyond. *Yale J Biol Med.* 2018;91(1):13-21.
5. Toda I. Dry eye after LASIK. *Invest Ophthalmol Vis Sci.* 2018;59(14):DES109-15.
6. Fea AM, Aragno V, Testa V, et al. The effect of autologous platelet lysate eye drops: an in vivo confocal microscopy study. *Biomed Res Int.* 2016;2016:8406832.
7. Wu Y, Xu L, Song Y, et al. Management of post-LASIK dry eye with intense pulsed light in combination with 0.1% sodium hyaluronate and heated eye mask. *Ophthalmol Ther.* November 6, 2021. [Epub ahead of print].

About  
Dr. Ajajian

Dr. Ajajian is the center director of Omni Eye Services of Atlanta and is board-certified by the American Board of Optometry. He currently serves as general chairman of the education committee for SECO International and the Georgia State Board of Optometry. He has no financial interests to disclose.



# Neurotrophic keratitis is a degenerative disease that warrants immediate attention<sup>1</sup>

oxervate®   
(cenegermin-bkbj ophthalmic solution) 0.002% (20 mcg/mL)

## OXERVATE is the first FDA-approved pharmacologic treatment that targets the root pathogenesis of neurotrophic keratitis (NK)<sup>2</sup>

Cenegermin-bkbj, the active ingredient in FDA-approved OXERVATE, is structurally identical to the human nerve growth factor (NGF) protein made in ocular tissues.<sup>3</sup>

Endogenous NGF is a protein involved in the differentiation and maintenance of neurons and is believed to support corneal integrity through three mechanisms (in preclinical models): corneal innervation, tear secretion, and epithelial cell growth.<sup>3-5</sup>

## In clinical studies, with a single 8-week course of therapy:

- Up to 72% of patients with NK achieved complete corneal healing<sup>\*†2</sup>
- 80% of patients who achieved complete corneal healing remained completely healed at 1 year (REPARO trial)<sup>6</sup>

OXERVATE is a recombinant human nerve growth factor indicated for the treatment of neurotrophic keratitis.

## Important Safety Information

### WARNINGS AND PRECAUTIONS

Patients should remove contact lenses before applying OXERVATE and wait 15 minutes after instillation of the dose before reinsertion.

### ADVERSE REACTIONS

The most common adverse reaction in clinical trials that occurred more frequently with OXERVATE was eye pain (16% of patients). Other adverse reactions included corneal deposits, foreign body sensation, ocular hyperemia, ocular inflammation, and increase in tears (1%-10% of patients).

Please see additional Important Safety Information on accompanying page and full Prescribing Information, including patient information, at [OXERVATE.com/prescribing-information](https://www.oxervate.com/prescribing-information).

You may report side effects to FDA at 1-800-FDA-1088 or [www.fda.gov/medwatch](https://www.fda.gov/medwatch). You may also report side effects to Dompé at 1-833-366-7387 or [Usmedinfo@dompe.com](mailto:Usmedinfo@dompe.com).

 **TREAT NK TODAY**  
[OXERVATE.com/HCP](https://www.oxervate.com/HCP)

<sup>\*</sup>Study NGF0212 (REPARO): 52 patients per group; European patients with NK in one eye; 72% of patients completely healed; key findings were after 8 weeks of treatment; 6 times daily; vehicle response rate 33.3%.<sup>2</sup> Study NGF0214: 24 patients per group; US patients with NK in one or both eyes; 65.2% completely healed; vehicle response rate 16.7%.<sup>2,7</sup>

<sup>†</sup>Complete corneal healing was defined as the absence of staining of the corneal lesion and no persistent staining in the rest of the cornea after 8 weeks of OXERVATE treatment.<sup>2</sup>

**References:** 1. Sacchetti M, Lambiase A. Diagnosis and management of neurotrophic keratitis. *Clin Ophthalmol*. 2014;8:571-579. 2. OXERVATE (cenegermin-bkbj) ophthalmic solution 0.002% (20 mcg/mL) [US package insert]. Boston, MA: Dompé U.S. Inc.; 2019. 3. Voelker R. New drug treats rare, debilitating neurotrophic keratitis. *JAMA*. 2018;320:1309. 4. Mastropasqua L, Massaro-Giordano G, Nubile M, Sacchetti M. Understanding the pathogenesis of neurotrophic keratitis: the role of corneal nerves. *J Cell Physiol*. 2017;232:717-724. 5. Muzi S, Colafrancesco V, Somelli F, et al. Nerve growth factor in the developing and adult lacrimal glands of rat with and without inherited retinitis pigmentosa. *Cornea*. 2010;29:1163-1168. 6. Data on file. Dompé U.S. Inc.; 2021. NGF0212. 7. Pflugfelder SC, Massaro-Giordano M, Perez VL, Hamrah P, Deng SX, Espandar L, et al. Topical recombinant human nerve growth factor (cenegermin) for neurotrophic keratopathy. *Ophthalmology*. 2020;127:14-26.



© 2021 Dompé U.S. Inc.  
All rights reserved.  
US-OXE-1900180.02.02/21



## Brief Summary of Safety

Consult the full Prescribing Information for complete product information.

### INDICATIONS AND USAGE

OXERVATE™ (cenegermin-bkbj) ophthalmic solution 0.002% is indicated for the treatment of neurotrophic keratitis.

### DOSAGE AND ADMINISTRATION

Contact lenses should be removed before applying OXERVATE and may be reinserted 15 minutes after administration.

If a dose is missed, treatment should be continued as normal, at the next scheduled administration.

If more than one topical ophthalmic product is being used, administer the eye drops at least 15 minutes apart to avoid diluting products. Administer OXERVATE 15 minutes prior to using any eye ointment, gel or other viscous eye drops.

### Recommended Dosage and Dose Administration

Instill one drop of OXERVATE in the affected eye(s), 6 times a day at 2-hour intervals for eight weeks.

### ADVERSE REACTIONS

Clinical Studies Experience Because clinical studies are conducted under widely varying conditions, adverse reaction rates observed in the clinical studies of a drug cannot be directly compared to rates in the clinical studies of another drug and may not reflect the rates observed in practice.

In two clinical trials of patients with neurotrophic keratitis, a total of 101 patients received cenegermin-bkbj eye drops at 20 mcg/mL at a frequency of 6 times daily in the affected eye(s) for a duration of 8 weeks. The mean age of the population was 61 to 65 years of age (18 to 95). The majority of the treated patients were female (61%). The most common adverse reaction was eye pain following instillation which was reported in approximately 16% of patients. Other adverse reactions occurring in 1-10% of OXERVATE patients and more frequently than in the vehicle-treated patients included corneal deposits, foreign body sensation, ocular hyperemia, ocular inflammation and tearing.

### USE IN SPECIFIC POPULATIONS

#### Pregnancy

Risk Summary There are no data from the use of OXERVATE in pregnant women to inform any drug associated risks.

Administration of cenegermin-bkbj to pregnant rats or rabbits during the period of organogenesis did not produce adverse fetal effects at clinically relevant doses. In a pre- and postnatal development study, administration of cenegermin-bkbj to pregnant rats throughout gestation and lactation did not produce adverse effects in offspring at clinically relevant doses.

#### Animal Data

In embryofetal development studies, daily subcutaneous administration of cenegermin-bkbj to pregnant rats and rabbits throughout the period of organogenesis produced a slight increase in post-implantation loss at doses greater than or equal to 42 mcg/kg/day (267 times the MRHOD). A no observed adverse effect level (NOAEL) was not established for post-implantation loss in either species.

In rats, hydrocephaly and ureter anomalies were each observed in one fetus at 267 mcg/kg/day (1709 times the MRHOD). In rabbits, cardiovascular malformations, including ventricular and atrial septal defects, enlarged heart and aortic arch dilation were each observed in one fetus at 83 mcg/kg/day (534 times the MRHOD). No fetal malformations were observed in rats and rabbits at doses of 133 mcg/kg/day and 42 mcg/kg/day, respectively. In a pre- and postnatal development study, daily subcutaneous administration of cenegermin-bkbj to pregnant rats during the period of organogenesis and lactation did not affect parturition and was not associated with adverse toxicity in offspring at doses up to 267 mcg/kg/day. In parental rats and rabbits, an immunogenic response to cenegermin-bkbj was observed. Given that cenegermin-bkbj is a heterologous protein in animals, this response may not be relevant to humans.

#### Lactation

There are no data on the presence of OXERVATE in human milk, the effects on breastfed infant, or the effects on milk production. The developmental and health benefits of breastfeeding should be considered, along with the mother's clinical need for OXERVATE, and any potential adverse effects on the breastfed infant from OXERVATE.

#### Pediatric Use

The safety and effectiveness of OXERVATE have been established in the pediatric population. Use of OXERVATE in this population is supported by evidence from adequate and well-controlled trials of OXERVATE in adults with additional safety data in pediatric patients from 2 years of age and older [see *Clinical Studies* (14)].

#### Geriatric Use

Of the total number of subjects in clinical studies of OXERVATE, 43.5 % were 65 years old and over. No overall differences in safety or effectiveness were observed between elderly and younger adult patients.

### NONCLINICAL TOXICOLOGY

Carcinogenesis and Mutagenesis Animal studies have not been conducted to determine the carcinogenic and mutagenic potential of cenegermin-bkbj.

Impairment of fertility Daily subcutaneous administration of cenegermin-bkbj to male and female rats for at least 14 days prior to mating, and at least 18 days post-coitum had no effect on fertility parameters in male or female rats at doses up to 267 mcg/kg/day (1709 times the MRHOD). In general toxicology studies, subcutaneous and ocular administration of cenegermin-bkbj in females was associated with ovarian findings including persistent estrus, ovarian follicular cysts, atrophy/reduction of corpora lutea, and changes in ovarian weight at doses greater than or equal to 19 mcg/kg/day (119 times the MRHOD).







BY MARC B. TAUB, OD, MS, AND PAMELA H. SCHNELL, OD

## FOCUS ON REFRACTION

# Double the Glasses, Double the Success

*The two-pair approach is a major contributor to the healing process post-brain injury.*

There is a rule of thumb that a former colleague and mentor used to say all the time: “If you’ve seen one brain injury patient, you’ve seen... one brain injury patient.” She was referring to the fact that these patients can each have significantly different symptoms, based on a multitude of factors, including age, location and extent of the injury, type of injury and time since the injury. Among the more common complaints are double vision, field loss, trouble focusing on reading material and fatigue while reading. All fall within the purview

of the optometrist tasked with providing visual rehab and correction.

Regardless of a patient’s symptoms and diagnoses, there is a first-line brain injury management method that is as simple as it is effective. It is so logical that it is often overlooked by doctors. This installment will cover the two-pair glasses approach and how to go about executing it in practice.

### Domino Effect

Since brain injuries typically occur in older populations, these patients generally use bifocals, either a flat-

top or a progressive addition lens (PAL). Even though they may have been using their multifocal lenses for upward of 30 to 40 years, the ability to focus the eyes on the right place in the X, Y and Z axes becomes a challenge when the brain is injured. Vergence, accommodation and ocular motility have all been shown to be impacted following a brain injury.<sup>1</sup> As these three systems are primarily responsible for making sure that the eyes get to where they need to go, it is not a leap to anticipate trouble when patients are using the small reading areas in both bifocals and PALs.

Don’t forget the role played by the rest of the body, of course. As numerous parts of the body can be impacted by the injury, so too can be the ability to support and point the head at the right place in space. If a patient is slumped off to one side, it is more than likely that they are not looking through the appropriate place in the lenses.



**The two-pair glasses approach can make a world of difference in the healing process for a brain injury patient.**

#### About Drs. Taub and Schnell

**Dr. Taub** is a professor, chief of the Vision Therapy and Rehabilitation service and co-supervisor of the Vision Therapy and Pediatrics residency at Southern College of Optometry (SCO) in Memphis. He specializes in vision therapy, pediatrics and brain injury. **Dr. Schnell** is an associate professor at SCO and teaches courses on ocular motility and vision therapy. She works in the pediatric and vision therapy clinics and is co-supervisor of the Vision Therapy and Pediatrics residency. Her clinical interests include infant and toddler eye care, vision therapy, visual development and the treatment and management of special populations. They have no financial interests to disclose.

## WELCOME, DR. SCHNELL!

I am thrilled to introduce *Review of Optometry* readers to a longtime colleague and good friend of mine, Dr. Pam Schnell.

When I first met Pam 10 years ago during her interview at SCO, it was pretty obvious right off the bat that we were two peas in a pod. She is the Jane of all trades, and I look forward to working with her as Focus on Refraction's latest co-columnist. Please join me in welcoming Dr. Schnell to the team!

—Dr. Taub

Also keep in mind that field cuts are a common finding related to a brain injury. If a piece of the field is missing, so is the patient's ability to use the lens. For some patients, it is already challenging enough to use bifocals or PALs, so imagine now that the little window is even smaller and that some of the distance, channel or reading portions of the PAL are gone. Add to this a potential finding of impaired cognition, and the issues increase.

### Don't Overthink It

The first step for these patients is to switch them from a multifocal to two pairs of glasses, one for distance and one for near. Having a larger area to see through is a huge relief to the patient and their over-taxed, healing brains. As an aside, we will often recommend a single-vision pair of reading glasses for many of our presbyopic patients who are avid readers.

Yes, it is an issue that patients are resistant to using separate distance and near vision glasses, but this can be overcome with proper education for the patient and their caregiver. After explaining why this is necessary in the treatment process and how it will aid sensory and motor functioning, the typical patient response is usually, "That makes so much sense!"

One of the benefits, apart from the larger viewing area, is the ability to offer different treatments for distance and near. This is most obvious when prescribing prism to alleviate diplopia. The ability to use different amounts of prism, typically issued using a Fresnel, is important and necessary. A Fresnel is used as a prism entry point since the hope is that it will be a temporary

measure and that the amount needed may decrease throughout the healing process. Once the amount is stable, we can then consider grinding in the prism. It is easier to grind in prism and for the patient to adapt to it with a single-vision lens.

In addition to patients with a brain injury, those suffering from a neurological condition can also benefit from the two-pair approach. Conditions such as multiple sclerosis, Parkinson's disease and ALS impact muscle function and control throughout

the body. While it is easier to compensate for large-muscle issues as there is more room for error, this is not true for the smaller muscles that control eye movements. Having more room for error in the form of larger viewing areas is a simple, effective strategy for these patients.

As part of the Vision Therapy and Rehabilitation service at Southern College of Optometry, I (Dr. Taub) see patients in rehabilitation facilities. While the most common patient is one who suffers from a brain injury, I also see those needing physical and occupational therapy related to various neuromuscular conditions like those discussed previously.

Recently, I saw patients with multiple sclerosis and Friedreich's ataxia. Both patients complained about not being able to concentrate when reading. Not surprisingly, both were also wearing PALs. As you might have guessed, I suggested that the next

time they visit their regular eye doctor, they ask about the two-pair approach. Even though there was nothing that could be done on my part for their immediate issues, with the recommended approach, they are set up for future visual success.

On the opposite end of the spectrum from patients who are unable to control their head and eye movements are patients who have limited mobility. Consider issues related to using a multifocal contact lens if you can't point your face at the object that you wish to view or tilt your head to enter a different portion of the lens. Patients who have experienced a traumatic event such as a car accident, or even those undergoing major cervical spinal surgery, may be forced to wear a halo

“Some patients who could previously compensate for poor binocularity may now experience double vision, so using two pairs also allows for easier Fresnel prism placement.”

as part of the healing process. Since limiting head movement is the point of the halo, this can have a negative impact on the patient's ability to have clear, single binocular vision.

Even after the halo is removed, mobility may still be reduced in some cases.

Issuing two pairs of glasses is the solution in these situations. Don't forget that some patients who could previously compensate for poor binocularity may now be subject to complaints of double vision post-injury, so using two pairs also allows for easier placement of Fresnel prism.

### Takeaways

The two-pair glasses treatment method is so obvious and simple that doctors often overlook it as an option. We all have patients in our offices who have suffered strokes or who struggle with a neurological condition. Consider using this approach proactively to help move the healing process along and reactively when patients are unable to use their multifocals effectively or efficiently. ■

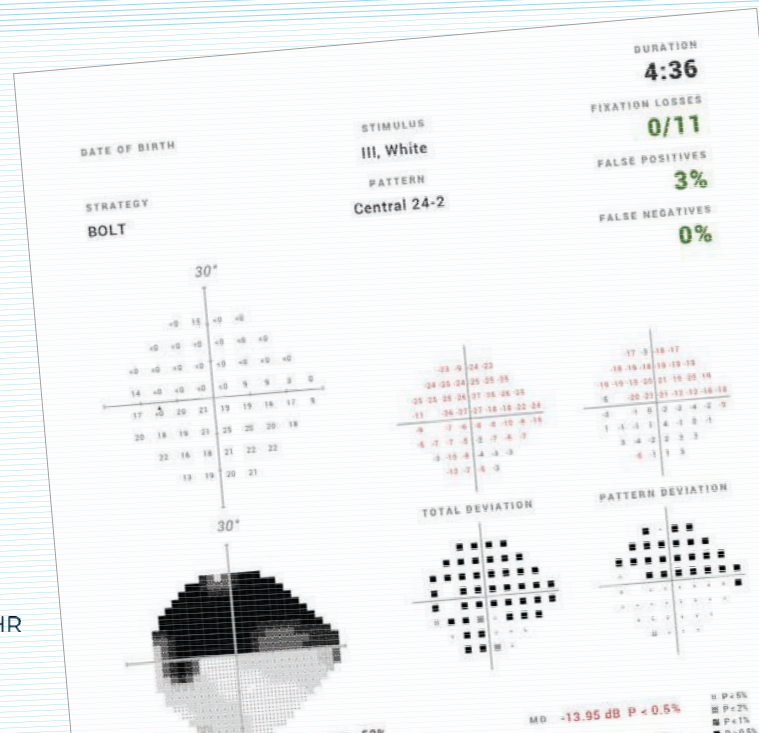
1. Suhr CL, Shust M, Prasad R, et al. Recognizing TBI-related vision disorders. *Rev Optom.* 2015;152(12):56-65.

# VIRTUAL FIELD

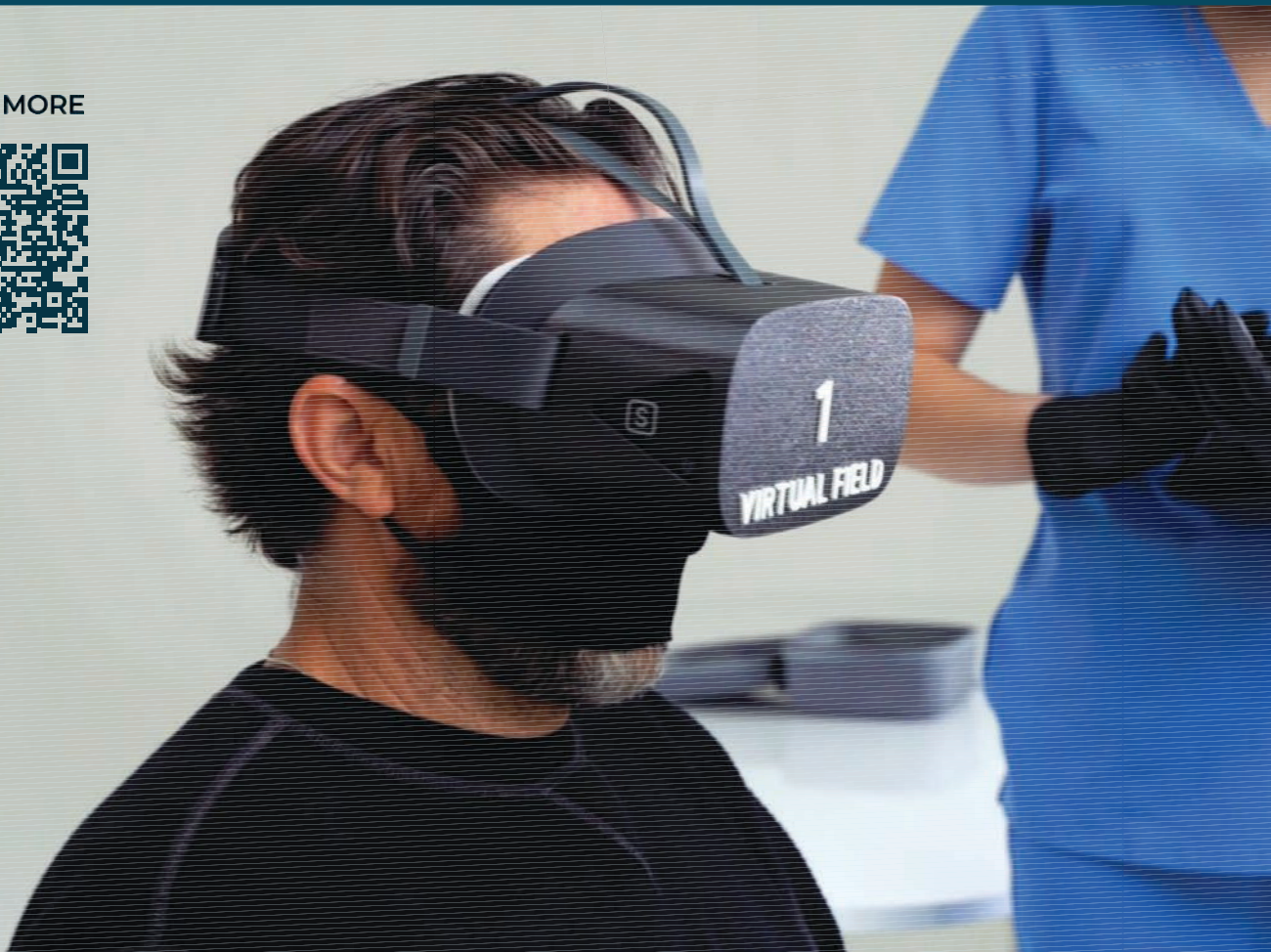The Virtual Field provides greater efficiencies with reduced testing time and the ability to test multiple patients at once with no eye patch necessary. The mobile, lightweight design allows patients to be tested anywhere with wifi access, and it is easier to clean than traditional perimeters.

## FEATURES

- Progression analysis
- Monocular or binocular testing
- Access results from any laptop, tablet, or mobile device
- Audio instructions and error prompts in 34 languages
- Download reports as PDF/JPG files for upload into any EHR
- Qualifies for ADA tax credit



LEARN MORE





# TACKLING THE BARRIERS OF MYOPIA MANAGEMENT

Learn tips to be successful in discussing this topic with patients and their parents.



BY ARIEL CERENZIE, OD  
CHARLOTTE, NC

Providing parents with a compelling message to pursue a myopia management modality, all the while working with the confinements of limited exam time, is an exasperating challenge. These discussions require the ability to share sufficient information without overwhelming the patient, to use easy-to-understand terminology while explaining a foreign concept, to convey the value of the treatment plan without push-back on added costs and, most of all, to gain their complete trust in an unfamiliar territory.

## The Two Barriers

What verbiage and techniques are necessary to aid in a parent or caretaker understanding that enrollment in your myopia management program is in their child's best interest vs. continuing along the traditional and less costly route of single vision correction? To answer this question, we need to understand the initial barriers.



**Use plus lenses to show parents what their child's vision may look like next year, or even three years later, based on the child's historical progression and risk factors.**

**Limited education:** a myopic eye sees a blurry world, but the world sees the myopic eye no differently. Look at the physical characteristics of two children, one with a refractive error of a  $-6.00D$ , and the other with a  $+0.50D$ . Would a parent be able to tell the difference? Myopia is easily overlooked as a benign condition, as the eye appears normal. Even if parents have myopia themselves, they are likely unaware of myopia as anything more than a nuisance.

This unawareness stems from the lack of options this generation had available as children. Instead, having their vision progress over time was "fixed" by a stronger prescription each year. One study polled parents on their basic knowledge and feelings towards a child's diagnosis of myopia. Many parents described myopia as merely an optical inconvenience, an expense, and a cosmetic inconvenience.<sup>1</sup>

**Limited time:** a typical comprehensive exam is too short of a period to provide adequate myopia management educa-

tion. With managed vision care driving most practices' revenue, optometrists are required to see anywhere from two to four—or even more—patients per hour. There is

### About the author

**Dr. Cerenzie** practices at Vision Source Studio 20/20 in Charlotte, NC. She is a Fellow of the American Academy of Optometry and Scleral Lens Education Society. She is also a member of the National Keratoconus Foundation and American Academy of Orthokeratology and Myopia Control. She serves as a key opinion leader for Vision Source's Myopia Management Protocol. She has no financial interests to disclose.

inadequate time during an exam to sufficiently explain to a family the importance of myopia management, why they have never heard of it before and what treatment options are available. If any attempts to do so are made, the doctor will have several frustrated patients wanting to get on their way. Most recommendations are to bring the patient back for a consultation; however, mechanisms need to be put in place to determine when that patient will come back and how the doctor will be compensated for their time.

Given these barriers, an impactful, initial discussion on the potential impact of myopia and the treatment options is key. After the initial discussion, the value of clear communication remains vital, as the child enrolls in your myopia management program to enable best practices when handling medical treatments such as atropine 0.05%, multifocals or orthokeratology (ortho-K) at home.

## The Six Steps to Success

Having a plan in set can help demonstrate to a parent or caretaker that myopia management should be a priority for their child. Let's walk through a potential case.

**1. Identify candidates in your exam chair.** Your technician reviews the next patient with you. "Your 10:00 am patient is an eight-year-old female, Claire. Her uncorrected acuities are 20/150 OD, 20/100 OS." Before stepping into the exam room with Claire, it is clear by her autorefractor printout and history that she is a young, progressive myope. It is also clear that if single vision correction is prescribed, it is merely a stopgap for the following years, and she will very likely continue to progress. This patient requires myopia management to provide the best standard of care, which is not what her parents are expecting to hear.

In situations like this, be prepared before stepping into the exam room.

Train your team to recognize these types of patients as potential candidates for your myopia management program and have educational brochures and pamphlets readily available. They can provide visuals and easy patient verbiage to help improve parent communication.

While establishing history and checking ocular health, get to know the child and parents by asking about

hobbies, what they enjoy doing on the weekends, if they are involved in sports, academic clubs, etc. Claire is a member of her swim team.

Start weighing the different modalities of myopia management that are available and what may benefit each patient the most. Specific questions can also help to assess risk factors of a child: Does mom or dad wear glasses? What things do you like to do outside? Do you like playing Minecraft like my niece?

Keep the exam light and fun. It is important to gain the trust of parents and their children by making a positive impression. Be light-hearted and laugh with them to help build a trusting relationship.

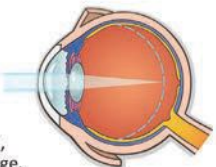
**2. Express genuine concern and partner with the family.** Now it is time for the big discussion, and there is only five minutes of the allotted exam time left. There is simply not enough time to educate them on myopia, the

### Clinical Myopia Profile

The clinical myopia profile is a summary of the extensive scientific data available on what increases and decreases risk of development or progression (worsening) of myopia.

Your optometrist has elected to profile your myopia because you/your child:

1. Currently has normal visual clarity but is AT RISK of developing myopia, or
2. Is already myopic, and at risk of further myopia progression.



**MYOPIA (shortsightedness)** is where the eyeball is too long or too powerful, resulting in blurred far vision. Vision for close objects is clear within a certain range.

**Why do we need to control myopia?**  
Generally once you become myopic, it tends to worsen over time. Higher levels of myopia are associated with higher risks of eye diseases like glaucoma, retinal detachment and cataract later in life.

**What causes myopia development and progression?**  
**Genetics, each individual's characteristics and environment.** Your clinical myopia profile is below.

**GENETICS: FAMILY HISTORY OF MYOPIA**

Neither parent myopic	One myopic parent <i>(three times risk)</i>	Two myopic parents <i>(six times risk)</i>
Low Risk	Medium Risk	High Risk

**INDIVIDUAL CHARACTERISTICS: VISUAL CLARITY – current far vision**

Age appropriate	Less than age-normal (at risk)	Already myopic
Low Risk	Medium Risk	High Risk

**VISUAL EFFICIENCY (eye teaming) 1 – esophoria / convergence excess**

Normal	Borderline	Esophoria
Low Risk	Medium Risk	High Risk

**VISUAL EFFICIENCY (eye teaming) 2 – accommodative lag**

Normal	Borderline	Accommodative lag
Low Risk	Medium Risk	High Risk

The Myopia Profile tool, designed by Kate Gifford, PhD, helps practitioners explain to the child and their parents the outcomes of the exam more effectively. It is available at [www.myopiaprofile.com](http://www.myopiaprofile.com), along with other resources from Dr. Gifford.

**TABLE 1. COMPARISON OF THREE MYOPIA TREATMENT OPTIONS**

	Ortho-K	Multifocal Lenses	Atropine 0.05%
Independence from daytime glasses	✓	✓	
Great for water activities	✓		
Recommended maturity level	Medium	High	Low
At-home control/parent over-sight	✓		✓
FDA approval for myopia management	✓	✓	
Requires less in-office time			✓
Familiar to parents		✓	
Follow-up frequency during the first year (office specific)	Minimum: one day, one week, one month, three months, six months	Minimum: one week, six months* *Additional visits required for contact lens troubleshooting	Minimum: one week, six months

effects of myopic progression, as well as the options that are available. Therefore, it is essential that parents sense your genuine concern, as they will recognize your body language, tone and verbalized concern. The goal is to use this limited time to heighten the parents’ awareness, so they will be driven to pursue a myopia management option.

Start by pulling up a chair next to the parent. Begin by saying, “Claire’s prescription has worsened, and her vision concerns me.” Your body language should mirror the concerned tone of your voice—leaning forward, serious face, slightly elevated eyebrows, etc. Parents may have difficulty comprehending the concepts behind myopia and myopia management, such as why myopia is a concern, how treatments work vs. conventional single-vision correction modalities. Demonstrating genuine concern will motivate the desire to learn more.

Continue by saying, “Claire has progressive myopia, which is a condition that will continue to progress if we continue to prescribe traditional glasses and contacts. This progression will occur until she is much older, typically not stabilizing until her late teens or early twenties.<sup>2</sup> I would like to demonstrate to you how she sees the world.”

**3. Demonstrate the child’s vision to the family.** Show Claire’s myopic vision to her parents by using plus lenses.

Ask her parents to step outside of the exam room and look at objects far away. Begin by having the parents hold plus lenses over both eyes that reflect last year’s myopic prescription, then demonstrate the change to the current myopic prescription. Next, show them what their child’s vision may look like next year, or perhaps three years later, based on the child’s historical progression and risk factors. Risk factors may include the age of myopia onset, amount of near work performed each day and parental myopia.<sup>3,4,5</sup>

Myopia prediction calculators, such as the one created by the Brien Holden Vision Institute, can also be helpful in demonstrating vision changes to parents. Input the child’s age, race, prescription and preferred treatment option into the calculator. Then, demonstrate what the child’s vision may look like three to four years later with vs. without treatment. Parents should be made aware that the calculator overestimates the child’s vision trajectory and data is hypothetical.

Demonstrating vision changes to parents may be more impactful than discussing scare tactics, such as the increased likelihood of ocular disease later in life. This emphasizes that they are occurring now, and these changes are irreversible. It will become clear that their child’s quality of life has been, and will continue to be, negatively impacted. Additionally, parents may feel guilty that they have been unaware of the implications of their child’s vision changes.

“You can see how impactful these vision changes will be over time. If we continue to prescribe regular glasses and contact lenses, this trend will likely continue. The good news is we have options now that have the ability to slow the worsening of Claire’s vision, which can improve her future quality of life and visual potential.”

Based on the parent’s and child’s questions following this short discussion, it will become clear what concerns they have and what guides their motivation, which may be different than anticipated. You can use these questions to drive the conversation in an assuring manner.

It is not necessary to discuss all the details related to myopia and the options available. This limited time is best spent alerting the parent that there is a problem now, you have a solution available and you will work alongside them to improve the child’s vision and quality of life. Quality of life improvements may include a potential

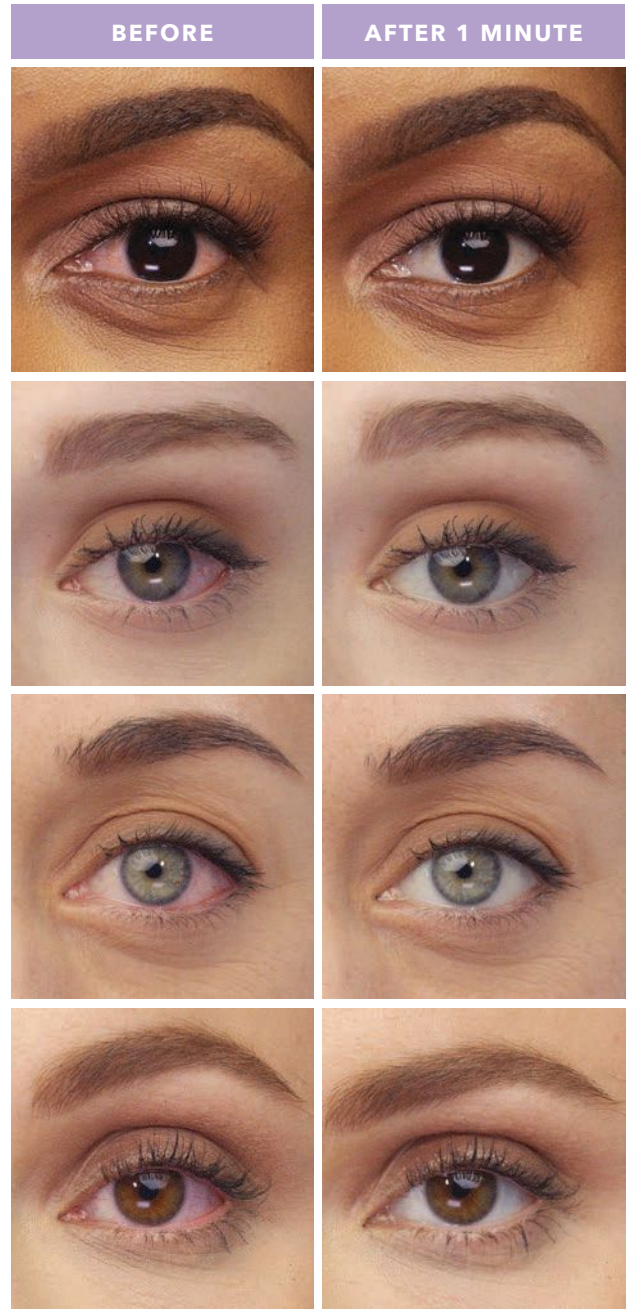

# LUMIFY®

BRIMONIDINE TARTRATE OPHTHALMIC SOLUTION 0.025%  
REDNESS RELIEVER EYE DROPS

## A redness reliever like no other\*

- ✓ **Unique method of action<sup>†</sup>** that selectively targets redness
- ✓ **Virtually no rebound redness** and no tachyphylaxis in clinical trials<sup>‡</sup>
- ✓ **Clinically proven safe and effective** in 6 clinical trials with over 600 patients



Actual results. No retouching. Consistent with average clinical trial results.

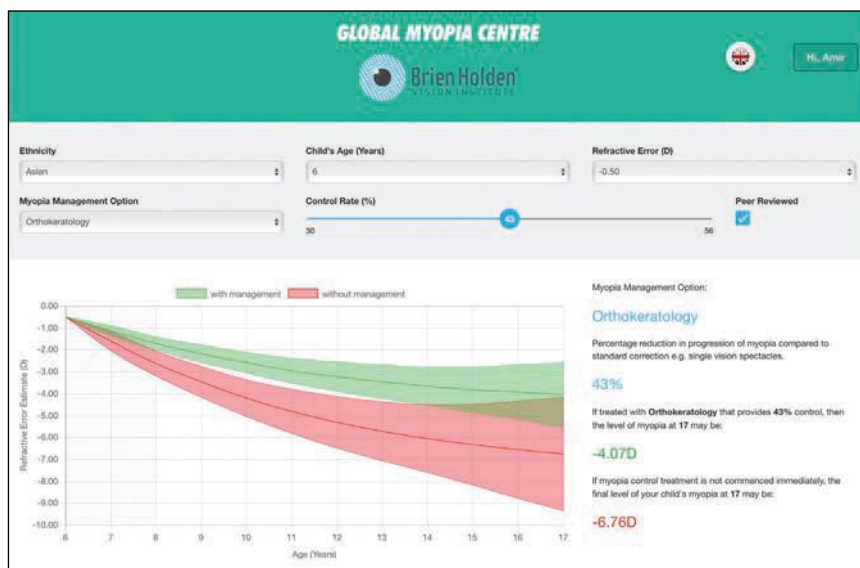\*Low-dose OTC brimonidine. †Low-dose brimonidine is an  $\alpha_2$ -AR agonist that primarily constricts the venule. ‡McLaurin E, et. al. *Optom Vis Sci.* 2018;95(3):264-271. §In clinical trials, one case of rebound redness was reported. ¶In Home Use Test, March 2018. n=301. LUMIFY is a trademark of Bausch & Lomb Incorporated or its affiliates. © 2021 Bausch & Lomb Incorporated or its affiliates. PN09924 LUM.0088.USA.21

➤ To learn more about LUMIFY visit: [LUMIFYDrops.com/Professional](https://LUMIFYDrops.com/Professional)

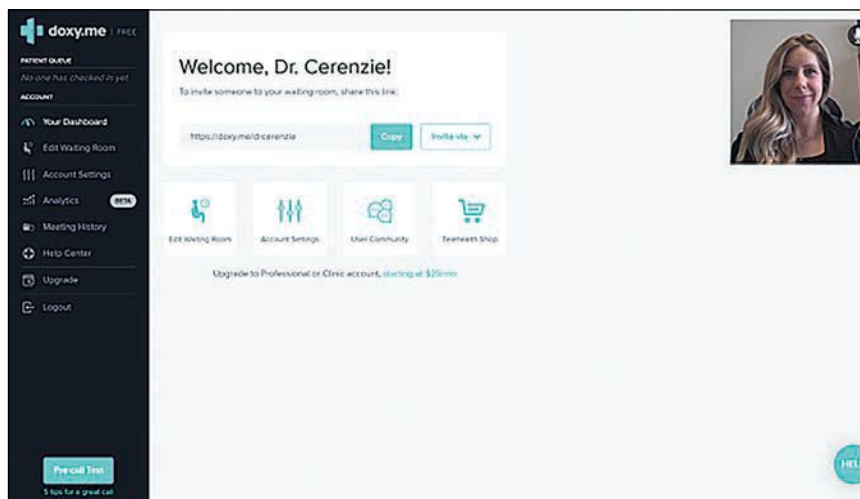
Call 1-833-4-LUMIFY (1-833-458-6439)  
for samples and patient resources

Call 1-800-828-9030  
to start selling LUMIFY in your office

**BAUSCH + LOMB**



**A myopia prediction calculator from the Brien Holden Vision Institute helps demonstrate vision changes to parents.**



**A telehealth platform can help fit any immediate follow-up to the myopia management discussion around a family's schedule.**

increase in self-confidence with contact lens modalities, less visual disability when uncorrected, improved likelihood for refractive surgery candidacy, etc.<sup>6</sup> Overall, try to keep it simple, provide resources for review and schedule a consultation.

**4. Explain options briefly and schedule consultation.** The closing remark could be, “I know this is a lot to take in at once. What are your thoughts on scheduling some time to discuss more after you have had a chance to review our options? Since Claire loves to swim, it appears that the best option may be ortho-K, so that she can be free from contact lenses while swimming. Another contact lens option is a daily disposable contact lens that is worn during the day and disposed of at night. Lastly, an eye drop called atropine can also slow the progression of Claire’s myopia and it is taken nightly. I will provide you

with more detailed information on all of these options, so you can all discuss which works best for you as a family. My team will schedule a follow-up visit, either in-person or virtually next week, where we can discuss this condition further. Here is my card if you have any questions before then.”

It is important that the closing remarks are followed by a call-to-action and a follow-up visit is scheduled. This visit can be in-person or virtual. In addition to providing physical resources, a customized email could be sent to parents outlining your recommendations specific to their child, based on the conversations from the exam. The email should include easy-to-understand websites, videos or graphics on myopia management and addressing frequently asked questions.

**5. Drive an effective consultation.**

At our office, we perform “tele-reviews” using a HIPAA-compliant telemedicine platform. This has been beneficial to encourage full family participation in the comfort of their own home. In addition, the office is not using resources for the visit. Visits can be scheduled during slow periods or when patients are not being seen. Consider charging for the consult and applying it towards their program if they move forward.

The consult is dedicated to answering all the parents’ questions and concerns. You can easily share resources during the consult. For example, if patients are concerned about safety of contact lenses, send over pertinent literature.<sup>7,8</sup>

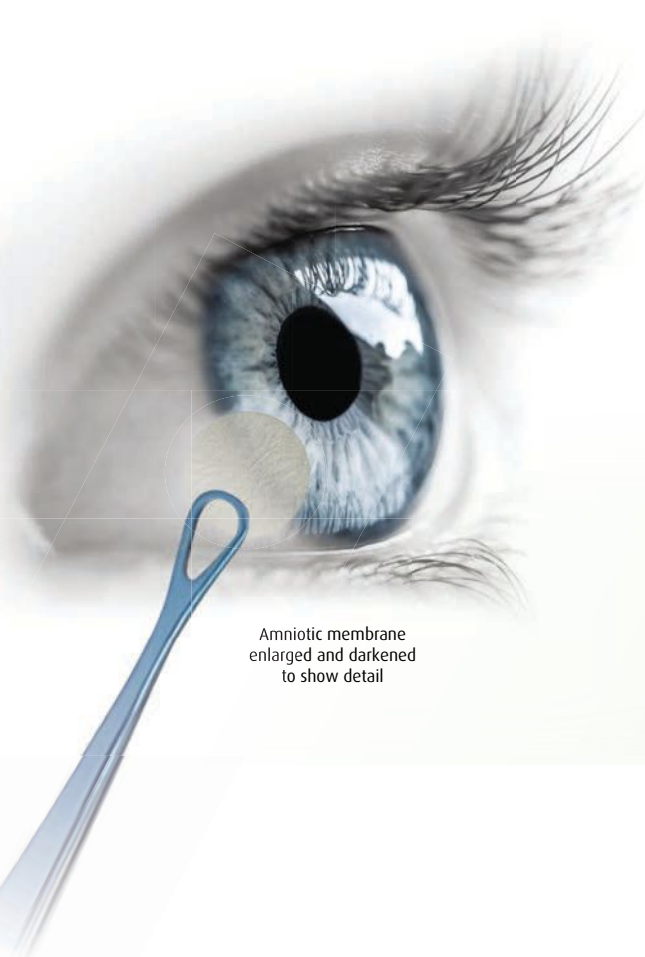There are several important points to cover. First, assess if the parents appear to understand why myopia management is necessary vs. the traditional, single vision correction route. If there is still some uncertainty, discussions could include:

- Demonstration of the child’s abnormal trajectory of axial length along a growth chart or by using a publicly available refractive error predictor calculator, such as the Brien Holden Vision Institute Calculator.

- Emphasize that, as the child’s prescription increases, their ability to navigate an unfamiliar room decreases. If they were to lose or break their glasses, their function could be significantly impacted until new ones are able to be ordered.

# Need Ocular Surface Repair?\*

## We've Got You Covered!



Amniotic membrane  
enlarged and darkened  
to show detail

**ACELLFX™**   
Acellular Amniotic Membrane

- Air-dried, not chemically dried
- Ready for immediate use without thawing or rinsing
- Flexible membrane with no ring required
- Convenient storage at room temperature

Learn more at [AcellFX.com](https://www.AcellFX.com)



\*AcellFX is an HCT/P (human cells, tissues, and cellular and tissue-based product) that is intended for homologous use, providing protection or covering in ocular surface repair.



- Discuss the decreased quality of life myopia can bring their child. This includes the need for thicker spectacle lenses annually. In addition to cosmesis concerns, lenses may become more costly as higher index materials will later be recommended. Through higher prescriptions, vision is decreased as objects are minified.

- Awareness that the child may not be a candidate for refractive surgery later in life and, with higher prescriptions, there are higher risks for surgical complications.

- Understanding that with increased levels of myopia, the risk for developing ocular disease also increases.

Parents need to be aware that myopia is certainly more than a nuisance but, potentially, a life-altering condition.

Next, discuss the treatment options the child is a candidate for and what option may be best suited for the child's lifestyle or hobbies. Discussion could also include the pros and cons of each treatment, frequency of use, expected follow-up frequency and total time expected in office for each visit.

In some studies, there is an association between limited outdoor time and excessive near work with increased myopic progression, though there is insufficient evidence of definitive causation. Unfortunately, there are no specific recommendations for time spent outdoors as it relates to progression, just recommendations on protecting against onset. Until more data is available, it may be helpful to encourage more time outdoors, as well as breaks from prolonged amounts of near work, including screen time. For near work, consider recommending the child holds reading materials or devices further than 30cm and takes breaks after 30 minutes after continuous near-work activity.<sup>9,10</sup>

Several reports have found that shorter working distances (<30cm) and continuous near-work activity (>30 minutes) are risk factors for myopia onset and progression.

An example for discussing ortho-K: "These lenses are custom-designed based on Claire's specific eye shape and prescription. She will be able from daytime correction and free to swim and play without worrying about glasses falling off her face. She will be required to complete an application and removal class, where we will teach her how to safely handle, apply and remove her custom lenses. We will also teach her how to clean her lenses and what specific solutions to use."

It may be beneficial to warn parents that the application and removal class may take several visits, as the child's safety is the office's priority. Lastly, discuss expectations on the follow-up frequency with parents. "Additionally, there will be a minimum of five follow-ups after dispense, one-day, one-week, one-month, three-month and six-month visits. Expect Claire to be here for around 30 to 60 minutes for each follow-up."

**6. Discuss pricing.** After the value of the program is understood, then discuss pricing in simple terms. "Our myopia management program is \$\_\_\_\_\_ for the year. The

## SETTING THE STAGE FOR SUCCESS

If you were successful with going forward with the ortho-K or the multifocal lens treatment option, there might be another tip that could help those new to contact lens wear: provide them with information on insertion and removal.

"We have a little homework for you before coming in for your contact lens class." Emailing patients and their families videos on lens application and removal, as well as care and handling, may be helpful for few reasons. Watching these videos can help the child feel more comfortable and prepared when the highly anticipated day comes. This will additionally help your technicians' efficiency, which they will be thankful for.

For ortho-K, it may be helpful to instill anesthetic in the eye to decrease the shock of contact lens awareness once initially applied. As the anesthetic wears off, the patient will gradually begin to sense the lenses, as opposed to immediately feeling discomfort.

It is critical to emphasize and demonstrate proper lens and hand hygiene at this visit and all subsequent visits.



Photo: Jeffrey J. Walline, OD

**Helping children with lens insertion and removal helps ease their anxieties of myopia care.**

reason is because these treatments require more time and testing than your typical glasses or contact lenses." It is unnecessary to explain or apologize for the program costs. Discussing larger sums of money may be uncomfortable, but myopia management requires more office time, technology, staff skills and overall, a higher level of care compared with traditional refractive care. The office should be compensated for that, and unapologetically so.

If costs are a concern for patients and their families, dividing the overall sum by monthly payments may be helpful, either directly through the practice or third-party financing. If the office chooses to provide the patient with a payment plan without third-party financing, it may be helpful to have a larger sum up front to cover practice costs.

It is beneficial to train your staff on how the fees for myopia management were determined. This will encourage confidence while discussions larger sums of money. One technique is to discuss chair cost with the team, which is the cost it takes to breakeven before the

practice profits. The average practice's chair cost is \$136, per the Management & Business Academy (MBA) metrics.<sup>11</sup> If a patient has six contact lens follow-up exams, then the practice needs to make a minimum of \$816 in services alone to breakeven.

In addition, educate your team on the expense of purchasing a topographer, biometer, additional continuing education and any other necessary tools. When your staff is aware of these expense metrics, the cost structure is more comprehensible, and it will be easier to discuss the costs of myopia management with patients.

### Clinical Takeaways

In the future, prescribing myopia management interventions will likely become the standard of care. The World Council of Optometry recently passed a resolution urging optometrists to regularly offer scientifically proven myopia management modalities as the new standard of care for young, progressive myopic patients.<sup>12</sup> Until there is widespread recognition of myopia as more than a nuisance—rather, a medical condition amenable to amelioration—education to unexpecting parents and children in-office is imperative.

By demonstrating genuine concern through both body language and verbal communication, parents will be encouraged to pursue your recommendations. Dedicate additional time to continue the myopia management conversation and to continue to provide a clear and effective dialogue throughout the prescribed regimen. Refining communication skills and adjusting our care patterns accordingly are the keys to growing and evolving your myopia management specialty. ■

1. McCrann S, Flitcroft I, Lator K et al. Parental attitudes to myopia: a key agent of change for myopia control? *Ophthalmic Physiol Opt*. 2018;38(3):298-308.

2. COMET Group. Myopia stabilization and associated factors among participants in the Correction of Myopia Evaluation Trial (COMET). *Invest Ophthalmol Vis Sci*. 2013;54:7871-84.

3. Huang HM, Chang DS, Wu PC. The association between near work activities and myopia in children - a systematic review and meta-analysis. *PLoS One*. 2015;10(10):e0140419.

4. Chua SY, Sabanayagam C, Cheung YB, et al. Age of onset of myopia predicts risk of high myopia in later childhood in myopic Singapore children. *Ophthalmic Physiol Opt*. 2016;36:388-94.

5. Morgan IG, Wu PC, Ostrin LA, et al; IMI risk factors for myopia. *Invest Ophthalmol Vis Sci*. 2021;62(5):3.

6. Bullimore, MA, Brennan NA. Myopia control: why each diopter matters. *Optom Vis Sci*. 2019;96(6):463-5.

7. Bullimore MA. The safety of soft contact lenses in children. *Optom Vis Sci*. 2017;94(6):638-46.

8. Chamberlain P, Peixoto-de-Matos SC, Logan NS, et al. A three-year randomized clinical trial of Misiight lenses for myopia control. *Optom Vis Sci*. 2019;96(8):556-67.

9. Brennan NA, Cheng X. Commonly held beliefs about myopia that lack a robust evidence base. *Eye Contact Lens*. 2019;45(4):215-25.

10. Gajjar S, Ostrin LA. A systematic review of near work and myopia: measurement, relationships, mechanisms and clinical corollaries. *Acta Ophthalmol*. October 7, 2021. [Epub ahead of print].

11. Essilor. Key Metrics: Assessing Optometric Practice Performance & Best Practices of Spectacle Lens Management Report. ECP University. 2018. [ecpu.com/media//wysiwyg/docs/ECPU\\_MBA\\_KeyMetricsReport\\_2018.pdf](https://ecpu.com/media//wysiwyg/docs/ECPU_MBA_KeyMetricsReport_2018.pdf). Accessed December 13, 2021.

12. World Council of Optometry. Resolution: the standard of care for myopia management by optometrists. [worldcouncilofoptometry.info/resolution-the-standard-of-care-for-myopia-management-by-optometrists](https://worldcouncilofoptometry.info/resolution-the-standard-of-care-for-myopia-management-by-optometrists). Accessed December 13, 2021.

## Are Axial Length Measurements a part of your myopia control program ?

# SCANMATE

Periodic axial length measurements have been identified as an essential procedure for monitoring the effectiveness of any myopia control program.

The Scanmate *A* is a portable, USB connected ultrasound A-Scan biometer used to obtain axial length measurements. The Scanmate *A* utilizes unique alignment and compression detection algorithms and provide real time audible feedback to the user. These exclusive features give real-time guidance for optimizing alignment and minimizing compression. You can be confident that your axial measurements will be consistent, accurate and reliable.



TECHNOLOGY, INC.  
**DGH**  
THE ULTRASOUND SPECIALIST

Serving Eye Care Professionals since 1982

# DEBATING THE VALUE OF DIAGNOSTIC TESTS

Four seasoned pros have a freewheeling conversation about whether or not several tried-and-true tools and concepts have run their course and should be modified or replaced.



**CHRISTINA HICKS-HUBBARD, OD**  
DETROIT, MI



**BRAD TAYLOR, OD**  
SAGINAW, MI



**SARA WEIDMAYER, OD**  
ANN ARBOR, MI



**TRACI SENG, OD**  
ANN ARBOR, MI

**W**e all have our favorite tests, tools and practices, but just because things have always been done a certain way doesn't mean they can't be modified for the better. Some staples of the ophthalmic work-up may be considered outdated and need to be swapped for new, more up-to-date techniques.

In what perhaps may be more polarizing than the state of politics in America, we're going to discuss many diagnostic tests and old-school ways of doing things that we think can be ditched or modified in optometry, and what is here to stay. Some of these may be controversial—opinions differ even among the four of us, as you'll see in our roundtable below. Keep in mind that our comments shouldn't be construed as the final word on these debates; our goal here is to start conversations, not end them. We invite you to follow along as we talk shop for a while!

*Editor's note: Readers are encouraged to share their own thoughts on specific topics, pro or con, in a letter to the editor. The panelists will consider any feedback they receive and weigh in with their takes in a future issue. Send your feedback to [editor@reviewofoptometry.com](mailto:editor@reviewofoptometry.com).*

## About the authors

**Dr. Hicks-Hubbard** provides ocular telehealth care to veterans throughout Michigan, Indiana and Ohio via the Louis Stokes VA based in Cleveland, OH. She has served as adjunct faculty for several optometry schools across the country. **Dr. Taylor** is the supervisory optometrist at the Aleda E. Lutz VA Medical Center in Saginaw, MI, and is a member of the Michigan State Board of Optometry. **Dr. Weidmayer** practices at the LTC Charles S. Kettles Medical Center, VA Ann Arbor Healthcare System in Ann Arbor, MI. She is also a clinical assistant professor for the Department of Ophthalmology and Visual Sciences, WK Kellogg Eye Center of the University of Michigan. **Dr. Seng** practices at the LTC Charles S. Kettles Medical Center, VA Ann Arbor Healthcare System. She is also a clinical instructor for the Department of Ophthalmology and Visual Sciences, WK Kellogg Eye Center of the University of Michigan and a clinical associate professor at Michigan College of Optometry of Ferris State University. They have no financial disclosures.

## Tools and Tests

Optometry is fortunate to have so many ways of assessing and documenting the status of the eye from both a structural and functional perspective. But when a more sophisticated test emerges, what should happen to the older protocols? Let's examine several in a 2022 context.

### Amsler Grid

**Dr. Seng:** In use since 1945, Amsler grid testing can detect functional disturbances in the central and paracentral region. The grid can be used to detect scotomas and metamorphopsia in the central 10° on all sides of fixation. Like the "facial Amsler grid" that is done during confrontation field testing, it has long been used as a screening tool, often completed by technicians, in patients at risk of conditions such as macular degeneration, toxic maculopathy, macular hole, retinal artery occlusion, central serous chorioretinopathy or homonymous loss from stroke. It is also used as a home screening tool so that patients can monitor their condition outside of the office, and while some might argue compliance is low and the test lacks sensitivity, it is certainly better than nothing.

However, with improved visual field protocols allowing for shorter and more reliable testing and most importantly, with SD-OCT testing now standard-of-care and available at the vast majority of eyecare offices, in-office Amsler testing can likely be retired when better tools are available. The Amsler grid has low sensitivity and is often somewhat



misunderstood by patients, giving it low overall value as a clinical test.<sup>1</sup> It is also likely that the results of testing, whether negative or positive, will not change the decision to move forward with additional and much more sensitive testing such as macular OCT scans. For this reason, I think Amsler grid testing can likely be removed from the routine preliminary testing protocol in most clinical settings.

Home Amsler grid testing's role is a little less clear. Paper copies of grids are still often given out to patients for at-home monitoring, especially in conditions with high-risk of disease progression and where early detection can impact clinical outcomes. Studies have shown that home Amsler testing not only has low sensitivity, but also low compliance of patient use.<sup>1</sup>

Many studies are looking at alternative methods for home monitoring, including threshold Amsler grid, entoptic perimetry and preferential hyperacuity perimetry. These have been found to be more sensitive than Amsler grid testing and could conceivably be used by patients for self-monitoring, but require financial resources as well as technology that has not yet been developed and deployed on a widespread basis.<sup>1,2</sup> They also do not necessarily solve the issue of poor patient sensitivity. So, while routine Amsler testing in-office has likely outlived its usefulness, home testing—while far from perfect—may still be the most practical method for improving early detection of vision changes indicative of disease progression in patients with high-risk macular disease.

**Dr. Hicks-Hubbard:** I'm anxiously waiting for a newer way to help patients monitor at home, but until then, the at-home Amsler grid is our best option. While it does have low sensitivity, we can still try our best with good patient education to help improve adherence to daily monitoring.

**Dr. Weidmayer:** Routine Amsler grid evaluation in-clinic is not a good use of time; however, it is occasionally useful for a patient to map out their area of distortion or scotoma to correlate functional abnormalities with structural findings. Don't totally throw away your grid.

**Dr. Taylor:** It is a quick test to perform and can be helpful in some instances; so, maybe it's not needed on every patient every time, but it has its place in the clinic. As far as the home Amsler grid goes, even the AOA Clinical Practice Guidelines for AMD acknowledge that Amsler often fails to detect abnormalities when used at home and emphasize carefully explaining how to monitor using Amsler to detect subtle changes. However, the guidelines still advise using it.

## B-Scan

**Dr. Taylor:** Optical coherence tomography (OCT) gives providers extensive information on the posterior segment, and has been widely adopted as the go-to method of imaging this region. But what do you do when it is not visible? How can you quickly analyze a patient's posterior segment in the presence of a tarsorrhaphy, opaque cornea, dense cataract, vitreous hemorrhage, hyphema or contraindication to dilation? B-scan ultrasonography permits two-dimensional visualization of the anterior and posterior segment when a direct view with the biomicroscope, indirect ophthalmoscopy or your OCT is not possible.

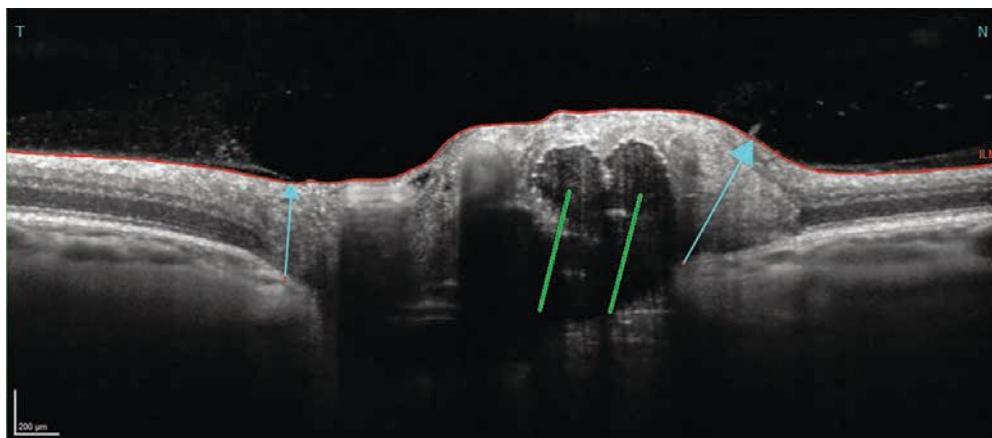
B-scan ultrasound imaging is accomplished by the transmission of high frequency soundwaves. When the soundwaves hit intraocular structures, they may be absorbed, transmitted or reflected. Echo signals are detected by the probe, and a two-dimensional image is then reconstructed for viewing.

Many conditions can be easily diagnosed by performing a B-scan. These include optic nerve head drusen, papilledema, choroidal masses, retinal detachment, choroidal detachment and vitreous opacities, to name just a few. It is easy to perform, noninvasive to the patient, gives a quick and repeatable result, takes up minimal space and can be easily moved around the office. B-scan instrumentation is relatively inexpensive, with units beginning at around \$7,500. In short: to conduct medical optometry, you need one!

**Dr. Weidmayer:** I mostly agree. You don't need one... until you do. I don't use mine often, but when you need it, you need it.

**Dr. Hicks-Hubbard:** The times I've needed the B-scan, I've been thankful for it! Like Dr. Taylor said, as a quick test that doesn't require much space, the B-scan is handy to have in-office.

**Dr. Taylor:** I have at least one patient a month where I say, "I wish we had a B-scan." I am old enough to remember when every cataract surgical patient had a B-scan as part of their pre-op testing.



An OCT line scan with the green lines annotating some visible optic disc drusen.

## Color Vision Testing

**Dr. Taylor:** This is an important baseline clinical test that should not be abandoned, as it can be beneficial in making occupational choices that require color differentiation. Also, congenital and acquired disorders that involve color vision can be identified and discerned by color vision screening techniques. The techniques used in color vision testing are fairly standardized and many different tests are commercially available. Which one is best for your office?

There are three broad categories of color vision tests: the Nagel anomaloscope, plate tests and arrangement tests. The anomaloscope is the definitive test for color vision deficiencies, but its expense, complexity of use and need for a skilled examiner makes it impractical for office use in most settings.

Plate tests have several advantages; mainly, they can be easily and quickly administered by minimally trained technicians. Color vision plates are inexpensive (under \$200) and can be used on children and nonverbal individuals. Improper lighting can be a difficulty with administering the test (the plates were designed for use under a specific viewing conditions). Most importantly, classifying defects based on test performance is not based on an exact scoring criterion. The type or extent of a color vision deficit does not easily correlate to the number of mistakes made on the test. Color vision plates are a screening test used to expose red/green color vision deficits; they often do not adequately screen for blue/yellow acquired deficiencies.<sup>3</sup>

The (Farnsworth) D-15, the most common arrangement test, is inexpensive, easy to score and is accurate in determining color confusion. This test will take longer to administer than color plate testing. Manual dexterity is required as is some degree of patience and concentration, so it is probably not your first color vision test choice. However, it does have value in patients with especially high needs for color vision differentiation for professional or personal reasons.

**Dr. Weidmayer:** In my practice, color plates are useful when assessing optic nerve function (vs. dysfunction). One should always stay in the office. The D-15? Maybe keep that as some sort of abstract artwork; otherwise, I can live my life without it!

**Dr. Taylor:** D-15 discrimination is real, Sara!

## Confrontation Visual Fields

**Dr. Hicks-Hubbard:** With automated perimetry and other forms of more thorough visual field testing becoming nearly ubiquitous, it would seem that confrontation visual fields (CVFs) would be of little use. Decades of research show us that confrontations aren't sensitive and can fail to detect certain defects.<sup>4</sup> So, why are we still performing them?

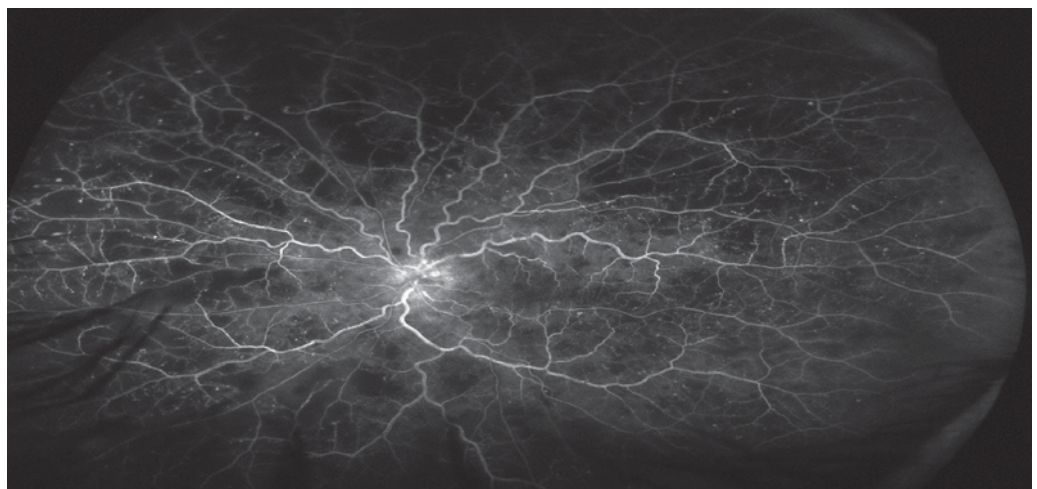
CVFs, while not perfect, are still of significant clinical value when performed properly. They are quick, simple to do and can provide immediate information regarding the visual pathway. For deep defects, such as a homonymous hemianopsia, confrontation CVFs are actually fairly reliable. Moreover, a provider can be confident that if they detect a defect on CVFs that it is real and truly present.<sup>4</sup> By knowing the limitations of CVFs, a provider can continue to use them confidently among the other examination tools to assess a patient's field of vision.

**Dr. Taylor:** Done correctly, confrontation fields give a wealth of information!

**Dr. Seng:** We tried for a short time to make frequency doubling technology take the place of confrontation fields; it didn't work. We found too many false positives—defects on frequency doubling technology screening that then required Humphrey Visual Field testing, only to not be repeatable on that platform. CVFs are quick, simple and rarely result in false positive defects, thus they are still necessary (and much quicker) for screening purposes.

## Fluorescein Angiography

**Dr. Weidmayer:** We have OCT-A! Who needs FA? The truth is: many patients do. OCT-A is amazing and has really broadened our ability to understand and manage disease. We are all enamored with it, and rightly so, in many ways. However, OCT-A does not show leakage or well-characterized vasculature with low flow like FA does.<sup>5</sup>



This later-stage widefield fluorescein angiography (FA) in a patient with an ischemic central retinal vein occlusion shows several areas of capillary dropout, which were targeted with panretinal photocoagulation (PRP).



# 200° of iCare



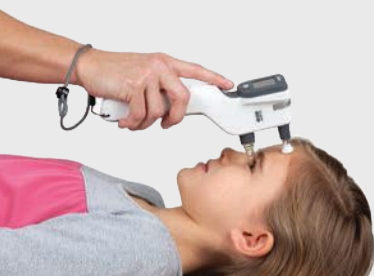## iCare EIDON

Eidon Ultra-Widefield:  
Now covering 200 degrees

iCare's unique combination of sharpness and TrueColor offers now even wider view on the retina from 120 with a single shot, up to 200 with Mosaic functionality, helping to detect subtle signs of pathologies further in the periphery.\*

- + Ultra-Widefield of view up to 200°
- + Rich in details from center to periphery
- + Imaging through media opacities

\* Ultra-Widefield imaging is available with the optional EIDON UWF Module.



## iCare IC200

200 degrees of  
tonometry

- + Supine, recline & seated operations
- + No corneal disruptions
- + Suitable for every patient
- + Single use probes to exceed infection control guidelines



For more information, scan,  
call 888.422.7313, or email  
infoUSA@icare-world.com  
[www.icare-world.com/USA](http://www.icare-world.com/USA)

For better perception **icare**



FA also gives us information about nearly the entire retina (depending on the field width of the camera), whereas OCT-A is limited typically to the macula or a section of the posterior pole at best. FA outperforms OCT-A for evaluating things like peripheral ischemia, which drives treatment decisions, such as PRP planning. So, while OCT-A is storming into clinical practice right now, it does not replace FA for many conditions.

**Dr. Hicks-Hubbard:** I agree! Being able to view in real time the perfusion of the fundus as well as neovascularization that becomes much easier to spot—FA is irreplaceable.

**Dr. Seng:** OCT-A may help decrease the frequency that FA is needed, just like OCT itself did; however, not yet to zero. Keep it!

### Gonioscopy

**Dr. Hicks-Hubbard:** With anterior segment OCT (AS-OCT) being readily available, many practitioners may wonder why they should bother with proparacaine, a contact lens and a contact gel. AS-OCT can be performed by a trained technician, provides an objective finding and can be more comfortable for a patient sensitive to ocular touch.

However, multiple references support gonioscopy as the gold standard for assessment of the anterior chamber angle.<sup>6-8</sup> While AS-OCT provides us with a trove of information, our gonioscopy lenses should not be replaced yet.<sup>9</sup> Assessing any case of newly diagnosed glaucoma for angle recession, neovascularization of the angle (NVA), pigment dispersion syndrome, pseudoexfoliation or a small area of peripheral anterior synechiae all require a view of the iridocorneal angle that can only be achieved with gonioscopy. Additionally, compression of the angle can only be achieved with a contact lens, which is something that cannot be completed using AS-OCT.

It's important to bear in mind that gonioscopy may be irreplaceable but AS-OCT can still provide unique clinical information. For instance, the patency of a laser peripheral iridotomy, as well as changes in iris configuration, can be imaged to provide a clinician further information regarding the angle.<sup>6</sup> As with many ophthalmic advances, a combination approach may provide the greatest clinical benefit.

**Dr. Weidmayer:** I use gonio lenses all the time. We get a direct, 360-degree view of the angle; it's invaluable for detection of NVA and I fully support Dr. Hicks-Hubbard's comment about compression/dynamic gonioscopy, especially to differentiate whether an angle is phacomorphic or to determine if a laser peripheral iridotomy would even help widen an angle.

**Dr. Taylor:** Dr. Weidmayer, I agree with you 100%.

### Pupil Testing

**Dr. Taylor:** The “swinging flashlight test” is one of the first diagnostic tests optometry students are taught. Pupillary abnormalities such as anisocoria, relative affer-

ent pupillary defect (APD), findings suggestive of Horner's syndrome, third nerve palsy or Adie's tonic pupil need to be detected, documented and thoroughly investigated at the earliest time possible.

Rather than ditching it, delegate it. Do you have someone in your office besides yourself that can efficiently and accurately examine pupils? Hav-

ing a well-trained staff will allow providers to see more patients and make office operations run more efficiently. Employees usually want to learn and develop their skills. Take the time to educate your technicians not only on how to check pupils, but also on the reasoning behind checking pupils. If you have trained your technicians to your satisfaction on pupillary testing, you then have to do the hard part: trust their results. Empower your technicians to practice, gain experience and learn from their mistakes.<sup>9</sup>

**Dr. Weidmayer:** I am very hesitant to agree. Missing a Horner's syndrome or an APD, for example, could literally have life-or-death consequences.

**Dr. Taylor:** For sure, but a majority of our patients are dilated before I see them, which is the same for every optometrist I have worked with. Our technicians are trained that if there is any question, they should let the doctor know; they know not to guess.

**Dr. Weidmayer:** I suppose we all have to calculate our own risk vs. benefit and consider carefully who we are trusting to do this important evaluation.

### Schirmer Testing

**Dr. Hicks-Hubbard:** Dry eye disease is a complex, multifactorial condition that is encountered frequently in primary eyecare examinations.<sup>10</sup> Dry eye is complicated by the lack of a gold standard test for appropriate diagnosis. Optometrists have many tools at their disposal—osmolarity testing, phenol red test, Schirmer testing, tear break-up-time—as well as numerous patient questionnaires.<sup>11</sup> These tests, among others, can tell optometrists whether to start treatment as well as what type of treatment will best aid the patient. But as technology and testing become more accessible, is it time to eliminate some of the originals, such as Schirmer testing?

A main fault with Schirmer testing is the lack of sensitivity and specificity in dry eye.<sup>11,12</sup> Knowing when to use this test increases its clinical value. This testing is most useful when examining a patient with suspected Sjögren's disease, but may not be as useful in the diagnosis of other forms of dry eye, such as evaporative.<sup>11</sup> While Schirmer

“FA outperforms OCT-A for evaluating things like peripheral ischemia, which drives treatment decisions, such as PRP planning.”

testing is not necessary on every patient with suspected dry eye, it still holds clinical value for a small subset with suspected severe aqueous-deficient dry eye disease.

**Dr. Weidmayer:** Schirmer's is a fairly objective measure, so it may be more useful for quantifying improvement with treatment more than diagnosing dry eye in the first place. Overall, I say ditch it.

**Dr. Taylor:** I used to do it all the time until I figured out I never used the result in my clinical decision-making.

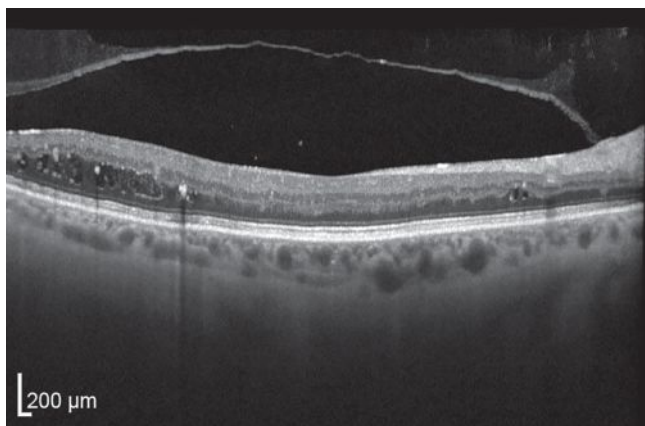
## Nomenclature

As new research changes our conceptions and challenges our habits, it should do the same to the terminology we use. Are we keeping up with the literature?

## Clinically Significant Diabetic Macular Edema (CSDME) Criteria

**Dr. Weidmayer:** This condition has long been defined by the Early Treatment Diabetic Retinopathy Study (ETDRS).<sup>13</sup> We should all be able to rattle off the criteria, but is it clinically relevant anymore? The ETDRS evaluated the efficacy of lasers for macular edema (vs. monitoring), a treatment modality that is, in most cases, now far secondary to anti-VEGF injections. Our ability to image the macula with OCT has also changed our practice patterns and challenged the relevance of ETDRS's CSDME criteria.<sup>14</sup>

There has been a paradigm shift from this CSDME model to that of a center-involved (CIDME or CI-DME) vs. non-center-involved DME, and visually significant vs. not visually significant DME. When to inject anti-VEGF for DME has largely become a game of monitoring unless there is central-involving and visually significant DME, as visual and anatomic outcomes have not been shown to differ with or without treatment in those with CI-DME but good acuity (typically defined as at least 20/30).<sup>15,16</sup> Certainly, this protocol varies per patient situation, but is broadly accepted.



This OCT shows non-center-involving but not visually significant diabetic macular edema (non-CI, NVS DME) with intraretinal fluid and exudates. This would qualify as CSDME per the ETDRS.

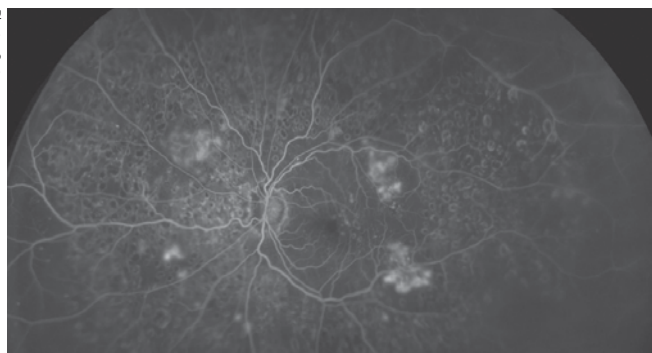
# Can One Device Have It All?

## SCANMATE FLEX

The Scanmate Flex, a portable, ophthalmic ultrasound platform, is the perfect product to enhance your practice's diagnostic capabilities. The Flex provides any desired combination of A-Scan, B-Scan, and UBM. It's hall mark is flexibility.

**DGH** TECHNOLOGY, INC.  
THE ULTRASOUND SPECIALIST  
Serving Eye Care Professionals since 1982





**Ultra-widefield imaging's expansive views of the retina highlight the shortcomings of conventional diabetic retinopathy staging.**

It is still important to have universal criteria for the purpose of clinical grading of diabetic retinopathy, research protocols/outcomes, coding and so on, but from a clinical standpoint, the classic “CSDME” has largely gone by the wayside.

**Dr. Hicks-Hubbard:** It is hard to lose the definition known so readily by all eyecare providers, but as the primary treatment modality has changed, so has the treatment criteria. As retina specialists shift away from CS-DME, so should optometrists.

### Diabetic Retinopathy Staging

**Dr. Hicks-Hubbard:** The classification of diabetic retinopathy has been based upon seven standardized photographs since the late '60s. While this classification and staging has evolved over time, a significant change hasn't been made since the ETDRS.<sup>16</sup> With so much time between then and now, are we overdue to adjust our staging?

It is essential to have universal criteria for diabetic retinopathy staging, but with recent technological advances, particularly the advent of ultra-widefield photography (UWF), it may be time to update our classification. With UWF photography, a larger portion of the retina can be photographed, reviewed, assessed and staged. When comparing UWF and the standard seven-field photograph series from the ETDRS, skilled readers demonstrate agreement in the grading of the severity of diabetic retinopathy. Furthermore, UWF has been shown to have the ability to image peripheral lesions previously not seen by the standardized seven-field photograph series.<sup>17</sup> However, it is still unknown what this peripheral pathology can tell us about the progression of the disease.<sup>17</sup>

Despite the clear advances in imaging technology, the clear-cut definitions and photographs from the ETDRS are not obsolete; rather, we may be adding to them. As we can better image the retina, we may be able to adjust or augment our staging based on peripheral retinal pathology, which will allow us to better assess a patient's risk of progression to more severe forms of diabetic retinopathy.

No new staging systems have been validated yet, but as one source recommends, we can adjust our staging in

a number of ways. This may not only include peripheral retinal pathology but also a more comprehensive assessment of visual outcomes, as well as better staging of both neovascularization and macular edema. The addition of these measures will need to be evaluated for impact on disease progression and visual outcomes but could provide further clarification and staging of retinopathy for diabetic patients.<sup>18</sup>

**Dr. Seng:** I agree that we should be able to ditch this; we should be able to do better. Honestly, standardized photos have not done much to standardize individuals' clinical staging diagnosis (I often see mild/moderate/severe used inconsistently) or decision-making. However, until there is a better system in widespread use, it is better than nothing.

### Blood Pressure and A1c Readings

**Dr. Taylor:** Hypertension (HTN) and diabetes are systemic diseases that have potentially sight-threatening complications. Are “normal” readings “normal” for everyone? Well, it depends. Knowing what is normal based on age and ethnicity is important, since it can play a vital role in what is considered normal for your particular patient.

Guidelines based on the 2017 results of the Systolic Blood Pressure Intervention Trial have a blood pressure reading of 130/80 as the criteria for the diagnosis of hypertension. No differentiation was made between different age groups with these guidelines, which were endorsed by the American Heart Association and the American College of Cardiology. The study concluded that having a systolic pressure of no more than 120mm Hg reduced the risk of heart attacks, heart failure and stroke over a three-year period. A systolic reading between 130 of 139 or a diastolic reading of 80 to 89 is classified as Stage 1 HTN. Stage 2 HTN occurs when systolic readings are 140 or higher or diastolic readings are over 90.<sup>19</sup>

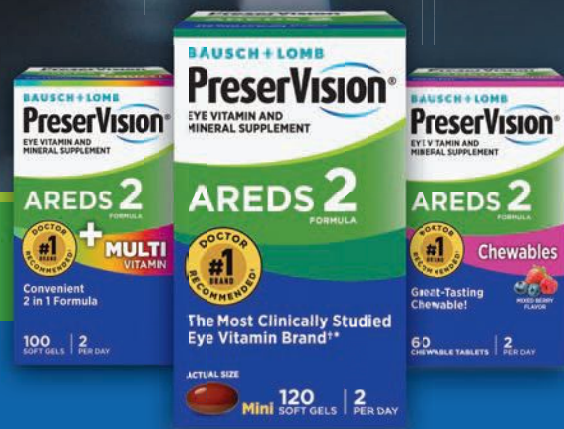Be cognizant of racial disparities in the incidence of HTN, along with patients who have comorbidities such as diabetes, chronic kidney disease and cardiovascular disease. African Americans statistically have higher blood pressure readings and suffer from hypertension at an earlier age than Caucasians. The reasons for racial differences in higher blood pressure and the associated risks are not clearly understood, but with African Americans at dramatically higher risk for stroke and end-stage kidney disease related to HTN, early diagnosis and appropriate referral is essential.<sup>20</sup>

In diabetes management, the A1c readings help guide management decisions. The A1c test measures the amount of glucose in blood attached to hemoglobin. The result is a percentage, with a normal reading being below 5.7%. There are hemoglobin variants, though, that can affect A1c readings. These variants are inherited from one's parents and have an ethnicity pattern. Since 2006, all states screen newborns for hemoglobin S, which is



# The most studied eye vitamin brand.<sup>†</sup>

## PreserVision<sup>®</sup>



PreserVision AREDS 2 is backed by 20 years of clinical studies and contains the EXACT nutrient formula recommended by the National Eye Institute to help reduce the risk of moderate to advanced AMD progression.\*<sup>2,3</sup>

Recommend PreserVision for your patients today

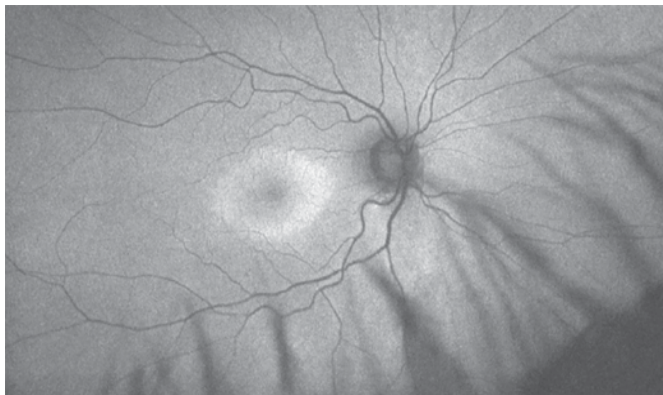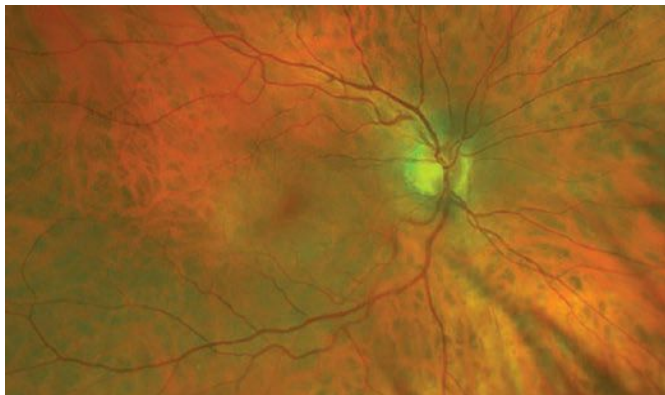
For samples, call **1-844-BL-VITES** (1-844-258-4837)

**BAUSCH + LOMB**

\*These statements have not been evaluated by the Food and Drug Administration. These products are not intended to diagnose, treat, cure, or prevent any disease.

Packaging may vary. AREDS=Age-Related Eye Disease Study.  
†Based on the AREDS and AREDS2 clinical studies.  
‡Data on file for #1 Dr. Recommended Brand, Bausch + Lomb. †National Eye Institute, National Institutes of Health; September 2015. Accessed November 4, 2020. [https://www.nei.nih.gov/sites/default/files/health-pdfs/WYSK\\_AMD\\_English\\_Sept2015\\_PRINT.pdf](https://www.nei.nih.gov/sites/default/files/health-pdfs/WYSK_AMD_English_Sept2015_PRINT.pdf) ‡Age-Related Eye Disease Study 2 Research Group. JAMA. 2013;309(19):2005-2015. doi:10.1001/jama.2013.4997

PreserVision is a trademark of Bausch & Lomb Incorporated or its affiliates. AREDS and AREDS2 are registered trademarks of the United States Department of Health and Human Services (HHS). © 2021 Bausch & Lomb Incorporated or its affiliates. PN09897 PVN.0040.USA.21



**Optos photo showing parafoveal outer retinal and RPE atrophy and FAF imaging showing parafoveal hyper-AF of classic bull's-eye maculopathy seen in Plaquenil toxicity.**

associated with sickle cell disease. Some states also screen for hemoglobin C and hemoglobin E disease. Suspect a hemoglobin variant in your patient if they have a family history of blood disorders or have family from a region of the world where variants are common.<sup>21</sup>

### Clinical Monitoring/Management

How we examine the eye, and what we look for, is another moving target. Let's see how a few staples are holding up today.

#### Dilated Exams

**Dr. Hicks-Hubbard:** The annual dilated exam is often dreaded by patients due to side effects and longer wait times in-office; therefore, some providers may feel that UWF photography is a way to combat those concerns. While UWF photography does alleviate those issues, dilation is here to stay. Dilation is still considered the gold standard for assessment and diagnosis of the internal structures of the eye.<sup>22</sup>

Peripheral retinal pathology is still better visualized when performing a dilated fundoscopic exam when compared to UWF photography. One study found that for retinal pathology anterior to the equator, one UWF camera was only sensitive for 45% of pathology detected via dilated fundoscopic exam.<sup>22</sup> That being said, another study demonstrated that imaging of ocular tumors can be documented, as well as managed, using UWF photography.<sup>23</sup> As mentioned above, UWF photography can also provide additional information in the management of diabetic retinopathy.<sup>17</sup> While the frequency of dilation is determined on a case-by-case basis and photography certainly offers some advantages, it seems that these work best in partnership with one another rather than exclusivity.

**Dr. Seng:** There may come a time when photography may be good enough to replace a dilated fundus exam, but I am doubtful. UWF cameras do allow for a more complete exam when a patient refuses dilation, or cannot be dilated, but they do not provide nearly good enough quality, nor do they get peripheral enough in all quadrants

on a consistent basis to replace a properly performed dilated exam. Most patients will agree to the procedure once they are educated on its importance and are prepared and expecting it as part of their complete exam at appropriate frequency as indicated by ocular and medical history.

#### Bull's-eye Maculopathy Screening

**Dr. Seng:** Chloroquine and hydroxychloroquine have long been known to be causative agents for vision-threatening bull's-eye maculopathy. However, the best clinical practices for early detection have evolved over time. Monitoring until the macular pigment changes that make up a bull's-eye can be detected is long outdated, as this represents end-stage disease with irreparable vision loss. Total dose prescribed (mg/kg of actual weight/day) and length of treatment (cumulative dose) are still important factors (the American Academy of Ophthalmology considers over 1,000 total grams to be at risk), as are other compounding risks such as tamoxifen use or kidney disease. However, the at-risk timeframe can be shorter than previous publications have suggested, and overall incidence of toxicity somewhat higher.<sup>24</sup>

In-office Amsler grid, color vision testing and fundus photos no longer play a significant role in preventative monitoring, according to the newest guidelines set forth in 2016. The key monitors that currently need to be employed include SD-OCT scans to evaluate for parafoveal photoreceptor ellipsoid zone discontinuity, autofluorescence imaging, 10-2 visual field testing and, when indicated, multifocal electroretinogram.<sup>25</sup> Of particular note, however, is that maculopathy in patients of Asian descent can develop outside of the macular zone, so 30-2 or 24-2 visual field testing should be employed, and the zone of monitoring with SD-OCT and autofluorescence should be adjusted to either widefield or off-axis testing.<sup>26</sup> We must be sure to follow up-to-date clinical practice guidelines to minimize patient morbidity in relation to this medication.

**Dr. Weidmayer:** I agree; if we ever see a bull's-eye, we've missed the boat.

**Dr. Taylor:** I agree.



## “Lumpy Bumpy” and “Lazy V” on OCT for Disc Drusen

**Dr. Weidmayer:** In the early years of OCT, we latched onto how a “lumpy-bumpy” internal contour of the optic disc indicated optic disc drusen, differentiating it from disc edema where we saw a “lazy V” pattern with a smooth contour.<sup>27</sup> The “lumpy-bumpy” vs. “lazy V” criteria gave us just less than two-thirds for both sensitivity and specificity; nonetheless, at the time this was tremendously helpful.<sup>27</sup>

However, with a shift from time-domain to spectral and swept-source OCT, we can now physically see optic disc drusen on OCT, and we also have tools such as autofluorescence imaging to easily highlight disc drusen. When all else fails we still have B-scan, which sorts this out nicely. “Lumpy-bumpy” vs. “lazy V” for optic disc drusen may be obsolete terminology.

**Dr. Taylor:** Optic nerve drusen are a good excuse to have a B-scan!

**Dr. Weidmayer:** Preach it, Brad.

## IOP Adjustment Factors

**Dr. Weidmayer:** Using a historic IOP adjustment factor for applanation tonometry to determine a corrected IOP depending on central corneal thickness (CCT) was never a true clinical calculation—it was a concept.

We do still need to consider how thin and thick CCT can contribute to inaccurate characterization of actual IOP, and we know thin CCT is important in considering glaucoma risk. However, we’ve also learned that corneal biomechanical properties (such as hysteresis) other than just the physical and geometric properties (such as CCT) affect IOP measurements as well, and moreover affect how the optic nerve is able to tolerate the IOP.<sup>28</sup> So, IOP is more than just applanation with an adjustment to account for CCT.

Rather than actually adjusting IOP measurements per the old tables, we can instead clinically consider a “thick or thin” mentality for CCT and consider how that—along with myriad other considerations—impacts glaucoma development and progression risk. Save yourself the math and throw away your IOP adjustment table.

**Dr. Hicks-Hubbard:** I agree with Sara! It is time to ditch the tables. The thickness of the cornea definitely needs to be considered, but a mindset of thick or thin is more relevant rather than an exact conversion.

**Dr. Taylor:** I agree!

## Scratching the Surface

Despite devoting nearly 5,000 words to the subject of diagnostic protocols, it’s clear that the topic could easily merit twice as much coverage—and still not achieve 100% consensus or touch on all the debates in play at any given moment. Such is the fun, and the frustration, of practicing optometry in an environment marked by constant advancement in our knowledge, capabilities and scope. Please share with us your own stance on the above points or others not addressed here! ■

*The views expressed by the authors do not necessarily reflect the positions of the US government or Department of Veterans Affairs.*

1. Trevino R, Kynn MG. Macular function surveillance revisited. *Rev Optom.* 2008;79(7):397-403.
2. Kampmeier J, Zorn MM, Lang GK, et al. Comparison of the preferential hyperacuity perimeter (PHP) test and amsler grid test in the diagnosis of different stages of age-related macular degeneration. *Klin Monbl Augenheilkd.* 2006;223(9):752-6.
3. National Research Council (US) Committee on Vision. *Procedures for Testing Color Vision: Report of Working Group 41.* Washington (DC): National Academies Press (US); 1981. PMID: 25032450.
4. Shahinfar S, Johnson LN, Madsen RW. Confrontation visual field loss as a function of decibel sensitivity loss on automated static perimetry. Implications on the accuracy of confrontation visual field testing. *Ophthalmology.* 1995;102(6):872-7.
5. Fayed AE, Fawzi A. OCTA vs dye: the pros and cons. *Rev Ophthalmol.* [www.reviewofophthalmology.com/article/octa-vs-dye-the-pros-and-cons](http://www.reviewofophthalmology.com/article/octa-vs-dye-the-pros-and-cons). January 5, 2019. Accessed January 25, 2022.
6. Maslin JS, Barkana Y, Dorairaj SK. Anterior segment imaging in glaucoma: an updated review. *Indian J Ophthalmol.* 2015;63(8):630-40.
7. Sakata LM, Lavanya R, Friedman DS, et al. Comparison of gonioscopy and anterior segment ocular coherence tomography in detecting angle closure in different quadrants of the anterior chamber angle. *Ophthalmology.* 2008;115(5):769-74.
8. Xu BY, Pardeshi AA, Burkemper B, et al. Differences in anterior chamber angle assessments between gonioscopy, EyeCam and anterior segment OCT: the Chinese American Eye Study. *Transl Vis Sci Technol.* 2019;8(2):5.
9. Thomas C. Clinical: the back. *Optometric Management.* November 2014;49:34-5, 45.
10. Craig JP, Nichols KK, Akpek EK, et al. TFOS DEWS II Definition and Classification Report. *Ocul Surf.* 2017;15(3):276-83.
11. Wolffsohn JS, Arita R, Chalmers R, et al. TFOS DEWS II Diagnostic Methodology report. *Ocul Surf.* 2017;15(3):539-74.
12. Scott CA, Catania LJ, Larkin KM, et al. Care of the patient with ocular surface disorders. American Optometric Association. [www.my.ico.edu/file/CPG-10--Ocular-Surface-Disorders.pdf](http://www.my.ico.edu/file/CPG-10--Ocular-Surface-Disorders.pdf).
13. Early Treatment Diabetic Retinopathy Study Research Group. Grading Diabetic Retinopathy from Stereoscopic Color Fundus Photographs—an Extension of the Modified Airlie House Classification. ETDRS Report Number 10. *Ophthalmology.* 1991;98(5):786-806.
14. Solomon SD, Goldberg MF. ETDRS grading of diabetic retinopathy: still the gold standard? *Ophthalmic Res.* 2019;62(4):190-5.
15. Zafar S, Smith K, Boland MV, et al. Real-world outcomes among eyes with center-involving diabetic macular edema and good visual acuity. *Curr Eye Res.* 2020;45(7):879-87.
16. Baker CW, Glassman AR, Beaulieu WT, et al. Effect of initial management with aflibercept vs laser photocoagulation vs observation on vision loss among patients with diabetic macular edema involving the center of the macula and good visual acuity: a randomized clinical trial. *JAMA.* 2019;321(19):1880-94.
17. Aiello LP, O’Day I, Glassman AR, et al. Comparison of early treatment diabetic retinopathy study standard 7-field imaging with ultrawide-field imaging for determining severity of diabetic retinopathy. *JAMA Ophthalmol.* 2019;137(1):65-73.
18. Sun JK, Aiello LP, Abràmoff MD, et al. Updating the staging system for diabetic retinal disease. *Ophthalmology.* 2021;128(4):490-3.
19. Reading the new blood pressure guidelines. Harvard Health Publishing. [www.health.harvard.edu/heart-health/reading-the-new-blood-pressure-guidelines](http://www.health.harvard.edu/heart-health/reading-the-new-blood-pressure-guidelines). November 16, 2021. Accessed January 25, 2022.
20. Lackland DT. Racial difference in hypertension: implications for high blood pressure management. *Am J Med Sci.* 2014;348(2):135.
21. Association of Public Health Laboratories and Centers for Disease Control and Prevention. Hemoglobinopathies: current practices for screening, confirmation and follow-up. Silver Spring, MD: Association of Public Health Laboratories; 2015. [www.cdc.gov/ncbddd/sicklecell/documents/nbs\\_hemoglobinopathy-testing\\_122015.pdf](http://www.cdc.gov/ncbddd/sicklecell/documents/nbs_hemoglobinopathy-testing_122015.pdf)
22. Mackenzie PJ, Russell M, Ma PE, et al. Sensitivity and specificity of the optos optomap for detecting peripheral retinal lesions. *Retina.* 2007;27(8):1119-24.
23. Callaway NF, Mruthyunjaya P. Widefield imaging of retinal and choroidal tumors. *Int J Retina Vitreous.* 2019;5(Suppl 1):49.
24. Melles RB, Marmor MF. The risk of toxic retinopathy in patients on long term hydroxychloroquine therapy. *JAMA Ophthalmol.* 2014;132:1453-60.
25. Marmor MF, Kellner U, Lai TY, et al. Recommendations on screening for chloroquine and hydroxychloroquine retinopathy. *Ophthalmology.* 2016;123:1386-94.
26. Melles RB, Marmor MF. Pericentral retinopathy and racial differences in hydroxychloroquine toxicity. *Ophthalmology.* 2015;122:110-6.
27. Johnson LN, Diehl ML, Hamm CW, et al. Differentiating optic disc edema from optic nerve head drusen on optical coherence tomography. *Arch Ophthalmol.* 2009;127(1):45-9.
28. Belovay GW, Goldberg I. The thick and thin of the central corneal thickness in glaucoma. *Eye (Lond).* 2018;32(5):915-23.



# GONIOSCOPY: A SIMPLE TOOL, TOO OFTEN FORGOTTEN

Sharpen your skills with this valuable technique.



**AMILA HERBERT, OD,<sup>1</sup>**  
**KELLY THOMPSON, OD,<sup>1</sup>**  
**AND CARLY ROSE, OD,<sup>2</sup>**  
<sup>1</sup> CINCINNATI, OH  
<sup>2</sup> MARIEMONT, OH

**W**e often see our student clinicians and residents become nervous when performing gonioscopy, but it is not just those fresh learners who need the help and practice with anterior segment assessment and analysis.

Gonioscopy is an important ocular health assessment that takes less than two minutes to perform and provides a tremendous amount of information.

Yet, many doctors in workshops we lead seldom perform gonioscopy.<sup>1</sup> Why? Likely because they never really became confident in performing it and have now avoided it for so long that they have lost this clinical skill. But have no fear: with practice, gonioscopy will become a quick and valuable tool.

## Tendency to Overlook

Gonioscopy is the process of assessing the anterior chamber in order to diag-

nose abnormalities of the intraocular drainage system. The globe produces and drains aqueous humor constantly. If the angle is narrow or closed, the drainage of the fluid would be obstructed, potentially causing an elevated intraocular pressure (IOP). Gonioscopy is the gold standard for diagnosing angle closure, is important in detecting signs of secondary glaucoma and provides an evaluation of the angle anatomy including iris configuration, the presence of peripheral anterior synechiae, pseudoexfoliation, pigmentation within the trabecular meshwork, neovascularization, tumors and angle recession.<sup>2</sup>

Unfortunately, gonioscopy is not being performed as often as it should be by doctors clinically. Gonioscopy needs to be performed on patients who have suspected angle narrowing or patients with a history of increased IOP, retinal vein occlusion, proliferative diabetic retinopathy, ocular ischemic events or ocular trauma. Performing gonioscopy on all your glaucoma patients will not only allow you to properly classify the type of glaucoma but also to continue

to practice and become much more confident identifying angle structures and pathology.

Clinicians often train their technicians to assess the anterior chamber using the Van Herick grading technique. Van Herick assessment uses a thin slit lamp beam at the peripheral edge of the cornea, angled at least 60°. You then compare the width of the corneal cross-section with the gap between the posterior cornea and the illumination on the iris to estimate depth. Any anterior chamber with a grade II or shallower by Van Herick must be fully assessed using gonioscopy.

However, studies have shown the Van Herick method has low accuracy in properly identifying narrow angles.<sup>3,4</sup> Without performing gonioscopy, many narrow angles are not being identified. Therefore, periodic gonioscopy re-evaluation is necessary, as patients who appeared to have an open angle in the past can go on to develop angle-closure.

Anterior segment optical coherence tomography (AS-OCT) can be helpful for patients with cloudy corneas or who

### About the authors

Dr. Herbert and Dr. Thompson practice at the Cincinnati VA Medical Center. Dr. Rose owns and practices at Eyecare on the Square in Mariemont, OH. They are Fellows of the American Academy of Optometry. They have no financial disclosures.

are unable to tolerate the procedure, but current AS-OCT technology is expensive, only measures a small fraction of the angle, can be disruptive to clinic flow and does not have a high enough specificity to be used as a general screening tool.<sup>5</sup>

AS-OCT is a great tool for quantitatively assessing the angle in scotopic vs. photopic situations. Though this can be done with gonioscopy subjectively, the objective nature of the OCT measurements are more accurate.

Gonioscopy remains the gold standard for angle assessment given the access to lenses vs. machines, as well as the ability to assess the angle 360° vs. small cross-sections on OCT, which does not depict the full picture.

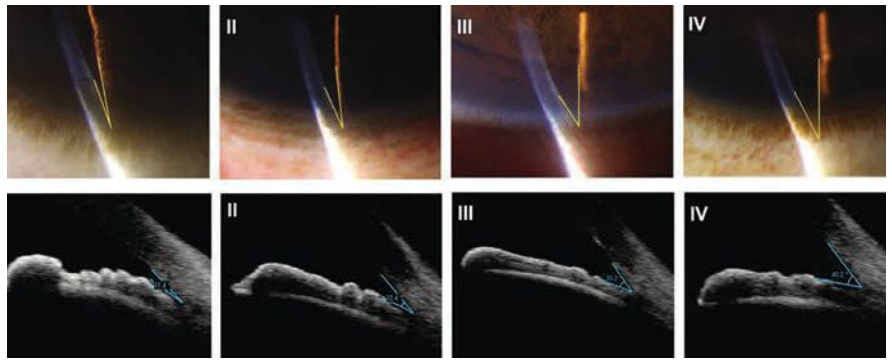
## Mirrors and Lenses

There are many types of gonioscopy lenses to view the angle, and each is beneficial in different situations.

Three-mirror lenses provide the best view of the angle but require a coupling solution. With using a larger diameter lens such as the three-mirror, using a coupling solution allows for fewer air bubbles in your view, as well as the suction of the lens to the cornea. Three-mirror lenses contain a central fundus lens, a thumbnail mirror (59°) for viewing the angle and ora serrata, a rectangular mirror (67°) for viewing the equator to ora and a trapezoid mirror (73°) for viewing the posterior pole to equator. You must rotate the lens 360° to view the entire angle.

The smallest and steepest mirror is used for gonioscopy, while the other two mirrors and the central lens are used for evaluation of the retina. This makes the three-mirror lens a particularly valuable multipurpose tool. Because of its outstanding optics and ease of handling, this lens is particularly useful for beginners.

Small lenses without a flange—most commonly four-mirror lenses—are more difficult to master, as the lens does not tightly affix to the anterior surface. But once you do master the technique, four-mirror lenses are faster and do not require a coupling solution.



**An assessment of the anterior chamber depth using the Van Herick method and grading system. This is a quick screening method to estimate anterior chamber depth.**

Small lenses also have the unique benefit of being able to perform dynamic gonioscopy, a technique in which the lens can be used to compress the cornea and the anterior chamber to assess if the chamber is anatomically closed vs. if there is peripheral anterior synechiae. Pushing in the cornea to make a few folds will push anterior chamber aqueous through the chamber. If the angle is narrow or closed with compression, the angle will widen; however, with synechial closure or with a plateau iris, the angle will stay the same depth.

There are also four-mirror lenses available with a flange, which combines the strengths of both the three-mirror and four-mirror lenses. Since there are four lenses for viewing the angle, the lens only needs to be rotated 11° to complete the 360° view.<sup>6</sup>

## Application and Technique

Ideally, gonioscopy should be performed on an undilated patient, in a room with dimmed light, using low slit lamp illumination. Physiologic pupil constriction due to light levels can artificially open the angle, thus overestimating the natural depth of the anterior chamber. Set your slit lamp initially at low magnification to better orient yourself within the lens. Once you have prepared your lens, adding coupling solution as necessary, instill topical anesthetic to both eyes of the patient.

Make sure to position the patient in the slit lamp as comfortably as possible. This will help to ensure the patient

does not move during the examination. The patient's lateral canthus should line up with the canthal marking line on the slit lamp to allow enough vertical movement of the slit lamp joystick so the patient and the clinician do not have to move once the lens is placed. Explain to the patient that the lens will come very close to the eye but it will not hurt. Brushing their eyelashes lightly with the lens will minimize the patient's surprise and impulse to pull away. Once you have inspected the corneal integrity and the patient's anterior surface is numb, you are ready to start.

Whether using a three-mirror or four-mirror indirect lens, have the patient look up and set the inferior edge of the lens on the bulbar conjunctiva. This will ensure that the lower lid is blocked from pushing the lens up. Have the patient look straight ahead while rocking and centering the lens on the corneal surface. You may need to use the other hand to move the upper eyelid up out of the way of the lens. Ideally, the lens is held inferiorly by the thumb and superiorly with the middle finger, allowing for the index finger to be free to rotate the lens as needed and your other hand to maneuver the joystick. The ring and pinky fingers thus can rest on the patient's cheek or forehead strap for stability during the exam. The clinician may need support under their elbow, which will aid in stability of the lens and comfort and stamina of the doctor.

Once the lens is in place, it is best practice to begin by assessing the inferior angle. Remember you are

In Patients With Diabetic Eye Disease (DR and DME),

# HELPING TO PROTECT VISION STARTS WITH YOU

## IF YOU SEE OR SUSPECT DIABETIC RETINOPATHY



### EDUCATE PATIENTS<sup>1</sup>

- Your early and frequent discussions about progression of disease, timely referral, and potential treatment options can empower patients<sup>1</sup>



### REFER APPROPRIATE PATIENTS<sup>1</sup>

- The AOA recommends referring patients with severe NPDR and PDR within 2 to 4 weeks, and patients with higher-risk PDR with or without macular edema within 24 to 48 hours<sup>1</sup>

## IMPORTANT SAFETY INFORMATION CONTRAINDICATIONS

- EYLEA is contraindicated in patients with ocular or periocular infections, active intraocular inflammation, or known hypersensitivity to aflibercept or to any of the excipients in EYLEA.

## WARNINGS AND PRECAUTIONS

- Intravitreal injections, including those with EYLEA, have been associated with endophthalmitis and retinal detachments. Proper aseptic injection technique must always be used when administering EYLEA. Patients should be instructed to report any symptoms suggestive of endophthalmitis or retinal detachment without delay and should be managed appropriately. Intraocular inflammation has been reported with the use of EYLEA.
- Acute increases in intraocular pressure have been seen within 60 minutes of intravitreal injection, including with EYLEA. Sustained increases in intraocular pressure have also been reported after repeated intravitreal dosing with VEGF inhibitors. Intraocular pressure and the perfusion of the optic nerve head should be monitored and managed appropriately.
- There is a potential risk of arterial thromboembolic events (ATEs) following intravitreal use of VEGF inhibitors, including EYLEA. ATEs are defined as nonfatal stroke, nonfatal myocardial infarction, or vascular death (including deaths of unknown cause). The incidence of reported thromboembolic events in wet AMD studies during the first year was 1.8% (32 out of 1824) in the combined group of patients treated with EYLEA compared with 1.5% (9 out of 595) in patients treated with ranibizumab; through 96 weeks, the incidence was 3.3% (60 out of 1824) in the EYLEA group compared with 3.2% (19 out of 595) in the ranibizumab group. The incidence in the DME studies from baseline to week 52 was 3.3% (19 out of 578) in the combined group of patients treated with EYLEA compared with 2.8% (8 out of 287) in the control group; from baseline to week 100, the incidence was 6.4% (37 out of 578) in the combined group of patients treated with EYLEA compared with 4.2% (12 out of 287) in the control group. There were no reported thromboembolic events in the patients treated with EYLEA in the first six months of the RVO studies.

Please see Important Safety Information throughout and Brief Summary of the full Prescribing Information on the following page.

EYLEA is a registered trademark of Regeneron Pharmaceuticals, Inc.

**REGENERON**<sup>®</sup>


© 2021, Regeneron Pharmaceuticals, Inc. All rights reserved.  
777 Old Saw Mill River Road, Tarrytown, NY 10591





# EYLEA<sup>®</sup> (aflibercept) Injection For Intravitreal Injection

Brought to you by **REGENERON**<sup>®</sup>



## FOLLOW UP WITH PATIENTS

- Encourage referred patients to promptly visit a retina specialist



## CONTINUE TO MONITOR PATIENTS<sup>1</sup>

- The AOA recommends frequent monitoring of patients<sup>1</sup>
  - At least every 6 to 9 months in patients with moderate NPDR and more frequently for patients with greater disease severity

**The more you know about anti-VEGF agents and other potential treatments for DR, the better you can help inform your patients. Find out more by visiting [diabeticretinaldisease.com](http://diabeticretinaldisease.com).**

## ADVERSE REACTIONS

- Serious adverse reactions related to the injection procedure have occurred in <0.1% of intravitreal injections with EYLEA including endophthalmitis and retinal detachment.
- The most common adverse reactions (≥5%) reported in patients receiving EYLEA were conjunctival hemorrhage, eye pain, cataract, vitreous detachment, vitreous floaters, and intraocular pressure increased.
- Patients may experience temporary visual disturbances after an intravitreal injection with EYLEA and the associated eye examinations. Advise patients not to drive or use machinery until visual function has recovered sufficiently.

## INDICATIONS

EYLEA<sup>®</sup> (aflibercept) Injection 2 mg (0.05 mL) is indicated for the treatment of patients with Neovascular (Wet) Age-related Macular Degeneration (AMD), Macular Edema following Retinal Vein Occlusion (RVO), Diabetic Macular Edema (DME), and Diabetic Retinopathy (DR).

anti-VEGF, anti-vascular endothelial growth factor; AOA, American Optometric Association; NPDR, nonproliferative diabetic retinopathy; PDR, proliferative diabetic retinopathy.

**Reference:** 1. Eye care of the patient with diabetes mellitus. American Optometric Association. Accessed April 2, 2021. <http://aoa.uberflip.com/i/1183026-evidence-based-clinical-practice-guideline-eye-care-of-the-patient-with-diabetes-mellitus-second-edition/>



**BRIEF SUMMARY**—Please see the EYLEA full Prescribing Information available on HCP.EYLEA.US for additional product information.

#### 1 INDICATIONS AND USAGE

EYLEA is a vascular endothelial growth factor (VEGF) inhibitor indicated for the treatment of patients with:

**Neovascular (Wet) Age-Related Macular Degeneration (AMD), Macular Edema Following Retinal Vein Occlusion (RVO), Diabetic Macular Edema (DME), Diabetic Retinopathy (DR).**

#### 4 CONTRAINDICATIONS

##### 4.1 Ocular or Periorbital Infections

EYLEA is contraindicated in patients with ocular or periorbital infections.

##### 4.2 Active Intraocular Inflammation

EYLEA is contraindicated in patients with active intraocular inflammation.

##### 4.3 Hypersensitivity

EYLEA is contraindicated in patients with known hypersensitivity to afibercept or any of the excipients in EYLEA. Hypersensitivity reactions may manifest as rash, pruritus, urticaria, severe anaphylactic/anaphylactoid reactions, or severe intraocular inflammation.

#### 5 WARNINGS AND PRECAUTIONS

##### 5.1 Endophthalmitis and Retinal Detachments

Intravitreal injections, including those with EYLEA, have been associated with endophthalmitis and retinal detachments [see *Adverse Reactions* (6.1)]. Proper aseptic injection technique must always be used when administering EYLEA. Patients should be instructed to report any symptoms suggestive of endophthalmitis or retinal detachment without delay and should be managed appropriately [see *Patient Counseling Information* (17)].

##### 5.2 Increase in Intraocular Pressure

Acute increases in intraocular pressure have been seen within 60 minutes of intravitreal injection, including with EYLEA [see *Adverse Reactions* (6.1)]. Sustained increases in intraocular pressure have also been reported after repeated intravitreal dosing with vascular endothelial growth factor (VEGF) inhibitors. Intraocular pressure and the perfusion of the optic nerve head should be monitored and managed appropriately.

##### 5.3 Thromboembolic Events

There is a potential risk of arterial thromboembolic events (ATEs) following intravitreal use of VEGF inhibitors, including EYLEA. ATEs are defined as nonfatal stroke, nonfatal myocardial infarction, or vascular death (including deaths of unknown cause). The incidence of reported thromboembolic events in wet AMD studies during the first year was 1.8% (32 out of 1824) in the combined group of patients treated with EYLEA compared with 1.5% (9 out of 595) in patients treated with ranibizumab; through 96 weeks, the incidence was 3.3% (60 out of 1824) in the EYLEA group compared with 3.2% (19 out of 595) in the ranibizumab group. The incidence in the DME studies from baseline to week 52 was 3.3% (19 out of 578) in the combined group of patients treated with EYLEA compared with 2.8% (8 out of 287) in the control group; from baseline to week 100, the incidence was 6.4% (37 out of 578) in the combined group of patients treated with EYLEA compared with 4.2% (12 out of 287) in the control group. There were no reported thromboembolic events in the patients treated with EYLEA in the first six months of the RVO studies.

#### 6 ADVERSE REACTIONS

The following potentially serious adverse reactions are described elsewhere in the labeling:

- Hypersensitivity [see *Contraindications* (4.3)]
- Endophthalmitis and retinal detachments [see *Warnings and Precautions* (5.1)]
- Increase in intraocular pressure [see *Warnings and Precautions* (5.2)]
- Thromboembolic events [see *Warnings and Precautions* (5.3)]

##### 6.1 Clinical Trials Experience

Because clinical trials are conducted under widely varying conditions, adverse reaction rates observed in the clinical trials of a drug cannot be directly compared to rates in other clinical trials of the same or another drug and may not reflect the rates observed in practice.

A total of 2980 patients treated with EYLEA constituted the safety population in eight phase 3 studies. Among those, 2379 patients were treated with the recommended dose of 2 mg. Serious adverse reactions related to the injection procedure have occurred in <0.1% of intravitreal injections with EYLEA including endophthalmitis and retinal detachment. The most common adverse reactions (≥5%) reported in patients receiving EYLEA were conjunctival hemorrhage, eye pain, cataract, vitreous detachment, vitreous floaters, and intraocular pressure increased.

**Neovascular (Wet) Age-Related Macular Degeneration (AMD).** The data described below reflect exposure to EYLEA in 1824 patients with wet AMD, including 1223 patients treated with the 2-mg dose, in 2 double-masked, controlled clinical studies (VIEW1 and VIEW2) for 24 months (with active control in year 1). Safety data observed in the EYLEA group in a 52-week, double-masked, Phase 2 study were consistent with these results.

**Table 1: Most Common Adverse Reactions (≥1%) in Wet AMD Studies**

Adverse Reactions	Baseline to Week 52		Baseline to Week 96	
	EYLEA (N=1824)	Active Control (ranibizumab) (N=595)	EYLEA (N=1824)	Control (ranibizumab) (N=595)
Conjunctival hemorrhage	25%	28%	27%	30%
Eye pain	9%	9%	10%	10%
Cataract	7%	7%	13%	10%
Vitreous detachment	6%	6%	8%	8%
Vitreous floaters	6%	7%	8%	10%
Intraocular pressure increased	5%	7%	7%	11%
Ocular hyperemia	4%	8%	5%	10%
Corneal epithelium defect	4%	5%	5%	6%
Detachment of the retinal pigment epithelium	3%	3%	5%	5%
Injection site pain	3%	3%	3%	4%
Foreign body sensation in eyes	3%	4%	4%	4%
Lacrimation increased	3%	1%	4%	2%
Vision blurred	2%	2%	4%	3%
Intraocular inflammation	2%	3%	3%	4%
Retinal pigment epithelium tear	2%	1%	2%	2%
Injection site hemorrhage	1%	2%	2%	2%
Eyelid edema	1%	2%	2%	3%
Corneal edema	1%	1%	1%	1%
Retinal detachment	<1%	<1%	1%	1%

Less common serious adverse reactions reported in <1% of the patients treated with EYLEA were hypersensitivity, retinal tear, and endophthalmitis.

**Macular Edema Following Retinal Vein Occlusion (RVO).** The data described below reflect 6 months exposure to EYLEA with a monthly 2 mg dose in 218 patients following central retinal vein occlusion (CRVO) in 2 clinical studies (COPERNICUS and GALILEO) and 91 patients following branch retinal vein occlusion (BRVO) in one clinical study (VIBRANT).

## REGENERON

Manufactured by:  
Regeneron Pharmaceuticals, Inc.  
777 Old Saw Mill River Road  
Tarrytown, NY 10591

Issue Date: 08/2019  
Initial U.S. Approval: 2011

Based on the August 2019  
EYLEA® (afibercept) Injection full  
Prescribing Information.  
EYL.20.09.0052

EYLEA is a registered trademark of Regeneron Pharmaceuticals, Inc.  
© 2020, Regeneron Pharmaceuticals, Inc.  
All rights reserved.

**Table 2: Most Common Adverse Reactions (≥1%) in RVO Studies**

Adverse Reactions	CRVO		BRVO	
	EYLEA (N=218)	Control (N=142)	EYLEA (N=91)	Control (N=92)
Eye pain	13%	5%	4%	5%
Conjunctival hemorrhage	12%	11%	20%	4%
Intraocular pressure increased	8%	6%	2%	0%
Corneal epithelium defect	5%	4%	2%	0%
Vitreous floaters	5%	1%	1%	0%
Ocular hyperemia	5%	3%	2%	2%
Foreign body sensation in eyes	3%	5%	3%	0%
Vitreous detachment	3%	4%	2%	0%
Lacrimation increased	3%	4%	3%	0%
Injection site pain	3%	1%	1%	0%
Vision blurred	1%	<1%	1%	1%
Intraocular inflammation	1%	1%	0%	0%
Cataract	<1%	1%	5%	0%
Eyelid edema	<1%	1%	1%	0%

Less common adverse reactions reported in <1% of the patients treated with EYLEA in the CRVO studies were corneal edema, retinal tear, hypersensitivity, and endophthalmitis.

**Diabetic Macular Edema (DME) and Diabetic Retinopathy (DR).** The data described below reflect exposure to EYLEA in 578 patients with DME treated with the 2-mg dose in 2 double-masked, controlled clinical studies (VIVID and VISTA) from baseline to week 52 and from baseline to week 100.

**Table 3: Most Common Adverse Reactions (≥1%) in DME Studies**

Adverse Reactions	Baseline to Week 52		Baseline to Week 100	
	EYLEA (N=578)	Control (N=287)	EYLEA (N=578)	Control (N=287)
Conjunctival hemorrhage	28%	17%	31%	21%
Eye pain	9%	6%	11%	9%
Cataract	8%	9%	19%	17%
Vitreous floaters	6%	3%	8%	6%
Corneal epithelium defect	5%	3%	7%	5%
Intraocular pressure increased	5%	3%	9%	5%
Ocular hyperemia	5%	6%	5%	6%
Vitreous detachment	3%	3%	8%	6%
Foreign body sensation in eyes	3%	3%	3%	3%
Lacrimation increased	3%	2%	4%	2%
Vision blurred	2%	2%	3%	4%
Intraocular inflammation	2%	<1%	3%	1%
Injection site pain	2%	<1%	2%	<1%
Eyelid edema	<1%	1%	2%	1%

Less common adverse reactions reported in <1% of the patients treated with EYLEA were hypersensitivity, retinal detachment, retinal tear, corneal edema, and injection site hemorrhage.

Safety data observed in 269 patients with nonproliferative diabetic retinopathy (NPDR) through week 52 in the PANORAMA trial were consistent with those seen in the phase 3 VIVID and VISTA trials (see Table 3 above).

##### 6.2 Immunogenicity

As with all therapeutic proteins, there is a potential for an immune response in patients treated with EYLEA. The immunogenicity of EYLEA was evaluated in serum samples. The immunogenicity data reflect the percentage of patients whose test results were considered positive for antibodies to EYLEA in immunoassays. The detection of an immune response is highly dependent on the sensitivity and specificity of the assays used, sample handling, timing of sample collection, concomitant medications, and underlying disease. For these reasons, comparison of the incidence of antibodies to EYLEA with the incidence of antibodies to other products may be misleading.

In the wet AMD, RVO, and DME studies, the pre-treatment incidence of immunoreactivity to EYLEA was approximately 1% to 3% across treatment groups. After dosing with EYLEA for 24-100 weeks, antibodies to EYLEA were detected in a similar percentage range of patients. There were no differences in efficacy or safety between patients with or without immunoreactivity.

#### 8 USE IN SPECIFIC POPULATIONS

##### 8.1 Pregnancy

###### Risk Summary

Adequate and well-controlled studies with EYLEA have not been conducted in pregnant women. Afibercept produced adverse embryofetal effects in rabbits, including external, visceral, and skeletal malformations. A fetal No Observed Adverse Effect Level (NOAEL) was not identified. At the lowest dose shown to produce adverse embryofetal effects, systemic exposures (based on AUC for free afibercept) were approximately 6 times higher than AUC values observed in humans after a single intravitreal treatment at the recommended clinical dose [see *Animal Data*].

Animal reproduction studies are not always predictive of human response, and it is not known whether EYLEA can cause fetal harm when administered to a pregnant woman. Based on the anti-VEGF mechanism of action for afibercept, treatment with EYLEA may pose a risk to human embryofetal development. EYLEA should be used during pregnancy only if the potential benefit justifies the potential risk to the fetus.

All pregnancies have a background risk of birth defect, loss, or other adverse outcomes. The background risk of major birth defects and miscarriage for the indicated population is unknown. In the U.S. general population, the estimated background risk of major birth defects and miscarriage in clinically recognized pregnancies is 2-4% and 15-20%, respectively.

##### Data

###### Animal Data

In two embryofetal development studies, afibercept produced adverse embryofetal effects when administered every three days during organogenesis to pregnant rabbits at intravenous doses ≥3 mg per kg, or every six days during organogenesis at subcutaneous doses ≥0.1 mg per kg.

Adverse embryofetal effects included increased incidences of postimplantation loss and fetal malformations, including anasarca, umbilical hernia, diaphragmatic hernia, gastroschisis, cleft palate, ectrodactyly, intestinal atresia, spina bifida, encephalomenocele, heart and major vessel defects, and skeletal malformations (fused vertebrae, sternbrae, and ribs; supernumerary vertebral arches and ribs; and incomplete ossification). The maternal No Observed Adverse Effect Level (NOAEL) in these studies was 3 mg per kg. Afibercept produced fetal malformations at all doses assessed in rabbits and the fetal NOAEL was not identified. At the lowest dose shown to produce adverse embryofetal effects in rabbits (0.1 mg per kg), systemic exposure (AUC) of free afibercept was approximately 6 times higher than systemic exposure (AUC) observed in humans after a single intravitreal dose of 2 mg.

##### 8.2 Lactation

###### Risk Summary

There is no information regarding the presence of afibercept in human milk, the effects of the drug on the breastfed infant, or the effects of the drug on milk production/excretion. Because many drugs are excreted in human milk, and because the potential for absorption and harm to infant growth and development exists, EYLEA is not recommended during breastfeeding. The developmental and health benefits of breastfeeding should be considered along with the mother's clinical need for EYLEA and any potential adverse effects on the breastfed child from EYLEA.

##### 8.3 Females and Males of Reproductive Potential

###### Contraception

Females of reproductive potential are advised to use effective contraception prior to the initial dose, during treatment, and for at least 3 months after the last intravitreal injection of EYLEA.

###### Infertility

There are no data regarding the effects of EYLEA on human fertility. Afibercept adversely affected female and male reproductive systems in cynomolgus monkeys when administered by intravenous injection at a dose approximately 1500 times higher than the systemic level observed with humans with an intravitreal dose of 2 mg. A No Observed Adverse Effect Level (NOAEL) was not identified. These findings were reversible within 20 weeks after cessation of treatment.

##### 8.4 Pediatric Use

The safety and effectiveness of EYLEA in pediatric patients have not been established.

##### 8.5 Geriatric Use

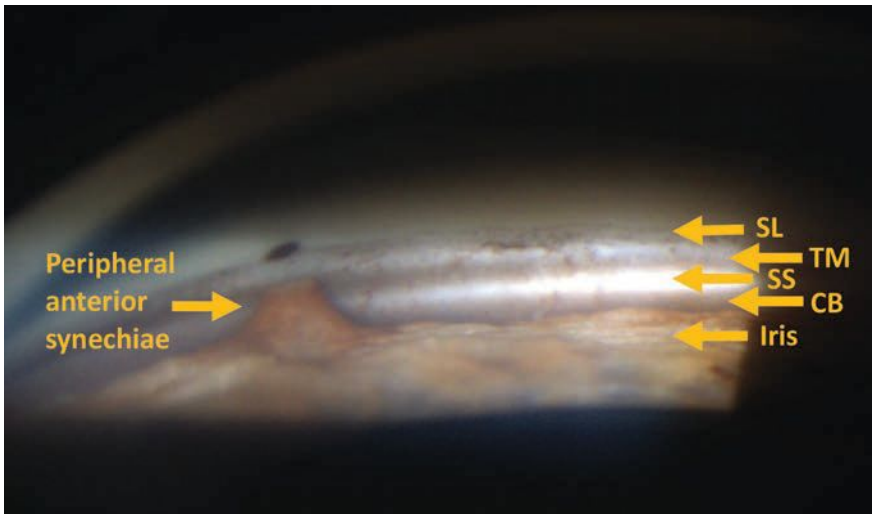
In the clinical studies, approximately 76% (2049/2701) of patients randomized to treatment with EYLEA were ≥65 years of age and approximately 46% (1250/2701) were ≥75 years of age. No significant differences in efficacy or safety were seen with increasing age in these studies.

#### 17 PATIENT COUNSELING INFORMATION

In the days following EYLEA administration, patients are at risk of developing endophthalmitis or retinal detachment. If the eye becomes red, sensitive to light, painful, or develops a change in vision, advise patients to seek immediate care from an ophthalmologist [see *Warnings and Precautions* (5.1)]. Patients may experience temporary visual disturbances after an intravitreal injection with EYLEA and the associated eye examinations [see *Adverse Reactions* (6)]. Advise patients not to drive or use machinery until visual function has recovered sufficiently.



**Properly positioning the patient is key for successful application and assessment. Ensure the patient is centered, lateral canthus aligned and their chin and forehead are always firmly pressed against the slit lamp.**



**Gonioscopy reveals peripheral anterior synechia.**

viewing the opposite quadrant, so the angle mirror to begin with will be the superior mirror. The inferior angle is often open the widest and has the most pigment. This will allow you the best opportunity to become orientated and identify the structures visible. For the inferior and superior angles, the beam should be a narrow vertical beam, and the beam should be switched to horizontal when assessing the nasal and temporal quadrants.

To remove a flanged lens, have the patient look nasally and squeeze their lids to loosen the suction between the cornea and gonioscopy lens. Be cau-

tious to not pull the lens away swiftly, as this can increase the risk of corneal irritation or abrasions, particularly in patients with epithelial basement membrane corneal dystrophy.

### **Anatomy: Angle Structures**

Once the gonioscopy lens is on the cornea, the next step is to assess what you see in your views. The key is to know what normal angular anatomy looks like; that way clinicians know when they are viewing a narrow angle or an angle with pathology. The first step is to identify the iris, the largest and most posterior portion of the

angle. After the iris root the order of structures is as follows (posterior to anterior): ciliary body (CB), scleral spur (SS), pigmented trabecular meshwork (TM), non-pigmented anterior TM and Schwalbe's line (SL).

The CB is made up of the ciliary muscle and the ciliary epithelium. The ciliary epithelium is responsible for production of the aqueous humor which is secreted into the posterior chamber of the globe. The ciliary muscle is responsible for controlling the zonular fibers, which adjust the lens for accommodation needs.

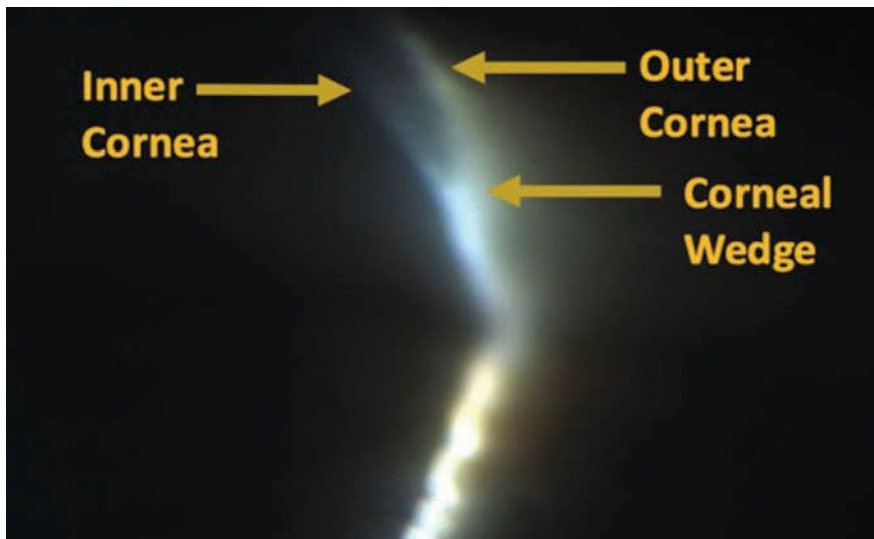
It is often the easiest to identify the SS, a thin pale line, which can yellow with age, between the ciliary body and pigmented TM. It is the site of attachment for the longitudinal muscle of the CB (pulls on the spur and opens the TM). If the clinician identifies the SS, they know it is a wide-open anterior chamber. This is easier to note in patients with darker irises, as the pigment helps delineate the anatomical bands.

The TM is responsible for draining 60% to 95% of the aqueous humor.<sup>1,6</sup> The anterior meshwork is usually non-pigmented, while the posterior meshwork becomes more pigmented over time (more flow through the posterior TM).

Thus, in patients with light irises, viewing and identifying these structures can be increasingly difficult as the lack of pigment can make it seem as though all the structures look the same; conversely, heavy pigmented angles can also be difficult to distinguish. This is where the corneal wedge technique can help orient you within the angle.

The corneal wedge technique allows for detection of the anterior edge of the TM by highlighting the SL, the most anterior structure of the angle. Set up the slit lamp to have a thin beam. With the oculars centered, adjust the light beam 15° to 20° off-center. This movement will form two beams of light: a brighter beam that follows the iris through the angle and onto the internal corneal surface, and the second





Slit lamp image of a corneal wedge through gonioscopy helps identify the anterior most portion of the angle.

broader and fuzzier beam that follows the external corneal surface as it meets the sclera. The apex of where the two beams meet is at the SL.

Being able to detect the most anterior surface can then allow the clinician to assess the more posterior angle structures confidently. In addition to evaluating how open the angle is, the clinician also needs to view and judge the configuration of the iris. The iris itself can be configured as flat, concave or convex.<sup>1,6</sup>

## Grading

There are three common gonioscopy grading systems used to document what is seen clinically. Comparing these are important to assess changes over time. If the clinician chooses not to use one of these grading systems, they must record, at minimum, the posterior structure seen, amount of angle pigmentation and iris configuration.

It is imperative that you document which grading system you are using when recording gonioscopy angles serially in patients' charts, as each grading system has a different terminology of angle structures seen.

**Shaffer system.** This asks how *open* is the angle? It estimates the angle between the iris and TM. A larger number notes a wide-open angle:

- 4=45° to 35°
- 3=35° to 20°
- 2=20°
- 1=≤10°
- Slit
- 0=closed

**Spaeth system.** This describes four aspects of the anatomy of the angle.

1. Level of iris insertion
  - A=anterior to SL
  - B=SL to SS (in area of TM)
  - C=posterior to scleral spur
  - D=deep into CB face (visible band of anterior CB)
  - E=extremely deep (wide band of CB visible)
2. Width of angle
  - Angle made by line tangential to iris and line tangential to face of the TM
  - 0° to 40°
3. Configuration of iris
  - s=steep or convex
  - r=regular or flat
  - q=queer or concave
4. Angle pigmentation; graded on a zero to four scale

**Scheie system.** In contrast to the Shaffer and Spaeth grading scaled, the Scheie grades in a way that looks at how *closed* the angle appears. It uses Roman numerals to describe the degree of angle closure and pigmentation. The larger number notes a narrower angle or heavier pigmentation.<sup>1</sup>

- 0=entire angle visible with wide ciliary body band
- I=iris obscures part of CB
- II=nothing posterior to TM visible
- III=posterior TM not visible
- IV=no structures posterior to SL visible

Angle pigmentation is graded from 0 (no pigmentation) to IV (heavy pigmentation).

## Keep Practicing

The key to mastering gonioscopy is multilayered but easily achievable. Remember that primary open angle glaucoma cannot be diagnosed without angle assessment. Far too often patients are misdiagnosed as open angle when they are on the angle-closure spectrum. Performing gonioscopy will identify if the patient must be referred for a laser procedure to assist in increasing the depth of the anterior chamber.

The first step, and often the scariest, is properly and confidently applying the lens. This is the step that often needs the most practice before it becomes second nature. The more you do it, the easier it will become and the more accurate you will be at distinguishing a normal vs. pathological angle.

Not having these skills can be costly to your practice. By not performing gonioscopy, you are losing billable procedures for your office, and if you repeatedly must refer out these patients for a simple gonioscopy procedure, you could lose them to another provider for good. ■

1. Hertzog LH, Albrecht KG, LaBree L, Lee PP. Glaucoma care and conformance with preferred practice patterns. examination of the private, community-based ophthalmologist. *Ophthalmology*. 1996;103(7):1009-13.

2. Dada T, Sharma R, Sobti A. *Gonioscopy: a text and atlas (with goniovideos)*. Jaypee Brothers Medical Pub; 2013.

3. Kim JM, Park KH, Han SY, et al. Changes in intraocular pressure after pharmacologic pupil dilation. *BMC Ophthalmol*. 2012;12:53.

4. Thomas R, George T, Braganza A, Muliylil J. The flashlight test and van Herick's test are poor predictors for occludable angles. *Aust N Z J Ophthalmol*. 1996;24(3):251-6.

5. Radhakrishnan S. Diagnosing angle closure: gonioscopy vs. OCT. *Rev Ophthalmol*. 2019;25(4):60-4.

6. Johnson TV, Ramulu PY, Quigley HA, Singman EL. Low sensitivity of the Van Herick method for detecting gonioscopic angle closure independent of observer expertise. *Am J Ophthalmol*. 2018;195:63-71.



Introducing REMLens<sup>®</sup>,  
**Rapid Eye Molding**, that  
changes sight, overnight.

Discover how REMLens<sup>®</sup>  
can benefit your patients,  
and your practice.

**GUIDANCE**  
from NCLE certified experts

X-Cel Specialty Contacts has been committed to the management of myopia for nearly two decades. The introduction of REMLens<sup>®</sup> is another step forward in our dedication to the myopia management category. With REMLens<sup>®</sup>, you can expect:

- **Consultation from NCLE certified experts to guide you through the entire fitting process**
- 89% First fit success rate\*
- Dynamic Edge Profile™ delivers remarkable comfort
- Simplified lens design, and ease of ordering
- Online lens design calculator
- Highly adjustable parameters
- Multiple diameter and optic zone options
- Worry-free refit policy
- Practice management tools
- 24-hour turnaround time
- Competitive pricing
- Hassle-free, no return warranty

Vision Shaping  
Treatment VST<sup>®</sup>



800.241.9312 | [xelspecialtycontacts.com/remlens](https://xelspecialtycontacts.com/remlens)

# ELEVATE YOUR DRY EYE PRACTICE

Let's break down every diagnostic test tier by tier to help you decide which ones are best for your patients.



BY LINDSAY SICKS, OD  
CHICAGO, IL

Have you ever had “analysis paralysis”—that feeling of having too many choices and not knowing which to choose? I have that feeling every time I stop for ice cream at my local shop with over 75 flavors. I also feel that way about the number of diagnostic tests we have available for dry eye. Are there too many? Do I need to perform them all? Which results are going to give me the most salient information to manage each patient's condition? Depending on your practice, you may have many or only a few diagnostic tests and tools available. Sometimes you're not limited by availability but rather by chair time. You may limit yourself to just one or two dry eye tests per visit and think that's all you need.

Here, we help you sort and tier your dry eye diagnostic tests in order to best position them for your specific practice and patient.

What are our “workhorse tests” that can and should be done on every potential dry eye patient to help you make a diagnosis? I label those *Tier 1*.

What are additional procedures that can elevate your dry eye practice and increase the specificity of your diagnosis and management, but which may not be available to or convenient for everyone (Tier 2)? Finally, what are some high-tech tests being done in some of the country's most high-touch dry eye practices today (Tier 3)?

The aim with Tier 1 tests in my mind is multifactorial; in theory, these are tests that are easy to perform, low-cost or free to use and available to most practitioners without upfront investment in much equipment.

Tier 2 tests may require more investment and skill to perform but they can help refine diagnosis and improve treatment.

Tier 3 tests are high-touch diagnostics that require an initial outlay of major capital or may only be used in the management of severe/advanced dry eye.

The current Tear Film and Ocular Surface (TFOS) Dry Eye Workshop (DEWS) II definition of dry eye, released in 2017, describes the presence of ocular surface symptoms and signs of dry eye. A dual strategy of quantifying symptoms paired with

strategic use of diagnostic, point-of-care testing, can help better determine the etiology of your patient's symptoms. This approach can shape your diagnostic testing selections or highlight additional treatment options at follow-up visits. For example, the TFOS DEWS II report distinguishes between aqueous-deficient and evaporative types of dry eye and each type may necessitate varying management strategies.<sup>1</sup>

It is also important to remember that these diagnostic tests can affect the results of one another if performed in sequence. Though many are noninvasive in nature, they still involve alterations in blinking patterns or bright illumination, which can affect results. As such, it is recommended that any dry eye diagnostic test be performed in a sequence from least to most invasive.<sup>1,2</sup>

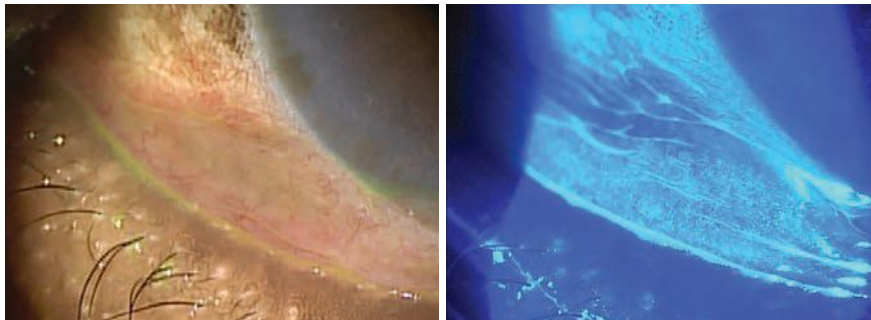
## Tier 1: Workhorse Tests For Everyone

These are the first set of tests that should be available in every practice. They are easy to perform, relatively low-cost and should be conducted on all patients showing dry eye symptoms.

### About the author

Dr. Sicks is an associate professor at ICO and a clinical attending in the Cornea Center for Clinical Excellence at the Illinois Eye Institute. She lectures and conducts research on specialty contact lenses.





**A 72-year-old female patient with severe conjunctivochalasis and recalcitrant ocular surface disease. She was eventually referred for conjunctival resection.**

## SYMPTOM SURVEYS

When considering any diagnosis of dry eye, start with symptoms. We generally think of case history as the best place to discuss symptoms; however, patient responses can be variable and inaccurate at times, especially if clinicians do not ask clear, pointed questions. Validated surveys are one key to clinching the initial diagnosis when patients present with one or more symptoms consistent with dry eye. The surveys can be repeated over time and there are several designs to fit your patient's needs.

The DEWS II Diagnostic Methodology report recommends performing diagnostic testing if the screening Dry Eye Questionnaire (DEQ-5) or the Ocular Surface Disease Index (OSDI) confirms that a patient might have dry eye disease. OSDI is the most widely used survey in clinical trials and the standard by which other questionnaires are judged.<sup>3</sup> OSDI measures frequency of symptoms, environmental triggers and vision-related quality of life. The screening cut-off is an OSDI score of  $\geq 13$ ; further, the scoring is categorized as mild (13 to 22 points), moderate (23 to 32 points) and severe ( $\geq 33$  points). The average healthy population's mean OSDI score is 9.6.<sup>3</sup>

If you're looking for a streamlined survey, you may opt for the DEQ-5 (or for contact lens wearers, the CLDEQ-8).<sup>4,5</sup> The DEQ-5 is short and easy to administer. It discriminates well between patients with and without dry eye, as well as between

dry eye patients with and without Sjögren's syndrome (SS).<sup>6</sup> In general, DEQ-5 scores  $>6$  suggest dry eye and scores  $>12$  may indicate further testing is necessary to rule out SS dry eye.

One other popular survey option is the Standard Patient Evaluation of Eye Dryness (SPEED) test.<sup>7</sup> The SPEED survey appears to be of superior value in evaporative dry eye.<sup>8</sup> In general, patients with no symptoms score zero on SPEED. Those scoring 1 to 9 are categorized as mild to moderate and those scoring  $\geq 10$  are categorized as severe.<sup>9</sup>

Since symptom surveys can vary in design and target audience, you may wish to do more research before deciding which is the best fit for your patient base. Repeating the survey at each visit can assess improvement—or lack thereof—in symptoms over time as therapy is initiated, continued or discontinued.

While symptom surveys can assist practitioners in identifying patient symptoms, relying solely on this approach can exclude a large number of patients, as signs and symptoms are often uncorrelated.<sup>1</sup> We must include other diagnostic tests in conjunction with symptom surveys to increase our ability to diagnose a condition as ubiquitous as dry eye.

## TEAR FILM STABILITY


According to the definition and classification subcommittee of TFOS DEWS II, "tear film instability" is part of the revised definition of dry eye.<sup>10</sup> Many ways of assessing tear

film stability have been described, including tear break-up time (TBUT) using fluorescein or noninvasive measures, thermography, variability in tear osmolarity and tear evaporation rate. It should be noted that thermography and tear evaporation rate are not well-established clinical techniques. Each test of tear film stability also requires meticulous performance and attention to exogenous factors, such as humidity or temperature, which may affect results. Overall, tear film stability testing is highly variable in outcomes.<sup>1</sup> Any tear film stability test should be performed prior to other invasive tests, such as eyelid manipulation or staining of the ocular surface.<sup>1</sup>

TBUT is probably the most familiar and widely used test to evaluate tear film stability in clinical practice. Given the inherent variability of the measurement, three measurements are often averaged.

One common method for TBUT assessment involves the application of sodium fluorescein (NaFl) using a dye-impregnated strip. The clinician should wet the NaFl strip with a drop of saline, taking care not to touch the bottle tip to the strip. The excess saline is flicked off of the strip and the strip is laid flat on the temporal bulbar conjunctiva. It is recommended to wait between one and three minutes before evaluation to allow the NaFl to equilibrate with the tear film. Before assessment, the patient is instructed to blink naturally three times and then refrain from blinking. The clinician can begin timing until the first dark spots (or break-up) are detected in the tear film. A break-up time of  $\leq 10$  seconds indicates tear film instability and  $\leq 5$  seconds more definitively suggests a diagnosis of dry eye.<sup>1</sup>

It should be noted that within the DEWS II Diagnostic Methodology Report, a noninvasive measure of tear break-up time (NITBUT) is preferred over the standard fluorescein-tear breakup time described above.<sup>1</sup> Interestingly, results for the two techniques are well correlated, but



**A cobalt blue filter can highlight more subtle areas of staining, as in this patient who presented with foreign body sensation.**

subjective aspects of FTBUT make it difficult to repeat among clinicians. Best practices for NITBUT include implementation of videokeratography for automated measurement, along with repeating the measurement three times to determine an average result. The instrumentation needed to perform NITBUT is not available in every office and thus, automated NITBUT may be relegated to Tier 3 testing in such scenarios. See also the discussions of Schirmer and phenol red thread testing below.

### OCULAR SURFACE STAINING


The TFOS DEWS II definition of dry eye implies that dry eye can occur without ocular surface damage. However, ocular surface staining is still often a hallmark inclusion criterion for dry eye studies and instilled dyes are employed extensively in the diagnosis and management of dry eye. This testing can be repeated at each follow-up visit to gauge improvement across the cornea, conjunctiva and lid margin. The distribution of punctate staining across the cornea may also provide etiological clues to astute clinicians to help identify conditions such as lagophthalmos or meibomian gland dysfunction.

Three frequently used ophthalmic dyes are NaFl, lissamine green (LG) and rose bengal. The latter has been shown to sting upon instillation,

induce reflex tearing and be toxic to human corneal epithelial cells. Thus, it is recommended to use lissamine green, which is less toxic but just as well tolerated as NaFl.<sup>1</sup>

Best practices for use of these ophthalmic dyes include proper instillation (typically temporal to avoid confounding damage to the conjunctiva and lid margins), use of sequential staining with more than one paper strip to increase the likelihood of observing ocular surface damage and proper recording of results in order to monitor changes over time.<sup>1</sup>

When assessing corneal surface staining, many scales are available including the van Bijsterveld Score (whole corneal staining intensity graded on a scale of 0 to 3; added to conjunctival staining score), NEI Workshop Guidelines (dividing the cornea into five sectors, scoring each on a scale of 1 to 3), Oxford Staining Score (a 0 to V grade, depending on



**Three commonly used vital dyes are rose bengal, NaFl and LG.**

the intensity of staining displayed) and the Ocular Staining Score, which quantifies corneal staining “dots” graded on a scale of 0 to 3:<sup>1,11</sup>

- grade 0: 0 dots
- grade 1: 1 to 5 dots
- grade 2: 6 to 30 dots
- grade 3: >30 dots

Using clinical grading scales can improve the repeatability of corneal and bulbar conjunctival assessment.

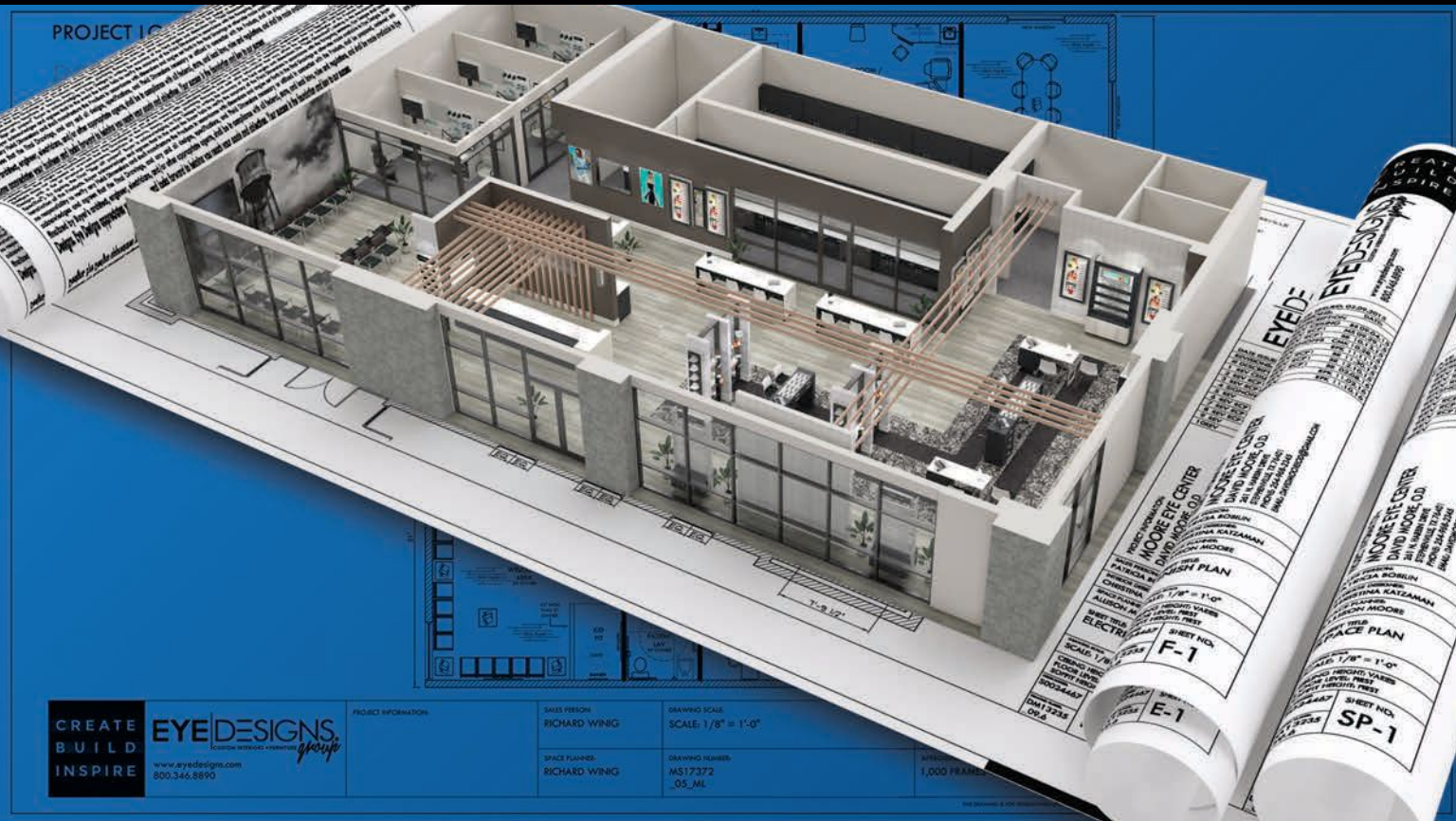
### BULBAR REDNESS ASSESSMENT

Conjunctival injection is the most common clinical sign suggesting ocular surface inflammation. Most likely, you are already completing this straightforward assessment during a routine slit lamp evaluation on each patient. Signs of ocular surface inflammation include a bulbar redness score of grade 2 or more (normal=grade 1 or less). Of course, other etiologies for bulbar redness should be ruled out, such as allergic conjunctivitis or infection, prior to determining the inflammation could be related to dry eye. Any degree of conjunctivochalasis should also be assessed at this time, as that can be a contributing factor to dry eye symptoms.

Similar to NITBUT, there are automated measures of bulbar redness which can be obtained using a videokeratograph, which would land it in the Tier 3 category, as these are usually in the same unit as a meibograph. Such objective measurements are more repeatable and reliable than subjective grading, especially when performed by multiple observers.<sup>12</sup> Bulbar redness assessment should be repeated at each visit and assessed prior to any ocular surface staining, drop instillation or other invasive tests.

### BLINK AND LID CLOSURE ANALYSIS

To assess lid closure, have your patient semi-reclined and place a transilluminator against their relaxed, closed, outer upper eyelids. The amount of light seen in the lid area between the lashes in the nasal, central and temporal sections of eyelids



CREATE  
BUILD  
INSPIRE

**EYEDESIGNS**  
group

www.eyedesigns.com  
800.346.8890

PROJECT INFORMATION

SALES PERSON  
RICHARD WING

DRAWING SCALE  
SCALE: 1/8" = 1'-0"

SPACE PLANNER  
RICHARD WING

DRAWING NUMBER  
MS17372  
03\_ML

# Space Planning, Design & Manufacturing.

Ophthalmic Space Planning, Interior Design, Optical Furniture, Exam Consoles & So Much More!

**REQUEST OUR  
NEW CATALOG!**



**See you at HOAECC Booth 312  
and SECO Booth 1453**

**EYEDESIGNS**  
CUSTOM INTERIORS + FURNITURE group

www.eyedesigns.com  
800-346-8890



can be quantified on a scale of 0 to 3:

- 0=no light
- 1=minimal
- 2=moderate
- 3=severe

Any score greater than zero suggests some level of insufficient lid seal, which correlates to dry eye symptoms upon waking.<sup>13</sup>

The insufficient seal identified by Korb-Blackie testing differs somewhat from the more obvious nocturnal lagophthalmos, where the patient has visible incomplete closure of the eyelids while asleep. It can be useful to ask patients if they have ever been told they sleep with their eyes open to determine whether nocturnal lagophthalmos is present. This feature, in addition to inferior interpalpebral conjunctival staining (exposure keratopathy) and lid laxity upon gentle closure, can help clinch the diagnosis.

Blink characteristics may also play a role in dry eye symptoms. With the increase in digital device use, blink rates are reduced, which can exacerbate symptoms. One simple test to determine a reduced blink rate is to watch the patient use a digital device for 15 seconds, counting the number of blinks. Once 15 seconds have passed, multiply your result by four to get the blink rate per minute. If it is less than 12 to 15 blinks per minute, your patient may benefit from blink training to increase their blink rate. This simple test can help bring attention to a patient's lack of blinking, which, in turn, affects their tear film stability.

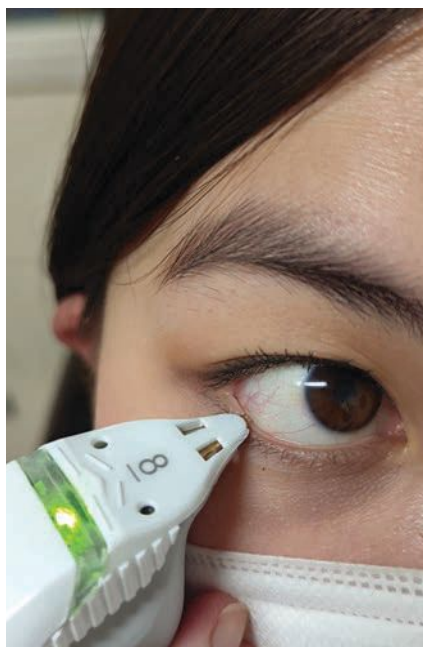
### LID MARGIN/MEIBOMIAN GLAND EVALUATION

In conjunction with the discussion of ocular surface staining using vital dyes above, staining of the lid margin and lid wiper with NaFl and LG can also give information regarding dry eye and ocular surface damage during a slit lamp evaluation. The presence of lid wiper epitheliopathy (LWE) may be associated with dry eye symptoms and is measured by repeat instillation of LG. An LG strip is wet, with

the drop retained for five seconds to elute the dye. A drop from the strip is instilled in the temporal conjunctiva. This is repeated after about five minutes with a second strip and the staining is evaluated with white light in the slit lamp three to six minutes later. LWE is considered present if there is more than 2mm (in length) of staining after instillation of LG or if the staining exceeds 25% of the sagittal width (excluding Marx's line).<sup>1</sup>

Diagnostic meibomian gland evaluation and expression can be employed in the course of a slit lamp evaluation using either a thumb, cotton swab or a device that applies a standardized pressure to the lid margin, such as the Meibomian Gland Evaluator (Johnson & Johnson Vision). Using such a device, one can apply pressure—equal to that of a blink—to the outer skin of the eyelid while visualizing the secretions from the meibomian gland (MG) orifices. The device is applied to the nasal, central and temporal lid, applying pressure to approximately eight glands at a time.

The number of MGs out of eight



**This patient was tested using a tear osmolarity system and the result showed elevated osmolarity level of 312 mOsm/L. It is important not to manipulate the lid while taking the sample.**

yielding liquid secretion is the “meibomian gland yielding liquid secretion” score.<sup>14</sup> The quality of the meibum expressed is assessed on a scale ranging from zero to three; zero is no expression, one is paste-like expression, two is turbid expression and three is normal expression of clear, thin, oil-like meibum. This diagnostic MG function evaluation can be repeated at each visit to gauge change over time from evaporative dry eye.

These diagnostic MG expression procedures contrast with the therapeutic expression procedures that are often used in treatment of MG dysfunction. The therapeutic procedures may involve eyelid warming followed by gland expression with the application of specialized forceps or paddles, or use of a dedicated therapeutic system that applies heat and pressure to the lids simultaneously. In these therapeutic expression procedures, the pressure applied to the lids exceeds that of the diagnostic expression.

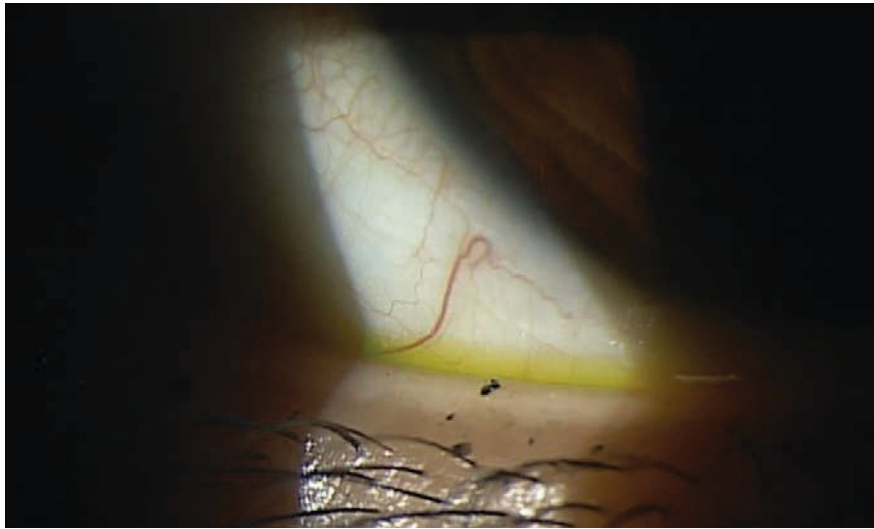
### Tier 2: Ancillary Testing For Refinement/Precision

Although these require an investment, they take your dry eye practice to the next level by refining diagnosis and improving treatment.

### SCHIRMER TESTING

This has been in use to assess aqueous tear volume since the early 1900s.<sup>15</sup> The most commonly used version for dry eye is Schirmer I, which measures both basal and reflex tear production. No anesthetic is used, and a Schirmer paper strip is placed on the lower eyelid margin for a duration of five minutes. Any value <10mm of wetting is considered abnormal. Some parties do not recommend Schirmer testing in the diagnosis of dry eye due to its variability and lack of accuracy; however, it is still recommended for the diagnosis of SS (where <5mm wetting is generally considered suspicious).<sup>15</sup>

An alternative to Schirmer testing is phenol red thread testing (PRTT),



**This patient's tear meniscus is highlighted by the addition of NaFl. A cobalt blue filter can also assist with visualization. This patient has an adequate tear meniscus, but their ocular surface symptoms are exacerbated by makeup debris and systemic medications.**

which is generally more comfortable for patients and faster to perform in only 15 seconds. The small yellow-colored thread changes to light-red in color once exposed to tears, and no topical anesthetic is necessary. The cut-off is also 10mm of wetting, with less wetting indicating likely dry eye. However, studies have suggested mixed results in terms of validity when comparing Schirmer testing with PRTT.<sup>16-18</sup>

### TEAR OSMOLARITY

Though this test is found in Tier 2, tear osmolality measurements should be performed after symptom survey and NITBUT testing but before ocular surface staining and other more invasive procedures. In a clinical setting, objective and quantitative measurement of tear osmolality is easily obtained using a point-of-care test (TearLab). The measurements should always be taken with a calibrated device that has been at room temperature for at least 30 minutes prior to testing.

While gathering the sample, care should be taken not to pull the eyelid down or away from the globe. The test card tip should make contact with the lower tear meniscus at the lid margin. A positive result is consid-

ered to be >308 mOsm/L but can also occur with an interocular difference of >8 mOsm/L.<sup>19,20</sup> Testing can be repeated as often as every dry eye-related visit, but may only need to be performed annually if the patient is stable.

### MMP-9 TESTING

Matrix metalloproteinase-9 (MMP-9) testing is now easily available in a point-of-care device that can assay levels in just ten minutes (InflammaDry, Quidel) and thus joins tear osmolality in Tier 2. The test is non-specific to the source of ocular inflammation and produces an easy-to-read positive (levels above 40ng/mL) or negative (levels below 40ng/mL) result. Similar to tear osmolality, MMP-9 testing can be repeated as often as every dry eye-related visit but may only need to be performed annually if the patient is stable. It can also be used to help guide steroid therapy, which should reduce MMP-9 levels in tears.

### TEAR MENISCUS HEIGHT (TMH) ASSESSMENT

This measurement is a generally accepted method to assess tear film volume. It can be performed using several methods, including with the aid of digital imaging or instrumenta-



**The 0.2mm spot size on your slit lamp can be used to help estimate TMH.**

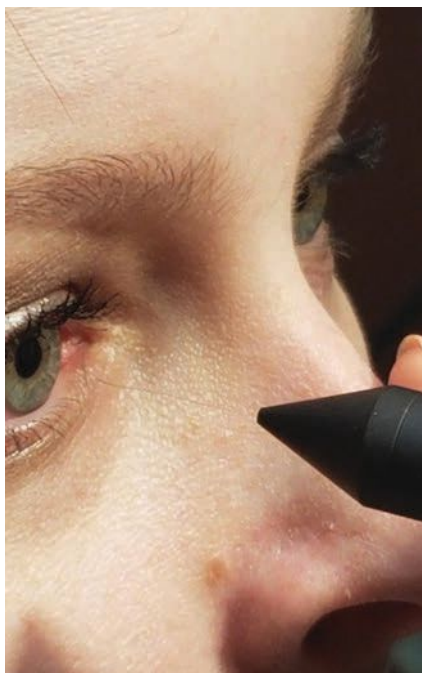tion. In the slit lamp, the TMH can be assessed by comparing its thickness to the lower lid margin or to a known size of slit beam. However, studies have shown greater repeatability using optical coherence technology (OCT) to image the TMH, which potentially places this automated method into Tier 3.<sup>21</sup>

Overall, it is suggested that TMH is a powerful predictor of tear film insufficiency.<sup>15,22</sup> Average values for TMH vary somewhat in the literature, from 0.2 to 0.7mm, with a lower cut-off for normal considered to be  $\leq 0.1$ mm.<sup>23</sup>

### CORNEAL SENSITIVITY TESTING

With the commercial availability of cenegenmin-bkbj ophthalmic solution (Oxervate), a recombinant human nerve growth factor for corneal healing in neurotrophic keratitis, corneal sensitivity testing has received more attention in recent years. Simple techniques for assessing corneal sensitivity have limited accuracy due to their subjective nature.

The simplest technique involves touching the cornea gently with a wisp of cotton from a swab (alternatively, one could use a 3cm length of unscented, waxed dental floss or the corner of a tissue) to initiate a blink response.<sup>24,25</sup> This low-cost approach



**Corneal sensitivity can be quantitatively measured using an esthesiometry instrument with a nylon filament.**

is quick and easy to perform but lacks the quantitative results that could be gained through use of a formal measuring device such as the Cochet-Bonnet esthesiometer.

Such a device quantifies corneal sensitivity using a fine nylon filament which just touches the corneal surface. The longer the filament, the more flexible it is, indicating that more corneal sensation is present.<sup>24</sup> Use of the Cochet-Bonnet may be more appropriately relegated to Tier 3 testing; however, the cotton swab approach is easily implemented by any clinician to rule out neurotrophic keratitis in patients with dry eye symptoms. It is recommended that corneal sensitivity be assessed in all four quadrants, along with the central cornea.

### Tier 3: High-Touch Expert-Level Testing

While costly, these cutting-edge tests are necessary for the most severe and advanced dry eye cases. Offering these elevates your dry eye practice to the highest level and can make your practice stand out in your area.

### MEIBOGRAPHY (MEIBOMIAN GLAND IMAGING)

While a basic form of meibography or meibomian gland imaging can be performed using a transilluminator on the everted lid, the technique has evolved to non-contact direct illumination of the glands using infrared illumination and computerized analysis of gland morphology.<sup>26,27</sup> The MGD Workshop proposed that patients 20 years and younger should have no MG dropout and those 20 years and older may have less than or equal to 25% dropout.<sup>14</sup>

### BLOOD WORK

Any eyecare practitioner can directly order or refer dry eye patients for bloodwork to rule out dry eye-related conditions such as rheumatoid arthritis, the seronegative spondylarthropathies and Sjögren's syndrome (SS). Specific to dry eye, we commonly order testing for these patients using a laboratory order form indicating the proper diagnosis code (most often, keratoconjunctivitis sicca not specified as SS) and tests to order.

The specific testing may differ depending on the patient but often includes classic SS biomarkers: SS-A/Ro, SS-B/La, antinuclear antibody and rheumatoid factor. Other novel biomarkers can also be ordered specifically in cases where SS is suspected, including autoantibodies to salivary gland protein-1, parotid secretory protein, and carbonic anhydrase VI. These novel biomarkers may allow for earlier diagnosis of SS.<sup>28</sup>

Sjö (Immco Diagnostics) is a diagnostic test kit for these novel biomarkers that became commercially available starting in 2014 but may currently be challenging to source. Thus, we have taken to ordering blood work with a request that the novel biomarkers also be tested in whatever way is preferred by the patient's receiving laboratory. Blood work can be performed initially and may not need repeating. However, if a patient is negative for the biomarkers of SS, their dry eye progresses and clinical

suspicion of SS remains high at a later date, it may be worth repeating the bloodwork to see if the values change.

### CONFOCAL IMAGING

*In vivo* confocal microscopy (IVCM) can be used to assess a variety of anterior segment structures involved in dry eye including the cornea, conjunctiva and meibomian glands. This instrument lands in Tier 3, as it is not seen in most individual offices but rather at larger academic medical centers and tertiary care facilities.

To assist in diagnosing dry eye, IVCM can confirm an increase in mean corneal dendritic cell (DC) density above normal values—an indicator for active immune response or inflammation in the cornea that has been reported in dry eye patients.<sup>29</sup> Aqueous-deficient dry eye patients have higher DC density when compared to evaporative dry eye patients, and aqueous deficient dry eye patients with related systemic immune disease showed higher DC density when compared with those dry eye patients with non-immune conditions.<sup>29,30</sup> Alterations in corneal nerve length and density are additional biomarkers that are predictive for dry eye.<sup>29</sup>

### INTERFEROMETRY

This sophisticated assessment of the tear film can be obtained via non-invasive imaging, the result of which assigns a predominant spectral color to the tear film lipid layer (TFLL) thickness. The reported thickness range of the normal TFLL is approximately 20µm to 160µm.<sup>14</sup> Thinning of the TFLL has been reported in cases of both aqueous-deficient and evaporative dry eye, and has been shown to improve after punctal occlusion surgery.<sup>14,31</sup> Varying tear interferometric patterns have been shown to identify differences in tear film kinetics among clinical subtypes of dry eye.<sup>32</sup>

### EPITHELIAL THICKNESS MAPPING

This OCT-derived measurement is currently only commercially available



thera  
tears®

EXTRA®



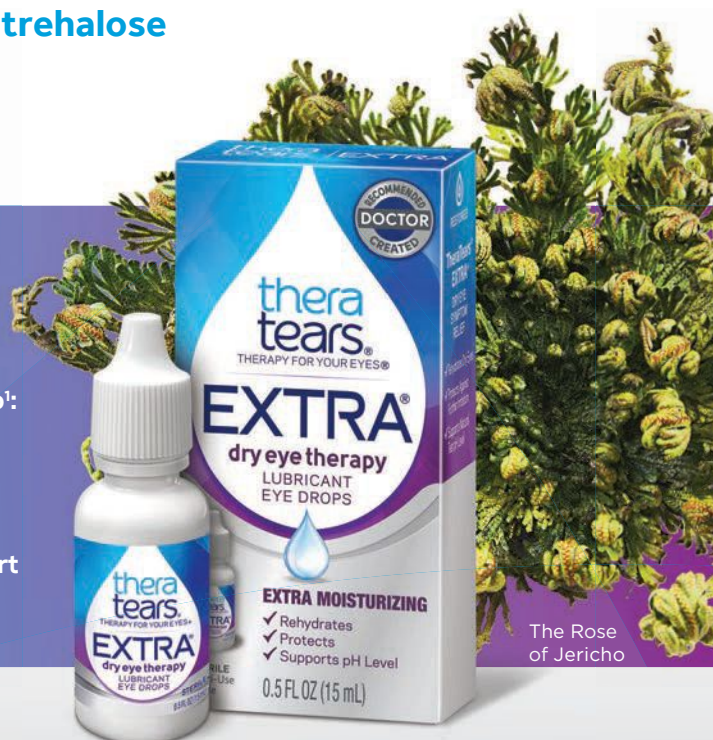# DRY EYE RELIEF INSPIRED BY NATURE

TheraTears® EXTRA® Dry Eye Therapy  
is enhanced with trehalose

Trehalose is a disaccharide that can be found in plants with moisture retention properties that help organisms survive in absence of water\*. In ophthalmic products, trehalose formulations can enhance active ingredients to help:

- Protect corneal cells from desiccation
- Restore osmotic balance to the ocular surface
- Maintain the homeostasis of corneal cells

-2017 DEWS II Report



The Rose of Jericho

Learn about our complete line of  
dry eye therapy products at [theratears.com](http://theratears.com)

\*TheraTears® EXTRA® contains synthetic trehalose.  
Reference: 1. Jones L, Downie L, Korb D, et al. TFOS Dews II Management and Therapy Report. The Ocular Surface Jul 2017; 575-628.  
© 2021 Prestige Consumer Healthcare | M17-047-01



**Tear osmolarity unit showing elevated osmolarity reading of 312 mOsm/L.**

on a few instruments from a single manufacturer in the United States (Optovue). The technology gives a non-contact, quantitative measurement of the corneal epithelium and stroma using ultra-high resolution anterior segment OCT. One study suggests superior thinning is characteristic of dry eye while another suggests central thickening. Overall, significant corneal epithelial irregularity is the hallmark finding.<sup>33-35</sup>

Other expert-level testing strategies for dry eye that are not currently in commercial use include impression cytology and tear ferning.

Impression cytology involves removing cells from the first to third most superficial layers of the conjunctival epithelium via application of cellulose acetate filters or biopore membranes. The cells are then analyzed by various methods, depending on the aim of the investigation, including microscopy, polymerase chain reaction and flow cytometry, among others.<sup>1</sup>

Tear ferning analysis involves drying tears on a glass plate to assess the crystallization (pattern of the tear fern) over a period of seven to ten minutes under normal room temperature and humidity.<sup>1</sup> Healthy tear samples produce compact, dense ferning patterns, while dry eye samples show a fragmented or absent tear

ferning pattern.<sup>36</sup> It is possible that one day these technologies will make their way into our clinical practice.

## Takeaways

No matter which way you choose to stratify the diagnostic tests, the most important piece of dry eye management is to use some number of diagnostic tests in your workup. Pick and choose a few to embrace and implement in your practice. Repeat them and use those results to inform your management strategies and educate your patients.

Over time, you may choose to implement more technologies that can improve your diagnostic capabilities and might even elevate you to “expert-level” territory. But even if you only have a slit lamp and your highly educated brain, you can still make a difference in the lives of patients with DED. ■

1. Wolffsohn JS, Arita R, Chalmers R, et al. TFOS DEWS II Diagnostic Methodology report. *Ocul Surf.* 2017;15(3):539-74.
2. Foulks GN. Challenges and pitfalls in clinical trials of treatments for dry eye. *Ocul Surf.* 2003;1(1):20-30.
3. Schiffman RM, Christianson MD, Jacobsen G, et al. Reliability and validity of the Ocular Surface Disease Index. *Arch Ophthalmol.* 2000;118(5):615-21.
4. Chalmers RL, Begley CG, Moody K, Hickson-Curran SB. Contact Lens Dry Eye Questionnaire-8 (CLDEQ-8) and opinion of contact lens performance. *Optom Vis Sci.* 2012;89(10):1435-42.
5. Chalmers RL, Keay L, Hickson-Curran SB, Gleason WJ. Cutoff score and responsiveness of the 8-item Contact Lens Dry Eye Questionnaire (CLDEQ-8) in a large daily disposable contact lens registry. *Cont Lens Anterior Eye.* 2016;39(5):342-52.
6. Chalmers RL, Begley CG, Caffery B. Validation of the 5-Item Dry Eye Questionnaire (DEQ-5): discrimination across self-assessed severity and aqueous tear deficient dry eye diagnoses. *Cont Lens Anterior Eye.* 2010;33(2):55-60.
7. Korb DR, Herman JP, Greiner JV, et al. Lid wiper epitheliopathy and dry eye symptoms. *Eye Contact Lens.* 2005;31(1):2-8.
8. Scaffidi RC, Korb DR, Greiner JV, Blackie CA. Lipid layer thickness and dry eye symptoms. *Invest Ophthalmol Vis Sci.* 2005;46(13):4444.
9. Blackie CA, Solomon JD, Scaffidi RC, et al. The relationship between dry eye symptoms and lipid layer thickness. *Cornea.* 2009;28(7):789-94.
10. Craig JP, Nichols KK, Akpek EK, et al. TFOS DEWS II Definition and Classification Report. *Ocul Surf.* 2017;15(3):276-83.
11. Begley C, Caffery B, Chalmers R, et al. Review and analysis of grading scales for ocular surface staining. *Ocul Surf.* 2019;17(2):208-20.
12. Sorbara L, Simpson T, Duench S, et al. Comparison of an objective method of measuring bulbar redness to the use of traditional grading scales. *Cont Lens Anterior Eye.* 2007;30(1):53-9.
13. Blackie CA, Korb DR. A novel lid seal evaluation: the Korb-Blackie Light Test. *Eye Contact Lens.* 2015;41(2):98.

14. Tomlinson A, Bron AJ, Korb DR, et al. The international workshop on meibomian gland dysfunction: report of the diagnosis subcommittee. *Invest Ophthalmol Vis Sci.* 2011;52(4):2006-49.

15. Holland EJ, Mannis MD FACS M, W. Barry Lee MDF. *Ocular Surface Disease: cornea, conjunctiva and tear film.* Elsevier Health Sciences. 2013.

16. Saleh TA, McDermott B, Bates AK, Ewings P. Phenol red thread test vs Schirmer's test: a comparative study. *Eye (Lond).* 2006;20(8):913-5.

17. Vashisht S, Singh S. Evaluation of Phenol Red Thread test versus Schirmer test in dry eyes: a comparative study. *Int J Appl Basic Med Res.* 2011;1(1):40-2.

18. Masmali A, Alqahtani TA, Alharbi A, El-Hiti GA. Comparative study of repeatability of phenol red thread test versus Schirmer test in normal adults in Saudi Arabia. *Eye Contact Lens.* 2014;40(3):127-31.

19. Lemp MA, Bron AJ, Baudouin C, et al. Tear osmolarity in the diagnosis and management of dry eye disease. *Am J Ophthalmol.* 2011;151(5):792-8.e1.

20. Jacobi C, Jacobi A, Kruse FE, Cursiefen C. Tear film osmolarity measurements in dry eye disease using electrical impedance technology. *Cornea.* 2011;30(12):1289-92.

21. Niedernolte B, Trunk L, Wolffsohn JS, et al. Evaluation of tear meniscus height using different clinical methods. *Clin Exp Optom.* 2021;104(5):583-8.

22. Mainstone JC, Bruce AS, Golding TR. Tear meniscus measurement in the diagnosis of dry eye. *Curr Eye Res.* 1996;15(6):653-61.

23. Doughty MJ, Laiquzzaman M, Oblak E, Button N. The tear (lacrimal) meniscus height in human eyes: a useful clinical measure or an unusable variable sign? *Cont Lens Anterior Eye.* 2002;25(2):57-65.

24. Remington LA, Goodwin D. *Clinical Anatomy and Physiology of the Visual System.* Elsevier Health Sciences. 2011.

25. Dua HS, Said DG, Messmer EM, et al. Neurotrophic keratopathy. *Prog Retin Eye Res.* 2018;66:107-31.

26. Nichols JJ, Berntsen DA, Mitchell GL, Nichols KK. An assessment of grading scales for meibography images. *Cornea.* 2005;24(4):382-8.

27. Johnson LN, Diehl ML, Hamm CW, et al. Differentiating optic disc edema from optic nerve head drusen on optical coherence tomography. *Arch Ophthalmol.* 2009;127(1):45-9.

28. Belovay GW, Goldberg I. The thick and thin of the central corneal thickness in glaucoma. *Eye (Lond).* 2018;32(5):915-23.

27. Pult H, Nichols JJ. A review of meibography. *Optom Vis Sci.* 2012;89(5):E760-9.

28. Beckman KA, Luchs J, Milner MS. Making the diagnosis of Sjögren's syndrome in patients with dry eye. *Clin Ophthalmol.* 2016;10:43-53.

29. Binotti WW, Bayraktar B, Ozmen MC, et al. A review of imaging biomarkers of the ocular surface. *Eye Contact Lens.* 2020;46 Suppl 2(2):S84-105.

30. Kheirkhah A, Rahimi Darabad R, Cruzat A, et al. Corneal epithelial immune dendritic cell alterations in subtypes of dry eye disease: a pilot in vivo confocal microscopic study. *Invest Ophthalmol Vis Sci.* 2015;56(12):7179-85.

31. Hosaka E, Kawamori T, Ogasawara Y, et al. Interferometry in the evaluation of precorneal tear film thickness in dry eye. *Am J Ophthalmol.* 2011;151(1):18-23.e1.

32. Arita R, Morishige N, Fujii T, et al. Tear interferometric patterns reflect clinical tear dynamics in dry eye patients. *Invest Ophthalmol Vis Sci.* 2016;57(8):3928-34.

33. Cui X, Hong J, Wang F, et al. Assessment of corneal epithelial thickness in dry eye patients. *Optom Vis Sci.* 2014;91(12):1446-54.

34. Kanellopoulos AJ, Asimellis G. In pursuit of objective dry eye screening clinical techniques. *Eye Vis (Lond).* 2016;3:1.

35. Abou Shousha M, Wang J, Kontadakis G, et al. Corneal epithelial thickness profile in dry-eye disease. *Eye.* 2020;34(5):915-22.

36. Masmali AM, Al-Qhtani S, Al-Gasham TM, El-Hiti GA, Purslow C, Murphy PJ. Application of a new grading scale for tear ferning in non-dry eye and dry eye subjects. *Cont Lens Anterior Eye.* 2015;38(1):39-43.

# New Technologies & Treatments in Eye Care

APRIL 8–10, 2022



SAN DIEGO, CALIFORNIA

## OVERVIEW

Join MedscapeLIVE! and Review Education Group in California this spring for a comprehensive, in-person weekend of continuing education, with a virtual attendance option.

The annual New Technologies & Treatments in Eye Care conferences are long-running and trusted programs for optometrists serving to keep you up-to-date with the latest diagnosis, treatment and management in the areas of dry eye, glaucoma, and retinal disease.

## PROGRAM CHAIR



### Paul M. Karpecki, OD, FAAO

Director of Cornea  
Kentucky Eye Institute  
Lexington, Kentucky  
Chief Clinical Editor  
*Review of Optometry*  
Director  
CJO Optometric Dry Eye  
Guidelines for Eye Care

**In-person Attendees: Earn up to 21 LIVE COPE credits\***

**Virtual Attendees: Earn up to 17 LIVE COPE credits\***

[www.reviewedu.com/ntt-sandiego](http://www.reviewedu.com/ntt-sandiego)



\*Approval pending

Review Education Group partners with Salus University for those ODs who are licensed in states that require university credit.





# HOW TO TRIAGE NON-TRAUMATIC OCULAR EMERGENCIES

These urgent cases rely on early diagnosis and effective treatment and/or referral for successful outcomes.



BY MOHAMMAD RAFIEETARY, OD,<sup>1</sup>  
SALAR RAFIEETARY, MD, AND<sup>1</sup>  
BLAKE BRIGGS, MD,<sup>2</sup>  
<sup>1</sup>GERMANTOWN, TN; <sup>2</sup>MOBILE, AL

**W**hen a patient presents with what appears to be a medical emergency, you need to act fast to prevent the situation from escalating even further and potentially resulting in irreversible, devastating consequences. Some ophthalmic diseases are considered vision- and/or life-threatening, warranting their inclusion in the spectrum of medical emergencies or urgencies.

We three doctors—an optometrist, an ophthalmologist and an emergency medicine physician—are involved in different stages of the care such patients require. Here, we've pooled our collective expertise to outline a few of these conditions from the perspective of the entire management team to give you a quick reference guide to the workup, diagnostic clues and management course likely to occur for each.

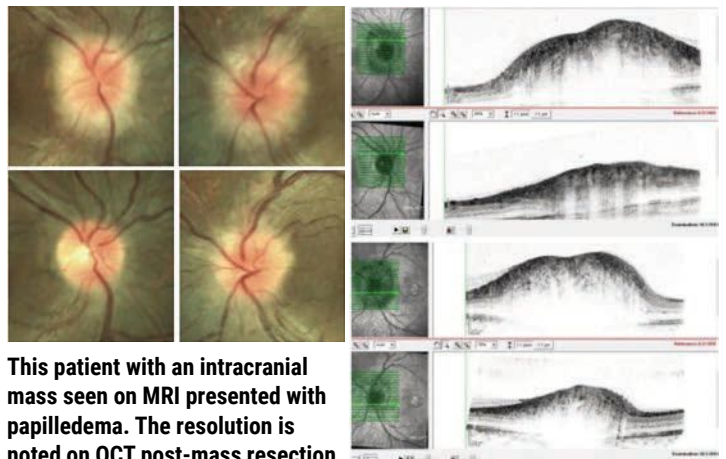
## Papilledema

Defined as bilateral swelling of the optic nerve head (ONH) caused by

increased intracranial pressure (ICP), papilledema can cause transient visual obscurations, visual field loss, pulse synchronous tinnitus, retrobulbar pain, diplopia,

headache, nausea and vomiting. Optic nerve damage is caused by intraneuronal ischemia and axoplasmic stasis.<sup>1</sup>

**History.** Ask patients about vision changes, binocular diplopia, tinnitus, headache, focal paresthesia, focal weakness, ataxia, aphasia, fevers, chills, recent pregnancy, recent weight gain and history of cancer. Review their meds; oral contraceptives, tetracyclines, vitamin A derivatives and exogenous steroids (to name a few) have been known to cause secondary intracranial hypertension.



**This patient with an intracranial mass seen on MRI presented with papilledema. The resolution is noted on OCT post-mass resection.**

**Examination.** Papilledema is more commonly bilateral and symmetric but can occasionally present with asymmetric involvement. Perform a complete eye exam with attention to pupils to monitor for an afferent pupillary defect (APD), color plates and confrontation visual fields. Note that if both optic nerves are equally affected, an APD may be absent.

Evaluate extraocular motility to assess for a sixth nerve palsy, frequently seen in idiopathic intracranial hypertension (IIH). Perform a dilated

### About the authors

**Dr. Mohammad Rafieetary** practices at the Charles Retina Institute in Germantown, TN. He is a speaker and consultant for Heidelberg Engineering, Notal Vision, Optos, Regeneron Pharmaceutical, Spark Therapeutics and Apellis Therapeutics. **Dr. Salar Rafieetary** also practices at the Charles Retina Institute. **Dr. Briggs** works at the University of Alabama Department of Emergency Medicine in Mobile, AL. Drs. Salar Rafieetary and Briggs have no financial interests to disclose.

fundus exam to assess the appearance of the optic nerves. There are varying degrees of disc elevation and blurred disc margins with or without associated peripapillary hemorrhages and cotton wool spots. Conduct visual field testing and optical coherence tomography (OCT) of the optic nerves. Consider fundus autofluorescence or B-scan imaging to rule out causes of pseudo-papilledema such as ONH drusen. Check blood pressure in all patients with bilateral optic nerve edema to rule out malignant hypertension.

**Differential diagnosis.** Causes of increased ICP include intracranial mass lesions, cerebral hemorrhage, cerebral edema, arteriovenous malformations, head trauma, cerebral venous sinus thrombosis, hydrocephalus, meningitis, encephalitis and IIH.

A study evaluating papilledema in the outpatient setting found that 87% of cases were caused by IIH and that 13% of patients had potentially life-threatening conditions, such as intracranial tumor, cerebral venous sinus thrombosis and granulomatous meningitis, 22% of whom had localizing neurologic signs.<sup>2</sup> This demonstrates the importance of prompt neuroimaging to rule out a life-threatening complication.

Other causes of optic nerve swelling not associated with elevated ICP include hypertensive retinopathy, diabetic papillopathy and toxic, infectious and inflammatory optic neuropathy.

**Workup.** All patients with ONH edema require prompt neuroimaging, including magnetic resonance imaging (MRI) with and without contrast and magnetic resonance venogram. After neuroimaging has ruled out intracranial mass lesions, lumbar puncture should be performed to evaluate ICP and cerebrospinal fluid (CSF). Elevated ICP is defined as greater than 25cm of water. Elevation of CSF white blood cells or CSF protein may be suggestive of an infectious, inflammatory or neoplastic cause. IIH is a diagnosis of exclusion when ICP is elevated and the CSF profile is negative.

It can be challenging to obtain timely neuroimaging and neurology consultation in the outpatient setting; thus, to rule out life-threatening complications, referral to the emergency department (ED) is indicated. If possible, refer to a regional medical center with access to neurology, neuroradiology and neurosurgery.

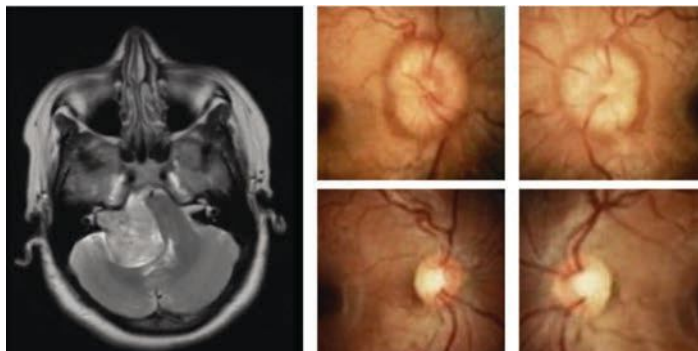
**Treatment.** This depends on the underlying cause of papilledema. IIH is treated with weight loss and diuretics such as acetazolamide. In cases refractory to medical therapy, surgical intervention is warranted with either optic nerve sheath fenestration performed by an oculoplastic surgeon or neuro-ophthalmologist or a ventriculoperitoneal or lumboperitoneal shunt performed by a neurosurgeon. Choice of surgical intervention depends on whether the prominent symptoms are vision loss/changes or headache, respectively.

Intracranial mass lesions such as tumors, abscesses and hemorrhages warrant emergent neurosurgical consultation. Infectious conditions such as meningitis and encephalitis warrant evaluation by neurology and infectious disease specialists.

Intracranial mass lesions such as tumors, abscesses and hemorrhages warrant emergent neurosurgical consultation. Infectious conditions such as meningitis and encephalitis warrant evaluation by neurology and infectious disease specialists.

### Central Retinal Artery Occlusion (CRAO)

This condition is marked by a partial or complete obstruction of the CRA, resulting in retinal infarction. It's most often caused by an embolic obstruction from atherosclerotic plaques in the carotid circulation or from cardiac valvular disease. These mechanisms are referred to as "non-arteritic" CRAO. In the case that CRAO occurs secondary to vasculitis, most com-



**This patient presented with papilledema and was diagnosed with IIH following lumbar puncture and negative MRI/MRA. After treatment with oral acetazolamide, complete resolution of disc edema is noted with some degree of secondary disc pallor.**

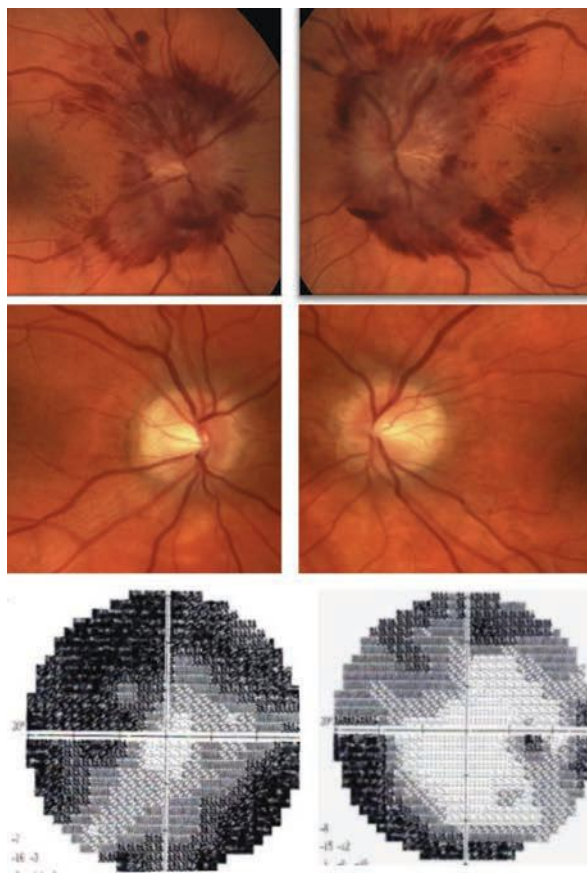
monly giant cell arteritis (GCA), it is referred to as "arteritic" CRAO.

The reported annual incidence of CRAO is 1.3 per 100,000 people.<sup>3</sup> Although CRAO is described as an ophthalmic emergency, it should be reclassified as a medical emergency because of the associated risk of other life-threatening complications such as cerebrovascular accident (CVA), myocardial ischemia and cardiovascular death.<sup>4</sup>

**Presentation.** Patients with CRAO present with a unilateral, sudden, painless loss of vision. Timing of presentation is variable. In a series of 260 patients with CRAO, 23.1% sought medical attention on the same day or within one day of symptoms, 48.8% within one week, 74.6% within one month and the remaining within a few months.<sup>5</sup>

**Examination.** Perform a complete eye exam with attention to visual acuity, pupils (checking for an APD), intraocular pressure and the anterior segment (looking for signs of neovascularization). Visual acuity is count fingers or worse in 93.2% of non-arteritic cases.<sup>5</sup> Present in 14.3% of cases is a cilioretinal artery, an arterial branch that originates from the lateral and medial posterior ciliary arteries and supplies part of the inner retina.<sup>5,6</sup> In these cases, visual acuity is often better, ranging from 20/20 to count fingers or worse.<sup>5</sup>

Confrontation or formal visual field testing is optional, but patients with



**This pregnant female patient presented with pre-eclampsia. Following optimal treatment and improvement of blood pressure, resolution of hemorrhagic papilledema is noted with secondary disc pallor. On the bottom right is a typical visual field finding associated with papilledema. The degree of visual field suppression is secondary to the severity of disc involvement.**

extensive central vision loss may have difficulty completing this task. Perform a dilated fundus exam. Findings include retinal whitening in the posterior pole (58%), a “cherry red spot” due to normal choroidal circulation in the fovea (90%), retinal arteriolar attenuation (32%), slow blood flow through the retinal arterioles (19%), optic disc edema (22%) and optic disc pallor (39%).<sup>7</sup>

**Pathophysiology.** An experimental study of rhesus monkeys with hypertension and atherosclerosis, in which the CRA was clamped at the site of entry to the ONH, demonstrated that CRAO lasting for 240 minutes results in massive irreversible retinal damage, seen both histologically and on electroretinogram.<sup>8</sup> CRAO lasting 97

minutes showed minimal damage.<sup>8</sup> Unlike many areas of the brain that have collateral circulation, the retinal ganglion cell layer is solely supplied by the CRA, with collateral capillaries present only around the optic disc.<sup>9</sup> Thus, prolonged ischemia can have devastating consequences. Cilioretinal sparing protects the inner retina and results in preserved central visual function.

**Workup.** Tools to help with diagnosis include OCT and fluorescein angiography (FA). OCT at the time of acute CRAO may show retinal thickening and inner retinal hyperreflectivity.<sup>10</sup> FA reveals absent or marked stasis of the retinal circulation.

CRAO should be referred emergently to a stroke center with access to on-call neurology, neuroradiology and cardiology.

Emboli can originate from atheromatous plaques in the internal carotid artery and cardiac valves.<sup>11</sup> Occasionally, retinal emboli can be seen on fundus exam. One study concluded that retinal emboli are an unreliable indicator for hemodynamically significant carotid artery stenosis.<sup>12</sup> Thus, perform carotid imaging on all patients in the form of ultrasound, computed tomography angiography (CTA) or magnetic resonance angiography (MRA).

Check the patient’s blood pressure. Perform electrocardiography (ECG) to evaluate for cardiac arrhythmias such as atrial fibrillation that may predispose a patient to cardioembolic events. Conduct echocardiography to look for structural valvular lesions. Consult neurology as well.

Ask patients 55 and older about symptoms of GCA, including headache, myalgias, fever, unintended weight loss, jaw claudication and hip or shoulder pain. Palpate temporal artery pulses. If the history or exam is suggestive of GCA, order C-reactive protein (CRP), erythrocyte sedimentation rate (ESR) and a platelet count. In a series of patients with biopsy-proven GCA, all those who presented with CRAO also had evidence of posterior ciliary artery circulatory abnormalities when FA was performed.<sup>13</sup>

**Treatment.** If clinical suspicion for GCA is present, initiate high-dose steroids while waiting on lab results to reduce the risk of further visual loss, involvement of the contralateral eye and other ischemic events (*i.e.*, stroke and myocardial infarction). Confirm GCA with a temporal artery biopsy (TAB).

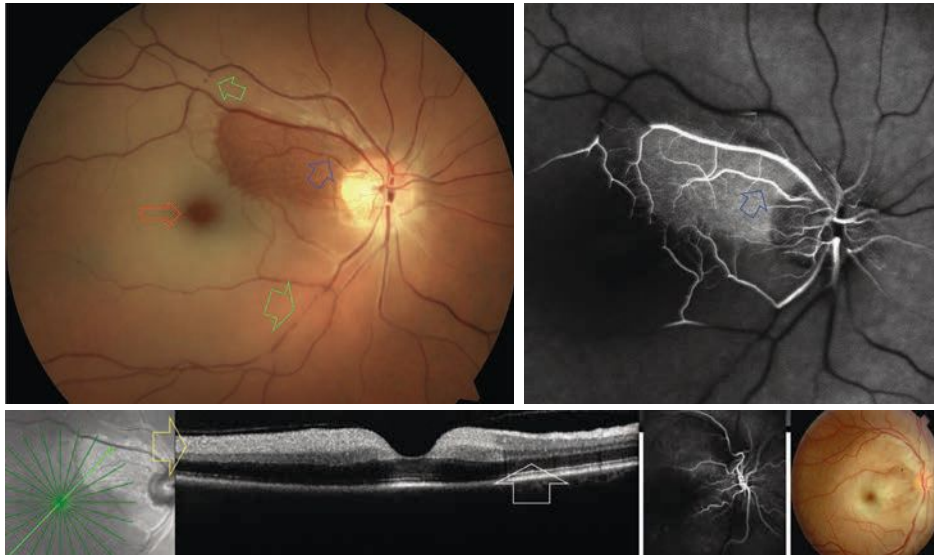
Unlike ischemic cerebral stroke, which has accepted treatment protocols, there are currently no evidence-based medical or surgical treatments that have been shown to affect the visual prognosis in CRAO.<sup>9</sup> Interventions such as ocular massage, anterior chamber paracentesis, sublingual isosorbide dinitrate and hyperosmotic agents have been investigated but have shown minimal efficacy.<sup>14</sup> Small case series and reports have documented improvement of visual acuity with prompt use of hyperbaric oxygen, but larger prospective randomized studies are needed to confirm whether this intervention affects prognosis.<sup>15,16</sup>

Management strategies should focus on preventing secondary vascular events.

### **Non-Arteritic Anterior Ischemic Optic Neuropathy (NAION)**

AION is a sudden cause of partial or complete unilateral, painless vision loss that can be broken down into arteritic (AAION) and NAION forms. NAION is defined as an idiopathic ischemic event affecting the anterior portion of the optic nerve. It is the most common optic neuropathy in the elderly population.<sup>17</sup> Diabetes and





**A cilioretinal artery (blue arrows) sparing CRAO. The areas of nonperfusion are noted to have retinal whitening with a prominent “cherry red spot” (red). Arterial plaques and segmentation “boxcarring” can be observed along the temporal vessels (green). On FA, significant vascular nonperfusion is noted outside the region supplied by the cilioretinal artery (blue). In the acute phase of CRAO, OCT typically reveals inner retinal hyperreflectivity (yellow). This is not present in the region spared by the cilioretinal artery (white). The upper right photo is an example of CRAO without cilioretinal sparing.**

systemic hypertension are common underlying causes.

The estimated annual incidence rate of NAION in patients over the age of 50 is 2.3 per 100,000 people.<sup>18</sup> The mean age at presentation is 66, with a peak age range of 60 to 69.<sup>19</sup> Systemic risk factors in patients older than 45 include hypertension, diabetes, ischemic heart disease, gastrointestinal ulcer and thyroid disease.<sup>20</sup> Additional risk factors include nocturnal hypotension and obstructive sleep apnea (OSA).<sup>21-24</sup> Small cup-to-disc ratio, seen in both the affected and fellow eyes, may play a role in the pathophysiology.<sup>25,26</sup> The proposed mechanism is mechanical constriction of the optic nerve axons within the scleral canal.

**Examination.** The clinical diagnosis of NAION is made based on sudden, painless vision loss in the presence of optic nerve edema and a visual field defect.

Perform a comprehensive exam, including visual acuity, pupils (checking for an APD), color plates, confrontation and/or formal visual fields and dilated fundus exam. An APD is

usually present unless there is bilateral symmetric eye involvement. Visual acuity is variable but not as drastic as the vision loss seen in AAION. Optic disc edema, either sectoral or general, is a prerequisite to diagnosing NAION. Examination of the fellow eye will reveal a small cup-to-disc ratio (“disc at risk”).<sup>25-27</sup> Visual field abnormalities include inferior altitudinal defects, superior altitudinal defects, central scotoma, diffuse constriction and peripheral field loss.<sup>28</sup>

OCT and scanning laser polarimetry conducted on patients with NAION showed statistically significant sectoral retinal nerve fiber layer (RNFL) thinning corresponding to the affected hemifield on visual field testing.<sup>29</sup> Interestingly, both diagnostic tests showed RNFL loss in the sectors corresponding to the unaffected hemifield as well.

The diagnosis of NAION is clinical. Lab tests are not indicated, and neither is neuroimaging nor referral to the ED. If the clinical picture or course is not consistent with a diagnosis of NAION, further workup may be warranted.

**Treatment.** Without intervention, 42.7% of patients with NAION experienced improvement of visual acuity in the affected eye by six months.<sup>30</sup> Optic disc edema usually resolves by eight weeks.<sup>31</sup> These patients have a 14.7% five-year risk of involvement of the fellow eye and should be counseled accordingly.<sup>32</sup>

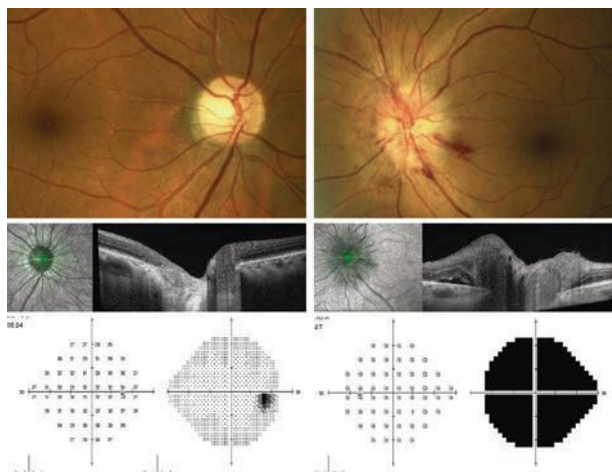
The most important step in management is to differentiate NAION from AAION, as delayed diagnosis and inaccurate treatment can have devastating consequences.

Optic nerve sheath decompression may result in more vision loss.<sup>30</sup> Visual recovery was seen in 42.7% of patients in the observation group at six months. Thus, this intervention has fallen out of favor.

Treatment with aspirin at the time of diagnosis does not affect visual acuity in the affected eye.<sup>33</sup> There is conflicting evidence about whether aspirin serves as a protective agent for the fellow eye. One study reported that the initiation of aspirin at the time of diagnosis reduced the risk of second eye involvement at two years but that the protective effect was not present at five years.<sup>34</sup> The incidence of second eye involvement in the Ischemic Optic Neuropathy Decompression Trial was not affected by the use of aspirin at five years. Despite the lack of evidence of long-term benefit with aspirin, many clinicians initiate this therapy due to the small side effect profile and the coexistence between NAION and other cardiovascular risk factors.

A recent randomized controlled trial showed no effect on visual acuity at six months with high-dose oral steroids.<sup>35</sup> Greater reduction in optic disc edema on OCT was seen at one month in the treatment group, but the percentage change in RNFL in both the treatment and observation groups at six months was statistically similar.

**Risk factor modification.** Patients with NAION have a higher likelihood of



**Presentation of AAION OS.** Note the peripapillary hemorrhages and swelling of the optic nerve seen on OCT as compared with the normal right eye. The 24-2 threshold visual field OS shows significant depression of the left eye, while the right eye remains normal.

experiencing myocardial infarctions and CVAs.<sup>36</sup> Thus, a goal of management should be risk factor modification. If risk factors for OSA are present, suggest a sleep study.

## AAION

The arteritic form of AION is an ischemic event caused by GCA that affects the optic nerve. Patients with GCA are usually older, with a median age of 75. These patients can have temporal headaches, tenderness of the temples on the ipsilateral side and jaw or tongue claudication. The estimated annual incidence rate for AAION in patients over the age of 50 is 0.36 per 100,000 people.<sup>18</sup>

**Presentation.** AAION presents with acute, often severe, painless vision loss. Clinical features that should increase clinical suspicion for AAION include older age, pallid swelling (“chalky white appearance”) of the optic nerve and constitutional symptoms such as headache, scalp tenderness, weight loss, jaw claudication, anorexia, proximal muscle aches or weakness, fever, fatigue and malaise.<sup>37</sup> Twenty-one percent of patients with GCA, however, can also present without systemic symptoms, a condition referred to as “occult GCA.” While no difference was seen in age or demographics, these

patients tend to have lower ESR and CRP compared with patients who had classic symptoms.<sup>38</sup>

In contrast to NAION, visual acuity in AAION is much worse, ranging from hand motion to no light perception.<sup>37</sup>

In patients with biopsy-proven GCA presenting with AAION, the presence of chalky white disc edema was seen in 93% of eyes (59% during the first week, 20% during the second, 14% during the third, 5% during

the fourth and 3% with unknown timing).<sup>13</sup> Tender or non-pulsatile temporal arteries can be present on exam, but the absence of these findings does not rule out GCA.<sup>37</sup>

GCA can affect any medium- to large-sized blood vessel. Of the ocular arteries, the posterior ciliary ones, which supply the choroid and the anterior portion of the optic nerve, are the most affected.<sup>37</sup> As the retina and the optic nerve are very sensitive to ischemic damage, the visual prognosis after an ischemic event such as AAION is very poor.

**Differential diagnosis.** The clinical diagnosis of AAION is made based on degree of vision loss, timing of symptoms, appearance of the optic disc and a concurrent diagnosis of GCA.

The American College of Rheumatology lists five criteria as the gold standard for diagnosis of GCA:<sup>39</sup>

- (1) age  $\geq 50$
- (2) new-onset of localized headache
- (3) temporal artery tenderness or decreased temporal artery pulse
- (4) elevated ESR  $\geq 50$ mm/hour
- (5) positive TAB

The absence of elevated inflammatory markers doesn't rule out GCA.<sup>40-42</sup> Elevated CRP and ESR have a sensitivity of 86.9% and 84.1%, respectively, for predicting a positive TAB.<sup>42</sup>

**Treatment.** AAION is a medical emergency and thus should be sent to the ED for workup and initiation of high-dose corticosteroids. If there is a logistical delay in getting the patient to the ED, initiate high-dose oral steroids in the office. Ideally, calling the ED ahead of time should reduce the likelihood of the patient being stuck in triage or the waiting room and not receiving timely treatment.

Do not delay treatment for lab confirmation. Treatment includes intravenous methylprednisolone 250mg every six hours for three to five days.<sup>43</sup> Some advocate for the use of concurrent aspirin as well. Steroid therapy is then transitioned to oral prednisone 1mg/kg/day until ESR and CRP normalize.

Labs include ESR, CRP and a complete blood count. In a comparison of patients with AAION vs. NAION, those with AAION had higher ESR, CRP, platelet counts and white blood cell counts and lower hemoglobin and hematocrit levels.<sup>44</sup>

Once high-dose steroids have been initiated, perform TAB within seven to 10 days to avoid a false negative diagnosis. A positive TAB is the gold standard for diagnosis of GCA. Due to the segmental nature of the granulomatous lesions, a biopsy of at least 2cm in length should be performed. TAB has a sensitivity of 87.1%.<sup>45</sup> A positive biopsy has a 100% specificity.<sup>43</sup>

Long-term immunomodulation therapy is best performed by a rheumatologist.

## Sudden-onset Diplopia

This condition has a broad differential diagnosis and can be subcategorized into monocular and binocular forms. Causes of monocular diplopia include dry eye, cataract and epiretinal membrane. Monocular diplopia is never caused by a neurologic abnormality. It can be elicited on exam by resolution of symptoms with monocular occlusion or pinhole testing.

In contrast, binocular diplopia is caused by ocular misalignment and warrants a neurologic review of systems, physical exam and, in many





# VISION | 2022 EXPO | NYC

MARCH 31 – APRIL 3 | JAVITS CENTER | NYC

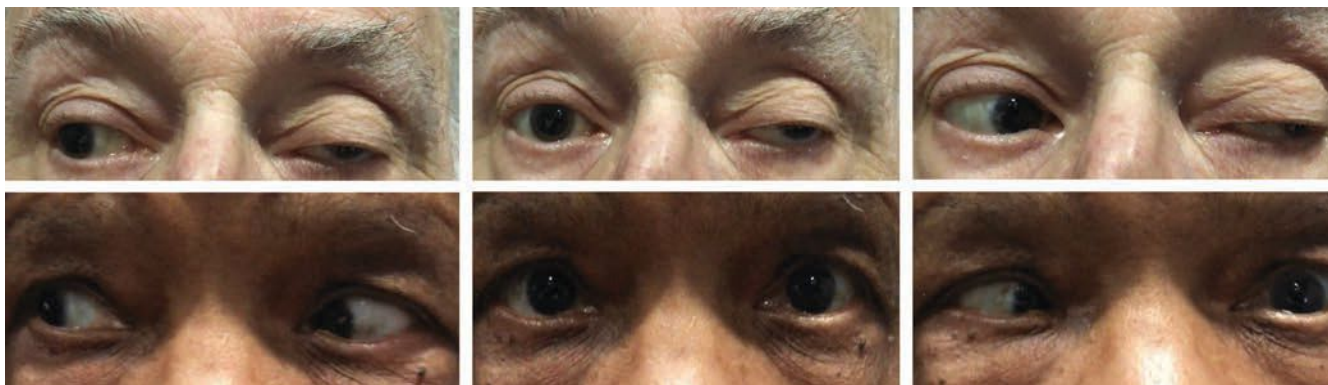


@VISIONEXPO



REGISTER TODAY AT [VEE2022.COM/ATTEND](https://vee2022.com/attend)





**Cranial nerve III palsy with exotropia, hypotropia and ptosis OS (top). There is restriction of left adduction, supraduction and infraduction. Note, both pupils are pharmacologically dilated. Isolated cranial nerve VI palsy OS (bottom). Note the subtle left esotropia in primary gaze with complete loss of abduction and normal adduction.**

cases, neuroimaging. Clarify timing of symptoms, if symptoms fluctuate during the day and whether there is eyelid or pupil involvement. Question patients with binocular diplopia over the age of 50 about symptoms of GCA, as GCA can present as an ischemic cranial nerve palsy. Use alternate cover testing to determine the amount and direction of ocular misalignment, noting whether the misalignment is comitant or incomitant.

In comitant misalignment, the deviation remains the same in all gazes. In incomitant misalignment, the deviation depends on position of gaze. Comitant misalignment is usually secondary to decompensated strabismus and does not require additional neurologic workup. In contrast, incomitant misalignment warrants additional history and workup.<sup>46</sup> The clinician should pay careful attention to lid position, pupil symmetry and reaction to light.

**Isolated cranial neuropathies.** These can occur secondary to compression, ischemia, trauma and inflammation. There is controversy in the management of an isolated cranial nerve palsy in the absence of other neurologic deficits. One study found that in a cohort of 93 patients older than 50 with acute isolated mononeuropathies including cranial nerve III, IV and VI palsies without other neurologic dysfunction, 4.3% were found to have lesions on MRI and only 1.1% were thought to have a structural lesion deemed

to be causative of the cranial nerve palsy.<sup>47</sup> The researchers concluded that neuroimaging may not be warranted in patients with isolated cranial nerve palsies without evidence of other neurologic deficits. A similar prospective study found a higher prevalence of structural lesions in 14% of patients with isolated cranial neuropathies.<sup>48</sup> This team concluded that neuroimaging should be included in the workup.

Ischemic cranial nerve palsies improve over six months, whereas compressive cranial nerve palsies do not self-resolve and may present with other neurologic deficits. If neuroimaging is not initially obtained, monitor patients closely to ensure resolution of the cranial neuropathy. If resolution is not seen or if other neurologic abnormalities are seen, obtain neuroimaging.

**Cranial nerve III palsy.** The third nerve (oculomotor) has several branches. The superior branch innervates the levator palpebrae superioris (LPS) and the superior rectus. The inferior branch innervates the medial rectus, inferior rectus and inferior oblique muscles. The superior rectus is innervated by the contralateral cranial nerve III nucleus. The LPS muscles are innervated by a joined single nucleus. Thus, an oculomotor nuclear lesion results in bilateral ptosis.

Compression of the third nerve by an aneurysm causes pupillary dilation due to involvement of the parasympathetic fibers. Compressive third nerve palsies can present without ptosis,

mydriasis or extraocular muscle deficits. This phenomenon is referred to as “incomplete.”

If complete paresis is seen of all the extraocular muscles innervated by cranial nerve III but the pupil is normal (*i.e.*, pupil-sparing), then an aneurysm can be ruled out. Some recommend patients be closely observed without neuroimaging in these cases. Others recommend conducting neuroimaging of all cranial nerve III palsies.

An unrecognized cerebral aneurysm can be a life-threatening emergency. Thus, carefully examine any patient who presents with diplopia and ptosis and keep cranial nerve III palsy high on the differential diagnosis. Urgent referral to a regional medical center with on-call neurologists, neuroradiologists and neurosurgeons is ideal if there is any concern for a compressive third nerve palsy. CT and CTA of the brain are included in the workup.

**Cranial nerve IV palsy.** The fourth nerve (trochlear) innervates the contralateral superior oblique muscle. The fourth nerve has the longest intracranial course of all cranial nerves and is thus most susceptible to trauma.

Patients with cranial nerve IV palsy present with ipsilateral hypertropia. The three-step test is used to make the diagnosis. Hypertropia increases in contralateral gaze and ipsilateral head tilt. One of the actions of the superior oblique is incyclotorsion; thus, patients with trochlear nerve palsies will have some degree of excyclotorsion.

Longstanding trochlear nerve palsies are differentiated from acute palsies based on the presence of old photos showing head tilt, facial asymmetry and increased convergence amplitudes.

**Cranial nerve VI palsy.** The sixth nerve (abducens) innervates the ipsilateral lateral rectus muscle. Thus, an abducens palsy presents with esotropia and limited abduction on the side ipsilateral to the lesion.

There is controversy in the management of an isolated sixth nerve palsy. Some advocate for neuroimaging, while others advocate for close observation if microvascular risk factors such as hypertension and diabetes are present and there are no other neurologic deficits. The natural course of a microvascular cranial neuropathy is spontaneous improvement over six months. If clinical improvement is not seen during this time or other cranial nerves are involved, then neuroimaging is indicated.

**Multiple cranial neuropathies.** When multiple cranial nerve abnormalities are localized on exam, urgent referral to the ED for imaging of the brain and orbit is indicated, specifically to evaluate the orbital apex, cavernous sinus and brainstem. Ideally, refer patients to a regional medical center with access to an on-call neurologist, neuroradiologist and neurosurgeon.

**Other motility deficits.** When multiple extraocular motility deficits and/or eyelid ptosis is seen that does not fit the pattern of a single or multiple cranial nerve palsies, consider myasthenia gravis, thyroid eye disease, Miller Fisher syndrome and skew deviation. Pupil involvement is not seen in myasthenia gravis. Outpatient referral to a neurologist or neuro-ophthalmologist can assist with workup.

## Other Presentations of Acute-onset Vision Loss

Patients can present with vision loss (unilateral or bilateral) without any significant physical ocular findings to support their claims. The following are a few scenarios and discussion of how to manage each:

**Scenario one.** A 70-year-old African American male with history of hypertension and diabetes presents with complaints of significant vision loss OD. Visual acuities are 20/30 OD and 20/20 OS. His history is positive for cataract surgery over 10 years ago, and there are no anterior or posterior segment findings to support his complaint. Visual fields reveal a right homonymous hemianopsia consistent with a posterior CVA.

Refer this patient to a stroke center for urgent CT of the brain to rule out hemorrhagic stroke, followed by MRI of the brain and either CTA or MRA to assess for vascular compromise. Cardiac workup including ECG and echocardiography are included in the stroke evaluation. If an ischemic stroke is recognized acutely and the patient is within the window for treatment with tissue plasminogen activator, then the neurologic deficits can be restored. However, oftentimes presentation to a medical provider is delayed. Goals of therapy are risk factor identification and modification. Outpatient referral is inappropriate in this context, even if symptoms are subacute.

**Scenario two.** A 34-year-old white female presents with sudden decrease of vision OS. She has no remarkable medical or ocular history. Her visual acuities are 20/20 OD and 20/60 OS. Pupils are equally reactive; however, she has an APD OS. She reports pain with eye movement. Otherwise, there are no remarkable anterior or posterior ocular findings to support the vision loss or the APD. Visual field testing shows a statistically remarkable overall depression of the left eye. Suspicion of retrobulbar optic neuritis is indicated.

Refer this patient to the ED for an urgent MRI of the brain and orbits with gadolinium and fat suppression to evaluate for optic neuritis. Per the Optic Neuritis Treatment Trial, the risk of recurrence of optic neuritis was lower in patients who received IV

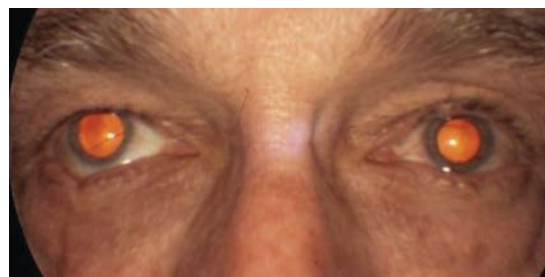steroids as opposed to oral steroids.<sup>49</sup> MRI is also indicated to evaluate for periventricular white matter lesions, which if seen would result in a diagnosis of multiple sclerosis (MS). Even in the absence of white matter lesions, counsel the patient on the long-term risk of developing MS. Other conditions that can have similar presentations include optic perineuritis (usually seen in infectious or inflammatory conditions) and neuromyelitis optica.

**Scenario three.** A 25-year-old male presents with sudden-onset vision loss OD and 20/200 visual acuity. However, all his examination findings are normal. There is no APD or signs of dry eye, keratoconus, cataract, inflammatory disease, retinal disease or macular disease. His visual field testing is inconclusive.

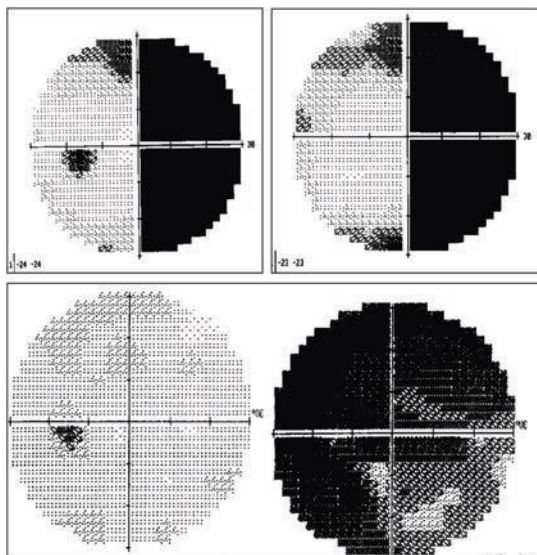
In the absence of an APD and no historical or exam findings suggestive of a neurologic abnormality, referral to the ED is not warranted and, without a working diagnosis or planned workup, can result in an unfocused, expensive shotgun workup that is usually of low diagnostic yield. Perform refraction to ensure vision is at its best-corrected potential. Establish close follow-up to ensure reproducibility of exam findings. Perform other tests such as tangent screening to rule out malingering. Factitious vision loss is a diagnosis of exclusion.

## Referral to the ED

Most of the conditions discussed here can have devastating neurologic consequences if not evaluated in an urgent manner. Ideally, refer these patients to



This patient developed diplopia after a car accident. He has a cranial nerve IV palsy with an up and out deviation OD shown in primary gaze, which is exaggerated by the traumatic scar on the lower lid of the same eye.



**Visual field defects in patients with sudden-onset vision loss with no significant anatomic ocular findings. On top, a patient is suffering from a right homonymous hemianopia caused by a left hemispheric CVA. These patients often perceive loss in the eye on the same side as their hemianopsia. In this case, the patient perceived loss of vision OD. Below, a patient is suffering from retrobulbar optic neuritis OD. These patients present with varying degrees of overall vision and visual acuity loss, often significantly reduced. Their examination is usually remarkable for pain with eye movement, an APD and red-colored desaturation. MRI of the brain and orbits with contrast and fat suppression is indicated to confirm optic nerve enhancement and to assess for periventricular white matter changes, indicative of MS.**

a regional medical center with access to on-call neurology, neuroradiology and board-certified emergency medicine doctors who can offer the highest level of care.

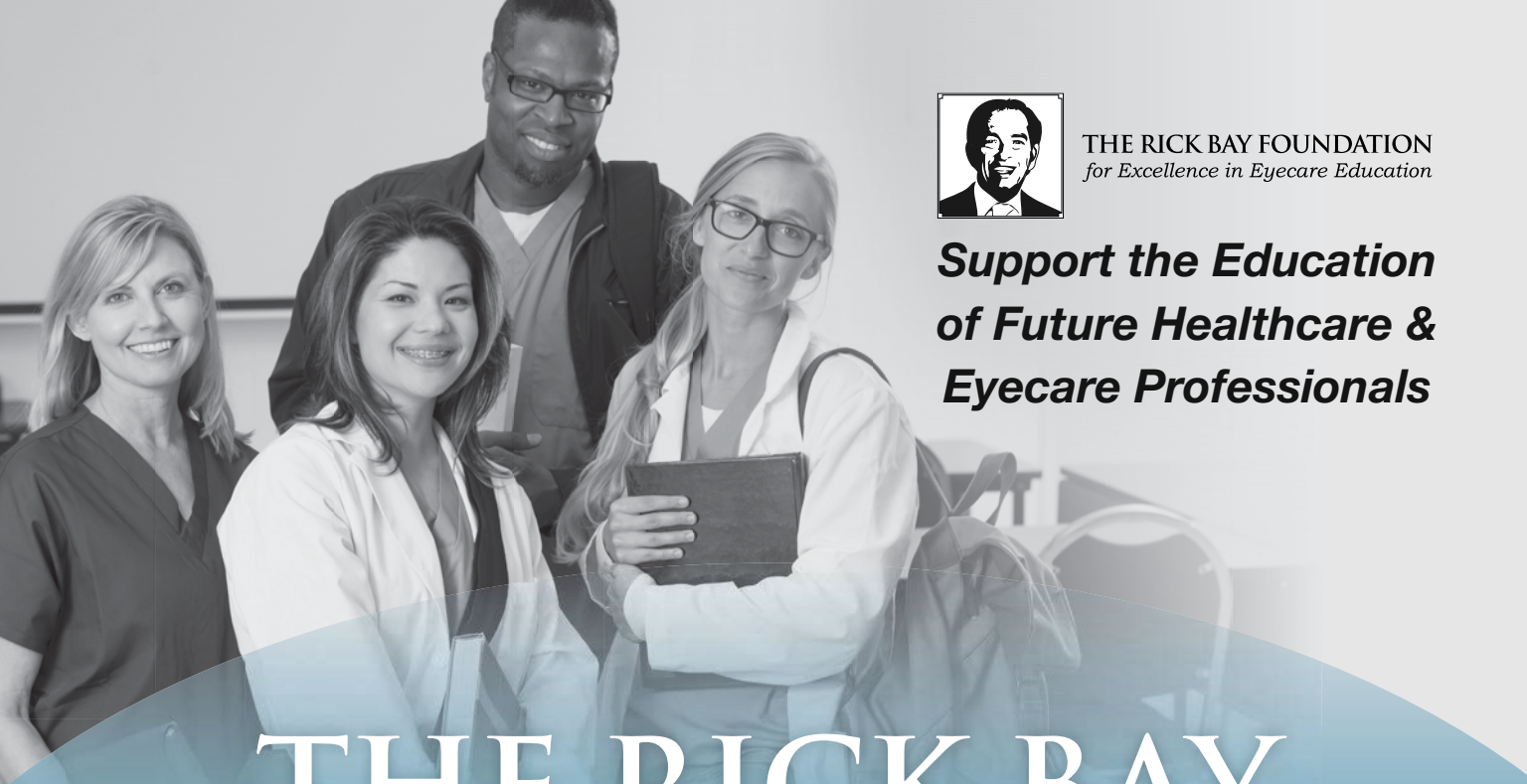
Provide either a copy of your exam notes or a letter documenting the patient's ocular exam findings, suspected diagnosis and recommended workup. If possible, call the ED and speak to the appropriate physician about your patient.

Ensure close follow-up is established post-hospitalization or arrange the appropriate follow-up with the appropriate subspecialist. ■

1. Rigi M, Almarzouqi SJ, Morgan ML, Lee AG. Papilledema: epidemiology, etiology, and clinical management. *Eye Brain*. 2015;7:47-57.
2. Crum OM, Kilgore KP, Sharma R, et al. Etiology of papilledema in patients in the eye clinic setting. *JAMA Netw Open*. 2020;3(6):e206625.
3. Leavitt JA, Larson TA, Hodge DO, Gullerud RE. The incidence of central retinal artery occlusion in Olmsted County, Minnesota. *Am J Ophthalmol*. 2011;152(5):820-3.

4. Dattilo M, Bousse V, Newman NJ. Update on the management of central retinal artery occlusion. *Neurol Clin*. 2017;35(1):83-100.
5. Hayreh SS, Zimmerman MB. Central retinal artery occlusion: visual outcome. *Am J Ophthalmol*. 2005;140(3):376-91.
6. Michalinos A, Zogana S, Kotsiomitis E, et al. Anatomy of the ophthalmic artery: a review concerning its modern surgical and clinical applications. *Anat Res Int*. 2015;2015:591961.
7. Hayreh SS, Zimmerman MB. Fundus changes in central retinal artery occlusion. *Retina*. 2007;27(3):276-89.
8. Hayreh SS, Zimmerman MB, Kimura A, Sanon A. Central retinal artery occlusion. Retinal survival time. *Exp Eye Res*. 2004;78(3):723-36.
9. Chronopoulos A, Schutz JS. Central retinal artery occlusion—a new, provisional treatment approach. *Surv Ophthalmol*. 2019;64(4):443-51.
10. Shah P, Schwartz SG, Flynn HW. Multimodal images of acute central retinal artery occlusion. *Case Rep Ophthalmol Med*. 2017;2017:5151972.
11. Recchia FM, Brown GC. Systemic disorders associated with retinal vascular occlusion. *Curr Opin Ophthalmol*. 2000;11(6):462-7.
12. Sharma S, Brown GC, Pater JL, Cruess AF. Does a visible retinal embolus increase the likelihood of hemodynamically significant carotid artery stenosis in patients with acute retinal arterial occlusion? *Arch Ophthalmol*. 1998;116(12):1602-6.
13. Hayreh SS, Podhajsky PA, Zimmerman B. Ocular manifestations of giant cell arteritis. *Am J Ophthalmol*. 1998;125(4):509-20.
14. Rumelt S, Dorenboim Y, Rehany U. Aggressive systematic treatment for central retinal artery occlusion. *Am J Ophthalmol*. 1999;128(6):733-8.
15. Beiran I, Goldenberg I, Adir Y, et al. Early hyperbaric oxygen therapy for retinal artery occlusion. *Eur J Ophthalmol*. 2001;11(4):345-50.
16. Kim YS, Nam MS, Park EJ, et al. The effect of adjunctive hyperbaric oxygen therapy in patients with central retinal artery occlusion. *Undersea Hyperb Med*. 2020;47(1):57-64.
17. Hattenhauer MG, Leavitt JA, Hodge DO, et al. Incidence of nonarteritic anterior ischemic optic neuropathy. *Am J Ophthalmol*. 1997;123(1):103-7.
18. Johnson LN, Arnold AC. Incidence of nonarteritic anterior ischemic optic neuropathy. Population-based study in the state of Missouri and Los Angeles County, California. *J Neuroophthalmol*. 1994;14(1):38-44.
19. Characteristics of patients with nonarteritic anterior ischemic optic neuropathy eligible for the Ischemic Optic Neuropathy Decompression Trial. *Arch Ophthalmol*. 1996;114(11):1366-74.
20. Hayreh SS, Joos KM, Podhajsky PA, Long CR. Systemic diseases associated with nonarteritic anterior ischemic optic neuropathy. *Am J Ophthalmol*. 1994;118(6):766-80.
21. Hayreh SS, Zimmerman MB, Podhajsky P, Alward WL. Nocturnal arterial hypotension and its role in optic nerve head and ocular ischemic disorders. *Am J Ophthalmol*. 1994;117(5):603-24.
22. Mojon DS, Hedges TR, Ehrenberg B, et al. Association between sleep apnea syndrome and nonarteritic anterior ischemic optic neuropathy. *Arch Ophthalmol*. 2002;120(5):601-5.
23. Bilgin G, Koban Y, Arnold AC. Nonarteritic anterior ischemic optic neuropathy and obstructive sleep apnea. *J Neuroophthalmol*. 2013;33(3):232-4.
24. Wu Y, Zhou LM, Lou H, et al. The association between obstructive sleep apnea and nonarteritic anterior ischemic optic neuropathy: a systematic review and meta-analysis. *Curr Eye Res*. 2016;41(7):987-92.
25. Beck RW, Savino PJ, Repka MX, et al. Optic disc structure in anterior ischemic optic neuropathy. *Ophthalmology*. 1984;91(11):1334-7.
26. Feit RH, Tomsak RL, Ellenberger C. Structural factors in the pathogenesis of ischemic optic neuropathy. *Am J Ophthalmol*. 1984;98(1):105-8.
27. Doro S, Lessell S. Cup-disc ratio and ischemic optic neuropathy. *Arch Ophthalmol*. 1985;103(8):1143-4.
28. Gerling J, Meyer JH, Kommerell G. Visual field defects in optic neuritis and anterior ischemic optic neuropathy: distinctive features. *Graefes Arch Clin Exp Ophthalmol*. 1998;236(3):188-92.
29. Deleón-Ortega J, Carroll KE, Arthur SN, Girkin CA. Correlations between retinal nerve fiber layer and visual field in eyes with nonarteritic anterior ischemic optic neuropathy. *Am J Ophthalmol*. 2007;143(2):288-94.
30. Optic nerve decompression surgery for nonarteritic anterior ischemic optic neuropathy (NAION) is not effective and may be harmful. The Ischemic Optic Neuropathy Decompression Trial Research Group. *JAMA*. 1995;273(8):625-32.
31. Hayreh SS, Zimmerman MB. Optic disc edema in nonarteritic anterior ischemic optic neuropathy. *Graefes Arch Clin Exp Ophthalmol*. 2007;245(8):1107-21.
32. Newman NJ, Scherer R, Langenberg P, et al. The fellow eye in NAION: report from the ischemic optic neuropathy decompression trial follow-up study. *Am J Ophthalmol*. 2002;134(3):317-28.
33. Botelho PJ, Johnson LN, Arnold AC. The effect of aspirin on the visual outcome of nonarteritic anterior ischemic optic neuropathy. *Am J Ophthalmol*. 1996;121(4):450-1.
34. Beck RW, Hayreh SS, Podhajsky PA, et al. Aspirin therapy in nonarteritic anterior ischemic optic neuropathy. *Am J Ophthalmol*. 1997;123(2):212-7.
35. Saxena R, Singh D, Sharma M, et al. Steroids versus no steroids in nonarteritic anterior ischemic optic neuropathy: a randomized controlled trial. *Ophthalmology*. 2018;125(10):1623-7.
36. Guyer DR, Miller NR, Auer CL, Fine SL. The risk of cerebrovascular and cardiovascular disease in patients with anterior ischemic optic neuropathy. *Arch Ophthalmol*. 1985;103(8):1136-42.
37. Hayreh SS. Ophthalmic features of giant cell arteritis. *Baillieres Clin Rheumatol*. 1991;5(3):431-59.
38. Hayreh SS, Podhajsky PA, Zimmerman B. Occult giant cell arteritis: ocular manifestations. *Am J Ophthalmol*. 1998;125(4):521-6.
39. Hunder GG, Bloch DA, Michel BA, et al. The American College of Rheumatology 1990 criteria for the classification of giant cell arteritis. *Arthritis Rheum*. 1990;33(8):1122-8.
40. Yoeuek E, Szurman P, Tatar O, et al. Anterior ischemic optic neuropathy due to giant cell arteritis with normal inflammatory markers. *Graefes Arch Clin Exp Ophthalmol*. 2008;246(6):913-5.
41. Poole TR, Graham EM, Lucas SB. Giant cell arteritis with a normal ESR and CRP. *Eye (Lond)*. 2003;17(1):92-3.
42. Kermani TA, Schmidt J, Crowson CS, et al. Utility of erythrocyte sedimentation rate and C-reactive protein for the diagnosis of giant cell arteritis. *Semin Arthritis Rheum*. 2012;41(6):866-71.
43. Scheurer RA, Harrison AR, Lee MS. Treatment of vision loss in giant cell arteritis. *Curr Treat Options Neurol*. 2012;14(1):84-92.
44. Costello F, Zimmerman MB, Podhajsky PA, Hayreh SS. Role of thrombocytosis in diagnosis of giant cell arteritis and differentiation of arteritic from non-arteritic anterior ischemic optic neuropathy. *Eur J Ophthalmol*. 2004;14(3):245-57.
45. Niederkofer RD, Levin LA. A Bayesian analysis of the true sensitivity of a temporal artery biopsy. *Invest Ophthalmol Vis Sci*. 2007;48(2):675-80.
46. Margolin E. Approach to patient with diplopia. *J Neurol Sci*. 2020;417:117055.
47. Murchison AP, Gilbert ME, Savino PJ. Neuroimaging and acute ocular motor mononeuropathies: a prospective study. *Arch Ophthalmol*. 2011;129(3):301-5.
48. Chou KL, Galetta SL, Liu GT, et al. Acute ocular motor mononeuropathies: prospective study of the roles of neuroimaging and clinical assessment. *J Neurol Sci*. 2004;219(1-2):35-9.
49. Beck RW, Cleary PA, Anderson MM, et al. A randomized, controlled trial of corticosteroids in the treatment of acute optic neuritis. The Optic Neuritis Study Group. *N Engl J Med*. 1992;326(9):581-8.





THE RICK BAY FOUNDATION  
*for Excellence in Eyecare Education*

**Support the Education  
of Future Healthcare &  
Eyecare Professionals**

# THE RICK BAY FOUNDATION

*for Excellence in Eyecare Education*

Scholarships are awarded to advance the education of students in both **Optometry** and **Ophthalmology**, and are chosen by their school based on qualities that embody Rick's commitment to the profession, including integrity, compassion, partnership and dedication to the greater good.

## INTERESTED IN BEING A PARTNER WITH US?

[www.rickbayfoundation.org](http://www.rickbayfoundation.org)

*(Contributions are tax-deductible in accordance  
with section 170 of the Internal Revenue Code.)*

### **ABOUT RICK**

Rick Bay served as the publisher of *The Review Group* for more than 20 years. To those who worked for him, he was a leader whose essence was based in a fierce and boundless loyalty. To those in the industry and the professions he served, he will be remembered for his unique array of skills and for his dedication to exceeding the expectations of his customers, making many of them fast friends.



*(The Rick Bay Foundation for Excellence in Eyecare Education is a nonprofit, tax-exempt organization under section 501(c)(3) of the Internal Revenue Code.)*

Earn 2 CE Credits  
(COPE APPROVED)

# PERIPHERAL RETINAL IMAGING AND DISEASE ASSESSMENT

Using the right tools can help differentiate lesions and degenerations in this region.



BY JULIE RODMAN, OD, MSC,  
VERONICA ACUÑA, OD, AND  
POOJA ALLOJU, OD  
FORT LAUDERDALE, FL

Retinal imaging has dramatically evolved since the advent of the first ophthalmoscope in 1851.<sup>1</sup> Advances in diagnostic technology have led to a broader understanding of retinal and choroidal disease and have provided new and innovative ways of evaluating the retina. Early imaging modalities helped capture the posterior pole; however, imaging of the retinal periphery was not viable. Diagnostic advances have since allowed for adequate visualization of the retinal periphery, which has become essential in the screening, diagnosis, monitoring and treatment of vision-altering diseases.

To establish consistent nomenclature regarding imaging of the retinal periphery, the International Widefield Imaging Study Group published guidelines on “widefield” and “ultra-widefield (UWF)” peripheral retinal

imaging. *Widefield* is defined as a single-capture image centered on the fovea that includes the retina in all four quadrants posterior to and including the vortex vein ampullae.

*UWF* imaging is a single-capture view of the retina in the far periphery in all four quadrants.<sup>2</sup> Standard imaging solely encompasses the posterior pole, retinal blood vessels, macula and optic nerve head. The introduction of UWF imaging has enabled image capture into the far periphery and has brought on a renewed interest in peripheral retinal abnormalities and their impact on various disease entities.

UWF imaging encompasses various modalities, including color fundus photography (using true color laser/confocal scanning laser ophthalmoscopy), UWF optical coherence tomography (OCT), fundus autofluorescence (FAF), fluorescein angiography (FA) and indocyanine green (ICG) angiography. To maximize interpretation of these modalities, a basic understanding of retinal anatomy is necessary.

## Retinal Anatomy Refresher

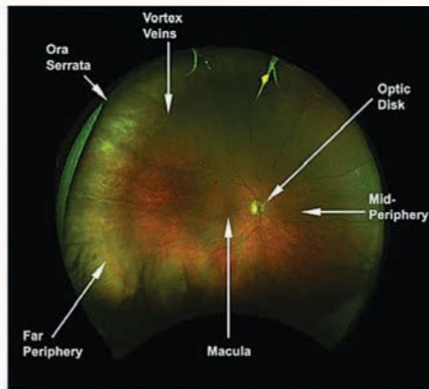
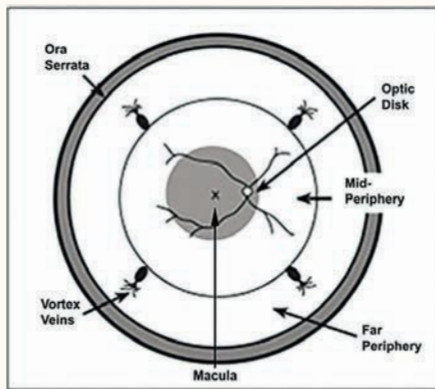
As we know, the retina is divided into various regions, including the posterior pole, equator and periphery. The posterior pole is made up of the optic nerve head, retinal vascular arcades and macula including the foveola, fovea, parafovea and perifovea.<sup>3</sup> These designations are essential for retinal image analysis.

The foveola, the innermost region of the macula, is located at the center of the fovea where cone photoreceptors are located. It has a diameter of 0.35mm and contains the highest density (50 cones per every 100µm), allowing for a greater degree of resolution of visual acuity.<sup>4</sup> The parafovea surrounds the fovea and the perifovea surrounds the parafovea.

The peripheral retina is divided into four distinct zones: the near periphery, middle periphery, far periphery and extreme periphery or ora serrata. The near periphery is defined as a 1.5mm ring adjacent to the 6mm diameter macula, the middle periphery is the

### About the authors

**Dr. Rodman** is chief of the Broward Eye Care Institute in Fort Lauderdale, FL. Her research interests include OCT/OCT-A and vitreoretinal disease. She receives consulting fees from Optovue, Maculogix and iCare. **Dr. Acuña** graduated from Nova Southeastern University's (NSU) College of Optometry in 2021, at which point she started her residency at NSU in primary care with an emphasis on ocular disease. **Dr. Alloju** graduated from Southern College of Optometry in 2021 and is currently pursuing her dual primary care and cornea and contact lens residency at NSU. Drs. Acuña and Alloju have no financial interests to disclose.



### Major landmarks in the retina.<sup>30,31</sup>

next 1.5mm ring, the far periphery measures the next 9mm to 10mm temporally and 16mm nasally and the ora serrata measures the last 2.1mm temporally and 0.7mm nasally.<sup>5</sup> The vitreous base is a 3mm to 6mm diameter area that borders the ora serrata and is the site where the collagen fibrils of the vitreous firmly attach to the internal limiting membrane of the peripheral retina.<sup>6</sup>

### History of Peripheral Retina Evaluation

Dilated fundus examination with use of both contact (*i.e.*, three-mirror Goldmann lens) and non-contact fundus lenses of various powers along with binocular indirect ophthalmoscopy has historically been the standard for evaluation of the retinal periphery. Adjunct use of scleral depression is case-specific and recommended in

certain scenarios such as those involving photopsia and floaters requiring a thorough exam of the vitreous base.

Scleral depression enables a greater field of view and provides a different retinal profile of suspicious areas that may reveal subclinical or subtle retinal breaks. Accurate descriptions of peripheral retinal findings were necessary, and detailed retinal drawings were used for documentation.

### Imaging Modalities

A comprehensive understanding of when and how to use the different imaging modalities is key to ensure accurate diagnosis and effective disease management.

**Fundus photography.** Retinal photography is used as a screening device as well as a tool to aid in the detection, documentation and management of disease. Traditional fundus cameras

allow for visualization of the posterior pole but provide limited views of the periphery. They have a 75° field of view with the use of eccentric fixation. Serial images can be obtained and montaged together to increase the field of view. However, montaging may result in distortion with magnification or minification of image detail.

In 2000, the Optomap (Optos) was introduced into the ophthalmic market. It is a non-contact camera that allows for a 200° field of view that covers 82.5% of the retinal surface.

This technology uses a scanning laser technology with an ellipsoid mirror that allows for imaging of the retinal periphery. The use of red and green lasers provides a pseudocolor retinal image that is easily discernible from a traditional retinal camera, which uses a white light. Optomap units can be equipped with adjunct imaging modalities such as FAF, UWF OCT, ICG angiography and FA, which all enhance the imaging capability of peripheral retinal anomalies.

Other widefield imaging units include the Clarus 500 (Zeiss), the Eidon (iCare) and the Spectralis (Heidelberg). The Clarus 500 is an UWF imaging instrument that uses three wide-spectrum LEDs to enable image capture in true color. It captures 133° with one capture or 200° with the auto-montage feature. The Eidon is a non-mydratric UWF confocal

**Release Date:** February 15, 2022

**Expiration Date:** February 15, 2025

**Estimated Time to Complete Activity:** two hours

Jointly provided by the Postgraduate Institute for Medicine (PIM) and Review Education Group

**Educational Objectives:** After completing this activity, the participant should be better able to:

- Discuss peripheral retinal imaging and disease assessment.
- Use OCT imaging to differentiate peripheral retinal lesions and degenerations.
- Recognize what these conditions look like on OCT imaging and other observational techniques.
- Review what conditions can arise in the peripheral retina.
- Diagnose peripheral retinal lesions and initiate management.

**Target Audience:** This activity is intended for optometrists engaged in managing patients with peripheral retinal disease.

**Accreditation Statement:** In support of improving patient care, this activity has been planned and implemented by PIM and the Review Education Group. PIM is jointly accredited by the Accreditation Council for Continuing Medical Education, the



Accreditation Council for Pharmacy Education and the American Nurses Credentialing Center to provide CE for the healthcare team. PIM is accredited by COPE to provide CE to optometrists.

**Reviewed by:** Salus University, Elkins Park, PA



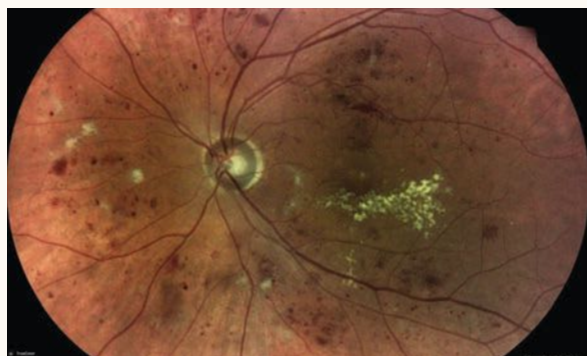
**Faculty/Editorial Board:** Julie Rodman, OD, MSc, Veronica Acuña, OD, and Pooja Alloju, OD

**Credit Statement:** This course is COPE-approved for two hours of CE credit. Activity #123219 and course ID 76573-TD. Check with your local state licensing board to see if this counts toward your CE requirement for relicensure.

**Disclosure Statements:** PIM requires faculty, planners and others in control of educational content to disclose all their financial relationships with ineligible companies. All identified conflicts of interest are thoroughly vetted and mitigated according to PIM policy. PIM is committed to providing its learners with high-quality, accredited CE activities and related materials that promote improvements or quality in healthcare and not a specific proprietary business interest of an ineligible company.

Those involved reported the following relevant financial relationships with ineligible entities related to the educational content of this CE activity: *Authors:* Dr. Rodman receives consulting fees from Optovue, Maculogix and iCare. Drs. Acuña and Alloju have no financial interests to disclose. *Managers and Editorial Staff:* The PIM planners and managers have nothing to disclose. The Review Education Group planners, managers and editorial staff have nothing to disclose.





**Severe nonproliferative diabetic retinopathy captured with the DRSpplus (iCare).**

fundus imaging system that allows for multiple imaging modalities including TrueColor, blue, red, red-free and infrared. It captures 120° on a single shot and up to 200° using the mosaic feature.

The Spectralis delivers 55° confocal scanning laser imaging that includes infrared reflectance, FAF and multi-color imaging, acquired by obtaining infrared, green and blue reflectance images and applying a false color scheme. Scanning laser imaging provides increased image resolution over white light photography. It allows for visualization at different layers of the retina with different filters; thus, to image choroidal pathology or superficial retinal lesions, the red/green channel can be used. In this way, these fundus photography systems have become even more diagnostic in nature than ever before.

**OCT.** Spectral-domain OCT (SD-OCT) is a diagnostic modality that provides noninvasive, cross-sectional views of the retina, choroid, optic nerve and surrounding structures. SD-OCT includes a wide range of scan protocols that can maximally capture any area of the posterior pole including the vitreoretinal interface. It has been instrumental in advancing and enhancing our ability to diagnose a variety of conditions and execute appropriate management decisions based on the diagnosis. In fact, this technology has become a pillar of posterior segment evaluation along with dilated fundus ophthalmoscopy. However, its application and use in peripheral retinal imag-

ing has been limited, bypassing the site of many vision-threatening pathologies.

The introduction of UWF SD-OCT has provided a new, innovative way of viewing the peripheral retina. UWF SD-OCT allows for precise visualization of peripheral anatomical features and can be extremely impactful

in differentiating between various lesions, which in turn helps to guide subsequent management decisions. Entities such as retinal tears, holes with or without lattice degeneration and retinal detachments (RDs) are just a few examples of peripheral retinal entities that can be captured using UWF SD-OCT. Identifying subtle features and visualizing the full extent of these conditions is beneficial in determining which patients need to be referred and which can be monitored. Although not a replacement for clinical or funduscopic observation, it can serve as an excellent adjunct to examination.

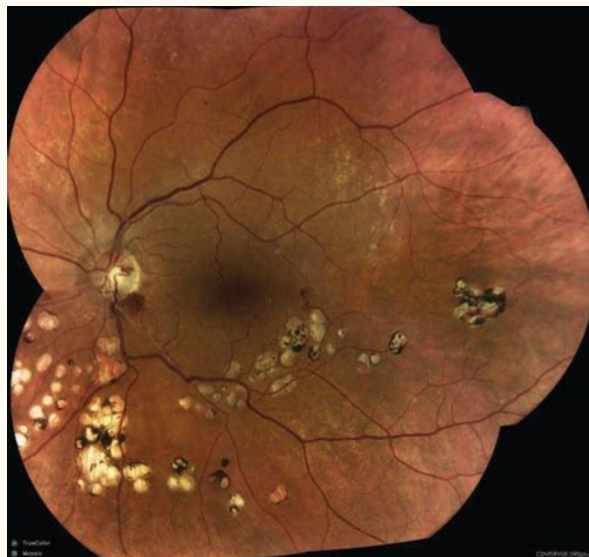UWF SD-OCT can be further used in evaluating peripheral choroidal and retinal pigment epithelium (RPE) lesions, such as congenital hypertrophy of the RPE, and determining malignant potential. When differentiating between choroidal nevi and melanomas, features suggestive of malignancy including anterior-posterior thickness >2mm with ultrasound, subretinal fluid and overlying retinal changes, such as to the photoreceptors or lipofuscin deposition, can be identified on simultaneous UWF SD-OCT capture and fundus imaging.<sup>7,8</sup>

Disruption to the overlying photoreceptors in the form of

“shaginess” or irregularity may be an indication that the choroidal lesion has infiltrated the subretinal space. Similarly, lipofuscin—a hyperreflective substance anterior to the RPE on OCT—is a harbinger of malignancy. In contrast, the presence of drusen overlying a suspicious lesion is a sign more consistent with benign nevi and is an indication of chronicity. UWF SD-OCT is not only helpful in diagnosing these lesions but also in monitoring for progression.

**FAF.** This is another modality used to evaluate retinal peripheral abnormalities. It is a noninvasive imaging technology that evaluates the metabolic activity of the photoreceptor cells and the RPE. FAF employs a light source of a specific wavelength to excite intrinsically fluorescent lipofuscin.<sup>9</sup> The intensity of autofluorescence depends on the amount of lipofuscin present. Eyes without pathology naturally emit a diffuse background autofluorescence except at the fovea, optic nerve head and retinal blood vessels. Increased autofluorescence is the result of excessive build-up of lipofuscin and is seen in diseases such as Stargardt’s disease, pattern dystrophy, Best’s disease and adult-onset vitelliform dystrophy.

FAF is extremely useful in evaluating various conditions affecting the posterior pole, including optic disc



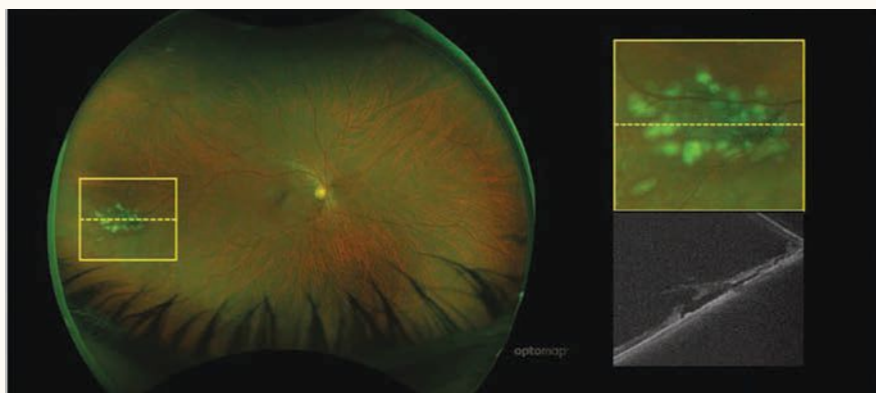
**Inferior retinal vein occlusion seen with the DRSpplus (iCare).**

drusen, age-related macular degeneration (AMD), Stargardt's and choroidal tumors, as well as in peripheral retinal diseases such as retinitis pigmentosa, choroideremia and cone/cone-rod dystrophy.<sup>9</sup>

**Retinal angiography.** Other invasive imaging platforms, such as fundus FA and ICG angiography, are remarkable technologies that remain at the forefront of retinal diagnostic imaging. These employ a water-soluble dye to visualize retinal and choroidal vasculature. ICG angiography uses a longer wavelength dye for better ocular penetration, making it the best modality to image the choroidal vasculature.<sup>10</sup> The introduction of UWF FA and UWF ICG angiography has allowed for the same level of visualization of the retinal periphery that we have grown accustomed to seeing in the posterior pole and equatorial regions.

Evaluation of widefield angiography in various diseases has proven beneficial, as patients without clinically visible peripheral retinal disease may manifest peripheral vascular variations that may alter the course of the disease.<sup>11</sup> When comparing highly myopic eyes with emmetropic eyes, the former have large areas of capillary nonperfusion, telangiectasia and microaneurysms on widefield FA.<sup>12</sup>

The utility of widefield FA has also been studied in AMD. The presence of peripheral leakage on angiography has been positively correlated with neovascular AMD development.<sup>13</sup> AMD is thus a panretinal disease as it manifests in the posterior pole but also affects the peripheral retina.



**UWF pseudocolor Optos image with corresponding OCT scan showing a far peripheral tear temporally. There is a visible break in the neurosensory retina with subretinal fluid within the lesion.**

Widefield angiography has also become extremely beneficial in managing diabetic patients. In diabetes, widefield FA images capture 3.9x more areas of retinal nonperfusion, 1.9x more retinal neovascularization and 3.2x more retinal surface area than the standard ETDRS map.<sup>14</sup> In addition, late leakage of peripheral retinal vessels in poorly perfused areas is correlated with the development of macular edema and neovascularization.

The presence of predominantly peripheral lesions in diabetic eyes is predictive of a threefold increased risk of diabetic retinopathy progression and a nearly fivefold increased risk of developing proliferative retinopathy.<sup>15</sup> These lesions correlate with areas of peripheral nonperfusion on widefield angiography and are thus linked to an increased risk of retinopathy progression.<sup>16</sup> Since these lesions are not readily visible in the posterior pole, it is essential to perform a peripheral retinal exam to gain insight into the

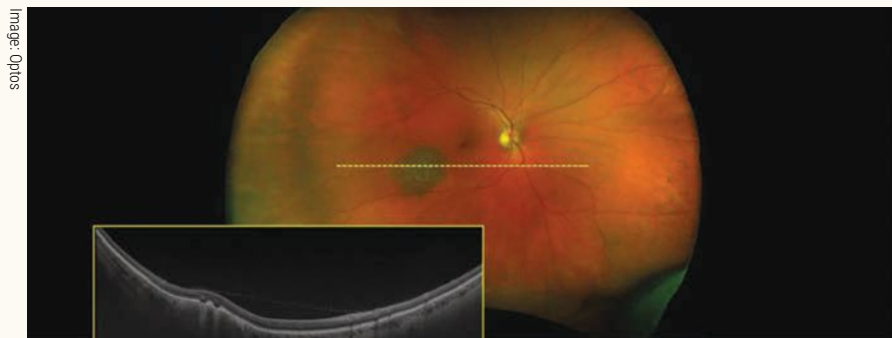
disease course. Patients with greater areas of retinal nonperfusion had better outcomes from anti-VEGF therapy, including improvements in macular thickness and visual acuity.<sup>17</sup> UWF imaging with FA also highlights abnormalities seen in noninfectious uveitis or vasculitis that may have been missed on standard fundus exam.<sup>18</sup>

### Conditions to Look Out For

Lattice degeneration is a common peripheral retinal degeneration, with a prevalence of 7% to 10% in the general population.<sup>19</sup> It is characterized by localized retinal thinning, vitreoretinal adhesion at the borders and overlying vitreous liquefaction. Lattice degeneration can vary widely in appearance; however, it is usually round, oval or elongated, with the long axis parallel to the ora serrata. It can also appear spindle-shaped and have associated sclerosed vessels. It is commonly seen bilaterally, more so in the superior and inferior quadrants.

In most cases, lattice can be adequately visualized using binocular indirect ophthalmoscopy. Often, the vitreoretinal traction is difficult to appreciate on peripheral retinal ophthalmoscopic examination and is more readily visible using UWF SD-OCT.

Characteristics of peripheral lattice degeneration on UWF SD-OCT include retinal thinning, retinoschisis, vitreous liquefaction anterior to the thinned retina and retinal breaks or atrophic holes with or without



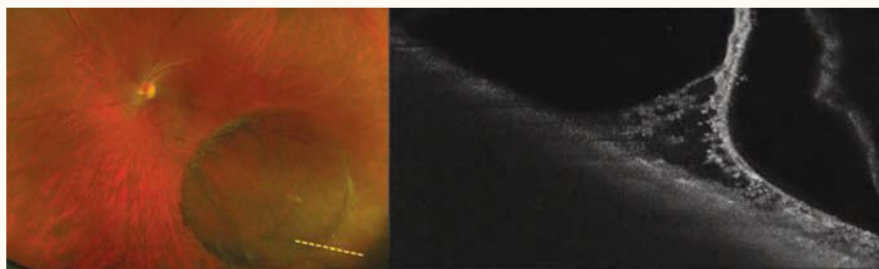
**UWF pseudocolor Optos image with corresponding OCT scan showing a slightly elevated choroidal nevus with overlying drusen within the inferior temporal arcades of the right eye.**

subretinal fluid.<sup>20</sup> Retinal holes within the lattice will manifest a full-thickness loss of retinal tissue with or without subretinal fluid adjacent to the hole. Peripheral atrophic holes not associated with lattice may also present with overlying operculum either attached, partially attached or completely detached. In instances of a partially attached operculum, hyper-reflective vitreous fragments may be visible surrounding the operculum.<sup>21</sup>

Senile (degenerative or acquired) retinoschisis is a commonly encountered peripheral retinal pathology with a prevalence of approximately 3.8%.<sup>22</sup> It presents clinically with microcystoid degeneration and/or separation of the neurosensory retina, resulting in an immobile, transparent bullous or smooth inner retinal elevation.<sup>23</sup>

RD is a clinically similar entity to retinoschisis. While sight-threatening, RD has an incidence of approximately one in 10,000.<sup>24</sup> Normally, the RPE maintains a tight junction with the overlying neurosensory retina; however, when exposed to stressors, this tight barrier deteriorates, resulting in an accumulation of subretinal fluid between the neurosensory retina and the RPE and causing an RD.

RDs can be characterized as one of four types: rhegmatogenous, tractional, exudative or combined tractional-rhegmatogenous. Rhegmatogenous RDs usually occur due to a retinal tear brought on by a preceding event, *i.e.*, a posterior vitreous detachment or trauma. Tractional RDs occur because of proliferation at the vitreoretinal



**Inferotemporally located retinoschisis with corresponding OCT scan in the left eye. OCT displays the schitic cavity separating the inner retinal layer from the outer retinal layers.**

interface creating tractional points that can pull on the neurosensory retina creating a separation. Tractional detachments occur in cases of proliferative diabetic retinopathy or proliferative sickle cell retinopathy, among others. Exudative RDs are seen because of subretinal fluid accumulation secondary to localized inflammation or exudative extravasation from a lesion.

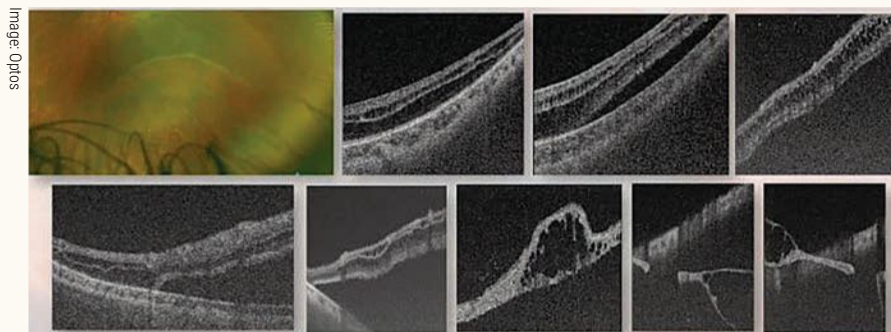
It is often challenging to differentiate a retinal detachment from senile retinoschisis. RDs can vary in appearance due to their wide array of etiologies, but rhegmatogenous RDs often present similarly to retinoschisis as smooth or bullous elevations. However, RDs are associated with a visible retinal break. Pigment demarcation lines may form at the edge of the detached/attached retina in chronic detachments, but they do not form at the edge of a retinoschisis.<sup>25</sup>

Scleral indentation and biomicroscopic evaluation are useful but self-limiting and not always sufficient. Scleral indentation will flatten an RD as the subretinal fluid will be displaced through the retinal break into the overlying vitreous.<sup>26</sup> Due to absence of a

break with retinoschisis, this presentation will not flatten on scleral depression. It is often difficult to obtain an adequate view of the lesion with scleral depression, resulting in a clinical conundrum. Adjunct use of UWF SD-OCT in these scenarios may prove to be extremely beneficial.


UWF SD-OCT renders a cross-sectional image of these lesions, providing a view of the retinal anatomy that aids in the diagnosis and differentiation of the lesions. On UWF SD-OCT, senile retinoschisis will present with hyporeflexive cystoid cavities and columns, creating a sawtooth-like schisis or splitting of the inner nuclear and outer plexiform layers of the retina.<sup>27</sup> OCT of an RD will display a full-thickness, fully detached neurosensory retina from the underlying RPE. A senile retinoschisis will exhibit attenuation of the inner retina and a splitting of the retinal layers at the inner nuclear layer-outer plexiform layer junction. At the edge of the lesion, fibers may extend across the schisis cavity connecting the inner and outer neurosensory retina. Often, the lesion quickly becomes highly elevated and bullous as you move into the lesion with a total separation of the outer from the inner retina. The outer retina remains in opposition to the RPE unlike in an RD.

UWF SD-OCT can help reduce the referral rates for common clinical findings such as white without pressure (WWOP) and dark without pressure (DWOP). WWOP is a commonly encountered peripheral retinal finding often found in young, myopic patients.<sup>28</sup> It is characterized by an area of retinal whitening found in the far periphery that blocks the view of the



**UWF pseudocolor Optos photography with corresponding OCT scan showing a chronic peripheral RD. OCT illustrates the separation between the neurosensory retina and underlying RPE. Serial OCT scans allow for full visualization of the lesion.**





**Optos photography and corresponding OCT showing a temporal retinal hole with scarring but without surrounding subretinal fluid cuff in the left eye. Scarring from previous laser is seen as distinct areas of hyperreflectivity adjacent to the retinal hole (absence of neurosensory retina).**

underlying choroid. Exact etiology is unknown; however, it is thought to be due to an anomalous vitreoretinal relationship. While these are relatively benign conditions, they are frequently misdiagnosed for the more pathologic RD or retinoschisis. Due to the similar appearance of these entities, scleral depression alongside UWF SD-OCT can be performed to determine if the retina is intact.

Unlike RDs or retinoschisis, OCT of WWOP and DWOP will reveal a flat lesion without lifting of the neurosensory retina from the RPE, as in an RD, or splitting of the retinal layers, as in a retinoschisis. On OCT, these lesions are correlated with an abrupt change of the photoreceptor reflectivity, with relative hyporeflectivity of photoreceptor zones (ellipsoid and interdigitation zones, as well as outer segments) within the dark lesions and relative hyperreflectivity within the white lesions.<sup>29</sup>

Peripheral cystoid degeneration is another entity that is well captured with peripheral retinal imaging and UWF SD-OCT. Peripheral cystoid degeneration consists of microcystic changes that are present in adult eyes. They are found in the ora serrata and expand posteriorly and circumferentially, increasing as a person ages. More specifically, they are closely packed cystic areas in the inner nuclear and outer plexiform layers of the retina with indistinct boundaries. They are

typically benign, hazy-gray lesions with depressions or cysts but can also lead to a degenerative type of retinoschisis. On SD-OCT, peripheral cystoid degeneration will present with hyporeflective cystoid cavities and columns creating a sawtooth pattern. Many of these cavities and columns span the entire thickness of the neural retina.<sup>21</sup>

## Takeaways

Optometrists play a pivotal role in eye care and can alter the course of myriad sight-threatening diseases our patients suffer from. Visualizing the retinal periphery through the integration of widefield imaging modalities allows for early detection and optimizes the overall prognosis in a variety of conditions. Integrating these technologies into our everyday practice elevates the level of care that we can provide and puts us at the forefront of our profession. ■

1. Keeler CR. The ophthalmoscope in the lifetime of Hermann von Helmholtz. *Arch Ophthalmol.* 2002;120:194-201.
2. Choudhry N, Duker JS, Freund KB, et al. Classification and guidelines for widefield imaging: recommendations from the international widefield imaging study group. *Ophthalmol Retina.* 2019;3:843-9.
3. Bringmann AS, Syrbe K, Gorner J, et al. The primate fovea: structure, function, and development. *Prog Retin Eye Res.* 2018;66:49-84.
4. Rehman I, Mahabadi N, Motlagh M, et al. Anatomy, Head and Neck, Eye Fovea. In: StatPearls [Internet]. Treasure Island (FL): StatPearls Publishing; 2021.
5. Duke-Elder SW. *System of Ophthalmology*, Vol. 11. The Anatomy of the Visual System. St. Louis: Kimpton Publishers; 1976.
6. Hogan MJ. The vitreous, its structure, and relation to the ciliary body and retina. Proctor award lecture. *Invest Ophthalmol.* 1963;2:418-45.
7. Shields CL, Shields JA. Clinical features of small choroidal melanoma. *Curr Opin Ophthalmol.* 2002;13:135-41.

8. Muscat S, Parks S, Kemp E, et al. Secondary retinal changes associated with choroidal nevi and melanomas documented by optical coherence tomography. *Br J Ophthalmol.* 2004;88:120-4.

9. Yung M, Klufas MA, Sarraf D. Clinical applications of fundus autofluorescence in retinal disease. *Int J Retin Vitreol.* 2016;2:12.

10. Staurenghi G, Bottoni F, Giani A. *Retina (Fifth Edition). Clinical Applications of Diagnostic Indocyanine Green Angiography.* WB Saunders; 2013.

11. Shah AR, Abbey AM, Yonekawa Y, et al. Widefield fluorescein angiography in patients without peripheral disease: a study of normal peripheral findings. *Retina.* 2016;36(6):1087-92.

12. Kaneko Y, Moriyama M, Hirahara S, et al. Areas of nonperfusion in peripheral retina of eyes with pathologic myopia detected by ultra-widefield fluorescein angiography. *Invest Ophthalmol Vis Sci.* 2014;55(3):1432-9.

13. Madhusudhan S, Beare N. Wide-field fluorescein angiography in wet age-related macular degeneration. *Scientific World J.* 2014;536161.

14. Wessel MM, Nair N, Aaker GD, et al. Peripheral retinal ischaemia, as evaluated by ultra-widefield fluorescein angiography, is associated with diabetic macular oedema. *Br J Ophthalmol.* 2012;96(5):694-8.

15. Silva PS, Cavallerano JD, Haddad NM, et al. Peripheral lesions identified on ultrawide field imaging predict increased risk of diabetic retinopathy progression over 4 years. *Ophthalmology.* 2015;122(5):949-56.

16. Kimble JA, Brandt BM, McGwin G, Jr. Clinical examination accurately locates capillary nonperfusion in diabetic retinopathy. *Am J Ophthalmol.* 2005;139(3):555-7.

17. Singer M, Tan CS, Bell D, et al. Area of peripheral retinal nonperfusion and treatment response in branch and central retinal vein occlusion. *Retina.* 2014;34(9):1736-42.

18. Hong BK, Khanamiri HN, Rao NA. Role of ultra-widefield fluorescein angiography in the management of uveitis. *Can J Ophthalmol.* 2013;48:489-93.

19. Flaxel CJ, Aldmen RA, Lim JI, et al. Posterior vitreous detachment, retinal breaks, and lattice degeneration PPP 2019. *American Academy of Ophthalmology.*

20. Tsai CY, Hung KC, Wang SW, et al. Spectral-domain optical coherence tomography of peripheral lattice degeneration of myopic eyes before and after laser photocoagulation. *J Formos Med Assoc.* 2019;118:679-85.

21. Choudry N, Golding J, Manry MW, et al. Ultra-widefield steering-based spectral-domain optical coherence tomography imaging of the retinal periphery. *Ophthalmology.* 2016;123:1368-74.

22. Buch H, Vinding T, Nielsen NV. Prevalence and long-term natural course of retinoschisis among elderly individuals: the Copenhagen City Eye Study. *Ophthalmology.* 2007;114:751-5.

23. Madjarov B, Hilton GF, Brinton DA, et al. A new classification of the retinoschisis. *Retina.* 1995;15:282-5.

24. Haiman MH, Burton TC, Brown CK. Epidemiology of retinal detachment. *Arch Ophthalmol.* 1982;100(2):289-92.

25. DiScialfani M, Wagner A, Humphrey W, et al. Pigmentary changes in acquired retinoschisis. *Am J Ophthalmol.* 1988;105:291-3.

26. Shukla SY, Batra NN, Ittiara ST, et al. Reassessment of scleral depression in the clinical setting. *Ophthalmology.* 2015;122(11):2360-1.

27. Stehouwer M, Tan SH, van Leeuwen TG, et al. Senile retinoschisis versus retinal detachment, the additional value of peripheral retinal OCT scans (SL SCAN-1, Topcon). *Acta Ophthalmol.* 2014;92(3):221-7.

28. Zhang T, Wei YT, Huang WB, et al. Prevalence and characteristics of peripheral myopic retinopathy in Guangzhou office workers. *Int J Ophthalmol.* 2018;11(8):1390-5.

29. Fawzi AA, Nielsen JS, Mateo-Montoya A, et al. Multimodal imaging of white and dark without pressure fundus lesions. *Retina.* 2014;34(12):2376-87.

30. Santini B. *Controlling Myopia in Children. Review of Myopia Management.* 2019.

31. Sasaki H, Jonasson F, Kojima M, et al. The Reykjavik Eye Study—prevalence of lens opacification with reference to identical Japanese studies. *Ophthalmologica.* 2000;214(6):412-20.

OPTOMETRIC STUDY CENTER QUIZ

To obtain CE credit through the Optometric Study Center, complete the test form on the following page and return it with the \$35 fee to: Jobson Healthcare Information, LLC, Attn.: CE Processing, 395 Hudson Street, 3rd Floor New York, New York 10014. To be eligible, please return the card within three years of publication. You can also access the test form and submit your answers and payment via credit card online at [revieweducationgroup.com](http://revieweducationgroup.com). You must achieve a score of 70 or higher to receive credit. Allow four weeks for processing. For each Optometric Study Center course you pass, you earn two hours of credit. Please check with your state licensing board to see if this approval counts toward your CE requirement for relicensure.

1. Which regions are the posterior pole made up of?
  - a. Optic nerve head.
  - b. Retinal vascular arcades.
  - c. Macula.
  - d. All of the above.
2. Which structure delineates the photosensitive and non-photosensitive parts of the retina?
  - a. Macula.
  - b. Optic nerve head.
  - c. Ora serrata.
  - d. RPE.
3. Which is the innermost region of the macula?
  - a. Foveola.
  - b. Fovea.
  - c. Parafovea.
  - d. Perifovea.
4. Which is defined as a 1.5mm ring adjacent to the 6mm-diameter macula?
  - a. Ora serrata.
  - b. Middle periphery.
  - c. Near periphery.
  - d. Far periphery.
5. Which is a diagnostic modality that provides noninvasive, cross-sectional views of the retina, choroid, optic nerve and surrounding structures?
  - a. FAF.
  - b. Confocal scanning laser polarimetry (GDx).
  - c. Retinal tomography (HRT II).
  - d. SD-OCT.
6. Which features are suggestive of an ocular malignancy?
  - a. Greater than 2mm of anterior-posterior thickness.
  - b. Subretinal fluid.
  - c. Overlying non-drusenoid retinal changes.
  - d. All of the above.
7. Which noninvasive imaging technology can be used to evaluate the metabolic activity of the photoreceptor cells and the RPE?
  - a. SD-OCT.
  - b. Confocal scanning laser polarimetry (GDx).
  - c. FAF.
  - d. Retinal tomography (HRT II).
8. With FAF imaging in normal eyes, hypofluorescence is expected in which area(s)?
  - a. Fovea.
  - b. Optic nerve head.
  - c. Retinal blood vessels.
  - d. All of the above.
9. In which conditions would you expect to see an excessive buildup of lipofuscin on FAF?
  - a. Stargardt's disease.
  - b. Best's disease.
  - c. Choroideremia.
  - d. Both a and b.
10. The dye used in which test emits a shorter wavelength to image the retina than ICG angiography?
  - a. FAF.
  - b. SD-OCT.
  - c. Fundus FA.
  - d. Confocal scanning laser polarimetry (GDx).
11. With which refractive error are patients expected to have large areas of capillary nonperfusion compared with emmetropic eyes on widefield FA?
  - a. Myopia.
  - b. Hyperopia.
  - c. Astigmatism.
  - d. Presbyopia.
12. Which peripheral retinal finding is characterized by an area of localized thinning with vitreoretinal adhesion at the borders with overlying vitreous liquefaction?
  - a. Senile retinoschisis.
  - b. Lattice degeneration.
  - c. WWOP.
  - d. Peripheral cystoid degeneration.
13. Which is the approximate prevalence of senile retinoschisis?
  - a. 1%.
  - b. 7% to 10%.
  - c. 4%.
  - d. 25%.
14. Often, vitreoretinal traction seen in the posterior pole can be difficult to appreciate ophthalmoscopically. Which test could readily confirm the traction?
  - a. Fundus photography.
  - b. FAF.
  - c. SD-OCT.
  - d. Corneal topography.
15. Which retinal finding on SD-OCT will appear with hyporeflective cavities and columns, creating a sawtooth pattern?
  - a. Peripheral cystoid degeneration.
  - b. WWOP.
  - c. RD.
  - d. Retinal hole.
16. Which additional procedure should be done when differentiating between retinoschisis and an RD?
  - a. Red-free filter assessment.
  - b. Scleral depression.
  - c. Tear osmolarity.
  - d. None of the above.
17. All are likely causes of rhegmatogenous RD except which of the following?
  - a. Hyperopia.
  - b. Hereditary and environmental factors.
  - c. Posterior vitreous detachment.
  - d. Trauma.
18. Which is the approximate incidence of an RD?
  - a. 1 in 10.
  - b. 1 in 100.
  - c. 1 in 1,000.
  - d. 1 in 10,000.
19. In which two quadrants is lattice degeneration more present?
  - a. Inferior and superior.
  - b. Superior and temporal.
  - c. Temporal and nasal.
  - d. Nasal and superior.
20. Possible presence of late leakage in diabetic patients with widefield FA correlates with which two findings?
  - a. Optic nerve cupping and intraretinal microvascular abnormalities.
  - b. Intraretinal microvascular abnormalities and macular edema.
  - c. Macular edema and neovascularization.
  - d. Neovascularization and optic nerve cupping.

# Examination Answer Sheet

## Peripheral Retinal Imaging and Disease Assessment

Valid for credit through February 15, 2025

**Online:** This exam can be taken online at [revieweducationgroup.com](http://revieweducationgroup.com). Upon passing the exam, you can view your results immediately and download a real-time CE certificate. You can also view your test history at any time from the website.

**Directions:** Select one answer for each question in the exam and completely darken the appropriate circle. A minimum score of 70% is required to earn credit.

**Mail to:** Jobson Healthcare Information, LLC, Attn.: CE Processing, 395 Hudson Street, 3rd Floor New York, New York 10014.

**Payment:** Remit \$35 with this exam. Make check payable to Jobson Healthcare Information, LLC.

**Credit:** This course is COPE-approved for two hours of CE credit. Course ID 76573-TD.

**Processing:** There is a four-week processing time for this exam.

Jointly provided by PIM and the Review Education Group.  
Salus University has sponsored the review and approval of this activity.

### Answers to CE exam:

1.  A  B  C  D
2.  A  B  C  D
3.  A  B  C  D
4.  A  B  C  D
5.  A  B  C  D
6.  A  B  C  D
7.  A  B  C  D
8.  A  B  C  D
9.  A  B  C  D
10.  A  B  C  D
11.  A  B  C  D
12.  A  B  C  D
13.  A  B  C  D
14.  A  B  C  D
15.  A  B  C  D
16.  A  B  C  D
17.  A  B  C  D
18.  A  B  C  D
19.  A  B  C  D
20.  A  B  C  D

### Post-activity evaluation questions:

Rate how well the activity supported your achievement of these learning objectives. 1=Poor, 2=Fair, 3=Neutral, 4=Good, 5=Excellent

21. Discuss peripheral retinal imaging and disease assessment. ① ② ③ ④ ⑤
22. Use OCT imaging to differentiate peripheral retinal lesions and degenerations. ① ② ③ ④ ⑤
23. Recognize what these conditions look like on OCT imaging and other observational techniques. ① ② ③ ④ ⑤
24. Review what conditions can arise in the peripheral retina. ① ② ③ ④ ⑤
25. Diagnose peripheral retinal lesions and initiate management. ① ② ③ ④ ⑤
26. Based upon your participation in this activity, do you intend to change your practice behavior? (Choose only one of the following options.)  
 A I do plan to implement changes in my practice based on the information presented.  
 B My current practice has been reinforced by the information presented.  
 C I need more information before I will change my practice.
27. Thinking about how your participation in this activity will influence your patient care, how many of your patients are likely to benefit? (please use a number):
28. If you plan to change your practice behavior, what type of changes do you plan to implement? (Check all that apply.)  
 A Apply latest guidelines  D Change in current practice for referral  G More active monitoring and counseling  
 B Change in diagnostic methods  E Change in vision correction offerings  H Other, please specify: \_\_\_\_\_  
 C Choice of management approach  F Change in differential diagnosis
29. How confident are you that you will be able to make your intended changes?  
 A Very confident  B Somewhat confident  C Unsure  D Not confident
30. Which of the following do you anticipate will be the primary barrier to implementing these changes?  
 A Formulary restrictions  D Insurance/financial issues  G Patient adherence/compliance  
 B Time constraints  E Lack of interprofessional team support  H Other, please specify: \_\_\_\_\_  
 C System constraints  F Treatment related adverse events
31. Additional comments on this course: \_\_\_\_\_

Please retain a copy for your records. Please print clearly.

First Name

Last Name

E-Mail

The following is your:  Home Address  Business Address

Business Name

Address

City  State

ZIP

Telephone #  -  -

Fax #  -  -

OE Tracker Number

### Rate the quality of the material provided:

1=Strongly disagree, 2=Somewhat disagree,  
3=Neutral, 4=Somewhat agree, 5=Strongly agree

32. The content was evidence-based.

① ② ③ ④ ⑤

33. The content was balanced and free of bias.

① ② ③ ④ ⑤

34. The presentation was clear and effective.

① ② ③ ④ ⑤

By submitting this answer sheet, I certify that I have read the lesson in its entirety and completed the self-assessment exam personally based on the material presented. I have not obtained the answers to this exam by any fraudulent or improper means.

Signature \_\_\_\_\_ Date \_\_\_\_\_ Lesson 122384 RO-OSC-0222





EDITED BY JOSEPH P. SHOVLIN, OD

## CORNEA AND CONTACT LENS Q+A

# Using CXL as 'Bug Killer'

*When meds alone don't bring resolution, consider photodynamic therapy with rose bengal and UV-A.*

**Q** One of my contact lens patients has a severe *Pseudomonas* infection with scleral extension. What options are available to salvage the eye?

**A** Colleagues Anat Galor, MD, MSPH, and Guillermo Amescua, MD, of the Bascom Palmer Eye Institute, draw on their clinical knowledge and expertise to dissect the findings of a similar case they saw and offer a solution for affected patients.

cin and ciprofloxacin, so the vancomycin and oral antibiotics, the infiltrate and corneal thinning worsened.

Prednisolone acetate 1% eye drops were started twice daily to address the inflammation, but the infection continued to progress. As such, the patient underwent rose bengal photodynamic antimicrobial therapy (RB-PDAT) four days after presenting and saw immediate improvement in pain.

Over the next few weeks, the infiltrate condensed and re-epithelialization slowly occurred with the help of autologous serum tears. A subconjunctival triamcinolone injection was given due to pupillary membrane formation.

After 2.5 months, the epithelium was fully healed with an underlying large corneal scar and the fibrous process in the anterior chamber had

resolved. However, BCVA remained count fingers. Five months later, the patient underwent a PKP, iris synchiolysis, cataract extraction and IOL placement. Fortunately, BCVA eight months post-surgery was 20/25 and IOP was normal.

### Treatment Option

During the last decade, CXL has been proposed as an adjuvant treatment for infectious keratitis. The initial treat-

ment consisted of riboflavin as the photosensitizing agent coupled with UVA light, an approach used to manage progressive keratoconus.

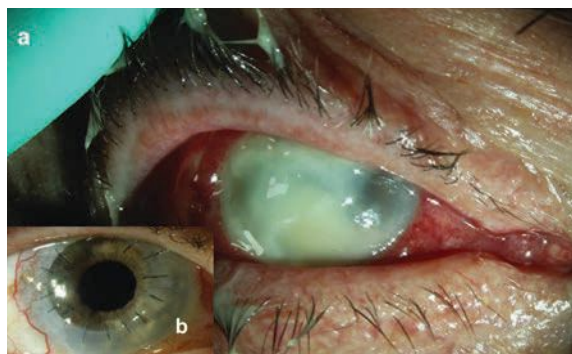
Drs. Galor and Amescua evaluated rose bengal as the photosensitizing agent activated by a green fluorescent light built by their bioengineering team and found it to be more efficient at killing bacteria and fungi *in vitro* than riboflavin.<sup>1</sup> The duo thus started using this therapy in patients with severe keratitis that was unresponsive to medical therapy.

RB-PDAT involves the topical application of rose bengal 0.1% to the de-epithelized cornea for 30 minutes followed by 15 minutes of irradiation provided by a custom-made LED light source (525nm) for a total energy of 5.4J/cm<sup>2</sup>. The proposed mechanism of action in keratitis is that photosensitization stimulates energy transfer to nearby triplet oxygen molecules, which results in the formation of reactive oxygen species (ROS) such as a singlet oxygen molecule. ROS interact with surrounding organic compounds in cells and tissues to produce a variety of effects, including eradication of a wide array of bacteria and fungi. In addition, stiffening of the collagen fibers may portend resistance to enzymatic degradation and slow corneal melting.

Drs. Galor and Amescua have had promising outcomes with RB-PDAT, coupled with medical therapy, in treating cases of severe bacterial and fungal infections. Fortunately, in patients who later undergo a PKP, they note that outcomes are generally excellent.<sup>2</sup> ■

1. Arboleda A, Miller D, Cabot F, et al. Assessment of rose bengal versus riboflavin photodynamic therapy for inhibition of fungal keratitis isolates. *Am J Ophthalmol.* 2014;158(1):64-70.

2. Naranjo A, Arboleda A, Martinez JD, et al. Rose bengal photodynamic antimicrobial therapy for patients with progressive infectious keratitis: a pilot clinical study. *Am J Ophthalmol.* 2019;208:387-96.





***Pseudomonas* keratitis with associated stromal necrosis and hypopyon and early involvement of superotemporal scleral tissue (a). Clean and compact corneal graft with intact corneal epithelium and quiet ocular surface (b).**

### Case Presentation

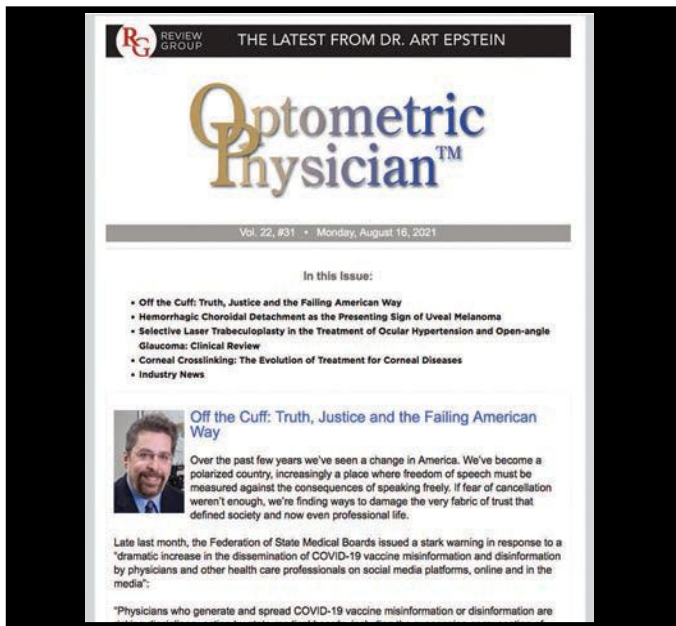
A 76-year-old white male presented with a four-day history of pain and redness OD. He had a large corneal ulcer extending to the temporal sclera with severe thinning of the cornea and a large hypopyon. He was started on hourly topical antibiotics (vancomycin 25mg/ml, tobramycin 14mg/ml and ciprofloxacin 0.3%) and oral ciprofloxacin 500mg BID. Cultures showed *Pseudomonas aeruginosa* sensitive to tobramycin

About Dr. Shovlin

**Dr. Shovlin**, a senior optometrist at Northeastern Eye Institute in Scranton, PA, is a fellow and past president of the American Academy of Optometry and a clinical editor of *Review of Optometry* and *Review of Cornea & Contact Lenses*. He consults for Kala, Aerie, AbbVie, Novartis, Hubble and Bausch + Lomb and is on the medical advisory panel for Lentechs.



## Read the Latest from Dr. Art Epstein



If you aren't already a subscriber, please be sure to sign up for Dr. Art Epstein's weekly e-journal, *Optometric Physician*, distributed by *Review of Optometry*.

Join the thousands of ODs, MDs and ophthalmic industry readers who turn to *Optometric Physician* each week for Dr. Epstein's very direct—and sometimes controversial—take on eye care and the world. You will also keep up with the latest, most relevant clinical studies, condensed and curated for quick reference, as well as a current digest of industry news.

Visit: **JMI | Newsletter Signup**  
[www.jhihealth.com/globalemail/](http://www.jhihealth.com/globalemail/)  
to sign up for *Optometric Physician*, and other e-newsletters distributed by Jobson Medical Information.

### OPTOMETRIC PHYSICIAN:

**Reaches 42,000 ODs weekly**

**Content:** Clinical information & Industry news

**Metrics:** 18.45% average opens

### FOR ADVERTISING OPPORTUNITIES, PLEASE CONTACT

**Michael Hoster:** Mhoster@jobson.com  
610-492-1028

**Michele Barrett:** Mbarrett@jobson.com  
215-519-1414

**Jon Dardine:** Jdardine@jobson.com  
610-492-1030



BY JOSEPH W. SOWKA, OD

## THERAPEUTIC REVIEW

# Down in the Basement

*Numerous options exist to ameliorate symptoms and visually rehabilitate eyes with corneal dystrophies.*

**A** 75-year-old woman presented with a complaint of an abrupt blurring of vision in her right eye while working on her computer two days earlier. She reported a dryness and scratchiness in the eye as well. Her uncorrected visual acuity in her right eye was 20/80 with pinhole improvement to 20/50. She manifested no relative afferent pupillary defect, and her examination was normal, save for corneal epithelial positive and negative staining in an amoeboid pattern. There was a similar appearance in her left eye, though much less notable. The diagnosis was anterior membrane dystrophy, and her visual symptoms were adequately explained by her poor ocular surface.

### On the Map

Anterior basement membrane dystrophy, also known as epithelial basement membrane dystrophy (EBMD), map-dot-fingerprint corneal dystrophy and Cogan's microcystic dystrophy, is one of the more commonly encountered corneal abnormalities in clinical practice.<sup>1</sup> Typically, it develops in adults between the ages of 20 and 40.<sup>2</sup> While EBMD is a bilateral disorder, some patients may show marked asymmetry.

EBMD is often described as map-dot-fingerprint dystrophy because of its classic biomicroscopic signs—"maps" (amorphous, grayish-white geographic areas often containing oval lacunae), "dots" (focal, grayish-white, round or comma-shaped opacities) and "fingerprints" (clusters of irregular concentric lines) within the cornea.

The instillation of sodium fluorescein dye helps delineate these areas, showing mostly negative staining in association with the tissue elevation created by the "maps and dots."

Patients with EBMD are often asymptomatic, while others experience intermittent or constant blurred vision, fluctuating vision, "ghosting" (*i.e.*, monocular diplopia) or glare. Others still may report photophobia or a foreign body sensation. Advanced cases may be predisposed toward developing a recurrent corneal erosion characterized by a periodic history of awakening with profound eye pain, blurred vision, blepharospasm or tearing.<sup>1-5</sup>

Some have classified EBMD not as a dystrophy but rather as a form of corneal degeneration.<sup>6</sup> The corneal basement membrane adheres, via hemidesmosomal junctions, to Bowman's layer, just anterior to the corneal stroma. Individuals with EBMD manifest a dysfunctional basement membrane, which becomes hypertrophied and misdirected.<sup>2</sup> The basal cells in these patients manufacture aberrant projections that protrude from an abnormally thickened basement membrane into the superficial epithelium, resulting in the classic clinical findings.<sup>1,2</sup>

In addition to inducing visible changes in the cornea, the structural alterations associated with EBMD can result in impaired adherence of the overlying epithelium, prompting focal, intermittent "sloughing" of epithelial sheets.<sup>3,5,7</sup>

### Treatment

EBMD does not generally require intervention. For asymptomatic patients, periodic evaluation of the corneal changes usually suffices. This may be done in a variety of ways, but anterior segment photography and/or corneal topography helps provide objective documentation.

Most patients' symptoms related to EBMD are similar to dry eye complaints. Ocular lubricants may help alleviate intermittent visual disturbances or discomfort. More substantial disease may warrant hypertonic agents, as these help to deturgesce the epithelium and enhance the cellular adhesion between the epithelial cells and underlying stroma.<sup>3,8</sup> An alternative to hypertonic solutions is FreshKote (Eyevance Pharmaceuticals, now a part of Santen), a non-prescription ocular lubricant that contains colloidal particles of rather large molecular weight that impart a high oncotic pressure. This agent may work in a similar capacity to hypertonic salt solutions, but with better overall lubrication and without the associated stinging upon instillation.

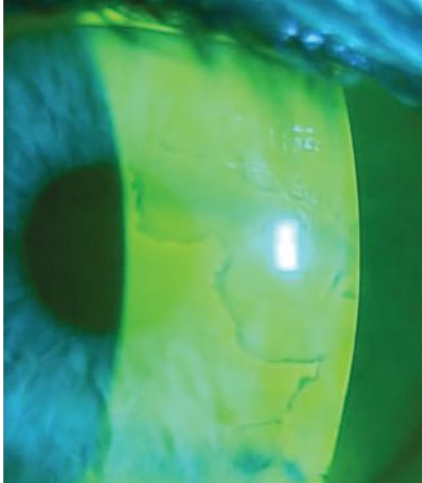
Contact lenses also have been used to resurface the irregular epithelium and overcome any accompanying visual disturbances.<sup>3</sup> Both soft and rigid lenses may be used in this capacity; however, select a material with a high Dk/t to minimize corneal edema. Patients with visual symptoms may also be treated via prophylactic epithelial debridement. A study involving 74 eyes of 55 patients treated over 15 years showed that simple manual debridement helped improve visual acuity by at least one Snellen line and diminish the incidence of recurrences.<sup>9</sup>

For patients who suffer from corneal erosions, acute care involves removal of the loose epithelium, topical cycloplegia, prophylactic topical antibiotics and

About  
Dr. Sowka

Dr. Sowka is an attending optometric physician at Center for Sight in Sarasota, FL, where he focuses on glaucoma management and neuro-ophthalmic disease. He is a consultant and advisory board member for Carl Zeiss Meditec and Bausch Health.





**The instillation of sodium fluorescein dye helps delineate maps and dots associated with EBMD by showing negative staining.**

oral or topical nonsteroidal anti-inflammatory agents as needed for pain. Bandage contact lenses often help facilitate re-epithelialization.<sup>8,10,11</sup>

Following resolution of the erosion, take steps to protect the eye while sleeping to prevent recurrences. Ointments, both bland and hypertonic, can prevent abrupt detachment of the epithelium upon awakening.<sup>3,12,13</sup> Likewise, sleep masks or goggles and nocturnal bandaging help prevent unconscious ocular trauma that could initiate a spontaneous erosion.

Those who do not respond to conservative management strategies may require more intensive therapy. Noninvasive treatment may involve pharmaceutical agents that mitigate the effects of matrix metalloproteinase. The combination of oral doxycycline 50mg BID and a topical steroid such as prednisolone acetate 1% or fluorometholone 0.1% TID has been effective in reducing symptoms associated with recurrent erosion.<sup>14,15</sup>

An advanced but still noninvasive option for recalcitrant cases is an amniotic membrane. This supportive therapy can greatly help regenerate corneal irregularities and provide a comfortable and visually clear surface.<sup>16,17</sup>

Another option that has been shown to ameliorate symptoms and visually rehabilitate eyes with EBMD is autologous serum tears. These tears are

specially formulated from a patient's own serum derived from blood drawn in a lab, formulated at 20% to 40% concentration and used four to eight times per day, depending upon severity. Autologous serum tears provide nutrients and growth factors not found in commercially available artificial tears and have wide applications for dry eye and other ocular surface disorders.<sup>18,19</sup>

Stromal puncture can manage recurrent corneal erosions by initiating scar formation at the level of the basement membrane, which can facilitate better adhesion between the epithelium and corneal stroma.<sup>13,20</sup> Using a 25-gauge needle under topical anesthesia, the clinician places 0.1mm-deep perforations, breaching Bowman's membrane at 0.25mm intervals, within the area of concern. This technique can also be achieved using the Nd:YAG laser.<sup>21</sup>

Other surgical options include superficial keratectomy using a diamond burr and excimer laser phototherapeutic keratectomy.<sup>21-24</sup> These two techniques appear to have similar efficacy, though diamond burr treatment reportedly has less of a tendency to induce secondary corneal haze and recurrence.<sup>25,26</sup>

### Takeaways

The patient presented here deferred an amniotic membrane and autologous serum tears in favor of more conservative therapy. She was prescribed non-preserved artificial tears and a hypertonic saline drop, both to be used QID in the affected eye. She returned two weeks later with some improvement in vision and appearance but found the hypertonic saline uncomfortable. The saline and tears were replaced by FreshKote to be used six times daily. She missed her follow-up appointment but relayed over the phone that she was seeing and feeling better and would return if she developed any further problems. ■

1. Labbe A, Nicola RD, Dupas B, et al. Epithelial basement membrane dystrophy: evaluation with the HRT II Rostock Cornea Module. *Ophthalmology*. 2006;113(8):1301-8.
2. Kobayashi A, Yokogawa H, Sugiyama K. In vivo laser confocal microscopy findings in patients with map-dot-fingerprint (epithelial basement membrane) dystrophy. *Clin Ophthalmol*. 2012;6:1187-90.

3. Laibson PR. Recurrent corneal erosions and epithelial basement membrane dystrophy. *Eye Contact Lens*. 2010;36(5):315-7.
4. Itty S, Hamilton SS, Baratz KH, et al. Outcomes of epithelial debridement for anterior basement membrane dystrophy. *Am J Ophthalmol*. 2007;144(2):217-21.
5. Payant JA, Eggenberger LR, Wood TO. Electron microscopic findings in corneal epithelial basement membrane degeneration. *Cornea* 1991;10(5):390-4.
6. Sayegh RR, Kouyoumjian PB, Vedula GG, et al. Cocaine-assisted epithelial debridement for the treatment of anterior basement membrane dystrophy. *Cornea*. 2013;32(6):889-92.
7. Bozkurt B, Irkec M. In vivo laser confocal microscopic findings in patients with epithelial basement membrane dystrophy. *Eur J Ophthalmol*. 2009;19(3):348-54.
8. Watson SL, Lee MH, Barker NH. Interventions for recurrent corneal erosions. *Cochrane Database Syst Rev*. 2012;9:CD001861.
9. Itty S, Hamilton SS, Baratz KH, et al. Outcomes of epithelial debridement for anterior basement membrane dystrophy. *Am J Ophthalmol*. 2007;144(2):217-21.
10. Fraunfelder FW, Cabezas M. Treatment of recurrent corneal erosion by extended-wear bandage contact lens. *Cornea*. 2011;30(2):164-6.
11. Moutray TN, Frazer DG, Jackson AJ. Recurrent erosion syndrome—the patient's perspective. *Cont Lens Anterior Eye*. 2011;34(3):139-43.
12. Hykin PG, Foss AE, Pavesio C, Dart JK. The natural history and management of recurrent corneal erosion: a prospective randomised trial. *Eye*. 1994;8(Pt 1):35-40.
13. Ramamurthi S, Rahman MQ, Dutton GN, Ramaesh K. Pathogenesis, clinical features and management of recurrent corneal erosions. *Eye (Lond)*. 2006;20(6):635-44.
14. Wang L, Tsang H, Coroneo M. Treatment of recurrent corneal erosion syndrome using the combination of oral doxycycline and topical corticosteroid. *Clin Exp Ophthalmol*. 2008;36(1):8-12.
15. Dursun D, Kim MC, Solomon A, Pflugfelder SC. Treatment of recalcitrant recurrent corneal erosions with inhibitors of matrix metalloproteinase-9, doxycycline and corticosteroids. *Am J Ophthalmol*. 2001;132(1):8-13.
16. Kotomin I, Valtink M, Hofmann K, et al. Sutureless fixation of amniotic membrane for therapy of ocular surface disorders. *PLoS One*. 2015;10(5):e0125035.
17. Miller DD, Hasan SA, Simmons NL, Stewart MW. Recurrent corneal erosion: a comprehensive review. *Clin Ophthalmol*. 2019;13:325-335.
18. Lee JH, Kim MJ, Ha SW, Kim HK. Autologous platelet-rich plasma eye drops in the treatment of recurrent corneal erosions. *Korean J Ophthalmol*. 2016;30(2):101-7.
19. Azari AA, Rapuano CJ. Autologous serum eye drops for the treatment of ocular surface disease. *Eye Contact Lens*. 2015 May;41(3):133-40.
20. Malecha MA. Anterior stromal puncture for recurrent corneal erosion after laser in situ keratomileusis. *J Cataract Refract Surg*. 2004;30(2):496-8.
21. Tsai TY, Tsai TH, Hu FR, Hou YC. Recurrent corneal erosions treated with anterior stromal puncture by neodymium: yttrium-aluminum-garnet laser. *Ophthalmology*. 2009;116(7):1296-300.
22. Tzelikis PF, Rapuano CJ, Hammersmith KM, et al. Diamond burr treatment of poor vision from anterior basement membrane dystrophy. *Am J Ophthalmol*. 2005;140(2):308-10.
23. Ryan G, Lee GA, Maccheron L. Epithelial debridement with diamond burr superficial keratectomy for the treatment of recurrent corneal erosion. *Clin Experiment Ophthalmol*. 2013;41(6):621-2.
24. van Westenbrugge JA. Small spot phototherapeutic keratectomy for recurrent corneal erosion. *J Refract Surg*. 2007;23(7):721-4.
25. Pogorelov P, Langenbacher A, Kruse F, Seitz B. Long-term results of phototherapeutic keratectomy for corneal map-dot-fingerprint dystrophy (Cogan-Guerry). *Cornea*. 2006;25(7):774-7.
26. Sridhar MS, Rapuano CJ, Cosar CB, et al. Phototherapeutic keratectomy versus diamond burr polishing of Bowman's membrane in the treatment of recurrent corneal erosions associated with anterior basement membrane dystrophy. *Ophthalmology* 2002; 109(4):674-9.



BY JAMES L. FANELLI, OD

## GLAUCOMA GRAND ROUNDS

# That Time of Year

*After the holidays come insurance coverage changes.*

**A** 72-year-old Caucasian female presented in November 2021 for a glaucoma progress evaluation as scheduled. She reported good compliance with her meds.

### Case

She was initially seen as a new patient in the summer of 2018 with complaints of blurred vision OU. At that time, it had been approximately five years since her last visit to an eye care provider. Entering visual acuities were 20/40 OD and 20/60 OS. Best-corrected visual acuities through hyperopic astigmatic correction were 20/20 OD and 20/60 OS. Pupils were ERRLA, with a subtle APD noted OS. EOMs were full in all positions of gaze.

A slit lamp examination of the anterior segments was remarkable for slightly narrowed anterior chamber angles. Otherwise, the anterior segments were unremarkable. Gonioscopy demonstrated similar findings with slightly narrowed angles; on indentation gonioscopy, the angles were eas-

ily opened further. It was deemed that the patient was safe to dilate. Prior to dilation, applanation tensions were 19mm Hg OD and 24mm Hg OS.

Through dilated pupils, the crystalline lenses were characterized by mild nuclear sclerosis OD and slightly more advanced nuclear cataracts OS. Bilateral PVDs were present. The patient's cup-to-disc ratios were judged to be 0.40x0.45 OD and 0.85x0.90 OS, with the left neuroretinal rim quite thinned temporally and eroded inferotemporally. A subtle wedge defect was seen clinically.

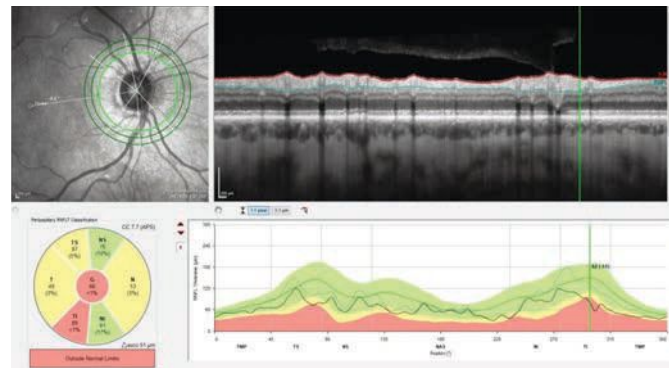
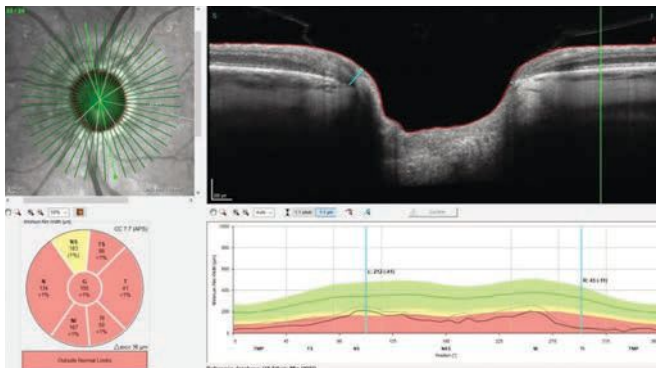
Her macular evaluations were essentially normal, with age-appropriate RPE granulation. Her retinal vascular examination was characterized by mild arteriolar sclerosis, consistent with her age and general health history of hypertension and hyperlipidemia, which was controlled by a calcium channel blocker and a statin. Her peripheral retinal evaluation was entirely normal. Fundus photos were obtained and, given the likelihood of glaucomatous damage, she was

schedule for a follow-up in one to two weeks for a full glaucoma work-up.

She presented as scheduled, and her IOPs were essentially the same. Pachymetry readings were 562µm OD and 525µm OS. HRT 3 findings confirmed optic cupping asymmetry, and OCT baseline scans demonstrated a normal series of findings in the right eye, but thinned BMO-MRW values in the left, along with thinning of the circumpapillary RNFL tissue at three circle scan diameters. These OCT findings correlated with the clinical *in vivo* findings seen at the slit lamp.

Based on the findings, glaucoma was diagnosed in the left eye, with the right at that time being diagnosed only as suspect. Travatan Z (travoprost, Novartis) one drop HS OS was initiated, and the patient was asked to return for follow-up in about two to three weeks to assess the efficacy of the medical therapy and obtain baseline visual field studies.

The patient presented as asked. Applanation tensions were 17mm Hg OD and 15mm Hg OS. There were no localized inflammatory side effects from the medication in the left eye, and she reported good compliance. Threshold visual field studies were essentially clear OD. The left demonstrated above and below arcuate



Progression can be seen in the damage to the neuroretinal rim OS.

Changes in peripapillary RNFL indicate conversion to frank glaucoma.

### About Dr. Fanelli

Dr. Fanelli is the founder and director of the Cape Fear Eye Institute in Wilmington, NC. He is chairman of the EyeSki Optometric Conference and the CE in Italy/Europe Conference. He is an adjunct faculty member of PCO, Western U. and UAB School of Optometry. He is on advisory boards for Heidelberg Engineering and Glaukos.

defects, with fixation involvement in the superior field. UBM studies of the anterior chamber angles demonstrated classic findings of plateau iris configuration OS>OD. Best-corrected visual acuities remained at 20/20 OD and 20/60 OS.

## Progression

While the initial response to the Travatan Z was encouraging, stability of glaucoma that is medicated cannot be determined over one or two visits. In fact, it needs to be continually assessed at each follow-up, as the condition may progress in spite of therapy. So, in essence, especially in new patients such as this one, there should be a period of close assessment to ensure that the patient is in fact stabilized. During this period, both structural and functional testing is repeated to determine stability. And of course, as in cases such as this where there is significantly advanced disease, there is a higher likelihood that the more advanced eye will progress to a greater extent than the fellow, less advanced eye.

Over the subsequent 18-month period, there were some adjustments to the patient's medication schedule, and ultimately, she was also put on medication in her right eye, as subtle changes were seen on OCT. Due to the decreased acuity in the left eye and the cataract being somewhat denser than the right, we opted to proceed with cataract surgery. The procedure was performed without complication and two iStents (Glaukos) were implanted into the left nasal anterior chamber angle. Unfortunately, visual acuity was not significantly improved with cataract extraction, owing to the visual field defects OS that involved fixation.

As far as glaucoma stability was concerned, several adjustments were made to her medications during this period until we were finally able to develop a therapeutic combination that resulted in stability. Usually, but not always, once I feel comfortable that the patient has been stabilized, we tend to space out our follow-up visits so they don't become a burden to the

patient. That said, each follow-up is still accompanied by the appropriate testing needed to ensure stability and no further progression. After much time and effort, we finally got to that point.


And then COVID-19 hit and interfered with patient care. Unfortunately, for the better part of 2020, the patient did not feel comfortable coming into the office for follow-up visits, but we did stay in communication, her medications were refilled appropriately and she reported good compliance with no overt changes to her vision.

When she did finally present to the office in January 2021, IOPs were 18mm Hg OD and 19mm Hg OS. Unfortunately, there was documented progression of neuroretinal rim and RNFL thinning. IOPs over the next two visits averaged 15mm Hg OD and 18mm Hg OS. Given the amount of damage that was present in the left eye, these IOPs were not at an adequate level to prevent further damage. We discussed options regarding medication modification, SLT and surgical intervention. Jointly, we decided to explore a medication change to the left eye to bring about stability, with the understanding that surgery may be likely.

Fortunately, we were able to obtain a significant decrease in pressure OD and OS with a change involving a nitrous oxide inhibitor. Visual fields, OCTs and HTR 3 studies performed throughout the second half of the year demonstrated no change or progression. We were finally back at the point where I felt she was stable enough to spread out her visits.

## Discussion

It's a relief to the provider and certainly to the patient when we reach that point of relative stability. Though it may not last forever, it does give us some breathing room. However, what happens at the end of the year to our Medicare Part D patients who are on chronic medical therapy? They get notified that the cost of their medica-



Note the paucity of the ganglion cell layer in the macula OS.

tions is changing, and usually not for the better. And that is exactly what the patient told me in December: her medication costs were changing, and she would not be able to afford one of the two medications that were keeping her stable.

A frustrating situation for the patient and myself indeed. The patient is finally stable, but then an insurance issue interferes with patient care. What do you do? These situations are difficult, and this patient was educated previously that surgical intervention may be in her future. Can you argue with the insurance company? Sure, just like you can argue with a stop sign. Can the patient change their coverage? Yes, and many do play the year-end game of looking for a plan that better covers their medications, but what is going to happen next year? The same thing, of course.

With some commercial insurances that require prior authorization, sometimes using the wording, "the patient will undisputedly lose vision without XYZ medication," is enough to give the patient access to the medication they need. With Medicare, unfortunately, that usually does not work.

Who gets shorted in these situations? The patient, of course. Our job is to provide the best care we can, in spite of the hurdles in our way. So, we figure out a way. How you proceed depends on several factors, as each case is different, but we proceed nonetheless. ■





# Crystal... Not So Clear

Going through this patient's medical history proved to be key in finding the correct diagnosis.

BY FAREESA SIDDIQUI, OD  
MIAMI

**A** 74-year-old Hispanic female presented for a comprehensive eye exam complaining of blurry vision, worse in her left eye. She believed this was due to glue she had used previously to repair her eyeglass frames.

Her best-corrected visual acuity was 20/40 OD and 20/50 OS and her potential acuity pinhole (PAP) VA was 20/30 OD and 20/50 OS. Her slit lamp exam revealed mild blepharitis and conjunctival chalasis OU. She had 2+ nuclear sclerosis and trace cortical cataracts OD and 1+ NS with trace cortical cataract OS. Her dilated fundus exam of the right eye appeared normal and the left eye showed lesions in the macula (Figures 1 and 2).

An OCT was performed and is available for review (Figure 3). Humphrey Field Analyzer 10-2 testing showed central defects OU (Figures 4 and 5). Color vision testing with Ishihara plates was performed and

was essentially normal (11/12 plates OD and 9/12 plates OS).

## Take the Retina Quiz

1. What do the yellow lesions seen in the fundus photo of the left eye represent?

- a. Exudates.
- b. Emboli
- c. Drusen
- d. Crystalline deposits.

2. How would you interpret the OCT findings in our patient?

- a. Normal.
- b. Disruption of the IS/OS junction.
- c. Focal superficial hyperreflective lesions.
- d. Both b and c.

3. What is the correct diagnosis for our patient?

- a. Idiopathic macular telangiectasia.
- b. Tamoxifen toxicity.
- c. Multiple evanescent white dot syndrome (MEWDS).
- d. Cystinosis.

4. What is the most likely cause of the patient's decreased PAP VA?

- a. Crystalline deposits.
- b. Disruption in IS/OS junction.
- c. Macular edema.
- d. Cataracts.

For answers, see page 106.

## Diagnosis

There was no doubt our patient has nuclear sclerotic cataracts in both eyes, but is that the reason for her reduced acuity? In the right eye, the cataract was indeed worse and possibly consistent with her visual acuity (20/40), but the cataract in the left eye was clearly not as bad. We graded the nuclear sclerosis in the OS at only 1+, and though there were cortical lens changes, the cataract did not account for 20/50 visual acuity. So, is there something else going on with our patient?

Examination of her macula did provide some important clues. Though the macula in her right eye appeared normal, there were multiple intraretinal crystals present in the macula in her left eye. What's more, there were also some interesting OCT findings that proved to be relevant. In both eyes, there were superficial hyperreflective retinal deposits and disruption in the inner segment-outer photoreceptor segment (IS/OS) junction. Interestingly, the findings in the right eye were not visible on funduscopy and only became apparent with OCT.

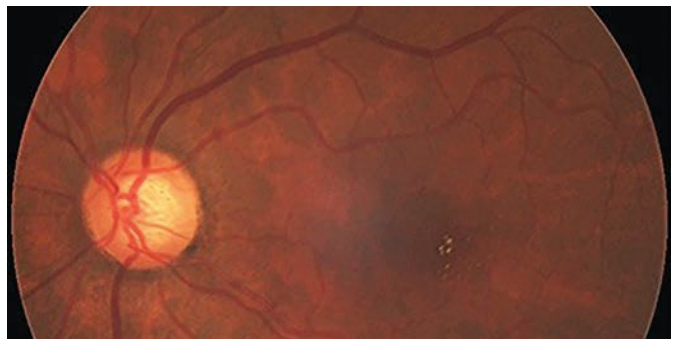
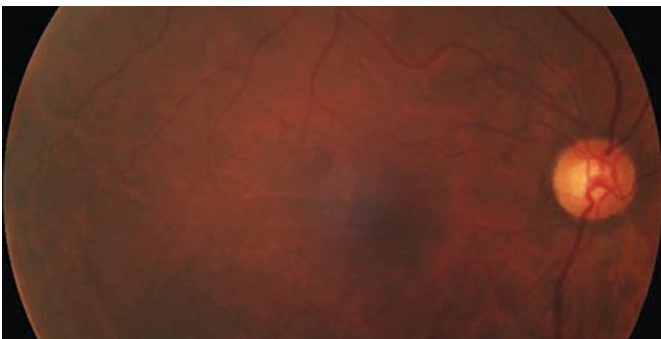


Fig. 1 and 2. Fundus photos of the right and left retina eyes. What do you see in her macula?

### About Dr. Dunbar

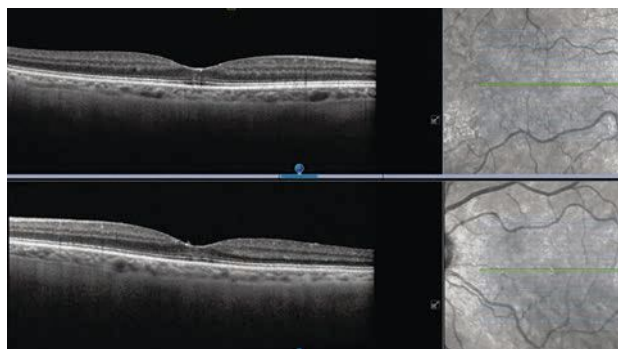
Dr. Dunbar is the director of optometric services and optometry residency supervisor at the Bascom Palmer Eye Institute at the University of Miami. He is a founding member of the Optometric Glaucoma Society and the Optometric Retina Society. Dr. Dunbar is a consultant for Carl Zeiss Meditec, Allergan, Regeneron and Genentech.

Given this finding, we went back through our patient's medical history and recalled that she had a history of breast cancer and was being treated with tamoxifen 20mg daily for about three years. Therefore, a diagnosis of tamoxifen retinopathy was made.

## Discussion

Tamoxifen is an oral selective estrogen receptor antagonist that targets breast cancer cells and has the ability to penetrate the blood-retinal barrier.<sup>1</sup> Case reports documenting tamoxifen toxicity exist from as early as 1994. Potential ocular manifestations of toxicity include a variety of corneal opacities, isolated instances of optic neuritis and varying changes to retinal layers. Retinal manifestations of tamoxifen toxicity reported thus far include intraretinal crystal deposition, which are thought to represent degenerated axonal material. Macular edema, retinal cavitation due to Müller cell disruption and disruption in the IS/OS junction have all been reported as well.<sup>2</sup>

As seen in the fundus photo, our patient appeared to have crystalline deposits in the left eye only until OCT later revealed that both eyes were affected. Because crystalline deposits are rarely visually significant, the IS/OS junction disruption in each eye is likely the cause for the decreased



**Fig. 3. Heidelberg OCT of the right and left eyes. Is this normal?**

vision. Further, the reduced PAP visual acuity suggests that the decrease in best-corrected visual acuity cannot be completely attributed to the cataracts alone, at least in the left eye.

In several case reports, there has been evidence of partial recovery of the IS/OS junction and reversal of macular edema after discontinuing tamoxifen.<sup>3</sup> However, crystals tend to remain within the retina for long periods of time.

While the exact mechanism of retinal toxicity is still unknown, previous studies involving human-derived RPE cells and mouse-derived photoreceptor cells have shown that tamoxifen may induce excess autophagy and cell death, as well as increased oxidative stress and zinc levels.<sup>1</sup> Due to differing imaging modalities used, the incidence of retinal changes has a wide range reported in literature, from 1.5% to approximately 12%.<sup>4</sup> Of note, studies that used OCT to identify retinopathy


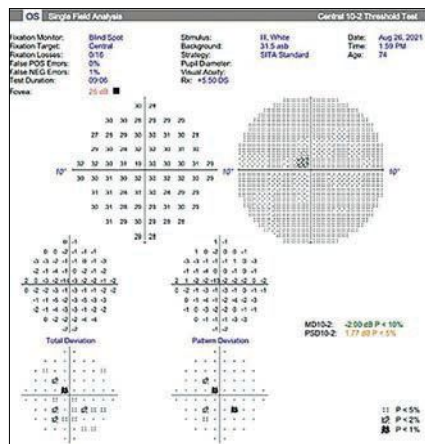
reported higher cases of retinopathy as compared to studies that solely used fundus photography or fundus exam. This may suggest that tamoxifen toxicity is in fact more common than earlier reports indicate.

Unlike with chloroquine toxicity, there is no established protocol for monitoring and screening patients for tamoxifen retinopathy. As

demonstrated in this case, toxicity can manifest subclinically; therefore, it may be of value to obtain baseline ancillary testing on patients taking tamoxifen so that future changes can be identified.

A retrospective analysis identified 30 of 251 patients with tamoxifen retinopathy, all of which were on a 20mg per day dose for two or more years.<sup>4</sup> They also found that patients with a higher BMI and hyperlipidemia may be at increased risk.<sup>4</sup> In contrast to earlier reports, this suggests that patients on a low dose of tamoxifen are still at risk for toxicity and may be more vulnerable if they possess these risk factors. Therefore, closer follow-up may be indicated than recommended in literature thus far.

Due to evident retinal changes that were seen in our patient, we consulted her oncologist to discuss alternative treatments and potential discontinuation of tamoxifen. Unfortunately, she did not return for her follow-up thereafter. ■



**Figs. 4 and 5. Standard Humphrey 10-2 visual fields were performed and show a central depression in both eyes. Does this represent artifact or is it a real defect?**

1. Cho KS, Yoon YH, Choi JA, et al. Induction of autophagy and cell death by tamoxifen in cultured retinal pigment epithelial and photoreceptor cells. *Invest Ophthalmol Vis Sci.* 2012;53(9):5344-53.
2. Nayfield SG, Gorin MB. Tamoxifen-associated eye disease. A review. *J Clin Oncol.* 1996;14(3):1018-26.
3. Ghassemi F, Masoomian B, Khodabandeh A, et al. Tamoxifen induced pachychoroid pigment epitheliopathy with reversible changes after drug discontinuation. *Int Med Case Rep J.* 2020;13:285-9.
4. Kim HA, Lee S, Eah KS, Yoon YH. Prevalence and risk factors of tamoxifen retinopathy. *Ophthalmology.* 2020;127(4):555-7.

## ABOUT THE AUTHOR



Dr. Siddiqui graduated from the Illinois College of Optometry and is completing her ocular disease residency at the Bascom Palmer Eye Institute.



BY DEREK N. CUNNINGHAM, OD, AND  
WALTER O. WHITLEY, OD, MBA

## SURGICAL MINUTE

# Those Pesky Floaters

*Vitreotomy is a safe option to rid patients of vitreous opacities.*

**H**ow often had you had a patient tell you about their vitreous opacities (VO)—a.k.a. floaters—and ask if there are any treatments available? We get this from patients daily. To ease their concern, we perform a thorough dilated examination and educate them about their condition and why they have VOs. Whether acute or chronic, our role is to explain the reason for floaters and to check for any retinal pathology like retinal breaks or detachment.

In the past, our discussions focused mainly on patient reassurance that their symptoms will resolve over time and the brain will adapt and ignore them (neuro-adaptation) over the next several weeks to months.

Unfortunately for some patients, VOs can be incredibly debilitating and have a significant impact on their quality of life. Because patients are willing to try anything to get rid of their floaters, they will search the internet high and low for various treatment options, from homeopathic remedies to in-office laser vitreolysis.

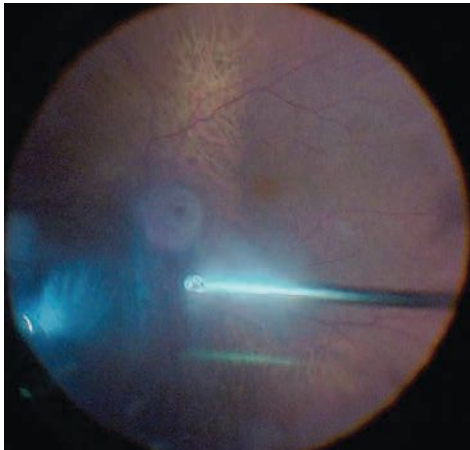
For a video of the procedure, read this article online at [www.reviewofoptometry.com](http://www.reviewofoptometry.com).

Although there are reports that laser vitreolysis is successful, clinical research and experience remain limited. The retina specialists we work with have not adopted the procedure and instead perform pars plana vitrectomy—a safe and viable option for patients with VOs.

### What Are VOs?

Familiar to all eye doctors, vitreous opacities are small dark shapes that float across your vision. Vitreous hemorrhages, pigmented cells and inflammatory cells are also VOs. Risk factors include age, nearsightedness, trauma, complications from cataract surgery, diabetic retinopathy and eye inflammation.

Photo: John Kitchens, MD



**When surgical intervention is needed, pars plana vitrectomy is the best option.**

Although most patients do not require surgical intervention, the main indications for surgery include symptomatic decrease in quality of vision and life (*e.g.*, can't read, drive) and/or symptomatic VO is greater than six months. Patients who are pseudophakic are optimal candidates compared to phakic candidates due to the development of cataracts post-vitreotomy. Anecdotally, patients with multifocal intraocular lenses seem more bothered by VOs.

As with any ocular surgery, communication is key. Discuss with your surgeon their thoughts on when it is appropriate to perform a vitrectomy, which will help prepare patients for the referral to the retina provider.

### Pars Plana Vitrectomy

Prior to surgery, patients receive a local retrobulbar injection to ensure good anesthesia is obtained. Next, the eye is prepped and draped in the usual sterile fashion. A 27-gauge 4mm infusion cannula is placed 3.5mm from the limbus inferotemporally. After confirming the position of the cannula, two superior 27-gauge sclerostomies are placed. Then, the vitrectomy device and light pipe are inserted. The surgeon identifies the VOs and begins a standard three-port pars plana vitrectomy to clear the opacities. Once complete, a 360° scleral depression is performed at the end of the case to ensure no breaks were noted. The last step is to remove the trocars and cannulas and ensure the eye is watertight. A subconjunctival injection of steroids and antibiotics is administered followed by patching/shielding the eye.

As with any ocular surgery, risks include cataract formation, retinal tear and detachment, macular pucker, macular edema and endophthalmitis. Typical postoperative visits are one day, one week and one month after the procedure.

So, next time you have a symptomatic patient complaining about floaters, consider a referral for a vitrectomy. With significant advances in technology, we are able to help improve our patients' vision and tackle those pesky floaters. ■

*Dr. Cunningham and Whitley wish to thank Rohit Adyanthaya, MD, for his contributions to this month's discussion.*

**About Drs. Cunningham and Whitley**

**Dr. Cunningham** is the director of optometry at Dell Laser Consultants in Austin, TX. He has no financial interests to disclose. **Dr. Whitley** is the director of professional relations and residency program supervisor at Virginia Eye Consultants in Norfolk, VA. He is a consultant for Alcon.





# A NEW WAY TO EXPERIENCE REVIEW OF OPTOMETRY

Follow us on Instagram at @revoptom for striking clinical images, daily news headlines, issue previews and great content from the magazine—all formatted for mobile



**REVIEW OF OPTOMETRY**  
NEW! NEW! - THE NEWS FEED - THE NEWS FEED - THE NEWS FEED - THE NEWS FEED - THE NEWS FEED

**Stories for 3-26-21**

**Missed Neuro Diagnoses Common, Can Lead to Patient Harm**  
Study finds half of all refractive error diagnoses with one in four of those error caused some kind of adverse impact on health.

**CDC Aims to Break Down Telenet Barriers in Oculocare**  
New telemedicine pilot funding for a 5-year investigation aims to improve and expand reach of remote ophthalmology.

**Thyroid Eye Disease Increases Risk of Optic Nerve Damage**  
Advanced optic nerve disease of the eye, not swollen optic nerve, increasing the likelihood of progression to unilateral optic neuropathy.

Read today at [www.reviewofoptometry.com/news](http://www.reviewofoptometry.com/news)

**REVIEW OF OPTOMETRY**

High myopia with a tessellated and thin choroid (red line), RPE disruption (gray line), ONP (yellow line), ONH (green line) and choroidal neovascularization (blue line) with early subfoveal and hyperreflective material (purple line) - all consistent with myopic CNV.

Choroidal folds causing sub-RPE undulations (red lines).

From "The Molecular Basis of a White Eye Lesion" by Lisa Brinkman, MD available at [www.reviewofoptometry.com/issue/February-19-2021](http://www.reviewofoptometry.com/issue/February-19-2021)

**REVIEW OF OPTOMETRY**

**DRY EYE READER SURVEY RESULTS**

What percent of your patients in each of these categories suffers from dry eye?

Category	1%	5%	10%	20%	30%	40%	50%	60%	70%
Adults 20-40 years old	10	15	20	25	30	35	40	45	50
Adults 41-60 years old	15	20	25	30	35	40	45	50	55
Adults 61 and older	20	25	30	35	40	45	50	55	60
Contact lens wearers	15	20	25	30	35	40	45	50	55
Men	10	15	20	25	30	35	40	45	50
Women	15	20	25	30	35	40	45	50	55
Postmenopausal women	10	15	20	25	30	35	40	45	50

From "Dry Eye Reader Survey Results, Habits and Trends" available at [www.reviewofoptometry.com/issue/January-19-2021](http://www.reviewofoptometry.com/issue/January-19-2021)

**REVIEW OF OPTOMETRY**

Redness associated with a subconjunctival hemorrhage.

From "The Molecular Basis of a White Eye Lesion" by Lisa Brinkman, MD available at [www.reviewofoptometry.com/issue/February-19-2021](http://www.reviewofoptometry.com/issue/February-19-2021)

**REVIEW OF OPTOMETRY**

**CLINICAL FEATURES OF COMMON SECONDARY CONDITIONS ASSOCIATED WITH GLAUCOMA**

CONDITION	CLINICAL APPROPRIATE	DIAGNOSTIC FACTORS
Normal-tension glaucoma	Asymptomatic or mild symptoms (e.g., anterior bowing and peripheral vision loss)	Asymptomatic or mild symptoms (e.g., anterior bowing and peripheral vision loss)
Pseudoexfoliation glaucoma	Dark, waxy, foamy material deposited on anterior surface of cornea, anterior lens capsule and trabecular meshwork	Deposition of hyaline material on cornea and trabecular meshwork
Angle-closure glaucoma	Peripheral anterior synechia or iris transillumination defects	Peripheral anterior synechia
High myopia	Dark, brown, foamy and waxy material deposited on anterior surface of cornea, anterior lens capsule and trabecular meshwork	Deposition of hyaline material on cornea and trabecular meshwork
Neovascular glaucoma	Neovascularization of the iris and retina	Neovascularization of the iris and retina

From "The Molecular Basis of a White Eye Lesion" by Lisa Brinkman, MD available at [www.reviewofoptometry.com/issue/February-19-2021](http://www.reviewofoptometry.com/issue/February-19-2021)

**REVIEW OF OPTOMETRY**

**RETINA QWIK: A 22-year-old white female high myope presented with blurred vision, ONH, for over six months, and had the best vision in her central vision. Medical history was significant for Crohn's disease since age 14, which had a recent flare-up. BCVA measured 20/400 OD with eccentric viewing and 20/10 OS. Reader grid showed a central scotoma in both eyes but was very dense OD. There was slight involution of both optic nerves. She had a normal-appearing fundus, and other significant changes noted none. (See page 10 for OCT scans)**

From "Retina QWIK" by Eric Springer, MD, edited by Mark Cantello, MD available at [www.reviewofoptometry.com/issue/March-19-2021](http://www.reviewofoptometry.com/issue/March-19-2021)

**REVIEW OF OPTOMETRY**

**MAR 2021**

**Dry Eye Issue**

Available March 2021  
[www.reviewofoptometry.com](http://www.reviewofoptometry.com)

**REVIEW OF OPTOMETRY**

**CLINICAL QUARANTERS: A 57-year-old female presented with redness, a painful eye of the lower lid and eyelashes. What do you think is happening, and how would you treat it?**

From "The Molecular Basis of a White Eye Lesion" by Lisa Brinkman, MD available at [www.reviewofoptometry.com/issue/February-19-2021](http://www.reviewofoptometry.com/issue/February-19-2021)

**REVIEW OF OPTOMETRY**

**Multiple Tomograms, Macular Color Shifts**

The normal values on this macular OCT indicate edema. Since the result is consistent with the clinical picture of severe retinal edema and mild outer retinal thickening seen in acute retinal detachment, the patient was diagnosed with a vitelliform outer retinal detachment (VORD).

From "The Molecular Basis of a White Eye Lesion" by Lisa Brinkman, MD available at [www.reviewofoptometry.com/issue/March-19-2021](http://www.reviewofoptometry.com/issue/March-19-2021)

**REVIEW OF OPTOMETRY**

**Additional studies that might yield diagnostically pertinent data:**

- 20/20 to 20/400 visual acuity
- ERG and dark adaptation testing for rod function suppression
- ERG and dark adaptation testing for cone function suppression
- ERG and dark adaptation testing for rod function suppression
- ERG and dark adaptation testing for cone function suppression

From "The Molecular Basis of a White Eye Lesion" by Lisa Brinkman, MD available at [www.reviewofoptometry.com/issue/February-19-2021](http://www.reviewofoptometry.com/issue/February-19-2021)



**REVIEW OF OPTOMETRY**

**An 81-year-old man presented with a new, "floaters" (floaters) OD, described as a constant and stationary. The number shows a small detached area of whitening.**

From "The Molecular Basis of a White Eye Lesion" by Lisa Brinkman, MD available at [www.reviewofoptometry.com/issue/March-19-2021](http://www.reviewofoptometry.com/issue/March-19-2021)

**REVIEW OF OPTOMETRY**

**Effuse corneal swelling with floaters in a patient with severe dry eye and a history of DR.**

From "The Molecular Basis of a White Eye Lesion" by Lisa Brinkman, MD available at [www.reviewofoptometry.com/issue/March-19-2021](http://www.reviewofoptometry.com/issue/March-19-2021)

**REVIEW OF OPTOMETRY**

**FAST FACTS ON CLAO**

- only present in approximately one in three people
- provides a secondary blood supply to the inner layers of the macula
- comprises only 3.3% to 7.1% of all retinal artery occlusions
- has been associated with embolism, lupus, retinoblastoma, sickle cell, pregnancy and systemic hypertension
- can present in three ways (1) with ischemic optic neuropathy in giant cell arteritis, (2) with concomitant central retinal vein occlusion or (3) isolated

**Management and prognosis**

If CCA: Critical to arrange for same-day ESI and CIP testing and begin IV therapy. Visual prognosis is the worst of the three due to lack of retinal blood circulation.

If CVO: Treatment focuses on macular edema and neovascularization. Better prognosis, as the retina circulation tends to be non-ischemic.

If isolated: Treatments can include ocular massage, paraneurial, intra-arterial thrombolysis and hyperbaric oxygen. Best visual prognosis.

**CASE OUTCOME**

This patient's case was diagnosed with CLAO and treated with ESI and CIP testing. The fundus defect resolved, but the vision remained 20/20 and the outcome was not as favorable.

From "The Molecular Basis of a White Eye Lesion" by Lisa Brinkman, MD available at [www.reviewofoptometry.com/issue/March-19-2021](http://www.reviewofoptometry.com/issue/March-19-2021)

**REVIEW OF OPTOMETRY**

**Peripheral retina with a subconjunctival hemorrhage associated with a subconjunctival hemorrhage.**

From "The Molecular Basis of a White Eye Lesion" by Lisa Brinkman, MD available at [www.reviewofoptometry.com/issue/February-19-2021](http://www.reviewofoptometry.com/issue/February-19-2021)

**REVIEW OF OPTOMETRY**  
NEW! NEW! - THE NEWS FEED - THE NEWS FEED - THE NEWS FEED - THE NEWS FEED - THE NEWS FEED

**Stories for 3-26-21**

**Missed Neuro Diagnoses Common, Can Lead to Patient Harm**  
Study finds half of all refractive error diagnoses with one in four of those error caused some kind of adverse impact on health.

**CDC Aims to Break Down Telenet Barriers in Oculocare**  
New telemedicine pilot funding for a 5-year investigation aims to improve and expand reach of remote ophthalmology.

**Thyroid Eye Disease Increases Risk of Optic Nerve Damage**  
Advanced optic nerve disease of the eye, not swollen optic nerve, increasing the likelihood of progression to unilateral optic neuropathy.

Read today at [www.reviewofoptometry.com/news](http://www.reviewofoptometry.com/news)

**REVIEW OF OPTOMETRY**

**Additional studies that might yield diagnostically pertinent data:**

From "The Molecular Basis of a White Eye Lesion" by Lisa Brinkman, MD available at [www.reviewofoptometry.com/issue/February-19-2021](http://www.reviewofoptometry.com/issue/February-19-2021)

**REVIEW OF OPTOMETRY**

**ANTERIOR CEMENT FACTORS IN GLAUCOMA**

**Set of 4 - Anterior segment inflammation**

LEI Proliferation on the anterior lens capsule associated with anterior synechia.

W/ Larger aggregation of pigment on anterior lens capsule surface

From "The Molecular Basis of a White Eye Lesion" by Lisa Brinkman, MD available at [www.reviewofoptometry.com/issue/March-19-2021](http://www.reviewofoptometry.com/issue/March-19-2021)

**REVIEW OF OPTOMETRY**

**This patient with severe retinal detachment secondary to a vitelliform outer retinal detachment (VORD) had a partial and elevated retina.**

From "The Molecular Basis of a White Eye Lesion" by Lisa Brinkman, MD available at [www.reviewofoptometry.com/issue/March-19-2021](http://www.reviewofoptometry.com/issue/March-19-2021)

# PRODUCT REVIEW



**ONLINE FIRST:**  
GET THE LATEST  
PRODUCT NEWS AT  
[www.reviewofoptometry.com](http://www.reviewofoptometry.com)

New items to improve clinical care and strengthen your practice.

## ► CONTACT LENSES

### **Adjustable Scleral Lens Now Suits More Corneal Shapes, Conditions**

For several years, scleral lenses have increasingly been used in optometric practice. As their popularity grows, expectations do, too—with practitioners now looking for things like multifocal correction, improved optics and greater versatility in fitting capabilities. To meet these demands, SynergEyes recently announced three additions to its SynergEyes VS scleral: a multifocal option, aberration control and broader limbal clearance.



The SynergEyes VS uses two bi-tangential landing zones—linear and toric—that can be adjusted independently without affecting the others to accommodate for the toricity of the sclera and fit its natural shape, the company says. Now, this lens can also be made with a front surface progressive center distance design that provides add powers of +1.00D to +3.00D in 0.5 steps, according to the company.

The multifocal version includes aberration control as a standard element; it's also available as an option on single-vision lenses. This helps minimize lens-induced aberrations and promotes a more consistent power flow through the optical zone, a company press releases states.

Finally, eyes with larger a horizontal visible iris diameter may need broader limbal clearance. SynergEyes VS now allows this to be boosted by 25µm or 50µm, the company says.

### **Alcon Adds Toric Option for DT1 Contact Lenses**



If you like the performance of Dailies Total1 contact lenses—Alcon's high-end daily disposable—you'll soon be able to offer it for

your astigmatic patients, too. DT1 lenses have been available in single vision and multifocal versions for some time; in March, a toric version will join them.

As with other products in the Dailies Total1 line, the new lens will use Alcon's water gradient matrix design to enhance comfort by achieving nearly 100% water content at the surface, the company says. Other features the company touts are prism ballasting at the 8 and 4 o'clock positions to improve stabilization (which the company calls Precision Balance 8|4) and the addition of a phospholipid to help stabilize the tear film (called SmarTears by the company). The same prism ballast is also used in Alcon's Precision1 and Air Optix toric daily disposables. Alcon says that feature allows

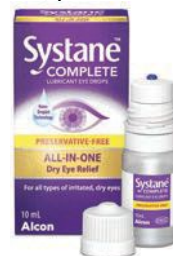lenses to settle in an average of 37 seconds and be within two degrees of ideal orientation in two minutes.

Alcon notes that the toric segment is the fastest growing part of the contact lens market, pointing to research showing that 32% of wearers have astigmatism but only about 10% currently wear a toric.

## ► DRY EYE

### **Multi-Dose Bottle for Alcon's Systane Complete PF**

Using preservative-free artificial tears prevents ocular irritation caused by benzalkonium chloride; however, patients may find themselves compromising on convenience and cost due to the single-use packaging commonly used for these formulations. One way to combat this problem is to redesign the tip of a multi-dose bottle to ensure a tight seal when not in use, an approach Alcon is planning to use with its preservative-free version of Systane Complete lubricant eye drops, which the company says will debut in the United States this year.



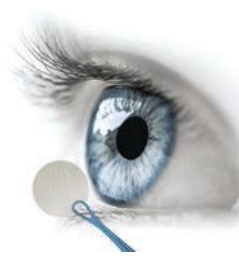The bottle features a one-way valve that prevents re-entry of contaminated liquid; Alcon calls this design "PureFlow" and says it eliminates the need for preservatives. This design is already used in the company's Systane Ultra and Systane Hydration preservative-free products.

Alcon says Systane Complete provides both fast hydration for rapid symptomatic relief and lipid stabilization for long-lasting tear film support to address all forms of dry eye: evaporative, aqueous-deficient and mixed.

## ► THERAPEUTICS

### **New Shelf-Stable Amniotic Membrane Protects, Heals Ocular Surface**

When patients experience ocular surface trauma from infection, injury or severe dry eye, applying an amniotic membrane can help jumpstart the healing response. The newest option, AcellFX from Akorn Eye Care, is a human acellular amniotic membrane that the company says is shelf-stable and ready for immediate use.



AcellFX is a thin, nearly transparent tissue with a diameter of 5mm, according to Akorn. The company says the product can be stored at room temperature for up to five years and requires no thawing or rinsing prior to placement. The

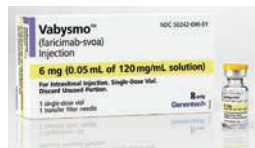
human amniotic membrane that makes up AcellFX should be naturally absorbed by the eye; amniotic tissue is donated by rigorously screened, healthy mothers giving birth through C-sections, product literature states.

### New Anti-VEGF Extends Treatment Interval

The newest entrant into the anti-VEGF field, faricimab from Genentech, matches the current standard-bearers in visual acuity gains but requires fewer treatments for many patients, the company stated in a press release announcing the drug's recent FDA approval. It will be marketed under

the brand name Vabysmo for treatment of wet AMD and DME.

In addition to blocking vascular endothelial growth factor, the drug also neutralizes angiopoietin-2, a substance that can contribute to vessel leakage, inflammation and angiogenesis when levels are elevated. Genentech and its clinical trial investigators point to this dual action as the reason for Vabysmo's greater durability of effect. After a loading phase of injections once per month for four months, retina specialists can begin to extend the time between treatments while monitoring to ensure visual acuity and anatomical stability. Over 70% of patients being treated for wet AMD or DME were able to go three months or longer between injections in the first year, Genentech says. Some DME patients may need six monthly loading doses, according to the company.

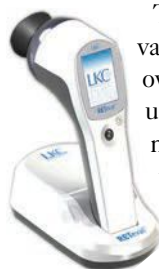

Phase III trials showed noninferiority to Regeneron's aflibercept in vision outcomes, central subfield thickness and choroidal neovascularization at one year, Genentech says.

### ▶ DIAGNOSTICS

#### Portable ERG Improves Tool for Glaucoma Detection

Recognizing glaucoma when it's still in its early stage is critical, but media opacity or unreliable subjective tests may hinder the effort. Now, doctors interested in using electrodiagnostic testing to get objective findings have a new test to consider. Measuring the photopic negative response (PhNR) via electroretinography (ERG) allows for evaluation of retinal ganglion cell function. If you have—or are considering getting—the RetEval ERG from LKC Technologies, note that the company has added a new protocol that brings PhNR to the device.



The enhanced algorithm has a test/retest variability that shows a fourfold improvement over the previous version, LKC reports. The updated normative reference range is 1.7 times narrower, which the company says increases the sensitivity of the test and aids in detection of abnormal ganglion cell function. The company says it believes the new PhNR protocol for glaucoma demonstrates a practical application of ERG that can expand its role beyond the realm of specialists and into mainstream practice. ■

## ADVERTISER INDEX

This index is published as a convenience and not as part of the advertising contract. Every care will be taken to index correctly. No allowance will be made for errors due to spelling, incorrect page number, or failure to insert.

Advancing Eyecare.....	37	Bausch + Lomb.....	2 & 3	MacuLogix.....	29
.....(800) LOMBART		.....www.bausch.com		.....www.maculogix.com	
.....www.lombartinstrument.com		Bausch + Lomb.....	7	Notal Vision.....	21
Akorn.....	43	.....www.biTRUE.com/professional		.....(855) 600-3112	
.....www.acellfx.com		Bausch + Lomb.....	41	.....www.foreseehome.com/doctor	
Alcon Laboratories.....	108	.....(833) 458-6439		.....info@olleyes.com	
.....www.alcon.com		.....www.lumifydrops.com/professional		.....www.olleyes.com	
Allergan.....	19	Bausch + Lomb.....	53	Oyster Point.....	13 & 14
.....(833) REF-SMPL		.....(844) 258-4837		.....www.tyrvaya-pro.com	
.....www.allergan.com		.....www.bausch.com		Prestige Consumer Healthcare -Theratears.....	71
Bausch + Lomb.....	2 & 3			.....www.theratears.com	
.....www.bausch.com				RegenerEyes.....	16
Bausch + Lomb.....	7			.....(877) 206-0706	
.....www.biTRUE.com/professional				.....www.regenereyes.com	
Bausch + Lomb.....	41			Regeneron Pharmaceuticals, Inc.....	58-59 & 60
.....(833) 458-6439				.....www.regeneron.com	
.....www.lumifydrops.com/professional				RVL Pharmaceuticals, Inc.....	23 & 24
Bausch + Lomb.....	53			.....(866) 600-4799	
.....(844) 258-4837				.....www.Upneeq.rvlpharma.com/signup	
.....www.bausch.com				X-Cel Specialty.....	63
				.....(800) 241-9312	
				.....xcelfinfo@xcelSpecialtycontacts.com	
				.....www.xcelSpecialtycontacts.com/remlens	
Bausch + Lomb.....	Cover Tip	Bausch + Lomb.....	27		
.....www.bauschinfuse.com		Bruder Healthcare Company.....	27		
		.....(888) 827-8337			
		.....eyes@bruder.com			
		.....order.bruder.com			
		CooperVision.....	107		
		.....www.cooperivision.com			
		DGH Technologies, Inc.....	45 & 51		
		.....info@dghkol.com			
		.....www.dghtechnology.com			
		Dompe.....	33 & 34		
		.....www.oxervate.com/HCP			
		Eye Designs.....	67		
		.....(800) 346-8890			
		.....www.eyedesigns.com			
		Glaukos.....	5		
		.....www.glaukos.com			
		Glaukos.....	11		
		.....www.iLinkExpert.com			
		Icare USA.....	49		
		.....(888) 422-7313			
		.....infoUSA@icare-world.com			
		.....www.icare-world.com/USA			
		Keeler Instruments.....	9		
		.....(800) 523-5620			
		.....customerservice@keelerusa.com			
		.....www.keelerusa.com			



Practice For Sale



Practice Sales • Appraisals • Consulting  
www.PracticeConsultants.com

PRACTICES FOR SALE  
NATIONWIDE

Visit us on the Web or call us to learn more about our company and the practices we have available.

info@PracticeConsultants.com

925-820-6758

www.PracticeConsultants.com

Charleston SC  
Practice For Sale

Gross over \$500K on 3.5 days  
Seller owns 1000 sq/ft suite  
EMR and medical model

Call 843 906-9694

Email [3Dmira@gmail.com](mailto:3Dmira@gmail.com)

REVIEW  
of OPTOMETRY

Do you have  
Products and  
Services for sale?

CLASSIFIED  
ADVERTISING WORKS

- JOB OPENINGS
- CME PROGRAMS
  - PRODUCTS
  - AND MORE...

Contact us today for  
classified advertising:  
Toll free: 888-498-1460  
E-mail: [sales@kerhgroup.com](mailto:sales@kerhgroup.com)



Career Opportunities

FLEXIBILITY.  
FREEDOM.  
CAREER GROWTH.

With SightRite, there's a better way  
to practice optometry.



Set your own  
schedule

Never work evenings or weekends again. We have plenty of flexible, part-time, and full-time positions available.



Work less,  
earn more

The average SightRite optometrist works approximately 5 hours a day while earning more than most doctors make in an 8-10 hour day. Looking to earn even more? Simply increase your patient load to increase your salary.

Opportunities currently available in:  
CA, CT, DC, DE, FL,  
MD, MO, NJ, NY, OH,  
PA, RI, TN, VA.

To find out more or to submit your resume go to:  
[sightright.com/careers](http://sightright.com/careers)

Email/call:  
[info@sightright.com](mailto:info@sightright.com)  
212-764-0008 ext 223  
[www.sightright.com](http://www.sightright.com)



SightRite™  
eye care services

We will be exhibiting at  
VISION EXPO EAST

Come visit us at  
BOOTH #F5051

**Faculty**

### ASSISTANT PROFESSOR POSITIONS: PRIMARY CARE &/OR OPHTHALMIC OPTICS

Full-time non-tenure track faculty positions for the Chicago College of Optometry

**Responsibilities:** Candidates are expected to be highly knowledgeable in the field of primary care and/or ophthalmic optics and develop and teach courses and/or laboratories in the subject area. The primary care candidate must also be able to provide direct patient care and clinical instruction to professional students as well as residents, and be involved in interdisciplinary practice with other educational professionals.

Candidates must be willing to actively participate in curricular assessment, professional development, student counseling and service activities within the college, university and the scientific community. Successful candidates are also expected to be involved in research and scholarly activities, and have a sincere commitment to optometric education, community service and patient care. Primary duties include, but are not limited to:

**a) Teaching**

- Developing and delivering lectures and/or laboratories for related areas, as assigned;
- Embracing and enhancing the didactic philosophies in the O.D. program;
- Maintaining and expanding the high quality clinical practice environment for optometry students on rotation;
- Precepting students on clinical rotation at the Midwestern University Eye Institute where applicable;

**b) Service**

- Helping to maintain and grow the state of the art optometry program with a strong interdisciplinary focus that meets the needs of patients in the surrounding community; is efficient, patient friendly, and cost-effective;
- Working closely together with all optometry and ophthalmology faculty to provide a complete range of eye and vision care services;
- Participating in leadership roles in state, regional, and national optometry organizations;

**c) Scholarly activity**

Engaging in research and scholarly activity, including presentations at scientific meetings, research, and publication in peer reviewed journals sufficient to qualify for academic advancement in a non-tenure or tenure track position.

**Qualifications:** Candidates must possess a Doctor of Optometry degree from an ACOE-accredited institution, must have completed an ACOE-accredited residency, and must be eligible for an Illinois optometric state license. Primary eye care clinical expertise is also required.

**Salary will be commensurate with qualifications and experience**  
**Review of applications will begin immediately and continue until the position is filled**

**Contact information:** Interested applicants should apply online at [www.midwestern.edu](http://www.midwestern.edu) and include curriculum vitae and letter of interest specifying the position and college that he/she wishes to be considered for. Application packet should include curriculum vitae and letter of interest. Inquiries may be directed to Dr. Melissa Suckow, Dean; Midwestern University: [msucko@midwestern.edu](mailto:msucko@midwestern.edu).

*Midwestern University is an Equal Opportunity/Affirmative Action employer that does not discriminate against an employee or applicant based upon race, color, religion, gender, national origin, disability, or veterans status, in accord with 41 C.F.R. 60-1.4(a), 250.5(a), 300.5(a) and 741.5(a).*

## UMSL Optometry UMSL College of Optometry Dean

With our institutional mission to transform lives, the University of Missouri–St. Louis invites nominations and applications for the Dean of the College of Optometry. This is an exciting opportunity for a leader with a strong record as an educator and scholar to strategically guide the college.

As one of the most culturally and ethnically diverse campuses in Missouri, UMSL is committed to maintaining a climate where all students, faculty, staff, and visitors can explore their interests, refine their talents and flourish. Inclusive excellence is embedded in our strategic plan which focuses on actions to recruit and retain diverse students and employees and promote activities that encourage civil and constructive discourse, reasoned thought, and sustained dialogue in an environment of inclusion, respect and appreciation.

**Qualifications**

- The Dean should be an accomplished optometrist, well versed in full scope, broad based optometric care, have a record of successful leadership, and be sensitive to issues facing education, research and scholarship, and the provision of high quality clinical services in the rapidly changing optometric profession.
- The Dean should be eligible for licensure in the state of Missouri.



- The Dean should be able to work closely with the constituencies of the profession to promote the College and its activities while bringing experience in alumni relations and fundraising.
- The Dean should be an individual of integrative vision and action, one who facilitates creativity and productivity in all aspects of modern optometry, able to lead the College into new areas of optometric practice while maintaining an evidence-based understanding of medico-legal best practices in optometry.
- The Dean should evaluate and promote positive change, value diversity, and have strong skills in consensual management.
- The Dean must have an O.D. degree or equivalent, and a record of accomplishments commensurate with senior academic rank, broad based clinical and research understanding, and management success that will allow him/her to work as a mentor for faculty and students alike.
- The Dean should set through action the highest standards for honesty and integrity, ethics and values, scholarship, and clinical practice.

The University of Missouri-St. Louis is a public, metropolitan land-grant institution committed to basic and applied research, teaching and service with 17,000 students and 1,325 full and part-time faculty members. [UMSL.edu](http://UMSL.edu)

The College of Optometry includes a 4-year professional degree (O.D.) program and post-professional residency programs. [optometry.umsli.edu](http://optometry.umsli.edu)

For priority consideration, applicant materials and inquiries should be received prior to February 11, 2022. Applications should include:

- A detailed cover letter addressing how the candidate meets the qualifications for this position including their background and vision for the role as well as their alignment with the campus mission
- A current Curriculum Vitae
- An inclusive excellence statement reflecting the candidate's understanding of, experience with, and ability to contribute to diverse and inclusive organizations, departments and classrooms.
- The names and contact information of three to six professional references from the candidate's various professional roles. References will not be contacted without prior notification to the candidates.

Review of materials will begin February 11, 2022, and continue until an adequate pool is established, or until the appointment is made. Electronic submission strongly encouraged.

<https://tinyurl.com/UMSLDeanOptometry>

Questions, inquiries or nominations may be submitted to: Roxanne Vandermause, Dean, College of Nursing, [vandermauserk@umsli.edu](mailto:vandermauserk@umsli.edu)

The University of Missouri-Saint Louis is an equal opportunity/affirmative action employer committed to excellence through diversity.



# Oh, That's Catchy!

*Is this a case of garden-variety red eye or something potentially more troubling?*

**A** 65-year-old Caucasian female, who worked as an elementary school administrator, presented for an eye evaluation because of recent-onset ocular redness, lid swelling and watery/mucoid discharge, OU. Her symptoms began in the right eye two days prior, then developed in the left eye. She also reported a sore throat of approximately seven days' duration.

Her ocular history was significant for silicone hydrogel contact lens wear, which she had discontinued two days prior to her visit. Her systemic history revealed hypercholesterolemia, for

which she was properly medicated. She reported allergies to sulfur-based drugs and tetanus toxoid.

## Clinical Findings

Her best-corrected acuities were 20/30 OD, 20/30 OS at distance and near. External examination was normal and there was no afferent pupillary defect. The pertinent anterior segment findings are demonstrated in the photographs.

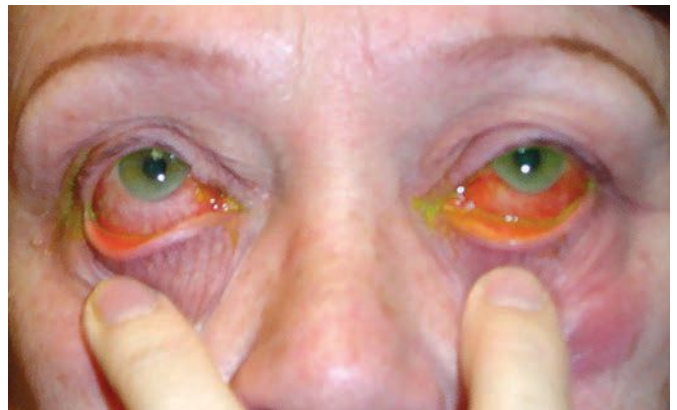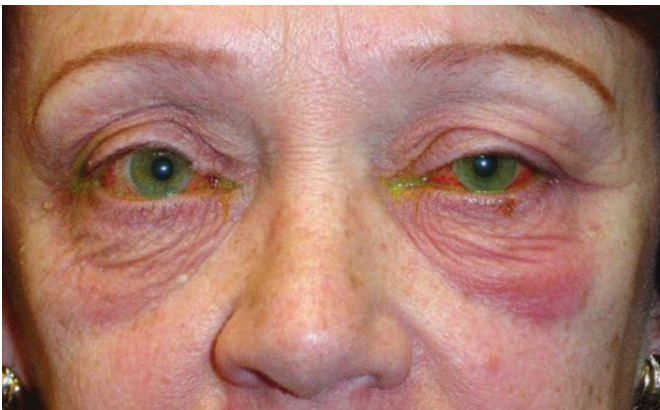
There was a grade I cellular response in the right anterior chamber and a grade II response in the left. Notable were a small group of faint

subepithelial infiltrates in the temporal right cornea. The balance of the biomicroscopic exam was normal OU and Goldmann applanation pressures measured 16mm Hg OU. The fundus evaluation was normal in each eye.

Additional testing included upper and lower eyelid eversion to examine the conjunctival surface for papillae, follicles and pseudomembrane formation; preauricular, submandibular, sublingual and submental lymph node palpation; sodium fluorescein examination of the anterior segments and corneal sensitivity testing.

## Your Diagnosis

What would be your diagnosis in this case? What is the patient's likely prognosis? Are any additional tests necessary? To find out, please read the online version of this article at [www.reviewofoptometry.com](http://www.reviewofoptometry.com). ■



How our patient presented at the clinic. What do these images suggest about her condition?

**About Dr. Gurwood** Dr. Gurwood is a professor of clinical sciences at The Eye Institute of the Pennsylvania College of Optometry at Salus University. He is a co-chief of Primary Care Suite 3. He is attending medical staff in the department of ophthalmology at Albert Einstein Medical Center, Philadelphia. He has no financial interests to disclose.

## Retina Quiz Answers (from page 98)—Q1: d, Q2: d, Q3: b, Q4: b

**NEXT MONTH IN THE MAG**

In March, we present our 15th annual issue on pharmaceuticals in eye care. Articles will include:

- Medical Management of Glaucoma: Updated Prescribing Protocols
- Inflammation in Dry Eye: Causes, Consequences and Corrections
- The Evolving Anti-VEGF Picture: New Therapies, New Indications, New Risks
- Make Presbyopia Therapy Work for You and Your Patients
- Prescribe Oral Meds Like a Pro
- Pediatrics: Drug Dosing Differences for Kids

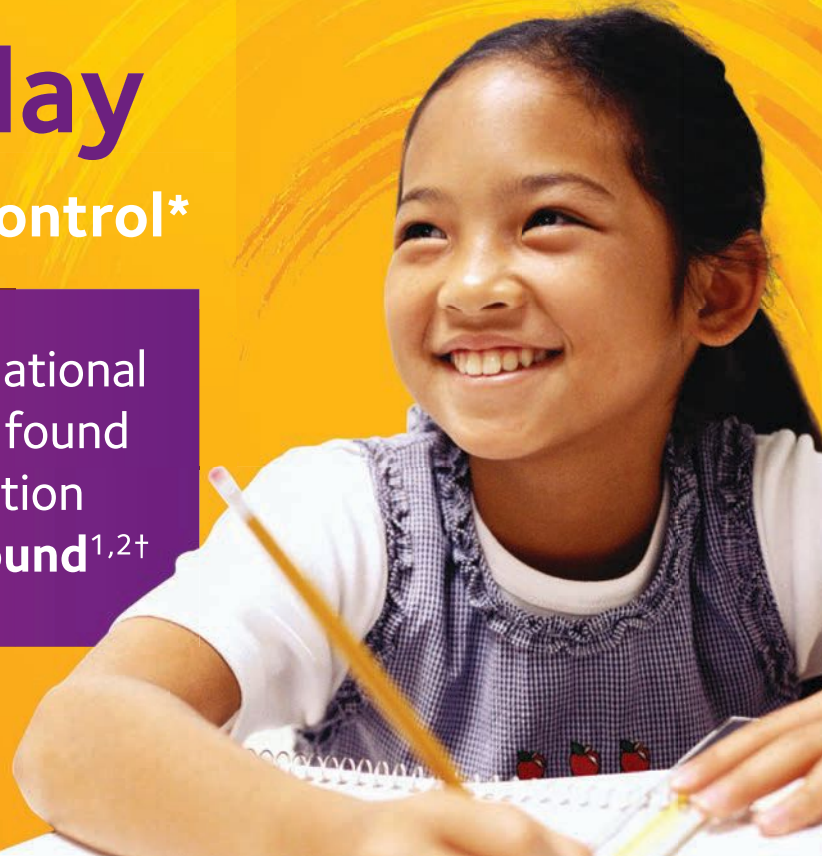

When it comes to myopia control in children who are 8-12 years of age at the initiation of treatment,


# MiSight® 1 day

is the ONE for myopia control\*

Year 7 results from the international MiSight® 1 day clinical study found that the mean axial elongation showed **no evidence of rebound**<sup>1,2†</sup>



MiSight® 1 day  
for daily wear



FDA-Approved\*

How can myopia control with MiSight® 1 day benefit your practice?

Learn more at [CooperVision.com](https://www.CooperVision.com)

**Disclaimer:** The stability of the myopia reduction effect 1-year post-treatment is being further evaluated in a post-approval study in the U.S. as a condition of FDA approval for MiSight® 1 day.

**\*Indications for use:** MiSight® 1 day (omafilcon A) soft (hydrophilic) contact lenses for daily wear are indicated for the correction of myopic ametropia and for slowing the progression of myopia in children with non-diseased eyes, who at the initiation of treatment are 8-12 years of age and have a refraction of -0.75 to -4.00 diopters (spherical equivalent) with ≤ 0.75 diopters of astigmatism. The lens is to be discarded after each removal.

<sup>†</sup>Preliminary international study data shows that, on average, for children that discontinued treatment at age 14-19 following 3 or 6 years of MiSight® 1 day wear, the eye growth reverted to age-expected average myopic progression rates.

**References:** 1. Chamberlain P, Arumugam B, et al. Myopia progression on cessation of dual-focus contact lens wear: MiSight® 1 day 7-year findings. *Optom Vis Sci.* 2021;98:E-abstract 210049. 2. Hammond D, Arumugam B, et al. Myopia control treatment gains are retained after termination of dual-focus contact lens wear with no evidence of a rebound effect. *Optom Vis Sci.* 2021;98:E-abstract 215130.



# SURFACING SOON.

Look for an ultimate in comfort and stability.



**Soon all will be revealed.** A new addition from the makers of the lens that **Feels Like Nothing™** is on its way. You will be able to fit more patients, more of the time, which is great for your patients and your practice.



**Scan QR code to see what's surfacing soon.**

See product instructions for complete wear, care and safety information.   
© 2021 Alcon Inc. US-DTA-2100012

**Alcon**