

FOCUS ON REFRACTION: A Life-Changing Use of Prism in a Parkinson's Patient, p. 28

REVIEW[®] *of* OPTOMETRY

Annual
Diagnostic Skills
& Techniques
Issue

Retina • Diplopia • Eyelids
OCT • Visual Fields

FEBRUARY 15, 2021 • www.reviewofoptometry.com

Leadership in clinical care

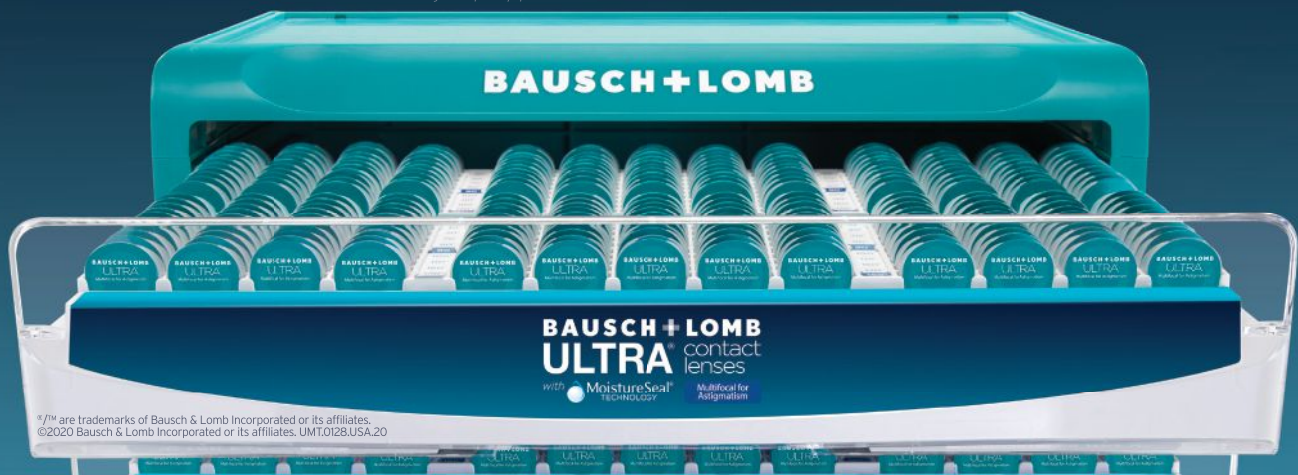NAVIGATING THE RETINAL PERIPHERY

BAUSCH + LOMB ULTRA[®] MULTIFOCAL FOR ASTIGMATISM

WHY MAKE 32 MILLION* PATIENTS WAIT?

The time for same-day multifocal toric fitting is now. Unlike other brands, Bausch + Lomb ULTRA[®] Multifocal for Astigmatism is available in office to save time and reduce follow-ups. Prescribe the only multifocal toric lens with **same-day convenience**.

*Estimated number of astigmatic presbyopes in the US.



^{®/™} are trademarks of Bausch & Lomb Incorporated or its affiliates.
©2020 Bausch & Lomb Incorporated or its affiliates. UMT,0128,USA,20

FOCUS ON REFRACTION: A Life-Changing Use of Prism in a Parkinson's Patient, P. 28

REVIEW[®] *of* OPTOMETRY

FEBRUARY 15, 2021 • www.reviewofoptometry.com

Leadership in clinical care

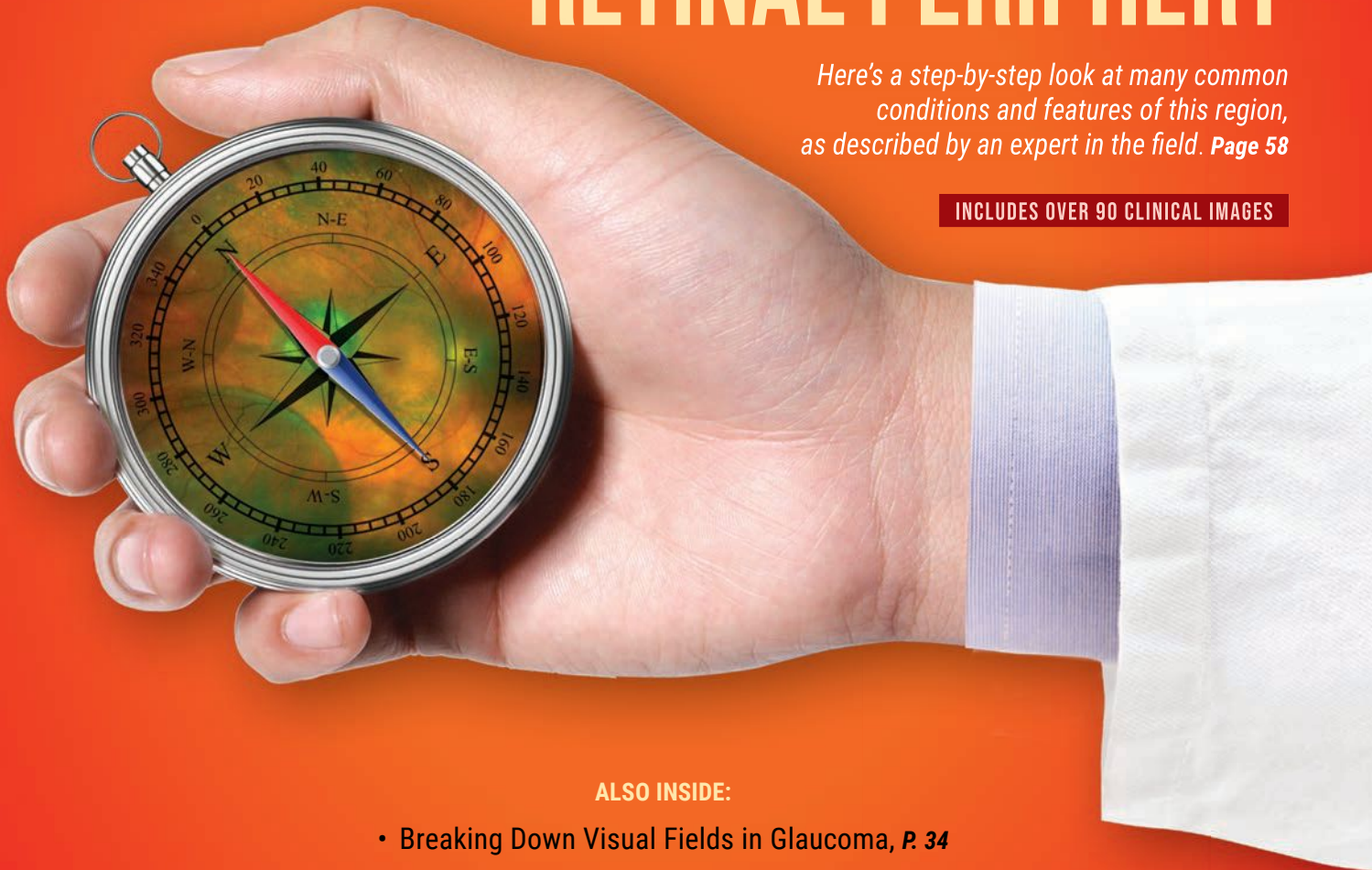
Annual
Diagnostic Skills
& Techniques
Issue

Retina • Diplopia • Eyelids
OCT • Visual Fields

NAVIGATING THE RETINAL PERIPHERY

Here's a step-by-step look at many common conditions and features of this region, as described by an expert in the field. Page 58

INCLUDES OVER 90 CLINICAL IMAGES



ALSO INSIDE:

- Breaking Down Visual Fields in Glaucoma, P. 34
- An Action Plan for Assessing Double Vision, P. 42
- Take Macular OCT to a Whole New Layer, P. 52
- The Role of Eyelids in Health and Disease, P. 70 – EARN 2 CE CREDITS

MOST.

The contact lens with the **most moisture** among leading brands.

MORE.

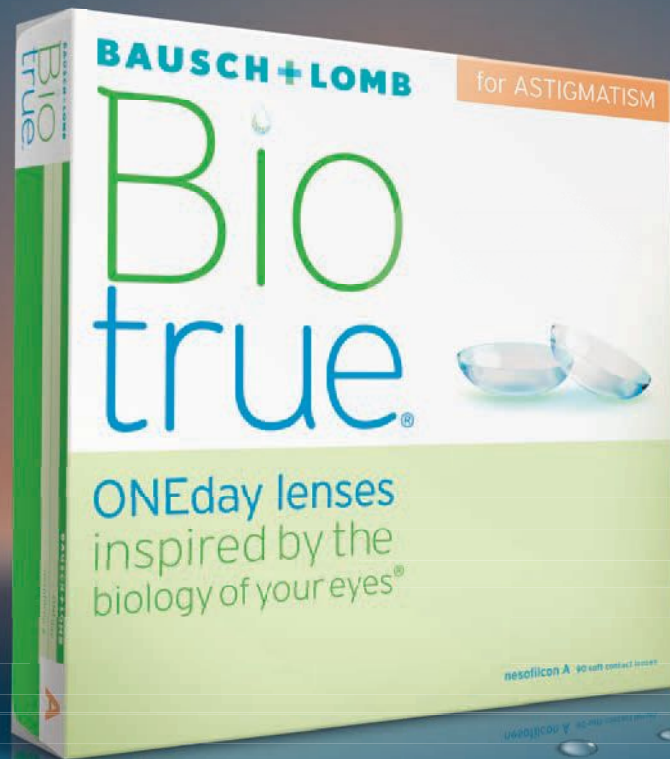The toric daily disposable with **more parameters** than any other.

ONLY.

Now, the **first and only** daily disposable with **-2.75 Cylinder** available as a standard offering.

-2.75 CYLINDER

DAILY DISPOSABLE IS NOW AVAILABLE



Fit the first and only daily disposable with a -2.75 Cylinder offering—Biotrue® ONEday for Astigmatism.



Most moisture and **toric parameters** among leading daily disposables



Helps reduce halos and glare, even in low light¹



Fast to fit with excellent centration at dispensing and follow-up²

Now available as a **standard offering** for **same-day fitting**.

REFERENCES: 1. Results of an online survey with patients who completed an evaluation program for Biotrue® ONEday for Astigmatism contact lenses and wore their trial lenses for ≥ 4 days (n=1001). **2.** Results from a 7-investigator, multi-site study of Biotrue® ONEday for Astigmatism contact lenses on 123 current non-daily disposable toric soft contact lens wearers. Lenses were worn on a daily wear basis for 1 week.

®/™ are trademarks of Bausch & Lomb Incorporated or its affiliates.
©2020 Bausch & Lomb Incorporated or its affiliates. BFA.0051.USA.20

BAUSCH + LOMB
See better. Live better.



Glaucoma Unduly Burdens Blacks, Asians

Study projects that the disease will primarily affect these ethnic groups by 2040.

A recent epidemiological literature review of glaucoma and those it affects suggests more interventions are needed to lighten the burden posed by this irreversible disease. Glaucoma is the second leading cause of blindness in the world and is estimated to affect approximately 76 million people today and as many as 111.8 million in the next 20 years.

The study found that 57.5 million people are affected by primary open-angle glaucoma (POAG) worldwide. In Europe, POAG affects 7.8 million people. The team's findings shed light on a potential genetic component of POAG.

East Asians under the age of 40 are more likely to be affected by primary angle-closure glaucoma (PACG) than European and Afro-Caribbean people. Those of the Igbo tribe of Nigeria—a very homogenous ethnic group—have the highest prevalence of glaucoma in the world.

“The severity of glaucoma begins at an earlier age and at a more aggressive course in Black people than in white people and Asians,” the researchers noted in their study. However, this may not be due entirely to genetic factors but partially “a result of a lack of early diagnosis and poor access to treatment,” they added. They noted that one study indicated that glaucoma service is affected by socioeconomic differences and inequalities.

Glaucoma's prevalence in those over 40 is highest among Black people, at 5.7% compared with 2.2% in white individuals. The prevalence of the

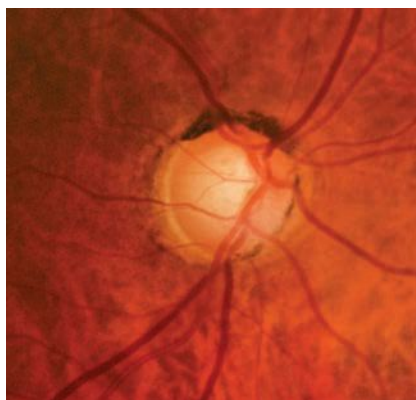


Photo: Justin Cole, OD, and Jarett Mazzarella, OD

Researchers recommend various interventions, such as telemedicine, regular glaucoma screening, genetic testing, a stronger educational push and more medication/surgery studies to reduce the risk.

disease generally increases with age, and POAG is strongly correlated with it; the investigators reported higher prevalences of glaucoma in older Hispanic and Latinx (18%), Black (15%), white (7%) and Asian (5%) individuals. They also found that males are 36% more likely to develop glaucoma than females. Males are at higher risk for POAG, while females are at higher risk for PACG.

Reporting rates of glaucoma in African countries tend to be lower since “surveys in African countries may have a limited diagnostic capacity.” Overall, West Africa tends to have a higher prevalence than South Africa, which has a higher prevalence than East Africa. Glaucoma prevalence in Nigeria is higher than that of Brazil, Iran, Qatar and the indigenous populations in Australia.

By 2040, most of those with

glaucoma will be of Asian or African ethnicities, according to the review. Europeans, North Americans and Oceanians will contribute to only a small number of the increase in POAG and PACG cases. Africa will see a projected 130.8% increase in cases from 2013 to 2040. Asia will see a 79.8% POAG increase and a 58.4% PACG increase in that same timespan. Stateside, one study estimated that Georgia's population, which is heavily Black, will have about 254,047 cases of glaucoma among those aged 40 and older by 2050.

The economic burden of glaucoma in the United States is \$2.9 billion. Studies reported that glaucoma patients incur, on average, an additional \$2,903 in annual total healthcare costs and higher outpatient costs by \$2,599 compared with those without the condition. Treating and preventing glaucoma costs approximately \$5.8 billion per year in the United States, and this number is expected to rise to \$12 billion by 2032 and \$17.3 billion by 2050. Prescription drugs are the main reason for the high cost.

“Detection at earlier stages is vital to prevent the progression of glaucoma,” the study authors concluded in their paper. They suggest a number of interventions, including telemedicine efforts (especially for rural areas), regular glaucoma screening, genetic testing, a stronger educational push, more medication/surgery studies and more diverse health care providers. ◀

Allison K, Patel K, Alabi O. Epidemiology of glaucoma: the past, present and predictions for the future. *Cureus*. November 24, 2020. [Epub ahead of print].

COMPREHENSIVE SERVICE SOLUTIONS



Repairs & Maintenance

Equipment repairs, lane tune-ups, cleaning, re-upholstery, and more



Protection Plans

Extended coverage for an individual instrument



Umbrella Policies

Comprehensive coverage for your entire practice

GET PEACE OF MIND

with full protection, prompt service, and ongoing support

CONVENIENT

Just one phone number to call for all of your repair and maintenance needs

EXPERIENCED

Manufacturer-trained technicians who are highly experienced in diagnostic and lane equipment repairs

AFFORDABLE

Major savings over individual service repairs from manufacturers



WE COVER MORE SO YOU WORRY LESS

Canon • Haag-Streit • Reliance • Heidelberg • Keeler • Lombart • Marco
Reichert • S4Optik • Topcon • Zeiss • And more!

Contact your local representative or call us directly for fast, reliable support.

855-777-2020

One Alliance • Six Industry Leaders • Hundreds of Years Experience

LOMBART



EMS



INNOVA

S4OPTIK

Vitamin B Combo Provides DED Relief

While omega-3s are commonly used to treat dry eye, a new study suggests oral vitamins B1 and mecobalamin, a form of B12, can also relieve symptoms, including dryness, pain and photophobia.

Investigators from China enrolled 152 eyes of 76 patients who were an average of 55 years old and divided them into four groups based on treatment regimen:

- Group 1: artificial tears
- Group 2: corticosteroid eye drops and artificial tears
- Group 3: oral vitamin B1, mecobalamin and artificial tears
- Group 4: same regimen as Group 3 with the addition of corticosteroid eye drops

The researchers assessed patients' symptoms, signs and satisfaction with treatment at baseline and again at one and two months.

Group 3 exhibited significant differences in dryness, foreign

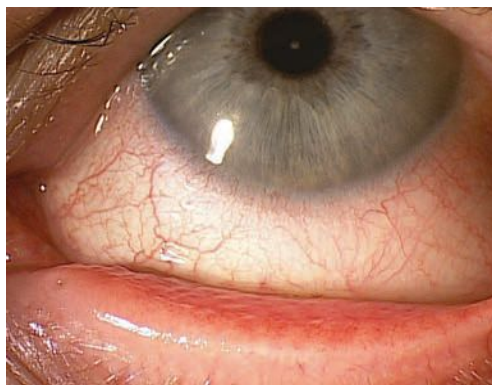


Photo: Paul Karpecki, OD, and Jeff Krall, OD

Dry eye symptoms improved significantly at two months following treatment with supplements and artificial tears.

body sensation, burning, average TBUT and patient satisfaction scores between months one and two following treatment. The same group also showed significant differences in dryness, foreign body sensation, photophobia and average TBUT between baseline and two months post-treatment.

Patients in Groups 3 and 4 had sig-

nificant differences in foreign body sensation between one and two months of treatment. Additionally, Group 4 patients noted significant improvements in pain, blurred vision and total symptom scores at one month after treatment.

The researchers also observed improvement in corneal nerve fiber density between baseline and one and two months after treatment in both of the groups taking vitamin B1.

“These observations suggest that oral vitamin B1 and mecobalamin can help nourish and repair the corneal nerve layer to some extent, thereby alleviating burning and photophobia,” the study authors concluded in their paper. Of note, oral vitamin B1 and mecobalamin were more effective in men than women, particularly for dryness and photophobia. ◀

Ren X, Chou Y, Jiang X, et al. Effects of oral vitamin B1 and mecobalamin on dry eye disease. *J Ophthalmol.* 2020;2020:9539674.

Exercise Causes Unique Ocular Changes in Kids

These eyes exhibited choroidal thinning and increased fundus vessel densities.

The benefits of exercise are well documented in all age groups; however, physical activity may impact children's eyes differently than adults, new research suggests.

A team from China and Singapore found that children who exercised for 20 minutes had significantly decreased choroidal thickness for at least 30 minutes after physical activity and increased fundus vessel density after rest. In addition, myopic and emmetropic eyes showed differences in choroidal thinning and retinal vessel density fluctuation after exercise.

The study enrolled 58 eyes of 58 children between ages nine and 13, including 40 myopic eyes (mean spherical equivalent [SE]: -3.27D) and 18

emmetropic eyes (mean SE: 0.03D). None of the participants had ocular or systemic disease, nor were they taking any medication.

The researchers conducted OCT imaging and measured heart rate, systolic and diastolic blood pressure and IOP before and immediately after the children cycled on a stationary bike for 20 minutes. These measurements were recorded again after 30 minutes of rest.

The investigators reported significantly decreased choroidal thickness after exercise in both myopic and emmetropic eyes and throughout the 30-minute rest period following physical activity. This finding differs from those reported in adults who had stable or even

increased choroidal thickness after exercise, the researchers noted.

Immediately after physical activity, retinal vessel density decreased in the deep retinal layers in myopic eyes. This result was consistent with previous studies investigating adult behavior, in which macular perfusion decreased after physical activity. Additionally, the vessel density of emmetropic eyes was higher in the superficial and deep layers after rest.

Another key finding: IOP didn't significantly change during exercise or after the rest period, which is contrary to results of similar studies in adults that showed a reduction in IOP. ◀

Li S, Pan Y, Xu J, et al. Effects of physical exercise on macular vessel density and choroidal thickness in children. *Sci Rep.* January 21, 2021. [Epub ahead of print].

Simplicity.

Quote, buy,
and download
your policy all
in 5 minutes.

Savings + Simplicity + Security,
it all adds up with Berxi. Get a
medical malpractice insurance
quote at berxi.com.



BERXI IS PART OF BERKSHIRE HATHAWAY SPECIALTY INSURANCE COMPANY

© Copyright 2020. The information contained herein is for general informational purposes only and does not constitute an offer to sell or a solicitation of an offer to buy any product or service. Any description set forth herein does not include all policy terms, conditions and exclusions. Please refer to the actual policy for complete details of coverage and exclusions. All policies are underwritten by Berkshire Hathaway Specialty Insurance Company, 1 Lincoln Street, 23rd Floor, Boston, MA 02111

Retina Reflects Drug Effectiveness in Psych Disorders

The retina is sometimes considered a window to the brain due to similarities in their development and mechanisms of pathology. Looking into the retina's ability to mirror the effects of treatment, researchers from Turkey found OCT imaging of RNFL thickness may be helpful in evaluating drug therapies for schizophrenia and bipolar disorder.

The study included 35 patients with schizophrenia, 46 patients with euthymic bipolar disorder and 31 controls. The patients in the schizophrenia group took either risperidone or clozapine. In the bipolar disorder group, a team measured the serum levels of valproate and lithium. Additionally, they calculated the chlorpromazine-equivalent doses of antipsychotics and mood stabilizers.

In the bipolar patients, the serum

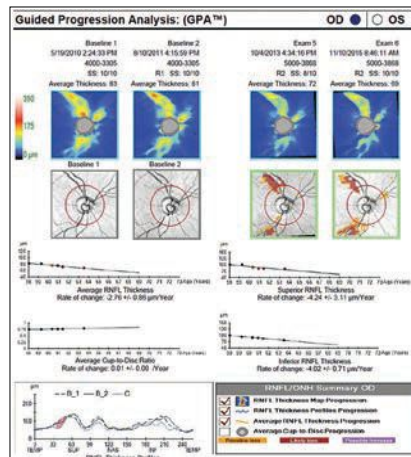


Photo: Danica J. Marelli, OD

Researchers from Turkey found RNFL thickness may help evaluate treatments for schizophrenia and bipolar disorder.

valproate level was a positive predictor for the thickness of the right macular inferior outer and left macular nasal outer regions and the right infero-

temporal, left inferotemporal and left temporal RNFL subregions.

Of importance, the chlorpromazine-equivalent dose of antipsychotics was a negative predictor of thickness in certain optic nerve regions in both schizophrenia and bipolar disorder. In schizophrenia patients, the chlorpromazine-equivalent risperidone doses were determined to be a negative predictor of the left nasal and left inferonasal region thickness.

“This outcome implies that valproate has neuroprotective effects on the optic nerve and macula, and this finding is consistent with the literature implying neurotrophic effects of valproate,” the authors concluded in their paper. ◀

Altun IK, Turedi N, Aras N, et al. Psychopharmacological signatures in the retina in schizophrenia and bipolar disorder: an optic coherence tomography study. *Psychiatr Danub.* 2020;32(3-4):351-8.

Migraine Associated with Increased Risk of RAO

Researchers from the Byers Eye Institute at the Stanford University School of Medicine recently determined that a migraine diagnosis is associated with increased risk of many types of retinal artery occlusion (RAO). They noted that individuals who are diagnosed with migraine with aura are at an even higher risk of RAO.

To investigate the association between migraine and risk of RAO, central RAO (CRAO), branch RAO (BRAO) and other types of occlusive disease, which includes transient and partial RAO, the study analyzed 418,965 patients with migraine and

matched controls. Among the participants, 1,060 (0.25%) patients with migraine were subsequently diagnosed with RAO, whereas only 335 (0.08%) patients without migraine were diagnosed with RAO.

Nevertheless, the hazard ratio (HR) for incident RAO in patients with migraine compared with those without migraine was 3.48. This association was consistent across all types of RAO, including CRAO (HR=1.62), BRAO (HR=2.09) and other types of RAO (HR=4.61).

The researchers found that patients with migraine with aura had a higher risk for incident RAO compared with

those with migraine without aura (HR=1.58). This association remained consistent for BRAO (HR=1.43) and other types of RAO (HR=1.67); however, it was not statistically significant for CRAO (HR=1.18).

The study noted that significant risk factors for the association between migraine and RAO risk included older age, male sex, acute coronary syndrome, valvular disease, carotid disease, hyperlipidemia, hypertension, retinal vasculitis and/or inflammation and systemic lupus erythematosus. ◀

Al-Moujahed, Tran EM, Azad A, et al. Risk of retinal artery occlusion in patients with migraine. *Am J Ophthalmol.* December 24, 2020. [Epub ahead of print].

IN BRIEF

Perimetry is a standard part of assessing glaucomatous visual field (VF) loss, but using only 24-2 or only 10-2 isn't sufficient to cover all the possible types of defects. **A recent**

study investigated the combined use of these two VF tests and found more satisfactory visual outcomes. For glaucoma patients with peripheral nasal step, combined VF testing and 24-2 perimetry were significantly superior to the 10-2 test regarding

the superotemporal topographic structure-function relationship with peripapillary retinal nerve fiber layer thickness. The combined VF test also demonstrated **“more favorable inferotemporal or inferonasal structure-function correlation**

with the corresponding ganglion cell-inner plexiform layer thickness when compared with results gleaned using the 24-2 VF test.”

Jung KI, Ryu HK, Hong KH, et al. Simultaneously performed combined 24-2 and 10-2 visual field tests in glaucoma. *Sci Rep.* 2021;11:1227.

UPNEEQ

Give Ptosis Patients an EYE-OPENING Lift
With a Daily Drop of Upneeq® (oxymetazoline hydrochloride ophthalmic solution), 0.1%¹

The only FDA-approved prescription eyedrop proven to lift upper eyelids in adults with acquired blepharoptosis (low-lying lids)¹

Learn more at Upneeq.com.

INDICATION

Upneeq® (oxymetazoline hydrochloride ophthalmic solution), 0.1% is indicated for the treatment of acquired blepharoptosis in adults.

IMPORTANT SAFETY INFORMATION

WARNINGS AND PRECAUTIONS

- Alpha-adrenergic agonists as a class may impact blood pressure. Advise Upneeq patients with cardiovascular disease, orthostatic hypotension, and/or uncontrolled hypertension or hypotension to seek medical care if their condition worsens.
- Use Upneeq with caution in patients with cerebral or coronary insufficiency or Sjögren's syndrome. Advise patients to seek medical care if signs and symptoms of potentiation of vascular insufficiency develop.
- Upneeq may increase the risk of angle closure glaucoma in patients with untreated narrow-angle glaucoma. Advise patients to seek immediate medical care if signs and symptoms of acute narrow-angle glaucoma develop.
- Patients should not touch the tip of the single patient-use container to their eye or to any surface, in order to avoid eye injury or contamination of the solution.

ADVERSE REACTIONS

Adverse reactions that occurred in 1-5% of subjects treated with Upneeq were punctate keratitis, conjunctival hyperemia, dry eye, blurred vision, instillation site pain, eye irritation, and headache.

DRUG INTERACTIONS

- Alpha-adrenergic agonists, as a class, may impact blood pressure. Caution in using drugs such as beta blockers, anti-hypertensives, and/or cardiac glycosides is advised. Caution should also be exercised in patients receiving alpha adrenergic receptor antagonists such as in the treatment of cardiovascular disease, or benign prostatic hypertrophy.
- Caution is advised in patients taking monoamine oxidase inhibitors which can affect the metabolism and uptake of circulating amines.

To report SUSPECTED ADVERSE REACTIONS or product complaints, contact RVL Pharmaceuticals at 1-877-482-3788. You may also report SUSPECTED ADVERSE REACTIONS to the FDA at 1-800-FDA-1088 or www.fda.gov/medwatch.

Please see next page for Brief Summary of full Prescribing Information.

Reference: 1. Upneeq® (oxymetazoline hydrochloride ophthalmic solution), 0.1%. [Prescribing Information].

RVL
PHARMACEUTICALS, INC.

Distributed by: RVL Pharmaceuticals, Inc.
Bridgewater, NJ 08807
Customer Service 1-866-600-4799
Upneeq is a registered trademark of RVL Pharmaceuticals, Inc.
©2021 RVL Pharmaceuticals, Inc.
PM-US-UPN-0197 01/21

Learn more at Upneeq.com



UPNEEQ[®]
(oxymetazoline hydrochloride ophthalmic solution), 0.1%*

*Each mL of Upneeq contains 1 mg of oxymetazoline hydrochloride, equivalent to 0.09 mg (0.09%) of oxymetazoline free base.

Eye-Opening Possibilities

UPNEEQ® (oxymetazoline hydrochloride ophthalmic solution), 0.1%, for topical ophthalmic use

*Each mL of UPNEEQ contains 1 mg of oxymetazoline hydrochloride, equivalent to 0.09 mg (0.09%) of oxymetazoline free base.

BRIEF SUMMARY: The following is a brief summary only; see full Prescribing Information at <https://www.upneeq.com/Upneeq-PI.pdf> for complete information.

1 INDICATIONS AND USAGE

UPNEEQ is indicated for the treatment of acquired blepharoptosis in adults.

2 DOSAGE AND ADMINISTRATION

Contact lenses should be removed prior to instillation of UPNEEQ and may be reinserted 15 minutes following its administration.

If more than one topical ophthalmic drug is being used, the drugs should be administered at least 15 minutes between applications.

4 CONTRAINDICATIONS

None.

5 WARNINGS AND PRECAUTIONS

5.1 Potential Impacts on Cardiovascular Disease

Alpha-adrenergic agonists may impact blood pressure. UPNEEQ should be used with caution in patients with severe or unstable cardiovascular disease, orthostatic hypotension, and uncontrolled hypertension or hypotension. Advise patients with cardiovascular disease, orthostatic hypotension, and/or uncontrolled hypertension/hypotension to seek immediate medical care if their condition worsens.

5.2 Potentiation of Vascular Insufficiency

UPNEEQ should be used with caution in patients with cerebral or coronary insufficiency, or Sjögren's syndrome. Advise patients to seek immediate medical care if signs and symptoms of potentiation of vascular insufficiency develop.

5.3 Risk of Angle Closure Glaucoma

UPNEEQ may increase the risk of angle closure glaucoma in patients with untreated narrow-angle glaucoma. Advise patients to seek immediate medical care if signs and symptoms of acute angle closure glaucoma develop.

5.4 Risk of Contamination

Patients should not touch the tip of the single patient-use container to their eye or to any surface, in order to avoid eye injury or contamination of the solution.

6 ADVERSE REACTIONS

6.1 Clinical Trials Experience

Because clinical trials are conducted under widely varying conditions, adverse reaction rates observed in the clinical trials of a drug cannot be directly compared to rates in the clinical trials of another drug and may not reflect the rates observed in practice.

A total of 360 subjects with acquired blepharoptosis were treated with UPNEEQ once daily in each eye for at least 6 weeks in three controlled Phase 3 clinical trials, including 203 subjects treated with UPNEEQ for 6 weeks and 157 subjects treated with UPNEEQ for 12 weeks. Adverse reactions that occurred in 1-5% of subjects treated with UPNEEQ were punctate keratitis, conjunctival hyperemia, dry eye, blurred vision, instillation site pain, eye irritation, and headache.

7 DRUG INTERACTIONS

7.1 Anti-hypertensives/Cardiac Glycosides

Alpha-adrenergic agonists, as a class, may impact blood pressure. Caution in using drugs such as beta-blockers, anti-hypertensives, and/or cardiac glycosides is advised.

Caution should also be exercised in patients receiving alpha adrenergic receptor antagonists such as in the treatment of cardiovascular disease, or benign prostatic hypertrophy.

7.2 Monoamine Oxidase Inhibitors

Caution is advised in patients taking MAO inhibitors which can affect the metabolism and uptake of circulating amines.

8 USE IN SPECIFIC POPULATIONS

8.1 Pregnancy

Risk Summary

There are no available data on UPNEEQ use in pregnant women to inform a drug-associated risk for major birth defects and miscarriage. In animal reproduction studies, there were no adverse developmental effects observed after oral administration of oxymetazoline hydrochloride in pregnant rats and rabbits at systemic exposures up to 7 and 278 times the maximum recommended human ophthalmic dose (MRHOD), respectively, based on dose comparison. [see Data]. The estimated background risks of major birth defects and miscarriage for the indicated population are unknown. All pregnancies have a background risk of birth defect, loss, or other adverse outcomes. In the U.S. general population, the estimated background risk of major birth defects and miscarriage in clinically recognized pregnancies is 2-4% and 15-20%, respectively.

Data

Animal Data

Effects on embryo-fetal development were evaluated in rats and rabbits following oral administration of oxymetazoline hydrochloride during the period of organogenesis. Oxymetazoline hydrochloride did not cause adverse effects to the fetus at oral doses up to 0.2 mg/kg/day in pregnant rats during the period of organogenesis (28 times the MRHOD, on a dose comparison basis). Oxymetazoline hydrochloride did not cause adverse effects to the fetus at oral doses up to 1 mg/kg/day in pregnant rabbits during the period of organogenesis (278 times the MRHOD, on a dose comparison basis). Maternal toxicity, including decreased maternal body weight, was produced at the high dose of 1 mg/kg/day in pregnant rabbits and was associated with findings of delayed skeletal ossification.

In a rat prenatal and postnatal development study, oxymetazoline hydrochloride was orally administered to pregnant rats once daily from gestation day 6 through lactation day 20. Maternal toxicity was produced at the high dose of 0.2 mg/kg/day (28 times the MRHOD, on a dose comparison basis) in pregnant rats and was associated with an increase in pup mortality and reduced pup body weights. Delayed sexual maturation was noted at 0.1 mg/kg/day (14 times the MRHOD, on a dose comparison basis). Oxymetazoline hydrochloride did not have any adverse effects on fetal development at a dose of 0.05 mg/kg/day (7 times the MRHOD, on a dose comparison basis).

8.2 Lactation

Risk Summary

No clinical data are available to assess the effects of oxymetazoline on the quantity or rate of breast milk production, or to establish the level of oxymetazoline present in human breast milk post-dose. Oxymetazoline was detected in the milk of lactating rats. The developmental and health benefits of breastfeeding should be considered along with the mother's clinical need for UPNEEQ and any potential adverse effects on the breastfed child from UPNEEQ.

8.4 Pediatric Use

Safety and effectiveness of UPNEEQ have not been established in pediatric patients under 13 years of age.

8.5 Geriatric Use

Three hundred and fifteen subjects aged 65 years and older received treatment with UPNEEQ (n = 216) or vehicle (n = 99) in clinical trials. No overall differences in safety or effectiveness were observed between subjects 65 years of age and older and younger subjects.

10 OVERDOSAGE

Accidental oral ingestion of topical intended solutions (including ophthalmic solutions and nasal sprays) containing imidazoline derivatives (e.g., oxymetazoline) in children has resulted in serious adverse events requiring hospitalization, including nausea, vomiting, lethargy, tachycardia, decreased respiration, bradycardia, hypotension, hypertension, sedation, somnolence, mydriasis, stupor, hypothermia, drooling, and coma. Keep UPNEEQ out of reach of children.

PATIENT COUNSELING INFORMATION

Advise the patient to read the FDA-approved patient labeling (Instructions for Use).

RVL
PHARMACEUTICALS, INC.

Manufactured for: RVL Pharmaceuticals, Inc.
Bridgewater, New Jersey 08807
©2021 RVL Pharmaceuticals, Inc.
UPNEEQ is a registered trademark of RVL Pharmaceuticals, Inc.
PM-US-UPN-0203 01/21

Vision Expo East Moves Dates and Venue

Breaking with tradition, Vision Expo East (VEE) will move out of its longtime setting at New York's Jacob Javits Center this year, opting instead for Orlando, The Vision Council announced recently. The decision was based on the current restrictions on large gatherings in New York State and the successful track record of previous events held at the Orange County Convention Center, a press release explains.

"It is our mission and responsibility to the vision care community to provide a platform to effectively show products and conduct business," said Mitch Barkley, vice president of Trade Shows and Meetings at The Vision Council. "With strict limitations on large gatherings still in place in New York, we wanted to find a suitable

location that would allow us to provide the exceptional Vision Expo experience that the community needs and deserves."

The show dates will also be pushed out a week. Originally planned to run May 25-28, VEE will now happen June 2-5, organizers say. Education begins June 2, and exhibits open the next day.

The Vision Council cites the new venue's "track record of successfully hosting more than 50 in-person events between March 2020 and December 2020" and expresses confidence that "the right decision is to move the show to the Orange County Convention Center as the new 2021 host site in order to give our customers every opportunity to network and share their new products."

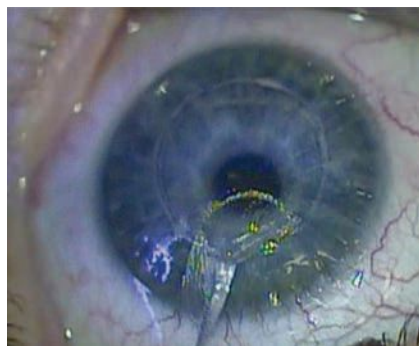
The Orlando convention center "has strict health and safety precautions in place," the press release notes. It explains that the event will be "upholding all nationally recommended precautions, including mandatory mask-wearing and social distancing."

"The decision to adjust the show dates and location is a positive solution in the midst of a challenging time for everyone," said Fran Pennella, event vice president, Vision Expo, at Reed Exhibitions. "As we continue our planning efforts, the health, wellbeing and safety of everyone in attendance at the Show continues to be our top priority, and we will be working closely with the Orange County Convention Center to ensure all health and safety guidelines and procedures are maintained." ◀

SMILE Gets Good Marks for High Myopes

Small-incision lenticule extraction (SMILE) has risen to fame as a safer alternative to LASIK for correcting myopia and astigmatism, but this technique—and corneal refractive surgery in general—sometimes results in increased higher-order aberrations (HOAs), such as coma and spherical aberration, which decrease vision quality. Considering the effectiveness of this procedure in high myopes, a recent study found that SMILE didn't alter the amplitude of accommodation, accommodative response or accommodative facility in these patients, nor did surgically induced corneal HOAs affect these patients' accommodative function.

A research team from Denmark and Singapore enrolled 35 highly myopic eyes (a myopic spherical equivalent of at least 6.00D) and 35 healthy patients who underwent SMILE surgery. Participants were evaluated at baseline and three



Accommodation issues were minimal after the procedure, research shows.

months after surgery. Preoperative accommodation assessment was performed while patients wore their contact lenses to correct their refractive error and neutralize any potential accommodative problems corresponding to a shift from a correction in the spectacle plane to the corneal plane.

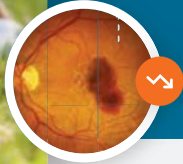Post-SMILE, the study found the amplitude of accommodation change

wasn't statistically significant (mean difference: -0.24D). Additionally, accommodative responses measured at 0.00D, 0.50D, 1.25D, 2.00D, 3.00D and 4.00D didn't markedly change. The accommodative facility was also unchanged with a mean difference of 1.11 cycles per minute, and no clinically significant associations between changes in accommodation and HOAs were noted.

Based on these results, patients with high myopia don't need to be informed about any particular risks for reduced accommodation due to SMILE per se, but all individuals—especially those with high myopia—should be informed about the extra accommodative effort needed when changing correction from the spectacle plane to the corneal plane, the researchers explained. ◀

Gyldenkerne A, Aagaard N, Jakobsen M, et al. Changes in accommodative function following small-incision lenticule extraction for high myopia. *PLoS One*. 2020;15(12): e0244602.

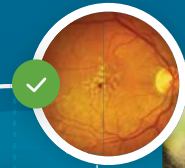AMD Standard of Care is Not Enough



IRIS REGISTRY

20/83 VA

Average at wet AMD diagnosis according to IRIS Registry real-world data¹



HOME STUDY

≥20/40 VA

Average at wet AMD diagnosis with ForeseeHome²



Early Detection Helps Preserve Vision

ForeseeHome is a **remote monitoring** program for at-risk dry AMD patients that helps **detect wet AMD earlier** and alerts you of changes.



ForeseeHOME™
AMD Monitoring Program

Remote patient monitoring leads to better outcomes and stronger optometric practices

- Provide a high level of care
- Differentiate your practice
- Solidify long-term relationships with your patients
- Strengthen your referral relationships with qualified wet AMD referrals

Our Diagnostic Clinic is the Key to Successful Remote Monitoring



Engagement & Education

Benefits Verification & Authorization

Continuous Monitoring



Practice Workflow Implementation

Remote Patient Management

Vision Alert Management



ForeseeHome is a registered trademark, and the ForeseeHome AMD Monitoring Program and logo and the Notal Vision logo are trademarks of Notal Vision. © 2020 Notal Vision, Inc. All rights reserved.

References: 1. Rao P et al. *Ophthalmology*. 2018;125(4):522-528. 2. Domalpally A, Clemons TE, Bressler SB, et al. *Ophthalmol Retina*. 2019;3(4):326-335.

See website for FDA Indication for Use.

SM-068.01



GET STARTED TODAY

1-855-600-3112

Mon-Fri, 8 AM to 6 PM EST

www.foreseehome.com/hcp

FEATURES

REVIEW OF OPTOMETRY • Vol. 158, No. 2 • FEBRUARY 15, 2021



CATCH UP ON THE LATEST NEWS

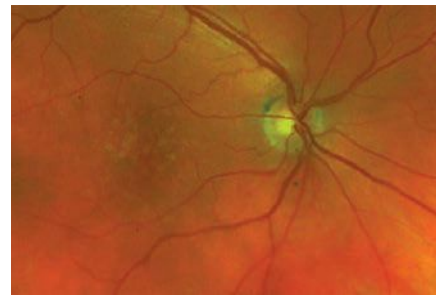
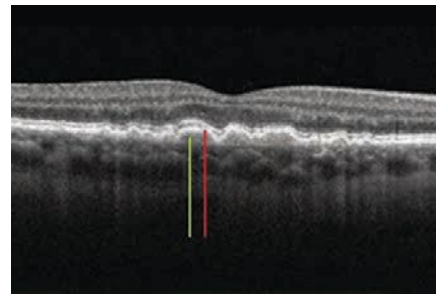
- ▶ Stories post online every weekday
- ▶ Weekly recap emailed every Sunday

52

Take Macular OCT to a Whole New Layer

Combine your clinical observations and knowledge with detailed imaging to put together the full picture of the diagnosis.

By Sara Weidmayer, OD



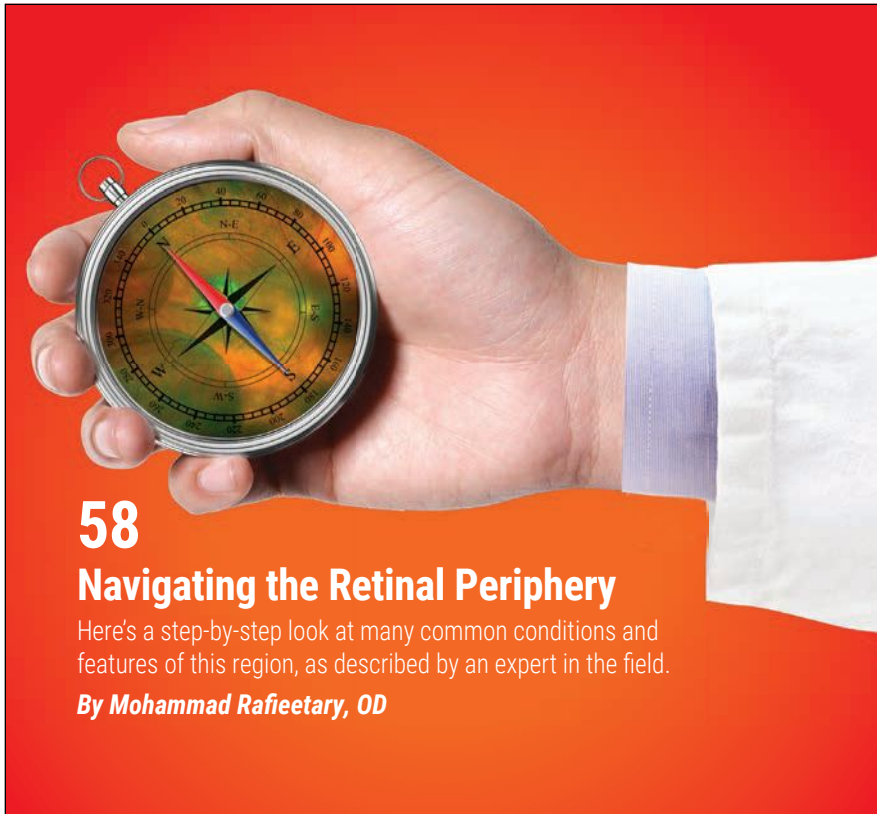
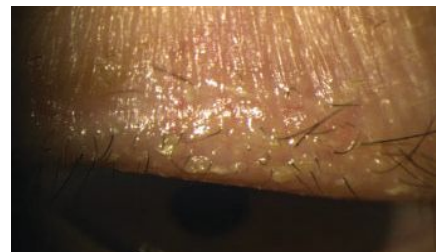70

The Role of Eyelids in Health and Disease

Understanding how the lids can fail is critical to ensuring optimal patient care.

By Victoria Roan, OD

EARN 2 CE CREDITS



58

Navigating the Retinal Periphery

Here's a step-by-step look at many common conditions and features of this region, as described by an expert in the field.

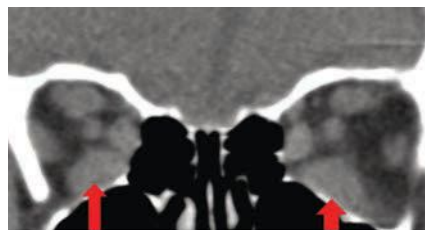
By Mohammad Rafieetary, OD

34

Breaking Down Visual Fields in Glaucoma

The OD must possess a solid understanding of the technology at their disposal in order to make the best decisions for patients.

By Danica Marrelli, OD

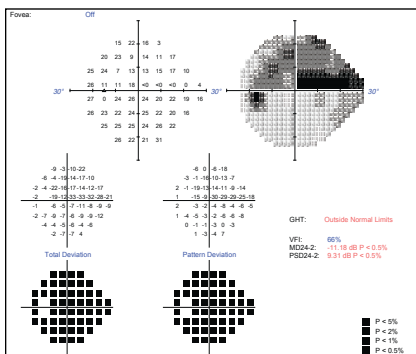


42

An Action Plan for Assessing Double Vision

Ask these 20 questions to work through a puzzling case of diplopia and figure out the best course of action.

By Erin Draper, OD, and Tina Zeng, OD



DEPARTMENTS

REVIEW OF OPTOMETRY • FEBRUARY 15, 2021

4

NEWS REVIEW

18

OUTLOOK

Can't Get There From Here

New grads who want to practice full-scope care may find no easy path available, with patients suffering collateral damage.

Jack Persico, Editor-in-Chief

20

THROUGH MY EYES

The Essential Eyelid Examination

In a busy practice, you can't do it all. But added emphasis on this aspect can help many patients with relative ease.

Paul M. Karpecki, OD

22

CHAIRSIDE

Shout-out to the Staffers

Don't forget these key things in the struggle to help us doctors appear more competent than we are.

Montgomery Vickers, OD

24

CLINICAL QUANDARIES

Blowing in the Wind

The case of a mysterious irritated eye can be solved with some targeted questions.

Paul C. Ajamian, OD

26

CODING CONNECTION

Specificity is the Spice of Life

Not only does each CPT code have a distinct definition, but it also reflects the characteristics for a specific procedure.

John Rumpakis, OD, MBA

28

FOCUS ON REFRACTION

A Twofold Effect

A small amount of prism was enough to give this patient visual relief as well as reduce his Parkinson's medication burden.

*Marc B. Taub, OD, MS,
and Paul Harris, OD*

30

THERAPEUTIC REVIEW

An Unexpected Visitor

An extremely late surgical complication led to this patient's symptoms.

Joseph W. Sowka, OD

78

CORNEA AND CONTACT LENS Q+A

Weigh Your Options

There are many different treatments available for corneal endothelial disease, but efficient patient selection leads to the most successful outcomes.

Joseph P. Shovlin, OD

80

GLAUCOMA GRAND ROUNDS

It Takes Two to Manage Glaucoma

New patients who present without a complete medical history must be willing to work even more closely with their OD.

James L. Fanelli, OD

84

OCULAR SURFACE REVIEW

Light Therapy: Which is Better, One or Two?

A look at dry eye treatments that focus on the healing powers of energy rather than pharmacology.

Paul M. Karpecki, OD

86

SURGICAL MINUTE

A New Wave

Vivity, a non-diffractive lens, seeks to up the ante in premium IOL visual quality for presbyopia correction.

By Patrizia Colmenares, OD

*Edited by Derek N. Cunningham, OD,
and Walter O. Whitley, OD, MBA*

85

ADVERTISERS INDEX

88

PRODUCT REVIEW

89

CLASSIFIED ADVERTISING

90

DIAGNOSTIC QUIZ

Unsafe at Any Speed

A patient experiences vision trouble after a car accident. What might have happened?

Andrew S. Gurwood, OD



VISIT US ON SOCIAL MEDIA

Facebook: www.facebook.com/revoptom

Twitter: twitter.com/revoptom



SUBMICRON STRONG

for

POTENCY + PROVEN STRENGTH^{1,2}

2× greater inflammation clearance
as compared to vehicle^{2*}

SM TECHNOLOGY™

- Engineered with SM Technology™ for efficient penetration at a low BAK level (0.003%)^{1,3}
- ~2× greater penetration to the aqueous humor than LOTEMAX® GEL (loteprednol etabonate ophthalmic gel) 0.5%³

Clinical significance of these preclinical data has not been established.

LOTEMAX® SM

(loteprednol etabonate
ophthalmic gel) 0.38%

SMALL & MIGHTY
SUBMICRON PARTICLES

*PROVEN STRENGTH

- 30% of LOTEMAX® SM patients had complete ACC resolution vs vehicle (15%) at Day 8 (N=371, $P < 0.0001$)^{1,2†}
- 74% of LOTEMAX® SM patients were completely pain-free vs vehicle (49%) at Day 8 (N=371, $P < 0.0001$)^{1,2‡}

†Pooled analysis of Phase 3 clinical studies. Study 1: 29% LOTEMAX® SM (N=171) vs 9% vehicle (N=172). Study 2: 31% LOTEMAX® SM (N=200) vs 20% vehicle (N=199); $P < 0.05$ for all.

‡Pooled analysis of Phase 3 clinical studies. Study 1: 73% LOTEMAX® SM (N=171) vs 48% vehicle (N=172). Study 2: 76% LOTEMAX® SM (N=200) vs 50% vehicle (N=199); $P < 0.05$ for all.

Indication

LOTEMAX® SM (loteprednol etabonate ophthalmic gel) 0.38% is a corticosteroid indicated for the treatment of post-operative inflammation and pain following ocular surgery.

Important Safety Information

- LOTEMAX® SM, as with other ophthalmic corticosteroids, is contraindicated in most viral diseases of the cornea and conjunctiva including epithelial herpes simplex keratitis (dendritic keratitis), vaccinia, and varicella, and also in mycobacterial infection of the eye and fungal diseases of ocular structures.
- Prolonged use of corticosteroids may result in glaucoma with damage to the optic nerve, defects in visual acuity and fields of vision. Steroids should be used with caution in the presence of glaucoma. If LOTEMAX® SM is used for 10 days or longer, IOP should be monitored.
- Use of corticosteroids may result in posterior subcapsular cataract formation.

BAUSCH + LOMB

©/TM are trademarks of Bausch & Lomb Incorporated or its affiliates.

© 2019 Bausch & Lomb Incorporated or its affiliates. All rights reserved. Printed in USA. LSM.0206.USA.19

Important Safety Information (cont.)

- The use of steroids after cataract surgery may delay healing and increase the incidence of bleb formation. In those with diseases causing thinning of the cornea or sclera, perforations have been known to occur with the use of topical steroids. The initial prescription and renewal of the medication order should be made by a physician only after examination of the patient with the aid of magnification such as slit lamp biomicroscopy and, where appropriate, fluorescein staining.
- Prolonged use of corticosteroids may suppress the host response and thus increase the hazard of secondary ocular infections. In acute purulent conditions, steroids may mask infection or enhance existing infections.
- Employment of a corticosteroid medication in the treatment of patients with a history of herpes simplex requires great caution. Use of ocular steroids may prolong the course and may exacerbate the severity of many viral infections of the eye (including herpes simplex).
- Fungal infections of the cornea are particularly prone to develop coincidentally with long-term local steroid application. Fungus invasion must be considered in any persistent corneal ulceration where a steroid has been used or is in use. Fungal cultures should be taken when appropriate.
- Contact lenses should not be worn when the eyes are inflamed.
- There were no treatment-emergent adverse drug reactions that occurred in more than 1% of subjects in the three times daily group compared to vehicle.

You are encouraged to report negative side effects of prescription drugs to the FDA. Visit www.fda.gov/medwatch or call 1-800-FDA-1088.

Please see brief summary of Prescribing Information on adjacent page.

References: 1. LOTEMAX SM Prescribing Information. Bausch & Lomb Incorporated. 2. Data on file. Bausch & Lomb Incorporated. 3. Cavet ME, Glogowski S, Lowe ER, Phillips E. Rheological properties, dissolution kinetics, and ocular pharmacokinetics of loteprednol etabonate (submicron) ophthalmic gel 0.38%. *J Ocul Pharmacol Ther.* 2019. doi: 10.1089/jop.2019.35(5):291-300.

Discover more at
www.LOTEMAXSM.com

LOTEMAX® SM
(loteprednol etabonate
ophthalmic gel) 0.38%

BRIEF SUMMARY OF PRESCRIBING INFORMATION

This Brief Summary does not include all the information needed to use LOTEMAX® SM safely and effectively. See full prescribing information for LOTEMAX® SM.

LOTEMAX® SM (loteprednol etabonate ophthalmic gel) 0.38%

For topical ophthalmic use

Initial U.S. Approval: 1998

INDICATIONS AND USAGE

LOTEMAX® SM is a corticosteroid indicated for the treatment of post-operative inflammation and pain following ocular surgery.

DOSAGE AND ADMINISTRATION

Invert closed bottle and shake once to fill tip before instilling drops. Apply one drop of LOTEMAX® SM into the conjunctival sac of the affected eye three times daily beginning the day after surgery and continuing throughout the first 2 weeks of the post-operative period.

CONTRAINDICATIONS

LOTEMAX® SM, as with other ophthalmic corticosteroids, is contraindicated in most viral diseases of the cornea and conjunctiva including epithelial herpes simplex keratitis (dendritic keratitis), vaccinia, and varicella, in mycobacterial infection of the eye and fungal diseases of ocular structures.

WARNINGS AND PRECAUTIONS

Intraocular Pressure (IOP) Increase: Prolonged use of corticosteroids may result in glaucoma with damage to the optic nerve, defects in visual acuity and fields of vision. Steroids should be used with caution in the presence of glaucoma. If this product is used for 10 days or longer, intraocular pressure should be monitored.

Cataracts: Use of corticosteroids may result in posterior subcapsular cataract formation.

Delayed Healing: The use of steroids after cataract surgery may delay healing and increase the incidence of bleb formation. In those diseases causing thinning of the cornea or sclera, perforations have been known to occur with the use of topical steroids. The initial prescription and renewal of the medication order should be made by a physician only after examination of the patient with the aid of magnification such as slit lamp biomicroscopy and, where appropriate, fluorescein staining.

Bacterial Infections: Prolonged use of corticosteroids may suppress the host response and thus increase the hazard of secondary ocular infections. In acute purulent conditions of the eye, steroids may mask infection or enhance existing infection.

Viral infections: Employment of a corticosteroid medication in the treatment of patients with a history of herpes simplex requires great caution. Use of ocular steroids may prolong the course and may exacerbate the severity of many viral infections of the eye (including herpes simplex).

Fungal Infections: Fungal infections of the cornea are particularly prone to develop coincidentally with long-term local steroid application. Fungus invasion must be considered in any persistent corneal ulceration where a steroid has been used or is in use. Fungal cultures should be taken when appropriate.

Contact Lens Wear: Contact lenses should not be worn when the eyes are inflamed.

ADVERSE REACTIONS

Because clinical trials are conducted under widely varying conditions, adverse reaction rates observed in the clinical trials of a drug cannot be directly compared to rates in the clinical trials of another drug and may not reflect the rates observed in practice. Adverse reactions associated with ophthalmic steroids include elevated intraocular pressure, which may be associated with infrequent optic nerve damage, visual acuity and field defects, posterior subcapsular cataract formation, delayed wound healing and secondary ocular infection from pathogens including herpes simplex, and perforation of the globe where there is thinning of the cornea or sclera. There were no treatment-emergent adverse drug reactions that occurred in more than 1% of subjects in the three times daily group compared to vehicle.

USE IN SPECIAL POPULATIONS

Pregnancy: Risk Summary: There are no adequate and well controlled studies with loteprednol etabonate in pregnant women. Loteprednol etabonate produced teratogenicity at clinically relevant doses in the rabbit and rat when administered orally during pregnancy. Loteprednol etabonate

produced malformations when administered orally to pregnant rabbits at doses 4.2 times the recommended human ophthalmic dose (RHOD) and to pregnant rats at doses 106 times the RHOD. In pregnant rats receiving oral doses of loteprednol etabonate during the period equivalent to the last trimester of pregnancy through lactation in humans, survival of offspring was reduced at doses 10.6 times the RHOD. Maternal toxicity was observed in rats at doses 1066 times the RHOD, and a maternal no observed adverse effect level (NOAEL) was established at 106 times the RHOD. The background risk of major birth defects and miscarriage for the indicated population is unknown. However, the background risk in the U.S. general population of major birth defects is 2 to 4%, and of miscarriage is 15 to 20%, of clinically recognized pregnancies. Data: Animal Data. Embryofetal studies were conducted in pregnant rabbits administered loteprednol etabonate by oral gavage on gestation days 6 to 18, to target the period of organogenesis. Loteprednol etabonate produced fetal malformations at 0.1 mg/kg (4.2 times the recommended human ophthalmic dose (RHOD) based on body surface area, assuming 100% absorption). Spina bifida (including meningocele) was observed at 0.1 mg/kg, and exencephaly and craniofacial malformations were observed at 0.4 mg/kg (17 times the RHOD). At 3 mg/kg (128 times the RHOD), loteprednol etabonate was associated with increased incidences of abnormal left common carotid artery, limb flexures, umbilical hernia, scoliosis, and delayed ossification. Abortion and embryofetal lethality (resorption) occurred at 6 mg/kg (256 times the RHOD). A NOAEL for developmental toxicity was not established in this study. The NOAEL for maternal toxicity in rabbits was 3 mg/kg/day. Embryofetal studies were conducted in pregnant rats administered loteprednol etabonate by oral gavage on gestation days 6 to 15, to target the period of organogenesis. Loteprednol etabonate produced fetal malformations, including absent innominate artery at 5 mg/kg (106 times the RHOD); and cleft palate, agnathia, cardiovascular defects, umbilical hernia, decreased fetal body weight and decreased skeletal ossification at 50 mg/kg (1066 times the RHOD). Embryofetal lethality (resorption) was observed at 100 mg/kg (2133 times the RHOD). The NOAEL for developmental toxicity in rats was 0.5 mg/kg (10.6 times the RHOD). Loteprednol etabonate was maternally toxic (reduced body weight gain) at 50 mg/kg/day. The NOAEL for maternal toxicity was 5 mg/kg. A peri-/postnatal study was conducted in rats administered loteprednol etabonate by oral gavage from gestation day 15 (start of fetal period) to postnatal day 21 (the end of lactation period). At 0.5 mg/kg (10.6 times the clinical dose), reduced survival was observed in live-born offspring. Doses \geq 5 mg/kg (106 times the RHOD) caused umbilical hernia/incomplete gastrointestinal tract. Doses \geq 50 mg/kg (1066 times the RHOD) produced maternal toxicity (reduced body weight gain, death), decreased number of live-born offspring, decreased birth weight, and delays in postnatal development. A developmental NOAEL was not established in this study. The NOAEL for maternal toxicity was 5 mg/kg.

Lactation: There are no data on the presence of loteprednol etabonate in human milk, the effects on the breastfed infant, or the effects on milk production. The developmental and health benefits of breastfeeding should be considered, along with the mother's clinical need for LOTEMAX® SM and any potential adverse effects on the breastfed infant from LOTEMAX® SM.

Pediatric Use: Safety and effectiveness of LOTEMAX® SM in pediatric patients have not been established.

Geriatric Use: No overall differences in safety and effectiveness have been observed between elderly and younger patients.

NONCLINICAL TOXICOLOGY

Carcinogenesis, Mutagenesis, Impairment of Fertility: Long-term animal studies have not been conducted to evaluate the carcinogenic potential of loteprednol etabonate. Loteprednol etabonate was not genotoxic *in vitro* in the Ames test, the mouse lymphoma tk assay, or in the chromosomal aberration test in human lymphocytes, or *in vivo* in the mouse micronucleus assay. Treatment of male and female rats with 25 mg/kg/day of loteprednol etabonate (533 times the RHOD based on body surface area, assuming 100% absorption) prior to and during mating caused preimplantation loss and decreased the number of live fetuses/live births. The NOAEL for fertility in rats was 5 mg/kg/day (106 times the RHOD).

LOTEMAX is a trademark of Bausch & Lomb Incorporated or its affiliates.

© 2019 Bausch & Lomb Incorporated

Bausch + Lomb, a division of Valeant Pharmaceuticals North America LLC
Bridgewater, NJ 08807 USA

LSM.0091.USA.19

Based on 9669600-9669700

Revised: 02/2019

CLINICAL EDITORS

CHIEF CLINICAL EDITOR ~ PAUL M. KARPECKI, OD

ASSOCIATE CLINICAL EDITORS ~ JOSEPH P. SHOVLIN, OD, CHRISTINE SINDT, OD

CONTRIBUTING EDITORS

PAUL C. AJAMIAN, OD, ATLANTA
DEREK N. CUNNINGHAM, OD, AUSTIN, TEXAS
MARK T. DUNBAR, OD, MIAMI
JAMES L. FANELLI, OD, WILMINGTON, NC
ANDREW S. GURWOOD, OD, PHILADELPHIA
PAUL HARRIS, OD, MEMPHIS, TENN.
PAUL M. KARPECKI, OD, LEXINGTON, KY.
BISANT LABIB, OD, ELKINS PARK, PA.

RICHARD B. MANGAN, OD, BOULDER, COLO.
JOHN RUMPAKIS, OD, MBA, PORTLAND, ORE.
JOSEPH P. SHOVLIN, OD, SCRANTON, PA.
JOSEPH W. SOWKA, OD, FORT LAUDERDALE, FLA.
MARC TAUB, OD, MEMPHIS, TENN.
MONTGOMERY VICKERS, OD, DALLAS, TEXAS
WALTER O. WHITLEY, OD, MBA, VIRGINIA BEACH, VA.

EDITORIAL ADVISORY BOARD

JEFFREY R. ANSHEL, OD, ENCINITAS, CALIF.
JILL AUTRY, OD, RPH, HOUSTON
SHERRY J. BASS, OD, NEW YORK
EDWARD S. BENNETT, OD, ST. LOUIS
MARC R. BLOOMENSTEIN, OD, SCOTTSDALE, ARIZ.
AARON BRONNER, OD, KENNEWICK, WASH.
MILE BRUJIC, OD, BOWLING GREEN, OHIO
CHRIS J. CAKANAC, OD, MURRYSVILLE, PA
JERRY CAVALLERANO, OD, PhD, BOSTON
WALTER L. CHOATE, OD, MADISON, TENN.
BRIAN CHOU, OD, SAN DIEGO
MICHAEL CHAGLASIAN, OD, CHICAGO
A. PAUL CHOUS, MA, OD, TACOMA, WASH.
GLENN S. CORBIN, OD, WYOMISSING, PA
MICHAEL DELGIODICE, OD, CLIFTON, NJ
ANTHONY S. DIECIDUE, OD, STROUDSBURG, PA
S. BARRY EIDEN, OD, DEERFIELD, ILL.
ARTHUR B. EPSTEIN, OD, PHOENIX
STEVEN FERRUCCI, OD, SEPULVEDA, CALIF.
MURRAY FINGERET, OD, HEWLETT, NY
IAN BEN GADDIE, OD, LOUISVILLE, KY
GARY S. GERBER, OD, HAWTHORNE, NJ
PAUL HARRIS, OD, MEMPHIS, TENN.
MILTON HOM, OD, AZUSA, CALIF.
DAVID KADING, OD, SEATTLE
JEROME A. LEGERTON, OD, MBA, SAN DIEGO
THOMAS L. LEWIS, OD, PhD, PHILADELPHIA

BLAIR B. LONSBERRY, MS, OD, MED, PORTLAND, ORE.
DOMINICK MAINO, OD, MED, CHICAGO
KELLY A. MALLOY, OD, PHILADELPHIA
RICHARD B. MANGAN, OD, BOULDER, COLO.
RON MELTON, OD, CHARLOTTE, NC
PAMELA J. MILLER, OD, JD, HIGHLAND, CALIF.
BRUCE MUCHNICK, OD, COATESVILLE, PA
MARC MYERS, OD, COATESVILLE, PA
CARLO J. PELINO, OD, JENKINTOWN, PA
JOSEPH PIZZIMENTI, OD, FORT LAUDERDALE, FLA.
CHRISTOPHER J. QUINN, OD, ISELIN, NJ
MICHAEL C. RADOIU, OD, STAUNTON, VA
MOHAMMAD RAFIEETARY, OD, MEMPHIS, TENN.
JOHN L. SCHACHET, OD, ENGLEWOOD, COLO.
JACK SCHAEFFER, OD, BIRMINGHAM, ALA.
LEO P. SEMES, OD, BIRMINGHAM, ALA.
DIANA L. SHECHTMAN, OD, FORT LAUDERDALE, FLA.
JEROME SHERMAN, OD, NEW YORK, NY
LEONID SKORIN, JR., OD, DO, ROCHESTER, MINN.
JOSEPH W. SOWKA, OD, FORT LAUDERDALE, FLA.
BRAD M. SUTTON, OD, INDIANAPOLIS
LORETTA B. SZCZOTKA, OD, PhD, CLEVELAND
MARC TAUB, OD, MEMPHIS, TENN.
TAMMY P. THAN, MS, OD, BIRMINGHAM, ALA.
RANDALL THOMAS, OD, CONCORD, NC
SARA WEIDMAYER, OD, ANN ARBOR, MICH.
KAREN YEUNG, OD, LOS ANGELES



Business Offices

19 Campus Boulevard, Suite 101
Newtown Square, PA 19073
Subscription inquiries (877) 529-1746 (USA only)
outside USA, call (847) 763-9630

PUBLISHER

MICHAEL HOSTER
(610) 492-1028
mhoster@jobson.com

EXECUTIVE DIRECTOR

JAMES HENNE
(610) 492-1017
jhenne@jobson.com

REGIONAL SALES MANAGER

MICHELE BARRETT
(610) 492-1014
mbarrett@jobson.com

REGIONAL SALES MANAGER

JONATHAN DARDINE
(610) 492-1030
jdardine@jobson.com

PRODUCTION MANAGER

FARRAH APONTE
212-274-7057 faponte@Jobson.com

PRODUCTION MANAGER

KAREN LALLONE
(610) 492-1010 klallone@Jobson.com

CLASSIFIED ADVERTISING

(888)-498-1460

SUBSCRIPTIONS

\$63 PER YEAR, \$99 (US) IN CANADA,
\$158 (US) IN ALL OTHER COUNTRIES
revoptometry@cambeywest.com

CIRCULATION

PO BOX 71, CONGERS, NY 10920-0071
(877) 529-1746
OUTSIDE USA: (845) 267-3065

SENIOR CIRCULATION MANAGER

HAMILTON MAHER
(212) 219-7870
hmaher@jhihealth.com

CEO, INFORMATION GROUP SERVICES

MARC FERRARA

SENIOR VICE PRESIDENT, OPERATIONS

JEFF LEVITZ

VICE PRESIDENT, HUMAN RESOURCES

TAMMY GARCIA

VICE PRESIDENT, CREATIVE SERVICES & PRODUCTION

MONICA TETTAMANZI

CORPORATE PRODUCTION DIRECTOR

JOHN ANTHONY CAGGIANO

VICE PRESIDENT, CIRCULATION

JARED SONNERS

Jobson Health Information/WebMD
395 Hudson Street, 3rd Floor, New York, NY 10014

Clinical Editors

Chief Clinical Editor • Paul M. Karpecki, OD
Associate Clinical Editors
Joseph P. Shovlin, OD, Christine W. Sindt, OD
Clinical & Education Conference Advisor
Paul M. Karpecki, OD
Case Reports Coordinator • Andrew S. Gurwood, OD
Clinical Coding Editor • John Rumpakis, OD, MBA

Columnists

Chairside – Montgomery Vickers, OD
Clinical Quandaries – Paul C. Ajamian, OD
Coding Connection – John Rumpakis, OD
Cornea and Contact Lens Q+A – Joseph P. Shovlin, OD
Diagnostic Quiz – Andrew S. Gurwood, OD
The Essentials – Bisant A. Labib, OD
Focus on Refraction – Marc Taub, OD, Paul Harris, OD
Glaucoma Grand Rounds – James L. Fanelli, OD
Ocular Surface Review – Paul M. Karpecki, OD
Retina Quiz – Mark T. Dunbar, OD
Surgical Minute – Derek Cunningham, OD, Walter Whitley, OD
Therapeutic Review – Joseph W. Sowka, OD
Through My Eyes – Paul M. Karpecki, OD
Urgent Care – Richard B. Mangan, OD



Jobson Medical Information, LLC
395 Hudson Street, 3rd Floor, New York, NY 10014

Subscription inquiries: (877) 529-1746
Continuing Education inquiries: (800) 825-4696

Printed in USA



BY JACK PERSICO
EDITOR-IN-CHIEF
OUTLOOK

Can't Get There From Here

New grads who want to practice full-scope care may find no easy path available, with patients suffering collateral damage.

Glaucoma's insidious nature—killing up to 40% of retinal ganglion cells before symptoms occur—pretty much guarantees that patients who suffer from it will be caught off guard. The same can't be said for the doctors and public health officials tasked with managing it. The severity of the problem and the Herculean effort needed to tackle it are plain as day. We have a huge base of fixed-income patients, often dispersed geographically away from care centers, experiencing inexorably progressive field loss that's held in check only by the frustratingly indirect method of IOP control, trying (and usually failing) to marshal the motivation and dexterity needed to put drops in their eyes every day.

Though glaucoma's challenges are self-evident, numbers sometimes help, even if only to give us a sobering look at the scale of the problem.

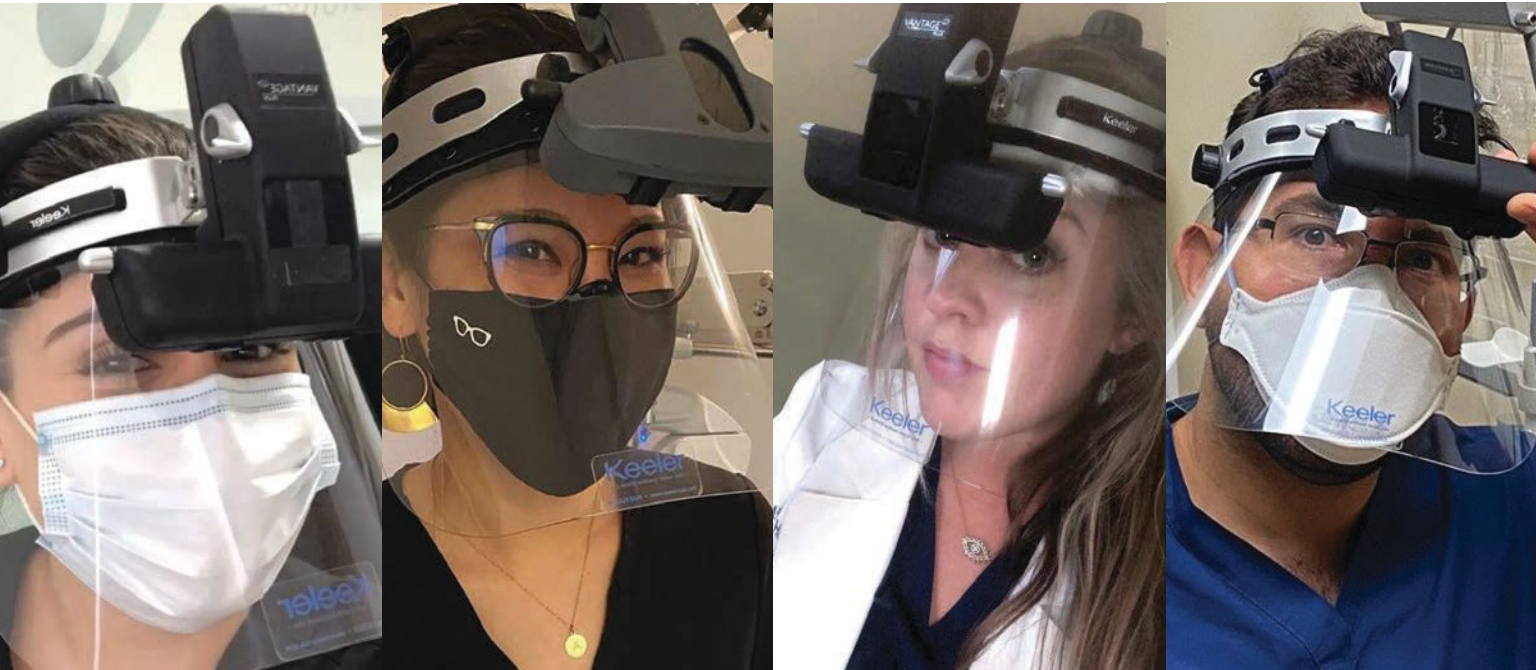We lead off our news section this month with a review of glaucoma's epidemiology, and some worrying trends therein. Glaucoma's current toll of 76 million people worldwide will rise to 112 million in the next 20 years. The disease disproportionately affects non-white ethnicities, with a prevalence of 5.7% among Black individuals vs. 2.2% in white populations, and that disparity will grow more acute. "The severity of glaucoma begins at an earlier age and at a more aggressive course in Black people than in white people and Asians," wrote the study authors, citing the perfect storm of intractable socioeconomic barriers to care and a genetic predisposition toward the disease. And the annual price tag for glaucoma care in the US alone is \$5.8 billion, a number that will double in a decade.

Phew! Ready for more? The problems are just as formidable on the provider side. With ophthalmology's capacity stagnant, it falls to optometry to pick up the slack. A survey we conducted last year found most ODs see about 10 glaucoma patients or suspects per week, far fewer than the volume needed to meet the demand. Worse, nearly 20% of the ODs who see these patients refer them out right away. The survey participants cited the high cost of equipment and inability to bill medical insurance plans as key impediments to greater attention to glaucoma. A less concrete (and hence less addressable) problem is a reluctance to take on glaucoma care that affects too many ODs.

Today's students get a great education in glaucoma, but these skills can wither on the vine if new grads move into a retail setting after college. Chain ODs often find themselves without the patient base, equipment or time to address glaucoma. In short, the incentives are all wrong in retail culture for medical optometry to thrive, and primary care-minded doctors may feel they have to "spin and grin" until they can transition to private practice. The worry is they'll bring retail culture with them and struggle to meet the needs of the more time-consuming cases that are the bread and butter of glaucoma.

Corporate optometry is often a necessary first job for newly minted ODs desperate to pay down debt. No one should be faulted for taking the best, or perhaps only, path available to them. But the mismatch of skills and culture in that setting—and the spillover consequences for patients—is just one of the tangles in the Gordian knot that is glaucoma. ■

Helping Heroes See Clear And Stay Safe



The Vantage BIO is great for ROP screening! It's lightweight, has settings for different pupil sizes, a cool, white LED light and the longest battery ever!!"

Dra. Paulina Ramirez Neria



I'm a big fan of the All Pupil BIO. I had issues with other models so when I started [my practice], I knew the All Pupil would be my go-to BIO...I greatly appreciate the new custom fit Keeler BIO shields as an added safety layer."

Dr. Annie Bacon



I chose my [Vantage Plus] for the optics and value...with other brands, I had difficulty focusing up close during my dilated fundus exams. [The oculars] made my eyes feel more relaxed, and I felt like my view was better."

Dr. Michelle Hammond



[I've] been seeing emergent and urgent cases every day during the COVID19 pandemic. I really like [the Vantage BIO] because [it's a] very good quality and provides a super clear view."

Dr. Reza Moradi

Choose one of the programs below when you purchase a BIO* between **September 1, 2020 and March 31, 2021**

*this program is valid for our wireless indirects: All Pupil II and Vantage Plus

1

RECEIVE A



\$850

credit towards any PPE

2

24-MONTH

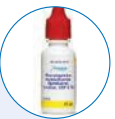0%

lease as low as \$128/month*

*All Pupil II: \$127.92/month; Vantage Plus: \$155/month (shipping and taxes not included).

3

RECEIVE



10 FREE
bottles of phenylephrine
2.5%, 15mL

***Leasing may also be combined with the PPE credit OR the phenylephrine option.**

Contact us at 800-523-5620 or customerservice@keelerusa.com to learn more or place your order. This promo cannot be combined with any other Keeler offers.

Keeler
— A world without vision loss —

www.keelerusa.com • 3222 Phoenixville Pike - Bldg. #50 • Malvern, PA 19355
Tel No: 1-610-353-4350 • Toll Free: 1-800-523-5620 • Fax: 1-610-353-7814


A Halma company



BY PAUL M. KARPECKI, OD
CHIEF CLINICAL EDITOR

THROUGH MY EYES

The Essential Eyelid Examination

In a busy practice, you can't do it all. But added emphasis on this aspect can help many patients with relative ease.

This month's theme of diagnostic skills and techniques gave me a chance to reflect on the amazing growth the profession has achieved in our clinical responsibilities. The downside is that scope expansion necessitates some picking and choosing among us all: we're approaching the point where we simply can't do it all.

With that in mind, I tasked myself with coming up with advice I believe can offer the most benefit for the most readers. If I can convey one message around the subject of diagnosis, it's to take a whole new look at the eyelids. Because of meibomian gland dysfunction, lids are responsible for about 86% of all dry eye disease.¹ And, of course, other lid-related problems abound.

Here are five tips for better lid assessment and care in your practice:

1. Examine the lash base. Research shows that long-standing blepharitis from *Staphylococcus* or *Demodex*, even at low-grade levels, can lead to significant morbidity, including loss of lashes, meibomian gland atrophy and chronic dry eye.² However, many cases of significant blepharitis go undiagnosed unless you have the patient look slightly down and run your slit beam across the base of the lashes, looking for collarettes on the lashes or biofilm escaping the follicles.

2. Express the glands. It is difficult to successfully treat dry eye without determining the type, and you can't do this well without expressing the

MGs. There are two ways to assess the health of the meibomian glands directly: meibography and MG expression. For the latter, use an expression tool such as the Mastrota Paddle (OcuSoft). At the slit lamp, place the paddle behind the lower central to nasal eyelid and your thumb on the outside of the lid. Move the paddle upwards while pressing gently.

“ I can't overstate how important the eyelids are in the diagnosis and care of so many anterior segment diseases we manage. ”

No anesthetic is necessary. Normal expression is clear and thin like olive oil. Abnormal is thickened, turbid, paste-like or non-expressible. Another effective tool is the Meibomian Gland Evaluator (Johnson & Johnson Vision).

3. Measure lid laxity. A quick and easy test to measure ectropion and lid laxity is to pull down the lower lid and observe how quickly it returns to normal position. It should happen almost instantly. Some patients with chronic ocular surface symptoms have lid laxity and, therefore, few treatments will help them. For entropion, perform the “squeeze test” by having patients squeeze their eyelids forcefully to see if this induces an entropion.

4. Observe eyelid closure. Start looking for patients with any of these three symptoms and you're likely to uncover lids that don't seal tight at night: inferior corneal staining, morning symptoms of discomfort or a positive K-B light test. The test, developed by Drs. Korb and Blackie, has become so important I find myself using it on 100% of my patients with dry eye symptoms. Have the patient close their eyes (not squeeze) as they would during sleep. In a darkened room, place a transilluminator (or penlight) above the tarsal plate of the outside closed eyelid. A beam of light that passes through the two eyelids indicates a poor lid seal.

5. Take on ptosis. Until recently, there was little we could do to improve the appearance or functioning of this condition, shy of surgical options. In congenital forms ptosis can result in amblyopia, and in acquired forms it can indicate a life-threatening condition. However, for the vast majority, ptosis is an age-associated dehiscence of the levator aponeurosis that makes patients feel and look old and affects their visual field. Upneeq (oxymetazoline 0.1%, Osmotica), recently FDA approved as a once-daily drop to treat acquired blepharoptosis, is an alpha-1 and partial alpha-2 adrenergic agonist capable of contracting Müller's muscle. In Phase III trials, treatment was well tolerated and significantly improved the superior visual field.

I can't overstate how important the eyelids are in the diagnosis and care of so many anterior segment diseases we manage. If there is just one area where it would behoove you to perfect your diagnostic skills and techniques, the eyelids are it. ■

1. Lemp MA, Crews LA, Bron AJ, et al. Distribution of aqueous-deficient and evaporative dry eye in a clinic-based patient cohort: a retrospective study. *Cornea*. 2012;31(5):472-8.

2. Rynerson JM, Perry HD. DEBS - a unification theory for dry eye and blepharitis. *Clin Ophthal-mol*. 2016;10:2455-2467.

About
Dr. Karpecki

Dr. Karpecki is medical director for Keplr Vision and the Dry Eye Institutes of Kentucky and Indiana. He is the Chief Clinical Editor for *Review of Optometry* and chair of the New Technologies & Treatments conferences. A fixture in optometric clinical education, he consults for a wide array of ophthalmic clients, including ones discussed in this article. Dr. Karpecki's full disclosure list can be found in the online version of this article at www.reviewofoptometry.com.

Adapt. Evolve. Grow.



As you **adapt** to the changes our industry is facing, you'll find there is also opportunity.

Discover how dark adaptation testing with AdaptDx Pro® guided by Theia™ can help you **evolve** your approach to AMD care. Become an AMD Center of Excellence® and unlock your potential to **grow** your practice revenue.

AdaptDx®
PRO
Guided by Theia™

Special Subscription Offer:
\$99/month for 1st six months
Learn more at maculogix.com/6months



Shout-out to the Staffers

Don't forget these key things in the struggle to help us doctors appear more competent than we are.

Doctors, this column is not for you. It is written entirely for your staff, your team, your posse...whatever you call them. You know, the ones who work relentlessly and against all odds to make you seem intelligent.

Now that I have your attention, miracle workers, let's get to it. You never fail to make us doctors look good, so I'd like to return the favor with some advice:

1. Never use any form of the word, "cancel." "Your four o'clock cancelled," immediately causes acute anxiety and depression in all doctors, and this black hole is not one that a little CBD can fix. From now on, the word is, "postpone." "Your four o'clock postponed," offers hope, and that is affirming.

2. Never say to a doctor, "Your last patient is ready." This insinuates that the doctor has a life-threatening illness or, even worse, the feds are at the door, ready to lock them up forever. Instead, clarify that the doctor's last patient *of the day* is ready. The worst-case scenario is that Happy Hour is pushed back 30 minutes. Death and jail time are no longer part of the conversation.

3. Always tell a doctor if his fly is unzipped, he has crumbs in his mustache, etc. He needs to look doctor-ish, and it's your job to be his mom.

4. Avoid the impulse to tell a doctor that their upcoming patient is grumpy, rude or otherwise annoying. You know how it goes. These patients treat the staff like frog muck, but as soon as the doctor walks in, they are all rose petals and giggles. The doctor would look at you like you are an idiot if you were to describe this lovely patient as a grouch.

5. Please wear your mask properly. If it's too big and saggy, get one that fits. Patients don't usually care if you correct their vision, but they will definitely leave a bad review if your nose is hanging out of your mask.

6. If one of your tools doesn't work for some reason, do not tell the patient that one of your tools doesn't work for some reason. Just smile and act like it is perfectly normal that you made them sit for 10 minutes watching you crawl around on the floor trying to plug the damn thing in.

7. No matter what the patient asks, do not respond. Just tell them the doctor will answer all of their questions. The only exception is when the patient asks if the doctor is a good one. The appropriate response is, "Of course. Our doctor is wonderful!"

8. Please make sure all of the equipment in the exam room is ready for use. Remember, the doctor has no clue how to turn it on. If you think a neurosurgeon knows how to turn on the MRI machine, guess again.

9. Leave your crazy life at home. Everyone is stressed. Everyone had a fight with their significant other. Everyone else wishes they actually had a significant other. Don't bring that stuff into the office. When you walk through the door, be present so that (a) your day is better, (b) everyone you

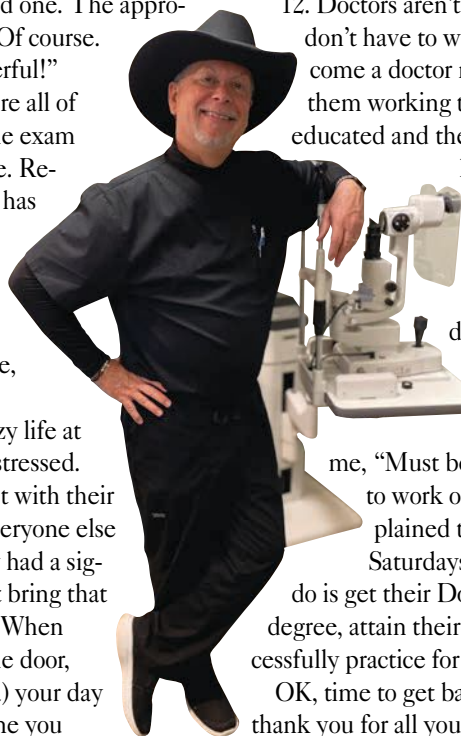
meet has a better day and (c) you are employed longer.

10. If a patient comes in with a caregiver, ask the name of the person in charge and make sure you know how they are related to the patient. The mom? The son? The nurse? The bookie? At times, they will turn out to be someone the doctor saw last week for their own eye exam, and you may feel embarrassed you asked, but better you than the doctor! Trust me on this, and you will become way more valuable to the doctor and the practice. Also, bringing donuts doesn't hurt either.

11. Don't ever, ever expect a bonus. Live like you will never get one. That way, it's not budgeted as part of your car payment. You know, the car that will be repossessed unless you get a bonus? Bonuses are not guaranteed. Don't rely on them to make ends meet, but appreciate them if they do come your way. Say something like, "Thank you!" rather than, "I thought it would be more."

12. Doctors aren't rich. Rich people don't have to work. Whatever income a doctor makes is a result of them working their rear off to get educated and then spending sleepless nights building their business with their own sweat and equity. If you're jealous of what a doctor makes, go become one yourself. One of my staffers recently said to me, "Must be nice not to have to work on Saturdays!" I explained they too could have Saturdays off. All they had to do is get their Doctor of Optometry degree, attain their license and successfully practice for 41 years. Simple!

OK, time to get back to work. And thank you for all you do! ■



About Dr. Vickers

Dr. Vickers received his optometry degree from the Pennsylvania College of Optometry in 1979 and was clinical director at Vision Associates in St. Albans, WV, for 36 years. He is now in private practice in Dallas, where he continues to practice full-scope optometry. He has no financial interests to disclose.

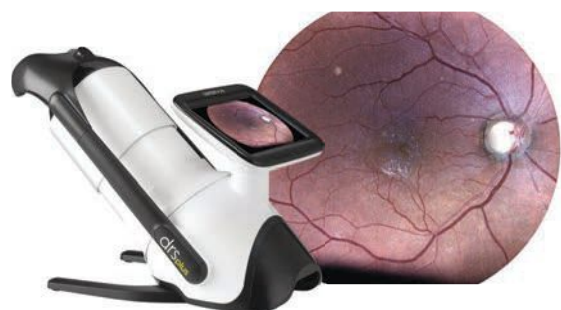
Keeping the world visible for all. Together.



iCare DRSplus

Automated TrueColor
retinal imaging

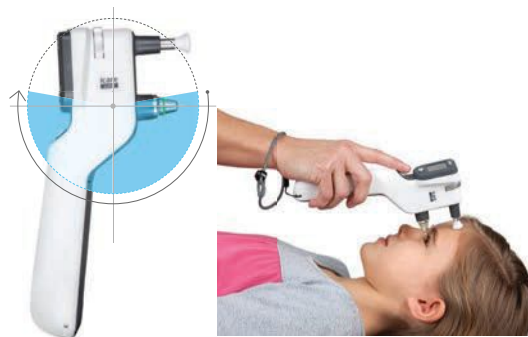
- + TrueColor confocal imaging
- + Ultra-high resolution
- + Fast image acquisition
- + No dilation (2.5 mm pupil size)
- + Space saving



iCare IC200

200 degrees of
tonometry

- + Supine, elevated & seated operation
- + No corneal disruptions
- + Suitable for every patient
- + Single use probes to exceed infection control guidelines



For more information, scan,
call 888.422.7313, or email
infousa@icare-world.com
www.icare-world.com/us

For better perception **icare**



EDITED BY PAUL C. AJAMAN, OD

CLINICAL QUANDARIES

Blowing in the Wind

The case of a mysterious irritated eye can be solved with some targeted questions.

Q I have a 66-year-old patient who has symptomatic dry eyes that have not responded to cyclosporine, lid scrubs or other measures. What should I do?

A When patients experience chronically dry and irritated eyes that don't improve with conventional therapy, there is often more going on than meets the eye. "Some of the most common etiologies for chronic ocular dryness, redness and irritation are complications derived from obstructive sleep apnea," says Brad Sutton, OD, professor at Indiana University's School of Optometry.

Sleeping Troubles

Sleep apnea is a major public health issue highly associated with an increased risk of cardiovascular diseases such as hypertension, stroke and myocardial infarction. It's also linked to many ocular conditions. Non-arteritic ischemic optic neuropathy (NAION), glaucoma, central serous chorioretinopathy and retinal vein occlusions occur more frequently in these patients.

"NAION is so common in sleep apnea sufferers that sleep apnea should be ruled out in any patient diagnosed with NAION," Dr. Sutton says.

There are two main factors to consider when sleep apnea patients complain of chronic dryness and irritation. They can experience ocular surface complications either related to the use of continuous positive airway pressure (CPAP) devices or to floppy eyelid syndrome, or both.

If the CPAP mask does not form a

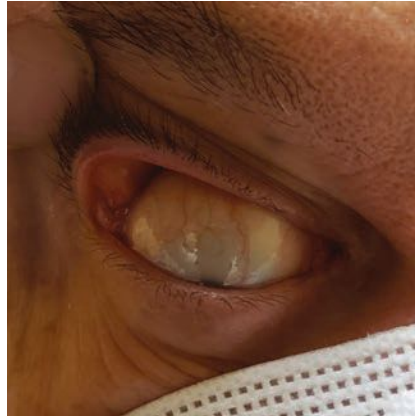

Fig. 1. Floppy eyelids should trigger questions about sleep apnea.

tight seal, the forced air can leak out and flow toward or directly into the eyes. If lagophthalmos is present, the situation is exacerbated by more exposure and punctate keratitis, dryness and conjunctivitis.

Patients with floppy eyelid syndrome often experience the same ocular surface issues but for a different reason—their eyelids become loose and rubbery. These eyelids evert easily with minimal contact on the pillow while sleeping, leading to both exposure concerns and issues with direct mechanical abrasion. If a patient always sleeps on one side, only that eye is affected. Only 5% of patients with sleep apnea develop floppy eyelid syndrome, but nearly all patients with floppy eyelid syndrome have sleep apnea. The lids of our patient led to more questioning, and he admitted to using CPAP therapy (*Figure 1*).

To help these patients who have tried many treatments without relief,

Dr. Sutton recommends detecting the underlying issue. Many patients do not list sleep apnea on their medical intake form unless prompted by a specific question. Relying on patients to include it on a review of systems is often ineffective. "It is far better for the doctor to outright ask if a patient has sleep apnea and if they use a CPAP device," Dr. Sutton notes.

In CPAP-induced ocular irritation and floppy eyelid syndrome, patients experience irritation, dryness and redness upon awakening. As the day goes on, the symptoms usually improve.

Treatment

In the case of CPAP-induced ocular surface exposure, ensure that the patient's sleep specialist maximizes the proper mask fit. Have the patient instill tear ointments, such as Refresh PM (Allergan), or gel-based artificial tears before bed to protect the ocular surface. Use gel-forming artificial tears upon awakening, and then use artificial tears throughout the day as needed. In severe cases, taping the eyelids closed at night can help. "Patients may not comply with surgical tape, so suggest placing nasal strips vertically from the upper lid to the cheek," Dr. Sutton recommends.

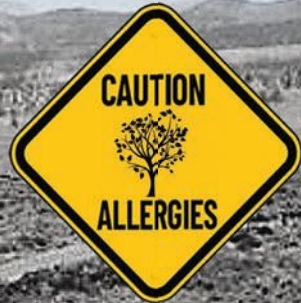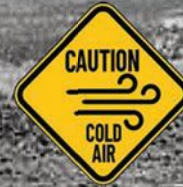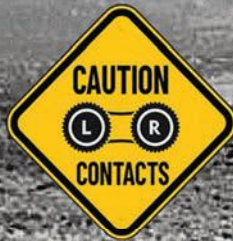Similar measures can help those with floppy eyelid syndrome. Dr. Sutton believes that switching the patient to a cylindrical pillow can be effective. This allows the patient's cheek, not the eyelids, to rest on the pillow and reduces mechanical eversion. Having the patient sleep on their back can help, but many people might not be able to do this.

"In some instances, wearing a firm sleep mask can also help prevent lid eversion," Dr. Sutton says. "In very severe cases, surgery can be considered to tighten the eyelids." ■

About
Dr. Ajaman

Dr. Ajaman is the center director of Omni Eye Services of Atlanta. He currently serves as general chairman of the education committee for SECO International. He has no financial interests to disclose.

FOR MOST PATIENTS, DRY EYE SYMPTOMS HAVE AN EPISODIC IMPACT



FLARES: THE SPEED BUMPS OF DRY EYE

Most patients with Dry Eye suffer from short-term, episodic exacerbations—*Dry Eye Flares*.¹⁻³

Many patients don't suffer from continuous symptoms.³

REENVISION
DRY EYE

kala
PHARMACEUTICALS

References: 1. Brazzell RK, Zickl L, Farrelly J, et al. Prevalence and characteristics of dry eye flares: a patient questionnaire survey. Presented at: AAO 2019: October 12-15, 2019; San Francisco, CA. 2. Brazzell RK, Zickl L, Farrelly J, et al. Prevalence and characteristics of symptomatic dry eye flares: results from patient questionnaire surveys. Poster presented at: AAOPT 2019: October 23-27, 2019; Orlando, FL. 3. 2020 Study of Dry Eye Sufferers. Conducted by Multi-sponsor Surveys, Inc.





BY JOHN RUMPAKIS, OD, MBA
CLINICAL CODING EDITOR

CODING CONNECTION

Specificity is the Spice of Life

Not only does each CPT code have a distinct definition—it also reflects the characteristics for a specific procedure.

It is easy to get excited about buying a new piece of diagnostic equipment, developing new diagnostic skills or simply refining the skill sets you already have. For the most part, every diagnostic procedure you do either with or without a piece of equipment has a very specific and appropriate CPT code to use. Each CPT code has a specific definition; beyond that, it also possesses a number of characteristics that are part of the CPT language for a specific procedure. The AMA system provides a standard language that accurately communicates exactly what took place in a patient-physician encounter.

The only way that you can describe to the world outside your practice what you did during a patient encounter is with a simple five-character code. CPT codes, by definition, are all five digits, unlike HCPCS Level II or Category III codes. You can alter the definition and characteristics of a CPT code to better fit the circumstances that occurred during the patient encounter by using a modifier to describe anything outside of the normal performance of that procedure. Use the CPT code that is highly specific to the procedure you are performing to keep an accurate medical record and avoid problems.

Adequate Answers

About 10 to 15 times per month a doctor or their staff will ask me what CPT code they should use for a specific diagnostic procedure or office visit. For example, a physician bills for an eye exam. What kind of eye exam was it?

There are currently 15 different codes that could describe an eye exam—each with a specific definition.

“**Match what was done with the patient to the most specific CPT code/definition that you can find.**”

In order to code your eye exam, you need to look at what was done with the patient and then match that to the most specific CPT code/definition that you can find. It troubles me that most ODs always default to a 920X4 level of service, even if the medical record demonstrates that the definition of the service was never met. The excuse I get from those doctors is that it's the only code they know and they always use and get paid for it, neither of which are adequate answers in a malpractice case or insurance audit.

Another timely example is the codes for extended ophthalmoscopy introduced in January 2020. Note the difference in the procedures' descriptions:

Prior to January 2020

- 92225: Ophthalmoscopy, extended, with retinal drawing (*e.g.*, for retinal detachment, melanoma), with interpretation and report; initial.
- 92226: Ophthalmoscopy, extended, with retinal drawing (*e.g.*, for retinal detachment, melanoma), with interpretation and report; subsequent.

Both codes have been unilateral in nature, and medical necessity for each

eye had to be clearly established in the medical record. The codes also required a drawing of specific size, traditionally with colored pencils, to denote various anatomical structures and markers as well as include an interpretation and report.

January 2020–Current

- 92201: Ophthalmoscopy, extended, with retinal drawing and scleral depression of peripheral retinal disease (*e.g.*, for retinal tear, retinal detachment, retinal tumor) with interpretation and report, unilateral or bilateral.
- 92202: Ophthalmoscopy, extended, with drawing of optic nerve or macula (*e.g.*, for glaucoma, macular pathology, tumor) with interpretation and report, unilateral or bilateral.

Consider the change due to region of retina examined and the change to a unilateral/bilateral status. Note that 92201 requires the use of scleral depression, whereas the older codes did not specify examination techniques, and, consistent with previous requirements, both tests must have detailed drawings of the respective areas of examination and concern. Additionally, a CCI edit precluding the use of 92201 and 92202 with fundus photography (92250) on the same date of service is anticipated.

Enhancing your diagnostic skill set or purchasing new diagnostic equipment requires that you use the CPT code that most accurately reflects the service performed during the patient encounter. Not only does the code govern your reimbursement based upon the collective relative value units associated with the procedure, but the other stakeholders in the patient care chain also rely on your accuracy and trustworthiness in following the CPT guidelines. ■

Send your coding questions to rocodingconnection@gmail.com.

About
Dr. Rumpakis

Dr. Rumpakis is president and CEO of Practice Resource Management, Inc., a firm that provides consulting, appraisal and management services for health care professionals and industry partners. As a full-time consultant, he provides services to a wide array of ophthalmic clients. Dr. Rumpakis's full disclosure list can be found in the online version of this article at www.reviewofoptometry.com.

A VISION THAT INSPIRES YOU



The New & Easy to Use
EFC-2600
FUNDUS CAMERA

Fully Automatic
Mosaic Visualization
Anterior & Posterior Segment
45°-100° Degree Angle Visual Field

12 MEGA
PIXELS

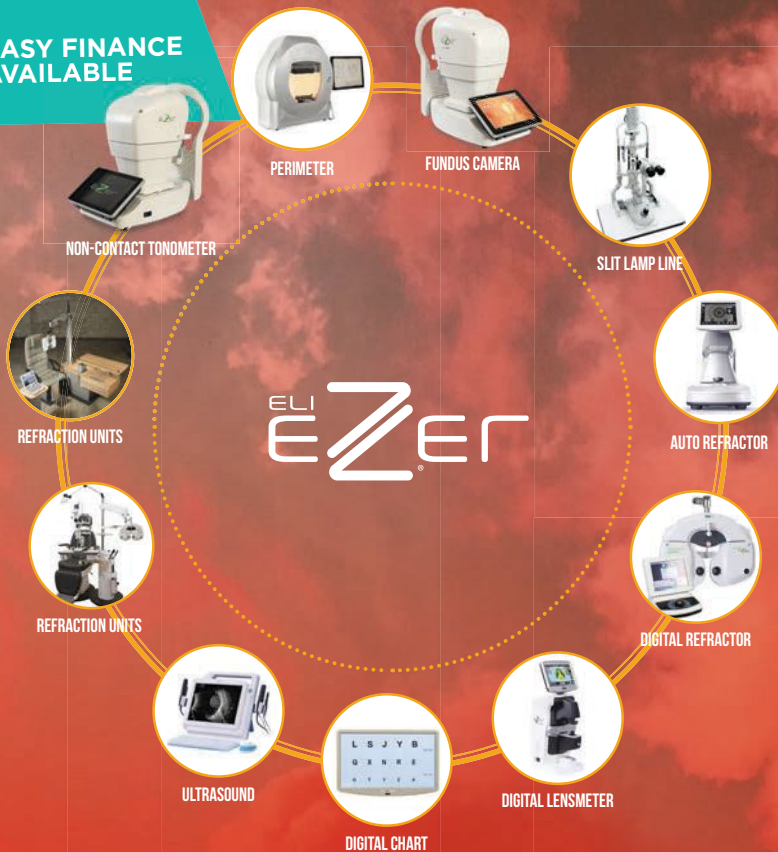
A TEAM BY YOUR SIDE

SATISFACTION GUARANTEED >>>>>>>>

FROM ONE INDEPENDENT OWNER TO ANOTHER

WE CARE FOR OUR COMMUNITY

\$ EASY FINANCE
AVAILABLE



EZER OPHTHALMIC LINE

The Ezer Way of Life

CONTACT US FOR INFORMATION

WWW.USOPHTHALMIC.COM | PH: 1.888.881.1122
INFO@USOPHTHALMIC.COM

Follow Our Social Media Channels @USOPHTHALMIC



9990 NW 14th Street, Unit #105, Doral, FL 33172 | USA



SCAN TO SEE MORE!

Read all the features and benefits
this item has to offer by connecting to
our page.

While you're there, don't forget to
Request A Virtual Demo Online!



A Twofold Effect

A small amount of prism was enough to give this patient visual relief—and even reduce his Parkinson’s medication burden.

Nearly 30 years ago, a staff member knocked on my exam door and said I had a call from a referring physician. I normally don’t let anything interrupt my appointments, but my coworker was very insistent. I relented and excused myself to take the call in my office. I picked up the phone and said my usual, “Dr. Harris speaking, what can I do for you?” And the voice on the other end hit me with, “Doctor, what did you do to my patient?”

I was too caught off guard to know how to respond, and the silence that followed was deafening. Thankfully, the referring physician saved me from that awful moment and followed up with, “I think I might be able to reduce my patient’s medication for his Parkinson’s, and I need to understand what you did to him.” I took a deep breath and, knowing exactly what she was talking about now, knew things were going to be just fine. So, what did I do for this patient? Let me tell you the story about how prism caused a domino effect in his life.

The Case

A previous vision therapy patient of mine had come in for her yearly exam and questioned me about her father. She explained that he was

experiencing some odd symptoms that she didn’t understand and that he was being treated for Parkinson’s disease. She asked if I would examine him, and I immediately agreed.

The exam proceeded naturally through the history and data collection, with no glaringly abnormal findings. I noticed on the cover test that there appeared to be a slight vertical deviation along with an exophoria. The exophoria was larger at near, and the vertical deviation seemed to occur at both distance and near.

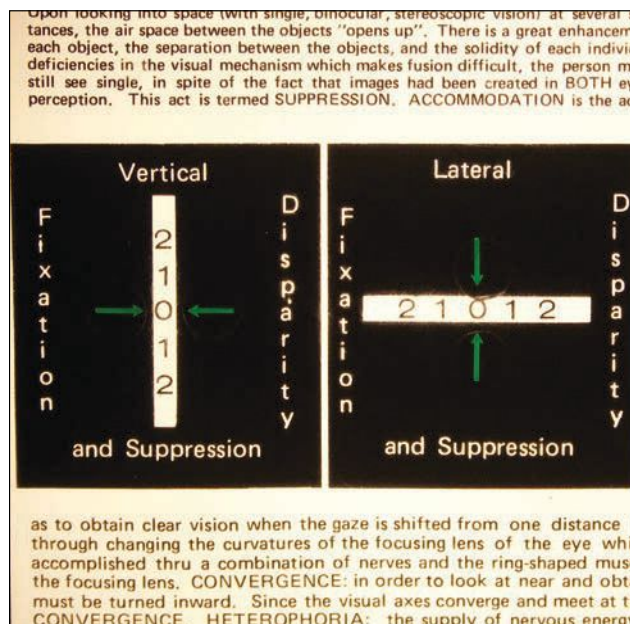
As part of the analytical exam, I usually perform phorias at distance and near and horizontal base-in and base-out at distance and near. The phorias matched the cover test with 5Δ of exo at distance and 14Δ of exo at near. The base-in and base-out ranges had strayed from normal, showing very reduced break points. The base-out break at distance was 5Δ instead of 19Δ, and the base-in break at distance was 3Δ instead of 9Δ. At near, with the fused cross-cylinder of +2.50 add in place, the reductions were similar.

I conducted vertical phoria testing and found 4Δ of left hyper at both distance and near. I redid the horizontal prism testing with the vertical compensating prism in place. I put 4Δ in front of the left eye and used the

Risley prism on the right eye to find the ranges. I knew that the patient might perceive the target moving right and left as I put in asymmetric lateral prism, and that’s exactly what happened. However, his break points nearly tripled in both directions. These improvements confirmed I should indeed prescribe the prism.

Perks of Prism

Even though I had determined the amount of prism based on von Graefe testing, I usually try to find a way to prescribe less if possible. I plotted the patient’s fixation disparity curve for the vertical misalignment and found that with the 4Δ of vertical in place, there was no residual fixation disparity. Though the arrows were not perfectly



This is the central part of a Mallett card. Each of the green arrows has a circular-shaped Polaroid material over it. When viewed with Polaroid glasses, the arrow to the right on the vertical test and the upper arrow on the lateral test can be seen with the right eye, and the other two can be seen with the left. Everything else is seen with both eyes and acts as fusion locks.

About Drs. Taub and Harris

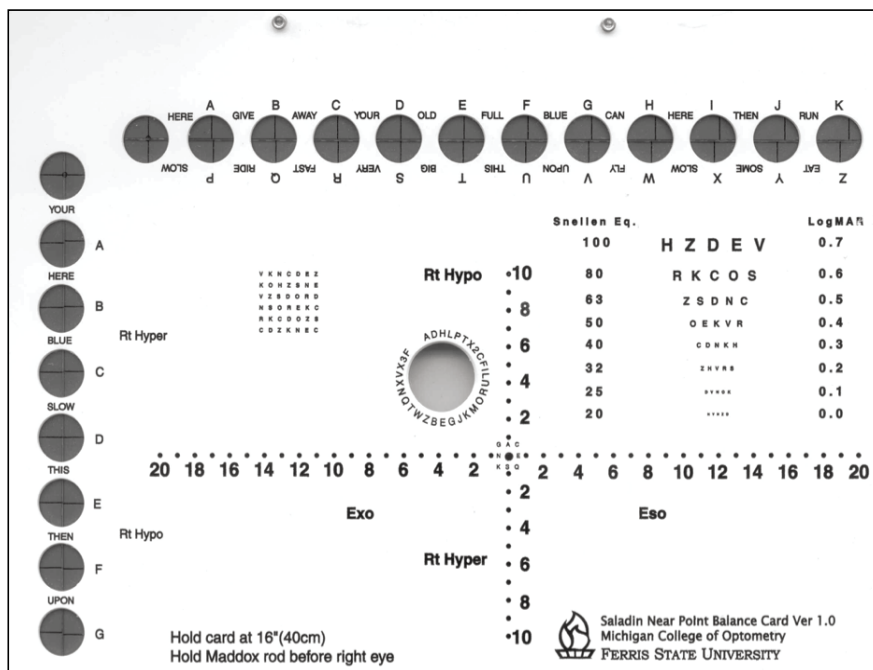
Dr. Taub is a professor, chief of the Vision Therapy and Rehabilitation service and co-supervisor of the Vision Therapy and Pediatrics residency at Southern College of Optometry (SCO) in Memphis. He specializes in vision therapy, pediatrics and brain injury. **Dr. Harris** is also a professor at SCO. Previously, he was in private practice in Baltimore for 30 years. His interests are in behavioral vision care, vision therapy, pediatrics, brain injury and electrodiagnostics. They have no financial interests to disclose.

aligned on the Mallett card with 3Δ, the misalignment was minimal. With 2Δ, the slippage was too much.¹

I trial-framed the 3Δ of vertical while the patient was in the chair. He reported less trouble with his vision and felt more relaxed. He did not complain of double vision. However, I found a small vertical misalignment. I decided to try some vertical prism. With it, the patient felt even more relaxed. It also greatly increased his range of clear binocular vision.

When the patient received his new pair of glasses, he again expressed how much better they made him feel. A couple of days later, he had the appointment with his primary care physician that prompted the call to my office. His doctor found that he was far more stable with Romberg testing than he had been in years. According to her assessment, his tremors had subsided as well. She felt that if his improvement persisted or improved further through his next follow-up visit, she might be able to reduce his Parkinson's medication.

Over time, the patient did remain stable, and his medication was reduced accordingly. He was my patient for over 15 years and continued to love his glasses with the small amount of prism.



The Saladin card has targets for measuring fixation disparities in both the horizontal and vertical directions.

Discussion

Small vertical misalignments may be present more often than we know. Generally, it is hard to detect misalignments of 4Δ or less on a cover test, even for most well-trained optometrists.

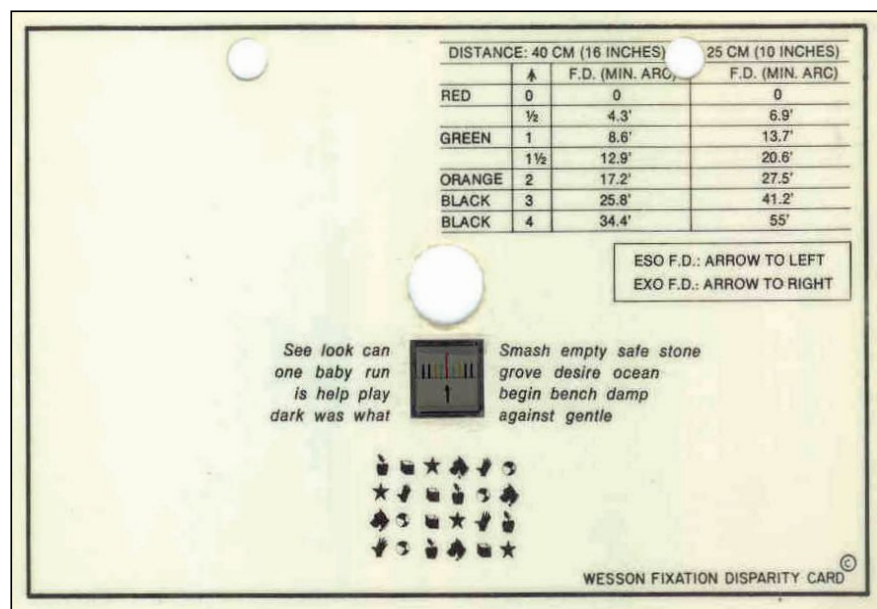
My gut feeling that there was something off about this patient's cover test results—a slight head tilt

if nothing else—along with his very small base-in and base-out ranges, prompted me to perform vertical phoria testing, vertical ranges and vertical fixation disparity testing.

The patient's daughter, my original patient, thought I might recommend vision therapy for her father, but the lenses took care of his symptoms all on their own, even though they didn't actually treat his underlying condition. The prism helped meet my patient's needs more than I could have ever imagined, and his primary care physician made sure I knew it.

This case brought home a theme that is often quite easy to lose sight of: everything is connected. We saw how correcting a small vertical misalignment profoundly changed the life of a patient, so much so that his physician felt she could reduce his medication for his Parkinson's' disease.

We truly practice a wonderful profession and have the power to change people's lives in more ways than one with our simple tools. ■



At near, fixation disparity and the associated phoria can be found with a Wesson card.

1. Suter PS, Harvey LH. Vision Rehabilitation: Multidisciplinary Care of the Patient Following Brain Injury. Routledge; 2011.



BY JOSEPH W. SOWKA, OD

THERAPEUTIC REVIEW

The Unexpected Visitor

An extremely late surgical complication led to this patient's symptoms.

A 68-year-old man presented urgently complaining of vision loss in his right eye that he described as a film or veiling of several days' duration. He reported an obstruction in his superior right visual field that he felt happened abruptly, though he acknowledged that he may not have fully noticed it for about one day. He couldn't remember any precipitating incidents.

He didn't report flashes or cobwebs in his vision, but his retinal history included a retinal break in his right eye that had been lasered several years earlier, and he was alert to any possible symptoms of retinal detachment. The retinal tear occurred shortly after YAG capsulotomy and was promptly treated without subsequent retinal detachment.

The patient also had a history of ocular hypertension, for which he was using timolol 0.5% BID OU, and he reported that his intraocular pressure (IOP) was slightly elevated at his last visit with his previous doctor.

Best-corrected visual acuity was 20/40 OD and 20/20 OS. His eyes were white and quiet. His pupils were reactive without afferent defect. Biomicroscopic evaluation showed a well-centered intraocular lens (IOL) OD with posterior opacification. This, however, was confounding, as he had a solid history of bilateral posterior capsulotomy. There was also a grade 2 anterior chamber cell reaction without flare. IOP was 31mm Hg OD and 21mm Hg OS. His left eye had a well-

centered IOL and an open posterior capsule.

Dilated examination revealed that he did indeed have an open capsule in his right eye from the previous capsulotomy. But the opacification seen through his undilated pupil was not the posterior capsule but a large superiorly located piece of retained lens fragment between the IOL and remaining posterior capsule. What was remarkable about this postoperative complication was that his cataract surgery occurred 13 years earlier.

“ Virtually all cases involving retained nuclear fragments will fail on topical therapy alone and require surgical removal. ”

Clearly, his visual obscuration, inflammation and elevated IOP came from the subsequent antigenic response induced by the retained lens, which had now dislodged from a protected space between the IOL and posterior capsule. Hence, his diagnosis was retained lens fragment with late-onset inflammation, often referred to as phacoanaphylaxis, or phacolytic glaucoma.

Dangerous Fragments

Phacoanaphylaxis describes inflammation caused by the crystalline lens and has been referred to as phacoanaphylactic uveitis,

phacoanaphylactic endophthalmitis, phacoanaphylactic glaucoma, phacolytic glaucoma, retained lens fragment and lens particle glaucoma.¹⁻⁶

In nearly all cases, patients are elderly with cataracts, though younger patients experiencing penetrating lens trauma or ocular surgery can also undergo phacoanaphylaxis. Typically, the patient has undergone cataract extraction, often seemingly without complications. In the immediate (and sometimes late) postoperative period, the eye will demonstrate persistent inflammation in the anterior chamber or the vitreous unresponsive to topical steroid treatment. IOP may be elevated, and, when this occurs, the condition is called phacoanaphylactic or phacolytic glaucoma.¹⁻⁶

Post-surgically, there may be either lens cortex or nucleus material that was inadvertently not completely removed during surgery. Retained lens fragments may be biomicroscopically visible in either the anterior or posterior chamber, though they may be elusive and visible only gonioscopically.⁷

Phacoanaphylaxis is an inflammatory response to release of sequestered lens proteins, which are recognized as foreign and antigenic even though they are the body's own tissue. Cortical and nuclear material are enveloped by the lens capsule and thus protected from the body's immune system. Once released into the anterior or posterior chamber, cortical and nuclear materials induce an antigen-antibody response. Exposed nuclear fragments are more likely to induce phacoanaphylaxis than cortical remnants.

Retained lens fragments are extensively infiltrated by polymorphonuclear leukocytes, histiocytes, eosinophils

About
Dr. Sowka

Dr. Sowka is an attending optometric physician at Center for Sight in Sarasota, FL, where he focuses on glaucoma management and neuro-ophthalmic disease. He is a consultant and advisory board member for Carl Zeiss Meditec and Bausch Health.

MASK-ASSOCIATED DRY EYE



By Paul M. Karpecki, OD, FAAO

Recently published articles have noted a marked increase in dry eye symptoms associated with regular use of face masks. Dr. Darrell White, MD, a Cleveland ophthalmologist, observed during the pandemic, “Even for a high-volume dry eye center, there sure were a ton of new cases coming in.” He found the likely culprit hanging from the ears of his patients, and termed the condition Mask-Associated Dry Eye (MADE). Some clinics have reported an increase in prevalence of dry eye associated symptoms among individuals who had never previously suffered from dry eyes.¹ Individuals using face masks regularly for extended periods of time appear more likely to report symptoms.

Being aware of potential issues caused by wearing a face mask, what should ECPs consider as appropriate remedies for their patients? As clinicians, we have experienced a large percentage of patients with dry eye symptoms and contact lens intolerance and have managed these dry eye patients appropriately. Is MADE any different?

According to Dr. Lyndon Jones, director of the Centre for Ocular Research & Education, “Face masks are crucial in the fight against COVID-19, and ECPs are well-positioned to provide patients with advice on appropriate wear in order to maximize eye comfort. Asking patients about their mask-wearing experiences and providing a few helpful tips takes little time and can make a substantial difference.”²

1. For starters, properly selecting and wearing a face mask is the first step. Masks should have a pliable nose-wire feature and must be fitted securely around the nose and mouth to prevent air from being directed upwards toward the eyes. Using a face mask to force your breath down or

to the side and not upward is the key.

2. Reduce the amount of time using digital handheld devices, computers, and avoid direct air from HVAC systems and fans.
3. Practice good hygiene: don't rub your eyes, especially with unwashed hands.
4. Take breaks every hour or so to remove the mask, when safe to do so, to allow the eyes to recover, blink frequently and apply lubricant eyedrops.

No single artificial tear solution will work for all dry eye patients. Each patient's symptoms, complaints, and diagnosis will play a role in your selection of the best dry eyedrop for his or her needs. However, for MADE, proper education of mask wearing as well as proper selection of artificial tears will provide your patients the relief and support they are seeking.

Which treatment option is best for your patients? One unique artificial tear is FreshKote Preservative Free (FKPF) from Eyevance Pharmaceuticals. The active ingredients in FKPF are a patented polymer blend of 2.7% polyvinyl alcohol (PVA) as well as 2.0% polyvinyl pyrrolidone (PVP or Povidone for short). This unique blend mimics the mucin layer of the tear film, enhances wettability, and integrates with the lipid layer to supplement and stabilize the tear film, reducing evaporation while lubricating and soothing the ocular surface. FKPF also introduces a high oncotic pressure gradient, which can help increase ocular surface integrity. Although the recommended dosing schedule is one drop BID, for best symptom relief during an acute dry eye episode, one drop QID is an option.

1. Moshirfar, M., West, W.B. & Marx, D.P. Face Mask-Associated Ocular Irritation and Dryness. *Ophthalmol Ther* 9, 397–400 (2020). <https://doi.org/10.1007/s40123-020-00282-6>
2. Jones, L. Practitioners Should Be Aware of Mask-Associated Dry Eye (MADE). *Eyewire News*, 08312020

Maria Pribis, OD, FAAO, who is in private practice in Stamford, Ct., contributed to this piece.

SPONSORED BY  eyevance
pharmaceuticals

FRESHKOTE®

Preservative Free
LUBRICANT EYE DROPS



MASK-ASSOCIATED DRY EYE (MADE)¹

Wearing a facial covering can lead to evaporative dry eye due to exposure from exhaled air in an upward flow.

SYMPTOMS

- Eyes feel dry
- Eyes feel gritty
- Vision is blurry

SIGNS

- Red eyes
- Irritated eyes
- Watery eyes

SOLUTIONS

- Reduce time on computers and digital devices
- Avoid direct air from fans and HVAC systems
- Don't rub your eyes
- Wash hands frequently
- When safe to do so, occasionally lower facial covering to avoid evaporation of tears
- Use preservative-free artificial tears



Offer FRESHKOTE PF directly to your patients for soothing relief and to prevent further irritation.^{1,2,3}

Order FRESHKOTE® PF (Preservative Free) for your practice and offer it to your patients for purchase at [FRESHKOTE PF.com](https://www.freshkotePF.com) or by calling 877-251-2194.

FRESHKOTE®
Preservative Free
LUBRICANT EYE DROPS

and giant cells. The iris and ciliary body are also inflamed and infiltrated by lymphocytes and plasma cells.^{2,8} Concurrent inflammation of the trabecular meshwork, as well as blockage by inflammatory cells and a poorly flowing proteinaceous aqueous, contribute to IOP rise and glaucoma development.

The timing of onset of phacoanaphylaxis can be perplexing. Most cases of phacoanaphylaxis occur and are discovered soon after surgery. However, there are numerous reports of phacoanaphylaxis from retained lens fragments occurring years after surgery.⁹⁻¹¹

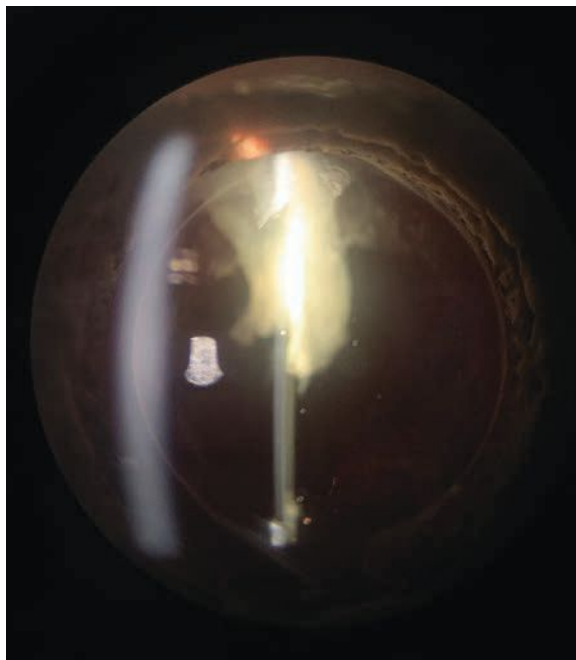
The general consensus held that in late-onset cases, the retained lens material gets stuck in a pocket between the peripheral IOL and posterior capsule, essentially existing in a compartment that retains residual protection from the immune system. However, this does not explain every case of delayed-onset phacoanaphylaxis.

Inflammation Control

Initial inclination in managing persistent postoperative inflammation is to continue or increase steroid use. This may be done initially to temporarily ameliorate the condition, but it is rarely curative. While phacoanaphylaxis from retained cortical fragments may have success with conservative therapy with topical steroids, virtually all cases involving retained nuclear fragments will fail on topical therapy alone, requiring surgical removal.¹²

As it is difficult to clinically differentiate cortical from nuclear fragments, if the complication of phacoanaphylaxis or phacoanaphylactic glaucoma arises, it is advocated to remove all retained lens fragments as soon as possible.

Topical steroids and cycloplegics can be used temporarily to ameliorate inflammation prior to surgery. Topical aqueous suppressants can be used



This large retained lens fragment protruding into this patient's visual axis caused phacoanaphylaxis.

to manage any significant IOP rises. Therapy is dictated by the severity of the inflammation and IOP rise.

However, if fragments are seen and the eye is quiet, there is no emergent need for extraction; many cases never convert to the inflammatory disease, while others do years later.

Vitrectomy is successful in removing retained lens fragments within the vitreous.¹³ Surgical irrigation and aspiration with phacoemulsification if necessary is the best approach for lens material in the anterior chamber.¹⁴

Prolonged duration of lens fragments in the setting of an inflammatory response increases the risk of corneal decompensation, so prompt intervention is necessary. Unfortunately, some eyes will continue to decompensate even after surgical removal, necessitating keratoplasty.

To Sum Up

The patient presented here was educated on his condition and the nature of his visual disturbance. Upon questioning, we determined that running while playing tennis may have precipitated the dislodgement of his IOL.

He was prescribed prednisolone acetate 1% QID OD and an additional ocular hypotensive fixed combination of brinzolamide 1%/brimonidine 0.2% and referred for removal of the residual lens material. Topical therapy in the four days prior to surgical consultation greatly reduced the patient's inflammation and IOP. He underwent successful removal of the retained lens fragments with a resultant visual acuity of 20/20. ■

- Mardelli PG, Mehanna CJ. Phacoanaphylactic endophthalmitis secondary to capsular block syndrome. *J Cataract Refract Surg.* 2007;33(5):921-2.
- McMahon MS, Weiss JS, Riedel KG, Albert DM. Clinically unsuspected phacoanaphylaxis after extracapsular cataract extraction with intraocular lens implantation. *Br J Ophthalmol.* 1985;69(11):836-40.
- Marak GE Jr. Phacoanaphylactic endophthalmitis. *Surv Ophthalmol.* 1992;36(5):325-39.
- Oprescu M. The etiopathology of phacoantigenic uveitis and phacolytic glaucoma. *Oftalmologia.* 1992;36(3):207-13.
- Moisseiev E, Kinori M, Glovinsky Y, et al. Retained lens fragments: nucleus fragments are associated with worse prognosis than cortex or epinucleus fragments. *Eur J Ophthalmol.* 2011;21(6):741-7.
- Teo L, Chee SP. Retained lens fragment in the anterior segment as a cause of recurrent anterior uveitis. *Int Ophthalmol.* 2010;30(1):89-91.
- Mokhtarzadeh A, Kaufman SC, Koozekanani DD, Meduri A. Delayed presentation of retained nuclear fragment following phacoemulsification cataract extraction. *J Cataract Refract Surg.* 2014;40(4):671-4.
- Hochman M, Sugino IK, Lesko C, et al. Diagnosis of phacoanaphylactic endophthalmitis by fine needle aspiration biopsy. *Ophthalmic Surg Lasers.* 1999;30(2):152-4.
- Mokhtarzadeh A, Kaufman SC, Koozekanani DD, Meduri A. Delayed presentation of retained nuclear fragment following phacoemulsification cataract extraction. *J Cataract Refract Surg.* 2014;40(4):671-4.
- Pandit RT, Coburn AG. Sudden corneal edema due to retained lens nuclear fragment presenting 8.5 years after cataract surgery. *J Cataract Refract Surg.* 2011;37(6):1165-7.
- Asensio-Sánchez VM, Ajami S, Ramoa-Osorio R, Trujillo-Guzmán L. Sudden macular edema two years after cataract surgery due to retained nuclear fragment. *Arch Soc Esp Oftalmol.* 2014;89(7):272-4.
- Zavodni ZJ, Meyer JJ, Kim T. Clinical features and outcomes of retained lens fragments in the anterior chamber after phacoemulsification. *Am J Ophthalmol.* 2015;160(6):1171-1175.
- Barthelmes D, Alexander S, Mitchell P, Chandra J. Hybrid 20/23-gauge pars plana vitrectomy for retained lens fragments after cataract surgery. *Retina.* 2012;32(9):1749-55.
- Stefaniotou M, Aspiotis M, Pappa C, et al. Timing of dislocated nuclear fragment management after cataract surgery. *J Cataract Refract Surg.* 2003;29(10):1985-8.

BREAKING DOWN VISUAL FIELDS IN GLAUCOMA

The OD must possess a solid understanding of the technology at their disposal in order to make the best decisions for patients.



BY DANICA MARRELLI, OD
HOUSTON

Automated perimetry is a critical tool in the diagnosis and follow-up care of glaucoma patients. While advancements in imaging technology (OCT) have improved our ability to evaluate structural damage, perimetry remains the primary method to evaluate visual function in glaucoma. Ultimately, the primary goal of glaucoma therapy is to maintain the patient's visual function throughout their lifetime, so a thorough understanding of perimetry is paramount.

The article provides a simple framework for the interpretation of the standard glaucoma visual field (VF) printout, presents new testing strategies and discusses detection of progressive field loss in the glaucoma patient.

The Basics of VF Interpretation

The amount of data presented on the standard VF printout can seem overwhelming to the busy clinician. A systematic approach is helpful to

simplify and speed up the review process. Two excellent publications to consider for more extensive information include *The Field Analyzer Primer: Effective Perimetry for the Humphrey Field Analyzer* (HFA; Zeiss) and *Visual Field Digest for the Octopus perimeter* (Haag-Streit).^{1,2} A three-step strategy for interpretation of the visual field includes assessing reliability, examining the field for specific glaucomatous defects and evaluating the global indices.

Establishing the reliability of the field is the first step in the review process. Historically, three measures of reliability have been considered: fixation losses, false negatives and false positives. Fixation losses are estimated by periodically presenting a stimulus in the blind spot. If the patient responds to the stimulus, the assumption is that the patient was not looking straight ahead. However, excessive fixation losses may occur for a variety of reasons, including a mis-plotted blind spot. The gaze tracker, which tracks eye movement throughout the test, has largely replaced fixa-

tion losses as an indicator of reliability.

False negative responses are meant to measure poor attention to the test. A false negative response occurs when a patient does not respond to a stimulus that should be easily visible. False negatives, however, are known to worsen with advancing disease and are no longer considered a good measure of reliability. The one reliability indicator that should never be ignored is the false positive rate.

False positives occur when the patient responds when no stimulus has actually been seen. A high number of false positive responses will make a field look better than it actually is and may mask shallow depressions. A false positive rate of 15% or more indicates an unreliable test that should be repeated.

The second step in evaluating the field is to look for defects consistent with glaucoma. Although the gray scale is not appropriate for decision-making, it can quickly draw attention to areas that need further evaluation. The deviation plots identify areas of reduced sensitivity. The total devia-

About the author

Dr. Marrelli is a clinical professor and assistant dean of clinical education at the University of Houston College of Optometry. She is a Diplomate in the disease section of the American Academy of Optometry. She is on the advisory board and participates in speaking engagements for Carl Zeiss Meditec, Ivantis, Aerie Pharmaceuticals, Allergan and Bausch & Lomb.

tion plot identifies abnormal points compared with an age-matched normative database. The information is presented both in decibels and in statistical probability maps, where darker symbols represent increasing significance.

The pattern deviation plot shows the remaining problem areas after adjusting for any generalized loss that might be due to cataract or other media problems, uncorrected refractive error or small pupils. The pattern deviation plot is arguably the most important part of the field printout because it highlights areas of localized loss that are common in glaucoma.

The clinician should look for clusters of abnormal points in areas that are typical of glaucoma: nasal step, arcuate bundle and paracentral defects that respect the horizontal midline. Remember that a single point that is statistically abnormal may not be clinically relevant, but a cluster of flagged points more likely indicates real loss.

The third step is to evaluate the Glaucoma Hemifield Test (GHT) and global indices. The GHT highlights how glaucoma damages superior and inferior fields asymmetrically. The GHT compares mirror image clusters of points above and below the horizontal midline to look for significant differences. A GHT message of “outside normal limits” that is repeatable is strong evidence of glaucoma and is a stand-alone criteria for diagnosing acquired glaucomatous damage according to the Hodapp-Parrish-Anderson criteria.³

The global indices of the Humphrey field include mean deviation (MD) and pattern standard deviation (PSD). Analogous measures on the Octopus perimeter are mean defect and loss variance. The MD measures the difference between the patient’s sensitivity and that of age-matched normal values, averaged across the entire field. The MD is significantly impacted by cataract and other media problems as well as uncorrected refractive error, and it is insensitive to

small, shallow localized defects that often occur in early glaucoma.

The PSD reflects the shape or “smoothness” of the hill of vision and is more reflective of the localized defects that occur in glaucoma. Both the MD and PSD values will display an alert when they reach statistical significance. The Visual Field Index (VFI) is a newer metric on the HFA that is similar to the MD but weighs the central points more heavily than peripheral points and is less sensitive to cataract because it is derived from the PSD data. The VFI ranges from 100% (normal field) to 0% (perimetrically blind).

Which Test Should I Run?

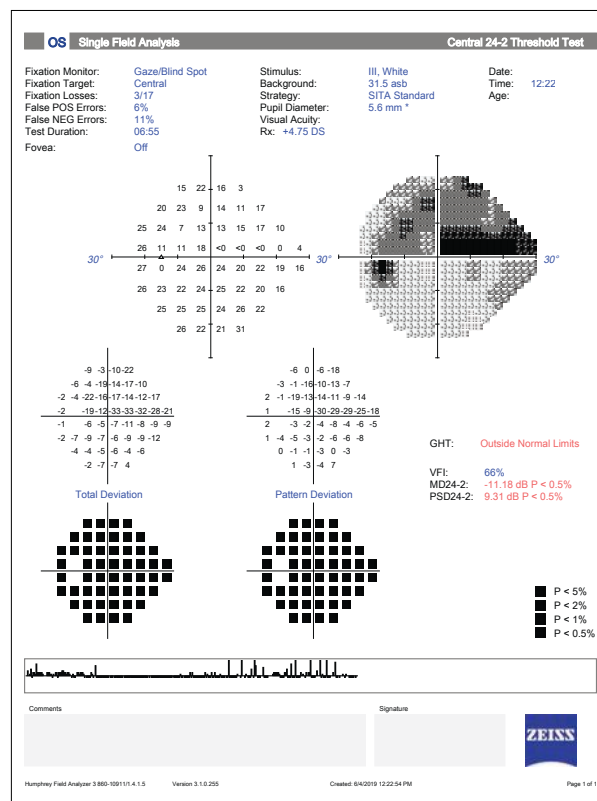
Standard automated perimetry (SAP) remains the primary perimetry method for glaucoma diagnosis and follow-up. The standard test pattern for glaucoma testing is the 24-2. Swedish Interactive Thresholding Algorithm (SITA) testing was quickly adopted when introduced on the HFA because it allows for more rapid testing compared with the original thresholding algorithm.

While the 24-2 SITA Standard or SITA Fast are the most commonly used tests for glaucoma, there have been two recent shifts in field testing: the development of an even faster

test and more attention to the central 10° of the field.

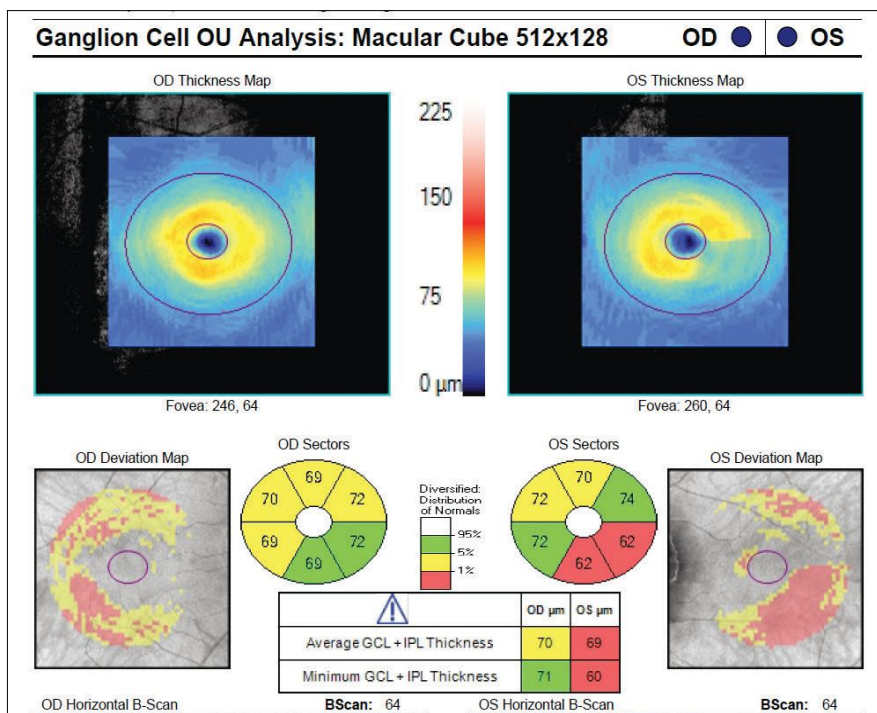
SITA Faster. SITA Standard and Fast testing have both been shown to be accurate, repeatable tests. While early reports showed that SITA Standard testing had better repeatability than SITA Fast, more recent studies have shown the two perform very similarly in a clinical setting and both are reasonable strategies to use.⁴⁻⁷ The newest thresholding algorithm on the HFA is the SITA Faster, which is roughly 50% quicker than the SITA Standard and approximately 30% faster than the SITA Fast.

This time-saving is achieved by modest modifications in the initial threshold value selection, by removing unnecessary delays between stimuli presentation and by removing both the blind spot and false negative catch trials.

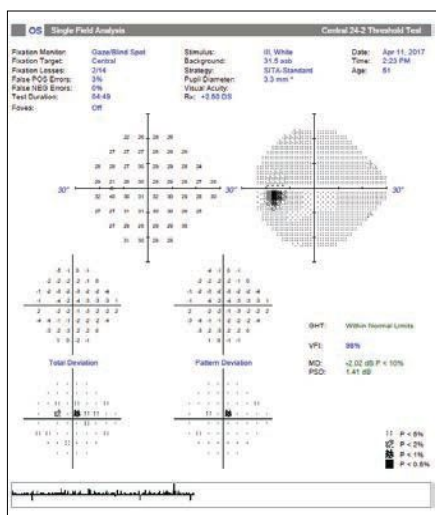


There are three points to keep in mind when interpreting this 24-2 SITA Standard printout:

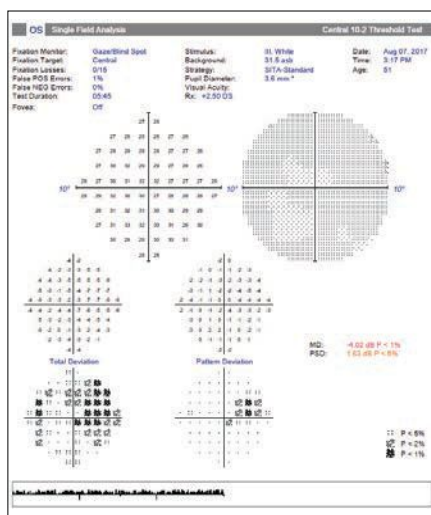
- 1. The test is reliable, without excessive fixation losses, false positive or false negative errors.**
- 2. The total deviation plot reveals highly significant depression over nearly the entire field. When adjusting for this overall depression, which was due to cataract, the pattern deviation plot shows a large, dense superior arcuate defect with a smaller inferior nasal step. This pattern of loss is characteristic of glaucoma.**
- 3. The GHT is outside normal limits due to the significant difference between the superior and inferior hemifield values; the MD and PSD are both highly abnormal.**



The patient shows the classic ganglion cell–inner plexiform layer thinning in the inferotemporal sector of the macula of the left eye.



The 24-2 SITA Standard reveals a single significant superior paracentral defect and a “within normal limits” message on the GHT. Although the point is statistically significant, it might be overlooked.



The 10-2 test grid of the same patient reveals a much more substantial superior nasal defect that correlates to the inferotemporal macular damage.

Reliability is now based on the gaze tracker and false positive trials only. These modifications have been shown to give nearly identical results as SITA Fast testing.⁸ However, the SITA Faster may have a higher number of unreliable tests compared with the SITA Standard test.⁹ Alert

patients switching from the SITA Standard or Fast to the SITA Faster that the stimuli will be presented more rapidly. SITA Faster testing is available only on the HFA3.

Emphasis on the Central 10°. In large part due to improved imaging techniques with OCT, an increasing

amount of attention over the past decade has been focused on damage to the macula in glaucoma, which can happen in early stages. One of the most comprehensive reports of macular damage in glaucoma reported that the 24-2 test grid may miss or underestimate the amount of functional damage to the central portion of the visual field due to the 6° separation between test points and poor sampling in the area of most dense retinal ganglion cell population.¹⁰ The 10-2 test grid spaces test points 2° apart and provides much better sampling across the macula.

The 10-2 has been shown to identify central visual field defects in patients whose 24-2 test would otherwise be considered normal.¹¹⁻¹³ This has prompted some to recommend adding the 10-2 VF to the glaucoma diagnostic protocol. However, another study showed that the large majority of patients with defects on the 10-2 demonstrated abnormal points in the central 10° on the 24-2 test.¹⁴

It is likely unnecessary to obtain a 10-2 on all glaucoma patients and suspects. While there is no current standard guideline for using the 10-2 in early glaucoma, it seems prudent to obtain a 10-2 on any patient who shows characteristic macular ganglion cell thinning on OCT or one or more abnormal points in the central 10° of a 24-2 test.¹⁵ The clinician should evaluate the central points of a 24-2 carefully, as a single depressed point (rather than the customary cluster of points) may be significant.

24-2C. This is a new test pattern on the HFA that adds 10 test points within the central 10° to the 24-2 test grid (five in the superior and five in the inferior hemifield). Test points were chosen by an expert group and were based on areas known to be susceptible to glaucoma damage from structural and functional studies. Not surprisingly, the 24-2C has been shown to identify more central defects and have better structure-function correlation than the 24-2.¹⁶



“ I didn't realize
STARS
were little dots that twinkled ”

—Misty L, *RPE65* gene therapy recipient

**WE'RE SEEING
AMAZING RESULTS.
AND SO ARE THEY.**

At the Foundation Fighting Blindness our mission is everybody's vision. Our work shines a light on the darkness of inherited retinal diseases (IRDs).

We're the world's leading organization searching for treatments and cures. We need your help to fuel the discovery of innovations that will illuminate the future for so many. We have robust disease information, a national network of local chapters and support groups, local educational events, and our My Retina Tracker® Registry to help keep your patients connected with clinical and research advancements.

Help accelerate our mission
by donating at ECPs4Cures.org.

**FOUNDATION
FIGHTING
BLINDNESS**

FightingBlindness.org

The 24-2C test, somewhat of a “hybrid” between the 24-2 and the 10-2, may represent a reasonable balance of testing the central points while avoiding the necessity of performing both 10-2 and 24-2 tests in early glaucoma diagnosis. It uses the SITA Faster algorithm and is available on the HFA3.

Detecting VF Progression

Once the diagnosis of glaucoma has been made, or a patient is identified as a glaucoma suspect, the focus shifts to detecting progression. Information about functional progression is paramount in determining which patients need escalation of therapy and which are being adequately controlled with their current therapy. Unfortunately, the inherent variability of visual fields makes distinguishing between normal fluctuation and real change quite difficult at times.

The frequency of visual field testing is an important consideration. Enough tests must be performed to overcome the inherent test-retest variability in order to detect true change. Several studies, using simulated and real patient data, have demonstrated that obtaining more frequent testing allows for earlier detection of progression.¹⁷⁻¹⁹ It is estimated, for example, that it would take at least five years to detect a rapidly progressing (-2dB/year) field if testing is done only once per year and could take much longer if the patient has highly variable fields.²⁰

That same progression could be detected in under two years if testing is done three times per year. Serial visual fields are challenging in terms of patient flow and costs, and a compromise between adequate detection of progression and the burden of running more tests must be struck.

A common strategy to rule out rapidly progressing visual fields is to obtain six visual fields within the first two years. This can be accomplished with two baseline tests in quick succession, followed by semi-annual testing, with repeat tests if needed

to confirm suspected progression. If minimal progression is observed in the first few years of follow-up, tests may be done less often.

Many clinicians use manual subjective review of serial fields in order to detect progression. The problem with this method is that it uses non-standard criteria for decision-making. Studies have shown that the agreement among even expert clinicians is poor to fair when using subjective judgment of fields.^{21,22} The use of progression software substantially improves that.

Progression software evaluates serial fields by two different methods, event-based and trend-based analysis.

Event-based analysis compares the current examination with a reference or baseline examination. In a sense, event analysis answers a yes/no question: Is today’s test worse than the baseline? In event-based analysis, a symbol is displayed when a point is worse than baseline and exceeds the expected test-retest variability.

In the Guided Progression Analysis (GPA) for the HFA, a message of “possible progression” is displayed if three or more points have been flagged on two consecutive tests; a stronger message of “likely progression” is displayed when that has occurred on three consecutive tests. A benefit of event-based analysis is that

Tips For Getting The Best Visual Field Possible

By correctly setting up the perimeter, appropriately explaining the test to the patient, carefully positioning the patient and providing encouragement throughout the test, your technician plays a key role in obtaining the best possible results. Here are some important steps to obtain good results.^{1,2}

1. Correctly set up the perimeter:

- a. Properly input the patient’s age (for appropriate age-matched comparison).
- b. Pick the appropriate test strategy.
- c. Choose the correct trial lens. The patient’s best distance refraction can be input into the instrument, which will calculate the appropriate trial lens based on age. There are rare exceptions when this will not be appropriate, such as a young pseudophakic patient, a cycloplegic patient or a patient wearing contact lenses during the test.
- d. The perimeter should be in a location that is free from distractions.

2. Correctly prepare the patient:

- a. Ensure that the patient is comfortably seated at the appropriate height for the test bowl; the patient should not have to stretch to reach the forehead rest, nor should they have to slump down into the chin rest. A straight back is usually the most comfortable position.
- b. Position the eye patch to fully block any stimulus from the untested eye, and make sure the cord of the occluder does not block the vision of the tested eye.
- c. Once the patient is positioned properly at the instrument, the trial lens should be moved as close to the eye as possible without touching the eyelashes. This will reduce the chance of a lens rim artifact.

3. Correctly instruct the patient:

- a. Tell the patient the purpose of the test, what to expect and how to perform the task.
- b. Instruct the patient to look straight ahead at the fixation target at all times and not to move the eye around to “look” for the stimuli.
- c. The patient should understand that the test is designed to show lights of various intensities and that they are not expected to see every light shown. This can reduce anxiety during the test.
- d. Ask the patient to blink normally during the test.
- e. The patient should know that they can pause the test if they need to rest or if they have questions simply by pressing and holding down the response button.
- f. The technician should provide gentle, encouraging reminders for the duration of the test.

it can be used earlier in the care of a patient because it does not require as many exams as trend-based analysis. Therefore, it may allow earlier detection of progression. In addition, because event analysis is based on the pattern deviation values, it emphasizes localized loss that is common in glaucoma and is less influenced by advancing cataract or other cause of overall depression.

A disadvantage of event-based analysis is that it is unable to detect progression for severely depressed points. To maximize event-based analysis, the two baseline exams must be reliable and appropriate for comparison; the instrument will default to the first two reliable exams, but if there is an apparent improvement due to the learning curve, reset the baseline to more appropriate tests.

It is also important to understand the nature of progressive changes in glaucoma. The most common form of progression is deepening of an existing scotoma, followed by enlargement of an existing scotoma.²² When a message of possible or likely progression is displayed, the clinician should evaluate where the flagged points are. Progressing points within or adjacent to an existing scotoma are much more likely to represent true change than points with no spatial relation to the existing field loss; likewise, clusters of points are more likely to be true progression than random, isolated points.

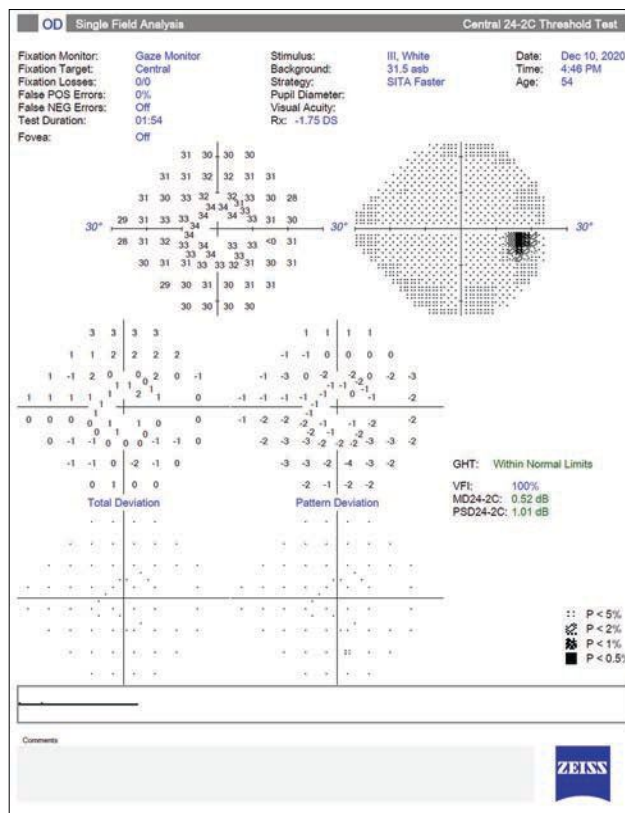
Trend-based analysis is used to quantify the rate of change by creating a linear regression of a given metric with time. This type of analysis allows for the discrimination between subtle, slow change and a patient who has considerable test-retest variability.²² The GPA software uses the VFI to quantify the rate of change; however, it also evaluates the MD over time in other programs. Trend-based analysis has been shown to have a higher sensitivity than event analysis, but it requires more tests to detect change. Because trend analysis is evaluating overall or global loss, it may miss subtle localized progres-

sion. This may be particularly true in the early stages of the disease.

In practice, both event- and trend-based analysis are useful in evaluating progression of visual fields. They tell us different things about the patient: whether or not the patient progressed (event) and at what rate (trend). The two methods will not always agree. One study looking at agreement between expert consensus, event analysis and trend analysis found only moderate agreement between the two.²³ Early in the course of the follow-up, event analysis is the main focus; later in the process, trend analysis may take on a more important role.

Finally, the fact that a field has reached an “event” (shown progression) does not necessarily dictate a change in the patient’s therapy. Consider these things before amplifying a patient’s therapy. How long did it take for the progression to occur? What is the patient’s life expectancy? Where is the field progressing (central vs. peripheral)? Is the progression likely to have a meaningful impact on the patient’s functional vision? What is the impact of the “next step” in amplification of therapy?

These considerations fall outside the scope of this article but only emphasize that progression software provides the clinician statistical analysis of serial visual fields. Remember that clinical decisions are based on more than statistical information.

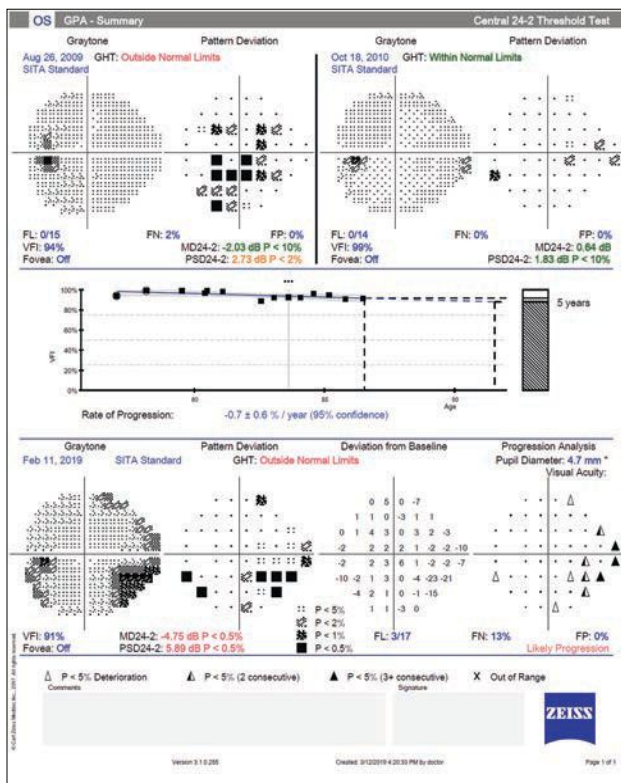


This image shows a normal 24-2C SITA Faster test, which adds 10 additional test points to the central 10° of the 24-2 test grid. The SITA Faster strategy allows for very rapid testing; this test was completed in less than two minutes.

Home-based Perimetry

In recent years, there has been significant interest in the development of home-based perimeters. A variety of tablet- and headset-based tools are in various stages of development.²⁴⁻³⁰ This year, M&S Technologies released the Melbourne Rapid Fields (MRF) for both in-office and home-based testing. The tablet-based application has been shown to be comparable with the 24-2 SITA Standard and SITA Fast on the HFA, even on multiple tests performed over the course of six months, with similar accuracy in test-retest variability.²⁸⁻³⁰

By performing perimetry more frequently, progression can be detected earlier. A simulation study demonstrated that weekly home-based perimetry was able to detect rapid progression in just under a year compared with 2.5 years that it would take with in-office testing



These are VFs performed over 10-year-period in a patient with pseudoexfoliation glaucoma. Event-based analysis shows a message of “likely progression” due to multiple points worsening in the inferior nasal quadrant on 3+ consecutive visits. Although event-based analysis clearly shows the development of an inferior partial arcuate defect, trend analysis shows that the rate of change is actually quite slow.

every six months.³¹ Of course, the performance of real patients may not be equivalent to that predicted by a simulation study.

In a study evaluating the adoption and performance of the MRF, glaucoma suspects and stable glaucoma patients were asked to perform the test at home six times at weekly intervals.²⁶ While 88% of subjects were able to perform at least one test, only 69% performed all six tests. Some of the barriers to compliance included technology issues, lack of motivation and competing life demands. Studies evaluating compliance over a longer period of time are needed.

Nevertheless, a tablet-based home testing system is now available and may be appealing in patient populations for whom in-office testing is not desirable or feasible.

Key Clinical Takeaways

Even in an era of rapidly advancing imaging technology, perimetry remains instrumental in the care of the glaucoma patient, as it provides valuable data for functional vision assessment. The clinician must possess a solid understanding of the technology in order to make sound clinical decisions regarding diagnosis and progression of glaucoma. Recent changes in testing strategies, and the introduction of home-based testing, may improve our ability to assess visual function in the clinic and patient acceptance of the test. ■

- Hood DC, Raza AS, de Moraes CG, et al. Glaucomatous damage of the macula. *Prog Retin Eye Res.* 2013;32:1-21.
- Grillo LM, Wang DL, Ramachandran R, et al. The 24-2 Visual Field Test misses central macular damage confirmed by the 10-2 visual field test and optical coherence tomography. *Transl Vis Sci Technol.* 2016;5(2):15.
- De Moraes CG, Hood DC, Thenappan A, et al. 24-2 visual fields miss central defects shown on 10-2 tests in glaucoma suspects, ocular hypertensives and early glaucoma. *Ophthalmology.* 2017;124(10):1449-56.
- Hood DC, Raza AS, de Moraes CG, et al. Initial arcuate defects within the central 10° in glaucoma. *Invest Ophthalmol Vis Sci.* 2011;52(2):940-6
- Sullivan-Mee M, Karin Tran MT, Pensyl D, et al. Prevalence, features and severity of glaucomatous visual field loss measured with the 10-2 achromatic threshold visual field test. *Am J Ophthalmol.* 2016;168:40-51.
- Park HY, Hwang BE, Shin HY, Park CK. Clinical clues to predict the presence of parafoveal scotoma on Humphrey 10-2 visual field using a Humphrey 24-2 visual field. *Am J Ophthalmol.* 2016;161:150-9.
- Phu J, Kalloniatis M. Ability of 24-2C and 24-2 grids to identify central visual field defects and structure-function concordance in glaucoma and suspects. *Am J Ophthalmol.* 2020;219:317-31.
- Wu Z, Saunders LJ, Daga FB, et al. Frequency of testing to detect visual field progression derived using a longitudinal cohort of glaucoma patients. *Ophthalmology.* 2017;124(6):786-92.
- Gardiner SK, Crabb DP. Frequency of testing for detecting visual field progression. *Br J Ophthalmol.* 2002;86(5):560-4.
- Nouri-Mahdavi K, Zarei R, Caprioli J. Influence of visual field testing frequency on detection of glaucoma progression with trend analyses. *Arch Ophthalmol.* 2011;129(12):1521-7.
- Chauhan BC, Garway-Heath DF, Goñi FJ, et al. Practical recommendations for measuring rates of visual field change in glaucoma. *Br J Ophthalmol.* 2008 ;92(4):569-73.
- De Moraes CG, Liebmann JM, Levin LA. Detection and measurement of clinically meaningful visual field progression in clinical trials for glaucoma. *Prog Retin Eye Res.* 2017;56:107-47.
- Aref AA, Budenz DL. Detecting visual field progression. *Ophthalmology.* 2017;124(12S):S51-6.
- Antón A, Pazos M, Martín B, et al. Glaucoma progression detection: agreement, sensitivity, and specificity of expert visual field evaluation, event analysis, and trend analysis. *Eur J Ophthalmol.* 2013;23(2):187-95
- Jones PR, Campbell P, Callaghan T, et al. Glaucoma Home monitoring using a tablet-based visual field test (Eyecatcher): an assessment of accuracy and adherence over six months. *Am J Ophthalmol.* 2020;223:42-52.
- Che Hamzah J, Daka Q, Azuara-Blanco A. Home monitoring for glaucoma. *Eye (Lond).* 2020;34(1):155-60.
- Jones PR, Smith ND, Bi W, Crabb DP. Portable perimetry using eye-tracking on a tablet computer-a feasibility assessment. *Transl Vis Sci Technol.* 2019;8(1):17.
- Prea SM, Kong GY, Guymer RH, Vingrys AJ. Uptake, persistence and performance of weekly home monitoring of visual field in a large cohort of patients with glaucoma. *Am J Ophthalmol.* November 19, 2020. [Epub ahead of print].
- Kong YX, He M, Crowston JG, Vingrys AJ. A comparison of perimetric results from a tablet perimeter and Humphrey Field Analyzer in glaucoma patients. *Transl Vis Sci Technol.* 2016 ;5(6):2.
- Kumar H, Thulasidas M. Comparison of perimetric outcomes from Melbourne Rapid Fields tablet perimeter software and Humphrey Field Analyzer in glaucoma patients. *J Ophthalmol.* 2020;2020:8384509.
- Prea SM, Kong YX, Mehta A, et al. Six-month longitudinal comparison of a portable tablet perimeter with the Humphrey Field Analyzer. *Am J Ophthalmol.* 2018;190:9-16.
- Anderson AJ, Bedggood PA, George Kong YX, Martin KR, Vingrys AJ. Can home monitoring allow earlier detection of rapid visual field progression in glaucoma? *Ophthalmology.* 2017;124(12):1735-42.

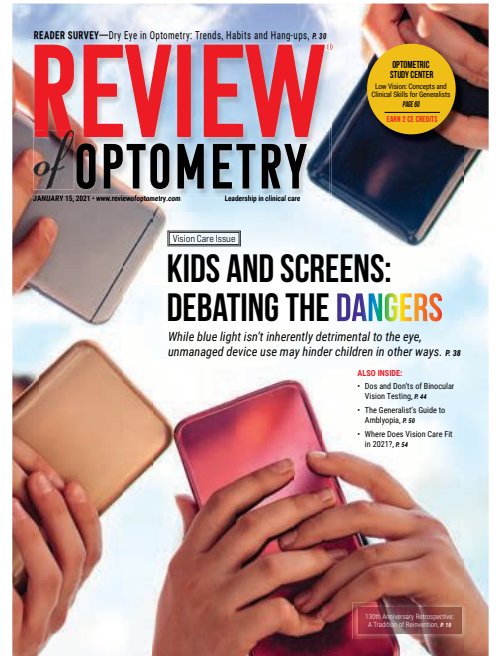A NEW LOOK FOR A NEW ERA

REVIEW[®] of OPTOMETRY

Leadership in clinical care.

We're 130 years old—and have never looked better!

Founded in 1891, *Review of Optometry* has consistently led the profession through its long evolution, always changing with the times. Our latest design, the first in over two decades, showcases our content—and our industry partners—better than ever.



LAYOUTS PUT CONTENT FRONT AND CENTER

When the Pressure's On
Elevated IOP is bad. Combine it with a rise in IOP and you get a potential emergency on your hands.

Fig. 1. Under photophobia, the patient's visual acuity is reduced to 20/400. The patient's visual acuity is reduced to 20/400. The patient's visual acuity is reduced to 20/400.

Fig. 2. Results of 20+ readings reveal fluctuations in the patient's IOP. The patient's IOP is 18 mmHg. The patient's IOP is 18 mmHg. The patient's IOP is 18 mmHg.

Fig. 3. A 300-micrometer laser power meter indicates the patient's IOP is 18 mmHg. The patient's IOP is 18 mmHg. The patient's IOP is 18 mmHg.

Fig. 4. A 300-micrometer laser power meter indicates the patient's IOP is 18 mmHg. The patient's IOP is 18 mmHg. The patient's IOP is 18 mmHg.

New design reinforces the enduring value and impact of our content.

- Clean, contemporary style that honors our history while suiting the aesthetic of today.
- Optometrists prefer print publications by a wide margin. We lean in to that, devoting more space to images, tables and graphics that augment the discussion and make *Review* “a keeper” in a world of throwaways.
- Full editorial spreads engage readers and aid quick reading for key highlights.
- From news briefs to in-depth features to CE courses, *Review* readers stay up to date on the latest insights from top thought leaders.
- *Review* gives the profession more content every issue than other publications—and has remained in print without interruption.

FOR AD RATES, CALL YOUR REVIEW SALES REP TODAY

Michael Hoster, Publisher

mhoster@jobson.com • 610-492-1028

Michele Barrett, Sales Representative
mbarrett@jobson.com • 215-519-1414

Jonathan Dardine, Sales Representative
jdardine@jobson.com • 610-492-1030

Feature: DRY EYE SURVEY

DRY EYE IN OPTOMETRY: TRENDS, HABITS AND HANG-UPS

Our reader survey finds most OEs opt for simple diagnostic tests and familiar treatments, convinced by financial pressures from advancing their care.

Fig. 1. What percentage of your total patient base has dry eye?

Fig. 2. What percent of your patients in each of these categories suffer from dry eye?

Fig. 3. Why do you have the prevalence of dry eye patients increased recently?

Fig. 4. When do you ask patients about dry eye?

Fig. 1. Why has the prevalence of dry eye patients increased recently?

Fig. 2. When do you ask patients about dry eye?

Fig. 3. Why do you have the prevalence of dry eye patients increased recently?

Fig. 4. When do you ask patients about dry eye?

© 2021 REVIEW OF OPTOMETRY

AN ACTION PLAN FOR ASSESSING DOUBLE VISION

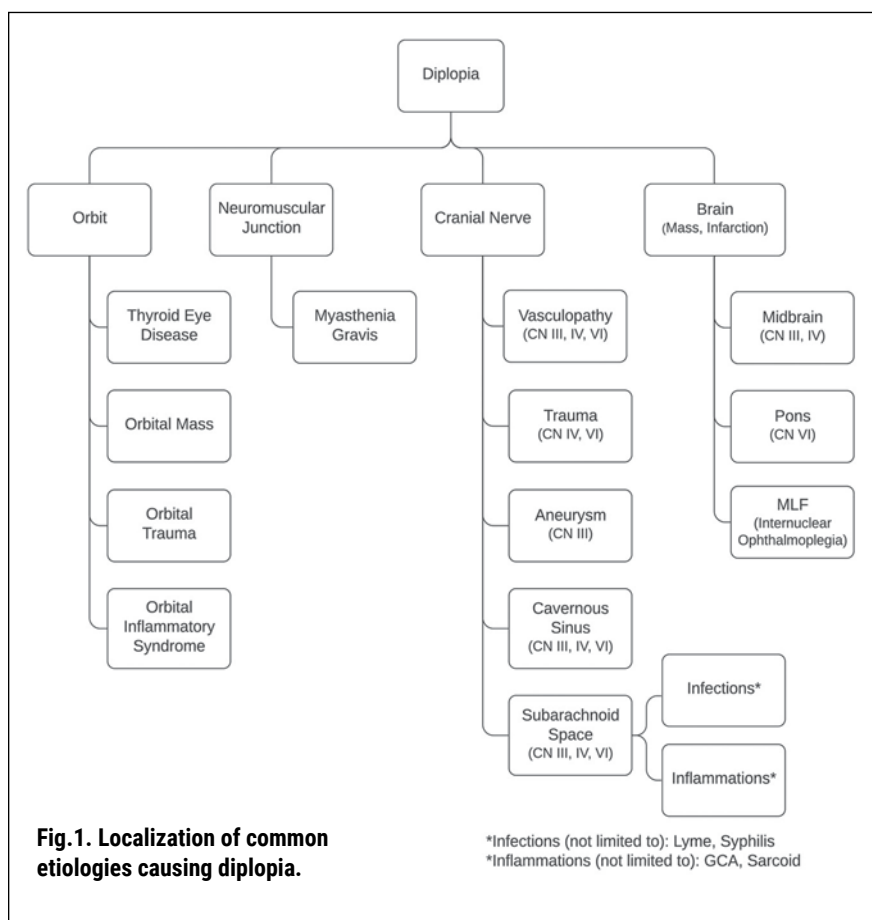
Ask these 20 questions to break down a puzzling case of diplopia and figure out the best course of action.



BY ERIN DRAPER, OD,
AND TINA ZENG, OD
PHILADELPHIA

Determining the etiology of a patient’s complaint of double vision can be akin to a detective solving a mystery in a novel; it is best to approach the case in a stepwise fashion and ask the appropriate questions. Here, we present a four-step process with 20 questions to ask or consider during an eye exam when a patient presents with diplopia.

This guide will help anatomically localize the cause of the diplopia and create a differential diagnosis. As the eye care provider goes through the exam, these questions will help determine if the cause is in the brain, nerve, junction between nerve and muscle or orbit. *Figure 1* presents some more common differentials for diplopia and their localization. Once they have created a differential diagnosis, the eye care provider will then be able to determine the appropriate management for their patient.



About the authors

Dr. Draper is an assistant professor at Salus University. She splits her time between clinical care at The Eye Institute in Philadelphia in the neuro-ophthalmic disease service and teaching anatomy and neuro-ophthalmic disease courses. Dr. Zeng is a resident of neuro-ophthalmic disease at The Eye Institute. They have no financial disclosures.

Step 1: Weigh Binocular vs. Monocular Diplopia

The first step to uncovering the etiology is to determine if the patient has true binocular diplopia.

Ask the patient:

1. Does the double vision go away if you cover one eye?

If no, then we have monocular diplopia and our neuro-ophthalmic mystery ends here. At this point, we can narrow down the etiology to being confined to the ocular structures (cornea, lens or retina). These patients should have a refraction and thorough biomicroscopic examination of the ocular media.

There are a few rare cases where a patient may have monocular diplopia of neurological etiology. These patients are likely to have lesions of the parieto-occipital region.¹

If the answer is yes, continue to question 2.

2. Does it matter which eye you cover?

If yes, then this is likely a case of monocular diplopia.

If no, then the patient likely has true binocular diplopia, and you need to continue to Step 2.

Step 2: Determine Misalignment Type

Ask the patient:

3. Is it constant or fluctuating?

A patient with intermittent or fluctuating diplopia can make the diagnosis more challenging because you may not be able to elicit the diplopia while in the exam room. Performing testing in different positions of gaze and at different distances may induce the diplopia. If the patient reports worse diplopia toward the end of the day or when fatigued, the leading differentials include myasthenia gravis (MG) and a decompensating phoria.

4. How are the images displaced (horizontal, vertical, diagonal)?

Direction	Differential
Horizontal	Medial/lateral rectus

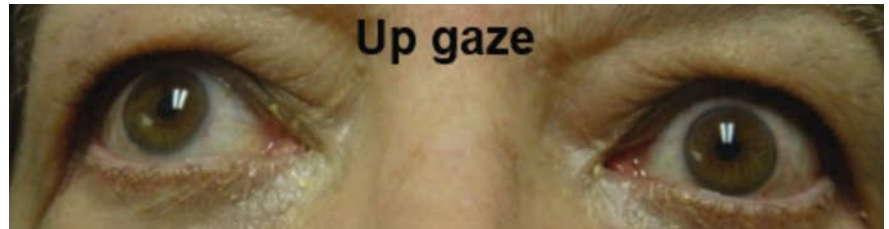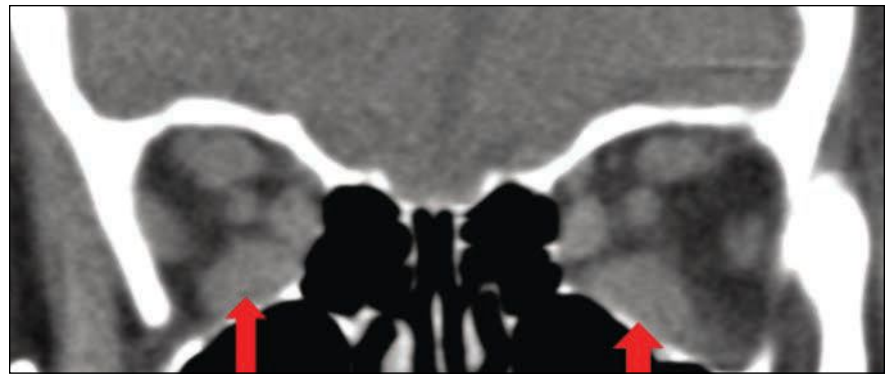


Fig. 2. Enlargement of the bilateral inferior recti muscles OS>OD as noted with the red arrows on the CT scan above resulted in a bilateral supraduction limitations. Note the Purkinje image is higher on the cornea of the left eye, which is the eye with the greater supraduction limitation.

Vertical/Diagonal	Obliques, superior/inferior rectus, multiple extraocular muscles
Tilt.....	Cranial nerve (CN) IV palsy or skew deviation

We now need to determine the pattern of diplopia in order to localize the problem and narrow down our differential diagnoses. Horizontal diplopia is more consistent with a lesion affecting the medial and/or lateral rectus, whereas vertical or diagonal may be more consistent with a lesion affecting the oblique muscles, superior rectus and/or inferior rectus or multiple extraocular muscles.

Some patients may also report a tilt to the images, which would indicate a torsional component and may point to a diagnosis of a CN IV palsy or skew deviation.

5. Is it worse in any particular distance (near or far) or direction of gaze (left, right, up, down)?

Many presentations of diplopia will have the same misalignment at all distances. If there is a difference,

this can be helpful in narrowing the differentials. For example, horizontal diplopia, which is present at distance only, is more indicative of either CN VI palsy or a divergence insufficiency. Conversely, if the horizontal diplopia is only present at near, it may point to a convergence insufficiency.

Some causes of diplopia may only be present or worse in a particular gaze. If the cause of the diplopia is paretic, the diplopia will be worse in the direction of the paresis. If there is an orbital mass, the gaze of worsening diplopia may depend on where the mass is located in the orbit. If the mass is more anterior, such as in an enlarged lacrimal gland or a space-occupying lesion, the diplopia will be worse in the direction of the mass. If there is enlargement of an extraocular muscle, such as in thyroid eye disease, the diplopia will be exacerbated in the opposite direction of the affected muscle (*Figure 2*).

Observing the patient for a compensating head posture can also be helpful. A patient with a left abduction deficit will often have their head turned to the left to put the eyes in right gaze and minimize the diplopia.

Feature DIPLOPIA

Additionally, a patient with CN IV palsy will often tilt their head to the contralateral side of the hypertropic eye.

6. How long has it been going on for and is it stable, worsening or improving?

Many patients presenting with diplopia may have risk factors for a vasculopathic etiology, such as diabetes, hypertension and smoking. However, if the onset of diplopia was greater than six months ago, then the etiology is not likely vasculopathic, and additional testing for other causes must be performed.

7. How did you first notice it?

This question will give the provider insight to any precipitating factor (*i.e.*, trauma or stroke). Additionally, characteristics of onset may help determine etiology. For example, if they report only noticing the diplopia because they were performing a particular task, this can be revealing.

8. Any history of childhood strabismus or prior orbital surgery?

If the patient has a history of being treated for strabismus or strabismic amblyopia as a child, such as with patching, this may indicate that they are now experiencing a decompensating phoria resulting in diplopia. However, the exam findings must be consistent with this diagnosis. If there is a noncomitant deviation, then additional etiologies must be ruled out. Note that other types of surgeries, such as cataract, glaucoma or scleral buckle for a rhegmatogenous retinal detachment, can also result in diplopia.²⁻⁴

Ask yourself during the exam:

9. Do I see any ductional limitation?

Careful assessment of ocular motilities frequently helps with

	Cover Test Findings for Right CN Palsy			Patterns of CN Palsies
	Right gaze		Left gaze	
CN III	2 exo	4 LHyper 8 Exo 2 LHyper 20 Eso 6 RHyper	16 exo	Reversing hyperdeviation with exo deviation greatest across from vertically limited eye
CN IV	8 RHyper	2 RHyper	4 RHyper 12 RHyper	Hyperdeviation worse in contralateral gaze and ipsilateral head tilt
CN VI		30 Eso	10 Eso 2 Eso	Esodeviation greatest in ipsilateral gaze

Fig. 3. Patterns of right CN palsies (CN III, CN IV and CN VI) on cover test.

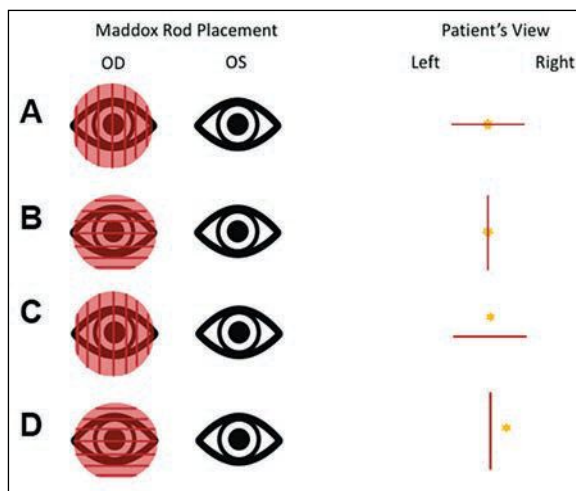


Fig. 4. Maddox rod testing for horizontal and vertical misalignments. The red line is viewed with the right eye, and the yellow star represents the light source viewed by the left eye. A is the patient view if no vertical deviation. B is the view if no horizontal deviation. C is the view of a left hyper deviation. D is the view of an eso deviation.

localization.⁵ It is important when performing versions that you put the patient's eyes in the fullest extent of their gaze. Purkinje images (PI) can be useful in assessing ductional limitations, particularly in vertical gazes (Figure 2).

10. Does my cover test or Maddox rod testing in different positions of gaze match the pattern of a specific CN palsy?

This is one of the most helpful in-office tests in localizing a lesion

causing diplopia. There are specific patterns of deviation that help identify isolated CN palsies. The results of a cover test are objective and the test does not require a verbal response from the patient. Additionally, a cover test can be helpful in determining a constant from an intermittent strabismus or a phoria. Conversely, Maddox rod testing requires that the patient understand the test and be able to give a verbal response. Figure 3 demonstrates the classic patterns of CN III, IV and VI palsies.

Maddox rod testing must be performed twice in each position of gaze: once with the cylinders oriented vertically, creating a horizontal red

CLINICAL PEARLS: ASSESSING OCULAR MOTILITY

- On lateral gaze, the sclera of both the abducting and adducting eyes should be buried.
- On up gaze, the eye with the PI higher on the cornea is the more limited eye.
- On down gaze, the eye with the PI lower on the cornea is the more limited eye.

Optometry CE Study Center



The CE You
Need in 2021

As low as
\$17.50
per Credit Hour

Buy just one 2-hour course for \$35 or buy as many as you need

Choose from over 50 individual CE courses

Includes the hard to find topics that fulfill your state requirements

All available in a convenient online format

Visit www.ReviewEdu.com for additional information and purchasing options.

The CE Study Center courses have been developed in conjunction with expert faculty from leading schools of optometry and are oriented toward clinical practice issues that are designed to assist eye care professionals in serving their patient's healthcare needs. CE Courses also appear in print monthly in *Review of Optometry*.

1-800-825-4696 • INFO@REVIEWSCE.COM

These COPE-Accredited CE courses are administered in partnership with an accredited school of optometry.

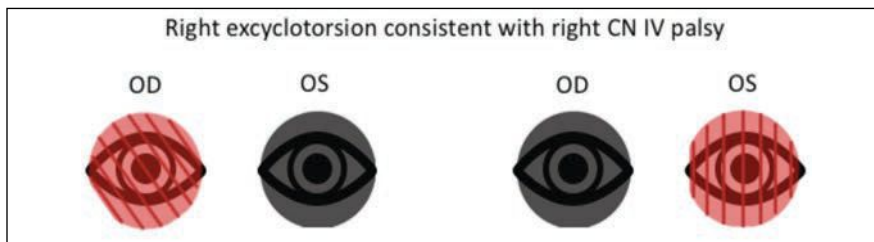


Fig. 5. Double Maddox rod testing showing excyclotorsion of the right eye and no torsion when placed over the left eye, consistent with a right CN IV palsy.

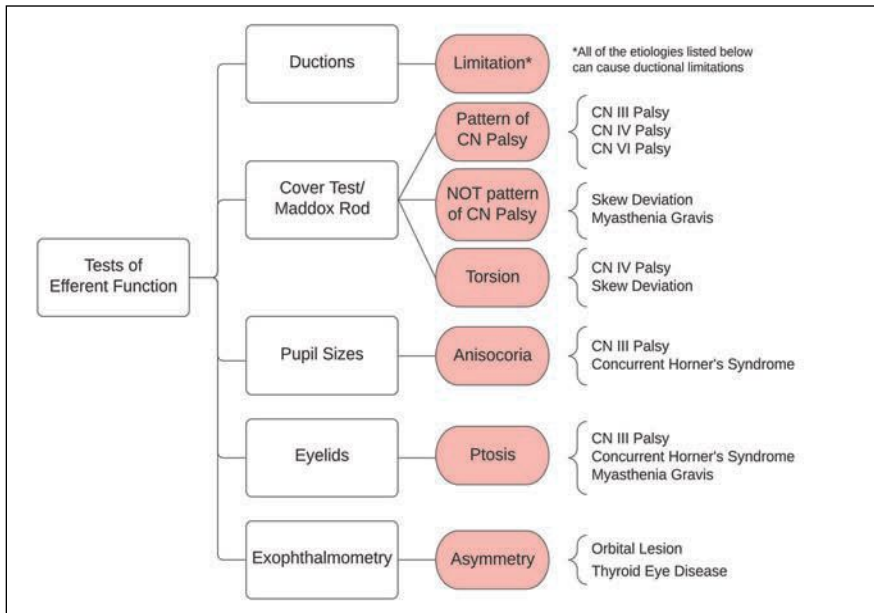


Fig. 6. Other efferent findings can aid in localizing the lesion.

line to assess the vertical deviation, and again with the cylinders oriented horizontally, creating a vertical red line to assess the horizontal deviation (Figure 4).

The Parks-Bielschowsky three-step test is useful in diagnosing an isolated unilateral CN IV palsy. This palsy pattern is a hyperdeviation greater on contralateral gaze and ipsilateral head tilt. Although this is a very useful test, it is not 100% sensitive. The test may fail to diagnose in approximately 30% of cases.⁶

11. If there is a vertical deviation, are the double Maddox rod results abnormal?

Double Maddox rod testing is helpful in assessing for torsion and should be completed on all patients presenting with a hypertropia. Place the Maddox rods in both oculars of a trial frame. Cover one eye and ask

the patient to rotate the cylinder until the line appears perfectly flat. If the cylinders are not aligned at 90°, this indicates torsion (Figure 5). Do this for both eyes.

Step 3: Localizing the Lesion

12. Are there any other associated ocular findings? (e.g., vision loss, ptosis, anisocoria, conjunctival injection, proptosis, uveitis, nystagmus, papilledema, signs of aberrant regeneration)

Thorough assessment of other afferent and efferent exam findings can also uncover clues which may help localize the cause of the diplopia. For example, proptosis and monocular vision loss would be more indicative of an orbital lesion or thyroid eye disease, while the presence of ptosis may indicate a CN III palsy, MG or a concurrent Horner's syndrome. Figure 6 highlights some additional efferent exam findings which are helpful for localization.

On biomicroscopy, the presence of conjunctival injection or a red eye may point to a cavernous sinus fistula, thyroid eye disease or inflammatory orbital pseudotumor. Any signs of a current or previous uveitis may indicate an infectious or inflammatory etiology, such as sarcoidosis, syphilis or lymphoma. Additionally, if a patient presents with a unilateral or bilateral abduction deficit, careful assessment of the optic nerve is necessary to look for any signs of papilledema secondary to increased intracranial pressure.

13. What are the results of a forced duction test?

If a patient presents with an obvious

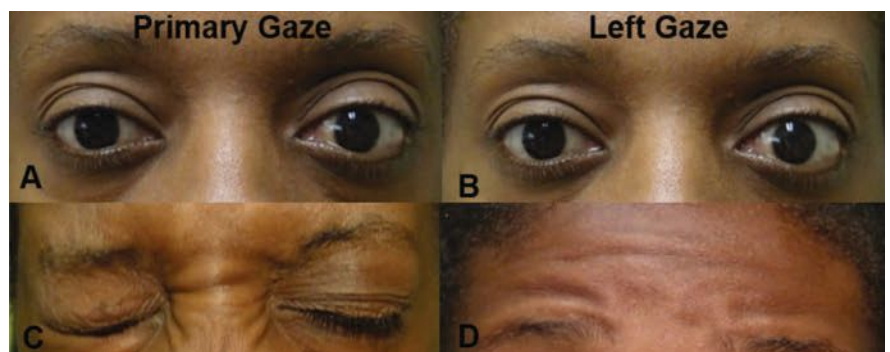

Fig. 7. In primary gaze (A), there is a noted difference in palpebral apertures due to the left lower lid lagophthalmos. In left gaze (B), there is no movement of either eye consistent with a left gaze palsy (likely at the left CN VI nucleus). There was associated left orbicularis oculi weakness (C) and left frontalis weakness (D), both consistent with a partial left CN VII lesion. The combination of these findings localizes the lesion to the left pons involving both the CN VI nucleus and CN VII fasciculus.

ductional limitation, a forced duction test could be useful in localizing the lesion. If the limitation is due to a restrictive etiology, the provider will be unable to physically move the globe. If the etiology is neurogenic, the globe should move into the desired position of gaze with physical manipulation.

14. Are there any other neurological signs (abnormal CN V, VII or VIII, extremity weakness, headache, ocular pain, ataxia, change in gait)?

To assess for additional neurological signs, it is helpful to complete a short neurological assessment. Break the examination down into five sections: mental status, CN testing, motor/reflex examination, coordination/gait and a general sensory exam.⁷

The presence of multiple CN involvement is more suggestive of a neurological etiology and can help with the localization of the lesion.

Evidence of additional CN involvement may assist in localizing the lesion (Figure 7). For example, if a patient presents with a left abduction deficit alone, it may be difficult to discern if the lesion is orbital, nerve or brain. However, the concurrent presence of a CN VII palsy would localize the lesion to the only anatomical location where the two nerves are in close proximity, which would be the ventral low pons of the brainstem.

Another localizing feature would be the concurrent presence of decreased sensation on the ipsilateral forehead or cheek, which indicates involvement of the ophthalmic or maxillary divisions of CN V. Anatomically, the location where these branches of CN V are in closest proximity to CN III, IV or VI is the cavernous sinus.

15. Are there any constitutional signs? (e.g., fatigue, weight loss, fever)

A yes to this question may indicate a systemic etiology and should prompt an urgent work-up. Any patient over the age of 50 who presents with diplopia should be evaluated for giant cell arteritis (GCA).

TABLE 1. DRUGS ASSOCIATED WITH DIPLOPIA⁸⁻¹³

Bupropion	Lorazepam
Citalopram	Lamotrigine
Felbamate	PD-1 inhibitors
Fluoxetine	Pergolide
Fluoroquinolone	Statins
Gabapentin	Topiramate
Interferon therapy	

16. Any known health problems? (e.g., vasculopathic disease, infectious disease, inflammatory disease, cancer)

The etiology of the diplopia may be secondary to an underlying systemic condition, so it is important to obtain a thorough history of known conditions, even if the patient has already been treated or is in remission. Always ask about a history of syphilis, Lyme disease, cancer, sarcoidosis and thyroid disease. For example, a patient with a prior infection of syphilis may develop neurosyphilis and present with new-onset diplopia.

A patient presenting with new-onset diplopia and a history of cancer, even if in remission, should have an urgent work-up. The presence of diplopia may be the first sign of a recurrence.

Vasculopathic diseases, such as diabetes and hypertension, are well known causes of acute-onset isolated CN palsies. Practitioners must be careful not to assume a vasculopathic etiology without first carefully assessing for other possible etiologies.

17. Is the patient on any medications known to cause diplopia?

A number of medications are associated with diplopia, though the mechanisms involved are varied and not all well understood (Table 1). There are also drugs that can exacerbate or induce MG (Table 2). A careful review of medication lists is warranted in any new-onset diplopia.

18. Where does this localize to?

The practitioner should now be able to determine if the etiology is localized in the brain, nerve, junction or orbit. The exact etiology may not

be known but a differential diagnosis can be created to help answer the questions in Step 4.

Step 4: Determine Additional Testing/Treatment

19. How urgent is this and what additional testing is warranted?

Generally, any acute-onset diplopia that shows any other abnormalities on exam (i.e., multiple CN involvement, proptosis, pain, significant systemic history) warrants urgent additional testing. The type of testing will depend on the list of differentials created. In many cases, neuroimaging and laboratory testing are necessary.

There is some debate on the necessity of neuroimaging and other additional testing in the setting of isolated CN palsies, particularly in older patients with vasculopathic risk factors. More recent studies have suggested that contrast-enhanced MRI has an important role in the initial evaluation of isolated CN palsies in patient populations of all ages.¹⁶⁻¹⁸

TABLE 2. AGENTS ASSOCIATED WITH DRUG-INDUCED MYASTHENIA GRAVIS^{14,15}

Drug Class	Specific Drugs
Anti-arrhythmic agents	Etafenone, peruvoside, procainamide
Antibiotics	Aminoglycosides, macrolides, beta-lactams
Antiepileptics	Phenytoin, carbamazepine, trimethadione
Beta-blockers	Atenolol, nadolol, oxprenolol, timolol oph
Calcium channel blockers	Amlodipine, felodipine, nifedipine
Corticosteroids	Hydrocortisone, methylprednisolone
H2 receptor antagonists	Cimetidine, ranitidine, roxatidine
Interferons	Alpha and beta
Penicillamine	
Psychotropic medications	Chlorpromazine, haloperidol, lithium
Quinolone derivatives	Quinine, quinidine, chloroquine

20. What can I do to help the patient?

The most important thing an eye care provider can do for a patient with diplopia is to rule out any underlying systemic conditions or potential lesions causing their symptoms. Using the history and exam findings will lead to a list of differentials that can help direct what the next step should be.

Before the patient leaves the office, the provider should also address their current quality of life and visual status. The provider should evaluate if the patient can achieve fusion with prismatic correction. If so, a Fresnel prism can be dispensed. Ground-in prism should not be given until the etiology is determined. If a patient does not respond to prismatic correction, an eye patch or occlusion filter should be dispensed.

Case Example

Let's apply our 20-question guide to a case of a 54-year-old Black man who presents for evaluation of diplopia.

Q1. Does the double vision go away if you cover one eye?

"Yes." He has been patching his left eye since the onset of his symptoms.

Q2. Does it matter which eye you cover?

"No." Therefore, this patient has true binocular diplopia and we will now move on to Step 2.

Q3. Is it constant or fluctuating?

"Constant." Due to the constant nature of his diplopia, we are less suspicious for myasthenia gravis or a decompensated phoria.

Q4. How are the images displaced (horizontal, vertical, diagonal)?

"The images are horizontally displaced." We are now suspicious for a lesion affecting the medial and/or lateral rectus.

Q5. Is it worse in any particular distance (near or far) or direction of gaze (left, right, up, down)?

"It is present at all distances but worse at distance and when looking left."

Since it is worse on left gaze, we can narrow down the location to a right

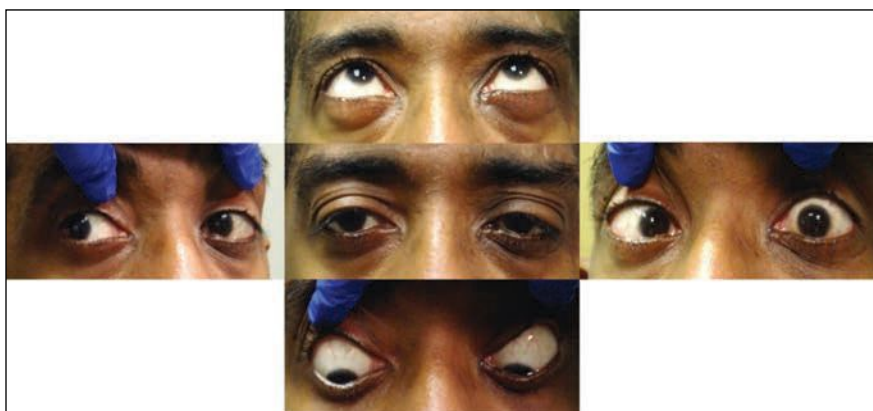

Fig. 8. Ductions revealed a left abduction limitation.

adduction deficit or left abduction deficit. Because the horizontal diplopia is worse at distance, this is more consistent with a left abduction deficit. If we consider that his diplopia is secondary to paresis, then we must consider a left CN VI palsy. If we consider enlargement of an extraocular muscle, then we must consider enlargement of the left medial rectus. An orbital mass must still be considered.

Q6. How long has it been going on for and is it stable, worsening or improving?

"This has been going on for the past three days." Since this is a case of acute-onset diplopia, we cannot differentiate it from vasculopathy or other etiologies at this point.

Q7. How did you first notice it?

"When I first woke up three days ago." There does not seem to be any precipitating factor.

Q8. Any history of childhood strabismus or prior orbital surgery?

"No." Therefore, the diplopia is less likely to be secondary to a decompensating phoria.

Q9. Do I see any ductional limitation?

Ductions were graded on "percent of normal." Upon examination, there was a -5% of abduction in the left eye only (Figure 8). All other ductions in horizontal and vertical gaze were 100% of normal in each eye. Therefore, this patient's diplopia is secondary to a left abduction deficit, as we suspected based on the answers to question 5.

Q10. Does my cover test or Maddox rod testing in different positions of gaze match the pattern of a specific cranial nerve palsy?

Cover test in different positions of gaze revealed an increasing eso deviation in left gaze, which is consistent with a CN VI palsy (Figure 9). It also revealed a left hyper deviation, worse in right head tilt. The hyper deviation did not follow the pattern of a CN IV palsy.


Although it is common to have a small hypertropia with an abducens palsy, further testing with double Maddox rod is indicated given the vertical deviation.¹⁹

	Right Gaze	Left Gaze	
47 Eso 8 LHyper	6 Eso 2 LHyper	65 Eso	14 Eso
	1 Eso	20 Eso 2 LHyper	
		20 Eso 4 LHyper	

Fig. 9. Cover test of patient is consistent with a CN VI palsy.

Q11. Is double Maddox rod testing abnormal?

Double Maddox rod testing revealed 3 excyclotorsion OD and 3 incyclotorsion OS. The hypertropic eye is intorted, which is consistent with a possible skew deviation. Given our examination findings, we must now consider etiologies for both a left CN VI palsy and a left skew deviation



SPRING AND SUMMER 2021

New Technologies & Treatments in Eye Care

MARCH 19–20 | JUNE 11–12

CALL FOR POSTER ABSTRACTS

**NEW TECHNOLOGIES & TREATMENTS IN EYE CARE VIRTUAL CONFERENCE SERIES
ANNOUNCES OUR 2021 CALL FOR POSTER ABSTRACTS**

We are currently soliciting poster abstracts for our upcoming virtual programs. Accepted abstracts will be included in both the spring, March 19–20, and summer, June 11–12 virtual conferences.

Poster submissions should contain subject matter pertinent and applicable to Optometrists actively practicing and advising patients in the field of optometry. Posters sharing studies in progress with substantive preliminary outcomes will also be considered. Topics of interest may include, but are not limited to glaucoma, dry eye, retina disease, surgical co-management, neuro-optometry, and viral eye disease.

Deadline to Submit: Monday, March 8, 2021

Notification Deadline: Wednesday, March 10, 2021

To submit your entry visit

www.ReviewEdu.com/NTT2021Posters

and attempt to localize the lesion with additional findings from our examination.

Q12. Are there any associated ocular findings (vision loss, ptosis, anisocoria, conjunctival injections, proptosis, uveitis, nystagmus, papilledema, signs of aberrant regeneration)?

Anterior segment evaluation revealed diffuse keratic precipitates in both eyes, greater and larger in the left eye. The patient reported a history of anterior uveitis in the left eye due to an unknown etiology approximately two years ago. Dilated fundus examination revealed small macular pigment epithelial detachments in both eyes. These findings suggest a possible infectious or inflammatory etiology.

Q13. What are the results of a forced duction test?

Forced duction test was negative. This further supports that it is not an orbital mass.

Q14. Are there any other neurologic signs (abnormal CN V, VII or VIII, extremity weakness, headache, ocular pain, ataxia, change in gait)?

Neurologic examination revealed partial weakness of the left frontalis, left orbicularis oculi and left zygomaticus major. There were no signs of motor, sensory or gait abnormalities. These findings were consistent with a partial CN VII palsy.

Q15. Are there any constitutional signs (fatigue, weight loss, fever)?

The patient reported losing 10-to-15lbs unintentionally over the course of the last several months. He has also been feeling very fatigued. He denied any headaches, jaw pain, scalp tenderness and fever.

Given his unexplained concurrent weight loss and fatigue, there is likely a systemic etiology contributing to his ocular presentation. Although he denied some symptoms of GCA, we must still consider it as a potential etiology based on his age.

Q16. Any known health problems (vasculopathic disease, infectious disease, inflammatory disease, cancer)?

He denied any history of vasculopathic disease, infectious disease, in-

flammatory disease and cancer but had not visited a primary care physician in the past three years. Blood pressure was normal on exam.

Q17. Is the patient on any medications known to cause diplopia?

He denied taking any such medications.

Q18. Where does this localize to?

We suspect a left CN VI palsy and a partial left CN VII palsy. The combination of the findings is suggestive of a lesion of the brainstem, specifically in left lower pons. His associated ocular and systemic findings are suggestive of an inflammatory or infectious etiology.

Q19. How urgent is this and what additional testing is warranted?

Given that his diplopia may be secondary to a lesion of the brainstem with a likely systemic inflammatory or infectious etiology, emergent work-up, including neuroimaging and neurology evaluation, is warranted. We recommend an MRI of the brain and orbits with and without contrast, with focus on the left lower pons and the pathway of CN VI up to and including the orbit.

Furthermore, our concern for inflammatory and infectious conditions necessitates serologic and/or cerebrospinal fluid testing to rule out other causes of diplopia (GCA, Lyme, syphilis, sarcoidosis and autoimmune conditions). We specifically recommend obtaining the following levels: ESR, CRP, Lyme, ANA, RPR, FTA-ABS and ACE. If this testing is inconclusive, we recommend serum testing for myasthenia gravis, including acetylcholine receptor antibody (binding, blocking, modulating).

Q20. What can I do to help the patient?

Prior to transferring his care to the emergency department, we also considered dispensing a Fresnel prism. However, the patient did not appreciate the prismatic correction and preferred to continue to patch his left eye.

After thorough investigation, we found a lesion in the pons accounting for the CN VI and VII palsies. He underwent further pathological evalua-

tion and was ultimately diagnosed with neurosarcoidosis and started on steroid treatment.

To Sum Up

After going through the 20 questions of diplopia outlined here, it is obvious that it is not always an easy task to determine the exact etiology. However, by following this guide, you can ask the necessary questions, keep your thought process logical and organized and create a differential diagnosis. This differential will guide your management of the patient and solve the case. ■

- Rizzo, M. Baron J. Chapter 13: Central disorders of visual function. In: Miller NR Newman NJ, eds. Walsh and Hoyt's clinical neuro-ophthalmology. 5th ed. Philadelphia, PA: Lippincott Williams & Wilkins; 2012.
- Goezinne F, La Heij EC, Liem AT, et al. The occurrence and treatment of diplopia after scleral buckling surgery for rhegmatogenous retinal detachment (RRD). Invest Ophthalmol Vis Sci. 2010;51(13):6067.
- Friedman DI. Pearls: diplopia. Semin Neurol. 2010;30(1):54-65.
- Iliescu DA, Timaru CM, Alexe N, et al. Management of diplopia. Rom J Ophthalmol. 2017;61(3):166-70.
- Malloy K. Neuro-ophthalmic disease basics: Focus on the efferent visual system evaluation. Rev Optom. 2015;152(2):74-83.
- Manchandia AM, Demer JL. Sensitivity of the three-step test in diagnosis of superior oblique palsy. J AAPOS. 2014;18(6):567-71.
- Maglione AK, Seidler KA. The neurological exam: step-by-step. Rev Optom. 2019;156(2):64-71.
- Lucca JM, Ramesh M, Parthasarathi G, Ram D. Lorazepam-induced diplopia. Indian J Pharmacol. 2014;46(2):228-9.
- Roper-Hall G. The influence of the vergence system on strabismus diagnosis and management. Strabismus. 2009;7(1):3-8.
- Fayyazi Bordbar MR, Jafarzadeh M. Bupropion-induced diplopia in an Iranian patient. Iran J Psychiatry Behav Sci. 2011;5(2):136-8.
- Fraunfelder FW, Fraunfelder FT. Diplopia and fluoroquinolones. Ophthalmology. 2009;116(9):1814-7.
- Rajak S, Sullivan T, Selva D. Orbital myositis: a side effect of interferon alpha 2b treatment. Ophthalmic Plast Reconstr Surg. 2015;31(1):75.
- Alves M, Miranda A, Narciso MR, Mieirol F, Fonseca T. Diplopia: a diagnostic challenge with common and rare etiologies. Am J Case Rep. 2015;16:220-3.
- Ahmed A, Simmons Z. Drugs which may exacerbate or induce myasthenia gravis: a clinician's guide. Internet J Neurol. 2008;10(2):1-8.
- Hussain N, Hussain F, Haque D, Chittivelu S. A diagnosis of late-onset myasthenia gravis unmasked by topical antibiotics. J Community Hosp Intern Med Perspect. 2018;8(4):230-2.
- Tamhankar MA, Biousse V, Ying GS, et al. Isolated third, fourth and sixth cranial nerve palsies from presumed microvascular vs. other causes: a prospective study. Ophthalmology. 2013;120(11):2264-9.
- Elder C, Hainline C, Galetta SL, et al. Isolated abducens nerve palsy: update on evaluation and diagnosis. Curr Neurol Neurosci Rep. 2016;16(8):69.
- Park KA, Oh SY, Min JH, et al. Cause of acquired onset of diplopia due to isolated third, fourth and sixth cranial nerve palsies in patients aged 20 to 50 years in Korea: a high resolution magnetic resonance imaging study. J Neurol Sci. 2019;407:116546.
- Pihlblad MS, Demer JL. Hypertropia in unilateral isolated abducens palsy. J AAPOS. 2014;18(3):235-40.



OD CLINICAL UPDATE

A Monthly Enduring Series

OVERVIEW

Brought to you by Review Education Group and MedscapeLIVE!, join our renowned experts who will deliver comprehensive, results-oriented strategies you can implement in your practice for improved patient outcomes. Released monthly, OD Clinical Update is your opportunity to stay relevant in the ever-changing landscape, while earning continuing education credits from your trusted partner in optometric education.

JANUARY 20th RELEASE

The Seven Habits of Highly Effective Anterior Uveitis Management

PRESENTER



Paul M. Karpecki, OD, FAAO
Kentucky Eye Institute
Lexington, Kentucky

FEBRUARY 20th RELEASE

**Ocular Emergencies:
Stories From an On-Call Optometrist**

PRESENTER



Jessilin Quint, OD, MBA, FAAO
Smart Eye Care
Augusta, Maine

*Earn 1 COPE credit per video, \$14.99

VIDEO RELEASES MONTHLY ON THE 20th

www.ReviewEdu.com



*Approved

*This activity, COPE Activity Number 120874, is accredited by COPE for continuing education for optometrists.

Review Education Group partners with Salus University for those ODs who are licensed in states that require university credit.

REVIEW
Education GROUP

TAKE MACULAR OCT TO A WHOLE NEW LAYER

Combine your clinical observations and knowledge with detailed imaging to put together the full picture of the diagnosis.



BY SARA WEIDMAYER, OD
ANN ARBOR, MI

Interpreting an abnormality on a macular optical coherence tomography (OCT) image can be daunting for practitioners relatively new to OCT. However, with some review and experience under your belt, you can identify what's wrong on an OCT, correlate this with the clinical exam to make more accurate diagnoses and then begin to get more comfortable managing many of these patients on your own.

Accurate diagnosing will improve with a solid understanding of normal anatomy, then recognition of various patterns of abnormality. To start differentiating various macular abnormalities seen on OCT, it helps to break it into anatomic subsets, then use these groups to create differential diagnoses based on how the scan looks.

For this article, we won't address every conceivable diagnosis. Rather, we'll focus on critically thinking about each layered zone on a macular OCT scan, review some examples of anomalies

and recognize how those abnormalities appear on OCT relative to normal structure. Doing this should enable you to form several reasonable differentials based on the areas affected and better understand what's happening and how to appropriately manage your patients.

OCT can show you some details you won't see clinically, yet it's important to consider OCT scans within the context of the entire clinical picture. Many conditions have similar pathologic features on OCT. For example, subretinal fluid (SRF) due to choroidal

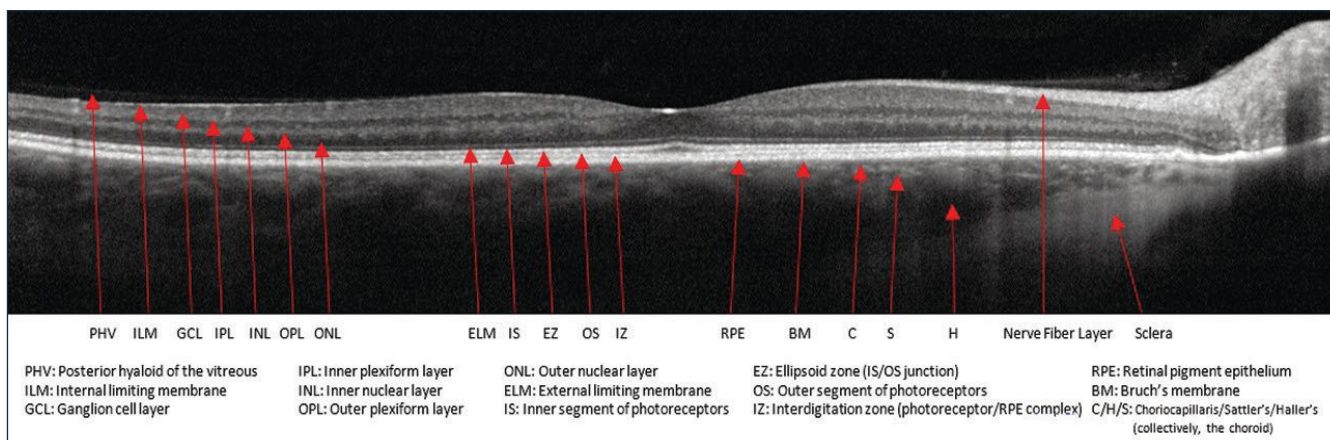


Fig. 1. Normal macular OCT with anatomic structures labeled.

About the author

Dr. Weidmayer practices at the VA Ann Arbor Healthcare System and is a clinical assistant professor in ophthalmology and visual sciences at the University of Michigan. She has no financial interests to disclose.

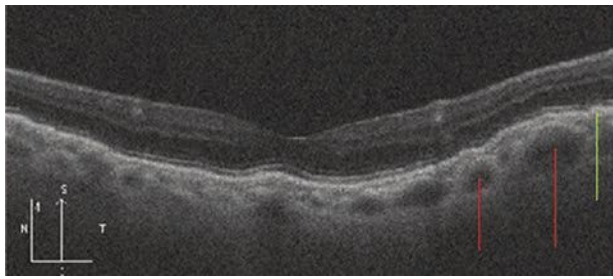


Fig. 2. Pachychoroid epitheliopathy. Note the larger choroidal vessels (red lines) causing choroidal thickening and inner-shifting of the RPE, and associated epitheliopathy (green line).

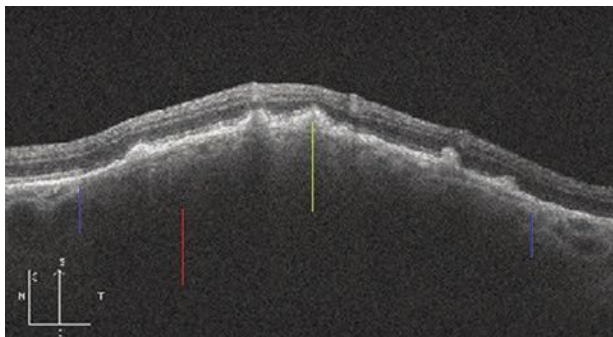


Fig. 3. Thickened choroidal nevus with posterior shadowing (red line) and overlying drusen (green line). The blue lines indicate the approximate inferior and superior margins of the nevus.

neovascularization (CNV) in exudative age-related macular degeneration (AMD) can resemble SRF due to CNV in myopic degeneration. Likewise, a serous macular detachment in central serous chorioretinopathy (CSCR) can look like a serous detachment in polypoidal choroidal vasculopathy (PCV).

An accurate diagnosis *cannot* be made simply by comparing your OCT to similar ones on the internet. The OCT is meant to augment your clinical exam, not replace it. Use it as a piece of the puzzle and analyze it by correlating it to the patient's history, clinical exam and other ancillary tests when appropriate.

Normal Structure

A normal macular OCT should look as familiar as the back of your hand; however, remembering what structure each band on the image represents is sometimes less than second nature. Having a well-labeled clinical reference nearby can be helpful, both to jog our memories and for patient education (Figure 1).

Sub-RPE/Choroid

Posterior to the retinal pigmented epithelium (RPE) is Bruch's membrane, the choriocapillaris, Haller's and Sattler's vascular layers, then the sclera.

The suprachoroidal space is a potential area between the choroid and the sclera that may become filled with fluid in certain pathologies, making it visible via OCT. Enhanced-depth imaging OCT and swept-source OCT are helpful in visualizing this zone, but even without them, a lot can be seen.

The normal choroidal thickness varies throughout the

eye and decreases with age by 16µm per decade on average.¹ The macular choroid is typically thickest under the fovea and thinnest nasally.¹ Abnormalities seen on OCT in this region broadly fit into the categories of thickening, thinning or simply irregular.

• **Thickening.** Anatomically or pathologically thickened choroids can be vascular (e.g., pachychoroid spectrum, hemangiomas), infiltrative (e.g., lymphoma, metastasis), inflammatory (e.g., sarcoidosis, effusion, Vogt-Koyanagi-Harada syndrome), infectious (e.g., tuberculosis) or tumorous/lesional (e.g., choroidal nevi, melanomas) in nature. Examples are shown in Figure 2 and Figure 3. Clinically, these generally appear as either diffuse or local-

ized areas of choroidal thickening that may look orangish, creamy or gray/pigmented, depending on etiology.

• **Thinning.** By contrast, thinning of the choroid includes cases of age-related generalized thinning, tessellated high myopia (Figure 4), choroidal dystrophy (e.g., central areolar choroidal dystrophy [CACD]) and iatrogenic causes (e.g., photodynamic therapy).² Clinical examination may show a generally lighter-appearing fundus in the areas of thinning due to a thinner vascularized layer over the white sclera.

• **Irregular.** A choroid can also be irregular without necessarily being thick or thin. A good example of this is choroidal folds (Figure 5), which can occur for several reasons. The mnemonic "THIN RPE" can be helpful in identifying the source of the choroidal folds. It stands for:

- Tumor
- Hypotony or Hyperopia
- Inflammation or Idiopathic
- Neovascularization
- Retrobulbar mass
- Papilledema
- Extraocular hardware

These appear clinically as undulations or striations of the RPE and may be associated with metamorphopsia because they can cause the overlying outer retina to ripple.

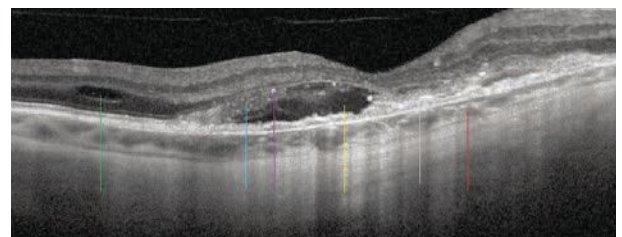


Fig 4. A highly myopic patient with a tessellated and thin choroid (red line), RPE disruption (gray line), SRF (yellow line), IRF (green line), edematous photoreceptors (blue line) with early tubulation and hyperreflective material (purple line) are all consistent with myopic CNV.

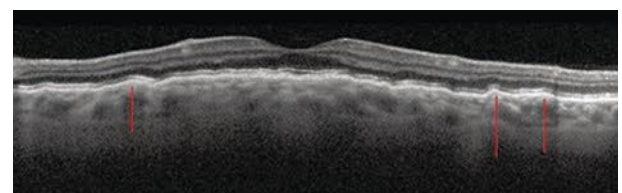
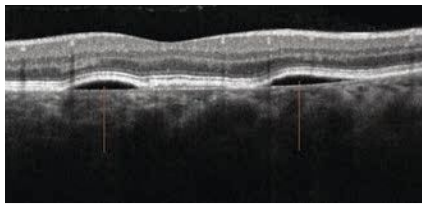


Fig. 5. Choroidal folds causing sub-RPE undulations (red lines).



Multifocal serous PEDs in the macula, where serous fluid appears dark posterior to/under the RPE (red lines).

How to Spot a PED

Pigment epithelial detachments can arise from a host of chorioretinal conditions. PEDs can be serous (which will look dark/optically empty), drusenoid (moderately reflective but generally uniform), fibrovascular (hyperreflective and heterogeneous) or hemorrhagic (where the anterior aspect is hyperreflective but the blood causes posterior shadowing, as seen in Figure 9).⁵

Here's how they are classified:

Serous PEDs. Conditions leading to increased choroidal vascular permeability (such as pachychoroid spectrum or inflammatory conditions such as Vogt-Koyanagi-Harada syndrome) lead to serous fluid accumulation under the RPE, causing serous PEDs. Note, however, that these can also be idiopathic.

Drusenoid PEDs develop due to drusen or drusenoid deposits under the RPE complex causing focal RPE elevations, such as in AMD.

Hemorrhagic PEDs occur when blood detaches the RPE complex, as can be seen in type 1 or 2 CNV due to a number of conditions (including AMD, PCV, myopia, choroidal rupture, POHS and several other conditions with the possibility of CNV/exudative complications).

Fibrovascular PEDs are more irregularly shaped detachments and are generally a result of occult CNV or of disciform scarring, a long-term complication of CNV.

Source: Zayit-Soundry S, Moroz I, Loewenstein A. Retinal pigment epithelial detachment. *Surv Ophthalmol.* 2007;52(3):227-43.

Since the choroid supports the function of the RPE and outer retina, thinning or atrophy of the choroid or choriocapillaris ultimately leads to RPE atrophy and subsequent outer retinal loss (e.g., CACD, geographic atrophy [GA]), which causes scotomas. Likewise, compression from the choroid

onto the choriocapillaris and RPE can disrupt choriocapillaris flow and stimulate RPE migration or loss, which also results in outer retinal damage (e.g., pachychoroid). Keep pathophysiology in mind when looking at structure.

RPE Complex

In and around the RPE are hotspots for pathological abnormalities seen on OCT. Extracellular debris can accumulate below the RPE (e.g., drusen) or in and anterior to it (e.g., lipofuscin). In some cases, the RPE itself can become irregular (e.g., pigment mottling/clumping). The RPE can die (e.g., atrophy), detach (e.g., pigment epithelial detachments [PED], type 1 CNV) or rip (e.g., RPE tears). It can be stimulated to change via compression (e.g., pachychoroid), and any disturbance in this area can lead to outer retinal disruption or atrophy, leaving it susceptible to the development of subretinal or intraretinal fluid (e.g., CNV, RPE insufficiency).

Various types of drusen and drusen-like deposits can develop, which can be seen in myriad conditions ranging from normal aging to dystrophies and degenerations. Some of the presentations more frequently encountered in general practice include:

- Hard drusen (Figure 6), which are well defined and uniform sub-RPE deposits.
- Cuticular drusen. These are generally numerous, very small (25µm to 75µm) and dot-like with a sawtooth outline on OCT due to their prolate or spindle shape.
- Soft drusen (Figures 7a, 7b), which are larger mounds (>125µm) with internal hyporeflectivity and are less well-circumscribed than hard drusen.
- Reticular pseudodrusen, which are structures that form between the RPE and the ellipsoid zone (EZ).³

Levels of RPE lipofuscin in excess of age-related normals (as in Stargardt's or vitelliform macular dystrophies [Figure 8] or Best disease) are associated with cellular dysfunction and ultimately RPE and retinal atrophy causing typically gradual bilateral vision loss.⁴ (See "Determining Macular Dystrophies on

OCT.") Lipofuscin accumulations are seen in and anterior to the RPE and appear orangish or yellow clinically.

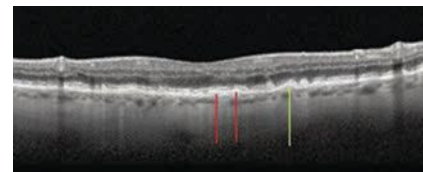


Fig. 6. Hard drusen (green line) with mild RPE mottling (red lines).

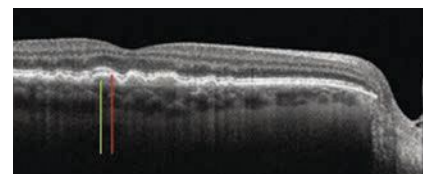


Fig. 7a. Soft drusen (green line) with drusenoid PEDs (red line).

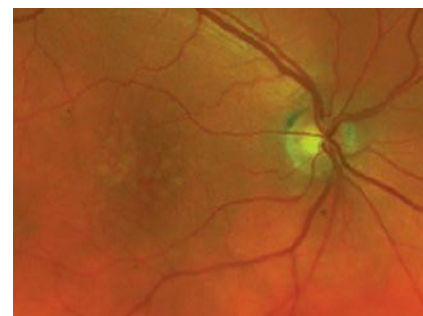


Fig. 7b. Clinical photo of the large soft drusen seen in Figure 7a.

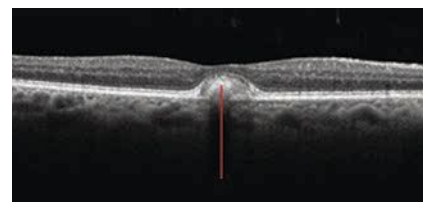

Fig. 8. Lipofuscin accumulation (red line) within and anterior to the RPE, here in adult-onset vitelliform macular dystrophy.

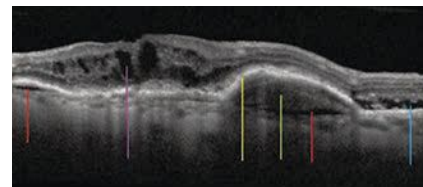


Fig. 9. Exudative macular degeneration demonstrating sub-RPE fluid (red lines), sub-RPE hemorrhage (green line) with exudative PED (yellow line), SRF (blue line) and intraretinal fluid (purple line).

Subretinal

We hate to see anything in the subretinal space. Anything separating the photoreceptors and outer retina from its critically important supporting RPE can ultimately lead to photoreceptor loss and, therefore, vision loss.

Frequently encountered actors in the subretinal space in primary eye care practice are subretinal fluid (SRF) (*e.g.*, central serous retinopathy), subretinal hemorrhage (SRH) (*e.g.*, type 2 CNV) and subretinal fibrosis (*e.g.*, disciform scarring), as seen in *Figure 9*. On OCT, SRF in this space appears dark or optically empty, whereas SRH is more reflective or opaque due to its composition. Fibrotic scarring, likewise, is more opaque with highly reflective and usually nodular fibrosis (*Figure 10*).

Clinically, SRF appears translucent, SRH is generally a deep red and subretinal fibrosis looks off-white. Early SRF may cause metamorphopsia, while subretinal fibrosis is associated with scotoma.

Outer Retina

The outer retinal layers are obviously critical for sight, and disruption here generally involves atrophy of some kind. Geographic atrophy (*e.g.*, AMD, CACD), macular telangiectasia type 2, retinal dystrophies (*e.g.*, rod/cone dystrophies [*Figure 11*]) and toxic maculopathy (*e.g.*, hydroxychloroquine toxicity) are frequently seen and ultimately demonstrate outer retinal layer loss.

In evaluating outer retinal loss, consider the integrity of the layers surrounding the outer retina. For example, if the RPE complex is normal while the EZ is disrupted, it likely indicates a photoreceptor issue rather than a chorioretinal atrophic issue.

Intraretinal

In the middle retinal layers, abnormalities come from a variety of sources with a range of presentations.

Macular edema, showing intraretinal cystic spaces, may occur related to several issues: diabetes (DME)

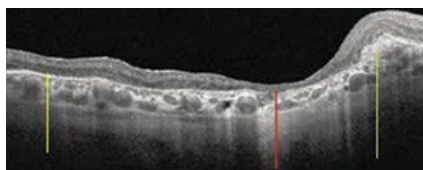


Fig. 10. A patient with previous exudative macular degeneration, now with subretinal fibrosis (green line) and atrophy. Areas where atrophy becomes very apparent are outer retinal atrophy (yellow line) and RPE/outer retinal/intraretinal atrophy (red line).

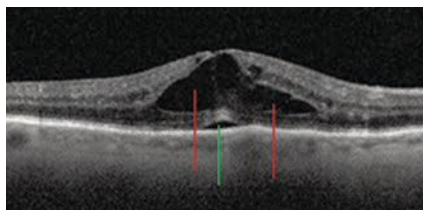


Fig. 12. Cystic intraretinal spaces (red lines) and a focal subfoveal neurosensory retinal detachment (green line) in Irvine-Gass/post-op CME.

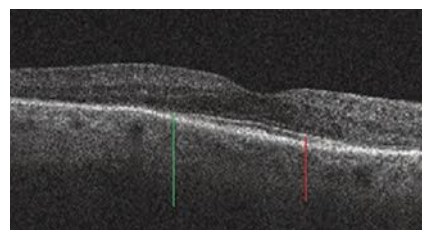


Fig. 11. In this rod-cone dystrophy, the outer retina (specifically ONL) has collapsed where the ellipsoid zone (red line) ends (green line).

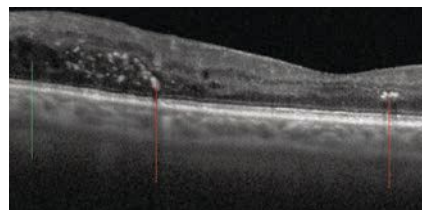


Fig. 13. Hyperreflective foci (red lines) within the retina corresponding to exudates in a patient with diabetic retinopathy and non-central macular edema/IRF (green line).

Determining Macular Dystrophies on OCT

Several macular dystrophies may present on OCT with features that are similar to one another and to more common maculopathies like macular degeneration. Here's what differentiates them:

Malattia Leventinese (also called Doyme's honeycomb dystrophy or familial dominant drusen) presents with radial drusenoid deposits throughout the macula and around the disc. These sub-RPE deposits appear similar to typical drusen, but in the macula they tend to be more elongated in shape.

Fundus flavimaculatus, a variant of Stargardt macular dystrophy, shows pisciform lipofuscin accumulation at the level of the RPE.

Best vitelliform macular dystrophy (BVMD or Best dystrophy) in younger patients or **adult-onset foveomacular vitelliform dystrophy** (AFVM or vitelliform) in older patients shows subfoveal lipofuscin accumulation, which over time evolves with various RPE changes and atrophy, ultimately with outer retinal atrophy as well.

Other pattern dystrophies primarily demonstrate a variety of RPE mottling or atrophy, occasionally with lipofuscin deposits, and outer retinal loss over time.

Central areolar choroidal dystrophy (CACD) initially shows RPE changes and eventual atrophic ovaloid patches that ultimately coalesce into a GA-like picture.

Rod-cone dystrophies ultimately show outer retinal thinning with ellipsoid zone loss due to photoreceptor atrophy and loss of the RPE-photoreceptor interdigitation zone.

or other vascular abnormalities or occlusions (*e.g.*, CME associated with hypertension or retinal vein occlusions), inflammatory conditions (*e.g.*, Irvine-Gass syndrome/postoperative CME [*Figure 12*], uveitis) or tractional causes (*e.g.*, epiretinal membranes or association with neovascular/proliferative traction). Macular edema can sometimes be difficult to see clinically

but appears as translucent cystic retinal thickening, which correlates to the serous intraretinal cysts seen on OCT.

Intraretinal deposits appear as very hyperreflective foci. Exudates (*e.g.*, diabetic retinopathy [*Figure 13*]) generally are in or around the inner plexiform layer, whereas deposits can be seen in all layers with various crystalline retinopathies.⁶

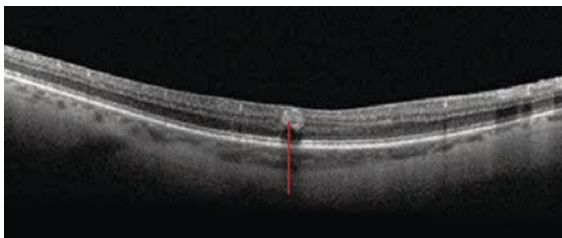

Fig. 14. An intraretinal hemorrhage (red line) seen in a patient with diabetic retinopathy.

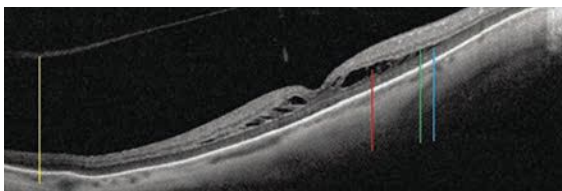


Fig. 15. Foveoschisis cavity (red line) separating the outer plexiform (green line) and outer nuclear (blue line) layers in this myopic patient, who also has a generally thin choroid. The posterior hyaloid of the vitreous (yellow line) is detached.

Microaneurysms (MAs) or intraretinal hemorrhages (IRH) are also often seen in this space. MAs appear round or oval, are well demarcated because of their capsular structure, are often associated with adjacent cystic spaces and occur predominantly in the inner nuclear layer.⁷ IRHs are more nebulous in shape than MAs, but the blood makes them appear dense (*Figure 14*).⁷ On clinical examination, MAs appear as focal red spots whereas IRHs are often described as red dot-or-blot hemorrhages.

Foveoschisis, often associated with

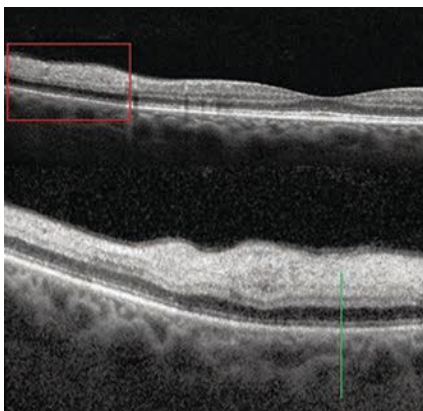


Fig. 16a. A broad (upper) and more magnified (lower) scan of NFL edema (green line) in an acute branch retinal artery occlusion.

myopia, shows broader areas of intraretinal separation that can involve several retinal layers, but is most often seen separating the inner plexiform and outer nuclear layers (*Figure 15*).⁵

Inner Retina

Abnormalities of the inner retina also generally fit into categories of thickening (*e.g.*, cotton-wool spots, edema) (*Figures 16a, 16b*), thinning (*e.g.*, atrophy after retinal artery occlusions or ischemic optic neuropathy). Hemorrhages may also be visible (*e.g.*, flame-shaped hemes in the nerve fiber layer).

Epiretinal/Vitreomacular/Vitreous Space

This area is frequently noted to have vitreomacular adhesion or traction and epiretinal membranes, all associated with the development of macular holes (*Figure 17*). Other epiretinal abnormalities can also involve traction, such as preretinal vascular membranes or fibrosis (*e.g.*, proliferative diabetic retinopathy). Any variety of traction on the macula can lead to intraretinal cysts or CME, schisis or SRF.⁵

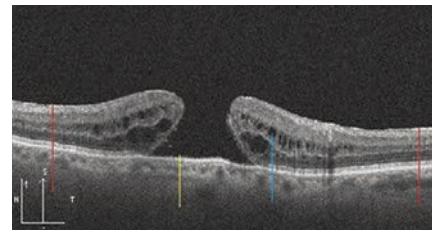


Fig. 17. A full-thickness macular hole (yellow line) with adjacent intraretinal cystic spaces (blue line) in a patient with epiretinal membrane (red lines).

The vitreous generally looks dark and optically empty on OCT but can have reflective foci if debris is present (*e.g.*, asteroid hyalosis, inflammatory/white, red or pigmented cells).

Putting the Pieces Together

In summary, when encountering an abnormal macular OCT, first consider which sections of the retina or adjacent structures are affected, then consider what the clinical exam looked like and, finally, put it together in the context of the patient's history and any other ancillary information you have available.

Thinking critically about these things should allow you to deduce an accurate diagnosis—or at least get you headed in the right direction. When in doubt, it's entirely appropriate to solicit the help of colleagues, but be sure to produce your own analysis first. ■

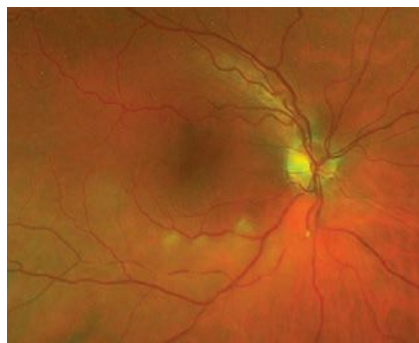



Fig. 16b. Clinical photo of a branch retinal artery occlusion with an intra-arterial embolus inferior to the disc, segmentation of blood flow downstream and cotton-wool spots in the posterior inferior-temporal arcade.

- Margolis R, Spaide RF. A pilot study of enhanced depth imaging optical coherence tomography of the choroid in normal eyes. *Am J Ophthalmol.* 2009;147(5):811-5.
- Zhou Y, Song M, Zhou M, et al. Choroidal and retinal thickness of highly myopic eyes with early stage of myopic chorioretinopathy: Tessellation. *J Ophthalmol.* 2018;2181602.
- Khan KN, Mahroo OA, Khan RS, et al. Differentiating drusen: Drusen and drusen-like appearances associated with ageing, age-related macular degeneration, inherited eye disease and other pathological processes. *Review Prog Retin Eye Res.* 2016;53:70-106.
- Sparrow JR, Boulton M. RPE lipofuscin and its role in retinal pathobiology. *Exp Eye Res.* 2005;80(5):595-606.
- Bhende M, Shetty S, Parthasarathy MK, Ramya S. Optical coherence tomography: A guide to interpretation of common macular diseases. *Indian J Ophthalmol.* 2018;66(1):20-35.
- Nag A, Chauhan G, Lim Ji. Crystalline retinopathy. *EyeWiki.* October 1, 2020. https://eyewiki.aao.org/Crystalline_retinopathy. Accessed October 18, 2020.
- Horii T, Murakami T, Nishijima K, et al. Optical coherence tomographic characteristics of microaneurysms in diabetic retinopathy. *Am J Ophthalmol.* 2010;150(6):840-8.



SPRING AND SUMMER 2021

New Technologies & Treatments in Eye Care

MARCH 19–20 | JUNE 11–12

 **VIRTUAL EVENT**

PROGRAM CHAIR



Paul M. Karpecki, OD, FAAO
Kentucky Eye Institute
Lexington, KY

*Earn up to 24 LIVE COPE Credits

For up-to-date information

www.ReviewEdu.com/NTT2021



*Approval pending

Review Education Group partners with Salus University for those ODs who are licensed in states that require university credit.



NAVIGATING THE RETINAL PERIPHERY

Here's a step-by-step look at many common conditions and features of this region, as described by an expert in the field.

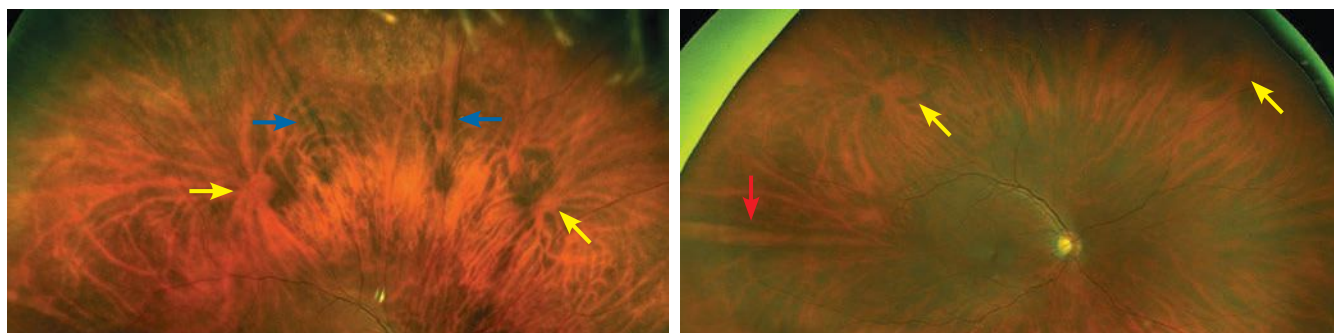


Fig. 1. Vortex ampullae (yellow arrows), long posterior ciliary nerves (red) and short posterior ciliary nerves (blue) are common findings.

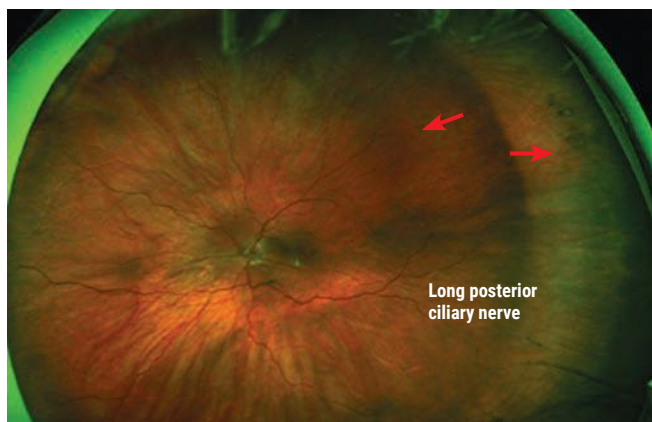


Fig. 2. The red arrows delineate a normal variation of RPE distribution from the retinal periphery toward the posterior retina. This variation can result in suspicions of retinal detachment or retinoschisis.



BY MOHAMMAD RAFIEETARY, OD
GERMANTOWN, TN

There are a number of clinical conditions associated with the peripheral retina, including primary lesions such as pars plana cysts. Some are degenerative, with potential vision-threatening consequences. Others are associated with systemic disease and may better correlate with the patients' presenting signs and symptoms.

Dilated fundus examination remains the standard of care for detection and evaluation of these findings. However, advances in imaging technologies, such as widefield and ultra-widefield photography and optical coherence tomography (OCT), have given us new, valuable tools in the differential diagnosis and management of not only central, but also peripheral, retinal pathology.

About the author

Dr. Rafieetary is a consultative optometric physician at the Charles Retina Institute in Germantown, TN. He is on advisory boards for Heidelberg Engineering, Optos, Regeneron, Notal Vision and Cardinal Health.

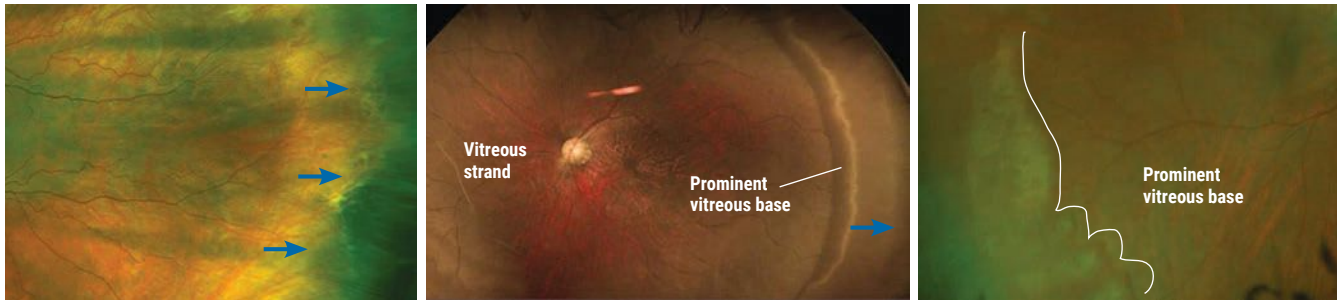


Fig. 3. Pigmented oral bays at the ora serrata are marked by the blue arrows. A smooth, scallop-shaped vitreous base can be seen. The structural shapes of the vitreous attachment to the peripheral retina may explain any arcs of light (flashes) caused by vitreous traction and horseshoe-shaped retinal tears (HSRT).

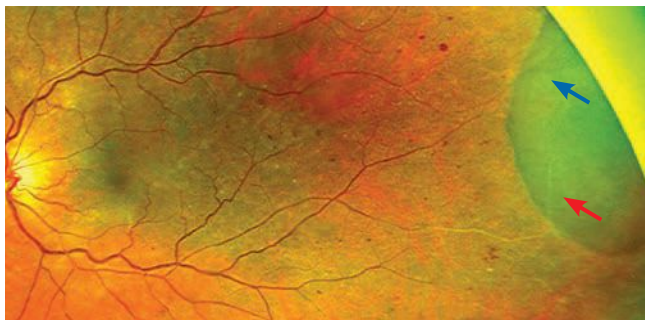


Fig. 4. A pars plana cyst may be detected in the more common temporal location of the retina as a coincidental finding during examination of a patient with diabetic retinopathy. This lesion can be differentiated from retinoschisis and RRD by following the retinal vasculature positioned under the cyst (blue arrow), instead of inward deflection seen in RRD or retinoschisis. In this case, some of the vasculature is occluded due to diabetes (red).

This review discusses various lesions, their morphology and their long-term prognosis and includes a pictorial review of those that I've seen throughout my years of experience with this particular area of expertise.

Explore the Landscape

There are certain anatomical features we need to first familiarize ourselves with as we extend the fundus examination from the posterior pole to the peripheral retina. The **vortex ampullae** located in the equatorial retina are one of them (Figure 1). Vortex veins have a variety of shapes and sizes.

The region anterior to the equator is the peripheral retina. Distribution differences in the retinal pigment epithelium (RPE) between the peripheral and central retina can result in unusual appearances and cause diagnostic dilemmas (Figure 2).

Other important anatomical landmarks include the **ora serrata**, the serrated region between the retina and ciliary body (Figure 3). Ora serrations, or oral bays, have varying degrees of pigmentation, shapes and sizes, often resulting in diagnostic challenges.

The **vitreous base**, a band of vitreous attachment extending 2mm anterior and 1mm to 3mm posterior to the ora,

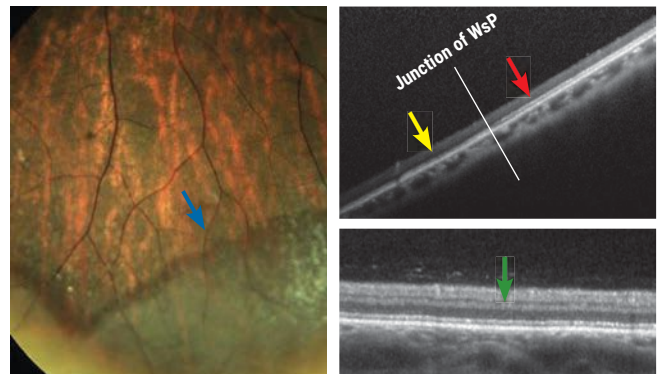


Fig. 5. WsP can be seen clinically (blue arrow). Observe the increased reflectance of the ellipsoid zone in the area where WsP is occurring (red) as opposed to the area free of WsP (yellow). A comparison can be made with the peripheral OCT of a patient without WsP where the ellipsoid zone appears as a uniformed line (green).

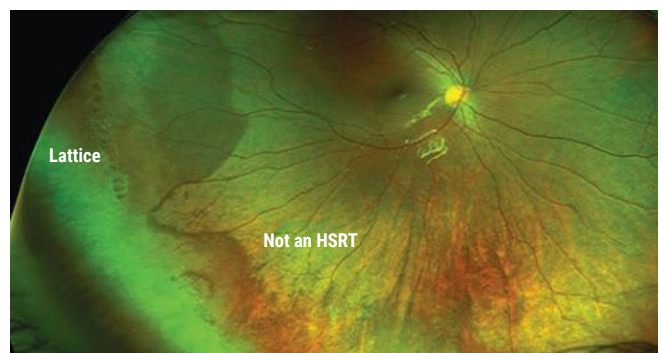


Fig. 6. This patient was referred for HSRT and retinal detachment or retinoschisis. These masqueraders are caused by white and dark without pressure. Finding other concomitant peripheral retinal degenerative lesions is common, particularly in myopic patients.

is more prominent and visible depending on the retinal sector and patient (Figure 3).

Another common normal retinal finding is the spear-shaped **long and short posterior ciliary nerves** (Figure 1). The long nerves are more prominent and are usually located in sectors three and nine. The short ciliary nerves can be seen at times in the sectors between three and nine.

Pars plana cysts are clear, bullous balloon-like structures

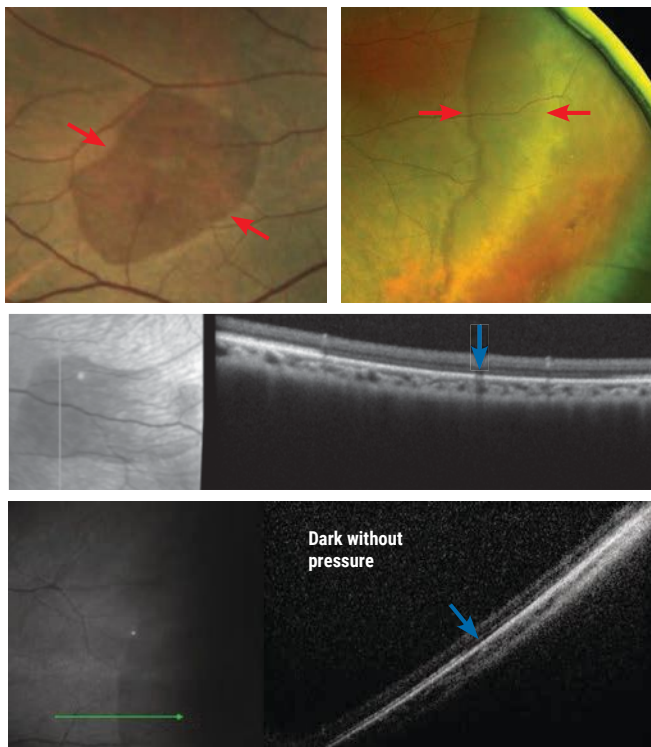


Fig. 7. Dark without pressure can be seen clinically (red arrows). On OCT, a loss of reflectance is noted in these areas but, once again, no vitreoretinal anomalies are observed (blue).

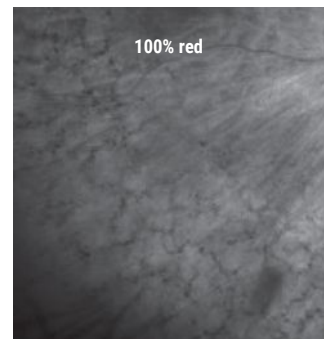
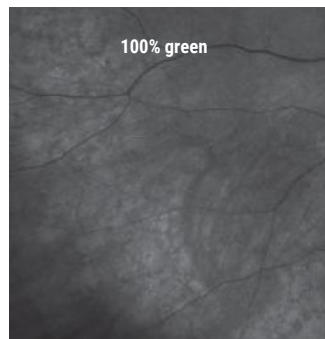
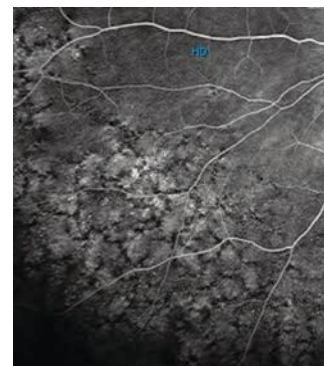
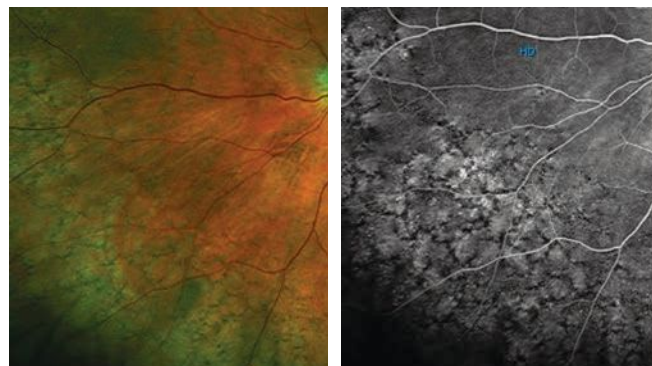
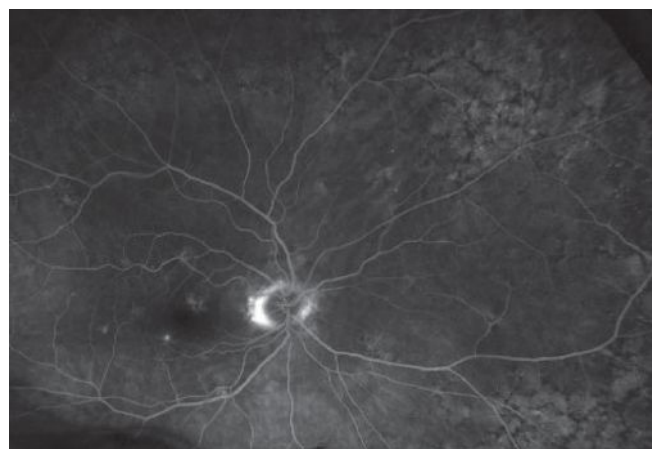
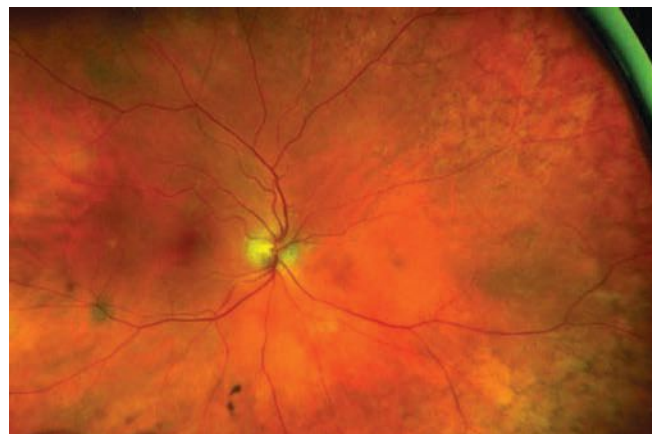
Fig. 9. The patient in the top two images has peripheral reticular degeneration (PRD). The net-like, hyperpigmented structures are more visible with fluorescein angiography. The patient in the next two images has PRD and peripheral drusen, both common concurrent findings. The green-free image of the bottom patient enhances the appearance of lesions at the RPE level, such as PRD.

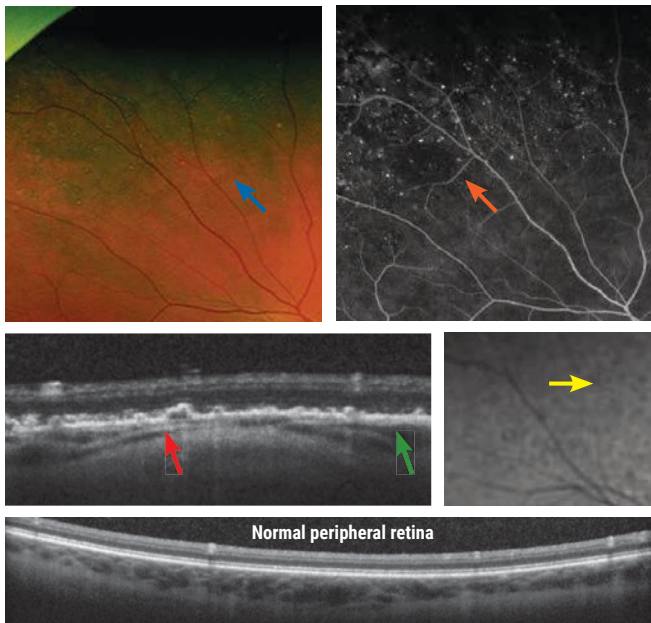


Fig. 8. Clinically, peripheral drusen have the same appearance as other structures, including the macula and retinal drusen. These glistening, yellowish lesions are marked by the blue arrow. On fluorescein angiography, drusen exhibit a slight glow and become more visible (orange). On fundus autofluorescence, drusen block emission of the fluorescent light, causing hypoautofluorescence (yellow). On OCT, drusen are seen as hyperreflective deposits of various sizes (green) and drusenoid pigment epithelial detachments (red).



Transforming the Medical Conference Experience for a Virtual World

Struggling to Transition From LIVE to Virtual Without Sacrificing the Attendee Experience?

Just like in the physical world, a spectacular digital conference takes months to plan and produce. The complexities of technology platforms and new formats can paralyze decision-making and stretch resources.

Partner with MedscapeLIVE!, the global leader in live and online medical learning, to effectively pivot your 2021 programming.

- Full-Service Event Management
- Broadcast Quality Production
- Immersive Virtual Platform
- Attendee, Sponsor, and Faculty Engagement

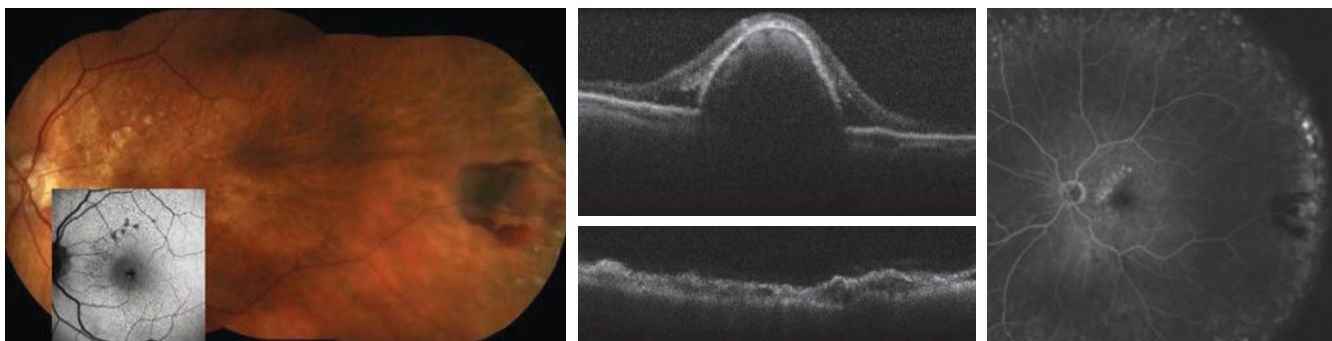


Fig. 10. The top patient has AMD in addition to peripheral drusen and a fibrovascular pigment epithelial detachment (CNVM) with a secondary subretinal hemorrhage. The bottom patient has a large subretinal hemorrhage secondary to a peripheral choroidal neovascular membrane. Hemorrhages should improve following intravitreal anti-VEGF therapy.

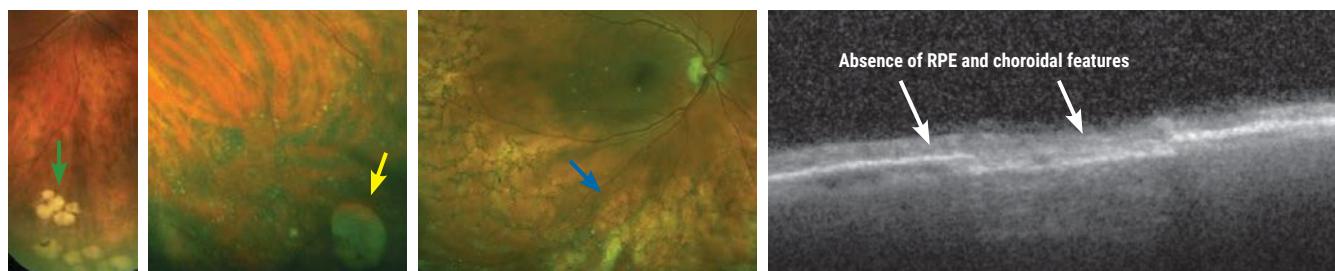
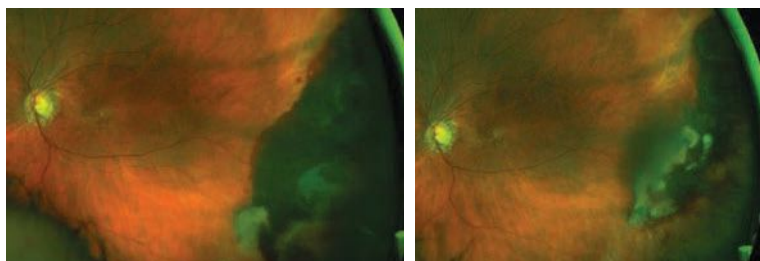


Fig. 11. The morphological features of pavingstone, or cobblestone, degeneration are similar to geographic atrophy. These progressive lesions may demonstrate anything from mild RPE atrophy (blue arrow) to further loss of the RPE that offers a better view of the underlying choroid (yellow) to advanced chorioretinal atrophy (green). Pavingstone degeneration is also an outer-retinal atrophy with no imposed risk of RRD and is often seen in patients with concurrent peripheral drusen and PRD.

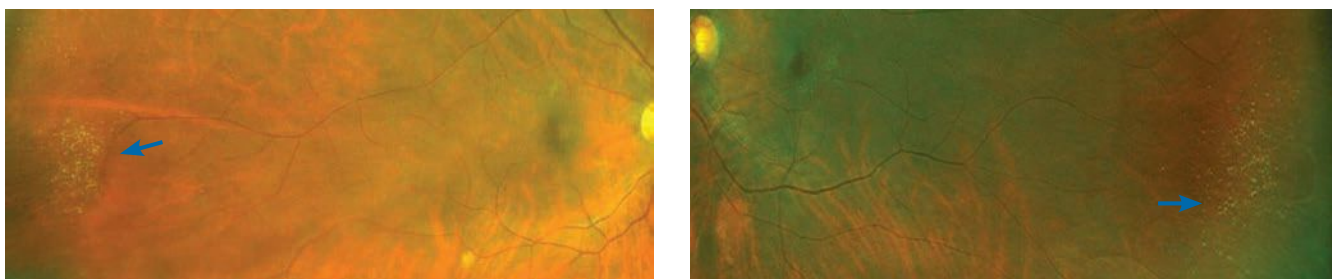


Fig. 12. Microcystoid degeneration is noted by the blue arrow.

that extend from the non-pigmented ciliary epithelium of the pars plana to the peripheral retina under the vitreous cortex (Figure 4). They more commonly appear in the temporal periphery and affect 5% to 10% of the global population.¹ Due to their location and the clear fluid (hyaluronic acid) they are usually filled with, they can go undetected.

These benign lesions can resemble small rhegmatogenous retinal detachments (RRD) or retinoschisis, but, as a distinction, the retinal vessels under the lesion are visible on close examination. The fluid content of these cystic structures can appear cloudy in the presence of abnormal serum protein, such as in patients with multiple myeloma.

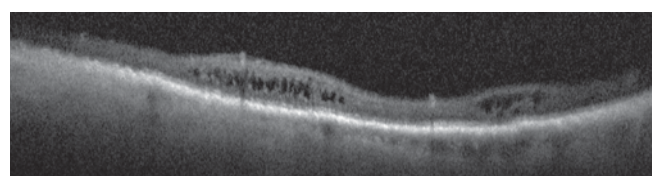


Fig. 13. Microcystoid degeneration presents clinically (blue arrow) and is accompanied by small cystic splitting of the intra-retinal layers on OCT.

White and dark without pressure are also common peripheral retinal findings. White without pressure (WwP) geographic areas appear as “retinal whitening” without scleral depression and are usually located in the equatorial

and peripheral retina.² Traditional thinking attributes the etiology of this condition to the vitreoretinal interface. However, this line of thought was disputed by examination with spectral-domain OCT, which shows thickening and increased hyperreflectivity of the ellipsoid zone, formally known as the IS-OS line (*Figure 5*).³

WsP is usually a coincidental, inconsequential finding, but it can result in diagnostic dilemmas in the differentiation of retinal breaks, RRD and retinoschisis (*Figure 6*). Also, as WsP is more prevalent in high myopia, these patients have a higher incidence of other peripheral retinal degenerative disease and RRD.

Dark without pressure regions, on the other hand, appear as darker areas compared with the surrounding retina. These usually do not increase the risk of RRD but are often seen in eyes that also have WsP and other peripheral retina degenerative findings. OCT imaging of dark without pressure shows findings opposite those of WsP; the ellipsoid zone appears less reflective than the adjacent area (*Figure 7*).

Peripheral drusen and peripheral reticular degeneration (PRD) are common and often underreported peripheral retinal findings that can be seen in patients with or without macular degeneration. Although these are both related to age, they are two distinct conditions with two different phenotypes and should be treated as such. As they are

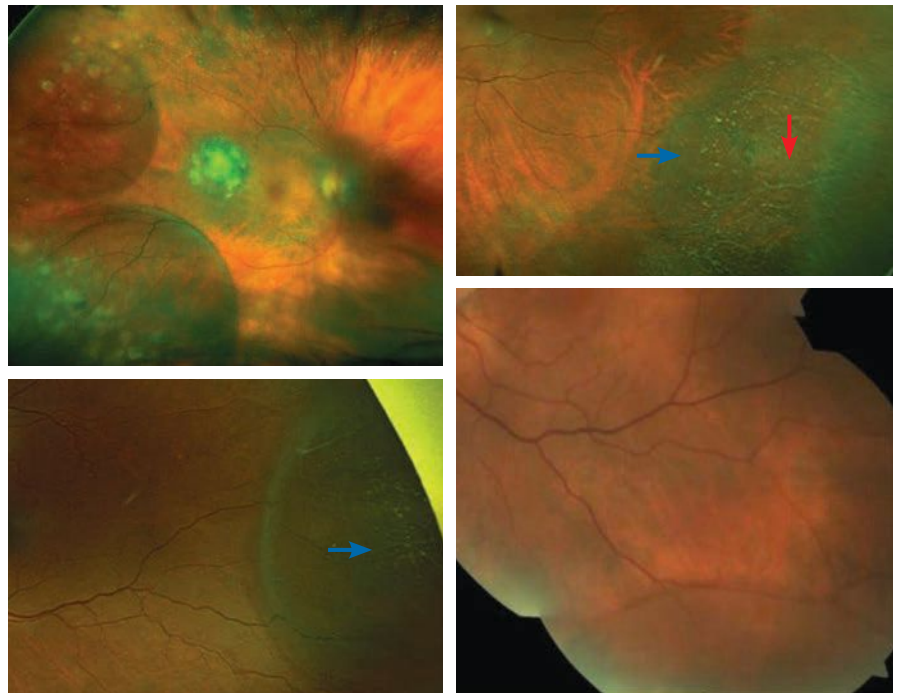


Fig. 14. Various presentations of acquired retinoschisis can be seen here. Top left is a bilobed bullous retinoschisis, with concurrent pavingstone degeneration and peripheral drusen. The lesion near the macula is an old CNVM. Gunn's dots are marked by the blue arrows. Retinal vascular changes, such as occluded vessels (red) and retinal hemorrhages, are associated with retinoschisis. Note the absence of any demarcation lines at the posterior edge of these lesions.

alterations of the outer retina, they do not pose a risk for RRD. However, the phenotypic (clinical, OCT and angiographic) findings of peripheral degeneration are similar to those of macular drusen (*Figure 8*). Reticular pigmentation appears as a net-like pigmented structure that may look similar to the pigmentary abnormalities associated with macular degeneration (*Figure 9*).

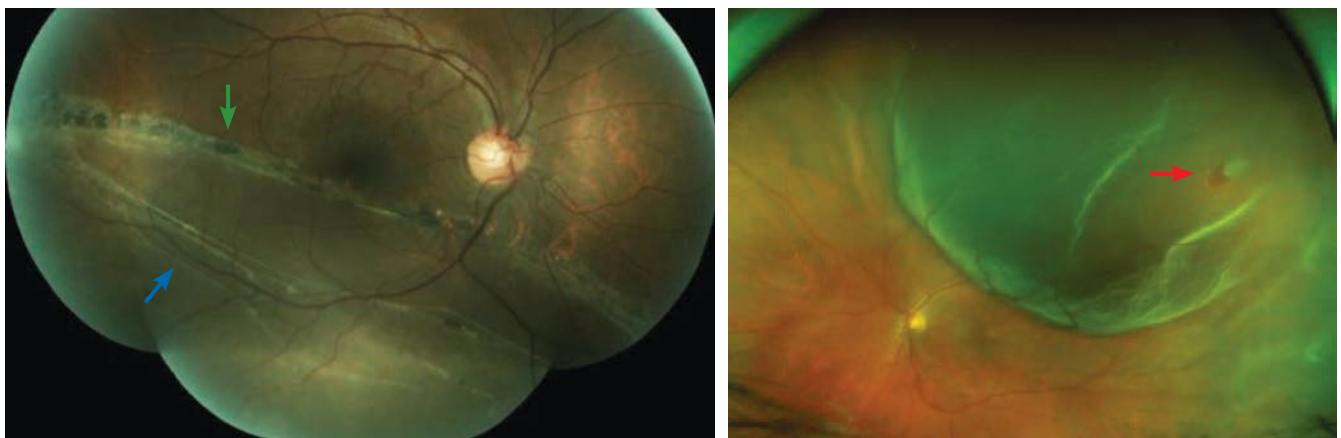
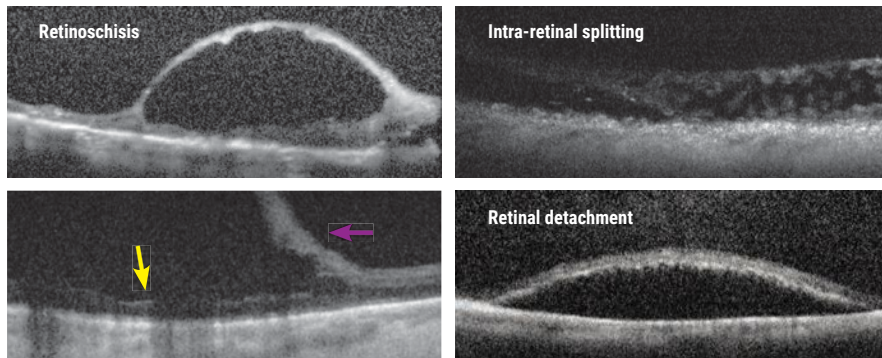


Fig. 15. The patient on the left has no significant symptoms but is suffering from chronic retinal detachment that resulted in subretinal inflammatory bands (blue arrow) associated with proliferative vitreoretinopathy as well as a pigmented demarcation line (green). Demarcation lines form at the border of the attached and detached retina. Subretinal fluid can break through, advancing the RRD. To the right is a patient with acute symptoms of flashes, floaters and peripheral loss of vision caused by a PVD-induced retinal tear (red) that resulted in an acute retinal detachment.

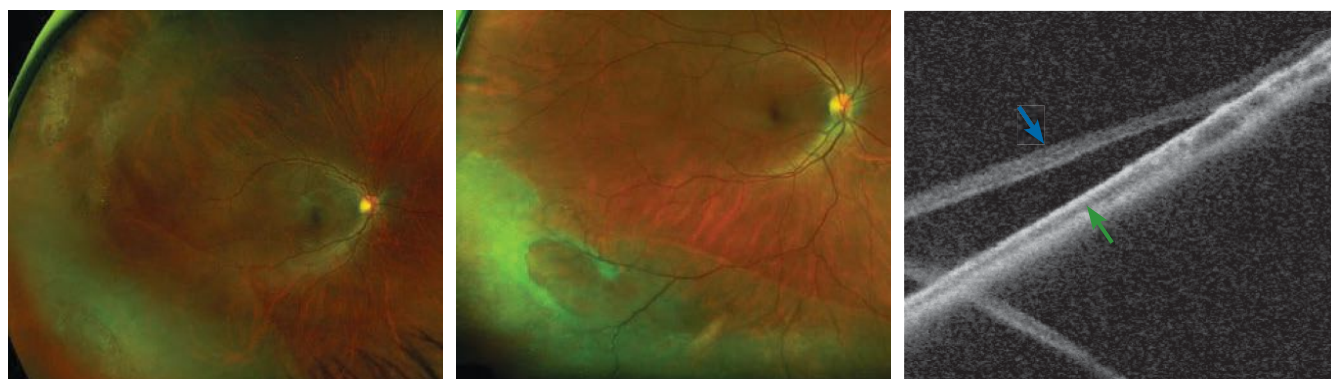

Fig. 16. To differentiate rhegmatogenous retinal detachment (top left) from retinoschisis (top middle), OCT shows the complete separation of the neurosensory retina (blue arrow) from the RPE (green) in a patient with a detached retina. By contrast, in retinoschisis the outer segment is contiguous with the RPE (yellow), while the inner segment is lifted into the vitreous cavity (purple). On the middle right scan within the schisis cavity, you can see intraretinal splitting.



There are also genotypic associations between peripheral degeneration findings and age-related macular degeneration (AMD).⁴ Additionally, peripheral drusen have also been considered a potential marker for Alzheimer's dementia (AD). Peripheral drusen and degeneration should not be used as diagnostic indicators for AD or AMD but should encourage practitioners to more thoroughly monitor patients with these two peripheral retinal degenerative conditions.⁵

Choroidal ischemia has also been associated with PRD.⁶ Peripheral choroidal neovascular membranes (CNVMs) can appear in cases of peripheral drusen as coincidental findings or in patients with associated symptoms caused by preretinal hemorrhage, vitreous hemorrhage or both (Figure 10). Peripheral CNVMs can be effectively treated with anti-VEGF injections in the same fashion as macular CNVMs, though they are often monitored without need for treatment. Patients with associated vitreous hemorrhage may require pars plana vitrectomy.

Pavingstone (or cobblestone) degeneration is another

outer-retinal and chorioretinal degeneration that does not impose a risk for rhegmatogenous retinal detachment. Pavingstone degeneration may share similar findings with geographic atrophy (Figure 11). These lesions, as well as PRD and peripheral drusen, are associated with choroidal vascular and possibly carotid artery insufficiency.⁶ This is not to suggest that every patient with these findings requires a carotid artery disease (CAD) workup; however, if

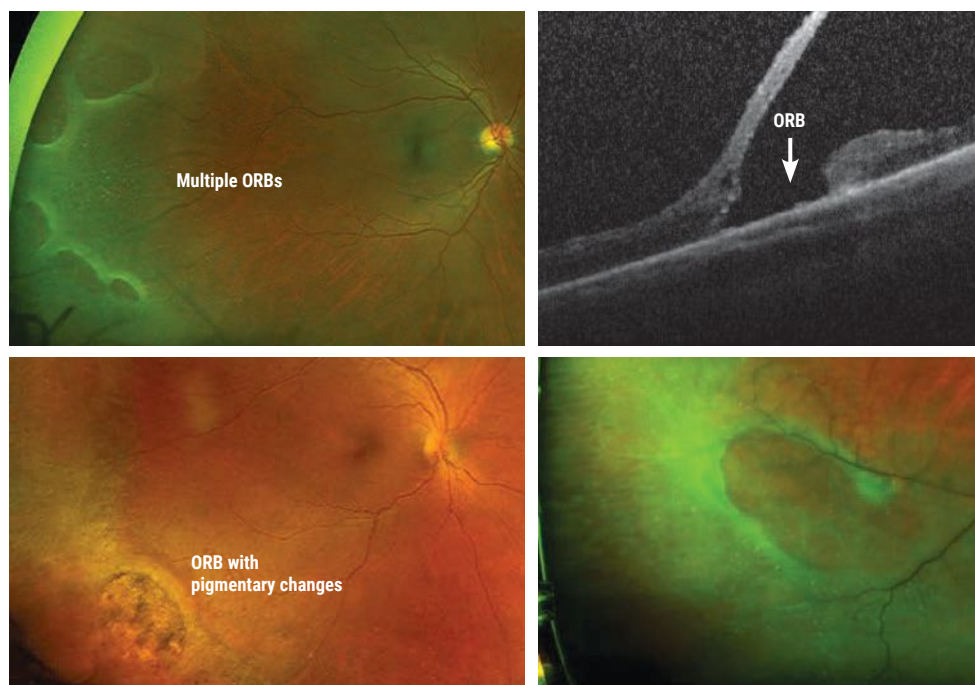


Fig. 17. There are many different variations of ORBs associated with retinoschisis.

See the retina from a **Safe Distance.**

- 200° single-capture
- Multi-mode
- Easy to clean

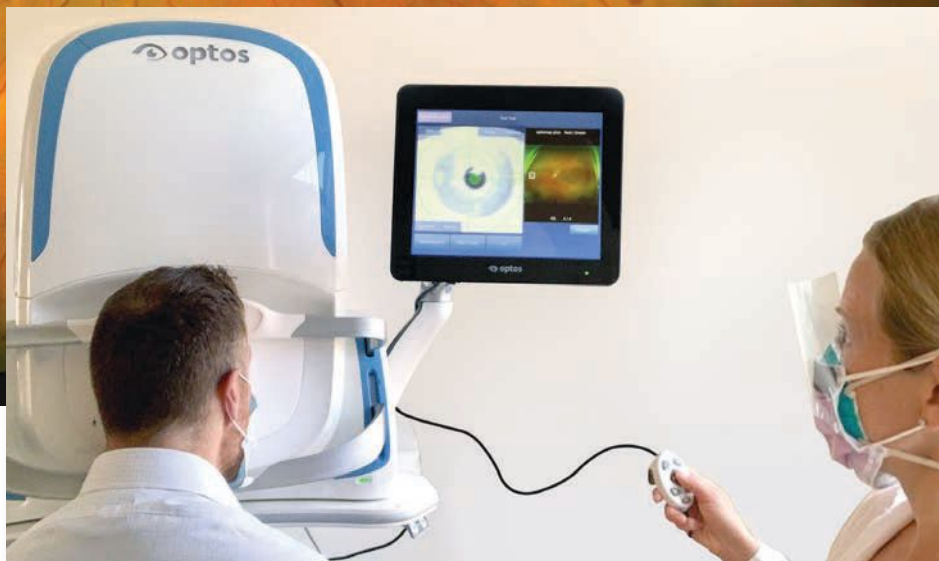Optos helps you see and document the retina with no face-to-face interaction.

optomap® single capture UWF imaging has been shown to increase practice flow and patient engagement.

Keep your staff and patients safer with optomap

Contact us today to put the power, efficiency and safety of **optomap** in your practice

800-854-3039 www.optos.com



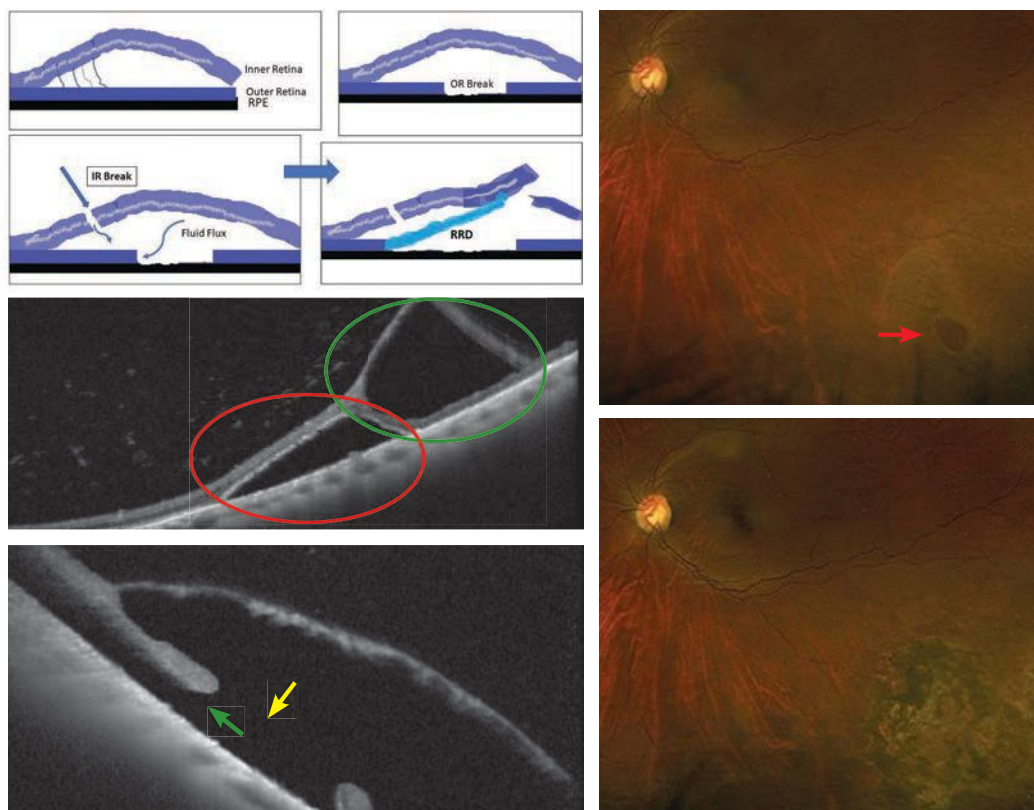


Fig. 18. During the progression of retinoschisis to retinal detachment, when both outer- (yellow arrow) and inner-retinal (red) breaks are present within the same schisis cavity, increased fluid caused by the inner-retinal break can build up around the ORB, causing a retinal detachment (green). The RRD can initially occur inside the schisis cavity; however, it will eventually exceed the area. In this case, the RRD (red circle) and schisis (green) can be seen on OCT. Since this case involved a localized retinal detachment, it was successfully treated with photocoagulation (bottom right).

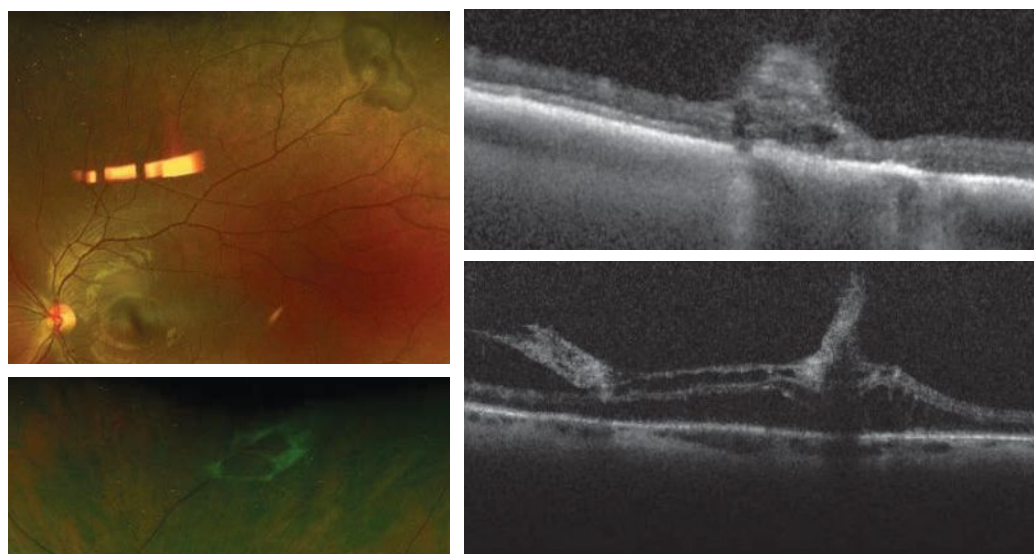


Fig. 19. Pictured here are both non-cystic and cystic vitreoretinal tufts.

other comorbidities are present, such as smoking and lipid disorder, evaluation for carotid artery disease may be warranted. Choroidal thinning is also an associated feature of AMD and myopic macular degeneration.⁷

Peripheral microcystoid degeneration is the most common intra-retinal degeneration.^{8,9} Clinically, microcystoid degeneration presents as small, yellowish bubble-like aggregates in the retinal periphery (Figure 12). On OCT, it appears as small cystic spaces involving the inner nuclear and outer plexiform layers (Figure 13). In itself, microcystoid degeneration is a benign condition; however, it is often a precursor to peripheral acquired retinoschisis.⁸

Peripheral acquired or age-related retinoschisis is a splitting in the neurosensory retina. This idiopathic and often progressive condition can result in bullous or balloon-like areas in the temporal or inferotemporal retinal periphery (Figure 14). On clinical examination, these lesions can have a wide range of widths and heights. They usually have small glistening or refractile deposits known as Gunn's dots, which are seen in the inner area of the schisis cavity (Figure 14).

Differentiating retinoschisis from RRD can be a challenging task.¹⁰ Shallow retinoschisis can resemble a chronic RRD. Distinguishing factors between the two include the absence of a demarcation line that is associated with

RRD, as well as the absence of a full-thickness retinal hole or break. Bullous retinoschisis can appear as acute RRD. A patient's symptomatology and the presence or absence of retinal breaks helps aid in telling the two apart (Figure 15).

Patients with RRD often are or eventually become symptomatic; whereas, in most cases, retinoschisis is a coincidental finding. OCT can assist in differentiating between the two (Figure 16). Slit lamp assessment may also be a helpful option, as the tool can determine whether the patient is able to see the light. Patients with retinoschisis will also have an absolute scotoma in the affected area, obstructing their vision.

The relative risk that retinoschisis poses increases as certain degenerative changes occur. Atrophic changes over time can result in loss of the outer retina in at least one location. These areas are called outer-retinal breaks (ORBs) within the schisis cavity and may have various appearances, including altered pigmentation and round or oval red or orange holes (Figure 17). As long as the inner layers of the schisis remain intact, the fluid flux between the vitreous side and RPE remains normal with no increased risk of RRD. However, if a hole or tear develops on the inner-side of the schisis in the presence of ORBs, the patient will become more prone to RRD (Figure 18).

Peripheral vitreous tufts are caused by congenital abnormality of the vitreoretinal interface.¹¹ Tufts can have cystic and non-cystic features (Figure 19). Vitreoretinal tufts have a low risk of leading to RRD. A vitreous tuft with a higher tensile strength than the retina at the site of its attachment may cause a retinal tear during posterior vitreous detachment (PVD) and serve as a precursor to RD (Figure 20).^{11,12}

Lattice degeneration is a common peripheral retinal (or vitreo-retinal) degeneration that results in abnormal thinning of peripheral retina. There are various clinical appearances of lattice; some have white lines, referred to as snail track, and some are pigmented. Partial- and full-thickness retinal holes and breaks are often found within and/or adjacent to the patches of lattice (Figure 21). Full-thickness retinal holes can predispose the patient to the development of slowly progressing

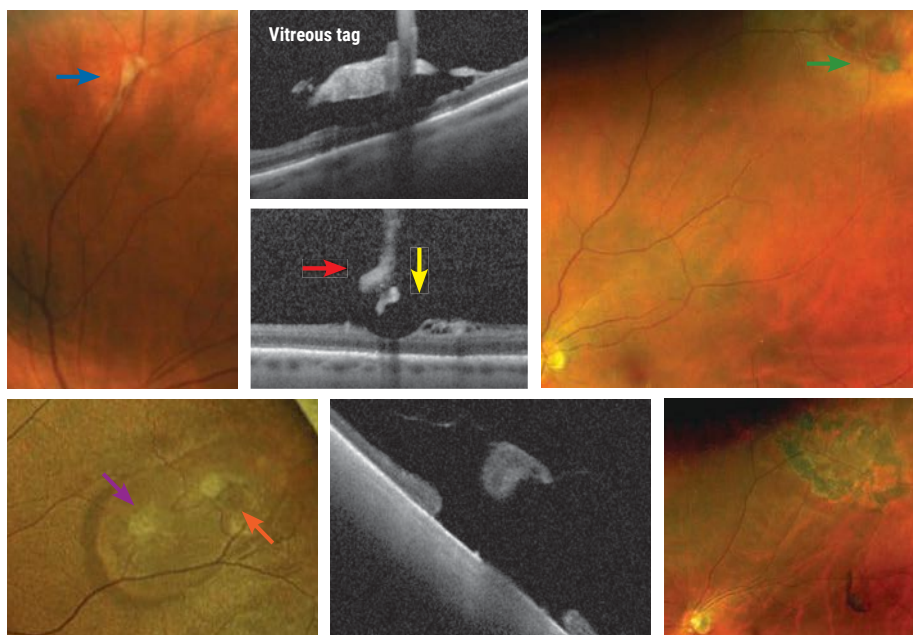


Fig. 20. Partial separation of the tuft (blue arrow) may result in a partial-thickness retinal hole (yellow) and associated operculum (red). A partial-thickness hole is not a risk factor for RRD; however, a full-thickness hole is (green). This was treated with laser. The bottom left image shows two adjacent tufts that caused retinal traction. One (purple) is still attached to the retinal surface, while the more anterior one (orange) has become a retinal hole with an attached flap. A full-thickness retinal break (bottom middle) was treated with laser (bottom right).

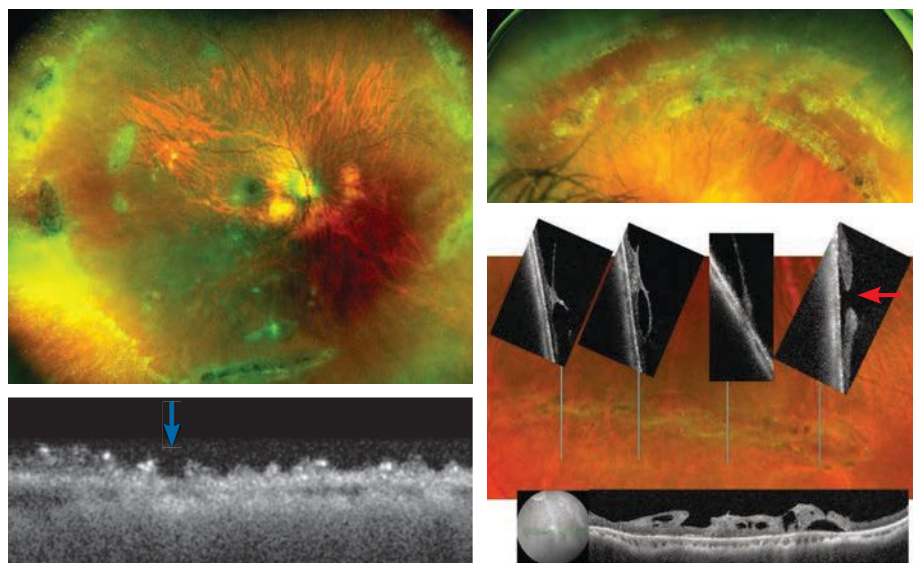


Fig. 21. Snail track and pigmented lattice degeneration can be seen here. OCT imaging shows degenerative retinal thinning. The sawtooth depressions (blue arrow) are partial-thickness holes within the lattice and can be monitored clinically. OCT dissection of a patch of lattice shows several features associated with lattice. Abnormalities of vitreous attachment and overlying liquefied vitreous, vitreoretinal tufts and partial- and full-thickness retinal holes are commonly associated with lattice. A full-thickness retinal hole (red) can increase a patient's risk of retinal detachment; therefore, prophylactic laser is beneficial.

RRD (Figure 22). Prophylactic laser around full-thickness atrophic holes can reduce this threat (Figure 23). During the process of PVD, areas affected by lattice degeneration are more easily torn, leading to acute RRD, which requires surgical intervention (Figure 24).¹³

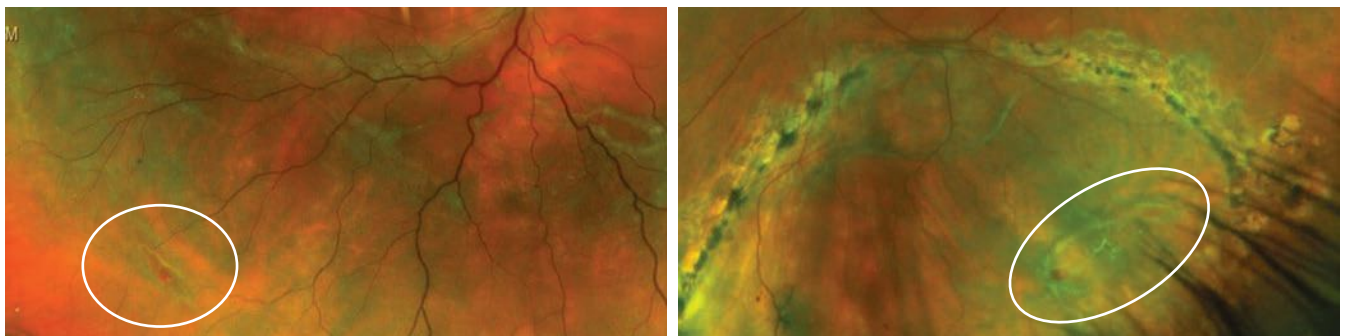


Fig. 22. Atrophic holes associated with lattice have resulted in chronic inferior retinal detachment in these two patients (white circles). Proliferative vitreoretinopathy (PVR) in the left case and PVR and the pigmented demarcation line in the right are a testament to the chronicity of the RRD.

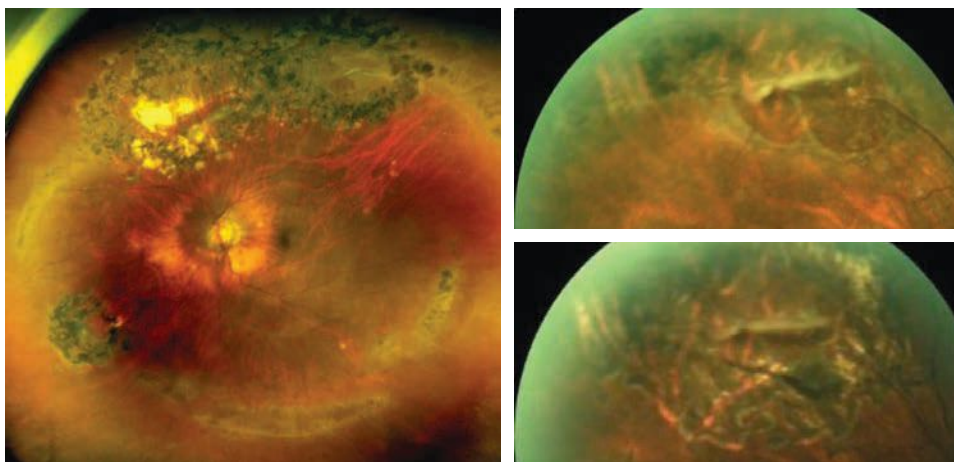


Fig. 23. Polyphasic laser of atrophic holes or retinal tears can significantly reduce the chance of retinal detachment.

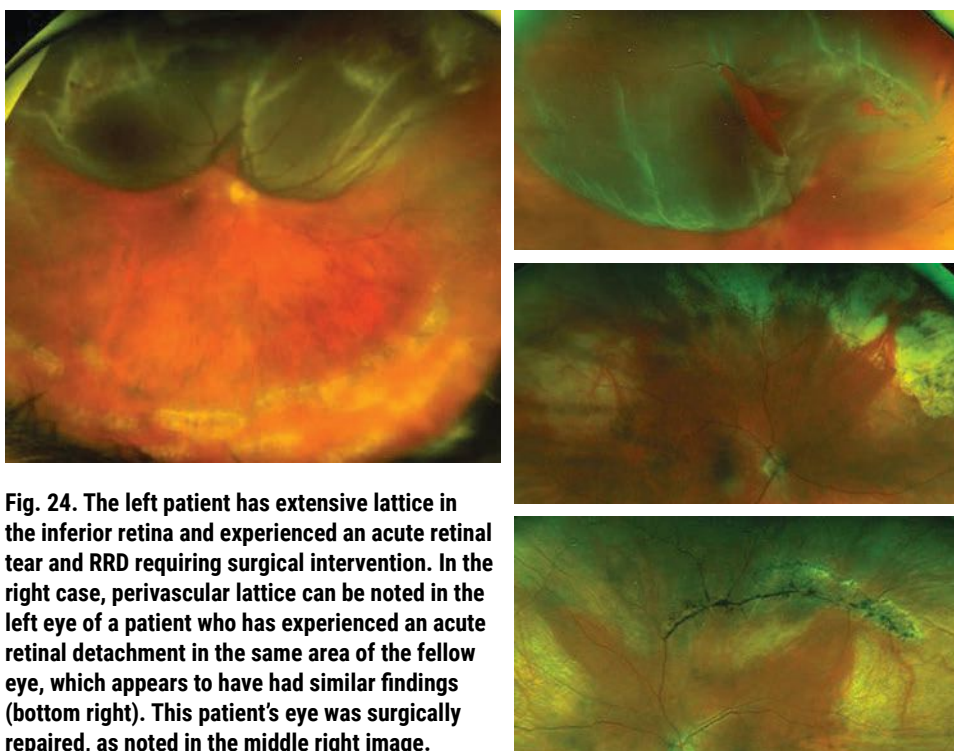



Fig. 24. The left patient has extensive lattice in the inferior retina and experienced an acute retinal tear and RRD requiring surgical intervention. In the right case, perivascular lattice can be noted in the left eye of a patient who has experienced an acute retinal detachment in the same area of the fellow eye, which appears to have had similar findings (bottom right). This patient's eye was surgically repaired, as noted in the middle right image.

Conclusion

Peripheral retinal degenerative conditions are common, and often seen concomitantly. Predisposing factors include age and myopic refractive error; however, these may also occur as coincidental findings. Since vision-threatening sequelae serve as potential side effects, dilated fundus examination and ancillary imaging are crucial to determine the need for prevention, treatment and proper follow-up. ■

1. Bracerros KK, Choi D, Gallemore R. Case report on giant pars plana cysts mimicking retinal detachment. *Int Med Case Rep J.* 2020;13:191-4.
2. Wilkinson C, Hinton D, Ryan S, eds. *Retina.* Philadelphia: Elsevier, 2006.
3. Diaz RI, Sigler EJ, Randolph JC, et al. Spectral domain optical coherence tomography characteristics of white-without-pressure. *Retina.* 2014;34(5):1020-1.
4. Seddon JM, Reynolds R, Rosner B. Peripheral retinal drusen and reticular pigment: association with CFHY402H and CFHrs1410996 genotype in family and twin studies. *Invest Ophthalmol Vis Sci.* 2009;50(2):586-91.
5. Ritchie CW, Peto T, Barzegar-Befroei N, et al. Peripheral retinal drusen as a potential surrogate maker for Alzheimer's dementia: a pilot study using ultra-wide angle imaging. *Invest Ophthalmol Vis Sci.* 2011;52:6683.
6. Bae K, Cho K, Kang SW, et al. Peripheral reticular pigmentary degeneration and choroidal vascular insufficiency, studied by ultra wide-field fluorescein angiography. *PLoS One.* 2017;12(1):e0170526.
7. Sigler EJ, Randolph JC. Comparison of macular choroidal thickness among patients older than age 65 with atrophic age-related macular degeneration and normals. *Invest Ophthalmol Vis Sci.* 2013;54:6307-13.
8. Hines JL, Jones WL. Peripheral microcystoid retinal degeneration and retinoschisis. *J Am Optom Assoc.* 1982;53(7):541-5.
9. Chhablani J, Bagdi AB. Peripheral retinal degenerations. *American Academy of Ophthalmology.* eyewiki.aao.org/Peripheral_Retinal_Degenerations. Updated October 1, 2020. Accessed January 19, 2021.
10. Rafeetary M, Huddleston S, Attar R. Rhegmatogenous retinal detachment: how to detect, how to manage. *Rev Optom.* 2017;154(9):78-84.
11. Rafeetary M, Huddleston S. A field guide to retina holes and tears. *Rev Optom.* 2019;156(6):52-7.
12. Chu RL, Pannullo NA, Adam CR, et al. Morphology of peripheral vitreoretinal interface abnormalities imaged with spectral domain optical coherence tomography. *J Ophthalmol.* June 9, 2019. [Epub ahead of print].
13. Kim TI. Lattice degeneration. *American Academy of Ophthalmology.* eyewiki.aao.org/Lattice_Degeneration. Updated December 18, 2020. Accessed January 19, 2021.

FOUNDATION FIGHTING
BLINDNESS *presents*



HOPE *from*
HOME

A UNITED NIGHT
TO SAVE SIGHT

Sunday, February 28, 2021

7 pm ET | 6 pm CT | 5 pm MT | 4 pm PT

Celebrating Rare Disease Day

Join the Foundation Fighting Blindness in kicking off our 50th anniversary year with a virtual gala hosted by Saturday Night Live alum Kevin Nealon and featuring musical entertainment by Charlie Kramer and Lachi!



Experience incredible entertainment and interactive rooms while supporting the mission of the Foundation Fighting Blindness – all from the comfort of your own home.

give.FightingBlindness.org/HopeFromHome

For more information, please contact
866-732-7330 or events@FightingBlindness.org.

Thank you to our National Partner: Genentech, A Member of the Roche Group

**FOUNDATION FIGHTING
BLINDNESS**
Together, we're winning.

Earn 2 CE Credits
(COPE APPROVED)

THE ROLE OF EYELIDS IN HEALTH AND DISEASE

Understanding how the lids can fail is critical to ensuring optimal patient care.



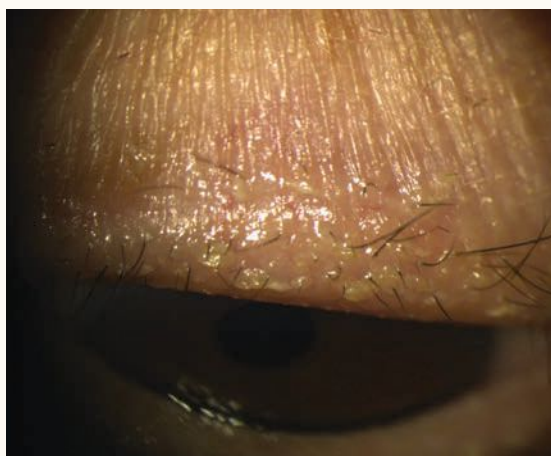
BY VICTORIA ROAN, OD
BELLEVUE, WA

Ocular surface health and functioning eyelids go hand-in-hand. However, the ways the eyelids can fail to protect the eye are often overlooked. As a result, it can be a challenge to understand why treatments that would otherwise work provide no relief to patients. There are a variety of lid conditions that can affect a patient's eye health, such as dry eye disease (DED), ptosis, meibomian gland dysfunction (MGD)/blepharitis and lid lesions, to name a few. To provide effective care, clinicians must understand the pathophysiology of these diseases and their potential impact.

This article highlights these common conditions, while taking a closer look at how compromises to the eyelids can have a cascading effect on the ocular system.

The Anatomy of the Eyelid

The eyelid is responsible for the proper lubrication of the ocular surface via 3,000 to 15,000 blinks per day. And



Stubborn debris and scurf along the base of lashes. The patient was started on a regimen of warm compresses and 0.01% hypochlorous acid lid cleaning routine BID OU.

yet, it is easy to overlook this adnexal structure that is both protective and supportive of ocular health. Before we can discuss the conditions of the eyelid, it is important to review their anatomy and function to better understand how these structures relate to potential vulnerabilities.

The lid is easily organized into the anterior and posterior lamellae, separated by the orbital septum, which also serves as a protective barrier from

infection and inflammation, as in discussions of orbital vs. preseptal cellulitis.

Anterior lamellae. During a comprehensive eye exam, optometrists may briefly scan the structures and function of the anterior lamellae, which is made up of the skin and subcutaneous layers, lid margin and orbicularis oculi muscle. Specifically, we are checking for lash base cleanliness, meibomian gland function, puncta patency and palpebral aperture width.

The most anterior aspect of the lid includes the cilia, flanked by both the sebaceous Zeis glands as well as Moll sweat glands. Adjacent to the nasal canthus, we can observe the superior and inferior puncta, which are positioned inward and staggered so as not to meet each other when the lids are closed. Next are the structures of the eyelid margin, which include the muscle of Riolan, which presents

About the author

Dr. Roan is a residency-trained optometrist at Pacific Cataract & Laser Institute in Bellevue, WA. She graduated from the University of Missouri–St. Louis College of Optometry and completed her residency at the Jonathan M. Wainwright Veterans Affairs Medical Center. She has no financial interests to disclose.

during slit lamp exam as a narrow band of gray between the lash base and meibomian gland orifices and is an extension of the orbicularis oculi muscle.

The orbicularis itself is separated into orbital and palpebral parts, both innervated by the facial nerve (CN VII). The orbital section is comprised of voluntary muscle fibers responsible for forced lid closures. The palpebral section consists of both voluntary and involuntary innervation and is responsible for the blink reflex. The latter houses Horner's muscle, which constricts the medial aspect of the lids to direct tears to the puncta for drainage.

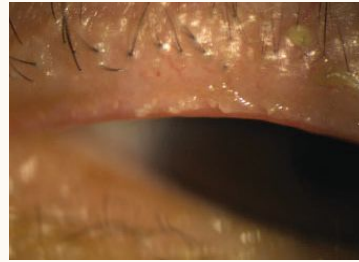
Posterior lamellae. As we move posteriorly past the orbital septum, the levator palpebral superioris muscle is innervated by CN III. Along with Whitnall's ligament, the lid moves in a vertical up-and-down motion with each blink, rather than a horizontal movement of anterior to posterior.

The tarsus of the upper and lower lids is made up of dense connective tissue, which houses the meibomian glands responsible for the oil layer of the tear film. The upper tarsus contains more meibomian glands than the lower tarsus. Another contributor to lid opening is the sympathetically innervated Müller's muscle, which originates from the levator superioris near the Whitnall's ligament and attaches

to the superior aspect of the upper tarsus. This muscle is affected and leads to ptosis in Horner's syndrome.

Lastly, the most posterior aspect of the lid is the palpebral conjunctiva, which we easily observe with lid eversion. The conjunctiva extends from the palpebral aspect to the fornix and transitions to the bulbar conjunctiva. It is home to the goblet cells, which are dispersed in their highest concentration in the fornices, inferior nasal bulbar conjunctiva and the line of Marx on the lid margin, where the act of blinking spreads the tear film across the ocular surface.

Vasculature. Several branching blood vessels supply the eyelid, stemming from both the external and internal carotid arteries. For the purposes of this article, we will focus on the superior and inferior palpebral arteries arising from the ophthalmic artery that originates from the internal carotid. These vessels begin medially and travel horizontally 2mm to 3mm about the lid margins, creating the superior and inferior marginal arterial arches. Along the superior eyelid, the marginal arcade then expands to supply the



A 68-year-old female presents with symptoms of foreign body sensation and itchiness. SLE found clogged meibomian glands with mild marginal telangiectasia.

superior peripheral arterial arcade via vertical vessels to cover the overall surface area of lid structures. This network sits superficially over Müller's muscle, where it is easily susceptible to trauma and noticeable vascularization. Treatments such as intense pulsed light (IPL) can target both the vasculature and meibomian glands when managing DED.

Ocular Surface Disease Factors

Now, let's talk about the ways lid dysfunction can manifest, as well as the impact it has on the eye and the symptoms that present as a result.

Our examination of the eyelid should include a complete history of the presentation, which is crucial for determining proper diagnosis, effect on ocular surface health and treatment plans. Compromise in one or more aspects of tear film production, distribution and retention provided by the eyelids might result in disruption of the delicate homeostasis of the ocular surface.

Meibomian gland dysfunction and blepharitis. These conditions do not always occur concurrently, but where there's one, there's likely

Release Date: February 15, 2021

Expiration Date: February 15, 2024

Estimated Time to Complete Activity: 2 hours

Jointly provided by Postgraduate Institute for Medicine (PIM) and Review Education Group

Educational Objectives: After completing this activity, the participant should be better able to:

- Review the anatomy of the eyelids.
- Recognize the impact eyelids have on the ocular system.
- Discuss the role eyelid complications play in dry eye.
- Describe the pathophysiology of common eyelid conditions.

Target Audience: This activity is intended for optometrists engaged in primary care of the anterior segment of the eye.

Accreditation Statement: In support of improving patient care, this activity has been planned and implemented by the Postgraduate Institute



for Medicine and Review Education Group. Postgraduate Institute for Medicine is jointly accredited by the Accreditation Council for Continuing Medical Education, the Accreditation Council for Pharmacy Education, and the American Nurses Credentialing Center, to provide continuing education for the healthcare team. Postgraduate Institute for Medicine is accredited by COPE to provide continuing education to optometrists.

Faculty/Editorial Board: Victoria Roan, OD

Credit Statement: This course is COPE approved for 2 hours of CE credit. Course ID is 71047-AS. Check with your local state licensing board to see if this counts toward your CE requirement for relicensure.

Disclosure Statements: *Author:* Dr. Roan has nothing to disclose.

Managers and Editorial Staff: The PIM planners and managers have nothing to disclose. The Review Education Group planners, managers and editorial staff have nothing to disclose.

mild presentation of the other. Both, however, present with slowly worsening symptoms over time. Blepharitis and MGD are extremely common contributors to evaporative dry eye. In recent years, increasing innovation and attention to eyelid hygiene have been expended to combat these problems. The goal for the provider is to diagnose and treat the condition early—before the patient becomes symptomatic.

Lash base debris, erythema, telangiectasia and permanent lid margin deformations are often detected with slit lamp examination when the patient presents with complaints of irritation, burning or itching of the eyes unresponsive to occasional artificial tear use. Commonly, patients with permanent eyeliner will present with meibomian gland dropout, and those with lash extensions can have trapped debris and bacterial buildup due to poor lid hygiene, resulting in low-grade lid inflammation and ultimately infection. Proper education on their risk factors for developing chronic issues should be reviewed and a management plan initiated. Even without these cosmetic indicators, a yearly evaluation of lid health for your patients is warranted.

Either a bacterial or mite infestation can result in chronic inflammation of the lid margin, which promotes obstruction of the meibomian glands. Ideally, yearly evaluation of lid hygiene and prompt education on the effects of these findings can help prevent symptoms alto-

gether. Anterior segment photos are beneficial for documentation and may help convince patients to start preventative treatments such as warm compresses and daily lid scrubs. For lashes with stubborn lid debris and scurf, mechanical exfoliators, such as BlephEx, can be used in clinic before the patient begins their at-home maintenance routine. In addition, consideration for omega-3 supplements can also be reviewed due to their anti-inflammatory benefits and ability to balance tear film osmolarity by improving meibum quality and, therefore, tear break-up time (TBUT).

Staphylococcus, *Propionibacterium* and *Corynebacterium* are the most common bacterial causes of chronic blepharitis.¹ Furthermore, increased prevalence of Demodex, either *D. folliculorum* or *D. brevis*, is expected with age. With the longer life expectancies of the population, optometrists should anticipate more patients presenting with associated adnexal complaints. One study demonstrated a clinically significant increase in Demodex infestation in those with chronic blepharitis (80.36%) compared to healthy subjects (45.65%), which is corroborated by similar research.¹⁻³

Therefore, when considering treatment options for chronic blepharitis, both a broad-spectrum antimicrobial and an anti-Demodex therapy should be implemented simultaneously. A low-dose (20mg) oral doxycycline twice a day for a month has been shown to be effective in these cases

due to its antimicrobial and anti-inflammatory properties.⁴ Alternatively, 1.25g of oral azithromycin for five to seven days is also effective.⁵ Early and aggressive treatment before the ocular surface is damaged and/or irreversible lid margin alterations occur will lead to better retention of patent meibomian glands and, ultimately, a better prognosis for long-term tear film health.

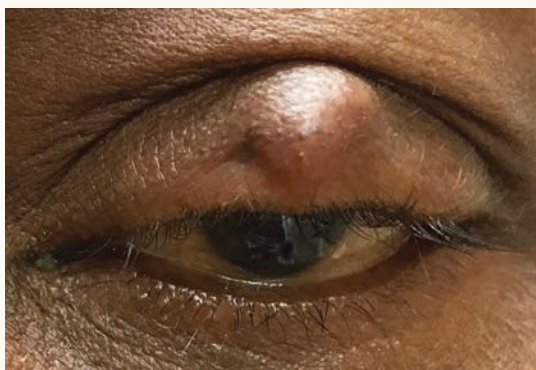Lid lesions. When the lid margin is affected by bacterial biofilms and mites, without proper management the meibomian and Zeis glands will become susceptible to infection. These acute inflammatory processes are typically localized elevations and are the majority of preventable eyelid conditions seen in practice.

Hordeola result from infection, predominantly staphylococcal, which results in painful bumps or styes made up of polymorphonuclear leukocytes along with tissue necrosis. For external hordeolum infections affecting the Zeis glands, a frequent schedule of warm compresses and a topical steroid with a macrolide antibiotic treatment can be highly effective in resolving persistent and painful lesions.⁶ Internal meibomian gland hordeola are deeper and may require an oral antibiotic for most effective treatment along with warm compresses.

A chalazion is a painless, inflammatory lipogranulomatous lesion due to a blockage of the distal meibomian glands. They are commonly associated with inflammatory systemic conditions like acne rosacea. They can present acutely or as a result of poor compliance with hordeolum treatment. The backed-up lipids build up in the glands and result in an immune response of neutrophils surrounding and encasing the material. Externally, the lid appears focally elevated with less erythema than a hordeolum.

Intralesional injection of a steroid or surgical intervention with transconjunctival incision and drainage may be necessary if conservative treatments are ineffective. Even if the lesion is painless and the patient is unbothered by the appearance, treatment is still recommended, since the lesion may expand and cause distortions to the lid margin as well as changes to vision from induced astigmatism.⁶ Only 25% to 50% of chalazia fully resolve on their own.⁷ Poor lid apposition to globe, ectropion or entropion with trichiasis and hyperkeratinization from lid pathology will contribute to worsening ocular surface disease.

Photo: Joseph Sawka, OD



Chalazia are granulomatous lid lesions arising from blockage of the distal meibomian glands.

If the patient's signs and symptoms persist following topical and oral therapies, referral to a lid specialist for triamcinolone acetonide injection, or incision and curettage, is appropriate. Optometric comanagement following incision and drainage is important, since post-op scarring and trauma to lid structures may lead to increased dry eye symptoms. Emphasizing proper post-op care to patients—including applying moist heat frequently TID for 10 minutes each time as well as avoiding eye rubbing, getting water in the eyes and using makeup for up to a month—will help with the healing process. Post-op topical antibiotics are typically used for one week, and topical steroids may be tapered throughout the month following the procedure; these instructions are typically reviewed with the patient at their surgical site.

If recurrent nodules appear in the same location in older patients, referral to an oculoplastic surgeon is also indicated to rule out a sebaceous cell carcinoma. As with any lid surgery, mechanical deficiencies may result, and careful assessment of function should be performed during post-op care.

Mechanical lid deficiency. Conditions involving lid mechanics, which can occur in adults and children, can limit or even completely block normal vision. With ptosis, whether congenital or acquired in etiology, the levator muscle is unable to fully retract. Ptosis secondary to nerve paralysis may resolve without surgical or topical intervention. For instance, cases of ischemic third nerve palsies are typically self-limiting, and 80% to 85% of patients notice resolution in three to six months.⁸ An acute presentation of unilateral ptosis should signal the need for careful patient history and assessment of the pupils to rule out Horner's syndrome. Again, the causes may vary, so treatment is based on the location and cause of the sympathetic nerve interference. A prompt referral to a neuro-ophthalmologist may ultimately save a patient from a serious systemic condition.

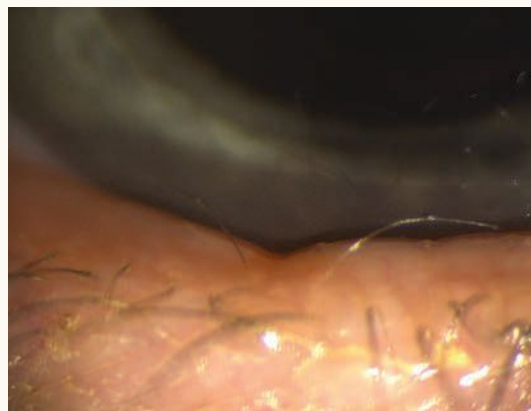
However, most commonly, aponeurotic ptosis is due to a thinning and loss of levator muscle tone and is amenable to surgical intervention.

Depending on the surgical approach, the patient risks exacerbation of dry eye if there is over-correction or damage to the lid structures and vasculature.⁹ Therefore, surgery is typically not recommended unless the patient has demonstrable visual symptoms. However, if surgery is indicated, the patient should be thoroughly educated on the risk of increased dry eye as a post-op complication.

Preoperative optimization of the tear film and postoperative management for DED should be initiated.

Weakening of the lower lid retractors and canthal tendon due to age or history of trauma will result in an inward (ectropion) or outward (entropion) turning of the lid margin. It is more commonly seen in the elderly population and primarily affects the lower lid. In ectropion, poor apposition of lid margin to globe results in poor tear film spreading and retention. The patient will present with exposure keratitis. In addition, the meibomian glands are unable to properly release the lipid layer of the tear film.

In entropion, however, the patient is at high risk for superficial corneal abrasions from secondary trichiasis and corneal infections brought on by the increased proximity of natural bacterial flora of the lid. The patient often notes a persistent foreign body sensation along with mucus discharge, depending on the condition's chronicity. Both entropion and ectropion are thought to be caused by increased levels of elastolytic activity, resulting in a loss of elastic fibers in tissues. The most common elastolytic enzymes belong to the matrix metalloproteinase family, which are overexpressed in a variety of conditions, such as local ischemia, inflammation and chronic mechanical trauma.¹⁰

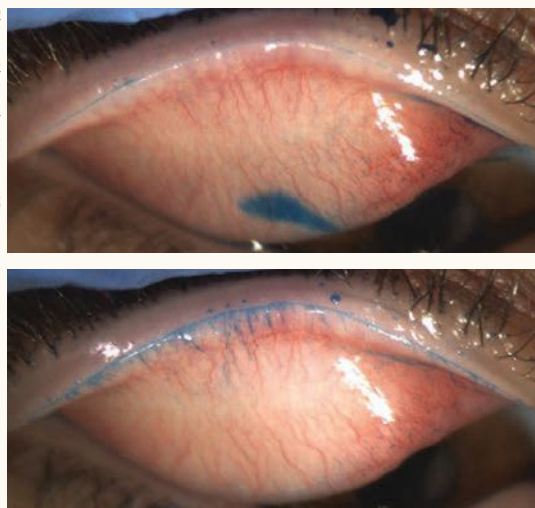


A 56-year-old female presented with lower lid notching and distichiasis without entropion, which can indicate a chronic inflammatory etiology. The patient was started on omega-3 supplements and daily lid hygiene. She returns for epilation every three to four months, as she is disinterested in surgical intervention.

Referral to an oculoplastic surgeon for either condition can restore normal eyelid architecture to enable proper lid closure and improve ocular protection and tear film spreading. Non-surgical management includes frequent lubrication, eyelid masks or ointment, use of bandage contact lenses and management of concurrent eyelid disease, such as MGD or blepharitis, for improved comfort in the interim. Surgical approaches may depend on the presence of orbicularis oculi overaction, horizontal laxity and/or vertical laxity.

Another common yet often overlooked contributor to poor ocular surface health is lagophthalmos. Complete eyelid closure with an involuntary blink is vital to proper tear film distribution and, therefore, a critical element for maintaining a healthy ocular surface. Common etiologies include cosmetic eyelid surgeries for dermatochalasis, ptosis repair, Botox (onabotulinumtoxinA) injections, Grave's disease, floppy eyelid syndrome (FES), lid deformities from lesions or trauma, use of scleral lenses, ectropion and reduced blink rate from excessive screen time.

Patients may present with increased dry eye symptoms first thing in the morning due to nocturnal lagophthalmos, particularly if using a CPAP



The top image reveals the line of Marx in a case of lid wiper epitheliopathy, while the bottom image shows additional proximal LWE staining.

machine for sleep apnea. Presence of lagophthalmos can be assessed at the time of the exam by measuring the palpebral fissure opening upon inferior gaze and gentle closure of lids, documenting the opening in millimeters to determine degree of the condition. The Korb-Blackie (KB) lid light test is also helpful in diagnosing the weak or lacking protective seal between upper and lower lids.

Acute cases should have a thorough exam of cranial nerve function with emphasis on orbicularis oculi muscle motility. Examine the amount of effort needed to achieve full lid closure as well as the presence of Bell's phenomenon, where the eye naturally rolls upward on voluntary lid closure. Those with a poor Bell's reflex are prone to keratopathy. Prolonged exposure of corneal surface and subsequent exposure keratitis can be noted on slit lamp exam with fluorescein or lissamine green staining occurring on the inferior cornea and conjunctiva. Measure TBUT and corneal sensitivity between the eyes, especially if there is a unilateral presentation.

Unfortunately, in chronic cases, corneal epithelial decompensation, sterile or infectious corneal ulcerations, neurotrophic keratitis or corneal neuropathic pain may occur. As previously mentioned, the facial

nerve (CN VII) innervates the orbicularis oculi, which closes the eyelids. CN VII palsies or damage will result in poor lid closure and inhibit the blink reflex and associated lacrimal pumping mechanism. As a result, the patient may have both a secondary aqueous and secondary evaporative dry eye.

Determining cause is important in dictating management and possibly comanagement with the patient's primary care provider and a neuro-ophthalmologist. For maintenance and symptom relief, these patients may benefit most from a mois-

ture-preserving sleep mask to prevent overnight exposure and exacerbations of signs and symptoms. Unfortunately, chronic cases may ultimately require surgical interventions such as a tarsorrhaphy, gold weight implantation, lower eyelid tightening and elevation, or upper eyelid retractions and levator recession to prevent corneal ulcerations.¹¹

If typical dry eye treatments are ineffective, eyelid laxity may be a contributing factor for poor tear film retention and distribution. FES is often seen in patients with sleep apnea, glaucoma and keratoconus. Floppy eyelid syndrome can exacerbate MGD, superficial exposure keratitis, giant papillary conjunctivitis and superior limbic keratoconjunctivitis. During the examination, a highly elastic and easily everted upper lid is an indication of FES. Treatment for such a presentation can include management of increased inflammatory agents on the lid margin as well as referral to the patient's PCP for sleep apnea evaluation.

The role of the optometrist is to help maintain eye integrity while also comanaging with the patient's primary care provider to address systemic conditions that may contribute to this lid finding. Referral to oculoplastic surgeons is often indicated.

Conjunctival factors. Most recently, lid wiper epitheliopathy (LWE) has been uncovered in patients with dry eye symptoms who present with normal TBUT times and normal Schirmer's test values. Oftentimes, these patients also have a negative fluorescein corneal staining. The "lid wiper region" sits just posterior to the line of Marx, where the lid's marginal conjunctiva opposes the ocular surface from the medial puncta to the lateral canthus horizontally.¹²

LWE occurs posterior to the line of Marx, extending on to the conjunctiva. Lissamine green can be used to identify the Marx line, which—when normal—is a thin band identifying the mucocutaneous junction. LWE presents as a horizontal expansion posterior to the line of Marx. The primary cause of LWE is hypothesized to be due to the friction when lubrication between the lid wiper and the ocular surface or a contact lens is insufficient. It is associated with abnormal blink patterns, irregular lid margins, tight lids as in Grave's disease, high myopia and aggressive eyelid surgery.

Several studies have shown an increased presentation of LWE in long-term contact lens wearers.^{13,14} One study recognized that 76% of non-contact lens wearing patients with dry eye symptoms, yet no corneal findings, presented with LWE.⁹ Essentially, diagnosis of LWE before ocular surface presentations may be valuable in signaling earlier diagnosis and preventative treatment of DED.

The conjunctival goblet cells are responsible for the production of a portion of the tear film's mucin layer. Though mucin consists of the thinnest layer of the tear film, these glycoproteins are important in making the tear film hydrophilic, not only allowing the tear film to stay on the ocular surface, but also aiding in the smooth and even dispersion of the aqueous layer across the eye. The main ocular mucins contributing to the tear film are MUC1, MUC5AC and MUC7.

MUC1 helps keep foreign bodies and inflammatory agents from

adhering to the eye, while MUC7 is thought to have antibacterial properties. Both are important for limiting retention of pro-inflammatory molecules, which can exacerbate dry eye symptoms. MUC5AC represents the gel-forming mucins that are most abundant on the ocular surface and play the largest role in promoting tear film equilibrium.

Loss of goblet cells will result in decreased mucin production, thereby rendering them unable to fully function properly to maintain lubrication on the ocular surface. Common contributors to loss of goblet cell density include over-use of eye drops with preservatives, vitamin A deficiency, chemical injuries and chronic conjunctival inflammation. Ultimately, this may be the most difficult component of the tear film to supplement and treat. Current studies have shown some benefits of topical vitamin A to increase mucin production or cyclosporine A to increase production of goblet cells in addition to aqueous production.^{15,16}

Other culprits capable of resulting in the chronic symptoms of eyelid-induced dry eye include a history of rosacea or eyelid eczema, chronic allergies and even some acute viral infections.¹⁷ Historically, intense pulsed light has been used by aestheticians and dermatologists to manage the inflammatory responses associated with both rosacea and eczema. The treatment helps reduce the signs of redness and superficial blood vessels. As mentioned earlier, IPL can also improve similar symptoms associated with chronic lid diseases like MGD, by targeting the telangiectatic vessels as well as the thickened meibum that causes clogged glands.

Separately, chronic allergies may be a result of cosmetics or cosmeceuticals. An often-overlooked culprit for recurrent blepharitis and MGD is a red dye called Carmine that is commonly used in eyeliners and eye shadows. Raising awareness to the potential for patient sensitivity to this ingredient will help prevent perma-

nent distortions from chronic inflammation. Though not directly affecting specific components responsible for creating a balanced tear film, palpebral conjunctival irregularities such as follicles, large capillaries and pseudomembranes will all contribute to mechanical friction across the ocular surface.

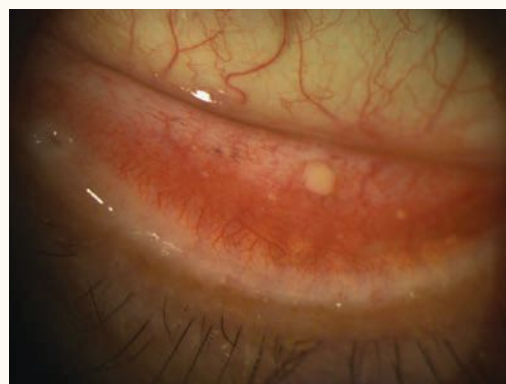
Take-home Message

Given the link between ocular surface health and the eyelids, focusing treatment on the ocular surface without also addressing lid contributors is an ineffective way of resolving patient symptoms. Artificial tears alone will only offer temporary relief and prevent further progression of any eyelid disease. Researchers found that up to 85% of dry eye disease has a lid component, resulting in the need to treat lipid deficiencies, specifically MGD.¹⁸

Optometrists have an arsenal of diagnostic tools and management methods to control the narrative on preventative care of the eyelids. We already know how to examine the eyelids. Expensive equipment and techniques are not necessary to begin to apply these basic skills to the prevention of eyelid disease and the treatment of dry eye.

Early efforts at patient education, beginning in the teen years, is a critical step for improving compliance and preventing the sequelae of chronic disease. Optometry is in the position to offer patients affordable and effective management of eyelid health. Efforts to address dry eye and other conditions will be mostly unsuccessful if any underlying causes involving eyelid compromise are not effectively managed. ■

1. Zhu M, Cheng C, Yi H, et al. Quantitative analysis of the bacteria in blepharitis with demodex infestation. *Front Microbiol.* 2018;9:1719.
2. Bhandari V, Reddy JK. Blepharitis: always remember demodex. *Middle East Afr J Ophthalmol.* 2014;21:317-20.
3. Zhao YE, Wu LP, Xu JR. Association of blepharitis with demodex: a meta-analysis. *Ophthalmic Epidemiol.* 2012;19(2):95-102.



Chronic ocular allergies can sometimes result in conjunctival concretions. This patient had complaints of persistent foreign body sensation, which resolved once the concretion was excised.

4. Yoo S, Lee D, Chang M. The effect of low-dose doxycycline therapy in chronic meibomian gland dysfunction. *Korean J Ophthalmol.* 2005;19(4):258-63.
5. De Benedetti G, Vaiano A. Oral azithromycin and oral doxycycline for the treatment of meibomian gland dysfunction: a 9-month comparative case series. *Indian J Ophthalmol.* 2019;67(4):464-71.
6. Baharestani S, Nguyen Burkat C, Marcet MM, et al. *Stye.* EyeWiki. 2015. Available at: eyewiki.aao.org/stye.
7. Goawalla A, Lee V. A prospective randomized treatment study comparing three treatment options for chalazia: triamcinolone acetonide injections, incision and curettage and treatment with hot compresses. *Clin Exp Ophthalmol.* 2007;35(8):706-12.
8. Bagheri N, BN W. *The Wills Eye Manual: Office and Emergency Room Diagnosis and Treatment of Eye Disease.* 7th ed. Philadelphia: Wolters Kluwer; 2017.
9. Zloto O, Matani A, Prat D, et al. The effect of a ptosis procedure to an upper blepharoplasty on dry eye syndrome. *Am J Ophthalmol.* 2020 Apr;212:1-6.
10. Damasceno RW, Avgitidou G, Belfort R, et al. Eyelid aging: pathophysiology and clinical management. *Arq Bras Oftalmol.* 2015;78(5):328-31.
11. Lawrence SD, Morris CL. Lagophthalmos evaluation and treatment. *EyeNet.* April 2008. www.aao.org/eyenet/article/lagophthalmos-evaluation-treatment.
12. Korb DR, Blackie CA. Marx's line of the upper lid is visible in upgaze without lid eversion. *Eye Contact Lens.* 2010;36(3):149-51.
13. Li W, Yeh TN, Leung T, et al. The relationship of lid wiper epitheliopathy to ocular surface signs and symptoms. *Invest Ophthalmol Vis Sci.* 2018;59(5):1878-87.
14. Korb DR, Herman JP, Blackie CA, et al. Prevalence of lid wiper epitheliopathy in subjects with dry eye signs and symptoms. *Cornea.* 2010;29(4):377-83.
15. Zhang X, Jeyalatha V, Qu Y, et al. Dry eye management: targeting the ocular surface microenvironment. *Int J Mol Sci.* 2017;18(7):1398.de
16. Oliveira RC, Wilson SE. Practical guidance for the use of cyclosporine ophthalmic solutions in the management of dry eye disease. *Clin Ophthalmol.* 2019;13:1115-22.
17. Liu J, Sheha H, Tseng S. Pathogenic role of Demodex mites in blepharitis. *Curr Opin Allergy Clin Immunol.* 2010;10(5):505-10.
18. Lemp MA, Crews LA, Bron AJ, et al. Distribution of aqueous-deficient and evaporative dry eye in a clinic-based patient cohort: a retrospective study. *Cornea.* 2012;31(5):472-8.

OPTOMETRIC STUDY CENTER QUIZ

To obtain continuing education credit through the Optometric Study Center, complete the test form on the following page and return it with the \$35 fee to: Jobson Healthcare Information, LLC, Attn.: CE Processing, 395 Hudson Street, 3rd Floor New York, New York 10014. To be eligible, please return the card within three years of publication. You can also access the test form and submit your answers and payment via credit card online at revieweducationgroup.com. You must achieve a score of 70 or higher to receive credit. Allow four weeks for processing. For each Optometric Study Center course you pass, you earn 2 hours of credit from Pennsylvania College of Optometry. Please check with your state licensing board to see if this approval counts toward your CE requirement for relicensure.

1. What is the average amount of eyelid blinks performed per day?
 - a. 1,000 to 2,000.
 - b. 3,000 to 15,000.
 - c. 20,000 to 22,000.
 - d. >24,000.
2. What structures are present at the most anterior aspect of the eyelid?
 - a. Tarsal plate.
 - b. Meibomian glands.
 - c. Glands of Zeiss and Moll.
 - d. Levator palpebrae muscle.
3. What type of glands are Zeis glands?
 - a. Sebaceous.
 - b. Apocrine.
 - c. Ceruminous.
 - d. Sudoriferous.
4. What muscle does Horner's syndrome affect and what is the resulting clinical sign?
 - a. Müller's muscle and lagophthalmos.
 - b. Levator palpebrae muscle and ptosis.
 - c. Müller's muscle and ptosis.
 - d. Levator palpebrae and lagophthalmos.
5. The conjunctiva is responsible for which aspect of the tear film?
 - a. The lipid layer.
 - b. The aqueous layer.
 - c. The mucin layer.
 - d. It is responsible for the production of all three layers.
6. Which group of organisms includes the main causes of blepharitis and meibomian gland dysfunction?
 - a. *Streptococcus*, *Staphylococcus* and *Diphtheroids*.
 - b. *Propionibacteria*, *Streptococcus* and *Demodex brevis*.
 - c. *Demodex folliculorum*, *Diphtheroids* and *Corynebacterium*.
 - d. *Streptococcus*, *Micrococci* and *Neisseria*.
7. In what glands do hordeola and chalazia occur?
 - a. Meibomian and Zeis.
 - b. Zeis and Moll.
 - c. Gland of Wolfring.
 - d. Both A and C.
8. What treatment targets both the meibomian glands and lid telangiectasia?
 - a. Warm compresses.
 - b. Tobradex ointment.
 - c. Intense pulsed light.
 - d. Lid hygiene with hypochlorous acid.
9. Which is true of ectropion and entropion?
 - a. They occur due to a weakening of lower lid retractors.
 - b. They may be a result of elastolytic enzymes such as MMPs.
 - c. Surgical approaches are dependent on horizontal vs. vertical laxity.
 - d. All of the above.
10. What can trigger high levels of matrix metalloproteinases?
 - a. Elevated vitamin A.
 - b. Increased sebaceous gland expression.
 - c. Chronic inflammation.
 - d. Low tear film pH levels.
11. Bell's palsy will present with which of the following signs/symptoms?
 - a. Bilateral ptosis that is typically self-resolving.
 - b. Inability for complete closure of palpebral fissure with effort.
 - c. Increased lacrimal gland production.
 - d. Both B and C.
12. Which of the following is a suggested treatment for chronic, severe lagophthalmos?
 - a. Tarsorrhaphy.
 - b. Botox.
 - c. Severing Whitnall's ligament.
 - d. None of the above.
13. Lid wiper epitheliopathy (LWE) affects which part of the eyelid anatomy?
 - a. Bulbar conjunctiva.
 - b. Muscle of Riolan.
 - c. Meibomian glands.
 - d. Conjunctival tissue behind the Marx line.
14. Clinical findings associated with LWE include _____.
 - a. Palpebral conjunctival follicles.
 - b. Staining posterior to the line of Marx using lissamine green dye.
 - c. Entropion and madarosis.
 - d. Both A and B.
15. Which of the following ocular mucin is matched correctly to its function?
 - a. MUC1: prevent goblet cell apoptosis in event of trauma.
 - b. MUC5AC: gel-forming structural mucin.
 - c. MUC7: potential bactericidal activities to protect the corneal surface.
 - d. Both B and C.
16. What are the common treatments for mucin deficiency?
 - a. Vectored thermal pulsation.
 - b. Intense pulsed light.
 - c. Intraductal probing.
 - d. None of the above.
17. What estimated percentage of dry eye patients present with the evaporative form of the condition?
 - a. 15%.
 - b. 46%.
 - c. 85%.
 - d. 100%.
18. Which eyelid vasculature structure is most commonly damaged during lid surgery?
 - a. The supraorbital artery.
 - b. Marginal arcade.
 - c. Transverse facial branch.
 - d. Lacrimal artery.
19. Which of the following is the proper management for chalazia?
 - a. Monitor with frequent warm compresses until it resolves.
 - b. Triamcinolone acetonide injections.
 - c. Incision and curettage.
 - d. All of the above.
20. The most common form of ptosis is _____.
 - a. Aponeurotic.
 - b. Neurogenic.
 - c. Traumatic.
 - d. Myogenic.

Examination Answer Sheet

The Role of Eyelids in Health and Disease

Valid for credit through February 15, 2024

Online: This exam can be taken online at revieweducationgroup.com. Upon passing the exam, you can view your results immediately and download a real-time CE certificate. You can also view your test history at any time from the website.

Directions: Select one answer for each question in the exam and completely darken the appropriate circle. A minimum score of 70% is required to earn credit.

Mail to: Jobson Healthcare Information, LLC, Attn.: CE Processing, 395 Hudson Street, 3rd Floor New York, New York 10014

Payment: Remit \$35 with this exam. Make check payable to Jobson Healthcare Information, LLC.

Credit: This course is COPE approved for 2 hours of CE credit. Course ID is 71047-AS.

Processing: There is a four-week processing time for this exam.

Jointly provided by Postgraduate Institute for Medicine and Review Education Group. Salus University has sponsored the review and approval of this activity.

Answers to CE exam:

1. A B C D
2. A B C D
3. A B C D
4. A B C D
5. A B C D
6. A B C D
7. A B C D
8. A B C D
9. A B C D
10. A B C D
11. A B C D
12. A B C D
13. A B C D
14. A B C D
15. A B C D
16. A B C D
17. A B C D
18. A B C D
19. A B C D
20. A B C D

Post-activity evaluation questions:

Rate how well the activity supported your achievement of these learning objectives. 1=Poor, 2=Fair, 3=Neutral, 4=Good, 5=Excellent

21. Review the anatomy of the eyelids. ① ② ③ ④ ⑤
22. Recognize the impact eyelids have on the ocular system. ① ② ③ ④ ⑤
23. Discuss the role eyelid complications play in dry eye. ① ② ③ ④ ⑤
24. Describe the pathophysiology of common eyelid conditions. ① ② ③ ④ ⑤
25. Based upon your participation in this activity, do you intend to change your practice behavior? (Choose only one of the following options.)
 A I do plan to implement changes in my practice based on the information presented.
 B My current practice has been reinforced by the information presented.
 C I need more information before I will change my practice.
26. Thinking about how your participation in this activity will influence your patient care, how many of your patients are likely to benefit? (please use a number):
27. If you plan to change your practice behavior, what type of changes do you plan to implement? (Check all that apply.)
 A Apply latest guidelines D Change in current practice for referral G More active monitoring and counseling
 B Change in diagnostic methods E Change in vision correction offerings H Other, please specify: _____
 C Choice of management approach F Change in differential diagnosis _____
28. How confident are you that you will be able to make your intended changes?
 A Very confident B Somewhat confident C Unsure D Not confident
29. Which of the following do you anticipate will be the primary barrier to implementing these changes?
 A Formulary restrictions D Insurance/financial issues G Patient adherence/compliance
 B Time constraints E Lack of interprofessional team support H Other, please specify: _____
 C System constraints F Treatment related adverse events _____

30. Additional comments on this course:

Please retain a copy for your records. Please print clearly.

First Name

Last Name

E-Mail

The following is your: Home Address Business Address

Business Name

Address

City State

ZIP

Telephone #

Fax #

OE Tracker Number

Rate the quality of the material provided:

1=Strongly disagree, 2=Somewhat disagree, 3=Neutral, 4=Somewhat agree, 5=Strongly agree

31. The content was evidence-based.

① ② ③ ④ ⑤

32. The content was balanced and free of bias.

① ② ③ ④ ⑤

33. The presentation was clear and effective.

① ② ③ ④ ⑤

By submitting this answer sheet, I certify that I have read the lesson in its entirety and completed the self-assessment exam personally based on the material presented. I have not obtained the answers to this exam by any fraudulent or improper means.

Signature _____ Date _____ Lesson 120883 RO-OSC-0221



EDITED BY JOSEPH P. SHOVLIN, OD

Weigh Your Options

There are many different treatments available for corneal endothelial disease, but efficient patient selection leads to the most successful outcomes.

Q Descemet's membrane endothelial keratoplasty (DMEK) seems to be the lamellar procedure of choice these days for corneal endothelial disease. Can you describe the use of artificial materials that have recently been reported and who would be the best candidate for each device?

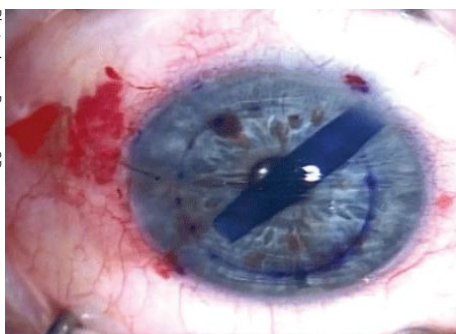
A "Corneal endothelial disease, such as Fuchs' endothelial dystrophy, posterior polymorphous dystrophy and iridocorneal endothelial syndrome, can lead to significantly impaired vision and quality of life," says Christopher Lopez, OD, who practices in Wisconsin. "Fortunately, continued technological advancement has led to an improvement in treatment and management options."

Current Options

Penetrating keratoplasty (PKP) used to be the primary surgical option for patients suffering from endothelial dysfunction. A PKP involves a full-thickness corneal tissue replacement with an allograft corneal button to replace damaged endothelial cells. Although its use has dwindled in favor of other techniques, PKP is still a contender under certain circumstances, especially when a patient has significant endothelial compromise.

Descemet's stripping endothelial keratoplasty (DSEK) is often favored over PKP in mild-to-moderate cases of endothelial dysfunction. A DSEK involves replacing the posterior cornea

Photo: Aaron Bonner, OD



During DMEK, donor Descemet's membrane tissue is stained with trypan blue for better visualization of the eye.

with donor tissue consisting of endothelial cells, Descemet's membrane and a portion of the posterior stroma. DSEK eyes tend to have favorable outcomes, with lower graft rejection rates, quicker visual recoveries and more predictable refractive endpoints compared with PKP eyes.

DMEK is similar to DSEK, with the distinction that DMEK donor grafts consist of healthy endothelial cells and Descemet's membrane without posterior stromal tissue. DMEK outcomes favor better visual acuity and even lower rejection rates than DSEK.

Descemetorhexis without endothelial keratoplasty (DWEK) is a newer technique in the rehabilitation of corneas with endothelial compromise. DWEK consists of removing Descemet's membrane without replacement with a donor graft. After the central area of Descemet's membrane is surgically stripped away, healthy peripheral endothelial cells should mi-

grate centrally to replace the removed cells. The goal is to improve corneal clarity and, therefore, enhance visual acuity.

Future Advancements

New research is exploring additional avenues for patients with corneal endothelial dysfunction. For example, stem cells have been engineered to replace the corneal endothelium.¹ Rho-kinase (ROCK) inhibitors have demonstrated enhancement of endothelial cells.² Additionally, endothelial cells can be multiplied and used in conjunction with ROCK inhibitors to increase endothelial cell count.³ Due to a worldwide shortage of tissue, several research centers are investigating artificial corneas. These areas of research show promising results but warrant further studies before they potentially evolve into mainstay treatments in the management of endothelial disease.

Takeaways

As with all of these procedures, proper patient selection is crucial in successfully improving corneal endothelial compromise. Additionally, each surgical technique has its own pros and cons. Gone are the days in which every patient undergoing corneal endothelial surgery is treated with a PKP. Scientific advancements have led to better surgical techniques with improved visual outcomes and enhanced safety profiles. ■

1. Yamashita K, Inagaki E, Hatou S, et al. Corneal endothelial regeneration using mesenchymal stem cells derived from human umbilical cord. *Stem Cells Dev.* 2018;27(16):1097-108.

2. Okumura N, Kinoshita S, Koizumi N. Application of rho kinase inhibitors for the treatment of corneal endothelial diseases. *J Ophthalmol.* 2017;2017:2646904.

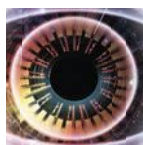3. Stephenson M. The newest treatment options for Fuchs'. *Rev Ophthalmol.* 2018;25(11):38-40.

About
Dr. Shovlin

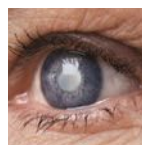
Dr. Shovlin, a senior optometrist at Northeastern Eye Institute in Scranton, PA, is a fellow and past president of the American Academy of Optometry and a clinical editor of *Review of Optometry* and *Review of Cornea & Contact Lenses*. He consults for Kala, Aerie, AbbVie, Novartis, Hubble and Bausch + Lomb and is on the medical advisory panel for Lentechs.

Register for an upcoming CE conference
from Review Education Group!

 VIRTUAL EVENTS



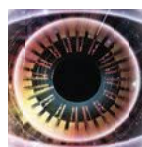**New Technologies
& Treatments in Eye Care**
SPRING | MARCH 19–20, 2021
EARN UP TO 12* LIVE COPE CREDITS
Register: www.ReviewEdu.com/NTT2021



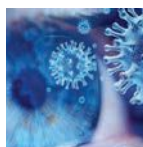Optometric Glaucoma Symposium
SPRING | MAY 7–8, 2021
EARN UP TO 12* LIVE COPE CREDITS
Register: www.ReviewEdu.com/OGS2021



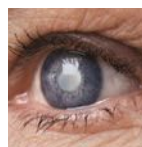
Intrepid Presents
**Innovations and Implications
in Practice**
APRIL 9–10, 2021
EARN UP TO 14* LIVE COPE CREDITS
More info: www.ReviewEdu.com/Events



**New Technologies
& Treatments in Eye Care**
SUMMER | JUNE 11–12, 2021
EARN UP TO 12* LIVE COPE CREDITS
Register: www.ReviewEdu.com/NTT2021



COVID Combat Conference
APRIL 24, 2021
EARN UP TO 8* LIVE COPE CREDITS
Register: www.ReviewEdu.com/CovidCombat



Optometric Glaucoma Symposium
WINTER | DECEMBER 10–11, 2021
EARN UP TO 12* LIVE COPE CREDITS
Register: www.ReviewEdu.com/OGS2021

For additional information visit

www.ReviewEdu.com/Events

e-mail: ReviewMeetings@MedscapeLIVE.com



*Approval pending

Review Education Group partners with Salus University for those ODs who are licensed in states that require university credit.





BY JAMES L. FANELLI, OD

GLAUCOMA GRAND ROUNDS

It Takes Two to Manage Glaucoma

New patients who present without a complete medical history must be willing to work even more closely with their OD.

A new patient presented to establish care with me after moving to North Carolina in February 2019. At the time, she was 75 years old and had a long-standing history of glaucoma—approximately 14 to 15 years.

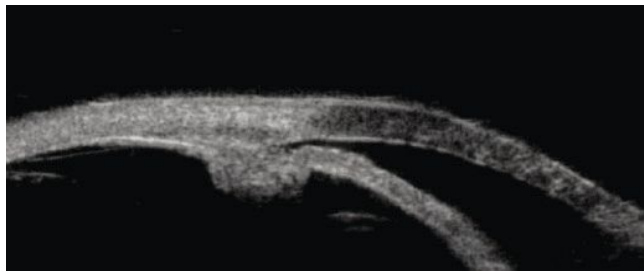The Case

At the initial visit, the patient reported that she underwent “laser surgery” in both eyes for her glaucoma at the outset of her diagnosis and had a second, “different surgical procedure” about 12 years prior in each eye.

As is often the case with glaucoma patients presenting to a new office for the first time, she did not come with any previous records. Presenting without records can make the initial visit challenging, but the goal of this visit is to simply get a feel for the severity of the glaucoma. The stability of the glaucoma is answered in subsequent visits.

The patient’s list of medications included Lipitor (atorvastatin, Pfizer) QD, Neurontin (gabapentin, Pfizer) 300mg BID, hydrochlorothiazide QD, omeprazole QD, Glucophage (metformin, Merck) QD, acetylsalicylic acid 81mg QD and multivitamins. She reported no allergies to medications.

As far as I could tell, she had developed type 2 diabetes over 20 years ago. Her most recent A1c was 6.0, and she does not regularly check her glucose levels. She was not taking any



My best guess is that this patient was lasered due to narrow angles, but UBM evaluation shows a classic iris plateau configuration. This makes an angle appear narrower on slit lamp examination and gonioscopy. LPIs generally are not effective in opening the angle; an iris plateau configuration is the basis of narrow angles.

glaucoma medications, though she did report diligence with bilateral digital ocular massage TID.

The patient’s best-corrected visual acuities were 20/30- OD and 20/50- OS. There was no pupillary defect noted, though her pupillary reactions were diminished in intensity bilaterally and ovoid in shape.

Slit lamp examination of her anterior segments was remarkable for bilateral dermatochalasis, but not significant enough to have a large effect on her visual acuities. Both corneas had mild inferior superficial punctate keratopathy. There were superiorly placed blebs OU, with adjacent surgical peripheral iridectomies. Both eyes also had laser peripheral iridotomies (LPIs) at 10 o’clock OD and 2 o’clock OS. Applanation tensions were 19mm Hg OD and 18mm Hg OS. Central corneal thickness measurements were

525µm OD and 497µm OS. Angles were open with no risk of angle closure.

Through dilated pupils, the patient’s crystalline lenses were characterized by moderate nuclear and cortical cataract formation OS>OD. I determined that her best-corrected acuities were consistent with the cata-

acts. A complete posterior vitreous detachment (PVD) was noted in the right eye, whereas the left had a partial PVD. Both maculae were characterized by bilateral retinal pigment epithelium granulation and fine drusen consistent with her age. Evaluation of the peripheral

retina was essentially unremarkable.

The patient’s optic nerves, as viewed stereoscopically at the slit lamp, were characterized by moderate and advanced glaucomatous damage OD and OS, respectively. There were no noted disc hemorrhages, and the retinal vasculature was characterized by mild arteriolar sclerotic retinopathy. I judged her cup-to-disc ratios to be 0.65x0.75 OD and 0.8x0.9 OS. The optic nerves were of average size.

Given the patient’s relatively thin pachymetry values and the level of her glaucomatous damage, I was not convinced that her intraocular pressure (IOP) was at an adequate level. This brought on further questioning, primarily related to glaucoma medication use. The patient mentioned that when she was initially diagnosed, she was on topical medications, but her previous provider was not happy with

About
Dr. Fanelli

Dr. Fanelli is in private practice in North Carolina and is the founder and director of the Cape Fear Eye Institute in Wilmington, NC. He is chairman of the EyeSki Optometric Conference and the CE in Italy/Europe Conference. He is an adjunct faculty member of PCO, Western U and UAB School of Optometry. He is on advisory boards for Heidelberg Engineering and Glaukos.

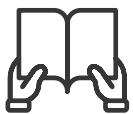REVIEW OF OPTOMETRY

The OD's TOP CHOICE

Ranked #1 Eye Care
Publication In
FIVE
Critical Readership
Categories:



Total Readers



Most Read Publication/
Website Within the Last
Six Months



Quality Clinical Content
I Use in My Practice



Average Page Exposures



Websites Visited within
the Last Six Months

Source: Kantar Media Eyecare 2020 Study

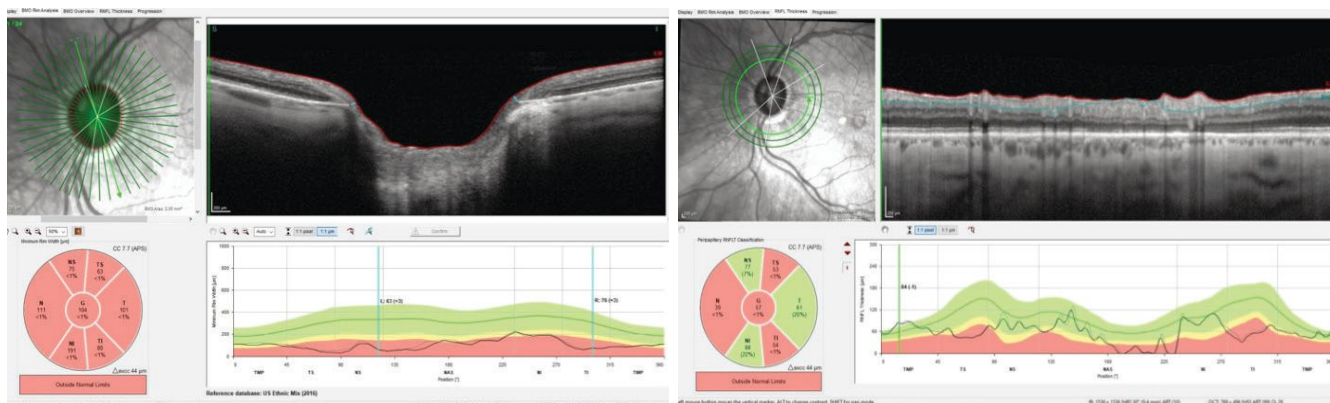
Practitioners rely on RO
more than any other eye
care publication



**Review also is number one in readership
across the following categories:**

- Total Optometrists
- ODs in High-Volume Practices
- Solo Practitioners
- Annual Practice Revenue (\$500k+)
- ODs who Purchase Examination Equipment
- Write Prescriptions (11+ per week)
- Perform Refractions (51+ per week)
- Contact Lens Prescribers
- Years in Practice (1-15 and 15+)
- Among Key Opinion Leaders

***To our readers:* Thank you for
your loyalty, time and trust.
We'll keep working hard to earn
your support.**



Bruch's membrane opening (left) and retinal nerve fiber layer (right) follow-up scans demonstrate significant neuroretinal rim and retinal nerve fiber layer damage, but with no progression from baseline.

their effect; thus, he had proceeded with the laser procedures that resulted in the LPIs.

Apparently, the patient's previous provider then proceeded with bilateral trabeculectomies for reasons unknown and was pleased with her post-op IOPs, ultimately discontinuing her glaucoma medications. She did, however, have to initiate ocular massage OU TID. She reported that she saw her provider every six months, and had done so six months prior to her visit with me, and that he raised no concern regarding her IOPs.

I was also not convinced that the patient's optic nerves were stable given her IOPs. The question of stability determined the frequency of our next few visits, which aimed to obtain baseline information about the structure and function of her optic nerves. I obtained OCT and HRT-3 images, visual field studies, gonioscopy evaluations and UBM images.

Subsequent IOP readings varied from 12mm Hg to 23mm Hg OD and from 10mm Hg to 20mm Hg OS. According to the patient, sometimes she performed ocular massage while in the waiting room prior to being seen. This may have played a role in the range of IOPs I measured. On the other hand, variations in IOP can simply occur in glaucoma patients who are not adequately controlled. Ultimately, once I determined she was not in an acute situation, we stretched our visits out somewhat,

though I continued to question her seemingly stable disease state.

Skeptical of Stability

In July 2020, the patient presented with complaints of decreased vision OS>OD. Not surprisingly, her cataracts had progressed gradually over the past year, accounting for some of the reduced acuity. Surprisingly, the decreased acuity OS was not due to worsening field loss affecting fixation but to vitreomacular adhesion (VMA) development in the left eye.

At this visit, the patient's acuities were 20/50 OD and 20/150 OS. Though VMA can either release on its own or with surgical management, I did not feel it was appropriate to pursue surgery without addressing the progressing cataracts as well. She preferred to revisit the topic in October. At that visit, her acuities were essentially unchanged, and the VMA had been slightly reduced. She opted to proceed with cataract surgery at some point at the beginning of 2021.

But what about the patient's glaucoma? Throughout the time I've been seeing her, her only daily intervention consisted of digital massage. Typically, this therapy is used following trabeculectomies once the eye is stabilized. Trabeculectomies are usually performed on patients who either have non-stable or advanced glaucoma with a long history of poorly controlled IOP. Digital massage can lower IOP, which is easy to do with a patent trabecu-

lectomy. But, some trabeculectomies tend to lower IOP too much, while others fail to reduce IOP at all. On top of that, how much pressure should a patient apply when they massage the eye? Doesn't massaging the eye actually increase IOP during the massage? Can this cause damage that the post-massage IOP reduction is trying to mitigate?

My clinical intuition told me that with IOPs as variable as this patient's, coupled with her advanced disease, she was not stable. However, OCT imaging of the neuroretinal rims, circumpapillary retinal nerve fiber layer and macular ganglion cells all showed remarkable stability in the 22 months that I've seen her. While her angles had narrowed slightly due to the progressing cataracts and her acuity was decreased, neither had direct bearing on her glaucoma.

Accordingly, the patient is continuing with her daily digital ocular massage and preparing for cataract extraction OU. The surgery is certainly not without risk given her advanced glaucoma, but it is necessary to prevent further reductions in her quality of life. Remember that for many glaucoma patients, topical therapy can have a negative effect on their quality of life, even if they are compliant and the medications work well. The least amount of medications that get the job done is a good mantra in glaucoma care management. And sometimes, digital massage is enough. ■

CELEBRATE 2021 GIVE SIGHT FOR THE NEW YEAR!



I Care & Share engages your patients or customers in your passion to help make eye care accessible to those in need. Your practice or company makes a donation for individual glasses or product sales. We provide you with materials to let your patients or customers know of your efforts to give back. We also make it easy for them to participate.



OPTOMETRY GIVING SIGHT

I CARE & SHARE

THANK YOU FOR YOUR SUPPORT!

To get started, go to
givingsight.org/i-care-share/
or contact us at:

USA 303 526 0430
usa@givingsight.org

CANADA 403 670 2619
canada@givingsight.org



BY PAUL M. KARPECKI, OD
CHIEF CLINICAL EDITOR

OCULAR SURFACE REVIEW

Light Therapy: Which is Better, One or Two?

A look at dry eye treatments that focus on the healing powers of energy rather than pharmacology.

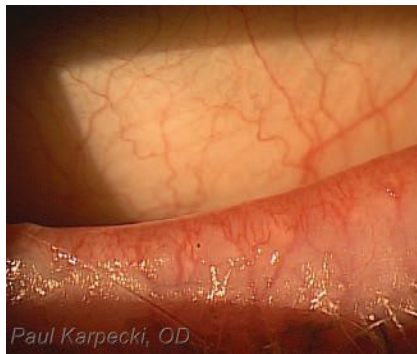As awareness of meibomian gland disease (MGD) grows, so too have available treatments that directly address the unique biology of this common contributor to ocular surface disease. From supplements and lid hygiene to in-office debridement, blepharoxfoliation and expression therapies, MGD treatment has evolved exponentially and continues still.

Intense pulsed-light (IPL) therapy is becoming an increasingly more mainstream alternative for patients with confirmed MGD, particularly if they also present with rosacea. Recently, a new form of IPL therapy has emerged using a two-step process that integrates traditional IPL with low-level light therapy (LLLT), a method of treating MGD using red to near-infrared light energy. This column reviews recent research into the modality.

What We Know About IPL

The value of IPL for the treatment of dry eye was first identified in 2002 by Rolando Toyos, MD, when patients who were being treated for skin problems reported improvements in their dry eye symptoms.¹ This makes sense, as greater than 80% of rosacea patients have concomitant MGD.²

IPL treatments are performed with 500nm to 1,200nm light pulses for 20 to 30 minutes; it can be repeated every four to five weeks.



Telangiectasia with ocular rosacea may be responsive to treatment with combined IPL/LLLT.

Potential mechanisms whereby IPL can achieve clinical improvement include:³

- Thrombosis of abnormal or telangiectatic blood vessels below the skin surrounding the eyes.
- Heating the meibomian glands and liquefying the meibum.
- Activation of fibroblasts and enhancing the synthesis of new collagen fibers.
- Decreasing the bacterial and pathogen load on the eyelids.
- Interference with the inflammatory cycle by regulation of anti-inflammatory agents and MMPs.
- Reducing the turnover of skin epithelial cells and decreasing the risk of physical obstruction of the meibomian glands.
- Changes in the levels of reactive oxidative species.

IPL is generally considered safe;

however, do not consider treatment in patients with Fitzpatrick skin type IV or lower, due to the risk of melanin damage and resultant hypopigmentation.⁴ Newer devices such as the Eye-Light (Innova Medical Ophthalmics) allow treatment for higher skin type ranges by adjusting the energy based on a measurement of skin pigment.

Adding a Second Light Source

LLLT is a different form of photobiomodulation than IPL, but one that also began in dermatology and is now demonstrating efficacy in MGD, specifically in terms of improved tear break-up time.^{5,6}

Combined light therapy involves the application of both IPL and LLLT.⁵

While IPL treatment offers thermal-based effects, LLLT is athermal and presumed to have additive photobiomodulation effects on the lids and periorbital area.⁵ The proposed mechanism of LLLT is photoactivation.^{5,7} The ability to apply LLLT to the upper lid, where it is generally considered unsafe to apply IPL, may further contribute to MGD improvement.⁵

A recent study of 460 eyes evaluated the effects of combined light therapy on patients who were unresponsive to previous medical management.⁵ The combined treatment consisted of intense, short pulses of light on the area of the face around the eye, followed by longer exposure to low-level red light on the cheek and over the closed lids.⁵

Researchers found that mean OSDI scores were significantly lower after combined treatment.⁵ Prior to treatment, 70.4% of patients had OSDI scores indicative of dry eye, whereas only 29.1% of patients had abnormal OSDI following treatment.⁵

About
Dr. Karpecki

Dr. Karpecki is medical director for Keplr Vision and the Dry Eye Institutes of Kentucky and Indiana. He is the Chief Clinical Editor for *Review of Optometry* and chair of the New Technologies & Treatments conferences. A fixture in optometric clinical education, he consults for a wide array of ophthalmic clients, including ones discussed in this article. Dr. Karpecki's full disclosure list can be found in the online version of this article at www.reviewofoptometry.com.

IPL Procedure Basics

Although there is some variation in protocol, standard IPL procedures involve placing protective eye shields over the eyes at the outset. Some systems require applying ultrasound gel on the skin to keep the treatment area cool. Treat only the skin inferior and lateral to the lower eyelid margin, as there is risk of light penetration through the eyelid and absorption within the intraocular structures with upper eyelid treatment.⁸ After two passes on each side, remove the ultrasound gel and apply a hot compress along the eyelids for two to three minutes.⁸

It is also been shown to be beneficial to express the meibomian glands following IPL treatment.^{9,10} In fact, meibum expressibility improvement might be a good therapeutic target of IPL treatment in patients with MGD and dry eye and could be an indicator of ocular surface inflammation during IPL treatment. In a recent study of 30 patients who underwent three IPL sessions, patients with low meibum expressibility and tear film instability experienced greater improvement in symptoms after IPL treatment.¹¹ The improvement in meibum expressibility was also associated with a decrease in tear inflammatory cytokine levels.¹¹

Finally, a topical steroid may be prescribed for two to three days following the procedure.⁸

1. Toyos R, McGill W, Briscoe D. Intense pulsed light treatment for dry eye disease due to meibomian gland dysfunction; a 3-year retrospective study. *Photomed Laser Surg.* 2015;33(1):41-6.
2. Viso E, Rodríguez-Ares MD, Oubiña B, Gude F. Prevalence of asymptomatic and symptomatic meibomian gland dysfunction in the general population of Spain. *Invest Ophthalmol Vis Sci.* 2012;53(6):2601-6.
3. Dell SJ. Intense pulsed light for evaporative dry eye disease. *Clin Ophthalmol.* 2017;11:1167-73.
4. Vora G, Gupta P. Intense pulsed light therapy for the treatment of evaporative dry eye disease. *Curr Opin Ophthalmol.* 2015;26:314-8.
5. Stonecipher K, Abell TG, Chotiner B, Chotiner E, Potvin R. Combined low level light therapy and intense pulsed light therapy for the treatment of meibomian gland dysfunction. *Clin Ophthalmol.* 2019;13:993-9.
6. Toyos R, Briscoe D, Toyos M. The effects of red light technology on dry eye disease due to meibomian gland dysfunction. *JOJ Ophthalmol.* 2017;3(5):555624.
7. Kim WS, Calderhead RG. Is light-emitting diode phototherapy (LED-LLLT) really effective?. *Laser Ther.* 2011;20(3):205-215.
8. Vora G, Gupta P. Intense pulsed light therapy for the treatment of evaporative dry eye disease. *Curr Opin Ophthalmol.* 2015;26(4):314-8.
9. Arita R, Mizoguchi T, Fukuoka S, et al. Multicenter study of intense pulsed light therapy for patients with refractory meibomian gland dysfunction. *Cornea.* 2018;37(12):1566-71.
10. Vegunta S, Patel D, Shen J. Combination therapy of intense pulsed light therapy and meibomian gland expression (IPL/MGX) can improve dry eye symptoms and meibomian gland function in patients with refractory dry eye: a retrospective analysis. *Cornea.* 2016;35(3):318-22.
11. Choi M, Han SJ, Ji YW, et al. Meibum expressibility improvement as a therapeutic target of intense pulsed light treatment in meibomian gland dysfunction and its association with tear inflammatory cytokines. *Sci Rep.* 2019;9(1):7648.

A one-step or greater reduction in MGD grading was also observed in 70% of eyes, with 28% having a two-step or greater reduction.⁵ Tear break-up time was ≤ 6 seconds in 86.7% of eyes prior to treatment and dropped to 33.9% of eyes after treatment.⁵ There were no ocular or facial adverse events or side effects related to treatment.⁵

Beyond efficacy and safety, practical benefits may also inspire use of combined light therapy. Specifically, the EyeLight device adjusts energy

levels for optimum effects based on the patient's level of MGD and the Fitzpatrick skin scale score.⁵

Further, no gel is required, due to a built-in cooling system of forced air that maintains the temperature of the crystal at a non-traumatic level for the patient's skin type.⁵

With so many tools at our disposal, we are well equipped to treat both the signs and symptoms of dry eye, ocular rosacea and MGD with greater ease and efficacy than ever before. ■

ADVERTISER INDEX

This index is published as a convenience and not as part of the advertising contract. Every care will be taken to index correctly. No allowance will be made for errors due to spelling, incorrect page number, or failure to insert.

Alcon Laboratories	92	Berkshire Hathaway	7	Lombart Instruments	5
..... (800) 932-5676	 www.berxi.com	 (855) 777-2020	
..... www.pataday.com			 www.lombartinstrument.com	
Bausch + Lomb	2-3	CooperVision	91	MacuLogix	21
..... (800) 323-0000	 (800) 341-2020	 (888) 392-6801	
..... www.bausch.com	 www.coopervision.com	 www.maculogix.com/6months	
Bausch + Lomb	15-16	EyeVance	31-32	Notal Vision	12
..... (800) 323-0000	 (817) 677-6120	 (855) 600-3112	
..... www.lotemaxsm.com	 www.eyevance.com	 www.foreseehome.com/hcp	
Bausch + Lomb	Cover Tip	Icare USA	23	Optos	65
..... (800) 323-0000	 (888) 422-7313	 www.optos.com	
..... www.bausch.com	 www.icare-world.com/us		RVL Pharmaceuticals, Inc.	9-10
Berkshire Hathaway	7	Kala Pharmaceuticals	25 www.upneeq.com	
..... www.berxi.com	 (781) 996-5252		US Ophthalmic	27
CooperVision	91 www.kalarx.com	 (888) 881-1122	
..... (800) 341-2020		Keeler Instruments	19 www.usophthalmic.com	
..... www.coopervision.com	 (800) 523-5620			
EyeVance	31-32 www.keelerusa.com			
..... (817) 677-6120					
..... www.eyevance.com					
Icare USA	23				
..... (888) 422-7313					
..... www.icare-world.com/us					
Kala Pharmaceuticals	25				
..... (781) 996-5252					
..... www.kalarx.com					
Keeler Instruments	19				
..... (800) 523-5620					
..... www.keelerusa.com					
Lombart Instruments	5				
..... (855) 777-2020					
..... www.lombartinstrument.com					
MacuLogix	21				
..... (888) 392-6801					
..... www.maculogix.com/6months					
Notal Vision	12				
..... (855) 600-3112					
..... www.foreseehome.com/hcp					
Optos	65				
..... www.optos.com					
RVL Pharmaceuticals, Inc.	9-10				
..... www.upneeq.com					
US Ophthalmic	27				
..... (888) 881-1122					
..... www.usophthalmic.com					



EDITED BY DEREK N. CUNNINGHAM, OD,
AND WALTER O. WHITLEY, OD, MBA

SURGICAL MINUTE

A New Wave

Vivity, a non-diffractive lens, seeks to up the ante in premium IOL visual quality for presbyopia correction.

BY PATRIZIA COLMENARES, OD
NORFOLK, VA

One of the most exciting aspects of cataract surgery is the continuous innovation in intraocular lens (IOL) technology. There are numerous companies working on the next generation of IOL platforms to improve both quality of vision and quality of life.

About a year ago, the first trifocal IOL—Alcon's PanOptix—hit the market, and largely exceeded expectations. More recently, Alcon introduced the AcrySof IQ Vivity Extended Vision IOL, which also offers a toric version. These IOLs are indicated for aphakic presbyopia correction in patients with up to 2.50D of corneal astigmatism. The manufacturer says this new platform provides high-quality distance vision, improved intermediate vision and functional near vision.

Lens Details

The Vivity is a UV-absorbing, blue light-filtering foldable IOL. Compared with a monofocal IOL, this lens is said to provide an extended range of vision from distance to intermediate (66cm) to near (44cm), potentially without increasing the incidence of visual disturbances. Unlike traditional refrac-

tive multifocal IOLs that use rings to split light energy, the Vivity IOL uses a non-diffractive design that stretches and shifts the wavefront to provide a continuous range of focus with minimal halos and glare, according to Alcon.




Photo: Alcon

Vivity's two surface transitions centrally work to alter the wavefront of light, extending the range of vision.

Company literature describes how two transition zones in the center optic accomplish this. First, a slightly elevated (by about 1µm) smooth plateau helps stretch the focal range; next, a slight curvature change across the central 2.2mm region shifts the wavefront to use all available light energy. Alcon calls this optic design "X-Wave."

Clinical Outcomes

Vivity is pupil-independent, allowing for enhanced visual performance in both bright and dim environments. Patients reported similar difficulties with glare, starbursts and halos with this IOL compared with a monofocal lens; only 2% of patients were bothered by starburst, 1% by halos and 0% by glare.¹ In the FDA clinical studies, 89% of patients had 20/25-2 or better uncorrected vision at distance, 86% had 20/25-2 or better uncorrected vision at the intermediate distance (26") and 91% had 20/40-2 or better uncorrected vision at near (16").¹

Candidate Selection

The Vivity IOL is a good option for motivated premium IOL candidates who want to be less dependent on visual correction but don't mind using readers for very small print. It can also be considered for those who may not be good candidates for traditional multifocal IOLs due to halo or starburst sensitivities. In our experience, it provides sharp vision with minimal complications, making it viable for those who require crisp, clear vision, especially at distance or at night.

It may also be a good choice for patients who don't want to sacrifice distance visual quality for near acuity. Patients with a history of maculopathy, glaucoma or mild ocular surface disease may be suitable candidates due to the optic design and its reduced side effects.

Takeaways

Innovation has become the norm in the world of IOLs, with novel technologies providing greater options for our patients, including Alcon's Vivity and PanOptix IOLs and soon Johnson & Johnson Vision's new Tecnis Eyhance and Synergy IOLs.

As optometrists, we can help our patients understand the differences between traditional monofocal IOLs, multifocal IOLs, extended depth-of-focus-IOLs and the latest extended vision IOLs to advise them on the pros and cons of each technology and find the best fit for their lifestyle. ■

1. Alcon. AcrySof IQ Vivity patient information brochure. www.accessdata.fda.gov/cdrh_docs/pdf/P930014S126D.pdf. Accessed January 11, 2021.

ABOUT THE AUTHOR



Dr. Colmenares practices at Virginia Eye Consultants in Norfolk, VA. She has no financial interests to disclose.

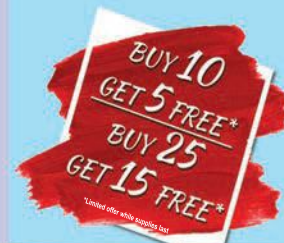About Drs.
Cunningham and Whitley

Dr. Cunningham is the director of optometry at Dell Laser Consultants in Austin, TX. He has no financial interests to disclose. Dr. Whitley is the director of professional relations and residency program supervisor at Virginia Eye Consultants in Norfolk, VA. He is a consultant for Alcon.

Contact Lenses

Impressions

Color Contact Lens



Unleash your true color!

Impressions colored contacts blend naturally with your patients eyes to create a beautiful look. Available in nine dazzling opaque colors of which Brown, Grey, Green, Hazel, Honey, Pure Hazel and True Sapphire are available in RX PL to -8.00. Impressions are fun, hip, fashionable and very competitively priced to help your bottom line. POP materials, posters, and trial kits are available upon request.

Available Exclusively at

NATIONAL LENS
 1-866-923-5600
 www.national-lens.com
 CALL US FOR ALL MAJOR BRANDS OF CONTACTS

Practice For Sale

Practice Sales • Appraisals • Consulting
 www.PracticeConsultants.com
**PRACTICES FOR SALE
 NATIONWIDE**
 Visit us on the Web or call us to learn more about our company and the practices we have available.
 info@PracticeConsultants.com
925-820-6758
www.PracticeConsultants.com

Do you have Products and Services for sale?
 CONTACT US TODAY
 FOR CLASSIFIED ADVERTISING
 Toll free: 888-498-1460
 E-mail: sales@kerhgroup.com

Equipment & Supplies

WHY PAY RETAIL?

Electric power lift table and adjusts from 25" to 50" Tabletop is 20" X 52" Tabletop will accommodate three instruments. Push button switch control. NEW IN BOX. Wholesale Price \$1,195.00 Call 800-522-2275

Place Your Ad Here!
 Toll free: 888-498-1460
 E-mail: sales@kerhgroup.com

Career Opportunities

Staff Optometrist Wanted

Bard Optical is a family owned full-service retail optometric practice with 22 offices (and growing) throughout Central Illinois. Bard Optical prides itself on having a progressive optometric staff whose foundation is based on one-on-one patient service. We are currently accepting CV/resumes for Optometrists to join our medical model optometric practice that includes extended testing. The practice includes but is not limited to general optometry, contact lenses and geriatric care. Salaried, full-time positions are available with excellent base compensation and incentive programs and benefits. Some part-time opportunities may also be available.

Current positions are available in Bloomington/Normal, Decatur/Forsyth, Peoria, Sterling and Canton as we continue to grow with new and established offices.

Please email your information to mhall@bardoptical.com or call Mick at 309-693-9540 ext 225. Mailing address if more convenient is:
Bard Optical
 Attn: Mick Hall, Vice President
 8309 N Knoxville Avenue
 Peoria, IL 61615

Bard Optical is a proud Associate Member of the Illinois Optometric Association.



www.bardoptical.com

PRODUCT REVIEW

New items on the market to improve clinical care and strengthen your practice.



ONLINE FIRST:
GET THE LATEST
PRODUCT NEWS AT
www.reviewofoptometry.com

► EQUIPMENT

Diagnostic Tool Aids Refractive Assessment

A new device from Haag-Streit aims to help practices engaged in myopia control efforts by measuring axial length and performing keratometry. Called Lenstar Myopia, the instrument combines the company's Lenstar 900 optical biometer with software for myopia assessment called EyeSuite Myopia.

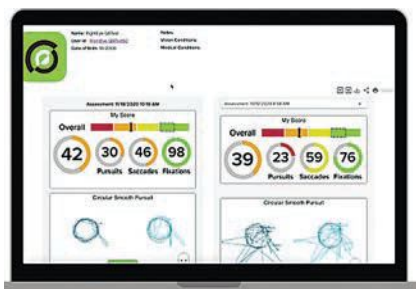The software is based on the latest research on refractive progression trends, axial length growth and environmental factors, according to Haag-Streit. The company says algorithms will be updated to reflect regional differences in demographics as they become available.

To educate patients and their parents about likely progression rates with and without intervention, the software produces charts that depict the impact of various myopia control efforts and even include environmental factors such as outdoor time. These graphic visualizations also track the efficacy of such interventions over time.



In Pursuit of Better Oculomotor Testing

If you've moved beyond the "follow my finger" assessment of ocular motility—or would like to—a recent software upgrade to the RightEye Vision System that makes the technology more useful may be better suited for you, according to a company press release.



The device digitally tracks eye movements and plots the results to uncover subtle deviations that might otherwise be missed. A new software module merges the prior two into a single assessment, making it easier to identify oculomotor impairments and document a patient's unique profile, RightEye says. Doctors offering vision therapy or rehab sessions will receive objective data on performance and be able to track, compare and show progress over time, making it easier to interpret test outcomes and communi-

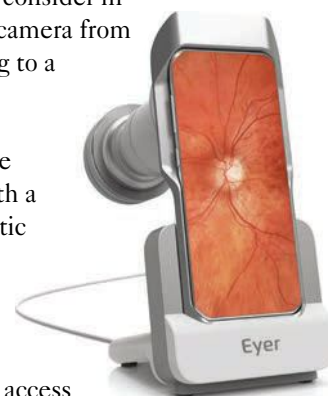
cate results to patients, the company explains.

Also, the system's reference population of normative values has been expanded 19-fold over the previous version, which RightEye says allows doctors to compare individual visualizations at a higher level of granularity and thereby gain a more in-depth understanding of visual status. Finally, the company says the system's dashboard was completely reimagined to provide users with more information much quicker, making it easier to find every test, patient or note.

A 'Smart' Way to Get into Fundus Photography

Practices looking to add fundus photography with more flexibility and lower costs than conventional retinal cameras have a new option to consider in the Eyer portable retinal camera from US Ophthalmic, according to a company press release.

The system couples a Samsung Galaxy S9 phone to an adapter outfitted with a 12 megapixel non-mydratric camera and is suitable for mobile imaging in or out of the office. Images are uploaded to a cloud server to allow for remote access and telemedicine consultation.



The Eyer offers color, red-free and stereophoto options at 45° of field. A panoramic mode creates composites with over 110° of field, US Ophthalmic says.

The BMW of BIO?

Practitioners who want top-of-the-line optics and functionality when performing binocular indirect ophthalmoscopy might be interested in the new Omega 600 BIO, just launched by Heine, the company says.

Several notable features set the Omega 600 apart, according to Heine:

- A new design based on an "ultralight" battery makes it the most lightweight high-end indirect on the market.
- A brightness regulator provides up to a 20% better view of the retina for examination of cataract patients with media opacities and an overall more tolerable light intensity for both the patient and the provider. Heine calls this system VisionBoost.
- The surface design allows easy cleaning and disinfection, and all cables and electronics are integrated into the new headband for unencumbered use.

- Easy adjustment of stereoscopic viewing to suit any pupil size (including newborns) and desired peripheral view.

- A better view through the optic by use of non-reflective front glass.

- Choice of yellow, cobalt blue and red-free filters.

Heine says it offers a five-year warranty on the quality of its materials, workmanship and design.



► CONTACT LENSES

Fully Custom Hybrid Lenses Now Available

If you've enjoyed fitting hybrid soft/GP contact lenses but wished for more customization options, here's good news: SynergEyes now offers a new lens design that does away with fixed skirt and base curve options. Instead, a patient's unique corneal diameter and curvature drive the specific lens design, the company says, with new linear skirts following the linear shape of the sclera.

Called SynergEyes iD, the lenses are individually designed to each patient's unique ocular anatomy based on K readings, HVID and refraction, a company press release explains. Lenses are fit empirically, eliminating the need for diagnostic sets and potentially expanding access to the lens by removing an upfront cost to practitioners. A pre-launch study of fits on over 1,500 eyes yielded an 84% success rate of first-lens dispense, high patient preference/satisfaction and revenue retention, according to the company.

A multifocal option uses an extended depth-of-focus design from the Brien Holden Vision Institute, according to SynergEyes.

New Mid-Range Toric Daily Disposable Debuts

Contact lens wearers interested in daily replacement at a budget-friendly price have a new option, as Alcon has added a toric lens to its Precision1 brand.

The new lens uses the same silicone hydrogel material (verofilcon A) as the Precision1 sphere and shares with that lens the 'microthin' (2µm to 3µm) moisture layer that Alcon calls SmartSurface, designed to improve comfort and support a stable tear film to reduce visual fluctuation, according to company press materials. Precision1 for Astigmatism also uses the company's water gradient design, with a water content of 51% at the core and greater than 80% at the anterior surface, according to Alcon.



To reduce rotation, the lens will include prism ballast at the 8 and 4 o'clock

points to help reduce lower lid interaction; Alcon calls this Precision Balance 8/4. The company says this design feature allows the lens to settle on-eye in under a minute and within 3° of ideal orientation, resulting in a 99% first-fit success rate.

Precision1 for Astigmatism will be offered in sphere powers from plano to -6D in quarter-diopter steps and cyl powers of -0.75D, -1.25D and -1.75D. Axes will be 90° and 180° ±20° in 10° steps.

A 90-pack of lenses lists for \$58, meaning that annual cost to the patient will be about \$470 under a daily replacement wear schedule.

Ortho-K Tweak Could Improve Efficacy

A new ortho-K option from CooperVision might bring more precision to your contact lens fits. The company says it now offers 5mm back optic zone diameter customization for its Paragon CRT and Paragon CRT Dual Axis contact lenses. Because this design offers more paracentral steepening than a 6mm zone, it may increase the efficacy of myopia management strategies, CooperVision says, assuming a dose-dependent relationship exists between paracentral steepening and the anti-myopia effect of ortho-K.

The company says Paragon CRT is recommended for patients with <0.75D of corneal astigmatism based on K values, while Paragon CRT Dual Axis is designed for those with >0.75D of corneal astigmatism to enhance the cornea-to-lens fitting relationship.

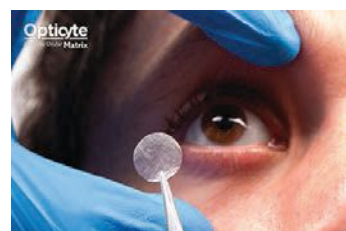► ANTERIOR SEGMENT CARE

Jump-Start Healing with New Amniotic Graft

Optometrists who treat severe ocular surface damage will be glad to hear that a new amniotic membrane therapy, called Opticyte, is on its way to the market. Manufactured by Merakris Therapeutics and distributed by Keeler, the product is a biological barrier graft that protects the ocular surface during healing and supports cell attachment and ingrowth in patients who suffer from dry eye disease or other corneal defects, according to Keeler.

The company says Opticyte uses a manufacturing process intended to retain extracellular matrix properties and structures—making it ideal for ocular applications—is processed without harsh chemical reagents that may cause irritation when placed in the corneal bed and is dehydrated for convenient storage.

Opticyte comes in 8mm, 10mm, 12mm and 14mm circular grafts along with 1x1cm and 1x2cm surgical repair graft options.





Unsafe at Any Speed

A patient experiences vision trouble after a car accident. What might have happened?

A 58-year-old Black female presented for a comprehensive ocular examination with a chief complaint of poor vision OD after being a passenger in an auto accident, during which she was struck in the face with an airbag. The patient denied any additional ocular history and reported a medical history of hypothyroidism, currently well-controlled with medication. The patient denied having any allergies to medications or environment. She is currently taking levothyroxine, lisinopril/hydrochlorothiazide, allopurinol, sertraline and ranitidine.

Diagnostic Data

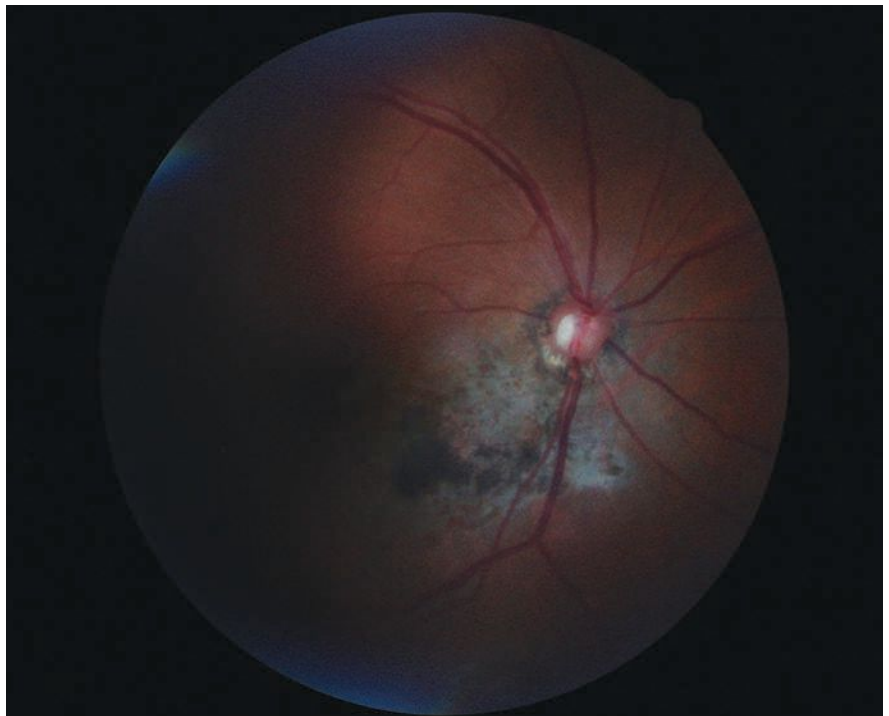Her best-corrected entering visual acuities were 20/20 OD and 20/30 OS at distance and near OU with no improvement upon pinhole. Her external examination was remarkable for superior constriction upon confrontation fields OD with a grade 1 afferent pupillary defect OD. Biomicroscopic evaluation of the anterior segment was unremarkable, with normal Goldmann applanation tonometry pressures of 17mm Hg OU. The pertinent retinal findings are demonstrated in the photograph.

Additional testing included baseline photodocumentation, baseline optical coherence tomography and baseline automated perimetry. Since “significant mechanism of injury” trauma, as in this case, can produce anatomical damage that can induce

secondary open-angle glaucoma, gonioscopy was also completed, uncovering an angle open to the ciliary body without angle recession.

Your Diagnosis

What would be your diagnosis in this case? What clues in the presentation led you to that decision? What is the patient’s likely prognosis? How would you manage the patient? To find out, please read the online version of this article at www.reviewofoptometry.com. ■



Dilated fundus exam of the patient revealed the findings shown here. In what way might they relate to the incident (an auto accident) she described upon presentation?

About Dr. Gurwood

Dr. Gurwood is a professor of clinical sciences at The Eye Institute of the Pennsylvania College of Optometry at Salus University. He is a co-chief of Primary Care Suite 3. He is attending medical staff in the department of ophthalmology at Albert Einstein Medical Center, Philadelphia. He has no financial interests to disclose.

NEXT MONTH IN THE MAG

Coming in March, *Review of Optometry* will present its 22nd annual dry eye report. Articles will include:

- MGD Causes and Corrections
- No Pain, All Gain: Managing Corneal Neuropathy in Dry Eye

- Don't Let Dry Eye Compromise Contact Lens Success

- How to Conduct a Good Dry Eye Assessment

Also included in March:

- Take Charge of the Cataract Conversation
- A Glaucoma Care Primer: Get Started The Right Way



KIDS SHOULD GROW STRONGER

Their myopia shouldn't.



Now you can help slow the progression of myopia in your age-appropriate patients.¹

Introducing the **Brilliant Futures™ Myopia Management Program with MiSight® 1 day** contact lenses.

MiSight® 1 day is the first and only FDA-approved* soft contact lens to slow the progression of myopia in children aged 8-12 at the initiation of treatment.^{1†}

59%

Slows Myopia Progression
on average^{1†}

52%

**Axial Length
Elongation Reduction**
on average^{1†}



Child Friendly¹
1 day lens

BRILLIANT FUTURES™

WITH MiSIGHT® 1 day



CooperVision®

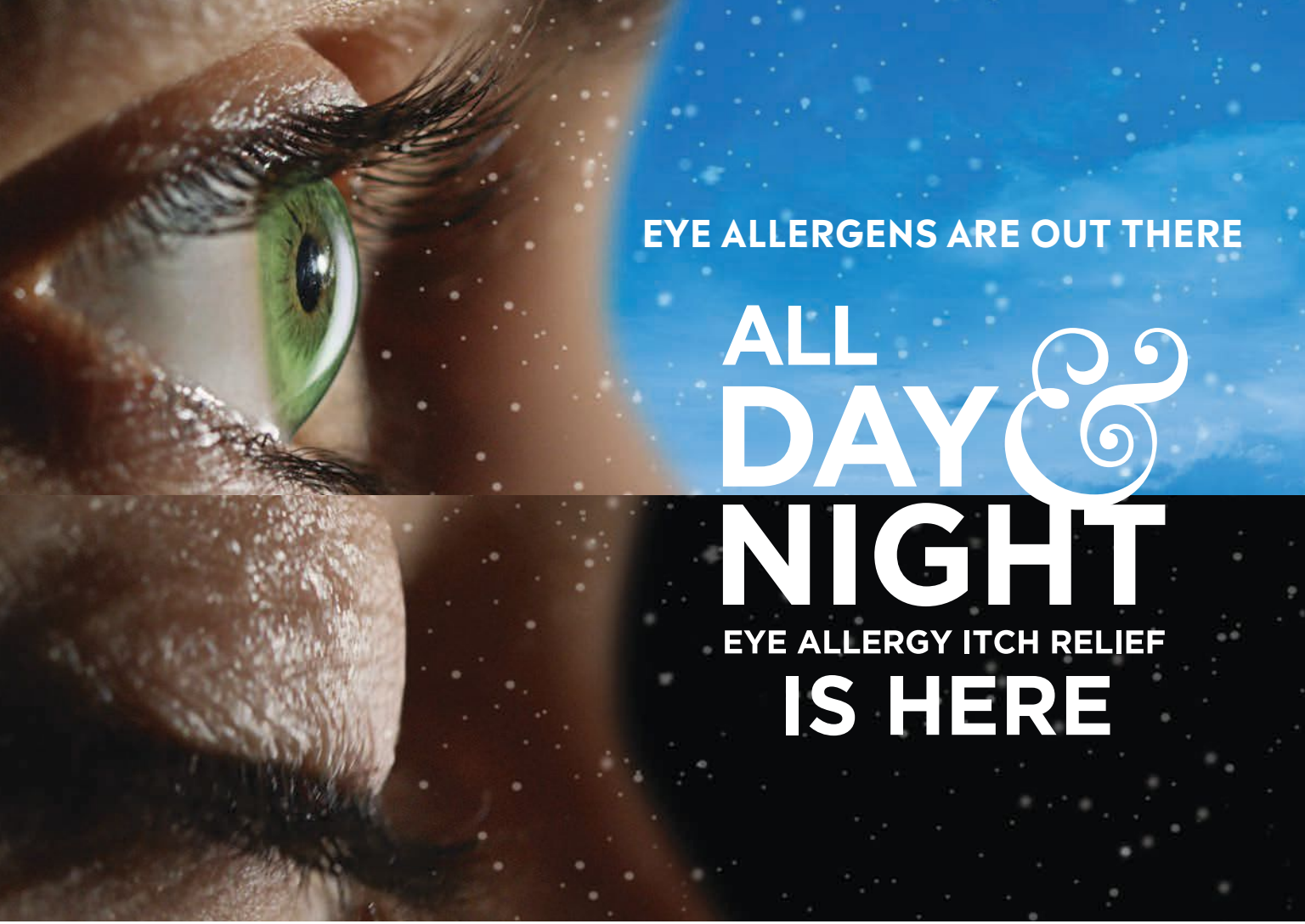Ask your CooperVision sales representative about Brilliant Futures™ with MiSight® 1 day lenses

Indications for use: MiSight® 1 day (omafilcon A) soft (hydrophilic) contact lenses for daily wear are indicated for the correction of myopic ametropia and for slowing the progression of myopia in children with non-diseased eyes, who at the initiation of treatment are 8-12 years of age and have a refraction of -0.75 to -4.00 diopters (spherical equivalent) with ≤ 0.75 diopters of astigmatism. The lens is to be discarded after each removal.

[†]Compared to a single vision 1 day lens over a 3 year period.

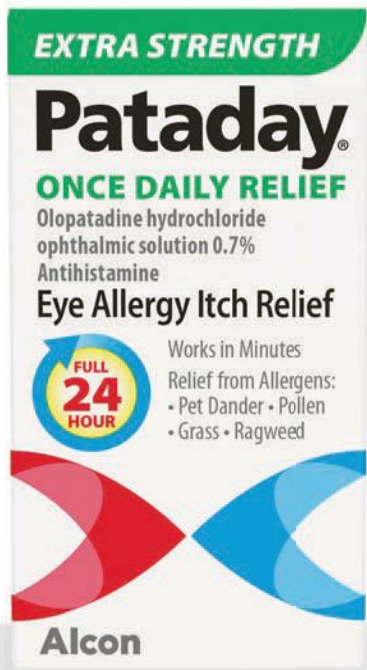¹Chamberlain P, et al. A 3-year randomized clinical trial of MiSight® lenses for myopia control. *Optom Vis Sci.* 2019; 96(8):556-567.

©2021 CooperVision, Inc. 10307RCCL 02/21



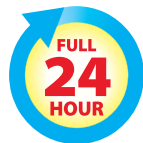EYE ALLERGENS ARE OUT THERE

ALL DAY & NIGHT EYE ALLERGY ITCH RELIEF IS HERE




Pazeo® has become Pataday® Once Daily Relief Extra Strength

Recommend to your patients for all day and night eye allergy itch relief.



One Drop Once a Day for 24-Hour Relief



Works in Minutes



Full Prescription Strength Pazeo® Available OTC