

Focus on Refraction: Buff Up Your Buffers, p. 26

# REVIEW<sup>®</sup> OF OPTOMETRY

December 15, 2020

[www.reviewofoptometry.com](http://www.reviewofoptometry.com)

ANNUAL INCOME  
SURVEY

## RIDING THE COVID ROLLER COASTER

Once-steady practice revenue

**NOW  
APPROVED!** COMING  
SOON

**kala**  
PHARMACEUTICALS

EYSUVIS is a trademark of Kala Pharmaceuticals. ©2020 Kala Pharmaceuticals  
All rights reserved. US-EYS-2000038 November 2020

[www.EYSUVIS.com](http://www.EYSUVIS.com)

**EYSUVIS<sup>™</sup>**  
(loteprednol etabonate  
ophthalmic suspension) 0.25%



Focus on Refraction: Buff Up Your Buffers, p. 26

# REVIEW<sup>®</sup> OF OPTOMETRY

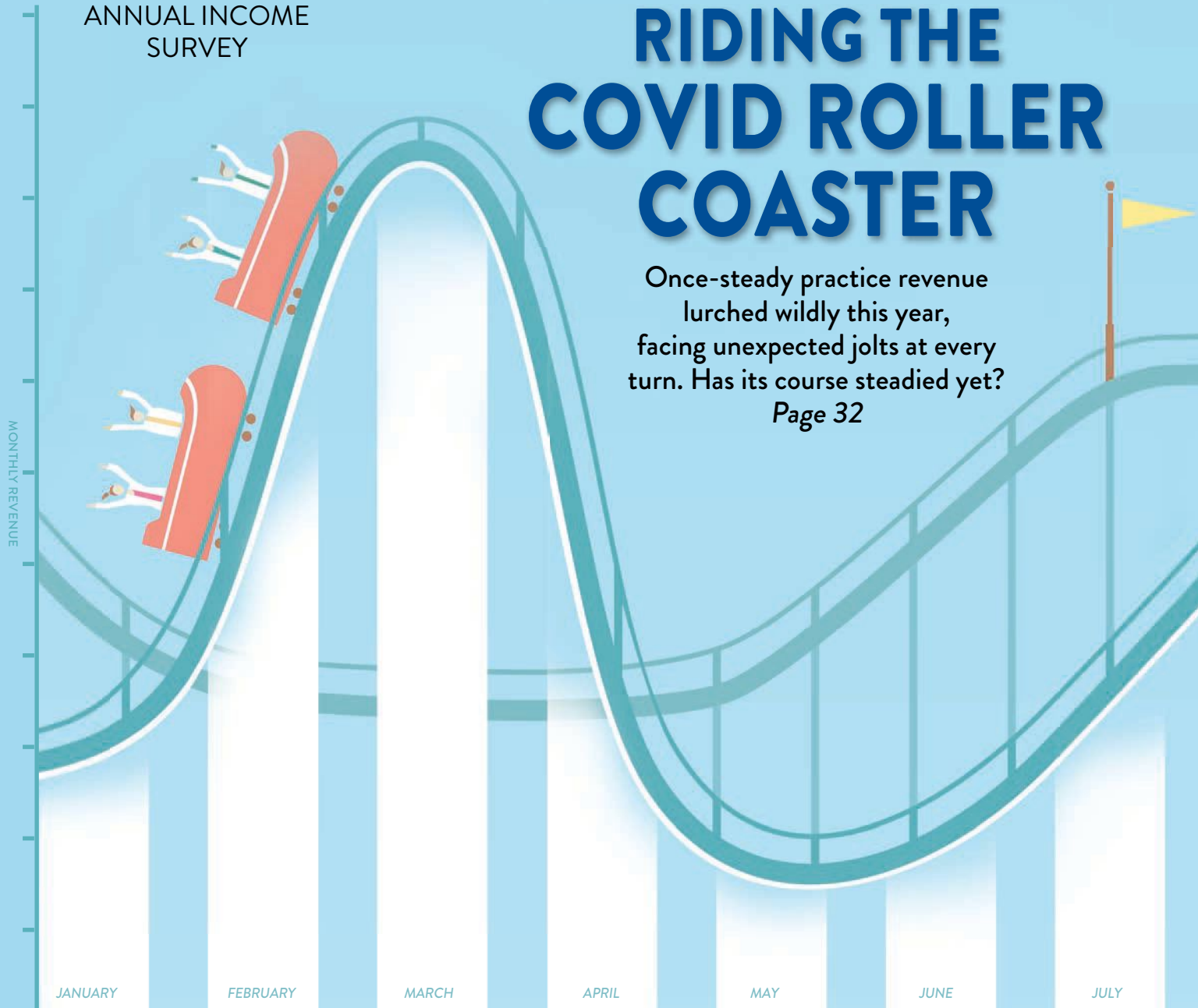December 15, 2020

www.reviewofoptometry.com

ANNUAL INCOME  
SURVEY

## RIDING THE COVID ROLLER COASTER

Once-steady practice revenue  
lurched wildly this year,  
facing unexpected jolts at every  
turn. Has its course steadied yet?  
*Page 32*



### ALSO INSIDE — 26th ANNUAL SURGERY REPORT:

Pearls of Postoperative Care, p. 38

Meet the New Trifocal IOL, p. 42

To Infinity and Beyond LASIK, p. 48

MIGS: Indications and Complications, p. 54



Not an actual patient.

\*In some patients with continued daily use. One drop in each eye, twice daily (approximately 12 hours apart).<sup>3</sup>

<sup>†</sup>Xiidra is an LFA-1 antagonist for the treatment of dry eye disease. Pivotal trial data: The safety and efficacy of Xiidra were assessed in four 12-week, randomized, multicenter, double-masked, vehicle-controlled studies (N=2133). Patients were dosed twice daily. Use of artificial tears was not allowed during the studies. The study end points included assessment of signs (based on Inferior fluorescein Corneal Staining Score [ICSS] on a scale of 0 to 4) and symptoms (based on patient-reported Eye Dryness Score [EDS] on a visual analogue scale of 0 to 100).<sup>3</sup> A larger reduction in EDS favoring Xiidra was observed in all studies at day 42 and day 84. Xiidra reduced symptoms of eye dryness at 2 weeks (based on EDS) compared to vehicle in 2 out of 4 clinical trials. Effects on signs of dry eye disease ICSS (on a scale from 0-4; 0=no staining; 4=coalescent) was recorded at each study visit. At day 84, a larger reduction in inferior corneal staining favoring Xiidra was observed in 3 of the 4 studies.<sup>3</sup>

## Indication

Xiidra® (lifitegrast ophthalmic solution) 5% is indicated for the treatment of signs and symptoms of dry eye disease (DED).


## Important Safety Information

- Xiidra is contraindicated in patients with known hypersensitivity to lifitegrast or to any of the other ingredients.



**Novartis Pharmaceuticals Corporation**  
East Hanover, New Jersey 07936-1080



A desk with a lamp, a clock, and a plant. The lamp is lit, casting a warm glow. The clock is round and white with black hands. The plant is a small potted orchid with white flowers. The background is dark, making the desk items stand out.

# SHE MAY NEED MORE THAN ARTIFICIAL TEARS TO DISRUPT INFLAMMATION IN DRY EYE DISEASE<sup>1,2</sup>

Her eyes deserve a change.

Choose twice-daily Xiidra  
for lasting relief that can start  
as early as 2 weeks.<sup>3\*†</sup>

The Xiidra logo features a stylized blue and yellow arc above the word "xiidra" in a lowercase, sans-serif font. Below "xiidra" is the text "(lifitegrast ophthalmic solution)5%" in a smaller, lowercase font.

xiidra<sup>®</sup>  
(lifitegrast  
ophthalmic solution)5%

## Important Safety Information (cont)

- In clinical trials, the most common adverse reactions reported in 5-25% of patients were instillation site irritation, dysgeusia and reduced visual acuity. Other adverse reactions reported in 1% to 5% of the patients were blurred vision, conjunctival hyperemia, eye irritation, headache, increased lacrimation, eye discharge, eye discomfort, eye pruritus and sinusitis.
- To avoid the potential for eye injury or contamination of the solution, patients should not touch the tip of the single-use container to their eye or to any surface.
- Contact lenses should be removed prior to the administration of Xiidra and may be reinserted 15 minutes following administration.
- Safety and efficacy in pediatric patients below the age of 17 years have not been established.

**For additional safety information about XIIDRA<sup>®</sup>, please refer to the brief summary of Full Prescribing Information on adjacent page.**

**References:** **1.** US Food and Drug Administration. Code of Federal Regulations, Title 21, Volume 5 (21CFR349). Accessed April 17, 2020. <https://www.accessdata.fda.gov/scripts/cdrh/cfdocs/cfcfr/CFRSearch.cfm?CFRPart=349&showFR=1> **2.** Jones L, Downie LE, Korb D, et al. TFOS DEWS II Management and Therapy Report. *Ocul Surf.* 2017;15(3):575-628. **3.** Xiidra [package insert]. East Hanover, NJ: Novartis Pharmaceuticals Corp; June 2020.

**XIIDRA, the XIIDRA logo and ii are registered trademarks of Novartis AG.**

**XIIDRA® (lifitegrast ophthalmic solution), for topical ophthalmic use**  
**Initial U.S. Approval: 2016**

**BRIEF SUMMARY: Please see package insert for full prescribing information.**

**1 INDICATIONS AND USAGE**

Xiidra® (lifitegrast ophthalmic solution) 5% is indicated for the treatment of the signs and symptoms of dry eye disease (DED).

**4 CONTRAINDICATIONS**

Xiidra is contraindicated in patients with known hypersensitivity to lifitegrast or to any of the other ingredients in the formulation [see *Adverse Reactions (6.2)*].

**6 ADVERSE REACTIONS**

The following serious adverse reactions are described elsewhere in the labeling:

- Hypersensitivity [see *Contraindications (4)*]

**6.1 Clinical Trials Experience**

Because clinical trials are conducted under widely varying conditions, adverse reaction rates observed in clinical trials of a drug cannot be directly compared to rates in the clinical trials of another drug and may not reflect the rates observed in practice.

In five clinical trials of DED conducted with lifitegrast ophthalmic solution, 1401 patients received at least one dose of lifitegrast (1287 of which received lifitegrast 5%). The majority of patients (84%) had less than or equal to 3 months of treatment exposure. One hundred-seventy patients were exposed to lifitegrast for approximately 12 months. The majority of the treated patients were female (77%). The most common adverse reactions reported in 5%-25% of patients were instillation-site irritation, dysgeusia, and reduced visual acuity.

Other adverse reactions reported in 1%-5% of the patients were blurred vision, conjunctival hyperemia, eye irritation, headache, increased lacrimation, eye discharge, eye discomfort, eye pruritus, and sinusitis.

**6.2 Postmarketing Experience**

The following adverse reactions have been identified during post-approval use of Xiidra. Because these reactions are reported voluntarily from a population of uncertain size, it is not always possible to reliably estimate their frequency or establish a causal relationship to drug exposure.

Rare serious cases of hypersensitivity, including anaphylactic reaction, bronchospasm, respiratory distress, pharyngeal edema, swollen tongue, urticaria, allergic conjunctivitis, dyspnea, angioedema, and allergic dermatitis have been reported. Eye swelling and rash have also been reported [see *Contraindications (4)*].

**8 USE IN SPECIFIC POPULATIONS**

**8.1 Pregnancy**

Risk Summary

There are no available data on Xiidra use in pregnant women to inform any drug-associated risks. Intravenous (IV) administration of lifitegrast to

pregnant rats, from pre-mating through gestation day 17, did not produce teratogenicity at clinically relevant systemic exposures. Intravenous administration of lifitegrast to pregnant rabbits during organogenesis produced an increased incidence of omphalocele at the lowest dose tested, 3 mg/kg/day (400-fold the human plasma exposure at the recommended human ophthalmic dose [RHOD], based on the area under the curve [AUC] level). Since human systemic exposure to lifitegrast following ocular administration of Xiidra at the RHOD is low, the applicability of animal findings to the risk of Xiidra use in humans during pregnancy is unclear [see *Clinical Pharmacology (12.3) in the full prescribing information*].

Data

Animal Data

Lifitegrast administered daily by IV injection to rats, from pre-mating through gestation day 17, caused an increase in mean pre-implantation loss and an increased incidence of several minor skeletal anomalies at 30 mg/kg/day, representing 5,400-fold the human plasma exposure at the RHOD of Xiidra, based on AUC. No teratogenicity was observed in the rat at 10 mg/kg/day (460-fold the human plasma exposure at the RHOD, based on AUC). In the rabbit, an increased incidence of omphalocele was observed at the lowest dose tested, 3 mg/kg/day (400-fold the human plasma exposure at the RHOD, based on AUC), when administered by IV injection daily from gestation days 7 through 19. A fetal no observed adverse effect level (NOAEL) was not identified in the rabbit.

**8.2 Lactation**

Risk Summary

There are no data on the presence of lifitegrast in human milk, the effects on the breastfed infant, or the effects on milk production. However, systemic exposure to lifitegrast from ocular administration is low [see *Clinical Pharmacology (12.3) in the full prescribing information*]. The developmental and health benefits of breastfeeding should be considered, along with the mother's clinical need for Xiidra and any potential adverse effects on the breastfed child from Xiidra.

**8.4 Pediatric Use**

Safety and efficacy in pediatric patients below the age of 17 years have not been established.

**8.5 Geriatric Use**

No overall differences in safety or effectiveness have been observed between elderly and younger adult patients.

Distributed by:  
Novartis Pharmaceuticals Corporation  
One Health Plaza  
East Hanover, NJ 07936  
T2020-87

## IN THE NEWS

Researchers from Spain found **forced blinks may influence tear film stability and can help clinicians provide clearer blinking instructions** while administering dry eye examinations. TBUT was statistically and clinically significantly shorter with unnaturally prolonged blinks than close-to-natural blinks, leading to inaccurate judgments of tear film stability. Likewise, the team added that **forced blinks seem to induce more abrupt tear film destabilization** than close-to-natural blinks.

Szczesna-Iskander DH, Quintana CL. Subjective and objective evaluation of the effect of blink type on tear-film breakup time and its estimation. *Optom Vis Sci.* October 28, 2020. [Epub ahead of print].

A new study looking into the impact of **omega-3 fatty acid supplements on the eye found a moderate daily dose may be an effective therapeutic approach for meibomian gland dysfunction.** The investigation reviewed the results of six clinical trials that cumulatively enrolled 350 participants. The lead researcher found that noninvasive TBUT is more precise compared with invasive NaFl-TBUT, which may signify the value of noninvasive TBUT in the clinic.

Al-Namaeh M. A systematic review of the effect of omega-3 supplements on meibomian gland dysfunction. *Ther Adv Ophthalmol.* 2020;12:2515841420952188.

New research has found a **reduced foveal avascular zone (FAZ) area and enhanced perifoveal microcirculation after IOP-lowering surgery.** The study noted that these changes didn't occur in the non-surgical fellow eye during the follow-up period, which argues in favor of FAZ growth in open-angle glaucoma patients and the mediating influence of surgery.

Shoji T, Kanno J, Weinreb RN, et al. OCT angiography measured changes in the foveal avascular zone area after glaucoma surgery. *Br J Ophthalmol.* November 5, 2020. [Epub ahead of print].

## ERs Unequipped to Manage Ocular Conditions

The tests personnel conducted often didn't match the results of consulted ophthalmologists.

By Jane Cole, Contributing Editor

Most ocular conditions that present in emergency departments aren't urgent and can be treated in an outpatient facility. Even if patients were to seek treatment in an ER, new research reports that the personnel in these facilities aren't usually equipped to measure important ocular vital signs, including visual acuity (VA) and intraocular pressure (IOP). The study suggests the need for a comprehensive ER triage plan to manage anterior segment conditions.

The researchers found the most common ocular diagnoses that presented emergently involved the cornea or conjunctiva. They included uveitis, corneal abrasion, corneal ulcer, meibomian gland dysfunction, dry eye, blepharitis, punctate epithelial erosion and conjunctivitis or epidemic keratoconjunctivitis.

ER doctors measured VA and IOP in about 41% and 17% of patients, respectively, while consulted ophthalmologists did so in 79% and 95% of cases, respectively. "Perhaps more concerning was that VA and IOP measurements were significantly different between ER providers and ophthalmologists," the researchers wrote in their paper.

VA measurement agreement between ER personnel and ophthalmologists was just under 12%. The

agreement between IOP testing was worse, with the two groups coming to the same conclusion less than 1% of the time. Diagnosis agreement occurred in about half the cases.

In terms of symptoms, patients presented with eye pain, irritation, foreign body sensation, dryness, light sensitivity or a combination of these signs. Although many ocular diseases share these symptoms, fewer than half of all ophthalmic presentations in the ER occur in the setting of acute trauma, which should provide ER staff with additional time to focus on the ocular complaint, the investigators explained. Likewise, most of the patients with anterior segment conditions included in the study didn't require admission after consultation with an ophthalmologist, they added. Still, the researchers said it's critical that the standard workup of ocular cases includes an accurate assessment of VA and IOP.

The investigators created a flowchart to aid ER physicians and ancillary staff in triaging patients presenting with a history, symptoms or signs suggestive of anterior segment pathology. They suggested ophthalmology be consulted in cases with an unclear diagnosis.

Tang VD, Safi M, Mahavongtrakul A, et al. Ocular anterior segment pathology in the emergency department: a five-year study. *Eye Contact Lens.* June 15, 2020. [Epub ahead of print].

NEWS STORIES POST EVERY WEEKDAY MORNING AT [www.reviewofoptometry.com/news](http://www.reviewofoptometry.com/news)

# Calif. ODs Push to Administer COVID Vaccines

As multiple COVID vaccines steam ahead toward FDA approval, optometrists in California also want the right to give shots to patients, citing the fact that most ODs already have the necessary training to do so. Optometrists are well equipped to provide vaccines since the statute in California already authorizes certified optometrists to administer flu, shingles and pneumonia immunizations to adults in the state, says California Optometric Association President Jason Tu, OD.

“The immunization training course for optometrists is the exact same course that is required for pharmacists and includes hands-on training on all vaccines,” he adds. “There are optometrists who work at community clinics that have taken the pharmacist-required course work but can’t administer vaccines because the statute prohibits it. All optometrists can be quickly trained and ready to help if we could just lift the arbitrary legal barriers that exist in California.”

## Within the Scope?

The intent of California’s expanded scope of practice law is to make it easier and more convenient for the general public to receive safe immunizations, says optometrist Brian Chou of San Diego.

“At the time this was passed, COVID-19 was not in the mental sphere of legislators or public health officials. It is, however, quite reasonable to expect that the skill and proficiency to administer coronavirus vaccination be equivalent to administering vaccinations for the flu, shingles or pneumonia,” he says.

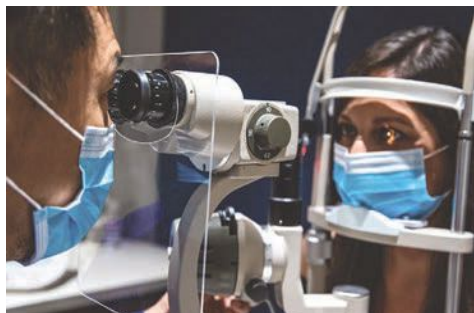

Photo: Brian Chou, OD

**ODs want to be fully recognized for their front-line, primary eye care role and included among Phase 1a distribution of the COVID-19 vaccine nationwide.**

Dr. Chou explains this is an opportunity for smart public health officials to use existing infrastructure to provide a significant public service, such as facilitating herd immunity to end the pandemic.

He also believes most citizens will recognize good reason to construe AB 443—the state’s expanded scope of practice bill that went into effect in January 2018—to permit appropriately trained and certified optometrists to vaccinate against the coronavirus.

“The entire vaccination effort will be an immense undertaking, so I believe it will be an ‘all hands on deck’ call to vaccinate the entire state’s population, especially considering there will be a booster and a second visit to achieve maximal efficacy. Battling COVID-19 has already spurred better and improved approaches on a variety of fronts, and I believe the traditional avenues of vaccination will also get updated,” Dr. Chou says.

Still, he expects the usual opponents of optometric scope expansion to reflexively catastrophize about ODs administering COVID-19 vaccination.

As a nationwide response to the

pandemic and recognizing the need to prepare for a huge public health campaign to vaccinate Americans, government policy leaders are recommending that states evaluate and expand their health care teams with regard to the provision of vaccinations, according to the AOA. The Department of Health and Human Services recently released guidance specifically recommending that states “assess the provider types that can administer immunizations” and “consider whether there should be expansions of providers, including mass immunizers.”

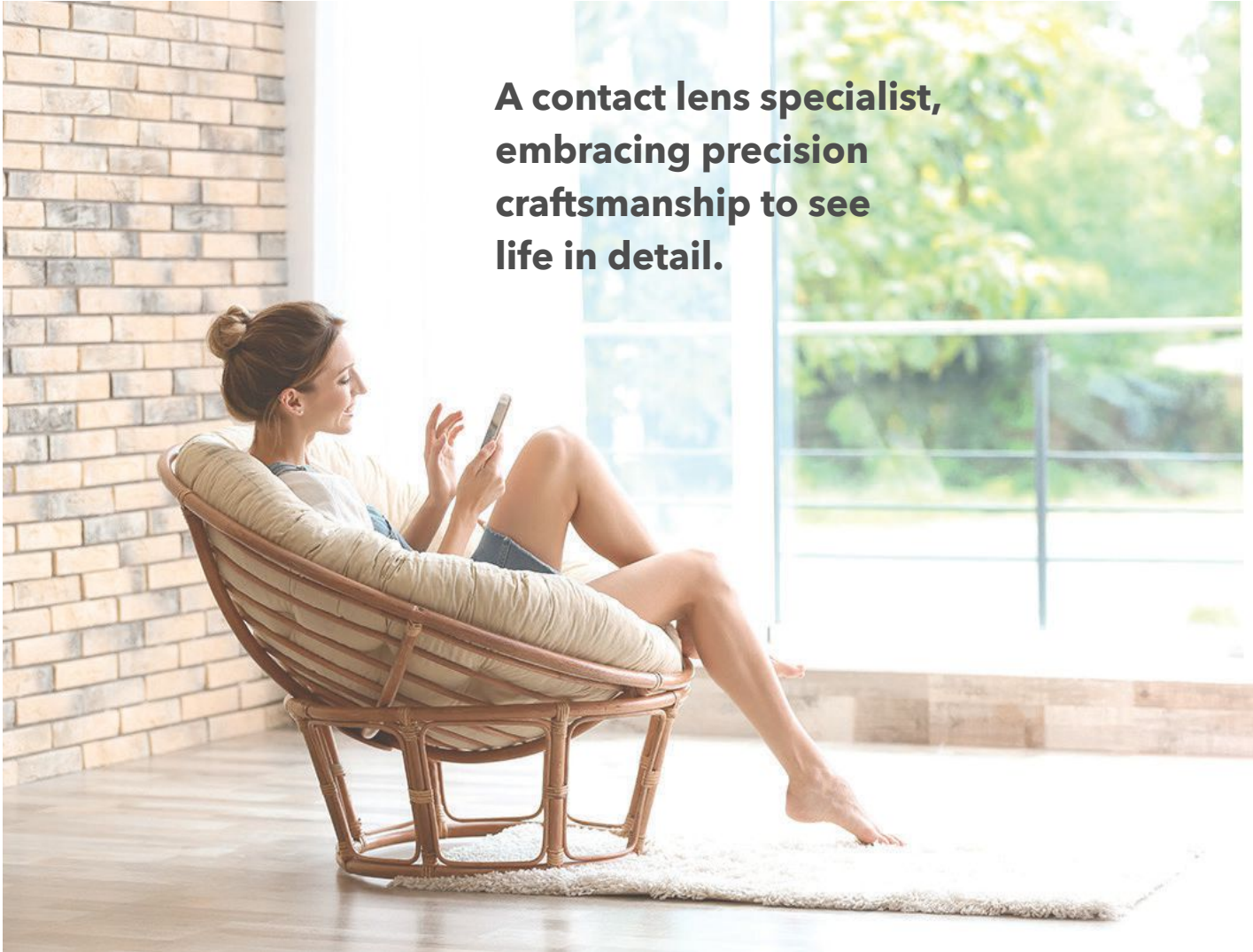Providing vaccination is part of the scope of practice for doctors of optometry in California, the AOA points out.

“As the nation’s focus pivots to the promise of a COVID-19 vaccine, doctors of optometry can serve as a critical resource and support to states as they develop immunization plans and protocols,” the AOA wrote in a statement. “The more-than-46,000 doctors of optometry who deliver more than 80% of primary eye care in America are well positioned to increase the public’s access to immunizations.”

Additionally, the AOA and affiliates are working with state authorities to ensure doctors of optometry are fully recognized for their front-line, primary eye health care provider role and consequently included among the Phase 1a distribution of the COVID-19 vaccine nationwide.

Bluth R. Kaiser Health News/NBC News. When coronavirus vaccines are ready, dentists, optometrists may give shots. [www.nbcnews.com/health/health-news/when-coronavirus-vaccines-are-ready-dentists-optometrists-may-give-shots-n1249010?cid=sm\\_npd\\_nn\\_tw\\_ma](http://www.nbcnews.com/health/health-news/when-coronavirus-vaccines-are-ready-dentists-optometrists-may-give-shots-n1249010?cid=sm_npd_nn_tw_ma). November 30, 2020.





**A contact lens specialist,  
embracing precision  
craftsmanship to see  
life in detail.**



**Menicon is a contact lens  
manufacturer born in Japan.**

For over 60 years, Menicon has been a pioneer in contact lens innovation, delivering groundbreaking contact lenses and lens care solutions across the globe.

To learn more, visit: [www.meniconamerica.com](http://www.meniconamerica.com)

## DR Staging System Outdated, Experts Say

Our understanding of diabetic retinopathy (DR) has increased dramatically with the availability of new information and advent of new technology. However, the original diabetic retinal disease staging system, developed over five decades ago, has not been updated to reflect these advancements. A group of retina subspecialists argued for an update to DR staging protocols in a recent editorial published in *Ophthalmology*.

Both the ETDRS and international DR grading scales can predict disease progression to sight-threatening outcomes, the authors noted, but they are limited in their overall capabilities. The severity scales evaluate the vascular component of DR without taking the peripheral retina into account. They are unable to measure pathophysiologic or neurodegenerative changes prior to DR presentation or document neovascularization changes in proliferative DR. Further, they cannot assess the visual effectiveness of different DR treatments or grade the severity of diabetic

macular edema, a common cause of vision loss in diabetic patients.

Knowing that failure to address these shortcomings could have devastating visual effects, the authors recommended incorporating more validated assessments to improve our ability to diagnose the disease, detect progression and treat accordingly for the best visual outcomes.

The team noted that a revised staging system should target vision loss risk, patient quality of life, prognosis prediction and therapy response. “Ideally, an updated staging system will address retinal, neural and vascular pathology and their contributions to visual function in the context of systemic influences, such as diabetes type, glycemic control, blood pressure, renal disease and anemia,” the editorial stated.

The authors highlighted the importance of testing different variables for inclusion in the new system. Joseph Pizzimenti, OD, an expert in retina care and systemic disease, echoes that sentiment. “It is true that there are some limitations

to current DR staging systems,” he says. “Any new scale needs to be based on the most rigorous, recent clinical research evidence.” Dr. Pizzimenti acknowledges the breadth of the data and suggests an app-based staging system with a simple-to-use interface for optimal results.

A multidimensional, comprehensive approach could reveal phenotypic variability not offered by the current grading scales and provide patient-specific information to guide DR management.

“The road toward developing and implementing an updated staging system for DR will necessitate involvement of multiple stakeholders, including scientists, clinicians, regulatory agencies and patients,” the editorial concluded. “The ultimate test of the system’s value will lie in demonstrating measurable benefits to patients with diabetes and improvement in functional outcomes for this vulnerable population.”

Sun JK, Aiello LP, Abramoff MD, et al. Updating the staging system for diabetic retinal disease. *Ophthalmology*. November 17, 2020. [Epub ahead of print].

## Tear Breakup Patterns Key to DED Treatment

Ocular surface inflammation may be the core problem for dry eye disease (DED) patients who have dot-like tear film breakup patterns, new research proposed. The researchers also suggested that DED subjects with a more random pattern will likely have signs and symptoms related to tear film instability.

The investigation included 91 DED patients divided into two groups: 37 individuals with a dot breakup pattern and 54 with a random breakup pattern.

Those with the dot breakup pattern had a statistically shorter tear film breakup time and a higher Oxford stain score than those with a random pattern. While the Ocular Surface Disease Index scores did not differ between groups, patients with dot breakup patterns had more severe dry eye and a higher concentration of inflammatory cytokines in their tears.

DED patients with the dot breakup pattern should be treated primarily with interventions suitable for ocular surface inflammation,

with a focus on corneal epithelial cell regeneration, the investigators suggested.

By contrast, patients in the random pattern group had relatively low corneal staining scores and smoother corneal surfaces. Since the mechanism of dry eye in these patients was related to the tear film, the authors proposed that treatment should focus on stabilizing this region. ■

Eom HD, Jung JU, Lee KP, et al. Simplified classification of tear film break-up patterns and their clinicopathological correlations in patients with dry eye disease. *Eye Contact Lens*. May 14, 2020. [Epub ahead of print].

**NOW  
APPROVED!** COMING  
SOON

  
**EYSUVIS**<sup>™</sup>  
(loteprednol etabonate  
ophthalmic suspension) 0.25%

  
kala  
PHARMACEUTICALS

# Stem Cell Therapy Might Regrow Stroma

Corneal transplants make up the bulk of human tissue transplants today, but the increasing demand for donor tissue and risks of suboptimal outcomes, immune rejection and graft failure have spurred researchers to investigate other options—namely, stromal stem cell therapy.

A recent paper summarized the available preclinical and clinical evidence on this treatment option and reported that a few types of cellular therapy show promise for stromal regeneration and corneal thickness enhancement.

**Preclinical studies:**

### *Collagen-based scaffolds.*

Decellularized corneal stroma is the most promising current approach. Multiple sections can be obtained from a single donor cornea, including xenogenic donors such as pigs. These decellularized sections have been recellularized with adipose-derived human adult stem cells in animal studies. In both preclinical and clinical studies, transplanted cells survived and differentiated into corneal keratocytes and integrated completely with the implant to mimic natural corneal strength and transparency with no rejection episodes. However, the researchers noted this approach is limited by the need for donor tissue. Synthetic scaffolds, however, don't require human donor tissue, but laboratory production costs are high, and they fall short of mimicking the transparency and strength of human corneas.

**Stem cell therapy without scaffolds.** This model aims to generate new extracellular corneal matrices within the corneal stroma without a scaffold. Different approaches in-

clude direct intrastromal transplantation and implantation at the ocular surface, intravenously or in the anterior chamber. Differentiation was successful with autologous, adipose-derived human adult stem cells in keratoconus. Clinical and preclinical evidence has shown that direct intrastromal implantation of mesenchymal stem cells within the cornea results in production of the extracellular corneal matrix but not in quantities sufficient to restore corneal thickness in advanced keratoconus.

**Mesenchymal stem cell exosomes.** These secrete paracrine factors like VEGF that promote cell migration and keratocyte survival. Studies hypothesize that direct treatment with these exosome growth factors can provide the benefits of cellular therapy without the cellular component itself. One study found that exosomes in culture media had immunosuppressive properties that significantly reduced stromal scarring *in vivo*. The authors noted that “the use of mesenchymal stem cell exosomes (without their cellular component) could overcome some of the limitations and risks associated with the direct delivery of stem cells to humans *in vivo* if exosomes could be applied topically.”

**Clinical studies:**

**Femto-assisted refractive stromal lenticule addition.** The popularity of SMILE procedures has resulted in more widely available corneal donor tissue. One approach involves femto-assisted, small-incision, sutureless, intrastromal lamellar keratoplasty as an alternative to corneal transplantation. The stromal lenticule addition in this procedure resulted in

improved visual acuity, a thicker lenticule and a reduction of 7.00D in the max keratometry reading, one study reported. “This procedure increases corneal thickness, providing additional strength to the weakened cornea and anterior corneal flattening when using a negative, meniscus-shaped lenticule,” the authors said. It's also been shown to induce corneal reinnervation.

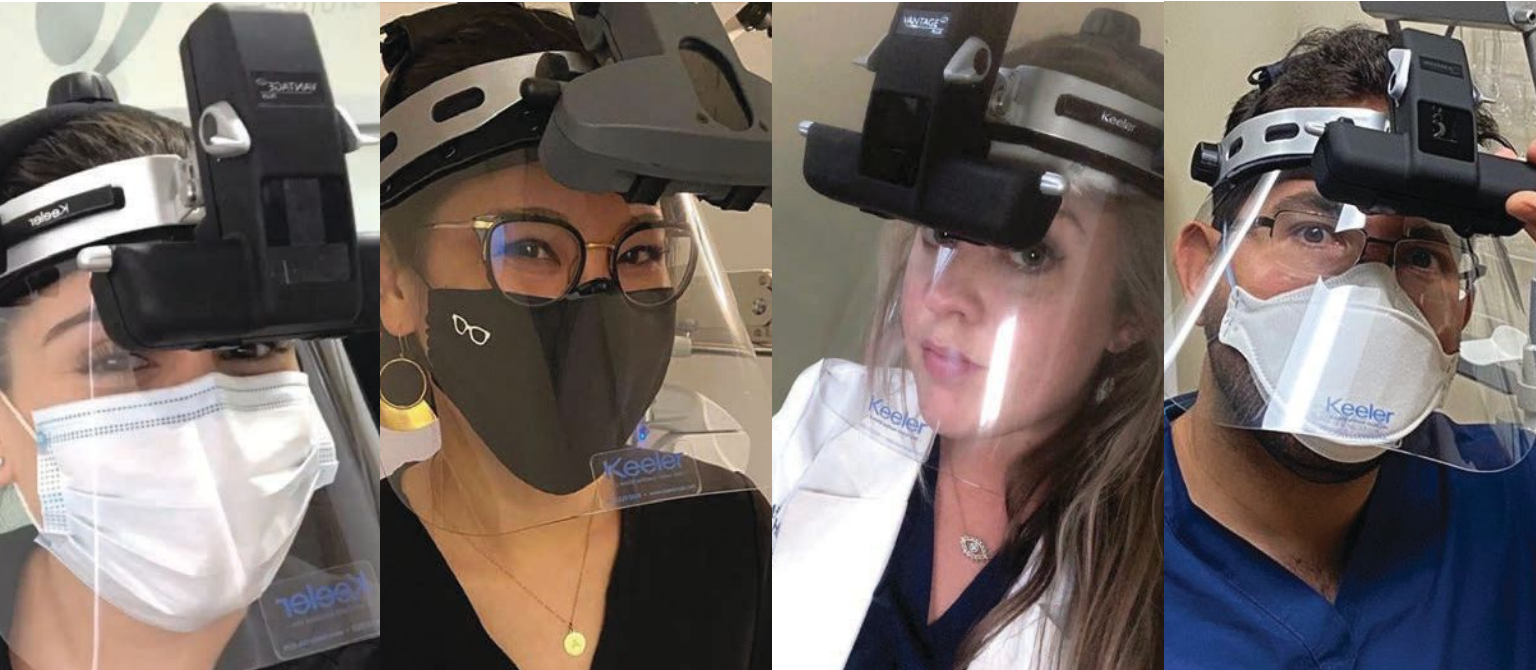**Stromal stem cell therapy for advanced keratoconus.** In one study, autologous, adipose-derived human adult stem cells were implanted in patients with advanced keratoconus. Tissue was obtained with liposuction and cultured. Each affected eye received an injection of the cultured cells in a buffered solution in the stromal pocket. During the three-year follow-up period, no haze or infection was observed, and patients recovered full transparency within the first day post-op. All cases continued to improve, with increased cell density over 12 months and statistically significant increases in the anterior, mid and posterior surfaces of decellularized and recellularized lamellas in the anterior and posterior host stroma.

The researchers concluded that implantation of autologous, adipose-derived human adult stem cells, decellularized human corneal stroma and allogenic SMILE lenticule corneal inlays may be effective therapies for keratoconus. Corneal stromal regeneration and corneal thickness enhancement are the strongest options for corneal stroma therapy, they noted.

Zarif ME, Alió del Barrio JL, Arnalich-Montiel F, et al. Corneal stroma regeneration: new approach for the treatment of cornea disease. *Asia Pac J Ophthalmol* (Phila). November 11, 2020. [Epub ahead of print].



# Helping Heroes See Clear And Stay Safe



The Vantage BIO is great for ROP screening! It's lightweight, has settings for different pupil sizes, a cool, white LED light and the longest battery ever!!"

**Dra. Paulina Ramirez Neria**



I'm a big fan of the All Pupil BIO. I had issues with other models so when I started [my practice], I knew the All Pupil would be my go-to BIO...I greatly appreciate the new custom fit Keeler BIO shields as an added safety layer."

**Dr. Annie Bacon**



I chose my [Vantage Plus] for the optics and value...with other brands, I had difficulty focusing up close during my dilated fundus exams. [The oculars] made my eyes feel more relaxed, and I felt like my view was better."

**Dr. Michelle Hammond**



[I've] been seeing emergent and urgent cases every day during the COVID19 pandemic. I really like [the Vantage BIO] because [it's a] very good quality and provides a super clear view."

**Dr. Reza Moradi**

Choose one of the programs below when you purchase a BIO\* between **September 1, 2020 and March 31, 2021**

\*this program is valid for our wireless indirects: All Pupil II and Vantage Plus

1

RECEIVE A



**\$850**

credit towards any PPE

2

24-MONTH

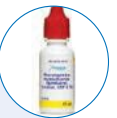**0%**

lease as low as \$128/month\*

\*All Pupil II: \$127.92/month; Vantage Plus: \$155/month (shipping and taxes not included).

3

RECEIVE



**10 FREE**

bottles of phenylephrine 2.5%, 15mL

**\*Leasing may also be combined with the PPE credit OR the phenylephrine option.**

Contact us at 800-523-5620 or customerservice@keelerusa.com to learn more or place your order. This promo cannot be combined with any other Keeler offers.

**Keeler**

- A world without vision loss -

www.keelerusa.com • 3222 Phoenixville Pike - Bldg. #50 • Malvern, PA 19355  
Tel No: 1-610-353-4350 • Toll Free: 1-800-523-5620 • Fax: 1-610-353-7814

A Halma company

## Good News For Coffee Drinkers

Two studies recently discovered the possible protective effects of drinking coffee: one determined that caffeine intake prior to cataract surgery significantly decreased UV-induced apoptosis of lens epithelial cells, and the other noted that healthy coffee drinkers can have lower intraocular pressure (IOP).

### Cataract Onset Delay

Researchers in Vienna have noted a protective effect of caffeine consumption on ultraviolet radiation (UVR)-induced apoptosis in lens epithelial cells *in vitro*.<sup>1</sup> They believe their findings back results from other epidemiological studies that also reported a protective effect of caffeine consumption on age-related cataract.

The study enrolled 20 patients who underwent cataract surgery in both eyes and abstained from caffeine for two weeks, starting one week prior to surgery of the first eye. The second eye was scheduled one week after the first. On the day of the second procedure, patients were given coffee containing 180mg

of caffeine shortly before surgery. A team transferred lens capsules containing epithelial cells, which were harvested after capsulorhexis, to a culture dish and immediately exposed them to UVR. They then analyzed the apoptotic lens epithelial cells by TUNEL staining 24 hours after UVR exposure.

While the researchers detected TUNEL-positive cells in UVR-exposed lens capsules both after caffeine intake and in controls, epithelial cells after caffeine intake showed significantly less TUNEL staining than cells without caffeine intake.<sup>1</sup>

The study pointed out that other antioxidant compounds of coffee might have boosted the protective effect of caffeine. Nevertheless, the authors concluded that caffeine might have a significant impact on delaying the onset of age-related cataract and recommended further epidemiological studies to confirm their findings.<sup>1</sup>

### IOP Reduction

Researchers from Kyoto, Japan, noted an association between

frequent coffee consumption and lower IOP in patients without glaucoma.<sup>2</sup> Habitual coffee consumption was not significantly associated with glaucoma.

In 9,418 study participants without glaucoma, the average IOP of both eyes was 14.7mm Hg. All participants underwent a standardized ophthalmic exam and completed a self-reported questionnaire.

The researchers' analysis revealed that habitual coffee consumption was significantly associated with reduced IOP. The IOP of the group that consumed coffee more frequently (three times a day or more) was 0.4mm Hg lower than that of the group that consumed coffee less frequently (less than once a day).<sup>2</sup>

The researchers concluded that additional experimental studies would help examine the effects of coffee on IOP and glaucoma risk.<sup>2</sup>

1. Kronschläger M, Ruit M, Dechat T, et al. Single high-dose peroral caffeine intake inhibits ultraviolet radiation-induced apoptosis in human lens epithelial cells *in vitro*. *Acta Ophthalmol*. October 30, 2020. [Epub ahead of print].

2. Nakano E, Miyake M, Hosada Y, et al. Relationship between intraocular pressure and coffee consumption in a Japanese population without glaucoma: the Nagahama study. *Ophthalmology*. November 5, 2020. [Epub ahead of print].

## COVID-19 Patients Face Retinal Changes

People who recovered from COVID-19 displayed alterations in their retinal microvasculature, including a significantly lower vessel density in the superficial and deep retinal capillary plexus, researchers recently reported.

This study included 31 recovered COVID-19 patients and 23 controls who underwent OCT angiography.

The team observed significantly lower mean superficial (44.98 vs. 48.36) and deep (49.74 vs. 53.03)

vessel densities of the foveal and parafoveal regions in the study cohort compared with controls. Within the study cohort, mean vessel density and foveal avascular zone (FAZ) area were lower in patients with a history of COVID-19 hospitalization but did not reach statistical significance.

The researchers noted that the cause of retinal capillary alterations in subjects was unclear but speculated that secondary effects

of inflammation may have played a role.

While they were cautious about drawing broad conclusions about COVID-19 patients as a whole, the team suggested that their findings argue in favor of larger-scale studies to continue to document the potential involvement of the retina in COVID-19. ■

Abrishami M, Emamveridian Z, Shoebli N, et al. Optical coherence tomography angiography analysis of the retina in patients recovered from COVID-19: a case-control study. *Can J Ophthalmol*. November 14, 2020. [Epub ahead of print].

## BRIEF SUMMARY OF PRESCRIBING INFORMATION

This Brief Summary does not include all the information needed to use LOTEMAX<sup>®</sup> SM safely and effectively. See full prescribing information for LOTEMAX<sup>®</sup> SM.

## LOTEMAX<sup>®</sup> SM (loteprednol etabonate ophthalmic gel) 0.38%

For topical ophthalmic use  
Initial U.S. Approval: 1998

### INDICATIONS AND USAGE

LOTEMAX<sup>®</sup> SM is a corticosteroid indicated for the treatment of post-operative inflammation and pain following ocular surgery.

### DOSAGE AND ADMINISTRATION

Invert closed bottle and shake once to fill tip before instilling drops. Apply one drop of LOTEMAX<sup>®</sup> SM into the conjunctival sac of the affected eye three times daily beginning the day after surgery and continuing throughout the first 2 weeks of the post-operative period.

### CONTRAINDICATIONS

LOTEMAX<sup>®</sup> SM, as with other ophthalmic corticosteroids, is contraindicated in most viral diseases of the cornea and conjunctiva including epithelial herpes simplex keratitis (dendritic keratitis), vaccinia, and varicella, in mycobacterial infection of the eye and fungal diseases of ocular structures.

### WARNINGS AND PRECAUTIONS

**Intraocular Pressure (IOP) Increase:** Prolonged use of corticosteroids may result in glaucoma with damage to the optic nerve, defects in visual acuity and fields of vision. Steroids should be used with caution in the presence of glaucoma. If this product is used for 10 days or longer, intraocular pressure should be monitored.

**Cataracts:** Use of corticosteroids may result in posterior subcapsular cataract formation.

**Delayed Healing:** The use of steroids after cataract surgery may delay healing and increase the incidence of bleb formation. In those diseases causing thinning of the cornea or sclera, perforations have been known to occur with the use of topical steroids. The initial prescription and renewal of the medication order should be made by a physician only after examination of the patient with the aid of magnification such as slit lamp biomicroscopy and, where appropriate, fluorescein staining.

**Bacterial Infections:** Prolonged use of corticosteroids may suppress the host response and thus increase the hazard of secondary ocular infections. In acute purulent conditions of the eye, steroids may mask infection or enhance existing infection.

**Viral infections:** Employment of a corticosteroid medication in the treatment of patients with a history of herpes simplex requires great caution. Use of ocular steroids may prolong the course and may exacerbate the severity of many viral infections of the eye (including herpes simplex).

**Fungal Infections:** Fungal infections of the cornea are particularly prone to develop coincidentally with long-term local steroid application. Fungal invasion must be considered in any persistent corneal ulceration where a steroid has been used or is in use. Fungal cultures should be taken when appropriate.

**Contact Lens Wear:** Contact lenses should not be worn when the eyes are inflamed.

### ADVERSE REACTIONS

Because clinical trials are conducted under widely varying conditions, adverse reaction rates observed in the clinical trials of a drug cannot be directly compared to rates in the clinical trials of another drug and may not reflect the rates observed in practice. Adverse reactions associated with ophthalmic steroids include elevated intraocular pressure, which may be associated with infrequent optic nerve damage, visual acuity and field defects, posterior subcapsular cataract formation, delayed wound healing and secondary ocular infection from pathogens including herpes simplex, and perforation of the globe where there is thinning of the cornea or sclera. There were no treatment-emergent adverse drug reactions that occurred in more than 1% of subjects in the three times daily group compared to vehicle.

### USE IN SPECIAL POPULATIONS

**Pregnancy: Risk Summary:** There are no adequate and well controlled studies with loteprednol etabonate in pregnant women. Loteprednol etabonate produced teratogenicity at clinically relevant doses in the rabbit and rat when administered orally during pregnancy. Loteprednol etabonate

produced malformations when administered orally to pregnant rabbits at doses 4.2 times the recommended human ophthalmic dose (RHOD) and to pregnant rats at doses 106 times the RHOD. In pregnant rats receiving oral doses of loteprednol etabonate during the period equivalent to the last trimester of pregnancy through lactation in humans, survival of offspring was reduced at doses 10.6 times the RHOD. Maternal toxicity was observed in rats at doses 1066 times the RHOD, and a maternal no observed adverse effect level (NOAEL) was established at 106 times the RHOD. The background risk of major birth defects and miscarriage for the indicated population is unknown. However, the background risk in the U.S. general population of major birth defects is 2 to 4%, and of miscarriage is 15 to 20%, of clinically recognized pregnancies. Data: Animal Data. Embryofetal studies were conducted in pregnant rabbits administered loteprednol etabonate by oral gavage on gestation days 6 to 18, to target the period of organogenesis. Loteprednol etabonate produced fetal malformations at 0.1 mg/kg (4.2 times the recommended human ophthalmic dose (RHOD) based on body surface area, assuming 100% absorption). Spina bifida (including meningocele) was observed at 0.1 mg/kg, and exencephaly and craniofacial malformations were observed at 0.4 mg/kg (17 times the RHOD). At 3 mg/kg (128 times the RHOD), loteprednol etabonate was associated with increased incidences of abnormal left common carotid artery, limb flexures, umbilical hernia, scoliosis, and delayed ossification. Abortion and embryofetal lethality (resorption) occurred at 6 mg/kg (256 times the RHOD). A NOAEL for developmental toxicity was not established in this study. The NOAEL for maternal toxicity in rabbits was 3 mg/kg/day. Embryofetal studies were conducted in pregnant rats administered loteprednol etabonate by oral gavage on gestation days 6 to 15, to target the period of organogenesis. Loteprednol etabonate produced fetal malformations, including absent innominate artery at 5 mg/kg (106 times the RHOD); and cleft palate, agnathia, cardiovascular defects, umbilical hernia, decreased fetal body weight and decreased skeletal ossification at 50 mg/kg (1066 times the RHOD). Embryofetal lethality (resorption) was observed at 100 mg/kg (2133 times the RHOD). The NOAEL for developmental toxicity in rats was 0.5 mg/kg (10.6 times the RHOD). Loteprednol etabonate was maternally toxic (reduced body weight gain) at 50 mg/kg/day. The NOAEL for maternal toxicity was 5 mg/kg. A peri-/postnatal study was conducted in rats administered loteprednol etabonate by oral gavage from gestation day 15 (start of fetal period) to postnatal day 21 (the end of lactation period). At 0.5 mg/kg (10.6 times the clinical dose), reduced survival was observed in live-born offspring. Doses  $\geq$  5 mg/kg (106 times the RHOD) caused umbilical hernia/incomplete gastrointestinal tract. Doses  $\geq$  50 mg/kg (1066 times the RHOD) produced maternal toxicity (reduced body weight gain, death), decreased number of live-born offspring, decreased birth weight, and delays in postnatal development. A developmental NOAEL was not established in this study. The NOAEL for maternal toxicity was 5 mg/kg.

**Lactation:** There are no data on the presence of loteprednol etabonate in human milk, the effects on the breastfed infant, or the effects on milk production. The developmental and health benefits of breastfeeding should be considered, along with the mother's clinical need for LOTEMAX<sup>®</sup> SM and any potential adverse effects on the breastfed infant from LOTEMAX<sup>®</sup> SM.

**Pediatric Use:** Safety and effectiveness of LOTEMAX<sup>®</sup> SM in pediatric patients have not been established.

**Geriatric Use:** No overall differences in safety and effectiveness have been observed between elderly and younger patients.

### NONCLINICAL TOXICOLOGY

**Carcinogenesis, Mutagenesis, Impairment of Fertility:** Long-term animal studies have not been conducted to evaluate the carcinogenic potential of loteprednol etabonate. Loteprednol etabonate was not genotoxic *in vitro* in the Ames test, the mouse lymphoma tk assay, or in the chromosomal aberration test in human lymphocytes, or *in vivo* in the mouse micronucleus assay. Treatment of male and female rats with 25 mg/kg/day of loteprednol etabonate (533 times the RHOD based on body surface area, assuming 100% absorption) prior to and during mating caused preimplantation loss and decreased the number of live fetuses/live births. The NOAEL for fertility in rats was 5 mg/kg/day (106 times the RHOD).

LOTEMAX is a trademark of Bausch & Lomb Incorporated or its affiliates.

© 2019 Bausch & Lomb Incorporated

Bausch + Lomb, a division of Valeant Pharmaceuticals North America LLC  
Bridgewater, NJ 08807 USA

LSM.0091.USA.19

Based on 9669600-9669700

Revised: 02/2019



# SUBMICRON STRONG

for

POTENCY + PROVEN STRENGTH<sup>1,2</sup>

2× greater inflammation clearance  
as compared to vehicle<sup>2\*</sup>

## SM TECHNOLOGY™

- Engineered with SM Technology™ for efficient penetration at a low BAK level (0.003%)<sup>1,3</sup>
- ~2× greater penetration to the aqueous humor than LOTEMAX® GEL (loteprednol etabonate ophthalmic gel) 0.5%<sup>3</sup>

Clinical significance of these preclinical data has not been established.

## LOTEMAX® SM

(loteprednol etabonate  
ophthalmic gel) 0.38%

**SMALL & MIGHTY**  
SUBMICRON PARTICLES

### \*PROVEN STRENGTH

- 30% of LOTEMAX® SM patients had complete ACC resolution vs vehicle (15%) at Day 8 (N=371,  $P < 0.0001$ )<sup>1,2†</sup>
- 74% of LOTEMAX® SM patients were completely pain-free vs vehicle (49%) at Day 8 (N=371,  $P < 0.0001$ )<sup>1,2‡</sup>

†Pooled analysis of Phase 3 clinical studies. **Study 1:** 29% LOTEMAX® SM (N=171) vs 9% vehicle (N=172). **Study 2:** 31% LOTEMAX® SM (N=200) vs 20% vehicle (N=199);  $P < 0.05$  for all.

‡Pooled analysis of Phase 3 clinical studies. **Study 1:** 73% LOTEMAX® SM (N=171) vs 48% vehicle (N=172). **Study 2:** 76% LOTEMAX® SM (N=200) vs 50% vehicle (N=199);  $P < 0.05$  for all.

## Indication

LOTEMAX® SM (loteprednol etabonate ophthalmic gel) 0.38% is a corticosteroid indicated for the treatment of post-operative inflammation and pain following ocular surgery.

## Important Safety Information

- LOTEMAX® SM, as with other ophthalmic corticosteroids, is contraindicated in most viral diseases of the cornea and conjunctiva including epithelial herpes simplex keratitis (dendritic keratitis), vaccinia, and varicella, and also in mycobacterial infection of the eye and fungal diseases of ocular structures.
- Prolonged use of corticosteroids may result in glaucoma with damage to the optic nerve, defects in visual acuity and fields of vision. Steroids should be used with caution in the presence of glaucoma. If LOTEMAX® SM is used for 10 days or longer, IOP should be monitored.
- Use of corticosteroids may result in posterior subcapsular cataract formation.

## BAUSCH+LOMB

©/TM are trademarks of Bausch & Lomb Incorporated or its affiliates.

© 2019 Bausch & Lomb Incorporated or its affiliates. All rights reserved. Printed in USA. LSM.0206.USA.19

## Important Safety Information (cont.)

- The use of steroids after cataract surgery may delay healing and increase the incidence of bleb formation. In those with diseases causing thinning of the cornea or sclera, perforations have been known to occur with the use of topical steroids. The initial prescription and renewal of the medication order should be made by a physician only after examination of the patient with the aid of magnification such as slit lamp biomicroscopy and, where appropriate, fluorescein staining.
- Prolonged use of corticosteroids may suppress the host response and thus increase the hazard of secondary ocular infections. In acute purulent conditions, steroids may mask infection or enhance existing infections.
- Employment of a corticosteroid medication in the treatment of patients with a history of herpes simplex requires great caution. Use of ocular steroids may prolong the course and may exacerbate the severity of many viral infections of the eye (including herpes simplex).
- Fungal infections of the cornea are particularly prone to develop coincidentally with long-term local steroid application. Fungus invasion must be considered in any persistent corneal ulceration where a steroid has been used or is in use. Fungal cultures should be taken when appropriate.
- Contact lenses should not be worn when the eyes are inflamed.
- There were no treatment-emergent adverse drug reactions that occurred in more than 1% of subjects in the three times daily group compared to vehicle.

You are encouraged to report negative side effects of prescription drugs to the FDA. Visit [www.fda.gov/medwatch](http://www.fda.gov/medwatch) or call 1-800-FDA-1088.

Please see brief summary of Prescribing Information on adjacent page.

References: 1. LOTEMAX SM Prescribing Information. Bausch & Lomb Incorporated. 2. Data on file. Bausch & Lomb Incorporated. 3. Cavet ME, Glogowski S, Lowe ER, Phillips E. Rheological properties, dissolution kinetics, and ocular pharmacokinetics of loteprednol etabonate (submicron) ophthalmic gel 0.38%. *J Ocul Pharmacol Ther*. 2019. doi: 10.1089/jop.2019.35(5):291-300.

Discover more at  
[www.LOTEMAXSM.com](http://www.LOTEMAXSM.com)

## LOTEMAX® SM

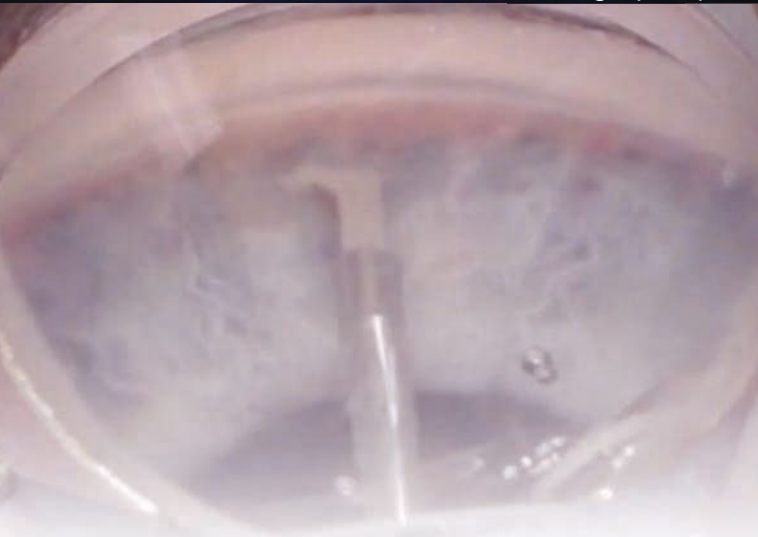
(loteprednol etabonate  
ophthalmic gel) 0.38%



# Contents

Review of Optometry, December 15, 2020

26th Annual Surgery Report



## 38 Pearls of Postoperative Care

Know the different strategies associated with each type of procedure, and be aware of potential complications.

By Andrew Mackner, OD, and Huy Do, OD, MEd

## 48 To Infinity and Beyond LASIK: A Refractive Surgery Update

Here's what you need to know about the new procedures that are expanding patients' options and improving visual outcomes.

By Bobby Saenz, OD, MS, and Mitch Ibach, OD

## 42 Meet the New Trifocal IOL

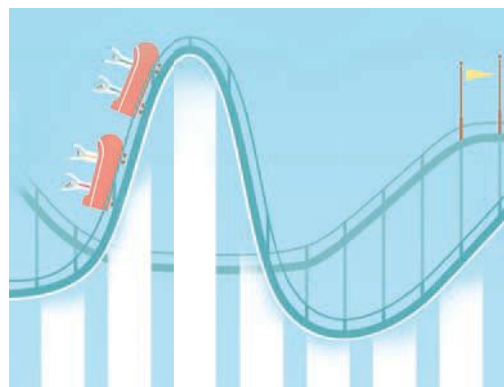
The most recent addition to the market is expanding the candidate pool for multifocal IOLs.

By Oliver Kuhn-Wilken, OD

## 54 MIGS: Indications and Complications

Optometrists can be the gatekeepers of this procedure. Here's what you need to know to refer properly and care for the post-op patient.

By Shradha Sanghvi Parikh, OD, and Elizabeth Warren Cody, OD



## 32 2020 Income: Riding the COVID Roller Coaster

Once-steady practice revenue lurched wildly this year, facing unexpected jolts at every turn. Has its course steadied yet?

By Catherine Manthorp, Associate Editor

# Departments

Review of Optometry December 15, 2020

## 5 News Review

### 18 Outlook

Subject to Change

JACK PERSICO

### 20 Through My Eyes

How to Pick the Right Surgeon

PAUL M. KARPECKI, OD

### 22 Chairside

The Fun Never Ends

MONTGOMERY VICKERS, OD

### 24 Clinical Quandaries

Shield Your Eyes

PAUL C. AJAMIAN, OD

### 26 Focus on Refraction

Buff Up Your Buffers

MARC B. TAUB, OD, MS,  
AND PAUL HARRIS, OD

### 31 Coding Connection

Comanagement Goes Premium

JOHN RUMPAKIS, OD, MBA

### 60 Cornea + Contact Lens Q&A

It's in the Way That You Use It

JOSEPH P. SHOVLIN, OD

### 62 Glaucoma Grand Rounds

Play it Safe

JAMES L. FANELLI, OD

### 64 Retina Quiz

Mellow Yellow

MARK T. DUNBAR, OD

### 66 Therapeutic Review

Reconsidering LPI

JOSEPH W. SOWKA, OD

### 68 Surgical Minute

Combo Platter

HALEE ALLEMAN, OD,  
DEREK N. CUNNINGHAM, OD,  
AND WALTER O. WHITLEY, OD, MBA

### 70 Product Review

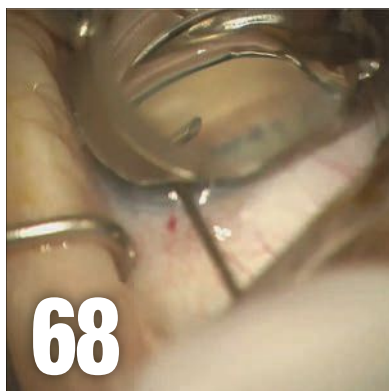
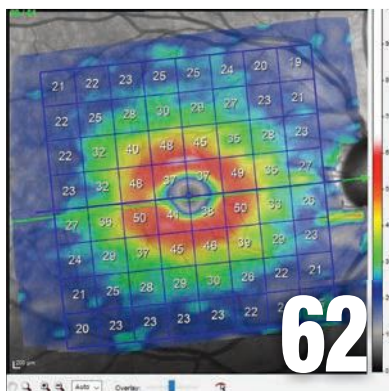
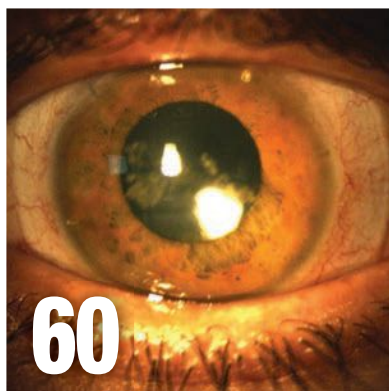
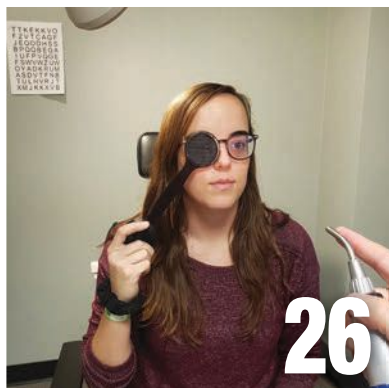### 71 Advertisers Index

### 72 Classifieds

### 74 Diagnostic Quiz

Field a Guess

ANDREW S. GURWOOD, OD



**REVIEW**  
OF OPTOMETRY

#### BUSINESS OFFICES

19 CAMPUS BLVD., SUITE 101  
NEWTOWN SQUARE, PA 19073

#### EXECUTIVE DIRECTOR

JAMES HENNE  
(610) 492-1017 • JHENNE@JOBSON.COM

#### PUBLISHER

MICHAEL HOSTER  
(610) 492-1017 • MHOSTER@JOBSON.COM

#### REGIONAL SALES MANAGER

MICHELE BARRETT  
(610) 492-1014 • MBARRETT@JOBSON.COM

#### REGIONAL SALES MANAGER

JONATHAN DARDINE  
(610) 492-1030 • JDARDINE@JOBSON.COM

#### VICE PRESIDENT, CLINICAL CONTENT

PAUL M. KARPECKI, OD, FAAO  
PKARPECKI@JOBSON.COM

#### PRODUCTION MANAGER

FARRAH APONTE  
(212) 274-7057 • FAPONTE@JOBSON.COM

#### SENIOR CIRCULATION MANAGER

HAMILTON MAHER  
(212) 219-7870 • HMAHER@JHIHEALTH.COM

#### CLASSIFIED ADVERTISING

(888) 498-1460

#### SUBSCRIPTIONS

\$56 A YEAR, \$88 (US) IN CANADA,  
\$209 (US) IN ALL OTHER COUNTRIES.

#### SUBSCRIPTION INQUIRIES

(877) 529-1746 (US ONLY)  
OUTSIDE US CALL: (845) 267-3065

#### CIRCULATION

PO Box 81  
CONGERS, NY 10920  
TEL: (TOLL FREE): (877) 529-1746  
OUTSIDE US: (845) 267-3065

CEO, INFORMATION SERVICES GROUP  
MARC FERRARA

SENIOR VICE PRESIDENT, OPERATIONS  
JEFF LEVITZ

VICE PRESIDENT, HUMAN RESOURCES  
TAMMY GARCIA

VICE PRESIDENT, CREATIVE SERVICES & PRODUCTION  
MONICA TETTAMANZI

CORPORATE PRODUCTION DIRECTOR  
JOHN ANTHONY CAGGIANO

CIRCULATION DIRECTOR  
JARED SONNERS



# The Latest Dry Eye Technology

Exclusively from Marco

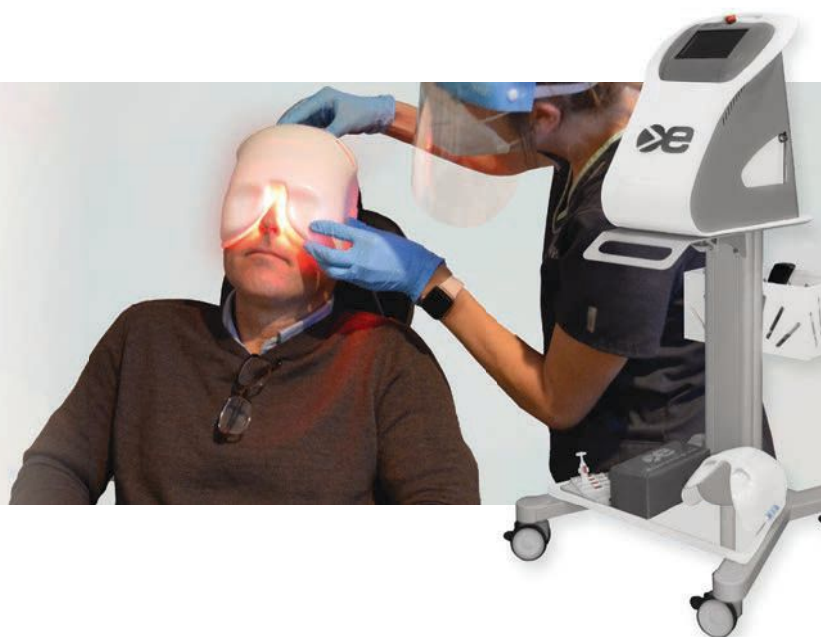

**Become a Dry Eye Center of Excellence** with innovative technology from Marco. Effectively diagnose and treat dry eye in your patients and **generate additional revenue streams** for your practice.

## Equinox Low Level Light Therapy

Developed by NASA, LLLT has proven effective at treating dry eye disease. LLLT uses specially designed LED lights to gently warm up the eyelids, causing the meibomian glands to unclog and release oils.

- » Comfortable, non-invasive MGD Treatment
- » Endogenous heating of meibomian glands
- » Low cost per patient
- » Complementary to your other devices



## Phoenix Dry Eye Workstation with Topography

The Phoenix Meibography Workstation with Topography gives a dynamic view of non-invasive tear film break-up time with tear meniscus height imaging and measurement.

- » Meibomian glands imaging and analysis
- » Imaging of the tear film dynamics
- » Interactive dry eye reports and graphs for easier diagnosis and patient education



Let us show you what's possible. **Contact Marco First.**

800.874.5274 | MARCO.COM



PRINTED IN USA

**FOUNDING EDITOR, FREDERICK BOGER**  
1891-1913

**EDITORIAL OFFICES**  
19 CAMPUS BLVD., SUITE 101  
NEWTOWN SQUARE, PA 19073

**SUBSCRIPTION INQUIRIES**  
1-877-529-1746

**CONTINUING EDUCATION INQUIRIES**  
1-800-825-4696

**EDITOR-IN-CHIEF • JACK PERSICO**  
(610) 492-1006 • JPERSICO@JOBSON.COM

**ASSOCIATE EDITOR • CATHERINE MANTHORP**  
(610) 492-1043 • CMANTHORP@JOBSON.COM

**ASSOCIATE EDITOR • MARK DE LEON**  
(610) 492-1021 • MDELEON@JOBSON.COM

**SPECIAL PROJECTS MANAGER • JILL GALLAGHER**  
(610) 492-1037 • JGALLAGHER@JOBSON.COM

**ART DIRECTOR • JARED ARAUJO**  
(610) 492-1032 • JARAUIJO@JOBSON.COM

**DIRECTOR OF CE ADMINISTRATION • REGINA COMBS**  
(212) 274-7160 • RCOMBS@JOBSON.COM

**EDITORIAL BOARD**

**CHIEF CLINICAL EDITOR • PAUL M. KARPECKI, OD**

**ASSOCIATE CLINICAL EDITORS • JOSEPH P. SHOVLIN, OD;**  
**CHRISTINE W. SINDT, OD**

**DIRECTOR OPTOMETRIC PROGRAMS • ARTHUR EPSTEIN, OD**

**CLINICAL & EDUCATION CONFERENCE ADVISOR**  
**PAUL M. KARPECKI, OD**

**CASE REPORTS COORDINATOR • ANDREW S. GURWOOD, OD**

**CLINICAL CODING EDITOR • JOHN RUMPAKIS, OD, MBA**

**COLUMNISTS**

**CHAIRSIDE • MONTGOMERY VICKERS, OD**

**CLINICAL QUANDARIES • PAUL C. AJAMIAN, OD**

**CODING CONNECTION • JOHN RUMPAKIS, OD**

**CORNEA & CONTACT LENS Q+A • JOSEPH P. SHOVLIN, OD**

**DIAGNOSTIC QUIZ • ANDREW S. GURWOOD, OD**

**THE ESSENTIALS • BISANT A. LABIB, OD**

**FOCUS ON REFRACTION • MARC TAUB, OD;**  
**PAUL HARRIS, OD**

**GLAUCOMA GRAND ROUNDS • JAMES L. FANELLI, OD**

**OCULAR SURFACE REVIEW • PAUL M. KARPECKI, OD**

**RETINA QUIZ • MARK T. DUNBAR, OD**

**SURGICAL MINUTE • DEREK N. CUNNINGHAM, OD;**  
**WALTER O. WHITLEY, OD, MBA**

**THERAPEUTIC REVIEW • JOSEPH W. SOWKA, OD**

**THROUGH MY EYES • PAUL M. KARPECKI, OD**

**URGENT CARE • RICHARD B. MANGAN, OD**

**JOBSON MEDICAL INFORMATION LLC**



**Outlook**

By Jack Persico, Editor-in-Chief



**Subject to Change**

Optometry's response to the pandemic showcases its strengths, and maybe its future.

One of the more unique projects we do at *Review* is the annual compendium of educational meetings that's enclosed with this issue, known as *The Conference Planner*. We talk to every CE provider we can find and ask what they have in store for the year ahead. Every year, I marvel at the breadth of optometric education available, from small meetings offering just one or two credits for a handful of people to the big, sprawling conferences that attract thousands.

This year was different, to say the least. Of all the facets of the profession altered or sidelined by the pandemic, hardest hit was probably live education. There hasn't been a major in-person optometric event since SECO concluded in early March, on the eve of the lockdown. In the weeks that followed, plans for in-person meetings kept getting knocked off one after another like the characters in a murder mystery. Would any survive to the end of the 2020 story? No, as it turned out.

Heading into 2021, the CE planners we talked to conveyed both a sense of frustration at the uncertainty they still face, but also a measure of confidence that their contingency plans will see them—and you—through. Everyone seems ready to go but poised to switch gears ASAP if needed. I can't tell you how many times we appended a listing in the 2021 *Conference Planner* with the fateful words "subject to change" or "to be determined" but, trust me, it was a lot.

With encouraging news about vaccines offering a realistic chance

that, by summer, in-person events won't be a white-knuckle experience, there's cause for optimism as we turn the page on 2020. Still, I wonder if some of the changes wrought by the pandemic will persist. Much of the response was improvised on the fly, but it also had the effect of accelerating developments that were already in motion. Telehealth consults, online dispensing and virtual CE all got a "baptism by fire" in 2020.

I think some online experiences will co-exist with traditional methods even once the pandemic has passed, especially in continuing education. When the Academy of Optometry switched its annual meeting to virtual, it was able to preserve seemingly the entire program—even the social events. And, tellingly, the potential audience expanded exponentially. The AAO told us its meeting usually has attendees from about 15 countries participate; in 2020, the virtual meeting brought in people from 55 countries.

Suddenly, it seems, optometry has gone global.

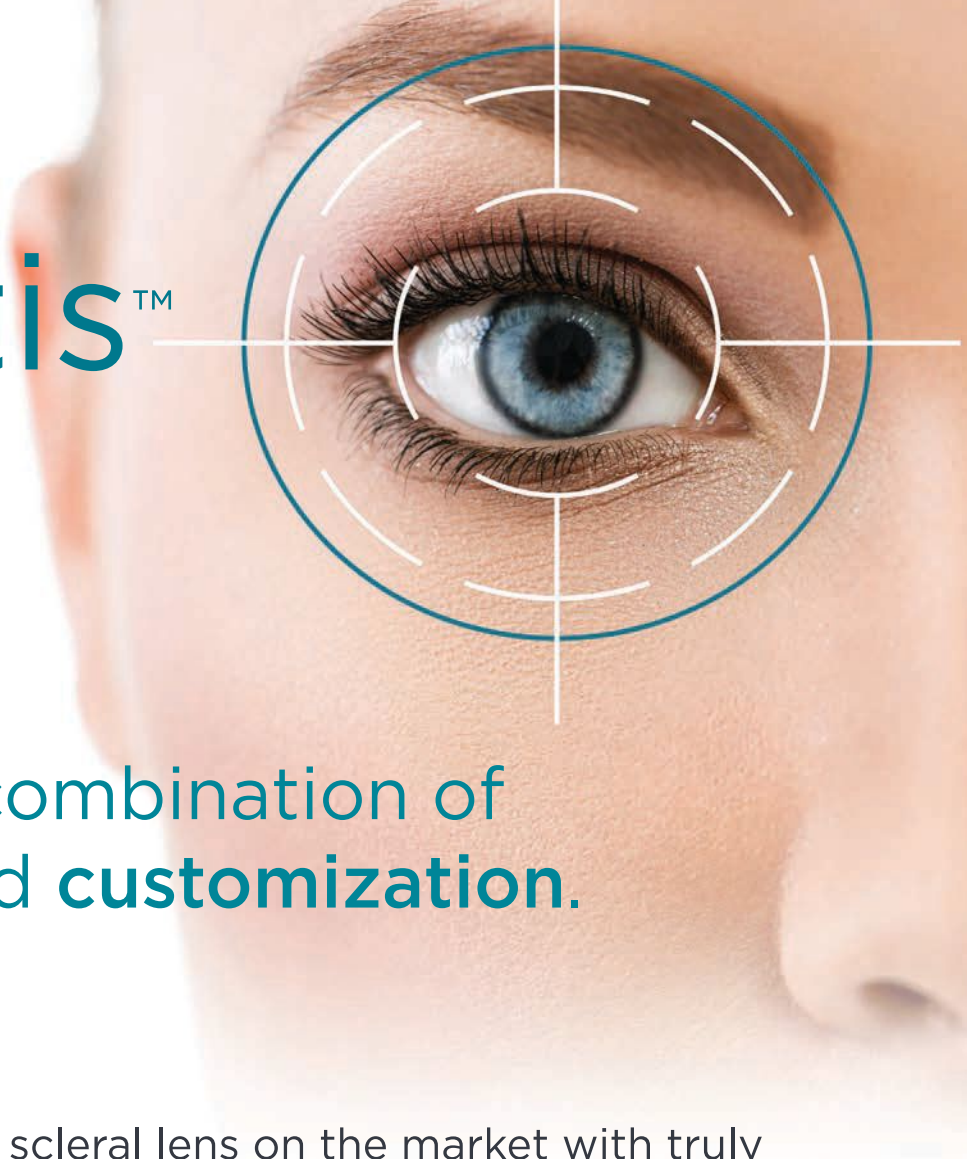Though the laws and customs of optometric practice are often radically different outside the US, I think your international colleagues will welcome the chance to experience the top-tier education that happens here, even if the credits don't transfer.

If there's one hallmark of the optometry profession's storied history, it's the ability to adapt to change. That spirit brought practitioners out of the jewelry stores and into private practices, and then to hospitals and teaching institutions. And perhaps now, the world stage. ■



# Atlantis™

SCLERAL



The perfect combination of **simplicity** and **customization**.

The easiest to fit scleral lens on the market with truly customizable independent zone design options for any corneal SAG or scleral shape.

- Independent central SAG adjustments
- Quadrant specific scleral zone
- Quadrant specific limbal zone
- 14.0 and 14.5 diameters for normal corneas

**Deepest discounts available on all fitting sets right now! Call today!**



**X-CEL**  
SPECIALTY CONTACTS

Recommended in:

**OPTIMUM**  
**INFINITE**

[xcelspecialtycontacts.com](http://xcelspecialtycontacts.com) | 800.241.9312 | [xcelfinfo@xcelspecialtycontacts.com](mailto:xcelfinfo@xcelspecialtycontacts.com)



# How to Pick the Right Surgeon

This checklist can help you make the best choice when referring a patient for surgery.

By Paul M. Karpecki, OD, Chief Clinical Editor

**W**hen a patient needs cataract surgery, you have a big decision to make: which surgeon is best? Patients rarely know who is the most talented, knowledgeable and compassionate, and they certainly don't know who has access to the most innovative resources. But we do.

You can follow this checklist to ensure you are identifying the ideal cataract surgeon for your patients.

## □ They Value Your Input

No surgeon or surgical practice can know your patient better after 15 minutes than you do after years as their primary eye doctor. These scenarios highlight valuable information a surgeon may not be privy to, unless you tell them:

- A patient who failed in monovision contact lenses will likely fail in monovision IOLs.
- A patient who is hypersensitive to change may not do well with a multifocal IOL.
- Those with prism in their Rx will require glasses post-op and shouldn't be offered the hope of being spectacle-free.

You should find a surgeon who is happy to have your input on the patient's clinical picture. This is a win-win: surgeons gain crucial insight to help them better serve the patient, and the patient receives the individualized care they deserve.

If a surgeon is unwilling to take your clinical insights into consideration, your patients are better served by another option.

## □ They Provide Options

One of the keys to a successful surgery is having options to address every patient's needs. Ensure your surgeon offers most of these:

- The latest premium IOL technologies, such as the AcrySof IQ Vivity (Alcon), PanOptix (Alcon) or Tecnis Symfony (Johnson & Johnson Vision).
- Toric IOLs for patients with significant astigmatism.
- The Light Adjustable Lens (RxSight).
- Minimally invasive glaucoma surgery (MIGS). Most of these procedures can only be performed at the time of cataract surgery, yet more than 50% of the time, the patient isn't even offered this option.
- Tools for correcting unexpected refractive outcomes, such as an excimer laser.

## □ They Have Access to Advanced Technologies

Office-based care is the future for cataract surgery, especially considering the impact COVID-19 has had on hospital-based procedures. Also, an ambulatory surgery center isn't much different from a hospital operating room, in most patients' eyes. Other advances that could benefit your patients include:

- Dropless or less drop procedures (e.g., Imprimis Dropless injections at the time of surgery) for patients who don't do well with topical agents.
- Omidria (topical phenylephrine/ketorolac, Omeros) can help sur-

geons maintain pupil size, preventing intraoperative miosis and reducing postoperative ocular pain.

- Access to a femtosecond laser or MiLoop (Carl Zeiss) to pre-fragment the lens.
- Zepto (Centricity Vision) can help the surgeon create a perfectly round capsulotomy.
- 3D cataract surgery, for example with the NGenuity system (Alcon).

The future of cataract surgery is filled with unimaginable innovations, such as artificial capsules that allow for future IOL exchange or placement of biometric sensors. So it's important to partner with surgeons who work with you to provide the latest technologies to your patients. With a strong referral relationship and exceptional comanagement skills, you can deliver the best patient results. ■

*Note: Dr. Karpecki consults for companies with products and services relevant to this topic.*

## Invest in a Surgical Suite

Optometry practices around the country are starting to set up a surgical suite in their office and have the surgeon come to them. This ensures the patient stays with the practice they are comfortable with and they avoid going to an ambulatory surgery center or hospital—which is challenging during COVID-19. It also allows you to share in the professional and surgical fees. This is a far more profitable option for practices referring 20 or more patients per month, and it's an easy turnkey process if you have the volume and space.

# Adapt. Evolve. Grow.



As you **adapt** to the changes our industry is facing, you'll find there is also opportunity.

Discover how dark adaptation testing with AdaptDx Pro™ guided by Theia™ can help you **evolve** your approach to AMD care. Become an AMD Center of Excellence™ and unlock your potential to **grow** your practice revenue.

AdaptDx™  
PRO

Guided by Theia™

Download *Practical Opportunities in AMD Management* for real-life perspectives from your fellow optometrists at [maculogix.com/opportunity](https://maculogix.com/opportunity)

# The Fun Never Ends

If you think you are going to be living on easy street when you retire, I've got news for you. **By Montgomery Vickers, OD**

Remember the good ol' days? Like 2019? Remember when retiring meant leaving work for the last time to sit by a lake? Now when you are retired, it just means you are tired again.

I started thinking about retiring the first day I saw my first patient. Unfortunately, what I thought then was, "That's so far away. I think I will buy stuff in the meantime." That worked out quite well because, looking around my house, I do indeed have a lot of stuff.

## Kiss the Old Dream Goodbye

Many OD Baby Boomers are still looking forward to the 2019 idea of retirement: finally learning how to golf, traveling the world, buying that convertible and selling the practice to some earnest, wet-behind-the-ears young doctor.

Well, let's face it: (A) you will never learn how to golf—even Tiger Woods doesn't have that figured out, (B) traveling the world could be hazardous to your health, (C) it's too hot/cold/windy/wet to ever drive with the top down and (D) those earnest, wet-behind-the-ears young doctors seem to have disappeared into the free-eye-exam-with-glasses snake pit.

Besides, with the fear of COVID-19, your depression after the election and the fact that your stinky Aunt Francie needs a place to stay—*indefinitely*—maybe you should just never retire and work until they pry your retinoscope from your cold, dead hand.

## A New Outlook

Don't worry, you can still retire. You might have to give up your monthly shipment of Bulgarian beef jerky. Maybe you will have to wear the same khaki pants you wore last year. When the kids invite you out to dinner, you won't fight over the bill.

But retirement doesn't mean you don't do anything. Here's an example: I know a very successful optometrist who sold his practice (for a pittance of its worth) to some ne'er-do-well ophthalmologists and retired to be close to his kids. His idea of retirement? Working twice the hours for half the money. Ok, it's me.

But I actually love optometry 98.67% of the time. Helping patients and driving them mad with stories of my grandchildren between number ones and twos makes me happy and keeps me young. To me, that's much better than throwing \$90 worth of golf balls into lakes all day. Although I do have some experience with that, too.

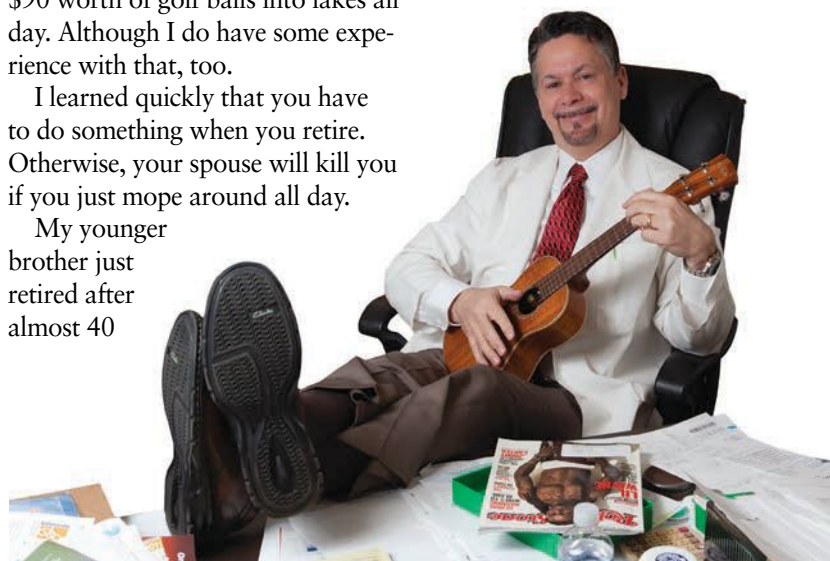
I learned quickly that you have to do something when you retire. Otherwise, your spouse will kill you if you just mope around all day.

My younger brother just retired after almost 40

years in the oil and gas industry. He has always worked hard and is one of the finest men I know. He has a wonderful family, a beautiful wife and a darling granddaughter. He has earned his retirement and now catches fish from his kayak when he's not riding his bike.

I never, ever rub it in his face that I have six grandchildren. Never. Brothers are never competitive like that. Yes, I have six. My brother only has one. Just one. I have six.

So, where are you on your retirement journey? Just starting out with a zillion dollars in student debt and living in mom's attic? Starting to see your bank account edge into the black and already shopping for a cooler car? Mid-career and shocked that you could be so successful (or unsuccessful, depending on your trajectory)? You're still eating, right? That's a sign of success. ■





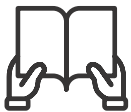REVIEW OF OPTOMETRY

# The OD's TOP CHOICE

Ranked #1 Eye Care  
Publication In  
**FIVE**  
Critical Readership  
Categories:



Total Readers



Most Read Publication/  
Website Within the Last  
Six Months



Quality Clinical Content  
I Use in My Practice



Average Page Exposures



Websites Visited within  
the Last Six Months

Source: Kantar Media Eyecare 2020 Study

Practitioners rely on RO  
more than any other eye  
care publication



**Review also is number one in readership  
across the following categories:**

- Total Optometrists
- ODs in High-Volume Practices
- Solo Practitioners
- Annual Practice Revenue (\$500k+)
- ODs who Purchase Examination Equipment
- Write Prescriptions (11+ per week)
- Perform Refractions (51+ per week)
- Contact Lens Prescribers
- Years in Practice (1-15 and 15+)
- Among Key Opinion Leaders

***To our readers:* Thank you for  
your loyalty, time and trust.  
We'll keep working hard to earn  
your support.**



# Shield Your Eyes

An excessive amount of UV light can damage the corneal epithelium.

Edited by Paul C. Ajamian, OD

**Q** A 27-year-old man who was plasma cutting without eye protection woke up in the middle of the night with excruciating pain. An ER visit at 3am resulted in a Polytrim (trimethoprim/polymyxin B sulfate, Allergan) prescription. He presented the next day with mild superficial punctate keratitis (SPK), still in severe pain and with photophobia. What is the best next step?

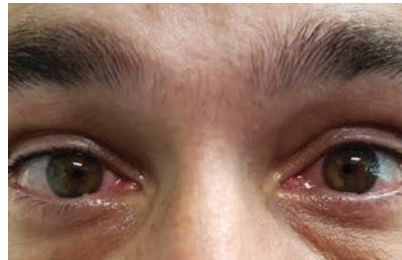**A** “What is confusing about these cases is that the patient usually admits that they knowingly broke eye protection safety protocol, resulting in their ocular injury,” Marc Myers, OD, of Coatesville Veterans Affairs Medical Center in Pennsylvania, says. “The patient may notice the welder flash burn only when symptoms begin, usually six to 12 hours after exposure.”

Less experienced welders may not be aware of safety standards, or more experienced welders may attempt to hastily complete a job without eye protection. Proper use of a welder’s hood can virtually eliminate these injuries.

## Overexposed

Plasma cutting, or plasma arc cutting, involves a super-heated (40,000°F) column of gas that cuts electrically conductive materials, such as steel, stainless steel and aluminum.<sup>1</sup> A plasma arc emits a broad-spectrum of electromagnetic radiation, extending into ultraviolet (UV) range.

Welding is thought to be the primary cause of UV keratitis.<sup>2</sup> Other sources of UV energy that may result in keratitis include unprotected



A patient might not notice a welder flash burn until symptoms begin.

exposure to intense sunlight, artificial light from a tanning bed, staring at a solar eclipse and powerful halogen and photography flood lamps.<sup>2-4</sup>

UV keratitis, or photochemical keratitis, occurs when the cornea is exposed to excessive UV light. The corneal epithelium is chiefly responsible for the greatest quantity of the absorption of UV light. Photochemical toxicity can damage the epithelium, and, in doing so, may result in mitosis inhibition, nuclear fragmentation production and loosening of the epithelial layer, which ultimately leads to SPK.<sup>5</sup>

Symptoms include a bilateral sandy, scratchy feeling of foreign body sensation (FBS) followed by redness, tearing, pain and reduced visual acuity.<sup>5</sup> “By understanding the mechanism behind the injury and predicting the course of recovery, treatment can address symptoms and improve the patient’s comfort,” Dr. Myers says.

## Management

According to Dr. Myers, treatment consists of topical preparations to manage FBS and pain and includes viscous lubricants, cycloplegics and


nonsteroidal anti-inflammatory drugs, steroids or a combination of these. The patient in question was put on Pred Forte (prednisolone acetate 0.1%, Allergan) QID, which quickly alleviated his symptoms. “I also encourage the use of an over-the-counter oral analgesic if topical therapy does not adequately control pain,” Dr. Myers says.

Customarily, a topical antibiotic is included as prophylaxis against potential infection. Encourage sunglasses to protect against photophobia and sleep during the recovery period. Lastly, Dr. Myers emphasizes appropriate eye protection when engaging in any form of activity that involves excessive UV exposure.

Fortunately, garden-variety cases of UV keratopathy respond well to treatment and significantly improve within 24 to 72 hours. Cases that involve the conjunctiva, UV keratoconjunctivitis, may take slightly longer to completely resolve when employing this same regimen of care. The cumulative effect of UV exposure may go beyond the cornea and result in pterygium and pinguecula as well as cataracts.

An ounce of prevention goes a long way, according to Dr. Myers. “In this case, always use the welder’s hood,” he notes. ■

1. Glassford E, Burr G, Glassford E, et al. Evaluating optical hazards from plasma arc cutting. *J Occup Environ Hyg*. 2018;15(1):D1-7.
2. Delic NC, Lyons JG, Di Girolamo N, Halliday GM. Damaging effects of ultraviolet radiation of the cornea. *Photochem and Photobiol*. 2017;93(4):920-9.
3. Podskochy A. Protective role of corneal epithelium against ultraviolet radiation damage. *Acta Ophthalmol Scand*. 2004;82(6):714-7.
4. Schein OD. Phototoxicity and the cornea. *J Nat Med Assoc*. 1992;84(7):579-83.
5. Willmann G. Ultraviolet keratitis: from the pathophysiological basis to prevention and clinical management. *High Alt Med Biol*. 2015;16(4):277-82.



SPRING AND SUMMER 2021

# New Technologies & Treatments in Eye Care

**MARCH 19–20 | JUNE 11–12**

## CALL FOR SPEAKER ABSTRACTS

### NEW TECHNOLOGIES & TREATMENTS IN EYE CARE VIRTUAL CONFERENCE SERIES ANNOUNCES OUR 2021 CALL FOR SPEAKER ABSTRACTS

We are currently soliciting speaker abstracts for our upcoming virtual programs.

Submission should contain subject matter pertinent and applicable to optometrists actively practicing and advising patients in the field of optometry. Topics of interest may include, but are not limited to glaucoma, dry eye, and retinal disease.

In order to be considered for submission, abstracts should contain the following information:

- Title
- Learning Outcomes (at least three)
- Brief description of what will be covered in your session. Please be sure your abstract includes tangible and actionable pearls that attendees can take back and implement into practice
- References (at least three)
- Current CV (include previous speaking experience)

Please submit all information to [awilkinson@reviewsce.com](mailto:awilkinson@reviewsce.com).

**Deadline to submit: January 1, 2021**

**Notification of acceptance/rejection via email by: January 15, 2021**



# Buff Up Your Buffers

Exophoria helps the body reduce the impact of visual stress.

By **Marc B. Taub, OD, MS, and Paul Harris, OD**

Optometrist A.M. Skeffington once postulated that, “The near-work demands imposed upon our culture are incompatible with our physiology and provoke a stress response.”<sup>1</sup> Over time, the human body set up a system to reduce the impact of visual stress: buffers. Buffers allow us to resist stress and come away unharmed by those same stressors.<sup>2</sup> Without the presence of buffers, we would experience symptoms almost as soon as stressors are encountered, and if their duration or intensity continues for too long, changes in structure would occur.

Low hyperopia and exophoria are the body’s ocular buffers and should be encouraged, not viewed as detriments. As Leo Manas, OD, put it, “The presence of orthophoria is undesirable, and remedial measures should be instituted to regain the buffer of exophoria as soon as possible.”<sup>3</sup> The cases below demonstrate how to keep your patients on the desired exophoria path during the prescribing process.

## Case 1

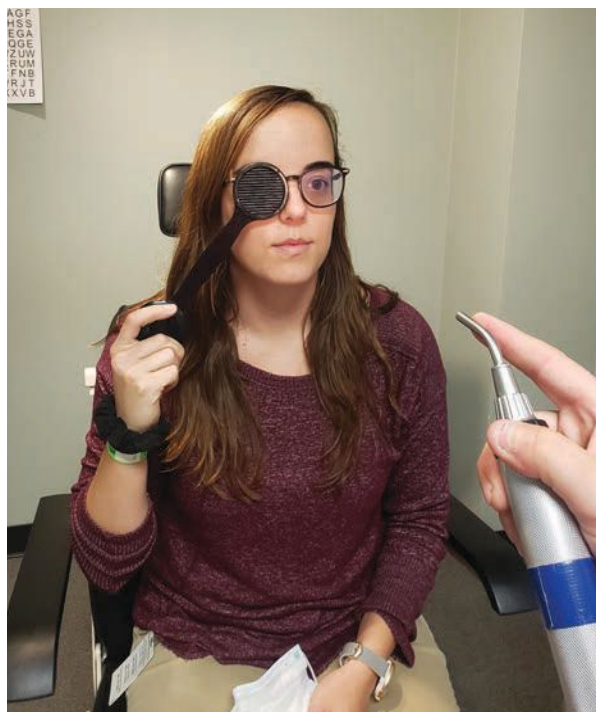A 10-year-old female patient presented complaining of distance blur with her glasses, which were -1.50-0.50x180 OD and -1.50 OS. Her acuities were 20/25- OD, 20/30 OS and 20/25 OU at distance and 20/20 OD, OS and OU at near.

Stereopsis yielded 20 seconds of arc using the Randot Stereo Test. Near point data, including the near point of convergence and accommodative amplitude, fell within expected values. However, the cover test stood out, showing orthophoria at distance and four esophoria at near with glasses.

A new prescription of -2.00 OU improved the patient’s acuities to 20/20 OD, OS and OU. Negative and positive relative accommodations were balanced at +2.50/-2.50, and the fused cross-cylinder test showed +1.00 (higher than the expected +0.50). The vergence ranges showed an imbalance at near (base-in x/16/8, base-out x/32/20). The cover test remained four esophoria at near.

While the patient’s numbers did not line up with its textbook definition, convergence excess was deemed the appropriate diagnosis.

The patient’s degree of esophoria indicated that we needed to help her reestablish exophoria. The first step was plus lenses in



Use a Maddox rod to determine a patient’s phoria.

the form of a bifocal. Given that the expected average accommodative convergence/accommodation ratio is four to one and that convergence excess is associated with a higher-than-average ratio, we trial-framed +1.00 over the new distance prescription. We were pleased to find the near cover test at two exophoria.

The final prescription was -2.00 OU with a +1.00 bifocal. While some practitioners set the segment height higher to ensure the patient takes advantage of the add, we decided, based on the patient’s maturity, that a traditional height



would suffice. A progressive, or stress-relieving, lens design was not discussed but is not out of the question for those who prefer a no-line option.

We will evaluate the patient again after six to eight weeks of new lens wear and consider vision therapy.

## Case 2

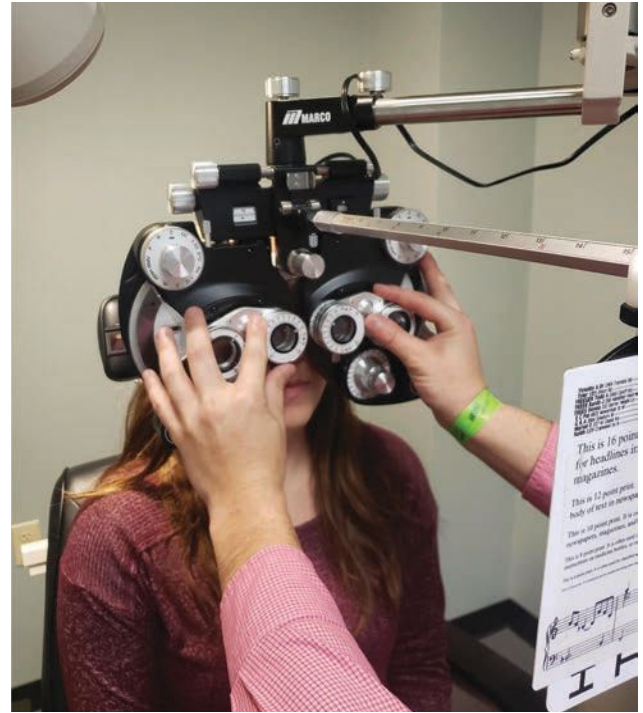
A 13-year-old female patient presented complaining of asthenopia at near, especially with increased computer work during virtual schooling. Her uncorrected visual acuities were 20/20 OD, 20/25 OS and 20/25 OU at distance and 20/25 OU at near. She had been prescribed glasses with a prescription of  $-0.75-0.75 \times 180$  OD and  $-1.00$  OS at an eye exam four weeks prior but did not see a difference in clarity and stopped using them.

She demonstrated a stereopsis of 50 seconds of arc. Cover testing showed six esophoria at distance and near. Her retinoscopy showed  $+2.00$  OU, which reduced her acuities to 20/50 OD and OS. Her

refraction was  $+1.00$  OU, which resulted in visual acuities of 20/20 OD, OS and OU.

With a trial frame, cover testing was two esophoria at distance and near. With the goal of reducing the eye turn as much as possible to support the natural buffer, we trialed extra plus at near and determined  $+1.00$  OU to be the “best bang for the buck.” With the new prescription, cover testing showed two exophoria at near.

The patient was prescribed  $+1.00$  OU with a  $+1.00$  bifocal for full-time use and was scheduled to come back in four to six weeks for a complete accommodative and binocular vision workup. At that point, we will consider vision therapy to further encourage the patient to actively solidify her buffer for long-term success.

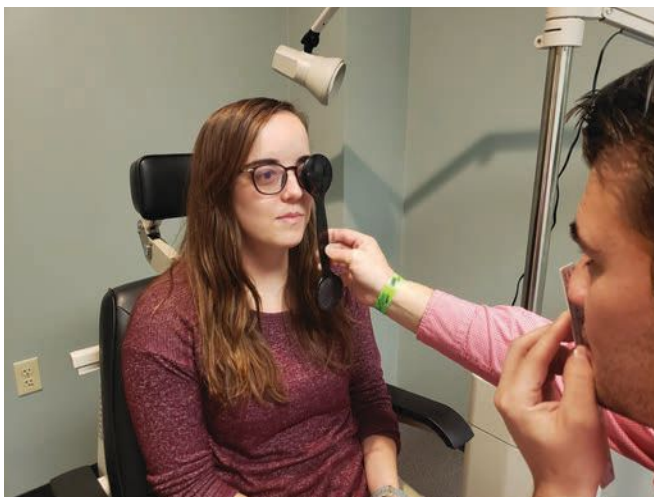

**A phoropter is also helpful in measuring the phoria.**

While the two patients described here are very different, we were able to use plus to help each of them restore their exophoric buffer in each case.

Prescribing lenses is a passive treatment. In some cases, it is sufficient enough to nudge the patient in the right direction. In many cases, though, vision therapy can build on the lenses and complete the process of preventing the visual system from building a higher exophoria at near (convergence insufficiency) and halting the buffer from reducing even further into orthophoria or esophoria (convergence excess). ■

1. Birnbaum MH. *Optometric Management of Nearpoint Vision Disorders*. Boston: Butterworth-Heinemann, 1993:33.
2. Selye H. *The Stress of Life*. New York: McGraw-Hill, 1976.
3. Manas L. *Visual Analysis*. Santa Ana, CA: Optometric Extension Program Foundation, 2009:14.



**This patient is undergoing near cover testing.**



**FIRST AND ONLY**

**FDA-APPROVED TREATMENT FOR THYROID EYE DISEASE**

IT'S TIME FOR A  
**BREAKTHROUGH**  
IT'S TIME FOR TEPEZZA

### INDICATION

TEPEZZA is indicated for the treatment of Thyroid Eye Disease.

### IMPORTANT SAFETY INFORMATION

#### Warnings and Precautions

**Infusion Reactions:** TEPEZZA may cause infusion reactions. Infusion reactions have been reported in approximately 4% of patients treated with TEPEZZA. Reported infusion reactions have usually been mild or moderate in severity. Signs and symptoms may include transient increases in blood pressure, feeling hot, tachycardia, dyspnea, headache, and muscular pain. Infusion reactions may occur during an infusion or within 1.5 hours after an infusion. In patients who experience an infusion reaction, consideration should be given to premedicating with an antihistamine, antipyretic, or corticosteroid and/or administering all subsequent infusions at a slower infusion rate.

**Preexisting Inflammatory Bowel Disease:** TEPEZZA may cause an exacerbation of preexisting inflammatory bowel disease (IBD). Monitor patients with IBD for flare of disease. If IBD exacerbation is suspected, consider discontinuation of TEPEZZA.

EXPLORE THE VIRTUAL BOOTH AT  
[TEPEZZAexperience.com](https://TEPEZZAexperience.com)



Visit the interactive virtual booth to test your knowledge of Thyroid Eye Disease (TED), see the breakthrough data for TEPEZZA, and experience TED through a patient's eyes.

**Hyperglycemia:** Increased blood glucose or hyperglycemia may occur in patients treated with TEPEZZA. In clinical trials, 10% of patients (two-thirds of whom had preexisting diabetes or impaired glucose tolerance) experienced hyperglycemia. Hyperglycemic events should be managed with medications for glycemic control, if necessary. Monitor patients for elevated blood glucose and symptoms of hyperglycemia while on treatment with TEPEZZA. Patients with preexisting diabetes should be under appropriate glycemic control before receiving TEPEZZA.

#### Adverse Reactions

The most common adverse reactions (incidence  $\geq 5\%$  and greater than placebo) are muscle spasm, nausea, alopecia, diarrhea, fatigue, hyperglycemia, hearing impairment, dysgeusia, headache, and dry skin.

Please see Brief Summary of Prescribing Information on following page.

TEPEZZA and the HORIZON logo are trademarks owned by or licensed to Horizon.  
© 2020 Horizon Therapeutics plc P-TEP-00645 10/20







# TEPEZZA™

## teprotumumab-trbw

For injection, for intravenous use

**Brief Summary - Please see the TEPEZZA package insert for full prescribing information.**

### INDICATIONS AND USAGE

TEPEZZA is indicated for the treatment of Thyroid Eye Disease.

### WARNINGS AND PRECAUTIONS

#### Infusion Reactions

TEPEZZA may cause infusion reactions. Infusion reactions have been reported in approximately 4% of patients treated with TEPEZZA. Signs and symptoms of infusion-related reactions include transient increases in blood pressure, feeling hot, tachycardia, dyspnea, headache and muscular pain. Infusion reactions may occur during any of the infusions or within 1.5 hours after an infusion. Reported infusion reactions are usually mild or moderate in severity and can usually be successfully managed with corticosteroids and antihistamines. In patients who experience an infusion reaction, consideration should be given to pre-medicating with an antihistamine, antipyretic, corticosteroid and/or administering all subsequent infusions at a slower infusion rate.

#### Exacerbation of Preexisting Inflammatory Bowel Disease

TEPEZZA may cause an exacerbation of preexisting inflammatory bowel disease (IBD). Monitor patients with IBD for flare of disease. If IBD exacerbation is suspected, consider discontinuation of TEPEZZA.

#### Hyperglycemia

Hyperglycemia or increased blood glucose may occur in patients treated with TEPEZZA. In clinical trials, 10% of patients (two-thirds of whom had preexisting diabetes or impaired glucose tolerance) experienced hyperglycemia. Hyperglycemic events should be controlled with medications for glycemic control, if necessary.

Monitor patients for elevated blood glucose and symptoms of hyperglycemia while on treatment with TEPEZZA. Patients with preexisting diabetes should be under appropriate glycemic control before receiving TEPEZZA.

### ADVERSE REACTIONS

The following clinically significant adverse reactions are described elsewhere in the labeling:

- Infusion Reactions [see Warnings and Precautions]
- Exacerbation of Inflammatory Bowel Disease [see Warnings and Precautions]
- Hyperglycemia [see Warnings and Precautions]

#### Clinical Trials Experience

Because clinical trials are conducted under widely varying conditions, adverse reaction rates observed in the clinical trials of a drug cannot be directly compared to rates in the clinical trials of another drug and may not reflect the rates observed in practice.

The safety of TEPEZZA was evaluated in two randomized, double-masked, placebo-controlled clinical studies (Study 1 [NCT:01868997] and Study 2 [NCT:03298867]) consisting of 170 patients with Thyroid Eye Disease (84 received TEPEZZA and 86 received placebo). Patients were treated with TEPEZZA (10 mg/kg for first infusion and 20 mg/kg for the remaining 7 infusions) or placebo given as an intravenous infusion every 3 weeks for a total of 8 infusions. The majority of patients completed 8 infusions (89% of TEPEZZA patients and 93% of placebo patients).

The most common adverse reactions (≥5%) that occurred at greater incidence in the TEPEZZA group than in the control group during the treatment period of Studies 1 and 2 are summarized in Table 1.

**Table 1. Adverse Reactions Occurring in 5% or More of Patients Treated with TEPEZZA and Greater Incidence than Placebo**

Adverse Reactions	TEPEZZA N=84 N (%)	Placebo N=86 N (%)
Muscle spasms	21 (25%)	6 (7%)
Nausea	14 (17%)	8 (9%)
Alopecia	11 (13%)	7 (8%)
Diarrhea	10 (12%)	7 (8%)
Fatigue <sup>a</sup>	10 (12%)	6 (7%)
Hyperglycemia <sup>b</sup>	8 (10%)	1 (1%)
Hearing impairment <sup>c</sup>	8 (10%)	0
Dysgeusia	7 (8%)	0
Headache	7 (8%)	6 (7%)
Dry skin	7 (8%)	0

a - Fatigue includes asthenia

b - Hyperglycemia includes blood glucose increase

c - Hearing impairment (includes deafness, eustachian tube dysfunction, hyperacusis, hypoacusis and autophony)

#### Immunogenicity

As with all therapeutic proteins, there is potential for immunogenicity. The detection of antibody formation is highly dependent on the sensitivity and specificity of the assay.

In a placebo-controlled study with TEPEZZA, 1 of 42 patients treated with placebo had detectable levels of antidrug antibodies in serum. In the same study, none of the 41 patients treated with TEPEZZA had detectable levels of antidrug antibodies in serum.

### USE IN SPECIFIC POPULATIONS

#### Pregnancy

##### Risk Summary

Based on findings in animals and its mechanism of action inhibiting insulin-like growth factor-1 receptor (IGF-1R), TEPEZZA may cause fetal harm when administered to a pregnant woman. Adequate and well-controlled studies with TEPEZZA have not been conducted in pregnant women. There is insufficient data with TEPEZZA use in pregnant women to inform any drug associated risks for adverse developmental outcomes. In utero teprotumumab exposure in cynomolgus monkeys dosed once weekly with teprotumumab throughout pregnancy resulted in external and skeletal abnormalities. Teprotumumab exposure may lead to an increase in fetal loss [see Data]. Therefore, TEPEZZA should not be used in pregnancy, and appropriate forms of contraception should be implemented prior to initiation, during treatment and for 6 months following the last dose of TEPEZZA.

If the patient becomes pregnant during treatment, TEPEZZA should be discontinued and the patient advised of the potential risk to the fetus.

The background rate of major birth defects and miscarriage is unknown for the indicated population. In the U.S. general population, the estimated background risks of major birth defects and miscarriage in clinically recognized pregnancies are 2-4% and 15-20%, respectively.

##### Data

##### Animal Data

In an abridged pilot embryofetal development study, seven pregnant cynomolgus monkeys were dosed intravenously at one dose level of teprotumumab, 75 mg/kg (2.8-fold the maximum recommended human dose [MRHD] based on AUC) once weekly from gestation day 20 through the end of gestation. The incidence of abortion was higher for the teprotumumab treated group compared to the control group. Teprotumumab caused decreased fetal growth during pregnancy, decreased fetal size and weight at caesarean section, decreased placental weight and size, and decreased amniotic fluid volume. Multiple external and skeletal abnormalities were observed in each exposed fetus, including: misshapen cranium, closely set eyes, micrognathia, pointing and narrowing of the nose, and ossification abnormalities of skull bones, sternbrae, carpals, tarsals and teeth. The test dose, 75 mg/kg of

teprotumumab, was the maternal no observed adverse effect level (NOAEL).

Based on mechanism of action inhibiting IGF-1R, postnatal exposure to teprotumumab may cause harm.

### Lactation

#### Risk Summary

There is no information regarding the presence of TEPEZZA in human milk, the effects on the breastfed infant or the effects on milk production.

### Females and Males of Reproductive Potential

#### Contraception

##### Females

Based on its mechanism of action inhibiting IGF-1R, TEPEZZA may cause fetal harm when administered to a pregnant woman (see Use in Specific Populations). Advise females of reproductive potential to use effective contraception prior to initiation, during treatment with TEPEZZA and for 6 months after the last dose of TEPEZZA.

#### Pediatric Use

Safety and effectiveness have not been established in pediatric patients.

#### Geriatric Use

Of the 171 patients in the two randomized trials, 15% were 65 years of age or older; the number of patients 65 years or older was similar between treatment groups. No overall differences in efficacy or safety were observed between patients 65 years or older and younger patients (less than 65 years of age).

### OVERDOSAGE

No information is available for patients who have received an overdosage.

### PATIENT COUNSELING INFORMATION

#### Embryo-Fetal Toxicity

Advise females of reproductive potential that TEPEZZA can cause harm to a fetus and to inform their healthcare provider of a known or suspected pregnancy.

Educate and counsel females of reproductive potential about the need to use effective contraception prior to initiation, during treatment with TEPEZZA and for 6 months after the last dose of TEPEZZA.

#### Infusion-Related Reactions

Advise patients that TEPEZZA may cause infusion reactions that can occur at any time. Instruct patients to recognize the signs and symptoms of infusion reaction and to contact their healthcare provider immediately for signs or symptoms of potential infusion-related reactions.

#### Exacerbation of Inflammatory Bowel Disease

Advise patients on the risk of inflammatory bowel disease (IBD) and to seek medical advice immediately if they experience diarrhea, with or without blood or rectal bleeding, associated with abdominal pain or cramping/colic, urgency, tenesmus or incontinence.

#### Hyperglycemia

Advise patients on the risk of hyperglycemia and, if diabetic, discuss with healthcare provider to adjust glycemic control medications as appropriate. Encourage compliance with glycemic control.

Manufactured by:  
Horizon Therapeutics Ireland DAC  
Dublin, Ireland  
U.S. License No. 2022

Distributed by:  
Horizon Therapeutics USA, Inc.  
Lake Forest, IL 60045

TEPEZZA and the HORIZON logo are trademarks owned by or licensed to Horizon.

© 2020 Horizon Therapeutics plc L-TEP-00018 03/20







# Comanagement Goes Premium

More patients are interested in premium IOLs and advanced refractive techniques. Here's how you handle the coding. **By John Rumpakis, OD, MBA, Clinical Coding Editor**

Although the COVID-19 pandemic postponed surgeries and limited in-person care, patients still need cataract surgery. It's incumbent on us to handle the pre- and post-op care, whether in-person or through telehealth. Additionally, patient education is more important than ever with new intraocular lens (IOL) technology and refractive surgery procedures.

Now is a good time to review your comanagement protocols to ensure patients are receiving the best care—and you are billing properly for your professional services.

## The More You Know

As first-line care providers, we are handling the vast majority of eye care. Thus, we are also the ones on the front lines providing professional advice on IOL choices and making appropriate referrals.

It is our responsibility to be familiar with the various technologies, even new ones such as the PanOptix IOL (Alcon), and the local surgeons who work with each platform, whether it be for a traditional monofocal IOL or a multifocal, toric or multifocal toric lens.

Not only that, but it is critical that your preoperative care include a comprehensive evaluation for the presence of ocular surface disease to ensure best outcomes post-surgically.

## The Hand-off

The formal transfer of care begins with the referral to the surgeon.

Once this happens, your patient is now formally their patient. Keep in

mind that comanagement is a non-financial arrangement between a physician performing surgery and a comanaging physician providing care to the patient for some portion of the global follow-up period.

## Back in Your Chair

The comanagement portion of any surgery begins with the formal transfer from the surgeon to the comanaging physician—typically to the physician who originally referred the patient, but not always. Remember, a referral to the surgeon cannot be based on the requirement that the surgeon refer the patient back. Most often, the patient is the one choosing the comanaging physician, so be sure to discuss the arrangement with your patient before the initial surgical evaluation. The patient must request that they be referred back to you for postoperative care.

When billing for the comanagement portion of the patient's care, the time period is 90 calendar days after the procedure. The appropriate coding for your post-op services is described by the surgical code that the surgeon uses, with the appropriate modifier appended to the code.

### Traditional monofocal IOL:

- 6698X – 55 -RT/LT, first eye
- 6698X – 79-55-RT/LT, second eye if performed in the global period of the first eye.

Use the appropriate ICD-10 cataract diagnosis throughout the comanagement period and make sure it matches the surgeon's code.

**Premium IOLs:** When billing for a multifocal, use the following code

descriptor to *bill the patient* directly for the premium portion of the IOL (this code is appropriate for the PanOptix and any multifocal toric).

- V2788 – Presbyopia-correcting function of intraocular lens

Make sure that you use the ICD-10 code for presbyopia (H52.4) that is mapped to this code.

When billing for a toric IOL, use the following code descriptor to *bill the patient* directly for the premium portion of the IOL:

- V2787 – Astigmatism-correcting function of intraocular lens.

Make sure that you use the appropriate ICD-10 code for astigmatism (H52.2XX) mapped to this code.

While it is common for clinicians to set their own fee for the premium portion of IOL comanagement, no money should be paid directly from the surgeon to the comanaging physician. Instead, it is far more prudent to have the patient pay each of the three entities separately for their respective portion of the care provided: one payment each to the surgical center, surgeon and comanaging physician.

COVID-19 should not stymie your comanagement of surgical patients, and making an informed referral to the right surgeon for the best outcome should always be paramount, no matter the circumstances. You must diagnose and treat preoperative conditions before surgical referral and stay up-to-date on new technology to provide the very best outcomes for patients. ■

Send your coding questions to [rocodingconnection@gmail.com](mailto:rocodingconnection@gmail.com).

# 2020 INCOME: Riding the COVID Roller Coaster

Once-steady practice revenue lurched wildly this year, facing unexpected jolts at every turn. Has its course steadied yet? **By Catherine Manthorp, Associate Editor**

**W**hen the world counted down the remaining seconds of 2019 and welcomed in what was supposed to be “the year of vision,” we had no way of knowing we were in for a shocking turn of events instead. Just 10 weeks into 2020, COVID-19 had become the focus of the world and had upended life as we knew it.

The steady income ODs typically enjoy took a roller coaster

ride when much of the economy shut down during the lockdown earlier this year, and has yet to fully recover. The result: 2020 painted a very different financial picture for optometry than years past, as told by our annual income survey.

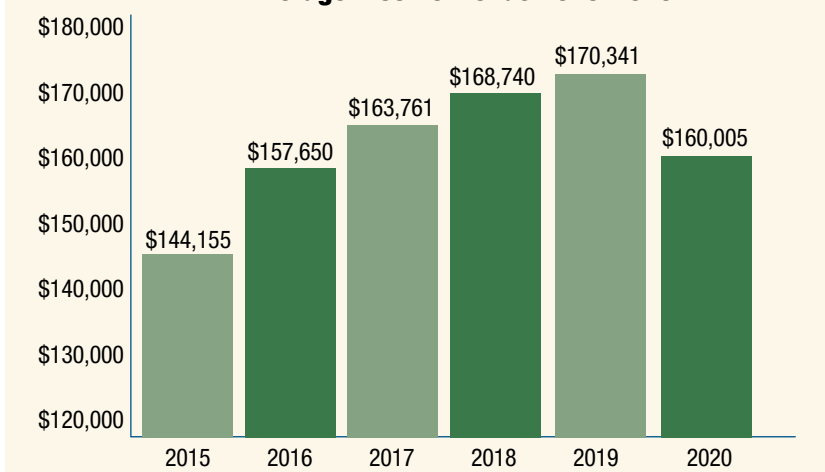
This year, 600 respondents shared their financial stories with us. Unfortunately, average annual income experienced a sharp drop to \$160,005, down 6% from 2019. While optometric income has been

increasing at slower rates over the last few years in our survey, this is the first time it’s dipped into the negatives, landing roughly in the middle of 2016’s and 2017’s numbers. Further, that 6% drop is an average that can mask the more acute factors that affected some segments of the audience. The majority of respondents (57%) reported that their income decreased, but 35% didn’t experience a financial change, and 8% even saw an increase in their earnings. For it all to net out at a 6% decline means some ODs really felt the pinch this year.

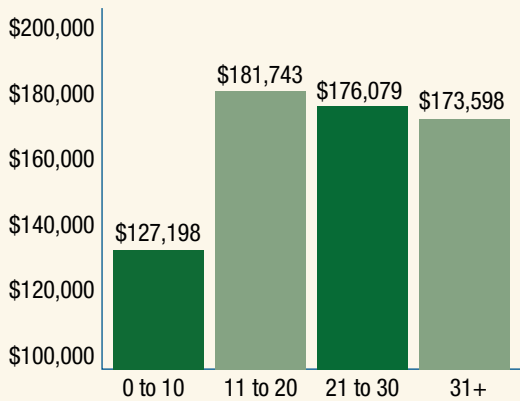
Those working part-time fared especially poorly. Part-timers made an average of \$88,791 in 2020, a whopping 30% less than last year. Among full-time workers, 2020 income was 3% less than 2019 at \$170,655.

When asked to explain the financial shortfall, many ODs named the shutdown in the spring/summer as the biggest influence behind their pay cut. Decreased patient volume/exam fee revenue, decreased product sales and increased expenses for

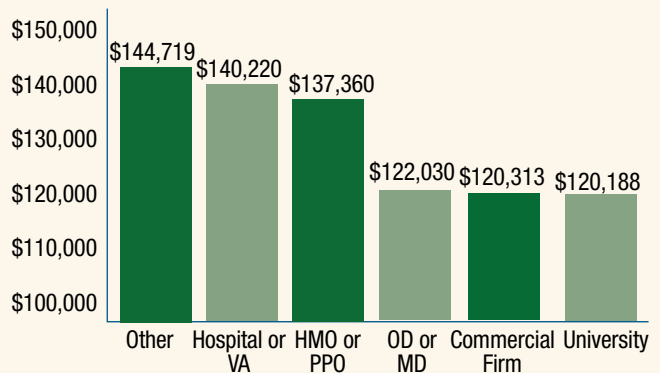
**Average Income Trends 2015-2020**



**2020 Income By Years In Practice**



**2020 Employed Income By Practice Setting**



PPE, disinfection and other safety measures followed, in order of importance. According to the survey, the cost of staff training/rehiring had the smallest impact on income.

Further, almost 60% of respondents said COVID-19 negatively affected their employment, with 27% being furloughed or laid off and 32% facing reduced hours. Only 35% were not affected job-wise, and 6% actually claimed increased hours.

*Editor's note: As always, be mindful that while we ask the same survey questions, the responses we compare from year to year come from different individuals, making trend analysis tricky, especially among a smaller cohort. The results offer a representative look at the profession but aren't considered statistically rigorous.*

### Practice Doesn't Always Pay Off

This year's survey cohort showed that more years of experience don't necessarily equate to a larger paycheck, much to more seasoned ODs' dismay.

Entry-level respondents (*i.e.*, those with up to 10 years of experience) earned an average of \$127,198, a 12% drop from the average income beginners made in 2019.

The average income leap from the

first experience bracket to the next one—11 to 20 years—skyrocketed 43% to \$181,743, representing a 7% increase from 2019. These ODs have settled into their career nicely, earning the highest income compared with their counterparts who have more or fewer years of experience.

Financial progress began to stall in the subsequent experience brackets, starting with those with 21 to 30 years of experience. These clinicians earned an average of \$176,079, 3% less than those with 11 to 20 years of experience. This also represents a slight decrease from the average income this experience group reported in 2019.

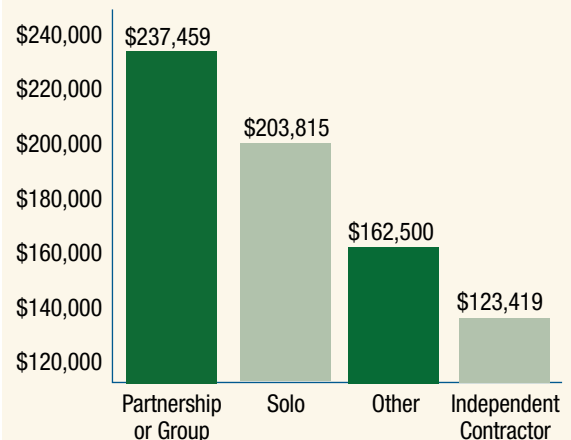
Perhaps the hardest blow was felt by the most veteran ODs. This year's participants who have been practicing for more than 30 years earned an average of \$173,598, a 17% decline from the average income this bracket reported in 2019; it's also 1% lower than their colleagues with 10 fewer years of experience.

### Benefits of Being the Boss

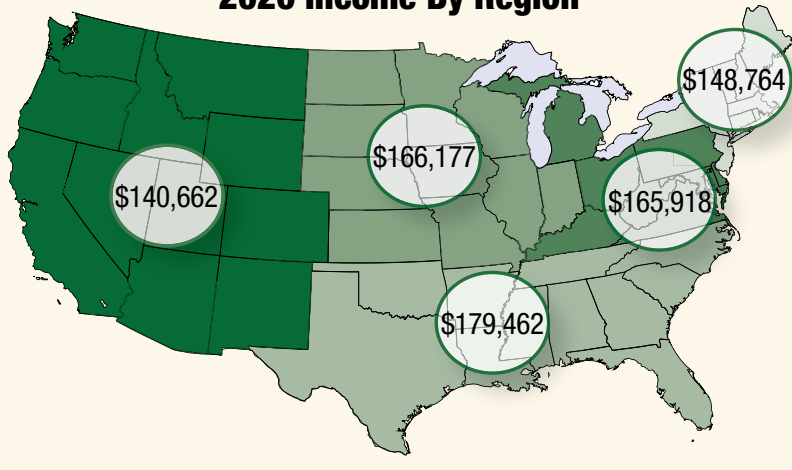
Working for yourself continues to pay off for survey respondents—literally. While the majority of participants (58%) are employed, those who are self-employed stole the show again in 2020, earning an average of \$204,347, a 61% increase from those who are employed (\$127,197 on average). While this is a significant monetary gap, it narrowed slightly over the last year due in part to both groups seeing a decrease in their average incomes from 2019, with employees making 4% less and self-employed workers making 7% less.

Of those who are employed, 46% work for another OD or an MD, 18% for a commercial firm, 10%

**2020 Self-employed Income By Practice Setting**



## 2020 Income By Region



for a hospital or VA, 9% for an HMO/PPO and 6% for a university. Eleven percent chose the “other” option. While these percentages were similar to years prior, average annual incomes reported were not; all but one category faced a decline.

University employment was the least lucrative, with professors earning an average of \$120,188 in 2020. This category fell a few ranks, and these ODs made 7% less compared with last year’s results.

Employment through a commercial firm moved down two rankings (14% less than last year at \$120,313) and working for an OD or MD (4% less at \$122,030) moved up one to comprise two of the more lower-paying gigs. HMO or PPO employees were bumped from the highest-ranking category to earn \$137,360 on average—down 15% compared with 2019. Those employed by a hospital or VA held onto the second highest-paying category for the second year in a row but made 7% less than last year at \$140,220.

Switching it up from 2019, when employees who chose the “other” option were the least profitable, this group earned the highest income this year at \$144,719, up 24%.

On the other hand, looking at those who are self-employed, 53% practice on their own, 33% are members of partnerships or groups and 13% are independent contractors. Less than 1% chose the “other” option. These percentages were comparable to last year’s; however, similarly to employed ODs, all but one self-employed category experienced a decrease in average annual income.

As it has been the past few years, working as an independent contractor was the least profitable option and only paid an average of \$123,419 in 2020, down 10% from last year.

Continuing to rise above the rest but bringing in 14% less than 2019, were self-employed ODs who work in partnerships or groups; they earned an average of \$237,459 in 2020.

### Location, Location, Location

While the decision to pack up and move takes time and thought, it might be a little easier to make if you knew you could be earning 28% more elsewhere. This year’s survey saw each region of the continental United States shift in its ranking and all but one experience

a decline in average annual income claimed by its OD residents.

Practitioners in the West were the least well-compensated this year, moving down a ranking and only making an average of \$140,662. This represents a 16% decrease in the average income reported in this region in 2019.

Moving up from the least profitable region in 2019 but still making 7% less this year, the Northeast made 6% more than the West at \$148,764. Earning 12% more than the Northeast, the Mid-Atlantic/Lower Great Lakes region was bumped from the most profitable region to practice in 2019 and made 11% less than last year’s counterparts at \$165,918. Neck-and-neck with this region was the Midwest, which moved up one ranking but made a little over 1% less than 2019, at \$166,177.

The South reclaimed its title as this year’s most profitable place to practice optometry, with ODs there earning an average income of \$179,462, 3% more than respondents from this part of the country claimed in 2019 and 8% more than those practicing in the Midwest reported in 2020.

### Gender Income Equality Faces Long Road Ahead

As we’ve consistently seen, the gender wage gap plays a prominent role

### 2020 Income By Gender





Learn More

888-579-5668  
[getweave.com/optometry](https://getweave.com/optometry)



# THE COMPLETE BUSINESS TOOLBOX

See why thousands of optometry offices across the country are using Weave. Take advantage of this month's promotion to see a demo of Weave and receive a \$50 Amazon gift card!

## WEAVE FEATURES FOR YOUR OFFICE:

---



### WEAVE PHONES

Smart phone system that can help you identify customers, heavy call times, and opportunities to schedule an overdue appointment or collect an overdue balance.



### WEAVE MESSAGES

Powerful two-way texting—wherever you are—to communicate with customers, send updates, schedule appointments and collect payments.



### WEAVE CUSTOMER INSIGHT

All your customer information in one place to give you a complete customer profile—manage, organize and view customer information for every interaction.



### WEAVE SCHEDULING

Easily view and manage your schedule—send appointment reminders, confirm or reschedule appointments and fill gaps in your schedule.



### WEAVE PAYMENTS

Full payment processing and easy collections with text to pay.



### WEAVE TEAM

Easy team communication wherever you are with Team Chat.



### WEAVE ANALYTICS


Powerful analytics to help you make better business decisions—Call Analytics, Payment Analytics.



Learn More

---

888-579-5668  
[getweave.com/optometry](https://getweave.com/optometry)



SPRING AND SUMMER 2021

# New Technologies & Treatments in Eye Care

**MARCH 19–20 | JUNE 11–12**

 **VIRTUAL EVENT**

## PROGRAM CHAIR



**Paul M. Karpecki, OD, FAAO**  
Kentucky Eye Institute  
Lexington, KY

\*Earn up to 24 LIVE COPE Credits

For up-to-date information:

**[www.ReviewEdu.com/Events](http://www.ReviewEdu.com/Events)**



\*Approval pending

Review Education Group partners with Salus University for those ODs who are licensed in states that require university credit.



# Income Survey

in optometry, and, unfortunately, it doesn't seem to be closing any time soon. Rather, the opposite was true for ODs in 2020. While the gender gap had been narrowing in recent years, in 2019 it widened by 10% to a 47% disparity between male and female ODs. The past 12 months saw the divide between genders open up even more; it now sits at 56%. This is the highest it's been over the last five years.

This year, men out-earned women on average \$194,460 to \$124,337. Further distancing the groups, men only made 2% less than their counterparts did in 2019, while women made 8% less.

The less one's experience, the less the disparity, 2019's survey found. This also holds true for 2020's results, except when it comes to beginners. Males with zero to 10 years in the field earned \$168,643 on average—56% more than their female counterparts who were also just starting out; these women made an average of \$108,216. The men in this cohort actually earned 5% more in 2020 than in 2019; for women, year-over-year earnings were 18% less, widening the 2020 income gap by 35% over the last year.

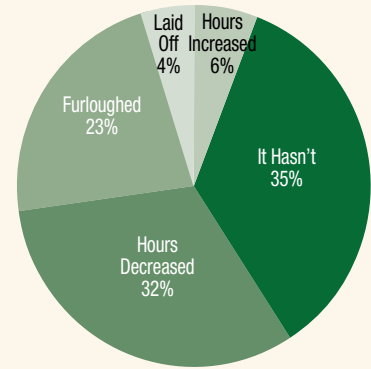
The smallest income disparity (although not small in its own right) belonged to men and women with

11 to 20 years of experience. Men earned an average of \$216,078, 45% more than the women in this group (\$148,946). This disparity is down 2% from last year's, with men making 6% more and women making 7% more compared with 2019.

The income gap between men and women with 21 to 30 years of experience under their belts was the same as that between beginners. Men earned an average of \$211,588, 56% more than women with the same level of experience, who reported an average income of \$135,727. While this gap is widening, it may continue doing so at a slower rate, as male and female ODs in this group experienced an increase in average income this year—4% and less than 1%, respectively.

Like last year, the largest income disparity between men and women at each experience level existed among those with the most experience in 2020. At an average income of \$184,353—18% less than last year—men who have been practicing for more than 30 years earned 89% more than female veterans, who sat at \$97,413 on average, 26% less than 2019. This represents another substantial step backwards for this category, with the gap continuing to widen in large increments.

## How Has COVID-19 Affected Your Employment?

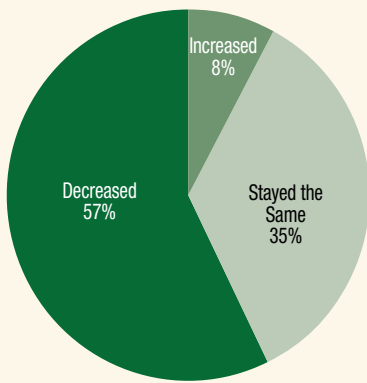


## Glass Half Full

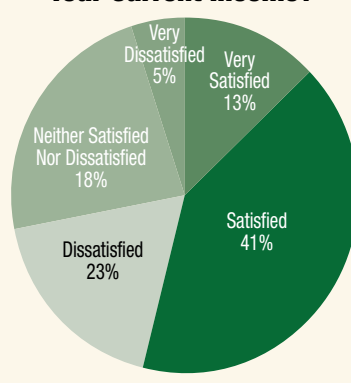
Despite the toll this year took on average annual income, the majority of respondents seemed to remain positive, as 54% reported feeling satisfied or very satisfied with their income (down from 67% last year). Many respondents had their annual take-home to thank for their comfortable lifestyle and work-life balance. Others named their income as the reason they're able to provide for their family while still planning for the future. The rewarding nature of the job took priority to a lot of respondents.

On the flip-side, many ODs who expressed dissatisfaction toward their income named COVID-19 as the culprit, with one respondent saying, "Owning my business during

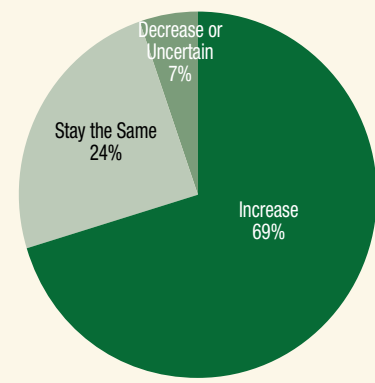
## How Has COVID-19 Affected Your Income?



## How Satisfied Are You With Your Current Income?



## Next Year, You Expect Your Income To...





this time is a huge struggle, and with the decreased income, it is borderline nightmarish.” These respondents seemed to share the mindset that they feel undervalued and think their pay is not commensurate with their experience or responsibilities. They named increased cost of business and reduced vision plan reimbursement as potential reasons. Others believe there should be more opportunities for upward mobility and pay raises.

Still, many are just happy to have a job during this period of extreme and overwhelming uncertainty. “I feel fortunate to be able to earn a good income and retain my practice during a time when so many small business owners in other industries were forced to close permanently,” said one survey respondent.

The majority of respondents had higher hopes for the year to come, with 69% expecting their income to increase (up from 53% last year). Some expressed uncertainty about the future due to factors such as the presidency and pandemic. These ODs said their answer depends on the state of the economy, the prospect of a COVID-19 vaccine and whether they will face another shutdown and more rounds of layoffs.

Many echoed a similar sentiment to the one this OD sums up: “This virus will not disappear. It will keep mutating. The general public has already been taught to be afraid of being out and in a social setting. The ‘free’ public world we had will not be back. People will still be afraid to a certain extent, and this will lead to a slower economy for most businesses, especially small ones.”

### Adapt and Overcome

As is always the case, some ODs did better than others in 2020, keeping in mind certain factors,

such as experience level, employment status, location and gender. All, however, felt the effects of the COVID-19 pandemic, even if only temporarily, in the widening gender wage gap and negative annual income rate.

Respondents didn’t let this year’s financial outcome get the best of them, though. Many have plans to offer more specialty services in the coming year, such as dry eye treatment, myopia control, specialty contact lenses and vision therapy.

Others are looking to drop certain vision plans, buy new equipment and take advantage of telemedicine. Still more hope for increased hours and patient volume and said the course of the pandemic will shape their plans to increase income and develop new sources of revenue.

The trials and tribulations of 2020 will soon be a memory, and the lessons learned will hopefully allow ODs to approach 2021 better prepared for anything life may throw at them. ■

Earn up to 12 CE credits in VAIL, CO

CLINICAL PERSPECTIVES ON PATIENT CARE

# WINTER OPHTHALMIC SUMMIT

Featuring Drs. Ron Melton & Randall Thomas  
February 3 - 5, 2021  
Vail, Colorado - Sonnenalp Hotel

Earn up to 12 CE credits. The annual meeting features relevant topics in dry eye, glaucoma, ocular disease and practice management.

[www.TarrTrek.com](http://www.TarrTrek.com)

26th Annual Surgery Report

# Pearls of POSTOPERATIVE CARE

Know the different strategies associated with each type of procedure, and be aware of potential complications. **By Andrew Mackner, OD, and Huy Do, OD, MEd**

**T**he management of post-operative ocular surgery patients is an important and growing part of optometric practice, regardless of practice modality. There are a multitude of benefits for a patient to continue their postoperative care with their primary optometrist, including but not limited to reduced travel costs and more personalized care. Additionally, in OD/MD group practices, shifting postoperative care to the optometrist opens the surgeon's schedule to manage more complex cases. Let's review how to manage some of the complications that may arise following a variety of anterior segment surgeries.

## Cataract Surgery

At the one-day postoperative exam following this procedure, elevated intraocular pressure (IOP) is a concern. Although multiple factors can contribute to this complication, retained viscoelastic material is thought to be the major contributor.<sup>1</sup>

The elevation in IOP typically peaks at three to seven hours following cataract extraction, and will



**Fig 1. Though rare, retained lens fragments may appear following uncomplicated cataract surgery.**

return to normal levels within 48 hours.<sup>2</sup> Through use of topical IOP-lowering drops, oral acetazolamide or both, reduce the pressure in patients where it is elevated above an acceptable level. Also, take patient ocular history and optic nerve head cupping into consideration. Despite elevated IOP being benign for most patients, it may be sight-threatening for certain high-risk patients, and thus prompt and appropriate treatment is necessary.

For patients with pressure above 30mm Hg, consider sideport para-

centesis for an immediate reduction in IOP. This involves applying pressure with a sterile instrument to release aqueous humor. The pressure has been shown to return to elevated levels within four hours. Add topical or oral hypotensives to ensure a sustained reduction.<sup>3,4</sup>

Patients are also at-risk for elevated IOP following the one-week post-op exam. These cases are most likely to be a steroid response, so either taper the steroids in these patients, stop them or switch the patient to an NSAID. Some cases may also require the addition of a topical hypotensive.

Postoperative cystoid macular edema (CME) following cataract surgery has been reported in 1% to 2% of cases.<sup>5</sup> Pre-existing maculopathy and prostaglandin analog use put patients at an increased risk of developing CME.<sup>5</sup> Identify CME with OCT in patients who do not correct to 20/20 with refraction and when the reduction in vision cannot be explained by other anterior or posterior segment findings.

Treatment for post-op CME involves the use of topical steroids and NSAIDs. Resolution may

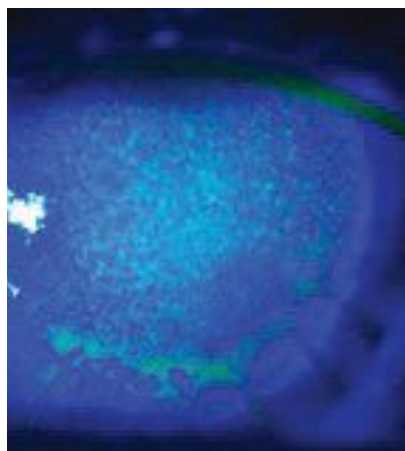
take four to 12 weeks with topical therapy.<sup>5</sup> If there is no improvement with topical therapy, refer the patient to a retina specialist for evaluation and further management.

Although relatively rare, practitioners may note retained lens fragment in the anterior chamber following uncomplicated cataract surgery. One study identified retained fragments in less than 1% of routine cases.<sup>6</sup> Most lens fragments can be identified on regular slit lamp examination, typically in the inferior angle (*Figure 1*). In cases with unexplained prolonged corneal edema or anterior chamber inflammation, perform gonioscopy to rule out a retained lens fragment. When noted, refer the patient back to the surgeon for decision on treatment with increased topical steroids vs. surgical removal.

During the first few weeks following surgery, patients may report a dark crescent or shadow temporally in their vision, which is typically related to the incision site. This visual phenomenon will fade and become less evident over the first month following surgery and eventually resolve. Less often, this can be secondary to negative dysphotopsias or even a retinal detachment. A negative dysphotopsia results from blockage of light on a portion of the retina and manifests as a dark crescent or curved shadow in the patient's vision.<sup>7</sup> In severe cases in which symptoms do not dissipate over time, consider referring back to the surgeon.

## MIGS

The goal of glaucoma treatment is to prevent progressive optic nerve damage by lowering IOP. For years, the mainstay treatment for early to mild glaucoma was primarily drops or laser treatment. More recently,



**Fig 2. Corneal edema may signal graft rejection post-PK.**

our armamentarium of glaucoma treatment options has expanded with the advent of minimally invasive glaucoma surgery (MIGS). Although MIGS procedures are effective in controlling glaucoma, they also carry a risk of visually threatening complications, and many patients require frequent follow-up visits.<sup>8</sup>

MIGS options have minimal tissue trauma, at least modest efficacy, rapid recovery and a high safety profile. MIGS can be categorized into six subgroups based on the mechanism of IOP reduction:<sup>8</sup>

- (1) trabecular meshwork bypass by stent placement
- (2) trabecular meshwork bypass by tissue excision
- (3) increased aqueous outflow through Schlemm's canal
- (4) increased aqueous outflow through suprachoroidal space
- (5) shunting aqueous outflow into the subconjunctival space
- (6) reducing aqueous production by ciliary ablation

Although there are a number of different devices and types of procedures available, selection depends on patient and surgeon preferences.

The iStent (Glaukos) and iStent Inject (Glaukos) are indicated

for patients with mild to moderate open-angle glaucoma. The first generation iStent is FDA-approved for *ab interno* placement in combination with cataract surgery.<sup>8</sup> One trial noted that 72% of iStent patients maintained an IOP less than or equal to 21mm Hg compared to 50% in the control group, and 66% of iStent patients had a decrease in IOP of more than 20% without topical hypertensives compared with 48% for controls.<sup>8</sup> Post-op complications associated with the iStent devices are well-reported, and the management of these complications can be applied to other MIGS procedures.

The most commonly reported complications associated with iStent placement include hyphema (up to 70%), stent obstruction (4% to 30%) and IOP elevation of >30mm Hg at a single visit or >10mm Hg above baseline (2% to 4.3%).<sup>8</sup> Eyes receiving the iStent inject have demonstrated a greater absolute reduction in IOP while being medication-free.<sup>9</sup> The most reported complications with iStent injection include IOP elevation or spike stent blockage or stent malposition and hyphema.<sup>10</sup>

When a stent is inserted into Schlemm's canal, a blood reflux is expected and is an indicator of proper placement. Although excessive bleeding may reduce vision at the one-day postoperative exam and a micro-hyphema may be noted, the OD can monitor this complication without further intervention, as it is typically self-limiting. Patients with hyphema may also be started on a cycloplegic and advised to sleep with their head slightly elevated. Cases of severe or recurrent hyphema may require device removal.<sup>8</sup>

Manage IOP elevation following MIGS procedures with topical

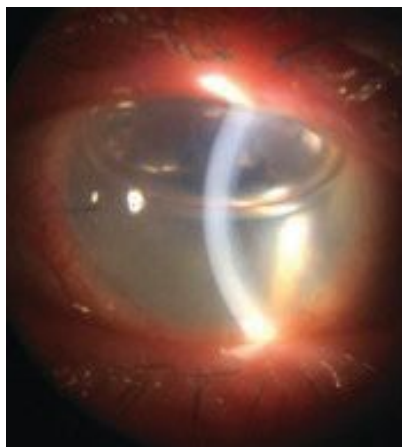## Post-op Management

hypotensives, as the increase in IOP in these cases is typically transient. Once the patient's IOP is under adequate control, reduce the number of meds. If the patient's IOP remains elevated, perform gonioscopy to assess for proper placement of the stent and evaluate for any peripheral anterior synechiae or iris-stent obstruction. In a randomized, controlled trial for iStent, 4.3% of patients required repositioning of the stent because it was placed above or below the level of the trabecular meshwork.<sup>8</sup>

Pay close attention to gonioscopy to ensure proper positioning of the stent. Stents that are positioned more posteriorly and in patients with narrow angles are more likely to become occluded with iris. If stent obstruction is noted, refer the patient back to their surgeon for evaluation. Some cases of stent obstruction can be treated with Nd:YAG laser while others may necessitate repositioning, removal or replacement.<sup>8</sup> Surgical intervention to relieve stent obstruction or malposition may be necessary.<sup>8</sup>

When and how to reduce a patient's topical medications following a MIGS procedure depends on the patient's level of glaucoma and risk of progression. Usually it is best to discontinue prostaglandin analogs at the one-day post-op visit or substitute them with another topical hypotensive if the patient still requires IOP reduction.

Prostaglandin analogs can cause an increase in or slow the resolution of postoperative inflammation. Patients with mild glaucoma and low risk of progression can typically be taken off one of their medications at either the one-day or one-week postoperative exam. For those with moderate to severe glaucoma, the MIGS procedure often acts as an additive treatment,



**Fig 3. Post-EK, the surgeon will fill the anterior chamber with air to keep the graft adherent to the host cornea.**

and reducing topical hypotensives or oral medications may not be indicated. If the patient is a steroid responder, wait until they are completely off of steroids for an accurate IOP assessment. Lastly, establish a new baseline for the patient following MIGS surgery to more effectively manage their glaucoma moving forward.

### Penetrating Keratoplasty (PK)

This transplantation involves the entire cornea and all of its layers. It is indicated in conditions such as advanced keratoconus, corneal degenerations and dystrophies, deep corneal scarring due to trauma or infection and corneal perforations.

Successful post-op management of PK starts with the patient understanding the expectations and limitations of the surgery. For PKs, a best-corrected visual acuity of 20/30 is considered successful. In most cases, patients will have high refractive error and astigmatism.

Patients must also understand that visual recovery will be a long, slow process, so they must be compliant with their post-op eye drops to prevent rejection. Eye drops are used post-surgically for at least one

year or indefinitely in many cases.

The typical post-op ocular medication schedule post-PKs includes a topical steroid (e.g., prednisolone acetate 1%), topical antibiotic (e.g., moxifloxacin, besifloxacin) and an NSAID (e.g., ketorolac, bromfenac) (Table 1). This will vary depending on the surgeon and the medication used.

Corneal epithelial defects one-day post-op occur up to 67% of the time.<sup>11</sup> Smaller defects generally resolve within a few days, but larger defects require additional management. For larger defects, consider a bandage contact lens or a temporary tape eyelid tarsorrhaphy to promote healing. Alternatively, use a cryopreserved or dehydrated amniotic membrane to speed up healing or in cases where the patient's epithelial defect persists.

A key short- and long-term complication to monitor for is corneal graft rejection. This complication's peak risk is within the first 1.5 years after transplantation.<sup>11</sup> However, even grafts that are 20 years old may unexpectedly undergo rejection.

The most common sign of corneal graft rejection is corneal edema (Figure 2).<sup>11</sup> Other signs to look for include white blood cells in the anterior chamber with or without hypopyon, endothelial keratic precipitates, neovascularization crossing the graft-vs.-host line, infiltrates and an epithelial or endothelial (Khodadoust) rejection line of white blood cells across the cornea.

It is imperative to discuss symptoms of rejection with the patient. An easy-to-remember mnemonic that is generally sufficient in education is "RSVP:" redness, sensitivity to light, vision loss and pain.

Loose or broken sutures can lead to irritation, corneal ulcers and, worst-case scenario, corneal graft



rejection. Interrupted or running sutures can secure the corneal PK graft but may become loose or break over time. Remove any loose sutures that no longer serve their function promptly. The area near the base of the suture can also be at high-risk for development of a corneal ulcer. Locate a loose suture by staining the eye with sodium fluorescein (NaFl) and viewing it through a cobalt blue filter. The NaFl dye will pool underneath the loose suture.

Corneal graft rejection treatment involves the frequent use of a topical steroid eye drop (e.g., prednisolone acetate 1%, difluprednate), typically one drop every two hours, and an eventual taper once the eye shows signs of improvement. Depending on the severity, the patient may require concurrent oral steroids or a subconjunctival steroid injection.

### Endothelial Keratoplasty (EK)

EKs are indicated in posterior corneal conditions such as Fuchs' dystrophy, posterior polymorphous dystrophy, or endothelial decompensation from ocular surgeries. The most common are Descemet's membrane endothelial keratoplasty (DMEK) and Descemet's stripping automated endothelial keratoplasty (DSAEK).

In a DMEK graft, the endothelium and Descemet's membranes are transplanted, while, in a DSAEK graft, the endothelium, Descemet's membrane and the posterior stroma are replaced. Also, DMEK grafts have less endothelial cell loss long-term, greater visual quality and outcome and a lower risk for rejection.<sup>12-14</sup> DSAEKs are reserved in more complicated cases, such as in eyes with preexisting tube shunts.

As with PK grafts, successful management of EK grafts begins

**Table 1. Drop Schedule for Post-PK and -EK Management**

	Day 1	Week 1	Month 1	Month 3	Month 6	Year 1
Prednisolone acetate 1%	QID	QID	QID	TID	BID	OD or B/C
Moxifloxacin 0.5%	QID	D/C	—	—	—	—
Bromfenac 0.07%	QD	QD	D/C	-0.42	—	—

with patient education. After the transplant, the surgeon will fill up to 80% of the anterior chamber with air to keep the graft adherent to the host cornea. On the one-day post-visit, the surgeon will use less (Figure 3). Too small an air bubble raises the risk for graft detachment, but too much air may result in pupillary block and subsequent spike in IOP. Any eye with a bubble that covers 20% or less of the anterior chamber should be considered for a rebubble the same day. In order for an air bubble to function correctly, the patient must spend the majority of their time supine, with their eyes looking straight up, for several days after surgery. This needs to be reiterated to increase compliance and reduce complications.

Signs and symptoms of graft rejection in these cases are similar to those in PKs. Visualize graft detachments under the slit lamp using an optic section, focusing on the posterior cornea. Overlying sectoral stromal edema can help guide the clinician in identifying a graft detachment. Treatment includes rebubbling and ensuring compliance with supine positioning for the next three to five days. The post-op drop schedule for EKs is similar to that of PKs.

Postoperative surgical procedure management is a growing and important part of contemporary optometric practice. Be prepared to manage postoperative complications that are within your scope of practice and make appropriate and

timely referrals back to the surgeon if and when surgical intervention is indicated. ■

*Dr. Mackner completed his residency in ocular disease and surgical comanagement at Omni Eye Services in New York and New Jersey. He practices at Edina Eye Physicians and Surgeons in Minnesota.*

*Dr. Do completed his residency in ocular disease and surgical comanagement at Georgia Eye Partners in Atlanta. He currently practices at Kaiser Permanente Northwest in Portland, OR. He is a Fellow of the American Academy of Optometry.*

1. Simon SS, Chee YE, Haddadin RI, Veldman PB, et al. Achieving target refraction after cataract surgery. *Ophthalmology*. 2014;121(2):440-4.
2. Kim JY, Jo M-W, Brauner SC, et al. Increased intraocular pressure on the first postoperative day following resident-performed cataract surgery. *Eye*. 2011;25(7):929-36.
3. John M, Soucek J, Noblitt R, et al. Sideport incision paracentesis vs. anti-glaucoma medication to control postoperative pressure rises after intraocular lens surgery. *J Cataract Refract Surg*. 1993;19(1):62-63.
4. Ahmed II, Kranenmann C, Chipman M, Malam F. Revisiting early postoperative follow-up after phacoemulsification. *J Cataract Refract Surg*. 2002;28(1):100-8.
5. Henderson BA, Kim JY, Ament CS, et al. Clinical pseudophakic cystoid macular edema: risk factors for development and duration after treatment. *J Cataract Refract Surg*. 2007;33(9):1550-8.
6. Zavodni ZJ, Meyer JJ, Kim T. Clinical features and outcomes of retained lens fragments in the anterior chamber after phacoemulsification. *Am J Ophthalmol*. 2015;160(6):1171-5.
7. Mamilis N. Negative dysphotopsia following cataract surgery. *J Cataract Refract Surg*. 2010;36(3):371-2.
8. Yook E, Vinod K, Panarelli JF. Complications of micro-invasive glaucoma surgery. *Curr Opin Ophthalmol*. 2018;29(2):147-54.
9. Manning D. Real-world case series of iStent or iStent inject trabecular micro-bypass stents combined with cataract surgery. *Ophthalmol Ther*. 2019;8(4):549-61.
10. Popovic M, Campos-Moller X, Saheb H, Ahmed IK. Efficacy and adverse event profile of the iStent and iStent inject trabecular micro-bypass for open-angle glaucoma: a meta-analysis. *J Curr Glaucoma Pract*. 2018;12(2):67-84.
11. Stechschulte SU, Azar DT. Complications after penetrating keratoplasty. *Int Ophthalmol*. 2000;40(1):27-43.
12. Feng M, Price M, Miller J, Price F. Air re-injection and endothelial cell density in Descemet's membrane keratoplasty: five-year follow-up. *J Cataract Refract Surg*. 2014;40(7):1116-21.
13. Guerra FP, Anshu A, Price MO, et al. Descemet's membrane endothelial keratoplasty: prospective study of one-year visual outcomes, graft survival and endothelial cell loss. *Ophthalmology*. 2011;118(12):2368-73.
14. Anshu A, Price MO, Price FW. Risk of corneal transplant rejection significantly reduced with Descemet's membrane endothelial keratoplasty. *Ophthalmology*. 2012;119(3):536-40.

# Meet the New Trifocal IOL

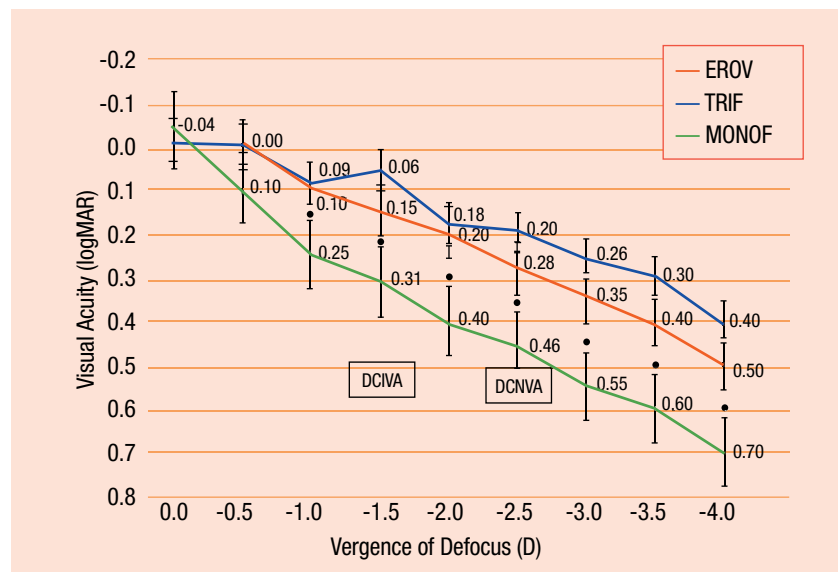
The most recent addition to the market is expanding the candidate pool for multifocal IOLs. **By Oliver Kuhn-Wilken, OD**

**A**s the first—and so far only—trifocal intraocular lens (IOL) available in the United States, the PanOptix (Alcon) is different from any other multifocal IOL in our armamentarium. Our surgery center has been working extensively with this new lens, and the results have been favorable so far. As with all multifocal IOLs, the PanOptix does involve trade-offs, and your patient must be realistic about what this lens can deliver. However, it also brings some new features not available in other lenses.

This article discusses the new lens design, how to identify good and bad candidates, how it compares with other lenses and post-op tips.

## A Different Kind of IOL

The PanOptix is an ultraviolet-filtering, foldable, one-piece lens. The anterior surface has an inner 4.5mm diameter diffractive zone



**Fig. 1. Mean binocular visual acuity with correction for distance vision measured four months postoperatively through three different IOLs: the Alcon PanOptix (blue), the J&J Symphony (red) and the Alcon monofocal AcrySof SN60WF (green). The PanOptix demonstrates peaks at plano, -1.50 and -2.50.<sup>11</sup>**

and is designed with a slight negative spherical aberration to counteract the positive spherical aberration of the average human

cornea.<sup>1</sup> The PanOptix has three focal points: emmetropia, +1.67D (60cm, or 24”) and +2.50D (40cm, or 16”). The lens distributes 44%

of incoming light energy to the far focus, 22% each to the intermediate and near foci, while 12% is lost.<sup>2</sup>

Previously, multifocal IOLs available in the United States created a bifocal optical system (with the ability to extend depth of focus in some cases). As a result, surgical centers have had to match the appropriate lens to the patient's preferred near point. The PanOptix's trifocal design makes this decision less important, and the three foci correspond well to most common tasks that require sharp acuity, such as driving, computer use and reading (*Figures 1 and 2*).

Good vision in any multifocal IOL requires tight astigmatism control. PanOptix is available in toric powers, with half-diopter steps that correspond to corneal astigmatism from roughly 1.00D to 2.50D. Keep in mind, only corneal astigmatism (i.e., keratometry) justifies a toric IOL, not total refractive astigmatism.

### Update Your Candidate Pool

Personality type is the key predictor of success with any multifocal IOL, including PanOptix.<sup>3</sup> Ideally, your patient should have a positive approach to life and be strongly motivated to see without glasses. Researchers have studied correlations between personality traits and satisfaction with multifocal IOLs and found patients with dominant traits of conscientiousness and agreeableness have the highest satisfaction.<sup>4</sup>

Patient selection should also include an individual's hobbies and habits. For example, a patient who wants to hike, shop online and read, all without glasses, might be well served by the three focal points of the PanOptix.

A patient's visual status is another important factor. Hyperopes have generally been the low-hanging fruit for multifocal IOLs; they often begin wearing correction later in life and are sometimes strongly motivated to return to freedom from glasses.

Historically, clinicians have shied away from promoting multifocal IOLs to myopes, as they are often highly accustomed to wearing glasses. However, we have found that myopes can be strong candidates for the PanOptix, since

the lens allows them to keep their functional near vision while also providing useful intermediate and distance vision. However, they must be aware and accepting of the aberrations intrinsic to multifocal IOLs.

Diffraction optics are not a biologically evolved focusing system, and even the best candidates usually require an adaptation period.<sup>5</sup> Neuroadaptation refers to changes the brain undergoes to accommodate a new condition—in this case, the visual

### A Quick Guide to Diffractive Optics

Most modern multifocal IOLs now incorporate diffractive optics, because diffraction offers better use of light with fewer dysphotopsias than simple refraction.

Diffraction occurs when light passes a sharp-edged obstruction—for instance, the concentric saw-tooth pattern on the surface of a multifocal IOL—and it propagates forward as waves. The speed of light is faster in aqueous than in the lens material, so the thicker side of each saw-tooth delays the light by approximately half a wavelength. When the light waves exit the posterior lens surface, they produce bands of constructive and destructive interference: bands where the light reinforces itself, and bands where the light negates itself.<sup>1,2</sup>

Typically, bifocal IOLs use the base refractive power of the IOL for far vision and diffracted light to create a near focus (first-order diffraction). However, diffraction must also bend some light in diminishing amounts toward even closer foci (e.g., second order, third order, etc.). This light is lost to useful vision and produces glare and haloes. The second diffractive order has a vergence that is double the amount of the first order, so if the bifocal is designed for a +3.00D add, the second order will have a vergence power of +6.00D.<sup>3</sup>

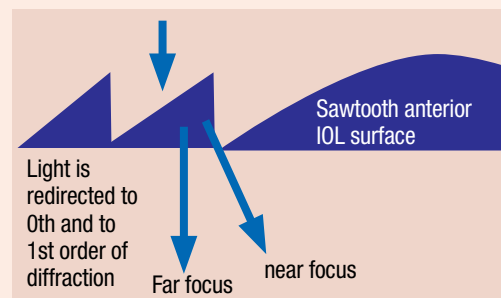
Trifocal IOLs use light diffracted to both an intermediate and a near focus.<sup>4</sup> They are designed so that the otherwise wasted light from the intermediate focal point's second diffractive order strengthens the near focal point. This is why bifocal IOLs lose about 19% of incident light, while the PanOptix only loses 12%.<sup>1</sup>

1. Cohen AL. Diffractive bifocal lens designs. *Optom Vis Sci.* 1993;70:6:461-68.

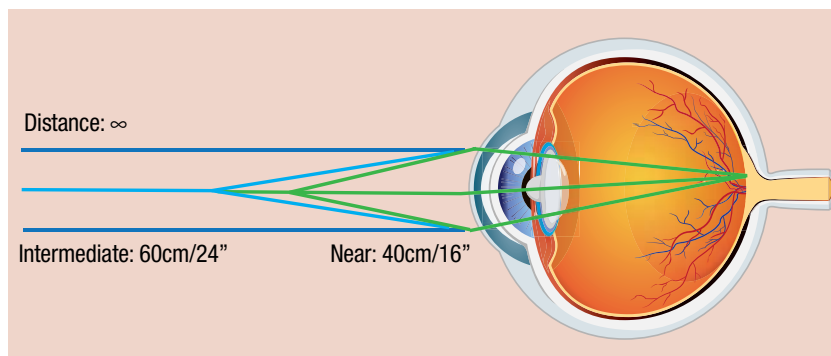
2. Gatinel D. La multifocalité pour les nuls. *Réalités ophtalmologiques.* 2017;240:15-19.

3. Gatinel D. Topography and longitudinal chromatic aberration characterizations of refractive-diffractive multifocal intraocular lenses. [www.gatinel.com/en/2019/11/topography-and-longitudinal-chromatic-aberration-characterizations-of-refractive-diffractive-multifocal-intraocular-lenses-loicq-j-willet-n-gatinel-d-jcrs-2019](http://www.gatinel.com/en/2019/11/topography-and-longitudinal-chromatic-aberration-characterizations-of-refractive-diffractive-multifocal-intraocular-lenses-loicq-j-willet-n-gatinel-d-jcrs-2019). Accessed October 15, 2020.

4. Loicq J, Willet N, Gatinel D. Topography and longitudinal chromatic aberration characterizations of refractive-diffractive multifocal intraocular lenses. *J Cataract Refract Surg.* 2019;45:1650-59.



**The phase shift induced by a diffractive step is equal to half a wavelength, which deflects the wavefront towards a single focus, the first diffraction order. Some light passes through undeflected: the zero order of diffraction. For clarity, higher orders of diffraction are not shown.**



**Fig. 2. PanOptix is designed for three focal points: plano (distance), intermediate (60cm, or 24"), and near (40cm, or 16"). Image adapted from Alcon.**

system learning to work with a new way of seeing. According to fMRI studies, this process continues for approximately six months after implantation of a multifocal IOL.<sup>6</sup> It can be helpful to educate potential candidates that, while their vision should be good initially, they may notice improvements for months after the procedure.

For patients with very mild cataracts, you can trial multifocal contact lenses before surgery as a rough approximation of the kind of vision they can expect with a multifocal IOL.<sup>7</sup> The simulation is rough but can yield important insights.

## Red Flags

The PanOptix, like all IOLs, comes with trade-offs, and you must give candidates realistic expectations of what the lens can and cannot deliver.

The lens creates permanent haloes and starbursts around all point sources of light; these are especially evident at night, but may also cause a slight softening of vision during the daytime. Patients who require crisp vision above all else, or patients who need sharp nighttime vision (e.g., bus drivers or truckers), will be happier with single-focus IOLs.

Individuals with a dominant personality trait of neuroticism (i.e., they report frequent mood swings, are often anxious or irritated, struggle to relax and often feel down) are not likely to enjoy multifocals of any kind and will do better with a simpler lens.<sup>8</sup>

Dissatisfaction with multifocal IOLs is also strongly correlated with personality traits of orderliness and compulsive checking.<sup>8</sup> In your clinic, these traits may manifest as frequent dissatisfaction with their vision correction, and a multifocal IOL is likely a mistake for these patients.

The three focal points of the PanOptix are well-suited to many activities, but be cognizant of the patient's specific distance needs. A cellist, for instance, will want sharp vision at their music stand, typically close to 36". A hunter who wants to see the iron sight on the end of their firearm may want a focal distance at 40". The PanOptix's 24" intermediate point will not help at those distances.

## Some Things Don't Mix

Almost any ocular disease that permanently limits vision, such as corneal and macular diseases, is an absolute contraindication for a PanOptix IOL. Like all multifocal IOLs, PanOptix degrades contrast

sensitivity, and these diseases compound this effect.

Many surgeons will implant a PanOptix in post-LASIK patients if everything else is favorable, but very few will do so if the patient has undergone radial keratotomy. We do not offer the PanOptix to monocular or amblyopic patients, as the lens works best binocularly.

Dry eye also represents a challenge. Multifocals rarely give chronic dry eye patients stable enough vision to be worth the cost. However, if you feel confident the dry eye can be successfully managed for the patient's lifetime, it is reasonable to consider the PanOptix. It is important to discuss this carefully with your patient to make sure they fully understand their commitment.

The PanOptix must control astigmatism to work well. If your patient has corneal astigmatism in excess of 3.00D, even the toric version will not provide good vision.

## The Competition

PanOptix enters a US market dominated by single-focus IOLs. At present, only 7% of cataract patients elect multifocals—all others choose monofocals. Due to its trifocality, PanOptix already has proven itself a formidable competitor in the current IOL landscape. Head-to-head studies comparing PanOptix to bifocal IOLs are rare, but so far, the limited investigations tend to show greater patient satisfaction and fewer visual side effects with the PanOptix.<sup>2</sup>

Perhaps the most significant competitor to the PanOptix is the Symphony (Johnson & Johnson Vision). Although the Symphony and the PanOptix have very different designs, they are currently the most optically sophisticated IOLs avail-



able domestically (*Figure 3*). The Symphony, marketed as an extended depth of vision IOL, is functionally akin to a bifocal IOL, with a near point at +1.75D (57cm, or 22"). This causes the focal points to overlap, especially through a small pupil.<sup>9</sup>

In head-to-head trials between the PanOptix and the Symphony, patients' distance and intermediate vision were indistinguishable between the two IOLs, but uncorrected near vision was better with the trifocal.<sup>9,10</sup> Both lenses are known for reduced glare and haloes compared with other multifocals.<sup>11,12</sup>

In optical bench comparisons, PanOptix and Symphony rate almost identically. They measure similarly on modulation transfer function, which combines resolution (i.e., acuity) and contrast sensitivity into one graph, and on the Strehl ratio, which quantifies how much an optical system aberrates a point source of light.<sup>11,13</sup> Their resolution is not as crisp as that of a monofocal, but close.

We have implanted several patients with a PanOptix in one eye and a Symphony in the other to achieve a variation of monovision, and have observed good results. Anecdotally, these patients report a very slight superiority in crispness at distance through the Symphony compared with the PanOptix. Thus, I consider the Symphony a good IOL for active patients who prioritize acuity but would like some near vision, and I suggest the PanOptix for patients who pursue a wide range of activities and want to read without glasses.

### Post-op Coaching

Your PanOptix patient will depend on you to guide them through the post-op period.

Remind your patient that, due to the necessary neuroadaptation, they will continue to see subtle improvements in their vision over time. We have noticed a tendency for relatively poor vision at the one-day exam despite an absence of any vision-limiting issues, which generally recovers by the one-week mark.


As with all multifocal IOLs, the PanOptix performs best with a good tear film, so you may need to recommend frequent instillation of non-preserved artificial tears.

The PanOptix also works best when it is well-centered behind the pupil. Small levels of decentration do not appear to significantly diminish the lens power. However, if the lens is so far decentered that part of its central optic is occluded by the pupil's edge in bright light, consider calling the surgery center.

Unfortunately, there is little a surgeon can do to correct this short of a pupilloplasty or IOL exchange.

If your patient complains of blur, your first step is to rule out an inaccurate refractive outcome, as this accounts for the majority of dissatisfied multifocal patients.<sup>14</sup> Refractions may have a somewhat soft endpoint, as the patient is able to simultaneously focus through multiple levels of vergence. The trick is to come out of plus slowly and take the first endpoint that gives 20/20 vision. If refractive error is the problem, the surgical center may consider an exchange or refractive laser.

The PanOptix is highly vulnerable to astigmatism, so if your patient is dissatisfied with their vision and you are noticing astigmatism of 1.00D or greater,



**Fig. 3. Side-by-side slit lamp view of the PanOptix (left) and the Symphony (right). The PanOptix has a smaller central optic and syncopated ring spacing.**

consider referring back to the surgeon for a surgical fix—a rotation if the problem is a toric that isn't situated on its intended axis, or LASIK or limbal relaxing incisions if that makes more sense.<sup>15</sup>

Many patients will want to know their odds of becoming free of glasses. Spectacle independence post-surgery depends significantly on patient personality and motivation. Still, the results so far have been encouraging. In studies,

67% to 96% of patients who received the PanOptix report never having to wear glasses for any purpose.<sup>11,16-18</sup>

## Final Thoughts

Since their introduction to the market many years ago, multifocal IOLs have steadily improved. We owe it to our patients to learn the benefits, contraindications and clinical care for each new lens. No lens can replicate natural, pre-presbyopic vision, and doctor and

patient alike must acknowledge that reality. Still, with its improved range of vision, useful focal points and minimal aberrations, the PanOptix will undoubtedly expand the candidate pool for multifocal IOLs. ■

*Dr. Kuhn-Wilken is a staff optometrist at Pacific Cataract & Laser Institute in Tualatin, OR.*

## On the Horizon

The PanOptix is not the only trifocal IOL in the global market, since these IOLs have been available outside the US since 2010. Besides the PanOptix, the worldwide market leaders are AT Lisa (Carl Zeiss Meditec) and FineVision trifocal extended depth-of-focus lens (PhysIOL).

Both AT Lisa and FineVision come in toric models, and they share many of the high-performance qualities of the PanOptix.<sup>1</sup> The crucial difference is that their intermediate focus is at 1.67D (80cm, or 31"), which is significantly less useful than the 24" intermediate focal point of the PanOptix. For comparison, a 31" focal point is the comfortable reading distance for an individual who is 6'8".

Other pseudo-accommodative IOLs are in the pipeline, and these appear to offer several advantages. Poised to enter the market soon are several non-diffractive IOLs, including the Alcon Vivity and Johnson & Johnson Eyehance, both of which purport to use advanced manipulation of the wavefront to achieve an extended range of focus with minimal compromise to distance vision.<sup>2</sup> Also, Johnson & Johnson expects to soon release an updated and more powerful version of the Symphony IOL—the Symphony Plus—as well as a hybrid extended depth of focus/multifocal lens, the Synergy IOL.<sup>3</sup>

The AcuFocus IC-8 uses a much older technology to extend the depth of focus: the pinhole effect. The IC-8 has an opaque annular mask with a central aperture diameter of 1.36mm. Crucially, doctors have found it is still possible to do a fundus exam and even retinal procedures in patients implanted with this IOL.<sup>4</sup>



Photo: Acufocus

**The pinhole IC-8 intraocular lens.**

1. Dalton M. Trifocal outperforming other premium lenses. Eyeworld. 2017. [www.eyeworld.org/trifocals-outperforming-other-premium-lenses](http://www.eyeworld.org/trifocals-outperforming-other-premium-lenses). Accessed October 15, 2020.  
 2. Ligabue E. In the Pipeline. AcrySof IQ Vivity: natural vision at a range of distances provided by novel optical technology. Cataract Refract Surg Today. April 2020. [crstoday.com/articles/2020-apr/in-the-pipeline](http://crstoday.com/articles/2020-apr/in-the-pipeline). Accessed October 15, 2020.  
 3. Assil KK. In the pipeline. Tecnis Symphony Plus: an IOL with novel advances, including a violet light blocker. Cataract Refract Surg Today. April 2020. [crstoday.com/articles/2020-apr/in-the-pipeline](http://crstoday.com/articles/2020-apr/in-the-pipeline). Accessed October 15, 2020.  
 4. Dick HB, Piovella M, Vukich J, et al. Prospective multicenter trial of a small-aperture intraocular lens in cataract surgery. J Cataract Refract Surg. 2017;43:956-68.

1. Kohnen T, Marchini G, Alfonso JF. Innovative trifocal (quadrifocal) presbyopia-correcting IOLs: 1-year outcomes from an international multicenter study. J Cataract Refract Surg. 2020;46:1142-48.  
 2. Sudhir RR, Dey A, Bhattacharyya S, et al. AcrySof IQ PanOptix intraocular lens versus extended depth of focus intraocular lens and trifocal intraocular lens: a clinical overview. Asia-Pac J of Ophthalmol. 2019;8(4):335-49.  
 3. Fiske DW. Consistency of the factorial structures of personality ratings from different sources. J Abnormal Soc Psychol. 1949;44(3):329-44.  
 4. Rudalevicius P, Lekaviciene R, Auffarth GU, et al. Relations between patient personality and patients' dissatisfaction after multifocal intraocular lens implantation: clinical study based on the five factor inventory personality evaluation. Eye. 2020;34(4):717-24.  
 5. Alió JL, Pikkol J, eds. Multifocal intraocular lenses: the art and the practice. Switzerland: Springer International Publishing; 2014.  
 6. Rosa AM, Miranda AC, Patricio MM, et al. Functional magnetic resonance imaging to assess neuroadaptation to multifocal intraocular lenses. J Cataract Refract Surg. 2017;43:1287-96.  
 7. Dalton M. Trifocal outperforming other premium lenses. Eyeworld. 2017. [www.eyeworld.org/trifocals-outperforming-other-premium-lenses](http://www.eyeworld.org/trifocals-outperforming-other-premium-lenses). Accessed October 15, 2020.  
 8. Mester U, Vaterrodt T, Goes F, et al. Impact of personality characteristics on patient satisfaction after multifocal intraocular lens implantation: results from the "happy patient study." J Refract Surg. 2014;30(10):674-78.  
 9. Loicq J, Willet N, Gatinel D. Topography and longitudinal chromatic aberration characterizations of refractive-diffractive multifocal intraocular lenses. J Cataract Refract Surg. 2019;45:1650-59.  
 10. de Medeiros AL, Motta AFP, Vilar BV, et al. Comparison of visual outcomes after bilateral implantation of a diffractive trifocal intraocular lens and blended implantation of an extended depth of focus intraocular lens with a diffractive bifocal intraocular lens. Clin Ophthalmol. 2017;11:1911-16.  
 11. Monaco G, Gari M, Di Censo F, et al. Visual performance after bilateral implantation of 2 new presbyopia-correcting intraocular lenses: Trifocal versus extended range of vision. J Cataract Refract Surg. 2017;43(6):737-47.  
 12. Ruiz-Mesa R, Abengózar-Vela A, Ruiz-Santos M. A comparative study of the visual outcomes between a new trifocal and an extended depth of focus intraocular lens. European J Ophthalmol. 2018;28(2):182-87.  
 13. Coehener B, Boutillier G, Lamard M, et al. A comparative evaluation of a new generation of diffractive trifocal and extended depth of focus intraocular lenses. J Refract Surg. 2018;34(8):507-14.  
 14. De Vries NE, Webers CAB, Touwslager WRH. Dissatisfaction after implantation of multifocal intraocular lenses. J Cataract Refract Surg. 2011; 37:859-65.  
 15. Carones F. Residual astigmatism threshold and patient satisfaction with bifocal, trifocal, and extended range of vision intraocular lenses. Open J Ophthalmol. 2017;7:1-7.  
 16. Mencucci R, Favuzza E, Caporossi O, et al. Comparative analysis of visual outcomes, reading skills, contrast sensitivity, and patient satisfaction with two models of trifocal diffractive intraocular lenses and an extended range of vision intraocular lens. Graefes Arch Clin Exper Ophthalmol. 2018;256:L1913-22.  
 17. Kohnen T, Herzog M, Hemkepler E, et al. Visual performance of a quadrifocal (trifocal) intraocular lens following removal of the crystalline lens. Am Journal of Ophthalmol. 2017;12:52-62.  
 18. Singh B, Sharma S, Dada S, et al. Comparative evaluation of visual outcomes after bilateral implantation of a diffractive trifocal intraocular lens and an extended depth of focus intraocular lens. Eye Contact Lens. 2020;46(5):314-18.

SAVE THE DATE  
**COVID Combat Conference**

**FEBRUARY 27, 2021**

 **VIRTUAL EVENT**

Please mark your calendars to join your colleagues for an interactive, one-day, multi-course CE meeting focused on infection control, prescribing and screening modifications, patient and staff safety, and effectively restarting and growing your practice in a peri- and post-COVID world.

**PROGRAM CHAIR**



**Paul M. Karpecki, OD, FAAO**  
Kentucky Eye Institute  
Lexington, KY

**Agenda coming soon**

For up-to-date information:

**[www.ReviewEdu.com/Events](http://www.ReviewEdu.com/Events)**



\*Approval pending

Review Education Group partners with Salus University for those ODs who are licensed in states that require university credit.



26th Annual Surgery Report

# To Infinity and Beyond LASIK: A Refractive Surgery Update

Here's what you need to know about the new procedures that are expanding patients' options and improving visual outcomes. **By Bobby Saenz, OD, MS, and Mitch Ibach, OD**

**W**ith near-instantaneous, life-changing visual improvement, laser-assisted *in situ* keratomileusis (LASIK) is widely considered one of the best elective procedures, with postoperative dissatisfaction rates near 1%.<sup>1</sup> Another marker of post-op success is visual acuity, and PROWL 1 and 2, which detailed patient-reported outcomes with LASIK, found uncorrected visual acuity (UCVA) of 20/20 or better in 97.5% and 91.5% of patients, respectively.<sup>2,3</sup>

It's no wonder LASIK is a mainstay for patients with ametropia who desire optical independence. But LASIK isn't the only game in town now, and patients have some choices to make when deciding on the best refractive surgery option for them. Here, we discuss where LASIK currently stands and some of the newer procedures available, including small-incision lenticule extraction (SMILE), implantable collamer lens (ICL) and refractive lens exchange (RLE).

## LASIK Basics

This surgical option involves two major steps: (1) the creation of a stromal flap and (2) laser tissue ablation. In corneal refractive surgery, LASIK is unique in that it necessitates two lasers—a femtosecond laser for flap creation and an excimer laser to reshape the corneal

curvature. Flap creation significantly accelerates visual recovery, which lends itself to near-instant gratification for patients. Postoperatively, patients typically experience transient symptoms, such as mild stinging, watering and photophobia.

LASIK candidacy covers a wide patient base. The procedure is FDA-

LASIK Advances		
Technology	Process	Benefits
Wavefront-guided	Wavefront aberrometers pass a single beam of light through the tear film, cornea, lens and vitreous, and the image that reports back from the retina is a patient's wavefront.	This measures lower-order aberrations, such as sphere and cylinder, and HOAs, such as coma, trefoil and spherical aberration. This is a great choice for patients with high preexisting HOAs.
Wavefront-optimized	This theoretically bypasses the individual's aberrometry with a goal of creating the "perfect" wavefront using age-matched norms and algorithms.	This aims to maintain corneal asphericity and minimize laser-induced spherical aberrations.
Topography-guided	These procedures are planned around the corneal data and shape. Using a placido disc topographer, this technology measures regular and highly aberrated corneas.	This is the first laser platform dedicated to normalizing the corneal shape while also minimizing refractive error. In addition, these treatments are independent of pupil size and center on the corneal apex rather than the pupil center. <sup>1</sup>

1. Friess DW, Stulting DR. Results of the T-CAT Phase III Clinical Trial. *Cataract Refract Surg Today*. May 2015. [Epub ahead of print].



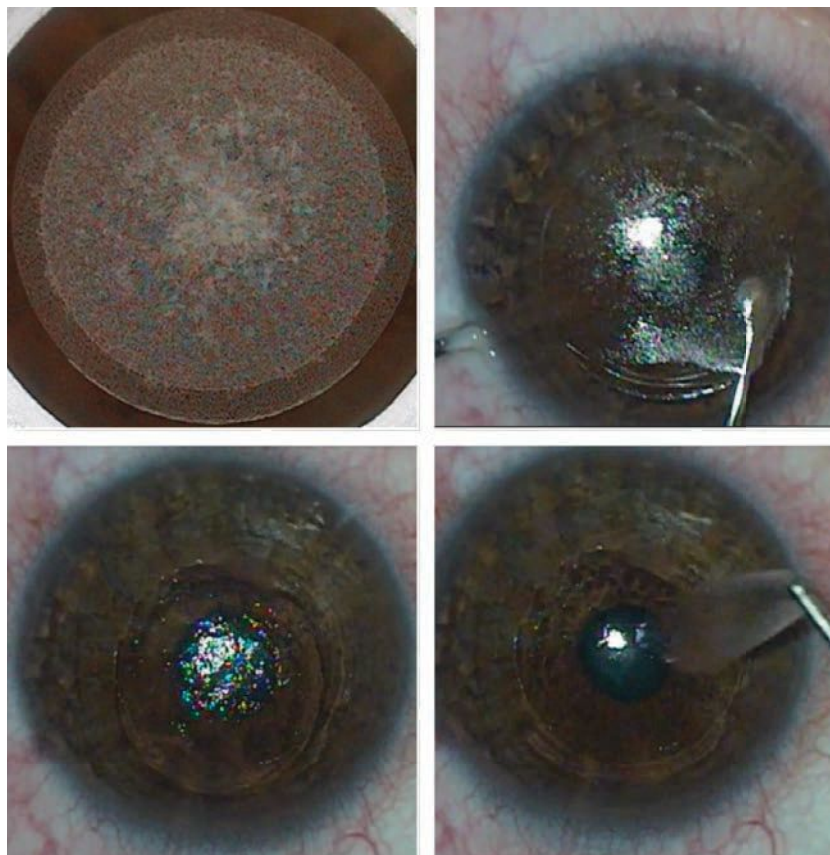
approved for myopia up to 14.00D and hyperopia and astigmatism up to 6.00D.<sup>4</sup> However, in our clinic we typically only treat up to 10.00D of myopia, 4.00D of hyperopia and 6.00D of astigmatism. If a patient fits within these parameters, the first consideration is corneal thickness, which needs to be sufficient to safely accommodate the necessary dioptric corrections. Average laser flaps are around 110 $\mu$ m, and we know the procedure removes around 16 $\mu$ m of tissue per diopter. These numbers help surgeons calculate residual stromal bed (RSB). A common conservative RSB is 300 $\mu$ m with more aggressive surgeons approaching 250 $\mu$ m. Clinicians should rule out mechanical eye-rubbing and measure corneal biometry to better understand when surgery might leave a thinner RSB.

Other pre-op parameters include corneal curvature, corneal sensitivity and, to some degree, pupil size.

For refractive stability, clinicians should wait to perform LASIK until age 18 at the earliest. LASIK has no upper age limit, and many patients who undergo refractive cataract surgery benefit from a postoperative LASIK enhancement.

LASIK contraindications include central corneal scars, corneal ectasia, ocular surface/corneal infection, recalcitrant dry eye disease (DED), pregnancy and ocular diseases that might limit best-corrected visual acuity.

As technology improves, so does LASIK. A first major improvement was moving from blade flaps (microkeratome) to laser flaps (femtosecond laser). Laser flaps increase the precision of the flap depth and thickness, leading to improved patient safety. The second big improvement was the development of wavefront-guided and wavefront-optimized treatments and, most recently,



**The SMILE procedure creates (top left), dissects (top right) and removes a lenticule (bottom left and right) to correct myopia and myopic astigmatism.**

topography-guided platforms. These are surgeon-specific technologies, so clinicians should become familiar with the options available at their local surgery centers.

Whether a patient elects to have conventional, wavefront-guided, wavefront-optimized or topography-guided, they can expect great UCVA. Studies comparing LASIK platforms generally show UCVA of 20/20 or better in more than 90% of patients, and the focus shifts instead to low-contrast acuity, measurable higher-order aberrations (HOAs) and other finite differences.<sup>5,6</sup>

With a well-established track record for safety and visual outcomes, it's no surprise that many patients present to a new refractive evaluation with a pre-determined mindset that they want LASIK.

## Time to SMILE

Despite the slow start for SMILE here in the United States, the newly approved expanded treatment parameters have many thinking now is the time to consider SMILE. The laser creates a lenticule that is extracted through a small opening, effectively flattening the central cornea, similar to an excimer laser ablation in LASIK or photorefractive keratectomy (PRK).

High-energy SMILE (HE-SMILE) was approved in 2016 to treat spherical myopia. This was a great step forward in expanding refractive surgery options, but the energy limitations impacted early visual recovery. Overall, visual recovery was faster than PRK, but slower than LASIK.<sup>7</sup> In addition, the initial approval excluded patients with astigmatism.

# Refractive Surgery

In March 2018, low-energy SMILE (LE-SMILE), which leads to a LASIK-like quick visual recovery, was approved to treat not only myopia but also myopic astigmatism. The expanded indication includes -1.00D to -10.00D of myopia, up to 3.00D of cylinder and a manifest refraction spherical equivalent up to 11.00D.

One study recently compared both SMILE procedures with LASIK and found that HE-SMILE provided 37% of patients 20/20 vision or better at one day post-op compared with LE-SMILE and LASIK, both of which gave more than 90% of patients 20/20 vision or better in the same timeframe.<sup>7</sup> The inclusion of astigmatism treatment and quick visual recovery has led to a rapid increase in SMILE procedures.

Recent peer-reviewed data shows that most LASIK patients experience transient postoperative dryness. The PROWL studies showed LASIK patients were three-times more likely to experience improved, rather than worsening, dryness symptoms.<sup>3</sup> Another study also found significantly more LASIK patients had less dryness postoperatively compared with those wearing contact lenses.<sup>8</sup>

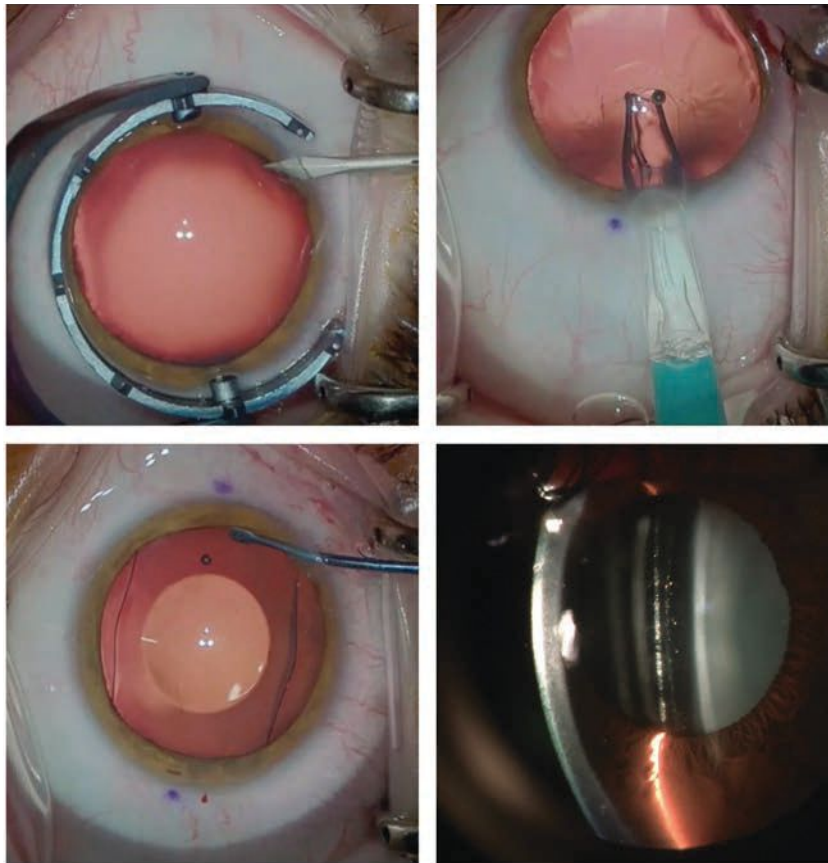
Studies show patients may experience fewer dry eye symptoms with SMILE compared with LASIK because SMILE uses a small opening, not a flap.<sup>9-11</sup> Patients may also experience faster recovery of corneal sensation after SMILE compared with LASIK.<sup>9-12</sup>

Because the procedure preserves more of the anterior stroma, it may also leave the cornea stronger com-

pared with LASIK.<sup>11,12</sup> Researchers who looked at the combined effect of corneal hysteresis and corneal resistance factor found SMILE preserved the corneal biomechanical strength better than LASIK.<sup>12,13</sup>

Interestingly, SMILE allows patients the ability to retreat with LASIK after the initial procedure. For example, a patient can have their small corneal opening turned into a LASIK-like flap.<sup>14-16</sup> The other possible option for an enhancement would be PRK.

Currently, more than three million SMILE procedures have been done worldwide.<sup>17</sup> Quicker healing times, the micro-invasive corneal opening, greater biomechanical stability and reduced postoperative dryness are why many patients are considering SMILE.<sup>3,7-13</sup>



**A small opening (top left) is created, and the ICL is inserted into the sulcus (top right) and centered (bottom left). ICL vault over the crystalline lens is evaluated (bottom right).**

## A Permanent Contact Lens

The Visian ICL (Staar Surgical) is an additive technology that corrects myopia and myopic astigmatism. It has been available for more than 15 years in the United States, and more than one million patients have opted for this implant. Still, adoption of this technology has been slow.

An ICL can correct myopia between -3.00D and -16.00D and is approved for myopic reduction between -16.00D and -20.00D.<sup>18</sup> It can also correct up to 4.00D of cylinder. The procedure is performed by creating a small opening in the cornea, similar to cataract surgery, where the surgeon inserts the soft, folded ICL. The footplates are tucked behind the iris, and the viscoelastic is removed as the ICL sits in the sulcus.

Most eye doctors think of an ICL as an option for patients who don't qualify for LASIK, such as those with high myopia, thin corneas and irregular topography. ICL surgery is also typically the procedure of choice

for patients with DED because of the small opening required.

But the procedure is an important option, even for LASIK candidates. One study comparing wavefront-optimized LASIK with ICLs found that both offered better nighttime contrast sensitivity compared with glasses, but an ICL provided the best nighttime contrast sensitivity.<sup>19</sup>

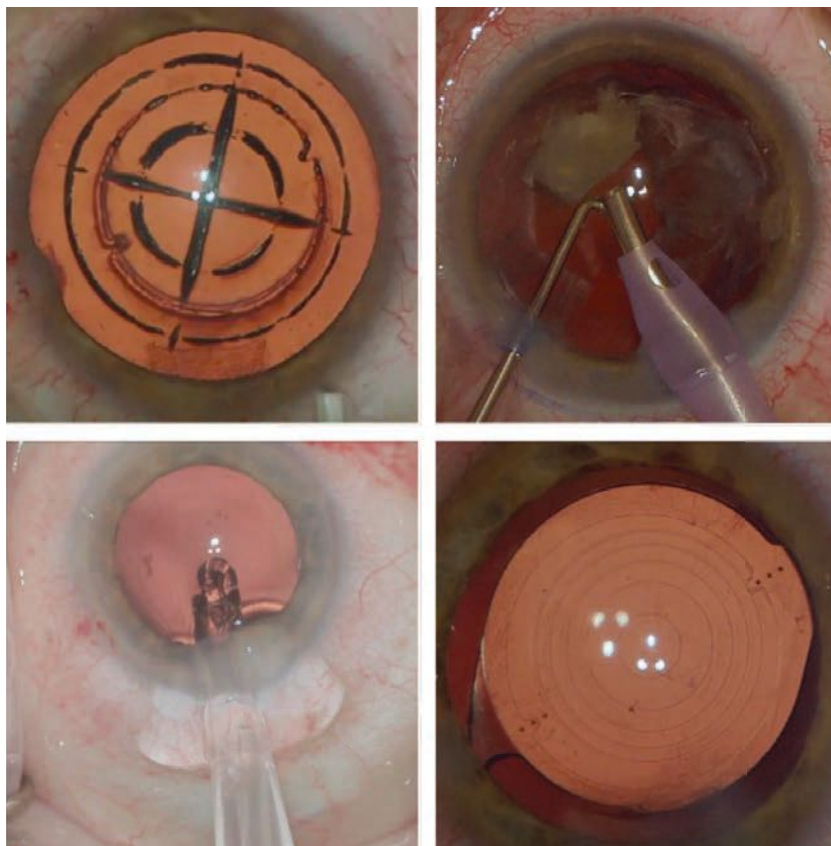
These implantable lenses are unique in that they are removable, opening the door for future surgical options as the patient ages. For example, if a -10.00D myope has LASIK, they may not be a candidate for the PanOptix (Alcon) trifocal lens when they need cataract surgery.

Laser refractive surgery for high myopia induces more spherical aberrations and may limit a patient's candidacy for multifocal intraocular lenses (IOLs). Thus, an ICL is a good option for patients with high myopia because the implant doesn't change their spherical aberrations or impinge on their candidacy for trifocals later in life.

A patient interested in an ICL must have myopia or myopic astigmatism and an anterior chamber depth above 2.9mm. Preoperatively, these patients require a wet refraction and an orbital ultrasound. When refracting patients with high myopia, use a contact lens for your over-refraction to minimize the impact of vertex factor. Although some doctors size the ICL based on white-to-white measurements, we believe ultrasound allows for more appropriate ICL sizing.

Postoperatively, doctors should carefully check the vault of the ICL (similar to evaluating the vault of a scleral lens with anterior segment optical coherence tomography or a slit lamp) and the patient's intraocular pressure and ensure the peripheral iridotomies are patent.

New ICL technology remains



**RLE uses a femtosecond laser to soften the lens, create the anterior capsulotomy and create astigmatic keratotomies to correct astigmatism (top left). The cataract or lens is removed by phacoemulsification (top right), and a new lens is inserted (bottom left). Toric IOL placement is evaluated post-op (bottom right).**

under investigation in the United States, and the Evo ICL (Staar Surgical) just completed enrollment for its Phase III clinical trial.<sup>20</sup> This lens is designed with a central hole to allow aqueous to pass through, eliminating the need for preoperative iridotomies. Outside the United States, the Evo Viva (Staar Surgical), a presbyopic ICL, was just approved as an ICL option for presbyopic myopic patients.<sup>21</sup>

### Out With the Old

Corneal-based refractive surgery may be an easy decision for many patients, but this isn't the case for everyone. Often, patients presenting for a refractive surgery evaluation are between the ages of 45 and 55,

are at least in the early stages of presbyopia and desire less dependence on glasses at both distance and near. These patients have often wanted refractive surgery for a long time and now have the disposable income to invest. They struggle with bifocal acceptance or have lost more reading glasses than they can count—not an easy clinical picture.

Reshaping the corneal curvature with a laser can change the distance or near power of each eye, but not both. Monovision may be a viable option for these patients, but for candidates who desire excellent depth perception, want to maintain bilateral distance vision or don't easily accept monovision, their refractive surgery options are limited.



Dysfunctional lens syndrome (DLS)—a newer term that incorporates presbyopia but also focuses on lens HOAs, early light scatter and decreased contrast secondary to lens aging—is a blind spot for laser refractive surgery.<sup>22</sup>

Staging DLS can be an effective way to stratify patients for laser-based refractive surgery vs. RLE. This option follows the same process and steps as cataract surgery but happens in the absence of visually significant opacification. RLE offers patients with DLS a refractive surgery option to improve distance and near vision while maintaining virgin corneal status. The procedure is also quite safe, with a 6% incidence of adverse events, only 0.9% of which are serious.<sup>23</sup>

Key candidacy considerations for RLE include patient age, which encompasses the accommodative status of the lens, and preoperative refraction. For myopic patients in general, blended vision or monovision is preferred until a patient reaches their early 50s. In hyperopes, where loss of accommodation is coupled with refractive error, RLE is a viable option for those who are younger than 50.

Although both laser vision correction and RLE can be successful, laser vision correction to steepen a hyperopic eye with early presbyopia tends to offer poorer visual quality and less near range compared with monovision in patients who were previously myopic.

In our practice, we avoid RLE in young myopic patients with a liquified vitreous and in those with a high axial length due to the risk of retinal tears or detachments and peripheral retinal pathology. Conversely, highly hyperopic patients (+4.00D to +6.00D) can do well with RLE, as conventional laser vision correction becomes less predictable.

RLE has three key advantages:

**Life-span.** Because the cornea is stable in early adulthood, removing the crystalline lens and implanting a fixed-power IOL provides years—if not a lifetime—of refractive stability.

**Presbyopic correction.** For patients with presbyopia, using a presbyopia-correcting IOL can provide great distance and near vision.

**Enhancements.** Patients with residual refractive error after a lensectomy and the insertion of a premium IOL can have a cornea-based laser adjustment, when needed, to maximize UCVA.

In our clinic, we have noticed that more patients have chosen RLE this year, perhaps due to the fact that the United States finally has an approved trifocal lens option. The PanOptix now allows properly selected patients to see at distance, intermediate and near without spectacle correction.<sup>24</sup> These patients typically have better than 20/25 vision at all distances and, with the same lens in both eyes, they have excellent depth perception.

## Embrace the Opportunities

The mask mandate due to the COVID-19 pandemic is driving more patients to seek refractive surgery to escape the problem of spectacle fogging. We should embrace this. Last year, only 20% of all LASIK patients were comanaged by optometrists—that's approximately \$565 million lost in comanagement opportunities with LASIK alone.

In our clinic, we often hear patients say that having refractive surgery was one of the best choices they've ever made, right up there with getting married, having kids and buying a house. By keeping up with the latest options and proactively discussing refractive surgery with patients, we can improve their lives and grow our practices. ■

*Dr. Saenz is the clinic and residency director at Parkhurst NuVision in San Antonio, TX, and an adjunct assistant clinical professor at the University of the Incarnate Word's Rosenberg School of Optometry.*

*Dr. Ibach is a residency-trained optometrist at Vance Thompson Vision in Sioux Falls, SD. He specializes in anterior segment surgical care, including cataract, corneal disease, glaucoma and refractive surgery.*

1. Sandoval HP, Donnenfeld ED, Kohnen T, et al. Modern laser in situ keratomileusis outcomes. *J Cataract Refract Surg*. 2016;42(8):1224-34.
2. Donnenfeld ED. The best for LASIK. Presented at AAO Subspecialty Day, November 10-11, 2017; New Orleans.
3. Eydelman M, Himantel G, Tarver ME, et al. Symptoms and satisfaction of patients in the Patient-Reported Outcomes With Laser In Situ Keratomileusis (PROWL) Studies. *JAMA Ophthalmol*. 2017;135(1):13-22.
4. Stonecipher K, Parrish J, Stonecipher M. Comparing wavefront-optimized, wavefront-guided and topography-guided laser vision correction. *Curr Opin Ophthalmol*. 2018;29(4):277-85.
5. Charters L. Wavefront-guided LASIK: bigger increases in corrected/uncorrected VA. *Ophthalmology Times*. [www.ophtalmologytimes.com/view/wavefront-guided-lasik-bigger-increases-corrected-uncorrected-va](http://www.ophtalmologytimes.com/view/wavefront-guided-lasik-bigger-increases-corrected-uncorrected-va), November 13, 2018. Accessed November 3, 2020.
6. Jain A, Malhotra C, Pasari A, et al. Outcomes of topography-guided versus wavefront-optimized laser in situ keratomileusis for myopia in virgin eyes. *J Cataract Refract Surg*. 2016;42:1302-11.
7. Nejad MN, Chen AC, Khorrami R, et al. Comparison of early visual outcomes following low-energy SMILE, high-energy SMILE, and LASIK for myopia and myopic astigmatism in the United States. *J Cataract Refract Surg*. August 25, 2020. [Epub ahead of print].
8. Price MO, Price DA, Bucci FA Jr., et al. Three-year longitudinal survey comparing visual satisfaction with LASIK and contact lenses. *Ophthalmology*. 2016;123(8):1659-66.
9. Shen Z, Zhu Y, Song X, et al. Dry eye after small incision lenticule extraction (SMILE) versus femtosecond laser-assisted in situ keratomileusis (FS-LASIK) for myopia: a meta-analysis. *PLoS One*. 2016;11(12):e0168081.
10. Li M, Zhou Z, Shen Y, et al. Comparison of corneal sensation between small incision lenticule extraction (SMILE) and femtosecond laser-assisted LASIK for myopia. *J Refract Surg*. 2014;30(2):94-100.
11. Reinstein DZ, Archer TJ, Randleman JB. Mathematical model to compare the relative tensile strength of the cornea after PRK, LASIK, and small incision lenticule extraction. *J Refract Surg*. 2013;29(7):454-60.
12. Guo H, Hosseini-Moghaddam SM, Hodge W. Corneal biomechanical properties after SMILE versus FLEX, LASIK, LASEK, or PRK: a systematic review and meta-analysis. *BMC Ophthalmol*. 2019;19(1):167.
13. Zhang Y, Shen Q, Jia Y, et al. Clinical outcomes of SMILE and FS-LASIK used to treat myopia: a meta-analysis. *J Refract Surg*. 2016;32(4):256-65.
14. Donate D, Théron R. Preliminary evidence of successful enhancement after a primary SMILE procedure with the sub-cap-lenticule-extraction technique. *J Refract Surg*. 2015;31(10):708-10.
15. Liu YC, Rosman M, Mehta JS. Enhancement after small-incision lenticule extraction: incidence, risk factors, and outcomes. *Ophthalmology*. 2017;124(6):813-21.
16. Chansue E, Tanheksakdi M, Swasdiutra S, et al. Safety and efficacy of VisuMax circle patterns for flap creation and enhancement following small incision lenticule extraction. *Eye Vis*. 2015;2:21.
17. Zeiss. Zeiss announces 3 million eyes treated with SMILE. [www.eyewire.com/news/articles/zeiss-announces-3-million-eyes-treated-with-smile](http://www.eyewire.com/news/articles/zeiss-announces-3-million-eyes-treated-with-smile), June 9, 2020. Accessed November 3, 2020.
18. US Food and Drug Association. Visian Toric ICL (Implantable Collamer Lens). [www.fda.gov/medical-devices/recently-approved-devices/visian-toric-icl-implantable-collamer-lens-p030016s001](http://www.fda.gov/medical-devices/recently-approved-devices/visian-toric-icl-implantable-collamer-lens-p030016s001), October 4, 2018. Accessed November 3, 2020.
19. Parkhurst GD. A prospective comparison of phakic collamer lenses and wavefront-optimized laser-assisted in situ keratomileusis for correction of myopia. *Clin Ophthalmol*. 2016;10:1209-15.
20. ClinicalTrials.gov. Multicenter clinical trial of a phakic implantable collamer lens (ICL). [clinicaltrials.gov/ct2/show/NCT04283149](http://clinicaltrials.gov/ct2/show/NCT04283149), Accessed November 3, 2020.
21. STAAR Surgical introduces EVO Viva presbyopia correcting lens—see young again! *Business Wire*. [www.businesswire.com/news/home/20200707005258/en/STAAR-Surgical-Introduces-EVO-Viva%E2%84%A2-Presbyopia-Correcting-Lens-%E2%80%93-See-Young-Again](http://www.businesswire.com/news/home/20200707005258/en/STAAR-Surgical-Introduces-EVO-Viva%E2%84%A2-Presbyopia-Correcting-Lens-%E2%80%93-See-Young-Again), July 7, 2020. Accessed November 3, 2020.
22. Durrie D. Dysfunctional lens syndrome, a new way to educate patients. Presented at ASCRS Refract Surg Subspecialty Day, October 14, 2016.
23. Schallhorn JM, Schallhorn SC, Teenan D, et al. Incidence of intraoperative and early postoperative adverse events in a large cohort of consecutive refractive lens exchange procedures. *Am J Ophthalmol*. 2019;208:406-14.
24. US Food and Drug Administration. AcrySof IQ PanOptix trifocal intraocular lens and AcrySof IQ PanOptix toric trifocal intraocular lens. [www.fda.gov/medical-devices/recently-approved-devices/alcon-laboratories-inc-acrysof-iq-panoptix-trifocal-intraocular-lens-model-tfnt00-and-acrysof-iq](http://www.fda.gov/medical-devices/recently-approved-devices/alcon-laboratories-inc-acrysof-iq-panoptix-trifocal-intraocular-lens-model-tfnt00-and-acrysof-iq), Accessed November 3, 2020.



## Optometry CE Study Center



The CE You  
Need in 2020

As low as  
**\$17.50**  
per Credit Hour

Buy just one 2-hour course for \$35 or buy as many as you need

Choose from over 50 individual CE courses

Includes the hard to find topics that fulfill your state requirements

All available in a convenient online format

Visit [www.ReviewEdu.com](http://www.ReviewEdu.com) for additional information and purchasing options.

The CE Study Center courses have been developed in conjunction with expert faculty from leading schools of optometry and are oriented toward clinical practice issues that are designed to assist eye care professionals in serving their patient's healthcare needs. CE Courses also appear in print monthly in *Review of Optometry*.

1-800-825-4696 • [INFO@REVIEWSCE.COM](mailto:INFO@REVIEWSCE.COM)

These COPE-Accredited CE courses are administered in partnership with an accredited school of optometry.



“ I didn't realize  
**STARS**  
were little dots that twinkled ”

—Misty L, *RPE65* gene therapy recipient

**WE'RE SEEING  
AMAZING RESULTS.  
AND SO ARE THEY.**

At the Foundation Fighting Blindness our mission is everybody's vision. Our work shines a light on the darkness of inherited retinal diseases (IRDs).

We're the world's leading organization searching for treatments and cures. We need your help to fuel the discovery of innovations that will illuminate the future for so many. We have robust disease information, a national network of local chapters and support groups, local educational events, and our My Retina Tracker® Registry to help keep your patients connected with clinical and research advancements.

Help accelerate our mission  
by donating at [ECPs4Cures.org](https://ECPs4Cures.org).

**FOUNDATION  
FIGHTING  
BLINDNESS**

[FightingBlindness.org](https://FightingBlindness.org)

26th Annual Surgery Report

# MIGS: Indications and Complications

Optometrists can be the gatekeepers of this procedure. Here’s what you need to know to refer properly and care for the post-op patient.

By Shradha Sanghvi Parikh, OD, and Elizabeth Warren Cody, OD

As a bridge between topical or laser treatment and incisional glaucoma surgery, minimally invasive glaucoma surgery (MIGS)—of which there are many—is growing in popularity. These procedures aim to provide a safer and less invasive means of reducing intraocular pressure (IOP) than traditional incisional surgery, while also decreasing dependency on topical hypotensive medications. The magnitude of IOP lowering depends largely on the respective mechanism of action of MIGS.

Here, we discuss various MIGS approaches, broken down by anatomical area, and the pertinent patient selection criteria. The clinical information will help clinicians competently incorporate MIGS into their surgical referral repertoire and



**iStent inject insertion directly following cataract surgery.**

Photo: Rachel Caywood, OD

## Trabecular Meshwork Bypass

The *iStent (Glaukos)* is used in combination with cataract surgery for patients with mild to moderate glaucoma. *Ab interno* placement of the L-shaped device improves the aqueous outflow by creating a channel through the trabecular meshwork (TM).

After two years, research shows no statistically significant difference in IOP between the iStent with phacoemulsification group (8.4mm Hg lower than base-

line) and the cataract surgery alone group (7.5mm Hg lower).<sup>1</sup> At the 24-month follow-up, 61% of the combination group maintained an IOP ≤21mm Hg without medication compared with only 50% of the control group.<sup>1</sup>

Although efficacy was modest, the iStent achieved a significant

select the best MIGS according to individual patient needs.

*Note: This article does not include a discussion of surgical modalities that aim to reduce aqueous humor production by cyclodestruction of the ciliary body, such as endocyclophotocoagulation and transscleral cyclophotocoagulation.*

line) and the cataract surgery alone group (7.5mm Hg lower).<sup>1</sup> At the 24-month follow-up, 61% of the combination group maintained an IOP ≤21mm Hg without medication compared with only 50% of the control group.<sup>1</sup>

Although efficacy was modest, the iStent achieved a significant



prolonged reduction in IOP as well as a reduction in topical medication burden. The safety profile is favorable and comparable with cataract surgery alone, the most common complications being transient IOP elevation and transient hyphema (commonly self-limiting).

Adverse events of stent obstruction, blockage or malposition, although they often only require monitoring, can be addressed with laser or surgical intervention.

The *iStent Inject (Glaukos)*, a second-generation model approved in 2018, is also used in combination with cataract surgery for patients with mild to moderate glaucoma. It was developed with the premise that multiple iStents may be more effective than a single iStent. The implant is smaller in size and contains four inlets vs. one, allowing a multidirectional outflow of aqueous.<sup>2</sup>

A multicenter clinical trial comparing cataract surgery and iStent Inject with cataract surgery alone found that 75.8% of patients in the treatment group achieved a  $\geq 20\%$  reduction in medication-free IOP

from baseline at 24 months compared with 61.9% in the control group. The mean reduction in medication-free IOP from baseline to 24 months was modestly improved with the combination group:  $7.0 \pm 4.0$  mm Hg vs.  $5.4 \pm 3.7$  mm Hg.<sup>3</sup>

The *Hydrus Microstent (Ivantis)* was FDA-approved in 2018 for use in combination with cataract surgery for mild to moderate glaucoma. The microstent is threaded into Schlemm's canal using an *ab interno* approach. After the implantation, the Hydrus dilates and expands the diameter of three clock hours of Schlemm's canal. This allows for enhanced aqueous outflow by providing TM bypass and direct access to multiple collector channels.

The Hydrus II study found 80% of patients treated with Hydrus and phacoemulsification achieved a 20% reduction from baseline IOP at 24 months compared with 46% of patients in the phacoemulsification

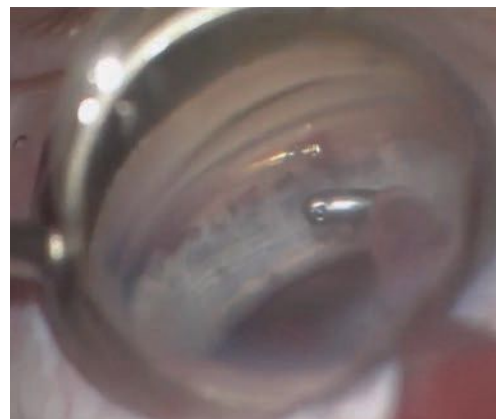


Photo: Brooke Mathie, OD

**Once the Hydrus device is in place, the surgeon confirms good stent placement before completing the procedure.**

alone group. In addition, 72.9% in the combination cohort remained free of topical medications vs. 37.8% in the control arm.<sup>4</sup> A larger randomized trial, the HORIZON study, found similar results.<sup>5</sup>

The Hydrus implant also has a favorable safety profile. Complications, while infrequent, were most notably transient hyphema and early IOP spike from baseline in less than 10% of patients thought to be attributed to retained viscoelastic material. Also, the Hydrus II study found few subjects developed focal peripheral anterior synechiae, which did not require any further intervention.<sup>4</sup>

The COMARE study is the first to directly assess the efficacy of two different MIGS devices as stand-alone treatments.<sup>6</sup> The study randomized both phakic and pseudophakic patients to receive either the Hydrus Microstent or two iStent trabecular bypass devices. Results demonstrated an improved success rate of the Hydrus over the two iStents in eliminating the need for medication use, 46.6% vs. 24%.<sup>6</sup> Among eyes without medication, the Hydrus achieved an IOP  $\leq 18$  mm Hg in 30.1% vs. 9.3% in the iStent group.<sup>6</sup> While both MIGS devices

## Patient Selection Pearls

MIGS procedures are changing the treatment strategies for patients with glaucoma, and optometrists must be prepared to make MIGS recommendations based on ocular findings and patient factors. The goal is to individualize the treatment approach by matching the surgical benefits with the disease stage. These three clinical pearls are paramount when educating patients on their options:

**Lens status.** Most MIGS are employed at the time of cataract surgery in patients with coexisting glaucoma. If cataract surgery is not indicated, a goniotomy or trabeculotomy procedure, cyclophotocoagulation or Xen gel stent are treatment choices.

**Disease type.** In conjunction with cataract surgery, most trabecular bypass MIGS have demonstrated good surgical benefits for mild to moderate open-angle glaucoma. Secondary glaucomas, such as pigmentary or pseudoexfoliation, may respond well to trabecular bypass procedures and goniotomy or trabeculotomy procedures. For angle-closure glaucoma, goniosynechiolysis and goniotomy can be very effective.

**Surgeon selection.** Glaucoma surgeons' proficiency and access to MIGS vary greatly. Comanagement requires communication with the surgeon regarding their surgical procedural preference and the availability of certain MIGS devices.<sup>1</sup>

1. Seibold L, Young CC. Which MIGS procedure is right for my patient? A guide for ophthalmology residents. Covalent Careers. [covalentcareers.com/resources/which-migs-procedure-ophthalmology-residents-guide](https://covalentcareers.com/resources/which-migs-procedure-ophthalmology-residents-guide). July 2, 2020. Accessed November 2, 2020.



had similar safety profiles, the Hydrus resulted in a higher surgical success rate and efficacy compared with the two iStents.

**Ab-interno trabeculectomy (Trabectome, Microsurgical Technology)** is a surgical technique that facilitates aqueous outflow by thermal ablation and removal of 30° to 180° of the TM and the inner wall of Schlemm's canal, thereby exposing collecting channels.<sup>7</sup>

Whether performed in a stand-alone manner or in combination with cataract surgery, research shows a significant and consistent decrease in IOP from baseline.<sup>8</sup> The success rate was nearly 85% at five years and 56% at 7.5 years (using the common definition of success of final IOP  $\leq$ 21mm Hg with a 20% decrease from baseline).<sup>8</sup>

In addition, the Global Trabectome Outcomes study showed that, at 90 months, the average IOP demonstrated a 29% reduction from a baseline of 23.0mm Hg to 16.5mm Hg, and the average number of glaucoma medications decreased by 38% from 2.6 to 1.6.<sup>9</sup>

*Ab interno* trabeculectomy has a lower success rate compared with incisional trabeculectomy; however,

the safety profile suggests it is a reasonable option for patients with early to moderate stage disease. Adverse events, mostly mild to moderate, include transient intraoperative or early postoperative reflux bleeding from the collector channels. The researchers noted a transient early postoperative IOP elevation, but no severe adverse events.<sup>8</sup>

The **Kabook Dual Blade (KDB, New World Medical)** is a surgical tool designed to remove a strip of TM tissue and the inner wall of Schlemm's canal up to 180°.

Clinical studies demonstrate success as both a stand-alone and combined procedure with phacoemulsification. Both approaches can provide a significant and sustained reduction in IOP and medication burden. The six-month outcome of success, defined as IOP reduction of more than 20% from baseline and medical regimen reduced by more than one medication, was 69.8% and 67.9%, respectively.<sup>10</sup> For the combined procedure, 12-month data indicated a 57.7% success rate for pressure reduction and 63.5% for treatment reduction.<sup>11,12</sup>

The efficacy is similar across disease severity, making this an effective and safe alternative to filtering surgery for patients with severe and refractory glaucoma.<sup>13</sup> Goniotomy performed with KDB has an excellent safety profile, consistent with other *ab-interno* procedures, with rare complications of postoperative IOP spike and hyphema.

The **Trab360 (Sight Sciences)**, released in 2015, provides an *ab interno* approach for access to 360° of Schlemm's canal. The cannula tip of the device

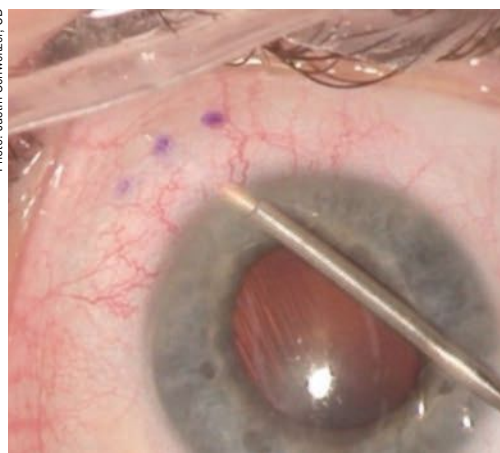


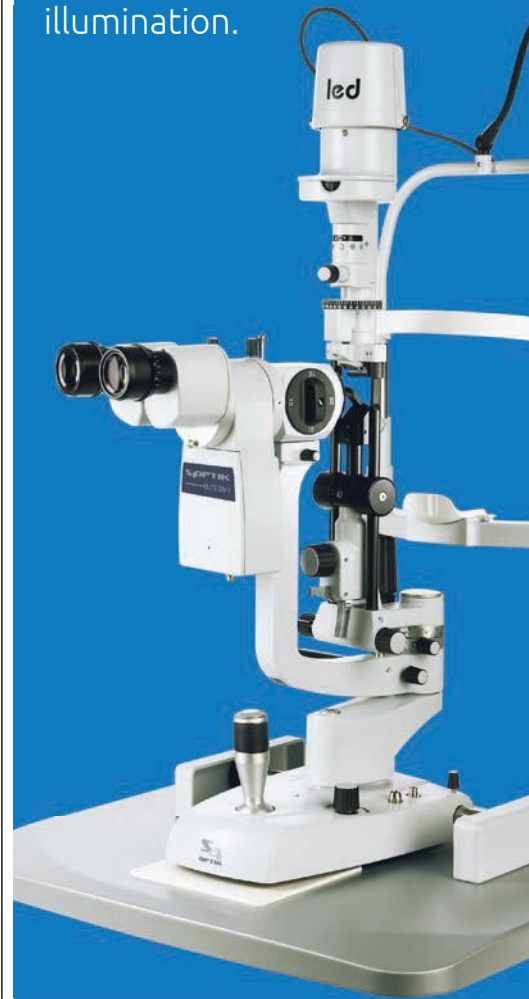Photo: Justin Schweitzer, OD

**The Xen gel stent creates a drainage pathway from the anterior chamber to the subconjunctival space to lower IOP.**

# S4OPTIK SLIT LAMPS

## NEW LED Illumination

More than 50,000  
hours of clear, cool  
illumination.



**Easier** observation of  
minute details.

**Color temperature**  
maintained through the full  
range of illumination  
adjustment.

# S4OPTIK

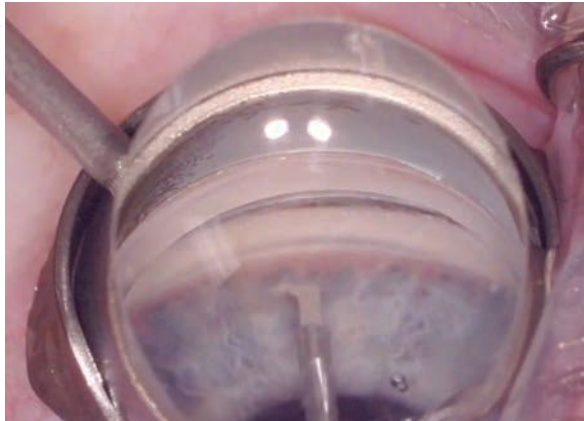
250 Cooper Ave., Suite 100 Tonawanda NY 14150

[www.s4optik.com](http://www.s4optik.com) | 888-224-6012

Sensible equipment. Well made, well priced.

For today's modern office.

Photo: Justin Schweitzer, OD



**The Kahook Dual Blade is designed to allow the surgeon to lift and excise the TM completely.**

pierces the TM to gain access into Schlemm's canal. A microcatheter is threaded through Schlemm's canal, and the TM is inwardly opened by pulling on the ends of the catheter, either in one direction for 180° or in both directions for a total 360° trabeculotomy. It can be either stand-alone or in combination with cataract surgery.<sup>14</sup>

One study of refractory glaucoma patients who had stand-alone 360° trabeculotomy with Trab360 found 59% of eyes achieved  $\geq 20\%$  reduction in IOP and IOP  $< 18\text{mm Hg}$  with the same or fewer medications at 12 months compared with baseline.<sup>15</sup> Another study indicated success of Trab360 for treating primary congenital glaucoma.<sup>16</sup> The Trab360 device demonstrates a favorable safety profile with mild transient hyphema as the most common adverse event noted.

**Gonioscopy assisted transluminal trabeculotomy**, an *ab-interno* circumferential trabeculotomy using a suture or microcatheter, is designed to decrease the proximal resistance of conventional outflow similarly to Trab360. One study showed patients with primary open-angle glaucoma demonstrated an IOP reduction of 7.7mm Hg at six months with an average of 0.9 fewer

medications.<sup>17</sup> Those with secondary glaucoma demonstrated an IOP reduction of 17.2mm Hg with an average of 2.2 fewer medications. These benefits were sustained in the 12-month study. Like other MIGS, the procedure has a favorable safety profile, with

transient hyphema being the most common adverse event.

## Schlemm's Canal

**Ab interno canaloplasty (ABiC, Ellex)** is designed to catheterize and viscodilate Schlemm's canal using the iTrack surgical system. The ABiC may be combined with cataract surgery or performed as a stand-alone procedure. The microcatheter is threaded into Schlemm's canal for 360°. Upon withdrawal of the microcatheter, a viscoelastic solution is injected to enlarge the canal and create a circumferential flow.<sup>18</sup> This results in reduction of outflow resistance through the TM, Schlemm's canal and the distal outflow system, beginning with the collector channels.

Results of a retrospective case review of patients who had ABiC with or without cataract surgery showed that IOP fell from  $20.4 \pm 4.7\text{mm Hg}$  pre-op to  $13.3 \pm 1.9\text{mm Hg}$  12 months post-op, and the medication burden decreased from  $2.8 \pm 0.9$  to  $1.1 \pm 1.1$ .<sup>19</sup> Furthermore, 40% of eyes post-procedure were medication-free.<sup>19</sup>

## Subconjunctival Space

The **Xen gel (Allergan) implant**, FDA-approved in 2016, targets

subconjunctival outflow with an *ab interno* approach. Made of biocompatible collagen-derived gelatin, the 6mm long tube with a lumen size of  $45\mu\text{m}$  creates a drainage pathway between the anterior chamber and the subconjunctival space.

The Xen gel implantation may be performed as a stand-alone procedure or in combination with cataract surgery for patients with mild to moderate glaucoma. Several studies indicate a high success rate

## Suprachoroidal Space

The **CyPass Micro-Stent (Alcon)** was the first FDA-approved MIGS to target the suprachoroidal space, and early evidence showed significant IOP and medication reduction when combined with cataract extraction. However, the CyPass device underwent an FDA recall in August 2018 following a five-year data review from the COMPASS-XT study suggesting a clinically significant increase in corneal endothelial cell loss (3% risk of loss per year compared with 1% per year in controls).<sup>1</sup>

The American Society of Cataract and Refractive Surgery task force recommends clinicians monitor these patients with specular microscopy for the development of visually significant complications from endothelial cell loss. Implantation depth and retention rings visible with gonioscopy have an apparent correlation with the rate of endothelial cell loss; however, repositioning or removing the device is discouraged.

A surgeon may attempt to clip the retention rings on the proximal end of the device, if necessary, to reduce protrusion into the anterior chamber.<sup>2</sup>

1. Reiss G, Clifford B, Vold S, et al. Safety and effectiveness of CyPass supraciliary micro-stent in primary open-angle glaucoma: 5-year results from the COMPASS XT study. *Am J Ophthalmol.* 2019;208:219-25.

2. US Food and Drug Administration. Update: Potential eye damage from Alcon CyPass micro-stent used to treat open-angle glaucoma: FDA Safety Communication. [www.fda.gov/medical-devices/safety-communications/update-potential-eye-damage-alcon-cypass-micro-stent-used-treat-open-angle-glaucoma-fda-safety](http://www.fda.gov/medical-devices/safety-communications/update-potential-eye-damage-alcon-cypass-micro-stent-used-treat-open-angle-glaucoma-fda-safety). October 24, 2018. Accessed November 2, 2020.

## SLIT LAMPS

EXCEPTIONAL OPTICS

of lowering IOP to  $\leq 18$ mm Hg, and high complete success, defined as pressure reduction  $\leq 18$ mm Hg without any topical medication, all at one year post-op.<sup>20-22</sup> The Xen gel implant can be efficacious in refractory glaucoma as well.<sup>23</sup>

Adverse events include transient anterior chamber bleed, transient hypotony, transient choroidal detachment and, more commonly, the need for additional needling. There is potentially a greater degree of postoperative management with Xen gel.

Currently, it is unclear if the efficacy, simplicity and safety profile of Xen gel outweigh the established efficacy of traditional filtering surgeries. The higher cost of Xen gel compared with standard filtering surgery is also a limiting factor.<sup>24</sup>

### Final Thoughts

Each MIGS procedure offers its own benefits and limitations. These devices are relatively new, and the long-term safety, efficacy and reproducibility of the outcomes are still under investigation.

While topical medications have an overall favorable safety profile and moderate success in lowering IOP, the efficacy depends heavily on patient adherence. Non-compliance rates in glaucoma can vary from 24% to as high as 59%.<sup>25</sup>

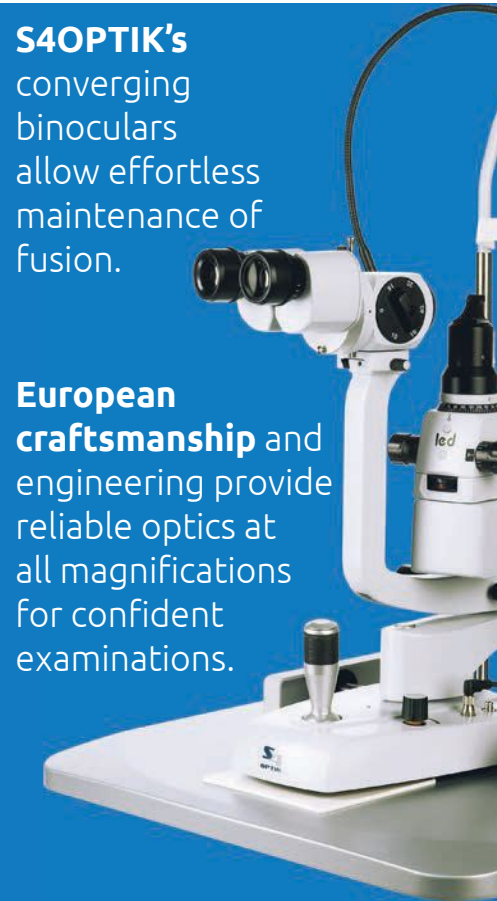MIGS procedures have the potential to adequately reduce IOP, decrease dependence on topical medications, provide an alternative to more invasive glaucoma surgeries and exhibit a favorable safety profile. These procedures are still trying to find their niche within glaucoma care, and ongoing research will help to improve clinicians' understanding of the optimal selection. ■

*Drs. Parikh and Cody work at the W.G. Hefner VA Medical Center in Salisbury, NC.*

1. Craven ER, Katz LJ, Wells JM, et al. Cataract surgery with trabecular micro-bypass stent implantation in patients with mild-to-moderate open-angle glaucoma and cataract: two-year follow-up. *J Cataract Refract Surg.* 2012;38(8):1339-45.
2. Pillunat LE, Erb C, Jünemann AGM, Kimmich F. Micro-invasive glaucoma surgery (MIGS): a review of surgical procedures using stents. *Clin Ophthalmol.* 2017;11:1583-600.
3. Samuelson W, Sarkisian SR, Lubeck DM, et al. Prospective, randomized, controlled pivotal trial of an ab interno implanted trabecular micro-bypass in primary open-angle glaucoma and cataract: two-year results. *Ophthalmology.* 2019;126(6):811-21.
4. Pfeiffer N, Garcia-Feljo J, Martínez-de-la-Casa JM, et al. A randomized trial of a Schlemm's canal microstent with phaco-emulsification for reducing intraocular pressure in open-angle glaucoma. *Ophthalmology.* 2015;122(7):1283-93.
5. Samuelson TW, Chang DF, Marquis R, et al. A Schlemm canal microstent for intraocular pressure reduction in primary open-angle glaucoma and cataract: The HORIZON study. *Ophthalmology.* 2019;126(1):29-37.
6. Ahmed IK, Fea A, Au L, et al. A prospective randomized trial comparing Hydrus and iStent microinvasive glaucoma surgery implants for standalone treatment of open-angle glaucoma: The COMPARE study. *Ophthalmology.* 2020;127(1):52-61.
7. Francis BA, Minckler D, Dustin L, et al. Combined cataract extraction and trabeculectomy by the internal approach for coexisting cataract and open-angle glaucoma: initial results. *J Cataract Refract Surg.* 2008;34(7):1096-103.
8. Kaplowitz K, Bussell I, Honkanen R, et al. Review and meta-analysis of ab-interno trabeculectomy outcomes. *Br J Ophthalmol.* 2016;100(5):594-600.
9. Okeke CO, Miller-Elis E, Rojas M, Trabectome Study Group. Trabectome success factors. *Medicine.* 2017;96(24):e7061.
10. Berdahl JP, Gallardo MJ, ElMallah MK, et al. Six-month outcomes of goniotomy performed with the Kahook Dual Blade as a stand-alone glaucoma procedure. *Adv Ther.* 2018;35(11):2093-102.
11. Dorairaj SK, Seibold LK, Radcliffe NM, et al. 12-month outcomes of goniotomy performed using the Kahook Dual Blade combined with cataract surgery in eyes with medically treated glaucoma. *Adv Ther.* 2018;35(9):1460-69.
12. Greenwood MD, Seibold LK, Radcliffe NM, et al. Goniotomy with a single-use dual blade: short-term results. *J Cataract Refract Surg.* 2017;43(9):1197-1201.
13. Salinas L, Chaudhary A, Berdahl JP, et al. Goniotomy using the Kahook Dual Blade in severe and refractory glaucoma: 6-month outcomes. *J Glaucoma.* 2018;27(10):849-55.
14. Bettin P, Khaw PT, eds. *Glaucoma Surgery.* 2nd ed. Basel, Switzerland: Karger; 2017:127-46.
15. Sarkisian SR, Mathews B, Ding K, et al. 360° ab-interno trabeculectomy in refractory primary open-angle glaucoma. *Clin Ophthalmol.* 2019;13:161-68.
16. Areaux RG Jr, Grajewski AL, Balasubramaniam S, et al. Trabeculectomy ab interno with the Trab360 device for childhood glaucomas. *Am J Ophthalmol.* 2020;209:178-86.
17. Grover DS, Godfrey DG, Smith O, et al. Gonioscopy-assisted transluminal trabeculectomy, ab interno trabeculectomy: technique report and preliminary results. *Ophthalmology.* 2014;121(4):855-61.
18. Bettin P, Khaw PT, eds. *Glaucoma Surgery.* 2nd ed. Basel, Switzerland: Karger; 2017:130-46.
19. Gallardo M, Supnet R, Ahmed II. Viscodilation of Schlemm's canal for the reduction of IOP via an ab-interno approach. *Clin Ophthalmol.* 2018;12:2149-55.
20. Galal A, Bilgic A, Eltanamly R, et al. XEN glaucoma implant with mitomycin C 1-year follow-up: result and complications. *J Ophthalmol.* 2017;2017:5457246.
21. Pérez-Torregrosa VT, Olate-Pérez Á, Cerdá-Ibáñez M, et al. [Combined phacoemulsification and XEN45 surgery from a temporal approach and 2 incisions]. *Arch Soc Esp Ophthalmol.* 2016;91(9):415-21.
22. De Gregorio A, Pedrotti E, Russo L, Morselli S. Minimally invasive combined glaucoma and cataract surgery: clinical results of the smallest ab interno gel stent. *Internat Ophthalmol.* 2018;38(3):1129-34.
23. Grover DS, Flynn WJ, Bashford KP, et al. Performance and safety of a new ab interno gelatin stent in refractory glaucoma at 12 months. *Am J Ophthalmol.* 2017;183:25-36.
24. Chaudhary A, Salinas L, Guidotti J, et al. XEN Gel Implant: a new surgical approach in glaucoma. *Exp Rev Med Dev.* 2018;15(1):47-59.
25. Tsai JC. Medication adherence in glaucoma: approaches for optimizing patient compliance. *Curr Opin Ophthalmol.* 2006;17(2):190-5.

S4OPTIK's converging binoculars allow effortless maintenance of fusion.

European craftsmanship and engineering provide reliable optics at all magnifications for confident examinations.



H-Series



Z-Series



Vertical and compact configurations available.





# It's in the Way That You Use It

Often, hypoxic corneal edema requires a change in scleral lens parameters, rather than a new modality. **Edited by Joseph P. Shovlin, OD**

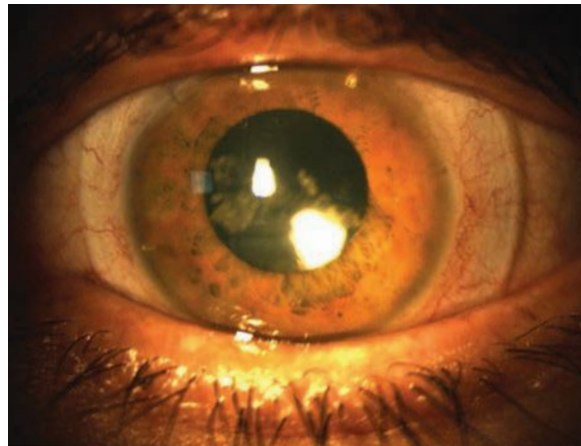
**Q** What are your options when a scleral contact lens patient complains of hazy, cloudy vision due to hypoxic corneal edema a few hours after lens application?

**A** Scleral lenses reduce the amount of oxygen that gets through to the cornea due to factors such as lens thickness and material, tear reservoir depth and the semi-sealed fit, according to Chelsea Bradley, OD, a clinical instructor at the Illinois College of Optometry. “When corneal edema occurs as a result of hypoxia, do everything you can to increase oxygen flux to the cornea,” she recommends.

## Optimize the Fit

In a perfect world, Dr. Bradley says, the patient would switch to a lens modality with a higher rate of tear exchange and greater oxygen transmission, such as a corneal gas permeable, hybrid or soft lens. However, she notes that many scleral lens wearers have an advanced form of disease that takes other lens modalities out of the running, so changing the parameters of the scleral lens is generally the only option.

Dr. Bradley suggests taking these steps: (1) Fit the scleral to have as little central clearance as possible while still maintaining a healthy fit (typically about 100µm after settling), (2) order the lens with



**A scleral lens with too much tear exchange can cause debris to collect in the bowl (seen centrally) and reduce the patient's visual acuity.**

the highest Dk material possible (most labs have a hyper-Dk material option available for scleral lenses) and (3) decrease the center thickness of the lens as much as possible to increase the Dk/t value. She recommends implementing these changes to any lens causing hypoxic edema, as they often resolve the issue.

If the edema persists, Dr. Bradley says to consider flattening the haptics of the lens to achieve a looser fit and promote greater tear exchange. However, she adds that this could introduce more debris into the bowl of the lens and cause patient discomfort, lens fogging or both. She offers another option: performing fenestrations or channels on the lens to promote additional tear exchange. While this used to be the most common solution to scleral lens-induced hypoxic

corneal edema, she notes that it fell to the sidelines with the invention of hyper-Dk materials, which typically allow enough oxygen to permeate.

In addition to making physical changes to the lens fit, Dr. Bradley says the patient can take breaks from scleral lens wear throughout the day when they have lower visual demands.

## Graft Considerations

For patients who have corneal grafts, Dr. Bradley notes that the same rules apply for minimizing edema. However, in these patients, she cautions that hypoxia is not the only contributing factor; endothelial cell count is also important.


These patients should have an endothelial cell count of at least 800 cells/mm<sup>2</sup> to lessen the risk of developing edema with scleral lens wear, according to Dr. Bradley. At an endothelial density lower than this, Dr. Bradley warns that many patients will develop corneal edema throughout the day, even if all the lens parameters are adjusted for maximum oxygen permeability.

## Final Thoughts

“Hypoxic corneal edema from scleral lenses is almost always treatable by making one or several of these changes,” Dr. Bradley concludes. ■



FOUNDATION FIGHTING  
BLINDNESS *presents*



**HOPE** *from*  
**HOME**

A UNITED NIGHT  
TO SAVE SIGHT

**Sunday, February 28, 2021**

**7 pm ET | 6 pm CT | 5 pm MT | 4 pm PT**

*Celebrating Rare Disease Day*



Join the Foundation Fighting Blindness in kicking off our 50th anniversary year with a virtual gala hosted by Saturday Night Live alum Kevin Nealon!

Experience incredible entertainment and interactive rooms while supporting the mission of the Foundation Fighting Blindness – *all from the comfort of your own home.*

**[give.FightingBlindness.org/HopeFromHome](https://give.FightingBlindness.org/HopeFromHome)**

**For more information, please contact  
866-732-7330 or [events@FightingBlindness.org](mailto:events@FightingBlindness.org).**

*Thank you to our National Partner:  
Genentech, A Member of the Roche Group*

**FOUNDATION FIGHTING  
BLINDNESS**  
*Together, we're winning.*



## Play it Safe

It often takes time, and repeat testing, to determine the appropriate course of action for a glaucoma patient who is new to your practice. **By James L. Fanelli, OD**

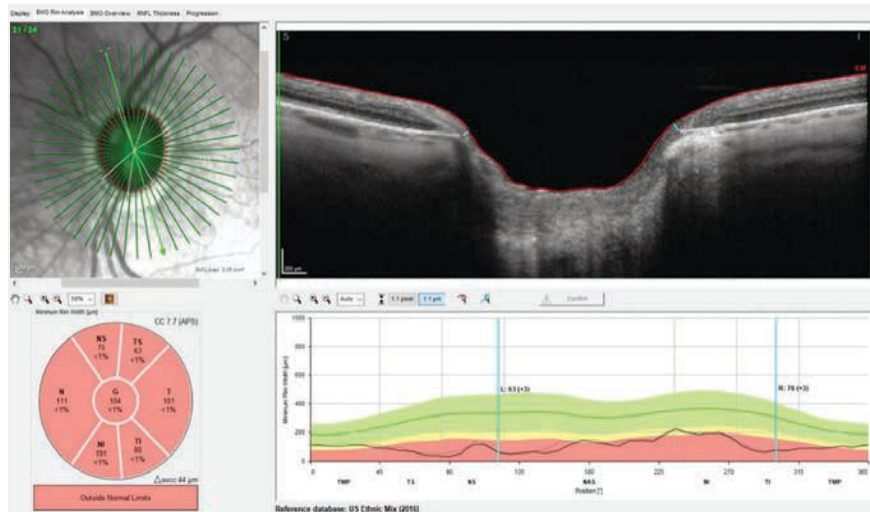
In August 2019, a 72-year-old Caucasian male presented as a new patient for continuation of care. Given that my practice is located in an area with a large influx of retirees, it's fairly common to pick up existing glaucoma patients. This particular patient had been diagnosed with glaucoma in both eyes in 1995. He was initially medicated with a series of drops that ultimately did not effectively reduce his intraocular pressure (IOP). He ended up having surgery in both eyes for his glaucoma.

The patient also had bilateral cataract surgery in 2003 and a retinal detachment repair in the left eye in 2005. From what I could determine, he had not taken topical or oral medications for his glaucoma since the cataract surgery, except for a short dose in the left eye following the retinal detachment repair. He reported that he performs daily ocular massages OU, as directed by his previous provider.

### Diagnostics

The patient's best-corrected visual acuities (BCVAs) were 20/40-OD and 20/150 OS. His pupils were round and reactive to light, and there was no frank pupillary defect noted in either eye.

Slit lamp examination of the anterior segments was remarkable for bilateral dermatochalasis. The



**Note the exceedingly thin neuroretinal rim, especially in the temporal portion of the optic nerve, consistent with advanced damage OS.**

patient's anterior segment evaluation further demonstrated bilateral trabeculectomies and surgical peripheral iridotomies.

The blebs were well-formed and not aberrant in any visible way. The corneas were clear, as were the anterior chambers. The angles were open, as the patient was pseudophakic. His intraocular lenses were well-centered OU.

The patient's applanation tensions were 20mm Hg OD and 21mm Hg OS at 10:15am. His pachymetry readings were 552 $\mu$ m OD and 497 $\mu$ m OS.

Through dilated pupils, the patient's cup-to-disc ratios were 0.65x0.75 OD and 0.85x0.90 OS. The neuroretinal rims were thinned, especially in the left eye, and consistent with advanced

glaucomatous optic neuropathy OS. They were well-perfused and not pale, and both discs were on the larger size.

The patient's macular evaluation was characterized by retinal pigmented epithelium disruption OS>OD and fine drusen OU. There was no evidence of angiogenic age-related macular degeneration in either eye. He had an epiretinal membrane in the left eye.

The patient's vascular evaluation was essentially normal despite mild age-related arteriolar sclerosis OU. His peripheral retinal evaluation OD was normal; the left was characterized by an encircling scleral buckle. There were no new holes, tears or traction noted in either eye.

## Discussion

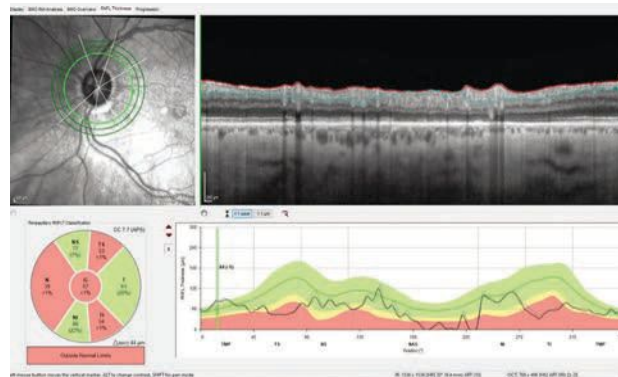
The more advanced the glaucoma, the quicker it can progress. These patients need to be watched more closely, and therapy changes should be expected. Initial visits with a new patient without records make it impossible to determine disease stability. The only indication I had about this patient's stability at his first visit was that his previous provider was comfortable enough to see him on a six-month basis.

I was eventually able to obtain a copy of the patient's previous records, which contained optical coherence tomography (OCT) printouts. The previous provider's OCT device was different than mine, but the images demonstrated similar disease states compared with my findings. While I was not able to compare data points across both devices

to the precision I would have liked, I was able to fill in an important piece of the glaucoma puzzle: this patient has had advanced disease OS for quite some time.

Given that I was not certain of his stability, I saw the patient back in two months, at which point his IOPs were 15mm Hg OD and 14mm Hg OS.

During the next few visits, no disc hemorrhages were noted. The blebs remained patent and well-formed. The OCTs remained stable, as did the visual fields. The patient's IOPs averaged in the mid-teens, OD and OS.



**The 3.50mm diameter RNFL scan demonstrates classic superotemporal and inferotemporal RNFL thinning in the left eye. Note the lack of change from baseline (gray).**

were the same as his initial visit.

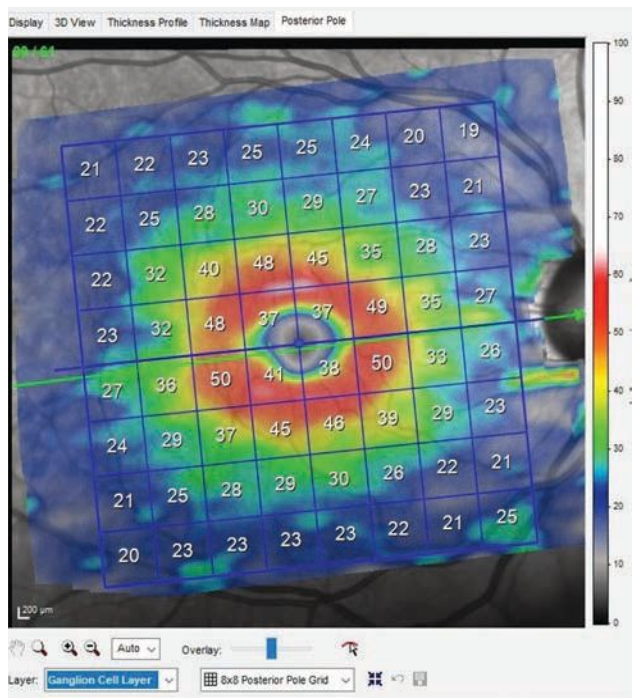
The patient's visual fields and OCTs were stable over the first year that I saw him, but his IOPs were the wild card. This is not surprising, as his method of IOP control included bilateral trabeculectomies and digital massages. Digital massaging is somewhat of a double-edged sword; with a well-formed bleb, it lowers IOP, but there are significant differences from patient to patient as to how long the IOP remains depressed. Also, during digital massage, IOP is artificially elevated for short periods of time, so too much pressure can be detrimental.

Structurally and functionally, the patient showed no indication of progression, so we decided on follow-ups every six months.

However, in July 2020, the patient's IOPs were 26mm Hg OD and 13mm Hg OS.

At his next visit in September 2020, the patient's IOPs again fell into his historical range. OCT demonstrated no significant change in the neuroretinal rim, peripapillary retinal nerve fiber layer (RNFL) or macular scans. His BCVAs

Advanced disease progresses much faster than mild disease, which has a built-in safety net with adequate remaining neuroretinal rim tissue. In both cases, though, the patient needs to be watched closely for structural or functional change. The specifics of visit timing, different testing and IOP-lowering often take time to flesh out, especially with patients who are new to your practice. ■



**OCT of the right eye shows a relatively normal macular ganglion cell layer. Ganglion cell layer thickness averages 40µm to 45µm in the macular region, with the thickest region adjacent to the foveal avascular zone.**



# Mellow Yellow

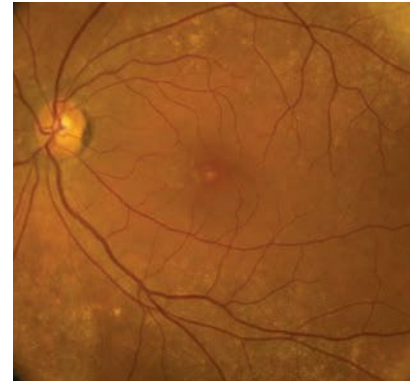
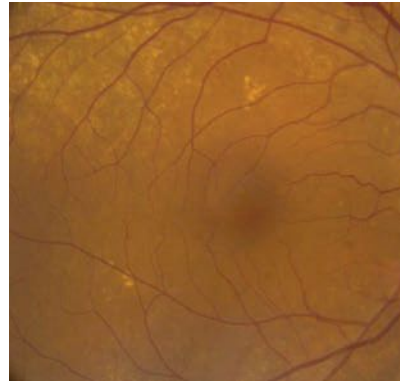
What could these macular findings signal in our patient?

By Mark Dunbar, OD

A 63-year-old Hispanic female presented with a two-day history of blurred vision in her left eye. She reported that, while working on an Excel spreadsheet, parts of the line of text were missing. She said her right eye was “perfect,” but, when she covered it, she could immediately see her central vision was blurred. Her last eye exam was three to four years ago. She wore a hyperopic correction with a progressive lens. Medical history was significant for hypertension and osteoporosis. She is currently on hydrochlorothiazide and losartan.

On examination, entering distance acuities measured 20/20 OD and 20/40 OS. Her extraocular motility testing was normal. Confrontation visual fields were full-to-careful finger counting OU. The pupils were equally round and strongly reactive; there was no afferent pupillary defect. Amsler grid testing in the right eye was normal. The left eye showed central metamorphopsia. The anterior segment examination was remarkable for trace nuclear sclerosis OU.

On dilated fundus exam of the right eye, there were peripheral drusen along the arcades. The macula appeared normal. We noted similar peripheral drusen in the left eye. In the macula, there was a deep yellow-white lesion (*Figure 1*). There did not appear to be any subretinal fluid. OCT and fluorescein angiography (FA) were performed and are available for review (*Figures 2 and 3*).



**Fig. 1.** This is a fundus photograph of the right and left eyes of our patient. Note the macular appearance of the left eye.

## Take the Retina Quiz

- How would you describe the OCT appearance?
  - Hyperreflective lesion, likely CNV
  - Focal disruption of the outer retina
  - Outer retinal placoid lesion
  - Focal pigment epithelial detachment
- What is the most likely diagnosis?
  - Solar maculopathy
  - Wet age-related macular degeneration (AMD)
  - Multiple evanescent white dot syndrome (MEWDS)
  - Unilateral acute idiopathic maculopathy (UAIM)
- How should this patient be managed?
  - Observation
  - Anti-VEGF injection
  - Prednisone PO
  - Acyclovir PO
- What would you expect her clinical prognosis to be?
  - Reasonably good central vision with treatment
  - Slow steady improvement of her vision over time
  - Rapid decline in her central vision without treatment
  - Impossible to know

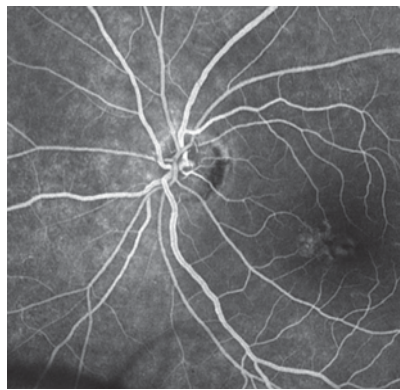
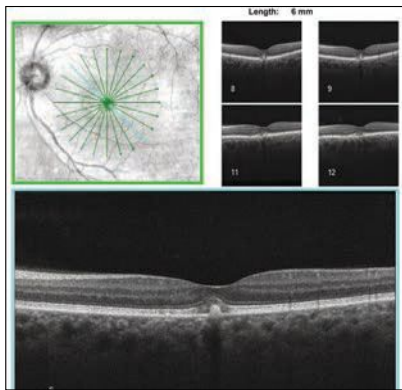
*For answers, see page 74.*

## Discussion

Based on the patient's history of sudden blurred vision in the left eye and the presence of drusen along the arcades, our initial thought was that she had macular degeneration and had likely developed a choroidal neovascularization in her left eye. The problem is that she didn't have any drusen in the macula of her right eye, which you would expect to see if she had AMD, as the dry form is usually a bilateral symmetric disease.

There was a deep yellow-appearing lesion in the macula that could





**Figs. 2 and 3. How do you interpret this SD-OCT of the left eye (left)? What do the macular changes represent in this late-phase FA of the left eye (right)?**

possibly be a drusen, but the other clinical findings in the left eye don't fit with CNV. The macula appeared flat, and there was no subretinal fluid or hemorrhage present. Instead, we saw some retinal pigment epithelium (RPE) disruption and this peculiar yellow lesion.

The OCT showed a focal hyper-reflective lesion in the outer retina corresponding to the yellow lesion with central IS/OS junction disruption. There was no subretinal or intraretinal fluid, which was consistent with our clinical exam. The FA showed a central area of hypofluorescence with surrounding hyperfluorescent staining but no leakage of the fluorescein dye, which is not consistent with CNV. Interestingly, there was a larger irregular area nasal to the fovea where there was also staining. So, what's going on with our patient?

This appeared to be an acute, unilateral process affecting the outer retina. Based on the clinical appearance and OCT findings, this is likely a post-viral process, such as UAIM.

### Atypical Findings

UAIM was originally described as sudden vision loss following a flu-like illness.<sup>1</sup> All the participants with UAIM in one study had an exudative macular detachment,

spontaneous resolution of the macular changes and near-complete recovery of their vision.

The researchers felt the clinical course and macular appearance were suggestive of an inflammatory disease of the RPE.<sup>1</sup> They were not able to determine a causative etiology, but some case reports suggest possible infection from coxsackievirus.<sup>2</sup>

Our patient did not report having a preceding viral-like infection nor did she have an exudated macular detachment. However, since the initial description, other case reports of UAIM show that not all patients present with neurosensory retinal detachment. In one published series, neurosensory detachment was seen within 48 hours of the onset of symptoms and improved over the first week.<sup>3</sup>

Despite not having an exudative retinal detachment, other notable characteristics included the circumscribed central granular yellow lesion as well as OCT findings that described a focal defect involving the outer retina and ellipsoid layer.

Interestingly, patients with UAIM also have a thickened choroid. We did not do enhanced depth imaging on our patient, so we don't know if she had a thickened choroid. The FA findings are also consistent with

what has been described. FA shows early central hypofluorescence and parafoveal patchy hyperfluorescence without leakage, which was exactly the same case with our patient.

The relationship between UAIM and coxsackievirus is interesting, but the virus has not been clearly established to be a causative agent in all cases. Coxsackievirus is a viral infection that may cause hand, foot and mouth disease, orchitis and epididymitis. It is usually seen in children, but adults can also get it. There is such a close relationship between UAIM and coxsackievirus that some authors wonder if UAIM should be renamed "coxsackievirus maculopathy."<sup>2</sup> Our patient did not have a preceding viral-like illness, so it's unlikely she had coxsackievirus.

Another atypical feature of our patient was her age. Most reports of UAIM describe patients as young adults, no older than mid- to late-30s.<sup>4</sup> However, a more recent case report described a 59-year-old patient who developed UAIM 30 days after developing yellow fever, which was much closer to our patient who was 63.<sup>5</sup>

We elected to observe our patient without treatment. She returned for follow-up two weeks later. Her vision had improved to 20/30, and she had less metamorphopsia. She did not return for follow-up after that. ■

1. Yannuzzi LA, Jampol LM, Rabb MF, et al. Unilateral acute idiopathic maculopathy. *Arch Ophthalmol.* 1991;109(10):1411-6.
2. Beck AP, Jampol LM, Glaser DA, Pollack JS. Is coxsackievirus the cause of unilateral acute idiopathic maculopathy? *Arch Ophthalmol.* 2004;122(1):121-3.
3. Nicolo M, Rosa R, Musetti D, et al. Early swept-source optical coherence tomography angiography findings in unilateral acute idiopathic maculopathy. *Ophthalmic Surg Lasers Imaging Retina.* 2016;47(2):180-2.
4. Freund KB, Yannuzzi LA, Barile GR, et al. The expanding clinical spectrum of unilateral acute idiopathic maculopathy. *Arch Ophthalmol.* 1996;114(5):555-9.
5. Dompieri RC, Manzano RPA, Frazão MAM, et al. Unilateral acute idiopathic maculopathy secondary to yellow fever disease: a case report. *Am J Ophthalmol Case Rep.* 2019;15:100464.



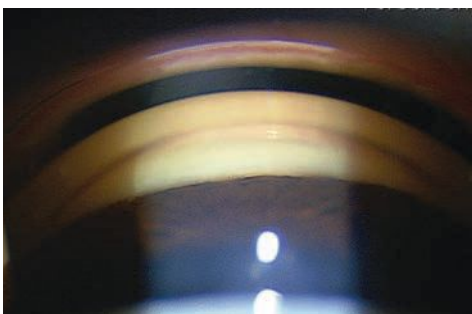
# Reconsidering LPI

It remains the go-to treatment for chronic angle-closure glaucoma, but are others worth looking into? **By Joseph W. Sowka, OD**

**A** 78-year-old Caucasian female came in for a routine comprehensive eye examination. She was only correctable to 20/100 OD and 20/60 OS. The main culprit, as had been noted the year prior, was cataracts. She was scheduled for cataract surgery last year but had cancelled since she felt that she didn't need it. Indeed, she still felt fine and had no problems with her vision despite the reduced acuity. Her refraction was essentially unchanged and didn't improve her acuity.

Notably, she was a moderate hyperope in the +2.75D range in each eye with mild astigmatism. Her intraocular pressures (IOP) were 17mm Hg OD and 18mm Hg OS, similar to last year's findings. It was apparent that she had a very shallow anterior chamber with narrow angles. A glaucoma surgeon strongly recommended prophylactic laser peripheral iridotomy (LPI). Like the cataract surgery, she cancelled that procedure as well.

Assessing and managing patients with chronic angle closure and those at risk of angle closure is challenging. Prophylactic LPI aims to prevent progression to acute or chronic angle closure. But it has always been difficult to identify those patients who would most benefit from the procedure, with most clinicians following their own personal experiences in recommending and performing LPI.



**This semi-narrow angle patient is a candidate for LPI.**

## The Angle Closure Spectrum

Historically, the term narrow angle glaucoma has been used to connote eyes either at risk of impending angle closure or those actually experiencing it. Though this term is still used today, it is more appropriate to speak in current terms of angle closure and assign eyes to one of four categories.

The first category is the primary angle closure suspect. Here, the pigmented trabecular meshwork is blocked by the iris for 180°. There is no peripheral anterior synechiae (PAS), the optic disc is normal and IOP is not elevated. These are the "at-risk" patients who are commonly encountered in clinical practice and often additionally have a low-to-moderate degree of hyperopia leading to crowding of the anterior chamber. It is not clear if LPI or observation is better for these patients.

The second category is primary angle closure where the pigmented trabecular meshwork is likewise blocked by the iris for 180°. In

contrast to the suspect, these eyes will have either PAS, elevated IOP or both. But there still is no disc damage or visual field loss. In these eyes, LPI is recommended.

The third category is primary angle-closure glaucoma that has all the features mentioned previously for primary angle closure but, additionally, has progressed to involve glaucomatous neuropathy and often visual field loss as well. In this situation, LPI is also

recommended.

The final category is the well-known primary angle-closure attack, with near complete apposition of the iris to the pigmented trabecular meshwork. Its classic signs and symptoms include redness, vision loss, nausea, emesis, halos, corneal edema, elevated IOP, inflammation, and a mid-dilated fixed pupil.

## PCACG Management

Primary chronic angle-closure glaucoma (PCACG) is the predominate form of the ocular disease and is more commonly encountered than acute attack. Anatomical features act in concert to cause shallowing of the anterior chamber. As a patient ages, thickening of the crystalline lens leads to a relative pupil block that exacerbates and partially contributes to the condition.

Since the closure is slow, there is an absence of symptoms that would typify an acute angle closure. There is more of a multi-mechanism, with some degree of pupil block as well as an anteriorly located lens and

Photo: Ian McWhirter, OD and Richard Mannan, OD

ciliary body that causes shallowing of the anterior chamber and overall congestion of the angle, leading to creeping synechial closure.<sup>1,2</sup>

PCACG is typically treated with LPI, though primary pupil block is not the major mechanism. While LPI can alter the anatomical status of the angle, a significant number of these patients will manifest residual angle closure after LPI from PAS.<sup>3</sup> Additionally, there will often be elevated IOP despite a laser-induced open anterior chamber angle due to damage to the trabecular meshwork from appositional and synechial closure.<sup>4</sup>

Medical therapy that has been successful in ameliorating the IOP in eyes with PCACG includes beta blockers, miotics, alpha-2 adrenergic agonists and prostaglandins.<sup>5,6</sup> Prostaglandin analogs seem to work especially well in eyes with PCACG that need IOP reduction both before and after LPI.<sup>7</sup> These medications are thought to lower IOP by increasing matrix metalloproteinase activity and subsequently reducing the amount of extracellular matrix material surrounding the ciliary muscle fiber bundles.<sup>8</sup>

## New Players in the Game

Preventing angle closure through LPI is commonly done in patients deemed anatomically at risk. LPI increases angle width in all stages of primary angle closure and has a good safety profile.<sup>9</sup> As mentioned, it is often difficult to determine which patients at risk of angle closure would most benefit from prophylactic LPI to prevent future disease. Recent study results have shed light on this issue.

One study noted that the rate of developing any angle closure endpoint was much lower than expected in primary angle closure suspect eyes at less than 1% per year.<sup>10</sup> Eyes

that underwent LPI did have a 47% reduction in the risk of developing primary angle closure or an acute attack.<sup>10</sup> LPI was safe with no long-term adverse events.<sup>10</sup> However, the study argued that prophylactic LPI is only of modest benefit over time, given the very low progression rate observed.<sup>10</sup>

While LPI is largely safe and easily performed, there may be less of a need for it based on the low incidence of conversion from primary angle closure suspect to pathological angle closure. At the very least, this study indicates that prophylactic LPI is not urgent in patients who are only anatomically at risk.

While LPI and stepped medical therapy (if needed) have been the traditional approach to managing patients with PCACG, results from the Effectiveness in Angle-closure Glaucoma of Lens Extraction (EAGLE) Study suggested an alternate and perhaps better option: phaco. Patients who underwent phacoemulsification lens extraction needed fewer IOP-controlling medications than those undergoing traditional therapy.<sup>11</sup> Only one patient needed trabeculectomy after phacoemulsification, compared with 24 patients in the LPI group.<sup>11</sup> Lens extraction was also seen to be the more cost-effective option.<sup>12</sup>

Researchers have shown that lens removal is a more effective treatment for an acute primary angle-closure attack than LPI. Compared with eyes that underwent LPI, the phacoemulsification eyes experienced fewer IOP elevations, required fewer medications and had deeper angles following lens removal.<sup>13</sup>

Does this compelling new information change our management? Prophylactic LPI provides a significant reduction in risk of future angle closure complications, but

very few patients progressed on to these complications without LPI. Since prophylactic LPI has been done for so long and has relatively few risks, most practitioners will still tend to do the procedure in eyes deemed “at risk” of closure. Removing a cataract in an eye with PCACG is easily justifiable, but removing a clear lens is harder to justify to patients and insurers.

Likely, LPI and medical therapy will remain popular. Removing the lens in acute closure situations may have some significant benefits, but LPI is easier to perform urgently and has a documented history of success.

For the patient presented here, dilation was deferred due to the potential of acute closure. She was educated about the condition and referred again for LPI. ■

1. Wang T, Liu L, Li Z, Zhang S. Studies of mechanism of primary angle-closure glaucoma using ultrasound biomicroscope. *Zhonghua Yan Ke Za Zhi*. 1998;34(5):365-8.

2. Marchini G, Chemello F, Berzaghi D, Zampieri A. New findings in the diagnosis and treatment of primary angle-closure glaucoma. *Prog Brain Res*. 2015;221:191-212.

3. Sihota R, Lakshmaiah NC, Wallia KB, et al. The trabecular meshwork in acute and chronic angle closure glaucoma. *Indian J Ophthalmol*. 2001;49(4):255-9.

4. Su WW, Chen PY, Hsiao CH, Chen HS. Primary phacoemulsification and intraocular lens implantation for acute primary angle-closure. *PLoS One*. 2011;6(5):e20056.

5. Ruangvaravate N, Kitnarong N, Methetrainut A, et al. Efficacy of brimonidine 0.2% as adjunctive therapy to beta-blockers: a comparative study between POAG and CACG in Asian eyes. *J Med Assoc Thai*. 2002;85(8):894-900.

6. Aung T, Wong HT, Yip CC, et al. Comparison of the intraocular pressure-lowering effect of latanoprost and timolol in patients with chronic angle closure glaucoma: a preliminary study. *Ophthalmology*. 2000;107(6):1178-83.

7. Chen MJ, Chen YC, Chou CK, et al. Comparison of the effects of latanoprost and bimatoprost on intraocular pressure in chronic angle-closure glaucoma. *J Ocul Pharmacol Ther*. 2007;23(6):559-66.

8. Lindsey JD, Kashiwagi K, Kashiwagi F, et al. Prostaglandins alter extracellular matrix adjacent to human ciliary muscle cells in vitro. *Invest Ophthalmol Vis Sci*. 1997;38:2214-23.

9. Radhakrishnan S, Chen PP, Junk AK, et al. Laser peripheral iridotomy in primary angle closure: a report by the American Academy of Ophthalmology. *Ophthalmology*. 2018;125(7):1110-20.

10. He M, Jiang Y, Huang S, et al. Laser peripheral iridotomy for the prevention of angle closure: a single-centre, randomised controlled trial. *Lancet*. 2019;393(10181):1609-18.

11. Azuara-Blanco A, Burr JM, Cochran C, et al. Effectiveness of early lens extraction for the treatment of primary angle-closure glaucoma (EAGLE): a randomized controlled trial. *Lancet*. 2016;388(10052):1389-97.

12. Mehdi Javanbakht M, Azuara-Blanco A, Burr JM, et al. Early lens extraction with intraocular lens implantation for the treatment of primary angle closure glaucoma: an economic evaluation based on data from the EAGLE trial. *BMJ Open*. 2017;7(1):e013254.

13. Lam DS, Leung DY, Tham CC, et al. Randomized trial of early phacoemulsification versus peripheral iridotomy to prevent intraocular pressure rise after acute primary angle closure. *Ophthalmology*. 2008;115(7):1134-40.



## Combo Platter

This MIGS method combines a pair of glaucoma procedures to address three points of aqueous resistance. **By Halee Alleman, OD**

Combining two anterior segment glaucoma procedures in one, the Omni Surgical System (Sight Sciences) is a minimally invasive glaucoma surgery (MIGS) with the potential to benefit glaucoma patients of all stages, from early to advanced. FDA-approved in January 2018, Omni lowers intraocular pressure (IOP) and restores the natural outflow of aqueous humor in the eye, in hopes of minimizing the burden of and need for topical medications. This is especially appealing for those who are non-compliant with topical medications or who have ocular surface issues associated with long-term use of IOP-lowering eye drops.

### Another MIGS in the Mix

The Omni uses transluminal viscoelastic delivery and trabeculotomy to address all three points of resistance to aqueous outflow: the trabecular meshwork, Schlemm's canal and the collector channels.

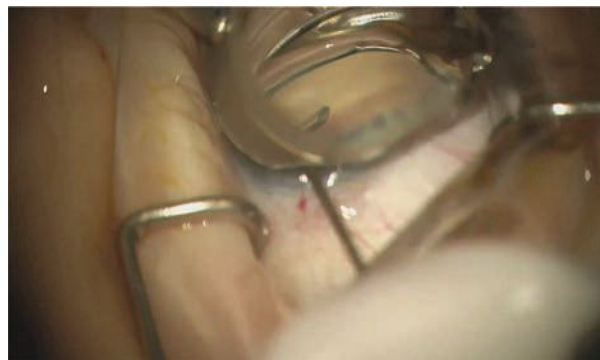First, the device is primed by inserting viscoelastic into the cannula. The cannula is then inserted into the trabecular meshwork and then into Schlemm's canal, where the viscoelastic is released. The viscoelastic travels through Schlemm's canal 180°. The device is then turned in the opposite direction, and the process is repeated for the

remaining 180° of Schlemm's canal. This causes the canal and collector channels to dilate. The catheter is extended into Schlemm's canal again, where it creates a trabeculotomy upon its removal.

The Omni can be performed as a stand-alone procedure or in combination with cataract surgery. One study looked into the effects of combining the two and found that 66% of patients had at least a 20% reduction in IOP and 100% of the patients with an initial IOP of 22mm Hg or greater had an IOP reduction of at least 20%.<sup>1</sup> The researchers concluded that the higher the IOP prior to surgery, the greater the reduction in IOP post-surgery.<sup>1</sup>

In the same study, each of the 13 pseudophakic eyes that received the standalone Omni procedure experienced an IOP reduction of at least 20%.<sup>1</sup> Eighteen months after surgery, those who had the Omni procedure combined with cataract surgery had a mean IOP reduction of 39%, and those who had a standalone Omni procedure had a mean IOP reduction of 40%.<sup>1</sup>

Risks associated with Omni are low but include a spike in IOP, hyphema and fibrin in the anterior chamber, which typically resolves within a week of surgery.



The Omni aims to improve aqueous flow at multiple junctures.

Postoperative medications following Omni are similar to those of standard cataract surgery and include topical antibiotics for a week, topical NSAIDs for a month and tapered topical steroids for a month. In our practice, we typically stop the prostaglandin drop immediately after surgery, but if patients are taking other glaucoma medications, we continue their use to address the occasional steroid response.

MIGS procedures, including the Omni, are changing the way we treat and manage glaucoma patients by providing another effective means of lowering IOP with minimal risks. ■

*Dr. Alleman is an ocular disease and ocular/refractive surgery resident at Virginia Eye Consultants. She graduated from the School of Optometry at the Massachusetts College of Pharmacy and Health Sciences in May 2020.*



For a video of this procedure, visit [www.reviewofoptometry.com](http://www.reviewofoptometry.com) or scan the QR code.

1. Brown R, Dhamdhere K, Tsegaw S, et al. Goniotomy combined with viscodilatation of Schlemm's canal for reducing IOP in open angle glaucoma. ASCRS presentation, May 2019.





I was only seeing light flashes early on, but light

**FLASHES**

when you've not seen anything for  
so many years—it was wonderful

—Keith H, retinal prosthesis recipient

**WE'RE SEEING  
AMAZING RESULTS.  
AND SO ARE THEY.**

At the Foundation Fighting Blindness our mission is everybody's vision. Our work shines a light on the darkness of inherited retinal diseases (IRDs).

We're the world's leading organization searching for treatments and cures. We need your help to fuel the discovery of innovations that will illuminate the future for so many. We have robust disease information, a national network of local chapters and support groups, local educational events, and our My Retina Tracker® Registry to help keep your patients connected with clinical and research advancements.

Help accelerate our mission  
by donating at [ECPs4Cures.org](http://ECPs4Cures.org).

**FOUNDATION  
FIGHTING  
BLINDNESS**

[FightingBlindness.org](http://FightingBlindness.org)

## Diagnostic Equipment

### New Eyecare Telehealth Platform Launches

The pandemic has shown doctors the value of being able to provide care at a distance, and a new product from Topcon aims to help. Called RDx, it's a software platform that works with the company's CV-5000S digital phoropter to allow doctors to perform remote refractions from any location without sacrificing quality of care, says a company press release.



A tech at your office guides the patient through the pre-exam testing and sets up the patient at the phoropter. The RDx system imports pre-test data and then prompts you to begin the refraction. A two-way video feed allows doctor and patient to connect in real-time during the exam, Topcon explains. The company says this process adds workflow efficiencies that can cut exam time almost in half.

The system can allow one doctor to provide care at several locations if suitably equipped, Topcon says, which can benefit multi-office practices and allow provision of care to rural areas without need for lengthy travel by doctors or patients.

Visit [www.topconhealthcare.com/products/rdx](http://www.topconhealthcare.com/products/rdx).

### Time-saving Digital Refraction System

Practices in the market for new vision testing equipment now have another option to consider, a device called Chronos from Topcon that measures objective and subjective refraction as well as keratometry. Combining these functions in a single instrument allows space-saving and encourages delegation of vision testing, according to a company press release.

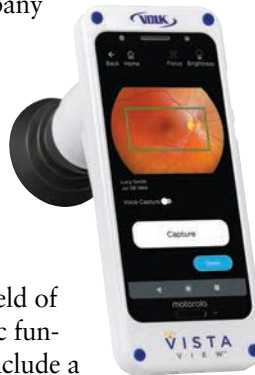

Chronos also includes a feature called SightPilot that Topcon says gives step-by-step instructions to the operator during refraction based on the patient's responses, as a way to speed up vision testing and improve workflow efficiency. Another convenience Topcon points out is the ability to remotely operate Chronos from a tablet or computer, to maintain a safe distance from the patient and also improve the ergonomics of refraction.

Visit [topconhealthcare.com/products/chronos](http://topconhealthcare.com/products/chronos).

### Handheld Retinal Camera For On-the-Go Imaging

If you want to perform high-quality posterior segment imaging at any location and share results immediately, Volk Optical says its new VistaView has you covered. According to a company press release, the mydriatic retinal camera combines high-resolution, double aspheric glass optics with an intuitive digital interface that allows doctors or techs to capture widefield fundus images while managing patient data right on the device.



Volk says the VistaView's 55° field of view is the widest of any mydriatic fundus camera in its class. Features include a voice capture option for hands-free operation; autofocus and manual imaging modes; illumination adjustment for photophobic patients and diverse retina pigments; and the ability to share password-protected reports and DICOM images for billing, consultation or referral.

Pricing is said to be below traditional desktop fundus cameras without compromising on image quality. The portable device "takes fundus photography out of the exam room to waiting rooms, patient rounds, nursing homes and screening events," the press release says.

Visit [www.volk.com/vista](http://www.volk.com/vista).

## Pharmaceuticals

### Steroid Approved for Dry Eye

Clinicians familiar with off-label steroid use to quickly quell dry eye now have an on-label way to do it, as the FDA recently approved a new loteprednol formulation. Marketed as Eysuvis by Kala Pharmaceuticals, the drug is an ophthalmic suspension of loteprednol etabonate, at 0.25% concentration, approved for up to two weeks of therapy. Eysuvis uses mucus-penetrating particles to enhance absorption, according to a Kala press release.

The approval stems from positive outcomes of four clinical trials (three Phase III and one Phase II) that demonstrated improvements in both the signs and symptoms of dry eye disease, the Kala release says. Specifically, conjunctival hyperemia and ocular discomfort severity both showed statistically significant gains from treatment. The company also says that Eysuvis was well-tolerated across the four trials, with adverse events and intraocular pressure increases comparable to that observed with vehicle.

Visit [www.eyisuvis.com](http://www.eyisuvis.com).

# Advertisers **Index**

<b>Allergan, Inc.</b> ..... 76	<b>Keeler Instruments</b> ..... 11
.....(800) 347-4500	.....(800) 523-5620
.....www.refreshbrand.com	.....customerservice@keelerusa.com
	.....www.keelerusa.com
<b>Bausch + Lomb</b> ..... 13 - 14	
.....www.lotemaxsm.com	
<b>Eye Ski Colorado</b> ..... 37	
.....www.tarrtrek.com	
<b>Horizon Pharma USA</b> .....28, 29 & 30	
.....info@kalarx.com	
.....www.tepezzaexperience.com	
<b>Kala Pharmaceuticals</b> ..... 9	
.....(781) 996-5252	
.....info@kalarx.com	
.....www.eyesuvis.com	
<b>Kala Pharmaceuticals</b> ..... 75	
.....(781) 996-5252	
.....info@kalarx.com	
.....www.kalarx.com	
<b>Kala Pharmaceuticals</b> ..... <b>Cover Tip</b>	
.....(781) 996-5252	
.....www.eyesuvis.com	
	<b>MacuLogix</b> ..... 21
	.....(888) 392-6801
	.....www.maculogix.com
	<b>Marco</b> ..... 17
	.....(800) 874-5274
	.....www.marco.com
	<b>Menicon America</b> ..... 7
	.....(800) 636-4266
	.....www.meniconamerica.com
	<b>Novartis Pharmaceuticals</b> ..... 2, 3 & 4
	.....www.novartis.com
	<b>S4OPTIK</b> .....57 & 59
	.....(888) 224-6012
	.....www.s4optik.com
	<b>X-cel Specialty Contacts</b> ..... 19
	.....(800) 241-9312
	.....xcelfinfo@xcelspecialtycontacts.com
	.....www.xcelspecialtycontacts.com

This advertiser index is published as a convenience and not as part of the advertising contract. Every care will be taken to index correctly. No allowance will be made for errors due to spelling, incorrect page number, or failure to insert.

# THE RICK BAY FOUNDATION

## *Support the Education of Future Healthcare & Eyecare Professionals*

Scholarships are awarded to advance the education of students in both **Optometry** and **Ophthalmology**, and are chosen by their school based on qualities that embody Rick's commitment to the profession, including integrity, compassion, partnership and dedication to the greater good.



**Interested in being a partner with us?**

Visit [www.rickbayfoundation.org](http://www.rickbayfoundation.org)

*(Contributions are tax-deductible in accordance with section 170 of the Internal Revenue Code.)*



**THE RICK BAY FOUNDATION**  
*for Excellence in Eyecare Education*

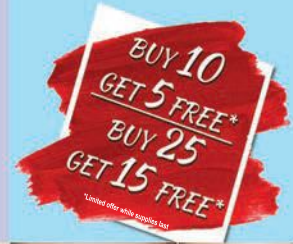(The Rick Bay Foundation for Excellence in Eyecare Education is a nonprofit, tax-exempt organization under section 501(c)(3) of the Internal Revenue Code.)



Contact Lenses

# Impressions

Color Contact Lens



*Unleash your true color!*

Impressions colored contacts blend naturally with your patients eyes to create a beautiful look. Available in nine dazzling opaque colors of which Brown, Grey, Green, Hazel, Honey, Pure Hazel and True Sapphire are available in RX PL to -8.00. Impressions are fun, hip, fashionable and very competitively priced to help your bottom line. POP materials, posters, and trial kits are available upon request.

Available Exclusively at

**NATIONAL LENS**  
1-866-923-5600  
www.national-lens.com

CALL US FOR ALL MAJOR BRANDS OF CONTACTS

Continuing Education

JOIN US at *FinalEyes* CE

**FEBRUARY  
6-7 2021**

**FEB 6: LIVESTREAM ONLY**  
**FEB 7: UNF ADAM W. HERBERT UNIVERSITY CENTER**  
12000 Alumni Drive, Jacksonville, Florida 32224  
Livestream Also Available

To Register, Visit [FinalEyesCE.com/Registration](http://FinalEyesCE.com/Registration)

**10** COPE APPROVED CE HOURS

**Agenda for 2021:** • 5 Triage Decisions to Save a Life and Oops Now What: Say This, Not That in Neuro-Op  
• Ptosis and Pseudoptosis: Evaluation and Treatment Options Friday at 4:00 PM: • Interesting and Challenging Cases  
• Florida Jurisprudence • Medical Errors

A Continuing Education Event Hosted By



Do you have Products and Services for sale?

**CLASSIFIED ADVERTISING WORKS**

- JOB OPENINGS
- CME PROGRAMS
- PRODUCTS
- AND MORE...

Contact us today for classified advertising:  
Toll free: **888-498-1460**  
E-mail: [sales@kerhgroup.com](mailto:sales@kerhgroup.com)





**Practice For Sale**



Practice Sales • Appraisals • Consulting  
[www.PracticeConsultants.com](http://www.PracticeConsultants.com)

**PRACTICES FOR SALE  
 NATIONWIDE**

Visit us on the Web or call us to learn more about our company and the practices we have available.  
[info@PracticeConsultants.com](mailto:info@PracticeConsultants.com)  
**925-820-6758**

[www.PracticeConsultants.com](http://www.PracticeConsultants.com)

**Central Illinois Optometry  
 Practice for Sale**

**30 year practice, gross over  
 \$1,200,000 per year**

135 miles from Chicago, IL,  
 90 miles from Indianapolis, IN

Full service lab, same day  
 service, 2 exam rooms

**Call or text 217-497-2018**

**Career Opportunities**

**Staff Optometrist Wanted**

Bard Optical is a family owned full-service retail optometric practice with 22 offices (and growing) throughout Central Illinois. Bard Optical prides itself on having a progressive optometric staff whose foundation is based on one-on-one patient service. We are currently accepting CV/resumes for Optometrists to join our medical model optometric practice that includes extended testing. The practice includes but is not limited to general optometry, contact lenses and geriatric care. Salaried, full-time positions are available with excellent base compensation and incentive programs and benefits. Some part-time opportunities may also be available.

Current positions are available in  
 Bloomington/Normal, Decatur/Forsyth,  
 Peoria, Sterling and Canton as we continue  
 to grow with new and established offices.

Please email your information to  
[mhall@bardoptical.com](mailto:mhall@bardoptical.com) or call  
 Mick at 309-693-9540 ext 225.  
 Mailing address if more convenient is:

**Bard Optical**  
 Attn: Mick Hall, Vice President  
 8309 N Knoxville Avenue  
 Peoria, IL 61615

Bard Optical is a proud  
 Associate Member of the  
 Illinois Optometric Association.



[www.bardoptical.com](http://www.bardoptical.com)

**Do you have Products  
 and Services for sale?**

**CONTACT US TODAY  
 FOR CLASSIFIED ADVERTISING**  
 Toll free: 888-498-1460  
 E-mail: [sales@kerhgroup.com](mailto:sales@kerhgroup.com)

**Equipment & Supplies**

**WHY PAY RETAIL?**



**Electric power lift table and adjusts  
 from 25" to 50" Tabletop is 20" X 52"  
 Tabletop will accommodate three  
 instruments. Push button switch  
 control. NEW IN BOX. Wholesale  
 Price \$1,195.00 Call 800-522-2275**

**Do you have Products  
 and Services for sale?**

Contact us today for  
 classified advertising.  
 Toll free: 888-498-1460  
 E-mail: [sales@kerhgroup.com](mailto:sales@kerhgroup.com)



**Targeting Optometrists?**

**CLASSIFIED ADVERTISING WORKS**

- JOB OPENINGS • CME PROGRAMS
- PRODUCTS & SERVICES • AND MORE...

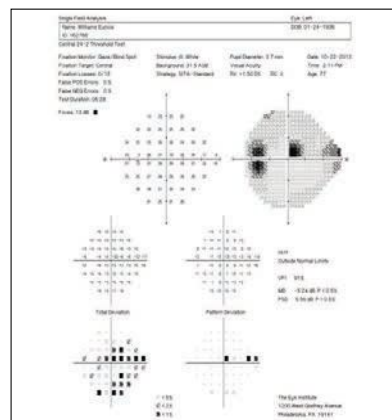
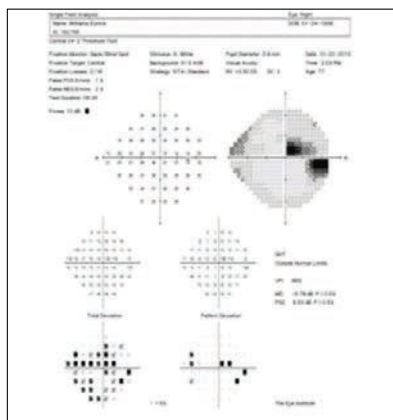
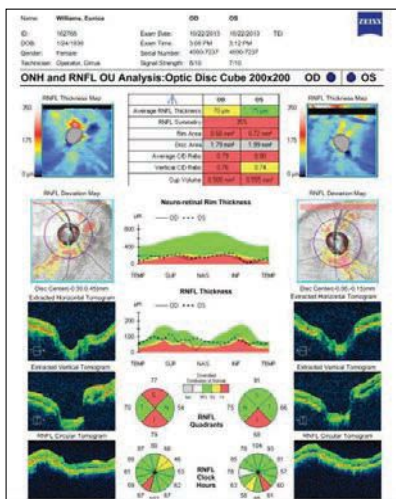
Contact us today for classified advertising:  
 Toll free: 888-498-1460  
 E-mail: [sales@kerhgroup.com](mailto:sales@kerhgroup.com)





## Field a Guess

What to do when perimetry doesn't align with other clues? **By Andrew S. Gurwood, OD**



**The homonymous field defect leads one to consider a differential diagnosis path that may or may not be supported by the exam findings and OCT results.**

### History

A 67-year-old Black female reported to the office for a glaucoma follow-up. She explained that her eye pressure had been managed by another doctor, but—since that practice no longer took her insurance—she was referred to us by her internist.

Systemic history was remarkable for hypertension, managed with atenolol 50mg QD; ocular history was significant for open-angle glaucoma of one year's duration, treated with latanoprost HS, OU. She denied exposure allergies of any kind.

### Diagnostic Data

Her best-corrected entering visual acuities were 20/20 OU at distance and near. Her external exam was normal with no evidence of afferent pupillary defect. The biomicroscopic exam of the anterior segment was normal with superficial evidence of open angles. Goldmann applanation tonometry measured 15mm Hg OU. The dilated fundus findings were normal peripherally and centrally with both nerves exhibiting moderately increased cup-to-disc ratios measuring 0.7/0.8 OU.

Additional studies included pachymetry (550µm OU), visual fields, OCT of the nerves, gonioscopy (D40r, no pigment, no exfoliation, no angle recession and no neovascularization) and a phone call to the old practice to attempt to obtain critical previous data.

### Your Diagnosis

What would be your diagnosis? What is the patient's likely prognosis? To find out, please read the online version of this article at [www.reviewofoptometry.com](http://www.reviewofoptometry.com). ■

### Next Month in the Mag

Coming in January, *Review of Optometry* will present a series on vision care. Articles will include:

- Vision Correction and Optometric Practice: It's Complicated
- Become a Binocular Vision Pro

- The Generalist's Guide to Amblyopia
- Kids and Screen Time: How Much is Too Much?
- Low Vision: Causes and Corrections

Also included in January:

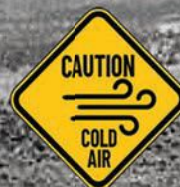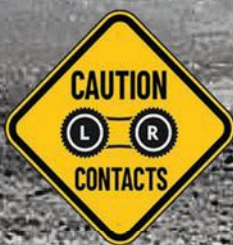- Dry Eye Reader Survey: What ODs See, and Do, About It

**Retina Quiz Answers** (from page 64)—Q1: b, Q2: d, Q3: a, Q4: a

REVIEW OF OPTOMETRY (ISSN 0147-7633) IS PUBLISHED MONTHLY, 12 TIMES A YEAR BY JOBSON MEDICAL INFORMATION LLC, 395 HUDSON STREET, 3RD FLOOR FLOOR, NEW YORK, NY 10014. PERIODICALS POSTAGE PAID AT NEW YORK, NY AND ADDITIONAL MAILING OFFICES. POSTMASTER: SEND ADDRESS CHANGES TO REVIEW OF OPTOMETRY, PO BOX 81, CONGERS, NY 10920-0081. SUBSCRIPTION PRICES: US: ONE YEAR \$56; TWO YEARS \$97, CANADA: ONE YEAR \$88, TWO YEARS \$160, INT'L: ONE YEAR \$209, TWO YEARS \$299. FOR SUBSCRIPTION INFORMATION CALL TOLL-FREE (877) 529-1746 (USA); OUTSIDE USA, CALL (845) 267-3065. OR EMAIL US AT REVOPOTOMETRY@CAMBEYWEST.COM. PUBLICATIONS MAIL AGREEMENT NO: 40612608. CANADA RETURNS TO BE SENT TO BLEUCHIP INTERNATIONAL, P.O. BOX 25542, LONDON, ON N6C 6B2.



# FOR MOST PATIENTS, DRY EYE SYMPTOMS HAVE AN EPISODIC IMPACT



## FLARES: THE SPEED BUMPS OF DRY EYE

Most patients with Dry Eye suffer from short-term, episodic exacerbations—*Dry Eye Flares*.<sup>1-3</sup>

Many patients don't suffer from continuous symptoms.<sup>3</sup>

**REENVISION**  
**DRY EYE**


kala  
PHARMACEUTICALS

**References:** 1. Brazzell RK, Zickl L, Farrelly J, et al. Prevalence and characteristics of dry eye flares: a patient questionnaire survey. Presented at: AAO 2019: October 12-15, 2019; San Francisco, CA. 2. Brazzell RK, Zickl L, Farrelly J, et al. Prevalence and characteristics of symptomatic dry eye flares: results from patient questionnaire surveys. Poster presented at: AAOPT 2019: October 23-27, 2019; Orlando, FL. 3. 2020 Study of Dry Eye Sufferers. Conducted by Multi-sponsor Surveys, Inc.





# CRACK THE CODE: RELIEVE EYE DRYNESS

 Artificial tears for today's  
digital device users.

A lot can happen in the blink of an eye. When using digital devices, incomplete blinking contributes to tear film instability, resulting in eye dryness.

## REFRESH® DIGITAL:

- Supports all three tear film layers
- Enables hydration with *HydroCell*™ technology
- Prevents tear evaporation due to lipid layer deficiencies



NEED REFRESH® SAMPLES AND RESOURCES?

Call **Refresh** CONCIERGE at **833-REF-SMPL** today!

 **Allergan**  
an AbbVie company