

CE Monograph



# PREVENTING VISION-THREATENING COMPLICATIONS OF DIABETES

Improving Identification and Management

Visit <https://tinyurl.com/preservevision> for online testing and instant CE certificate

## FACULTY



Jeffry Gerson,  
OD, FAAO



Diana L. Shechtman,  
OD, FAAO



Charles C. Wykoff,  
MD, PhD

Original Release: December 1, 2019 Expiration: November 26, 2022



COPE approved for 2.0 credits for optometrists  
COPE Course ID: 65675-PS  
COPE Course Category: Treatment & Management of Ocular Disease: Posterior Segment (PS)

Sponsored by



Administrator



This continuing education activity is supported through unrestricted educational grants from Regeneron Pharmaceuticals, Inc, and Optos.

Distributed with



## LEARNING METHOD AND MEDIUM

This educational activity consists of a supplement and twenty (20) study questions. The participant should, in order, read the learning objectives contained at the beginning of this supplement, read the supplement, answer all questions in the post test, and complete the Activity Evaluation/Credit Request form. To receive credit for this activity, please follow the instructions provided on the post test and Activity Evaluation/Credit Request form. This educational activity should take a maximum of 2.0 hours to complete.

## CONTENT SOURCE

This continuing education (CE) activity captures content from a regional dinner meeting series.

## ACTIVITY DESCRIPTION

By the year 2050, it is estimated that the prevalence of vision-threatening diabetic retinopathy in the United States will nearly triple, from 1.2 million (in 2005) to 3.4 million. Diabetic retinopathy is the leading cause of blindness among working-aged adults. Approximately half of patients with diabetes have some degree of diabetic retinopathy or even diabetic macular edema at diagnosis. A rapid evolution in widefield retinal imaging enables earlier detection and more accurate staging of diabetic retinopathy, which in turn facilitates timely referral and treatment as well as provides prognostic information that can be used for effective comanagement and patient education. Recent research also continues to refine the management of diabetic retinopathy and diabetic macular edema. Diabetic retinopathy can now be treated in the absence of diabetic macular edema. Additionally, some forms of diabetic macular edema might be observed when vision is not affected. The increasingly complex management of diabetic retinopathy and diabetic macular edema requires a collaborative approach between optometrists and retina specialists, with communication at the forefront. The desired results of this activity are to enable optometrists to better identify patients with diabetic retinopathy and diabetic macular edema and to improve how care is coordinated so that effective treatment practices can ultimately improve visual outcomes of patients with diabetes.

## TARGET AUDIENCE

This activity intends to educate optometrists.

## LEARNING OBJECTIVES

Upon completion of this activity, participants will be better able to:

- Appraise the role of peripheral retinal imaging in detection and grading of diabetic retinopathy
- Differentiate stages of diabetic retinopathy in individual patients according to guidelines and widefield/ultrawidefield images
- Design monitoring and referral strategies for individual patients according to severity of diabetic retinopathy
- Describe treatments for diabetic retinopathy and diabetic macular edema to patients with diabetes
- Discuss treatment strategies for diabetic retinopathy and diabetic macular edema with retina specialists

## ACCREDITATION STATEMENT



COPE approved for 2.0 CE credits for optometrists.  
COPE Course ID: 65675-PS  
COPE Course Category: Treatment & Management of Ocular Disease: Posterior Segment (PS)

Administrator

**MedEdicus**

## DISCLOSURES

**Jeffrey Gerson, OD**, had a financial agreement or affiliation during the past year with the following commercial interests in the form of *Consultant/Advisory Board*: Allergan; AstaReal, Inc; Bausch & Lomb Incorporated; Genentech, Inc; Maculogix, Inc; Optos; Optovue, Incorporated; Regeneron Pharmaceuticals, Inc; Vision Service Plan; and ZeaVision LLC; *Honoraria from promotional, advertising or non-CME services received directly from commercial interests or their Agents*

(eg, *Speakers Bureaus*): Genentech, Inc; Maculogix, Inc; Regeneron Pharmaceuticals, Inc; Vision Service Plan; and ZeaVision LLC.

**Diana L. Shechtman, OD**, had a financial agreement or affiliation during the past year with the following commercial interests in the form of *Consultant/Advisory Board*: Allergan; Genentech, Inc; Regeneron Pharmaceuticals, Inc; and Zeiss; *Honoraria from promotional, advertising or non-CME services received directly from commercial interests or their Agents* (eg, *Speakers Bureaus*): AstaReal, Inc; and Optos.

**Charles C. Wykoff, MD, PhD**, had a financial agreement or affiliation during the past year with the following commercial interests in the form of *Consultant/Advisory Board*: Adverum; Aerpio Therapeutics; Alimera Sciences; Allegro Ophthalmics, LLC; Allergan; Apellis Pharmaceuticals; Bayer Corporation; Chengdu Kanghong Pharmaceutical Group Co Ltd; Clearside Biomedical; D.O.R.C.; EyePoint Pharmaceuticals; F. Hoffmann-La Roche Ltd; Genentech, Inc; IVERIC bio; Kodiak Sciences Inc; Novartis Pharmaceuticals Corporation; ONL Therapeutics; PolyPhotonix; Recens Medical, Inc; Regeneron Pharmaceuticals, Inc; Regenxbio Inc; Santen Inc; Shanghai Fosun Pharmaceutical Group Co, Ltd; and Takeda Pharmaceuticals USA, Inc; *Contracted Research*: Adverum; Aerpio Therapeutics; Allergan; Apellis Pharmaceuticals; Chengdu Kanghong Pharmaceutical Group Co Ltd; Clearside Biomedical, Inc; F. Hoffmann-La Roche Ltd; Genentech, Inc; IVERIC bio; Kodiak Sciences Inc; Neurotech Pharmaceuticals; Novartis Pharmaceuticals Corporation; Opthea; Outlook Therapeutics, Inc; Recens Medical, Inc; Regeneron Pharmaceuticals, Inc; Regenxbio Inc; Samsung BioLogics; and Santen Inc; *Honoraria from promotional, advertising or non-CME services received directly from commercial interests or their Agents* (eg, *Speakers Bureaus*): Regeneron Pharmaceuticals, Inc.

## EDITORIAL SUPPORT DISCLOSURES

The planners and staff of MedEdicus LLC have no relevant commercial relationships to disclose.

## DISCLOSURE ATTESTATION

The contributing physicians listed above have attested to the following:

- 1) that the relationships/affiliations noted will not bias or otherwise influence their involvement in this activity;
- 2) that practice recommendations given relevant to the companies with whom they have relationships/affiliations will be supported by the best available evidence or, absent evidence, will be consistent with generally accepted medical practice; and
- 3) that all reasonable clinical alternatives will be discussed when making practice recommendations.

## PRODUCT USAGE IN ACCORDANCE WITH LABELING

Please refer to the official prescribing information for each drug and/or device discussed in this activity for approved indications, contraindications, and warnings.

## GRANTOR STATEMENT

This continuing education activity is supported through unrestricted educational grants from Regeneron Pharmaceuticals, Inc, and Optos.

## SPONSORED BY



## TO OBTAIN CE CREDIT

We offer instant certificate processing and support Green CE. Please take this post test and evaluation online by going to <http://tinyurl.com/preservevision>. You must answer 14 out of 20 questions correctly in order to pass, and may take the test up to 2 times. Upon passing, you will receive your certificate immediately. There are no fees for participating in and receiving CE credit for this activity.

## DISCLAIMER

The views and opinions expressed in this educational activity are those of the faculty and do not necessarily represent the views of the State University of New York College of Optometry; MedEdicus LLC; Regeneron Pharmaceuticals, Inc; Optos; or *Review of Optometry*.

This CE activity is copyrighted to MedEdicus LLC ©2019. All rights reserved. 192

## FACULTY

### Jeffrey Gerson, OD, FAAO

Grin Eye Care  
Olathe, Kansas  
Consultant  
Kansas City VA Medical Center  
Kansas City, Missouri

### Diana L. Shechtman, OD, FAAO

Consultative Optometric Physician  
Retina Macula Specialists of Miami  
Miami, Florida

### Charles C. Wykoff, MD, PhD

Director of Research  
Retina Consultants of Houston  
Deputy Chair for Ophthalmology  
Blanton Eye Institute  
Houston Methodist Hospital  
Houston, Texas

# PREVENTING VISION-THREATENING COMPLICATIONS OF DIABETES

## Improving Identification and Management

### INTRODUCTION

The epidemiology of diabetes mellitus reveals an epidemic of the disease. Diabetes affects more than 30 million people in the United States today.<sup>1</sup> Another 84 million have prediabetes and are at risk of developing diabetes.<sup>1</sup> By 2020, 43 million people in the United States are projected to have diabetes; by 2030, approximately half of all Americans will have either diabetes (55 million) or prediabetes (108 million).<sup>2</sup> Diabetic retinopathy (DR)—a common microvascular complication of diabetes—is the leading cause of vision loss and blindness in working-aged Americans.<sup>3</sup> Diabetic retinopathy also adversely affects quality of life.<sup>4</sup> The development of inhibitors of vascular endothelial growth factor (VEGF) has significantly altered the therapeutic landscape for both DR and diabetic macular edema (DME). Clinical trials demonstrating the benefit of anti-VEGF therapy for DME also demonstrated regression of DR, leading to the recent PANORAMA study of aflibercept—the first study designed specifically to evaluate DR improvement with anti-VEGF therapy among eyes with nonproliferative DR (NPDR) without DME.<sup>5</sup> In this educational activity, the clinical findings characteristic of DR as well as diagnosis, grading, treatment, and screening recommendations will be reviewed.

### DIABETES MELLITUS AND DIABETIC RETINOPATHY

Diabetes is a family of related conditions that share in common hyperglycemia, which leads to microvascular complications—such as retinopathy, nephropathy, and neuropathy—as well as macrovascular complications—such as coronary heart disease and stroke.<sup>6</sup> Metabolic control of hyperglycemia is the mainstay of diabetes therapy and can modify the risk of vascular complications of the disease, including DR. Other risk factors for diabetes include positive family history, hypertension, hyperlipidemia, smoking, high body mass index, sleep apnea, and certain ethnicities/races (African American, Hispanic, and Native American).<sup>7-9</sup>

Diabetic retinopathy is the leading cause of vision loss and blindness among adults aged 20 to 74 years in the United States.<sup>3</sup> Diabetic retinopathy is nearly ubiquitous among people with long-standing diabetes: after  $\geq 20$  years with the disease, nearly 100% of people with type 1 diabetes<sup>10</sup> and 60% of people with type 2 diabetes<sup>11</sup> have some degree of DR. Numerous studies have demonstrated that optimal control of blood glucose levels and cardiovascular risk factors reduces the risk of both the development and progression of DR.<sup>12,13</sup> Even small

**Table.** Diabetic Retinopathy Severity Scale and Clinical Features That Differentiate Stages<sup>7,15-17</sup>

International Council of Ophthalmology	Modified ETDRS	ETDRS	Clinical Features	Follow-Up/Referral Guideline
No DR	Healthy	10, 12	No abnormalities	Follow up in 6 months to 2* years
Mild NPDR	Very mild NPDR	14, 15, 20	Microaneurysms only	Follow up in 6-12 months; referral not required
	Mild NPDR			
Moderate NPDR	Moderate NPDR	35, 43	Microaneurysms plus: <ul style="list-style-type: none"> <li>• Mild or moderate hemorrhages</li> <li>• Hard exudates</li> <li>• Cotton wool spots</li> <li>• IRMA in 1-3 fields</li> </ul>	Follow up in 3-6 months; referral not required unless DME is present (AOA); referral required (AAO, ICO)
	Moderately severe NPDR	47	Moderate plus: <ul style="list-style-type: none"> <li>• Severe hemorrhages</li> <li>• IRMA in 4-5 fields</li> <li>• Venous beading</li> </ul>	
Severe NPDR	Severe NPDR	53	<b>4-2-1 rule:</b> Any of the following and no signs of proliferative retinopathy: <ul style="list-style-type: none"> <li>• Severe intraretinal hemorrhages and microaneurysms in each of 4 quadrants</li> <li>• Definite venous beading in 2 or more quadrants</li> <li>• Moderate IRMA in 1 or more quadrants</li> </ul>	Prompt referral
PDR	Mild PDR	60, 61	Severe NPDR plus: <ul style="list-style-type: none"> <li>• Neovascularization</li> <li>• Vitreous/Preretinal hemorrhage</li> </ul>	Prompt referral
	Moderate PDR	65		
	High-risk PDR	71, 75, 81, 85		

Abbreviations: AAO, American Academy of Ophthalmology; AOA, American Optometric Association; DR, diabetic retinopathy; ETDRS, Early Treatment Diabetic Retinopathy Study; ICO, International Council of Ophthalmology; IRMA, intraretinal microvascular abnormality; NPDR, nonproliferative diabetic retinopathy; PDR, proliferative diabetic retinopathy.

\* Follow-up extension to 2 years should be considered only in low- or intermediate-resource settings. In high-resource settings, follow-up should occur at least yearly.

improvements in glucose control can have positive effects on outcomes—as little as a 1% reduction in HbA<sub>1c</sub>, which translates to a 30-mg/dL drop in average blood sugar, can reduce the risk of DR progression by 50%.<sup>14</sup> Optometrists can positively affect the course of DME and DR by counseling patients on the importance of blood glucose optimization and to seek help from their physicians and dietitians for effective ways to maintain acceptable blood glucose levels. Once a patient has developed DR, optometrists play a vital role in identifying, staging, and referring to a retina specialist. Retina specialists in turn are now able to treat DR at an even earlier stage, preventing vision loss that was once considered an inevitable consequence of the disease.

Even small improvements in glucose control can have positive effects on outcomes—as little as a 1% reduction in HbA<sub>1c</sub>, which translates to a 30-mg/dL drop in average blood sugar, can reduce the risk of DR progression by 50%.

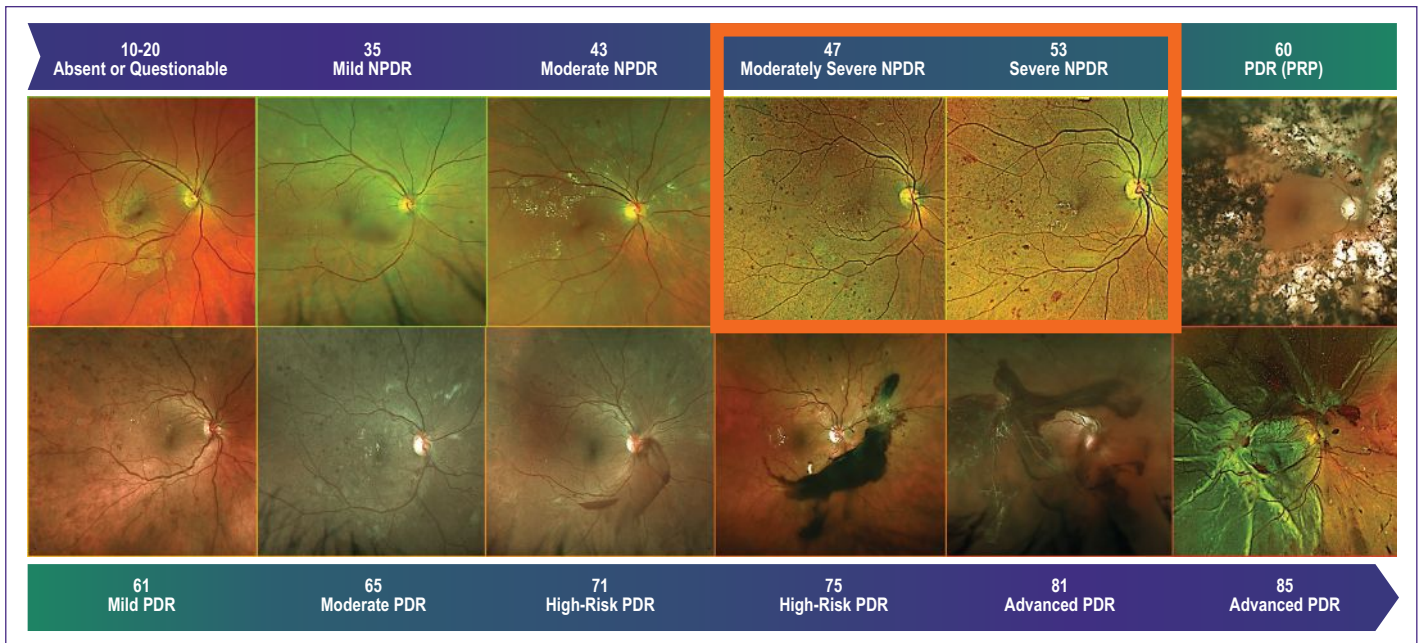
## DIABETIC RETINOPATHY: GRADING AND SCREENING

Diabetic retinopathy exists across a spectrum of severity. The consensus international Diabetic Retinopathy Severity Scale

(DRSS) (**Table**) lists 5 levels of DR, ranging from none to several stages of NPDR to proliferative DR (PDR).<sup>7,15-17</sup> The clinical manifestations at each stage (**Figure 1**) reflect the condition's underlying pathogenesis. Guidelines for evaluating and managing DR have been developed by multiple organizations dedicated to visual health, including the American Optometric Association (AOA),<sup>7</sup> the American Academy of Ophthalmology (AAO),<sup>16</sup> and the International Council of Ophthalmology (ICO).<sup>15</sup> Each of these organizations has developed guidance on the timing of referral, treatment, and next appropriate follow-up interval, as determined by the clinical stage of DR.

### Mild Nonproliferative Diabetic Retinopathy

The primary pathophysiologic insult in DR is to the small blood vessels of the body. High blood glucose concentrations damage the pericytes—the small support cells that line the retinal capillaries and maintain their health and function. Early loss of retinal capillary pericytes causes weakening of capillary walls.<sup>18</sup> Focal loss of capillary support can give rise to outpouchings in the capillaries called microaneurysms, which are the characteristic lesion of mild NPDR. Mild NPDR can be safely observed without treatment; reexamination is reasonable within 6 to 12 months.



**Figure 1.** Representative widefield color fundus photographs of diabetic retinopathy at various Early Treatment Diabetic Retinopathy Study (numerals) and International Council of Ophthalmology (text) stages

Abbreviations: NPDR, nonproliferative diabetic retinopathy; PDR, proliferative diabetic retinopathy; PRP, panretinal photocoagulation.

Figure courtesy of Charles C. Wykoff, MD, PhD. All rights reserved.

### Moderate Nonproliferative Diabetic Retinopathy

With persistent elevations of blood glucose, progressive retinal vascular damage ensues. Weakened capillaries can also rupture, leading to retinal dot/blot hemorrhages and, upon resorption of blood, residual lipid accumulations in the retinal tissue seen as hard exudates. These microvascular insults contribute to tissue nonperfusion and hypoxia in capillary beds, which can give rise to focal retinal ischemia, seen as cotton wool spots. In some cases, shunt vessels will develop to supply areas of nonperfused retina; these are called intraretinal microvascular abnormalities (IRMAs). Once at this stage, the risk of progression to PDR is 4.5% in 1 year, 14.4% in 3 years, and 25.1% in 5 years.<sup>17</sup> According to the AAO and ICO guidelines, moderate NPDR should be referred to a retina specialist, whereas the AOA guidelines do not require referral unless DME is present.<sup>7,15,16</sup>

### Moderately Severe Nonproliferative Diabetic Retinopathy

Although not part of the international classification system, some physicians use an interim grade of “moderately severe” NPDR, which is more severe than moderate NPDR but does not meet the criteria for severe NPDR. The lesions seen at this stage are the same as those in moderate NPDR, but are greater in number. At this stage, the 1-, 3-, and 5-year risks of progressing to PDR are 26%, 47.6%, and 66.4%, respectively.<sup>17</sup> As with moderate NPDR, moderately severe NPDR should be referred to the retina specialist according to both the AAO and ICO guidelines, although the AOA guidelines specify that this is only necessary if DME is also present.<sup>7,15,16</sup>

### Severe Nonproliferative Diabetic Retinopathy

Severe NPDR is the last stage of NPDR before PDR appears. Diagnosis of severe NPDR follows a **4-2-1** rule: more than 20 intraretinal hemorrhages in each of the **4** quadrants; venous beading in **2** or more quadrants; prominent IRMAs in **1** or more quadrants; and no signs of PDR. At this stage, the risk of progression to PDR is 51.5%, 71.1%, and 79.5% at 1, 3, and 5 years, respectively.<sup>17</sup> Severe NPDR warrants prompt referral, with consensus among the 3 guidelines.<sup>7,15,16</sup>

### Proliferative Diabetic Retinopathy

PDR is the natural consequence of untreated NPDR. Ischemic tissues in eyes with NPDR release VEGF, a potent angiogenic molecule that triggers the growth of new blood vessels in an effort to restore tissue perfusion.<sup>19</sup> Neovascularization of the retina in a diabetic eye heralds the onset of PDR. Neovascularization can occur from the surface of the optic disc (NVD) or elsewhere in the retina. In the classification rubric described previously, PDR is described as neovascularization of the retina, vitreous/preretinal hemorrhage, or both.<sup>15</sup> PDR poses a greater threat to vision than does NPDR. As blood vessels grow in response to VEGF release in eyes with PDR, fibrous tissue accompanies the vascular tissue growth. These vessels are fragile, and are prone to leak and to rupture, potentially causing significant vitreous hemorrhages (**Figure 1, see High-Risk PDR**). As the fibrovascular tissues proliferate, they create traction on the retina that can lead to retinal tears and detachments. All cases of PDR warrant prompt referral.<sup>7,15,16</sup>

## Diabetic Macular Edema

In addition to its angiogenic activity, VEGF is also a potent vascular permeability factor and causes retinal capillaries to become leaky.<sup>19</sup> Fluid that escapes from these capillaries collects within the retinal tissue of the macula, leading to edema. DME can occur in eyes with or without other forms of DR and is a common cause of vision loss in people with diabetes. At the time of diabetes diagnosis, only 2% to 3% of people will have DME, but after living with diabetes for  $\geq 20$  years, approximately 30% of people will develop DME.<sup>20</sup> All cases of DME warrant prompt referral, the most urgent of which are those in which the DME involves the center of the macula and those associated with vision loss.<sup>7,15,16</sup>

Screening is crucial for detecting early DR before the onset of vision loss. The guidelines of the AOA, AAO, and ICO also include recommendations for screening.<sup>7,15,16</sup> In general, patients newly diagnosed with type 1 diabetes should have the first eye examination within 5 years and annual examinations thereafter, whereas those with type 2 diabetes should be examined at diagnosis and annually thereafter, unless there is reason for more frequent evaluations, such as the presence of retinopathy.

## DIABETIC RETINOPATHY IMAGING

For many years, standard imaging for DR consisted of  $\geq 1$  color fundus photographs (often assembled into a collage) to document DR and to educate patients; fluorescein angiography (FA) was used to identify and stage DR lesions. In recent years, widefield—and now ultrawidefield—imaging has emerged as a powerful tool for the detection of DR, especially in the peripheral retina, which is difficult to examine and to photograph by standard means. Widefield imaging is centered on the fovea and includes the retina in all 4 quadrants posterior to and including the vortex vein ampullae, whereas ultrawidefield imaging includes the far periphery of the retina, anterior to the vortex vein ampulla (**Figure 2**).<sup>21</sup> The Optos California device is capable of providing a complete view of the vortex veins and retinal periphery, without the need for montage, whereas the CenterVue and Zeiss devices show a montage of 2 or more images to achieve widefield imaging.

Although most DR lesions are found within the ETDRS (Early Treatment Diabetic Retinopathy Study) standard fields making up the posterior pole and representing approximately 30% of the total retina area, approximately 30% of microaneurysms, intraretinal microvascular abnormalities, and neovascularization occur more peripherally.<sup>22</sup> Interestingly, in a comparative grading study between standard and ultrawidefield imaging, 10% of eyes were classified as having more severe DR when peripheral retinal imaging was considered, suggesting that the disease might not progress from the macula outward as once thought, but rather manifest first and more severely in the periphery.<sup>22</sup>

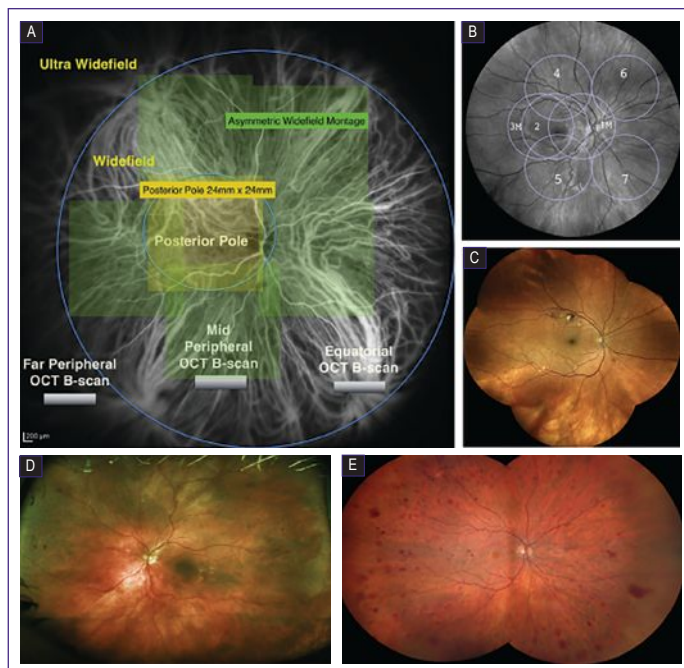


Figure 2. Retinal imaging using fundus photography on different devices. (A) Indocyanine green angiography captured with a Heidelberg device.<sup>21</sup> The inner blue circle delineates the posterior pole, and the outer blue circle delineates the midperiphery and the field of view captured using widefield imaging. The area outside the outer blue circle is defined as the far periphery, and imaging that captures this area is defined as ultrawidefield. (B) An image captured with a Topcon device, with the 7 standard Early Treatment Diabetic Retinopathy Study fields overlaid.<sup>21</sup> (C) Widefield imaging captured using a CenterVue device with montage. (D) Ultrawidefield imaging captured with an Optos device. (E) Widefield imaging captured using a Zeiss device and montage.

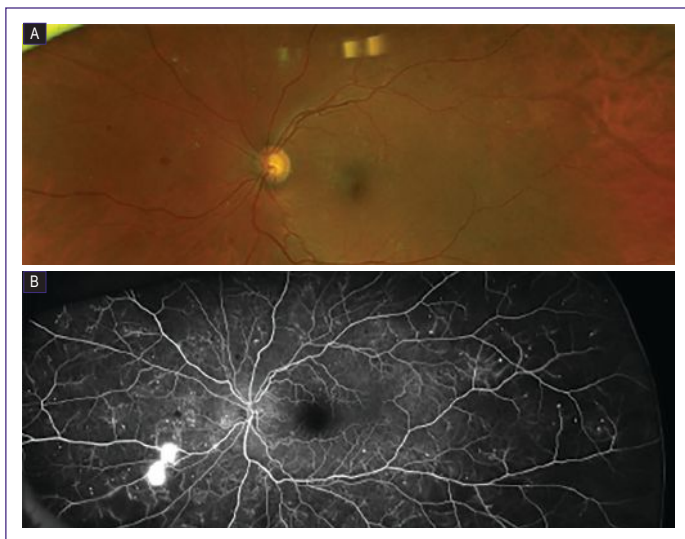
Abbreviation: OCT, optical coherence tomography.

Images courtesy of Steven Ferrucci, OD (Figure 2C), Charles C. Wykoff, MD, PhD (Figure 2D), and Diana L. Shechtman, OD (Figure 2E)

Peripheral DR lesions also have an important prognostic value. Over 4 years of follow-up, patients with predominantly peripheral lesions (PPLs) had a 3.2-fold higher risk of progressing by  $\geq 2$  grades on DRSS (34% vs 11% for patients without PPLs) and a 4.6-fold higher risk of developing PDR (25% vs 6% for patients without PPLs).<sup>23</sup> In other words, of patients who present with more microaneurysms and/or hemorrhages in the periphery than is observed in the central fields, 1 in 4 will go on to develop PDR within 4 years without intervention. Surprisingly, patients with PPLs might represent approximately 40% of patients with NPDR, as indicated in the preliminary analysis of the Diabetic Retinopathy Clinical Research Network's (DRCR Retina Network) Protocol AA data.<sup>24</sup> It is reasonable to follow up with these patients more frequently in order to ensure timely referral when needed.

Over 4 years of follow-up, patients with predominantly peripheral lesions (PPLs) had a 3.2-fold higher risk of progressing by  $\geq 2$  grades on DRSS (34% vs 11% for patients without PPLs) and a 4.6-fold higher risk of developing PDR (25% vs 6% for patients without PPLs).

Fluorescein angiography can also be performed in conjunction with ultrawidefield imaging. This technique can help identify peripheral lesions, particularly areas of nonperfusion that might not be evident on clinical examination or color photography and that might be a sign of worsening DR.<sup>25</sup> In some cases, ultrawidefield FA can reveal occult hemorrhage or neovascularization that is not evident on color fundus photography (**Figure 3**). This observation suggests that in certain patients, earlier referral to a retina specialist for FA could potentially help accurately grade DR and enable timely treatment to avert loss of vision.



**Figure 3.** (A) Ultrawidefield color fundus photography suggestive of moderate NPDR. (B) Fluorescein angiography of the same eye as in (A), showing widespread peripheral nonperfusion, numerous microaneurysms, and neovascularization indicative of PDR.

*Images courtesy of Diana L. Shechtman, OD*

## TRANSLATING RECENT ADVANCES TO BETTER TREATMENT OF DIABETIC RETINOPATHY

The best way to treat DR is to prevent it in the first place, which can potentially be accomplished with intensive blood glucose management.<sup>12,13</sup> Laser panretinal photocoagulation (PRP) was the only mainstay of therapy for severe NPDR and PDR for decades. More recently, the intravitreal injection of drugs that inhibit VEGF has been shown to be effective in treating NPDR, PDR, and DME. These drugs include aflibercept, ranibizumab, and bevacizumab. Of these, only aflibercept and ranibizumab were developed and formulated specifically for intraocular use, have been evaluated in phase 3 clinical trials to demonstrate their efficacy in treating both DR and DME, and are approved by the US Food and Drug Administration for use in DR and DME. Recently, both aflibercept and ranibizumab packed in prefilled syringes have been approved for use in the United States.

Initially, these drugs were evaluated as treatments for DME. As described subsequently, observations of improved DR in studies of DME led to their approval to treat DR as well. The effect of

DR on quality of life has been studied. A progressive drop in quality of life is seen when DR reaches a severity of  $\geq 43$  on DRSS, which corresponds to moderate NPDR.<sup>4</sup> Thus, anti-VEGF therapy has the potential to improve visual acuity (VA) by treating DME and to improve quality of life by treating DR.

Aflibercept was first approved for the management of DME following the successful VIVID and VISTA phase 2 clinical trials.<sup>26</sup> In these identically designed trials, patients with center-involved (CI) DME were treated with 2 mg of intravitreal aflibercept injections (IAIs) every 4 or 8 weeks after 5 monthly loading doses or macular laser. Rescue laser was permitted in the IAI groups, and rescue IAI was permitted in the laser group. After 3 years of treatment, the mean change in best-corrected VA (BCVA) from baseline in VISTA was 10.4, 10.5, and 1.4 ETDRS letters, respectively ( $P < .0001$ ). Results from VIVID were comparable. Both IAI dosing groups had significantly higher proportions of eyes with a  $\geq 2$ -step improvement in DRSS grading compared with the laser group ( $P \leq .035$ ). The most common adverse event was cataract formation, which occurred in 3.1% of the 291 eyes receiving IAI every 4 weeks, in 2.1% of the 287 eyes receiving IAI every 8 weeks, and in 0.3% of the 287 eyes receiving laser.

Aflibercept's utility in treating DR was first seen in the VIVID and VISTA studies and recently confirmed in the PANORAMA study.<sup>5</sup> The PANORAMA study was the first—and only, to date—study specifically designed to assess regression of DR as the primary end point. Patients with moderately severe or severe NPDR without DME were treated with IAI 2 mg every 8 ( $n = 134$ ) or 16 ( $n = 135$ ) weeks following 4 and 5 loading doses, respectively, or sham injections ( $n = 133$ ). The primary outcome measure was improvement of  $\geq 2$  DRSS steps at week 52 of this ongoing, 100-week study; improvement was achieved by 79.9%, 65.2%, and 15.0% of eyes, respectively ( $P < .0001$ ). Both IAI dosing groups had significantly lower rates of vision-threatening complications (VTCs) (progression to PDR or anterior segment neovascularization) or CI-DME than did the sham group. The rate of VTC or CI-DME through 52 weeks of therapy was 40.6% in the sham group, 9.6% (a 76.3% reduction) in the group receiving IAI every 16 weeks, and 11.2% (a 72.4% reduction) in the group receiving IAI every 8 weeks ( $P < .0003$  for both IAI groups vs sham). This magnitude of effect suggests that 3 patients need to be treated to prevent 1 case of VTC or CI-DME. In contrast, the Ocular Hypertension Treatment Study found that the number-needed-to-treat was 20 patients with ocular hypertension to prevent the development of a single case of early open-angle glaucoma.<sup>27</sup> Systemic safety assessments revealed no increase in cardiovascular or cerebrovascular complications compared with sham injections.

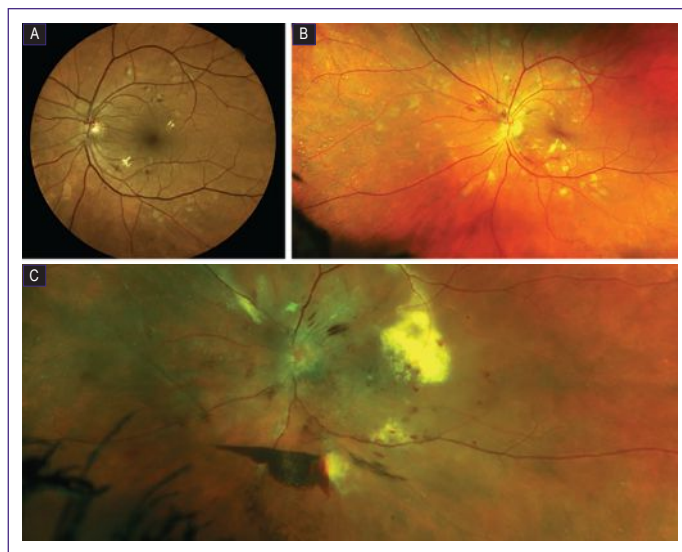
Ranibizumab's efficacy in treating both DME and DR was established in the phase 3 RIDE/RISE trials.<sup>28</sup> The primary

end point of these studies was improvement in BCVA related to DME; DR regression was explored secondarily. Three-year outcomes in these trials also demonstrated significantly better VA gains in eyes with DME receiving ranibizumab than in those receiving sham. In eyes with DR, the likelihood of a  $\geq 2$ -step DRSS improvement was higher with ranibizumab than with sham. A 5-year clinical trial—DRCR Retina Network's Protocol S—comparing PRP with ranibizumab in eyes with PDR demonstrated comparable BCVA but better peripheral visual field preservation and less macular edema (a well-known potential complication of PRP<sup>29</sup>) in the ranibizumab-treated eyes.<sup>30</sup> A European clinical trial (PROTEUS) comparing combination therapy with PRP and ranibizumab ( $n = 41$ ) with PRP alone ( $n = 46$ ) demonstrated greater regression of neovascularization in the combination group at month 12 (92.7% vs 70.5%, respectively).<sup>31</sup> No significant difference in mean VA was seen between the groups.

Although bevacizumab is not formulated for intraocular injection, it is often used off-label for the same conditions for which aflibercept and ranibizumab have been shown to be beneficial treatments. The DRCR Retina Network's Protocol T demonstrated bevacizumab's efficacy in treating DME. Compared with ranibizumab and aflibercept, bevacizumab produced modestly smaller VA gains at 2 years ( $P = .02$  for aflibercept vs bevacizumab and  $P = .11$  for ranibizumab vs bevacizumab).<sup>32</sup> In the same study, eyes receiving bevacizumab had similar rates of  $\geq 2$ -step DRSS improvement to those of eyes receiving aflibercept or ranibizumab at 2 years.<sup>33</sup>

A common clinical scenario is the patient with CI-DME, as shown on optical coherence tomography (OCT), who has preserved central VA. Should such a patient be treated or observed? The DRCR Retina Network's Protocol V generated data to guide management of this scenario.<sup>34</sup> Patients with CI-DME and a VA of 20/25 or better were randomly assigned to receive aflibercept, laser with anti-VEGF therapy added if needed, or observation with anti-VEGF therapy added if needed. After 2 years, there were similar outcomes with each management strategy, suggesting each of the treatment approaches can be employed depending on the individual patient's clinical scenario. It should be noted that patients in this trial were relatively well adherent to their treatment and follow-up regimens, whereas in the real world, the potential for loss to follow-up should not be overlooked.

For refractory cases of DME, corticosteroid therapy can be beneficial. To improve pharmacodynamics, devices providing sustained release of various steroids (dexamethasone, fluocinolone acetonide) have been developed for intraocular implantation. These devices can reduce the frequency of treatment often necessitated by nondevice-based steroids such as triamcinolone. In eyes with severe PDR or DME recalcitrant to all pharmacologic interventions, vitrectomy might be of value.



**Figure 4.** Fundus photographs from the patient presented in Case 1. (A) Standard color photograph of the posterior pole revealing moderate nonproliferative diabetic retinopathy at presentation. (B) Ultrawidefield imaging revealing moderately severe nonproliferative diabetic retinopathy 1 year later. (C) Ultrawidefield imaging revealing severe proliferative diabetic retinopathy and diabetic macular edema after an additional year lost to follow-up.

## CASE 1: LONG-STANDING TYPE 1 DIABETES

*From the Files of Jeffrey Gerson, OD, FAAO*

*A 60-year-old female had a 52-year history of type 1 diabetes. Her HbA<sub>1c</sub> was approximately 8.5%, and she reported difficulty maintaining consistency of her blood glucose levels. Her VA was 20/20 OU. **Figure 4A** shows her fundus examination photographs at the time of presentation. On the basis of more than just microaneurysms (dot-blot hemorrhages and hard exudates are also present), but without venous beading or IRMAs, she was diagnosed with moderate NPDR, observed without treatment, and asked to follow up every 6 months. When seen at the 12-month follow-up visit, her VA had remained 20/20 OU, she had progressed to moderately severe NPDR (**Figure 4B**), and she was referred for vitreoretinal consultation, which resulted in an FA and the decision to observe without treatment on the basis that no CI-DME or PDR was present. She was then lost to follow-up. When seen 12 months later, her VA had dropped to hand motions only, her blood glucose control had worsened, and she had progressed to PDR with DME (**Figure 4C**). She was again referred to a vitreoretina surgeon and was thereafter lost to follow-up.*

This case illustrates that guidelines might be beneficial when applied to populations, but are not always ideally suited to individuals. This patient with very poor blood glucose control progressed from moderate to moderately severe DR within 1 year, and from there to PDR with DME within another year. When she was diagnosed with moderate NPDR, she was



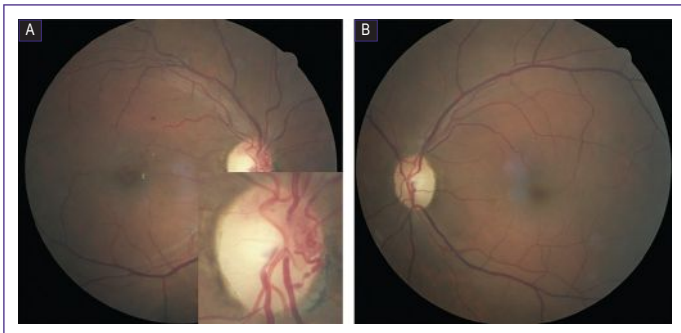
observed closely and reevaluated within 6 months. The AOA guidelines support this approach, although the AAO and ICO guidelines suggest referral to a retina specialist at this stage.<sup>7,15,16</sup> Given the appearance of her retina, the decision not to refer at that time was reasonable. When she developed moderately severe NPDR, she was promptly referred, which is consistent with all 3 guidelines.

Whether or not to treat eyes with moderately severe NPDR without DME is a matter of discretion and should be evaluated on a case-by-case basis by the physician and patient. The PANORAMA study included patients such as this one and showed a benefit to treatment with aflibercept 2 mg dosed either every 8 or 16 weeks, but the results of the trial were not available at the time this patient was seen. Close observation is a reasonable plan so long as the patient is adherent with follow-up. Unfortunately, in this case, she was lost to follow-up during the critical period when she progressed to PDR.

## CASE 2: PROLIFERATIVE RETINOPATHY

From the Files of Diana L. Shechtman, OD, FAAO

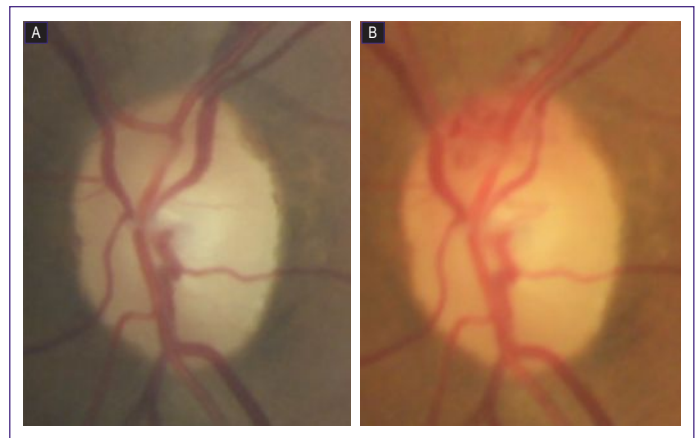
A 68-year-old male with a 10-year history of diabetes presented with a complaint of reduced vision in the right eye for several months. His HbA<sub>1c</sub> was 10%. His BCVA was 20/25 OD and 20/20 OS. **Figure 5** shows his fundus photographs. The right eye had some hemorrhages and hard exudates, and careful inspection of the optic nerve head revealed NVD. The left eye showed only minimal microaneurysms.



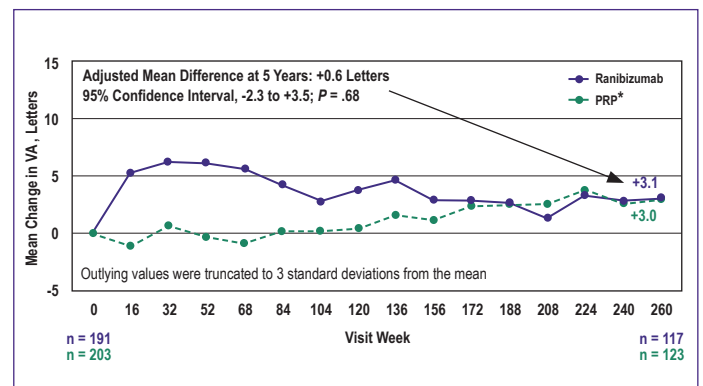
**Figure 5.** Fundus photographs of the patient presented in Case 2: (A) right eye (with magnified view of the optic nerve head inset) and (B) left eye

Because he had PDR in the right eye, the patient underwent PRP during a time in which anti-VEGF therapy was not readily used for PDR. Three months later, his NVD had regressed significantly, but VA was now 20/60 and DME was present, which was possibly aggravated by the PRP. He was then lost to follow-up for 1 year. During this time, he developed NVD in the contralateral eye (**Figure 6**).

Ideally, this patient would have had anti-VEGF therapy and regular follow-up. PRP is the best alternative to anti-VEGF



**Figure 6.** Left optic disc of the patient presented in Case 2 after panretinal photocoagulation (A) and after loss to follow-up for 1 year (B). Superior neovascularization of the disc is noted, which developed during the year following panretinal photocoagulation.



**Figure 7.** Visual acuity outcomes in Diabetic Retinopathy Clinical Research Network's Protocol S comparing ranibizumab with PRP for proliferative diabetic retinopathy<sup>30</sup>

Abbreviations: PRP, panretinal photocoagulation; VA, visual acuity.

\* Note: Among 5-year completers, 71 eyes (58%) received at least 1 study ranibizumab injection for diabetic macular edema through 5 years

Figure adapted from the Diabetic Retinopathy Clinical Research Network public Web Site.

therapy and can provide comparable long-term VA outcomes, according to the 5-year data analysis of DRCR Retina Network's Protocol S (**Figure 7**), but with more adverse events, specifically loss of peripheral visual field and a higher incidence of macular edema.<sup>30</sup> Importantly, 58% of patients in the PRP arm of Protocol S received at least 1 injection of ranibizumab for DME through 5 years, which could have contributed to the mean VA gains seen over time in that group. During the initial 2 years of Protocol S, patients treated with anti-VEGF therapy had superior VA gains, which might be relevant for patients who require good vision for their activities of daily living. It is also worth noting the considerable dropout rate in Protocol S. This speaks to the difficulty patients with diabetes face in adhering to a strict treatment regimen. Unfortunately, this patient was also 1 of the 38% who develop vision-affecting macular edema after PRP.

Both this case and Case 1 demonstrate the detrimental effects that nonadherence with follow-up can produce. Educating patients on the severity of their disease and their risk of vision loss is the first step to ensuring follow-up adherence. Imaging—either fundus photography or OCT—can be a helpful way to show patients exactly how their diabetes is affecting their eyes. This can encourage adherence with both systemic diabetes therapy and with follow-up for eye care. For a patient with moderately severe or severe NPDR in whom follow-up is strongly suspected to be an issue—either due to employment constraints or other reasons—both PRP and anti-VEGF therapy might be considered. The PROTEUS trial demonstrated that combination treatment produced high regression rates. Anti-VEGF injections might be started with the expectation of follow-up. PRP in the case of nonadherence with follow-up—perhaps a light treatment—coupled with the anti-VEGF drug would be effective while minimizing the complications of PRP.

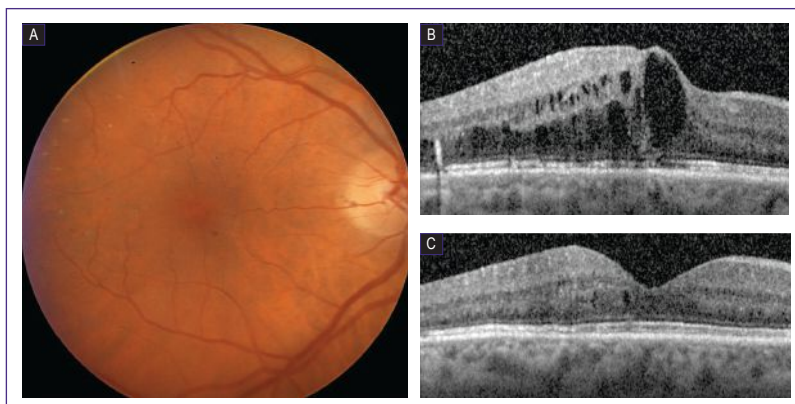
### CASE 3: CENTER-INVOLVED DIABETIC MACULAR EDEMA

*From the Files of Charles C. Wykoff, MD, PhD*

*A 75-year-old female with a long history of type 2 diabetes presented with decreased vision in the right eye. Evaluation revealed VA of 20/160, and OCT revealed significant CI-DME in the affected eye (Figures 8A and 8B). After a series of anti-VEGF injections given over a 3-year period, her VA improved to 20/25 and her edema, as noted on OCT, appeared to have resolved (Figure 8C).*

DME can take a long time to improve, both in terms of fluid seen and VA gains. It is not uncommon for eyes with DME to take up to a year to maximize their full visual and anatomic potential. Prompt and adequate treatment is important for optimizing long-term outcomes. Treatment delays can limit the amount of VA gained once treatment is initiated, as evidenced by the suboptimal VA improvement seen among patients initially randomized to receive sham or laser treatment in the RIDE/RISE and VIVID/VISTA trials after they ultimately received access to anti-VEGF treatment.<sup>26,28</sup>

Once the macular edema has resolved, the treatment plan is less well defined. DME might or might not recur without treatment. This patient's diabetes has not gone away, and unless she has accomplished a significant improvement in blood control, her DME might recur when therapy is stopped. It is unclear how often anti-VEGF therapy should be repeated in eyes that stabilize with good central VA. The injection rate should be minimized for many reasons, among them, time costs, economic costs, and safety. Although these injections



**Figure 8.** Color fundus photography (A) and spectral domain optical coherence tomography images of the right macula of the patient presented in Case 3, showing significant center-involved diabetic macular edema (B) that resolved with anti-vascular endothelial growth factor therapy (C).

are very safe, sight-threatening complications such as endophthalmitis are possible. In such a case, treatment can be withheld until there is evidence of recurrence of DME or progression of underlying DR even if DME does not recur. Alternatively, a treat-and-extend approach can be helpful, in which the interval between injections can be steadily increased to an interval of every 12 to 16 weeks to maintain stability and minimize the risk of DME recurrence and DR progression.

### TAKE-HOME POINTS

- Diabetic retinopathy is the leading cause of vision loss and blindness among working-aged adults in the United States
- Diabetic retinopathy exists across a spectrum of severity, with nonproliferative DR graded as mild, moderate, moderately severe, and severe; proliferative DR and DME also occur and account for most VA loss
- Patients with type 1 diabetes should have the first eye examination within 5 years of diagnosis and annual examinations thereafter, whereas those with type 2 diabetes should be examined at diagnosis and annually thereafter
- Although most DR lesions occur in the posterior pole, 30% of lesions occur in the periphery and are associated with higher rates of progression to PDR; widefield and ultrawidefield photography coupled with angiography can help identify these high-risk eyes
- Both DR and DME contribute to reductions in VA and quality of life
- Anti-VEGF therapy leads to resolution of DME and regression of DR, thus improving both VA and quality of life
- Delayed treatment of DME and DR limits the benefits of therapy; prompt identification and referral are critical for therapeutic success

Complete the CE Post Test online at  
<https://tinyurl.com/preservevision>

## REFERENCES

- Centers for Disease Control and Prevention. *National Diabetes Statistics Report, 2017*. Atlanta, GA: Centers for Disease Control and Prevention; 2017.
- Rowley WR, Bezold C, Arian Y, Byrne E, Krohe S. Diabetes 2030: insights from yesterday, today, and future trends. *Popul Health Manag*. 2017;20(1):6-12.
- Centers for Disease Control and Prevention. Vision Health Initiative (VHI). Common eye disorders. <https://www.cdc.gov/visionhealth/basics/ced/index.html>. Reviewed September 29, 2015. Accessed October 22, 2019.
- Mazhar K, Varma R, Chouhury F, McKean-Cowdin R, Shtir CJ, Azen SP; Los Angeles Latino Eye Study Group. Severity of diabetic retinopathy and health-related quality of life: the Los Angeles Latino Eye Study. *Ophthalmology*. 2011;118(4):649-655.
- Wykoff CC. Intravitreal aflibercept for moderately severe to severe non-proliferative diabetic retinopathy (NPDR): the phase 3 PANORAMA study. Abstract presented at: Angiogenesis, Exudation, and Degeneration 2019; February 9, 2019; Miami, FL.
- Fowler MJ. Microvascular and macrovascular complications of diabetes. *Clin Diabetes*. 2008;26(2):77-82.
- American Optometric Association. *Eye Care of the Patient With Diabetes Mellitus*. 2nd ed. St Louis, MO: American Optometric Association; 2019.
- Scanlon PH, Aldington SJ, Stratton IM. Epidemiological issues in diabetic retinopathy. *Middle East Afr J Ophthalmol*. 2013;20(4):293-300.
- Zhu Z, Zhang F, Liu Y, et al. Relationship of obstructive sleep apnoea with diabetic retinopathy: a meta-analysis. *Biomed Res Int*. 2017;2017:4737064.
- Klein R, Knudtson MD, Lee KE, Gangnon R, Klein BE. The Wisconsin Epidemiologic Study of Diabetic Retinopathy XXII: the twenty-five-year progression of retinopathy in persons with type 1 diabetes. *Ophthalmology*. 2008;115(11):1859-1868.
- Centers for Disease Control and Prevention. Public health focus: prevention of blindness associated with diabetic retinopathy. *MMWR*. 1993;42(10):191-195.
- The relationship of glycemic exposure (HbA1c) to the risk of development and progression of retinopathy in the Diabetes Control and Complications Trial. *Diabetes*. 1995;44(8):968-983.
- UK Prospective Diabetes Study (UKPDS) Group. Intensive blood-glucose control with sulphonylureas or insulin compared with conventional treatment and risk of complications in patients with type 2 diabetes (UKPDS 33). *Lancet*. 1998;352(9131):837-853.
- Nathan DM, Genuth S, Lachin J, et al; Diabetes Control and Complications Trial Research Group. The effect of intensive treatment of diabetes on the development and progression of long-term complications in insulin-dependent diabetes mellitus. *N Engl J Med*. 1993;329(14):977-986.
- Wong TY, Sun J, Kawasaki R, et al. Guidelines on diabetic eye care: the International Council of Ophthalmology recommendations for screening, follow-up, referral, and treatment based on resource settings. *Ophthalmology*. 2018;125(10):1608-1622.
- Retina/Vitreous Preferred Practice Pattern® Panel. *Preferred Practice Pattern®. Diabetic Retinopathy*. San Francisco, CA: American Academy of Ophthalmology; 2017.
- Early Treatment Diabetic Retinopathy Study Research Group. Fundus photographic risk factors for progression of diabetic retinopathy. ETDRS report number 12. *Ophthalmology*. 1991;98(5) (suppl):823-833.
- Bandello F, Lattanzio R, Zucchiatti I, Del Turco C. Pathophysiology and treatment of diabetic retinopathy. *Acta Diabetol*. 2013;50(1):1-20.
- Cai J, Boulton M. The pathogenesis of diabetic retinopathy: old concepts and new questions. *Eye*. 2002;16(3):242-260.
- Klein R, Klein BE, Moss SE, Davis MD, DeMets DL. The Wisconsin epidemiologic study of diabetic retinopathy. IV. Diabetic macular edema. *Ophthalmology*. 1984;91(12):1464-1474.
- Choudhry N, Duker JS, Freund KB, et al. Classification and guidelines for widefield imaging: recommendations from the International Widefield Imaging Study Group. *Ophthalmol Retina*. 2019;3(10):843-849.
- Silva PS, Cavallerano JD, Sun JK, Soliman AZ, Aiello LM, Aiello LP. Peripheral lesions identified by mydriatic ultrawide field imaging: distribution and potential impact on diabetic retinopathy severity. *Ophthalmology*. 2013;120(12):2587-2595.
- Silva PS, Cavallerano JD, Haddad NM, et al. Peripheral lesions identified on ultrawide field imaging predict increased risk of diabetic retinopathy progression over 4 years. *Ophthalmology*. 2015;122(5):949-956.
- Aiello LP, Oda I, Glassman AR, et al; Diabetic Retinopathy Clinical Research Network. Comparison of Early Treatment Diabetic Retinopathy Study standard 7-field imaging with ultrawide-field imaging for determining severity of diabetic retinopathy. *JAMA Ophthalmol*. 2019;137(1):65-73.
- Nicholson L, Ramu J, Chan EW, et al. Retinal nonperfusion characteristics on ultra-widefield angiography in eyes with severe nonproliferative diabetic retinopathy and proliferative diabetic retinopathy. *JAMA Ophthalmol*. 2019;137(6):626-631.
- Heier JS, Korobelnik JF, Brown DM, et al. Intravitreal aflibercept for diabetic macular edema: 148-week results from the VISTA and VIVID studies. *Ophthalmology*. 2016;123(11):2376-2385.
- Kass MA, Heuer DK, Higginbotham EJ, et al. The Ocular Hypertension Treatment Study: a randomized trial determines that topical ocular hypotensive medication delays or prevents the onset of primary open-angle glaucoma. *Arch Ophthalmol*. 2002;120(6):701-713.
- Brown DM, Nguyen QD, Marcus DM, et al; RIDE and RISE Research Group. Long-term outcomes of ranibizumab therapy for diabetic macular edema: the 36-month results from two phase III trials: RISE and RIDE. *Ophthalmology*. 2013;120(10):2013-2022.
- Reddy SV, Husain D. Panretinal photocoagulation: a review of complications. *Semin Ophthalmol*. 2018;33(1):83-88.
- Gross JG, Glassman AR, Liu D, et al; Diabetic Retinopathy Clinical Research Network. Five-year outcomes of panretinal photocoagulation vs intravitreal ranibizumab for proliferative diabetic retinopathy: a randomized clinical trial. *JAMA Ophthalmol*. 2018;136(10):1138-1148.
- Figueira J, Fletcher E, Massin P, et al; EVICR.net Study Group. Ranibizumab plus panretinal photocoagulation versus panretinal photocoagulation alone for high-risk proliferative diabetic retinopathy (PROTEUS study). *Ophthalmology*. 2018;125(5):691-700.
- Wells JA, Glassman AR, Ayala AR, et al; Diabetic Retinopathy Clinical Research Network. Aflibercept, bevacizumab, or ranibizumab for diabetic macular edema: two-year results from a comparative effectiveness randomized clinical trial. *Ophthalmology*. 2016;123(6):1351-1359.
- Bressler SB, Liu D, Glassman AR, et al; Diabetic Retinopathy Clinical Research Network. Change in diabetic retinopathy through 2 years: secondary analysis of a randomized clinical trial comparing aflibercept, bevacizumab, and ranibizumab. *JAMA Ophthalmol*. 2017;135(6):558-568.
- Diabetic Retinopathy Clinical Research Network. Treatment for center-involved diabetic macular edema in eyes with good visual acuity (Protocol V). [http://publicfiles.jaeb.org/drcrnet/v1\\_finalset\\_5\\_23\\_19.pptx](http://publicfiles.jaeb.org/drcrnet/v1_finalset_5_23_19.pptx). Accessed October 23, 2019.



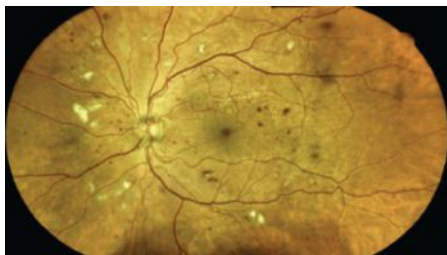
## CE POST TEST QUESTIONS

To obtain COPE CE Credit for this activity, read the material in its entirety and consult referenced sources as necessary.

We offer instant certificate processing and support Green CE. Please take this post test and evaluation online by going to <http://tinyurl.com/preservevision>. Upon passing, you will receive your certificate immediately. You must score 70% or higher to receive credit for this activity, and may take the test up to 2 times.

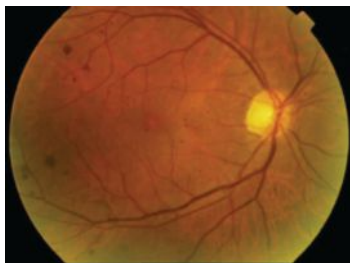
1. A 53-year-old male with diabetes is found to have moderate NPDR with intraretinal hemorrhages that are predominantly peripherally located on widefield fundus photography. Compared with a patient whose lesions are evenly distributed between the posterior pole and peripherally, what is his approximate relative risk of developing PDR?
  - a. 5-fold lower
  - b. 5-fold higher
  - c. 10-fold lower
  - d. 10-fold higher

2. According to the latest AOA, AAO, and ICO guidelines, for the image given below, how would you grade this patient's DR?



- a. Mild NPDR
- b. Moderate NPDR
- c. Severe NPDR
- d. PDR

3. Should the patient in Question 2 be referred to a retina specialist?
  - a. Yes
  - b. No
4. What is the appropriate follow-up interval for the patient whose retinal fundus photograph is shown below?



- a.  $\leq$  3 months
- b. 3 to 6 months
- c. 6 to 12 months
- d. 2 years

5. How much of the retina does widefield imaging capture?
  - a. Posterior pole only
  - b. Posterior 30% of the retina
  - c. 4 quadrants posterior to and including the ampullae of the vortex veins
  - d. Far periphery in all 4 quadrants
6. How much of the retina does ultrawidefield imaging capture?
  - a. Posterior pole only
  - b. Posterior 30% of the retina
  - c. 4 quadrants posterior to and including the ampullae of the vortex veins
  - d. Far periphery in all 4 quadrants

7. A patient with only a few scattered microaneurysms in the posterior pole has a \_\_\_\_\_ stage of DR according to DRSS.
  - a. Mild
  - b. Moderate
  - c. Moderately severe
  - d. Severe

8. Which of the following distinguishes PDR from NPDR?
  - a. Microaneurysms
  - b. Hard exudates
  - c. IRMAs
  - d. Neovascularization

9. What proportion of DR lesions occur in the posterior pole?
  - a. 10%
  - b. 30%
  - c. 50%
  - d. 70%

10. What percentage of eyes are reclassified as having more severe DR when peripheral lesions are considered?
  - a. 5%
  - b. 10%
  - c. 25%
  - d. 60%

11. What additional risk for 4-year progression to PDR is associated with the presence of predominantly peripheral DR lesions?
  - a. 2.1-fold
  - b. 3.2-fold
  - c. 4.6-fold
  - d. 5.8-fold

12. Which patient is least likely to benefit from referral to a retina specialist?
  - a. A patient with DME and BCVA of 20/30
  - b. A patient with moderate NPDR
  - c. A patient with a few scattered microaneurysms
  - d. A patient with a vitreous hemorrhage

13. Which patient should be reevaluated at the shortest follow-up interval?
  - a. A patient with newly diagnosed type 2 diabetes with no retinopathy
  - b. A patient with hemorrhages in 4 quadrants, venous beading in 2 quadrants, and 3 scattered IRMAs
  - c. A patient with DME and BCVA of 20/20
  - d. A patient with a few scattered dot-blot hemorrhages and hard exudates

14. The 4-2-1 rule refers to:
  - a. 4-month follow-up if 2 or more eyes have 1 DR lesion
  - b. 4 monthly injections of 2 mg of aflibercept to achieve a 1-grade improvement in DRSS score
  - c. 4 quadrants of retina hemorrhages with 2 quadrants of venous beading and IRMAs in 1 or more quadrants
  - d. 4 microaneurysms in 2 quadrants with 1 IRMA

15. What is the best first-line approach to preventing VA secondary to diabetes?
  - a. Anti-VEGF therapy
  - b. Laser
  - c. Vitrectomy
  - d. Prevention through effective control of blood glucose levels

16. Which of the following is true regarding anti-VEGF therapy for DR and DME?
  - a. All 3 anti-VEGF agents (aflibercept, ranibizumab, bevacizumab) are US Food and Drug Administration approved for the treatment of DR
  - b. All 3 anti-VEGF agents (aflibercept, ranibizumab, bevacizumab) are US Food and Drug Administration approved for the treatment of DME
  - c. Bevacizumab produces VA gains that are superior to those of either aflibercept or ranibizumab in eyes with DME
  - d. Eyes that are refractory to anti-VEGF therapy might respond to corticosteroid therapy

17. In the PANORAMA study, 15% of eyes receiving sham and \_\_\_\_\_ of eyes receiving aflibercept 2 mg every 8 weeks manifested a  $\geq$  2-step improvement in DR over 52 weeks.
  - a. 35%
  - b. 48%
  - c. 66%
  - d. 80%

18. In the PANORAMA study, treatment of \_\_\_\_\_ with aflibercept resulted in a 70% to 75% reduction in the risk of VTCs, including PDR and CI-DME, compared with sham treatment.
  - a. Mild or moderate NPDR without DME
  - b. Moderately severe or severe NPDR without DME
  - c. PDR
  - d. NPDR with non-CI-DME

19. According to DRCR Retina Network's Protocol V study, which of the following is true regarding CI-DME in eyes with VA of 20/25 or better?
  - a. Immediate laser is best for preventing vision loss
  - b. Immediate anti-VEGF therapy is best for preventing vision loss
  - c. Combination therapy with anti-VEGF drugs and laser is best for preventing vision loss
  - d. Close observation is reasonable, with treatment initiated if VA worsens

20. The DRCR Retina Network's Protocol S compared anti-VEGF therapy with PRP in eyes with PDR. What were the study's key findings?
  - a. Comparable VA and safety between groups
  - b. Worse VA outcomes and more adverse events with PRP vs anti-VEGF therapy
  - c. Comparable VA outcomes and more visual field loss with PRP
  - d. Comparable VA outcomes and more macular edema with anti-VEGF therapy