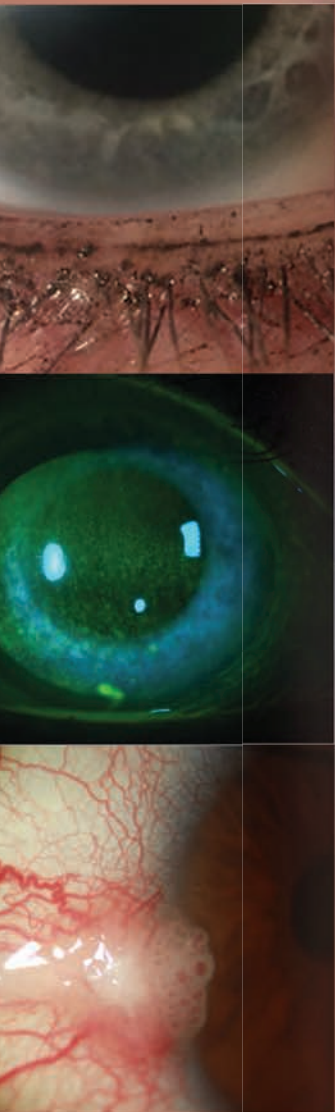


The Neuroimaging Dilemma: Should You Scan All Oculomotor Defect Patients?, p.30

# REVIEW<sup>®</sup> OF OPTOMETRY

November 15, 2018

[www.reviewofoptometry.com](http://www.reviewofoptometry.com)



Lids

Cornea

Conjunctiva

## OCULAR SURFACE HEALTH

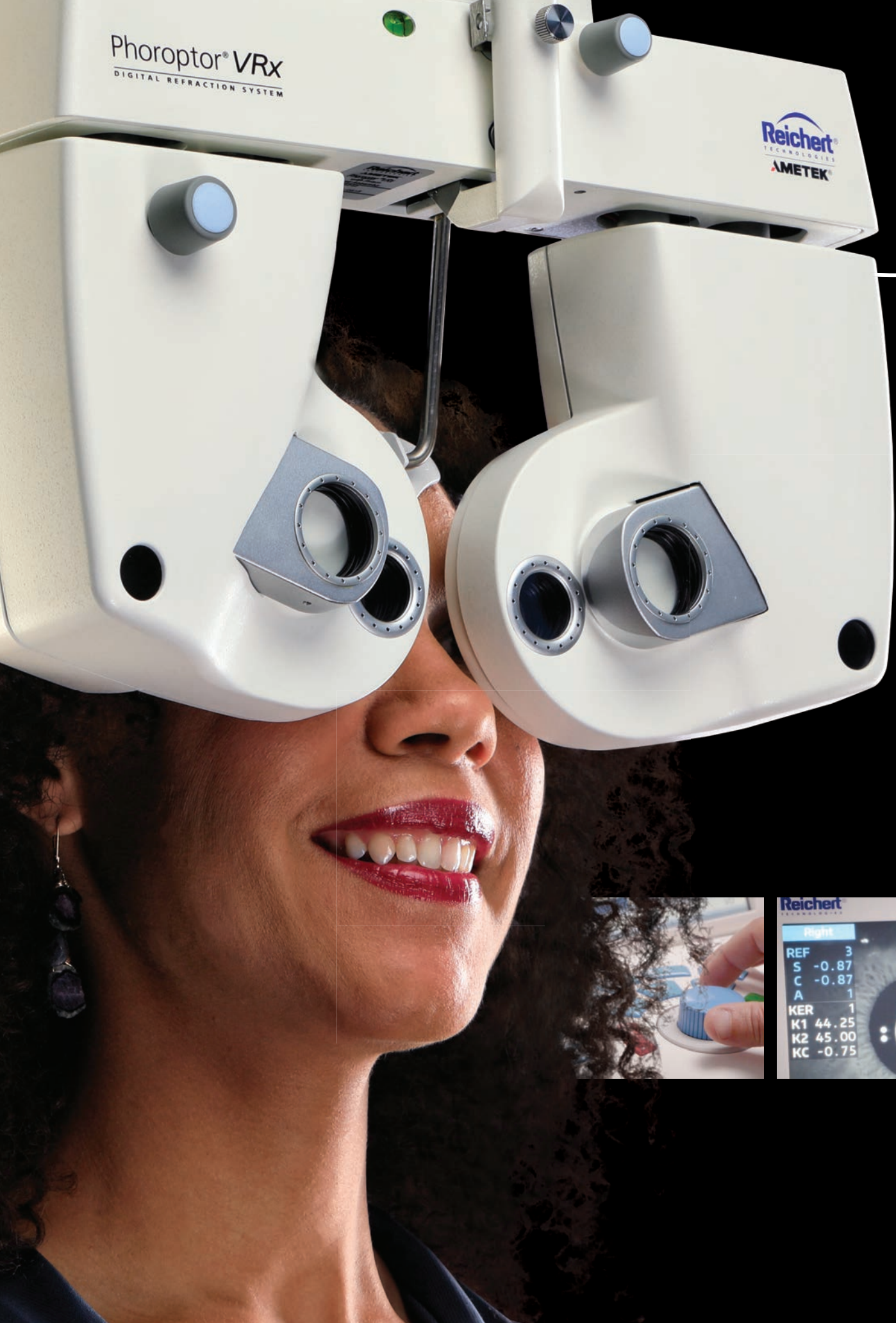- How to Evaluate the Lid and Ocular Surface, p. 34
  - Point-of-care Tools for Dry Eye, p. 42
- Master the Maze of Artificial Tears, p. 48
  - Simple Strategies for Dry Eye, p. 58
  - Comorbidities of Dry Eye, p. 67

**ALSO:** The Dilated Exam in the Age of Ultra-widefield Imaging, p. 76




Phoroptor® VRx  
DIGITAL REFRACTION SYSTEM

Reichert®  
TECHNOLOGIES  
AMETEK



Reichert  
TECHNOLOGIES

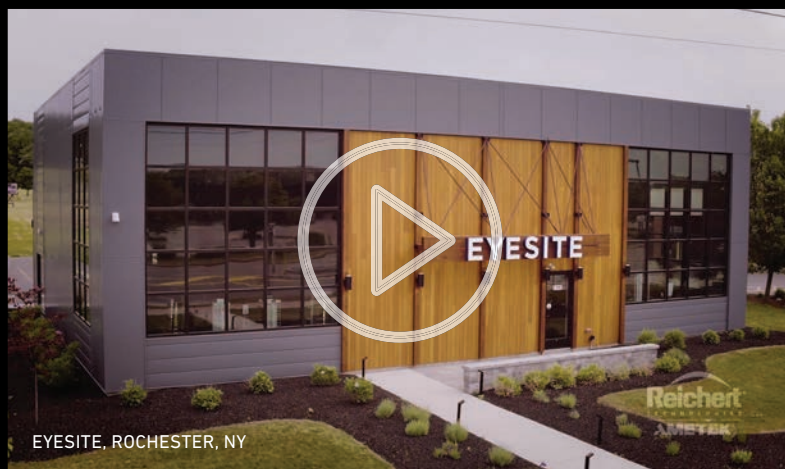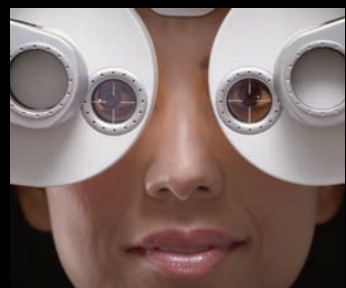Right	
REF	3
S	-0.87
C	-0.87
A	1
KER	1
K1	44.25
K2	45.00
KC	-0.75



# Passionate About Eye Care!

We share your **passion for patient experience** with our complete line of digital refraction devices, featuring the most advanced Phoroptor® ever, **Phoroptor® VRx**, and our pixel-perfect **ClearChart® 4** family of digital acuity systems.

**INTRODUCING OUR 'PASSIONATE ABOUT EYE CARE VIDEO SERIES':  
WATCH AT REICHERT.COM/PASSIONATE**



EYESITE, ROCHESTER, NY



reichert.com

## IN THE NEWS

Researchers found an independent association between **obstructive sleep apnea** (OSA) and both hypertension and Type 2 diabetes—and the retinopathy associated with each is also associated with OSA, suggesting that patients with **diabetic retinopathy or retinopathy of hypertension** could also be experiencing OSA without even realizing it. Evidence also suggests a link between OSA and two other ocular conditions: central serous retinopathy and nonarteritic anterior ischemic optic neuropathy.

Wong B, Fraser C. Obstructive sleep apnea in neuro-ophthalmology. *J Neuro-Ophthalmol*. October 8, 2018. [ePub ahead of print].

**People of Arabic ethnicity have a high rate of keratoconus (KC)**, and a new study found the highest levels yet documented. Saudi researchers enrolled 522 pediatric patients in a prospective study that noted a KC prevalence of 4.79%, or a ratio of 1:21 patients. These results showed a 95-fold increase in prevalence vs. earlier studies. Prior to this latest study, the highest rate reported was 3.30% (approximately one in 30 patients) in a Lebanese population. Another study, conducted in Israel, found a KC prevalence of 3.18%.

Torres Netto EA, Al-Otaibi WM, Hafezi NL, et al. Prevalence of keratoconus in pediatric patients in Riyadh, Saudi Arabia. *Br J Ophthalmol*. 2018 Oct;102(10):1436-41.

Eyes with **tilted disc syndrome (TDS)** are likely to experience a **superotemporal shifting of the line of sight**, according analysis of 80 subjects with TDS and 70 controls. The investigators say the shift must be accounted for to prevent decentralization and provide satisfactory outcomes for refractive and multifocal intraocular lens implantation.

Kosekahya P, Sarac O, Koc M, Caglayan M, Hondur G, Cagil N. Shifting of the line of sight in tilted disc syndrome. *Eye & Contact Lens* 2018;44: S33-S36.

# Oklahoma Rejects Big Box Eye Care

ODs were thrilled to see a controversial ballot initiative voted down. **By Bill Kekevia, Senior Editor**

**A**mong the recent election night's fervor, as Americans in red or blue hats rode the ups and downs of the political tide, optometrists in Oklahoma were celebrating a vote of their own—not one of an elected representative, but rather a state ballot question strung together by retailers that could have changed eye care as Oklahomans know it.

The proposal, State Question 793, would have stripped the state's board of the power to dictate what constitutes a comprehensive eye exam, say doctors from the state. Optometric and other medical groups opposing the move eked out a victory when voters rejected it by a mere 5,589 votes, according to [newsok.com](http://newsok.com).

“An extremely close result, but in the end, the hard work by the Oklahoma Association of Optometric Physicians, our doctors, and our friends and colleagues from across the nation delivered the result we were hoping for,” says Oklahoman Nathan Lighthizer, OD, a prominent advocate for the advancement of optometric scope of practice.

The proposal was backed by a committee that included Walmart, a retailer that has clashed with optometrists in the state before

in unsuccessful attempts to bring optometric services into its stores. Oklahoma has a strict “two-door” policy that requires companies to entirely separate doctors from their stores.

In addition to overriding the state's board of optometry, the text of the question reads that the measure “does not prohibit optometrists and opticians from agreeing with retail mercantile establishments to limit their practice.”

This passage, Oklahoma optometrists feared, could establish a protocol by which patients receive refractive exams without undergoing a clinical exam. While Walmart has denied that accusation, the company did confirm that their doctors would not perform some of the surgical procedures that other optometrists in the state can provide under Oklahoma's broad scope-of-practice laws.

“The citizens of Oklahoma said no to an out-of-state corporation trying to change our state constitution to benefit their business model,” explains Dr. Lighthizer. He attributes the victory to optometrists communicating their concerns directly with patients as well as the efforts of the OAOP.

NEWS STORIES POST EVERY WEEKDAY MORNING AT [www.reviewofoptometry.com/news](http://www.reviewofoptometry.com/news)



# THE JOURNEY TO **IMPROVED VISION** STARTS WITH *YOU*

Successful cataract surgery often depends on strong collaboration between patients, optometrists, and surgeons. **Alcon is here to support YOU** in building those partnerships.

## Alcon Surgical Offerings

- The AcrySof® family of IOLs has been implanted over **100 MILLION TIMES**<sup>1</sup> – more than any other brand – and provides exceptional quality, clarity, and stability.<sup>2-4</sup>
- Our full range of products helps you meet each individual's needs, including astigmatic and presbyopic patients.
- We provide resources to support collaborative care between the optometrist and ophthalmologist.

Visit [myalcon.com/cataractresources](https://myalcon.com/cataractresources) to order resources for your patients and your practice.

**Alcon** A Novartis  
Division

 AcrySof® IQ IOL Family

**References:** 1. Alcon sales data on file. 2. Wirtitsch MG, Findl O, Menapace R, et al. Effect of haptic design on change in axial position after cataract surgery. *J Cataract Refract Surg.* 2004;30(1):45-51. 3. Visser N, Bauer NJ, Nuijts RM. Toric intraocular lenses: Historical overview, patient selection, IOL calculation, surgical techniques, clinical outcomes, and complications. *J Cataract Refract Surg.* 2013;39(4):624-637. 4. Potvin R, Kramer BA, Hardten DR, Berdahl JP. Toric intraocular lens orientation and residual refractive astigmatism: An analysis. *Clin Ophthalmol.* 2016;10:1829-1836.

© 2018 Novartis 04/18 US-ODE-18-E-0547a

## AcrySof® Family of Single-Piece IOLs Important Product Information

(AcrySof® UV, AcrySof® IQ, AcrySof® IQ Toric, AcrySof® IQ ReSTOR®, and AcrySof® IQ ReSTOR® Toric IOLs)

**CAUTION:** Federal law restricts these devices to sale by or on the order of a physician. **INDICATION:**

The family of AcrySof® single-piece intraocular lenses (IOLs) includes AcrySof® UV-absorbing IOLs ("AcrySof® UV"), AcrySof® IQ, AcrySof® IQ Toric and AcrySof® IQ ReSTOR® and AcrySof® IQ ReSTOR® Toric IOLs. Each of these IOLs is indicated for visual correction of aphakia in adult patients following cataract surgery. In addition, the AcrySof Toric IOLs are indicated to correct pre-existing corneal astigmatism at the time of cataract surgery. The AcrySof IQ ReSTOR IOLs are for cataract patients with or without presbyopia, who desire increased spectacle independence with a multifocal vision. All of these IOLs are intended for placement in the capsular bag. **WARNINGS/PRECAUTIONS:**

### General cautions for all AcrySof® and AcrySof® UV IOLs:

Careful preoperative evaluation and sound clinical judgment should be used by the surgeon to decide the risk/benefit ratio before implanting any IOL in a patient with any of the conditions described in the Directions for Use that accompany each IOL. Caution should be used prior to lens encapsulation to avoid lens decentration or dislocation. Viscoelastic should be removed from the eye at the close of surgery. **Additional Cautions associated with AcrySof® IQ ReSTOR® IOLs:**

Some patients may experience visual disturbances and/or discomfort due to multifocality, especially under dim light conditions. A reduction in contrast sensitivity may occur in low light conditions. Visual symptoms may be significant enough that the patient will request explant of the multifocal IOL. Spectacle independence rates vary with all multifocal IOLs; as such, some patients may need glasses when reading small print or looking at small objects. Clinical studies indicate that posterior capsule opacification (PCO), when present, may develop earlier into clinically significant PCO with multifocal IOLs. **Additional Cautions associated with AcrySof® IQ Toric, AcrySof® UV Toric and ReSTOR® Toric IOLs:**

Optical theory suggests that, high astigmatic patients (i.e. > 2.5 D) may experience spatial distortions. Possible toric IOL related factors may include residual cylindrical error or axis misalignments. Toric IOLs should not be implanted if the posterior capsule is ruptured, if the zonules are damaged, or if a primary posterior capsulotomy is planned. Rotation can reduce astigmatic correction; if necessary lens repositioning should occur as early as possible prior to lens encapsulation. Prior to surgery, physicians should provide prospective patients with a copy of the appropriate Patient Information Brochure available from Alcon informing them of possible risks and benefits associated with the AcrySof® IQ Toric, AcrySof® IQ ReSTOR® and AcrySof® IQ ReSTOR® Toric IOLs. Do not resterilize. Do not store at temperatures over 45° C. Use only sterile irrigating solutions to rinse or soak IOLs.

**ATTENTION:** Refer to the Directions for Use labeling for the specific IOL for a complete list of indications, warnings and precautions.



AcrySof® IQ IOL Family

**Alcon** A Novartis  
Division

## ‘Big Data’ Anticipates Myopia Disease Course

*Refraction at age 18 could be predicted as early as age 10.*

Researchers in Guangzhou, China have used large-scale data analysis from electronic health records to develop an algorithm that can predict high myopia onset among Chinese school-aged children with clinically acceptable accuracy. They trained and validated the algorithm using a large real-world dataset.

This study analyzed 687,063 longitudinal electronic medical records from the largest ophthalmic centers in China, and developed and validated individualized prediction models for myopia prediction based on machine learning techniques. Researchers believe that their algorithm can predict spherical equivalent and onset of high myopia at 18 years of age at a clinically acceptable accuracy as early as 10 years old. However, the accuracy of

the prediction is reduced when the targeted prediction time increases. Still, the 95% predicted diopter of refraction was within 0.5D to 0.8D of the true value at eight years.

Large-scale, long-term electronic medical records and machine learning algorithms provide unique opportunities for the development of prediction models for progressive diseases. School-age myopia is the most prevalent eye disease in the Chinese population and the researchers note that their work can help change current approaches used to manage school myopia by pediatric and general ophthalmologists as well as general practitioners and optometrists, who are often the first point of care.

Lin H, Long E, Ding X, et al. Prediction of myopia development among Chinese school-aged children using refraction data from electronic medical records: A retrospective, multicentre machine learning study. PLOS Medicine. November 6, 2018. [Epub ahead of print].

## FDA Updates CyPass Protocol

Periodically evaluate patients implanted with the CyPass (Alcon) stent for potential endothelial cell loss, says advice issued by the FDA. Specifically, look at endothelial cell density using specular microscopy until the rate of loss stabilizes.

Alcon voluntarily withdrew the product in August after it was connected to potential eye damage. The company became aware of the issue when a five-year study's results showed statistically significant endothelial cell loss in patient's who received the device, which is

implanted during cataract surgery, compared with patients who underwent cataract surgery alone.

"Eye care providers should evaluate all patients with CyPass to assess device positioning by visualization of the number of retention rings visible on the proximal end of the device. Patients with two or more rings visible upon examination should be evaluated for endothelial cell loss as soon as possible," the FDA's statement notes. Surgeons have also been advised to discontinue implanting the device and return it to the company.



# Technology in balance



Health



Vision




Comfort

---

Miru 1 month: a unique family of silicone hydrogel monthly lenses.

---

MeniSilk™ and Nanogloss™ technologies designed to meet the demands of today's contact lens wearer.\*



## Material and surface technologies

### MeniSilk™

- Ultra high Dk/t - 161 @ -3.00D
- Exceptional hydration
- Optimized transparency

### Nanogloss™

- Super smooth surface
- Resistance to bacteria
- Excellent wettability



www.meniconamerica.com

\*Menicon data on file April 2016



## More Evidence Links OPP to POAG

The complex pressure gradients in the eye are easily disrupted, potentially predisposing a patient to primary open-angle glaucoma (POAG). Low systolic ocular perfusion pressure (SOPP) may be associated with the condition, and this association may be secondary to low systolic blood pressure (SBP) and high intraocular pressure (IOP), according to a new study published in the *British Journal of Ophthalmology*.

Researchers in Singapore investigated the relationship between POAG and ocular perfusion pressure (OPP), blood pressure (BP), and IOP profiles in this population-based sample of nearly 10,000 Asian individuals from three ethnic groups in Singapore: Malays, Indians and Chinese. Participants were recruited from the Singapore Epidemiology of Eye Diseases Study and underwent standardized ocular and systemic examinations.

The study enrolled 9,877 participants (19,587 eyes), including 213 POAG cases (293 eyes). Researchers found eyes with the lowest levels of systolic OPP (<110mm Hg) were 1.85x more likely to have POAG compared with eyes with mid-range levels (123-137mm Hg). Investigators consistently found the lowest quartile of systolic BP (<12 mm Hg) was 1.69x more likely to have POAG compared with mid-range SBP levels (138-153mm Hg). Also, researchers noted the effect of lower SBP on POAG was more pronounced in eyes with IOP  $\geq$ 21mm Hg.

In contrast with previous studies, mean ocular perfusion pressure and diastolic OPP were not associated with glaucoma after adjusting for relevant confounders and IOP, researchers said. Investigators also reported both low and high levels of SOPP were associated with POAG compared with mid-range

SOPP levels, suggesting a “U-shaped” association between SOPP and POAG. “Third, low SBP was also associated with POAG and this effect was especially more pronounced among eyes with ocular hypertension, further indicating that identification of concurrent low SBP and ocular hypertension may also be a useful approach in stratifying POAG risk group,” the researchers wrote in their paper.

They concluded, “To date, this is the first population-based study which comprehensively demonstrated that the effect of OPP surrogates on POAG was in part secondary to either high IOP or low SBP. Our findings collectively provided additional clarity on the roles of OPP surrogates and BP profiles in POAG.”

Tham YC, Lim SH, Gupta P, et al. Inter-relationship between ocular perfusion pressure, blood pressure, intraocular pressure profiles and primary open-angle glaucoma: the Singapore Epidemiology of Eye Diseases study. *Br J Ophthalmol*. 2018 Oct;102(10):1402-06.

## Small-particle Air Pollution May Increase IOP

Ambient black carbon exposure may be a risk factor for increased intraocular pressure (IOP) in individuals susceptible to other biological oxidative stressors. The results of a recent study may point to the potential need to broaden the factors considered when evaluating and managing elevated IOP.

Researchers investigated the association of long-term ambient black carbon (a byproduct of combustion processes) exposure with intraocular pressure in community-dwelling older adults. The effort used data from the Normative Aging Study of the US Department of Veterans Affairs, an analysis that included 419 older men based in New England with a total of 911 follow-up visits. Of those exams, 57.1% had a high endothelial function allelic risk score, 70.7% had a high metal-processing allelic risk score and 68.4% had a high oxidative stress allelic risk score.

They found the association of black carbon with IOP was greater in individuals with a high oxidative stress allelic score. When patients with high or low oxidative stress allelic risk scores were compared, the study detected a moderate difference in mean IOP (0.73mm Hg) for an increase in one year of black carbon exposure.

The team is interested in whether their findings persist in more diverse populations experiencing greater pollution and in study designs that can demonstrate causality. If future studies substantiate their association, integrated initiatives—combining environmental improvement, socioeconomic outreach and targeted pharmaceutical interventions—may prove useful for future policy or public health initiatives aimed at addressing eye disease.

Nwanaji-Enwerem JC, Wang W, Nwanaji-Enwerem O, et al. Association of long-term ambient black carbon exposure and oxidative stress allelic variants with intraocular pressure in older men. *JAMA Ophthalmol*. November 8, 2018. [Epub ahead of print].





**LET'S TAKE THE LONG VIEW TOGETHER.**

## **The trail is clear.**

Weaving along Hawaii's Na Pali Coast is the breathtaking Kalalau Trail. The trail is demanding...but in the end, its beauty is worth every step. Kalalau was early inspiration for us, today representing our innovative spirit and deep commitment to advancing the treatment of eye diseases. This is the journey we're all on at Kala and the one we can take together.

## **The technology in sight.**

Our proprietary and barrier-breaking **AMPPLIFY™** Drug Delivery Technology is designed to help us keep improving what's possible for eye care.

## **The vista awaits us.**

Visit [kalarx.com](http://kalarx.com) and let's get our journey underway.

**kala**   
PHARMACEUTICALS

© 2018 Kala Pharmaceuticals  
All rights reserved. AMPPLIFY™ is a trademark of Kala Pharmaceuticals. Printed in the USA.  
US-INV-1800002 August 2018



## Post-Cataract Pain Masquerades as Dry Eye

If a patient complains of nagging dry eye symptoms months after cataract surgery, their real diagnosis could be persistent postsurgical pain (PPP), a new study suggests.

A group of Miami researchers found PPP in the form of persistent dry eye–like symptoms was present in approximately 34% of individuals six months after cataract surgery. Additionally, the study found the frequency of PPP after cataract surgery mirrored other post-procedure periods, including laser refractive surgery, dental implants and genitourinary procedures, which suggests cataract surgery could be classified as a medium-risk procedure.

Since the cornea is among the most densely innervated tissues in the body, investigators sought to find out whether PPP occurred after ocular procedures. Researchers conducted phone interviews with 119 individuals who had cataract surgery performed by a single surgeon at the Bascom Palmer Eye Institute. Investigators did the interviews six months following the surgery and placed the participants in two groups: patients with postsurgical pain who had a Dry Eye Question-

naire Five (DEQ-5) score greater than six and those without PPP with a DEQ-5 score of less than six, half a year following the procedure. The average age of the participants was 73.

Based on the results of the DEQ-5, 41 individuals reported having PPP (34%) and 78 individuals reported having no symptoms. Researchers noted the frequency of severe PPP was 18% (22 people).

Investigators found most medical comorbidities and medications were not associated with an increased risk of PPP. However, they found individuals with an autoimmune disease such as rheumatoid arthritis, systemic lupus, Sjögren's, polymyalgia rheumatica or multiple sclerosis had an increased risk of PPP. Patients who had pain disorders—headache, migraine, lower back pain or fibromyalgia—were also more prone to PPP. And for those patients who had dry eye issues before cataract surgery, their risk also increased.

Patients at a greater risk of PPP were female, had an autoimmune or non-ocular chronic pain disorder or used antihistamines, anti-reflux medication, antidepressants or anti-

insomnia medications. PPP patients also reported more frequent use of artificial tears, higher ocular pain levels and greater neuropathic ocular pain symptoms, specifically burning, wind sensitivity and light sensitivity.

“Dry eye symptoms are classically believed to arise because of a disturbance in either the tear film or the orbital structures that give rise to or interact with the tear film, but recent consensus has highlighted a concomitant role of neurogenic stress and ocular surface inflammation,” the researchers wrote in their paper. “Dense innervation of the cornea and the known corneal nerve injury that occurs at a surgical incision likely form the backdrop for the development of PPP after cataract surgery.”

Symptom management after cataract surgery may focus on minimizing ocular surface nerve damage by careful surgical dissection, pre-surgical treatment of modifiable comorbid risk factors like anxiety, and perioperative pain control, the study noted.

Sajjani R, Raia S, Gibbons A, et al. Epidemiology of persistent postsurgical pain manifesting as dry eye-like symptoms after cataract surgery. *Cornea*. 2018 Dec;37(12):1535-41.

## Iron Supplements Linked to Retinal Hemorrhage

Non-anemic patients with neovascular age-related macular degeneration (AMD) who take oral iron supplements may be at risk of retinal/subretinal hemorrhage. Particularly among those with hypertension, the association was dose-dependent.

A recent study investigated the association among participants in the Comparison of AMD Treatments trial, a multicenter study of anti-

VEGF treatments for neovascular AMD. Among 1,165 participants, baseline retinal/subretinal hemorrhage was present in the study eye in 71% of 181 iron users and in 61% of 984 participants without iron use. The significant association was strongest among those taking an iron dose of 18mg to 36mg. The association also remained significant among hypertensive participants without anemia.

In AMD patients, iron supplements may interact with genetics to damage vascular endothelial cells, the authors propose. Researchers believe further investigations should help elucidate the mechanisms of iron and complement dysregulation in retinal pigment epithelium and retinal vascular endothelial cells.

Song, D, Ying GS, Dunaief JL, et al. Association between oral iron supplementation and retinal or subretinal hemorrhage in the comparison of age-related macular degeneration treatments trials. *Retina*. August 28, 2018. [Epub ahead of print].



# The all new Katena.com



## EXPLORE • LEARN • ORDER

All customers establishing a validated account on the new site will receive a Katena Diamond series 90D reusable lens.\*

\*Offer ends 12/31/2018 (one lens per facility per ship to, USA HCPs only. Free lens must be mailed to a practice/facility address)




[www.katena.com](http://www.katena.com)

FROM THE EXPERTS IN LOTE Prednol Etabonate FOR OVER 20 YEARS

# COMING SOON

BAUSCH + LOMB'S NEWEST ARRIVAL



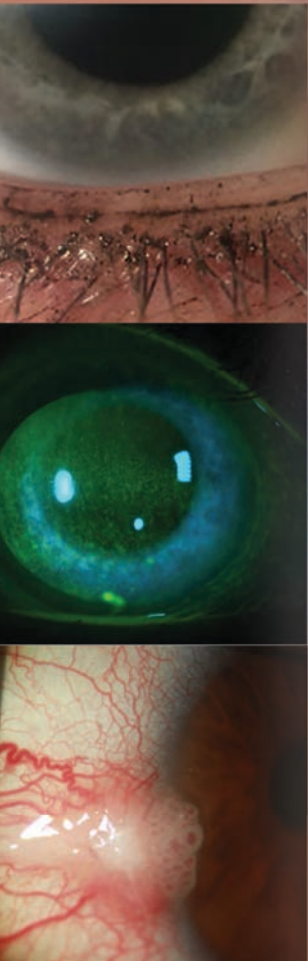
A **NEW** LOTE Prednol Etabonate FORMULATION

# BAUSCH + LOMB



# Contents

Review of Optometry November 15, 2018



## OCULAR SURFACE HEALTH

### 34 Checking Under the Hood: How to Evaluate the Lid and Ocular Surface

*Recognizing minor signs of underlying ocular surface or lid disease requires a thorough evaluation. Here's a guide to a comprehensive exam of the ocular surface.*

BY MARLON J. DEMERITT, OD, AND BEATA I. LEWANDOWSKA, OD

### 42 Familiarize Yourself with Point-of-care Tools for Dry Eye

*A plethora of new tools are rewriting the anterior segment disease monitoring protocol.* BY SUZANNE SHERMAN, OD, AND FIZA SHUJA, OD

### 48 Master the Maze of Artificial Tears

*Having so many choices can be overwhelming, but knowing what each one offers can help you steer patients in the right direction.*

BY MEAGHAN HORTON, OD, MATT HORTON, OD, AND ERIC REINHARD, OD

### 58 Dry Eye Therapy: Keeping it Simple

*Not everything you recommend has to cost a fortune. These low-budget tricks can help patients combat dry eye and stay on budget.*

BY BARBARA CAFFERY, OD, PhD

### 67 Earn 2 CE Credits: Dry Eye Disease: Know Your Comorbidities



*Dry, irritated eyes can be one of the trickiest clinical findings. These systemic associations may be the key.* BY CECELIA KOETTING, OD

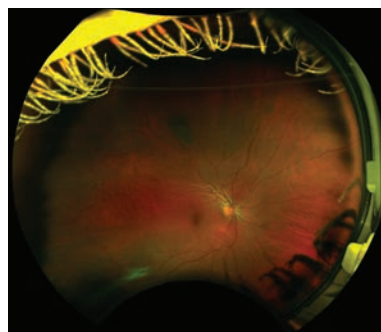
## ALSO INSIDE

### The Dilated Exam in the Age of Ultra-widefield Imaging

*The technology's pros and cons have made it a hot topic in recent years. Here's where it currently stands in clinical practice.*

BY HEIDI WAGNER, OD, MPH

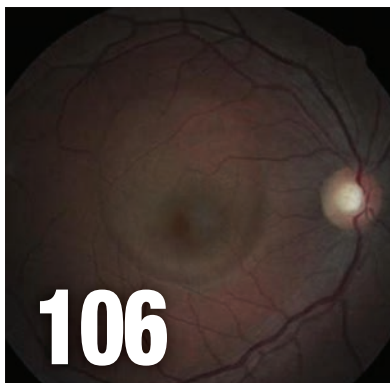
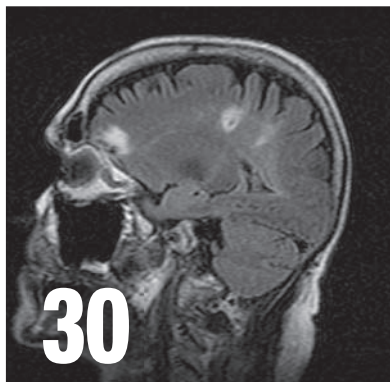
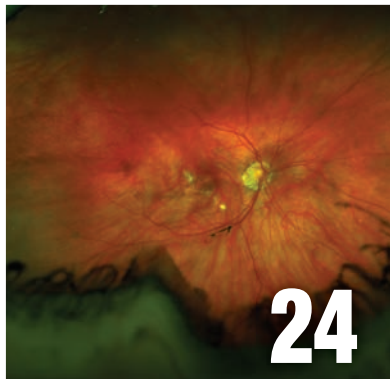
PAGE 76



# Departments

Review of Optometry November 15, 2018

- 4 News Review**
- 18 Outlook**  
The Revolution that Wasn't  
**JACK PERSICO**
- 20 Through My Eyes**  
Hiding in Plain Sight  
**PAUL M. KARPECKI, OD**
- 22 Chairside**  
Wanted: An Eye For Business  
**MONTGOMERY VICKERS, OD**
- 24 Clinical Quandaries**  
Widefield Tech Not a Solo Act  
**PAUL C. AJAMIAN, OD**
- 26 Coding Connection**  
Take on Point-of-care Testing  
**JOHN RUMPAKIS, OD, MBA,**  
**CLINICAL CODING EDITOR**
- 28 The Essentials**  
Why SVP Matters  
**MARC B. TAUB, OD, MS, AND**  
**PAUL HARRIS, OD**
- 30 Neuro Clinic**  
The Neuroimaging Dilemma  
**MICHAEL TROTTINI, OD, AND**  
**MICHAEL DELGIODICE, OD**
- 84 Cornea + Contact Lens Q&A**  
Breaking Down Resistance  
**JOSEPH P. SHOVLIN, OD**
- 87 Ocular Surface Review**  
The Many Methods of MGD  
**PAUL M. KARPECKI, OD**
- 91 Urgent Care**  
Hydrops it Like it's Hot  
**AZINDA MORROW, OD, AND**  
**RICHARD MANGAN, OD**
- 95 Review of Systems**  
ION: Low Pressure, High Risk  
**CARLO J. PELINO, OD, AND**  
**JOSEPH J. PIZZIMENTI, OD**
- 99 Retina Quiz**  
A Hazy, Shaded Vision  
**MARK T. DUNBAR, OD**
- 101 Classifieds**
- 105 Meetings + Conference**
- 105 Advertisers Index**
- 106 Diagnostic Quiz**  
Not Fade Away  
**ANDREW S. GURWOOD, OD**



## REVIEW<sup>®</sup> OF OPTOMETRY

**BUSINESS OFFICES**  
11 CAMPUS BLVD., SUITE 100  
NEWTOWN SQUARE, PA 19073

**CEO, INFORMATION SERVICES GROUP**  
MARC FERRARA  
(212) 274-7062 • MFERRARA@JOBSON.COM

**PUBLISHER**  
JAMES HENNE  
(610) 492-1017 • JHENNE@JOBSON.COM

**REGIONAL SALES MANAGER**  
MICHELE BARRETT  
(610) 492-1014 • MBARRETT@JOBSON.COM

**REGIONAL SALES MANAGER**  
MICHAEL HOSTER  
(610) 492-1028 • MHOSTER@JOBSON.COM

**VICE PRESIDENT, OPERATIONS**  
CASEY FOSTER  
(610) 492-1007 • CFOSTER@JOBSON.COM

**VICE PRESIDENT, CLINICAL CONTENT**  
PAUL M. KARPECKI, OD, FAAO  
PKARPECKI@JOBSON.COM

**PRODUCTION MANAGER**  
SCOTT TOBIN  
(610) 492-1011 • STOBIN@JOBSON.COM

**SENIOR CIRCULATION MANAGER**  
HAMILTON MAHER  
(212) 219-7870 • HMAHER@JHIHEALTH.COM

**CLASSIFIED ADVERTISING**  
(888) 498-1460

**SUBSCRIPTIONS**  
\$56 A YEAR, \$88 (US) IN CANADA,  
\$209 (US) IN ALL OTHER COUNTRIES.

**SUBSCRIPTION INQUIRIES**  
(877) 529-1746 (US ONLY)  
OUTSIDE US CALL: (845) 267-3065

**CIRCULATION**  
PO Box 81  
CONGERS, NY 10920  
TEL: (TOLL FREE): (877) 529-1746  
OUTSIDE US: (845) 267-3065



**CEO, INFORMATION SERVICES GROUP**  
MARC FERRARA

**SENIOR VICE PRESIDENT, OPERATIONS**  
JEFF LEVITZ

**VICE PRESIDENT, HUMAN RESOURCES**  
TAMMY GARCIA

**VICE PRESIDENT, CREATIVE SERVICES & PRODUCTION**  
MONICA TETTAMANZI

**CORPORATE PRODUCTION DIRECTOR**  
JOHN ANTHONY CAGGIANO

**VICE PRESIDENT, CIRCULATION**  
EMELDA BAREA

# Are you tired of...

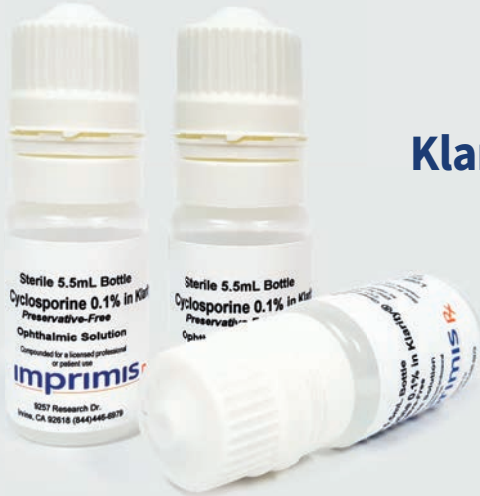...countless **prior authorizations** with **repeat denials**?

...handing out **stacks of coupons** that often **don't work** for many of your patients?

... multiple **call backs** from pharmacies and patients taking up your **valuable time**?



## NOW ONE MONTHLY PRICE\*



## TOTALTEARS®

**Klarity-C™ Cyclosporine 0.1% / Chondroitin Sulfate Ophthalmic Emulsion\*\***  
(preservative-free) 5.5mL Bottles

**\$50 a Month!**  
(ships in packs of 3)

**No Prior Authorizations | No Coupons | No Pharmacy Call Backs**

Learn more at: [www.totaltears.com](http://www.totaltears.com)

**Visit us at Academy 2018 San Antonio Booth #1646**

\*Automatic refill setup required to enroll in our monthly patient program.

\*\*For professional use only. Imprimis Pharmaceuticals specializes in customizing medications to meet unique patient and practitioner needs. Imprimis Pharmaceuticals dispenses only to individually identified patients with valid prescriptions. No compounded medication is reviewed by the FDA for safety or efficacy. Imprimis Pharmaceuticals does not compound copies of commercially available products. References available upon request.

Klarity-C, Total Tears and ImprimisRx are trademarks of Imprimis Pharmaceuticals, Inc. ©2018 Imprimis Pharmaceuticals, Inc. All Rights Reserved. IMPO0289 Rev4 10/18

**Imprimis** Rx®  
844.446.6979



# DRY EYE

## INSTITUTE

### The Top Ten Reasons to Attend Dry Eye Institute:

1. The Customized Step by Step Implementation Plan for Your Individual Office
2. Witness 2 New Patient Evaluations Incorporating the Dry Eye Equation
3. Hands-On Training with the Latest OSD Treatments and Procedures
4. Learn Specific Scripting and Verbiage to Create Patient Buy-in
5. Billing and Coding Resources
6. The Turn Key Marketing Kit
7. Staff Training Tools
8. Establish an Educational Foundation to Diagnose and Treat OSD (COPE CE)
9. Take Home Approximately \$7000 in Product Samples Plus Ongoing Discounts
10. Develop a Personal Network of Innovative Dry Eye Doctors

Register at:



Crystal Brimer  
OD, FAO

[WWW.DRYEYE.INSTITUTE](http://WWW.DRYEYE.INSTITUTE)



Wilmington, NC


## CONTRIBUTING EDITORS

PAUL C. AJAMIAN, OD, ATLANTA  
AARON BRONNER, OD, KENNEWICK, WASH.  
MILE BRUJIC, OD, BOWLING GREEN, OHIO  
DEREK N. CUNNINGHAM, OD, AUSTIN, TEXAS  
MARK T. DUNBAR, OD, MIAMI  
ARTHUR B. EPSTEIN, OD, PHOENIX  
JAMES L. FANELLI, OD, WILMINGTON, NC  
FRANK FONTANA, OD, ST. LOUIS  
GARY S. GERBER, OD, HAWTHORNE, NJ  
ANDREW S. GURWOOD, OD, PHILADELPHIA  
ALAN G. KABAT, OD, MEMPHIS, TENN.  
DAVID KADING, OD, SEATTLE  
PAUL M. KARPECKI, OD, LEXINGTON, KY.  
JEROME A. LEGERTON, OD, MBA, SAN DIEGO  
JASON R. MILLER, OD, MBA, POWELL, OHIO  
CHERYL G. MURPHY, OD, BABYLON, NY  
CARLO J. PELINO, OD, JENKINTOWN, PA.  
JOSEPH PIZZIMENTI, OD, FORT LAUDERDALE, FLA.  
JOHN RUMPAKIS, OD, MBA, PORTLAND, ORE.  
DIANA L. SHECHTMAN, OD, FORT LAUDERDALE, FLA.  
JEROME SHERMAN, OD, NEW YORK  
JOSEPH P. SHOVLIN, OD, SCRANTON, PA.  
JOSEPH W. SOWKA, OD, FORT LAUDERDALE, FLA.  
MONTGOMERY VICKERS, OD, ST. ALBANS, W.VA.  
WALTER O. WHITLEY, OD, MBA, VIRGINIA BEACH, VA.

## EDITORIAL REVIEW BOARD

JEFFREY R. ANSHEL, OD, ENCINITAS, CALIF.  
JILL AUTRY, OD, RPH, HOUSTON  
SHERRY J. BASS, OD, NEW YORK  
EDWARD S. BENNETT, OD, ST. LOUIS  
MARC R. BLOOMENSTEIN, OD, SCOTTSDALE, ARIZ.  
CHRIS J. CAKANAC, OD, MURRYSVILLE, PA.  
JERRY CAVALLERANO, OD, PHD, BOSTON  
WALTER L. CHOATE, OD, MADISON, TENN.  
BRIAN CHOU, OD, SAN DIEGO  
A. PAUL CHOUS, MA, OD, TACOMA, WASH.  
ROBERT M. COLE, III, OD, BRIDGETON, NJ  
GLENN S. CORBIN, OD, WYOMISSING, PA.  
ANTHONY S. DIECIDUE, OD, STROUDSBURG, PA.  
S. BARRY EIDEN, OD, DEERFIELD, ILL.  
STEVEN FERRUCCI, OD, SEPULVEDA, CALIF.  
MURRAY FINGERET, OD, HEWLETT, NY  
IAN BEN GADDIE, OD, LOUISVILLE, KY.  
PAUL HARRIS, OD, MEMPHIS, TN  
MILTON HOM, OD, AZUSA, CALIF.  
BLAIR B. LONSBERRY, MS, OD, MED, PORTLAND, ORE.  
THOMAS L. LEWIS, OD, PHD, PHILADELPHIA  
DOMINICK MAINO, OD, MED, CHICAGO  
KELLY A. MALLOY, OD, PHILADELPHIA  
RICHARD B. MANGAN, OD, LEXINGTON, KY.  
RON MELTON, OD, CHARLOTTE, NC  
PAMELA J. MILLER, OD, JD, HIGHLAND, CALIF.  
BRUCE MUCHNICK, OD, COATESVILLE, PA.  
MARC MYERS, OD, COATESVILLE, PA.  
WILLIAM B. POTTER, OD, FREEHOLD, NJ  
CHRISTOPHER J. QUINN, OD, ISELIN, NJ  
MICHAEL C. RADOIU, OD, STAUNTON, VA.  
MOHAMMAD RAFIETARY, OD, MEMPHIS, TN  
JOHN L. SCHACHET, OD, ENGLEWOOD, COLO.  
JACK SCHAEFFER, OD, BIRMINGHAM, ALA.  
LEO P. SEMES, OD, BIRMINGHAM, ALA.  
LEONID SKORIN, JR., OD, DO, ROCHESTER, MINN.  
JOSEPH W. SOWKA, OD, FORT LAUDERDALE, FLA.  
SRUTHI SRINIVASAN, PHD, BS OPTOM, WATERLOO, ONT.  
BRAD M. SUTTON, OD, INDIANAPOLIS  
LORETTA B. SZCZOTKA, OD, PHD, CLEVELAND  
MARC TAUB, OD, MEMPHIS, TN  
TAMMY P. THAN, MS, OD, BIRMINGHAM, ALA.  
RANDALL THOMAS, OD, CONCORD, NC  
SARA WEIDMAYER, OD, ANN ARBOR, MI  
KATHY C. WILLIAMS, OD, SEATTLE  
KAREN YEUNG, OD, LOS ANGELES

# DRY EYE DISEASE: NOT ONLY A MEDICAL CONDITION, BUT A QUALITY-OF-LIFE CONDITION!



"I love long bike rides off the beaten path. Eye drops limited my freedom. Occlusion Therapy not only relieved my dry eye symptoms, but eliminated the need for eye drops. The back country is mine again!"<sup>1</sup>

VisiPlugs<sup>®</sup> and  
LacriPro<sup>®</sup> Punctum Plugs:  
For all your  
dry eye patients!



Lacrimedics

(800) 367-8327

E-mail: [info@lacrimedics.com](mailto:info@lacrimedics.com)

[www.lacrimedics.com](http://www.lacrimedics.com)

<sup>1</sup>Dramatization. Not a real patient.

©2017 Lacrimedics, Inc.



PRINTED IN USA

FOUNDING EDITOR, FREDERICK BOGER  
1891-1913

EDITORIAL OFFICES  
11 CAMPUS BLVD., SUITE 100  
NEWTOWN SQUARE, PA 19073

SUBSCRIPTION INQUIRIES  
1-877-529-1746

CONTINUING EDUCATION INQUIRIES  
1-800-825-4696

EDITOR-IN-CHIEF • JACK PERSICO  
(610) 492-1006 • JPERSICO@JOBSON.COM

MANAGING EDITOR • REBECCA HEPP  
(610) 492-1005 • RHEPP@JOBSON.COM

SENIOR EDITOR • BILL KEKEVIAN  
(610) 492-1003 • BKEKEVIAN@JOBSON.COM

ASSOCIATE EDITOR • CATHERINE MANTHORP  
(610) 492-1043 • CMANTHORP@JOBSON.COM

ASSOCIATE EDITOR • MARK DE LEON  
(610) 492-1021 • MDELEON@JOBSON.COM

SPECIAL PROJECTS MANAGER • JILL HOFFMAN  
(610) 492-1037 • JHOFFMAN@JOBSON.COM

ART DIRECTOR • JARED ARAUJO  
(610) 492-1032 • JARAUJO@JOBSON.COM

DIRECTOR OF CE ADMINISTRATION • REGINA COMBS  
(212) 274-7160 • RCOMBS@JOBSON.COM

**EDITORIAL BOARD**

CHIEF CLINICAL EDITOR • PAUL M. KARPECKI, OD

ASSOCIATE CLINICAL EDITORS • JOSEPH P. SHOVLIN, OD;  
ALAN G. KABAT, OD; CHRISTINE W. SINDT, OD

DIRECTOR OPTOMETRIC PROGRAMS • ARTHUR EPSTEIN, OD

CLINICAL & EDUCATION CONFERENCE ADVISOR  
PAUL M. KARPECKI, OD

CASE REPORTS COORDINATOR • ANDREW S. GURWOOD, OD

CLINICAL CODING EDITOR • JOHN RUMPAKIS, OD, MBA

CONSULTING EDITOR • FRANK FONTANA, OD

**COLUMNISTS**

CHAIRSIDE • MONTGOMERY VICKERS, OD

CLINICAL QUANDARIES • PAUL C. AJAMIAN, OD

CODING CONNECTION • JOHN RUMPAKIS, OD

CORNEA & CONTACT LENS Q+A • JOSEPH P. SHOVLIN, OD

DIAGNOSTIC QUIZ • ANDREW S. GURWOOD, OD

THE ESSENTIALS • BISANT A. LABIB, OD

FOCUS ON REFRACTION • MARC TAUB, OD;  
PAUL HARRIS, OD

GLAUCOMA GRAND ROUNDS • JAMES L. FANELLI, OD

NEURO CLINIC • MICHAEL TROTTINI, OD;  
MICHAEL DELGIODICE, OD

OCULAR SURFACE REVIEW • PAUL M. KARPECKI, OD

RETINA DILEMMAS • DIANA L. SHECHTMAN, OD;  
JAY M. HAYNIE, OD

RETINA QUIZ • MARK T. DUNBAR, OD

REVIEW OF SYSTEMS • CARLO J. PELINO, OD;  
JOSEPH J. PIZZIMENTI, OD

SURGICAL MINUTE • DEREK N. CUNNINGHAM, OD;  
WALTER O. WHITLEY, OD, MBA

THERAPEUTIC REVIEW • JOSEPH W. SOWKA, OD;  
ALAN G. KABAT, OD

THROUGH MY EYES • PAUL M. KARPECKI, OD

URGENT CARE • RICHARD B. MANGAN, OD

JOBSON MEDICAL INFORMATION LLC



# Outlook

By Jack Persico, Editor-in-Chief



## The Revolution that Wasn't

Expect artificial intelligence to come to optometry gradually. In fact, it's already here.

It's tempting to be weary of artificial intelligence (AI) discussions right now. As it's one of the dominant topics whenever anyone talks about the future of health care, we're possibly at the saturation point where people get a little fed up hearing about the utopia—or, depending on the speaker, doomsday—it will bring. I propose a more modest view: AI's effect will be unobtrusive, imperfect and kind of annoying. Think C-3PO, not HAL-9000.

People sometimes assume AI is going to happen in a radical and practice-changing way all at once—boom, one day the computers will do all the work and doctors will just be clerks. Fact is, you've been using AI for years without quite realizing it. If you have an OCT, the normative databases in those devices are an early form of AI. And the reliability indices on automated perimeters have been giving eye doctors a helping hand for far longer than that.

Expect AI integration to continue along established and familiar vectors like those. The next wave of AI will enter your office by way of a perfunctory software download, not a battering ram to the door. Topcon just bought a small company that specializes in using AI for diagnostic purposes, most notably diabetic retinopathy screening, and will be adding those capabilities to its imaging product lines at some point.

AI's future is inevitably going to be linked with that of telemedicine, too. As computers get better at scanning large datasets for anomalies they can then apply prospectively to patient screenings, the need for face-to-face

real-time interaction between doctor and patient decreases. While some doctors may find this troublesome, others see it as liberating. It “can create an environment that improves outcomes and provides more care for more individuals—the right place, the right care, the right time,” said Anthony Cavallerano, OD, in his talk on telemedicine during the plenary session of the recent American Academy of Optometry annual meeting. But again, this will happen incrementally, not overnight.

A previous speaker at the plenary, Ezekiel Emanuel, MD, PhD, noted that health care is decentralizing away from hospitals and doctors' offices and out into the communities, including chains like CVS and Walmart. This ‘retail medicine’ has been alarming to some, but Dr. Emanuel said it helps people with chronic diseases work their healthcare needs into their everyday lives. With a telemedicine link back to a qualified doctor, this ‘bring the mountain to Mohammed’ approach stands to be a net positive.

Dr. Cavallerano noted that one of the biggest proponents of television in its earliest days was RCA. Maybe that's not surprising, until you learn that the acronym stands for Radio Corporation of America. The company in control of the dominant medium of communication was eager to move to the next big thing, and ushered it in. The message: don't fear the future, help invent it yourself.

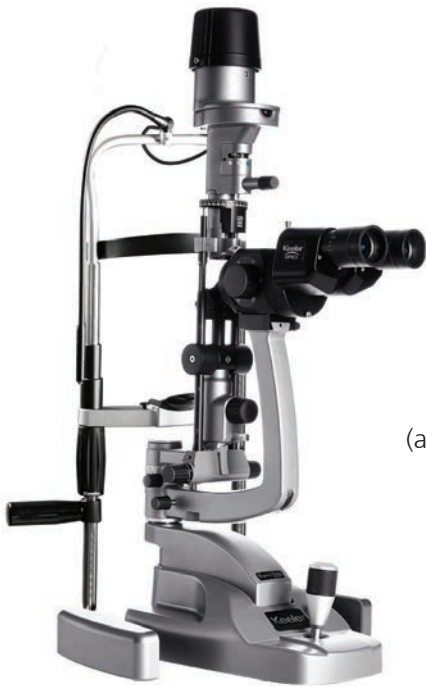Because all intelligence—human and otherwise—is fallible, doctors' expertise will always remain the linchpin. AI will help you be a better doctor, not an unemployed one. ■



# The Keeler<sup>3</sup> Trade In Program

## Buy 3 // Trade 3 // Get 1 Free

The Power of 3. Purchase any 3 Keeler Slit Lamps and trade in 3 of your old Slit Lamps and we'll send you a 4th Keeler Slit Lamp absolutely free of charge.



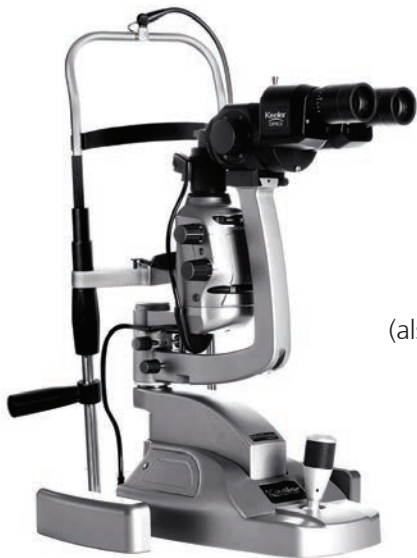**KSL-H**

(also in Digital Ready)



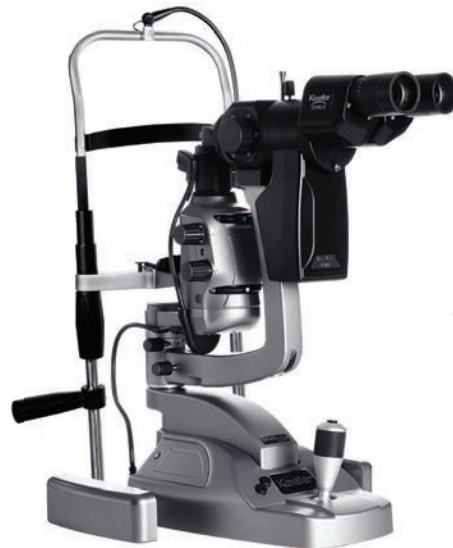**KSL-H-D**

(full Digital)



**KSL-Z**

(also in Digital Ready)



**KSL-H-D**

(full Digital)

**Keeler**  
OPTICS

Keeler Instruments, Inc. • 3222 Phoenixville Pike, bldg. 50 • Malvern, PA 19355  
Tel: (800) 523-5620 • Fax: (610) 353-7814 • email: keeler@keelerusa.com

**Offer valid until December 31, 2018.**

Contact Keeler or one of our authorized dealers for more information.



# Hiding in Plain Sight

Dry eye patients are everywhere—and yet, too often we fail to get them identified and treated. **By Paul M. Karpecki, OD, Chief Clinical Editor**

**H**ere in the US, where approximately 30 million people live with dry eye disease (DED) each day, and perhaps as few as 1.5 million of those are being actively treated, we need to ask ourselves what causes so many sufferers to fall through the cracks. Though many issues contribute to that gap, to me the answer comes down to diagnosis. A wide swathe of conditions promote dry eye—and an even *bigger* swathe masquerades as it.

Known masqueraders include trigeminal dysphoria, fixation disparity, convergence insufficiency, GPC, conjunctival concretions, allergic conjunctivitis, epithelial basement membrane dystrophies, mucin fishing syndrome, conjunctivochalasis, several forms of blepharitis, contact lens solution reactions, pingueculitis, pterygia, exposure keratopathy, medicamentosa, limbal stem cell deficiency, Salzmann's nodular degeneration, floppy eyelid syndrome, episcleritis, superior limbic keratoconjunctivitis and others.

Whew! That's quite a list. I truly believe the ultimate achievement of a doctor who focuses on dry eye is the ability to differentiate it from conditions that clearly sound like dry eye but don't behave like it. Each day in clinic, I encounter many patients who complain of dry, gritty, burning eyes, sometimes accompanied by redness and/or fluctuating vision. Symptoms, signs, systemic health and history can all vary widely. It makes it hard to even find a starting point.

I see a solution in point-of-care (POC) testing. In our field—where a single tear sample could identify allergic conjunctivitis, adenovirus or an array of other systemic diseases without needing to draw blood or conduct invasive exams—POC testing truly presents a way to accomplish more in less time than conventional methods of diagnosis. I'd even say that without POC testing, I could not run my clinic.

If osmolarity testing in one of these patients falls between 280mOsmol/L and 295mOsmol/L in each eye and within 8mOsmol/L between the two eyes, meibomian gland expression shows normal to mildly turbid meibum and there are only subtle corneal signs like mild inferior staining, they've most likely been misdiagnosed. Meanwhile, high osmolarity values or high discordance between the eyes tells me to strongly suspect dry eye. Other POC tests, like tear film testing of matrix metalloproteinase-9, can help hone the DED diagnosis.

## Only Half the Battle

Of course, once DED patients are identified, they need interventions. There are many new treatment options worthy of review.

As 86% of all DED involves meibomian gland dysfunction (MGD), it's safe to start with treating the lids. In today's digital world, we are holding a fixed gaze and blinking less. As a result, we see more meibomian gland dysfunction, exposure, evaporation and a build-up of biofilm.

New devices specifically for MGD include LipiFlow for thermal pulsation, iLux for thermal expression and Blephex for blepharoexfoliation. These preventative care solutions can even help patients avoid contact lens intolerance and dropout.

In prescription DED therapy, a new 0.09% concentration of cyclosporine, Cequa (Sun Pharma), has recently come to market; other new cyclosporines are anticipated.

Although treating DED requires us to treat the inflammation with drugs such as lifitegrast, cyclosporine, corticosteroids or omega fatty acids, palliative care between dosing has an important role, too.

Systane Complete is a new formulation containing more HP Guar than Systane Balance but with the comfort of Systane Ultra. The new TheraTears Xtra contains trehalose to protect cellular structures and provide for greater water binding. And, lastly, Lumify for dry eye patients with injection is the first redness remover that works on the veins as opposed to constricting the arteries, an older concept that caused ischemia and led to rebound hyperemia and tachyphylaxis.

The point is, although DED is complex and patient care can be tricky, an abundance of advances simplify both diagnosis and management. We can finally give patients the attention they deserve. ■

*Note: Dr. Karpecki consults for a number of manufacturers with products relevant to this topic.*



**NEW!**

Available without  
a prescription

# zenoptiq™

Hypochlorous Acid Solution



Daily eyelid and  
eyelash cleanser.

Gentle | Soothing | All Natural

Zenoptiq Hypochlorous Acid is a natural cleansing agent. Zenoptiq gently cleanses eyelids, removing debris that may cause blockage of the glands. Studies have shown Hypochlorous Acid kills bacteria and may reduce inflammation giving patients relief from symptoms associated with MGD, Blepharitis and Dry Eye. Conveniently stored in a safe, shatterproof bottle,

Zenoptiq is an easy choice for daily cleansing.



For More Information or To Order  
Please Visit [Zenoptiq.com](http://Zenoptiq.com)  
or Call (866) 752-6006

Sold exclusively by



FOCUS Laboratories, Inc.  
(866) 752-6006  
[Focuslaboratories.com](http://Focuslaboratories.com)



Manufactured for:  
Paragon BioTech | Portland, OR 97239  
(888) 424-1192 | [Paragonbiotech.com](http://Paragonbiotech.com)

Trademarks: Zenoptiq™ (Paragon BioTech, Inc.)  
Copyright © 2018 Paragon BioTech, Inc. All Rights Reserved.

Copyright © 2018 FOCUS Laboratories, Inc. All Rights Reserved.

FLM188-1018-01

# Wanted: An Eye For Business

I feel bad for all of you who thought knowing how to perform a refraction was the key to optometry. **By Montgomery Vickers, OD**

By now we all know if you give everyone a raise or hire new employees, business will plummet before the ink dries on the contract. If you decide things are good enough to get the family out of town for a week or two, cash flow will decline at least twice as long as you and the crew were lollygagging at the beach. Oh, and you know if you buy a new car, suddenly everyone wants to get their glasses online.

Why? Well, either Satan runs your business or God has an unusual sense of humor. Either way, my advice is to stay calm and, if all else fails, fire everyone. As soon as you are grossly understaffed, business will explode. Soon your office will be full of patients who would love to buy stuff from you, if you only had someone in the office who actually knew how to post a check.

## The Missing Link

Handling these ups and downs is the crux of running a successful small business—one thing we were never taught in school, even though it's probably more important in optometry than all the dials on a phoropter. Of course, if our professors actually knew anything about running a successful small business they wouldn't be professors, right?

I am sorry if any professors took offense to that. Those of you who have successfully run a small business can reach out and I'll apologize to both of you. And selling quilted glasses cases on Etsy does not count.

Am I being too harsh? Maybe,

but do I make a good point? Why would someone with a doctorate in optometry offer a free exam if you buy glasses next door? One business class would have saved their soul.

Now that I think about it, we did have a business class in school and it was taught by a well-respected and successful private practice OD. During the two-hour class, he showed slides of his very successful practice. There were at least 20 slides of his bathroom. It was quite nice and the toilet paper appeared to be of excellent quality. His décor was velvety and filled with Japanese tapestries, Ming vase wannabees and various Samurai swords.

I guess I should have decorated my office more like his.

## Filling the Void

There are, of course, business courses offered at CE meetings, mostly sponsored by labs and other vendors. The extremely engaging speaker assures you that if you buy the stuff produced by the sponsoring labs and vendors, your business will be healthy and growing. The speaker's own speaking business will be healthy and growing too, as they will never have to

face another patient whose progressive adds drive everyone crazy. Now, that is a business plan!

I know, I know. There are plenty of optometrists who do great in private practice. In fact, probably the worst optometrist in America still has a nice car and is a member of the country club. I guess that could be because he doesn't really practice optometry and drives for Uber. The point is, he has a Doctor of Optometry and is doing just fine.

Also, I know optometrists who have MBAs. This additional financial training gives them not only the ability to accurately analyze every facet of their small business, but also another diploma to hang on the wall. They never hang Samurai swords on their office walls—makes it too easy to commit harakiri when their checkbooks don't balance.

Remember: fire everyone and watch the phones explode! ■



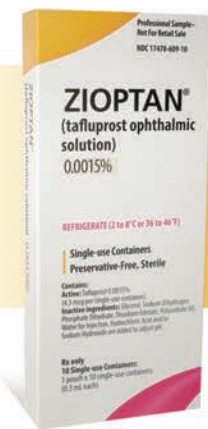



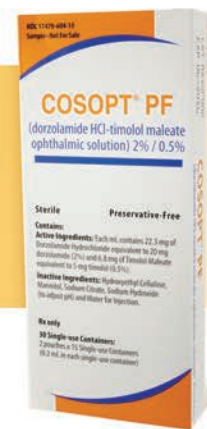# 100% PRESERVATIVE-FREE

**ZIOPTAN<sup>®</sup>**  
(tafluprost ophthalmic solution) 0.0015%

**Cosopt<sup>®</sup> PF**  
(dorzolamide HCl - timolol maleate ophthalmic solution) 2% / 0.5%



## ORDER FREE SAMPLES



Go to either website and select "Request Sample"

[www.Zioptan.com](http://www.Zioptan.com)

[www.CosoptPF.com](http://www.CosoptPF.com)

Cosopt is a registered trademark of Merck Sharp & Dohme Corp and is used under license. ZIOPTAN is a registered trademark of Merck Sharp & Dohme Corp and is used under license.

**Santen** ZIOPTAN is licensed by Santen Pharmaceutical Co., Ltd.





# Widefield Tech Not a Solo Act

Don't get complacent with ultra-wide imaging alone; remember to dilate and avoid trouble. **Edited by Paul C. Ajamian, OD**

**Q** I don't dilate my patients much anymore due to ultra-wide non-dilated photography. Is this the standard of care and am I at risk of missing something?

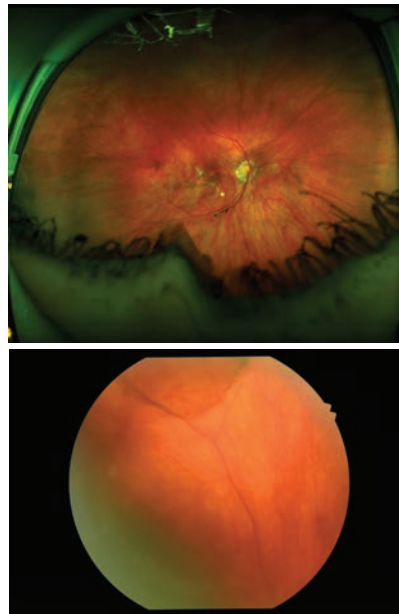
**A** "Although widefield photography is a useful screening tool, it has limitations," says Robert Vandervort, OD, of Heartland Eye Consultants in Omaha, NE. He suggests that periodic dilated fundus examinations should always be performed in addition to any widefield screening.

Dr. Vandervort notes that, while the technology is improving, widefield imaging remains a screening tool that frequently does not allow proper examination of the peripheral fundus, especially in the superior and inferior portions of the retina. In addition, the lower magnification of widefield imaging reduces its value in assessing the subtle signs of vascular disease or early glaucomatous cupping.

On the other hand, the technology does provide the doctor with a stable image to review and, many times, picks up problems that might have been missed with a binocular indirect ophthalmoscope (BIO) or 90D fundus lens. However, it is not an outright replacement for a dilated fundus examination with binocular indirect ophthalmoscopy.

## A Thorough Look

A patient was referred to Dr. Vandervort's office after a routine eye examination for evaluation of chorioretinal atrophy in the macula. The patient was asymptomatic for



**The standard fundus photo (below) was able to detect a superior retinal detachment that UWI (top) did not catch.**

any vision loss or any visual symptoms. Interestingly, while performing a dilated fundus examination of the right eye with BIO, he detected a superior retinal detachment (RD) with a pigment demarcation line in addition to the chorioretinal atrophy in the macula the referring doctor noted. Dr. Vandervort referred the patient to a local retina specialist for treatment with laser retinopathy.

Analyzing the widefield images sent to him, Dr. Vandervort noted that the inferior and superior retinal images provided limited views due to interference from the eyelashes and a narrow palpebral fissure width. This caused the retinal detachment to be obscured and go unnoticed.

The macular chorioretinal scars were prominent and easily noted.

## The Appropriate Standard

Both patients and doctors have reasons to avoid dilation. Patients dislike the examination process and the resultant blurred vision and light sensitivity. Doctors would sometimes rather not interrupt a packed schedule by convincing patients of the value of dilation and the additional exam procedures needed to examine the fundus.

While Dr. Vandervort agrees that practitioners should be considerate of a patient's wishes and comfort, he still recommends periodic dilation to avoid missing important and vision threatening findings. Widefield photos can be used in between dilated examinations, he adds.

"Just like any test we do, widefield imaging has value when appropriately balanced as part of the traditional examination techniques and tools we have available to us," Dr. Vandervort explains. Overreliance on widefield imaging, and using it as a substitute for a thorough dilated fundus examination, can lead doctors into trouble.

Dilation is still the standard of care, especially in higher risk patients. Dr. Vandervort advises that patients often have more than one condition —meaning that if they present with a red eye, don't forget to examine the fundus. "When you need a thorough examination of the retina, there is no substitute for dilation by a capable and experienced clinician," he adds. ■



Introducing

**eyeleve**<sup>™</sup>  
by **Bruder**<sup>®</sup>

## CONTACT LENS COMPRESS

- EXTEND COMFORTABLE WEAR TIME
- REDUCE THE RISK OF INFECTION

THE **ONLY** EYE COMPRESS CLINICALLY  
PROVEN TO EXTEND COMFORTABLE  
WEARING TIME OF CONTACT LENSES



**Bruder** | Better. By Design.

Learn more at [www.eyeleve.com](http://www.eyeleve.com) | 888-827-8337 | [eyeleve@bruder.com](mailto:eyeleve@bruder.com)





# Take on Point-of-care Testing

Follow the proper certification steps and benefit from its impact on clinical outcomes.

By John Rumpakis, OD, MBA, Clinical Coding Editor

Because our health care system rewards quality of care rather than quantity of care, it underscores the importance of early and accurate diagnosis of clinical conditions. Using point-of-care (POC) testing helps us counteract this issue.

POC testing is becoming more prevalent in the average optometric practice as technology improves and weaves its way into our daily clinical regimen. Much of the POC testing we do today concerns the anterior surface, specifically TearLab osmolarity testing, AdenoPlus (Quidel), InflammDry (Quidel) and Sjö (Bausch + Lomb). The number of tests and type of testing for conditions, such as macular degeneration, Sjögren's syndrome and diabetes, continue to increase as new entries come to market.

## Getting Started

POC testing is easy and important to incorporate into your daily routine; however, there are some basics to understand before deciding to test, code and bill. In order to incorporate this simple yet important aspect of clinical care into your practice, you must be familiar and accredited with your Clinical Lab Improvement Amendments (CLIA) certification.

Assuming that performing CLIA-waived tests are within your scope of practice, you must do two things before you can perform and get reimbursed for CLIA-waived tests. First, your office must be designated as a CLIA-approved laboratory,

and, second, one of the doctors must be designated and approved as a clinical lab director. To do this, you must apply with the Centers for Medicare and Medicaid Services to get your CLIA certification.<sup>1</sup> This certification is absolutely critical.

Lab tests are paid from a national laboratory fee schedule and do not follow the RBRVS reimbursement model. The codes are designated in the 8XXXX range in the CPT. Additionally, you can only perform tests that have the "waived" designation and carry the -QW modifier designation.

For testing both eyes and coding for them, include two lines. The claim form looks like the following:

- 8XXXX-QW-LT
- 8XXXX-QW-RT

Tests that we typically perform in our practice are:

*TearLab*—83861-QW  
(Microfluidic analysis utilizing an integrated collection and analysis device, tear osmolarity)

*AdenoPlus*—87809-QW  
(Infectious agent antigen detection by immunoassay with direct optical observation; adenovirus)

*InflammDry*—83516-QW  
(Immunoassay for analyte other than infectious agent antibody or infectious agent antigen; qualitative or semiquantitative, multiple step method)

## Covering Your Bases

However, not all POC testing is clinical or requires CLIA certification. Tests for Sjögren's and diabetes require collection of blood

that may or may not be within your state's scope of practice. Keep in mind that while the patient may be able to stick their own finger for the blood sample, you may not be. If you are, this collection is described with CPT code 36415 (routine venipuncture) and pays about \$3.

It is important to realize that quantifying and interpreting the results in the medical record—should you have to defend them—is an important part of the clinical regimen. There should always be signs, symptoms, complaints or a personal history of disease recorded in the medical record that would prompt your testing and establish medical necessity for point-of-care tests performed. There are no limitations on the quantity of tests that you can perform in a clinical episode of care, but the number should be reasonable and demonstrate that the testing influenced your clinical decision-making.

Delivering better outcomes by incorporating testing that allows us to diagnose earlier and treat with greater specificity is vitally important in today's healthcare environment. Incorporating point-of-care testing allows you to be able to do so in an efficient and effective manner. ■

Send questions and comments to [rocodingconnection@gmail.com](mailto:rocodingconnection@gmail.com).

1. Clinical laboratory improvement amendments (CLIA) application for certification. Centers for Medicare and Medicaid Services. [www.cms.gov/Medicare/CMS-Forms/CMS-Forms/Downloads/CMS116.pdf](http://www.cms.gov/Medicare/CMS-Forms/CMS-Forms/Downloads/CMS116.pdf). Accessed November 1, 2018.

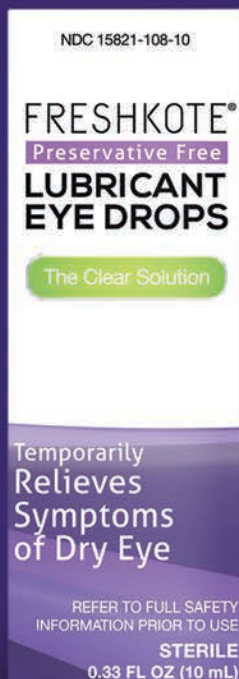
# FRESHKOTE®

Preservative Free  
LUBRICANT EYE DROPS

The Clear Solution

## FRESHKOTE® PF is now available— **preservative-free** in a multidose bottle

- ✓ For temporary relief of dry eye symptoms
- ✓ Gentle, preservative-free drops can be used with contact lenses
- ✓ Exclusive patented formulation
- ✓ Unique phospholipid blend combats tear evaporation
- ✓ State-of-the-art Novelia® multidose bottle dispenses drops with precision



► For more information, visit **FRESHKOTE.com**

NOW AVAILABLE  
FROM

 **eyeVance**<sup>™</sup>  
pharmaceuticals

© 2018 EyeVance Pharmaceuticals. All rights reserved.  
FRESHKOTE is a registered trademark of EyeVance Pharmaceuticals.  
Novelia is a registered trademark of Nemera Development.

FRE-002 10/2018



# Why SVP Matters

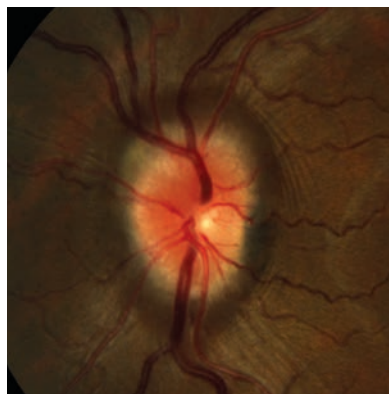In medicine as in life, it's good to be spontaneous. **By Bisant A. Labib, OD**

The evaluation of the optic nerve is an essential part of any ocular health examination. The structure and integrity of the neuroretinal rim must be assessed, as well as the presence of adequate optic nerve perfusion. The presence or absence of distinct disc margins is noted as it is an essential clue in determining the etiology of disc swelling and/or suspected papilledema.

Frequently, the optometrist is faced with very subtle findings and is forced to decide whether these represent normal variations or something that warrants an emergent workup and referral. In such cases, the most helpful element of the examination is the presence or absence of a spontaneous venous pulse (SVP).

## Clues in the Anatomy

To understand the clinical and physiologic importance of the SVP, it is important to recall the course of the optic nerve (ON). The ON runs from the retina towards the optic chiasm and is classified into four segments. The first is the intraocular segment, which measures only 1mm in length and is evident on routine fundoscopic examinations at the level of the lamina cribrosa. The ON continues on as the intraorbital segment, which measures 20mm to 30mm and extends from the posterior globe to the orbital apex. Next is the intracanalicular segment (4mm to 9mm), which travels within the bony optic canal. Finally, the intracranial segment (10mm) extends from the optic canal to the optic chiasm.<sup>1</sup>



**Optic nerve swelling secondary to increased intracranial pressure with loss of SVP.**

With the exception of the intraocular segment, the entirety of the ON is surrounded by the same meningeal layers as the brain—pia, arachnoid and dura. Furthermore, the subarachnoid space of the brain is contiguous with the subarachnoid space around the ON. Finally, it is important to remember that the central retinal vein and artery enter the intraorbital segment of the ON and continue towards the retina.

Because of these anatomic orientations, the ON and central retinal vein are exposed to, and influenced by, changes in intracranial cerebrospinal fluid (CSF) pressure.<sup>1</sup>

## What are SVPs?

The phenomenon is defined as rhythmic pulsations occurring in the retinal vein(s) as they cross the optic disc.<sup>2</sup> These pulsations are synchronized with the patient's cardiac cycle, with the venous caliber steadily narrowing during systole and expanding with diastole.<sup>2,4</sup>

Because portions of the ON and central retinal vein are exposed to the subarachnoid space before traversing the lamina cribrosa, the pressure difference between the subarachnoid space and intraocular space gives rise to the SVP—in essence, the SVP is a physical manifestation of this pressure difference.<sup>2,3</sup>

Typically, the intraocular pressure is greater than the intracranial CSF pressure. However, when there is a rise in intracranial CSF pressure such that it equates to the intraocular pulse pressure, the SVP ceases to occur. This is because there is no longer a pressure gradient to produce the venous pulsation.<sup>2,4</sup> This fact makes SVP an essential component in the evaluation of patients with suspected papilledema secondary to increased intracranial pressure—the documentation of an SVP will often rule out papilledema.

Since only 80% to 90% of normal, healthy eyes will exhibit SVP, its absence does not necessarily indicate an underlying pathological condition.<sup>2,5</sup> An SVP may be absent in healthy patients due to certain optic disc configurations in which the pulsating retinal vein may be obscured by overlying retinal arteries or glial tissue as it enters the cup.<sup>4,6,7</sup> Additional congenital variations, wherein the veins enter the optic disc peripherally instead of centrally in a shallow cup, may also obscure visibility.<sup>4</sup>

Even in patients with disc swelling that is not secondary to a rise in intracranial pressure, an SVP may be difficult to observe due to



the local mechanical compression of the superficial veins.<sup>4</sup> Because of these normal variants and special cases, the absence of an SVP in and of itself is not particularly helpful. Rather, the presence of an SVP or the loss of a previously documented SVP proves of the greatest clinical value in suspicious cases.

### Clinical Relevance

SVPs are often crucial in the management of patients with subtle disc elevation in determining the need for an emergent workup to exclude a pathological manifestation of intracranial disease. As such, the eye care provider should be comfortable and skilled in looking for this subtle finding as part of a routine ocular health assessment, to either aid in ruling out disease processes or to document its presence or absence in healthy patients for future monitor-

ing. The best way to check for an SVP is to use the direct ophthalmoscope, as it offers 15x magnification to best visualize the vessels through a dilated eye.<sup>2</sup>

A great deal of emphasis has been placed on the significance of SVPs in cases of suspected papilledema, but they also play a role in glaucoma, where SVPs are present in only 54% of patients.<sup>7,8</sup> The subset of glaucoma patients most affected by a loss of SVP is normotensive, as they have been shown to have alterations in ocular and systemic perfusion and blood flow velocities.<sup>8</sup> Preliminary studies suggest that the loss of an SVP may serve as a marker for glaucoma severity and progression.<sup>8</sup>

Although a subtle finding, a SVP can be a very telling sign and should be documented on routine ocular health assessments. The loss of a previously documented SVP may

be a harbinger of underlying intracranial pathology in the setting of suspected papilledema. Furthermore, loss of a SVP may also indicate worsening glaucoma, possibly suggesting the need for more aggressive management. ■

1. Gala F. Magnetic resonance imaging of optic nerve. *Indian J Radiol Imaging.* 2015;25(4): 421-438.
2. Jacks AS, Miller NR. Spontaneous retinal venous pulsation: aetiology and significance. *J Neurol Neurosurg Psychiatry.* 2003;74:7-9.
3. Kim M, Ji Lee E, Seo Je, et al. Relationship of Spontaneous Retinal Vein Pulsation with Ocular Circulatory Cycle. *PLoS ONE.* 2014;9(5):1-5.
4. Lascaratos G, Ahmed S, Madill S. Spontaneous venous pulsation and its role in differentiating papilledema from pseudopapilledema. *Neurology.* 2010:e53-e54.
5. Morgan WH, et al. Retinal Vein Pulsation is in Phase with Intracranial Pressure and Not Intraocular Pressure. *Physiology and Pharmacology.* 2012;53:4676-4681.
6. Donnelly SJ, Subramanian PS. Relationship of Intraocular Pulse Pressure and Spontaneous Venous Pulsations. 2009;147(1):51-55.
7. Morgan WH, et al. Intraocular Pressure Reduction is Associated with Reduced Venous Pulsation Pressure. *PLOS ONE.* 2016:1-9.
8. Pinto LA, et al. Lack of spontaneous venous pulsation: possible risk indicator in normal tension glaucoma? *Acta Ophthalmologica.* 2012;91:514-520.

**EYEDESIGNS**  
CUSTOM INTERIORS + FURNITURE *group*  
WWW.EYEDESIGNS.COM  
800.346.8890

We are your  
complete  
resource.

So much more than just optical  
displays & exam lanes.

IRIS/ [opticaldisplays.com](http://opticaldisplays.com)

ORVOJ EXAM ENVIRONMENTS LUM RETINAL LIGHTING GROUP



# The Neuroimaging Dilemma

Progress and proper detection can offer early diagnosis and other benefits.

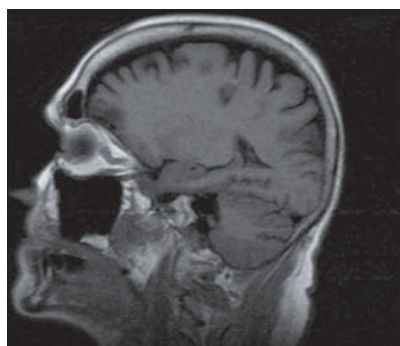
By Michael Trottni, OD, and Michael DeGiodice, OD

Many have debated whether all acute isolated ocular motor cranial neuropathies in patients older than 50 with or without vascular factors should undergo neuroimaging. While conventional wisdom demonstrates that isolated third, fourth and sixth cranial neuropathies are a frequent cause of presumed microvascular ischemia, identifiable causes of non-microvascular mononeuropathies have ranged from 1% to 15%.<sup>1-3</sup> Based on these findings, some authors offer evidence to suggest the clinical rationale for imaging all acute isolated third, fourth and sixth nerve palsies.

## Third Nerve Palsy

The third nerve's two major functions are oculomotor and pupillo-motor. Both partial and complete third nerve palsy (TNP) can be a manifestation of presumed ischemia in the setting of diabetes, hypertension and more serious pathology.<sup>4</sup> Common pathologies involving the oculomotor nerve include ischemic and hemorrhagic infarctions, aneurysm, cavernous malformation and demyelinating disease.<sup>5</sup>

Knowing which cases require neuroimaging can be thought-provoking, as many have debated which cases need emergent testing. TNP can be differentiated as either partial or complete and pupil-sparing or pupil-involving. While acute headache and TNP may suggest an ominous cause, cases report co-involvement in as few as 30%



**Three dark lesions within the frontal-parietal-occipital region represents edema from ischemia in a patient with acute, isolated SNP.**

of patients with aneurysmal TNP and in up to 50% with presumed microvascular cause. Aneurysms are likely to affect pupillo-motor fibers in complete TNP but spare its function in superior division palsies.<sup>6</sup> Conversely, up to 20% of patients with microvascular TNP may have pupil involvement, with anisocoria of 1.5mm or less.<sup>6</sup> The relative incidence of aneurysm as a cause of isolated TNP ranged from 14% to 56%.<sup>7,8</sup> While evidence supports observation in acute, complete, isolated TNP without pupil involvement, numerous cases implicate midbrain strokes, neoplasms, infections, vasculitis, pituitary apoplexy and carotid artery occlusion.

Our recommendation is to obtain an emergent neuroimaging with computed tomography (CT) computed tomography angiography (CTA) or magnetic resonance imaging (MRI)/magnetic resonance angiography (MRA) in all cases of TNP.

In ambiguous cases, it is vital that a neuroradiologist interprets the study before one discounts an aneurysm.

## Fourth Nerve Palsy

The most common causes of fourth nerve palsy (FNP) are congenital, traumatic and vasculopathic. While the etiology of truly isolated FNP in older patients is often vasculopathic, many report isolated palsies as manifestations of midbrain hemorrhages, pituitary macroadenoma, posterior fossa tumors, dural fistulas, schwannomas and cavernomas.<sup>9-17</sup>

A small number of isolated FNP cases were identified as having a trochlear nerve schwannoma, as well as etiologies which included cavernous meningioma, intra-cavernous carotid artery aneurysm and a carotid-cavernous fistula.<sup>13,18,19,20</sup> While it may be reasonable to observe truly isolated cases, one might miss an important lesion, especially if the patient were to develop additional neurologic symptoms. We recommend that contrast-enhanced MRI of the brain be obtained, with attention to the cavernous sinus.

## Sixth Nerve Palsy

Sixth nerve palsy (SNP) is the most common ocular motor nerve palsy.<sup>21</sup> The etiology of SNP is most often attributed to ischemia; however, a brain MRI is not routinely performed in all patients. Non-microvascular causes of SNP may include: demyelinating



# THE LFA-1 ANTAGONIST THAT'S FIRST IN ITS CLASS

As the only lymphocyte function-associated antigen-1 (LFA-1) antagonist available for Dry Eye Disease, Xiidra is in a class of its own<sup>1,2</sup>

Xiidra, the first in a class of LFA-1 antagonists for Dry Eye Disease, is a prescription eye drop FDA-approved to treat both signs and symptoms of the disease.<sup>1,3</sup>

.....

There's no substitute.<sup>2,4</sup>  
Check out patient resources,  
insurance coverage, and  
more at **Xiidra-ECP.com**

.....

References:

1. Xiidra [Prescribing Information]. Lexington, MA: Shire US.
2. TFOS DEWS II Research Subcommittee. Report of the Research Subcommittee of the Tear Film & Ocular Surface Society Dry Eye WorkShop II (2017). *Ocul Surf.* 2017;15(3):269-649.
3. FDA approves new medication for dry eye disease. FDA News Release. July 2016. <http://www.fda.gov/newsevents/newsroom/pressannouncements/ucm510720.htm>. Accessed July 12, 2016.
4. Food and Drug Administration. Electronic Orange Book. <http://www.fda.gov/downloads/Drugs/DevelopmentApprovalProcess/UCM071436.pdf>. Accessed June 26, 2018.

**Indication**

Xiidra® (lifitegrast ophthalmic solution) 5% is indicated for the treatment of signs and symptoms of dry eye disease (DED).

**Important Safety Information**

Xiidra is contraindicated in patients with known hypersensitivity to lifitegrast or to any of the other ingredients.

In clinical trials, the most common adverse reactions reported in 5-25% of patients were instillation site irritation, dysgeusia and reduced visual acuity. Other adverse reactions reported in 1% to 5% of the patients were blurred vision, conjunctival hyperemia, eye irritation, headache, increased lacrimation, eye discharge, eye discomfort, eye pruritus and sinusitis.

To avoid the potential for eye injury or contamination of the solution, patients should not touch the tip of the single-use container to their eye or to any surface.

Contact lenses should be removed prior to the administration of Xiidra and may be reinserted 15 minutes following administration.

Safety and efficacy in pediatric patients below the age of 17 years have not been established.

For additional safety information, see accompanying Brief Summary of Safety Information on the adjacent page and Full Prescribing Information on Xiidra-ECP.com.





## BRIEF SUMMARY:

Consult the Full Prescribing Information for complete product information.

## INDICATIONS AND USAGE

Xiidra® (lifitegrast ophthalmic solution) 5% is indicated for the treatment of the signs and symptoms of dry eye disease (DED).

## DOSAGE AND ADMINISTRATION

Instill one drop of Xiidra twice daily (approximately 12 hours apart) into each eye using a single-use container. Discard the single-use container immediately after using in each eye. Contact lenses should be removed prior to the administration of Xiidra and may be reinserted 15 minutes following administration.

## CONTRAINDICATIONS

Xiidra is contraindicated in patients with known hypersensitivity to lifitegrast or to any of the other ingredients in the formulation.

## ADVERSE REACTIONS

### Clinical Trials Experience

Because clinical studies are conducted under widely varying conditions, adverse reaction rates observed in clinical studies of a drug cannot be directly compared to rates in the clinical trials of another drug and may not reflect the rates observed in practice. In five clinical studies of dry eye disease conducted with lifitegrast ophthalmic solution, 1401 patients received at least 1 dose of lifitegrast (1287 of which received lifitegrast 5%). The majority of patients (84%) had  $\leq 3$  months of treatment exposure. 170 patients were exposed to lifitegrast for approximately 12 months. The majority of the treated patients were female (77%). The most common adverse reactions reported in 5-25 % of patients were instillation site irritation, dysgeusia and reduced visual acuity. Other adverse reactions reported in 1% to 5% of the patients were blurred vision, conjunctival hyperemia, eye irritation, headache, increased lacrimation, eye discharge, eye discomfort, eye pruritus and sinusitis.

### Postmarketing Experience

The following adverse reactions have been identified during postapproval use of Xiidra. Because these reactions are reported voluntarily from a population of uncertain size, it is not always possible to reliably estimate their frequency or establish a causal relationship to drug exposure.

Rare cases of hypersensitivity, including anaphylactic reaction, bronchospasm, respiratory distress, pharyngeal edema, swollen tongue, and urticaria have been reported. Eye swelling and rash have been reported.

## USE IN SPECIFIC POPULATIONS

### Pregnancy

There are no available data on Xiidra use in pregnant women to inform any drug associated risks. Intravenous (IV) administration of lifitegrast to pregnant rats, from pre-mating through gestation day 17, did not produce teratogenicity at clinically relevant systemic exposures. Intravenous administration of lifitegrast to pregnant rabbits during organogenesis produced an increased incidence of omphalocele at the lowest dose

tested, 3 mg/kg/day (400-fold the human plasma exposure at the recommended human ophthalmic dose [RHOD], based on the area under the curve [AUC] level). Since human systemic exposure to lifitegrast following ocular administration of Xiidra at the RHOD is low, the applicability of animal findings to the risk of Xiidra use in humans during pregnancy is unclear.

### Animal Data

Lifitegrast administered daily by intravenous (IV) injection to rats, from pre-mating through gestation day 17, caused an increase in mean preimplantation loss and an increased incidence of several minor skeletal anomalies at 30 mg /kg / day, representing 5,400-fold the human plasma exposure at the RHOD of Xiidra, based on AUC. No teratogenicity was observed in the rat at 10 mg /kg /day (460-fold the human plasma exposure at the RHOD, based on AUC ). In the rabbit, an increased incidence of omphalocele was observed at the lowest dose tested, 3 mg /kg /day (400-fold the human plasma exposure at the RHOD, based on AUC), when administered by IV injection daily from gestation days 7 through 19. A fetal No Observed Adverse Effect Level (NOAEL) was not identified in the rabbit.

### Lactation

There are no data on the presence of lifitegrast in human milk, the effects on the breastfed infant, or the effects on milk production. However, systemic exposure to lifitegrast from ocular administration is low. The developmental and health benefits of breastfeeding should be considered, along with the mother's clinical need for Xiidra and any potential adverse effects on the breastfed child from Xiidra.

### Pediatric Use

Safety and efficacy in pediatric patients below the age of 17 years have not been established.

### Geriatric Use

No overall differences in safety or effectiveness have been observed between elderly and younger adult patients.

## NONCLINICAL TOXICOLOGY

### Carcinogenesis, Mutagenesis, Impairment of Fertility

**Carcinogenesis:** Animal studies have not been conducted to determine the carcinogenic potential of lifitegrast.

**Mutagenesis:** Lifitegrast was not mutagenic in the *in vitro* Ames assay. Lifitegrast was not clastogenic in the *in vivo* mouse micronucleus assay. In an *in vitro* chromosomal aberration assay using mammalian cells (Chinese hamster ovary cells), lifitegrast was positive at the highest concentration tested, without metabolic activation.

**Impairment of fertility:** Lifitegrast administered at intravenous (IV) doses of up to 30 mg/kg/day (5400-fold the human plasma exposure at the recommended human ophthalmic dose (RHOD) of lifitegrast ophthalmic solution, 5%) had no effect on fertility and reproductive performance in male and female treated rats.



Manufactured for: Shire US Inc., 300 Shire Way, Lexington, MA 02421.

For more information, go to [www.Xiidra.com](http://www.Xiidra.com) or call 1-800-828-2088.

Marks designated ® and ™ are owned by Shire or an affiliated company.

©2018 Shire US Inc. SHIRE and the Shire Logo are trademarks or registered trademarks of Shire Pharmaceutical Holdings Ireland Limited or its affiliates.

Patented: please see <https://www.shire.com/legal-notice/product-patents>  
Last Modified: 01/2018 S33769

disease, metastasis, aneurysm and intracranial hypertension.<sup>22</sup> However, because hypertension and diabetes cause SNP in up to 35% of patients, some argue that monthly follow ups are the best approach in the absence of associated neurologic findings or history of cancer sans MRI confirmation.<sup>23,24</sup> Additionally, research shows the potential for spontaneous recovery of SNP in the presence of extramedullary compression by a tumor at the base of the brain.<sup>25</sup>

Published research does not support observation alone. With the risk of delaying a potential serious intracranial pathology, we recommend obtaining an initial contrast-enhanced MRI of the brain in those with acute isolated SNP, as previous studies have shown a lack of diagnostic benefit from computed tomography (CT).<sup>26</sup>

## Discussion

With the advent of MRI, it's now possible to detect small ischemic, inflammatory and space-occupying lesions that would have been missed on CT. Observation seemed reasonable since much of the past literature identified a low rate of non-ischemic causes in isolated neuropathies.<sup>2</sup> However, in a review of all MRIs ordered for varying ophthalmologic pathologies, 28% of patients had relevant findings, like demyelinating disease, stroke and metastases.<sup>27</sup>

Until recently, no well-designed studies or prospective case series existed. One study followed patients with acute, non-traumatic, isolated ocular motor nerve palsies.<sup>28</sup> Of the 66 patients, nine had significant causes: four patients with third nerve palsy, two of which were pupil-involving; one patient with fourth nerve palsy and four patients with sixth nerve palsy. Excluding pupil-involving TNP, the study identified

11% of patients with a significant etiology, including neoplasm, brainstem infarct, demyelinating disease and pituitary apoplexy.<sup>28</sup> We believe there is sufficient data for arguing that all acute cranial nerve palsies undergo imaging, regardless of the lack of associated neurological symptoms.

One observational case series estimated the proportion of patients suffering from isolated ocular motor nerve palsies from presumed microvascular ischemia versus other causes by using contrast-enhanced MRI of the brain in patients 50 and older with acute isolated third, fourth and sixth nerve palsies.<sup>3</sup> Due to advances in medical and surgical management, these patients benefited from early diagnosis.

Possible exceptions for ordering imaging may include a combination of the following: no insurance coverage in patients older than 50 with isolated fourth or sixth nerve palsies, positive vasculopathic risk factors, low risk medical history and palsies that resolve within three months.

Each clinician must know their threshold for imaging. High quality neuroimaging is now safe, accessible and readily available, and withholding a possibly life-saving diagnosis seems counterintuitive. While a "normal" imaging study may seem useless, it can provide both a psychological and emotional benefit for the patient and clinician. ■

1. Patel SV, Mutyala S, Leske DA, et al. Incidence, associations, and evaluation of sixth nerve palsy using a population-based method. *Ophthalmology*. 2004;111:369-75.
2. Bendszus M, Beck A, Koltzenburg M, et al. MRI in isolated sixth nerve palsies. *Neuroradiology*. 2001;43:742-5.
3. Tamhankar MA, Biouesse V, Ying GS, et al. Isolated third, fourth, and sixth cranial nerve palsies from presumed microvascular versus other causes: a prospective study. *Ophthalmology*. 2013; 120(11):2264-2269.
4. Jacobson DM, McCanna TD, Layde PM. Risk factors for ischemic ocular motor nerve palsies. *Arch Ophthalmol*. 1994;112:961-966.
5. Bruce BB, Biouesse V, Newman NJ. Third nerve palsies. *Semin Neurol* 2007;27:257-68.

6. Trobe JD. Managing oculomotor nerve palsy. *Arch Ophthalmol*. 1998;116:798-802.
7. Lee AG, Hayman LA, Brazis PW. The evaluation of isolated third nerve palsy revisited: an update on the evolving role of magnetic resonance, computed tomography, and catheter angiography. *Surv Ophthalmol*. 2002;47:137-157.
8. Mathew MR, Teasdale E, McFadzean RM. Multidetector computed tomographic angiography in isolated third nerve palsy. *Ophthalmology*. 2008;115(8):1411-15.
9. Galetta SL, Balcer LJ. Isolated fourth nerve palsy from midbrain hemorrhage: case report. *J Neuroophthalmol*. 1998;18:204-205.
10. Petermann SH, Newman NJ. Pituitary macroadenoma manifesting as an isolated fourth nerve palsy. *Am J Ophthalmol*. 1999;127:235-236.
11. Krohel GB, Mansour AM, Petersen WL, et al. Isolated trochlear nerve palsy secondary to a juvenile pilocytic astrocytoma. *J Clin Neuroophthalmol*. 1982;2:119-123.
12. Mielke C, Alexander MS, Anand N. Isolated bilateral trochlear nerve palsy as the first clinical sign of a metastatic [correction of metastatic] bronchial carcinoma. *Am J Ophthalmol*. 2001;132(4):593-4.
13. Selky AK, Purvin VA. Isolated trochlear nerve palsy secondary to dural carotid-cavernous sinus fistula. *J Neuroophthalmol*. 1994;14:52-54.
14. Feinberg AS, Newman NJ. Schwannoma in patients with isolated unilateral trochlear nerve palsy. *Am J Ophthalmol*. 1999;127:183-188.
15. Maurice-Williams RS. Isolated schwannoma of the fourth cranial nerve: case report. *J Neuro Neurosurg Psychiatry*. 1989; 52:1442-1443. 2001;132:593-594.
16. Leibovitch I, Pakrou D, Selva D, et al. Neuro-ophthalmic manifestations of intracranial cavernous hemangiomas. *Eur J Ophthalmol*. 2006;16:148-152.
17. Surucu O, Sure U, Mittelbronn M, et al. Cavernoma of the trochlear nerve. *Clin Neurol Neurosurg*. 2007;109:791-793.
18. Feinberg AS, Newman NJ. Schwannoma in patients with isolated unilateral trochlear nerve palsy. *Am J Ophthalmol*. 1999;127(2):183-8.
19. Slavin M. Isolated trochlear nerve palsy secondary to cavernous sinus meningioma. *Am J Ophthalmol*. 1987;104:433-4.
20. Arruga J, de Rivas P, Espinet H, Conesa G. Chronic isolated trochlear nerve palsy produced by intracavernous internal carotid artery aneurysm. *J Clin Neuro-ophthalmol*. 1991;11:104-8.
21. Rosenberg RN. *Comprehensive Neurology*. New York: Raven Press, 1991.
22. Richards BW, Jones FR, Younge BR. Causes and prognosis in 4,278 cases of paralysis of the oculomotor, trochlear, and abducens cranial nerves. *Am J Ophthalmol*. 1992;113(5):489-496.
23. Patel S. V., Mutyala S., Leske D. A. et al. Incidence, associations, and evaluation of sixth nerve palsy using a population-based method. *Ophthalmology*. 2004;111:369-75.
24. Moster ML, Savino PJ, Sergott RC, et al. Isolated sixth-nerve palsies in younger adults. *Arch Ophthalmol*. 1984;102:1328-30.
25. Volpe NJ, Lessell S. Remitting sixth nerve palsy in skull base tumors. *Arch Ophthalmol*. 1993;111:1391-5.
26. Nolan J. Diplopia. *Br J Ophthalmol*. 1968; 52:166-71.
27. Volpe NJ. Socioeconomics of neuroimaging in neuroophthalmology. Oral presentation at NANOS Annual Meeting; March 2008; Orlando, FL. [collections.lib.utah.edu/details?id=180818&q=identifier%3A20080313\\_nanos\\_diagnostoneuroimagsympo\\_s\\_01%2A&id=title%2Ccreator%2Cdescription%2Cidentifier%26sort=facet\\_title\\_s+asc&facet\\_setname\\_s=ehsl\\_novel\\_nam](https://collections.lib.utah.edu/details?id=180818&q=identifier%3A20080313_nanos_diagnostoneuroimagsympo_s_01%2A&id=title%2Ccreator%2Cdescription%2Cidentifier%26sort=facet_title_s+asc&facet_setname_s=ehsl_novel_nam). Accessed November 1, 2018.
28. Volpe N. The Work Up of Isolated Ocular Motor Palsy: Who to Scan and Why. Oral presentation at NANOS Annual Meeting; February 2009; Lake Tahoe, CA. [pdfs.semanticscholar.org/03f9/295c3712be8cf794492739c9a2d342122427.pdf](https://pdfs.semanticscholar.org/03f9/295c3712be8cf794492739c9a2d342122427.pdf). Accessed November 1, 2018.

# Checking Under the Hood:

## How to Evaluate the Lid and Ocular Surface

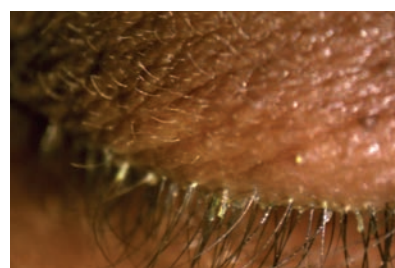
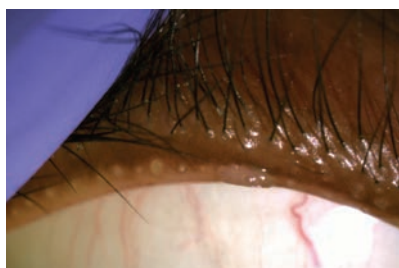Recognizing minor signs of underlying ocular surface or lid disease requires a thorough evaluation. Here's a guide to a comprehensive exam of the ocular surface.

By Marlon J. Demeritt, OD, and Beata I. Lewandowska, OD

The ocular surface is comprised of the cornea, conjunctiva, eyelids, eyelashes, tear film, main and accessory lacrimal glands and meibomian glands.<sup>1</sup> The eyelids play a major role in protecting and spreading the moisture over the ocular surface. The lower eyelid supports the tear film, and the glands of Zeiss and Moll, as well as the meibomian glands, secrete lipids. The blinking action stimulates the release of lipids into the tear film as well as moves the tear film towards the puncta. Any disruption in the normal anatomy and physiology of this system can cause the patient to become symptomatic of ocular surface pathology.

### The Grand Tour

When scanning the closed eyelids, pay attention to the epidermis (e.g., peeling, scaling) and dermis (e.g., hyperemia, edema, ecchymosis), as well as the position of the eyelids to rule out entropion and ectropion. Additionally, be on the lookout for any lesions that disrupt the proper anatomy or cause inflammatory



**At left, this anterior segment photo depicts severe meibomian gland capping and a small squamous cell papilloma of the eyelid margin. The image on the right shows cylindrical dandruff around the roots of the lashes.**

pathology, such as papillomas, molluscum contagiosum, herpetic vesicles, hordeola or chalazia. Ask yourself: are the puncta open?

While scanning the eyelashes, direct your attention to any greasy scales, cylindrical dandruff around the roots of the lashes, or discharge. Check for any misdirected lashes rubbing against the ocular surface. Ask the patient to look down, and while pulling up the upper eyelid to scan the eyelid margin. Observe the meibomian gland orifices and the tissue around them. Note any capping or telangiectasias, as well as any changes in the normal contour of the eyelid margins. Examine the superonasal,

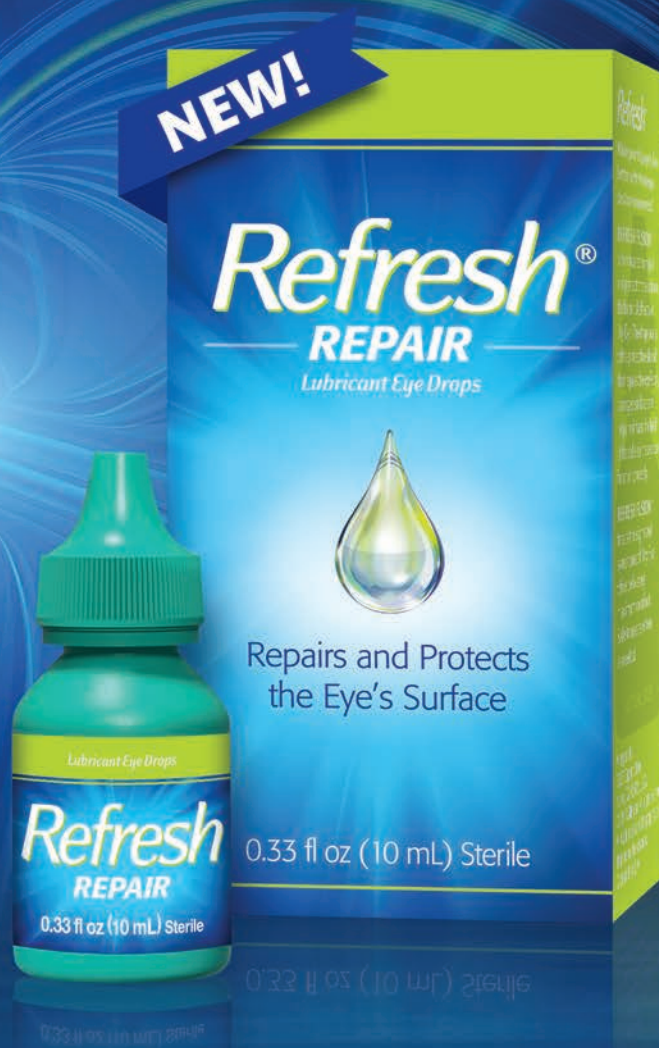superior and superotemporal bulbar conjunctiva. Blebs created during trabeculectomy will be visible superior to the cornea. Evert the upper eyelid and scan the superior palpebral conjunctiva looking for foreign bodies, concretions, papillae or hyperemia.


Ask the patient to look up, so you can pull down the lower eyelid to scan the eyelid margin. Apply pressure to the glands expressing the meibum and evaluate the appearance of the secretion. Pull down a little farther to examine the lower palpebral conjunctiva looking for cystic changes, concretions, follicles, papillae, hyperemia and foreign bodies. While the patient



INTRODUCING  
**REFRESH<sup>®</sup> REPAIR**

The first and only artificial tear in the U.S.  
formulated with CMC, HA,\* and Osmoprotectants.



REFRESH<sup>®</sup> REPAIR helps promote healing of the cornea and conjunctival epithelia and improves visual performance in Dry Eye patients. Safe to use with contacts. 

[refreshbrand.com/doc](http://refreshbrand.com/doc) | 

 **Allergan.**

\*HA is an inactive ingredient.

© 2018 Allergan. All rights reserved. All trademarks are the property of their respective owners. REF115212 05/18

is still looking upward, scan the inferonasal, inferior and infero-temporal bulbar conjunctiva while asking the patient to change gazes. Scan the nasal canthus then nasal bulbar conjunctiva, for it is not uncommon to note pinguecula and pterygium as you approach the limbus. Scan the temporal bulbar conjunctiva looking for lid-parallel conjunctival folds that could indicate conjunctivochalasis (CCH).

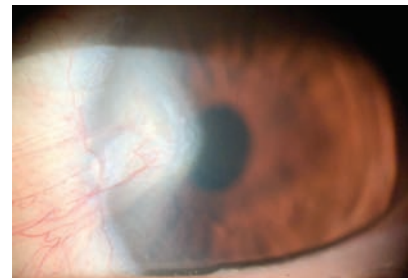
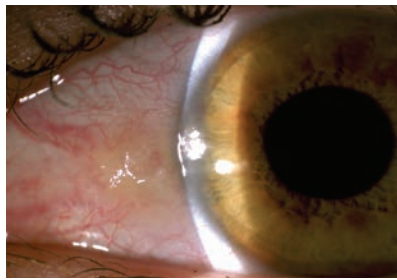
Next, proceed to examine the corneal epithelium, stroma and endothelium, looking for punctate epithelial erosions, limbal neovascularization, dystrophies and degenerations, old scars from foreign bodies, trauma, refractive surgery or previous infections, as well as pannus, infiltrates, edema, guttatae, endothelial pigment and endothelial folds.

## Lid abnormalities

In most countries, life expectancy is increasing, so an expected increase in ophthalmic conditions due to involutional changes are expected as well. It is not uncommon to diagnose involutional entropion or ectropion in middle-aged and older adults. Although increasing age is not the sole cause of lid anomalies, such as entropion and ectropion, involutional changes are deemed the most common.<sup>2</sup> It is not uncommon to find more women to be afflicted with involutional entropion than men.<sup>3</sup> In addition to involutional causes, entropion and ectropion can also stem from a cicatricial etiology.

## Trichiasis

This is a condition in which lashes can grow or be misdirected toward the eye. Every time the patient blinks or even rubs their eyes, the possibility of the lashes scratching against the ocular surfaces increases. Trichiasis can cause irri-



These photos show patients with pinguecula (left) and pterygium (right).

tation, tearing and pain. Trichiasis is commonly caused by trachoma, which can lead to significant corneal scarring. However, trachoma is uncommon in the United States, so cases here are usually deemed idiopathic or secondary to a traumatic etiology, ocular cicatricial pemphigoid, Stevens-Johnson syndrome, chemical burn or severe blepharitis.<sup>4</sup>

It is not uncommon for the signs and symptoms of punctate epithelial erosions, along with tearing, foreign body sensation and redness to be shared between trichiasis and entropion. Left untreated, trichiasis may result in serious ocular sequelae such as corneal ulcers, punctate keratopathy, abrasions and scarring.<sup>4</sup> The quality of these patients' vision, as well as the ocular surface, can be severely impacted in these cases, so it is imperative to be aware of misdirected lashes when evaluating ocular health. Because some patients may be asymptomatic, clinicians must have astute observation skills.

## Entropion

During the initial assessment of the ocular health, you may notice inward turning of the eyelid. If you do, you must determine if there is only trichiasis (an inward turning of the eyelid margin).

Entropion always presents with trichiasis (assuming the patient has eyelashes), but trichiasis can

occur without entropion. Due to the frictional forces that occur with blinking, both conditions can cause significant punctate erosions on the cornea, which may cause the patients to present with complaints of redness, foreign body sensation, irritation and tearing.

The ocular surface and pathologic eyelid findings associated with involutional entropion include lateral canthal tendon laxity (78%), dry eye (72%), superficial punctate keratopathy (62%), lower retractor laxity (53%), chronic blepharitis (49%), chronic conjunctivitis (23%), and medical canthal tendon laxity (15%).<sup>3</sup>

## Ectropion

On the other hand, during examination you may notice an outward turning of the eyelid (ectropion). This has several possible causes, but an age-related or involutional etiology is the most common. Like involutional entropion, ectropion has a gender bias as well. Older males are more likely to be afflicted with involutional ectropion.<sup>3</sup>

Because of the ectropion, you may notice punctate epithelial erosions secondary to rapid tear evaporation and chronic exposure of the ocular surface. Ocular surface and eyelid abnormalities associated with involutional ectropion include lateral canthal tendon laxity (80%), dry eye (52%), chronic blepharitis (43%),



Earn up to  
**18-28 CE**  
Credits\*

**REVIEW GROUP**  
VISION CARE EDUCATION, LLC

NEW TECHNOLOGIES  
& TREATMENTS IN  
**2019 EYE CARE**



Join us for our  
**2019 MEETINGS**



**FEBRUARY 15-19, 2019 - ASPEN, CO**

**Annual Winter Ophthalmic Conference**

Westin Snowmass Conference Center

Program Co-chairs: Murray Fingeret, OD, and Leo Semes, OD

**REGISTER ONLINE:** [www.skivision.com](http://www.skivision.com)



**MARCH 7-10, 2019 - ORLANDO, FL**

Disney Yacht & Beach Club

Program Chair: Paul Karpecki, OD, FAAO



**APRIL 11-14, 2019 - SAN DIEGO, CA\*\***

Manchester Grand Hyatt

Program Chair: Paul Karpecki, OD, FAAO



**May 17-19, 2019 - NASHVILLE, TN**

Gaylord Opryland

Program Chair: Paul Karpecki, OD, FAAO



**NOVEMBER 1-3, 2019 - BALTIMORE, MD**

Renaissance Baltimore Harborplace

Program Chair: Paul Karpecki, OD, FAAO

Visit our website for the latest information: [www.reviewsce.com/events](http://www.reviewsce.com/events)  
e-mail: [reviewmeetings@jhihealth.com](mailto:reviewmeetings@jhihealth.com) or call: 866-658-1772

Administered by

**Review Group Vision Care Education, LLC**



\*Approval pending



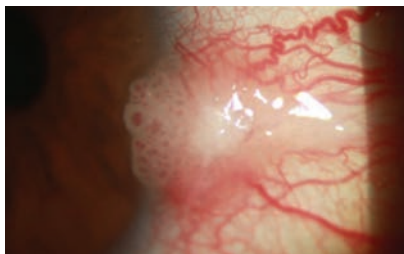
Pennsylvania College of Optometry



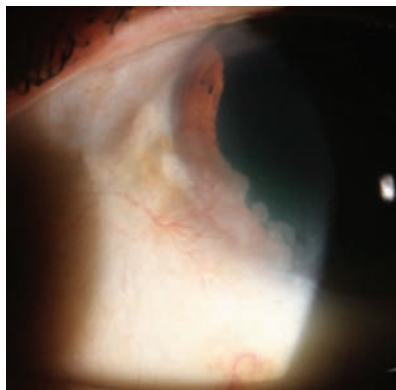
\*\*16th Annual Education Symposium  
Joint Meeting with NT&T in Eye Care

Review Group Vision Care Education, LLC partners with Salus University for those ODs who are licensed in states that require university credit.  
See [www.reviewsce.com/events](http://www.reviewsce.com/events) for any meeting schedule changes or updates.





**Above, this patient has a pink, raised, limbal lesion extending over the cornea with tortuous dilated feeder vessels and keratinized central surface plaque. In addition, corkscrew vessels are seen, giving the lesion a strawberry-like appearance. The patient at right portrays an opalescent cornea from 7 o'clock to 9 o'clock with feeder vessels.**



chronic conjunctivitis (40%), lower retractor laxity (40%).<sup>3</sup>

## Punctal Stenosis

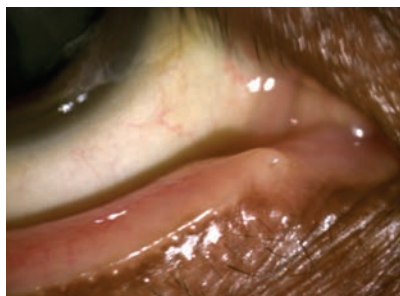
Punctal stenosis may be easy to overlook during the clinical exam—in fact, if you quickly gloss over the punctum during your biomicroscopic exam, stenosed or closed puncta may not even be observed. However, in patients older than 80, it is common.

Clinically, patients are diagnosed with dry eye disease due to their epiphora complaints; however, instilling artificial tears in a patient with punctal stenosis only exacerbates their complaints. In cases such as these, it is best to observe a stenosed puncta when the patient has complaints of epiphora. Interestingly, punctal stenosis, also known as external punctal stenosis (EPS), results from one of two possible etiologies, acquired and age-related. Acquired causes can be due to topical or systemic medication use, various infections, lid malposition, trauma or tumors.<sup>5-7</sup> Age-related changes are mostly due fibrosing of the tissue surrounding the puncta.<sup>8</sup>

In cases of acquired punctal

stenosis, practitioners should be aware of the possible relationship between EPS and long-term use of topical anti-glaucoma medications. Because practitioners commonly encounter patients with ectropion, they should also be aware of the relationship between ectropion and punctal stenosis. It has been postulated that the cause of punctal stenosis in relationship to lid ectropion is due to underuse of an external punctum unopposed to the tear meniscus or secondary to inflammation.<sup>9</sup>

Patients with punctal stenosis may also present with dry eye disease. Punctal plugs are commonly used in the management of patients with dry eye disease. Clinically, stenosed puncta function similarly to punctal plugs, so patients, especially the elderly, may benefit from having stenosed puncta. One study suggested not to promote surgical intervention in cases of punctal stenosis in order to

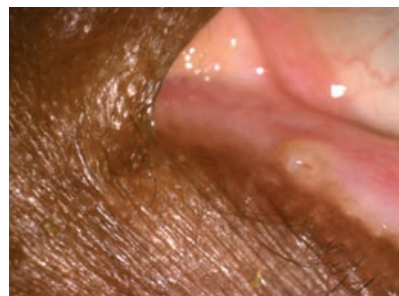

prevent disruption of the suspected protective mechanism.<sup>10</sup> However, practitioners should remember that punctal plugs and stenosed punctum may be contraindicated in cases of inflammatory-based dry eye disease due to the possibility of exacerbating the condition from retained inflammatory cytokines in the tear film.

## Blepharitis and Demodicosis

Meibomian gland dysfunction (MGD) plays a major role in ocular surface pathology. Terminal duct obstruction and qualitative as well as quantitative changes in the glandular secretion result in altered tear film.

The spectrum and severity of the signs associated with blepharitis depends on the location and the degree of inflammation. In one form of anterior blepharitis, the skin of the eyelids, the base of the eyelashes, and the eyelash follicles are affected by *Staphylococcus*, leading to scaling, crusting and erythema of the eyelid margin with collarette formation at the base of the cilia, which can cause eyelash loss and corneal punctate epithelial erosions, marginal infiltrates and neovascularization. In the seborrheic type of anterior blepharitis, greasy, foamy scales called scurf surround the bases of the cilia. The patient may also present with signs of both types as well as with co-existing meibomianitis.<sup>11</sup>



**This patient displays punctal stenosis in both the right (at left) and left eyes.**

In posterior blepharitis, the inflammation affects the meibomian glands and their orifices. Prominent blood vessels crossing the mucocutaneous junction, frothy discharge along the eyelid margin, pouting or plugging of meibomian orifices, expression of meibomian secretions that range from turbid fluid to thick, cheese-like material, thickening and scalloping of the eyelid margin, trichiasis and chalazia may all be observed.<sup>11</sup>

Ocular demodicosis, characterized by cylindrical dandruff around the root of the eyelashes, is often associated with blepharitis, chalazia and keratitis.<sup>12</sup> Both *Demodex follicularum* and *Demodex brevis* can cause chronic and recurrent inflammation of the eyelid margin, as well as trichiasis, distichiasis and madarosis.<sup>12</sup> While the larger *D. follicularum* mites congregate in the hair follicles, the smaller *D. brevis* mites reside in the sebaceous glands.<sup>12</sup>

### Dry Eye Disease

In 2017, the Tear Film & Ocular Surface Society's International Dry Eye Workshop II set out to create an evidence-based definition and a contemporary classification system for dry eye disease.<sup>1</sup> As a result, the following definition was accepted:

*"Dry eye is a multifactorial disease of the ocular surface characterized by a loss of homeostasis of the tear film, and accompanied by ocular symptoms, in which tear film instability and hyperosmolarity, ocular surface inflammation and damage, and neurosensory abnormalities play etiological roles."*<sup>1</sup>

Clinical signs include diffuse conjunctival hyperemia as well as corneal punctate epithelial erosions. Tissue staining with fluorescein, lissamine green or rose bengal are clinically beneficial in determination of the severity of ocular surface dryness.

### Conjunctivochalasis

Conjunctival folds, also known as conjunctivochalasis (CCH), are more prevalent in the elderly, and only increase with age.<sup>13-15</sup> Patients with CCH may experience epiphora or dry eye disease symptoms such as irritation, burning and foreign body sensation.<sup>16-18</sup>

Clinically, you should look for a delayed tear clearance and tear film instability. Due to anatomical obstruction of the punctum by the redundant conjunctival folds, destruction of the lacrimal lake and impediment of the tear flow by the conjunctival folds, the patient may experience delayed tear clearance.<sup>19-23</sup> As the flow of tears is impeded, the conjunctival folds cause instability of the tear film, which can lead to ocular surface inflammation.<sup>18,19,24</sup>



# NuLids™ transformational dry eye therapy

Transforms your patients' lives



Finally... A doctor-directed at-home treatment for dry eye disease that is safe, effective and easy to use.

A multi-center study<sup>1</sup> showed:

- 50% decrease in dry eye symptoms
- 65% improvement in TBUT
- 80% increase in meibomian glands yielding liquid secretions.

For more information visit  
[www.NuSightMedical.com/ropt11](http://www.NuSightMedical.com/ropt11)  
or call us at 833-368-5437



<sup>1</sup> Schanzlin, Olkowski, Coble, Gross. NuLids II Study, April 2018



NuLids™

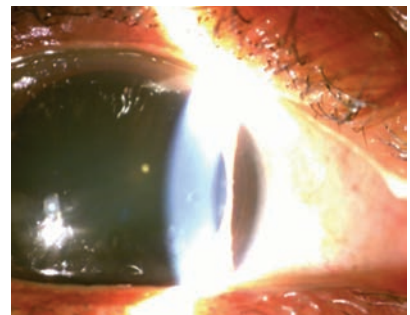
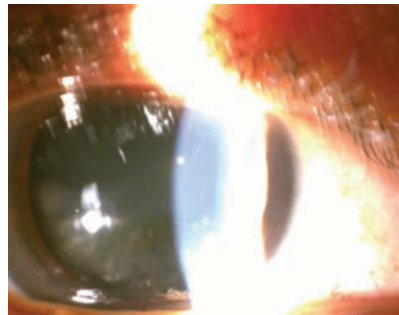
Doctor prescribed, at-home dry eye relief

The clinical suspicion of conjunctival folds is confirmed by biomicroscopic examination and use of vital dyes. While examining the anterior segment with the slit lamp, you may find redundant conjunctival folds over the inferior eyelid margin, which move with blinking. During your clinical exam, you can change the appearance of the folds based on how you manipulate the eyelids. If you press upward on the lower lid, you'll notice worsening of the folds. Conversely, pulling the lid away from the globe while the patient looks up will cause the folds to disappear.<sup>18</sup>

Vital dyes can help the clinician further assess the redundant folds as well as the tear film. Fluorescein staining will show the classic pre-corneal tear film as well as punctate erosions. Additionally, it will show the folds along with the interrupted or decimated tear meniscus. Unlike dry eye disease where rose bengal and Lissamine green reveal staining in the exposure zone of the conjunctiva, these two dyes will stain non-exposure zones of the conjunctiva as well as detect punctate erosions over the redundant conjunctival folds.<sup>18</sup>

## Pinguecula, Pterygium and Squamous Neoplasia

Approaching the limbus while scanning the nasal and temporal bulbar conjunctiva within the palpebral fissure, the clinician will often observe a round, yellowish elevation. Pinguecula, which is more commonly found on the nasal aspect of the limbus, is a condition of abnormal differentiation characterized by squamous metaplasia with proliferation.<sup>25</sup> While the condition is benign, its presence results in tear film instability that may lead to symptoms of irritation and signs of inflammation.



Here, a patient shows map-dot-fingerprint dystrophy.

Another commonly encountered finding in the nasal limbal area, especially in patients exposed to UV radiation, is a pterygium.<sup>26</sup> This wing-like hypertrophy of the subconjunctival connective tissue and overlying epithelium drags the conjunctival vessels as it crosses the limbus and approaches the visual axis. These lesions may be thin and flat or elevated and gelatinous. They may be quiet or inflamed. Stocker's line, a punctate, brownish subepithelial iron line passing vertically in front of the invasive apex of the pterygium, may often be observed and is a sign of chronicity.<sup>27</sup> Pterygia may induce astigmatism, decrease visual acuity as they obscure the visual axis, cause symptoms of irritation when inflamed, and be cosmetically displeasing to the patient.

It is important to examine limbal lesions closely to differentiate them from ocular surface squamous neoplasia (OSSN). A pink, gelatinous lesion along the limbus with tortuous, dilated feeder vessels and sometimes with keratinized plaques on its surface is likely to be a form of OSSN.<sup>28</sup> These typically show abrupt onset and rapid progression may present as opalescence on the cornea or chronic conjunctivitis.<sup>28</sup>

## Ocular Surface Conditions

Disruption to the ocular surface has various etiologies. Because treat-

ment of each etiology varies, it is imperative for the practitioner to carefully evaluate the ocular surface and the cause of damage to the surface before initiating treatment. Corneal epithelial defects are a frequent cause of ocular irritation, foreign body sensation, tearing, pain, redness and, quite possibly, photophobia. While performing biomicroscopy, the astute clinician may detect corneal irregularities beneath the epithelial layer. With the use of sodium fluorescein, the practitioner may notice negative staining on the cornea, which helps to delineate the corneal irregularities commonly associated with epithelial basement membrane dystrophy (EBMD), also known clinically as anterior basement membrane dystrophy or map-dot-fingerprint dystrophy.

It is not uncommon for the clinician to notice corneal irregularities during biomicroscopy or decreased visual acuity because of a compromised ocular surface. If you suspect EBMD, ask the patient if they have ever had symptoms of recurrent corneal erosion (RCE), because approximately 10% of EBMD patients experience symptoms of pain or decreased vision secondary to corneal surface irregularity.<sup>29,30</sup> Ocular surface dryness can have a tremendous impact on patients with EBMD, as they are highly likely to rub their epithelial surface off if they rub their eye aggressively



or have their epithelial surface adhere to their superior palpebral conjunctival when they open their eyes in the morning. Because EBMD patients are at increased risk of RCE due to their corneal irregularities, judicious use of artificial tears, lubricating ointment or 5% NaCl ointment at bedtime may help minimize the risk of erosion. ■

*Dr. Demeritt is an assistant professor at Nova Southeastern University College of Optometry.*

*Dr. Lewandowska is an assistant professor at Nova Southeastern University College of Optometry.*

1. Craig J, Nichols K, Akpek E, et al. TFOS DEWS II Definition and Classification Report. *Ocul Surf.* 2017;15:276-283.
2. Hintschich C. Correction of entropion and ectropion. *Dev Ophthalmol.* 2008;41:85-102.
3. Damasceno R, Osaki M, Dantas P, Belfort R. Involitional entropion and ectropion of the lower eyelid: prevalence and associated risk factors in the elderly population. *Ophthalmic Plast Reconstr Surg.* 2011;27(5):317-20.
4. Choo P. Distichiasis, trichiasis, and entropion: advances in management. *Int Ophthalmol Clin.* 2002 Spring;42(2):75-87.
5. Seiff S, Shorr N, Adams T. Surgical treatment of punctal canalicular fibrosis from 5 fluorouracil therapy. *Cancer.* 1985;56(8):2148-9.
6. Tabbara, K. F., & Bobb, A. A. (1980). Lacrimal system complications in trachoma. *Ophthalmol.* 1980;87(4):298-301.
7. Brink H, Beex L. Punctal and canalicular stenosis associated with systemic fluorouracil therapy. *Documenta Ophthalmologica.* 1995;90(1):1-6.
8. Kristan R. Treatment of lacrimal punctal stenosis with a one-snip canaliculotomy and temporary punctal plugs. *Arch Ophthalmol.* 1988;106(7):878-9.
9. Soiberman U, Kakizaki H, Selva D, Leibovitch I. Punctal stenosis: definition, diagnosis, and treatment. *Clin Ophthalmol.* 2012;6:1011-8.
10. Ulusoy M, Kivanc S, Atakan M, Akova-Budak B. How important is the etiology in the treatment of epiphora? *Journal of Ophthalmology.* [www.hindawi.com/journals/joph/2016/1438376/](http://www.hindawi.com/journals/joph/2016/1438376/).
11. American Academy of Ophthalmology (AAO) Cornea/External Disease Preferred Practice Pattern Panel. Preferred practice pattern guidelines. Blepharitis. [www.aao.org/preferred-practice-pattern/blepharitis-ppp--2013](http://www.aao.org/preferred-practice-pattern/blepharitis-ppp--2013). October 2013. Accessed October 24, 2018.
12. Luo X, Li J, Chen C, et al. Ocular demodicosis as a potential cause of ocular surface inflammation. *Cornea.* 2017;36:S9-S14.
13. Hashemi H, Rastad H, Emamian M, Fotouhi A. Conjunctivochalasis and related factors in an adult population of Iran. *Eye & contact lens.* 2018;44:S206-S209.
14. Watanabe A, Yokoi N, Kinoshita S, et al. Clinicopathologic study of conjunctivochalasis. *Cornea.* 2004;23(3):294-8.
15. Zhang X, Li Q, Zou H, et al. Assessing the severity of conjunctivochalasis in a senile population: a community-based epidemiology study in Shanghai, China. *BMC Public Health.* 2011;11(1):198.
16. Balci O. Clinical characteristics of patients with conjunctivochalasis. *Clin. Ophthalmol.* 2014;8:1655-60.
17. Chhadva P, Alexander A, McClellan A, et al. The impact of conjunctivochalasis on dry eye symptoms and signs. *Invest Ophthalmol Vis Sci.* 2015;56(5):2867-71.
18. Meller D, Tseng S. Conjunctivochalasis: literature review and possible pathophysiology. *Survey of ophthalmology.* 1998;43(3):225-32.
19. Di Pascuale M, Espana E, Kawakita T, Tseng S. Clinical characteristics of conjunctivochalasis with or without aqueous tear deficiency. *Bri J Ophthalmol.* 2004;88(3):388-92.
20. Erdogan-Poyraz C, Mocan M, Irkeç M, Orhan M. Delayed tear clearance in patients with conjunctivochalasis is associated with punctal occlusion. *Cornea.* 2007;26(3):290-3.
21. Huang Y, Sheha H, Tseng S. Conjunctivochalasis interferes with tear flow from fornix to tear meniscus. *Ophthalmol.* 2013;120(8):1681-7.
22. Liu D. Conjunctivochalasis. A cause of tearing and its management. *Ophthalmic plastic and reconstructive surgery.* 1986;2(1):25-8.
23. Prabhasawat P, Tseng S. Frequent association of delayed tear clearance in ocular irritation. *Bri J Ophthalmol.* 1998;82(6):666-75.
24. Yokoi N, Komuro A, Nishii M, et al. Clinical impact of conjunctivochalasis on the ocular surface. *Cornea.* 2005;24(8):S24-S31.
25. Dong N, Li W, Lin H, et al. Abnormal epithelial differentiation and tear film alteration in pinguecula. *Invest Ophthalmol Vis Sci.* 2009;50(6):2710-5.
26. Moran D, Hollows F. Pterygium and ultraviolet radiation: a positive correlation. *Bri J of Ophthalmol.* 1984;68(5):343-6.
27. Hansen A, Norm M. Astigmatism and surface phenomena in pterygium. *Acta ophthalmologica.* 1980;58(2):174-81.
28. Cicinelli M, Marchese A, Bandello F, Modorati G. Clinical management of ocular surface squamous neoplasia: A review of the current evidence. *Ophthalmol Ther.* [link.springer.com/article/10.1007/s40123-018-0140-z](http://link.springer.com/article/10.1007/s40123-018-0140-z). July 20, 2018. Accessed October 24, 2018.
29. Waring III G, Rodrigues M, Laibson P. Corneal dystrophies. I. Dystrophies of the epithelium, Bowman's layer and stroma. *Surv ophthalmol.* 1978;23(2):71-122.
30. Werblin T, Hirst L, Stark W, Maumenee I. Prevalence of map-dot-fingerprint changes in the cornea. *Bri J Ophthalmol.* 1981;65(6):401-9.

# NuLids™ transformational dry eye therapy

## Transforms your practice

The NuLids System helps reduce patient out-of-pocket expenses while creating an additional revenue stream for the practice – all without impacting overhead costs or disrupting other in-office treatments.

A multi-center study<sup>1</sup> showed 95% were satisfied or very satisfied with the treatment.

For more information visit  
[www.NuSightMedical.com/ropt11](http://www.NuSightMedical.com/ropt11)  
or call us at 833-368-5437

<sup>1</sup> Schanzlin, Olkowski, Coble, Gross. NuLids II Study, April 2018



**NuLids™**

*Doctor prescribed, at-home dry eye relief*



# Familiarize Yourself with Point-of-care Tools for Dry Eye

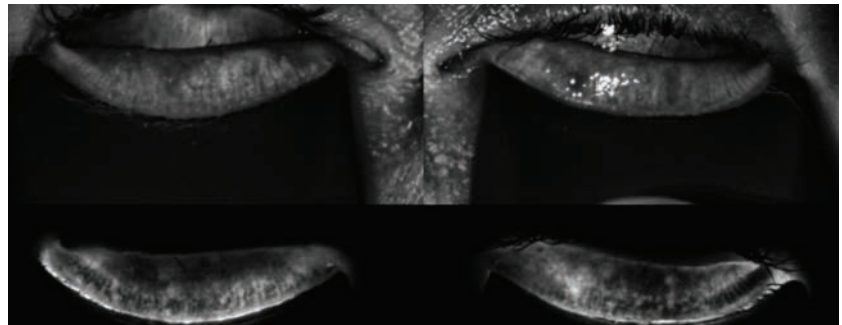A plethora of new tools are rewriting the anterior segment disease monitoring protocol.

By Suzanne Sherman, OD, and Fiza Shuja, OD

**M**eibomian gland dysfunction and tear film insufficiency can severely affect the ocular surface and, if not addressed, can make treatment difficult.<sup>1</sup> But any management is dependent upon proper disease identification, which can be tricky with the varied presentations of conditions such as dry eye disease (DED), meibomian gland dysfunction (MGD), allergic conjunctivitis and viral conjunctivitis.

Point-of-care (POC) testing allows diagnostic equipment to aid the ophthalmic exam and to facilitate optimal patient care while reducing patient cost and the optometrist's time.<sup>2</sup> These tests, however, can only help when the clinician understands the nature of these tests and how to use them for best patient care.

POC testing provides quick diagnosis and rapid treatment.<sup>3</sup> Nevertheless, they are only adjunctive tests meant to complement a clinical exam that includes patient history, slit lamp evaluation and dilated fundus exam. This article



The LipiScan image shows the meibomian glands using near infrared illumination in a quick, noninvasive, in-office test.

provides a guide on what POC tests are available for patients with ocular surface conditions, when to apply them and how to incorporate them into your standard testing protocol to assure your patients are diagnosed accurately and monitored regularly.

## Meibomian Glands


According to the recent publication in the 2017 Tear Film and Ocular Surface Society DEWS II report, dry eye is “a multifactorial disease of the ocular surface characterized by loss of homeostasis of the tear film, and accompanied by ocular symptoms, in which tear film insta-

bility and hyperosmolarity, ocular surface inflammation and damage, and neurosensory abnormalities play etiological roles.”<sup>4</sup>

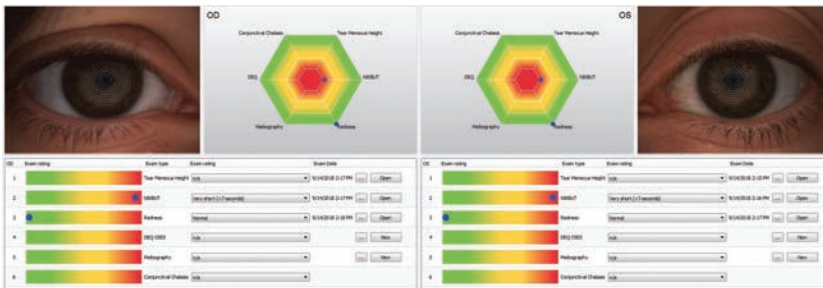
Any clinical exam used in conjunction with POC testing must focus on distinguishing what amount of their disease is evaporative in nature—such as MGD—and what amount stems from aqueous deficiency.<sup>4</sup> Prior to this recent publication, researchers suggested that these two types of dry eye did not overlap, but that thinking has since been turned on its head.<sup>4</sup> However, POC testing can provide the kind of information that can guide an optometrist's next step. One exam-



# S4OPTIK ANTARES



The Keratograph 5M (Oculus) is a multi-functional, noninvasive, in-office device that can provide information about meibomian glands and the tear film. It also offers advanced placido ring corneal topography with a built-in real keratometer with a color camera included for external imaging.



ple is the state of the meibomian glands. MGD can result in alteration of the tear film, symptoms of eye irritation, clinically apparent inflammation and ocular surface disease. Fluorescein staining, tear break-up time and clinical imaging of the glands will give the practitioner a hint about the root of the patient's symptoms.


Meibography has become a critical tool in how optometrists diagnose and treat MGD. Tools like these can help establish the patient's level of gland atrophy and help the clinicians determine whether treatments such as a warm compresses will suffice, or if their disease is too far progressed for that kind of solution.

LipiScan (TearScience) provides a noninvasive image of the glands in 10 seconds. The glands are imaged using near infrared illumination from multiple light


sources, minimizing reflection and modifying the light intensity across the surface to compensate for lid thickness variations.<sup>5</sup>

The LipiView II (TearScience) offers the same high definition imaging along with new functions, including real-time visualization of the lipid layer to evaluate the dynamic response of lipids to blinking, noise canceling technology to measure submicron thickness of the lipid layer and video analysis of blink dynamics. Unlike the LipiScan, the LipiView does not have a screen monitor attached. To display the results on a screen for patients, an extra monitor needs to be attached.

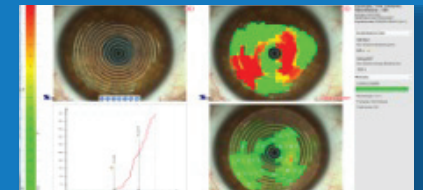
Meibox (Box Medical Solutions) is a portable slit-lamp mounted meibographer compatible with more than 35 slit lamp models. The Meibox offers image processing, which includes dynamic



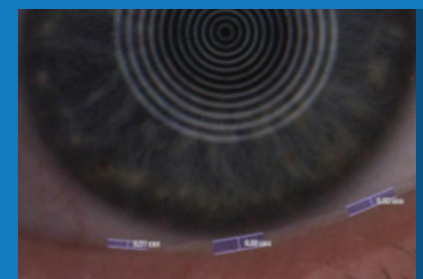
## Corneal Topography & More!



## Meibomian Gland Imaging & Analysis



## Non-Invasive Tear Film Break-up Analysis



## Tear Meniscus Height

# S4OPTIK

250 Cooper Ave., Suite 100 Tonawanda NY 14150

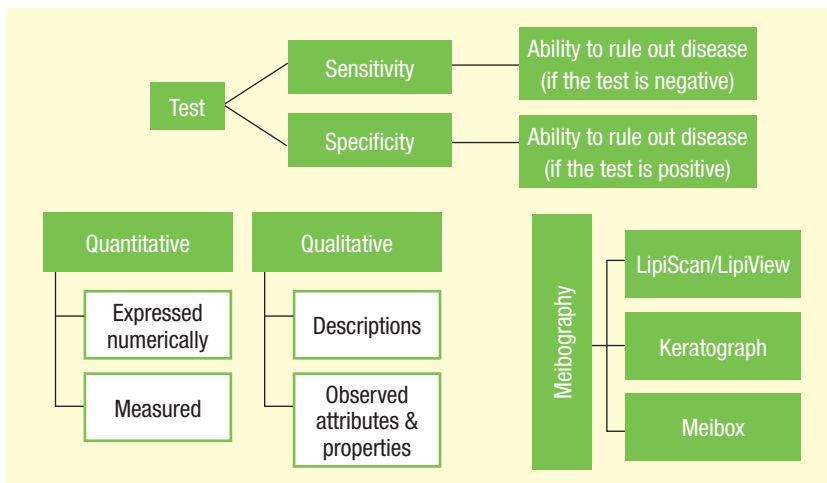
[www.s4optik.com](http://www.s4optik.com) | 888-224-6012

Sensible equipment. Well made, well priced

For today's modern office.



# Diagnostic Testing



**These flowcharts are designed to help guide clinicians in the terminology and use of point-of-care tests.**

images that enhance the outlines of the meibomian glands. The images are stored on cloud-based software and can be accessed anywhere. The Meibox can be attached to your computer via a USB cord. Similar to LipiScan and LipiView, Meibox is technician friendly, and due to its portability, technicians can bring the Meibox to the patient, reducing chair time.

The Keratograph 5M (Oculus) provides information about both the meibomian glands and the tear film as well as advanced placido ring corneal topography, with a built-in keratometer and a color camera included for external imaging.<sup>6</sup> Its Meibo-Scan software uses infrared light to image the meibomian glands in high definition. Tear film dynamics are measured with white light, and a quantitative measurement of the tear meniscus height and the non-invasive tear breakup time.

Along with the tear meniscus height and non-invasive tear breakup time, a lipid layer interference and particle flow assessment are available. The particle flow assessment measures the tear

film particle velocity by tracking the reflective particles in the tear film. The Keratograph uses blue diodes for fluo-images, which can be used for documentation of your slit lamp fluorescein exam. After the Keratograph has collected this data, it offers a final report that offers visual pie graphs, explanations and abbreviations the patient will understand.

## Osmolarity

Tear osmolarity is the central pathophysiologic mechanism for all forms of dry eye disease.<sup>4</sup> It reduces the ability of mucins to lubricate due to inflammation and cell apoptosis. This ultimately leads to breakdown of homeostatic control and eventually causes tear film instability.<sup>7</sup>

The Tearlab Tear Osmolarity system has 88% specificity and 75% sensitivity in detecting mild to moderate dry eye disease, and 95% sensitivity in detecting severe dry eye disease, according to the manufacturer.<sup>8</sup> The DEWS II section on tear osmolarity reports that new questions arise about the variability of the current measure-

ment technique with TearLab. Various cut-off values have been reported in the literature ranging from 305mOsm/L all the way to 316mOsm/L, as well as a variety of sensitivities, specificities and positive predictive values have been published, which differ from the manufacturer's data.<sup>4</sup>

Even though we are still learning and researching the proper way to measure tear osmolarity, TearLab Osmolarity System gives us objective quantitative measurements that allow practitioners to follow appropriate dry eye management in office.

Another option to test tear osmolarity is the I-Pen (I-Med Pharma). That device employs single-use sensors to gather a sample with approximately two to five seconds of contact with the tear-soaked palpebral conjunctiva, rather than a liquid sample as the TearLab system uses. This may be appropriate for patients with severe dry eye as it may be difficult to obtain a tear sample from them. Once a sample is obtained, the I-Pen measures the electrical impedance in the tear-soaked tissues and calculates the osmolarity of the tear film.<sup>9</sup>

## MMP-9

Usually, dry eye treatment involves artificial tears and, possibly, punctal plugs. But if the patient has an inflammatory component, practitioners need to think twice about plugs and instead consider anti-inflammatory agents. The MMP-9 Rapid Pathogen Screening InflammDry test (Quidel) is a non-specific measure of the presence of matrix metalloproteinase-9 (MMP-9), an enzyme that is elevated in dry eye patients.<sup>10</sup> MMP-9 testing should be performed before administering ocular anesthetic, topical

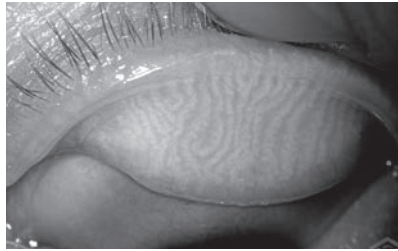
dyes or Schirmer test. Tear samples are collected from the palpebral conjunctiva with a sample collector fleece. When it starts to glisten, this indicates that the sample fleece is saturated. This is then placed within the test cassette with the addition of buffer solution.

If there is an MMP-9 antibody-antigen interaction on the immunoassay test strip, the result window will read positive with two lines (one blue and one red) within 10 minutes. This is the qualitative result (yes or no). According to the manufacturer, the intensity of the red lines should be directly related to the amount of MMP-9 present.<sup>8</sup> The lower detection limit is 40ng/ml, which means that at 40ng/ml, 100% of people will see a positive result. Between 30ng/ml to 40ng/ml, a significant number of patients will be perceived as positive, with more faint positive lines. A negative result will only show a blue line present.<sup>8</sup>

Studies suggest that MMP-9 presence or absence tell you whether or not a patient will respond to treatment with cyclosporine, doxycycline or steroids, helping reach a more efficient treatment plan with patients.<sup>11,12</sup>

### Viral Infection

Conjunctivitis affects approximately six million Americans annually.<sup>13</sup> The common presentation and symptom of “red eye” requires clinicians to include conjunctivitis in their list of differentials, while also making sure to rule out other etiologies, such as dry eye and uveitis.<sup>13</sup> Viral conjunctivitis, unlike bacterial conjunctivitis, can present with varied symptoms that coincide with other diseases, even bacterial or allergic conjunctivitis.<sup>13</sup> A timeline of symptoms should be noted in the patient history to ensure accurate diagnosis.

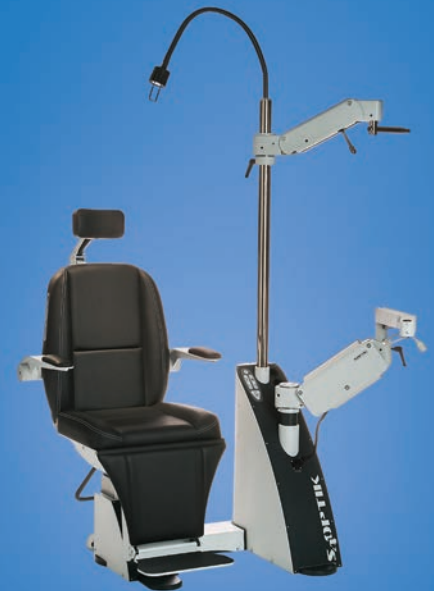

**The Meibox produces enhanced images of the meibomian glands that can be stored on cloud-based software for access from any location.**

A viral etiology can comprise 20% to 70% of infectious conjunctivitis, with adenovirus comprising 60% to 90% of the causes.<sup>14</sup> Adenovirus can cause pharyngoconjunctival fever, epidemic keratoconjunctivitis, acute nonspecific follicular conjunctivitis and chronic keratoconjunctivitis.<sup>15</sup> Research shows misdiagnosis of conjunctivitis is extremely common amongst clinicians.<sup>15</sup> The similarities in signs and symptoms are often to blame for the incorrect diagnoses, leading to inappropriate treatment, prolonging and spreading the disease. It is always important to watch for the hallmark signs of the disease, such as serous discharge, chemosis, pseudomembranes or a follicular reaction.<sup>15</sup> Viral conjunctivitis can also be accompanied by preauricular lymphadenopathy, which clinicians can easily test for in-office.

Viral conjunctivitis can take longer to culture for a definitive diagnosis. Laboratory testing for the adenovirus is not commonly used, however, because of the delay in obtaining results; viral cell culture with confirmatory immunofluorescence assay (CC-IFA) need to be evaluated over a 14-day growth period.<sup>13</sup> Polymerase chain reaction (PCR) is increasingly used more often because it has higher sensitivity than CC-IFA and can produce results in four hours, but

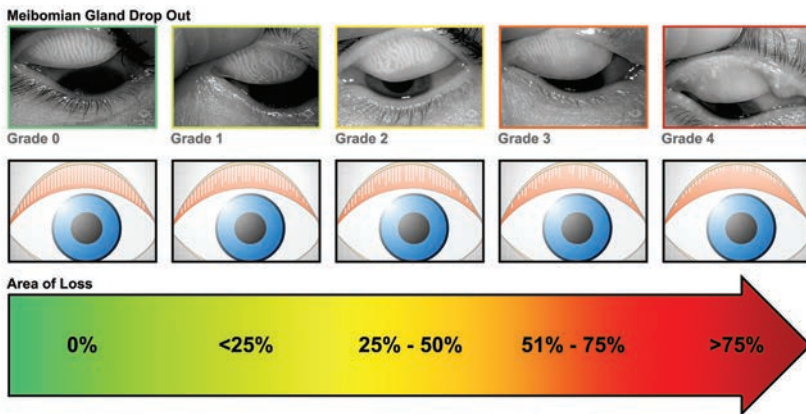
## Optimize space and functionality.



## Affordable, space-saving chair & stand solutions.

Small footprint  
41.2" x 34.2"

# Diagnostic Testing



The Meibox device helps physicians determine the grade of gland drop out in MGD.

still requires a laboratory to analyze the test sample.<sup>14</sup> The difficulty with CC-IFA, PCR and antigen testing, such as enzyme immunoassays, is the laboratory service. Most clinicians either do not have labs within their office or do not have access to labs that can deliver results as quickly as required for accurate diagnosis. Because these tests require multiple steps, a CLIA waiver cannot be obtained for in-office testing.

There is, however, the FDA approved and CLIA waived Adeno-Plus (Quidel). The practitioner cost is estimated at \$105 per box, with 10 tests per box. The test uses immunoassay technology and delivers results within 10 minutes.<sup>13,14</sup> Tear fluid is taken from the inferior palpebral conjunctiva and placed onto a sample collector, which is transferred to a test strip. The strip is dipped into a buffer that allows the antigens to bind to the antibodies, resulting in either a positive or negative result.

Reading the test is also simple because it displays one line for a negative result and two lines for a positive result, a similar reading like the ones found in pregnancy tests. The process is said to be able to identify the 53 serotypes of adenovirus.<sup>13</sup>

## Allergic Conjunctivitis

Ocular allergy is an inflammatory disease that affects the ocular surface. It can be divided into four categories: allergic conjunctivitis (including seasonal and perennial), atopic keratoconjunctivitis (AKC), vernal keratoconjunctivitis (VKC) and giant papillary conjunctivitis (GPC).<sup>15</sup> The latter three are more severe forms of the disease.

Type 1 hypersensitivity reactions more commonly occur, wherein an offending antigen triggers the allergy cascade. The early-phase reaction occurs with the release of chemical mediators, including histamine, leukotriene and prostaglandin, into the conjunctiva after degranulation of mast cells.<sup>16</sup> This is where mast cell stabilizers, (e.g., Pataday, Zaditor) and antihistamine agents (e.g., Azelastine, Bepreve, Lastacast) treat the disease process. The late-phase reaction occurs with the presence of eosinophils and type 2 helper cells.<sup>16</sup> This is treated with corticosteroids and immunosuppressive agents.

Determining the presence of the chemical mediators and cells present in the conjunctiva is key to appropriately treating the disease. The need to test for specific biomarkers on the ocular surface aids in identifying the target area for treatment and improved patient care.

The IgE-mediated response in the conjunctiva is well documented in allergic conjunctivitis, vernal and atopic keratoconjunctivitis.<sup>17</sup> With vernal, there is greater involvement by T-cells, eosinophils and cytokines. Atopic keratoconjunctivitis also has T-cell participation, with more TH1-mediated cells.

Advanced Tear Diagnostics has produced a microassay test called Tear Scan that can specifically test for IgE and lactoferrin.<sup>17</sup> The test checks for total IgE antibodies in the tear sample. A 0.5µl tear sample mixed with a diluent is placed on the test strip, and after approximately three minutes, the test results can be evaluated. This is beneficial in obtaining an appropriate diagnosis for a patient's symptoms, ruling out aqueous dry eye disease as a potential diagnosis, leading to appropriate treatment.

The second portion of the Tear Scan microassay system evaluates lactoferrin, a protein with antibacterial, antiviral, antifungal and antiparasitic properties found in a variety of human fluids, including tears.<sup>18</sup> The main lacrimal gland secretes a majority of lactoferrin, but ocular epithelial cells and meibomian glands are also contributors.<sup>18</sup> An average lactoferrin amount is approximately 1.42mg/ml. Over time, with age and conditions such as dry eye, keratitis and conjunctivitis, a person's naturally produced ocular lactoferrin decreases.<sup>19</sup> The loss of lactoferrin causes greater susceptibility to infections.<sup>19</sup> The Tear Scan microassay for lactoferrin has a similar protocol to the IgE test.<sup>17</sup> A 0.5µl sample of tear fluid is mixed with a diluent, shaken and deposited into a well. The microassay then measures the amount of lactoferrin. Any amount lower than 1.4mg/ml is considered abnormal.<sup>20</sup>



The ability to test for both IgE and lactoferrin in combination allows for better diagnosis of aqueous deficient dry eye excluding or including ocular allergy. Being able to diagnose both conditions allows for a better approach to treatment because now treatment can be initiated for each disease.

The Ocular Allergy Diagnostic System-Doctor's Rx (Bausch + Lomb) offers another in-office test for allergy testing.<sup>21</sup> The Doctor's Rx is FDA approved and can be billed to insurance. It is a noninvasive, requires no needles and responds to at least 58 allergens, according to B+L.<sup>21</sup> The test involves a plastic applicator that is applied to the patient's forearm, but it does not prick or draw blood. The test takes three minutes to perform and provides results within 15 minutes. Testing for allergens, especially those specific to a region, makes it easier to identify an appropriate treatment course and how to remove the offending agent. This will only increase improvement in patient care and satisfaction.

### Forego The Lab

As new technologies are developed, practitioners can develop novel ways to treat patients, monitor their compliance and track their outcome. Each of these tests can be performed by the OD—or a properly trained technician, adding efficiency to a busy daily schedule. With these tests, optometrists are no longer limited in our ability to diagnose and monitor by the time constrains and expense of lab testing for our patients' many ocular surface issues. ■

*Dr. Sherman is an instructor in Optometric Science (in Ophthalmology) at Columbia University Medical Center, NY. She specializes*

*in complex and medically necessary contact lens fittings and ocular disease.*

*Dr. Shuja is an optometrist at New York-Presbyterian Hospital.*

1. Scott C, Catania L, Larkin K. Care of the patient with ocular surface disorders. American Optometric Association. [www.aoa.org/documents/optometrists/CPG-10.pdf](http://www.aoa.org/documents/optometrists/CPG-10.pdf). December 2010. Accessed October 23, 2018.
2. Bowling E. How point-of-care diagnostic lab tests help clinical decisions. Optometry Times. [www.optometrytimes.com/modern-medicine-cases/how-point-care-diagnostic-lab-tests-help-clinical-decisions](http://www.optometrytimes.com/modern-medicine-cases/how-point-care-diagnostic-lab-tests-help-clinical-decisions). May 9 2016. Accessed October 23, 2018.
3. Yesterday, Today & Tomorrow: NIH Research Timelines. National Institutes of Health, U.S. Department of Health and Human Services. [www.report.nih.gov/nihfactsheets](http://www.report.nih.gov/nihfactsheets). June 30, 2018. Accessed October 31, 2018.
4. Craig J, Nichols K, Akpek E. TFOS DEWS II Report Executive Summary. The Ocular Surface. Ocul Surf. 2017;15(3):276-83.
5. A Versatile Range of MGD Products Suited to Your Practice. TearScience. [tearscience.com](http://tearscience.com). Accessed October 31, 2018.
6. Oculus, Inc. Oculus Keratograph 5M—Topography Highlights. [www.oculus.de/us/products/topography/keratograph-5m/highlights/](http://www.oculus.de/us/products/topography/keratograph-5m/highlights/). Accessed October 31, 2018.
7. Bowling E. The clinical use of ophthalmic point-of-care diagnostic lab tests. American Academy of Optometry 2014. [www.aaopt.org/docs/default-document-library/as-15-outline.pdf?sfvrsn=85b3f99e\\_0](http://www.aaopt.org/docs/default-document-library/as-15-outline.pdf?sfvrsn=85b3f99e_0). American Academy of Optometry. November 15, 2014. Accessed October 31, 2018.
8. Foulks G, Lemp M, Berg M, et al. TearLab Osmolarity as a biomarker for disease severity in mild to moderate dry eye disease. American Academy of Ophthalmology P0382, 2009. [www.tearlab.com/pdfs/2009%20AAO%20Poster%20Hand-out%20-%20Reduced.pdf](http://www.tearlab.com/pdfs/2009%20AAO%20Poster%20Hand-out%20-%20Reduced.pdf). Accessed October 31, 2018.
9. Hessen M. All about osmolarity. Rev Optom. 2018;155(5):42-8.
10. Sambursky R, Davitt W, Friedberg M, Tauber S. Prospective, multicenter, clinical evaluation of point-of-care matrix metalloproteinase-9 test for confirming dry eye disease. Cornea. 2014;33(8):812-8.
11. Chotikavanich S, de Paiva CS, Li de Q, et al. Production and activity of matrix metalloproteinase-9 on the ocular surface increase in dysfunctional tear syndrome. Invest Ophthalmol Vis Sci. 2009;50:7:3203-9.
12. Gürdal C, Genç I, Saraç O, et al. Topical cyclosporine in thyroid orbitopathy-related dry eye: Clinical findings, conjunctival epithelial apoptosis, and MMP-9 expression. Curr Eye Res. 2010;35:9:771-7.
13. Azari A, Barney N. Conjunctivitis: a systematic review of diagnosis and treatment. JAMA. 2013;310(16):1721-9.
14. Sambursky R, Trattler W, Tauber S, et al. Sensitivity and specificity of the AdenoPlus test for diagnosing adenoviral conjunctivitis. JAMA Ophthalmol. 2013;131:17-22.
15. O'Brien T, Jeng B, McDonald M, Raizman M. Acute conjunctivitis: Truth and misconceptions. Curr Med Res Opin. 2009;25(8):1953-61.
16. Shoji J, Aso H, Inada N. Clinical usefulness of simultaneous measurement of the tear levels of CCL17, CCL24, and IL-16 for the biomarkers of allergic conjunctival disorders. Curr Eye Res. 2017;42(5):677-84.
17. Sanchez-Hernandez, M, Montero J, Rondon C, et al. Consensus document on allergic conjunctivitis. J Invest Allergol Clin Immunol. 2015;25(2):94-106.
18. Rageh A, Ferrington D, Roehrich H. Lactoferrin expression in human and murine ocular tissue. Curr Eye Res. 2016;41(7): 883-9.
19. Rusciano D, Pezzino S, Oliveri M. Age-related dry eye lactoferrin and lactobionic acid. Ophthal Res. 2018;60:94-9.
20. Bethke W. An objective look at dry eye syndrome. Rev Ophthalmol. 2012;19(12):12-3.
21. Doctor's Rx Allergy Formula: Ocular Allergy Diagnostic System. Bausch + Lomb. [www.bausch.com/ecp/our-products/diagnostics/ocular-allergy-diagnostic-system](http://www.bausch.com/ecp/our-products/diagnostics/ocular-allergy-diagnostic-system). Accessed October 31, 2018.

# S4OPTIK

## LCD Visual Acuity System VA-1



### Comprehensive Visual Acuity Solution

- Multiple optotype selections
- All acuity slides presented with ETDRS Spacing
- Contrast sensitivity testing
- Crowding bars (for pediatrics)
- Multimedia system and more!



# S4OPTIK

250 Cooper Ave., Suite 100 Tonawanda NY 14150

[www.s4optik.com](http://www.s4optik.com) | 888-224-6012

Sensible equipment. Well made, well priced.

For today's modern office.

# Master the Maze of Artificial Tears

Having so many choices can be overwhelming, but knowing what each one offers can help you steer patients in the right direction.

By Meaghan Horton, OD, Matt Horton, OD, and Eric Reinhard, OD

**A**lthough the prevalence and incidence of dry eye disease (DED) varies widely due to a lack of standardized testing and criteria, a recent report estimates more than 16 million adults in the United States are diagnosed with DED.<sup>1</sup> Dry eye accounts for almost 25% of medical eye care visits and has been estimated to cost the US healthcare system \$3.84 billion annually—this number increases to \$55.4 billion when considering societal costs.<sup>2-4</sup> While optometrists are fortunate to have an expanding armamentarium, artificial tears remain an integral part of the basic management strategy as a recommended first-line option.<sup>5-7</sup> Although they do not directly address the underlying etiology of dry eye, artificial tears can effectively control symptoms and may be the primary therapeutic component for many with mild or episodic dry eye.<sup>8</sup>

Here, we review the most com-

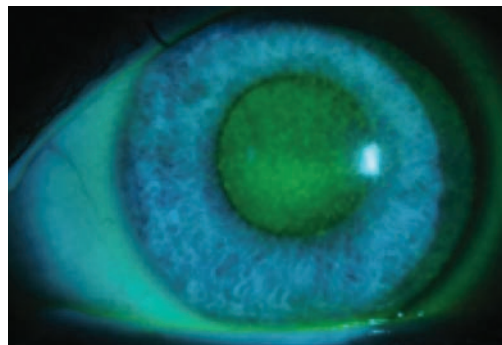


Photo: Christine W. Smith, OD

**This patient has chemical toxicity secondary to multiple topical antimicrobial medications. Clinicians should avoid iatrogenic DED by considering all concurrent ocular drops before recommending a preserved artificial tear.**

mon commercially available artificial tears, the FDA-approved ingredients they use and the factors to consider when making treatment decisions and recommendations.

## Approving Agents

The FDA provides guidelines to facilitate and streamline the artificial tear approval process. The monograph includes approved active

ingredients and concentrations, specific labeling requirements and good manufacturing processes (*Table 1*).

The primary active ingredients found in most artificial tears are either ophthalmic demulcents or emollients.

*Demulcents* are substances that soothe mucous membranes and, in the case of artificial tears, provide lubrication in the form of a mucoprotective film. They can alleviate discomfort, aid in water retention and decrease friction across the ocular surface. The FDA has

established six categories of ophthalmic demulcents that must fall within a specified range of concentrations: cellulose derivatives, dextran 70, gelatin, liquid polyols, polyvinyl alcohol (PVA) and povidone. These products can be used alone or in combinations of up to three.<sup>9</sup>

One of the most commonly used demulcents is carboxymethylcellulose (CMC), a cellulose derivative.

# LOMBART LANE PACKAGES

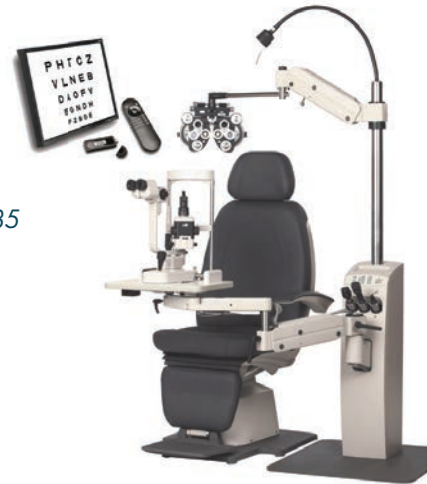## VALUE LANE PACKAGE

- ✓ LOMBART CS-5 Instrument Stand & Exam Chair
- ✓ Topcon SL-2G Slit Lamp
- ✓ Topcon VT-10 Refractor
- ✓ LOMBART CVSe Acuity System

~~\$16,580~~

**\$13,995**

Savings of up to \$2,585



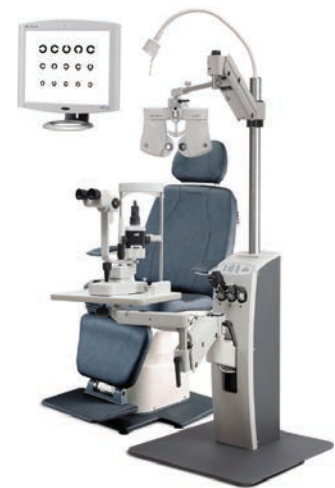## DIGITAL REFRACTION PACKAGE

- ✓ LOMBART CS-5 Instrument Stand & Exam Chair
- ✓ Topcon SL-2G Slit Lamp
- ✓ Premium Digital Refractor (Reichert or Topcon)
- ✓ Corresponding Acuity System

~~\$33,380~~

**\$29,485**

Savings of up to \$3,895



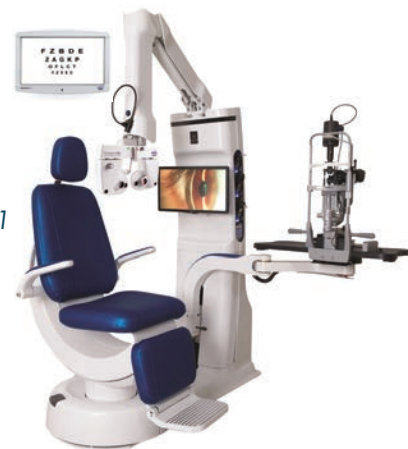## PLATINUM LANE PACKAGE

- ✓ Reliance XOMA Instrument Stand & Exam Chair
- ✓ Haag-Streit BQ 900 LED Slit Lamp + Tonometer
- ✓ Haag-Streit IM 900 Digital Imaging
- ✓ Reichert Phoropter® VRx Digital Refraction System
- ✓ Reichert ClearChart® 4 Digital Acuity System
- ✓ Reliance 5346 Stool

~~\$77,888~~

**\$62,627**

Savings of up to \$15,261



**ASK US ABOUT QUICK DELIVERY!**

(1) FREE Preventative Maintenance in First Two Years

**CALL US TODAY AT 1-800-LOMBART**

**LOMBART**

YOUR OPHTHALMIC PARTNER

800.LOMBART [www.lombartinstrument.com](http://www.lombartinstrument.com)



# Artificial Tears

CMC increases the viscosity of tears and has mucoadhesive properties that allow it to remain on the ocular surface for long periods of time.<sup>10</sup> The commercially available artificial tear concentration can range from 0.2% to 1%.<sup>9</sup> The increased viscosity of higher concentrations can cause transient blur and eyelid debris, which is why these artificial tears should only be applied at night and to treat more severe DED. Another commonly used cellulose derivative is hydroxypropyl methylcellulose (HPMC), or hypromellose. HPMC increases viscosity by cross-linking after contact with the ocular surface. Cellulose derivatives are found in products like Refresh Tears (Allergan), GenTeal Tears (Alcon) and TheraTears (Akorn).

Dextran 70 must be combined with another demulcent due to the compound's low viscosity.<sup>9</sup> This ingredient increases the mechanical strength of the tear film.

PVA, one of the oldest demulcents, lowers a solution's viscosity. It is no longer found frequently in branded artificial tears due to the availability of more effective ingredients. Povidone, a water-soluble synthetic polymer, is also used in products like Betadine (Purdue Pharma) due to its antiseptic properties when combined with iodine. Povidone and PVA are found in drops like Refresh Classic (Allergan), FreshKote (Eyevance Pharmaceuticals) and Murine (Care Pharmaceuticals).

Other demulcents include liquid polyols, such as propylene glycol (PPG), polyethylene glycol (PEG) and glycerin. These increase viscosity by forming a mucoprotective layer and are found in Systane (Alcon), Blink (Johnson & Johnson Vision) and Soothe (Bausch + Lomb). Glycerin is used in Oasis (Oasis Medical) and Refresh Optive (Allergan).

Polysorbate 80 is included in eye drops to aid in the emulsification of formulations with oil, such as Soothe XP (Bausch + Lomb) and Refresh Optive Mega-3 (Allergan). The latter includes polysorbate 80, glycerin 1% and castor oil, all of which are inactive ingredients in Restasis (Allergan).

**Emollients**, such as fats or oils, increase the lipid layer thickness of the tear film, stabilize the tear film and reduce evaporation. More artificial tears containing lipids are becoming available due to an increased awareness of the role meibomian gland dysfunction (MGD) plays in DED.<sup>11</sup> Emollients, found in ointments and lipid-based tears, typically use a combination of mineral oil, light mineral oil and white petrolatum.

Artificial tears that contain lipids must be formulated as an emulsion, which can be classified based on the size of the oil droplet it contains: macroemulsions (larger than 100nm), nanoemulsions (10nm to 100nm), microemulsions (less than 10nm). Both the particle size and lipid concentration can affect visual blur on instillation. Manufacturers employ various methods to enhance emulsion stability, increase even spreading, enhance bioavailability of active ingredients and reduce unwanted side effects. Current lipid-based artificial tears include Systane Balance and Systane Complete (mineral oil, Alcon), Refresh Optive Advanced (castor oil, Allergan) and Refresh Optive Mega-3 (castor oil and flaxseed oil), Soothe XP (mineral oil and light mineral oil

**Table 1. FDA-approved Demulcents for Artificial Tears by Group<sup>9</sup>**

Active Ingredient	Concentration	Function(s)
Cellulose Derivatives		
CMC	0.2% to 2.5% (up to 1% commercially)	Increases viscosity
Hydroxyethyl cellulose, HPMC, methylcellulose	0.2% to 2.5% (up to 0.8% commercially)	Crosslinks with ocular surface, increases viscosity
Dextran 70	0.1%	Increases mechanical strength of tear film
Liquid Polyols		
PEG 300	0.2% to 1%	Increases viscosity
PEG 400	0.2% to 1%	Increases viscosity
Glycerin	0.2% to 1%	Increases viscosity, is an osmoprotectant
Polysorbate 80	0.2% to 1%	Stabilizes emulsions
PVA	0.1% to 4% (up to 1.4% commercially)	Lowers viscosity
Povidone	0.1% to 2%	Increases viscosity

and Retaine MGD (mineral oil and light mineral oil, Ocusoft). With the exceptions of Refresh Optive Advanced and Refresh Optive Mega-3, most lipid-based artificial tears require shaking prior to use to ensure a uniform concentration.

While more research needs to compare artificial tears with and without lipids in patients with MGD and DED, several studies have found that lipid-based drops improve dry eye symptoms.<sup>12-15</sup>

## Gray Areas

Inactive ingredients are not specified in the FDA's ophthalmic monograph, but the guidelines state that ingredients must be suitable and safe and cannot interfere with a product's effectiveness.<sup>16</sup> The FDA maintains a vast list of approved inactive ingredients that may function as buffers, electrolytes, emulsifiers, osmoprotectants or viscosity-enhancers. These ingredients set individual drops apart from one another.

Buffers and electrolytes can adjust the pH and osmolarity of artificial

# Advanced relief for dry eyes

## VeraPlug™ FlexFit™

The **VeraPlug™ FlexFit™** is an advanced solution to the discomfort of dry eye. It is simple to size and insert, comfortable for your patients, and comes with the confidence of our industry leading 45 day retention pledge.



### 45-DAY RETENTION PLEDGE\*

If a VeraPlug™ FlexFit™ is lost within 45 days of insertion, Lacrivera will replace it free of charge.

#### ALSO AVAILABLE

##### VeraPlug™


- Engineered to perfectly fit the puncta for **superior retention**
- Low-profile dome for **enhanced patient comfort**
- Proprietary shaft design for **easy insertion** and **proper anatomic fit**



#### TEMPORARY OCCLUSION


##### Vera90™ Synthetic Inserts

Extended-duration punctal inserts for diagnostic use and post-operative dry eye.



##### VeraC7™ Collagen Inserts

Temporary punctal inserts for diagnostic use, providing occlusion for up to 10 days.



A FRESH PERSPECTIVE™

[lacrivera.com](http://lacrivera.com) (855) 857-0518

2500 Sandersville Rd • Lexington KY 40511 USA



LACRIVERA

# Artificial Tears

tears. Many studies have looked into the association between tear film osmolarity and DED, which was highlighted in the TFOS DEWS report.<sup>17</sup> Research shows a reduction in tear osmolarity correlates with reduced dry eye symptoms in patients treated with artificial tears.<sup>18</sup>

Although artificial tear osmolarity is not widely reported, TheraTears, a hypo-osmolar drop with an osmolarity well below that of other artificial tears, may relieve patients of their dry eye symptoms.<sup>19,20</sup>

Trehalose, an osmoprotectant found in Refresh Optive Mega-3

and TheraTears Extra, stabilizes cell membrane lipids and proteins and can protect corneal epithelial cells from death by desiccation.<sup>21</sup>

Sodium hyaluronate, a glycosaminoglycan, is added to drops like Blink and Oasis to increase lubrication and enhance viscosity. Refresh Optive Repair (Allergan) is a new option, the first in the United States to contain both CMC and sodium hyaluronate.<sup>22</sup>

Another unique inactive ingredient is hydroxypropyl-guar (HP-guar), a polymetric thickener that acts as a gelling agent in the Systane line of artificial tears. HP-guar combines with the two demulcents in Systane to form a low viscosity gel that activates as it interacts with the ocular surface and the pH changes.<sup>23</sup>

Homeopathic artificial tears, such as Similasan, do not fall under the ophthalmic monograph and are not evaluated by the FDA for safety and effectiveness. Instead, they fall under the Federal Food, Drug and Cosmetic Act.<sup>24</sup> Currently, homeopathic drug use is allowed in over-the-counter (OTC) artificial tears so long as the drugs are listed in the Homeopathic Pharmacopoeia of the United States (HPUS). The FDA requires these homeopathic drugs meet standards of active ingredients regarding strength, quality and purity as specified in the HPUS.<sup>24,25</sup>

## Keeping it Fresh

All multidose artificial tears must contain at least one substance to inhibit microbial growth and include appropriate guidelines for proper use (Table 2). In the United States, multidose eye care products undergo preservative testing that must pass the United States Pharmacopeia preservative effectiveness test.

The most commonly used preservative in ophthalmic drops is benzalkonium chloride (BAK), a

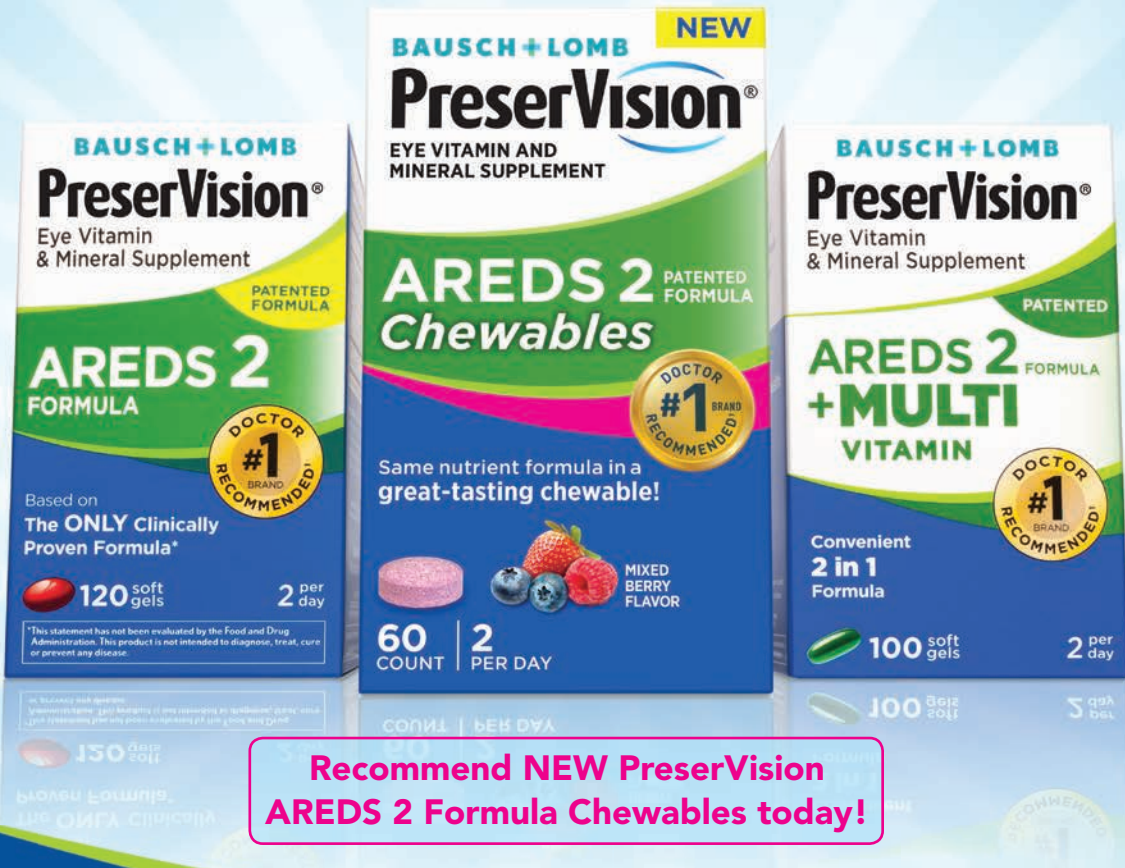**Table 2. Commercially Available Artificial Tears**

Name	Concentration	Preservative
PEG and PPG		
Blink/PF	0.25%	OcuPure/None
Blink Gel	0.25% PEG	OcuPure
Systane Gel	0.4% PEG, 0.3% PPG, HP-guar (inactive)	Polyquaternium-1
Systane Ultra/PF	0.4% PEG, 0.3% PPG, HP-guar (inactive)	Polyquaternium-1/None
Soothe PF	0.6% PPG (also 0.6% glycerin)	None
Systane Balance and Systane Complete	0.6% PPG, mineral oil (inactive); Systane Complete has "nano-droplets"	Polyquaternium-1
Rohto Dry-aid	0.3% PPG (also 0.68% povidone)	Polyaminopropyl biguanide
CMC		
TheraTears/PF	0.25%	Sodium perborate/None
TheraTears Extra	0.25% (trehalose inactive)	Sodium perborate
Refresh Tears/Plus	0.5%	Sodium chlorite/None
Refresh Tears Liquigel/Celluvisc	1%	Sodium chlorite/None
Hypromellose/Dextran 70		
GenTeal Tears Mild	0.3%/0.1%	Polyquaternium-1
GenTeal Tears Moderate/PF	0.3%/0.1% (also glycerin 0.2%)	Polyquaternium-1/None
GenTeal Tears Gel	0.3% (no dextran 70)	Sodium perborate
Glycerin		
Oasis	0.2% (15%)	None
Oasis Plus	0.2% (30%)	None
Refresh Optive/Sensitive	0.9% (also 0.5% CMC)	Sodium chlorite/None
Refresh Optive Repair	0.9% (also 0.5% CMC), sodium hyaluronate (inactive)	Sodium chlorite
Refresh Optive Advanced/PF	1% (also 0.5% CMC, polysorbate 80 0.5%), castor oil (inactive)	Sodium chlorite/None
Refresh Optive Mega-3	1% (also 0.5% CMC, polysorbate 80 0.5%), castor oil, flaxseed, trehalose (inactive)	None
Clear Eyes Pure Relief	0.25%	None (PF multidose)
PVA		
Refresh Classic	1.4% (also 0.4% povidone)	None
FreshKote	2.7% (also 2.0% povidone)	Polixetonium
Murine	0.5% (also 0.6% povidone)	BAK
Clear Eyes Artificial Tears	0.5% (also 0.6% povidone)	BAK
Mineral Oil		
Retaine MGD	0.5% light mineral oil, 0.5% mineral oil	None
Soothe XP/PF	1.0% light mineral oil, 4.5% mineral oil	Polyquaternium-1/None



# Welcome a **new** addition to the PreserVision® family

Same proven nutrient formula, now in a convenient **chewable**



Now, with new PreserVision® Chewables, it's even easier for patients to get all the benefits of the clinically proven AREDS 2 Formula\*:

- Contains the exact levels of nutrients recommended by the National Eye Institute<sup>1,2†</sup>
- Ideal for patients who have difficulty swallowing pills
- Great-tasting mixed berry flavor

Because it's their vision. PreserVision  
[www.preservision.com](http://www.preservision.com)

\*These statements have not been evaluated by the Food and Drug Administration. This product is not intended to diagnose, treat, cure or prevent any disease.

<sup>†</sup>To help reduce the risk of progression for patients with moderate-to-advanced age-related macular degeneration.

References: 1. Yong JJ, Scott IU, Greenberg PB. *Ophthalmology*. 2015;122(3):595-599. 2. Age-Related Eye Disease Study 2 Research Group. *JAMA*. 2013;309(19):2005-2015.

PreserVision is a trademark of Bausch & Lomb Incorporated or its affiliates. AREDS and AREDS2, studies conducted by the National Eye Institute (NEI), are registered trademarks of the United States Department of Health and Human Services (HHS). ©2018 Bausch & Lomb Incorporated. PVC.0018.USA.18

**BAUSCH+LOMB**  
See better. Live better.

# Artificial Tears


quaternary ammonium compound that is an efficacious antimicrobial. It can range in concentration from 0.004% to 0.02% but is usually 0.01% in artificial tear formulations. BAK can cause both corneal and conjunctival cell apoptosis (in a dose-dependent manner, particularly in doses above 0.005%), delay wound healing, decrease goblet cell density and damage corneal nerves.<sup>26-29</sup>

While the most common artificial tears recommended by optometrists do not contain BAK, most OTC drops by major company and large store brands are preserved with 0.01% BAK. Even “softer” preservatives, such as sodium chlorite, can have potential negative effects on the ocular surface, although more studies are needed to compare them with non-preserved formulations.<sup>30</sup>

Most artificial tear brands now have unit-dose vials available in preservative-free formulations. In 2016, the FDA approved the first preservative-free multidose artificial tear, Clear Eyes Pure Relief (Prestige Brands). This drop uses a gas permeable unidirectional filter in the bottle tip to avoid contamination.

## Making the Right Choice

There is a dearth of randomized controlled trials that compare the efficacy of commercially available artificial tears. The FDA approval process for artificial tears does not require individual study submissions, and much of the available research is industry-funded—which can further complicate drawing clinically applicable evidence. A 2016 meta-analysis reviewed 43 head-to-head artificial tear trial studies and concluded that while patients treated



**NaFl corneal staining (left) and lissamine green conjunctival staining (right) significantly correlate when diagnosing DED. Patients at each stage of disease severity may benefit from artificial tear substitutes.**

Photos: Jason Miller, OD

with artificial tears experience better symptom relief than those treated with placebo tears or not treated at all, it is unclear whether some artificial tears are better than others at relieving patient symptoms.<sup>8</sup>

An optimal artificial tear provides efficacious, long-lasting relief from symptoms and has good instillation comfort and low blur. These can be imparted by the drop's surface tension, pH, viscosity, duration of action and the presence or absence of preservatives. Other factors to consider include the ease of instillation and the cost:

- Drops of higher viscosity can provide a longer duration of effect but may also come with a higher incidence of visual blur.<sup>31</sup> Lower viscosity drops tend to be better solutions for daytime use, and higher viscosity gel drops should be reserved for nighttime application.

- Cost can be the primary reason patients discontinue treatment.<sup>32</sup> The cheapest artificial tears are generic brand PVA tears, which cost less than \$2 per 15mL. Branded artificial tears can cost two to seven times more, with prices typically ranging from \$8 to \$13 for a 10mL to 15mL bottle. Generic formulations may be available for many branded artificial tears, but the inactive ingredients and preservatives will vary significantly. When recommending preservative-free drops, costs may increase significantly (particularly when dos-

ing many times daily).

- Burning or stinging, which can occur when a patient's tear pH does not align with the pH of the instilled drop, during instillation can significantly deter compliance with drop regimens, and a trial may be necessary to find the artificial

tear that best matches a patient's own tear pH.<sup>33</sup> Discomfort can also be addressed by switching to a preservative-free drop.

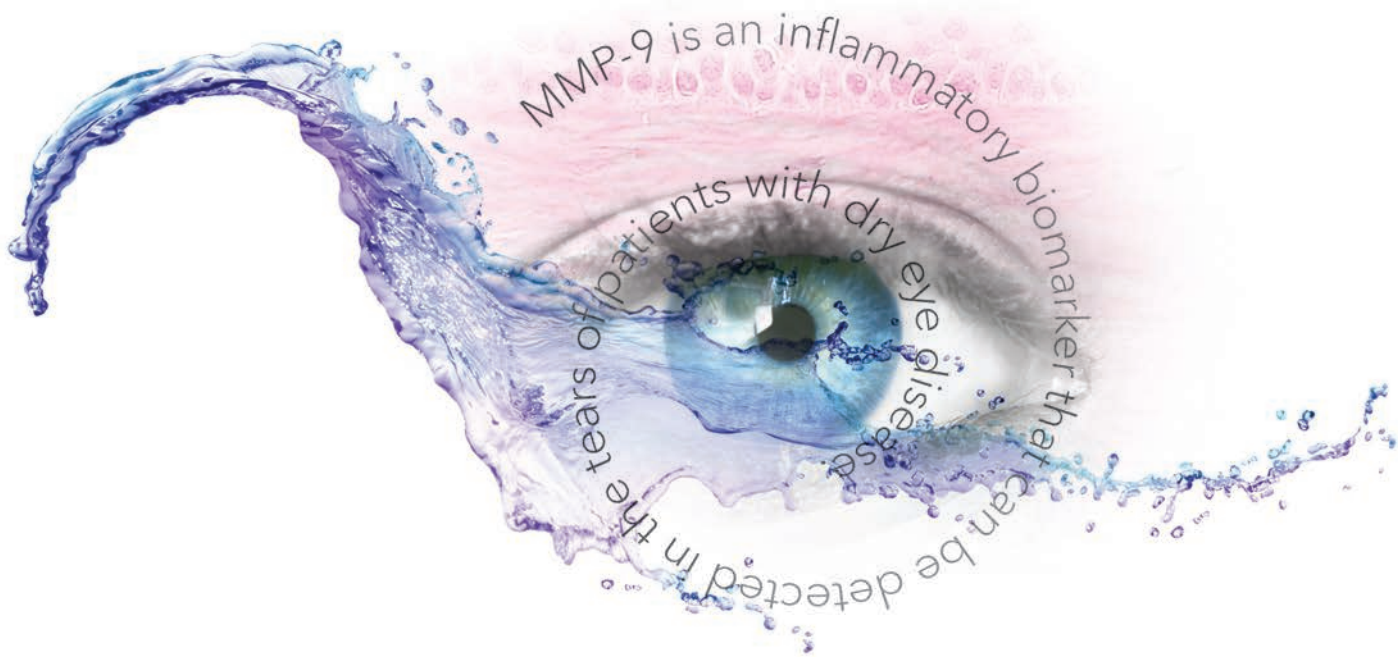
- In-office education with artificial tears is integral. Studies show that the majority of patients, particularly elderly patients, who use chronic drop therapy have poor instillation technique.<sup>34,35</sup> Unit-dose vials may present more challenges to these patients, but results are mixed.<sup>36,37</sup>

Artificial tear substitutes generally target at least one tear film layer, so understanding the primary deficiency of your patient's tear film should help guide your treatment strategy. However, many patients have overlap in different areas of tear film deficiency, and those with a primary lacrimal insufficiency will represent a minority of your patient population. New formulations, such as Refresh Optive Advanced and Systane Complete, target multiple tear components to appeal to a broader range of patients.

A significant portion of patients using artificial tears may also wear contact lenses. Several artificial tears have been studied in contact lens wear, but most artificial tears are used off-label in contact lens patients without incidence.

## Treatment Pearls

Keep in mind these practice tips when recommending artificial tears to DED patients:



Are dry, itchy eyes caused by contact lenses?

It's not complicated.

Your contact lens wearing patient presents with dry, itchy eyes. It's easy for doctor and patient to assume that this is a complication associated with lens wear, but that's not always the case. With similarities in lens related and inflammatory related dry eye symptoms it's critical to perform the proper diagnostics.

If elevated MMP-9, a key inflammatory biomarker for dry eye, is tested for and detected you'll know that it's more than just their contact lenses. You'll have an opportunity to create a more comprehensive treatment plan, aimed at alleviating symptoms and improving comfort while mitigating potential complications of lens wear with the presence of inflammatory dry eye disease.

InflammaDry is the only rapid, CLIA-waived, in-office, point-of-care test that detects MMP-9. InflammaDry provides results in minutes, is easily performed in 4 simple steps, is minimally invasive and requires no special equipment.

To find out how testing for MMP-9 with InflammaDry can take the complication out of your dry itchy eye treatment therapies before there are complications, contact your Quidel Account Manager at **800.874.1517**.



InflammaDry®



• Most of your patients will likely have mild DED and should start with a low viscosity artificial tear. Modern lubricants outperform older lubricants, such as povidone and PVA, so clinicians should recommend more efficacious lubricants unless cost is a major concern.<sup>11</sup> Generic preserved drops should only be considered for occasional use in mild DED patients with episodic symptoms due to the overwhelming presence of BAK in these drops.

• When an artificial tear is not well tolerated or is insufficient for relief, consider active ingredients and mechanisms of action when choosing an alternative. Move toward higher viscosity gel drops when symptoms are not well controlled after dosing every four to six hours.

• All patients with moderate to severe disease should ideally be on preservative-free formulations, as should any patient using artificial tears more than four times daily.

• Preservative-free drops should also be used for glaucoma patients on chronic-preserved glaucoma medications, postoperative patients who require lubrication and patients with acute keratoconjunctivitis.

• DED and significant MGD should be targeted with a lipid-based

artificial tear. Using a drop that simply increases aqueous volume in patients with a deficient tear lipid layer may increase symptoms.<sup>38</sup>

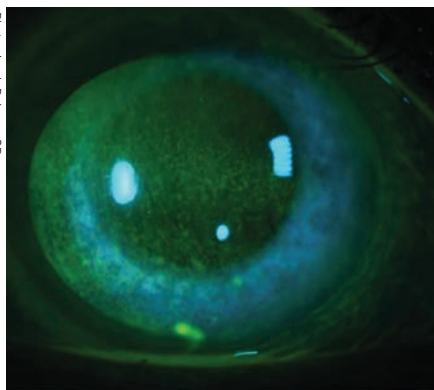
Thanks in part to the FDA ophthalmic monograph for OTC ophthalmic drug products, a plethora of artificial tear options exists. As front-line eye care providers for dry eye patients, we must be equipped to offer our patients specific recommendations for drops, as no single drop works in all clinical scenarios. The art of medicine is applying our science to meet the needs of our diverse patient populations. ■

*Drs. Horton, Reinhard and Horton are optometrists at the Cincinnati VA Medical Center and adjunct faculty members at the Ohio State University College of Optometry.*

- Farrand KF, Fridman M, Stillman IO, Schaumberg DA. Prevalence of diagnosed dry eye disease in the United States among adults aged 18 years and older. *Am J Ophthalmol*. 2017;182:90-8.
- Hikichi T, Yoshida A, Fukui Y, et al. Prevalence of dry eye in Japanese eye centers. *Graef Arch Clin Exp Ophthalmol*. 1995;233(9):555-8.
- Doughty MJ, Fonn D, Richter D, et al. A patient questionnaire approach to estimating the prevalence of dry eye symptoms in patient presenting to optometric practices across Canada. *Optom Vis Sci*. 1997;74(8):624-31.
- Yu J, Asche CV, Fairchild CJ. The economic burden of dry eye disease in the United States: a decision tree analysis. *Cornea*. 2011;30(4):379-87.
- Jones L, Downie LE, Korb D, et al. TFOS DEWS II management and therapy report. *Ocular Surface*. 2017;15(3):575-628.
- Optometric Clinical Practice Guideline. Care of the patient with ocular surface disorders. [www.aaao.org/documents/optometrists/CPG-10.pdf](http://www.aaao.org/documents/optometrists/CPG-10.pdf). Accessed May 30, 2018.
- American Academy of Ophthalmology. Preferred Practice Pattern Guidelines. Dry eye syndrome. [www.aaao.org/ppp](http://www.aaao.org/ppp). Accessed June 15, 2018.
- Pucker AD, Ng SM, Nichols JJ. Over the counter (OTC) artificial tear drops for dry eye syndrome. *Cochrane*. 2016;2.
- Food and Drug Administration: Ophthalmic Drug Products for Over-the-counter Human use; Final Monograph. 21 CFR Parts 349 and 369. *Federal Register* 1988;53(43):7076-93.
- Qian G, Simmons PA, Xu S, et al. Carboxymethylcellulose binds to human corneal epithelial cells and is a modulator of corneal epithelial wound healing. *Invest Ophthalmol Vis Sci*. 2007;48(4):1559-67.
- Moshirfar M, Pierson K, Hanamaikai K, et al. Artificial tears potpourri: a literature review. *Clin Ophthalmol*. 2014;8:1419-1433.
- Korb DR, Scaffidi RC, Greiner JV, et al. The effect of two novel lubricant eye drops on tear film lipid layer thickness in subjects with dry eye symptoms. *Optom Vis Sci*. 2005;82(7):594-601.
- Scaffidi RC, Korb DR. Comparison of the efficacy of two lipid emulsion eyedrops in increasing tear film lipid layer thickness. *Eye Contact Lens*. 2007;33(1):38-44.
- Simmons PA, Carlisle-Wilcox C, Chen R, et al. Efficacy, safety, and acceptability of a lipid-based artificial tear formulation: a randomized, controlled, multicenter clinical trial. *Clinical Therapeutics*. 2015;37(4):858-68.
- Simmons P, Carlisle C, Shi G, Vehige J. Clinical comparison of lipid-based and aqueous lubricant eye drops. *Invest Ophthalmol Vis Sci*. 2013;54(15):4329.

- Code of Federal Regulations. Over-the-counter (OTC) human drugs which are generally recognized as safe and effective and not misbranded. 21CFR1.330.1. [www.ecfr.gov/cgi-bin/text-idx?SID=5b9cfa96ac759f232cdf16c19ac5f9cb&mc=true&node=se21.5.330.11&rgn=div8](http://www.ecfr.gov/cgi-bin/text-idx?SID=5b9cfa96ac759f232cdf16c19ac5f9cb&mc=true&node=se21.5.330.11&rgn=div8). Accessed June 15, 2018.
- The definition and classification of dry eye disease: report of the definition and classification subcommittee of The International Dry Eye Workshop. *Ocular Surface*. 2007;5(2):75-92.
- Cómez AT, Tufan HA, Kocayiyik O, Gencer B. Effects of lubricating agents with different osmolalities on tear osmolality and other tear function tests in patients with dry eye. *Current Eye Research*. 2013;38(11):1095-1103.
- Tong L, Petznick A, Lee S, Tan J. Choice of artificial tear formulation for patients with dry eye: where do we start? *Cornea*. 2012;31(Suppl 1):S32-36.
- Stahl U, Wilcox M, Stapleton F. Role of hypo-osmotic saline drops in ocular comfort during contact lens wear. *Cont Lens Ant Eye*. 2010;33(2):68-75.
- Hill-Bator A, Misiuk-Hojlo M, Marycz K, Grzesiak J. Trehalose-based eye drops preserve viability and functionality of cultured human corneal epithelial cells during desiccation. *Biomed Research International*. 2014;2014:292139.
- Allergan Expands Refresh Portfolio With New Refresh Repair Lubricant Eye Drops. Chicago: PR Newswire. 2018. [www.prnewswire.com/news-releases/allergan-expands-refresh-portfolio-with-new-refresh-repair-lubricant-eye-drops-300677992.htm](http://www.prnewswire.com/news-releases/allergan-expands-refresh-portfolio-with-new-refresh-repair-lubricant-eye-drops-300677992.htm). Accessed September 5, 2018.
- Christensen MT. Corneal staining reductions observed after treatment with Systane. *Advances in Therapy*. 2008;25(1):1191-9.
- US Food and Drug Administration. Manual of Compliance Policy Guides. Sec. 400.400. Conditions Under Which Homeopathic Drugs May Be Marketed. [www.fda.gov/ICECI/ComplianceManuals/CompliancePolicyGuidanceManual/ucm074360.htm](http://www.fda.gov/ICECI/ComplianceManuals/CompliancePolicyGuidanceManual/ucm074360.htm). Accessed May 30, 2018.
- US Food and Drug Administration. Drug Products Labeled as Homeopathic. Guidance for FDA Staff and Industry. 2017. [www.fda.gov/downloads/Drugs/GuidanceComplianceRegulatoryInformation/Guidances/UCM589373.pdf](http://www.fda.gov/downloads/Drugs/GuidanceComplianceRegulatoryInformation/Guidances/UCM589373.pdf). Accessed May 30, 2018.
- Chung SH, Lee SK, Cristol SM, et al. Impact of short-term exposure of commercial eyedrops preserved with benzalkonium chloride on premeconal mucin. *Molecular Vision*. 2006;12:415-21.
- Lin Z, He H, Zhou T, et al. A mouse model of limbal stem cell deficiency induced by topical medication with the preservative benzalkonium chloride. *Invest Ophthalmol Vis Sci*. 2013;54(9):6314-25.
- Chen W, Zhang Z, Hu J, et al. Changes in rabbit corneal innervation induced by the topical application of benzalkonium chloride. *Cornea*. 2013;32(12):1599-1606.
- Pinheiro R, Panfil C, Schrage N, Dutescu RM. The impact of glaucoma medications on corneal wound healing. *J Glaucoma*. 2016;25(1):122-7.
- Schrage N, Frenzt M, Spoeler F. The Ex Vivo Eye Irritation Test (EVEIT) in evaluation of artificial tears: Purite-preserved versus unpreserved eye drops. *Graef Arch Clin Exp Ophthalmol*. 2012;25(9):1333-40.
- LaMotte JO, Ridder WH, Kuan T, et al. The effect of artificial tears with different CMC formulations on contrast sensitivity. *Invest Ophthalmol Vis Sci*. 2002;43(13):3151.
- Taylor SA, Galbraith SM, Mills RP. Causes of non-compliance with drug regimens in glaucoma patients: a qualitative study. *J Ocular Pharmacol Ther*. 2002;18(5):401-9.
- Asbell PA. Increasing importance of dry eye syndrome and the ideal artificial tear: consensus views from a roundtable discussion. *Curr Med Res Opin*. 2006;22:11:2149-57.
- Tatham AJ, Sarodia U, Gatrad F, Awan A. Eye drop instillation technique in patients with glaucoma. *Eye*. 2013;27(11):1293-8.
- Gao X, Yang Q, Huang W, et al. Evaluating eye drop instillation technique and its determinants in glaucoma patients. *J Ophthalmol*. 2018;1376020.
- Parkkari M, Lavvala T, Ropo A. Handling test of eye drop dispenser—Comparison of unit-dose pipettes with conventional eye drop bottles. *J Ocular Pharmacol Ther*. 2010;26(3):273-6.
- Dietlein TS, Jordan JF, Luke C, et al. Self-application of single-use eyedrop containers in an elderly population: comparisons with standard eyedrop bottle and with younger patients. *Acta Ophthalmologica*. 2008;86(8):856-9.
- Calvaio-Santos G, Borges C, Nunes S, et al. Efficacy of 3 difference artificial tears for the treatment of dry eye in frequent computer users and/or contact lens users. *European J Ophthalmol*. 2011;21(5):538-44.
- Sullivan BD, Crews LA, Messmer EM, et al. Correlations between commonly used objective signs and symptoms for the diagnosis of dry eye disease: clinical implications. *Acta Ophthalmol*. 2014;92:161-6.

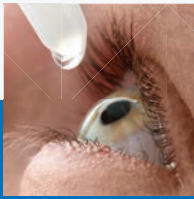
Photo: Jacob R. Lang, MD



**Because many glaucoma drugs and generic artificial tears that contain BAK can cause punctate epitheliopathy, glaucoma patients should avoid using preserved artificial tears.**

VISIT US AT AAO  
BOOTH 3503

# Autologous serum eye drops **made easy.**



## Simple.

Vital Tears eye drops are easy to order and even easier to use.



## Precise.

Available in your choice of dilution options in a 3 or 6 month supply.



## Accessible.

300+ outpatient blood collection facilities. Direct delivery to your patient.

LEARN MORE AT [vitaltears.org](http://vitaltears.org) OR CALL (800) 360-9592



10560 N Ambassador Dr Suite 210  
Kansas City MO 64153

© 2018 Vital Tears LLC. All rights reserved.

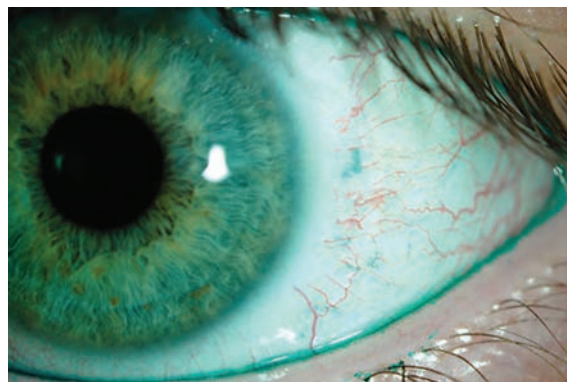# Dry Eye Therapy: Keeping it Simple

Not everything you recommend has to cost a fortune. These low-budget tricks can help patients combat dry eye and stay on budget. **By Barbara Caffery, OD, PhD**

**D**ry eye disease (DED) is a common presentation in eye care offices. Studies of the prevalence of DED vary significantly depending on the definition, the study population and the criterion for diagnosis. North American studies show a prevalence of symptomatic dry eye in males as low as 4.3%, and as high as 21.6% in the elderly.<sup>1,2</sup>

DED is often chronic and therefore requires ongoing management. However, patients are rarely prepared for the true complexity of the disease and the sometimes equally complex treatment plan. Unprepared patients are prone to noncompliance—the biggest obstacle for long-term therapy regimens such as those often required for dry eye.

These diagnostic, pharmaceutical and lifestyle tips can help you prepare DED patients for the therapy road ahead, and shift their mindset from one of burdensome treatment to ongoing eye care.



**TFOS DEWS II lists ocular surface staining, seen here with lissamine green, as an important diagnostic tool for dry eye—the first step in the management process.**

Photo: Jalalain Varikouly, Centre for Contact Lens Research

## Gear Up for the Challenge

The first step of dry eye management is a thorough diagnosis and categorization of the disease based on the new Tear Film and Ocular Surface Society's (TFOS) Dry Eye Work Shop II (DEWS II) definition: “Dry eye is a multifactorial disease of the ocular surface characterized by a loss of homeostasis of the tear film, and accompanied by ocular symptoms, in which tear film instability and hyperosmolarity, ocular surface inflammation,

and neurosensory abnormalities play etiological roles.”<sup>3</sup>

As highlighted by this definition, dry eye is a complex disease that recently got even a little more complicated. In addition to the well-known fact that signs of DED don't always correlate with symptoms, the newest aspect of the disease is the neurosensory component.<sup>3</sup> Based on current literature, we now know that some patients can present with pristine-looking ocular surfaces but suffer from dry eye symptoms that are, in



**ONLY**

**AzaSITE<sup>®</sup>**

(azithromycin ophthalmic solution) 1%



Now included in the  
**EyeRx Direct<sup>®</sup> Service**

Patients save significantly on their  
prescription and AzaSite<sup>®</sup> can be  
delivered to their home for free

Visit [azasite.com](http://azasite.com) to learn more



AzaSite<sup>®</sup> is a registered trademark of Insite Vision Incorporated and is used under license.  
©2017 Akorn, Inc. All rights reserved. P807 REV 10/17

fact, a neuropathy.<sup>4</sup> We refer to these patients as having “pain without stain.” In these cases, a diagnosis of pre-clinical ocular surface disease (OSD) or neuropathic pain—not DED—comes long before clinical signs.

To get to the bottom of a patient’s dry eye symptoms, clinicians should follow the TFOS DEWS II essential diagnostic test recommendations: a dry eye questionnaire followed by tear break-up time (TBUT, noninvasive diagnosis <10sec, F-BUT diagnosis <5sec), osmolarity (diagnosis  $\leq 308$ mOsm/L) and ocular surface staining (diagnosis >5 corneal spots or conjunctiva >9 spots).<sup>5</sup> Not all testing is available to each clinician, and only one of these tests needs to be abnormal to move the diagnosis forward.

The categorization of DED is also integral to direct treatment, and it help the patient better understand the mechanism underlying their particular form of dry eye, whether it’s aqueous deficient, evaporative or a mixture of the two. Clinicians can determine much of this by measuring the tear meniscus height (categorized as mild with 0.2mm, moderate with 0.1mm and severe with 0.0mm) and analyzing meibomian gland function (graded as mild, moderate or severe). Treatments usually begin in a step-like manner going from simple to complex, depending on the severity of the condition and the response to treatments. At the end of a dry eye workup, the clinician will have not only the diagnosis, but also valuable information about its etiology, severity and any meibomian gland dysfunction (MGD).

Armed with this information, clinicians should then spend time properly educating the patient. Whether it’s a female, age-related post-menopausal dry eye, an aqueous deficient dry eye related to an autoimmune disease such as Sjögren’s syndrome or strictly a meibomian gland disease, that information is invaluable for patients. When they understand the particular characteristics of their disease state, they are more likely to comply with the treatment.

## Climbing the Management Mountain

Dry eye therapy is often incredibly daunting to patients. Most people are familiar with diseases treated with a course of medication, surgery or a few weeks of palliative measures as their body fights off the untreatable virus. Unfortunately, dry eye tends to be chronic and



**Patients are confronted with a multitude of lubricating drops at the drug store. It’s the OD’s job to help them narrow their options.**

patients must understand that they are in for a lifetime of care. I liken this new eye care approach to that of their dental care. Without thinking, most of us floss, brush and see our dentist regularly. Similarly, all patients, and dry eye patients in particular, need to care for and maintain a healthy ocular surface over their lifetime.

A second barrier to compliant dry eye care is the cost. Topical over-the-counter lubricants can cost as much as \$50 per bottle,

and the cost of prescription medications such as Restasis (cyclosporine, Allergan) and Xiidra (lifitegrast, Shire) can overwhelm the patient. Both of these factors play an important part in the patient’s decision to adhere to the treatment plan you discuss with them.

**Lubricants.** In almost every form of DED, a lubricant is needed. However, the sheer number of ocular lubricants on drug store shelves is overwhelming. Patients need guidance in choosing the correct product for their specific form of dry eye, especially regarding generic brands, in which the preservatives often differ from branded products. For example, patients with predominantly MGD-induced evaporative dry eye will likely do better with a lipid-based drop, at least until those glands are functioning normally.

For those who do not need the extra lipid or those who do not do well on a lipid-based drop, the biggest decision is whether to recommend preserved or non-preserved drops. Clearly, benzalkonium chloride (BAK) should be avoided if possible, but the effects of other preservatives have yet to be studied on a clinical level. The rising trend is to use non-preserved drops, a clinical wisdom without clear clinical scientific evidence. In theory, preservative free formulations eliminate one possible irritant; in practice, many of the new preservatives seem to work well for patients and the formulations are often less expensive.

The problems associated with the use of BAK-preserved drops are well-known, and this preservative should be avoided if possible.<sup>6-9</sup> However, we do not have comparative studies that show the ocular insult associated with other “modern” preservatives such as polyquad, sodium perborate, Purite, Ocupure and PHMD. In addition, ridding a drop of preservatives does not negate the effect of the active ingredients, which can themselves be toxic.

While choosing a non-preserved drop eliminates

# Biotruth

# #52




Over 4 million households in the US made Biotrue® MPS #1\*



## More households choose Biotrue® MPS over Opti-Free PureMoist\*

### Are you still recommending Opti-Free PureMoist?

Even people who regularly use Opti-Free PureMoist solution agree Biotrue® MPS is pretty great.

-  **94%** agree it allows them to forget they're wearing contact lenses<sup>1</sup>
-  **95%** agree lenses stay comfortable at the end of the day<sup>1</sup>
-  **98%** agree lenses stay comfortable when using digital devices for long hours<sup>1</sup>

Recommend Biotrue®—the #1 multi-purpose solution\* that provides exceptional performance.



# #1

MULTI-PURPOSE SOLUTION\*

\*Highest household penetration among multi-purpose solutions; IRI Data MULO 52 weeks ending 08/12/18.

REFERENCES: 1. Results of an online survey of Opti-Free PureMoist multi-purpose solution users (n=127) who completed an evaluation program for Biotrue multi-purpose solution. Survey results include patients who strongly agreed, agreed, or slightly agreed (on a 6-point agreement scale).

Biotrue is a trademark of Bausch & Lomb Incorporated or its affiliates. All other products/brand names and/or logos are trademarks of the respective owner. ©2018 Bausch & Lomb Incorporated. BIO.0136.USA.18

**BAUSCH+LOMB**  
See better. Live better.



any iatrogenic toxic complication from preservatives, the cost can be overwhelming. My particular style is to begin with a preserved, less expensive drop to first understand the treatment effect on that particular patient. This starts the patient at the lowest end of the treatment scale: easy, effective (hopefully) and inexpensive. Carrying a bottle of artificial tears in a purse or pocket is much easier and safer than carrying a unit-dose vial that has been opened and will be reused during the day, whether we like it or not.

If a non-preserved drop is necessary, clinicians must emphasize to the patient that the extra cost is warranted. Most patients are aware that their sensitive eyes need special care.

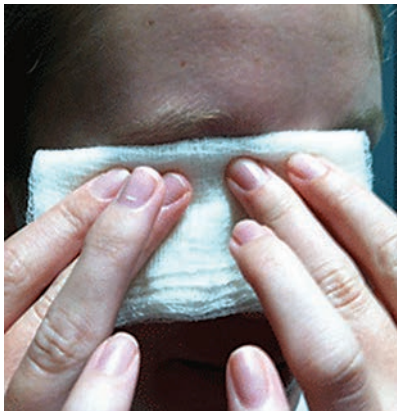Compliance is always a problem when expense is considered. Reminding patients that using drops for dry eyes is the same as using creams for dry skin can be helpful. Many patients understand quite well that moisturizing cream does not go on once and solve the problem. It must be applied daily, and many also use a night cream as well.

The prescription medications Restasis and Xiidra are expensive for those without drug plans. If a patient's treatment plan includes these medications, the manufacturers have provided cost-reduction cards to most practitioners to help offset the cost. Cost limitations may prompt patients to use one vial per day—once in the morning and again at night—rather than two vials per day as instructed. However, this is risky because of the non-preserved nature of the vials. The new Restasis multidose non-preserved bottle would be a safer choice.

**Lids.** Evaporative dry eye is the most prevalent form of DED, and MGD is one of the most common causes. Researchers have studied the prevalence of MGD outside the United States and have found it as low as 30.5% in Spain and as high as 68.3% in China.<sup>10,11</sup>

When dysfunctional, the meibomian glands can be treated with massage and heat. However, achieving the necessary 40° Celsius (roughly 104° Fahrenheit) heat for at least 10 minutes is no easy task without expenditures.<sup>12</sup> Several eye masks work well that can be heated in the microwave, but some are expensive and usually last no more than one year. More affordable masks, such as the TheraPearl eye mask (Bausch + Lomb), often work well.

Photo: Alan G. Kahal, OD, and Joseph W. Sowka, OD



**Conventional therapy for most patients with MGD includes warm compresses and lid massage.**

Also, if cost is a factor, patients can use hot water compresses with a clean face cloth, but they will invariably struggle to keep the temperature at 40°C. Other methods to keep the temperature up longer, such as using tea bags, rice in a sock and potatoes wrapped in cloths, may help, but have a tendency to overheat. Clinicians should counsel patients accordingly if they express interest in these alternatives.

Cleaning lashes and massaging the oil glands are both integral to MGD and anterior blepharitis treatment. Many excellent and expensive lid wipes exist, including those

with medicinal additives such as tea tree oil. Patients unwilling to use these items can use their clean fingers and a lubricant face wash, such as off-label Spectro Jel (GlaxoSmithKline), to clean their lids in the shower. A toothbrush-like back and forth motion of scrubbing the lids while counting to 10 and then rubbing the base of the glands at the orbital side of the lids helps to clean lashes and massage the meibomian glands.

Clinicians should keep in mind that studies now show that baby shampoo does not solve anterior blepharitis and may make it worse, as it often contains cocamidopropyl betaine, a surfactant and lathering agent that can cause eyelid dermatitis.<sup>13,14</sup>

**Oral supplements.** For years we have prescribed omega-3 fatty acids (FA) for MGD and dry eye. Recently, the DREAM study has changed how we see this practice.<sup>15</sup> Basically, the study demonstrated that the particular FA supplements used in the well-designed trial did not help MGD any more than the sham pills that contained small amounts of olive oil determined to be easily met by most North American diets. With the heart community also finding little benefit to omega-3 supplements, many practitioners are discontinuing that recommendation.<sup>16</sup> Patients probably won't complain, considering the high cost of these supplements.

**Environment.** Many environmental changes are inexpensive and particularly effective. Patients should use wraparound glasses and sunglasses when outside to prevent wind current from drying the eyes. In our office, we keep examples of Pantoptix glasses and other forms of protection such as Cocoon (Live Eyewear) that can be worn over regular glasses.

A small humidifier placed on the work desk can reduce dryness and artificial tear use while using the

**The BEST piece of equipment you don't own yet.  
Now is the BEST time to complete your practice!**

**EyeRes**<sup>TM</sup>  
Digital Imaging Systems

**A Versatile System:**

*Anterior-segment imaging,  
Retinal imaging, and Functional  
Meibography all from a slit lamp.*

**Save time . . .**

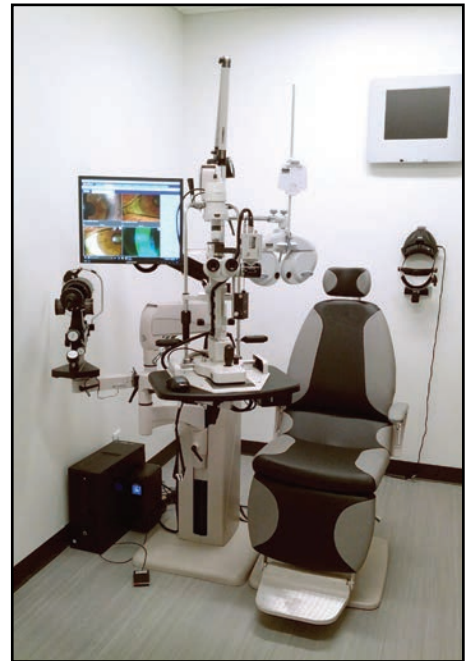Just tap the foot pedal and your images are permanently saved. No clicking!  
Network ready for EHR.

**Increase income . . .**

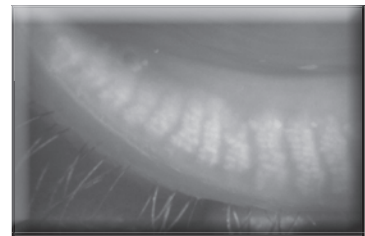
Revenue from Anterior Segment Photography can more than cover the equipment cost.

**Save space . . .**

The Platinum EyeRes System takes very little space without crowding you or your patient.



The Platinum EyeRes system is compatible with most slit lamps.



Optional module for Functional Meibography

Reap the many benefits of owning an **EyeRes**<sup>TM</sup> imaging system from TelScreen.  
**Finance for as little as \$270/month. Quantity Discounts available.**

Call **800.769.4933** today.

**TelScreen. It's worth it!**  
[www.TelScreen.com](http://www.TelScreen.com)



# Dry Eye

computer. If cost is a factor, a bowl of water with as much surface area as possible will also add moisture to the air. Patients should redirect any vents in the room away from their face.

For patients who use a computer throughout the day, clinicians should recommend they sit a little higher in their chair or lower the desk to ensure the gaze down at the computer. This allows the upper lid to cover more of the ocular surface, thus protecting more cells and thickening the tear film.

Blinking is free, as are several easy blinking exercise apps. Patients should adhere to the 20/20/20/20 rule: every 20 minutes take 20 seconds to look 20 feet away and blink 20 times. For those who struggle to incorporate regular blinking exercises, free apps, such as the Donald Korb Blink Training App (TearScience) and EyeLeo, encourage proper blinking with reminders and proper pacing.<sup>17,18</sup>

Patients should always keep airflow away from their eyes to avoid exacerbating dry eye. Counsel them to avoid long-term exposure to ceiling and box fans (especially at night) and to keep the heat and air conditioning in the car at their feet, not in their face.

**Lifestyle.** Those who smoke should be counseled on the myriad benefits of quitting, including the benefits for their ocular health. Research shows tobacco smoke can exacerbate dry eye, as it causes tear film instability and increases ocular surface staining.<sup>19-21</sup> In fact, one study found patients who smokers are nearly twice as likely to have dry eyes.<sup>20</sup> Encouraging smoking cessation and avoidance of smoke will save them a fortune and prolong their life.

Getting enough sleep is an inexpensive way to help protect the eyes from symptoms of dry eye.<sup>22</sup> Oversleeping is unnecessary, but getting enough sleep is essential, as one study found 45% of dry eye patients reported poor sleep quality.<sup>23</sup> Other researchers conducted focus group sessions with 38 patients with dry eye to better understand their various coping methods and found sufficient, good-quality sleep helped many participants.<sup>24</sup>

Patients should go to bed at regular hours and keep the bedroom moist with pans of water or a humidi-

fier. A recent study also suggests sleep position may play a small part in dry eye symptoms. Researchers found elevated Ocular Surface Disease Index scores in patients who slept on their sides compared with those who slept on their back and a statistically significant difference with back sleeping compared with left side sleeping using lissamine green staining.<sup>25</sup> Clinicians can consider recommending patients try to adjust their habitual sleeping position to better protect their eyes from overnight drying.

Also, those who use a continuous positive airway pressure machine for obstructive sleep apnea may experience worse dry eye in the morning, as air can leak from the mask directly onto the ocular surface. These patients can use goggles to protect the eyes overnight and minimize ocular involvement.

Cosmetics can cause or exacerbate any number of ocular issues, including dry eye. Patients should never wear eyeliner inside the lash line, as it can plug the meibomian glands and cause inflammation. In addition, many eyeliners use BAK as the preservative, which, when it remains in contact with the lid cells, can cause damage.<sup>26</sup> Clinicians should counsel patients to take all of their makeup off before bed, and use a soft cloth to wipe and massage the lids as they remove the makeup.

Hydration is important for everyone, but especially for dry eye patients. Although a simple recommendation, asking patients to remember to drink plenty of water and avoid diuretic drinks like alcohol and coffee can have a significant impact on ocular dryness.<sup>27</sup>

As inflammation is a known part of dry eye, an anti-inflammatory diet may be worth recommending to patients in search of alternative dry eye remedies.<sup>28</sup> Fresh food with few additives as described in the Mayo Clinic diet may make a difference to joints and the eyes.

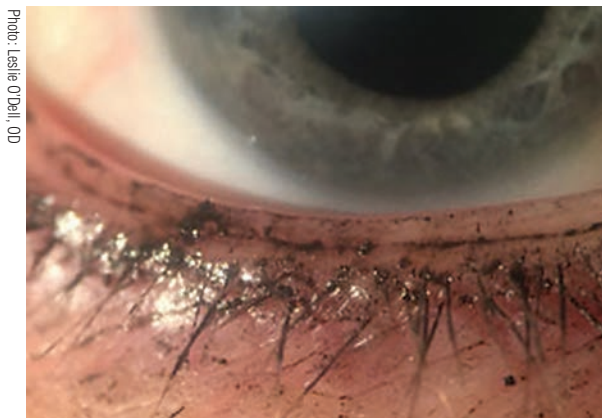


Photo: Leslie O'Dell, OD

**Even when applied properly, makeup debris can migrate to the lid and conjunctiva, contributing to dry eye symptoms.**

Dry eye disease requires a concerted effort on the patient's part to modify their external and internal environment to help encourage ocular health. It also requires regular use of lubricants and lid care. Optometrists serve their patients well if they diagnose, and then educate them about the type and degree of dry eye that is present. Time spent explaining the options for

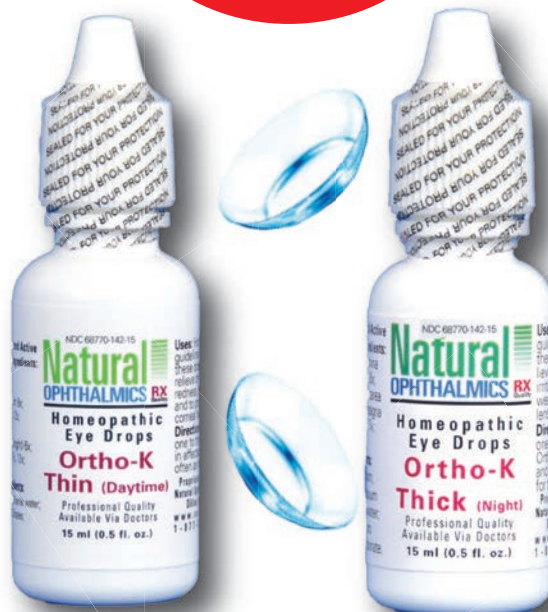

treatments that include less expensive forms, is time well spent to improve patient outcomes. ■

*Dr. Caffery practices at Toronto Eye Care in Toronto. She also participates in two hospital-based clinics: the University Health Network Multidisciplinary Sjögren's Syndrome Clinic and the Therapeutic Contact Lens Clinic at Kensington Eye Institute. She has served on the Board of Directors of the American Academy of Optometry since 2006 and is the current president. She has also served on the Medical Advisory panel of the Sjögren's Society of Canada since 2008.*

- Schaumberg D, Dana R, Buring J, Sullivan D. Prevalence of dry eye disease among us men: estimates from the physicians' health studies. *Arch Ophthalmol.* 2009;127:763-8.
- Moss S, Klein R, Klein B. Long term incidence of dry eye in an older population. *Optom Vis Sci.* 2008;85:668-74.
- Craig JP, Nichols KK, Akpek EK, et al. TFOS DEWS II definition and classification report. *Ocul Surf.* 2017;15(3):276-83.
- Belmonte C, Nichols JJ, Cox SM, et al. TFOS DEWS II pain and sensation report. *Ocul Surf.* 2017 Jul;15(3):404-37.
- Wolffsohn JS, Arita R, Chalmers R, et al. TFOS DEWS II diagnostic methodology report. *Ocul Surf.* 2017;15(3):539-74.
- Chung SH, Lee SK, Cristol SM, et al. Impact of short-term exposure of commercial eyedrops preserved with benzalkonium chloride on precorneal mucin. *Molecular Vision.* 2006;12:415-21.
- Lin Z, He H, Zhou T, et al. A mouse model of limbal stem cell deficiency induced by topical medication with the preservative benzalkonium chloride. *Invest Ophthalmol Vis Sci.* 2013;54(9):6314-25.
- Chen W, Zhang Z, Hu J, et al. Changes in rabbit corneal innervation induced by the topical application of benzalkonium chloride. *Cornea.* 2013;32(12):1599-1606.
- Pinheiro R, Panfil C, Schrage N, Dutescu RM. The impact of glaucoma medications on corneal wound healing. *J Glaucoma.* 2016;25(1):122-7.
- Viso E, Gude F, Rodriguez-Ares M. The association of meibomian gland dysfunction and other common ocular diseases with dry eye: a population based study in Spain. *Cornea.* 2011;30:1-6.
- Jie Y, Xu L, Wu Y, Jonas J. Prevalence of dry eye among adult Chinese in the Beijing Eye Study. *Eye (Lond).* 2009;23:688-93.
- Olson MC, Korb DR, Greiner JV. Increase in tear film lipid layer thickness following treatment with warm compresses in patients with meibomian gland dysfunction. *Eye Contact Lens.* 2003;29(2):96-9.
- Welling JD, et al. Chronic eyelid dermatitis secondary to cocamidopropyl betaine allergy in a patient using baby shampoo eyelid scrubs. *JAMA Ophthalmol.* 2014;132(3):357-9.
- Sung S, Wang MTM, Lee SH, et al. Randomized double-masked trial of eyelid cleansing treatments for blepharitis. *The Ocular Surface.* 2018;16:77-83.
- Maguire M, Asbell P, Group DSR. N-3 fatty acid supplementation and dry eye disease. *N Engl J Med.* 2018;378:1681-90.
- Abdelhamid A, Brown T, Brainard J, et al. Omega 3 fatty acids for the primary and secondary prevention of cardiovascular disease. *Cochrane.* 2018;7:Cd003177.
- Korb Blink Training App. [itunes.apple.com/us/app/donald-korb-blink-training/id941412795?mt=8](https://itunes.apple.com/us/app/donald-korb-blink-training/id941412795?mt=8). Accessed August 30, 2018.
- Eyeleo PC application. [eyeleo.com](https://www.eyeleo.com). Accessed August 30, 2018.
- Thomas J, Jacob GP, Abraham L, Noushad B. The effect of smoking on the ocular surface and the precorneal tear film. *Australas Med J.* 2012;5(4):221-6.
- Moss SE, Klein R, Klein BE. Prevalence of and risk factors for dry eye syndrome. *Archives of Ophthalmology.* 2000;118(9):1264-8.
- Xu L, Zhang W, Zhu X, et al. Smoking and the risk of dry eye: a meta-analysis. *Int J Ophthalmol.* 2016;9:1480-6.
- Lee W, Lim SS, Won JU, et al. The association between sleep duration and dry eye syndrome among korean adults. *Sleep Medicine.* 2015;16:1327-31.
- Kawashima M, Uchino M, Yokoi N, et al. The association of sleep quality with dry eye disease: the Osaka study. *Clin Ophthalmol.* 2016;10:1015-21.
- Yeo S, Louis Tong L. Coping with dry eyes: a qualitative approach. *BMC Ophthalmol.* 2018;18:8.
- Alevi D, Perry HD, Wedel A, et al. Effect of sleep position on the ocular surface. *Cornea.* 2017;36:567-71.
- Chen X, Sullivan D, Sullivan A, et al. Toxicity of cosmetic preservatives on human ocular surface and adnexal cells. *Exp Eye Res.* 2018;170:188-97.
- Caffery B. Influence of diet on tear function. *Optom Vis Sci.* 1991;68:58-72.
- Sears B. Anti-inflammatory diets. *J Am Coll Nutr.* 2015;34:14-21.

## Contact Lens Discomfort



- Excellent for any contact lens fitting sessions
- Corneal healing & vitality
- Lens awareness
- Dryness, redness
- Foreign body sensation
- For hard and soft lenses

### Free Trial Pack

Call today  
877-220-9710

**Natural**  
OPHTHALMICS **RX**  
Quality

[www.NaturalEyeDrops.com](http://www.NaturalEyeDrops.com)



## Optometry CE Study Center



# The CE You Need In 2018!

As low as  
**\$17.50**  
per Credit Hour

Buy just one 2-hour course for \$35 or buy as many as you need

Choose from over 50 individual CE courses

Includes the hard to find topics that fulfill your state requirements

All available in a convenient online format

**Purchase Now!**

[www.reviewsce.com](http://www.reviewsce.com)

The CE Study Center courses have been developed in conjunction with expert faculty from leading schools of optometry and are oriented toward clinical practice issues that are designed to assist eye care professionals in serving their patient's healthcare needs. CE Courses also appear in print monthly in Review of Optometry.

1-800-825-4696 • [INFO@REVIEWSCE.COM](mailto:INFO@REVIEWSCE.COM)

These COPE-Accredited CE courses are administered in partnership with an accredited school of optometry.



2 CE  
Credits  
(COPE approved)



# DRY EYE DISEASE: KNOW YOUR COMORBIDITIES

Dry, irritated eyes can be one of the trickiest clinical findings. These systemic associations may be the key. **By Cecelia Koetting, OD**

**A**s a multifactorial disease affecting more than 30 million people within the United States, dry eye disease (DED) is an unavoidable clinical finding in optometric practice.<sup>1</sup> Although race, sex and age are all factors that can affect a patient's likelihood of DED, the condition can manifest in just about any patient population with variable signs and symptoms, or none at all. For example, studies have shown that women have a 50% to 70% increased risk of DED and worsening of signs—decreased tear osmolarity, Schirmer's score and increased meibomian gland dysfunction

(MGD)—particularly in postmenopausal women.<sup>1,2</sup> Added to this complex clinical picture is the association between DED and many systemic conditions such as diabetes, inflammatory diseases, thyroid dysfunction and dermatological, psychological and neurological diagnoses. With myriad comorbidities causing and contributing to a patient's dry eye, clinicians must have a basic understanding of many health arenas to properly diagnose and manage the disease.

This article highlights many common systemic conditions that may be contributing to your patient's dry eye. A brief discussion of the

current literature and mechanisms of action will help clinicians better recognize patients presenting with multiple diagnoses contributing to one another.

## Who's Hung Out to Dry

Some of the common systemic diseases associated with dry eye ODs may encounter in clinical practice include:

**Diabetes.** The estimated 30.2 million Americans (12.2% of the population) with diabetes mellitus (DM) type 1 or 2—and another estimated 84.1 million who are prediabetic—are all more prone to DED and ocular surface disease.<sup>3,4</sup> A recent study

**Release Date:** November 15, 2018

**Expiration Date:** October 22, 2021

**Goal Statement:** Dry eye disease can manifest in just about any patient population with variable signs and symptoms, or none at all. Myriad systemic conditions can cause and contribute to a patient's dry eye, and clinicians must have a basic understanding of many health arenas to properly diagnose dry eye and its etiology. This article discusses the current literature and mechanisms of action for many common systemic conditions that can contribute to dry eye to help clinicians better recognize patients presenting with multiple diagnoses.

**Faculty/Editorial Board:** Cecelia Koetting, OD

**Credit Statement:** This course is COPE approved for 2 hours of CE credit. Course ID is **59742-AS**. Check with your local state licensing board to see if this counts toward your CE requirement for relicensure.

**Disclosure Statements:**

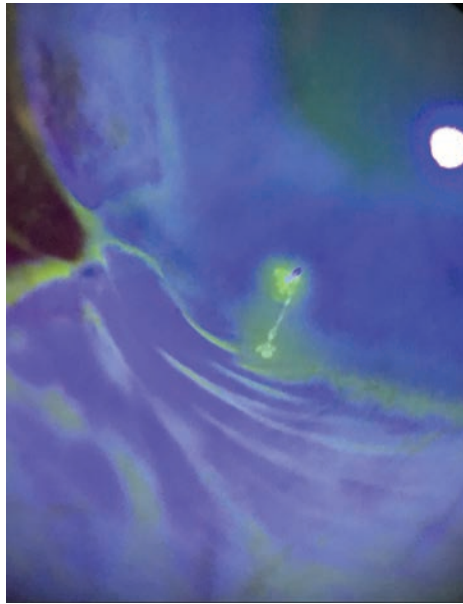
**Authors:** The author has no relationships to disclose.

**Editorial staff:** Jack Persico, Rebecca Hepp, William Kekevan, Catherine Manthorp and Mark De Leon all have no relationships to disclose.



found that 51.3% of the participants with diabetes had DED but were undiagnosed.<sup>5</sup> These patients often have a decreased tear break-up time (TBUT) and tear instability related to the decreased mucin layer caused by a reduction in goblet cell density in the conjunctiva.<sup>1,4</sup> When testing diabetes patients for DED, clinicians should be aware that not all tests are equal. One study compared diagnostic tests in this patient population and found that the Ocular Surface Disease Index (OSDI) only detected 17.1% of DED patients, which was the lowest compared with TBUT, Schirmer's score, corneal/conjunctival staining and tear osmolarity.<sup>6</sup>

MGD is also a major cause of DED in patients with type 2 diabetes. A study of diabetic patients and DED patients without DM looked at the OSDI score, TBUT, Schirmer's score, corneal staining, lipid layer thickness, meibomian gland parameters, HbA1C and duration of diabetes.<sup>7</sup> The researchers found tear volume in DED patients without DM was higher than in patients with DM; however, the meibomian gland parameters were higher with normal OSDI scores in the diabetic patients without DED.<sup>7</sup> Thus, MGD likely presents before ocular symptoms in this



**This Sjögren's syndrome patient has filamentary keratitis.**

population, and clinicians should treat any signs of DED, regardless of whether DM patients are complaining of symptoms.<sup>7</sup>

Research also suggests these patients may experience damage to the microvascular supply of the lacrimal gland, causing decreased production and reduced lacrimal innervation from the autonomic neuropathy and decreased conjunctival injection.<sup>1,5,8</sup> Notably, a decrease in tear secretion may be more severe in patients with non-proliferative diabetic retinopathy (NPDR) compared with those without NPDR.<sup>4,9</sup>

In conjunction, patients with diabetes experience a decrease in corneal sensitivity and wound healing known to lead to, among other prob-

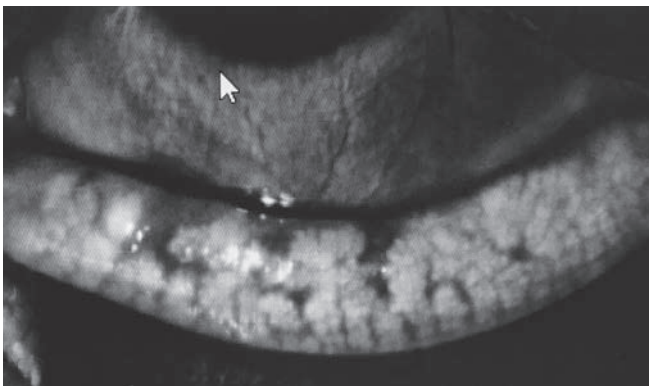
lems, a reduced reflex and basal tear secretion.<sup>5</sup> These patients are at a higher risk for DED progression and non-compliance with treatment because they don't note early dry eye symptoms.

The recommended yearly diabetic eye exam to monitor for ocular signs of complications should include a careful assessment of the ocular surface for signs of dry eye.<sup>6,10</sup> At the very least, this ought to involve TBUT and both corneal and conjunctival staining. Clinicians should also consider adding tear osmolarity and meibography.<sup>6</sup>

**Chronic inflammatory diseases.** These conditions, including rheumatoid arthritis (RA), Sjögren's syndrome (SS), inflammatory bowel disease (IBD) and sarcoidosis can all contribute to an increase in DED. One study found that 11% of RA patients had persistent ocular and oral dryness, and 17.5% had sporadic dryness—a 1.24x increased risk compared with patients not diagnosed with RA.<sup>11</sup> The prevalence of ocular dryness also increased by 10% to 13% for every 10 years of treatment.<sup>11</sup> Higher rates of self-reported body pain and fatigue were also noted to have the highest clinical correlation to dryness.<sup>11</sup> A study in the United Kingdom also found that 70% of RA patients had dry eye, but only 12% were being treated for it.<sup>12</sup>

SS is most typically identified by the altered lacrimal and salivary gland function and may be present in conjunction with other autoimmune syndromes such as RA, Wegener's granulomatosis and systemic lupus erythematosus (SLE).<sup>13,14</sup> One study found 57% of patients with SLE also suffered from pathological dry eye.<sup>15</sup>

With SS, the exocrine glands are infiltrated by lymphocytes CD4+ T- and B-cells causing dysfunction



**In this meibography of a diabetic patient with MGD, note the gland truncation and poor gland structure.**

and destruction.<sup>16</sup> The most commonly affected are the salivary and lacrimal glands, which can be biopsied to confirm diagnosis. Research shows increased expression of cell surface adhesion molecule ICAM-1, which binds to LFA-1 on lymphocytes and recruits antigen-presenting cells that initiate an immune-mediated inflammatory response.<sup>16</sup>

This chronic inflammation leads to worsening of DED and keratoconjunctivita

sicca, which can be monitored with corneal/conjunctival staining, TBUT and tear osmolarity.<sup>16</sup>

The inflammatory disease sarcoidosis causes collections of granulomas to form within organs throughout the body. Most commonly, these non-caseating granulomas form in the lungs, lymph nodes, lacrimal glands and skin.<sup>17</sup> Approximately 40% of sarcoidosis patients have ocular manifestations, with uveitis being the most common, but exocrine gland and lacrimal gland involvement can occur.<sup>17,18</sup> When the exocrine gland is affected, it can cause symptoms of both dry eye and mouth similar to SS.<sup>17,19</sup>

Because sarcoidosis and SS present similarly, bloodwork and a biopsy are often necessary to differentiate the two. When the lacrimal gland develops granulomas, it can cause ocular adnexa swelling and a decrease in lacrimal production, leading to both aqueous deficiency and mechanical exposure from potential lagophthalmos.<sup>17-19</sup>

Patients with IBD often experience ocular manifestations such as episcleritis, scleritis, iritis and DED.<sup>20,21</sup> One study found that 22% of patients with IBD experienced DED, in comparison with only 11% of the control patients.<sup>20</sup>

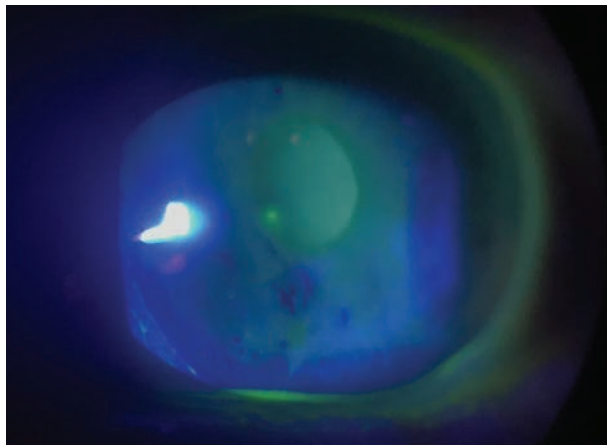


Photo: Matt Dixon, OD

**Dry eye is a common ocular side effect of both hyper- and hypothyroidism.**

Pathophysiology of this increased diagnosis of DED in IBD patients is poorly understood, but researchers suspect an increased inflammation due to local action of antigen-antibody complexes that are produced against the bowel wall vessels and transported via the blood stream.<sup>21</sup>

**Thyroid dysfunction.** Graves' orbitopathy, or thyroid eye disease, is an autoimmune disease where the patient's thyroid-stimulating hormone receptor auto-antibodies cause excess thyroid hormone production. It is most frequently seen in patients with hyperthyroidism but can also be found with hypothyroidism and euthyroid states.<sup>22</sup> This condition causes orbital tissue inflammation, leaving these patients more prone to ocular surface prob-

lems and DED. One study estimates as many as 85% of Graves' orbitopathy patients experience dry eye symptoms.<sup>22</sup>

Physical changes such as lagophthalmos and exophthalmos can lead to poor lid closure, causing dryness from exposure and incomplete blinking.<sup>22</sup> This may also result in high tear osmolarity secondary to evaporation.<sup>22</sup> Researchers suspect the reduction in tear production occurs due to the inflammatory

process that causes lacrimal gland deficiency.<sup>22</sup> These physical changes may also be an indicator in patients who are being treated for dry eye that a thyroid issue may be present and warrant bloodwork, including T3, T4, TSH and TSI.

These patients often experience an active phase of Graves' orbitopathy within 12 to 18 months of the manifestation of systemic symptoms and then go into remission, with the possibility of reactivation in the future.<sup>22</sup> Once out of the active phase, symptoms of Graves' orbitopathy may lessen or even resolve, depending on severity.<sup>22</sup>

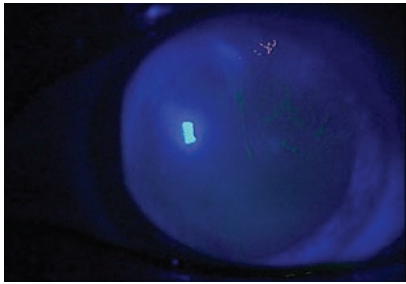
Working with the patient's physician is important for systemic treatment to decrease ocular effects of thyroid imbalance.

### **Migraines: Double-edged Swords**

Unfortunately for patients known to suffer from migraines, DED can both exacerbate the condition and be caused by it at the same time.<sup>1</sup> A study found that patients who experience migraines had decreased mean TBUT and Schirmer's scores and increased OSDI scores and lissamine green staining when compared with the control group.<sup>1</sup> These patients may also be more likely to experience dry eye because of corneal physiological changes. One study used confocal microscopy to view the sub-basal corneal nerve plexus in chronic migraine patients. Compared with non-migraine sufferers, these patients had significantly decreased nerve fiber density, decreased nerve fiber length and symptoms of DED.<sup>2</sup>

1. Kottekir BE, Celik G, Karalezli A, Kal A. Dry eyes and migraines: is there really a correlation? *Cornea*. 2012;31(12):1414-6.

2. Kinard KI, Smith AG, Singleton JR, et al. Chronic migraine is associated with reduced corneal nerve fiber density and symptoms of dry eye. *Headache*. 2015;55(4):543-9.



**This patient with OSA has DED and anterior membrane dystrophy.**

**Dermatological conditions.** Acne rosacea and acne vulgaris can manifest with ocular sequelae, including eye dryness. In the case of rosacea, this chronic skin disorder affects the sebaceous glands, and ocular involvement can include irritation, blepharitis, epiphora and eyelid margin erythema telangiectasia.<sup>23</sup> Ocular findings can occur with or without the primary skin findings, and the estimated incidence varies between 6% and 72%.<sup>23</sup> The mechanism isn't well understood, but chronic inflammation is at the root of ocular symptoms.<sup>23</sup> Inflammation of the meibomian glands can cause abnormal lipid secretion and clogged glands, leading to tear film quality changes clinicians can measure with both TBUT and tear osmolarity.<sup>23</sup>

Dry eye in patients with acne vulgaris is usually related to the medication rather than the disease. Isotretinoin, which is commonly used to treat acne vulgaris, causes decreased density and atrophy of the meibomian glands, leading to ocular surface problems.<sup>24</sup> One study noted a decreased TBUT in 69.1% of patients and the development of blepharitis in 40% of patients.<sup>25</sup> Another study found similar results of decreased TBUT in 50% of patients and blepharitis in 55%.<sup>26</sup> In both studies, the changes disappeared within one month of patients discontinuing the medication.<sup>25,26</sup> However, when a patient experiences permanent sebaceous gland dysfunc-

tion and meibomian gland dropout, the DED will not likely resolve with discontinuation of the medication.<sup>26</sup>

**Psychological conditions.** For patients with anxiety or depression, DED can be exacerbated by both the medication and physiological changes. Research shows chronic depression can worsen DED because of an increase in pro-inflammatory cytokines production.<sup>27</sup> It can also hinder the patient's ability to deal with the discomfort and pain of the condition, as well as feed into a negative feedback loop that exacerbates the depression or anxiety.<sup>27</sup> Unresponsive dry eye patients who also exhibit depressive behavior can be referred for an evaluation with their primary care provider if not already diagnosed and under treatment.

A large Veterans Affairs study found patients who experienced DED had a higher odds ratio for both post-traumatic stress disorder (PTSD) and depression.<sup>27,28</sup> The data showed that 19% of male patients and 22% of female patients diagnosed with PTSD were also diagnosed with DED. An odds ratio of 1.92 DED risk was calculated for PTSD patients. An increased risk was found for the same patients who were using multiple systemic medications.<sup>28</sup>

Attention deficit hyperactive disorder (ADHD) has been linked to an increased incidence of DED, and the medications used to treat ADHD, Adderall (dextroamphetamine/amphetamine, Teva Pharmaceuti-

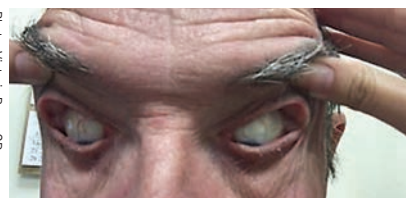cals) and Ritalin (methylphenidate hydrochloride, Novartis), can also cause dry eye.<sup>29</sup> One study found patients with ADHD had a higher OSDI score and rate of DED symptoms compared with non-ADHD patients.<sup>29</sup> However, limited information exists and the mechanism is poorly understood, indicating further studies are necessary to further investigate the validity of this claim.

**Parkinson's disease (PD).** These patients are predisposed to dry eye caused by both motor function and physiological changes. Blink rate is significantly decreased, allowing for more exposure time of the cornea and an increase in dryness. One study found PD patients had an average blink rate of 12.7 times per minute, significantly lower than the control patients' average blink rate of 21.8 times per minute.<sup>30</sup> The same study noted that PD patients had significantly decreased meibomian gland function and tear meniscus height.<sup>30</sup> Another study found lower Schirmer scores and higher overall OSDI scores.<sup>31</sup> Researchers speculate this is due to decreased androgen levels and autonomic dysfunction caused by Lewy bodies at the sympathetic ganglia, substantia nigra and peripheral parasympathetic ganglia.<sup>32,33</sup>

Also, researchers believe oxidative stress occurs in both Parkinson's and Alzheimer's disease, further exacerbating DED.<sup>19</sup> Mice studies found that the functional knockout of the mev-1 gene caused a decrease in tear production, lacrimal dysfunction and DED and conclude that oxidative stress causes inflammation and leads to these problems.<sup>34,35</sup>

Future studies with human subjects may one day show the same correlation, providing an earlier indicator of DED and the need for early intervention for those who suffer from diseases with known oxidative stress.

Photo: Victoria Roan, OD



**This patient's elastic, easily pliant eyelids prompt a diagnosis of FES, which is linked to several severe ocular and systemic diseases.**



**Neuropathic pain.** This is caused by a lesion or disease of the somatosensory system, leading to sensitization of the peripheral and central nerves. In turn, this causes maladaptive neuroplastic changes to both the PNS and CNS sensory processing pathways. A discrepancy in signs and symptoms can be found in a subgroup of DED. These patients also show signs of ocular neuropathic pain, including abnormal sensations, spontaneous pain, pain from light or wind and exaggerated pain to normal stimulus.<sup>27</sup>

Ocular neuropathic pain can happen with reoccurring corneal nerve injury or inflammation, which causes chronic changes to both the peripheral and central corneal somatosensory pathways. Research has found this same mechanism of corneal nerve injury and regeneration in LASIK patients, which is believed to be the cause of dry eye symptoms post-surgery.<sup>27</sup>

Studies have also shown chronic pain syndrome (CPS) is associated with DED. One study of 154 patients found that patients with CPS had worse dry eye symptoms and ocular pain compared with controls.<sup>27</sup> These patients may also be more prone to neuropathic ocular pain, which would exhibit in the clinic as pain out of proportion with ocular signs of DED.<sup>27</sup>

**Sleep disorders.** The lack of quality sleep—the right amount of REM cycles, or deep sleep—can lead to myriad adverse outcomes, including circadian rhythm disruption, hypertension, metabolic syndrome and even ocular sequelae.<sup>36-38</sup> A recent study of the association between sleep quality and DED found 45% of DED patients also reported poor sleep quality.<sup>36</sup> Prior studies found tear instability and decreased secretion related to changes in circadian rhythm, as well as lower tear secretion in metabolic syndrome.<sup>36,38,39</sup>

**Table 1. Common Medications Causing or Aggravating Dry Eye<sup>1,2</sup>**

<b>Amphetamines</b> Dextroamphetamine/amphetamine Methylphenidate hydrochloride	<b>Antineoplastics</b>
<b>Antiarrhythmics</b> Propranolol Oxprenolol Clonidine Pindolol Nadolol Metoprolol Carvedilol	<b>Anti-Parkinson's</b>
<b>Antidepressants</b> Sertraline Paroxetine Amitriptyline Doxepin	<b>Antipsychotics</b> Thioridazine Chlorpromazine Pimozide
<b>Antihistamines</b> Diphenhydramine Chlorpheniramine Loratadine Cetirizine Desloratadine Fexofenadine	<b>Antirheumatics</b>
<b>Antihypertensives</b> Thiazides Hydrochlorothiazide Furosamide Atenolol Acebutolol	<b>Antispasmodics</b>
<b>Antimalarials</b> Hydroxychloroquine	<b>Decongestants</b>
	<b>Dermatologic</b> Isotretinoin
	<b>Gastrointestinal</b> Lansoprazole Omeprazole Esomeprazole magnesium Ranitidine Cimetidine
	<b>Hormone replacement therapy</b> Estrogen Progestines
	<b>Neurotoxins</b> Botulinum toxins A and B
	<b>Pain relief</b> Opioids Hydrocodone/acetaminophen Propoxyphene napsylate/acetometaphin Ibuprofen
	<b>Sedatives</b> Primidone

1. Bowling E. Which oral meds cause dry eye? RCCL. June 2011.

2. Fraunfelder FT, Sciubba JJ, Mathers WD. The role of medications in causing dry eye. J Ophthalmol. 2012;2012:285851.

Nearly 18 million adults in America suffer from obstructive sleep apnea (OSA), according to the National Sleep Foundation.<sup>40</sup> This condition has also been linked to floppy eyelid syndrome (FES), corneal erosions, keratitis and punctate corneal epitheliopathy.<sup>41</sup> These patients often experience a continual state of inflammation in the eye due to increased accumulation of pro-inflammatory cytokines produced

by the lacrimal gland caused by chronic intermittent hypoxia. This in turn damages the meibomian glands and goblet cells, decreases corneal sensitivity and reduces tear production.<sup>41,42</sup>

Studies looking at DED in patients with OSA without FES found higher OSDI scores and significantly decreased TBUT and Schirmer scores in moderate and severe sleep apnea patients when compared with those

in the control group.<sup>41</sup> Dryness can also be exacerbated by ill-fitting continuous positive airway pressure masks that leak air toward the eye.

FES is caused by lid laxity due to a decrease in elastin content, lending the patient to spontaneous inversion, eversion or both.<sup>43</sup> The spontaneous nocturnal eyelid eversion leads to irritation of the conjunctiva and possible corneal abrasions. Poor apposition of the lids causes a compromise of the tear film, in theory leading to DED.<sup>43</sup>

Although not all patients with OSA have FES, an increased incidence exists in patients with OSA. Those with both conditions have a higher correlation of DED than patients with OSA only.<sup>41</sup>

### Medication Woes

Many pharmaceuticals used to treat psychological conditions, dermatological conditions, allergies, epilepsy and seizure disorders can cause or exacerbate DED (*Table 1*). When discussing a patient's systemic disorder and related medications, it is important to be thorough, as many patients may be resistant to discussing their health history without understanding the connection with their ocular health.

Often, discontinuing an offending medication is not an option. In these cases, optometrists must address the patient's ocular signs and symptoms as best as possible. Clinicians should always comanage with the treating physician to discuss alternatives when DED therapy isn't working and the patient's vision is at risk.

While all patients should be treated as a whole, those with DED may warrant a little extra care. Many systemic conditions can cause or exacerbate dry eye, as can the various treatments necessary to maintain a patient's quality of life.

Optometrist should remain familiar with ongoing research to help

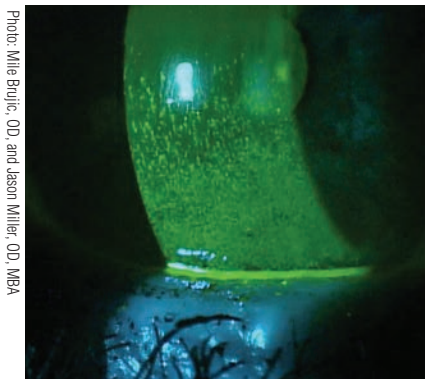


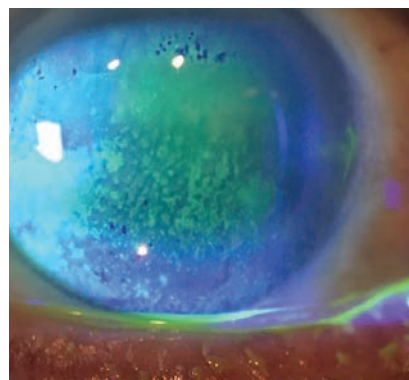
Photo: Mile Brujic, OD, and Jason Miller, OD, MBA

### Significant corneal staining in a patient with Sjögren's, fibromyalgia and rheumatoid arthritis.

uncover more concrete evidence of these associations, as many studies have yet to discern the true cause of DED—the systemic condition or the systemic medication. Because neither one is often modifiable, ODs must be prepared for the ongoing care and comanagement these patients need.

The first step is identifying the comorbidities themselves. Only then can clinicians make informed treatment decisions to improve patient comfort and satisfaction. ■

*Dr. Koetting is the referral optometric care and externship program coordinator at Virginia Eye Consultants in Norfolk, VA. She is a fellow of the American Academy of Optometry and a trustee of the Virginia Optometric Association.*



### This DED patient on medication for depression has diffuse superficial punctate keratitis.

1. Stapleton F, Alves M, Bunya VY, et al. TFOS DEWS II epidemiology report. *Ocul Surf*. 2017;15(3):334-65.
2. Sullivan DA, Rocha EM, Aragona P, et al. TFOS DEWS II sex, gender, and hormones report. *Ocul Surf*. 2017;15(3):284-333.
3. Center for Disease Control. National Diabetes Statistics Report, 2017. [www.cdc.gov/diabetes/pdfs/data/statistics/national-diabetes-statistics-report.pdf](http://www.cdc.gov/diabetes/pdfs/data/statistics/national-diabetes-statistics-report.pdf). July 18, 2017. Accessed August 20, 2018.
4. Skarbez K, Priestley Y, Huepf M, Koevary SB. Comprehensive review of the effects of diabetes on ocular health. *Expert Rev Ophthalmol*. 2010;5:557-77.
5. Schwartz S, Halleran C, Doll T, et al. Does diabetes make a difference in dry eye? *ARVO* 2018. Abstract 956-B0134.
6. Najafi L, Malek M, Valojerdi AE, et al. Dry eye disease in type 2 diabetes mellitus; comparison of the tear osmolarity test with other common diagnostic tests: a diagnostic accuracy study using STARD standard. *J Diabetes Metab Disord*. 2015;14:39.
7. Wu H, Xie F, Luo S, et al. Meibomian gland dysfunction is an early sign and major cause of dry eye in Type 2 diabetes. *ARVO* 2018. Abstract 4900-C0345.
8. Kaiserman I, Kaiserman N, Nakar A, Vinker S. Dry eye in diabetic patients. *Am J Ophthalmol*. 2005;139:498-503.
9. Yoon KC, Im SK, Seo MA. Changes in tear film and ocular surface in diabetes mellitus. *Korean J Ophthalmol*. 2004;18:168-74.
10. American Optometric Association. Evidence-based clinical practice guideline: Eye care of the patient with diabetes mellitus. 2014.
11. Wolfe F, Kaleb M. Prevalence, risk, and risk factors for oral and ocular dryness with particular emphasis on rheumatoid arthritis. *J Rheumatol*. 2008;35(6):1023-30.
12. Piper H, Douglas KM, Trehan GJ, et al. Prevalence and predictors of ocular manifestations of RA: is there a need for routine screening? *Musculoskeletal Care*. 2007;5(2):102-17.
13. Gilboe IM, Kvien T, Uhlig T, Husby G. Sicca symptoms and secondary Sjögren's syndrome in systemic lupus erythematosus: comparison with rheumatoid arthritis and correlation with disease variables. *Ann Rheumatic Dis*. 2001;60(12):1103-9.
14. Bron AJ, de Paiva CS, Chauhan SK, et al. TFOS DEWS II pathophysiology report. *Ocul Surf*. 2017;15(3):438-510.
15. Ostaneck L. Ocular manifestations in patients with systemic lupus erythematosus and antiphospholipid syndrome. *Pol Arch Med Wewn*. 2007;117 Suppl:18-23.
16. Stern ME, Gao J, Schwalb TA, et al. Conjunctival T-cell subpopulations in Sjögren's and non-Sjögren's patients with dry eye. *Invest Ophthalmol Vis Sci*. 2002;43(8):2609-14.
17. Drosos AA, Constantopoulos SH, Psychos D, et al. The forgotten cause of sicca complex; sarcoidosis. *J Rheumatol*. 1989;16(12):1548-51.
18. Groen F, Rothova A. Ocular involvement in sarcoidosis. *Semin Respir Crit Care Med*. 2017;38(4):514-22.
19. Zoukhrif D. Effect of inflammation on lacrimal gland function. *Exp Eye Res*. 2006;82(5):885-98.
20. Felekis T, Katsanos K, Kitsanou M, et al. Spectrum and frequency of ophthalmologic manifestations in patients with inflammatory bowel disease: a prospective single center study. *Inflamm Bowel Dis*. 2009;15(1):29-34.
21. Troncoso LL, Biancardi AL, de Moraes HV Jr, Zaltman C. Ophthalmic manifestations in patients with inflammatory bowel disease: a review. *World J Gastroenterol*. 2017;23(32):5836-48.
22. Selter JH, Gire AI, Sikder S. The relationship between Graves' ophthalmopathy and dry eye syndrome. *Clin Ophthalmol*. 2015;9:57-62.
23. Arman A, Demirseren DD, Takmaz T. Treatment of ocular rosacea: comparative study of topical cyclosporine and oral doxycycline. *Intern J Ophthalmol*. 2015;8(3):544-9.
24. Mathers WD, Shields WJ, Sachdev MS, et al. Meibomian gland morphology and tear osmolarity: changes with Accutane therapy. *Cornea*. 1991;10(4):286-90.
25. Egger SF, Huber-Spitzy V, Böhler K, et al. Ocular side effects associated with 13 cis retinoic acid therapy for acne vulgaris: clinical features, alterations of tearfilm and conjunctival flora. *Acta Ophthalmologica Scandinavica*. 1995;73(4):355-7.
26. Bozkurt B, Irkec MT, Atakan N, et al. Lacrimal function and ocular complications in patients treated with systemic isotretinoin. *Eur J Ophthalmol*. 2002;12:3:173-6.
27. Han SB, Yang HK, Hyon JY, Wee WR. Association of dry eye disease with psychiatric or neurological disorders in elderly patients. *Clin Interv Aging*. 2017;12:785-92.
28. Galor A, Feuer W, Lee DJ, et al. Depression, post-traumatic stress disorder, and dry eye syndrome: a study utilizing the national United States Veterans Affairs administrative database. *Am J Ophthalmol*. 2012;154(2):340-6.e2.

29. Cho KJ, Kim HK, Lim MH, et al. Depression, ADHD, job stress and sleep problems with dry eye disease in Korea. *Am J Psychiatry*. 2015;172(9):958-964.
30. Cengaver T, Melek IM, Duman T, Oksüz H. Tear film tests in Parkinson's disease patients. *Ophthalmology*. 2005;112(10):1795.
31. Nowacka B, Lubinski W, Honczarenko K, et al. Ophthalmological features of Parkinson disease. *Med Sci Monit*. 2014 Nov;20:2243-9.
32. Kandel ER, Schwartz, Jessell TM. *Principles of Neural Science*. 3rd ed. New York: Elsevier; 1991.
33. Okun MS, McDonald WM, DeLong MR. Refractory nonmotor symptoms in male patients with Parkinson disease due to testosterone deficiency: a common unrecognized comorbidity. *Arch Neurol*. 2002;59:807-11.
34. Uchino Y, Kawakita T, Miyazawa M, et al. Oxidative stress induced inflammation initiates functional decline of tear production. *PLoS One*. 2012;7(10):e45805.
35. Yi W, Asbell PA. The core mechanism of dry eye disease (DED) is inflammation. *Eye Contact Lens*. 2014;40(4):248-56.
36. Kawashima M, Uchino M, Yokoi N, et al. The association of sleep quality with dry eye disease: the Osaka study. *Clin Ophthalmol*. 2016 Jun 1;10:1015-21.
37. Gangwisch JE. Epidemiological evidence for the links between sleep, circadian rhythms and metabolism. *Obes Rev*. 2009;10(Suppl 2):37-45.
38. Wolk R, Somers VK. Sleep and the metabolic syndrome. *Exp Physiol*. 2007;92:67-78.
39. Yaguchi S, Ogawa Y, Shimmura S, et al. Angiotensin II type 1 receptor antagonist attenuates lacrimal gland, lung, and liver fibrosis in a murine model of chronic graft-versus-host disease. *PLoS One*. 2013;8:e64724.
40. Hauri P. *The Sleep Disorders*. National Sleep Foundation. 2018.
41. Karaca EE, Akcam HT, Uzun F, et al. Evaluation of ocular surface health in patients with obstructive sleep apnea syndrome. *Turk J Ophthalmol*. 2016;46(3):104-8.
42. Acar M, Firat H, Acar U, Ardic S. Ocular surface assessment in patients with obstructive sleep apnea-hypopnea syndrome. *Sleep Breath*. 2013;17:583-8.
43. Miyamoto C, Santo LCE, Roisman L, Osaki M. Floppy eyelid syndrome. *Arquivos Brasileiros de Oftalmologia*. 2011;74(1):64-6.

## OSC QUIZ

**Y**ou can obtain transcript-quality continuing education credit through the Optometric Study Center. Complete the test form and return it with the \$35 fee to: Jobson Medical Information, Dept.: Optometric CE, 440 9th Avenue, 14th Floor, New York, NY 10001. To be eligible, please return the card within one year of publication. You can also access the test form and submit your answers and payment via credit card at *Review of Optometry* online, [www.reviewsofsc.com](http://www.reviewsofsc.com).

You must achieve a score of 70 or higher to receive credit. Allow four weeks for processing. For each Optometric Study Center course you pass, you earn 2 hours of transcript-quality credit from Pennsylvania College of Optometry and double credit toward the AOA Optometric Recognition Award—Category 1.

Please check with your state licensing board to see if this approval counts toward your CE requirement for relicensure.

1. Which two systemic diseases that contribute to dry eye manifest similarly to one another?  
 a. Sarcoid and thyroid disease.  
 b. Sjögren's syndrome and diabetes.  
 c. Sjögren's syndrome and sarcoid.  
 d. Diabetes and hypertension.

2. Which of the following conditions causes potential damage to the microvascular supply of the lacrimal gland, thereby leading to decreased tear production?  
 a. Thyroid disease.  
 b. Diabetes.  
 c. Rheumatoid arthritis.  
 d. Acne vulgaris.

3. Sjögren's syndrome has been found in conjunction with all of the following, except:  
 a. Rheumatoid arthritis.

b. Systemic lupus erythematosus.  
 c. Wegeners granulomatosis.  
 d. Ankylosing spondylitis.

4. What percentage of patients with thyroid eye disease experience dry eye symptoms?  
 a. 65% to 85%.  
 b. 100%.  
 c. 25% to 30%.  
 d. 45% to 60%.

5. Which of the following is not a sign/symptom of thyroid eye disease?  
 a. Dry eye.  
 b. Lagophthalmos.  
 c. Dry mouth.  
 d. Exophthalmos.

6. Which of these is a cause of dry eye in patients with diabetes?  
 a. Infiltration of exocrine glands by lymphocytes.  
 b. Reduced goblet cell density in the conjunctiva.  
 c. Lacrimal gland secreting thyroid-stimulating hormone receptors that are attacked by autoantibodies.  
 d. Formation of granulomas.

7. Which condition presents with dry eye symptoms due to the medication moreso than the disease process itself?  
 a. Diabetes.  
 b. Sjögren's syndrome.  
 c. Sarcoid.  
 d. Acne.

8. Which condition causes granulomas in the lacrimal gland, leading to ocular adnexa swelling and decreased tear production?  
 a. Sarcoid.  
 b. Diabetes.  
 c. Sjögren's syndrome.  
 d. Acne rosacea.

9. Which disease causes reduced corneal sensitivity, thereby making patients less symptomatic to dryness?  
 a. Thyroid eye disease.  
 b. Acne.  
 c. Diabetes.  
 d. Rheumatoid arthritis.

10. Which of these medications is commonly used to treat acne vulgaris and causes dry eye symptoms?  
 a. Diflucan.  
 b. Isotretinoin.  
 c. Metformin.  
 d. Prolensa.

11. Parkinson's disease patients usually have dry eyes because:  
 a. They blink less.  
 b. It increases production of pro-inflammatory cytokines.  
 c. Of chronic intermittent hypoxia.  
 d. Of damage to the goblet cells.

12. Depression worsens dry eye disease by:  
 a. Increasing production of pro-inflammatory cytokines.  
 b. Decreasing patient's ability to deal with discomfort and pain.  
 c. Feeding into a negative feedback loop that makes depression worse.  
 d. All of the above.

13. Ocular neuropathic pain:  
 a. Could be the cause of dry eye symptoms post-LASIK.  
 b. Increases tear function.  
 c. Causes chronic changes only to the peripheral somatosensory pathway.  
 d. Occurs with an acute episode of corneal abrasion.

14. Sleep disturbance is linked to:  
 a. Circadian rhythm disruption.



**OSC QUIZ**

- b. Hypertension.
  - c. Metabolic syndrome.
  - d. All of the above.
15. Sleep apnea is associated with all of the following, except:
- a. Keratitis.
  - b. Punctate corneal epitheliopathy.
  - c. Floppy eyelid syndrome.
  - d. Retinal hemorrhages.
16. Sleep apnea:
- a. Damages the glands of zeiss.
  - b. Increases corneal sensitivity.
  - c. Reduces accumulation of cytokines.
  - d. Causes a decreased state of inflammation.
17. Floppy eyelid syndrome is associated with:
- a. Parkinson's disease.
  - b. PTSD patients.
  - c. Keratoconus.
  - d. Depression.
18. Research shows migraine patients have:
- a. Increased TBUT.
  - b. Increased OSDI scores.
  - c. Increased Schirmer's scores.
  - d. All of the above.
19. Decreased nerve fiber density in the corneal nerve plexus was seen in patients with:
- a. Sleep apnea.
  - b. Migraines.
  - c. ADHD.
  - d. Depression.
20. Obstructive sleep apnea has been linked to all the following, except:
- a. Guttata.
  - b. Floppy eyelid syndrome.
  - c. Corneal erosions.
  - d. Punctate corneal epitheliopathy.



**TAKE THE TEST ONLINE TODAY!**  
<https://www.reviewsce.com>

**Examination Answer Sheet**

Dry Eye Disease: Know Your Comorbidities  
 Valid for credit through October 22, 2021

**Online:** This exam can be taken online at [www.reviewsce.com](http://www.reviewsce.com). Upon passing the exam, you can view your results immediately and download a real-time CE certificate. You can also view your test history at any time from the website.

**Directions:** Select one answer for each question in the exam and completely darken the appropriate circle. A minimum score of 70% is required to earn credit.

**Mail to:** Jobson Healthcare Information, LLC, Attn.: CE Processing, 395 Hudson Street, 3rd Floor, New York, NY 10014.

**Payment:** Remit \$35 with this exam. Make check payable to Jobson Healthcare Information, LLC.

**Credit:** This course is COPE approved for 2 hours of CE credit. Course ID is **59742-AS**.

**Sponsorship:** This course is joint-sponsored by the Pennsylvania College of Optometry.

**Processing:** There is a four-week processing time for this exam.

**Answers to CE exam:**

1. (A) (B) (C) (D)
2. (A) (B) (C) (D)
3. (A) (B) (C) (D)
4. (A) (B) (C) (D)
5. (A) (B) (C) (D)
6. (A) (B) (C) (D)
7. (A) (B) (C) (D)
8. (A) (B) (C) (D)
9. (A) (B) (C) (D)
10. (A) (B) (C) (D)
11. (A) (B) (C) (D)
12. (A) (B) (C) (D)
13. (A) (B) (C) (D)
14. (A) (B) (C) (D)
15. (A) (B) (C) (D)
16. (A) (B) (C) (D)
17. (A) (B) (C) (D)
18. (A) (B) (C) (D)
19. (A) (B) (C) (D)
20. (A) (B) (C) (D)

**Post-activity evaluation questions:**

*Rate how well the activity supported your achievement of these learning objectives:  
 1=Poor, 2=Fair, 3=Neutral, 4=Good, 5=Excellent*

21. Improve my understanding of the prevalence of dry eye associated with various systemic conditions. (1) (2) (3) (4) (5)
22. Become familiar with the mechanisms of action contributing to dry eye associated with systemic conditions. (1) (2) (3) (4) (5)
23. Increase my understanding of the complex interplay between dry eye, systemic disease and systemic therapies. (1) (2) (3) (4) (5)
24. Better understand the connection between dry eye and diabetes. (1) (2) (3) (4) (5)
25. Increase my knowledge of the role chronic inflammatory diseases and thyroid dysfunction play in dry eye. (1) (2) (3) (4) (5)
26. Improve my ability to recognize the impact of psychological and dermatological conditions on dry eye. (1) (2) (3) (4) (5)

*Rate the quality of the material provided:  
 1=Strongly disagree, 2=Somewhat disagree, 3=Neutral, 4=Somewhat agree, 5=Strongly agree*

27. The content was evidence-based. (1) (2) (3) (4) (5)
28. The content was balanced and free of bias. (1) (2) (3) (4) (5)
29. The presentation was clear and effective. (1) (2) (3) (4) (5)
30. Additional comments on this course:

Please retain a copy for your records. Please print clearly.

First Name

Last Name

E-Mail

The following is your:  Home Address  Business Address

Business Name

Address

City  State

ZIP

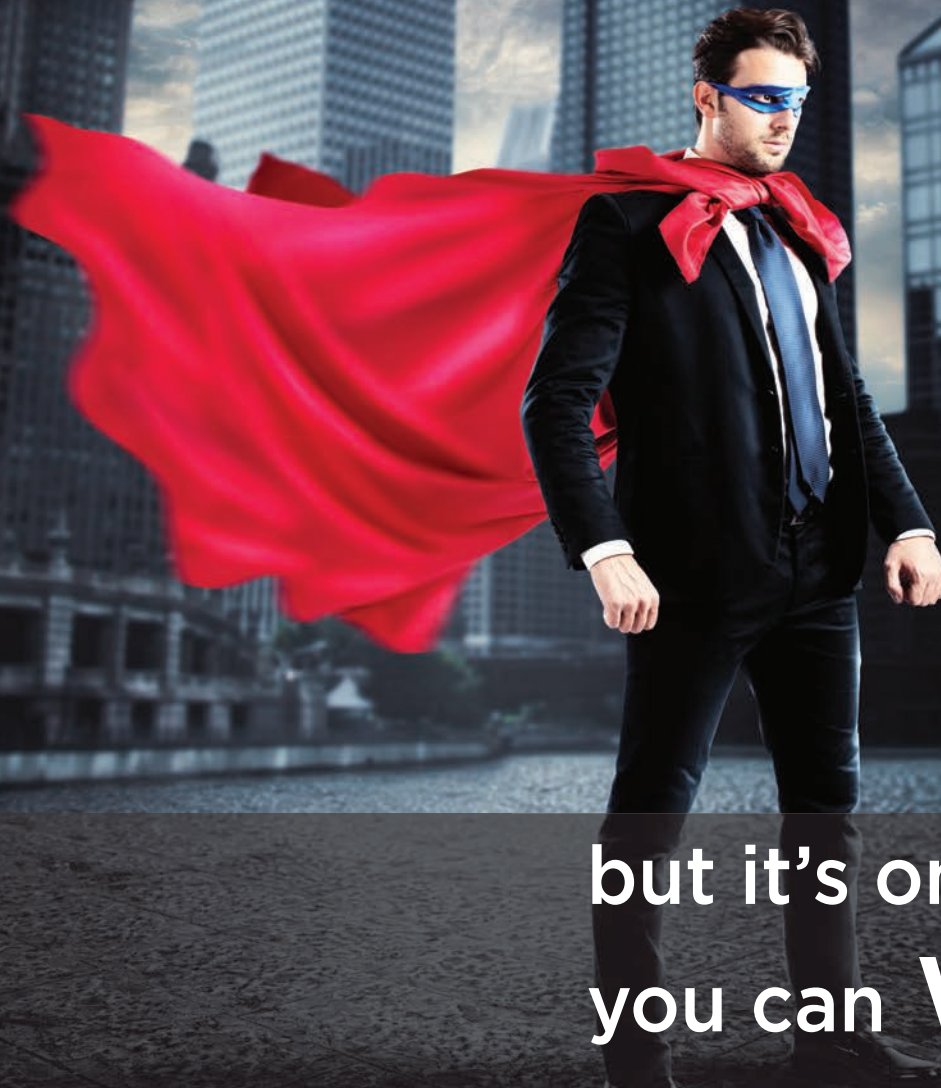Telephone #  -  -

Fax #  -  -

By submitting this answer sheet, I certify that I have read the lesson in its entirety and completed the self-assessment exam personally based on the material presented. I have not obtained the answers to this exam by any fraudulent or improper means.

Signature \_\_\_\_\_ Date \_\_\_\_\_

It may seem like a war...



but it's one  
you can **WIN.**

7

## Ways to Protect Your Contact Lens Practice

Every time you dispense a "one size fits all" disposable, you create a patient who can shop anywhere for a replacement lens. It could be a competitor, a discount online operation, or a company that promotes directly to patients.

Extreme H2O® disposable lenses are special because they provide unique fitting solutions that are not available from other companies. And by "fitting" your patients in lenses that are designed for their individual needs, there's a better chance they come back to YOU for their specialty disposable lenses.

**Learn More at: [www.7-Ways-CL.com](http://www.7-Ways-CL.com)**

877.336.2482 | [www.xcelspecialtycontacts.com](http://www.xcelspecialtycontacts.com)



**X-CEL**  
SPECIALTY CONTACTS

# The Dilated Exam in the Age of Ultra-widefield Imaging

The technology's pros and cons have made it a hot topic in recent years. Here's where it currently stands in clinical practice. **By Amanda S. Legge, OD**

**T**he advent of and improvements in ultra-widefield imaging (UWFI) technology now provide clinicians an excellent view of the posterior segment without dilation. On the surface, the technology offers many benefits. For the patient, it can decrease in-office wait time and eliminate any side effects of dilation. For the clinician, it can provide an opportunity to use a patient's own retinal image to discuss findings—thus improving patient care with visual education. But limitations to these instruments still exist, and most clinicians continue to question their place in clinical practice. This article takes a closer look at the standards of care for when dilated fundus examination (DFE) is indicated and where this new technology fits in.

## Set Your Standards Straight

A dilated fundus examination is considered the standard of care.<sup>1</sup> In fact, an optometrist could be legally liable if a UWFI image fails

to identify disease that could be reasonably proven was present at the time of the examination but was missed because of lack of dilation. DFEs remain the best method to maximally and stereoscopically visualize the posterior segment compared with UWFI alone from a legal, ethical and clinical standpoint. And when a UWFI instrument does image a suspicious retinal lesion, dilation is still the standard to further evaluate and accurately diagnose the finding.<sup>2</sup>

Despite this, some question the support for routinely dilating healthy, asymptomatic patients. Studies show that routine DFE has a low yield for discovery of serious ocular events and may be ineffective in altering the course and outcome of incidental findings, even at 10-year intervals in asymptomatic patients.<sup>3</sup> Others have found that dilated exams yield clinical findings in approximately 5% of asymptomatic, low-risk patients and few of these findings are beyond the

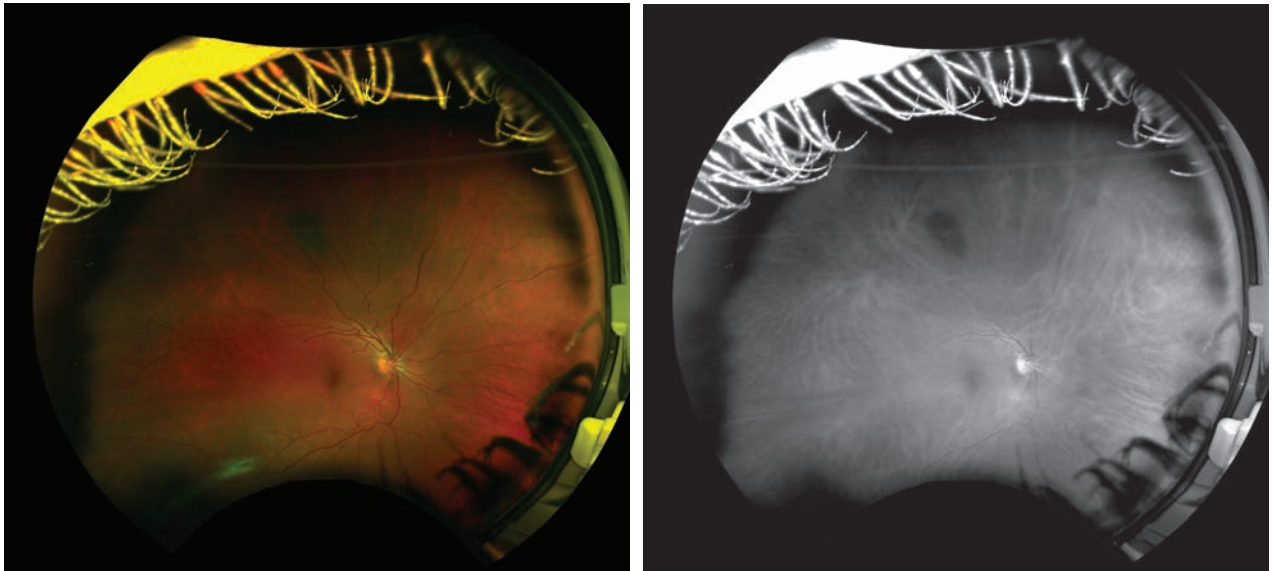
view of a direct ophthalmoscope or undilated indirect exam and even fewer were in need of treatment or intervention.<sup>4</sup> Despite the paucity of support in the literature, considering the ocular disease we can identify in those 5% of patients, it is ethically and legally our responsibility to perform regular DFEs, even on asymptomatic patients. UWFI without dilation should never be offered as a universal option to all patients, as it is below clinical standard of care.

Given the current standard, the choice to image rather than dilate remains a medical decision best made on a case-by-case basis. To make the right decision, clinicians must understand the evidence-based studies, the pros and cons of UWFI devices and dilation and the pitfalls of imaging alone.

## Consider the Evidence

UWFI performance compared with DFE varies based on the disease studied. Clinicians should carefully consider the evidence of commonly





**Figs. 1 and 2.** This patient has a longstanding choroidal nevus in the superior midperiphery that appears very light in color during funduscopy and could be easily overlooked if the biomicroscope is too bright and bleaches out the faint nevus. Even in the color UWFI image (left), it is somewhat difficult to appreciate; however, the green-free image (right) provides a clear view.

encountered posterior segment symptoms and diseases before recommending UWFI to the patient.

**Diabetes.** Given that nearly 86% of individuals with type 1 diabetes and 40% of those with type 2 diabetes have some form of clinically evident diabetic retinopathy (DR), the American Optometric Association's (AOA) Evidence Based Clinical Practical Guidelines and the American Academy of Ophthalmology's (AAO) Preferred Practice Pattern, recommend individuals with diabetes receive at least annual dilated eye examinations.<sup>5-7</sup> More frequent exams may be needed depending on the presence of DR, and the AOA outlines specific recommendations based on the severity.<sup>5</sup>

Several studies have demonstrated good agreement between Optomap UWFI (Optos) and dilated funduscopy of grading DR by doctors of varying levels of expertise.<sup>8</sup> Of the discrepancies noted, there were minimal to no instances where the difference in grading would have significantly or adversely affected

patient outcomes. In fact, data shows a tendency for clinical grading to be less severe than image grading, which could be a potential source of clinical risk if it delays treatment, as the disease severity changes the recommended follow-up schedule.<sup>8</sup>

Generally, studies conclude that although results seem promising for UWFI as a telemedicine screening tool in diabetes, a larger study size is required before it can be considered the standard of care.<sup>8-10</sup>

**Primary open-angle glaucoma.** The AOA and the AAO recommend an examination of the optic nerve that requires stereoscopic visualization with adequate magnification.<sup>11,12</sup> To achieve stereopsis, the pupils must be dilated and the patient examined with a 78D or 90D lens. Evaluation of the optic nerve also includes ruling out other potential causes of optic atrophy or subtle abnormalities that might result in visual field loss similar to that caused by glaucoma.<sup>11,12</sup> Therefore, patients with glaucoma

should be dilated on a regular basis to best assess definitive optic nerve head changes with stereopsis, which is still considered the standard for monitoring glaucoma.<sup>13</sup>

Currently, no reliable studies compare dilation with UWFI for grading either cup-to-disc ratio or

### Restricted Access

In our practice, patients are only eligible for UWFI screening in lieu of dilation under several conditions:

- (1) They had a normal dilated examination within the past two years.
- (2) They do not have any known ocular pathology.
- (3) They are not at high risk for any ocular disease, such as diabetic retinopathy.

Other considerations include the patient's refractive error, family history and current list of medications. The UWFI screening option is only offered to patients on a case-by-case basis by the doctors and is never discussed as an option by our staff. We do not have a universal option for patients to choose dilation vs. UWFI themselves.

# Dilation

the rate of glaucoma diagnosis and management. However, several studies show good agreement and high reproducibility in the evaluation of vertical cup-to-disc ratio compared with stereoscopic optic disc imaging, suggesting UWFI may be helpful for glaucoma diagnosis in situations in which standard color digital stereoscopy is not available.<sup>14</sup>

In some instances, certain UWFI features that allow easier assessment of the retinal nerve fiber layer (RNFL) may help improve glaucoma diagnosis and management, including red-free imaging and fundus autofluorescence (FAF). Although UWFI is not specifically designed to quantifiably measure RNFL loss, subtle RNFL defects seen using red-free images may indicate early glaucomatous damage before the development of glaucomatous optic nerve cupping.

Visible RNFL loss on red-free imaging should be further investigated as a potential indicator of glaucoma or other optic neuropathy as you would with other clinically identifiable risk factors. Red-free serial imaging can also be used to monitor for RNFL wedge defect progression over time.<sup>15</sup> Additionally, FAF can detect and monitor the extent of peripapillary atrophy, although not enough evidence exists to correlate hypo-FAF in peripapillary atrophy to functional glaucomatous damage.<sup>16</sup>

**Age-related macular degeneration (AMD).** Both the AOA and the AAO recommend stereoscopic

biomicroscopic examination of the macula.<sup>17,18</sup> Even conservative recommendations include comprehensive examinations with dilation every one to two years after the age of 65 to catch the subtle early signs

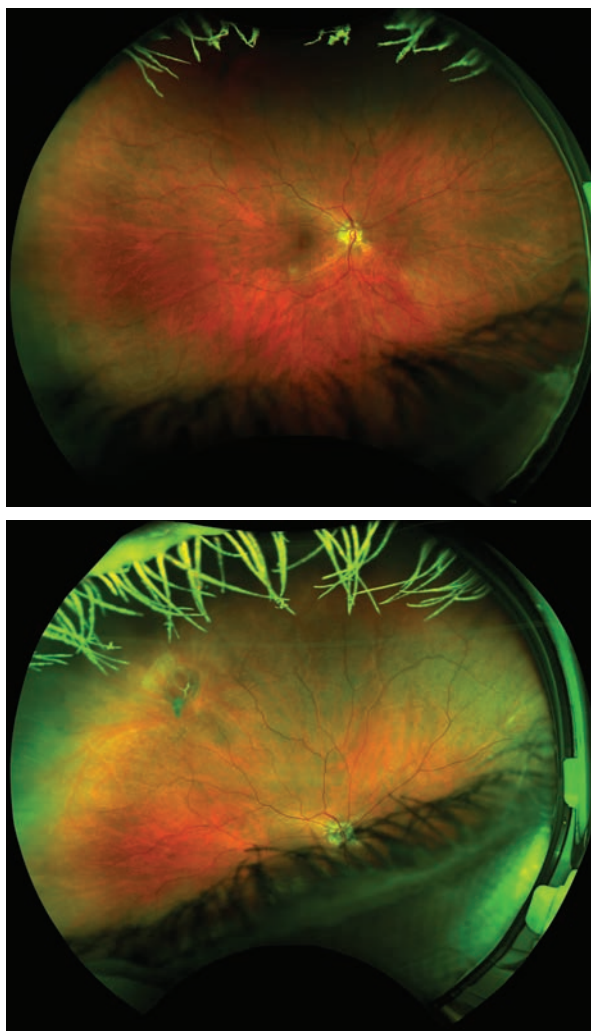
of macular degeneration.<sup>19</sup>

Patients diagnosed with AMD require dilation at appropriate intervals, depending on disease severity, to detect the earliest signs of choroidal neovascularization.

No studies show that color image UWFI has apparent benefits over dilated exams for the diagnosis or management of macular degeneration. While ongoing studies are evaluating the ability to phenotype the retinal periphery with UWFI to monitor peripheral pathologic changes in AMD, these peripheral grading criteria are difficult to assimilate into clinical practice.<sup>20,21</sup>

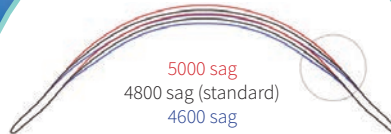**Posterior vitreous detachment and peripheral vitreoretinal disease.** According to the AOA, binocular indirect ophthalmoscopy with pupillary dilation is generally necessary to diagnose a peripheral retinal break or detachment with scleral depression, if indicated. The AAO's Preferred Practice Patterns specifically states "wide-field color photography can detect some peripheral retinal breaks but does not replace careful ophthalmoscopy" for peripheral vitreoretinal disease.<sup>22,23</sup>

Several studies compare dilation with UWFI modalities for non-traumatic retinal breaks, and most agree that UWFI is a useful adjunct for documentation, but its ability to detect the break, especially in the inferior and superior periphery, is low to moderate compared with DFE.<sup>24</sup> One study shows that for retinal



**Figs. 3 and 4.** Despite no entering symptoms, a DFE revealed a large operculum with four large retinal holes with surrounding subretinal fluid. Optomap imaging was recommended to photodocument the finding, and the initial photograph (top) was wide and reliable with the patient fixating straight as per routine protocol. After instructing the patient to look in the direction of known pathology, the holes were easily detected by the instrument (bottom). If this patient had not been dilated and UWFI were used to assess retinal health alone in primary gaze, her image would have been read as unremarkable. Instead, a thorough DFE enabled prompt diagnosis and same-day laser retinopexy.

# Indicated for Ocular Surface Disease Including Dry Eye



## SmartCurve™ Technology

Simplify your fitting.  
Modify only those parameters  
that need to change.



## MicroVault™ Technology

Fully vaults the lens over elevations  
that might interfere with a  
proper landing.

## Straight. Forward. Technology.

For Straightforward Scleral Lens Fitting.



### For irregular corneas

- Vaults the cornea and limbus to fit a wide range of corneas
- Lens diameters of 16.0 mm and 17.0 mm
- Prolate and oblate designs for a variety of corneal shapes



### For regular corneas

- Smaller diameters of 14.8 mm and 15.4 mm for regular corneas
- Single profile prolate design

Assistance from FCLSA\*  
trained fitting consultants

\* Fellow of Contact Lens Society of America

**Scleral lens technology to help you...  
and your patients.**

To learn more, call or visit:

**800-253-3669 • [www.bauschsvp.com](http://www.bauschsvp.com)**

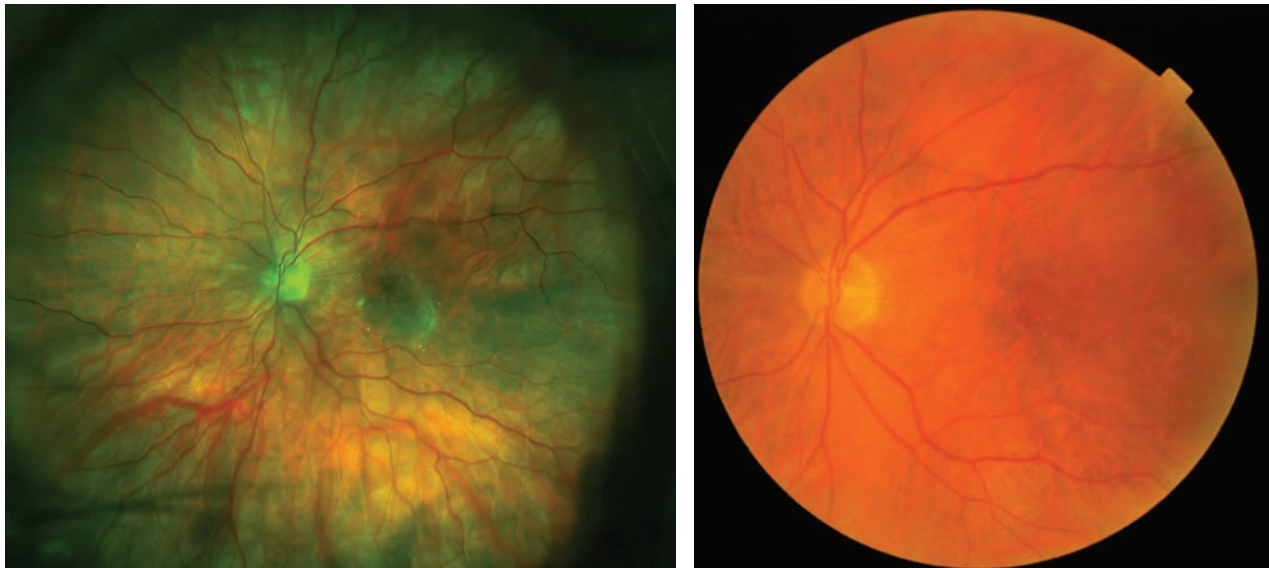
\*/TM are trademarks of Bausch & Lomb Incorporated or its affiliates. © Bausch & Lomb Incorporated. ALZN.0056.USA.17



**BAUSCH+LOMB**  
**Specialty**  
VISION PRODUCTS



# Dilation



**Figs. 5 and 6.** This patient has significant fine drusen throughout the posterior pole that was difficult to image using UWFI, left. If UWFI were the only modality used to monitor this patient's retinal health, it would likely be interpreted as normal. Instead, this patient's fundus photograph, right, clearly shows well defined, hard, small drusen scattered in the posterior pole, leading to further testing and a diagnosis of early AMD.

lesions posterior to the equator, sensitivity of detection was 74%; however, for anterior lesions it was only 45%.<sup>25</sup> Furthermore, occasional instrument artifacts can result in a false positive diagnosis of retinal detachment, choroidal lesions, vascular inflammation or retinal elevation, which causes undue stress to the patient. Thus, dilation remains the standard for detecting retinal tears in new symptomatic patients for peripheral retinal break.

## The Asymptomatic, Low-risk Patient

Few would argue that dilation is the preferred method of evaluation in the presence of known ocular disease or symptoms. However, significant contradictory evidence exists on the subject of annual dilation for asymptomatic, low-risk patients.

No strong evidence defines the optimal frequency of eye exams of patients younger than 65 with no ocular symptoms or signs. In fact, some evidence suggests the diagnos-

tic yield of DFEs in asymptomatic patients is not high, particularly in younger age groups.<sup>26,27</sup> Both the AAO and AOA acknowledge the lack of published research to support or refute the use of routine pharmacologic dilation in asymptomatic, low risk patients.<sup>1,19</sup>

The majority of studies comparing dilation with UWFI in asymptomatic, low-risk patients agree with a sensitivity and specificity of approximately 75%, which draws the conclusion that UWFI is a potential alternative to dilation. In addition, because of the automated red-free and green-free images offered with most devices, UWFI can sometimes be more sensitive for subtle findings such as small peripheral hemorrhages or microaneurysms and faint choroidal nevi.<sup>28,29</sup>

## The Pros of UWFI

Several benefits of using UWFI to examine posterior segment health exist. In addition to patient convenience and the elimination of

the side effects of dilation, it also impresses patients. Some may even seek out offices that are known to offer UWFI to avoid dilation if possible, which makes this technology quite profitable, as it is typically an additional out-of-pocket charge.

It also provides the doctor several advantages. It creates a permanent visual record clinicians can use to educate patients about their ocular health and any findings suspicious for diabetes, hypertension and other diseases. It can also document serial imaging over years to prove change over time and track progression. In addition, some pathology is actually more noticeable in imaging than dilated examinations when using the red-free and green-free images. For many conditions, seeing a wide view of the retina provides context to more accurately diagnose lesions (Figures 1 and 2).<sup>30</sup>

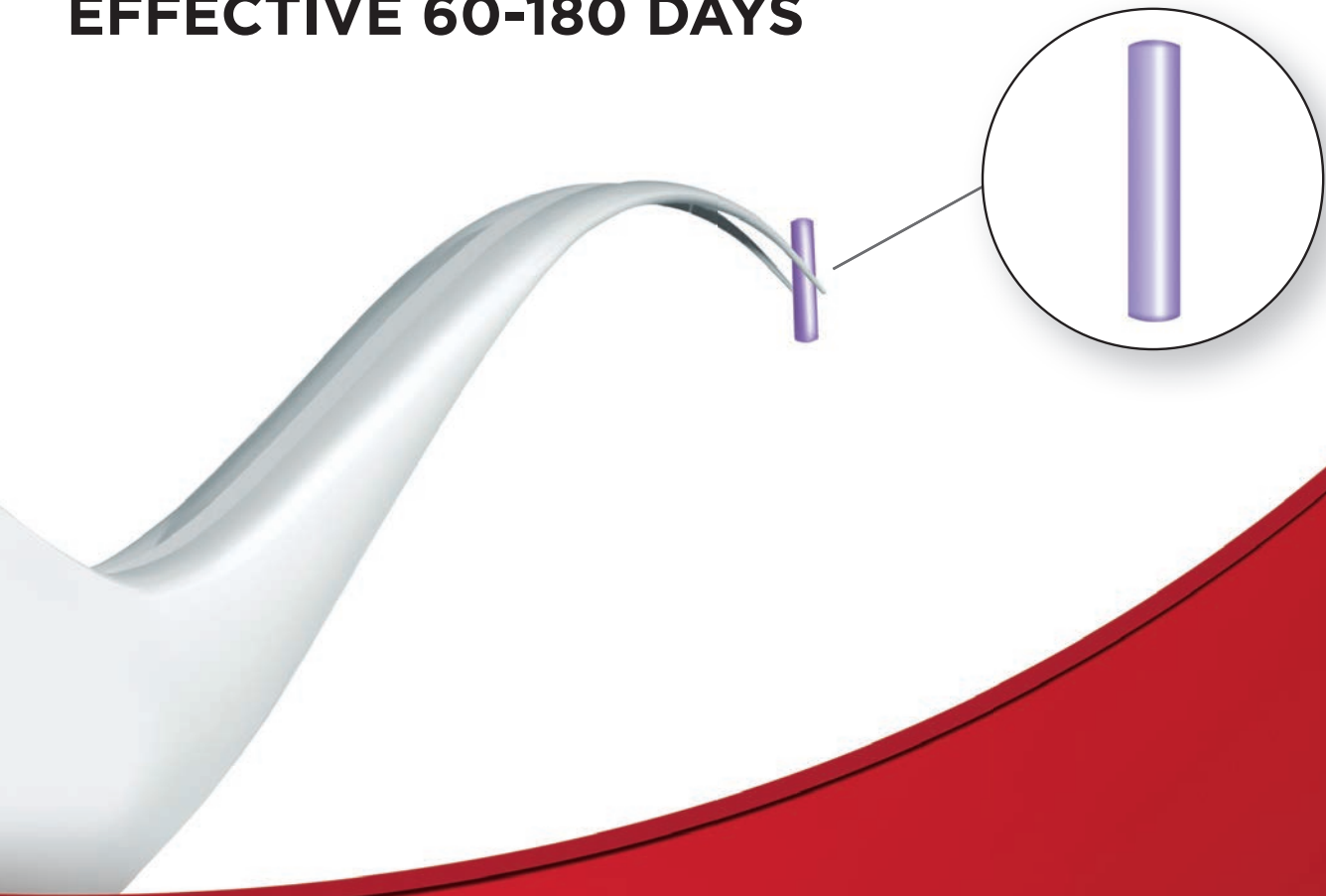
## The Limitations of UWFI

The most significant limitation of these devices is the inability to image

# DURAPLUG<sup>®</sup>

 EagleVision<sup>®</sup>  
A KATENA BRAND

## SYNTHETIC TEMPORARY PUNCTAL INSERTS EFFECTIVE 60-180 DAYS



**DuraPlug<sup>®</sup> is available in four sizes:  
0.2 mm, 0.3 mm, 0.4 mm, and 0.5 mm**

***Effective up to 180 days***

**Ideal for:**

- ✓ Treatment of post-LASIK induced dry eye
- ✓ Seasonal dry eye
- ✓ Retention of ocular medications

 **katena**  
DESIGNED FOR SIGHT<sup>®</sup>

800-225-1195 • [www.katena.com](http://www.katena.com)

the entire retina. Approximately 18% of the retina cannot be imaged, even through a dilated pupil with current technology.<sup>30</sup> Furthermore, this value is based on best-case scenario imaging. In a clinic setting, not every patient images well due to poor patient attention, dry eye, ocular media obscurations, lid ptosis or small pupils and/or dark choroid causing a dark image. Within most studies of UWFI, approximately 10% of images taken were of insufficient quality to interpret. Sometimes the anterior retinal pathology found during funduscopy cannot be imaged with UWFI, even with a fully dilated pupil (*Figures 3 and 4*).

Furthermore, because the UWFI image is an artificial composite of red and green light sources and uses an elliptical mirror to capture the widefield image, most UWFI devices often do not capture fine macular detail to the degree that a DFE or a traditional dilated macula photograph does. In some cases, artifacts in the macular region can preclude accurate diagnosis of more subtle abnormalities, particularly in the case of fine drusen that is indicative of early macular degeneration (*Figures 5 and 6*).<sup>31</sup>

## The Combo Approach

One of the best clinical uses of UWFI is as an adjunct to DFE. Research shows an Optomap-assisted fundus examination can improve pathology detection and help the clinician efficiently target an area of the retina during funduscopy in need of further investigation. Having a widefield image prior to performing the DFE improves the rate and accuracy of posterior segment disease diagnosis. One study showed a 30% increase in retinal lesion discovery compared with traditional DFE alone.<sup>32</sup>

UWFI can be particularly useful

in diagnosing and managing peripheral as well as posterior retinal pathology when used with other widefield imaging modalities such as red-free and green-free imaging, fundus autofluorescence, fluorescein angiography and indocyanine green angiography.

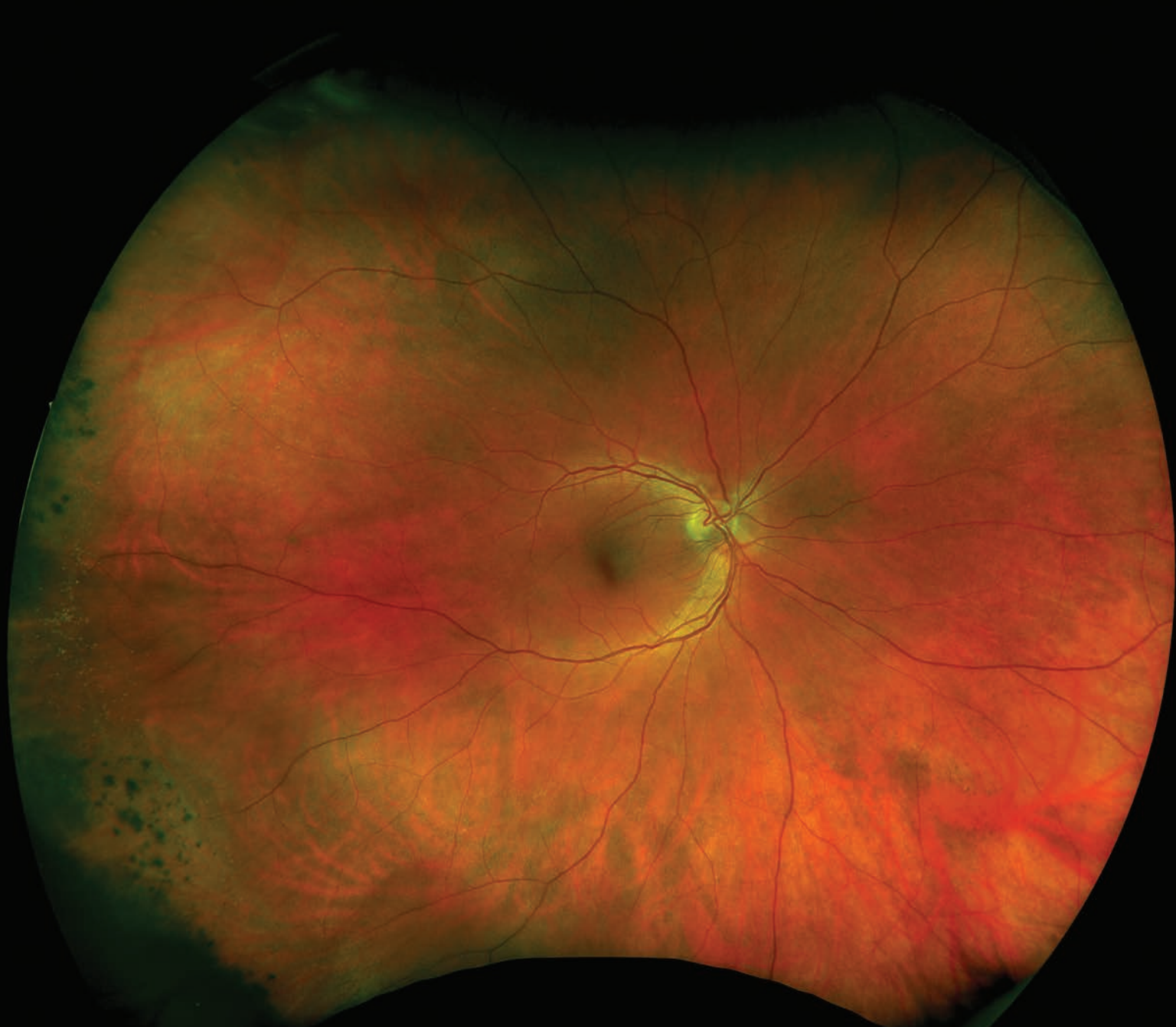While standards have yet to formally change, UWFI continues to affect the landscape of diagnosing and monitoring retinal pathology. It can be an invaluable adjunct to the traditional DFE for improving the rate of pathology detection, and it can help to capture peripheral lesions for medical photodocumentation. In cases of known disease, UWFI cannot replace a dilated fundus examination altogether. But in asymptomatic, low-risk patients, it may be a beneficial screening modality. It should never take away from our ability to care for each patient as an individual prior to advising a universal management protocol in lieu of what is still considered the standard of care. ■

*Dr. Legge is in private practice in Wyomissing, PA.*

1. AOA Evidence-based Optometry Committee. Evidence-Based Clinical Practice Guideline. Comprehensive Adult Eye and Vision Examination. American Optometric Association. 2015.
2. Bailey RN, Heitman E, eds. An Optometrist's Guide to Clinical Ethics. American Optometric Association, 2000. [www.aoa.org/documents/optometrists/book.pdf](http://www.aoa.org/documents/optometrists/book.pdf). Accessed September 12, 2018.
3. Varner P. How frequently should asymptomatic patients be dilated? *J Optom.* 2014;7(1):57-61.
4. Pooack AL, Brodie SE. Diagnostic yield of the routine dilated fundus examination. *Ophthalmology.* 1998;105(2):382-6.
5. AOA Evidence-based Optometry Committee. Evidence-based Clinical Practice Guideline: Eye Care of the Patient with Diabetes Mellitus. 2014.
6. American Academy of Ophthalmology Retina/Vitreous Panel. Preferred Practice Pattern Guidelines. Diabetic Retinopathy. American Academy of Ophthalmology. 2017.
7. Hazin R, Barazi MK, Summerfield M. Challenges to establishing nationwide diabetic retinopathy screening programs. *Curr Opin Ophthalmol.* 2011;22(3):174-9.
8. Purbrick R, Izadi S, Gupta A, Chong NV. Comparison of Optomap ultrawide-field imaging versus slit-lamp biomicroscopy for assessment of diabetic retinopathy in a real-life clinic. *Clin Ophthalmol.* 2014;8:1413-7.
9. Sallam A, Scanlon PH, Stratton IM, et al. Agreement and reasons for disagreement between photographic and hospital biomicroscopy grading of diabetic retinopathy. *Diabet Med.* 2011; 28(6):741-6.
10. Neubauer AS, Kernt M, Haritoglou C, et al. Nonmydriatic

- screening for diabetic retinopathy by ultra-widefield scanning laser ophthalmoscopy (Optomap). *Graefes Arch Clin Exp Ophthalmol.* 2008;246(2):229-35.
11. Fingeret M, Mancil GL, Baily IL, et al. Optometric Clinical Practice Guideline: Care of the Patient with Open Angle Glaucoma. 2010. [www.aoa.org/documents/optometrists/CPG-9.pdf](http://www.aoa.org/documents/optometrists/CPG-9.pdf). Accessed September 12, 2018.
  12. American Academy of Ophthalmology Glaucoma Panel. Preferred Practice Pattern Guidelines. Primary Open-Angle Glaucoma. American Academy of Ophthalmology. 2015.
  13. Thomas R, Loibl K, Parikh R. Evaluation of a glaucoma patient. *Indian J Ophthalmol.* 2011;59(Suppl1):S43-S52.
  14. Quinn N, Azuara-Blanco A, Graham K, et al. Can ultra-wide field retinal imaging replace colour digital stereoscopy for glaucoma detection? *Ophthalm Epidemiol.* 2017;5(1):63-9.
  15. Sherman J, Patel H, Nath S, et al. Correlation between Optos ultra widefield imaging and traditional diagnostic methods in glaucoma. *Ophthalmology.* 2009;80(6):302-3.
  16. Reznicek L, Seidensticker F, Mann T, et al. Correlation between peripapillary retinal nerve fiber layer thickness and fundus autofluorescence in primary open-angle glaucoma. *Clin Ophthalmol.* 2013;7:1883-8.
  17. American Academy of Ophthalmology Glaucoma Panel. Preferred Practice Pattern Guidelines. Age-Related Macular Degeneration. American Academy of Ophthalmology. 2015.
  18. AOA Consensus-based Optometry Committee. Consensus-Based Clinical Practice Guideline. Care of the Patient with Age-Related Macular Degeneration. 2004.
  19. American Academy of Ophthalmology Preferred Practice Patterns Guidelines. Comprehensive Adult Medical Eye Evaluation. American Academy of Ophthalmology. 2010.
  20. Lengyel I, Csutak A, Florea D, et al. A population-based ultra-widefield digital image grading study for age-related macular degeneration-like lesions at the peripheral retina. *Ophthalmology.* 2015;122(7):1340-7.
  21. Writing Committee for the OPTOS PPeripheral Retina (OPERA) study (Ancillary Study of Age-Related Eye Disease Study 2). Peripheral retinal changes associated with age-related macular degeneration in the Age-Related Eye Disease Study 2: Age-Related Eye Disease Study 2 Report Number 12 by the Age-Related Eye Disease Study 2 Optos PPeripheral Retina (OPERA) Study Research Group. *Ophthalmology.* 2017 Apr;124(4):479-87.
  22. AOA Consensus-based Optometry Committee. Consensus-Based Clinical Practice Guideline: Care of the Patient with Retinal Detachment and Peripheral Vitreoretinal Disease. 2004.
  23. American Academy of Ophthalmology Preferred Practice Patterns Guidelines. Posterior Vitreous Detachment, Retinal Breaks, and Lattice Degeneration. American Academy of Ophthalmology. 2014.
  24. Kornberg DL, Klufas MA, Yannuzzi NA, et al. Clinical utility of ultra-widefield imaging with the Optos Optomap compared with indirect ophthalmoscopy in the setting of non-traumatic rhegmatogenous retinal detachment. *Semin Ophthalmol.* 2016;31(5):505-12.
  25. Mackenzie P, Russell M, Ma PE, et al. Sensitivity and specificity of the Optos Optomap for detecting peripheral retinal lesions. *Retina.* 2007;27(8):1119-24.
  26. Pollack AL, Brodie SE. Diagnostic yield of the routine dilated fundus examination. *Ophthalmology.* 1998;105:382-6.
  27. Batchelder TJ, Fireman B, Friedman GD, et al. The value of routine dilated pupil screening examination. *Arch Ophthalmol.* 1997;115:1179-84.
  28. Nath S, Sherman J, Battaglia M. Is Optos imaging additive or duplicative to a dilated fundus exam? *Invest Ophthalmol Vis Sci.* 2005;46(13):1554.
  29. Nath S, Sherman J, Hossain SM. Comparison of panoramic imaging (Optos P200C) with traditional dilated retinal evaluation. *Invest Ophthalmol Vis Sci.* 2009;50(13):339.
  30. Shoughy S, Arevalo JF, Kozak I. Update on wide- and ultra-widefield retinal imaging. *Indian J Ophthalmol.* 2015;63(7):575-81.
  31. Pandya AN, Friberg TR, Eller AW. Optos non-mydratric widefield imaging vs. clinical dilated fundus exam for retinal diagnosis and management. *Invest Ophthalmol Vis Sci.* 2002;43(13):2860.
  32. Brown K, Sewell JM, Trempe C, et al. Comparison of image-assisted versus traditional fundus examination. *Eye and Brain.* 2013;2013(5):1-8.





▶ **optomap<sup>®</sup>** Image beyond the vortex vessels  
**in less than ½ second**

the **ONLY** ultra-widefield single-capture retinal image

Contact us for your risk-free evaluation at 800-854-3039 or [BDS@optos.com](mailto:BDS@optos.com)



A Nikon Company



Building *The* Retina Company

©2018 Optos. All rights reserved. Optos<sup>®</sup>, optos<sup>®</sup> and optomap<sup>®</sup> are registered trademarks of Optos plc.



# Breaking Down Resistance

While non-responsiveness to drugs like acyclovir during herpes simplex treatment is rare, doctors must know how to proceed if they run into this problem.

Edited by Joseph P. Shovlin, OD

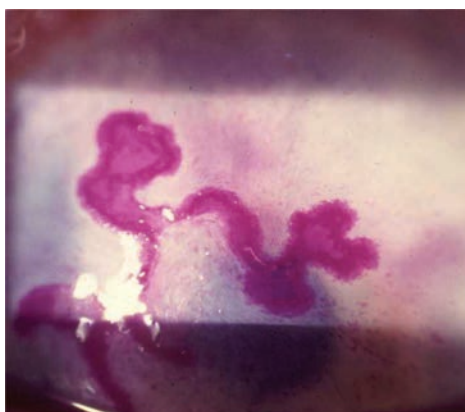**Q** I have a chronic herpes simplex patient with significant epithelial keratitis who might be resistant to acyclovir. Compliance does not appear to be an issue, but Valtrex along with steroid use is no longer helping. How can I be certain there is resistance? If there is, what is the best approach?

**A** Managing herpes simplex of the eye is mediated by frequency of occurrence and relative risk of vision loss over time, according to Jim Thimons, OD, medical director and founding partner of Ophthalmic Consultants of Connecticut. Of the possible treatments, Dr. Thimons says chronic oral therapy can help mitigate vision loss from tissue damage over time. Long-term therapy, however, can pose potential problems.

Because patients are living longer, they are receiving oral antiviral therapy for extended periods of time, Dr. Thimons notes. He adds that some could be on therapy indefinitely. As such, the rate of resistance to treatment has been slowly but steadily rising.

“With increased utilization, it is inevitable that the effect of the drug on the disease state is probably going to be altered,” Dr. Thimons adds.

Regardless, Dr. Thimons notes that the majority of immunocompetent patients—those who have herpes simplex keratitis but are healthy otherwise—have sig-



**Pictured here is a large dendrite with end bulbs that are stained with rose bengal.**

nificant and persistent responses to acyclovir, the primary agent against which all sensitivities are tested. Resistance is rare in these patients—more than 99% are sensitive to the drug, according to Dr. Thimons. Immuno-incompetent patients, on the other hand, develop resistance to treatment the longer it is administered, and they do so at a much higher rate, Dr. Thimons says.

## A Mutating Case

Resistance usually develops due to mutations in the thymidine kinase pathway that cause patients to become non-sensitive to acyclovir and its pro-drug valacyclovir, according to Dr. Thimons. He adds that these mutations occur randomly in immunocompetent patients but can be predicted by the severity of the disease state in immunocompetent patients.

## Response to a Rarity

In this particular case, the prescriber followed the appropriate treatment course but ran into a rare situation, says Dr. Thimons, who offers several treatment recommendations moving forward. His first suggestion is switching the patient from acyclovir to famciclovir or topical ganciclovir, both of which do not belong to the same family as acyclovir and contain different molecules that the patient could be sensitive to, he notes. Dr.

Thimons also recommends ODs consider the use of “old school drugs” like trifluridine and vidarabine, which are less effective than current oral agents but play an active role in managing viral infectious processes, he notes. He adds that these drugs have different mechanisms of action, so patients might be more sensitive to them.

According to Dr. Thimons, the solution to this problem could be as simple as switching medications, but he warns doctors not to wait too long or else they could risk the chance of glaucoma developing in their patient. If new drugs are administered but are not effective within a week or two, Dr. Thimons advises referring to a corneal specialist for cellular analysis to determine what type of mutation is present and, from there, what path to take for the most successful results. ■

# SIMPLE AND EFFECTIVE LENS CARE

A CLEAR CHOICE FOR PATIENTS AND PRACTICES IS CLEAR CARE® PLUS



April Jasper, OD, FAO

Advanced Eyecare Specialists  
(private practice)  
West Palm Beach, FL

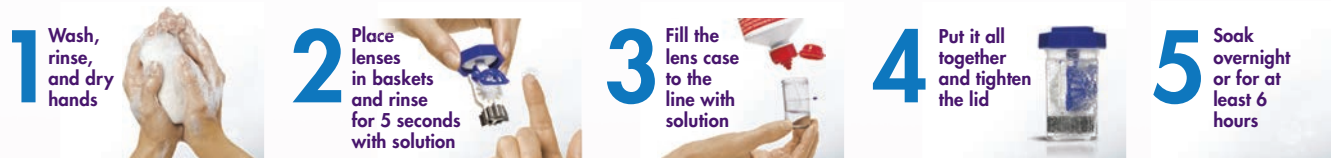Dr. Jasper was compensated by Alcon for her participation in this advertorial.



I met with a young professional patient the other day who, like so many others, was excited about the opportunity to wear contact lenses. I knew that a monthly replacement lens would be a great option for his vision and lifestyle needs, and also how important good lens care would be. Of course, we can all be... well, forgetful sometimes —

the lens care routine. In addition, CLEAR CARE® PLUS' bubbling action provides a visual reminder to patients to use fresh solution every time. Similar to what I see in practice, study data show that CLEAR CARE® PLUS' design supports significantly greater lens care compliance than MPS.<sup>6,7</sup> My experience with CLEAR CARE® PLUS is also that enthusiasm for the

## CLEAR CARE® PLUS CLEANS AND DISINFECTS LENSES IN A FEW SIMPLE STEPS\*

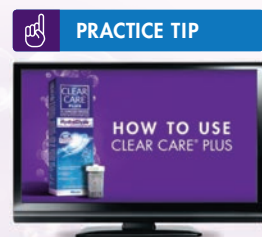

which is why I introduced him to CLEAR CARE® PLUS for his daily lens cleaning and disinfection. CLEAR CARE® PLUS is highly effective against a wide range of organisms,<sup>1,2</sup> supports outstanding lens comfort,<sup>3,4</sup> and maybe most importantly, is easy to use.<sup>3</sup> For patients new to contact lenses, this translates to a safe and enjoyable lens wear from day one!

The reasons why I chose CLEAR CARE® PLUS for this patient are the same reasons why I recommend it every day. With its five simple steps, CLEAR CARE® PLUS is a great option for new and experienced lens

product does not end when people leave the office — my patients continue to use CLEAR CARE® PLUS long after my initial recommendation, a sign of just how much they like using it.

A practice-wide approach to patient education about lens care is important to supporting patients' success, and the resources and tools that Alcon offers help make this possible. My office staff loves being able to walk patients through the simple steps for CLEAR CARE® PLUS use — and patients really value hearing it from someone other than their doctor. The same resources that help me talk about CLEAR CARE® PLUS in the exam room ("How to Use CLEAR CARE® PLUS" video and the Patient Tip Card with coupon) also help my staff take an active role in setting patients up for success.



View this video at  
[https://youtu.be/mJMGPD\\_kn0](https://youtu.be/mJMGPD_kn0)

**PRACTICE TIP**  
In addition to walking patients through how to use CLEAR CARE® PLUS, I always show them Alcon's "How to Use CLEAR CARE® PLUS" video, to reinforce the information that I have just shared with them. I also make sure that they know where to find the video online any time they need a quick refresher or want to show their family and friends how much they love their lens care solution!

wearers alike. Patients are always pleasantly surprised by how easy CLEAR CARE® PLUS is to use,<sup>3</sup> and are excited to try it for themselves. The lack of a rub step with CLEAR CARE® PLUS (a required but often neglected step among multipurpose solution (MPS) users<sup>5,6</sup>) simplifies

For any patient not in daily disposable contact lenses, I recommend CLEAR CARE® PLUS lens care. It is highly effective,<sup>1,2</sup> and, thanks to the inclusion of Alcon's HydraGlyde® Moisture Matrix, supports outstanding lens comfort.<sup>3,4</sup> Just as importantly, I love the simplicity of using CLEAR CARE® PLUS<sup>3</sup> — it makes educating patients easy and helps ensure that they are taking advantage of its efficacy and comfort benefits. With CLEAR CARE® PLUS, I know that I am giving my patients the opportunity to enjoy simple, effective lens care every day.



**References** 1. Gabriel MM, Bartell J, Walters R, et al. Biocidal efficacy of a new hydrogen peroxide contact lens care system against bacteria, fungi, and Acanthamoeba species. *Optom Vis Sci*. 2014;91:E-abstract 145192. 2. Gabriel MM, McAnally C, Bartell J, et al. Biocidal efficacy of a hydrogen peroxide lens care solution incorporating a novel wetting agent. *Eye & Contact Lens*. 2018;Epub ahead of print. 3. Alcon data on file, 2016. 4. Alcon data on file, 2016. 5. Dumbleton KA, Woods CA, Jones LW, Fonn D. The relationship between compliance with lens replacement and contact lens-related problems in silicone hydrogel wearers. *Cont Lens Anterior Eye*. 2011;34:216-222. 6. Woods J, Srinivasan S, Jones L. Compliance with the use of hydrogen peroxide and multipurpose solution care regimens. *Contact Lens Spectrum*. In press. 7. Guthrie S, Dumbleton K, Jones L. Contact lens compliance: Is there a relationship between care system and compliance? *Contact Lens Spectrum*. 2016;31:40-43.







It's not too late to still support the **Challenge**

*Help a child to see.*



✓ Please make your donation by November 30th!

Visit [givingsight.org](https://givingsight.org) or call 303-526-0430



**OPTOMETRYGIVINGSIGHT**

*Transforming lives through the gift of vision*



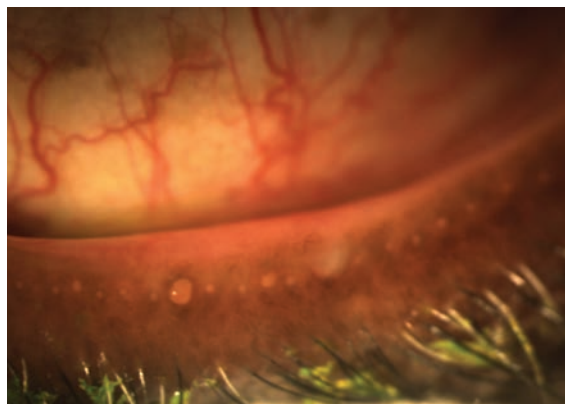
# The Many Methods of MGD

More options for cleaning and treating the lid margins and meibomian glands means better patient care. **By Paul M. Karpecki, OD**

**B**ecause a majority of patients with dry eye have the evaporative form that accompanies meibomian gland dysfunction (MGD), with or without aqueous deficiency, researchers, manufacturers and clinicians have all focused on methods to clear obstructed meibomian glands and restore the flow of healthy lipids into the tear film.<sup>1</sup> This has led to the rise of many in-office treatments that provide the promise of symptomatic relief for patients with MGD, as well as new revenue opportunities for clinicians and practices.

## Tried and True

The most established treatment for MGD is Lipiflow (Johnson & Johnson Vision), which has many peer-reviewed papers in the literature to support its efficacy. The 12-minute, automated treatment heats the inner eyelid closest to the meibomian glands and simultaneously massages the lids to evacuate gland contents. Several studies have reported sustained effects over 12 months or more following a single treatment, including significant reductions in symptoms and improvements in MG secretions.<sup>2-4</sup> Reports also note increased comfortable contact lens wear time of more than four hours following a single Lipiflow treatment.<sup>5</sup>



**These obstructed meibomian glands respond to digital pressure by releasing thickened, cloudy meibum. Newer treatments seek to improve results and patient comfort.**

Photo: Dean Hunt/Kevok, OD

biofilm may have a significant impact on dry eye disease, supporting therapeutic interventions such as Blephex.<sup>7</sup> More than just a simple debridement, this procedure removes biofilm contributing to MGD and DEBS from the meibomian glands, lid margins and lashes. A spinning, disposable, medical-grade micro-sponge removes scurf and debris, exfoliating the affected areas. The brush cleans all four lids in seven to 10 minutes.

## Adjunctive Therapies

A number of other in-office strategies can help to increase the efficacy of home-based lid hygiene measures and extend the effectiveness of therapeutic treatments:

**Lid debridement.** Mechanical debridement/scaling of the line of Marx and the lid margin removes keratin from the meibomian gland orifices that can obstruct lipid expression to the ocular surface; these keratin deposits can also predispose the patient to blepharitis. One study found that debridement on its own provided statistically significant symptom relief and improved meibomian gland function.<sup>6</sup> The technique can have a synergistic effect when combined with other treatments that heat or express the glands.

**Blephex.** According to the dry eye blepharitis syndrome (DEBS) theory, mechanical removal of

## Intense pulsed light (IPL).

Dermatologists have used these systems for years to treat acne rosacea. Treatments are performed with 500nm to 1,200nm light pulses for 20 to 30 minutes, and can be repeated every four to five weeks. Doctors with aesthetic practices noticed that treatment often seemed to improve dry eye symptoms as well, and some began performing IPL for MGD. The theory is that high-intensity light is absorbed by oxyhemoglobin, potentially reducing the amount of inflammatory mediators reaching the meibomian glands. Although preliminary results have shown some improvement in tear break-up time (TBUT) with IPL, it is not entirely clear which patients benefit most and whether IPL should be considered a primary or adjunctive treatment.<sup>8</sup>

## New to Market

Recently launched by Tear Film Innovations, iLux is a small, cost-effective in-office treatment for MGD that has a hand piece with a detachable, disposable, sterile tip and a magnifying lens. It is designed to provide better visualization of the blocked meibomian gland orifices and expressed meibum before and during the treatment. Once the LED-based heat source warms the inner and outer lids to a therapeutic temperature range, the clinician applies compression to express the melted meibum.

Based on the patient's needs, the clinician can move the tip to different locations on the upper and lower lids and adjust the degree and duration of compression needed at each location. Most patients can be treated in under eight minutes.

In a randomized, open-label, multisite clinical trial comparing the iLux system to a predicate device, 142 patients were randomized between treatment options. Researchers looked at Meibomian Gland Score (MGS), TBUT and the Ocular Surface Disease Index (OSDI) questionnaire.

MGS improved from 5.6 prior to treatment with the iLux to 23.6 at week four, and tear-break-up time improved by more than 75% by week four; however, both improved as soon as two weeks. The OSDI scores also improved from more than 50 prior to treatment to about 20 by two weeks after treatment and improved further at four weeks.

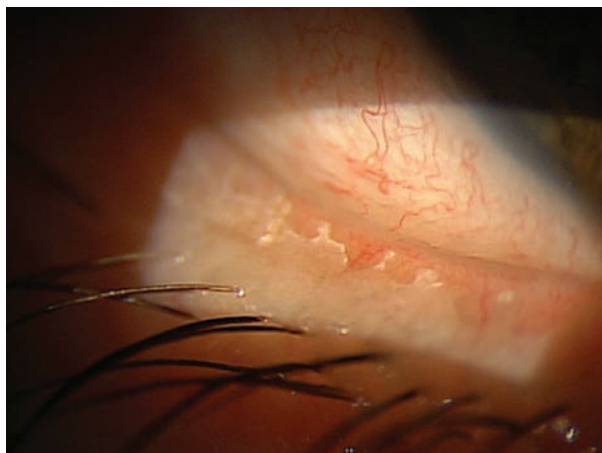
Overall, both treatments produced statistically and clinically significant

improvements in the signs and symptoms of MGD, meeting the FDA criteria for approval.

## In the Pipeline

The TearCare system (Sight Sciences)—an in-office treatment that just debuted at the Academy of Optometry meeting and is being rolled out now—includes a single-use treatment kit that consists of four adhesive applicators that deliver heat (at 41°C to 45°C) to the external lids. The applicators are connected by a cable to a small, reusable handheld unit. Patients are instructed to blink normally during the 12-minute procedure to express meibum, and the clinician uses expression forceps afterwards to further evacuate the glands.

A prospective, randomized, pilot study demonstrated that the treatment had an immediate improvement on objective measures (TBUT, MGS and corneal and conjunctival staining) that was sustained through six months, while no such improvement was seen in the control group using daily at-home warm compresses with the washcloth bundle method.<sup>9</sup>



**Removing biofilm from the lid margin via Blephex reduces risk of blepharitis and dry eye as well.**

## The More, the Merrier

In-office treatment for meibomian gland dysfunction can be a great service for patients who are suffering from the symptoms of MGD and dry eye disease. The importance of good eyelid health and hygiene provides comfort, reduces risk of blepharitis and protects the ocular surface from potential compromise. Care of the lids and meibomian glands can also help set your patients up for success when preparing for cataract or refractive surgery or experiencing decreased contact lens wearing time.

These treatments can also be an important new revenue source for an optometric practice. This is a great time to evaluate available and upcoming treatments to determine how they might best fit into your practice. ■

*Note: Dr. Karpecki consults for a number of manufacturers with products relevant to this topic.*

1. Lemp MA, Crews LA, Bron AJ, et al. Distribution of aqueous-deficient and evaporative dry eye in a clinic-based patient cohort: a retrospective study. *Cornea*. 2012;31(5):472-8.
2. Lane SS, DuBiner HB, Epstein RJ, et al. A new system, the LipiFlow, for the treatment of meibomian gland dysfunction. *Cornea*. 2012;31(4):396-404.
3. Blackie CA, Coleman CA, Holland EJ. The sustained effect (12 months) of a single-dose vectored thermal pulsation procedure for meibomian gland dysfunction and evaporative dry eye. *Clin Ophthalmol*. 2016;10:1385-96.
4. Greiner JV. Long-term (3-year) effects of a single thermal pulsation system treatment on meibomian gland function and dry eye symptoms. *Eye Contact Lens*. 2016;42(2):99-107.
5. Kading D. Presented at Vision Expo West (VEW), 2015; Las Vegas, NV.
6. Korb DR, Blackie CA. Debridement-scaling: A new procedure that increases meibomian gland function and reduces dry eye symptoms. *Cornea*. 2013;32(12):1554-7.
7. Rynerson JM, Perry HD. DEBS—a unification theory for dry eye and blepharitis. *Clin Ophthalmol*. 2016;10:2455-67.
8. Toyos R, McGill W, Briscoe D. Intense pulsed light treatment for dry eye disease due to meibomian gland dysfunction; A 3-year retrospective study. *Photomedicine and Laser Surgery*. 2015;33(1):41-6.
9. Badawi D. A novel system, TearCare, for the treatment of the signs and symptoms of dry eye disease. *Clin Ophthalmol*. 2018;12:683-94.



new!

thera  
tears.

EXTRA



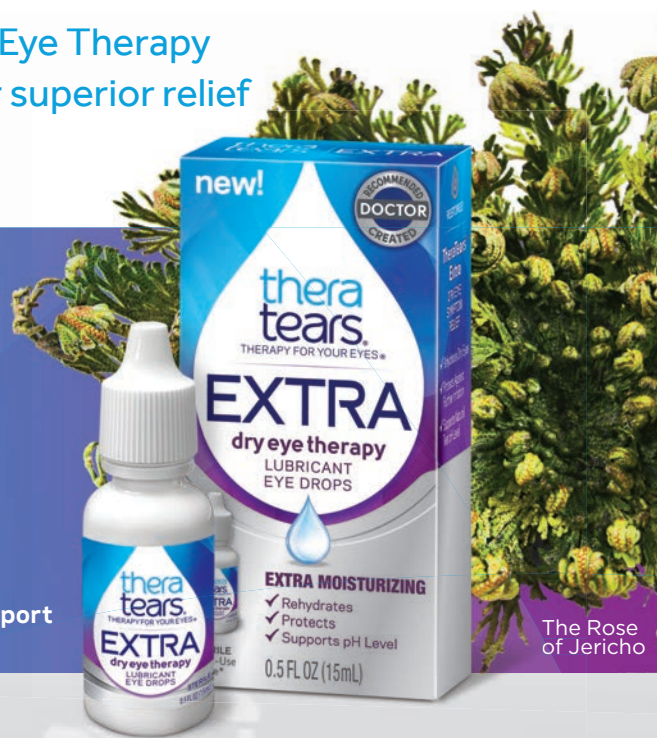# HARNESS EXTRA POWER FROM A NATURAL WONDER

NEW TheraTears® Extra Dry Eye Therapy  
is enhanced with trehalose for superior relief

Trehalose is a natural disaccharide found in plants with moisture retention properties that help organisms survive in absence of water. In ophthalmic products, trehalose enhances active ingredients to help<sup>1</sup>:

- Protect corneal cells from desiccation
- Restore osmotic balance to the ocular surface
- Maintain the homeostasis of corneal cells

-2017 DEWS II Report



The Rose  
of Jericho

Learn about our complete line of  
dry eye therapy products at [theratears.com](http://theratears.com)

Reference: 1. Jones L, Downie L, Korb D, et al. TFOS Dews II Management and Therapy Report. The Ocular Surface Jul 2017; 575-628.

© 2018 Akorn Consumer Health | A Division of Akorn, Inc. | M17-047

25<sup>TH</sup> ANNUAL

# OPHTHALMIC

## *Product Guide*



Innovative products to  
enhance your practice

The **future**  
is in your  
hands. One  
tap, many  
possibilities.

Experience the digital edition on your handheld device.  
Use your smart device to scan the code below or visit:



[www.reviewofoptometry.com/publications/archive](http://www.reviewofoptometry.com/publications/archive)

Download a QR scanner app. Launch app and hold your mobile device over  
the code to view <https://www.reviewofoptometry.com/publications/archive>

**REVIEW**  
OF OPTOMETRY



# Hydrops it Like it's Hot

If you can quickly resolve edema in these cases, you'll reduce the need for a transplant.

By Azinda Morrow, OD, and Richard Mangan, OD

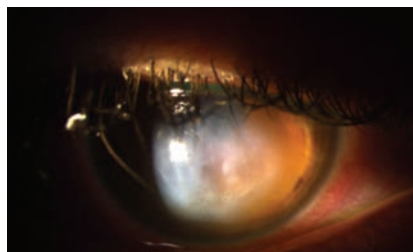Advanced imaging technologies are showing that corneal ectasias such as keratoconus are more prevalent than previously thought—up to 265 cases per 100,000 people.<sup>1</sup> Those with family history, eye rubbing and atopy, as well as Down syndrome tend to be more commonly affected, and are typically diagnosed during puberty.<sup>2</sup> Acute corneal hydrops—a severe complication of corneal ectasia—occurs in as few as 2%, and up to 13%, of patients.<sup>3-5</sup>

## History

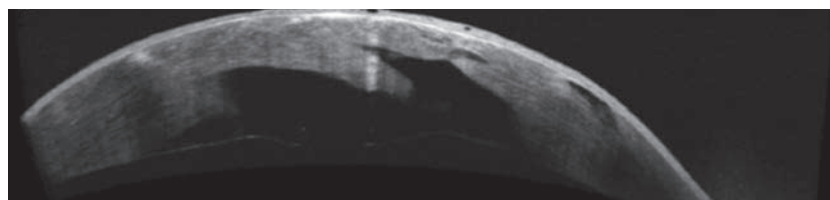
A 40-year-old African-American male presented with sudden-onset pain in the right eye for the last two days, and associated blurry vision. He rated the pain an “eight out of 10” in severity. He also complained of redness and photophobia but denied any discharge, history of ocular surgery, foreign material entering the eye or trauma. This was the first occurrence of these symptoms. The patient attempted to use artificial tears without relief. His ocular history was significant, however, for keratoconus, for which he was prescribed scleral lenses.

## Examination

The patient's entering uncorrected visual acuity was 20/800 at one foot in the right eye, with mild improvement on pinhole to 20/400 at two feet. Corrected visual acuity in the left eye with the scleral lens was 20/20. An external examination revealed an area of corneal opacification in the right eye, causing pupil



**Fig. 1.** At left, this patient's right eye shows grade 3+ global conjunctival injection, grade 3+ corneal edema, trace micro bullae and epithelial defects.



**Fig. 2.** This anterior segment OCT shows a break in the patient's Descemet's membrane and corneal edema.

testing to be difficult. The left pupil was round, reactive and had no signs of an afferent pupillary defect. Confrontation visual fields were full to hand motion in the right eye and full to finger counting in the left eye. Extraocular muscle testing was normal. Biomicroscopy of the right eye revealed grade 3+ global conjunctival injection, grade 3+ corneal edema, trace micro bullae and epithelial defects (*Figure 1*). Intraocular pressure was normotensive and dilated fundus exam was unremarkable. An anterior segment OCT was performed revealing a break in Descemet's membrane and corneal edema (*Figure 2*).

## Diagnosis

Corneal hydrops is caused by splitting of Descemet's membrane, leading to an influx of aqueous into the corneal stroma with resultant edema and haze.<sup>6</sup> Depending on the patient and the extent of the tear, corneal edema and pain can range from

relatively asymptomatic to severe with visual impairment.<sup>4,6</sup> Corneal hydrops is more common in males between the ages of 20 and 40, but has no race predilection.<sup>3-6</sup>

Acute corneal hydrops is self-limiting, with or without treatment, and tends to resolve over the course of three to four months as Descemet's membrane re-seals.<sup>3</sup> Depending on the size of the break and the patient's risk of corneal infection or neovascularization, time to complete healing may be extended.<sup>3,4,6</sup> Corneal perforation, although rare, occurs in 3% of patients who develop hydrops.<sup>3</sup> To prevent secondary complications, minimize patient symptoms and limit corneal scarring, initiation of medical management is typically warranted.

## Treatments

A variety of medical and surgical options are available to treat corneal hydrops. Topical hyperosmotics, can reduce corneal edema (albeit

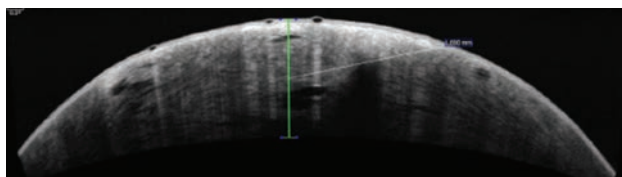


slowly), and improve acuity. To further manage corneal edema while also reducing the risk for potential neovascularization, ODs can prescribe topical steroids—usually starting with a twice-daily dose.

Since steroids have the potential to hinder corneal healing or cause corneal perforation, initiating steroid treatment at onset, or even once Descemet's membrane heals, is controversial. A cycloplegic agent, typically dosed at twice per day (more if pain persists), can be added to reduce ocular pain from a secondary uveitis. Other options for pain relief include oral or topical nonsteroidal anti-inflammatory agents or a bandage contact lens. However, depending on the severity of the patient's keratoconus the lens may fail to fit appropriately with significant edge fluting and decentration. As long as epithelial defects are present, a prophylactic antibiotic should be prescribed to decrease the potential for infection.

Research shows oral doxycycline (10mg to 50mg twice per day) and vitamin C (1,000mg per day)—typically dosed early in the course of acute hydrops—can be beneficial.<sup>7,8</sup> Doxycycline may also reduce matrix metalloproteinases, which promotes corneal healing.<sup>8</sup> Vitamin C has a role in the extracellular matrix and corneal composition, and can decrease opacification and neovascularization.<sup>7</sup> Other options to enhance corneal healing include amniotic membrane transplants and copious preservative-free artificial tears.

Surgical interventions include injection of air or gas, sulfur hexafluoride (SF<sub>6</sub>) or perfluoropropane (C<sub>3</sub>F<sub>8</sub>), into the anterior chamber to mechanically close the opening in Descemet's membrane.<sup>9,10</sup> These



**Fig. 3. This image shows the patient's corneal thickness three weeks after treatment. It had thinned by approximately 400µm.**

improve healing time but do not impact visual acuity outcomes, making them controversial due to potential adverse events.<sup>9,10</sup> For maximum effect, these procedures must be performed typically within days after the initial onset of symptoms.<sup>9,10</sup>

### Recovery

The longer the hydrops takes to heal, the more likely a transplant will be required, due to residual scarring. If this scar is large, or directly on the visual axis, either a deep anterior lamellar keratoplasty or a penetrating keratoplasty may be performed, depending on the extent of the scarring.<sup>3</sup> Some surgeons advocate for earlier intervention before any corneal neovascularization occurs, to decrease the risk of transplant rejection. Prior to any surgical referral, attempting a gas permeable contact lens fitting will allow for assessment of best visual acuity and can delay surgery, if the patient can achieve functional vision.

In our patient's case, we prescribed a hyperosmotic ointment, cycloplegic and antibiotic, along with oral doxycycline and vitamin C. Within three weeks, his corneal thickness was thinner by approximately 400µm (Figure 3). Although standard pachymetry can be helpful to monitor for resolution, 'global' pachymetry or AS-OCT are more beneficial as a larger area of the cornea can be imaged and healing of Descemet's membrane can be visualized. Patients with acute corneal

hydrops should be monitored every two to three days after initial onset, followed by every one to two weeks once healing has begun. However, if the cornea appears significantly thinned, more frequent follow-up

is prudent to prevent perforation. Use of a fox shield is recommended. Once healed, these patients should follow-up every three months for repeat imaging.

Practitioners should strive to minimize patient symptoms and avoid devastating long-term complications with appropriate medical management. Diagnostic imaging equipment can be helpful not only with initial diagnosis, but also in monitoring resolution. While corneal hydrops is rare, advances in detection and treatments of keratoconus, with corneal crosslinking may reduce or eliminate it in the future. ■

*Dr. Morrow is an assistant clinical professor at the State University of New York College of Optometry.*

1. Godefrooij D, de Wit G, Uiterwaal C, et al. Age-specific incidence and prevalence of keratoconus: a nationwide registration study. *Am J Ophthalmol.* 2017;175(3):169-72.
2. Gokhale N. Epidemiology of Keratoconus. *Indian J Ophthalmol.* 2013;61(8):382-3.
3. Barsam A, Petruslin H, Brennan M, et al. Acute corneal hydrops in keratoconus: a national prospective study of incidence and management. *Eye (Lond).* 2015;29(4):469-74.
4. Gokul A, Krishnan T, Emanuel P, et al. Persisting extreme acute corneal hydrops with a giant intrastromal cleft secondary to keratoconus. *Clin Exp Optom.* 2015;98(5):483-6.
5. Thimons J. Managing acute corneal hydrops in keratoconus. *Rev Cornea & Cont Lens.* 2015;152(3):32-3.
6. Fuentes E, Sandali O, El Sanharawi M, et al. Anatomic predictive factors of acute corneal hydrops in keratoconus: an optical coherence tomography study. *Ophthalmol.* 2015;122(8):1653-9.
7. Cho Y, Yoo W, Kim S, et al. Efficacy of systemic vitamin C supplementation in reducing corneal opacity resulting from infectious keratitis. *Medicine (Balt).* 2014;93(23):1-8.
8. Perry H, Hodes L, Seedor J, et al. Effect of doxycycline hyclate on corneal epithelial wound healing in the rabbit alkali burn model. *Cornea.* 1993;12(5):379-82.
9. Maharana P, Sharma N, Vajpayee R. Acute corneal hydrops in keratoconus. *Indian J Ophthalmol.* 2013;61(8):461-4.
10. Shaw J. Acute hydrops: rethinking treatment. *EyeNet Magazine.* [www.aaopt.org/eyenet/article/acute-hydrops-rethinking-treatment](http://www.aaopt.org/eyenet/article/acute-hydrops-rethinking-treatment). June 2012. Accessed October 15, 2018.

Earn up to  
**11 CE**  
Credits\*

# SAVE THE DATE!

The Optometric Retina Society &  
Review Group Vision Care Education Present

# RETINAUPDATE 2018

November 30 - December 1 • Scottsdale, AZ



## FAIRMONT SCOTTSDALE

7575 E Princess Drive  
Scottsdale, AZ 85255  
480-585-4848

A limited number of rooms have been reserved at \$259/night plus applicable taxes. Make your reservations with the hotel at 1-800-344-4758, mention "Review's Optometric Retina Society Meeting" for group rate.

### REGISTRATION COST:

ORS Member: \$405    Non-member: \$450

**PROGRAM CHAIRS:** Steven Ferrucci, OD, FFAO  
Mohammad Rafieetary, OD, FFAO

**FACULTY:** Mark Barakat, MD; Jeffry Gerson, OD, FFAO;  
Leo Semes, OD, FFAO; Brad Sutton, OD, FFAO

## ORS MISSION STATEMENT

*The mission of the Optometric Retina Society (ORS) is to promote the advancement of vitreoretinal knowledge for clinicians, ophthalmic educators, residents, and students.*

*The ORS is dedicated to posterior segment disease prevention, diagnosis, management and co-management.*

## THREE WAYS TO REGISTER

email: [reviewmeetings@jhihealth.com](mailto:reviewmeetings@jhihealth.com) | call: 800-999-0975

online: [www.reviewsce.com/orsretupdate2018](http://www.reviewsce.com/orsretupdate2018)

Administered by

**Review Group Vision Care Education, LLC**



Partially supported by unrestricted educational grants from

**REGENERON**  
Carl Zeiss Meditec

Review Group Vision Care Education, LLC partners with Salus University for those ODs who are licensed in states that require university credit. See event website for up-to-date information.

10<sup>TH</sup> ANNUAL  
**2018**

# WEST COAST Optometric Glaucoma Symposium

Earn up to  
**12 CE  
Credits\***

**DECEMBER 14-15, 2018**

Join our faculty of renowned ODs and MDs for a highly interactive meeting covering the most up-to-date information in glaucoma care. Up to 12 CE credits for only \$325.

## MONARCH HOTEL

1 Monarch Beach Resort  
Dana Point, CA 92629  
949-234-3900

## MEETING CO-CHAIRS:



Murray Fingeret, OD



Robert Weinreb, MD

**SPEAKERS:** Andrew Camp, MD  
Ben Gaddie, OD

Alex Huang, MD, PhD  
Richard Madonna, OD

## THREE WAYS TO REGISTER

[www.reviewsce.com/WCOGS2018](http://www.reviewsce.com/WCOGS2018)

Email: [reviewmeetings@jhihealth.com](mailto:reviewmeetings@jhihealth.com)

Call Lois DiDomenico: 877-451-6514

Administered by

**Review Group Vision Care Education, LLC**



\*Approval pending



Pennsylvania College of Optometry

Partially supported by  
unrestricted educational grants from

**Bausch + Lomb** **Aerie**  
**Novartis**

Review Group Vision Care Education, LLC partners with Salus University for those ODs who are licensed in states that require university credit.





# ION: Low Pressure, High Risk

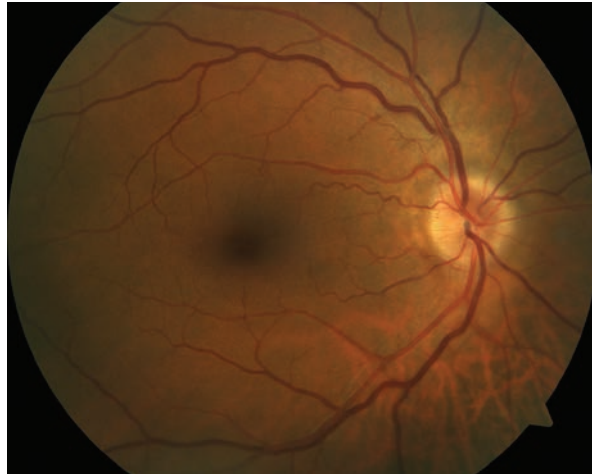
Infarction of the optic nerve has many systemic implications to guard against.

By Carlo J. Pelino, OD, and Joseph J. Pizzimenti, OD

An 80-year-old white female presented for acute vision loss in her left eye. She reported symptoms of mild fatigue and a recent 10-pound weight loss. While there were no reported allergies, her history was positive for dyslipidemia, BP was 125/80 and she was showing signs of early dementia. She reported that she smokes two cigarettes a day and takes Lipitor.

In the left eye, the patient demonstrated light perception only with pupils showing a grade 4 afferent pupillary defect (APD). Counting fingers were full in the right eye and non-existent in the left. Intraocular pressure was 14mm Hg in each eye and there was no anterior or posterior inflammation found. There were no color plates in the left eye and a posterior pole examination showed pale swelling of the left optic nerve. As these symptoms are consistent with arteritic AION, an immediate neuro-ophthalmology consult was obtained.

Results from subsequent testing demonstrated that her erythrocyte sedimentation rate (ESR) was 100, she had elevated C-reactive protein at 5 and elevated platelets. A temporal artery biopsy showed inflammation and intravenous (IV) methylprednisolone was administered at a dose of 1,000mg daily for three days. From there, she was put on high dose of oral prednisone 80mg/day and he has been treated on steroids for over a year.



**A 60-year-old white male with systemic hypertension and optic nerve typical of a 'disc at risk.' A small nerve head with a small c/d ratio is a risk factor for non-arteritic AION, as is his hypertension.**

## The Many Sides of ION

Ischemic optic neuropathy (ION) or infarction of the optic nerve can be anterior (AION) or posterior (PION). Both types can be arteritic, non-arteritic, or perioperative. Non-arteritic ION, which occurs more frequently and affects adults age 50 and older, tends to cause less severe vision loss than the arteritic variant. Arteritic on the other hand, affects an older population, age 70 and above.

As the only common symptom among the variants is painless vision loss, monitoring for the many systemic implications in your patients can help prevent further vision loss in the affected and fellow eye.

Let's go right to the heart of the matter: the optic nerve. Moving

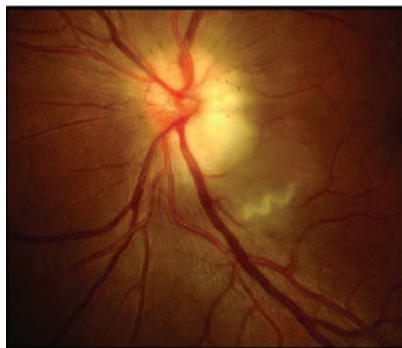from the anterior to posterior regions of the nerve, are four distinct sections: intraocular (AKA, the optic nerve head or optic disc), intraorbital, intracanalicular and intracranial.

The anterior segment of the optic nerve lies between the optic disc and the site of entry where the central retinal artery enters the nerve. This part

is supplied by two vascular networks: the peripheral system and the axial vascular system, present in 75% of optic nerves and supplied by 1–8 intraneural branches of the central retinal artery.<sup>1</sup>

The posterior segment of the optic nerve, on the other hand, lies between the site of entry of the central retinal artery and the orbital apex, directly prior to entering the intracanalicular portion. This part of the nerve is primarily supplied by the peripheral vascular system and multiple small collateral arteries. These typically stem directly from the ophthalmic artery and less often from other orbital arteries.<sup>1,2</sup>

Since the intraorbital portion of the nerve is supplied by more than one arterial system, watershed



**An 80-year old white female with acute loss. VA is light perception in the left eye. Pale, swollen nerve is consistent with arteritic AION (GCA).**

vascular zones exist within the nerve. Within these watershed zones, the intraorbital optic nerve suffers low perfusion pressure, causing areas within the watershed zone to be most vulnerable. Structural abnormalities of the optic nerve, such as a crowded nerve head with a small cup and other vascular risk factors, leave many patients predisposed to the development of AION.

While the development of AION is primarily due to ischemia of the prelaminar and laminar areas where the nerve exits the globe, PION has been linked primarily to ischemia of the intraorbital portion. It's important to note that this potentially devastating variant can be characterized by the acute, painless vision loss in one or both eyes and can present without optic disc swelling.

### Risk Factors on the Radar

When atherosclerotic narrowing of the posterior ciliary arteries occurs, the eye may be predisposed to non-arteritic AION, particularly after a hypotensive episode.<sup>1,3</sup> So, while there are typically no defined medical conditions connected to non-arteritic ION, it's important to look out for factors contributing

to atherosclerosis such as diabetes, smoking, dyslipidemia and hypertension, obstructive sleep apnea, certain drugs (e.g., amiodarone, possibly phosphodiesterase-5 inhibitors) and hypercoagulable disorders.<sup>5</sup> Vision loss on awakening leads clinicians to suspect nocturnal hypotension as a potential cause of the non-arteritic AION.<sup>4,5</sup>

Any of the inflammatory arteritides, especially giant cell arteritis (GCA), can precipitate the arteritic type of infarction.<sup>1,3</sup> Acute ischemia in these cases can cause optic nerve edema, which will then further worsen the ischemia.

### Making the Diagnosis

Before making a diagnosis, key clinical factors such as the state of the optic disc should be thoroughly investigated. In the presence of AION, the optic disc will be edematous, and the swollen nerve fibers will obscure the fine surface vessels of the nerve. The disc edema may present in a sectoral fashion and hemorrhages may surround the nerve head. The disc may appear pale in the arteritic variety and hyperemic in the non-arteritic type.

In both arteritic and non-arte-

ritic types, perimetry will often demonstrate a defect in the inferior and central fields. Additionally, small and crowded nerve head is a predisposing risk factor for the development of non-arteritic AION, while a large cup-to-disc ratio in the fellow eye should make one think about arteritic AION in the affected eye.<sup>3-5</sup> For this reason, when AION is suspected, the clinician should examine the fellow eye to see if it has a "disc at risk," as it's called. OCT may be used to further assess the disc edema, ganglion cell thickness and retinal nerve fiber layer thickness, as well as documenting resolution versus stability or progression.

While diagnosis of optic nerve infarction is based mainly on clinical evaluation, ancillary testing may be necessary. Most importantly, the clinician must first rule out the arteritic form, which would require emergency treatment to protect the fellow eye. Immediate tests should include ESR, complete blood count (CBC) and C-reactive protein. ESR is usually dramatically elevated in the arteritic form, often exceeding 100mm/h, and typically normal in the non-arte-

**Table 1. Common Symptoms and Signs in Patients with ION<sup>3-5</sup>**

- General malaise, especially in arteritic
- Muscle aches and pains, especially in arteritic
- Headaches over the temple (arteritic)
- Pain when combing hair (arteritic)
- Jaw claudication (arteritic)
- Tenderness over the temporal artery (arteritic)
- Painless, rapid vision loss (over minutes, hours, or days)
- Afferent pupillary defect
- Optic disc is elevated and swollen in AION
- Hemorrhages may surround the disc.
- Pallor of swollen disc in arteritic; hyperemic swelling in non-arteritic
- Visual field defect in the inferior and central fields

ritic variant. CBC is done to identify thrombocytosis ( $>400 \times 10^3/\mu\text{L}$ ), which adds to the positive and negative predictive value of using ESR alone.<sup>3-5</sup>

If GCA is suspected, a temporal artery biopsy should be performed as soon as possible. Monitoring changes in C-reactive protein level will be necessary for tracking disease activity and the response to treatment. For isolated cases of progressive vision loss, neuroimaging may be obtained to rule out compressive lesions.<sup>5</sup>

Lastly, narrowing the diagnosis for non-arteritic ION may include testing for obstructive sleep apnea, especially where symptoms such as excessive daytime sleepiness, obesity or loud snoring are present.

### Treatment

While up to 40% of eyes with

non-arteritic AION spontaneously recover some useful vision, it should be noted that vision loss in arteritic AION, when caused by GCA, will typically be irrecoverable.<sup>5</sup> Arteritic ION, for this reason, must be treated immediately with systemic high-dose steroids to prevent further loss and protect the fellow eye. Inadequate treatment can cause relapses and additional vision loss.

Oral prednisone is the most frequent first-line therapy, though intravenous methylprednisolone has been recommended for severe cases. It is prudent to seek comanagement with neurology or neuro-ophthalmology in these such cases.<sup>4,5</sup> For non-arteritic ION, the clinician should investigate for vasculopathic risk factors and sleep apnea and also check blood pressure, glycosylated hemoglo-

bin (A1C) and lipids.<sup>5</sup> As always, patients should be encouraged to maintain a healthy diet, exercise, and avoid smoking.

With a watchful eye on the potential symptoms and systemic implications of ischemic optic neuropathy, we as clinicians can make an early diagnosis and initiate the proper treatment plan to prevent further vision loss. ■

1. Hayreh SS. Anterior ischaemic optic neuropathy I. Terminology and pathogenesis. *Br J Ophthalmol* 1974; 58:955-963.
2. Hayreh SS. Posterior ischaemic optic neuropathy: clinical features, pathogenesis, and management. *Eye* 2004; 18:1188-1206.
3. Arnold, Anthony C. "Ischemic optic neuropathy." *Clinical neuro-ophthalmology* 1 2005: 349-384.
4. Sohan Singh Hayreh, Ischemic optic neuropathy, In *Progress in Retinal and Eye Research* 2009; Volume 28, Issue 1, pp. 34-62.
5. Atkins EJ, Bruce BB, Newman NJ, Biousse V. Treatment of Nonarteritic Anterior Ischemic Optic Neuropathy. *Survey of ophthalmology*. 2010;55(1):47-63. doi:10.1016/j.survophthal.2009.06.008.
6. Satta SR, Nee M, Miller NR, Biousse V, Newman NJ, Kouzis A. Clinical spectrum of posterior ischemic optic neuropathy. *Am J Ophthalmol* 2001; 132:743-750.

# Hiring Optometric Staff?

More Ophthalmic &  
Optometric Professionals  
find jobs on Local Eye Site  
than anywhere else.



Save 20% with coupon  
code: **REVOPT**

[localeyesite.com](http://localeyesite.com)





# YOUR CAMPAIGN YOUR SUPPORT



**Think About Your Eyes** drove **3.4MM incremental eye exams** and **\$752MM in incremental industry revenue** in 2017.

These industry leaders make the campaign a reality, and to keep it going, they need your support. Show them your appreciation, and encourage other companies you do business with to join the campaign.

**Think About your Eyes can get even bigger and more impactful with your help.**

**think**about  
**youreyes**.com

Brought to you by the AOA  
AMERICAN OPTOMETRIC ASSOCIATION



# A Hazy, Shaded Vision

A young, otherwise healthy patient is suddenly beset by floaters.

By Mark T. Dunbar, OD

A 34-year-old Hispanic female presented with symptoms of hazy vision and floaters in her left eye for a few months. The eye was not red and she denied having any pain or discomfort. The right eye was unaffected.

She reported good general health and had no prior ocular problems. She was not nursing or pregnant.

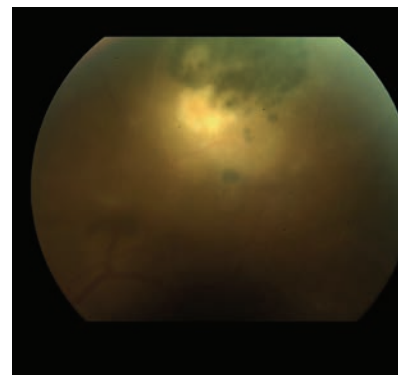
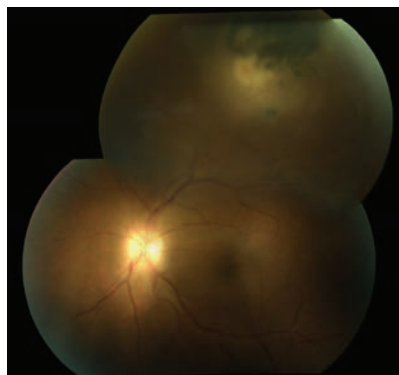
Upon examination, her best-corrected visual acuity was 20/20 OD and 20/30 OS. Confrontation visual fields were full to careful finger counting OU and ocular motilities were normal.

Her pupils were equal, round and reactive to light with no afferent pupillary defect. The right eye was completely normal. The left eye showed trace cell, but was otherwise normal.

On dilated fundus exam, the right eye was unremarkable. The vitreous of the left eye had 2+ vitreous cells. The exam did reveal some other changes (Figure 1). An SD-OCT of the macula in the left eye was normal.

## Take the Quiz

1. What does the fluffy white lesion represent?
  - a. Myelinated nerve fiber (MNF).
  - b. Cotton wool spot.
  - c. Active retinochoroiditis.
  - d. Chorioretinal scar.
2. What is the correct diagnosis for the fundus lesion?
  - a. Active syphilis.
  - b. *Toxocara canis*.



**Fig. 1. Can this 34-year-old patient's fundus images explain anything about her hazy vision and influx of floaters?**

- c. Toxoplasmosis.
  - d. Histoplasmosis.
3. What is the treatment for this patient?
    - a. Bactrim PO, clindamycin PO, steroids PO, folic acid.
    - b. Azithromycin PO.
    - c. Doxycycline PO.
    - d. Observation.
  4. What additional testing would be most helpful in making the correct diagnosis?
    - a. Elisa blood test for IgG and IgM.
    - b. Blood test for FTA-ABS, RPR.
    - c. PPD.
    - d. HLA-B27, HLA-A29.
  5. Which statement best characterizes her condition?
    - a. Likely acquired.
    - b. Likely congenital.
    - c. Reactivation.
    - d. Autoimmune.

For answers, see page 106.

## Discussion

Our patient presented with symptoms of hazy vision with an increase in floaters. These symptoms are due to the vitreous cells that were seen on her clinical exam once she was dilated. She also has a fluffy-white lesion superotemporal that is adjacent to a pigmented chorioretinal scar. This is a classic presentation of active toxoplasmosis retinochoroiditis. Because it is adjacent to the pigmented chorioretinal scar, this likely represents reactivation of a previous infection.

Toxoplasmosis is the most common cause of posterior uveitis and accounts for approximately 90% of focal necrotizing retinitis.<sup>1</sup> It is caused by an intracellular parasite *Toxoplasma gondii*.<sup>1</sup> Cats are the definitive hosts for *Toxoplasma gondii*, and humans and other mammals act as intermediate hosts. *T. gondii* exists in three forms, all of which are able to infect its hosts. Tachyzoites can infect almost all

nucleated cells through a process of active invasion. Tissue cysts, which contain the bradyzoites, are the dormant form and primarily found in the brain and skeletal muscles. Oocysts are produced during the sexual cycle that takes place in the intestine of acutely infected felines.

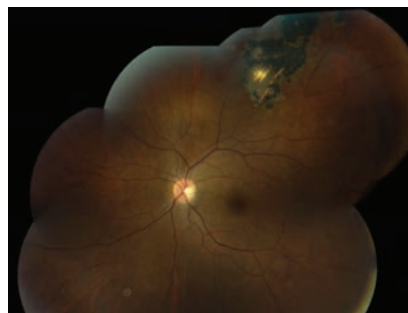The transmission occurs by many routes, including ingestion of raw or undercooked meat infected with tissue cysts, ingestion of food and water contaminated with oocysts, ingestion of eggs and milk contaminated with tachyzoites, blood transfusion, organ transplantation or transplacental transmission.

The most common form of transmission of the disease is mother to child, transplacentally. Mothers who are seropositive for toxoplasmosis show rates of transmission between 60% and 81%, often noticeable in the third trimester.<sup>2</sup> Manifestations of congenital toxoplasmosis include: hydrocephalus, seizures, intracranial calcifications, and retinochoroiditis. Pregnant mothers are cautioned to avoid contact or exposure to litter boxes.

## Making the Call

The diagnosis toxoplasmosis is usually made based on the clinical presentation. Serologic blood studies such as the Toxoplasma ELISA can be performed to confirm the diagnosis. Detection of IgM antibody titers are present within the first two weeks of infection and suggests a recently acquired infection. IgG antibodies means they were exposed to the infection some time in their life time. The IgG antibodies are produced within two weeks and peak at two months and will be present for life.

Interestingly, a positive toxoplasmosis titer doesn't always ensure that the diagnosis of a lesion in the eye is from toxoplasmosis. This is



**Fig. 2. This fundus image shows our patient three years after her initial presentation. She was able to resolve on her own without treatment.**

because there is a high seropositivity in the general population. In fact, more than 60 million people in the United States may have been affected with the parasite, but those who have been affected have few symptoms, if any.<sup>3</sup> This is because a healthy person's immune system usually keeps the parasite from causing illness. A negative titer should give strong deliberation to alternate diagnosis.<sup>2</sup> Blood work up was not performed on our patient because it was a pretty "classic" presentation.

Toxoplasmosis is generally self-limiting in immunocompetent patients and will resolve spontaneously in four to eight weeks. Treatment is reserved for lesions threatening or involving the macular or optic nerve or if there is a significant reduction in visual acuity due to a severe vitritis. Other indications for treatment include an active lesion greater than one disc diameter in size and /or any immunocompromised patient.<sup>1-2</sup> Peripheral lesions that do not affect visual acuity generally can be carefully followed without treatment.

## Treatment

The standard for treating active toxoplasmosis patient is clindamycin 30mg PO TID, Bactrim DS PO

BID, and prednisolone 40mg PO QD. This is referred to as "triple-therapy." Some uveitis specialists will also give an intravitreal injection of dexamethasone 0.4mg/ clindamycin 1mg. This is considered quadruple therapy.<sup>4</sup>

In one study of 68 patients with active toxoplasmosis, investigators compared the standard triple-therapy (34 patients) with local therapy with only an intravitreal injection of clindamycin and dexamethasone (34 patients) and found both groups of patients did equally well. They concluded that this might be an acceptable alternative to the classic triple-drug treatment in ocular toxoplasmosis.

Advantages of intravitreal treatment include convenience, improved systemic side effect profile, greater availability and fewer follow-up visits and hematological evaluations.<sup>5</sup>

Azithromycin has also emerged as an alternative treatment for toxoplasmosis. Research comparing traditional triple therapy with azithromycin shows no significant difference in results.<sup>6</sup>

Our patient did not admit to having any cats nor eating any raw or undercooked pork, lamb or venison. She was observed without treatment and spontaneously resolved on her own. ■

1. Yanhoff N, Duker J. Uveitis and Other Intraocular Inflammations" Ophthalmology: Expert consult, 3rd edition. Mosby November 2008; 828-831.

2. Chaudhry S, Gad N, Koren G. Toxoplasmosis and pregnancy. Can Fam Physician. 2014;60(4):334-6.

3. Gerstenblith A, Rabin M. The Wills Eye Manual: office and emergency room diagnosis and treatment of eye disease, 6th edition. Philadelphia, Lippincott Williams & Wilkins 2012; 369-371.

4. Kim S, Scott I, Brown G, et al. Interventions for toxoplasma retinochoroiditis: a report by the american academy of ophthalmology. Ophthalmology, vol. 120, no. 2, pp. 371-378, 2013

5. Bosch-Driessen L, Verbraak F, Suttorp-Schulten M, et al. A prospective, randomized trial of pyrimethamine and azithromycin vs pyrimethamine and sulfadiazine for the treatment of ocular toxoplasmosis. Am J Ophthalmol. 2002;134:34-40.

6. Bosch-Driessen L, Verbraak F, Suttorp-Schulten M, et al. A prospective, randomized trial of pyrimethamine and azithromycin vs pyrimethamine and sulfadiazine for the treatment of ocular toxoplasmosis. Am J Ophthalmol. 2002;134(1):34-40.

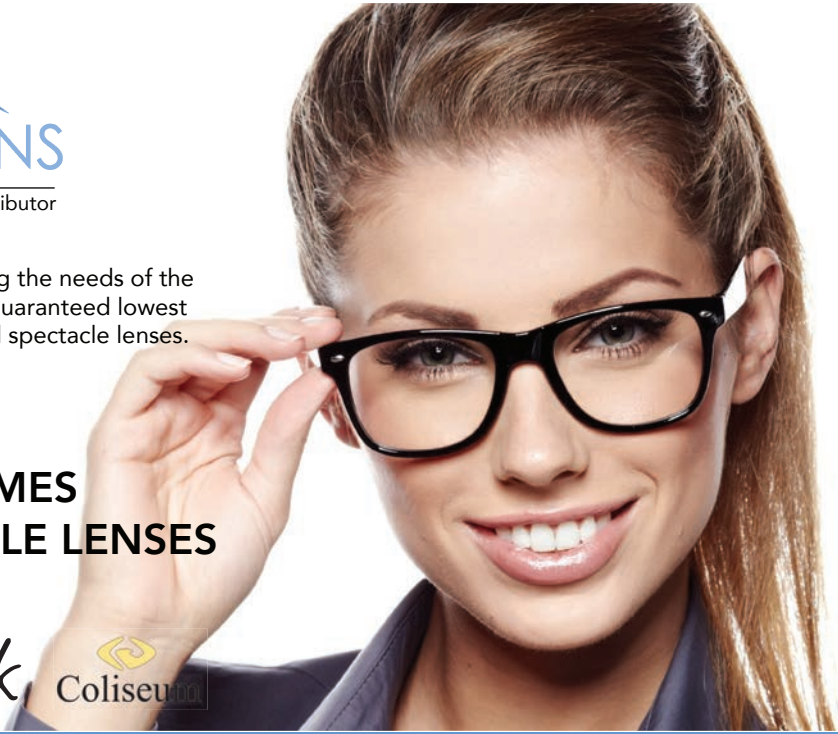


Merchandise Offered



National Lens is dedicated to fulfilling the needs of the optical profession by providing the guaranteed lowest prices on contact lenses, frames, and spectacle lenses.

**CONTACT LENSES**  
**100% ITALIAN FRAMES**  
**FINISHED SPECTACLE LENSES**



**GUARANTEED LOWEST PRICES | FREE FIRST CLASS SHIPPING\***  
\*in stock products (when available)

Contact Lenses

# Impressions

*Color Contact Lens*

*Unleash your true color!*

Amethyst	* Brown	* Grey	* Green	
Turquoise	* Hazel	* Honey	* Pure Hazel	* True Sapphire

Impressions colored contacts blend naturally with your patients eyes to create a beautiful look. Available in nine dazzling opaque colors of which Brown, Grey, Green, Hazel, Honey, Pure Hazel and True Sapphire are available in RX PL to -8.00. Impressions are fun, hip, fashionable and very competitively priced to help your bottom line. POP materials and posters are available upon request.

Available Exclusively at

**NATIONAL LENS**  
 America's Leading Discount Optical Distributor  
 1-866-923-5600 • 1-866-923-5601 FAX  
 www.national-lens.com

**Career Opportunities**

**30 year private optometry practice opportunity**  
 in Fairbanks, Alaska.  
 See patients of all ages.  
 Excellent leased location on busy thoroughfare.  
**907-978-7481**  
 or email [virginialind@yahoo.com](mailto:virginialind@yahoo.com)

**Equipment and Supplies**

**WHY PAY RETAIL???**



**Pretesting Tables of all shapes and sizes at Wholesale Prices.**

**Search the word PRETESTING at EBAY**

**Save hundreds even thousands on all your pretesting needs.**

**Or call: 316-734-4265**

**Want an OCT?  
Afraid of cost?**

Add a Zeiss Stratus OCT for a fraction of the cost. Good condition, great scans.  
**\$2995 plus shipping**

**Call 325-212-9140**



**Do you have  
CE Programs?**

**CONTACT US TODAY  
FOR CLASSIFIED ADVERTISING**  
 Toll free: **888-498-1460**  
 E-mail: [sales@kerhgroup.com](mailto:sales@kerhgroup.com)

**Staff Optometrist Wanted**

Bard Optical is a family owned full-service retail optometric practice with 22 offices (and growing) throughout Central Illinois. Bard Optical prides itself on having a progressive optometric staff whose foundation is based on one-on-one patient service. We are currently accepting CV/resumes for Optometrists to join our medical model optometric practice that includes extended testing. The practice includes but is not limited to general optometry, contact lenses and geriatric care. Salaried, full-time positions are available with excellent base compensation and incentive programs and benefits. Some part-time opportunities may also be available.

**Current positions are available in Bloomington/Normal, Decatur/Forsyth, Peoria, Sterling and Canton as we continue to grow with new and established offices.**

Please email your information to [mhall@bardoptical.com](mailto:mhall@bardoptical.com) or call Mick at **309-693-9540 ext 225**.  
 Mailing address if more convenient is:

**Bard Optical**  
**Attn: Mick Hall, Vice President**  
**8309 N Knoxville Avenue**  
**Peoria, IL 61615**

*Bard Optical is a proud Associate Member of the Illinois Optometric Association.*



[www.bardoptical.com](http://www.bardoptical.com)

**Continuing Education**

**MEDICAL OPTOMETRISTS**

The American Board of Certification in Medical Optometry (ABCMO) is recognized at Joint Commission (JC) accredited medical facilities as issuing board certification in the specialty of medical optometry and those ABCMO certifies are eligible for credentialing at these facilities as specialists rather than general optometry practitioners.\*

The Joint Commission, the accepted national Gold Standard, reviews and accredits over 21,000 federal, state and local-chartered medical facilities.

**To Be Eligible for ABCMO board certification:**

1. Complete an accredited residency in medical optometry
2. Pass the national Advanced Competence in Medical Optometry Examination
3. Practice in a medical setting for a minimum of two years.\*

[www.abcmo.org](http://www.abcmo.org)



Visit [www.abcmo.org](http://www.abcmo.org) to understand how JC accredited medical facilities credential specialists and why specialty certification can enhance the careers of optometrists who complete residencies in medical optometry.

**For Application procedures see [www.abcmo.org](http://www.abcmo.org) or contact [myers.kenj@gmail.com](mailto:myers.kenj@gmail.com)**

\* At this time, 127 JC accredited hospitals, clinics and teaching institutions recognize ABCMO specialist certification.  
 \* [www.jointcommission.org](http://www.jointcommission.org)  
 \* Waived for two years after residency

**Practice For Sale**

**ARE YOU IN CONTROL?**

Don't buy a job...acquire a business.

Select clients have larger practices available for outright purchase. Positive cash flow and 100% financing available. America's leading optometry business development consultancy provides support before, during and after closure.

We'll help you acquire the optometry practice of your dreams with no cost to you. See our current offerings at:

<http://www.cleinman.com/buy>  
**800-331-5536**



Practice Sales • Appraisals • Consulting  
[www.PracticeConsultants.com](http://www.PracticeConsultants.com)

**PRACTICES FOR SALE  
NATIONWIDE**

Visit us on the Web or call us to learn more about our company and the practices we have available.

[info@PracticeConsultants.com](mailto:info@PracticeConsultants.com)

**800-576-6935**

[www.PracticeConsultants.com](http://www.PracticeConsultants.com)

**GREAT OPPORTUNITY**

retail optical in Beverly Hills Golden Triangle Room for exams/ in house lab/ **perfect** for retail optometric practice

Serving the community for over 50 years

Please fax all inquiries to:  
**(310) 276-4219**

## Career Opportunities



### ASSOCIATE DIRECTOR OF EXAMINATION INNOVATION NATIONAL BOARD OF EXAMINERS IN OPTOMETRY (NBE)

Founded in 1951, the National Board of Examiners in Optometry (NBE), is one of the few national boards in any profession with a repertoire of exams which include computer-based tests, an advanced competence exam, and clinical skills test using standardized patients at the National Center of Clinical Testing in Optometry. The mission of NBE is to serve the public and profession of optometry by developing, administering, scoring and reporting results of valid examinations that assess competence.

The Associate Director of Examination Innovation will report to the Executive Director and will be responsible for leading and directing the division of new examination development at NBE.

Primary responsibility includes overseeing the restructure of the Part III Clinical Skills Examination and the development of patient scenario testing.

This candidate's past experiences should demonstrate a history of progressive leadership development. This individual will be required to relocate to Charlotte, NC.

To view the full job description, visit our website at

[www.optometry.org](http://www.optometry.org)

Applicants should send a cover letter and CV to [jill.bryant@optometry.org](mailto:jill.bryant@optometry.org)

## Faculty

**UMSL Optometry**  
University of Missouri–St. Louis  
[optometry.umsl.edu](http://optometry.umsl.edu)

#### Full-time Faculty Positions Available Non-Tenure Track Assistant, Associate, or Clinical Professor (Various Emphasis Areas)



The College of Optometry at the University of Missouri-Saint Louis invites applications for full-time non-tenure track positions with an opportunity to join a dynamic and progressive academic community. Successful applicants will receive a nine-month appointment. Initial rank for the full-time clinical appointments will be commensurate with prior experience, qualifications and individual interests. There is the possibility for a summer instructional assignment if mutually agreeable.

Applications are encouraged from a variety of areas including:

- Eye and Vision Research
- Sports Vision and Performance
- External Disease and Dry Eye
- Ocular and Systemic Disease including diagnostic and therapeutic procedures
- Primary Eye Care

**Responsibilities** - Successful candidates for clinical ranks are expected to provide instruction in the professional program and serve as a mentor for student research. The primary areas of emphasis depend upon prior accomplishments, qualifications and candidate interests.

**Qualifications** - All positions require:

- Ability to contribute to the development, evaluation, and enhancement of optometric education
- Ability to contribute to the mission and strategic priorities of the College of Optometry
- Open to development and use of innovative instructional strategies and technology
- Commitment to effective dissemination of evidence based practice and translating research into clinical care and education.
- Demonstrated knowledge in area of emphasis and contemporary issues in optometry and healthcare.

The positions require a Doctor of Optometry (OD) degree, license to practice optometry in Missouri, a commitment to work with diverse student and patient populations, and alternative teaching styles such as learner-centered and case-based approaches. A license to practice in Illinois is desirable. Candidates with a Masters or Doctoral Degree with a record of scholarship or who have completed an ACOE-accredited residency are preferred.

The University of Missouri-St. Louis is a public, metropolitan land-grant institution committed to basic and applied research, teaching and service with 17,000 students and 1,325 full and part-time faculty members. UMSL is the largest university in the

St. Louis region and the 3rd largest in Missouri with 131 degree and associate programs.

For additional information about UMSL see: [umsl.edu](http://umsl.edu)

The College of Optometry includes a 4-year professional degree (O.D.) program and post-professional residency programs. For additional information about the College see: [optometry.umsl.edu](http://optometry.umsl.edu)

Those who wish to be considered a candidate for a position must provide an application that includes a letter of interest, curriculum vitae and a list of four professional references. Formal submissions via the University website: [www.umsl.jobs](http://www.umsl.jobs). Applications will be accepted and reviewed immediately. The positions will remain open until filled.

Questions may be directed to:  
Julie DeKinder, OD  
Director, Academic Programs  
[dekinderj@umsl.edu](mailto:dekinderj@umsl.edu)

The University of Missouri-Saint Louis is an equal opportunity/affirmative action employer committed to excellence through diversity.



**Faculty**



**ASSISTANT PROFESSOR POSITIONS: PEDIATRICS**  
**Full-time non-tenure track faculty positions for the Chicago College of Optometry**

**RESPONSIBILITIES:** Candidates are expected to be highly knowledgeable in the field of pediatric optometry and develop and teach courses and/or laboratories in the subject area. The primary care candidate must also be able to provide direct patient care and clinical instruction to professional students as well as residents, and be involved in interdisciplinary practice with other educational professionals.

Candidates must be willing to actively participate in curricular assessment, professional development, student counseling and service activities within the college, university and the scientific community. Successful candidates are also expected to be involved in research and scholarly activities, and have a sincere commitment to optometric education, community service and patient care. Primary duties include, but are not limited to:

- |   |  |  |
|---|--|--|
| <p><b>a) Teaching</b></p> <ul style="list-style-type: none"> <li>• Developing and delivering lectures and/or laboratories for related areas, as assigned;</li> <li>• Embracing and enhancing the didactic philosophies in the O.D. program;</li> <li>• Maintaining and expanding the high quality clinical practice environment for optometry students on rotation;</li> <li>• Precepting students on clinical rotation at the Midwestern University Eye Institute where applicable;</li> </ul> | <p><b>b) Service</b></p> <ul style="list-style-type: none"> <li>• Helping to maintain and grow the state of the art optometry program with a strong interdisciplinary focus that meets the needs of patients in the surrounding community; is efficient, patient friendly, and cost-effective;</li> <li>• Working closely together with all optometry and ophthalmology faculty to provide a complete range of eye and vision care services;</li> <li>• Participating in leadership roles in state, regional, and national optometry organizations;</li> </ul> | <ul style="list-style-type: none"> <li>• Participating on College and University committees, as assigned;</li> <li>• Participating in College and University service activities.</li> </ul> <p><b>c) Scholarly activity</b></p> <p>Engaging in research and scholarly activity, including presentations at scientific meetings, research, and publication in peer reviewed journals sufficient to qualify for academic advancement in a non-tenure track position.</p> |
|---|--|--|

**QUALIFICATIONS:** Candidates must possess a Doctor of Optometry degree from an ACOE-accredited institution, must have completed an ACOE-accredited residency, and must be eligible for an optometric state license in the state in which the college is located. Primary eye care clinical expertise is also required.

**Salary will be commesurate with qualifications and experience**

**Review of applications will begin immediately and continue until the position is filled**

**CONTACT INFORMATION:** Contact information: Interested applicants should apply online at [www.midwestern.edu](http://www.midwestern.edu) and include curriculum vitae and letter of interest specifying the position and college that he/she wishes to be considered for. Inquiries may be directed to Dr. Melissa Suckow, Dean; Midwestern University: [msucko@midwestern.edu](mailto:msucko@midwestern.edu).

*Midwestern University is an Equal Opportunity/Affirmative Action employer that does not discriminate against an employee or applicant based upon race, color, religion, gender, national origin, disability, or veterans status, in accord with 41 C.F.R. 60-1.4(a), 250.5(a), 300.5(a) and 741.5(a).*



**ASSISTANT PROFESSOR POSITIONS: PRIMARY CARE/OPTOMETRIC THEORY AND METHODS**  
**Full-time non-tenure track faculty positions for the Chicago College of Optometry**

**RESPONSIBILITIES:** Candidates are expected to be highly knowledgeable in the field of primary care optometry and optometric theory and methods and develop and teach courses and/or laboratories in the subject area. The primary care candidate must also be able to provide direct patient care and clinical instruction to professional students as well as residents, and be involved in interdisciplinary practice with other educational professionals.

Candidates must be willing to actively participate in curricular assessment, professional development, student counseling and service activities within the college, university and the scientific community. Successful candidates are also expected to be involved in research and scholarly activities, and have a sincere commitment to optometric education, community service and patient care. Primary duties include, but are not limited to:

- |   |  |  |
|---|--|--|
| <p><b>a) Teaching</b></p> <ul style="list-style-type: none"> <li>• Developing and delivering lectures and/or laboratories for related areas, as assigned;</li> <li>• Embracing and enhancing the didactic philosophies in the O.D. program;</li> <li>• Maintaining and expanding the high quality clinical practice environment for optometry students on rotation;</li> <li>• Precepting students on clinical rotation at the Midwestern University Eye Institute where applicable;</li> </ul> | <p><b>b) Service</b></p> <ul style="list-style-type: none"> <li>• Helping to maintain and grow the state of the art optometry program with a strong interdisciplinary focus that meets the needs of patients in the surrounding community; is efficient, patient friendly, and cost-effective;</li> <li>• Working closely together with all optometry and ophthalmology faculty to provide a complete range of eye and vision care services;</li> <li>• Participating in leadership roles in state, regional, and national optometry organizations;</li> </ul> | <ul style="list-style-type: none"> <li>• Participating on College and University committees, as assigned;</li> <li>• Participating in College and University service activities.</li> </ul> <p><b>c) Scholarly activity</b></p> <p>Engaging in research and scholarly activity, including presentations at scientific meetings, research, and publication in peer reviewed journals sufficient to qualify for academic advancement in a non-tenure track position.</p> |
|---|--|--|

**QUALIFICATIONS:** Candidates must possess a Doctor of Optometry degree from an ACOE-accredited institution, must have completed an ACOE-accredited residency, and must be eligible for an optometric state license in the state in which the college is located. Primary eye care clinical expertise is also required.

**Salary will be commesurate with qualifications and experience**

**Review of applications will begin immediately and continue until the position is filled**

**CONTACT INFORMATION:** Contact information: Interested applicants should apply online at [www.midwestern.edu](http://www.midwestern.edu) and include curriculum vitae and letter of interest specifying the position and college that he/she wishes to be considered for. Inquiries may be directed to Dr. Melissa Suckow, Dean; Midwestern University: [msucko@midwestern.edu](mailto:msucko@midwestern.edu).

*Midwestern University is an Equal Opportunity/Affirmative Action employer that does not discriminate against an employee or applicant based upon race, color, religion, gender, national origin, disability, or veterans status, in accord with 41 C.F.R. 60-1.4(a), 250.5(a), 300.5(a) and 741.5(a).*

# Meetings + Conferences

## November 2018

■ **28-Dec. 2.** *Art & Science of Optometric Care—A Behavioral Perspective.* OEP National Education Center, Timonium, MD.

Hosted by: Optometric Extension Center. Key faculty: Paul Harris. CE hours: 35. For more information, email Karen Ruder at [karen.ruder@oep.org](mailto:karen.ruder@oep.org), call (410) 561-3791 or go to [www.oep.org](http://www.oep.org).

■ **30-Dec. 1.** *Retina Update 2018.* Fairmont Scottsdale Princess, Scottsdale, AZ. Hosted by: *Review of Optometry* and the Optometric Retina Society. Key faculty: Mohammad Rafieetary, Steve Ferrucci, Mark Barakat, Jeff Gerson, Leo Semes, Brad Sutton. CE hours: 11. For more information, email Lois DiDomenico at [reviewmeetings@jmihealth.com](mailto:reviewmeetings@jmihealth.com) or go to [www.reviewsce.com/orsretupdate2018](http://www.reviewsce.com/orsretupdate2018).

■ **30-Dec. 1.** *Fourth Annual Tulsa Winter Weekend.* Renaissance Tulsa Hotel & Convention Center, Tulsa, OK. Hosted by: Oklahoma College of Optometry. CE hours: 9. For more information, email Callie McAtee at [mcateec@nsuok.edu](mailto:mcateec@nsuok.edu), call (918) 316-3602 or go to [optometry.nsuok.edu/continuingeducation](http://optometry.nsuok.edu/continuingeducation).

## December 2018

■ **2.** *Clinical Topics in Optometry.* Marshall B. Ketchum University, Fullerton, CA. Hosted by: Southern California College of Optometry. CE hours: 8. For more information, email Antoinette Smith at [asmith@ketchum.edu](mailto:asmith@ketchum.edu) or go to [www.ketchum.edu/ce](http://www.ketchum.edu/ce).

■ **2-3.** *35th Annual Cornea, Contact Lens & Contemporary Vision Care Symposium.* Westin Memorial City, Houston, TX. Hosted by: University of Houston College of Optometry. Key faculty: Jan Bergmanson. CE hours: 16. For more information, email [optce@central.uh.edu](mailto:optce@central.uh.edu) or go to [ce.opt.uh.edu](http://ce.opt.uh.edu).

■ **8-9.** *Orlando Super Weekend.* Nova Southeastern University—Orlando Campus, Orlando, FL. Hosted by: Nova Southeastern University College of Optometry. Key faculty: Mile Brujic, Leo Semes, Marco Gonzalez. CE hours: 8. For more information, email Vanessa McDonald at [oceaa@nova.edu](mailto:oceaa@nova.edu) or go to [optometry.nova.edu/ce/index.html](http://optometry.nova.edu/ce/index.html).

■ **14-15.** *West Coast Optometric Glaucoma Symposium.* Monarch Beach Resort, Dana Point, CA. Hosted by: *Review of Optometry*. Key faculty: Murray Fingeret, Robert Weinreb, Andrew Camp, Ben Gaddie, Alex Huang, Richard Maddonna. CE hours: 8. For more information, email Vanessa McDonald at [oceaa@nova.edu](mailto:oceaa@nova.edu) or go to [optometry.nova.edu/ce/index.html](http://optometry.nova.edu/ce/index.html).

### To list your meeting, please send the details to:

Mark De Leon, Associate Editor

Email: [mdeleon@jobson.com](mailto:mdeleon@jobson.com)

Phone: (610) 492-1021

# Advertisers Index

<b>Akorn Consumer Health</b> .....89	<b>Lacrimedics, Inc</b> .....17
Phone ..... (800) 579-8327	Phone ..... (800) 367-8327
<a href="http://www.akornconsumerhealth.com">www.akornconsumerhealth.com</a>	Fax ..... (253) 964-2699
	..... info@lacrimedics.com
	..... www.lacrimedics.com
<b>Akorn Pharmaceuticals</b> 23, 59	<b>Lacriviera</b> .....51
Phone ..... (800) 932-5676	Phone ..... (855) 857-0518
<a href="http://www.akorn.com">www.akorn.com</a>	..... www.lacriviera.com
<b>Alcon Laboratories</b> .....5, 6	<b>Lombart Instruments</b> .....49
.....85, 108	Phone ..... (800) 446-8092
Phone ..... (800) 451-3937	Fax ..... (757) 855-1232
Fax ..... (817) 551-4352	<b>Menicon</b> .....7
<b>Allergan, Inc.</b> .....35	Phone ..... (800) MENICON
Phone ..... (800) 347-4500	..... information@menicon.com
<b>Bausch + Lomb</b> ..... 12, 53, 61	..... www.meniconamerica.com
.....79, 107	<b>Natural Ophthalmics, Inc.</b> ...65
Phone ..... (800) 323-0000	Phone ..... (877) 220-9710
Fax ..... (813) 975-7762	..... Info@NaturalEyeDrops.com
<b>Bruder Ophthalmic Products</b>	..... www.NaturalEyeDrops.com
.....25	<b>NuSight Medical Operations</b>
Phone ..... (888) 827-8337	.....39, 41
<a href="mailto:eyes@bruderophthalmic.com">eyes@bruderophthalmic.com</a>	Phone ..... (833) 468-5437
<b>Dry Eye Institute</b> .....16	<a href="http://www.NuSightMedical.com">www.NuSightMedical.com</a>
Phone ..... (910) 447-2020	<b>Optos North America</b> .....83
..... www.dryeyeinstitute.com	Phone ..... (877) 455-8855 x 100
<b>Eye Designs</b> .....29	Fax ..... (508) 486-9310
Phone ..... (800) 346-8890	<b>Quidel</b> .....55
Fax ..... (610) 489-1414	Phone ..... (800) 874-1517
<b>Eyevence Pharmaceuticals</b> 27	..... customerservice@quidel.com
Phone ..... (817) 677-6120	..... www.quidel.com
..... eyevence.com	<b>Reichert Technologies</b> .....2-3
<b>Focus Laboratories, Inc.</b> .....21	Phone ..... (888) 849-8955
Phone ..... (866) 752-6006	Fax ..... (716) 686-4545
Fax ..... (501) 753-6021	..... www.reichert.com
..... www.focuslaboratories.com	<b>S4OPTIK</b> ..... 43, 45, 47
<b>Imprimis Pharmaceuticals, Inc.</b>	Phone ..... (888) 224-6012
.....15	<b>Shire Ophthalmics</b> .....31, 32
Phone ..... (858) 704-4040	..... www.shire.com
Fax ..... (858) 345-1745	<b>TelScreen</b> .....63
..... www.imprimispharma.com	..... www.TelScreen.com
<b>Kala Pharmaceuticals</b> .....9	..... DryEye@TelScreen.com
Phone ..... (781) 996-5252	<b>Vital Tears</b> .....57
Fax ..... (781) 642-0399	Phone ..... (800) 360-9592
..... info@kalarx.com	Fax ..... (816) 255-1395
..... www.kalarx.com	..... info@vitaltears.org
<b>Katena</b> ..... 11, 81	..... www.vitaltears.org
Phone ..... (800) 225-1195	<b>Keeler Instruments</b> .....19
..... www.katena.com	Phone ..... (800) 523-5620
<b>Keeler Instruments</b> .....19	Fax ..... (610) 353-7814
Phone ..... (800) 523-5620	<b>X-Cel Speciality Contacts</b> ...75
Fax ..... (610) 353-7814	Phone ..... (877) 336-2482
	<a href="http://www.xcelspecialitycontacts.com">www.xcelspecialitycontacts.com</a>

*This advertiser index is published as a convenience and not as part of the advertising contract. Every care will be taken to index correctly. No allowance will be made for errors due to spelling, incorrect page number or failure to insert.*



## Not Fade Away

By Andrew S. Gurwood, OD

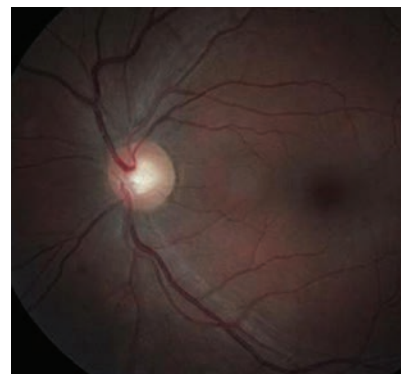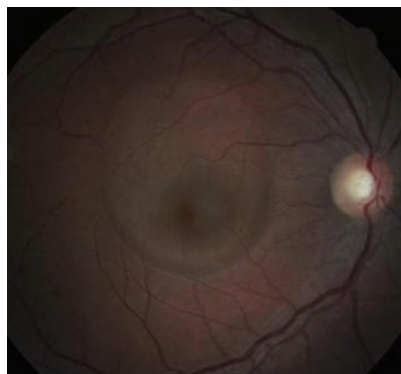
### History

A 45-year-old male presented to the office with an unsettling complaint; “My right eye is going blind!” He explained that his vision seemed to be gradually changing for the worse over the last couple of days.

He reported the left eye was unaffected, and claimed to experience no eye pain, redness, flashes, floaters or photophobia.

His systemic history was complicated, with hypertension for 15 years and kidney and liver cancer diagnosed two years earlier, with chemotherapy treatments ongoing. He also had a pituitary adenoma resection six years earlier. His medications included prednisone 5mg QD PO, Lovenox (enoxaparin sodium, Sanofi) and prochlorperazine 10mg QD PO. He had discontinued his hypertensive medication, claiming that without it he was still adequately controlled.

He did, however, volunteer that his wife was filing for divorce, which was adding to his stress.



**Can these fundus images of the patient’s right (at left) and left eye uncover the cause of our 45-year-old patient’s reported gradual vision loss?**

### Diagnostic Data

Best-corrected entering visual acuity was 20/40 OD and 20/20 OS, respectively, with no improvement upon pinhole. Pupils were equal and responsive to light with no evidence of afferent defect. Confrontation visual fields were full with mild distortion of the central face in the right eye.

His color vision and motilities were normal. The anterior segment was normal, with Goldmann intraocular pressures measuring 14mm

Hg OU. The pertinent clinical observation is demonstrated in the photographs.

### Your Diagnosis

Does the case presented require any additional tests, history or information? What steps would you take to manage this patient? Based on the information provided, what would be your diagnosis? What is the patient’s most likely prognosis? To find out, visit [www.reviewofoptometry.com](http://www.reviewofoptometry.com). ■

**Retina Quiz Answers (from page 99):** 1) c; 2) c; 3) d; 4) a; 5) c.

### Next Month in the Mag

*Review of Optometry* presents its Annual Surgery Report.

Topics include:

- *Adding Minor Procedures in the Optometric Office*
- *Surgery and the Ocular Surface: Pretreating Patients to Improve Outcomes*
- *Screening for, and preventing, post-LASIK ectasia*
- *Clinical Optics of Intraocular Lenses*

REVIEW OF OPTOMETRY (ISSN 0147-7633) IS PUBLISHED MONTHLY, 12 TIMES A YEAR BY JOBSON MEDICAL INFORMATION LLC, 440 9TH AVENUE, 14TH FLOOR, NEW YORK, NY 10013-1678. PERIODICALS POSTAGE PAID AT NEW YORK, NY AND ADDITIONAL MAILING OFFICES. POSTMASTER: SEND ADDRESS CHANGES TO REVIEW OF OPTOMETRY, PO BOX 81, CONGERS, NY 10920-0081. SUBSCRIPTION PRICES: US: ONE YEAR \$56; TWO YEARS \$97, CANADA: ONE YEAR \$88, TWO YEARS \$160, INT'L: ONE YEAR \$209, TWO YEARS \$299. FOR SUBSCRIPTION INFORMATION CALL TOLL-FREE (877) 529-1746 (USA); OUTSIDE USA, CALL (845) 267-3065. OREMAIL US AT REVOPOTOMETRY@CAMBEYWEST.COM. PUBLICATIONS MAIL AGREEMENT NO: 40612608. CANADA RETURNS TO BE SENT TO BLEUCHIP INTERNATIONAL, P.O. BOX 25542, LONDON, ON N6C 6B2.





ASTIGMATIC

# SUCCESS

from chair

# TO WEAR

**Bausch + Lomb ULTRA® for Astigmatism**

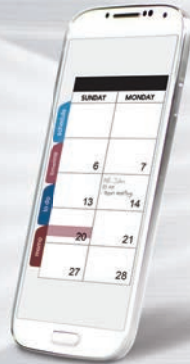
The **only** monthly toric lens with a  
-2.75D Cylinder in your fit set



Contact your representative  
to request lenses for your office



# THIS IS WHY correcting presbyopia will never be the same



NEAR



INTERMEDIATE



DISTANCE

The world's first and only Water Gradient lens designed for presbyopic patients.

### Seamless Vision Correction

Industry-leading Precision Profile™ Design is built to deliver clear, uninterrupted vision.<sup>1,2</sup>



### Exceptional Comfort<sup>3</sup>

Water Gradient technology creates a cushion of moisture on the eye.<sup>4</sup>



PERFORMANCE DRIVEN BY SCIENCE®

References: 1. Alcon data on file, 2017. 2. Alcon data on file, 2008. 3. Alcon data on file, 2011. 4. Angelini TE, Nixon RM, Dunn AC, et al. Viscoelasticity and mesh-size at the surface of hydrogels characterized with microrheology. *Invest Ophthalmol Vis Sci.* 2013;54:E-abstract 500.