

# REVIEW<sup>®</sup> OF OPTOMETRY

July 15, 2017

www.reviewofoptometry.com

## 23<sup>rd</sup> ANNUAL **GLAUCOMA** REPORT

Mastering MIGS: Today and Tomorrow,  
*Page 34*

Glaucoma Surgery: Are You Ready to  
Refer?, *Page 40*


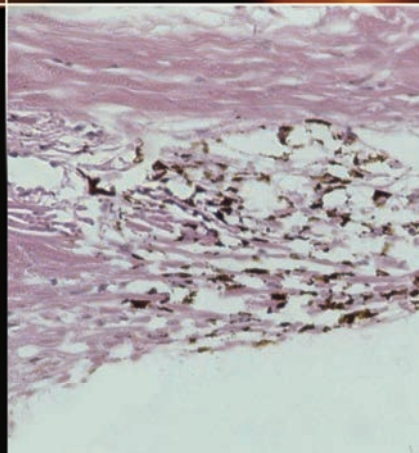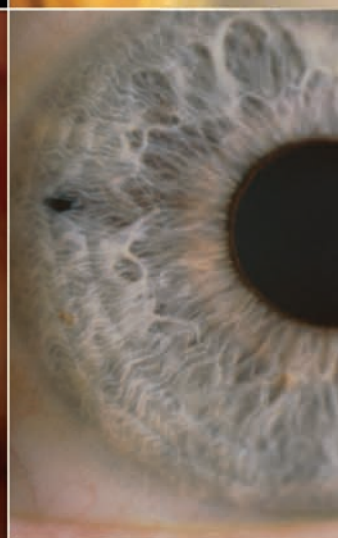
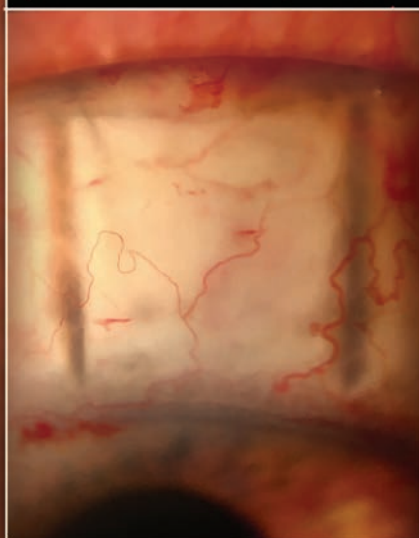
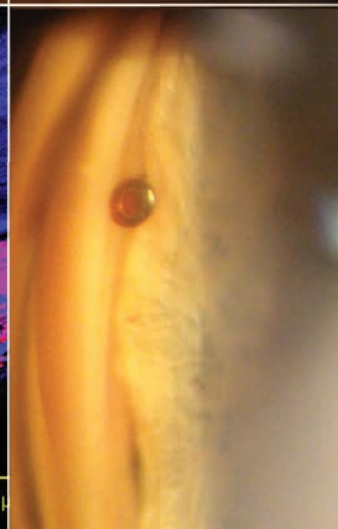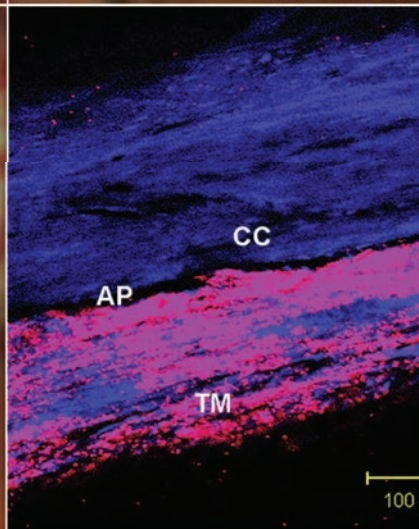
Looking to the Future of Glaucoma  
Treatment, *Page 48*

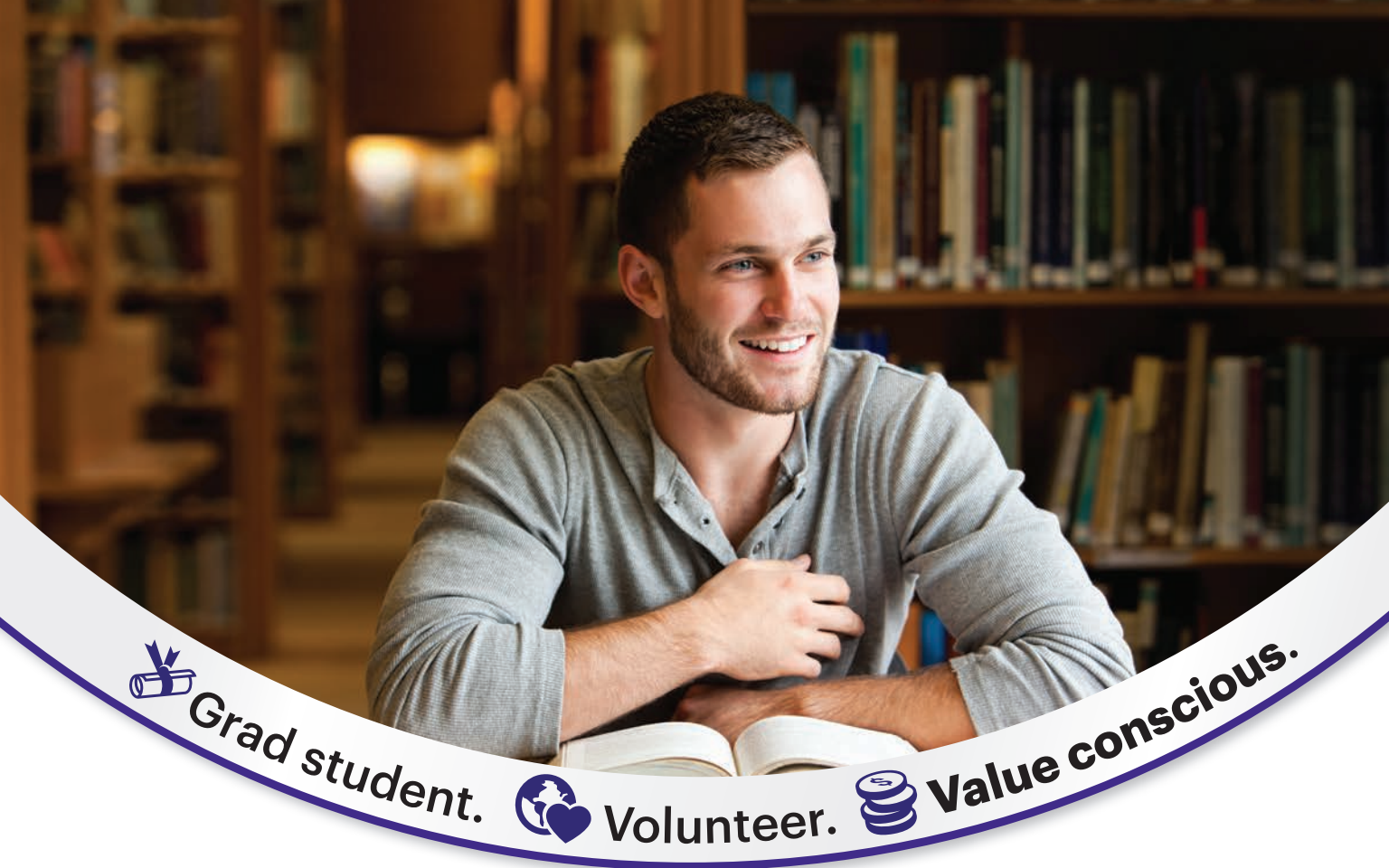10-2 Visual Field Testing: A Tool for All  
Glaucoma Stages, *Page 54*

### ALSO INSIDE

Be a Hero to Your HSVK Patients, *Page 64*

Caring for Patients with Brain Injury, *Page 72*  
— Earn 2 CE Credits





Grad student.



Volunteer.



Value conscious.

## When your monthly patients tell you they are happy... *are they?*

A study of 758 monthly patients shows that two-thirds experience comfort-related issues.<sup>1</sup> Of those patients...

**84%** COMPENSATE with lens removal, breaks, or rewetting drops

**82%** Feel ANNOYED, INCONVENIENCED or FRUSTRATED

**73%** DON'T PLAN TO TELL their eye care professional

ACUVUE® VITA® Brand Contact Lenses are indicated for vision correction as a daily wear lens with one-month recommended replacement. As with any contact lens, eye problems, including corneal ulcers, can develop. Some wearers may experience mild irritation, itching or discomfort. Lenses should not be prescribed if patients have any eye infection, or experience eye discomfort, excessive tearing, vision changes, redness or other eye problems. Consult the package insert for complete information. Complete information is also available by visiting [acuvueprofessional.com](http://acuvueprofessional.com), or by calling: In Canada: Johnson & Johnson Vision Care division of Johnson & Johnson, Inc. at 1-800-843-2020; In the US: Johnson & Johnson Vision Care, Inc. at 1-800-843-2020.

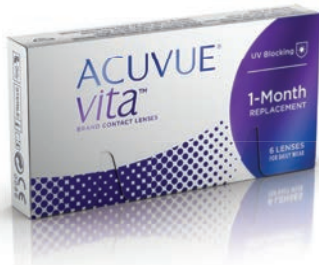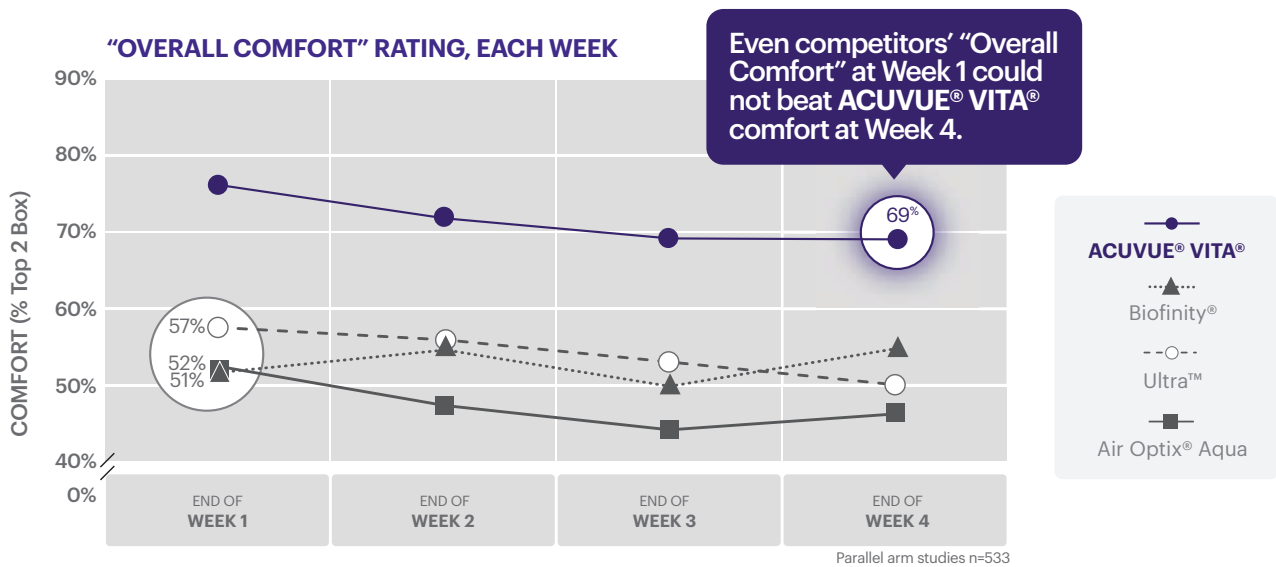
Third-party trademarks used herein are the property of their respective owners.

ACUVUE® and ACUVUE® VITA® are trademarks of the Johnson & Johnson Vision Care, Inc.

© Johnson & Johnson Vision Care, Inc. 2017 10529926-C April 2017

# ACUVUE® VITA® Brand Contact Lenses were created to address the needs of monthly patients who suffer in silence.

In a clinical study, patient ratings for ACUVUE® VITA® were superior for "Overall Comfort" compared to Air Optix® Aqua, Biofinity® and Ultra® at weeks 1, 2, 3 and 4.



Reliable, Superior Comfort – All Month Long. Plus, the only monthly contact lens with Class 1 UV protection.

Don't miss the opportunity to elevate the experience of your monthly patients. Let them try ACUVUE® VITA® today.



1. Habitual Air Optix® Aqua and Biofinity® patients who were independently recruited and masked to study sponsor.

\*Helps protect against transmission of harmful UV radiation to the cornea and into the eye.

† **WARNING:** UV-absorbing contact lenses are NOT substitutes for protective UV-absorbing eyewear such as UV-absorbing goggles or sunglasses because they do not completely cover the eye and surrounding area. You should continue to use UV-absorbing eyewear as directed. **NOTE:** Long-term exposure to UV radiation is one of the risk factors associated with cataracts. Exposure is based on a number of factors such as environmental conditions (altitude, geography, cloud cover) and personal factors (extent and nature of outdoor activities). UV-blocking contact lenses help provide protection against harmful UV radiation. However, clinical studies have not been done to demonstrate that wearing UV-blocking contact lenses reduces the risk of developing cataracts or other eye disorders. Consult your eye care practitioner for more information.

## IN THE NEWS

To better understand the relationship between **retinal nerve fiber layer (RNFL) defects** and **disc hemorrhages (DHs)**, researchers screened 168,044 patients older than 20, and found that DHs located in the inferotemporal quadrant were associated with RNFL defects, even after adjusting for proximal location. After adjusting for quadrant location, they found **DHs with the proximal end located at the cup margin** were more likely to be **accompanying RNFL defects** compared with DHs located outside the disc.

Yoo YC, Kim JM, Park HS et al. Specific location of disc hemorrhage is linked to nerve fiber layer defects. *Optom Vis Sci.* 2017;94(6):647-53.

Using online surveys, investigators found that respondents experience **dry eye symptoms more frequently in their work environment** than at home. In addition, up to 70% said they experienced some inhibition of daily activity at work due to eye symptoms, and more than 5% experience symptoms most or all of the time. The researchers suggest these findings highlight the need for a multidisciplinary understanding of the negative impact of dry eye in work environments.

van Tilborg MM, Murphy PJ, Evans KS. Impact of dry eye symptoms and daily activities in a modern office. *Optom Vis Sci.* 2017;94(6):688-93.

After studying postmortem tissue of 30 patients, researchers discovered some brain tissue proteins continue to develop into midlife—specifically, the **visual cortex matures until 36 years of age**, plus or minus 4.5 years or so. The findings may impact how clinicians approach **treatment options** for patients with **eye conditions such as amblyopia**, the researchers conclude.

Siu CR, Beshara SP, Jones DG, Murphy KM. Development of glutamatergic proteins in human visual cortex across the lifespan. *J Neuroscience.* 2017 May;2304-16.

# AMD May be Underdiagnosed

New data suggests optometrists need to take a closer look at fundus images to catch the disease early.

By **Rebecca Hepp, Managing Editor**

**A**fter collating data from ophthalmology and optometry practices in Birmingham, Ala., researchers found that roughly 25% of 1,288 eyes deemed normal based on the most recent dilated fundus exam had characteristics of age-related macular degeneration (AMD) on fundus photography, as identified by trained raters.

The study included 644 patients 60 or older with normal macular health and no AMD diagnosis in the medical record. While 75.2% had no AMD, which correlated with their medical record, 24.8% had AMD, the researchers said. Of those undiagnosed with AMD, 10.0% had hyperpigmentation, 13.4% had hypopigmentation, 77.8% had small drusen, 78.1% had intermediate drusen and 30.0% had large drusen. The data further shows the lack of AMD diagnoses was associated with older age, male sex and lower education. The prevalence of undiagnosed AMD was no different between ophthalmologists and optometrists.

“This data is very unsettling; undiagnosed AMD in the setting of having had a dilated eye exam is unacceptable,” says Sara Weidmayer, OD, of Ann Arbor, Mich. “Primary eye care providers arguably should be able to detect clinical features of AMD based solely on

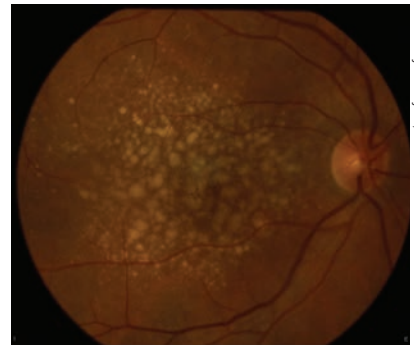


Photo: Jay M. Havens, OD

**More patients may have characteristics of early AMD than previously thought.**

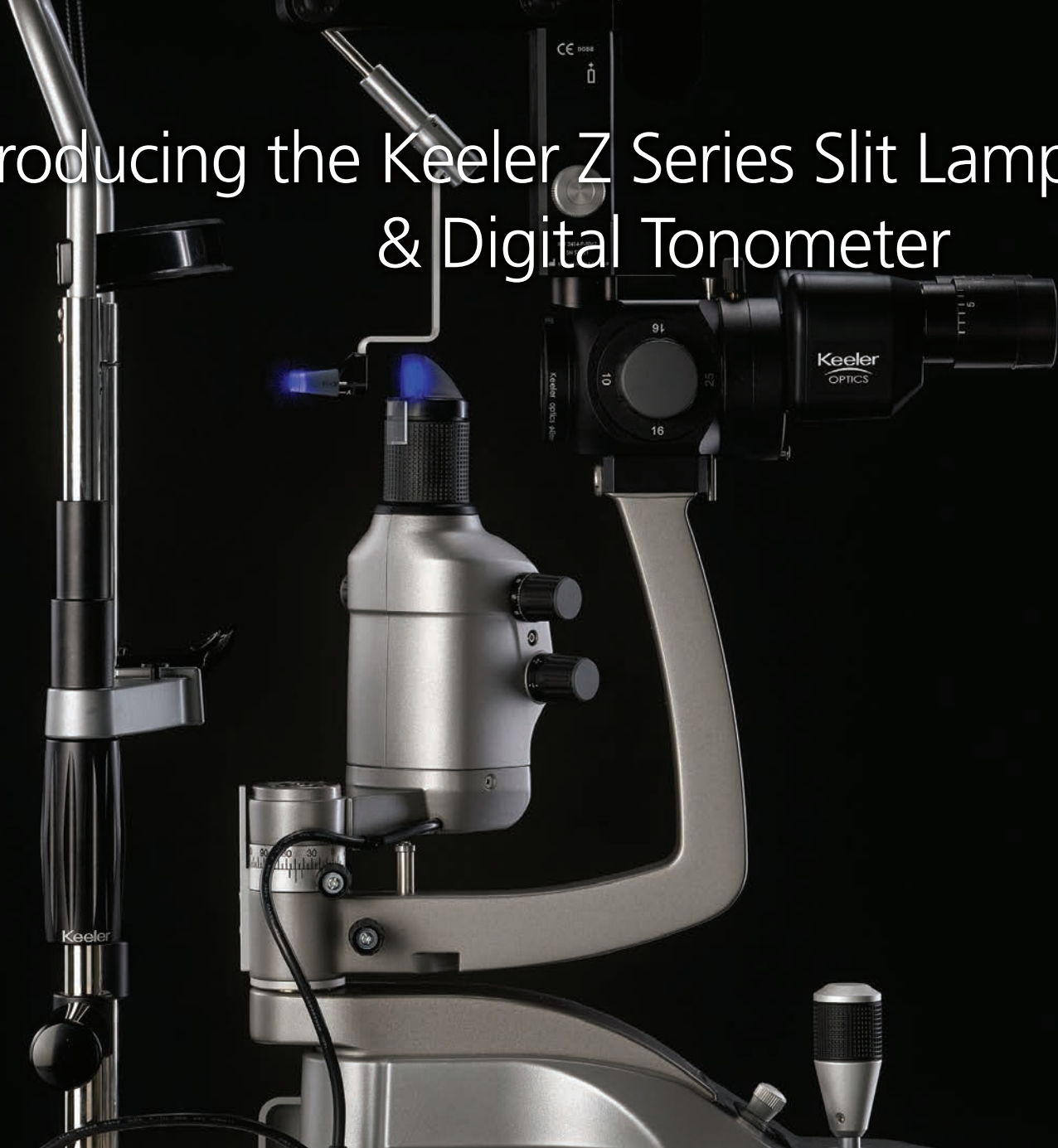a comprehensive dilated eye exam. While the authors suggest several possible causes for this lack of diagnosis, one that individual providers can strive to improve is their level of attention. Efficiency of care should not outweigh quality of care.”

The undiagnosed eyes with AMD with large drusen would have been treatable, the researchers conclude, highlighting the long-term impact of early diagnosis. They hope these findings help clinicians improve early detection and treatment.

“This data should be a call to action for primary eye care providers to heighten our awareness as we carefully examine to detect disease in our patients,” Dr. Weidmayer says.

Neely DC, Bray KJ, Huisinigh CE, et al. Prevalence of undiagnosed age-related macular degeneration in primary eye care. *JAMA Ophthalmol.* 2017;135(6):570-5.

# Introducing the Keeler Z Series Slit Lamp & Digital Tonometer



## Keeler Optics...says it all.

The Z Series Slit Lamp is the latest line from Keeler featuring legendary Keeler optics housed in a stylish, contemporary design.

Your choice of 3 or 5 step magnification option in a standard, digital ready, or comprehensive digital capture system.

Check out some of these great features:

- Converging or parallel binoculars
- 14mm Slit length / maximum aperture
- X 6 to x 40 (5 step) or X 10 to X 25 (3 step) magnifications
- Blue, red-free, clear, neutral density and diffuser filters
- 360 degree continuous slit rotation
- Integrated yellow barrier filter
- 1m Square aperture for Uveitis assessment
- LED illumination
- Illumination control mounted next to joystick
- 3 year warranty



*Order now and receive a limited edition bronze D-KAT tonometer.*

*Contact your preferred Keeler distributor for details.*

# Keeler

Learn more at [www.keelerusa.com](http://www.keelerusa.com)

Keeler Instruments, Inc. • 3222 Phoenixville Pike #50 • Malvern, PA 19008  
Tel: (800) 523-5620 • Fax: (610) 353-7814 • email: [keeler@keelerusa.com](mailto:keeler@keelerusa.com)

# Visual Fields Vary with Cognitive Decline

**G**laucoma patients and suspects with cognitive decline also have increased variable visual fields (VFs) over time, according to a new study. Researchers suggest screening for and monitoring cognitive dysfunction may be important when practitioners assess their glaucoma patients' VFs.

To determine if, and to what extent, patients' VFs vary, researchers monitored 115 patients for a mean period of 2.5 years with standard automated perimetry (SAP) and longitudinal assessment of cognitive ability using the Montreal Cognitive Assessment (MoCA).

They observed a statistically significant association between cognitive decline and VF variability over time. A five-point decline in the MoCA score was associated with

an increase in VF variability. After adjusting for baseline MoCA score, SAP mean deviation, age, sex, race/ethnicity, educational level, income and number of SAP tests, each five-point decline in MoCA score was associated with an even greater increase in VF variability.

Mohammad Rafieetary, OD, of Charles Retina Institute in Germantown, Tenn., says practitioners should consider all the possible reasons behind test results.

"When clinicians rely on testing to diagnose and manage conditions, we should consider all the possible impelling factors affecting the results of the specific test," says Dr. Rafieetary. This is even more important in those tests that rely on patient's subjective input, he explains. "Visual fields as a psycho-

metric test relies heavily on patients' understanding of the test, cooperation during testing and reliability in responding to the stimuli. Therefore, it is justifiable to conclude that patients' cognition will play a role in visual field results."

Neurodegenerative conditions may directly affect the VF as well, according to Dr. Rafieetary. "Vision and visual perception are neuro-processing functions; therefore, it is conceivable to assume that neurodegenerative conditions may directly affect visual field," he says.

Lastly, practitioners should consider the possibility of glaucoma itself being a neurodegenerative disorder, Dr. Rafieetary says.

Diniz-Filho A, Delano-Wood L, Daga FB, et al. Association between neurocognitive decline and visual field variability in glaucoma. JAMA Ophthalmol. May 2017. [Epub ahead of print].

**2017**  
Office Design  
Contest  
Call for Entries



**H**ave you recently renovated your office or redesigned a new space? Enter our office design contest and share your new digs with your colleagues!

**Eligibility:** Newly built offices, remodels or expansions completed between July 1, 2015 and July 30, 2017 are eligible to enter.

**Judging:** Entries will be judged by a panel of fellow optometrists previ-

ously recognized for their expertise in office design.

**Awards:** "Office Design of the

Year" will be awarded to the best overall facility based on functional design, efficient space planning, style and integration of equipment. Two runners-up will be chosen based on the same standards.

Each winner will receive an engraved office plaque recognizing the practice's achievement, in addition to editorial coverage online and in our December 2017 print edition.

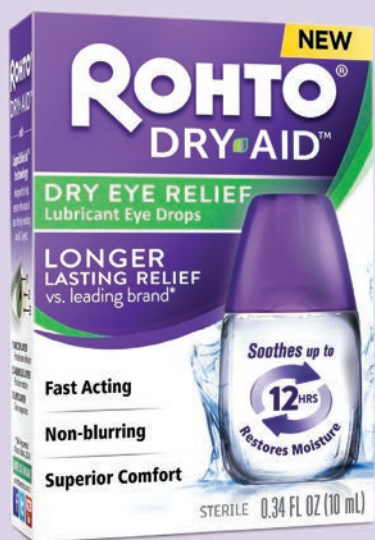*All entries must be received by September 15, 2017.*

### Scan or Click to Enter:

To read the contest rules and enter your new space for a chance to win Office Design of the Year, visit [www.reviewofoptometry.com](http://www.reviewofoptometry.com) or scan this QR code. Send your high-resolution images to Rebecca Hepp, managing editor, at [rhepp@jobson.com](mailto:rhepp@jobson.com).



# THE SOLUTION FOR DRY EYE, THAT LASTS ALL DAY.



From the #1 Global OTC Eye Care Brand†, New Rohto® Dry-Aid™ is clinically shown to help restore and protect the natural tear film. Formulated with Liquidshield™ technology Rohto® Dry-Aid™ works on all three layers of the tear to provide continuous relief all day.

For more information visit:

[www.rohtoeyedrops.com/professionals](http://www.rohtoeyedrops.com/professionals)

© 2017 The Mentholatum Company

\* Clinicaltrials.gov Identifier: NCT03183089. Publication Pending

† Euromonitor International Limited: Consumer Health Eye Care definition, retail value share, 2016 data

## 12 HRS

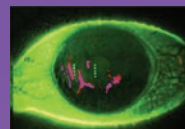
CONSISTENT & CONTINUOUS SYMPTOM RELIEF\*

**5** DRY EYE SYMPTOM RELIEF

- Dryness
- Irritation
- Grittiness
- Burning
- Stinging

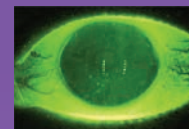
## 51%

IMPROVEMENT IN TEAR FILM STABILITY\*



Before using

Rohto® Dry-Aid™

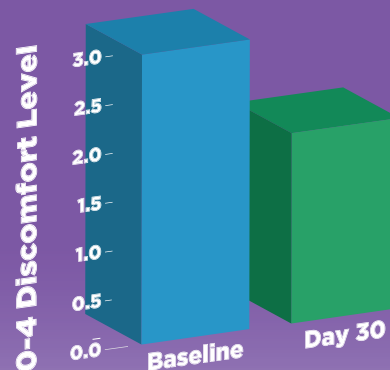


After using

Rohto® Dry-Aid™

## 33%

REDUCTION IN PATIENT DISCOMFORT\*



# Contact Lenses for Kids

Your pediatric patients may be better candidates for contact lenses than you thought, according to a new research review. After looking at large-scale epidemiological studies, hospital-based case series, long- and short-term prospective studies and multicenter retrospective studies, Mark A. Bullimore, MCOptom, PhD, from the University of Houston College of Optometry found the incidence of corneal infiltrates in children who wear contact lenses is no higher than it is in adults. Dr. Bullimore also suggests the incidence may be even lower in children ages eight to 11, according to the data.<sup>1</sup>

This research suggests “children are capable of soft, gas permeable and orthokeratology contact lens wear,” says Jeffrey J. Walline, OD, PhD, associate dean for Research at The Ohio State University. “Although no single study provides a comprehensive examination of contact lens safety in children, a review of the literature provides consistent evidence of the safety of pediatric contact lens wear.”

Based on three large prospective studies representing between 159 and 723 years of soft contact lens wear in eight- to 14-year-olds, the incidence of corneal infiltrative events is up to 136 per 10,000 years, Dr. Bullimore found. A large retrospective study found a rate of 97 per 10,000 years in eight- to 12-year-olds and 335 per 10,000 years in 13- to 17-year-olds.<sup>1</sup>

In comparison, Dr. Bullimore



Photo: Kathleen Elliott, OD

**Kids as young as eight may be able to safely switch from glasses to contact lenses, according to new data.**

notes the incidence of symptomatic corneal infiltrative events in adults in the last decade was 432 per 10,000 patient years of mostly daily wear and 316 per 10,000 patient years for daily silicone hydrogel lens wear with monthly replacement.<sup>1</sup>

None of the prospective studies that included safety data report any cases of microbial keratitis. While one retrospective study found no cases of microbial keratitis in the eight- to 12-year-old participants, it found an incidence of 15 per 10,000 patient years in 13- to 17-year-olds. This rate is no higher than the incidence of microbial keratitis in adults wearing soft contact lenses on an overnight basis, according to Dr. Bullimore.<sup>1</sup>

Given the data, he concludes the incidence of corneal infiltrative events in children fit in contact lenses does not exceed the incidence in adults, and may even be significantly lower in children ages eight to 11. This lower rate found in eight- to

## REVIEW<sup>®</sup> OF OPTOMETRY

### BUSINESS OFFICES

11 CAMPUS BLVD., SUITE 100  
NEWTOWN SQUARE, PA 19073

### CEO, INFORMATION SERVICES GROUP

MARC FERRARA  
(212) 274-7062 • MFERRARA@JOBSON.COM

### PUBLISHER

JAMES HENNE  
(610) 492-1017 • JHENNE@JOBSON.COM

### REGIONAL SALES MANAGER

MICHELE BARRETT  
(610) 492-1014 • MBARRETT@JOBSON.COM

### REGIONAL SALES MANAGER

MICHAEL HOSTER  
(610) 492-1028 • MHOSTER@JOBSON.COM

### VICE PRESIDENT, OPERATIONS

CASEY FOSTER  
(610) 492-1007 • CFOSTER@JOBSON.COM

### VICE PRESIDENT, CLINICAL CONTENT

PAUL M. KARPECKI, OD, FAAO  
PKARPECKI@JOBSON.COM

### PRODUCTION MANAGER

SCOTT TOBIN  
(610) 492-1011 • STOBIN@JOBSON.COM

### SENIOR CIRCULATION MANAGER

HAMILTON MAHER  
(212) 219-7870 • HMAHER@JHIHEALTH.COM

### CLASSIFIED ADVERTISING

(888) 498-1460

### SUBSCRIPTIONS

\$56 A YEAR, \$88 (US) IN CANADA,  
\$209 (US) IN ALL OTHER COUNTRIES.

### SUBSCRIPTION INQUIRIES

(877) 529-1746 (US ONLY)  
OUTSIDE US CALL: (845) 267-3065

### CIRCULATION

PO Box 81  
CONGERS, NY 10920  
TEL: (TOLL FREE): (877) 529-1746  
OUTSIDE US: (845) 267-3065



### CEO, INFORMATION SERVICES GROUP

MARC FERRARA

### SENIOR VICE PRESIDENT, OPERATIONS

JEFF LEVITZ

### VICE PRESIDENT, HUMAN RESOURCES

TAMMY GARCIA

### VICE PRESIDENT, CREATIVE SERVICES & PRODUCTION

MONICA TETTAMANZI

### CORPORATE PRODUCTION DIRECTOR

JOHN ANTHONY CAGGIANO

### VICE PRESIDENT, CIRCULATION

EMELDA BAREA

### Correction

On page 37 of the 2017 *Clinical Guide to Ophthalmic Drugs* print edition, acyclovir should be dosed 800mg five times daily.



11-year-olds may be a result of patient behavior rather than biological factors, and may also be influenced by greater parental supervision, Dr. Bullimore said in the study.<sup>1</sup>

“Some of the improved safety of contact lens wear in children may be due to a large portion being fitted with daily disposable contact lenses,” adds Dr. Walline.

These findings could have a significant impact on special populations as well, Dr. Walline says. Take myopia control, for example.

Research suggests contact lenses can slow myopia progression from 25% to 72% compared with spectacles and come with a lower risk side effects compared with atropine use.<sup>2-8</sup> Yet some practitioners may shy away from the modality for fear of increased adverse events in pediatric patients.

“Hopefully clinicians will begin to consider young myopic children as patients who are capable of independent contact lens care,” says Dr. Walline. “Clinicians may be more comfortable using contact lens myopia control methods, knowing that children can safely wear contact lenses.” ■

1. Bullimore MA. The safety of soft contact lenses in children. *Optom Vis Sci.* 2017;94(6):638-46.

2. Chia A, Lu Q, Tan D. Atropine for the treatment of childhood myopia: safety and efficacy of 0.5%, 0.1%, and 0.01% doses (Atropine for the Treatment of Myopia 2). *Ophthalmology.* 2012;119(2):347-54.

3. Sankaridurg P, Donovan L, Varnas S, et al. Spectacle lenses designed to reduce progression of myopia: 12-month results. *Optom Vis Sci.* 2010;87(9):631-41.

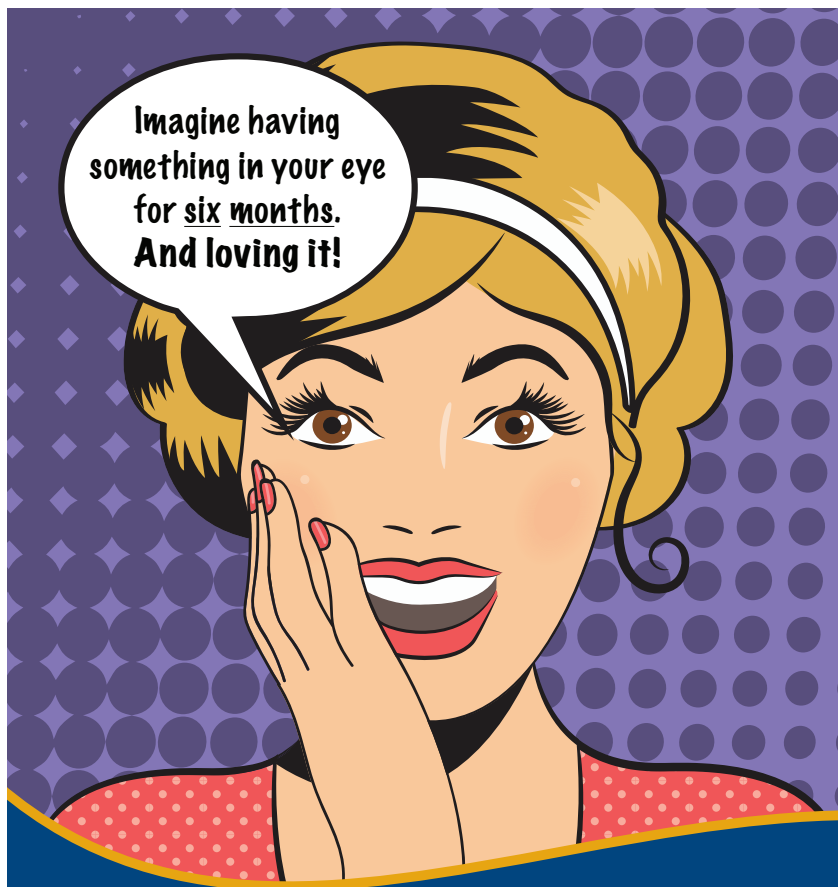4. Hasebe S, Jun J, Varnas SR. Myopia control with positively aspherized progressive addition lenses: a 2-year, multicenter, randomized, controlled trial. *Invest Ophthalmol Vis Sci.* 2014;55(11):7177-88.

5. Berntsen DA, Sinnott LT, Mutti DO, Zadnik K. A randomized trial using progressive addition lenses to evaluate theories of myopia progression in children with a high lag of accommodation. *Invest Ophthalmol Vis Sci.* 2012;53(2):640-9.

6. Anstice NS, Phillips JR. Effect of dual-focus soft contact lens wear on axial myopia progression in children. *Ophthalmology.* 2011;118(6):1152-61.

7. Sankaridurg P, Holden B, Smith E, et al. Decrease in rate of myopia progression with a contact lens designed to reduce relative peripheral hyperopia: one-year results. *Invest Ophthalmol Vis Sci.* 2011;52(13):9362-7.

8. Walline JJ, Greiner KL, McVey ME, Jones-Jordan LA. Multifocal contact lens myopia control. *Optom Vis Sci.* 2013; 90(11):1207-14.



## Six Full Months\* of Effective Dry Eye Relief

The Extend 180™ Long-Term Dissolvable Implant

### Featuring

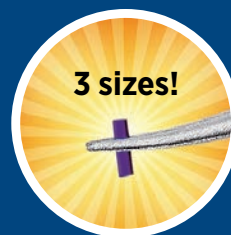- Simple insertion technique
- No foreign body sensation
- Exceptionally reliable retention

### Indications

- Post-ocular surgery or seasonal dry eye
- Contact lens intolerance
- Dry eye associated with digital eye strain

For introductory pricing, please call:


866-906-8080 or [customersupport@beaver-visitec.com](mailto:customersupport@beaver-visitec.com)



**bvi** Beaver Visitec  
*Keeping Your Vision in Sight*

\* 510(k) Summary K162361

Beaver-Visitec International, Inc., 411 Waverley Oaks Road, Waltham, MA 02452  
BVI, BVI Logo and all other trademarks (unless noted otherwise) are property of  
Beaver-Visitec International ("BVI") © 2017 BVI



Coming soon,  
**VYZULTA**<sup>™</sup>

(latanoprostene bunod  
ophthalmic solution) 0.024%

**BAUSCH + LOMB**

VYZULTA is a trademark of Bausch & Lomb Incorporated or its affiliates.  
©2016 Bausch & Lomb Incorporated. All rights reserved. VYZ.0014.USA.16

# Contents

Review of Optometry July 2017

## 23<sup>RD</sup> ANNUAL GLAUCOMA REPORT

### 34 Mastering MIGS: Today and Tomorrow

These procedures have changed the glaucoma treatment landscape—and more are on the way. Here's a primer for ODs. **By Justin Schweitzer, OD**

### 40 Glaucoma Surgery: Are You Ready to Refer?

Surgery is inevitable for many patients with glaucoma. These tips can help you refer when the time is right—and comanage after the fact.

**By Rick Trevino, OD, Carolyn Majcher, OD, and William Sponsel, MD**

### 48 Looking to the Future of Glaucoma Treatment

A trio of new therapies is poised to change how ODs fight the disease.

**By Michael Rebar, OD, and Andrew S. Gurwood, OD**

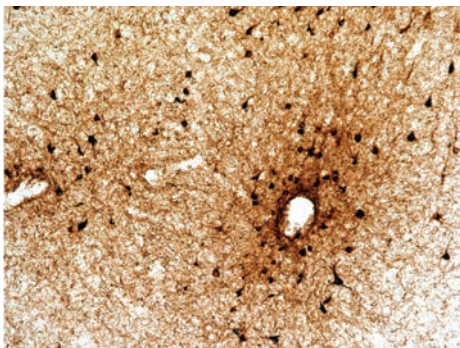
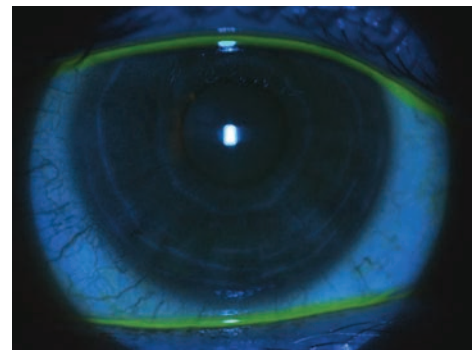
### 54 10-2 Visual Field Testing: A Tool for All Glaucoma Stages

This diagnostic tool is a must for detecting paracentral and visual field defects close to fixation in glaucoma, even the early-moderate stage.

**By Austin Lifferth, OD, Brian Fisher, OD, April Stursma, OD, Sarah Cordes, OD, Stephanie Carter, OD, and Trina Perkins, OD**

### 64 Be a Hero to Your HSVK Patients

It is important for ODs to have a thorough understanding of this sight-threatening disease.  
**By Shannon Leon, OD, and Joseph J. Pizzimenti, OD**



EARN 2 CE CREDITS

### 72 Caring for Patients With Brain Injury

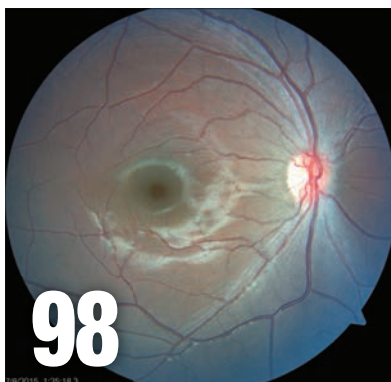
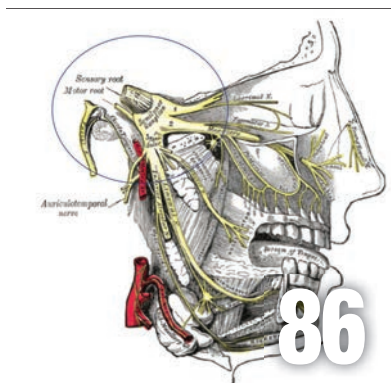
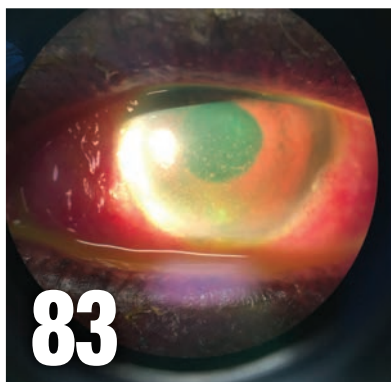
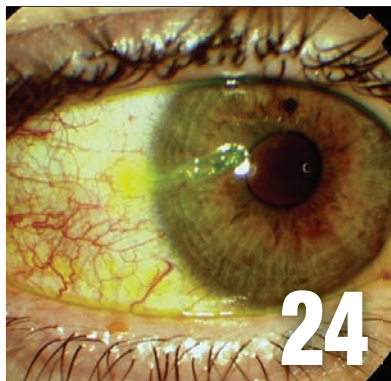
More often than not, TBI affects a patient's vision, and ODs must be prepared to evaluate and manage this population.

**By Aaron K. Tarbett, OD**

# Departments

Review of Optometry July 2017

- 4 News Review**
- 18 Outlook**  
The More Things Change...  
**JACK PERSICO**
- 20 Through My Eyes**  
5 Steps to Better Glaucoma Care  
**PAUL M. KARPECKI, OD**
- 22 Chairside**  
Who's the Boss?  
**MONTGOMERY VICKERS, OD**
- 24 Clinical Quandaries**  
What a Pain!  
**PAUL C. AJAMIAN, OD**
- 26 Ocular Surface Review**  
Hitting a Nerve  
**PAUL M. KARPECKI, OD**
- 30 Coding Connection**  
Decoding MIGS Coding  
**JOHN RUMPAKIS, OD, MBA**
- 80 Neuro Clinic**  
Every Picture Tells a Story  
**MICHAEL DELGIODICE, OD, AND  
MICHAEL TROTTINI, OD**
- 83 The Essentials**  
Lymphocytes on the Loose  
**BISANT A. LABIB, OD**
- 86 Review of Systems**  
Not Just Another Headache  
**CARLO J. PELINO, OD, AND  
JOSEPH J. PIZZIMENTI, OD**
- 89 Therapeutic Review**  
Prescribe with Laser Focus  
**ALAN G. KABAT, OD, AND  
JOSEPH W. SOWKA, OD**
- 91 Advertisers Index**
- 92 Meetings & Conferences**
- 94 Classifieds**
- 98 Diagnostic Quiz**  
Beginner's Luck  
**ANDREW S. GURWOOD, OD**



## On The Web >> and more

Check out our multimedia and continuing education online at:  
[www.reviewofoptometry.com](http://www.reviewofoptometry.com)

### Digital Edition



Left your copy of *Review of Optometry* at the office? No problem! Access *Review* on your computer or mobile device!

Go to [www.reviewofoptometry.com](http://www.reviewofoptometry.com) and click on the digimag link for the current issue.

### Facebook and Twitter



For daily updates, "Like" our page on Facebook or "Follow" us on Twitter!


- [www.facebook.com/revoptom](http://www.facebook.com/revoptom)
- <http://twitter.com/#!/revoptom>

Look for augmented content and special offers from *Review* and our advertisers. Specified pages work in conjunction with your smartphone or other mobile device to enhance the experience. With Layar, interactive content leaps off the page!



**Step 1:** Download the free Layar app for iPhone or Android.



**Step 2:** Look for pages with the Layar Logo.  INTERACTIVE PRINT



**Step 3:** Open the Layar app, hold the phone above the page and tap to scan it. Hold the phone above the page to view the interactive content.

The first 150 app downloads and completed forms will be entered into a drawing for a complimentary registration to one of *Review's* 14-hour CE meetings, valued at \$495.

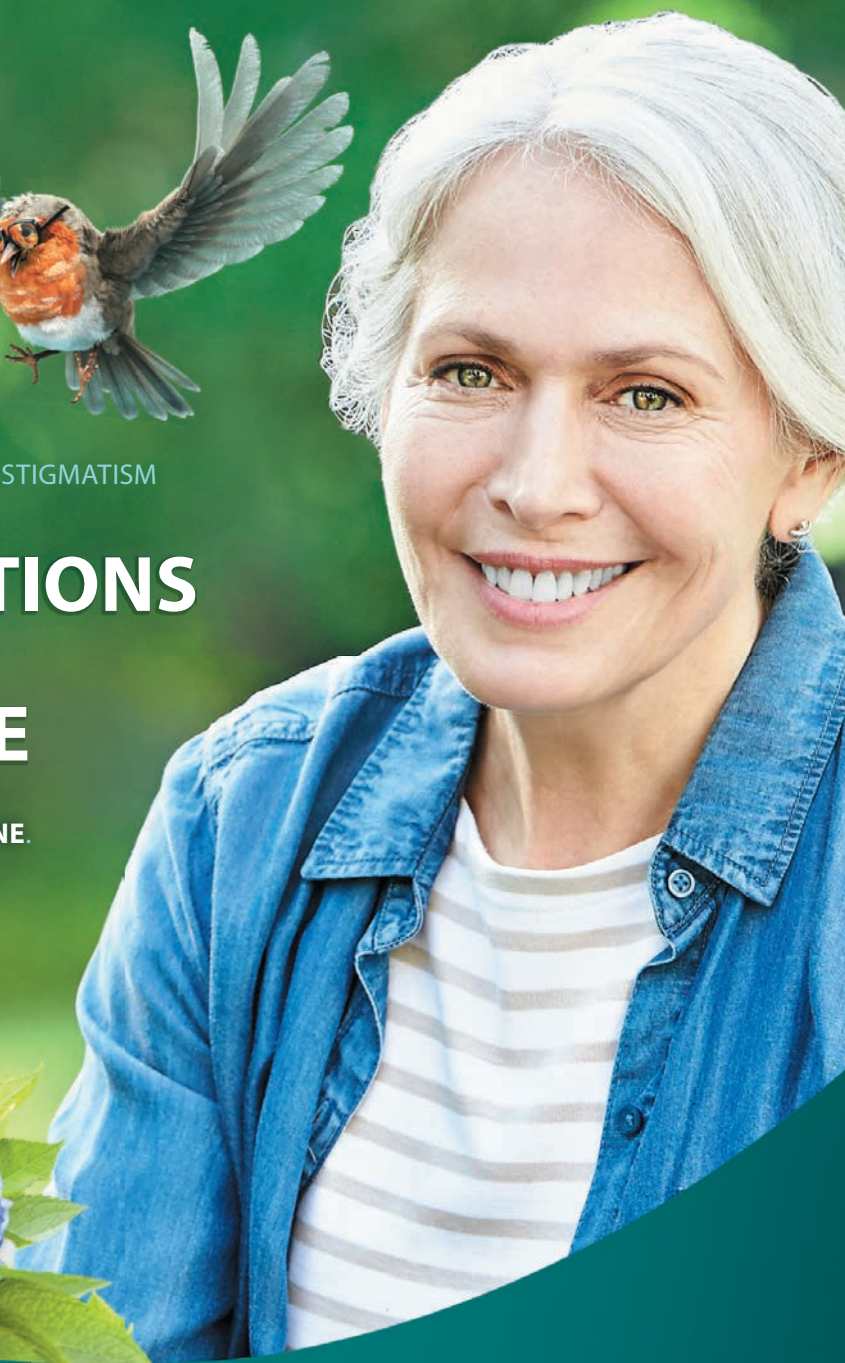


CATHY CATARACTS & ANDY ASTIGMATISM

# 2 1

## EYE CONDITIONS PROCEDURE

GET TWO BIRDS WITH ONE STONE.  
HELP YOUR PATIENTS CORRECT  
**CATARACTS & ASTIGMATISM**  
WITH **ONE PROCEDURE**.



Talk to your astigmatic patients about toric IOL options earlier, and help them see cataract surgery as an opportunity to correct two eye conditions at once.

[mycataracts.com](http://mycataracts.com): online patient resources  
**1-844-MYCATARACT** (1-844-692-2827): cataract counselors

**Alcon** A Novartis  
Division

© 2016 Novartis 10/16 US-ODE-16-E-4365



xiidra®  
(lifitegrast  
ophthalmic solution) 5%

# Diisc

**Proven to treat the signs of inferior corneal staining in 12 weeks  
and symptoms of eye dryness in 12, 6, and as little as 2.**

Xiidra helped provide symptom relief from eye dryness in some patients at week 2—and a measurable reduction in signs of inferior corneal staining in just 12 weeks. Consider Xiidra to help your Dry Eye patients find the relief they've been waiting for.

**Take it all in at [Xiidra-ECP.com](http://Xiidra-ECP.com)**

Four randomized, double-masked, 12-week trials evaluated the efficacy and safety of Xiidra versus vehicle as assessed by improvement in the signs (measured by Inferior Corneal Staining Score) and symptoms (measured by Eye Dryness Score) of Dry Eye Disease (N=2133).

# OVER

what Dry Eye patients have been waiting for

## Indication

Xiidra® (lifitegrast ophthalmic solution) 5% is indicated for the treatment of signs and symptoms of dry eye disease (DED).

## Important Safety Information

In clinical trials, the most common adverse reactions reported in 5-25% of patients were instillation site irritation, dysgeusia and reduced visual acuity. Other adverse reactions reported in 1% to 5% of the patients were blurred vision, conjunctival hyperemia, eye irritation, headache, increased lacrimation, eye discharge, eye discomfort, eye pruritus and sinusitis.

To avoid the potential for eye injury or contamination of the solution, patients should not touch the tip of the single-use container to their eye or to any surface.

Contact lenses should be removed prior to the administration of Xiidra and may be reinserted 15 minutes following administration.

Safety and efficacy in pediatric patients below the age of 17 years have not been established.

**For additional safety information, see accompanying Brief Summary of Safety Information and Full Prescribing Information on Xiidra-ECP.com.**



## BRIEF SUMMARY:

Consult the Full Prescribing Information for complete product information.

## INDICATIONS AND USAGE

Xiidra® (lifitegrast ophthalmic solution) 5% is indicated for the treatment of the signs and symptoms of dry eye disease (DED).

## DOSAGE AND ADMINISTRATION

Instill one drop of Xiidra twice daily (approximately 12 hours apart) into each eye using a single use container. Discard the single use container immediately after using in each eye. Contact lenses should be removed prior to the administration of Xiidra and may be reinserted 15 minutes following administration.

## ADVERSE REACTIONS

### Clinical Trials Experience

Because clinical studies are conducted under widely varying conditions, adverse reaction rates observed in clinical studies of a drug cannot be directly compared to rates in the clinical trials of another drug and may not reflect the rates observed in practice. In five clinical studies of dry eye disease conducted with lifitegrast ophthalmic solution, 1401 patients received at least 1 dose of lifitegrast (1287 of which received lifitegrast 5%). The majority of patients (84%) had  $\leq 3$  months of treatment exposure. 170 patients were exposed to lifitegrast for approximately 12 months. The majority of the treated patients were female (77%). The most common adverse reactions reported in 5-25 % of patients were instillation site irritation, dysgeusia and reduced visual acuity. Other adverse reactions reported in 1% to 5% of the patients were blurred vision, conjunctival hyperemia, eye irritation, headache, increased lacrimation, eye discharge, eye discomfort, eye pruritus and sinusitis.

## USE IN SPECIFIC POPULATIONS

### Pregnancy

There are no available data on Xiidra use in pregnant women to inform any drug associated risks. Intravenous (IV) administration of lifitegrast to pregnant rats, from pre-mating through gestation day 17, did not produce teratogenicity at clinically relevant systemic exposures. Intravenous administration of lifitegrast to pregnant rabbits during organogenesis produced an increased incidence of omphalocele at the lowest dose tested, 3 mg/kg/day (400-fold the human plasma exposure at the recommended human ophthalmic dose [RHOD], based on the area under the curve [AUC] level). Since human systemic exposure to lifitegrast following ocular administration of Xiidra at the RHOD is low, the applicability of animal findings to the risk of Xiidra use in humans during pregnancy is unclear.

## Animal Data

Lifitegrast administered daily by intravenous (IV) injection to rats, from pre-mating through gestation day 17, caused an increase in mean preimplantation loss and an increased incidence of several minor skeletal anomalies at 30 mg /kg /day, representing 5,400-fold the human plasma exposure at the RHOD of Xiidra, based on AUC. No teratogenicity was observed in the rat at 10 mg /kg /day (460-fold the human plasma exposure at the RHOD, based on AUC ). In the rabbit, an increased incidence of omphalocele was observed at the lowest dose tested, 3 mg /kg /day (400-fold the human plasma exposure at the RHOD, based on AUC), when administered by IV injection daily from gestation days 7 through 19. A fetal No Observed Adverse Effect Level (NOAEL) was not identified in the rabbit.

## Lactation

There are no data on the presence of lifitegrast in human milk, the effects on the breastfed infant, or the effects on milk production. However, systemic exposure to lifitegrast from ocular administration is low. The developmental and health benefits of breastfeeding should be considered, along with the mother's clinical need for Xiidra and any potential adverse effects on the breastfed child from Xiidra.

## Pediatric Use

Safety and efficacy in pediatric patients below the age of 17 years have not been established.

## Geriatric Use

No overall differences in safety or effectiveness have been observed between elderly and younger adult patients.

## NONCLINICAL TOXICOLOGY

### Carcinogenesis, Mutagenesis, Impairment of Fertility

**Carcinogenesis:** Animal studies have not been conducted to determine the carcinogenic potential of lifitegrast.

**Mutagenesis:** Lifitegrast was not mutagenic in the *in vitro* Ames assay. Lifitegrast was not clastogenic in the *in vivo* mouse micronucleus assay. In an *in vitro* chromosomal aberration assay using mammalian cells (Chinese hamster ovary cells), lifitegrast was positive at the highest concentration tested, without metabolic activation.

**Impairment of fertility:** Lifitegrast administered at intravenous (IV) doses of up to 30 mg/kg/day (5400-fold the human plasma exposure at the recommended human ophthalmic dose (RHOD) of lifitegrast ophthalmic solution, 5%) had no effect on fertility and reproductive performance in male and female treated rats.



Manufactured for: Shire US Inc., 300 Shire Way, Lexington, MA 02421.

For more information, go to [www.Xiidra.com](http://www.Xiidra.com) or call 1-800-828-2088.

Marks designated ® and ™ are owned by Shire or an affiliated company.

©2016 Shire US Inc.

US Patents: 8367701; 9353088; 7314938; 7745460; 7790743; 7928122; 9216174; 8168655; 8084047; 8592450; 9085553; 8927574; 9447077; 9353088 and pending patent applications.

Last Modified: 12/2016 S26218



## CONTRIBUTING EDITORS

PAUL C. AJAMIAN, OD, ATLANTA  
AARON BRONNER, OD, KENNEWICK, WASH.  
MILE BRUJIC, OD, BOWLING GREEN, OHIO  
DEREK N. CUNNINGHAM, OD, AUSTIN, TEXAS  
MARK T. DUNBAR, OD, MIAMI  
ARTHUR B. EPSTEIN, OD, PHOENIX  
JAMES L. FANELLI, OD, WILMINGTON, NC  
FRANK FONTANA, OD, ST. LOUIS  
GARY S. GERBER, OD, HAWTHORNE, NJ  
ANDREW S. GURWOOD, OD, PHILADELPHIA  
ALAN G. KABAT, OD, MEMPHIS, TENN.  
DAVID KADING, OD, SEATTLE  
PAUL M. KARPECKI, OD, LEXINGTON, KY.  
JEROME A. LEGERTON, OD, MBA, SAN DIEGO  
JASON R. MILLER, OD, MBA, POWELL, OHIO  
CHERYL G. MURPHY, OD, BABYLON, NY  
CARLO J. PELINO, OD, JENKINTOWN, PA.  
JOSEPH PIZZIMENTI, OD, SAN ANTONIO, TEXAS  
JOHN RUMPAKIS, OD, MBA, PORTLAND, ORE.  
DIANA L. SHECHTMAN, OD, FORT LAUDERDALE, FLA.  
JEROME SHERMAN, OD, NEW YORK  
JOSEPH P. SHOVLIN, OD, SCRANTON, PA.  
JOSEPH W. SOWKA, OD, FORT LAUDERDALE, FLA.  
MONTGOMERY VICKERS, OD, LEWISVILLE, TEXAS  
WALTER O. WHITLEY, OD, MBA, VIRGINIA BEACH, VA.

## EDITORIAL REVIEW BOARD

JEFFREY R. ANSHEL, OD, ENCINITAS, CALIF.  
JILL AUTRY, OD, RPH, HOUSTON  
SHERRY J. BASS, OD, NEW YORK  
EDWARD S. BENNETT, OD, ST. LOUIS  
MARC R. BLOOMENSTEIN, OD, SCOTTSDALE, ARIZ.  
CHRIS J. CAKANAC, OD, MURRYSVILLE, PA.  
JERRY CAVALLERANO, OD, PHD, BOSTON  
WALTER L. CHOATE, OD, MADISON, TENN.  
BRIAN CHOU, OD, SAN DIEGO  
A. PAUL CHOUS, MA, OD, TACOMA, WASH.  
ROBERT M. COLE, III, OD, BRIDGETON, NJ  
GLENN S. CORBIN, OD, WYOMISSING, PA.  
ANTHONY S. DIEDICUE, OD, STROUDSBURG, PA.  
S. BARRY EIDEN, OD, DEERFIELD, ILL.  
STEVEN FERRUCCI, OD, SEPULVEDA, CALIF.  
MURRAY FINGERET, OD, HEWLETT, NY  
IAN BEN GADDIE, OD, LOUISVILLE, KY.  
PAUL HARRIS, OD, MEMPHIS, TN  
MILTON HOM, OD, AZUSA, CALIF.  
BLAIR B. LONSBERRY, MS, OD, MED, PORTLAND, ORE.  
THOMAS L. LEWIS, OD, PHD, PHILADELPHIA  
DOMINICK MAINO, OD, MED, CHICAGO  
KELLY A. MALLOY, OD, PHILADELPHIA  
RICHARD B. MANGAN, OD, LEXINGTON, KY.  
RON MELTON, OD, CHARLOTTE, NC  
PAMELA J. MILLER, OD, JD, HIGHLAND, CALIF.  
BRUCE MUCHNICK, OD, COATESVILLE, PA.  
MARC MYERS, OD, COATESVILLE, PA.  
WILLIAM B. POTTER, OD, FREEHOLD, NJ  
CHRISTOPHER J. QUINN, OD, ISELIN, NJ  
MICHAEL C. RADOIU, OD, STAUNTON, VA.  
MOHAMMAD RAFIETARY, OD, MEMPHIS, TN  
JOHN L. SCHACHET, OD, ENGLEWOOD, COLO.  
JACK SCHAEFFER, OD, BIRMINGHAM, ALA.  
LEO P. SEMES, OD, BIRMINGHAM, ALA.  
LEONID SKORIN, JR., OD, DO, ROCHESTER, MINN.  
JOSEPH W. SOWKA, OD, FORT LAUDERDALE, FLA.  
SRUTHI SRINIVASAN, PHD, BS OPTOM, WATERLOO, ONT.  
BRAD M. SUTTON, OD, INDIANAPOLIS  
LORETTA B. SZCZOTKA, OD, PHD, CLEVELAND  
MARC TAUB, OD, MEMPHIS, TN  
TAMMY P. THAN, MS, OD, BIRMINGHAM, ALA.  
RANDALL THOMAS, OD, CONCORD, NC  
SARA WEIDMAYER, OD, ANN ARBOR, MI  
KATHY C. WILLIAMS, OD, SEATTLE  
KAREN YEUNG, OD, LOS ANGELES

# CONNECT WITH MILLENIALS

To grow your practice with  
millennial patients, your website  
needs to be on the mobile devices  
they can't live without.



To see how your website can connect  
you to more new patients, contact us  
for a **FREE website evaluation** and  
get **40% off of setup!**

📞 877.716.0927

🌐 [go.imatrix.com/ReviewOptometry](http://go.imatrix.com/ReviewOptometry)





PRINTED IN USA

FOUNDING EDITOR, FREDERICK BOGER  
1891-1913

EDITORIAL OFFICES

11 CAMPUS BLVD., SUITE 100  
NEWTOWN SQUARE, PA 19073

WEBSITE • WWW.REVIEWOFOPTOMETRY.COM

SUBSCRIPTION INQUIRIES

1-877-529-1746

CONTINUING EDUCATION INQUIRIES

1-800-825-4696

EDITOR-IN-CHIEF • JACK PERSICO

(610) 492-1006 • JPERSICO@JOBSON.COM

MANAGING EDITOR • REBECCA HEPP

(610) 492-1005 • RHEPP@JOBSON.COM

SENIOR EDITOR • BILL KEKEVIAN

(610) 492-1003 • BKEKEVIAN@JOBSON.COM

ASSOCIATE EDITOR • MICHAEL RIVIELLO

(610) 492-1021 • MRIVIELLO@JOBSON.COM

ASSOCIATE EDITOR • MICHAEL IANNUCCI

(610) 492-1043 • MIANNUCCI@JOBSON.COM

SPECIAL PROJECTS EDITOR • JILL HOFFMAN

(610) 492-1037 • JHOFFMAN@JOBSON.COM

ART DIRECTOR • JARED ARAUJO

(610) 492-1032 • JARAUJO@JOBSON.COM

DIRECTOR OF CE ADMINISTRATION • REGINA COMBS

(212) 274-7160 • RCOMBS@JOBSON.COM

EDITORIAL BOARD

CHIEF CLINICAL EDITOR • PAUL M. KARPECKI, OD

ASSOCIATE CLINICAL EDITORS • JOSEPH P. SHOWLIN, OD;  
ALAN G. KABAT, OD; CHRISTINE W. SINDT, OD

DIRECTOR OPTOMETRIC PROGRAMS • ARTHUR EPSTEIN, OD

CLINICAL & EDUCATION CONFERENCE ADVISOR  
PAUL M. KARPECKI, OD

CASE REPORTS COORDINATOR • ANDREW S. GURWOOD, OD

CLINICAL CODING EDITOR • JOHN RUMPAKIS, OD, MBA

CONSULTING EDITOR • FRANK FONTANA, OD

COLUMNISTS

CHAIRSIDE • MONTGOMERY VICKERS, OD

CLINICAL QUANDARIES • PAUL C. AJAMIAN, OD

CODING CONNECTION • JOHN RUMPAKIS, OD

CORNEA & CONTACT LENS Q+A • JOSEPH P. SHOWLIN, OD

DIAGNOSTIC QUIZ • ANDREW S. GURWOOD, OD

THE ESSENTIALS • BISANT A. LABIB, OD

FOCUS ON REFRACTION • MARC TAUB, OD;

PAUL HARRIS, OD

GLAUCOMA GRAND ROUNDS • JAMES L. FANELLI, OD

NEURO CLINIC • MICHAEL TROTTINI, OD;

MICHAEL DELGIODICE, OD

OCULAR SURFACE REVIEW • PAUL M. KARPECKI, OD

RETINA QUIZ • MARK T. DUNBAR, OD

REVIEW OF SYSTEMS • CARLO J. PELINO, OD;

JOSEPH J. PIZZIMENTI, OD

SURGICAL MINUTE • DEREK N. CUNNINGHAM, OD;

WALTER O. WHITLEY, OD, MBA

THERAPEUTIC REVIEW • JOSEPH W. SOWKA, OD;

ALAN G. KABAT, OD

THROUGH MY EYES • PAUL M. KARPECKI, OD

URGENT CARE • RICHARD B. MANGAN, OD

JOBSON MEDICAL INFORMATION LLC



## Outlook

By Jack Persico, Editor-in-Chief



# The More Things Change...

Glaucoma care has flourished in recent decades, but still can't crack its toughest challenge.

Imagine treating glaucoma without prostaglandin analogs, evaluating patients without OCT and recommending surgery to improve aqueous flow only for the most advanced, intractable cases. That was roughly the state of affairs in 1994, when we launched our first annual glaucoma report.

Latanoprost was still two years away from launch—beta blockers ruled the roost—and the cutting-edge diagnostic technology of the day was retinal tomography. Glaucoma surgery was, if anything, *maximally* invasive in those days, as MIGS procedures were at least a decade away. ALT was making waves as an early laser surgical alternative to meds, but its safer, better successor—SLT—had yet to arrive. The OHTS trial had only just begun enrolling patients that year, so good luck figuring out what to make of your ocular hypertensives. And the influence of genetics and nutrition on glaucoma rarely got mentioned outside of ARVO.

Needless to say, glaucoma care has gotten dramatically more sophisticated in the 23 years since our first report—but with one frustrating exception that tempers the success of all the others.

First the good news: The technology to view and assess the optic nerve and nerve fiber layer has advanced by leaps and bounds. Surgeons essentially invented a brand new category of procedures: minimally invasive glaucoma surgeries. And newer drugs have improved the ability to lower IOP effectively and comfortably for patients.

What *hasn't* evolved? The target. IOP lowering remains the goal of every medical and surgical intervention in the toolbox. And it's been so for decades. "Nothing is being developed at the moment that is fundamentally different than what already exists," an author wrote back in our 1994 report. "With this prognosis, glaucoma's legacy for frustrating patients and clinicians alike may very well continue until the next century." Indeed it has.

I'm struck by the naiveté (or maybe call it optimism) of the subtitle we used on that 1994 article: "Despite advances, researchers are still years away from a cure." That strongly suggests that a cure is possible, and it's just a matter of time until we get there. Nobody talks like that anymore about glaucoma. If you do, write to me and tell me why; I'd truly like to hear from you.

Is there any serious work afoot in neuroprotection? In 2011, the Low-pressure Glaucoma Treatment Study showed a protective effect from brimonidine. But the clinical trials needed to study neuroprotective agents and bring them to market would be hugely complex and take many years to run. Perhaps genetics and nutrition will identify more modifiable risk factors, or ocular perfusion pressure and its effect on metabolic processes will open up new avenues of exploration. Let's hope the field one day finally sheds its obsession with IOP.

For now, the tools and techniques of glaucoma care are better than ever, and our 23rd report helps you stay ahead of this complex field. ■



# So many advantages for such a small piece of medical technology

**Tapered Shaft**  
facilitates better  
patient retention

**Low Profile Cap**  
superb comfort  
with less  
foreign body  
sensation

**Fine Distal Tip**  
for easy  
insertion

**Soft Pliable Silicone**  
to accommodate  
any anatomy



## 5 Steps to Better Glaucoma Care

Optometry has to take the lead with glaucoma, especially with recent advancements.

We, as a profession, are integral to glaucoma management; we are the most likely to make the original diagnosis and can manage treatment for most cases. But with new advancements in glaucoma surgery, some ODs question our role. These five steps can help us stay in charge:

**1. Diagnose it sooner.** With new OCT modalities, we can diagnose the disease sooner than ever and begin treatment earlier. However, ODs must use this technology with caution and be sure to have a firm grasp on the data provided. We have to understand what we are looking at with the deceptively simple red, yellow and green charts to avoid over- or under-diagnosing glaucoma.

Other new diagnostics can help as well. Corneal hysteresis may predict visual field loss progression and can play a role in deciding when to treat and in setting treatment expectations. And someday, 24-hour home monitoring of IOP may completely transform our management strategies.

**2. Understand the disease better.** While we don't fully understand what causes glaucoma, we know IOP is a risk factor, as is corneal thickness and hysteresis, family history, age, race, high myopia, systemic conditions, previous trauma and chronic inflammation. Knowing the cause will one day allow us to treat the disease more effectively. One theory suggests it's caused by an imbalance between IOP inside the eye and intracranial pressure (ICP) around the optic nerve, affecting the eye's metabolic needs.<sup>1</sup> For example, patients

with idiopathic intracranial hypertension have a bowing of their optic nerve, and 50% of astronauts develop vision loss because their cerebral spinal fluid increases disproportionately higher than their IOP, resulting in a hyperopic shift and optic nerve edema.<sup>1</sup> So the key ratio may be IOP minus ICP—not just elevated IOP.

**3. Rethink surgery.** The introduction of minimally invasive glaucoma surgeries (MIGS) has forever changed glaucoma treatment. We must be ready to help manage patient compliance, understand the options for those on maximum therapy and properly educate and refer patients with both glaucoma and cataracts. Invasive surgeries such as trabeculectomy will go by the wayside, making room for a greater combination of MIGS, laser procedures such as SLT, and next-generation pharmaceuticals.

**4. Take advantage of new therapeutics.** It's been two decades since we've had a significant new glaucoma drug, but that could change in the next few months. In a recent study, Vyzulta (latanoprostene bunod 0.024%, Bausch + Lomb), a nitric oxide-donating prostaglandin F2-alpha analog, lowered IOP by 9mm Hg compared with timolol at 7mm Hg—a significant finding, considering few, if any, previous glaucoma medications showed superiority to timolol in FDA trials.<sup>2,3</sup> A new drug class, rho-kinase inhibitors, may also change the landscape of glaucoma management. Rhopressa (netarsudil, Aerie Pharmaceuticals) gives us a different and perhaps complementary mechanism of action

because it increases TM outflow, decreases aqueous production and decreases episcleral venous pressure. A Phase II trial shows Rolatan (netarsudil plus latanoprost, Aerie Pharmaceuticals) has an IOP-lowering effect 1mm Hg to 3mm Hg greater than monotherapy with either of its two components.<sup>4</sup> New drug delivery systems may provide significant benefits for patient compliance as well. For example, Phase III clinical trials for a travoprost-eluting punctal plug (Ocular Therapeutix) suggest the therapeutic effect may last three months with each plug.<sup>5</sup>

**5. Treat the ocular surface.** Optometrists can't forget the impact of glaucoma therapies on the ocular surface. Staining, blurred vision, irritation or dryness from chronic meds can cause patients to decrease or even discontinue their use. Something as simple as managing the ocular surface may improve compliance and, ultimately, outcomes.

Glaucoma is a condition that affects all of our practices, and these five elements may well dictate the future of disease management, our understanding and innovations in patient care. ■

1. Berdahl JP, Allingham RR. Intracranial pressure and glaucoma. *Curr Opin Ophthalmol*. 2010;21(2):106-11.  
2. Weinreb RN, Scassellati Storzolini B, Vittitow J, Liebmann J. Latanoprostene bunod 0.024% versus timolol maleate 0.5% in subjects with open-angle glaucoma or ocular hypertension: The APOLLO study. *Ophthalmology*. 2016;123(5):965-73.  
3. Hedman K, Alm A. A pooled-data analysis of three randomized, double-masked, six-month clinical studies comparing the intraocular pressure reducing effect of latanoprost and timolol. *Eur J Ophthalmol*. 2000;10(2):95-104.  
4. Aerie Pharmaceuticals. Rolatan Mercury 2 Phase 3 Topline Results. <http://investors.aeriepharma.com/events.cfm>. Accessed June 28, 2017.  
5. Ocular Therapeutix. Dextenza. [www.ocutx.com/pipeline/dextenza](http://www.ocutx.com/pipeline/dextenza). Accessed June 28, 2017.

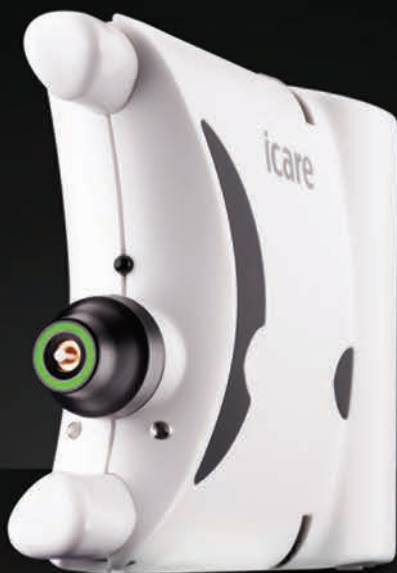# SUMMER SPECIAL!

# WIN A FREE

# TONOMETER\*

**icare**  
**HOME**

ANYWHERE, ANYTIME



**icare**  
**ic100**

THE INTELLIGENT  
CHOICE

\*OFFER EXPIRES 08.31.2017. FIND YOUR LOCAL REPRESENTATIVE AT [WWW.ICARE-USA.COM](http://WWW.ICARE-USA.COM) FOR MORE DETAILS.

Learn more: [info@icare-usa.com](mailto:info@icare-usa.com) or [www.icare-usa.com](http://www.icare-usa.com)

# Who's the Boss?

Spoiler alert: it isn't you. So tread carefully. **By Montgomery Vickers, OD**

There is a force in our offices that can move our practices closer and closer to the perfection we all know exists, or can destroy the fabric of our being.

I like to refer to this exciting, frightening behemoth as... the Office Manager.

## Slay the Beast

When I first started, the office manager had been with the practice for more than 25 years, and she had limitless power over all. She built pyramids and destroyed whole villages with a single glance—and was paid probably five times more than me, a mere mortal doctor.

She was the staffer who decided patients could buy glasses and contact lenses with no money down and a simple monthly payment of any amount, even as little as \$3 every 90 days. Brilliant business strategy!

When I became the boss, I had her exorcised from the practice on day one. My senior partner was aghast, until we had twice as much net income within the next year and a half with no angry patients. The good ol' boys he said didn't have the money to pay us outright started pulling out huge wads of Benjamins to get that 10% "cash discount." We did not miss that office manager/Goddess of War.

## A New Sheriff in Town

Years ago, I wrote a column about my next office manager called, "Sleeping with the Office Manager." This got a lot of attention until you realized I was also married to the office manager. Oh, you can be sure

the earth shook and both angels and fiends huddled in fear when she walked the halls, and by "earth," "angels" and "fiends" I mean "Dr. Vickers."

I had enough sense to get out of her way and let her build the practice with her smarts, amazing humor and loving and giving personality. I was overjoyed that at least one of us had those qualities. Every day I thanked my lucky stars that I had lost that Super Bowl bet and had to propose.

We had a great run all the way up to selling our 36-year-old practice in 2015 and moving to Texas.

## Hirer Beware

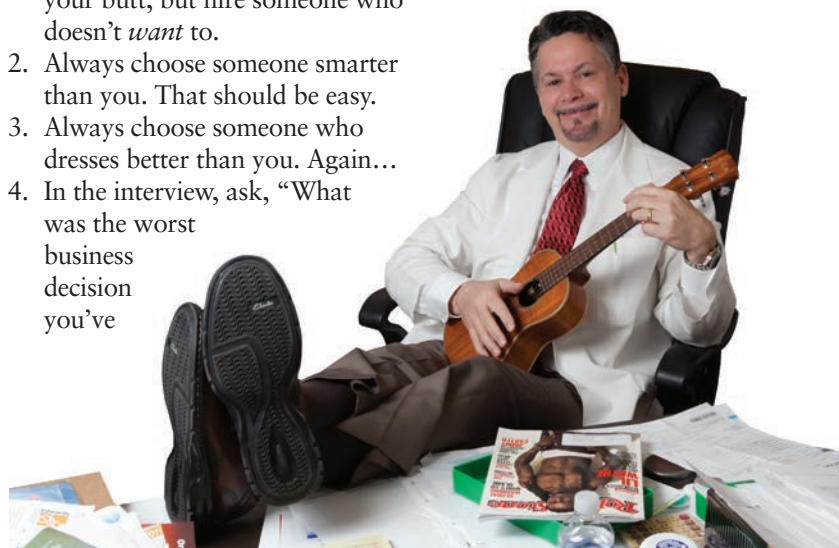Assuming you choose not to bet on Super Bowls when choosing your next office manager, I have some tips to help guide you:

1. Never choose anyone who seems to want to whup your butt. They will *all* be able to whup your butt, but hire someone who doesn't *want* to.
2. Always choose someone smarter than you. That should be easy.
3. Always choose someone who dresses better than you. Again...
4. In the interview, ask, "What was the worst business decision you've

ever made?" Avoid the impulse to add, "until today."

5. Ask them, "When was the last time you had your eyes checked?" If they answer 'Uh oh,' that does not disqualify them. If they answer 'My what?' then think again.
6. Nail the window of your office shut and ask them to open it. Their reaction will tell you a lot. If they can open the window, don't say anything that will tick them off.

We have a new office manager here in Texas. Shelly meets every requirement referenced in the above list. She also has a notable lack of experience in the eye care field, which means she has an open mind that has already helped us a lot. Someday I will tell her there's no such thing as "cryopia" for patients whose eyes water a lot. For now, it's my little secret. ■



# LIVE THE GOOD LIGHT™



## Lenses that keep up with kids. Everywhere they go.

From the backyard to their favorite screen and everywhere in between, Transitions® lenses help protect young patients from UV rays and harmful blue light, indoors and out. So their lenses keep up with them no matter where they go.



**Transitions®**  
ADAPTIVE LENSES®

**Find Back-to-School Materials at [TransitionsPRO.com/Kids](https://www.transitionspro.com/kids)**



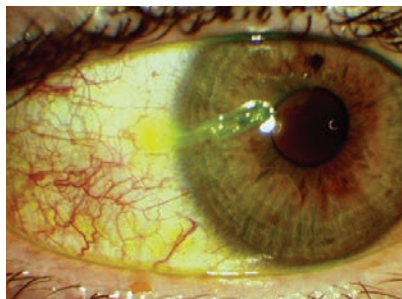
# What a Pain!

The profession fights to expand and maintain its privileges at every turn—they're vital to providing care. Don't take your DEA license for granted. **Edited by Paul C. Ajamian, OD**

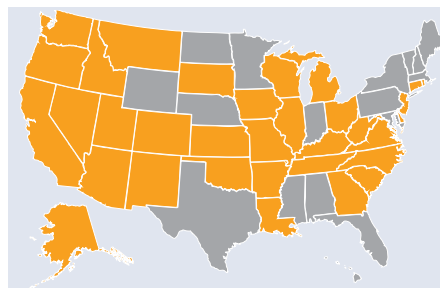
**Q** I just got my DEA registration renewal—for \$731! I wrote two pain med Rx's last year. Is it worth it?

**A** Having recently gone through a scope of practice battle in his home state, Ben Casella, OD, of Augusta, Ga., is more mindful than ever of how hard optometry's predecessors fought to obtain the privileges some assume have always existed. "It takes tremendous efforts just to be able to practice what we are taught as optometrists," says Dr. Casella, immediate past president of the Georgia Optometric Association. "Every prescription we write is possible because of giants in our profession who fought for the privilege—and it *is* a privilege," he says.

Practitioners need to be ready for any patient that comes into the office. Narcotic analgesics have a definite role in primary eye care and are critical to treating a patient in distress. "Eye pain can mean severe pain, especially related to the cornea," says Dr. Casella. "So, when I get the call at 9pm on a Friday for a large fingernail abrasion, my DEA license is my insurance policy—it ensures I am able to treat



**Pain meds can be vital when needed, as in this instance of trauma.**



### Pain Med Privileges

A number of states have reworded their drug laws following narcotic scheduling changes, allowing ODs to continue to prescribe narcotics and acetaminophen/narcotic combination drugs; other state's laws were already strong enough to withstand challenges. Both are shown at left, depicted in orange.

that patient to the best of my ability and get them through the night and weekend."

If a bandage contact lens alone doesn't alleviate the patient, narcotic analgesics may be indicated. Since these medications work through the central nervous system to elevate one's pain threshold—thus altering the perception of pain—their peak effect occurs around two hours after ingestion, says Dr. Casella. "It's important to educate the patient that a pill will not have the immediate effect that a drop of proparacaine or a bandage contact lens may," he says. Patients need to stay ahead of the pain and not wait to dose.

It's important to remember that a full day of treatment with the maximum recommended dosage of an oral NSAID approaches the analgesic effect of a narcotic. Dr. Casella points out that, of course, most hydrocodone narcotics that ODs prescribe are combined with either acetaminophen or an NSAID. Be alert to any additional over-the-counter analgesics the patient is taking so you can calculate combined dosages. Topical NSAIDs can take the edge off, but typically won't provide enough relief on their own.

### Fixing the Legislation

Several years ago, the FDA moved hydrocodone from schedule III to schedule II. "This change meant that ODs in many states would no longer be able to prescribe common narcotic analgesics," such as an acetaminophen/hydrocodone combination, says Dr. Casella. He explains that there is a push for states to pass so-called "hydrocodone fix" legislation, adding this narcotic back to an ODs prescribing regimen. "We've accomplished this in Georgia, and a number of states have also passed such provisions in recent years."

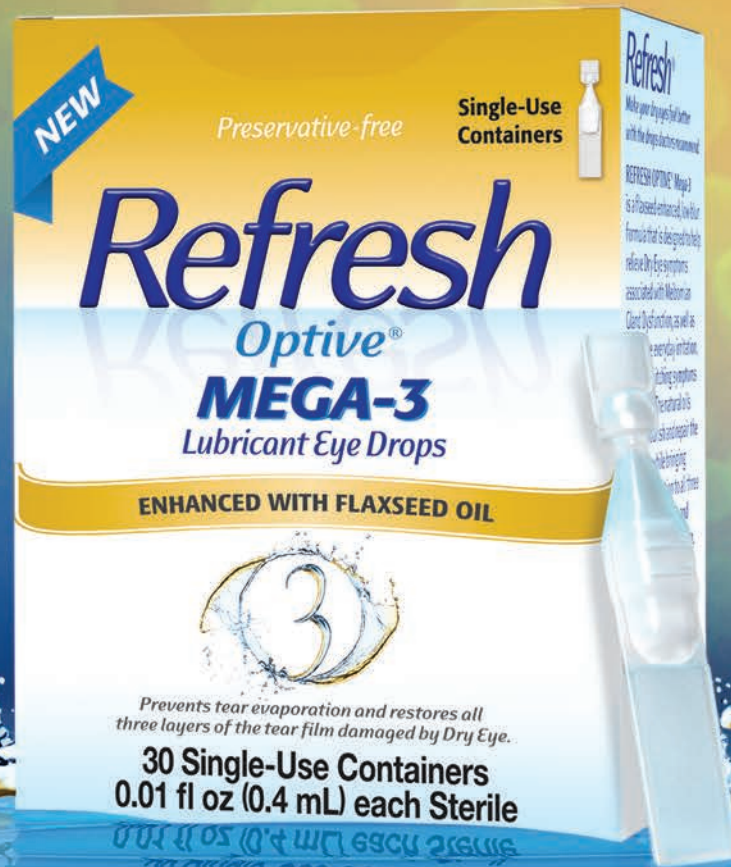Incredibly, privileges can be jeopardized by something as simple as the language in legislation, inadvertently stripping the profession of rights its predecessors fought for and maintain through lobbying efforts.

"The DEA moved ODs to mid-level practitioner status years ago—who's to say that if enough ODs let their DEA licenses lapse, we couldn't continue to lose ground?" asks Dr. Casella. Use your privileges, he advises, because they allow you to care for patients in times of need.

"Hold your nose and pay the fee to renew," says Dr. Ajamian. We've worked too hard not to. ■



MEGA-3 FORTIFIES THE LIPID LAYER  
WHEN MGD PATIENTS SUFFER FROM DRY EYE.



MEGA-3 is formulated with a blend of natural oils, which protects tears from evaporating while nourishing the tear film.

[refreshbrand.com/doc](http://refreshbrand.com/doc)



© 2017 Allergan. All rights reserved. All trademarks are the property of their respective owners. REF107942 05/17



# Hitting a Nerve

Here's what you need to know about the newest technology approved for dry eye disease therapy. **By Paul M. Karpecki, OD**

**N**eurostimulation has been an invaluable addition to the medical field since the 1950s with the invention of the first implantable pacemaker.<sup>1</sup>

Today, it's used in implantable defibrillators and cochlear implants and for treating chronic pain, refractory epilepsy, Parkinson's disease and essential tremor, obsessive-compulsive disorder, obesity, depression and migraine prophylactically.<sup>2</sup> As a means of applying stimulation to regions of the nervous system to alter neurophysiological signals affecting tissues and organs, it has the potential to affect almost any part of the body—and that includes the eyes.<sup>3</sup>

For one, the Argus II retinal implant (Second Sight) provides some hope for patients with retinitis pigmentosa. It is intended to stimulate the intact inner retinal neurons.<sup>4</sup>

The latest neurostimulation device to hit the eye care market, TrueTear (Allergan) for the stimulation of tears in patients with aqueous tear deficient dry eye disease (DED), opens the door to new treatment options for patients looking for relief beyond artificial tears.

## Pathophysiology in Play

Neurostimulation provides patients an alternative option to pharmaceutical agents. Often, it is seen as more natural, as it stimulates the patient's own neurological system



Image: Allergan

**Although an unusual approach, this new neurostimulator may be a big help for patients looking to increase tear production.**

to produce the signals necessary for tissue function. TrueTear, for example, stimulates cranial nerve (CN) V, which is directly responsible for innervation of the lacrimal functional unit (LFU), including the meibomian glands, goblet cells and lacrimal and accessory lacrimal glands.<sup>5</sup> Stimulating a patient's own tear secretion can provide the ocular surface with antibacterial components such as lysozyme, key proteins such as lactoferrin and albumin and anti-inflammatory components.

CN V is the largest cranial nerve with three divisions: the ophthalmic, maxillary and mandibular nerves. The ophthalmic nerve, comprised of the lacrimal, nasociliary and frontal nerves, innervates the LFU.<sup>5,6</sup> In response to any external or internal stimuli, the LFU and central nervous system (CNS) communicate via the

trigeminal nerve using afferent and efferent neurons. Thus, external stimuli trigger sensory nerves on the ocular surface, as the efferent neural system involves CNS-processed signals that travel via parasympathetic and sympathetic fibers from the CNS to the sphenopalatine ganglion. The signals ultimately reach the LFU via branches of the ophthalmic nerve, which then stimulate the secretion of the aqueous glands, goblet cells and meibomian glands.

## The New Game in Town

TrueTear is a handheld device designed to deliver an electrical current to the nasal branch of the trigeminal nerve by two prongs inserted into the nasal passages.<sup>7</sup> The power is adjustable, and patients can alter the frequency or intensity of the stimuli to minimize neuroadaptation. The device is also designed with disposable tips made of soft hydrogel.<sup>7</sup>

One of the biggest advantages to this new technology is it may allow patients to enhance their tear film, quality and function without pharmaceutical intervention.<sup>7</sup> In clinical trials, 93% of patients were satisfied with the treatment and would recommend it to friends and family.<sup>8,9</sup>

## Its Place in DED Care

TrueTear's unconventional approach to DED treatment may slow its adoption in optometric practice. Patient

NOW AVAILABLE




# CHARTING THE NEW COURSE FOR MIGS

## SEE WHAT'S ON THE HORIZON

*CyPass® Micro-Stent* — the next wave  
in micro-invasive glaucoma surgery.  
Get on board today.

LEARN MORE AT [GETCYPASS.COM](http://GETCYPASS.COM)





## CyPass® Micro-Stent

### IMPORTANT PRODUCT INFORMATION

**CAUTION: FEDERAL (USA) LAW RESTRICTS THIS DEVICE TO SALE BY OR ON THE ORDER OF A PHYSICIAN.**

**INDICATION:** The CyPass® Micro-Stent is indicated for use in conjunction with cataract surgery for the reduction of intraocular pressure (IOP) in adult patients with mild to moderate primary open-angle glaucoma (POAG).

**CONTRAINDICATIONS:** Use of the CyPass Micro-Stent is contraindicated in the following circumstances or conditions: (1) in eyes with angle-closure glaucoma; and (2) in eyes with traumatic, malignant, uveitic, or neovascular glaucoma or discernible congenital anomalies of the anterior chamber angle.

**MRI INFORMATION:** The CyPass Micro-Stent is magnetic resonance (MR) Safe: the implant is constructed of polyimide material, a non-conducting, non-metallic, non-magnetic polymer that poses no known hazards in all magnetic resonance imaging environments.

**WARNINGS:** Gonioscopy should be performed prior to surgery to exclude peripheral anterior synechiae (PAS), rubeosis, and other angle abnormalities or conditions that would prohibit adequate visualization of the angle that could lead to improper placement of the stent and pose a hazard.

**PRECAUTIONS:** The surgeon should monitor the patient postoperatively for proper maintenance of intraocular pressure. The safety and effectiveness of the CyPass Micro-Stent has not been established as an alternative to the primary treatment of glaucoma with medications, in patients 21 years or younger, in eyes with significant prior trauma, chronic inflammation, eyes with an abnormal anterior segment, eyes with chronic inflammation, eyes with glaucoma associated with vascular disorders, pseudophakic eyes with glaucoma, eyes with uveitic glaucoma, eyes with pseudoexfoliative or pigmentary glaucoma, eyes with other secondary open-angle glaucomas, eyes that have undergone prior incisional glaucoma surgery or cilioablativ procedures, eyes with laser trabeculoplasty performed  $\leq 3$  months prior to the surgical screening visit, eyes with unmedicated IOP less than 21 mmHg or greater than 33 mmHg, eyes with medicated IOP greater than 25 mmHg, in the setting of complicated cataract surgery with iatrogenic injury to the anterior or posterior segment, and when implantation is without concomitant cataract surgery with IOL implantation for visually significant cataract. The safety and effectiveness of use of more than a single CyPass Micro-Stent has not been established.

**ADVERSE EVENTS:** In a randomized, multicenter clinical trial comparing cataract surgery with the CyPass Micro-Stent to cataract surgery alone, the most common postoperative adverse events included: BCVA loss of 10 or more letters at 3 months after surgery (8.8% for the CyPass Micro-Stent vs. 15.3% for cataract surgery only); anterior chamber cell and flare requiring steroid treatment 30 or more days after surgery (8.6% vs. 3.8%); worsening of visual field mean deviation by 2.5 or more decibels (6.7% vs. 9.9%); IOP increase of 10 or more mmHg 30 or more days after surgery (4.3% vs. 2.3%); and corneal edema 30 or more days after surgery, or severe in nature (3.5% vs. 1.5%).

**ATTENTION: PLEASE REFER TO THE INSTRUCTIONS FOR A COMPLETE LIST OF CONTRAINDICATIONS, WARNINGS, PRECAUTIONS, AND ADVERSE EVENTS.**

**Alcon** A Novartis Division

## Ocular Surface Review

education on properly placing the device for optimal neurostimulation will be key to its success. Clinicians must remember it is an adjunct to current treatment options, and many patients will continue to need treatment for other underlying dry eye issues such as obstruction, inflammation and biofilm control.<sup>10-12</sup>

While adverse events were mild in the current trials, 10.3% of study participants noted nasal pain, discomfort or burning, and other possible mild events included transient electrical discomfort, nosebleed, nasal congestion and headaches.<sup>7</sup> More research will better outline its safety and effectiveness for longer than six months.<sup>7</sup>

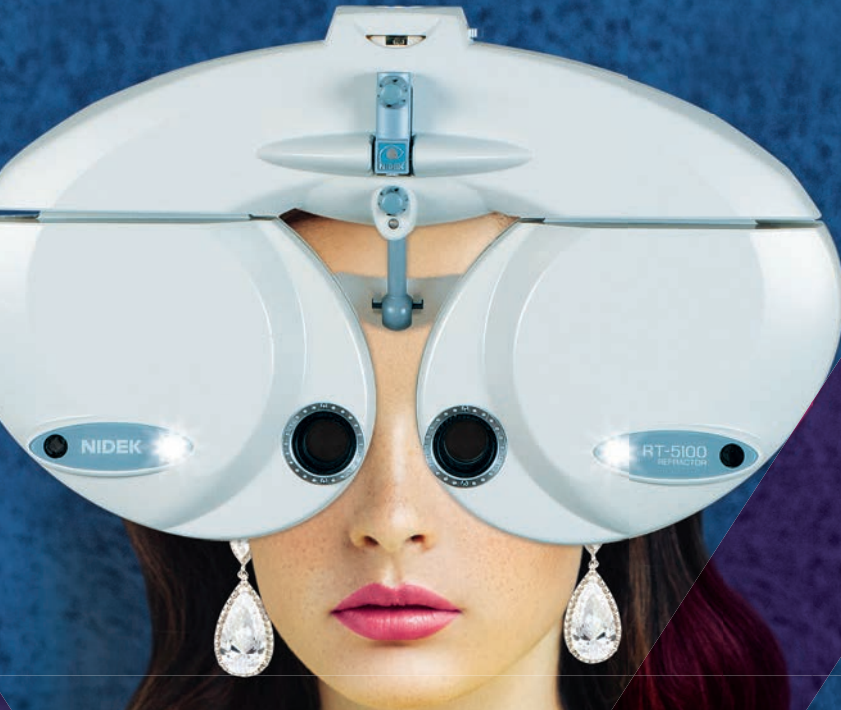Clinicians should not prescribe the device to patients with any implanted electronic device such as a pacemaker or defibrillator, those with chronic or recurrent nosebleeds or patients with bleeding conditions.<sup>7</sup> In addition, patients with a significantly deviated septum or other issues related to anatomical access to the nasal branch of the trigeminal nerve such as reconstructive surgery or previous rhinoplasty are not good candidates.

The company estimates TrueTear's recharging base will cost roughly \$300, and the disposable tips will run about \$25 to \$30 per month.

TrueTear is designed to work in conjunction with our current armamentarium of dry eye products that treat meibomian gland obstruction and inflammation and support biofilm control. It may be a welcome novel treatment approach for patients not wanting to instill artificial tears. ■

*Dr. Karpecki is a consultant for Allergan Pharmaceuticals.*

1. Gardner J, Williams C. Responsible research and innovation: A manifesto for empirical ethics? *Clin Ethics*. 2015;10(1-2):5-12.
2. Danilov YP, Kublanov VS. Emerging noninvasive neurostimulation technologies: CN-NINM and sympatocorection. *J Behav Brain Sci*. 2014;4:105-13.
3. Zhu S, Marmura MJ. Non-invasive neuromodulation for headache disorders. *Curr Neurol Neurosci Rep*. 2016;16(2):11.
4. Second Sight Medical Products. New Enrollment Post-Approval Study of the Argus® II Retinal Prosthesis System. [www.clinicaltrials.gov/ct2/show/NCT00407602](http://www.clinicaltrials.gov/ct2/show/NCT00407602). Accessed May 30, 2017.
5. Kossler AL, Wang J, Feuer W, Tse DT. Neurostimulation of the lacrimal nerve for enhanced tear production. *Ophthalm Plast Reconstr Surg*. 2015;31(2):145-51.
6. Bhavsar AS, Bhavsar SG, Jain SM. A review on recent advances in dry eye: Pathogenesis and management. *Oman J Ophthalmol*. 2011;4(2):50-6.
7. Allergan. Allergan granted marketing authorization by the FDA for TrueTear, the first intranasal neurostimulating device proven to temporarily increase tear production. April 25, 2017. [www.allergan.com/News/News/Thomson-Reuters/Allergan-Granted-Marketing-Authorization-by-the-FDA](http://www.allergan.com/News/News/Thomson-Reuters/Allergan-Granted-Marketing-Authorization-by-the-FDA). Accessed May 31, 2017.
8. Multicenter Trial Evaluating Quality of Tears Produced by Nasal Neurostimulation. April 2017. [www.clinicaltrials.gov/ct2/show/NCT02385292?term=neurostimulation+and+tears&rank=1](http://www.clinicaltrials.gov/ct2/show/NCT02385292?term=neurostimulation+and+tears&rank=1). Accessed May 31, 2017.
9. Six Month Study to Evaluate the Safety and Effectiveness of the Intranasal Lacrimal Neurostimulator. [www.clinicaltrials.gov/ct2/show/NCT02526290?term=neurostimulation+and+tears&rank=3](http://www.clinicaltrials.gov/ct2/show/NCT02526290?term=neurostimulation+and+tears&rank=3). June 2016. Accessed May 31, 2017.
10. Arita R, Morishige N, Koh S, et al. Increased tear fluid production as a compensatory response to meibomian gland loss: a multicenter cross-sectional study. *Ophthalmology*. 2015;122(5):925-33.
11. Hesse M, Akpek EK. Dry eye: an inflammatory ocular disease. *J Ophthalmic Vis Res*. 2014;9(2):240-50.
12. Rynerson JM, Perry HD. DEBS – a unification theory for dry eye and blepharitis. *Clin Ophthalmol*. 2016;10:2455-67.



**EDUCATION.FASHION.INNOVATION.**

**REGISTER TODAY!**

**LAS VEGAS SEPTEMBER 13-16, 2017**

[VisionExpoWest.com](http://VisionExpoWest.com)

BROUGHT TO YOU BY:



PROUD SUPPORTER OF:



PRODUCED BY:





# Decoding MIGS Coding

Clinicians must know how to code for these novel additions when comanaging glaucoma surgical patients. **By John Rumpakis, OD, MBA, Clinical Coding Editor**

**M**inimally invasive glaucoma surgeries (MIGS) are becoming more common in the surgical management of glaucoma. A number of procedures are in development, and several currently FDA-approved, including the iStent (Glaukos), CyPass MicroStent (Alcon), Ex-Press Glaucoma Filtration Device (Alcon), Xen Gel Stent (Allergan) and Trabectome (NeoMedix). Each procedure is unique based on the mechanism of action and method of insertion: *ab interno* and *ab externo* (Table 1).<sup>1</sup>

Just as unique is the coding that accompanies the comanagement of patients undergoing one of these procedures. A clinician's first task is to remember the difference between an HCPCS level I code and a HCPCS level III code.<sup>2,3</sup>

## Level I

CPT level I codes have several requirements, including:<sup>2</sup>

- All devices and drugs necessary for performance of the procedure or service have received FDA clearance or approval when such is required for performance of the procedure or service.
- The procedure or service is performed by many physicians or other qualified health care professionals across the United States.
- The procedure or service is performed with frequency consistent with the intended clinical use (i.e., a service for a common condition should have high volume, whereas a service for a rare condition may

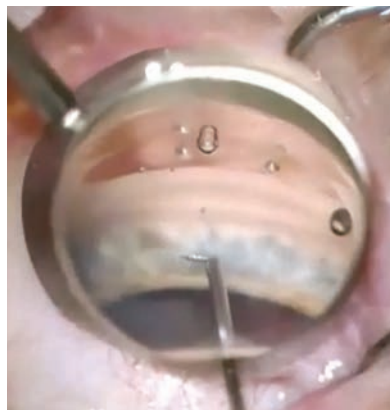

Photo: Constance O. O'Keefe, MD, MSCE

**As MIGS, such as the iStent procedure here, become more popular, ODs need to be familiar with their role in caring for their glaucoma patients and the coding requirements of postoperative visits.**

have low volume).

- The procedure or service is consistent with current medical practice.
- The clinical efficacy of the procedure or service is documented in literature that meets the requirements set forth in the CPT code change application.

## Level III

MIGS that have an associated code use CPT category level III codes, which are a set of temporary codes that allow data collection for emerging technology, services, procedures and service paradigms. These codes are used to substantiate widespread usage or to provide documentation for the FDA approval process.<sup>3</sup>

Level III codes are not developed as a result of a panel review of an incomplete proposal, the need for

more information or a lack of CPT Advisory Committee support of a code change application. Unlike level I codes, CPT level III codes are not referred to the AMA-Specialty RVS Update Committee (RUC) for valuation because no relative value units (RVUs) are assigned to these codes.<sup>3</sup> Payment for these services or procedures is based on the policies of payers and not on a yearly fee schedule.

After three to five years of data collection, a committee then decides if the level III code is worthy of becoming a level I code and including all benefits associated with a level I code.

## Codes in Action

To be used by a comanaging physician, the CPT code itself must have a global period and have a percentage of the overall CPT reimbursement designated for postoperative care. Comanagement as a formal process is allowed with the only CPT procedure listed for some MIGS, 66183 (insertion of anterior segment aqueous drainage device, without extraocular reservoir, external approach).<sup>4</sup> The 2017 CMS National Payment amount is \$1047.23, with a 90-day global period and a 10% comanagement percentage.<sup>4</sup> Comanaging optometrists would be eligible for \$104.72 if they provide postoperative care for the full 90 days.

As an alternative, clinicians can still care for a MIGS patient postoperatively without being formally



# Down, Boy.

Help Tame Postoperative Ocular Inflammation  
and Pain With **LOTEMAX<sup>®</sup> GEL**

## Indication

**LOTEMAX<sup>®</sup> GEL** (loteprednol etabonate ophthalmic gel) 0.5% is indicated for the treatment of post-operative inflammation and pain following ocular surgery.

## Important Safety Information about **LOTEMAX<sup>®</sup> GEL**

- **LOTEMAX<sup>®</sup> GEL** is contraindicated in most viral diseases of the cornea and conjunctiva including epithelial herpes simplex keratitis (dendritic keratitis), vaccinia, and varicella, and also in mycobacterial infection of the eye and fungal diseases of ocular structures.
- Prolonged use of corticosteroids may result in glaucoma with damage to the optic nerve, defects in visual acuity and fields of vision. If this product is used for 10 days or longer, IOP should be monitored.
- Use of corticosteroids may result in posterior subcapsular cataract formation.
- Use of steroids after cataract surgery may delay healing and increase the incidence of bleb formation and occurrence of perforations in those with diseases causing corneal and scleral thinning. The initial prescription and renewal of the medication order should be made by a physician only after examination of the patient with the aid of magnification, and where appropriate, fluorescein staining.
- Prolonged use of corticosteroids may suppress the host response and thus increase the hazard of secondary ocular infection. In acute purulent conditions, steroids may mask infection or enhance existing infection.
- Use of a corticosteroid medication in the treatment of patients with a history of herpes simplex requires great caution. Use of ocular steroids may prolong the course and exacerbate the severity of many viral infections of the eye (including herpes simplex).
- Fungal infections of the cornea are particularly prone to develop coincidentally with long-term local steroid application. Fungus invasion must be considered in any persistent corneal ulceration where a steroid has been used or is in use.
- Patients should not wear contact lenses when using **LOTEMAX<sup>®</sup> GEL**.
- The most common ocular adverse drug reactions reported were anterior chamber inflammation (5%), eye pain (2%) and foreign body sensation (2%).

Please see brief summary of Prescribing Information on adjacent page.

®/™ are trademarks of Bausch & Lomb Incorporated or its affiliates. © 2015 Bausch & Lomb Incorporated. All rights reserved. Printed in USA. US/LGX/15/0041(1)

**BAUSCH + LOMB**

 **LOTEMAX<sup>®</sup> GEL**  
loteprednol etabonate  
ophthalmic gel 0.5%

## BRIEF SUMMARY OF PRESCRIBING INFORMATION

This Brief Summary does not include all the information needed to prescribe Lotemax Gel safely and effectively. See full prescribing information for Lotemax Gel.

## Lotemax (loteprednol etabonate ophthalmic gel) 0.5%

Rx only

Initial Rx Approval: 1998

### INDICATIONS AND USAGE

LOTEMAX is a corticosteroid indicated for the treatment of post-operative inflammation and pain following ocular surgery.

### DOSAGE AND ADMINISTRATION

Invert closed bottle and shake once to fill tip before instilling drops.

Apply one to two drops of LOTE MAX into the conjunctival sac of the affected eye four times daily beginning the day after surgery and continuing throughout the first 2 weeks of the post-operative period.

### CONTRAINDICATIONS

LOTE MAX, as with other ophthalmic corticosteroids, is contraindicated in most viral diseases of the cornea and conjunctiva including epithelial herpes simplex keratitis (dendritic keratitis), vaccinia, and varicella, and also in mycobacterial infection of the eye and fungal diseases of ocular structures.

### WARNINGS AND PRECAUTIONS

#### Intraocular Pressure (IOP) Increase

Prolonged use of corticosteroids may result in glaucoma with damage to the optic nerve, defects in visual acuity and fields of vision. Steroids should be used with caution in the presence of glaucoma. If this product is used for 10 days or longer, intraocular pressure should be monitored.

#### Cataracts

Use of corticosteroids may result in posterior subcapsular cataract formation.

#### Delayed Healing

The use of steroids after cataract surgery may delay healing and increase the incidence of bleb formation. In those diseases causing thinning of the cornea or sclera, perforations have been known to occur with the use of topical steroids. The initial prescription and renewal of the medication order should be made by a physician only after examination of the patient with the aid of magnification such as slit lamp biomicroscopy and, where appropriate, fluorescein staining.

#### Bacterial Infections

Prolonged use of corticosteroids may suppress the host response and thus increase the hazard of secondary ocular infections. In acute purulent conditions of the eye, steroids may mask infection or enhance existing infection.

#### Viral Infections

Employment of a corticosteroid medication in the treatment of patients with a history of herpes simplex requires great caution. Use of ocular steroids may prolong the course and may exacerbate the severity of many viral infections of the eye (including herpes simplex).

#### Fungal Infections

Fungal infections of the cornea are particularly prone to develop coincidentally with long-term local steroid application. Fungus invasion must be considered in any persistent corneal ulceration where a steroid has been used or is in use. Fungal cultures should be taken when appropriate.

#### Contact Lens Wear

Patients should not wear contact lenses during their course of therapy with LOTE MAX.

### ADVERSE REACTIONS

Adverse reactions associated with ophthalmic steroids include elevated intraocular pressure, which may be associated with infrequent optic nerve damage, visual acuity and field defects, posterior subcapsular cataract formation, delayed wound healing and secondary ocular infection from pathogens including herpes simplex, and perforation of the globe where there is thinning of the cornea or sclera.

The most common adverse drug reactions reported were anterior chamber inflammation (5%), eye pain (2%), and foreign body sensation (2%).

### USE IN SPECIFIC POPULATIONS

#### Pregnancy

#### Teratogenic Effects

Loteprednol etabonate has been shown to be embryotoxic (delayed

ossification) and teratogenic (increased incidence of meningocele, abnormal left common carotid artery, and limb flexures) when administered orally to rabbits during organogenesis at a dose of 3 mg/kg/day (35 times the maximum daily clinical dose), a dose which caused no maternal toxicity. The no-observed-effect-level (NOEL) for these effects was 0.5 mg/kg/day (6 times the maximum daily clinical dose). Oral treatment of rats during organogenesis resulted in teratogenicity (absent innominate artery at  $\geq 5$  mg/kg/day doses, and cleft palate and umbilical hernia at  $\geq 50$  mg/kg/day) and embryotoxicity (increased post-implantation losses at 100 mg/kg/day and decreased fetal body weight and skeletal ossification with  $\geq 50$  mg/kg/day). Treatment of rats with 0.5 mg/kg/day (6 times the maximum clinical dose) during organogenesis did not result in any reproductive toxicity. Loteprednol etabonate was maternally toxic (significantly reduced body weight gain during treatment) when administered to pregnant rats during organogenesis at doses of  $\geq 5$  mg/kg/day.

Oral exposure of female rats to 50 mg/kg/day of loteprednol etabonate from the start of the fetal period through the end of lactation, a maternally toxic treatment regimen (significantly decreased body weight gain), gave rise to decreased growth and survival, and retarded development in the offspring during lactation; the NOEL for these effects was 5 mg/kg/day. Loteprednol etabonate had no effect on the duration of gestation or parturition when administered orally to pregnant rats at doses up to 50 mg/kg/day during the fetal period.

There are no adequate and well controlled studies in pregnant women. LOTE MAX should be used during pregnancy only if the potential benefit justifies the potential risk to the fetus.

#### Nursing Mothers

It is not known whether topical ophthalmic administration of corticosteroids could result in sufficient systemic absorption to produce detectable quantities in human milk. Systemic steroids appear in human milk and could suppress growth, interfere with endogenous corticosteroid production, or cause other untoward effects. Caution should be exercised when LOTE MAX is administered to a nursing woman.

#### Pediatric Use

Safety and effectiveness in pediatric patients have not been established.

#### Geriatric Use

No overall differences in safety and effectiveness have been observed between elderly and younger patients.

### NONCLINICAL TOXICOLOGY

#### Carcinogenesis, Mutagenesis, Impairment Of Fertility

Long-term animal studies have not been conducted to evaluate the carcinogenic potential of loteprednol etabonate. Loteprednol etabonate was not genotoxic *in vitro* in the Ames test, the mouse lymphoma tk assay, or in a chromosome aberration test in human lymphocytes, or *in vivo* in the single dose mouse micronucleus assay. Treatment of male and female rats with up to 50 mg/kg/day and 25 mg/kg/day of loteprednol etabonate, respectively, (600 and 300 times the maximum clinical dose, respectively) prior to and during mating did not impair fertility in either gender.

### PATIENT COUNSELING INFORMATION

#### Administration

Invert closed bottle and shake once to fill tip before instilling drops.

#### Risk of Contamination

Patients should be advised not to allow the dropper tip to touch any surface, as this may contaminate the gel.

#### Contact Lens Wear

Patients should be advised not to wear contact lenses when using LOTE MAX.

#### Risk of Secondary Infection

If pain develops, redness, itching or inflammation becomes aggravated, the patient should be advised to consult a physician.

Bausch + Lomb, a division of Valeant Pharmaceuticals North America LLC  
Bridgewater, NJ 08807 USA

US Patent No. 5,800,807

©Bausch & Lomb Incorporated

Lotemax is a registered trademark of Bausch & Lomb Incorporated or its affiliates.

LGX.0114.USA.16

Based on 9269101/9269201

Revised: 08/2016



**Table 1. Current MIGS Procedures**

Brand Name	Procedure	CPT/HCPCS Level III Code
<i>FDA approved</i>		
CyPass Micro-Stent (Alcon) <sup>1,6</sup>	<i>Ab interno</i> with cataract extraction; Placed in the angle between the ciliary body and the sclera and terminates in the suprachoroidal space	0474T
Ex-Press Glaucoma Filtration Device (Alcon) <sup>1,7</sup>	<i>Ab externo</i> with or without cataract extraction; Inserted under a conjunctival flap to shunt aqueous from the anterior chamber towards a subconjunctival reservoir	66183
iStent (Glaukos) <sup>1,8</sup>	<i>Ab interno</i> with cataract extraction; Implanted through the nasal aspect of the trabecular meshwork into Schlemm's canal	0191T
Trabectome (NeoMedix) <sup>1,9</sup>	<i>Ab interno</i> with or without cataract extraction; Ablates 60° to 120° of trabecular meshwork and the inner wall of Schlemm's canal	65850
Xen Gel Stent (Allergan) <sup>1</sup>	<i>Ab interno</i> with or without cataract extraction; Shunts aqueous from the anterior chamber to subconjunctival space	0449T +0450T
<i>In clinical trials</i>		
Hydrus Microstent (Ivantis) <sup>1</sup>	<i>Ab interno</i> with cataract extraction; Implanted in Schlemm's canal to increase outflow	TBD
InnFocus Microshunt (Santen) <sup>1,10</sup>	<i>Ab externo</i> with or without cataract extraction; Inserted through a scleral flap into the anterior chamber to increase flow from anterior chamber to subconjunctival space	66183
iStent Supra Micro-Bypass Stent (Glaukos) <sup>1,8</sup>	<i>Ab interno</i> with or without cataract extraction; Placed in the supraciliary space to increase flow into the uveoscleral space	0253T
iStent inject (Glaukos) <sup>1,8</sup>	<i>Ab interno</i> with or without cataract extraction; Two second-generation iStents are implanted sequentially in adjacent areas of trabecular meshwork	0191T +0376T
Solx Gold Shunt (Solx) <sup>1</sup>	<i>Ab externo</i> with or without cataract extraction; Implanted between the anterior chamber and suprachoroidal space to increase outflow	66183

designated as the comanaging physician (and are thus not bound by the rules or reimbursement of comanaging) by simply billing the patient or the patient's insurance directly for the medically necessary services provided.

### Changes in the Air

But coding for these procedures isn't set in stone. In fact, an update on coverage was recently published in a proposed/draft LCD by National Government Services, a CMS contractor covering Illinois, Minnesota, Wisconsin, Connecticut, New York, Maine, Massachusetts, New Hampshire, Rhode Island and Vermont.<sup>5</sup> National Government Services proposes that one iStent or CyPass device per eye is medically reasonable and necessary for the treatment of mild or moderate open-angle glaucoma when the patient is currently taking an ocular hypoten-

sive medication and the procedure is being performed in conjunction with cataract surgery.<sup>4</sup>

As a draft, this change is not yet in place as a formal policy. Should the policy be adopted as proposed, this rule would be in effect for those jurisdictions.

The role MIGS plays within the glaucoma treatment algorithm continues to shift, and differs from the role of more traditional glaucoma surgeries such as trabeculectomy or external aqueous drainage implants. Currently, all other indications are considered not reasonable and necessary.

As these glaucoma treatment options are evolving rapidly, so are the coding procedures that accompany them. But together, glaucoma surgeons and ODs can work closely to bring new technology and better care to patients who suffer from this chronic condition. ■

*Send questions and comments to [rocodingconnection@gmail.com](mailto:rocodingconnection@gmail.com).*

1. Aetna. Glaucoma surgery. [www.aetna.com/cpb/medical/data/400\\_499/0484.html](http://www.aetna.com/cpb/medical/data/400_499/0484.html). Updated May 30 2017. Accessed June 7, 2017.
2. American Medical Association. CPT process: how a code becomes a code. [www.ama-assn.org/practice-management/cpt/C2%AE-process-how-code-becomes-code#category\\_I\\_CPT\\_code\\_criteria](http://www.ama-assn.org/practice-management/cpt/C2%AE-process-how-code-becomes-code#category_I_CPT_code_criteria). Accessed May 26, 2017.
3. American Medical Association. CPT® category III codes code descriptors. [www.ama-assn.org/sites/default/files/media-browser/public/cpt/cptcat3-desc-january2017.pdf](http://www.ama-assn.org/sites/default/files/media-browser/public/cpt/cptcat3-desc-january2017.pdf). Accessed May 25, 2017.
4. [www.codesatplus.com](http://www.codesatplus.com).
5. Centers for Medicare and Medicaid Services. License for use of physicians' current procedural terminology, fourth edition (CPT). [www.cms.gov/medicare-coverage-database/details/lcd-details.aspx?LCDId=37243&ContrlId=297&ver=19&ContrVer=1&CtrCtrSelected=297](http://www.cms.gov/medicare-coverage-database/details/lcd-details.aspx?LCDId=37243&ContrlId=297&ver=19&ContrVer=1&CtrCtrSelected=297). Accessed May 30, 2017.
6. American Medical Association. CPT Category III Codes Code Descriptors. [www.ama-assn.org/sites/default/files/media-browser/public/cpt/cptcat3-desc-january2017.pdf](http://www.ama-assn.org/sites/default/files/media-browser/public/cpt/cptcat3-desc-january2017.pdf). Accessed June 7, 2017.
7. Alcon Reimbursement Services. [www.myalcon.com/products/surgical/docs/1308A11-ARS-EXP-category-announcement.pdf](http://www.myalcon.com/products/surgical/docs/1308A11-ARS-EXP-category-announcement.pdf). Accessed June 7, 2017.
8. Glaukos. Glaukos announces five-year extensions for three category III CPT codes related to micro-invasive glaucoma surgery. March 16, 2017. <http://investors.glaukos.com/investors/press-releases/press-release-details/2017/Glaukos-announces-five-year-extensions-for-three-category-III-CPT-codes-related-to-micro-invasive-glaucoma-surgery/default.aspx>. Accessed June 7, 2017.
9. Fellman R, Mattox C, Vicchirilli S. Modifiers and glaucoma: take this high-pressure quiz. EyeNet. 2013 June; 53.
10. Santen. InnFocus MicroShunt glaucoma drainage system. <http://innfocusinc.com/index.php/microshunt/innfocus-microshunt>. Accessed June 7, 2017.

# Mastering MIGS: Today and Tomorrow

These procedures have changed the glaucoma treatment landscape—and more are on the way. Here's a primer for ODs. **By Justin Schweitzer, OD**

In recent years, minimally invasive glaucoma surgeries (MIGS) have exploded onto the scene to help fill a gap in the glaucoma treatment algorithm. Traditionally, first-line therapy for primary open-angle glaucoma (POAG) relied on topical glaucoma medications or selective laser trabeculoplasty to lower intraocular pressure (IOP). If those treatment options didn't work, the patient would be referred to a glaucoma surgeon to consider more aggressive filtration surgical procedures such as trabeculectomy or tube shunts, which come with risks such as bleb-related complications, diplopia and hypotony.<sup>1,2</sup>

However, the majority of glaucoma patients in the average practice have neither completely mild nor advanced disease; rather, they lie somewhere in the middle. These



**With Cypass, a cyclodialysis cleft can be seen with gonioscopy around the edges of the device.**

patients are often taking multiple medications, are not ideally controlled and could benefit from a treatment modality more aggressive than topical medication, but less so than filtration surgery. This is where MIGS fit in.

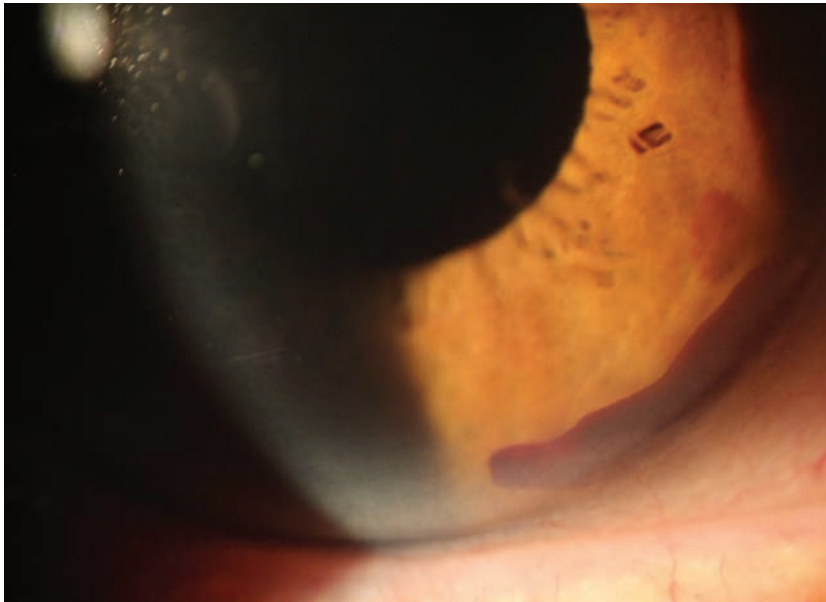
Although MIGS offer mild to moderate glaucoma patients a low risk profile similar to cataract surgery, the question remains as to whether the procedure provides a corresponding low reward. So far, the literature continues to show that MIGS provide low risk for glaucoma patients while also lowering IOP and, arguably just as important, decreasing the medication burden on our glaucoma patients. This article discusses recent data on MIGS and the role

optometry plays in the comanagement of these surgeries.

## What are MIGS?

MIGS share five distinct characteristics:<sup>3</sup>

(1) *ab-interno* approach



**Hyphema is one of a few postoperative complications to consider with MIGS.**

- (2) minimally traumatic, with little disruption of normal anatomy and physiology
- (3) at least modest efficacy
- (4) high safety
- (5) rapid recovery

MIGS can be classified by the anatomical structure they target in an attempt to allow or decrease resistance to aqueous outflow.

**Schlemm's canal.** This is accessed by stenting through the trabecular meshwork and dilating Schlemm's canal or ablating or excising the trabecular meshwork.

**Supraciliary space.** This anatomical structure has an enormous surface area and is very absorptive; therefore, it carries the potential to substantially lower IOP. It is accessed by stenting, and access to this space comes with the added benefit of bypassing outflow obstructions encountered with the trabecular meshwork, specifically episcleral venous resistance.

**Subconjunctival space.** Like the supraciliary space, some MIGS take advantage of the subconjunctival space's bypass of outflow obstructions

involving the trabecular meshwork. Procedures that target this anatomical area are bleb-forming. Therefore, though they are more effective at lowering IOP, they carry a slightly increased risk, and some glaucoma surgeons categorize them as "MIGS plus." The Holy Grail MIGS would produce an IOP-lowering effect similar to traditional trabeculectomy, but with the safety profile of cataract surgery.

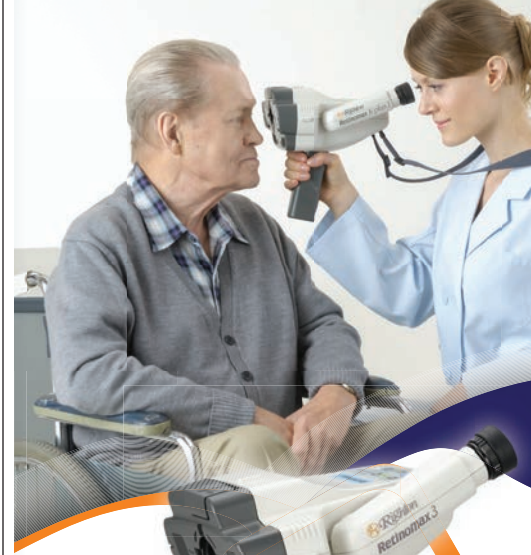
### MIGS in the Literature

Here is a look at the current research on several of the more well-known MIGS, based on their anatomical target:

#### *Trabecular meshwork and Schlemm's canal devices.*

- *Trabectome (Neomedix).*

Although it predates the coining of the term "minimally invasive glaucoma surgery," this device started the MIGS revolution with FDA approval in 2004 for use independently or in conjunction with cataract surgery.<sup>4</sup> The procedure involves ablating 120 to 180 degrees



The Series 3

# RETINOMAX HAND-HELD Autorefractor

Precise measurements  
Anywhere - Anytime



- Accurate
- Fast
- Portable
- Efficient

 **Righton**  
**S4 OPTIK**

250 Cooper Ave., Suite 100 Tonawanda NY 14150  
[www.s4optik.com](http://www.s4optik.com) | 888-224-6012

Sensible equipment. Well made, well priced.

**For today's modern office.**

of the trabecular meshwork and the inner wall of Schlemm's canal to lower resistance to aqueous outflow.<sup>5</sup>

A large study of 5,435 patients receiving Trabectome surgery with up to 90 months of follow-up provides some positive results for this procedure. Researchers found that, after 90 months, IOP dropped from 23.0mm Hg (+/-7.9) to 16.5mm Hg (+/-3.8), while decreasing the number of glaucoma medications needed from 2.6 (+/-1.3) to 1.6 (+/-1.3).<sup>6</sup> They, along with other researchers, found the most common postoperative complication with Trabectome is transient hyphema.<sup>6-8</sup>

- *iStent (Glaukos)*. Approved in 2012 for use in conjunction with cataract surgery, this device is designed to serve as a bypass through the trabecular meshwork to facilitate outflow of aqueous.<sup>7</sup> Studies show the iStent reduces IOP and the need for glaucoma medications more than cataract surgery alone.<sup>9-11</sup> One study revealed key points in the FDA pivotal clinical trial in regards to cataract surgery plus iStent insertion vs. cataract surgery alone.<sup>9</sup> In the study, a 20% reduction in IOP without medication was achieved in 66% of eyes treated with cataract surgery plus an iStent vs. 48% of eyes treated with cataract surgery alone.<sup>9</sup> In addition, twice as many patients in the cataract surgery only group were back on medications at one year compared with patients in the cataract surgery plus iStent group.<sup>9</sup> Research also indicates the iStent is quite safe, showing minimal to essentially no added risk to the cataract procedure.<sup>9,11</sup>

Because of the relatively modest reduction in IOP found during the initial FDA study, questions still remain regarding the extent to which cataract surgery is contributing to the lowered IOP when

an iStent is implanted. Recently, a retrospective study reported two-year results of 42 pseudophakic eyes implanted, off-label, with one iStent. Two years post-procedure, mean IOP dropped from 20.26mm Hg (+/- 6.00) to 13.62mm Hg (+/-4.55), with the need for fewer medications.<sup>12</sup> Three patients experienced an IOP increase of 15mm Hg above baseline IOP, and all of them responded to topical therapy.<sup>12</sup>

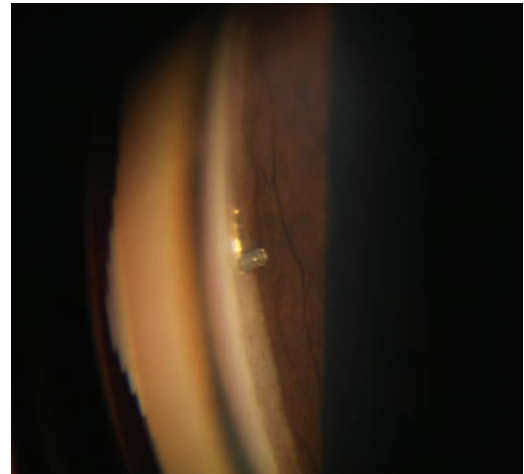
Two other devices, the iStent Inject and iStent Supra are in FDA clinical trials. The iStent Inject resembles a punctal plug, with the end inserted into Schlemm's canal and the head in the anterior chamber. This allows aqueous to flow through the lumen of the device and into Schlemm's canal.

The iStent Supra is a supraciliary device designed to release aqueous through the uveoscleral outflow pathway. The 4mm tube is made of polyethersulfone and titanium and targets the large absorptive capacity of the suprachoroidal space.

- *Ab interno canaloplasty (ABiC) (Ellex)*. This procedure uses an illuminated microcatheter through a corneal incision of 1.8mm to address all aspects of outflow resistance, including the trabecular meshwork, Schlemm's canal and the collector channels. In contrast to traditional canaloplasty, ABiC does not require a tensioning suture to lower IOP.<sup>13</sup>

Recent data on 57 patients with mild to moderate POAG undergoing ABiC alone experienced a 24.4% reduction in mean IOP and a 64.5% reduction in medication use at one year postoperatively.<sup>14</sup>

- *Kabook Dual Blade (New World Medical)*. This is a device that excises or removes the trabecular

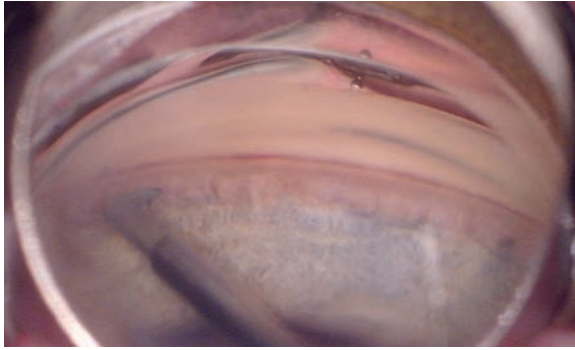


**The iStent acts as a bypass through the trabecular meshwork to facilitate aqueous outflow.**

meshwork and the inner wall of Schlemm's canal to lower resistance to aqueous outflow and enable better IOP control.<sup>15</sup> The dual blade has demonstrated a more complete removal of trabecular meshwork compared with a microvitrectomy blade or Trabectome, leaving behind no residual trabecular meshwork leaflets, which are prone to close.<sup>15</sup> This allows for sustained IOP reduction and control.<sup>15</sup>

A recent study included 120 eyes with mild, moderate and severe glaucoma treated as a standalone procedure, combined with cataract surgery or combined with other procedures.<sup>16</sup> The results show mean IOP fell from 18.7mm Hg (+/-6.7) to 12.9mm Hg (+/-4.2) at nine months post-op.<sup>13</sup> Glaucoma medication use dropped from 1.8 (+/-1.3) to 0.7 (+/-0.8).<sup>13</sup> The most common postoperative complication was transient hyphema.<sup>16</sup>

- *Hydrus Microstent (Ivantis)*. The Hydrus is an 8mm stent with the 1mm inlet segment resting in the anterior chamber, and the 7mm scaffold segment residing in Schlemm's canal.<sup>17</sup> The Hydrus II study shows 80% of patients that had Hydrus implantation plus cataract surgery



**The Kahook Dual Blade removes the trabecular meshwork and the inner wall of Schlemm's canal to enable better IOP control. Here, the retinal architecture is partially obscured, indicative of macular thickening.**

had a 20% reduction in IOP vs. 46% in cataract surgery alone at 24 months. Additionally, 73% of patients in the combined group were medication-free compared to 38% of patients in the cataract alone group. Recently, enrollment was completed in the Hydrus IV pivotal trial, and is expected to close in a few years.

#### *Supraciliary devices.*

- *Cypass Micro-Stent (Alcon).*

This device, approved in 2016 for use in conjunction with cataract surgery, is designed to access the supraciliary space, bypass the conventional outflow pathway and target the uveoscleral outflow path.<sup>18</sup> The increase of aqueous through the uveoscleral outflow path has the potential to lower IOP more than devices that target compromised outflow through the trabecular meshwork, according to research.<sup>18</sup> Once the device is implanted, a small cyclodialysis cleft is typically visible with gonioscopy around the edges of the device.

The Compass clinical trial included 505 eyes, two years of follow-up and patient randomization in a 1:3 ratio to either cataract surgery alone or cataract surgery in conjunction with Cypass implantation.<sup>18</sup> At two years post-op, 60%

of eyes that received cataract surgery alone and 77% of those who received the stent achieved a reduction in non-medicated IOP of at least 20%.<sup>18</sup> IOP decreased by 7.4mm Hg in the stent group vs. 5.4mm Hg in the standalone cataract surgery group.<sup>18</sup> Of the stent group, 61% had a non-medicated IOP between 6mm

Hg and 18mm Hg compared with 44% in the group who received cataract surgery alone.<sup>18</sup>

Postoperative complications included transient hypotony in 2.9% of stent cases, which resolved within the first two weeks, and hyphema, which was observed in 2.7% of eyes that received the stent.<sup>18</sup>

#### *Subconjunctival devices.*

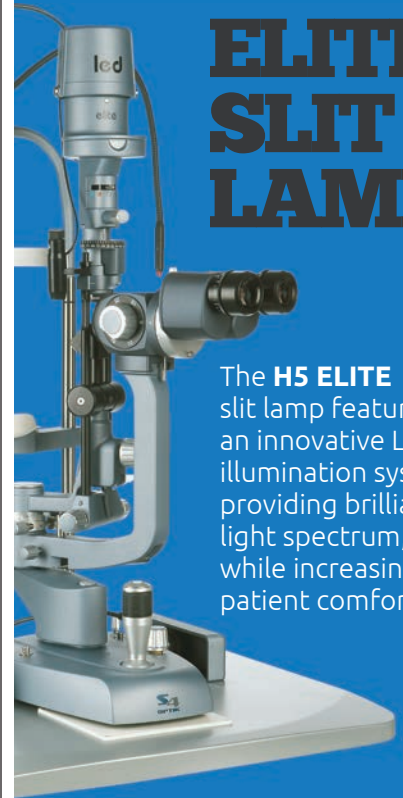
- *Xen gel stent (Allergan).*

Approved in 2016 as a standalone procedure or in conjunction with cataract surgery, this device lowers IOP by creating a drainage pathway that takes an intrascleral course from the anterior chamber to the subconjunctival space.<sup>19</sup> It is designed to expand and conform to the shape of the surrounding tissue after implantation.<sup>19</sup> The device typically will be visualized in the anterior chamber with gonioscopy, with 1mm visible in the anterior chamber and 2mm visible in the subconjunctival space. A bleb will be noted on the first day postoperatively.

One study included 65 eyes of refractory glaucoma patients who experienced a failure of previous filtering or other procedures or whose IOP was unresponsive to maximally tolerated medical therapy.<sup>20</sup> Twelve months after the Xen gel stent

# S4OPTIK

## ELITE SLIT LAMP



The **H5 ELITE** slit lamp features an innovative LED illumination system providing brilliant light spectrum, while increasing patient comfort.

**An extensive power range**, with five magnification settings from 6x to 40x. Standard on all ELITE slit lamps.

## IMAGING

The **S4OPTIK H5 ELITE** slit lamp comes digital ready. Combine with the S4OPTIK all-in-one digital camera to acquire exceptional still and video images.



# S4OPTIK

250 Cooper Ave., Suite 100 Tonawanda NY 14150

[www.s4optik.com](http://www.s4optik.com) | 888-224-6012

Sensible equipment. Well made, well priced.

For today's modern office.

implantation, the mean IOP was 25.1mm Hg (+/-3.7), compared with 15.9mm Hg (+/-5.2) preoperatively. Medication use fell from 3.5 (+/-1.0) to 1.7 (+/-1.5).<sup>16</sup> The main postoperative complications included hypotony in 16 subjects (24.6%) and 21 subjects (32.3%) requiring bleb needling.<sup>20</sup>

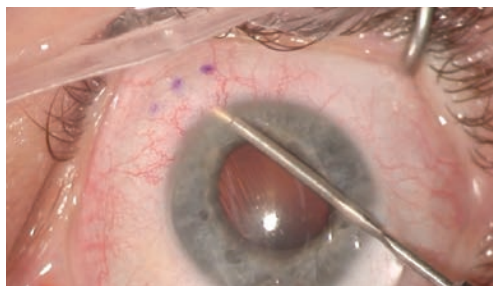## Postoperative Considerations

Collaborative care is common between optometry and ophthalmology in the postoperative management of cataract surgery—and the same will be true with pre- and postoperative management of MIGS. With the exception of a few additional aspects, post-op care following MIGS is essentially the same as following cataract surgery.

**Gonioscopy.** It is imperative to have a thorough understanding of the angle anatomy and be proficient with gonioscopy, not only to visualize the angle preoperatively to check for abnormalities and assess candidacy, but also to evaluate proper placement of MIGS devices postoperatively and identify potential problems.

**Managing complications.** IOP spikes, similar to those after cataract surgery, are a particular concern because glaucoma patients already suffer from a condition that has compromised the health of the optic nerve head. The severity of both the disease and the IOP spike will dictate the level of treatment.

Most of the time, these patients can be managed by adding one or two topical glaucoma medications. Aggressive tapering of postoperative steroid should be considered as well. In some cases, if the IOP spike is aggressive and early in the postoperative period, such as day one, clinicians can consider anterior decompression.



**The Xen gel stent creates a drainage pathway from the anterior chamber to the subconjunctival space to lower IOP.**

Anterior decompression is an effective way to decrease IOP rapidly, but does come with risks, namely endophthalmitis and decompression retinopathy.<sup>21,22</sup> It should be reserved for patients presenting with emergent IOP spikes and at risk for optic nerve head damage. The patient should be placed on a topical glaucoma medication after anterior decompression and their IOP monitored for two to seven days.

With any patient experiencing IOP spikes, clinicians should establish a follow-up plan dictated by the severity of the disease and the spike.

The angle of the eye has an abundant vasculature, and it is not uncommon for a patient to experience a mild, transient hyphema in the early postoperative period. Patients with hyphema will typically present within the first few weeks with a complaint of cloudy vision. On examination of the anterior segment, the practitioner will see what appears to be an aggressive anterior chamber reaction, which in actuality is the presence of red blood cells in the anterior chamber. A small amount of blood also may be noted in the angle anatomy.

The key factor in managing a hyphema after MIGS is patient education. No intervention is needed in most cases, and practitioners should educate the patient that the cloudy vision will decrease and resolve over

the next week. In the case of a large hyphema, the patient may need to be referred back to the surgeon to have an anterior chamber washout.

Placing stents in the angle of the eye puts the stent in close proximity to the iris. Although uncommon, a tuft of iris can occasionally obstruct the lumen of a stent. If the stent is obstructed on gonioscopy and IOP is elevated, clinicians

should refer the patient back to the surgeon to remove the obstruction.

The rate of hypotony is low with most MIGS, as many of them do not bypass episcleral venous pressure, which means IOP won't decrease below 10mm Hg. The exceptions are devices acting via the supraciliary and subconjunctival spaces.

In two FDA clinical trials involving supraciliary and subconjunctival devices, hypotony was defined as an IOP less than 6mm Hg at any time during the study. In one study involving a supraciliary device, the rate of hypotony was minimal at 2.9%.<sup>18</sup> Research involving a subconjunctival device found 16 out of 57 eyes (24.6%) had hypotony.<sup>20</sup> Out of the 16 eyes that suffered hypotony, only two needed intervention; the other eyes resolved on their own.<sup>20</sup>

Optometrists managing these devices need to observe the anterior chamber to make sure it is deep and there is no iridocorneal touch. A fundus exam will rule out choroidal effusion. If the anterior chamber is formed and no choroidal folds exist, the optometrist can monitor the patient without a referral back to the surgeon. If the anterior chamber is flat or shallow, or if iridocorneal touch or choroidal folds exist, they must refer the patient to the surgeon for an anterior chamber reformation. Finally, in the setting of

hypotony, it is important for patients to discontinue use of their topical glaucoma medications.

**New baselines.** Clinicians must establish a new baseline IOP once IOPs have stabilized following MIGS. This postsurgical IOP will become the new baseline used to monitor the patient and make decisions about the need for future treatment. Clinicians should also obtain new visual fields and retinal nerve fiber layer analysis after MIGS to better monitor the patient for progression.

The number of patients diagnosed with glaucoma worldwide is expected to exceed 70 million by 2020, meaning optometrists will be managing more and more of these patients.<sup>23</sup> MIGS are an important addition to the glaucoma treatment armamentarium, filling the gap between topical treatment and more invasive, traditional filtration surgeries. They can be helpful for some patients, and optometrists must be comfortable with their postoperative and long-term management. MIGS procedures open up new possibilities for the patient to be managed prior to (and possibly supplant) tubes and trabs, and the treatment landscape will continue to evolve as other devices become available. It is an exciting opportunity for optometry to be involved in the management of glaucoma. ■

*Dr. Schweitzer practices at Vance Thompson Vision in Sioux Falls, SD, and is an adjunct clinical professor at the Illinois College of Optometry.*

*Financial Disclosures: Dr. Schweitzer receives consultation or lecture fees from the following companies: Allergan, Bausch + Lomb, Glaukos, Biotissue, Alcon, Tear Science and Reichert.*

- DeBry PW, Perkins TW, Heatley G, et al. Incidence of late onset bleb-related complications following trabeculectomy with mitomycin. *Arch Ophthalmol.* 2002;120:297-300.
- Edmunds B, Thompson JR, Salmon JF, Wormald RP. The National Survey of Trabeculectomy III. Early and late complications. *Eye (Lond).* 2002;16:297-303.
- Saheb H, Ahmed, IK. Micro-invasive glaucoma surgery: current perspectives and future directions. *Curr Opin Ophthalmol.* 2012;23(2):96-104.
- Administration FDA. FDA 510 (k) Database Entry Neomedix NMX-1000 (Trabectome). 2012. [www.accessdata.fda.gov/scripts/cdrh/cfdocs/cfPMN/pmn.cfm?ID=K040584](http://www.accessdata.fda.gov/scripts/cdrh/cfdocs/cfPMN/pmn.cfm?ID=K040584). Accessed June 28, 2017.
- Minckler DS, Baerveldt G, Alfaro MR, Francis BA. Clinical results with the Trabectome for treatment of open-angle glaucoma. *Ophthalmology.* 2005;112:962-7.
- Mosaed S. The first decade of global Trabectome outcomes. *Eur Ophthalmic Rev.* 2014;8(2):113-19.
- Kaplowitz K, Bussell II, Honkanen R, et al. Review and meta-analysis of ab-interno trabeculectomy outcomes. *Br J Ophthalmol.* 2016;100(5):594-600.
- Maeda M, Watanabe M, Ichikawa K. Evaluation of Trabectome in open-angle glaucoma. *J Glaucoma.* 2013;22(3):205-8.
- Samuelson TW, Katz L, Wells J, et al. Randomized evaluation of the trabecular micro-bypass stent with phaco-emulsification in patients with glaucoma and cataract. *Ophthalmology.* 2011;118(3):459-67.
- Fea AM. Phacoemulsification versus phacoemulsification with micro-bypass stent implantation in primary open-angle glaucoma: randomized double-masked clinical trial. *J Cataract Refract Surg.* 2010;36(3):407-12.
- Craven ER, Katz LJ, Wells JM, Giamporcaro JE. Cataract surgery with trabecular micro-bypass stent implantation in patients with mild-to-moderate open-angle glaucoma and cataract: two-year follow-up. *J Cataract Refract Surg.* 2012;38:1339-45.
- Ferguson TJ, Berdahl JP, Schweitzer JA, Sudhagani R. Evaluation of a trabecular micro-bypass stent in pseudo-phakic patients with open-angle glaucoma. *J Glaucoma.* 2016;25(11):896-900.
- Lewis RA, von Wolff K, Tetz M, et al. Canaloplasty: three-year results of circumferential viscodilatation and tensioning of Schlemm's canal using a microcatheter to treat open-angle glaucoma. *J Cataract Refract Surg.* 2011;37:682-690.
- Khaimi M. Twelve-month follow-up of ab interno canaloplasty as a standalone treatment and in adjunct to cataract surgery for the treatment of primary open-angle glaucoma. Poster presented at the 27th Annual AGS Meeting, March 9, 2017; Coronado, CA.
- Selbold LK, Soohoo JR, Ammar DA, Kahook MY. Preclinical investigation of ab interno trabeculectomy using a novel dual-blade device. *Am J Ophthalmol.* 2013;155(3):524-9.
- Greenwood MD, Abdullah S, Radcliffe NM, et al. A novel dual blade device for goniotomy: 9 month follow up. Poster present at ASCRS/ASOA Congress & Symposium, May 5-9, 2017; Los Angeles.
- Pfeiffer N, Garcia-Feijoo J, Martinez-de-la-Casa JM, et al. A randomized trial of a Schlemm's canal microstent with phacoemulsification for reducing intraocular pressure in open-angle glaucoma. *Ophthalmology.* 2015;122(7):1283-93.
- Vold S, Ahmed, II, Craven ER, et al. Two-year COMPASS trial results: supraciliary microstenting with phacoemulsification in patients with open-angle glaucoma and cataracts. *Ophthalmology.* 2016;123:2103-12.
- Lewis RA. Ab interno approach to the subconjunctival space using a collagen glaucoma stent. *J Cataract Refract Surg.* 2014;40(8):1301-6.
- Allergan. Xen Gel Stent: Established Effectiveness. [www.xengelstent.com/clinical-efficacy](http://www.xengelstent.com/clinical-efficacy). Accessed June 28, 2017.
- Lee S, Lee J, Kim S. Multiple retinal hemorrhage following anterior chamber paracentesis in uveitic glaucoma. *Korean J Ophthalmol.* 2006;20:128-30.
- Rao S, Greenberg P, Macintyre R, Ducharme J. Ocular decompression retinopathy after anterior chamber paracentesis for uveitic glaucoma. *Retina.* 2009;29:280-1.
- Tham YC, Li X, Wong TY, et al. Global prevalence of glaucoma and projections of glaucoma burden through 2040: a systematic review and meta-analysis. *Ophthalmology.* 2014;121(11):2081-90.

# S4OPTIK FULL POWERED

## EXAMINATION CHAIR

2500-CH



**Powerful, precise,  
automated.**

**Choose the S4OPTIK 2500-CH  
Examination Chair for convenient,  
motorized reclining.**

- KleanTech Lift System®
- Weight bearing armrests
- Robust footrest
- Precision engineered

**S4OPTIK**

250 Cooper Ave., Suite 100 Tonawanda NY 14150

[www.s4optik.com](http://www.s4optik.com) | 888-224-6012

Sensible equipment. Well made, well priced.

For today's modern office.

## 23rd Annual Glaucoma Report

# Glaucoma Surgery: Are You Ready to Refer?

Surgery is inevitable for many patients with glaucoma. These tips can help you refer when the time is right—and comanage after the fact.

By Rick Trevino, OD, Carolyn Majcher, OD, and William Sponsel, MD

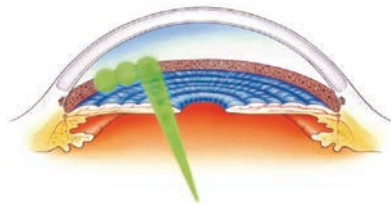
**W**hile optometrists can serve the needs of most patients with glaucoma, many will eventually require a referral to a glaucoma specialist. The most frequent reasons for a consultation are for surgical care, diagnostic dilemmas and complex or unusual cases.

The timing of surgical consults, however, can be tricky, as the need may arise early or late in the course of open-angle glaucoma (OAG), depending on the case. In addition, optometrists should be prepared for patients susceptible to angle closure.

Here, we discuss the available surgical options for glaucoma, when optometrists should consider a referral and post-op care.

## Mild to Moderate OAG

Laser trabeculoplasty, which includes argon laser trabeculoplasty and selective laser trabeculoplasty (SLT), is a common treatment option for patients with mild to moderate OAG. SLT involves the application of a low energy, Q-switched, frequency-doubled Nd:YAG laser (532nm) to the trabecular meshwork (TM).<sup>1</sup> Researchers speculate the laser energy “selectively” targets pigmented TM cells with minimal



**For SLT, large spots of a low-energy laser are applied to the trabecular meshwork.**

collateral thermal damage.<sup>2,3</sup> Studies also indicate the mechanism of action of SLT is low-level inflammation that recruits macrophages to clear debris from and increase aqueous outflow through the TM.<sup>2,3</sup>

Success, defined as no less than a 20% decrease in intraocular pressure (IOP) following primary SLT, is achieved in approximately 70% of eyes at six months and 60% to 95% at 12 months.<sup>4-10</sup> The benefits of SLT are known to wane with time such that about half of eyes will lose the IOP-lowering effect by two years.<sup>4-10</sup> SLT may also blunt diurnal IOP fluctuation, especially at night.<sup>2,11</sup> Because SLT does not physically alter the TM, it theoretically can be repeated as necessary.

**When to refer.** SLT is indicated for the treatment of mild to moderate OAG. Its excellent safety profile,

ability to lower IOP by 20% to 30% in most patients and repeatability make it a good choice as first-line therapy for many patients.<sup>4,6,7,12-15</sup> SLT may be employed as an adjunct therapy in eyes with uncontrolled or progressive glaucoma already being treated with topical medical therapy or as replacement therapy to reduce the number of medications or improve compliance.

Nearly any form of OAG with an intact and gonioscopically visible TM is amenable to SLT. This includes primary OAG (POAG), ocular hypertension, secondary OAGs such as pigment dispersion and pseudoexfoliation, normal tension glaucoma and steroid-induced glaucoma.<sup>1,2,4</sup> Contraindications include angle-recession, congenital/developmental and neovascular glaucomas. Inflammatory glaucomas are also contraindicated due to risk of post-op inflammation.<sup>1,2,4</sup>

Pretreatment IOP is generally considered the best predictor of SLT success, with greater baseline IOPs resulting in greater post-SLT IOP reductions.<sup>4,16</sup> Studies have also correlated the density of angle pigment with SLT efficacy, although patients with even modest TM pigment often achieve significant reduction.<sup>4,17</sup>



Therefore, ideal SLT candidates have IOPs in the upper twenties and at least moderate TM pigment.

**Postoperative care.** For most eyes, a substantial IOP response appears at least six weeks following SLT.<sup>18</sup> Thus, patients should continue their glaucoma medications postoperatively until a response is seen.

Most clinicians do not prescribe topical anti-inflammatory medications following SLT because allowing postoperative inflammation to run its course naturally may enhance the effectiveness of the procedure.


SLT is generally safe with a low risk profile, but complications can occur. Perhaps the greatest risk is simply that the procedure will fail. An IOP spike, occurring in approximately 4% to 5% of eyes, is often transient and rarely requires surgical intervention.<sup>19</sup> Mild iritis is common within the first few days following SLT and may affect up to 83% of eyes, but is often self-limiting and can be observed.<sup>19</sup> In symptomatic patients, clinicians can consider topical NSAIDs or steroids to alleviate any discomfort. Other, less frequent complications include hyphema, macular edema, corneal haze, refractive error shift, peripheral anterior synechiae and choroidal effusion.<sup>19</sup>

## MIGS

A variety of minimally invasive glaucoma surgeries (MIGS) are now available for patients with mild to moderate glaucoma. These procedures share many of the benefits of SLT, but also have one important disadvantage—the surgeon must enter the globe, creating additional risks such as infection and hemorrhage. To minimize this additional risk, most MIGS are performed at the time of cataract extraction.

**When to refer.** While cataract surgery alone often improves IOP control, adding a MIGS procedure can further lower postoperative IOP and decrease dependence on topical medications. The specific clinical indications and patient selection criteria vary among procedures, but most patients with mild to moderate POAG in need of cataract surgery are candidates for MIGS.

For instance, the iStent (Glaukos) device is placed into Schlemm's canal during cataract surgery to enable aqueous to bypass the high resistance of the TM and flow directly into the canal.<sup>20</sup> A more recent MIGS innovation is the *ab interno* canaloplasty (ABiC), which restores the natural outflow pathways without the formation of a bleb.<sup>20</sup> Preliminary reports indicate it can lower IOP by approximately 30%.<sup>21</sup> ABiC is one of the few MIGS procedures approved for use outside cataract surgery in the United States.



# Corneal Hysteresis: His sight depends on your confidence.

## Ocular Response Analyzer® G3

Add clarity to your glaucoma decision making.  
Corneal Hysteresis: CPT code 92145

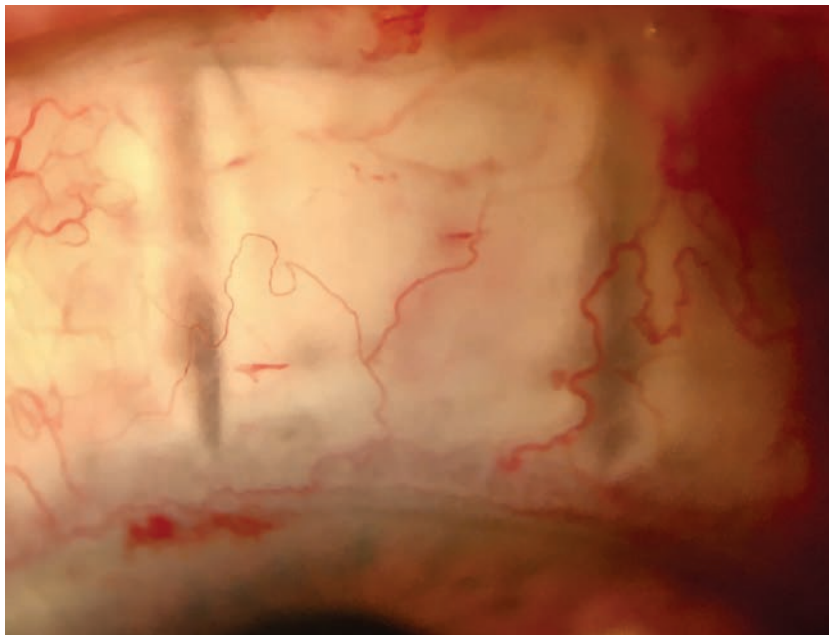
Watch the videos at [reichert.com/glaucomaconfidence](http://reichert.com/glaucomaconfidence)

**Reichert**  
TECHNOLOGIES

**AMETEK** © 2017 AMETEK, Inc. & Reichert, Inc. (5-2017) - Made in USA

Ocular Response Analyzer is a registered trademark of Reichert, Inc. · [www.reichert.com](http://www.reichert.com)





**Variations of trabeculectomy, such as non-penetrating deep sclerectomy, seen here early post-op, further improve surgical outcomes for patients with advanced disease.<sup>38</sup>**

Endocyclophotocoagulation (ECP) is a cyclodestructive procedure that is delivered internally using a diode laser and an endoscope that allows direct visualization of the ciliary processes—creating minimal collateral damage.<sup>22</sup> Ablation of the ciliary processes results in decreased aqueous production and reduced IOP. Investigators found that, when performed on patients with mild to moderate OAG, ECP in conjunction with phacoemulsification decreased IOP by at least 20% in about 60% of eyes.<sup>23</sup> Phacoemulsification alone in patients with POAG lowers IOP by only 13%.<sup>24</sup>

**Postoperative care.** Because MIGS is typically performed in conjunction with cataract extraction, the postoperative care process is essentially the same as that following conventional cataract surgery.

The addition of MIGS may increase the risk of certain complications such as hyphema. However, the less invasive nature of MIGS tends to produce fewer postoperative com-

plications compared with traditional glaucoma surgery.

A key element of the care process for MIGS is re-evaluating the patient's glaucoma medications. Most patients require fewer medications to control their IOP following MIGS. Some clinicians choose to stop all glaucoma medications one month prior to surgery and then restart them as needed afterward. This strategy aims to minimize the risk of postoperative hypotony. Others will defer adjusting medications until after surgery, based upon the observed IOP lowering effect of the procedure.

## Advanced Glaucoma

Trabeculectomy is the most frequently performed surgical procedure for late-stage glaucoma. It creates an alternative outflow pathway for aqueous and results in the formation of a filtering bleb under the conjunctiva where the aqueous accumulates and is gradually absorbed by the tissue.<sup>25</sup> A successful

trabeculectomy often results in IOPs in the high single digits to low mid-teens without use of medication.<sup>25</sup>

**When to refer.** Clinicians must weigh many variables before referring a patient for trabeculectomy, including severity of disease, target IOP, rate of progression and life expectancy. In general, incisional surgery is indicated when medical and laser therapy has failed to adequately control IOP.<sup>25</sup>

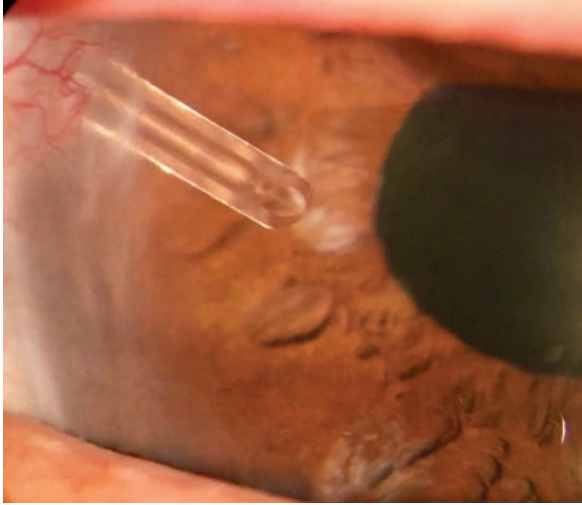
Careful assessment of the rate of progression is key to identifying patients who may benefit from referral for trabeculectomy.

Although central fixation is often spared until late in the course of the disease, patients whose central visual field (VF) becomes involved early, possibly influencing the risk of decreased visual acuity and blindness, may benefit from early referral for surgery.<sup>26,27</sup>

With improvements in surgical outcomes, clinicians can consider a patient a candidate for trabeculectomy after failing to adequately control IOP with two to three drugs.<sup>28</sup>

Some particularly aggressive forms of glaucoma are difficult, or even impossible, to manage successfully without surgery, increasing the importance of prompt referral. Examples include patients with neovascularization or synechial closure of the chamber angle, iridocorneal endothelial syndrome and most lens-associated glaucomas.

**Postoperative care.** The long-term success of filtering surgery depends on appropriate postoperative care. In the immediate postoperative period, steroids are tapered over eight to 12 weeks, or longer as needed, to control inflammation. Cycloplegics are prescribed for two to three weeks after surgery to maintain anterior chamber depth and prevent synechia. Broad-spectrum antibiotics are used for the first two weeks after



**When a glaucoma drainage device is positioned in the anterior chamber, aqueous drains through the tube to a reservoir on the ocular surface.**

surgery to prevent infection.

Following filtration surgery, IOP should ideally be in the 7mm Hg to 12mm Hg range.<sup>25</sup> The bleb should appear noninflamed, slightly elevated and diffuse with indistinct margins. The bleb walls should be thin and appear microcystic.

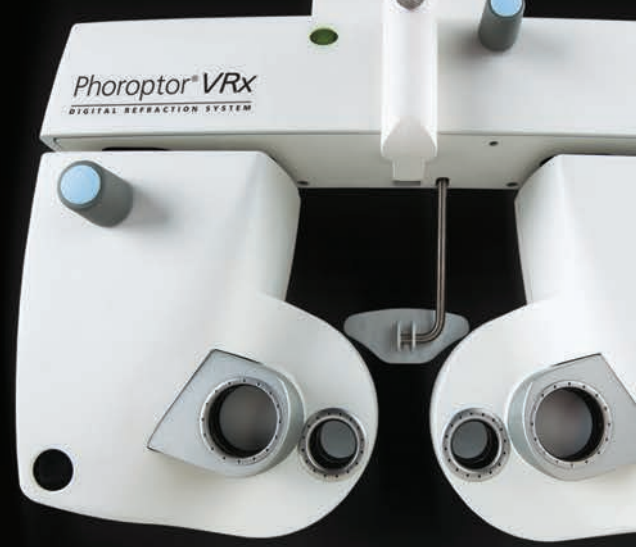Elevated IOP in the early postoperative period may be due to tight suturing of the scleral flap. Tight sutures are often used to avoid postoperative hypotony, with the expectation that they will be cut postoperatively. Suture lysis can be done as early as one week after surgery and as far out as 18 weeks.<sup>20</sup>

Early postoperative complications include wound leaks, choroidal detachment and bleb infection or failure.<sup>20</sup> If a patient has a shallow or flat anterior chamber without a wound leak, clinicians should suspect a choroidal effusion.

### Other Procedures for Advanced Glaucoma

Implantation of a glaucoma drainage device and trans-scleral cyclodestructive procedures are also options for advanced glaucoma management. Glaucoma drainage devices, or tube shunts, are often employed in patients with a severely damaged TM, as may occur in neovascular glaucoma or severe uveitis.

Trans-scleral cyclodestructive procedures use a Nd:YAG or diode laser to damage the ciliary body of eyes with refractory glaucoma, impairing the ability to produce aqueous humor. They are generally a last resort in eyes with unsuccessful filtering surgery, eyes



# The most advanced Phoroptor® ever built.

**Phoroptor® VRx Digital Refraction System**

Incredibly fast. Ultra-quiet. Effortless integration.

Made in the USA with premium components.

Watch the video at [reichert.com/vrx](http://reichert.com/vrx)

**Reichert®**  
TECHNOLOGIES

**AMETEK®** © 2017 AMETEK, Inc. & Reichert, Inc. (5-2017) · Made in USA

Phoroptor is a registered trademark of Reichert, Inc. · [www.reichert.com](http://www.reichert.com)

# Comanagement

with limited vision potential or eyes that are not candidates for other glaucoma procedures.<sup>20</sup>

## Angle-closure Glaucoma

Pupil block is responsible for approximately 90% of all cases of angle-closure glaucoma (ACG).<sup>29</sup>

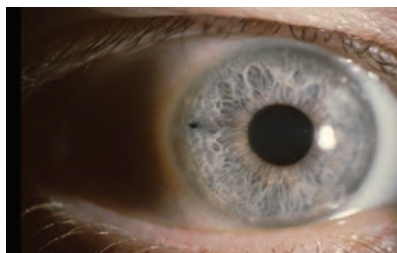In these cases, a laser peripheral iridotomy (LPI) uses an argon or Nd:YAG laser to create a full-thickness hole in the iris to permit aqueous to flow into the anterior chamber without having to pass through the pupil.

**When to refer.** An LPI should be performed whenever evidence of previous or current angle closure exists.<sup>30</sup> Ideally, it is performed prior to the development of acute or chronic IOP elevation and VF loss.

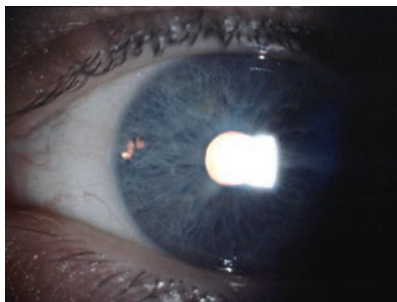
Ancillary anterior chamber imaging can be useful for identifying and quantifying anatomical characteristics that predispose a patient to ACG such as a shallow peripheral or anterior chamber depth, convex iris configuration, reduced anterior chamber volume (typically less than 100mm<sup>3</sup>), a thicker and anteriorly displaced lens and small corneal diameter.<sup>31</sup> These imaging techniques are also useful for assessing the efficacy and patency of an LPI post-surgery.<sup>32</sup>

Clinicians should perform indentation gonioscopy not only to differentiate appositional closure from synechial closure, but also to gauge the flexibility of the iris. If only minimal pressure is needed to push the iris posteriorly into a concave position, the iris will likely conform to only mild increases in posterior chamber pressure, resulting in iris bombé. An angle that deepens with indentation in which minimal peripheral anterior synechiae (PAS) are present can be expected to do well with LPI.

Clinicians should make every attempt to document some degree



**A temporal placement of LPI, above, may decrease the risk of postoperative dysphotopsia. Transillumination, below, is not the best way to test patency. Instead, clinicians should use direct visualization through the iridotomy.**



of functional or structural damage prior to referring a patient for LPI.<sup>30</sup> More sensitive tests such as pattern electroretinography and frequency-doubling VF testing may reveal early damage when conventional OCT and white-on-white VF testing are normal. If any of these tests show signs of early damage in an eye identified as shallow or occludable with gonioscopy, clinicians should strongly consider an LPI.

An LPI may also be performed to prevent ACG in asymptomatic eyes deemed potentially occludable and at substantial risk.<sup>30</sup> Although a lack of literature makes it difficult to predict which eyes will go on to develop ACG, most eyes at risk are initially identified with routine Van Herick angle screening. Gonioscopy should be performed on all eyes with a peripheral anterior chamber depth that is  $\frac{1}{4}$  of the peripheral corneal thickness or less (Van Herick grades one and two).<sup>29</sup> An eye is considered

occludable if the posterior TM is obscured without indentation in two or more quadrants. Such eyes should then undergo a thorough evaluation for structural or functional glaucomatous damage and a pointed history to uncover ACG symptoms. Even in the absence of glaucomatous damage or symptoms, an LPI may be appropriate when multiple ACG risk factors exist or if the patient has limited access to medical care.<sup>30</sup> If there is doubt a patient is capable of recognizing the symptoms of acute angle closure and promptly returning to the clinic, clinicians should discuss a prophylactic LPI.

**Postoperative care.** Patients will normally be prescribed a topical steroid to manage inflammation following LPI surgery. In addition, some patients will be on an IOP-lowering drop. The post-op medications can usually be discontinued at the one-week post-op visit. Some patients will suffer chronic elevation of IOP despite an open anterior chamber angle following resolution of their angle closure and may require long-term treatment.

Complications of LPI are usually mild and transient, including hyphema, anterior uveitis and IOP spike.<sup>20</sup> Rare complications include retinal detachment and cataract, and up to 4% of patients may suffer visual disturbances related to light transmission through the iridotomy.<sup>33</sup> Iridotomies partially exposed at the upper eyelid margin are most frequently associated with vision disturbance; thus, temporally located LPIs may carry a lower risk of dysphotopsia.<sup>34</sup>

The patency of the iridotomy should be assessed at each postoperative visit using direct visualization of the lens capsule, zonules or posterior chamber through the iridotomy using the biomicroscope.<sup>30</sup> The iridotomy may become occluded

All-new!

by inflammatory debris or clumps of iris tissue in the immediate postoperative period. Because the lens used to create the iridotomy generally offers the best view through it, the surgeon may have to assess patency for difficult cases.

If pupil block was present prior to undergoing LPI, a substantial deepening of the anterior chamber angle is expected following the procedure. The central anterior chamber depth will not change following LPI because the position of the lens is not affected by the procedure. Rather, the chamber volume or angle depth will reflect the deepening that occurs postoperatively.<sup>35</sup> Postoperative deepening of the angle will confirm patency of the LPI and that the patient had primary pupil block preoperatively. Shallow anterior chamber angles in the presence of a patent iridotomy may be caused by plateau iris syndrome (PIS), PAS, space-occupying lesions in the posterior chamber or other conditions that produce anterior displacement of the lens-iris diaphragm.<sup>30</sup>

### Other Procedures for ACG

Removal of a cataractous lens will improve the patient's vision and resolve the pupil block.<sup>30</sup> While lens extraction is always curative for pupil block, LPI, as a less-invasive procedure, is the preferred treatment for eyes without cataract. However, a recent study suggests lens extraction could be considered a first-line treatment for ACG even in patients without cataract.<sup>36</sup>

For patients with ACG without pupil block, LPI is of no benefit. Treatment must be directed toward the cause of the angle closure, such as PIS. PIS is diagnosed when the angle remains predisposed to closure after LPI has been performed. Argon laser peripheral iridoplasty is an effective treatment whereby laser burns placed in the peripheral iris will cause contraction of the iris root and pull the iris out of the angle.<sup>37</sup>

Many interventions for patients with OAG and ACG can significantly impact long-term outcomes. The trick is knowing when to follow, when to refer and how to care for patients post-procedure. The savvy OD can handle almost any patient with glaucoma, if they incorporate these tips into their glaucoma practice and properly comanage with the surgeon. ■

*Dr. Trevino is an associate professor and director of Residency Programs at the Rosenberg School of Optometry.*

*Dr. Majcher is an assistant clinical professor at the Rosenberg School of Optometry.*

*Dr. Sponsel is a professor of Vision Science at the Rosenberg School of Optometry.*



## Pixel-perfect acuity testing.

**ClearChart® 4 · 4X · 4P Digital Acuity Systems**  
Simple-to-use interface. 24-inch, LED backlit display.  
Custom developed for acuity testing. Made in USA.

See the full line at [reichert.com/clearchart](http://reichert.com/clearchart)

**Reichert**  
TECHNOLOGIES

**AMETEK** © 2017 AMETEK, Inc. & Reichert, Inc. (5-2017) · Made in USA   
ClearChart is a registered trademark of Reichert, Inc. · [www.reichert.com](http://www.reichert.com)

Up to  
11 CE  
Credits\*

## SAVE THE DATE!

The Optometric Retina Society  
and *Review of Optometry* Present:

# RETINAUPDATE 2017

December 1-2, 2017 • Anaheim, CA



### SHERATON PARK HOTEL

1855 S. Harbor Boulevard  
Anaheim, California 92802

A limited number of rooms have been reserved at \$169/night plus applicable taxes. Make your reservations with the hotel at 866-837-4197, mention "Review of Optometry" for group rate.

#### REGISTRATION COST:

ORS Member: \$405      Non-member: \$450

#### PROGRAM CHAIR:



Mohammad Rafieetary, OD

#### PROGRAM COMMITTEE:



Steve Ferrucci, OD



Leo Semes, OD

### ORS MISSION STATEMENT

*The mission of the Optometric Retina Society (ORS) is to promote the advancement of vitreoretinal knowledge for clinicians, ophthalmic educators, residents, and students.*

*The ORS is dedicated to posterior segment disease prevention, diagnosis, management and co-management.*

SEE REGISTRATION  
WEBSITE FOR  
EARLY BIRD DISCOUNTS

Deadline: September 30, 2017

### THREE WAYS TO REGISTER

email: [reviewmeetings@jobson.com](mailto:reviewmeetings@jobson.com) | call: 800-999-0975

online: [www.reviewofoptometry.com/orsretupdate2017](http://www.reviewofoptometry.com/orsretupdate2017)

Administered by  
**Review of Optometry®**

**COPE®**  
\*Approval pending

See event website for up-to-date information.

1. Shaarawy T, Sherwood M, Hitchings R, Crowston J. *Glaucoma*. 2nd ed. Philadelphia: Saunders; 2014.
2. Kramer T, Noecker R. Comparison of the morphologic changes after selective laser trabeculoplasty and argon laser trabeculoplasty in human eye bank eyes. *Ophthalmology*. 2001;108(4):733-79.
3. Allingham R, Damji K, Freedman S, et al, eds. *Shields' Textbook of Glaucoma*. 6th ed. Philadelphia: Lippincott Williams & Wilkins; 2011.
4. Kennedy J, SooHoo J, Kahook M, Seibold L. Selective laser trabeculoplasty: An update. *Asia Pac J Ophthalmol*. 2016;5(1):63-9.
5. Latina M, Sibayan S, Shin D, et al. Q-switched 532-nm Nd:YAG laser trabeculoplasty (selective laser trabeculoplasty): a multicenter, pilot, clinical study. *Ophthalmology*. 1998;105(11):2082-8.
6. Woo D, Healey P, Graham S, Goldberg I. Intraocular pressure-lowering medications and long-term outcomes of selective laser trabeculoplasty. *Clin Exper Ophthalmol*. 2015;43(4):320-7.
7. Gracner T, Falez M, Gracner B, Pahor D. Long-term follow-up of selective laser trabeculoplasty in primary open-angle glaucoma. *Klin Monbl Augenheilkd*. 2006;223(9):743-7.
8. Kent S, Hutnik C, Birt C, et al. A randomized clinical trial of selective laser trabeculoplasty versus argon laser trabeculoplasty in patients with pseudoexfoliation. *J Glaucoma*. 2015;24(5):344-7.
9. Bovell A, Damji K, Hodge W, et al. Long term effects on the lowering of intraocular pressure: selective laser or argon laser trabeculoplasty? *Can J Ophthalmol*. 2011;46(5):408-13.
10. Weinand F, Althen F. (2006). Long-term clinical results of selective laser trabeculoplasty in the treatment of primary open angle glaucoma. *Eur J Ophthalmol*. 2006;16(1):100-4.
11. Tojo N, Oka M, Miyakoshi A, et al. Comparison of fluctuations of intraocular pressure before and after selective laser trabeculoplasty in normal-tension glaucoma patients. *J Glaucoma*. 2014;23(8):138-43.
12. Nagar M, Ogunyomade A, O'Brart D, et al. A randomised, prospective study comparing selective laser trabeculoplasty with latanoprost for the control of intraocular pressure in ocular hypertension and open angle glaucoma. *Br J Ophthalmol*. 2005;89(11):1413-7.
13. Melamed S, Ben Simon G, Levkovich-Verbin H. Selective laser trabeculoplasty as primary treatment for open-angle glaucoma: a prospective, nonrandomized pilot study. *Arch Ophthalmol*. 2003;121(7):957-60.
14. McIlraith I, Strasfeld M, Colev G, Hutnik C. Selective laser trabeculoplasty as initial and adjunctive treatment for open-angle glaucoma. *J Glaucoma*. 2006;15(2):124-30.
15. Giaconi J, Law S, Nouri-Mahdavi K, et al, eds. *Pearls of Glaucoma Management*. 2nd ed. Berlin: Springer-Verlag; 2016.
16. Martow E, Hutnik C, Mao A. SLT and adjunctive medical therapy: a prediction rule analysis. *J Glaucoma*. 2011;20(4):266-70.
17. Wasyluk J, Piekarniak-Wozniak A, Grabska-Liberek I. The hypotensive effect of selective laser trabeculoplasty depending on iridocorneal angle pigmentation in primary open angle glaucoma patients. *Arch Med Sci*. 2014;10(2):306-8.
18. Samples J, Schacknow P, eds. *Clinical Glaucoma Care: The essentials*. New York: Springer; 2014.
19. Song J. Complications of selective laser trabeculoplasty: A review. *Clin Ophthalmol*. 2016;10:137-43.
20. Kahook M, ed. *Essentials of Glaucoma Surgery*. Thorofare, NJ: Slack Inc.; 2012.
21. Elex iScience. Ab-interno canaloplasty - The minimally invasive glaucoma surgery that keeps its promise: 12-month case series review. 2016. [www.ellex.com/wp-content/uploads/sites/9/Ellex-ABIC-Whitepaper-12-Months-ELECTRONIC.pdf](http://www.ellex.com/wp-content/uploads/sites/9/Ellex-ABIC-Whitepaper-12-Months-ELECTRONIC.pdf). Accessed May 18, 2017.
22. Seibold L, SooHoo J, Kahook M. Endoscopic cyclophotocoagulation. *Middle East Afr J Ophthalmol*. 2015;22(1):18-24.
23. Rathi S, Radcliffe N. Combined endocyclophotocoagulation and phacoemulsification in the management of moderate glaucoma. *Surv Ophthalmol*. March 2, 2017. [Epub ahead of print].
24. Chen P, Lin S, Junk A, et al. The effect of phacoemulsification on intraocular pressure in glaucoma patients: a report by the American Academy of Ophthalmology. *Ophthalmology*. 2015;122(7):1294-1307.
25. Kahook M, Schuman J, eds. *Chandler and Grant's Glaucoma*. Thorofare, NJ: Slack Inc.; 2013.
26. Drance S. The glaucomatous visual field. *Invest Ophthalmol*. 1972;11(2):85-96.
27. Peters D, Bengtsson B, Heijl A. Threat to fixation at diagnosis and lifetime risk of visual impairment in open-angle glaucoma. *Ophthalmology*. 2015;122(5):1034-9.
28. Fechtner R. Maximal medical therapy. *J Glaucoma*. 2001;10(5):S73-5.
29. Wormington C. *Ophthalmic Lasers*. Oxford: Butterworth-Heinemann; 2003.
30. Prum B, Herndon L, Moroi S, et al. Primary angle closure preferred practice pattern guidelines. *Ophthalmology*. 2016;123(2):P1-P40.
31. Guo X, He M. Angle-closure glaucoma: Risk factors. In: Giaconi J, Law S, Nouri-Mahdavi K, et al, eds. *Pearls of Glaucoma Management*. 2nd ed. Berlin: Springer-Verlag; 2016.
32. Li S, Wang H, Mu D, et al. Prospective evaluation of changes in anterior segment morphology after laser iridotomy in Chinese eyes by rotating Scheimpflug camera imaging. *Clin Exp Ophthalmol*. 2010;38(1):10-4.
33. Spaeth G, Idowu O, Seligsohn A, et al. The effects of iridotomy size and position on symptoms following laser peripheral iridotomy. *J Glaucoma*. 2005;14(5):364-7.
34. Vera V, Naqi A, Belovay G, et al. Dysphotopsia after temporal versus superior laser peripheral iridotomy: a prospective randomized paired eye trial. *Am J Ophthalmol*. 2014;157(35):929-35.
35. Lee K, Sung K, Shon K, et al. Longitudinal changes in anterior segment parameters after laser peripheral iridotomy assessed by anterior segment optical coherence tomography. *Invest Ophthalmol Vis Sci*. 2013;54(5):3166-70.
36. Azuara-Blanco A, Burr J, Ramsey C, et al. Effectiveness of early lens extraction for the treatment of primary angle-closure glaucoma (EAGLE): a randomised controlled trial. *Lancet*. 2016;388(10052):1389-97.
37. Ramakrishnan R, Mitra A, Abdul Kader M, Das S. To study the efficacy of laser peripheral iridoplasty in the treatment of eyes with primary angle closure and plateau iris syndrome, unresponsive to laser peripheral iridotomy, using anterior-segment oct as a tool. *J Glaucoma*. 2016;25(5):440-6.
38. Sponsel WE, Groth SL. Mitomycin-augmented non-penetrating deep sclerectomy: preoperative gonioscopy and postoperative perimetric, tonometric and medication trends. *Br J Ophthalmol*. 2013;97:357-61.



All-new!

## Elements of pre-test.

OptoChek™ Plus Auto Refractor + Keratometer  
 LensChek™ Plus & Pro Digital Lensometers

Reichert® combines technology, simplicity,  
 and value at the core of your exam.

Learn more at [reichert.com/exam](http://reichert.com/exam)

**Reichert**  
 TECHNOLOGIES

**AMETEK** © 2017 AMETEK, Inc. & Reichert, Inc. (5-2017)

[www.reichert.com](http://www.reichert.com)

## 23rd Annual Glaucoma Report

# Looking to the Future of Glaucoma Treatment

A trio of new therapies is poised to change how ODs fight the disease.

By Michael Rebar, OD, and Andrew S. Gurwood, OD

As far as we know, intraocular pressure (IOP) is the only modifiable risk factor with respect to altering glaucoma's characteristic death of retinal ganglion cells.<sup>1-15</sup> IOP quantifies the balance between aqueous humor (AH) secretion by the ciliary body epithelia and its drainage through the conventional, pressure-sensitive pathway and unconventional, pressure-insensitive or "uveoscleral" pathways.<sup>6,13-17</sup> IOP will increase along with any resistance to aqueous outflow.<sup>18</sup> This can result from age-related cellular dysfunction in the conventional outflow pathway or a normal outflow system unable to handle overproduction.<sup>18</sup> The rate of aqueous production is dependent on blood flow to the ciliary body and the rate of active secretion from the ciliary epithelium.<sup>12</sup> The estimated turnover rate is 1.0% to 1.5% (2.5ml/minute) of the anterior chamber volume per minute.<sup>10,13</sup> Research shows a 20% to 30% decrease in IOP can significantly reduce the risk of progression of primary open-angle glaucoma (POAG).<sup>1</sup>

Since altering other mechanisms in the pathophysiology of

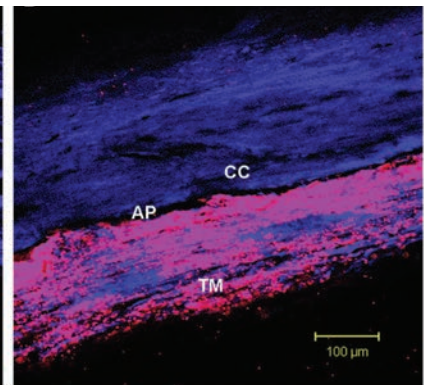
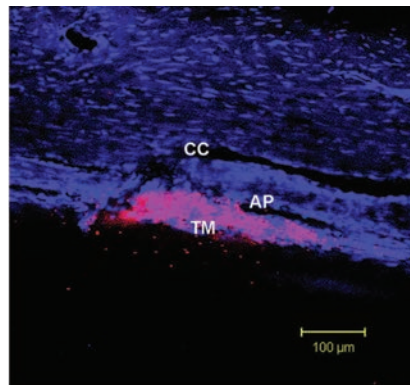


Photo: Patrick A. Scott, OD, PhD

**Rho-kinase inhibitors appear to lower IOP by inducing cellular relaxation and disrupting focal adhesions in the TM and the endothelial lining of Schlemm's canal.**

the disease is not possible without profound risk to the patient, lowering IOP is the only means of arresting disease progression.<sup>13-18</sup> In the United States, the current guidelines for the initial intervention of newly discovered cases of POAG recommend a first-line approach with topical ocular hypotensives.<sup>27</sup> To that end, three new agents that are under investigation aim to decrease IOP without upsetting the physiology. If successful, these medications could help keep the primary outflow pathway functioning.

This article introduces these new medical interventions and explains

how they can impact IOP for glaucoma patients.

## Aqueous Outflow

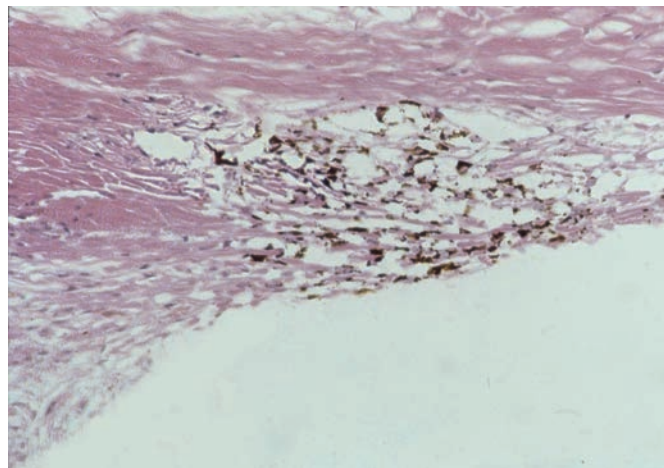
The conventional or trabecular meshwork (TM) outflow pathway accounts for 80% to 90% of aqueous outflow under normal physiological conditions.<sup>1-17</sup> The uveoscleral outflow pathway covers the remaining 10% to 20%.<sup>7</sup> Anatomically, the TM can be separated into distinct regions based on location and function. The uveal and corneoscleral meshwork consist of arrays of lamellae comprised of fenestrated collagen beams



covered by endothelial-like cells, with loose extracellular matrix (ECM) occupying the spaces between the cells of the adjacent beams.<sup>19-22</sup> The ECM provides a channel for AH to cross the juxtacanalicular tissue (JCT) and exit the anterior chamber through Schlemm's canal (SC), where the AH is eventually drained into the venous circulation.<sup>7-17</sup> The ECM is an active structure, possess-

ing many bioactive molecules that influence outflow resistance. This activity in the extracellular environment is linked to alterations in the intracellular actin cytoskeleton and vice-versa.<sup>7-17</sup> For normal patients, resistance to aqueous flow is greatest in the JCT region, the inner wall of SC or both.<sup>7-17</sup>

Regulation of aqueous outflow in the primary outflow pathway is mitigated by the interaction of two cell types in the JCT: the TM and SC endothelia. TM cells express smooth muscle-like properties, including contractility, electro-mechanical characteristics and expression of actin and myosin specific to smooth muscle tissue.<sup>1</sup> This highly structured cellular actomyosin system affects the overall contractile tone of the tissue influencing outflow resistance.<sup>12</sup> Research confirms that actin depolymerization coupled with decreased cell-ECM interactions and myosin II phosphorylation within cells of the trabecular pathway increases AH outflow, consequently decreasing IOP.<sup>8,12</sup> The majority of aqueous flowing across the SC endothelia is thought to pass through micron-sized pores. SC cells are highly contractile, and increased contraction



**Rho-kinase inhibitors improve drainage through the trabecular meshwork, seen here under a microscope.**

Photo: Thomas Fiedler, MD, PhD

greatly increases their cell stiffness. Altered cell stiffness modifies pore formation, ultimately affecting downstream egress of AH from the eye.<sup>7-17</sup>

### Outflow Mechanics

While normal individuals will see a reduction of aqueous outflow facility through the TM of approximately 7% to 10% per decade, POAG patients develop an increased resistance to outflow.<sup>7-17</sup> Research supports a link between cytoskeletal integrity within the cells of the trabecular pathway and AH outflow through that route.<sup>8</sup> Histological changes observed in POAG patients, possibly contributing to decreased aqueous outflow, include declining number of TM cells, increased and changed ECM components, deposition of extracellular plaques and stiffening of the TM with decreased contractility force of the elastic fibers.<sup>7-17</sup>

Specifically, as the smooth muscle-like properties of TM cells facilitate dynamic tissue restructuring, marked loss of these cells, which seems to be exaggerated in glaucoma, leads to fusion and thickening of the trabecular lamellae,

impairing its function.<sup>1-19</sup> The deposition of extracellular plaques within glaucomatous JCT ECM is similar to the characteristics of the process of fibrosis. These aberrant accumulations adhere to the sheaths of the elastic fibers and their connections to the inner endothelium wall of SC.<sup>13-16</sup> Research shows these increased cell-cell junction adherences between SC cells and accumulated ECM underlie the pathological increased

resistance to aqueous outflow.<sup>13-16</sup> In addition, the subcortical SC cell stiffness is elevated by as much as 50% in glaucomatous eyes.<sup>13-16</sup> This correlates with decreased pore density, impairing the egress of AH from the eye.<sup>7-16</sup>

### Current Approaches

Topical and oral glaucoma medications lower IOP by reducing production, increasing AH outflow, or both. These include topical prostaglandin analogs (PGAs), beta-blockers, topical and oral carbonic anhydrase inhibitors, topical sympathomimetics and topical miotics.

PGAs are the most efficacious at lowering IOP, and work primarily by increasing uveoscleral outflow. Although some studies show they may alter resistance in TM outflow, that effect is minimal.<sup>29-32</sup> In the United States, miotics are the only available medications that have a mechanical effect on the conventional outflow pathway. These agents work as parasympathomimetics, contracting both the iris constrictor and ciliary muscles, which increases the mechanical pull on the TM and opens the meshwork's parasellar spaces.<sup>33-36</sup> While

the medicines in this class are inexpensive, unfortunately they require frequent dosing and carry significant ocular side effects such as brow ache, small pupil size (which can accentuate the effects of cataract in older patients) and increased risk of retinal detachment.<sup>34,35</sup> New therapeutic approaches aim to harness this pathway with less deleterious side effects.<sup>33-41</sup>

Recent investigations suggest the TM outflow tissues are avascular and dependent on AH to supply antioxidants, growth factors, chemokines and nutrients.<sup>9,42</sup> Ironically, therapies that suppress aqueous production or enhance uveal and scleral outflow decrease the supply of AH across the outflow tissues.<sup>9,42</sup> Reduction of IOP unquestionably protects the optic nerve; however, researchers wonder if nutrient deprivation from fluid reduction, in the long run, creates a greater than normal degradation of the trabecular outflow pathway and in turn greater risks over time.<sup>9,42</sup>

While surgical options are available for cases that exhibit progression in the setting of maximum topical therapy, new agents can decrease IOP without upsetting the physiology.

## ROCK Inhibitors

Rhopressa (netarsudil ophthalmic topical solution 0.02%, Aerie Pharmaceuticals), currently in Phase III clinical trials, is unlike the current first-line therapies that focus on enhancing unconventional aqueous outflow through the uveoscleral pathway. Data from preclinical and clinical trials suggests that Rhopressa, dosed once daily, lowers IOP via four mechanisms.<sup>38</sup> First, it is a rho kinase (ROCK) inhibitor. ROCK inhibitors increase actomyosin contraction in smooth muscle-like cells, including the

myofibroblast-like cells of the TM, increasing outflow.<sup>39</sup> Second, pre-clinical trials showed netarsudil had antifibrotic effects on TM cells, producing increased perfusion through the TM.<sup>37</sup> Third, netarsudil also lowered episcleral venous pressure in animal studies, in turn lowering IOP by reducing resistance to AH outflow.<sup>37</sup> The fourth mechanism of IOP reduction is due to norepinephrine transporter (NET) inhibition.<sup>38</sup> NET inhibition occurs in the ciliary body, resulting in increased norepinephrine levels which decrease AH secretion via activation of  $\alpha 2$  adrenergic receptors.<sup>43</sup>

The mean IOP-lowering effect of netarsudil during Phase II and Phase III clinical trials was 5.5mm Hg.<sup>40</sup> In the Rocket 1 clinical study, netarsudil was found to be inferior to timolol at higher levels of baseline IOP.<sup>38</sup> The drug seems to possess better IOP-lowering capabilities at IOPs less than 25mm Hg. This may result in FDA labeling for use in cases where IOP lowering is necessary but the untreated measurement is less than 25mm Hg.

Netarsudil is currently under analysis in two Phase III clinical trials (Rocket 3 and Rocket 4). Rocket 3 is a 12-month safety-only study in Canada. Rocket 4 is designed to provide adequate six-month safety data for regulatory filing purposes in Europe.<sup>38</sup> In addition, the Rocket 4 top-line 90-day efficacy data successfully demonstrated non-inferiority to timolol at its primary endpoint range.<sup>38</sup>

Throughout the clinical trials, there were no drug-related serious adverse events and no evidence of treatment-related systemic effects. The most common side effect in the treatment group was conjunctival hyperemia (seen in approximately 48% of the cohort).<sup>38</sup> Other side effects, which were noted in 3% to

5% of the treatment group, included cornea verticillata, conjunctival hemorrhage, increased lacrimation, erythema of eyelid and blurred vision.<sup>38</sup> Since side effects such as these are possible, patient education is of the utmost importance. While these are undesirable, their possibility alone should not prevent clinicians from suggesting Rhopressa for treatment.

## Another ROCK Option

Preclinical and clinical research demonstrates that Roclatan (netarsudil/latanoprost ophthalmic solution 0.02%/0.005%, Aerie Pharmaceuticals) works on all known mechanisms of IOP reduction; decreasing aqueous production, increasing outflow from the TM, increasing outflow from the uveal scleral outflow pathway and reducing episcleral venous pressure.<sup>38</sup>

Roclatan has undergone multiple Phase III clinical trials: Mercury 1, Mercury 2 and Mercury 3. Mercury 1 is a 12-month safety trial in 718 patients with a 90-day efficacy readout. During this trial, Roclatan showed superiority to each of its components, achieving up to a 3mm Hg greater IOP lowering effect.<sup>38</sup> Mercury 2 is a 90-day efficacy trial that commenced in March 2016.<sup>38</sup> Mercury 3 is a registration trial not needed for FDA approval or commercialization, but designed to help with approval and release in Europe.<sup>38</sup>

## Reducing Resistance

Vyzulta (latanoprostene bunod ophthalmic solution 0.024%, Bausch + Lomb), works as a nitric oxide (NO) donating prostaglandin F<sub>2</sub> $\alpha$  analog.<sup>44,45</sup> Upon instillation, latanoprostene bunod is hydrolyzed by endogenous corneal esterases into latanoprost acid and butanediol mononitrate, which is

# LOMBART CS-5 CHAIR & STAND

## Quality, Style & Value

Package includes:

- The *Lombart CS-5*  
Chair & Stand 
- *Topcon VT-10* Refractor
- *Topcon SL-2G* Slit Lamp



- *Lombart CVS Essential*  
*Visual Acuity System*  
with RF Remote Control
- Additional upgrades  
& configurations available.

## \$13,995

Or lease for \$277/mo.  
for 60 months\*

\*Lease rate subject to credit approval, 1st payment is due at signing with 59 remaining rental payments of \$265 and a \$1.00 purchase option. Taxes, freight and installation additional. Hand Instruments optional. Subject to change without notice.

1-800-566-2278

## Call 1-800-Lombart

Or Your Local Lombart Representative

Corporate Office - 5358 Robin Hood Road, Norfolk, VA 23513-2430

757-853-8888 | FAX 757-855-1232 | 800-566-2278

[www.lombartinstrument.com](http://www.lombartinstrument.com)

[lombart@lombartinstrument.com](mailto:lombart@lombartinstrument.com)

Sales and Service Centers Coast to Coast

ATLANTA • BALTIMORE/WASHINGTON D.C. • BOSTON • BOYNTON BEACH/MIAMI • BRADENTON • CHARLOTTE • CHICAGO • CINCINNATI • DALLAS • DENVER • DETROIT • GREENSBORO • HOUSTON  
JACKSON • KANSAS CITY • KNOXVILLE • LOS ANGELES • MILWAUKEE • MINNEAPOLIS • NEW JERSEY/NEW YORK/PENNSYLVANIA • NORFOLK • PORTLAND • SAN ANTONIO • SAN DIEGO • SAN FRANCISCO



Get the most from your TAYE listing!

**UPGRADE**  
— to —  
**PREMIUM**  
**TODAY!**



**Premium listings enjoy 5 times more patient activity than a Basic listing.**

Going Premium will help your practice appear at the top of search results in your area. Because prospective patients are looking for **COMPREHENSIVE EYE EXAMS**, your patient traffic will increase. And that means you'll be helping even more patients see their best!

**think**about  
**youreyes**.com

 AMERICAN OPTOMETRIC ASSOCIATION

Simply log in at **enroll.thinkaboutyoureyes.com** and upgrade today!  
Leadership State Members upgrade for \$200 per year!

©2017 All rights reserved. Think About Your Eyes® is a public awareness campaign focused on educating consumers on the importance of vision health.

further metabolized to NO and the inactive 1,4-butanediol.<sup>45,46</sup> NO reduces IOP by enhancing aqueous outflow through the TM and SC. Latanoprost acid, the active metabolite in latanoprost, increases the presence of matrix metalloproteinases (MMPs). MMPs degrade collagen, specifically types I, III and IV. This degradation reduces outflow resistance through the uveoscleral pathway, ultimately lowering IOP.<sup>46</sup>

The most notable clinical trial for latanoprostene bunod was Voyager.<sup>42</sup> This Phase II clinical trial demonstrated latanoprostene's superiority over latanoprost.<sup>44,45</sup> Constellation, a Phase II, small-scale trial demonstrated superiority over timolol twice daily.<sup>45</sup> Phase III trials include Apollo, Lunar and Jupiter.

Apollo, a larger trial, compared latanoprostene bunod with timolol and demonstrated superiority in overall IOP reduction. The study had a greater number of participants with IOP less than or equal to 18mm Hg and showed a higher percentage of IOP reduction greater than or equal to 25%.<sup>44</sup> These clinical trials show Vyzulta has the potential to provide an additional 1mm Hg to 3mm Hg drop in IOP, compared with the addition of latanoprost and timolol.<sup>45</sup> Twenty-two percent of subjects reported at least one adverse ocular event. These events were mild, transient and consistent with those seen caused by other topical glaucoma medications, including conjunctival hyperemia, eye irritation and eye pain.<sup>44,45</sup>

The incidence of glaucoma continues to rise and the more ammunition provided to the armamentarium the better. Surgical interventions, such as cataract extraction, filtering procedures and the placement of drainage devices, increase risk to the patient. These new topical therapies, both

as primary choices or as an addition to an established course of therapy have shown great promise for reducing IOP in the setting of once-daily dosing with excellent safety profile.

Their ability to act on the conventional and unconventional outflow mechanisms in addition to having other IOP-lowering mechanisms not available with current topical treatment modalities makes them valuable and anticipated. ■

*Dr. Rebar is coordinator of residency programs in Primary Care and Cornea & Contact Lens at Salus University*

*Dr. Gurwood is a clinical director and professor with the Eye Institute at Salus University.*

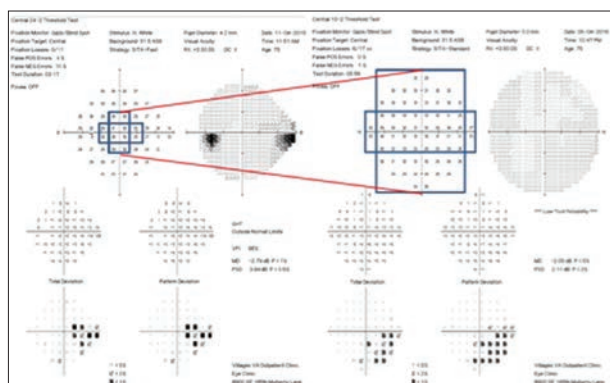
1. Quigley H. New paradigms in the mechanisms and management of glaucoma. *Eye*. 2005;19(12):1241-8.
2. Quigley H, Broman A. The number of people with glaucoma worldwide in 2010 and 2020. *Br J Ophthalmol*. 2006;90(3):262-7.
3. Tham Y, Li X, Wong T, et al. Global prevalence of glaucoma and projections of glaucoma burden through 2040: a systematic review and meta-analysis. *Ophthalmology*. 2014;121(11):2081-90.
4. Kapetanakis V, Chan M, Foster P, et al. Global variations and time trends in the prevalence of primary open angle glaucoma (POAG): a systematic review and meta-analysis. *Br J Ophthalmol*. 2016;100(1):86-93.
5. Weinreb R, Aung T, Medeiros FA. The pathophysiology and treatment of Glaucoma: A Review. *JAMA*. 2014;311(18):1901-11.
6. Janssen SF, Gorgels TG, Ramdas WD, et al. The vast complexity of primary open angle glaucoma: Disease genes, risks, molecular mechanisms and pathobiology. *Prog Retin Eye Res*. 2013 Nov;37:31-67.
7. Alm A, Nilsson SF. Uveoscleral outflow - a review. *Experimental Eye Research*. 2009;88(4):760-768.
8. Brubaker RF. Targeting outflow facility in glaucoma management. *Surv Ophthalmol*. 2003;48(Suppl 1):S17-20.
9. Stamer WD, Braakman ST, Zhou EH, et al. Biomechanics of Schlemm's canal endothelium and intraocular pressure reduction. *Prog Retin Eye Res*. 2015;44(1):86-98.
10. Goel M, Picciani RG, Lee RK, Bhattacharya SK. Aqueous humor dynamics: a review. *Open Ophthalmol J*. 2010 Sep;4:52-9.
11. Kanski J. *Clinical ophthalmology: a systematic approach*, 6th ed. Edinburgh: Elsevier Butterworth-Heinemann; 2007.
12. McDougal DH, Gamli PD. Autonomic control of the eye. *Compr Physiol*. 2015;5(1):439-73.
13. Gabelt BT, Kaufman PL. Aqueous humor hydrodynamics. In: Hart WM, Ed. *Adler's Physiology of the Eye*, 9th ed. St. Louis, MO: Mosby; 2003.
14. Johnson M. What controls aqueous humor outflow resistance? *Exp Eye Res*. 2006;82(4):545-57.
15. Tamm ER. The trabecular meshwork outflow pathways: structural and functional aspects. *Exp Eye Res*. 2009;88(4):648-55.
16. Lutjens-Dreocoll E. Functional morphology of the trabecular meshwork in primate. *Prog Retin Eye Res*. 1999;18(1):91-119.
17. Tian B, Gabelt BT, Geiger B, Kaufman P. The role of the actomyosin system in regulating trabecular fluid outflow. *Exp Eye Res*. 2009;88(4):713-17.
18. Keller KE, Acott TS. The juxtacanalicular region of ocular trabecular meshwork: A tissue with a unique extracellular matrix and specialized function. *J Ocul Biol*. 2013;1(1):3-15.
19. Keller KE, Aga M, Bradley JM, et al. Extracellular matrix turnover and outflow resistance. *Exp Eye Res*. 2009; 88(4):676-682.
20. Tektas OY, Lutjens-Dreocoll E. Structural changes of the trabecular meshwork in different kinds of glaucoma. *Exp Eye Res*. 2009;88(4):769-75.
21. Roy Chowdhury U, Hann CR, Stamer WD, Fautsch MP. Aqueous humor outflow: dynamics and disease. *Invest Ophthalmol Vis Sci*. 2015;56(5):2993-3003.
22. Overby DR, Zhou EH, Vargas-Pinto R, et al. Altered mechanobiology of Schlemm's canal endothelial cells in glaucoma. *Proc Natl Acad Sci USA*. 2014;111(38):13876-81.
23. Zhang M, Maddala R, Rao PV. Novel molecular insights into RhoA GTPase-induced resistance to aqueous humor outflow through the trabecular meshwork. *Am J Physiol Cell Physiol*. 2008;295(5):C1057-70.
24. Brubaker RF. Introduction: three targets for glaucoma management. *Surv Ophthalmol*. 2003;48(Suppl 1):S1-2.
25. Kameda T, Inoue T, Inatani M et al. The effect of rho associated protein kinase inhibitor on monkey Schlemm's canal endothelial cell. *Invest Ophthalmol Vis Sci*. 2012;53(6):3092-3103.
26. Li T, Lindsley K, Rouse B, et al. Comparative effectiveness of first-line medications for primary open-angle glaucoma: A systematic review and network meta-analysis. *Ophthalmology*. 2016;123(1):129-140.
27. Parrish RK, Palmberg P, Sheu WP, XLT Study Group. A comparison of latanoprost, bimatoprost, and travoprost in patients with elevated intraocular pressure: a 12-week, randomized, masked-evaluator multicenter study. *Am J Ophthalmol*. 2003;135(5):688-703.
28. Alm A, Villumsen J. PhXA34, a new potent ocular hypotensive drug. A study on dose-response relationship and on aqueous humor dynamics in healthy volunteers. *Arch Ophthalmol*. 1991;109(11):1564-1568.
29. Toris CB, Camras CB, Yablonski ME. Effects of PhXA41, a new prostaglandin F2, analog on aqueous humour dynamics on human eyes. *Ophthalmology*. 1993;100(9):1297-304.
30. Toris CB, Gabelt BT, Kaufman PL. Update on the mechanism of action of topical prostaglandins for intraocular pressure reduction. *Surv Ophthalmol*. 2008;53(S1):S107-20.
31. Fung DS, Whitson JT. An evidence-based review of unoprostene isopropyl ophthalmic solution 0.15% for glaucoma: place in therapy. *Clin Ophthalmol*. 2014;10(8):543-54.
32. Lee DA, Higginbotham EJ. Glaucoma and its treatment: A Review. *Am J Health Syst Pharm*. 2005;62(7):691-9.
33. Kopiczynski CC, Epstein DL. Emerging trabecular outflow drugs. *J Ocul Pharmacol Ther*. 2014;30(2-3):85-7.
34. Webster AR, Luff AJ, Canning CR, Elkington AR. The effect of pilocarpine on the glaucomatous visual field. *Br J Ophthalmol*. 1993;77(11):721-5.
35. Sihota R, Agarwal HC, Rajashekar YL. A comparative evaluation of pilocarpine 1% and clonidine 0.125% versus timolol 0.5%. *Indian J Ophthalmol*. 1996;44(2):87-9.
36. Burr J, Azuara-Blanco A, Avenell A, Tuulonen A. Medical versus surgical interventions for open angle glaucoma. *Cochrane Database Syst Rev*. 2012;(9):CD004399.
37. Alm A, Camras CB, Watson PG. Phase III latanoprost studies in Scandinavia, the United Kingdom and the United States. *Surv Ophthalmol*. 1997;41(Suppl 2):S105-110.
38. Aerie Pharmaceutical Products. <http://aeriepharma.com/products-at-a-glance/>. Accessed April 22, 2017.
39. Ren R, Li G, Le TD, et al. Netarsudil increases outflow facility in human eyes through multiple mechanisms. *Invest Ophthalmol Vis Sci*. 2016;57:6197-209.
40. Lua LJ, Tsai JC, Lua J. Novel pharmacologic candidates for treatment of primary open-angle glaucoma. *Yale Journal of Biology and Medicine*. 2017;90:111-8.
41. Bacharach J, Dubiner HB, Levy B, et al. Double-masked, randomized, dose-response study of AR-13324 versus latanoprost in patients with elevated intraocular pressure. *Ophthalmology*. 2015;122(2):302-7.
42. Perumal N, Manicam C, Steinicke M, et al. Characterization of the human aqueous humor proteome: A comparison of the genders. *PLoS One*. 2017;12(3):e0172481.
43. Kaufman PL. Latanoprostene bunod ophthalmic solution 0.024% for IOP lowering in glaucoma and ocular hypertension. *Expert Opinion on Pharmacotherapy*. 2017;18(4):433-444.
44. Garcia GA, Ngai P, Mosaed S, Lin KY. Critical evaluation of latanoprostene bunod in the treatment of glaucoma. *Clinical Ophthalmology*. 2016 Oct;10:2035-50.
45. Krauss AH, Impagnatiello F, Toris CB, et al. Ocular hypotensive activity of BOL-303259-X, a nitric oxide donating prostaglandin F2α agonist, in preclinical models. *Exp Eye Res*. 2011;93(3):250-55.

# 10-2 Visual Field Testing: A Tool for **All** Glaucoma Stages

This diagnostic tool is a must for detecting paracentral and visual field defects close to fixation in glaucoma, even the early-moderate stage. **By Austin Lifferth, OD, Brian Fisher, OD, April Sturmsma, OD, Sarah Cordes, OD, Stephanie Carter, OD, and Trina Perkins, OD**

**A**dvancing technology has revolutionized our toolbox for detecting and following glaucoma progression—but knowing which tests provide the best diagnostic information is trickier than ever. Although 24-2 and 30-2 perimetry remain the gold standard—despite advancements in retinal nerve fiber layer (RNFL) and ganglion cell analysis (GCA) optical coherence tomography (OCT)—it may not be the most sensitive test to catch patients at the highest risk of functional visual impairment.<sup>1,2</sup> Central 10-2 visual field (VF) testing, however, may be under-used in all stages of glaucoma.

These glaucoma cases—incorporating 10-2 and 24-2 perimetry, RNFL and GCA OCT and optic nerve head photos—highlight the benefits of 10-2 perimetry in detecting paracentral and VF defects close to fixation in all stages of glaucoma, with special attention to the early-moderate stage. In addition, these cases also suggest the benefits of



**Fig. 1. As this comparison shows, 10-2 perimetry has greater sensitivity and detects more points than 24-2 perimetry.**

using 10-2 VF testing to monitor progression and change in advanced visual field loss.

## Why 10-2?

The 24-2 and 30-2 threshold VF testing patterns assess a total of 54 and 74 points, respectively, each six degrees apart (three degrees from the horizontal and vertical meridians) with only 12 points tested within the central 10 degrees (*Figure 1*). Furthermore, only four of these points are actually tested within the macular region (the central eight degrees)—the area that accounts for over 30% of the total retinal gan-

glion cells and over 60% of the visual cortex area.<sup>3</sup>

By comparison, 10-2 threshold VF testing assesses 68 points, more than five times as many points in the central 10 degrees compared with 24-2 and 30-2 testing. These points are all two degrees apart, just one degree from either side of the horizontal and vertical meridians.<sup>4</sup> As a result of this greater sensitivity, many paracentral scotomas involv-


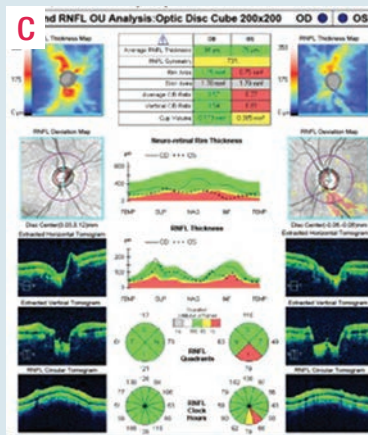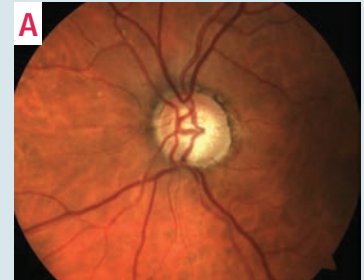

ing only a small area of the visual field at or near fixation may be missed with 24-2 and 30-2 perimetry and are only detected with 10-2 testing.<sup>5</sup>

## Early and Moderate Glaucoma

Although central and paracentral glaucomatous VF damage more commonly occurs in advanced stages of glaucoma, such defects also occur in patients with earlier stages of glaucoma and with relatively minimal peripheral VF loss.<sup>6</sup> Recent studies suggest these early central defects are usually more common in the upper VF, deeper and generally

## Case 1

This 76-year-old patient has early-moderate primary open-angle glaucoma in the left eye and is a high-risk glaucoma suspect in the right. His IOPs were stable with current topical ocular hypotensive medications. Gonioscopy was normal OU and pachymetry measurements were thinner than average, 504 $\mu$ m OD and 508 $\mu$ m OS. Despite limited commitment to follow-up, his most recent 24-2 for his left eye (B) confirmed overall stable superior paracentral defects, which were consistent with inferior neuroretinal rim thinning (A) and moderate inferior/inferior-temporal RNFL loss on OCT testing (C). The patient's current 24-2 test pattern isn't sufficient to fully understand his level of visual impairment and reliably monitor for glaucomatous progression. Central 10-2 testing (D), however, can help reveal the risk of potential visual impairment and better monitor for disease progression.

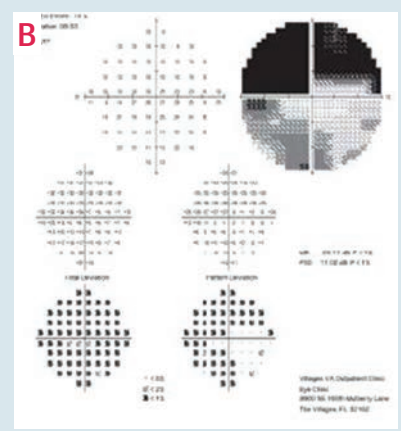



have an arcuate-like pattern that is closer to fixation than those in the inferior VF.<sup>7</sup>

Central and paracentral defects in patients with early or moderate glaucoma are more common than you might expect. According to one study, more than 50% of eyes with mild-moderate glaucoma have such defects within the central three degrees.<sup>8</sup> Furthermore, research suggests macular damage evidenced on GCA OCT, with correlating functional damage on 10-2 testing, occurs almost as frequently as peripheral defects in patients with early glaucoma; approximately 16% of these patients may have undetected functional central defects when using 24-2 testing alone.<sup>4,9</sup> Another study found 9% of normal 30-2 threshold VFs in glaucoma suspects or early glaucoma patients were actually classified as abnormal with 10-2 testing.<sup>10</sup> Additionally,

## Case 2

This patient's 24-2 VF testing shows apparent advanced structural and functional glaucomatous damage with diffuse and deep superior central and paracentral damage (A). Such testing alone can lead clinicians to not only underestimate the extent of glaucomatous VF damage, but also overestimate the extent of damage and potentially miss the area of remaining superior temporal paracentral sensitivity (B).




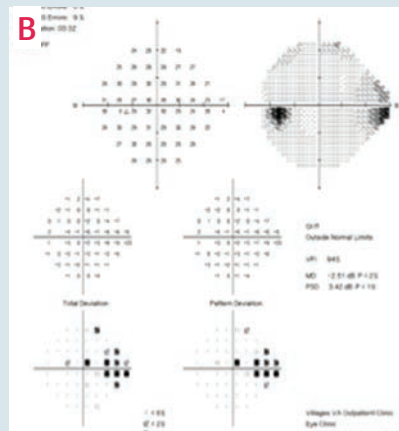
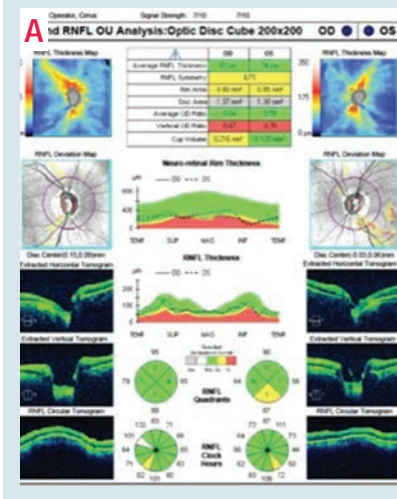


30-2 underestimated the level of glaucomatous damage in 13% of the hemifields.<sup>10</sup> Other researchers found 11 eyes with normal 24-2

VFs outside the central 10 degrees showed arcuate defects within the central 10 degrees with 10-2.<sup>11</sup> In a study published online May

## Case 3

This patient has detectable rim loss upon optic nerve evaluation and OCT testing (A) with correlating nasal step visual field defects OU, more so in the right eye than the left, and presumed minimal central involvement on visual field 24-2 testing, again more so in the right eye than the left (B and C). Central 10-2 visual field testing shows that 24-2 testing underestimates these potential central defects (D and E).



24, 2017, researchers found that, in cases of normal 24-2 testing, 10-2 found abnormal central defects in 35% of the patients with ocular hypertension, 39% of glaucoma suspects and 61% of the patients with early glaucoma.<sup>12</sup> An abnormal 10-2 result was significantly associated with at least one location on the total deviation or pattern deviation plot ( $p < 0.5\%$ ) within the central 10 degrees on 24-2 testing.<sup>12</sup> They also found patients of African descent were more likely to have central VF defects.<sup>12</sup>

**Key point:** Armed with such evidence, one group of researchers recommends 10-2 VF testing always be considered if: there are any depressed points in the central 12 degrees less than 0.5% on 24-2 or 30-2 VF testing; the paracentral

defect is greatly depressed relative to the mean deviation (MD) on 24-2; or there are any abnormal points in the central 12 points on 24-2 testing that spatially correlate to thinning in the macular ganglion cell inner plexiform layer (GC IPL) area.<sup>13</sup>

## Advanced Glaucoma

According to the Hodapp, Parrish, and Anderson visual field classification system, one of the criteria for advanced glaucoma is if the VF has any points within the central five degrees with a sensitivity less than or equal to 0dB, or if both hemifields have depressed points with sensitivity less than 15dB within the central five degrees of fixation—regardless of the status of the rest of the visual field.<sup>14</sup> For these patients in particular, and even for patients with good

central visual acuities, clinicians should regularly use 10-2 testing to better understand the significance of the defect and better monitor for progression.<sup>15,16</sup> Furthermore, researchers highly recommend all patients with advanced glaucoma undergo a combination of 24-2 or 30-2 and 10-2 testing as close to one another as possible, or at least alternated at future follow-up visits, to help monitor for progression.<sup>6</sup>

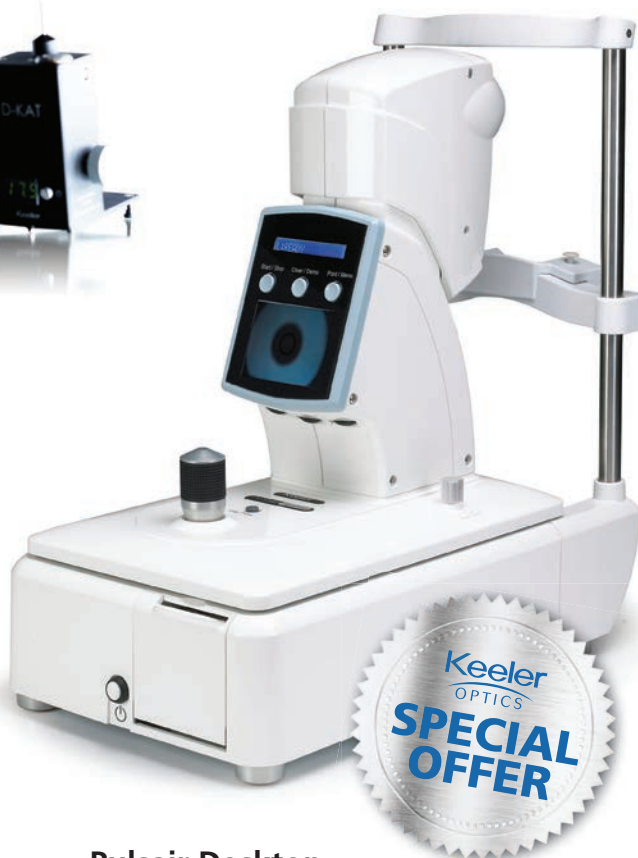For advanced cases, several studies have found that 10-2 testing with non-standard V size stimulus (as opposed to the standard III size stimulus) can more reliably measure visual function that was otherwise undetected on 30-2 testing with standard III size and thus help monitor progression of points with lower sensitivity for a longer period.<sup>17,6</sup>



# Tonometry Done Right



**D-KAT Digital**  
Keeler quality.



**Pulsair Desktop**  
Smallest footprint and simple to use!

*Purchase a Pulsair Desktop by  
September 30, 2017 and get  
a \$1,326 Instant Rebate!*

**Intellipuff**  
The standard for hand held mobility.

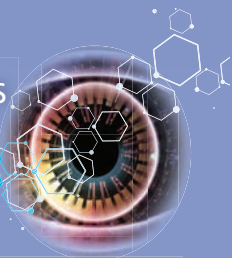Buy Online!  
[keelerusa.com](http://keelerusa.com)



**Keeler**  
OPTICS

Up to  
18 CE  
Credits\*

NEW TECHNOLOGIES  
& TREATMENTS IN  
2017 EYE CARE



REVIEW OF OPTOMETRY®  
EDUCATIONAL MEETINGS OF CLINICAL EXCELLENCE

# Philadelphia

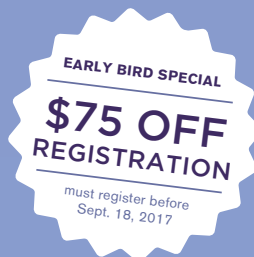
November 3-5, 2017

Join *Review of Optometry's* New Technologies & Treatments in Eye Care on November 3-5, 2017 in Philadelphia, PA. This meeting provides up to 18\* COPE CE credits including interactive workshops!\*\*

## Loews Philadelphia Hotel

1200 Market Street,  
Philadelphia, PA 19107  
Phone: (215) 627-1200

Discounted room rate: \$189/night\*



**Program Chair:**  
Paul Karpecki, OD, FAAO

## Registration Cost: \$495

Receive \$75 off if registered before September 18, 2017.

## Three Ways to Register

**Online:** [www.reviewofoptometry.com/philadelphia2017](http://www.reviewofoptometry.com/philadelphia2017)

**E-mail:** [reviewmeetings@jobson.com](mailto:reviewmeetings@jobson.com)

**Phone:** 866-658-1772



Photo: Loews Philadelphia Hotel



### Iridocyclitis and HZO

- Most common and most often overlooked ocular complication (43%)
- Highly elevated IOP



Administered by  
**Review of Optometry®**

**cope**  
\*Approval pending

**SALUS**  
UNIVERSITY  
Pennsylvania College of Optometry



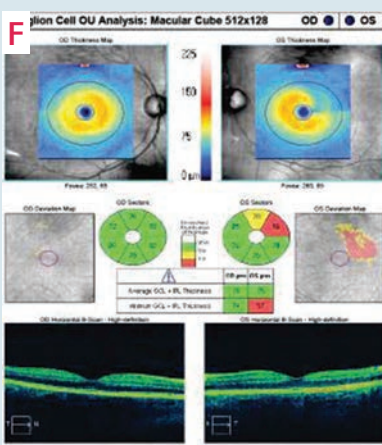

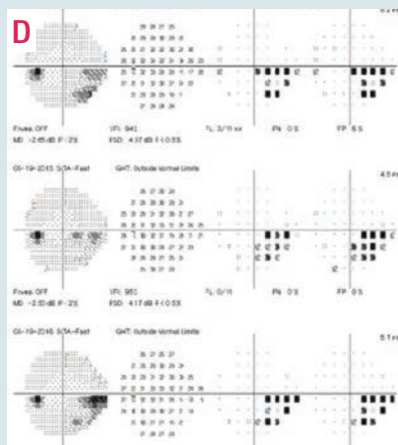
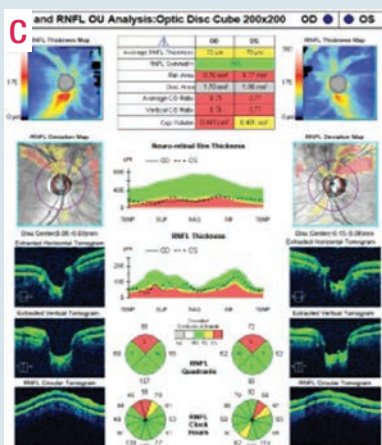
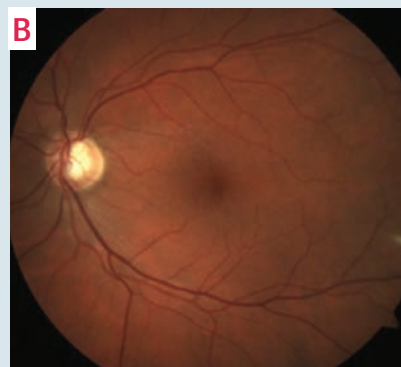
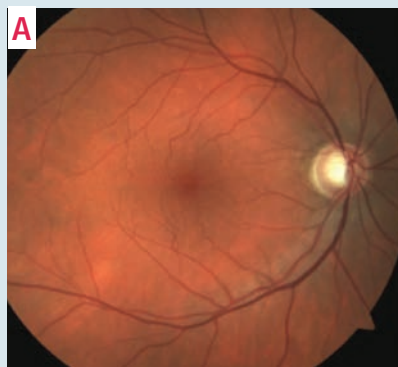
Partially supported by  
unrestricted educational grants from

**Shire Alcon**

\*Rooms limited. \*\*Subject to change, separate registration required. See event website for complete details.

## Case 4

This patient has superior rim thinning (A and B) with correlating RNFL loss on OCT testing (C and D). This corresponds to associated inferior paracentral and nasal visual field defects with variable central defects in both eyes (D and E). Due to these borderline defects and the spatially correlating ganglion cell complex thinning in the left eye (F), central 10-2 visual field testing better documented the breadth and depth of these defects (G and H).



## Glaucoma Progression

Early evidence-based research shows 10-2 perimetry detects central and paracentral glaucomatous progression more frequently than 24-2 VF testing.<sup>18</sup> In addition, one study found the rate of MD change was similar on 24-2 and 10-2 VF testing with mild to moderate VF loss,

but the rate of MD change was significantly greater on 10-2 compared with 24-2 testing for eyes with advanced VF loss (-0.19 dB/year for 24-2 testing and -0.26 dB/year for 10-2 testing).<sup>15</sup>

By using central 10-2 VF testing more routinely, clinicians can hopefully diagnose glaucoma ear-

lier, detect progression sooner and minimize the risk of under- or over-estimating the extent of the glaucomatous visual field damage—in all stages of glaucoma. ■


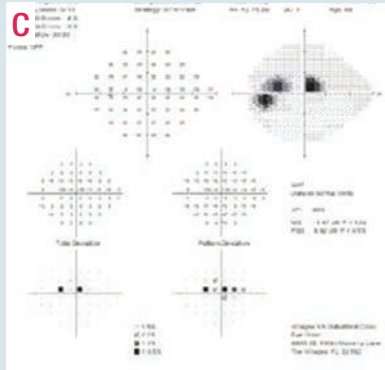
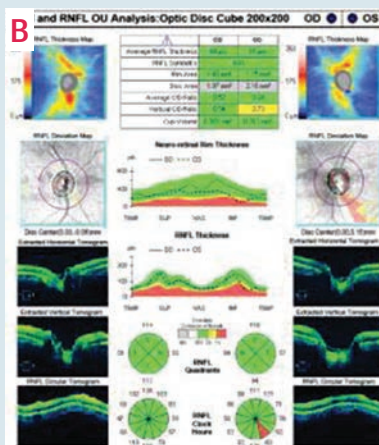
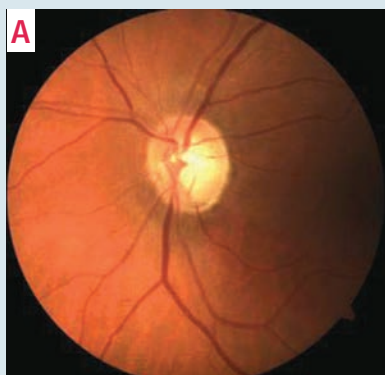
*Drs. Lifferth, Fisher, Cordes, Carter and Perkins are attending optometrists at The Villages VA Outpatient Clinic, in Fla.*

## Dr. Stursma is an attending optometrist at the Ocala Community Based VA Outpatient Clinic in Ocala, Fla.

1. Khoury J, Donahue S, Lavin P, Tsai J. Comparison of 24-2 and 30-2 perimetry in glaucomatous and nonglaucomatous optic neuropathies. *J Neuroophthalmol.* 1999;19(2):100-8.
2. Hejji A, Bengtsson B, Chauhan B, et al. A comparison of visual field progression criteria of 3 major glaucoma trials in early manifest glaucoma trial patients. *Ophthalmology.* 2008;115(9):1557-65.
3. Schira MM, Wade AR, Tyler CW. Two-dimensional mapping of the central and parafoveal visual field to human visual cortex. *J Neurophysiol.* 2007;97(6):4284-95.
4. Traynis I, de Moraes CG, Raza AS, et al. Prevalence and nature of early glaucomatous defects in the central 10 degrees of the visual field. *JAMA Ophthalmol.* 2014;132(3):291-97.
5. Hangai M, Ikeda H, Akagi T, et al. Paracentral scotoma in glaucoma detected by 10-2 but not by 24-2 perimetry. *Jpn J Ophthalmol.* 2014;58(2):188-96.
6. de Moraes C, Liebmann J, Medeiros F, et al. Management of advanced glaucoma: characterization and monitoring. *Surv Ophthalmol.* 2016;61(5):597-615.
7. Hood D, Slobodnick A, Raza A, et al. Early glaucoma involves both deep local, and shallow widespread, retinal nerve fiber damage of the macular region. *Invest Ophthalmol Vis Sci.* 2014;55(2):632-49.
8. Schiefer U, Papageorgiou E, Sample PA, et al. Spatial pattern of glaucomatous visual field loss obtained with regionally condensed stimulus arrangements. *Invest Ophthalmol Vis Sci.* 2010;51(11):5685-9.
9. Teixeira IC, Bresciani-Battilana E, Barbosa D, et al. Correlation between the ganglion cell complex and functional measures in glaucoma patients and suspects. *Int Ophthalmol.* 2015;35:81-7.
10. Langerhorst C, Carenini L, Bakker D, et al. Measurements for description of very early glaucomatous field defects. In: Wall M, Hejji A, eds. *Perimetry Update 1996/1997.* New York, NY: Kugler Publications;1997:67-73.
11. Hood DC, Raza AS, de Moraes CG, et al. Initial arcuate defects within the central 10 degrees in glaucoma. *Invest Ophthalmol Vis Sci.* 2011;52(2):940-6.
12. de Moraes C, Hood D, Liebmann J, et al. 24-2 visual fields miss central defects shown on 10-2 tests in glaucoma suspects, ocular hypertensives, and early glaucoma. *Ophthalmology.* May 24, 2017. [Epub ahead of print].
13. Park H, Hwang B, Shin H, et al. Clinical clues to predict the presence of parafoveal scotoma on Humphrey 10-2 visual field using a Humphrey 24-2 visual field. *Am J Ophthalmol.* 2016 Jan;161:150-9.
14. Brusini P, Johnson C. Staging functional damage in glaucoma: review of different classification methods. *Surv Ophthalmol.* 2007;52(2):156-79.
15. Weinreb RN, Garway-Heath DF, Leung C, et al, eds. *Progression of Glaucoma: The 8th Consensus Report of the World Glaucoma Association.* Amsterdam: Kugler Publications; 2011:15.
16. Rao HL, Begum VU, Khadka D, et al. Comparing glaucoma progression on 24-2 and 10-2 Visual field examinations. *PLoS One.* 2015;10(5):e0127233.
17. Zalta A. Use of a central 10 degrees field and size V stimulus to evaluate and monitor small central islands of vision in end stage glaucoma. *Br J Ophthalmol.* 1991;75(3):151-4.
18. Park S, Kung Y, Ritch R, et al. Parafoveal scotoma progression in glaucoma: Humphrey 10-2 versus 24-2 visual field analysis. *Ophthalmol.* 2013;120(8):1546-50.




### Case 5

Despite relatively mild inferior temporal neuroretinal rim loss in this patient's right eye (A) with confirmed RNFL loss on OCT (B), and regardless of the status of the rest of the visual field, this patient has advanced visual field loss on 24-2 visual field testing (C). Due to this deep central involvement, 10-2 visual field testing is critical to better understand the significance of this defect and monitor for progression (D).



### Case 6

This patient presented with severe inferior temporal glaucomatous structural damage and has a corresponding superior central and paracentral 24-2 VF defect (A). Central 10-2 testing reveals the extent of this defect and better highlights the possible progression that likely would have been underestimated or missed on 24-2 testing alone (B and C).





## Classic beta blocker adjunctive therapy for the right patient at the right time<sup>3</sup>

The concomitant use of two topical beta-adrenergic blocking agents is not recommended<sup>4,5</sup>

### Indications and Usage

ISTALOL® (timolol maleate ophthalmic solution) is a non-selective beta-adrenergic receptor blocking agent indicated in the treatment of elevated intraocular pressure in patients with ocular hypertension or open-angle glaucoma.

Preservative-free TIMOPTIC® (timolol maleate ophthalmic solution) in OCUDOSE® (dispenser) is indicated in the treatment of elevated intraocular pressure in patients with ocular hypertension or open-angle glaucoma. It may be used when a patient is sensitive to the preservative in TIMOPTIC (timolol maleate ophthalmic solution), benzalkonium chloride, or when use of a preservative-free topical medication is advisable.

### Important Safety Information for Istalol® and Timoptic® in Ocusdose®

- Both ISTALOL® (timolol maleate ophthalmic solution) and TIMOPTIC® (timolol maleate ophthalmic solution) in OCUDOSE® (dispenser) are contraindicated in patients with: bronchial asthma; a history of bronchial asthma; severe chronic obstructive pulmonary disease; sinus bradycardia; second or third degree atrioventricular block; overt cardiac failure; cardiogenic shock; hypersensitivity to any component of the product.
- **The same adverse reactions found with systemic administration of beta-adrenergic blocking agents may occur with topical administration. Severe respiratory reactions and cardiac reaction, including death due to bronchospasm in patients with asthma, and rarely death in association with cardiac failure, have been reported following systemic or ophthalmic administration of timolol maleate.**
- Patients with a history of atopy or severe anaphylactic reactions to a variety of allergens may be unresponsive to the usual doses of epinephrine used to treat anaphylactic reactions.
- Timolol has been reported rarely to increase muscle weakness in some patients with myasthenia gravis or myasthenic symptoms.
- Beta-adrenergic blocking agents may mask signs and symptoms of acute hypoglycemia or certain clinical signs of hyperthyroidism. Patients subject to spontaneous hypoglycemia, or diabetic patients receiving either insulin or oral hypoglycemic agents, or patients suspected of developing thyrotoxicosis, should be managed carefully, with caution.
- In patients undergoing elective surgery, some authorities recommend gradual withdrawal of beta adrenergic receptor blocking agents because these agents impair the ability of the heart to respond to beta-adrenergically mediated reflex stimuli.
- The most frequently reported adverse reactions have been burning and stinging upon instillation. This was seen in 38% of patients treated with ISTALOL and in approximately one in eight patients treated with TIMOPTIC in OCUDOSE. Additional reactions reported with ISTALOL at a frequency of 4 to 10% include: blurred vision, cataract, conjunctival injection, headache, hypertension, infection, itching and decreased visual acuity.

Please see Brief Summary of Prescribing Information for ISTALOL and TIMOPTIC in OCUDOSE on the following pages.

For the patients who need incremental IOP reduction in a preservative free form<sup>6</sup>



For the patients who need incremental IOP reduction in a once a day form<sup>6</sup>

**Istalol®**  
(timolol maleate  
ophthalmic solution) 0.5%

**References:** 1. Alm A, Stjernschantz J. Effects on Intraocular Pressure and Side Effects of 0.005% Latanoprost Applied Once Daily, Evening or Morning. *Ophthalmology*. 1995;102:1743-1752. 2. Brubaker R. Flow of Aqueous Humor in Humans. *IOVS*. 1991;32(13):3145-3166. 3. Obstbaum S, Cioffi GA, Kriegstein GK, et al. Gold Standard Medical Therapy for Glaucoma: Defining the Criteria Identifying Measures for an Evidence-Based Analysis. *Clin Ther*. 2004;26(12):2102-2119. 4. Istalol [package insert]. Bridgewater, NJ: Bausch & Lomb Incorporated; 2013. 5. Timoptic in Ocusdose [package insert]. Lawrenceville, NJ: Aton Pharma; 2009. 6. Stewart W, Day DG, Sharpe ED. Efficacy and Safety of Timolol Solution Once Daily vs Timolol Gel Added to Latanoprost. *Am J Ophthalmol*. 1999;128(6):692-696.

Timoptic and Ocusdose are trademarks of Valeant Pharmaceuticals International, Inc. or its affiliates. Bausch + Lomb and Istalol are trademarks of Bausch & Lomb Incorporated or its affiliates.

**BAUSCH + LOMB**

©Bausch & Lomb Incorporated.

US/TOP/14/0017(1)

## BRIEF SUMMARY OF PRESCRIBING INFORMATION

This Brief Summary does not include all the information needed to use ISTALOL® (timolol maleate ophthalmic solution) 0.5% safely and effectively. See full prescribing information for ISTALOL.

## Istalol® (timolol maleate ophthalmic solution) 0.5%

Initial U.S. Approval: 1978

### STERILE

### INDICATIONS AND USAGE

Istalol (timolol maleate ophthalmic solution) 0.5% is a non-selective beta-adrenergic receptor blocking agent indicated in the treatment of elevated intraocular pressure (IOP) in patients with ocular hypertension or open-angle glaucoma.

### CONTRAINDICATIONS

**4.1 Asthma, COPD:** Istalol is contraindicated in patients with bronchial asthma; a history of bronchial asthma; severe chronic obstructive pulmonary disease (see **WARNINGS AND PRECAUTIONS**, 5.1, 5.3).

**4.2 Sinus Bradycardia, AV Block, Cardiac Failure, Cardiogenic Shock:** Istalol is contraindicated in patients with sinus bradycardia; second or third degree atrioventricular block; overt cardiac failure; cardiogenic shock (see **WARNINGS AND PRECAUTIONS**, 5.2).

**4.3 Hypersensitivity Reactions:** Istalol is contraindicated in patients who have exhibited a hypersensitivity reaction to any component of this product in the past.

### WARNINGS AND PRECAUTIONS

**5.1 Potentiation of Respiratory Reactions Including Asthma:** Istalol contains timolol maleate; and although administered topically, it can be absorbed systemically. Therefore, the same adverse reactions found with systemic administration of beta-adrenergic blocking agents may occur with topical administration. For example, severe respiratory reactions and cardiac reactions including death due to bronchospasm in patients with asthma, and rarely death in association with cardiac failure, have been reported following systemic or ophthalmic administration of timolol maleate (see **CONTRAINDICATIONS**, 4.1).

**5.2 Cardiac Failure:** Sympathetic stimulation may be essential for support of the circulation in individuals with diminished myocardial contractility, and its inhibition of beta-adrenergic receptor blockade may precipitate more severe failure. In patients without a history of cardiac failure, continued depression of the myocardium with beta-blocking agents over a period of time can, in some cases, lead to cardiac failure. At the first sign or symptom of cardiac failure, Istalol should be discontinued (see **CONTRAINDICATIONS**, 4.2).

**5.3 Obstructive Pulmonary Disease:** Patients with chronic obstructive pulmonary disease (e.g., chronic bronchitis, emphysema) of mild or moderate severity, bronchospastic disease, or a history of bronchospastic disease [other than bronchial asthma or a history of bronchial asthma in which Istalol is contraindicated] should, in general, not receive beta-blocking agents, including Istalol.

**5.4 Increased Reactivity to Allergens:** While taking beta-blockers, patients with a history of atopy or a history of severe anaphylactic reactions to a variety of allergens may be more reactive to repeated accidental, diagnostic, or therapeutic challenge with such allergens. Such patients may be unresponsive to the usual doses of epinephrine used to treat anaphylactic reactions.

**5.5 Potentiation of Muscle Weakness:** Beta-adrenergic blockade has been reported to potentiate muscle weakness consistent with certain myasthenic symptoms (e.g., diplopia, ptosis, and generalized weakness). Timolol has been reported rarely to increase muscle weakness in some patients with myasthenia gravis or myasthenic symptoms.

**5.6 Masking of Hypoglycemic Symptoms in Patients with Diabetes Mellitus:** Beta-adrenergic blocking agents should be administered with caution in patients subject to spontaneous hypoglycemia or to diabetic patients (especially those with labile diabetes) who are receiving insulin or oral hypoglycemic agents. Beta-adrenergic receptor blocking agents may mask the signs and symptoms of acute hypoglycemia.

**5.7 Masking of Thyrotoxicosis:** Beta-adrenergic blocking agents may mask certain clinical signs (e.g., tachycardia) of hyperthyroidism. Patients suspected of developing thyrotoxicosis should be managed carefully to avoid abrupt withdrawal of beta-adrenergic blocking agents that might precipitate a thyroid storm.

**5.8 Contamination of Topical Ophthalmic Products After Use:** There have been reports of bacterial keratitis associated with the use of multiple-dose containers of topical ophthalmic products. These containers had been inadvertently contaminated by patients who, in most cases, had a concurrent corneal disease or a disruption of the ocular epithelial surface (see **PATIENT COUNSELING INFORMATION**, 17).

**5.9 Impairment of Beta-adrenergically Mediated Reflexes During Surgery:** The necessity or desirability of withdrawal of beta-adrenergic blocking agents prior to major surgery is controversial. Beta-adrenergic receptor blockade impairs the ability of the heart to respond to beta-adrenergically mediated reflex stimuli. This may augment the risk of general anesthesia in surgical procedures. Some patients receiving beta-adrenergic receptor blocking agents have experienced protracted severe hypotension during anesthesia. Difficulty in restarting and maintaining the heartbeat has also been reported. For these reasons, in patients undergoing elective surgery, some authorities recommend gradual withdrawal of beta-adrenergic receptor blocking agents. If necessary during surgery, the effects of beta-adrenergic blocking agents may be reversed by sufficient doses of adrenergic agonists.

**5.10 Angle-Closure Glaucoma:** In patients with angle-closure glaucoma, the immediate objective of treatment is to reopen the angle. This may require constricting the pupil. Timolol maleate has little or no effect on the pupil. Istalol should not be used alone in the treatment of angle-closure glaucoma.

**5.11 Cerebrovascular Insufficiency:** Because of potential effects of beta-adrenergic blocking agents on blood pressure and pulse, these agents should be used with caution in patients with cerebrovascular insufficiency. If signs or

symptoms suggesting reduced cerebral blood flow develop following initiation of therapy with Istalol, alternative therapy should be considered.

**5.12 Choroidal Detachment:** Choroidal detachment after filtration procedures has been reported with the administration of aqueous suppressant therapy (e.g., timolol).

### ADVERSE REACTIONS

**6.1 Clinical Trials Experience:** Because clinical trials are conducted under widely varying conditions, adverse reaction rates observed in the clinical trials of a drug cannot be directly compared to rates in the clinical trials of another drug and may not reflect the rates observed in practice.

The most frequently reported adverse reactions have been burning and stinging upon instillation in 38% of patients treated with Istalol. Additional reactions reported with Istalol at a frequency of 4 to 10% include: blurred vision, cataract, conjunctival injection, headache, hypertension, infection, itching and decreased visual acuity. The following additional adverse reactions have been reported less frequently with ocular administration of this or other timolol maleate formulations.

**Timolol (Ocular Administration):** *Body as a whole:* Asthenia/fatigue and chest pain; *Cardiovascular:* Bradycardia, arrhythmia, hypotension, syncope, heart block, cerebral vascular accident, cerebral ischemia, cardiac failure, worsening of angina pectoris, palpitation, cardiac arrest, pulmonary edema, edema, claudication, Raynaud's phenomenon and cold hands and feet; *Digestive:* Nausea, diarrhea, dyspepsia, anorexia, and dry mouth; *Immunologic:* Systemic lupus erythematosus; *Nervous System/Psychiatric:* Dizziness, increase in signs and symptoms of myasthenia gravis, paresthesia, somnolence, insomnia, nightmares, behavioral changes and psychic disturbances including depression, confusion, hallucinations, anxiety, disorientation, nervousness and memory loss; *Skin:* Alopecia and psoriasisiform rash or exacerbation of psoriasis; *Hypersensitivity:* Signs and symptoms of systemic allergic reactions, including angioedema, urticaria, and localized and generalized rash; *Respiratory:* Bronchospasm (predominantly in patients with pre-existing bronchospastic disease), respiratory failure, dyspnea, nasal congestion, cough and upper respiratory infections; *Endocrine:* Masked symptoms of hypoglycemia in diabetic patients (see **WARNINGS AND PRECAUTIONS**, 5.6); *Special Senses:* Signs and symptoms of ocular irritation including conjunctivitis, blepharitis, keratitis, ocular pain, discharge (e.g., crusting), foreign body sensation, itching and tearing, and dry eyes; ptosis, decreased corneal sensitivity; cystoid macular edema; visual disturbances including refractive changes and diplopia; pseudophthalmos; choroidal detachment following filtration surgery (see **WARNINGS AND PRECAUTIONS**, 5.12); *Urogenital:* Retroperitoneal fibrosis, decreased libido, impotence, and Peyronie's disease.

### 6.2 Postmarketing Experience

**Oral Timolol/Oral Beta-blockers:** The following additional adverse effects have been reported in clinical experience with ORAL timolol maleate or other ORAL beta-blocking agents and may be considered potential effects of ophthalmic timolol maleate: *Allergic:* Erythematous rash, fever combined with aching and sore throat, laryngospasm with respiratory distress; *Body as a Whole:* Extremity pain, decreased exercise tolerance, weight loss; *Cardiovascular:* Worsening of arterial insufficiency, vasodilatation; *Digestive:* Gastrointestinal pain, hepatomegaly, vomiting, mesenteric arterial thrombosis, ischemic colitis; *Hematologic:* Nonthrombocytopenic purpura; thrombocytopenic purpura, agranulocytosis; *Endocrine:* Hyperglycemia, hypoglycemia; *Skin:* Pruritus, skin irritation, increased pigmentation, sweating; *Musculoskeletal:* Arthralgia; *Nervous System/Psychiatric:* Vertigo, local weakness, diminished concentration, reversible mental depression progressing to catatonia, an acute reversible syndrome characterized by disorientation for time and place, emotional lability, slightly clouded sensorium and decreased performance on neuropsychometrics; *Respiratory:* Rales, bronchial obstruction; *Urogenital:* Urination difficulties.

### DRUG INTERACTIONS

**7.1 Beta-Adrenergic Blocking Agents:** Patients who are receiving a beta-adrenergic blocking agent orally and Istalol® should be observed for potential additive effects of beta-blockade, both systemic and on intraocular pressure. The concomitant use of two topical beta-adrenergic blocking agents is not recommended.

**7.2 Calcium Antagonists:** Caution should be used in the co-administration of beta-adrenergic blocking agents, such as Istalol, and oral or intravenous calcium antagonists because of possible atrioventricular conduction disturbances, left ventricular failure, and hypotension. In patients with impaired cardiac function, co-administration should be avoided.

**7.3 Catecholamine-Depleting Drugs:** Close observation of the patient is recommended when a beta blocker is administered to patients receiving catecholamine-depleting drugs such as reserpine, because of possible additive effects and the production of hypotension and/or marked bradycardia, which may result in vertigo, syncope, or postural hypotension.

**7.4 Digitalis and Calcium Antagonists:** The concomitant use of beta-adrenergic blocking agents with digitalis and calcium antagonists may have additive effects in prolonging atrioventricular conduction time.

**7.5 CYP2D6 Inhibitors:** Potentiated systemic beta-blockade (e.g., decreased heart rate) has been reported during combined treatment with CYP2D6 inhibitors (e.g., quinidine) and timolol.

**7.6 Clonidine:** Oral beta-adrenergic blocking agents may exacerbate the rebound hypertension which can follow the withdrawal of clonidine. There have been no reports of exacerbation of rebound hypertension with ophthalmic timolol maleate.

### USE IN SPECIFIC POPULATIONS

#### 8.1 Pregnancy

**Teratogenic Effects:** Pregnancy Category C: Teratogenicity studies have been performed in animals. Teratogenicity studies with timolol in mice, rats, and rabbits at oral doses up to 50 mg/kg/day (7,000 times the systemic exposure following the maximum recommended human ophthalmic dose) demonstrated no evidence of fetal malformations. Although delayed fetal ossification was observed at this dose

in rats, there were no adverse effects on postnatal development of offspring. Doses of 1000 mg/kg/day (142,000 times the systemic exposure following the maximum recommended human ophthalmic dose) were maternotoxic in mice and resulted in an increased number of fetal resorptions. Increased fetal resorptions were also seen in rabbits at doses of 14,000 times the systemic exposure following the maximum recommended human ophthalmic dose, in this case without apparent maternotoxicity. There are no adequate and well-controlled studies in pregnant women. Istalol should be used during pregnancy only if the potential benefit justifies the potential risk to the fetus.

**8.3 Nursing Mothers:** Timolol has been detected in human milk following oral and ophthalmic drug administration. Because of the potential for serious adverse reactions from Istalol in nursing infants, a decision should be made whether to discontinue nursing or to discontinue the drug, taking into account the importance of the drug to the mother.

**8.4 Pediatric Use:** Safety and effectiveness in pediatric patients have not been established.

**8.5 Geriatric Use:** No overall differences in safety or effectiveness have been observed between elderly and younger patients.

### OVERDOSAGE

There have been reports of inadvertent overdosage with Istalol resulting in systemic effects similar to those seen with systemic beta-adrenergic blocking agents such as dizziness, headache, shortness of breath, bradycardia, bronchospasm, and cardiac arrest. An *in vitro* hemodialysis study, using <sup>14</sup>C timolol added to human plasma or whole blood, showed that timolol was readily dialyzed from these fluids; however, a study of patients with renal failure showed that timolol did not dialyze readily.

### NONCLINICAL TOXICOLOGY

**13.1 Carcinogenesis, Mutagenesis, Impairment of Fertility:** In a two-year study of timolol maleate administered orally to rats, there was a statistically significant increase in the incidence of adrenal pheochromocytomas in male rats administered 300 mg/kg/day (approximately 42,000 times the systemic exposure following the maximum recommended human ophthalmic dose). Similar differences were not observed in rats administered oral doses equivalent to approximately 14,000 times the maximum recommended human ophthalmic dose. In a lifetime oral study in mice, there were statistically significant increases in the incidence of benign and malignant pulmonary tumors, benign uterine polyps and mammary adenocarcinomas in female mice at 500 mg/kg/day, (approximately 71,000 times the systemic exposure following the maximum recommended human ophthalmic dose), but not at 5 or 50 mg/kg/day (approximately 700 or 7,000, respectively, times the systemic exposure following the maximum recommended human ophthalmic dose). In a subsequent study in female mice, in which post-mortem examinations were limited to the uterus and the lungs, a statistically significant increase in the incidence of pulmonary tumors was again observed at 500 mg/kg/day. The increased occurrence of mammary adenocarcinomas was associated with elevations in serum prolactin which occurred in female mice administered oral timolol at 500 mg/kg/day, but not at doses of 5 or 50 mg/kg/day. An increased incidence of mammary adenocarcinomas in rodents has been associated with administration of several other therapeutic agents that elevate serum prolactin, but no correlation between serum prolactin levels and mammary tumors has been established in humans. Furthermore, in adult human female subjects who received oral dosages of up to 60 mg of timolol maleate (the maximum recommended human oral dosage), there were no clinically meaningful changes in serum prolactin. Timolol maleate was devoid of mutagenic potential when tested *in vivo* (mouse) in the micronucleus test and cytogenetic assay (doses up to 800 mcg/kg) and *in vitro* in a neoplastic cell transformation assay (up to 100 mcg/mL). In Ames tests the highest concentrations of timolol employed, 5,000 or 10,000 mcg/plate, were associated with statistically significant elevations of revertants observed with tester strain TA100 (in seven replicate assays), but not in the remaining three strains. In the assays with tester strain TA100, no consistent dose response relationship was observed, and the ratio of test to control revertants did not reach 2. A ratio of 2 is usually considered the criterion for a positive Ames test. Reproduction and fertility studies in rats demonstrated no adverse effect on male or female fertility at doses up to 21,000 times the systemic exposure following the maximum recommended human ophthalmic dose.

### PATIENT COUNSELING INFORMATION

Patients with bronchial asthma, a history of bronchial asthma, severe chronic obstructive pulmonary disease, sinus bradycardia, second or third degree atrioventricular block, or cardiac failure should be advised not to take this product. (see **CONTRAINDICATIONS**, 4.1, 4.2) Patients should also be instructed that ocular solutions, if handled improperly or if the tip of the dispensing container contacts the eye or surrounding structures, can become contaminated by common bacteria known to cause ocular infections. Serious damage to the eye and subsequent loss of vision may result from using contaminated solutions. (see **WARNINGS AND PRECAUTIONS** 5.8) Patients should also be advised that if they have ocular surgery or develop an intercurrent ocular condition (e.g., trauma or infection), they should immediately seek their physician's advice concerning the continued use of the present multidose container. If more than one topical ophthalmic drug is being used, the drugs should be administered at least five minutes apart. Patients should be advised that Istalol® contains benzalkonium chloride which may be absorbed by soft contact lenses. Contact lenses should be removed prior to administration of the solution. Lenses may be reinserted 15 minutes following Istalol® administration.

### Rx Only

Distributed by:  
Bausch + Lomb, a division of Valeant Pharmaceuticals North America LLC Bridgewater, NJ 08807 USA

Under License from:

SENJU Pharmaceutical Co., Ltd

Osaka, Japan 541-0046

Istalol is a trademark of Bausch + Lomb Incorporated or its affiliates.

© Bausch + Lomb Incorporated

## BRIEF SUMMARY OF PRESCRIBING INFORMATION

This Brief Summary does not include all the information needed to use TIMOPTIC® 0.25% AND 0.5% (timolol maleate ophthalmic solution) in OCUDOSE® (DISPENSER) safely and effectively. See full prescribing information for TIMOPTIC in OCUDOSE.

PRESERVATIVE-FREE STERILE OPHTHALMIC SOLUTION in a Sterile Ophthalmic Unit Dose Dispenser

# TIMOPTIC® 0.25% AND 0.5% (TIMOLOL MALEATE OPHTHALMIC SOLUTION) in OCUDOSE® (DISPENSER)

## INDICATIONS AND USAGE

Preservative-free TIMOPTIC in OCUDOSE is indicated in the treatment of elevated intraocular pressure in patients with ocular hypertension or open-angle glaucoma.

Preservative-free TIMOPTIC in OCUDOSE may be used when a patient is sensitive to the preservative in TIMOPTIC (timolol maleate ophthalmic solution), benzalkonium chloride, or when use of a preservative-free topical medication is advisable.

## CONTRAINDICATIONS

Preservative-free TIMOPTIC in OCUDOSE is contraindicated in patients with (1) bronchial asthma; (2) a history of bronchial asthma; (3) severe chronic obstructive pulmonary disease (see WARNINGS); (4) sinus bradycardia; (5) second or third degree atrioventricular block; (6) overt cardiac failure (see WARNINGS); (7) cardiogenic shock or (8) hypersensitivity to any component of this product.

## WARNINGS

As with many topically applied ophthalmic drugs, this drug is absorbed systemically.

**The same adverse reactions found with systemic administration of beta-adrenergic blocking agents may occur with topical administration. For example, severe respiratory reactions and cardiac reactions, including death due to bronchospasm in patients with asthma, and rarely death in association with cardiac failure, have been reported following systemic or ophthalmic administration of timolol maleate (see CONTRAINDICATIONS).**

**Cardiac Failure:** Sympathetic stimulation may be essential for support of the circulation in individuals with diminished myocardial contractility, and its inhibition by beta-adrenergic receptor blockade may precipitate more severe failure.

**In Patients Without a History of Cardiac Failure:** continued depression of the myocardium with beta-blocking agents over a period of time can, in some cases, lead to cardiac failure. At the first sign or symptom of cardiac failure, Preservative-free TIMOPTIC in OCUDOSE should be discontinued.

**Obstructive Pulmonary Disease:** Patients with chronic obstructive pulmonary disease (e.g., chronic bronchitis, emphysema) of mild or moderate severity, bronchospastic disease, or a history of bronchospastic disease (other than bronchial asthma or a history of bronchial asthma, in which TIMOPTIC in OCUDOSE is contraindicated (see CONTRAINDICATIONS)) should, in general, not receive beta-blockers, including Preservative-free TIMOPTIC in OCUDOSE.

**Major Surgery:** The necessity or desirability of withdrawal of beta-adrenergic blocking agents prior to major surgery is controversial. Beta-adrenergic receptor blockade impairs the ability of the heart to respond to beta-adrenergically mediated reflex stimuli. This may augment the risk of general anesthesia in surgical procedures. Some patients receiving beta-adrenergic receptor blocking agents have experienced protracted severe hypotension during anesthesia. Difficulty in restarting and maintaining the heartbeat has also been reported. For these reasons, in patients undergoing elective surgery, some authorities recommend gradual withdrawal of beta-adrenergic receptor blocking agents.

If necessary during surgery, the effects of beta-adrenergic blocking agents may be reversed by sufficient doses of adrenergic agonists.

**Diabetes Mellitus:** Beta-adrenergic blocking agents should be administered with caution in patients subject to spontaneous hypoglycemia or to diabetic patients (especially those with labile diabetes) who are receiving insulin or oral hypoglycemic agents. Beta-adrenergic receptor blocking agents may mask the signs and symptoms of acute hypoglycemia.

**Thyrotoxicosis:** Beta-adrenergic blocking agents may mask certain clinical signs (e.g., tachycardia) of hyperthyroidism. Patients suspected of developing thyrotoxicosis should be managed carefully to avoid abrupt withdrawal of beta-adrenergic blocking agents that might precipitate a thyroid storm.

## PRECAUTIONS

**General:** Because of potential effects of beta-adrenergic blocking agents on blood pressure and pulse, these agents should be used with caution in patients with cerebrovascular insufficiency. If signs or symptoms suggesting reduced cerebral blood flow develop following initiation of therapy with Preservative-free TIMOPTIC in OCUDOSE, alternative therapy should be considered.

Choroidal detachment after filtration procedures has been reported with the administration of aqueous suppressant therapy (e.g., timolol).

**Angle-closure glaucoma:** In patients with angle-closure glaucoma, the immediate objective of treatment is to reopen the angle. This requires constricting the pupil. Timolol maleate has little or no effect on the pupil. TIMOPTIC in OCUDOSE should not be used alone in the treatment of angle-closure glaucoma.

**Anaphylaxis:** While taking beta-blockers, patients with a history of atopy or a history of severe anaphylactic reactions to a variety of allergens may be more reactive to repeated accidental, diagnostic, or therapeutic challenge with such allergens. Such patients may be unresponsive to the usual doses of epinephrine used to treat anaphylactic reactions.

**Muscle Weakness:** Beta-adrenergic blockade has been reported to potentiate muscle weakness consistent with certain myasthenic symptoms (e.g., diplopia, ptosis, and generalized weakness). Timolol has been reported rarely to increase muscle weakness in some patients with myasthenia gravis or myasthenic symptoms.

**Information for Patients:** Patients should be instructed about the use of Preservative-free TIMOPTIC in OCUDOSE.

Since sterility cannot be maintained after the individual unit is opened, patients should be instructed to use the product immediately after opening, and to discard the individual unit and any remaining contents immediately after use.

Patients with bronchial asthma, a history of bronchial asthma, severe chronic obstructive pulmonary disease, sinus bradycardia, second or third degree

atrioventricular block, or cardiac failure should be advised not to take this product. (See CONTRAINDICATIONS.)

**Drug Interactions:** Although TIMOPTIC (timolol maleate ophthalmic solution) used alone has little or no effect on pupil size, mydriasis resulting from concomitant therapy with TIMOPTIC (timolol maleate ophthalmic solution) and epinephrine has been reported occasionally.

**Beta-adrenergic blocking agents:** Patients who are receiving a beta-adrenergic blocking agent orally and Preservative-free TIMOPTIC in OCUDOSE should be observed for potential additive effects of beta-blockade, both systemic and on intraocular pressure. The concomitant use of two topical beta-adrenergic blocking agents is not recommended.

**Calcium antagonists:** Caution should be used in the coadministration of beta-adrenergic blocking agents, such as Preservative-free TIMOPTIC in OCUDOSE, and oral or intravenous calcium antagonists, because of possible atrioventricular conduction disturbances, left ventricular failure, and hypotension. In patients with impaired cardiac function, coadministration should be avoided.

**Catecholamine-depleting drugs:** Close observation of the patient is recommended when a beta blocker is administered to patients receiving catecholamine-depleting drugs such as reserpine, because of possible additive effects and the production of hypotension and/or marked bradycardia, which may result in vertigo, syncope, or postural hypotension.

**Digitalis and calcium antagonists:** The concomitant use of beta-adrenergic blocking agents with digitalis and calcium antagonists may have additive effects in prolonging atrioventricular conduction time.

**CYP2D6 inhibitors:** Potentiated systemic beta-blockade (e.g., decreased heart rate, depression) has been reported during combined treatment with CYP2D6 inhibitors (e.g., quinidine, SSRIs) and timolol.

**Clonidine:** Oral beta-adrenergic blocking agents may exacerbate the rebound hypertension which can follow the withdrawal of clonidine. There have been no reports of exacerbation of rebound hypertension with ophthalmic timolol maleate.

**Injectable epinephrine:** (See PRECAUTIONS, General, Anaphylaxis)

**Carcinogenesis, Mutagenesis, Impairment of Fertility:** In a two-year oral study of timolol maleate administered orally to rats, there was a statistically significant increase in the incidence of adrenal pheochromocytomas in male rats administered 300 mg/kg/day (approximately 42,000 times the systemic exposure following the maximum recommended human ophthalmic dose). Similar differences were not observed in rats administered oral doses equivalent to approximately 14,000 times the maximum recommended human ophthalmic dose.

In a lifetime oral study in mice, there were statistically significant increases in the incidence of benign and malignant pulmonary tumors, benign uterine polyps and mammary adenocarcinomas in female mice at 500 mg/kg/day (approximately 71,000 times the systemic exposure following the maximum recommended human ophthalmic dose), but not at 5 or 50 mg/kg/day (approximately 700 or 7,000 times, respectively), the systemic exposure following the maximum recommended human ophthalmic dose. In a subsequent study in female mice, in which post-mortem examinations were limited to the uterus and the lungs, a statistically significant increase in the incidence of pulmonary tumors was again observed at 500 mg/kg/day.

The increased occurrence of mammary adenocarcinomas was associated with elevations in serum prolactin which occurred in female mice administered oral timolol at 500 mg/kg/day, but not at doses of 5 or 50 mg/kg/day. An increased incidence of mammary adenocarcinomas in rodents has been associated with administration of several other therapeutic agents that elevate serum prolactin, but no correlation between serum prolactin levels and mammary tumors has been established in humans. Furthermore, in adult human female subjects who received oral dosages of up to 60 mg of timolol maleate (the maximum recommended human oral dosage), there were no clinically meaningful changes in serum prolactin.

Timolol maleate was devoid of mutagenic potential when tested *in vivo* (mouse) in the micronucleus test and cytogenetic assay (doses up to 800 mg/kg) and *in vitro* in a neoplastic cell transformation assay (up to 100 mcg/mL). In Ames tests the highest concentrations of timolol employed, 5,000 or 10,000 mcg/plate, were associated with statistically significant elevations of revertants observed with tester strain TA100 (in seven replicate assays), but not in the remaining three strains. In the assays with tester strain TA100, no consistent dose response relationship was observed, and the ratio of test to control revertants did not reach 2. A ratio of 2 is usually considered the criterion for a positive Ames test.

Reproduction and fertility studies in rats demonstrated no adverse effect on male or female fertility at doses up to 21,000 times the systemic exposure following the maximum recommended human ophthalmic dose.

**Pregnancy: Teratogenic Effects — Pregnancy Category C.** Teratogenicity studies with timolol in mice, rats and rabbits at oral doses up to 50 mg/kg/day (7,000 times the systemic exposure following the maximum recommended human ophthalmic dose) demonstrated no evidence of fetal malformations. Although delayed fetal ossification was observed at this dose in rats, there were no adverse effects on postnatal development of offspring. Doses of 1000 mg/kg/day (142,000 times the systemic exposure following the maximum recommended human ophthalmic dose) were maternotoxic in mice and resulted in an increased number of fetal resorptions. Increased fetal resorptions were also seen in rabbits at doses of 14,000 times the systemic exposure following the maximum recommended human ophthalmic dose, in this case without apparent maternotoxicity.

There are no adequate and well-controlled studies in pregnant women. Preservative-free TIMOPTIC in OCUDOSE should be used during pregnancy only if the potential benefit justifies the potential risk to the fetus.

**Nursing Mothers:** Timolol maleate has been detected in human milk following oral and ophthalmic drug administration. Because of the potential for serious adverse reactions from timolol in nursing infants, a decision should be made whether to discontinue nursing or to discontinue the drug, taking into account the importance of the drug to the mother.

**Pediatric Use:** Safety and effectiveness in pediatric patients have not been established.

**Geriatric Use:** No overall differences in safety or effectiveness have been observed between elderly and younger patients.

## ADVERSE REACTIONS

The most frequently reported adverse experiences have been burning and stinging upon instillation (approximately one in eight patients).

The following additional adverse experiences have been reported less frequently with ocular administration of this or other timolol maleate formulations:

**BODY AS A WHOLE:** Headache, asthenia/fatigue, and chest pain.

**CARDIOVASCULAR:** Bradycardia, arrhythmia, hypotension, hypertension, syncope, heart block, cerebral vascular accident, cerebral ischemia, cardiac failure, worsening of angina pectoris, palpitation, cardiac arrest, pulmonary edema, edema, claudication, Raynaud's

phenomenon, and cold hands and feet.

**DIGESTIVE:** Nausea, diarrhea, dyspepsia, anorexia, and dry mouth.

**IMMUNOLOGIC:** Systemic lupus erythematosus.

**NERVOUS SYSTEM/PSYCHIATRIC:** Dizziness, increase in signs and symptoms of myasthenia gravis, paresthesia, somnolence, insomnia, nightmares, behavioral changes and psychic disturbances including depression, confusion, hallucinations, anxiety, disorientation, nervousness, and memory loss.

**SKIN:** Alopecia and psoriasisiform rash or exacerbation of psoriasis.

**HYPERSENSITIVITY:** Signs and symptoms of systemic allergic reactions including

anaphylaxis, angioedema, urticaria, and localized and generalized rash.

**RESPIRATORY:** Bronchospasm (predominantly in patients with pre-existing bronchospastic disease), respiratory failure, dyspnea, nasal congestion, cough and upper respiratory infections.

**ENDOCRINE:** Masked symptoms of hypoglycemia in diabetic patients (see WARNINGS).

**SPECIAL SENSES:** Signs and symptoms of ocular irritation including conjunctivitis, blepharitis, keratitis, ocular pain, discharge (e.g., crusting), foreign body sensation, itching and tearing, and dry eyes; ptosis; decreased corneal sensitivity; cystoid macular edema; visual disturbances including refractive changes and diplopia; pseudophthalmos; choroidal detachment following filtration surgery (see PRECAUTIONS, General); and tinnitus.

**UROGENITAL:** Retroperitoneal fibrosis, decreased libido, impotence, and Peyronie's disease.

The following additional adverse effects have been reported in clinical experience with ORAL timolol maleate or other ORAL beta blocking agents, and may be considered potential effects of ophthalmic timolol maleate: **Allergic:** Erythematous rash, fever combined with aching and sore throat, laryngospasm with respiratory distress; **Body as a Whole:** Extremity pain, decreased exercise tolerance, weight loss; **Cardiovascular:** Worsening of arterial insufficiency, vasodilatation; **Digestive:** Gastrointestinal pain, hepatomegaly, vomiting, mesenteric arterial thrombosis, ischemic colitis; **Hematologic:** Nonthrombocytopenic purpura; thrombocytopenic purpura; agranulocytosis; **Endocrine:** Hyperglycemia, hypoglycemia; **Skin:** Pruritus, skin irritation, increased pigmentation, sweating; **Musculoskeletal:** Arthralgia; **Nervous System/Psychiatric:** Vertigo, local weakness, diminished concentration, reversible mental depression progressing to catatonia, an acute reversible syndrome characterized by disorientation for time and place, emotional lability, slightly clouded sensorium, and decreased performance on neuropsychometric tests; **Respiratory:** Rales, bronchial obstruction; **Urogenital:** Urination difficulties.

## OVERDOSAGE

There have been reports of inadvertent overdosage with Ophthalmic Solution TIMOPTIC (timolol maleate ophthalmic solution) resulting in systemic effects similar to those seen with systemic beta-adrenergic blocking agents such as dizziness, headache, shortness of breath, bradycardia, bronchospasm, and cardiac arrest (see also ADVERSE REACTIONS).

Overdosage has been reported with Tablets BLOCADREN® (timolol maleate tablets). A 30 year old female ingested 650 mg of BLOCADREN (maximum recommended oral daily dose is 60 mg) and experienced second and third degree heart block. She recovered without treatment but approximately two months later developed irregular heartbeat, hypertension, dizziness, tinnitus, faintness, increased pulse rate, and borderline first degree heart block.

An *in vitro* hemodialysis study, using <sup>14</sup>C timolol added to human plasma or whole blood, showed that timolol was readily dialyzed from these fluids; however, a study of patients with renal failure showed that timolol did not dialyze readily.

## DOSAGE AND ADMINISTRATION

Preservative-free TIMOPTIC in OCUDOSE is a sterile solution that does not contain a preservative. The solution from one individual unit is to be used immediately after opening for administration to one or both eyes. Since sterility cannot be guaranteed after the individual unit is opened, the remaining contents should be discarded immediately after administration.

Preservative-free TIMOPTIC in OCUDOSE is available in concentrations of 0.25 and 0.5 percent. The usual starting dose is one drop of 0.25 percent Preservative-free TIMOPTIC in OCUDOSE in the affected eye(s) administered twice a day. Apply enough gentle pressure on the individual container to obtain a single drop of solution. If the clinical response is not adequate, the dosage may be changed to one drop of 0.5 percent solution in the affected eye(s) administered twice a day.

Since in some patients the pressure-lowering response to Preservative-free TIMOPTIC in OCUDOSE may require a few weeks to stabilize, evaluation should include a determination of intraocular pressure after approximately 4 weeks of treatment with Preservative-free TIMOPTIC in OCUDOSE.

If the intraocular pressure is maintained at satisfactory levels, the dosage schedule may be changed to one drop once a day in the affected eye(s). Because of diurnal variations in intraocular pressure, satisfactory response to the once-a-day dose is best determined by measuring the intraocular pressure at different times during the day.

Dosages above one drop of 0.5 percent TIMOPTIC (timolol maleate ophthalmic solution) twice a day generally have not been shown to produce further reduction in intraocular pressure. If the patient's intraocular pressure is still not at a satisfactory level on this regimen, concomitant therapy with other agent(s) for lowering intraocular pressure can be instituted taking into consideration that the preparation(s) used concomitantly may contain one or more preservatives. The concomitant use of two topical beta-adrenergic blocking agents is not recommended. (See PRECAUTIONS, Drug Interactions, Beta-adrenergic blocking agents.)

Manuf. for:

**ATON** Lawrenceville  
NJ 08648  
P H A R M A USA

By: Laboratories Merck Sharp & Dohme-Chibret  
63963 Clermont-Ferrand Cedex 9, France

Based on PI - 5142662/069A-03/09/9689-9690  
US/70P/14/0018 Issued February 2009

\* Registered trademark of ATON PHARMA, INC.  
COPYRIGHT © 2009 ATON PHARMA, INC.  
All rights reserved

# Be a Hero to Your HSVK Patients

It is important for ODs to have a thorough understanding of this sight-threatening disease. **By Shannon Leon, OD, and Joseph J. Pizzimenti, OD**

**H**erpes simplex virus (HSV) is a major health concern. This is evidenced by the epidemic of genital herpes and the enhanced acquisition of human immunodeficiency virus (HIV) associated with HSV.<sup>1</sup> Its prevalence in the ocular world is just as strong, with HSV keratitis (HSVK) standing as the leading infectious cause of corneal blindness among developed nations, primarily because of its recurrent nature.<sup>2</sup> Here, you'll find a review of HSVK, including proper differential diagnosis and contemporary antiviral medical management.

## Assessing the Eye

Humans are the only known natural reservoir for HSV. Along with the nose and mouth, the eyes are a main access point (Table 1).<sup>3</sup> Systemic viral infections from other areas of the body may also manifest in the ocular tissues, resulting in potentially sight-threatening complications.

HSV-related ocular disease is classified as either primary or recurrent. It is also classified as blepharitis, conjunctivitis, HSVK, iridocyclitis

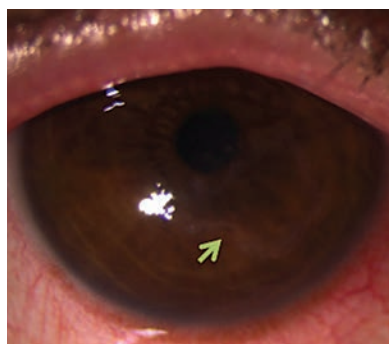


Photo: Lisa Martin, MD

**Advanced dendritic lesions during HSV epithelial keratitis can result in geographic ulcers (green arrow). These defects are more diffuse in appearance, but still maintain branched features along their borders.**

or retinitis based on the specific ocular tissues affected.

HSVK is classified by the location of the principal site of corneal involvement. This includes HSVK of the epithelium (HSV epithelial keratitis), HSVK of the stroma (HSV stromal keratitis with or without ulceration) and HSVK of the endothelium (HSV endothelial keratitis).<sup>4</sup>

Ocular complications of HSV include lid, conjunctival and corneal

involvement, as well as intraocular infections and retinitis.<sup>2,5</sup> Approximately 72% of ocular HSV disease involves the corneal epithelium; 41% involves the lid or conjunctiva; 12% affects the corneal stroma; and 9% involves the iris and associated uveal tract.

Primary ocular HSV infections typically involve rapidly spreading corneal dendrites or geographic ulcers in the epithelium, as there is no antibody in the tear film to act against the virus. In these cases, there is no associated immune reaction to cloud the stroma or deeper ocular tissues.<sup>6,7</sup>

Those undergoing chemotherapy, recipients of bone marrow or organ transplants and people with HIV infection can develop multiple and extensive lesions. In some cases, visceral spread may occur.<sup>2,3,5</sup>

## HSV-1 or HSV-2?

An estimated 3.7 billion people under age 50 worldwide have HSV-1 infection.<sup>8</sup> HSV-1 is transmitted primarily through direct contact with infected secretions



(i.e., saliva or tears) or lesions. Complications of HSV-1 infection occur mainly in the orofacial and ocular areas, but they can also include genital herpes.<sup>5,8,9</sup>

HSV-2 is less prevalent, with an estimated 417 million people ages 15 to 49 affected worldwide.<sup>8</sup> It is sexually transmitted and causes genital herpes. The decreasing prevalence of HSV-1 before puberty in affluent and developed countries, and the increase in orogenital sexual practice, have led to a change in the epidemiology of HSV-1 and HSV-2. HSV-1 is now causing disease in a territory formerly inhabited exclusively by HSV-2 and vice-versa.<sup>9</sup>

Recurrences of HSV may be triggered by fever, hormonal changes, ultraviolet exposure, psychological stress, ocular surgery, ocular trauma and trigeminal nerve manipulation.<sup>5,8</sup> Although pregnant women do not fit the traditional definition of immunosuppressed, the changes in immune response due to the pregnancy increase the risk of both primary and recurrent HSV infections.<sup>10</sup> HSV-1 tends to recur in the orofacial area but not in the genital area after primary infection; conversely, HSV-2 tends to recur in the genital area but not in the orofacial area after primary infection.<sup>9</sup>

Both HSV-1 and HSV-2 infections are lifelong. Vaccines have been ineffective to date, but researchers continue to study the possibilities.<sup>8</sup>

### Making the Diagnosis

HSVK is often diagnosed without the need for laboratory testing, so an understanding of the clinical signs and symptoms is critical. Proper diagnosis begins with a

**Table 1. Major Viruses of Ophthalmic Significance<sup>3</sup>**

DNA	
Family	Ophthalmic Involvement
<i>Adenoviridae</i>	• Epidemic keratoconjunctivitis (most commonly associated serotypes are adenovirus 8, 19 and 37)
<i>Herpesviridae</i>	• Herpes simplex ocular disease • Varicella-zoster ophthalmicus • Cytomegalovirus retinitis (human herpes virus 5)
<i>Papoviridae</i>	• Human papilloma virus of lids, adnexa, conjunctiva
<i>Poxviridae</i>	• Molluscum contagiosum of lids, adnexa
RNA	
<i>Togaviridae</i>	• Rubella retinopathy
<i>Retroviridae</i>	• HIV – affects many ocular tissues

detailed history. Optometrists should elicit the exact clinical course of the patient's symptoms. Some history items to probe include HSV recurrence, contact lens wear, medical and systemic history, nasal and oral cold sore history, recent topical or systemic steroid treatment and recent fever or ultraviolet light exposure.<sup>4,11</sup> The clinician should ask also about recent ocular surgery or trauma, previous corneal abrasions and recurrent erosions. This will help to narrow down the list of differential diagnoses.

During the clinical examination, if the patient presents with skin vesicles, note their distribution. For example, vesicles on the forehead, scalp and nose that respect the vertical midline are more suggestive of varicella-zoster (VZV) than HSV.<sup>11</sup> The slit lamp examination should include a detailed evaluation of the cornea. Vital dye staining with fluorescein and either rose bengal or lissamine green should also be performed. The typical epithelial lesion in HSVK presents as a true dendritic ulcer with terminal endbulbs.<sup>12</sup> This is different from the presentation of VZV keratitis (VZVK), which usually presents as a pseudodendrite without terminal bulb staining. In differentiating HSVK from VZVK, remember that ulceration

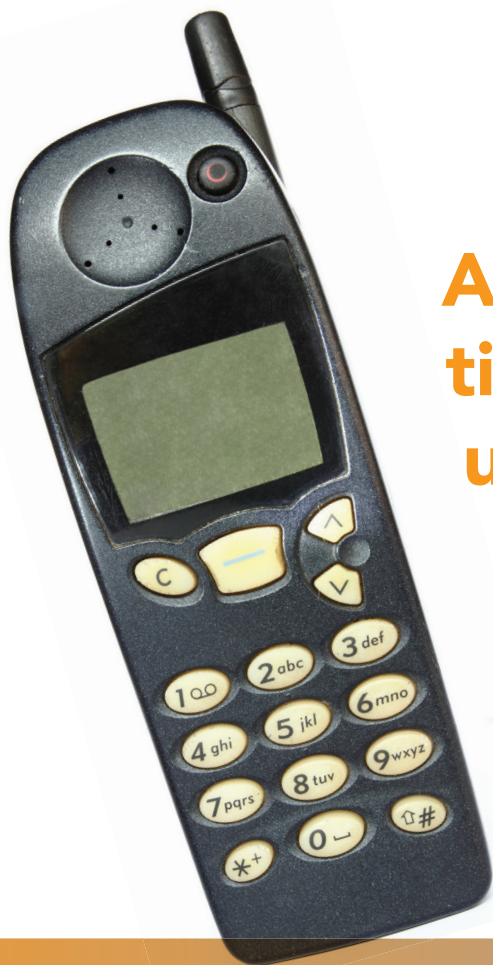is frequently present in an HSV dendrite. Conversely, there is frequently minimal or no ulceration or epithelial defect in a VZVK pseudodendrite.

It is also prudent to evaluate corneal sensitivity bilaterally.<sup>9</sup> Unlike other microbial infections and corneal abrasions, where corneal sensitivity is heightened, patients

with HSVK often present with decreased sensitivity in the involved eye relative to the fellow eye.<sup>11</sup> To test this, gently apply a cotton swab to the patient's cornea and evaluate the blink reflex. You should test the uninvolved eye first so the patient can use it as a basis for comparison. A higher or lower sensitivity in one eye may manifest as a subjective increase or decrease of feeling, touch or sensitivity.

HSV has the ability to establish a latent infection. This allows it to live in the host without inducing pathology. As a result, it is difficult to detect. While laboratory testing is generally not needed to establish a diagnosis of HSVK, it can help to provide confirmation in the rare complicated case where the diagnosis is in doubt. The standard in diagnosis of HSVK is viral isolation in a culture.<sup>13</sup> Due to potentially lengthy turnaround time, standard HSV culture is not useful for rapid clinical diagnosis.

Additional tests that can be conducted include Giemsa stains of the cornea and skin scrapings, enzyme-linked immunosorbent assay testing, HSV antibody titers and polymerase chain reaction assays.<sup>4,11,13</sup> Serology is of limited use because there is a high prevalence of antibodies in the normal population. These tests are



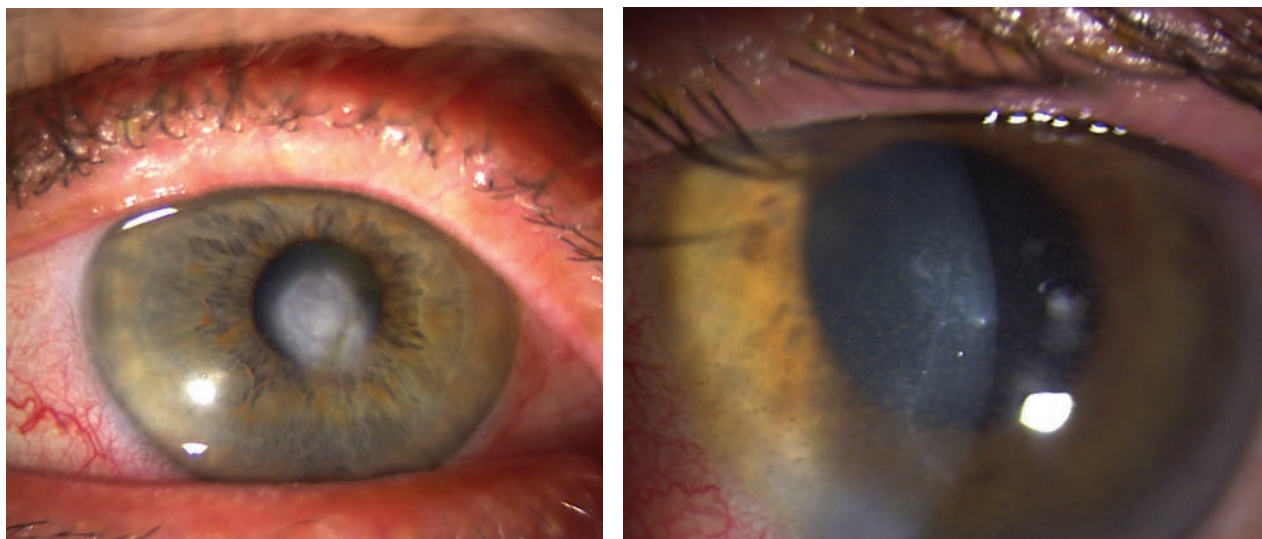
**Are you wasting  
time and money  
using outdated  
technology?**

## **It's time to upgrade your lens processing.**

Invest in the latest lens processing software and equipment to make an exponential difference in your bottom line. Save time and money while preparing your business for the future of the eyewear industry.

Need convincing? Visit with more than 40 industry-leading organizations at International Vision Expo West 2017 – view the latest lens technologies in person, get hands-on demonstrations, and talk to industry experts about the best solutions for your business.

**Access a complete library of member companies, find their Vision Expo booth locations and get free Vision Expo registration at [lpt.thevisioncouncil.org](http://lpt.thevisioncouncil.org).**



**At left, significant scarring from deep corneal inflammation, which is one of the most common causes of vision loss in HSVK. At right, keratic precipitates with anterior chamber reaction and stromal haze, which are hallmarks of HSV endothelial keratitis.**

only positive when a live virus is present (as seen in HSV epithelial keratitis) and cannot be used to diagnose, or exclude, active disease caused by immunologic reactions against HSV triggered by prior infections, which is typically the case for HSV stromal keratitis.

### HSVK or a Masquerader?

The initial presentation of ocular HSV may or may not represent primary infection by the virus. In one study of 108 adult patients with primary ocular HSV, 84% of patients had moderate to severe conjunctivitis, 38% had moderate to severe blepharitis, 35% had a concomitant upper respiratory infection and 31% had generalized symptoms. Only 15% of patients had dendritic ulcers, while 2% had HSV endothelial keratitis and 19% had bilateral disease.<sup>14</sup>

Because of its variable presentation and ability to affect all corneal layers, HSVK has several masqueraders and differential diagnoses. For example, any keratitis that creates a dendriform lesion could be mistaken for HSV epithelial

keratitis. Infectious masqueraders include *Acanthamoeba* keratitis, VZVK, adenovirus epithelial keratitis, Epstein-Barr epithelial keratitis, chlamydial keratitis and other varying microbial keratitis.<sup>4,12</sup> Non-infectious differentials include Thygeson's superficial punctate keratopathy, exposure keratopathy, epithelial defects from topical medications (i.e., antivirals and beta-blockers), epithelial defects due to contact lens wear, epithelial regeneration lines, epithelial basement membrane disease and recurrent corneal erosions.<sup>4,12</sup> Appropriate patient history, demographics and a comprehensive workup will help you sift through masqueraders.

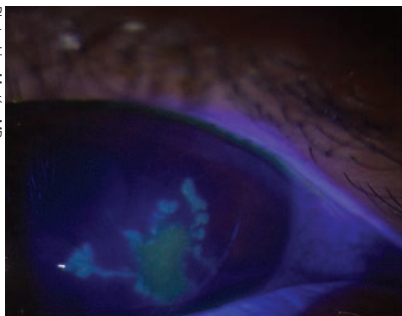
There are several differential diagnoses for both HSV stromal keratitis and HSV endothelial keratitis. Differentials for HSV stromal keratitis include an exhaustive list of interstitial and microbial keratitis. In diagnosing HSV stromal keratitis without ulceration, consider other interstitial keratitis such as that caused by syphilis, Cogan's syndrome, Lyme disease, leprosy, lymphoma, tuberculosis and sar-

coidosis.<sup>4,12</sup> When diagnosing HSV stromal keratitis with ulceration, consider all forms of microbial keratitis as well as exposure and neurotropic keratopathy.<sup>4,12</sup>

Of the different types of HSVK, endothelial is the least common. The presence of stromal and epithelial edema with inflammation at the level of the endothelium, signified by keratic precipitates in the absence of significant anterior uveitis, is classified as endothelial keratitis. The list of differential diagnoses for HSV endothelial keratitis is the same as that for stromal keratitis, in addition to any form of keratouveitis, Posner-Schlossman syndrome, cytomegalovirus endothelial keratitis and corneal graft rejection.<sup>4,12</sup> These differential diagnoses frequently present with raised intraocular pressure (IOP). Herpetic eye disease should be considered the cause of acute-onset, unilateral corneal edema unless proven otherwise.

The wide variety of conditions that can masquerade as HSVK makes the history and work-up vital to a correct diagnosis. In any case of epithelial, stromal or endothelial

Photo: Lisa Martin, MD



**HSV epithelial keratitis doesn't always present with the classic corneal dendrite. Sometimes, the epithelial defect will be more coalesced in appearance.**

keratitis, if the patient's story does not fit the clinical findings, then HSVK should be at the top of your differentials.

## Treatment

Once a diagnosis has been made, focus should shift to treatment.

*HSV epithelial keratitis* is thought to account for 50% to 80% of all ocular herpes infections.<sup>13</sup> HSV epithelial keratitis is the result of the virus' destruction of corneal epithelial cells secondary to viral replication.<sup>13</sup> Patients often present with the classic symptoms of HSV ocular infection such as redness, tearing, foreign body sensation, pain, photophobia and blurred vision.<sup>11,12,15</sup>

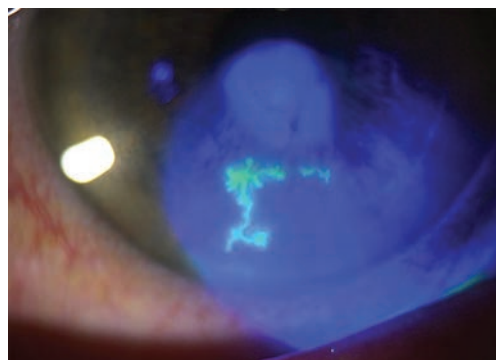
The cornea generally shows diffuse punctate areas that eventually coalesce into a distinct dendritic lesion with terminal bulbs.<sup>12</sup> If the ulcer is more advanced, a more diffuse epithelial lesion, known as a geographic ulcer, will be present.

The Herpetic Eye Disease Study (HEDS) I showed no benefit in combining both oral and topical antivirals, so choose one course of treatment.<sup>15</sup> One exception to this may be prescribing for immunocompro-

mised patients with HSV epithelial keratitis, as the prevalence of acyclovir-resistant (ACVR) HSV-1 isolates is much higher (4.3% to 14%) than that in immunocompetent patients (0.1% to 0.6%).<sup>16</sup> This difference is likely due to longer mucosal persistence of ACVR HSV variants. Therefore, it may be prudent to treat immunocompromised patients with HSVK both systemically and topically.

HSV epithelial keratitis is usually treated with antiviral medication, which may be topically applied or systemically administered. The two most common topical antiviral agents include Viroptic (trifluridine 1%, Pfizer) and Zirgan (ganciclovir 0.15%, Bausch + Lomb). Both of these agents are FDA approved for treating HSVK. Viroptic is generally dosed one drop nine times daily in the affected eye until the ulcer is resolved, whereas Zirgan is dosed one drop five times daily until the ulcer is resolved, then three times daily for seven additional days. Viroptic is effective, but also known for its toxicity, which can delay corneal healing. As a result, Zirgan is often the topical treatment of choice.

Unlike topical antivirals, oral antiviral medications should be used with caution in patients with kidney or liver disease due to the internal



**Here is an example of the classic HSVK epithelial dendrite with terminal bulbs.**

processing (i.e., metabolism, excretion) of these agents. Available oral formulations include Zovirax (acyclovir, GlaxoSmithKline), Valtrex (valacyclovir, GlaxoSmithKline) and Famvir (famciclovir, Novartis).

Oral antivirals tend to be the treatment of choice for HSV epithelial keratitis because they are often less expensive than topical agents, and the dosing schedule is more adaptable to daily use (*Table 2*).

In addition to prescribing antiviral therapy, clinicians should stabilize the ocular surface by prescribing preservative-free tear supplements. Topical immunomodulatory medications may be added for increased tear production and anti-inflammatory support. Lacrimal plugs and bandage contact lenses may be implemented in long-term ocular surface management.

*HSV stromal keratitis without epithelial ulceration* is the more common of the two HSV stromal infections. As its name implies, stromal keratitis without ulceration is thought to occur due to viral proteins that remain in the cornea even after the infection has resolved.<sup>17</sup> In response to these remaining proteins, the body produces an inflammatory response, which results in a stromal keratitis without necrosis. Patients will generally present with symptoms of blurry vision, photophobia and halos around lights brought on by edema of the stroma.<sup>15</sup>

Clinical signs include stromal edema, anterior chamber reaction, stromal opacity and neovascularization.<sup>13</sup> This significant inflammatory response, in combination with recurrent disease, often makes stromal keratitis the instigator of irreversible damage and significant scarring. Stromal keratitis without ulceration requires the

Photo: Lisa Martin, MD

Up to  
18-28 CE  
Credits\*

NEW TECHNOLOGIES  
& TREATMENTS IN  
2018  
EYE CARE



REVIEW OF OPTOMETRY®  
EDUCATIONAL MEETINGS OF CLINICAL EXCELLENCE

# 2018 MEETINGS

**FEBRUARY 16-20, 2018**

**Winter Ophthalmic Conference**  
**ASPEN, CO**

Westin Snowmass  
Conference Center  
*Program Chairs: Murray Fingeret, OD & Leo Semes, OD*

**APRIL 6-8, 2018**

**NASHVILLE, TN**  
Nashville Marriott at Vanderbilt  
*Program Chair: Paul Karpecki, OD*

**APRIL 26-29, 2018**

**SAN DIEGO, CA**  
*Program Chair: Paul Karpecki, OD*

**MAY 17-20, 2018**

**ORLANDO, FL**  
Disney's Yacht & Beach Club  
*Program Chair: Paul Karpecki, OD*

**NOVEMBER 2-4, 2018**

**PHILADELPHIA, PA**  
*Program Chair: Paul Karpecki, OD*

Visit our website for the latest information:

[www.reviewofoptometry.com/events](http://www.reviewofoptometry.com/events)

email: [reviewmeetings@jobson.com](mailto:reviewmeetings@jobson.com) | call: 866-658-1772

Administered by  
Review of Optometry®

  
\*Approval pending

 **SALUS**  
UNIVERSITY  
Pennsylvania College of Optometry

Review of Optometry® partners with Salus University for those ODs who are licensed in states that require university credit.  
See Review website for any meeting schedule changes or updates.

use of a topical corticosteroid along with an oral antiviral.

**HSV stromal keratitis with ulceration** is, fortunately, less common than stromal keratitis without ulceration. Stromal keratitis with ulceration is also an immune-mediated response to the proteins left behind in the stroma.<sup>12</sup> However, instead of producing inflammation, the cells signal tissue necrosis, resulting in ulceration and, ultimately, stromal bed destruction.

Clinical symptoms are similar between the two types of stromal keratitis. Patients with HSV stromal keratitis with ulceration present with necrosis of the stromal tissue. This results in an opacification of the stroma, which can lead to thinning of the tissue and increased risk of corneal perforation.<sup>12</sup>

The treatment of stromal keratitis with ulceration is still commonly debated. A limited number of studies exist regarding treatment; thus, a well-established protocol does not exist. It is thought, however, that similar to stromal keratitis without ulceration, a combination of topical corticosteroids and oral antivirals is best suited to treat stromal keratitis with ulceration.<sup>4</sup>

**HSV endothelial keratitis** stems from inflammation due to viral proteins within the corneal endothelium.<sup>13</sup> Patients with HSV endothelial keratitis present with symptoms similar to other forms of HSVK, including pain, redness, photophobia and blurry vision. HSV endothelial keratitis is also marked by a deep stromal opacification with anterior chamber reaction, keratic

precipitates and, occasionally, elevated IOP.<sup>12</sup> The elevation of IOP is a common sign of endotheliitis and should never be overlooked. Much like its stromal counterpart, HSV endothelial keratitis is thought to respond well to a combination of oral antivirals and topical corticosteroids. Because Zirgan and Viroptic do not penetrate the cornea deeply, oral antivirals are the preferred method of treating HSV endothelial keratitis.<sup>4</sup>

**Table 2. Oral Antiviral Therapy Dosing<sup>4</sup>**

<b>Dendritic Epithelial Keratitis (Seven to 10 days)</b>	
<b>Antiviral</b>	<b>Dosage</b>
Acyclovir	400mg five times daily
Valacyclovir	500mg three times daily
Famciclovir	250mg two or three times daily
<b>Geographic Epithelial Keratitis (14 to 21 days)</b>	
Acyclovir	800mg five times daily
Valacyclovir	1g three times daily
Famciclovir	500mg three times daily
<b>Stromal Keratitis Without Ulceration* (At least 10 weeks)</b>	
Acyclovir	400mg two times daily
Valacyclovir	500mg once daily
Famciclovir	250mg two times daily
<b>Stromal Keratitis With Ulceration** (Seven to 10 days)</b>	
Acyclovir	800mg three to five times daily
Valacyclovir	1g three times daily
Famciclovir	500mg two times daily
<b>Endothelial Keratitis*** (Variable)</b>	
Acyclovir	400mg three to five times daily
Valacyclovir	500mg two times daily
Famciclovir	250mg two times daily
<b>Prophylaxis of Recurrent HSVK (At least one year)</b>	
Acyclovir	400mg two times daily
Valacyclovir	500mg once daily
Famciclovir	250mg two times daily

\*Antiviral treatment is prophylactic since patients are also treated with a therapeutic dose of topical steroid.  
\*\*Limited dose of topical steroid plus therapeutic dose of antiviral.  
\*\*\*Therapeutic dose of topical steroid and therapeutic dose of antiviral. Oral antiviral agent is reduced to prophylactic dose after seven to 10 days and maintained as long as steroid is in use.

**Post-HSVK** eyes should be carefully monitored for IOP rise secondary to trabeculitis.<sup>17</sup> In some cases, long-term use of topical steroids is needed to prevent future flare-ups and scarring. Whenever corticosteroids are used with a patient with previous history of HSV ocular infection, antivirals are needed to prevent recurrence.

For patients with significant corneal scarring from recurrent HSVK episodes, consider use of an amniotic membrane to boost corneal repair. Although not considered a first-line treatment for HSVK, amniotic membranes can help decrease inflammation and provide the building blocks to heal corneal tissue. Even when scarring appears to be beyond repair, these devices may be able to improve the corneal appearance and give the ocular surface a second chance.

Surgical intervention is seldom necessary in the management of HSVK. Progressive stromal thinning with impending or actual perforation may occur, although it is rare. Conservative surgical intervention with application of cyanoacrylate glue is usually sufficient, although tectonic keratoplasty may be required to preserve the integrity of the globe. Adjunctive temporary or permanent tarsorrhaphy is recommended in such cases.

### When Acute Becomes Chronic

A maintenance dose of systemic antiviral therapy may help some patients with HSVK. In the HEDS II study, a maintenance dose of either 400mg of acyclovir BID or 500mg

valacyclovir QD for 12 months after resolution of the initial episode significantly decreased the probability of recurrence.<sup>18</sup> Patients who have had more than one episode of HSVK and those with HSV stromal keratitis are prime candidates for a maintenance course of antiviral medication, which can often spare patients significant scarring and loss of vision.

HSVK is the most frequent cause of corneal blindness in the United States and the most common source of infectious blindness in the Western world.<sup>2</sup> A detailed, targeted history and meticulous clinical work-up are essential to proper diagnosis, effective treatment and preservation of visual function. With timely, aggressive treatment, the prognosis in HSVK is generally favorable. ■

*Dr. Leon is an optometrist at the South Texas Eye Institute. She is a graduate of the Rosenberg School of Optometry at the University of the Incarnate Word, where she completed a residency in primary care optometry.*

*Dr. Pizzimenti is a full-time faculty member at the University of the Incarnate Word in San Antonio, Texas, where he coordinates the Primary Care Residency Program. He is also a contributing editor for Review of Optometry.*





1. Freeman EE, Weiss HA, Glynn JR, et al. Herpes simplex virus 2 infection increases HIV acquisition in men and women: systematic review and meta-analysis of longitudinal studies. *Aids*. 2006;20(1):73-83.
2. Farooq AV, Shukla D. Herpes simplex epithelial and stromal keratitis: an epidemiologic update. *Surv Ophthalmol*. 2012;57(5):448-62.
3. Harding SP. Viral infections of the eye. *Reviews in Medical Virology*. 1993;161-71.
4. White ML, Chodosh J. Herpes simplex virus keratitis: a treatment guideline. *The American Academy of Ophthalmology Clinical Guidelines*. June 2014.
5. Kaye S, Choudhary A. Herpes simplex keratitis. *Prog Retin Eye Res*. 2006;2(4):355-80.

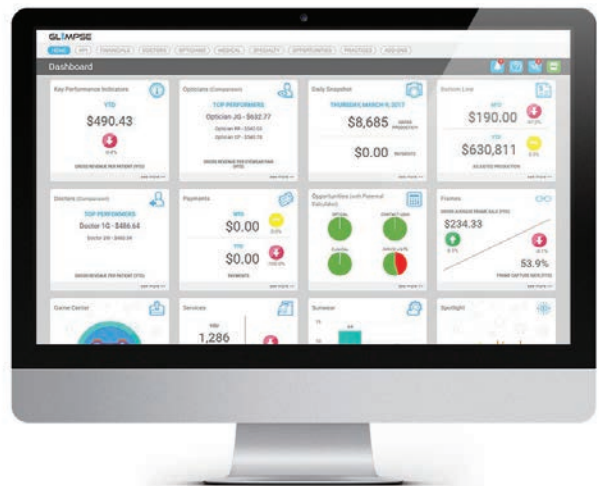6. Pavan-Langston D. Part one: the research perspective. *Advances in the management of ocular herpetic disease*. *Candao Clin Sci Comm*. 2011;1-9.
7. Toma HS, Murina AT, Areaux RG Jr, et al. Ocular HSV-1 latency, reactivation and recurrent disease. *Semin Ophthalmol*. 2008;23(4):249-73.
8. World Health Organization fact sheet on herpes simplex virus. [www.who.int/mediacentre/factsheets/fs400/en/](http://www.who.int/mediacentre/factsheets/fs400/en/). January 2017. Accessed June 15, 2017.
9. Azher TN, Yin XT, Tajfirouz D, et al. Herpes simplex keratitis: challenges in diagnosis and clinical management. *Clin Ophthalmol*. 2017;11:185-191.
10. Langford KS. Infectious disease and pregnancy. *Obstetrics, Gynaecology and Reproductive Medicine*. 2002;12(3):125-30.
11. Rabinowitz MP. Herpes simplex virus. *Wills Eye Manual Office and Emergency Room Diagnosis and Treatment of Eye Disease*. 6th ed. Philadelphia: Lippincott Williams & Wilkins; 2012.
12. Hill GM, Ku ES, Dwarakanathan S. Herpes simplex keratitis. *Disease-a-Month*. 2014;60(6):239-46.
13. Zhu L, Zhu H. Ocular herpes: the pathophysiology, management and treatment of herpetic eye diseases. *Virologica Sinica*. 2014;29(6):327-42.
14. Liesegang, TJ. Herpes simplex virus epidemiology and ocular importance. *Cornea*. 2001;20(1):1-13.
15. Murphy C, Shahnazaryan D. Managing herpes simplex keratitis. *Iris Medical Times*. 2011;45(16):35.
16. Duan R, de Vries RD, Osterhaus ADME, et al. Acyclovir-resistant corneal HSV-1 isolates from patients with herpetic keratitis. *J Infect Dis*. 2008;198(5):659-63.
17. Adams MJ, Carstens EB. Ratification vote on taxonomy proposals to the International Committee on Taxonomy of Viruses. *Arch Virol*. 2012;157(7):1411-22.
18. Wilhelmus KR, Beck RW, Moke PS, et al. Acyclovir for the prevention of recurrent herpes simplex virus eye disease. *N Engl J Med*. 1998;339:300-6.



Unlocking the Future of Healthcare Analytics

## ARE YOU KEEPING UP WITH THE COMPETITION?

-  Quickly identify missed revenue opportunities
-  Create your own metric dashboard
-  Complete accuracy customized to your billing habits
-  Have fun and engage your team with Gamification



# Caring for Patients With Brain Injury

More often than not, TBI affects a patient's vision, and ODs must be prepared to evaluate and manage this population. **By Aaron K. Tarbett, OD**

A “silent epidemic.”<sup>1</sup> That's how traumatic brain injury (TBI) was described in the 1990s. Today, with conservative estimates of 2.8 million Americans suffering a TBI every year and accounting for 10% of Americans with disabilities, it's hardly silent anymore.<sup>2,3</sup> From sports-related concussion to military TBI, it's better recognized and often covered in the lay media.<sup>4</sup> It's also more prevalent in optometric practice.

Approximately 50% of the brain's neural circuitry is dedicated to vision, and 75% of TBI patients will experience visual symptoms.<sup>5,6</sup>

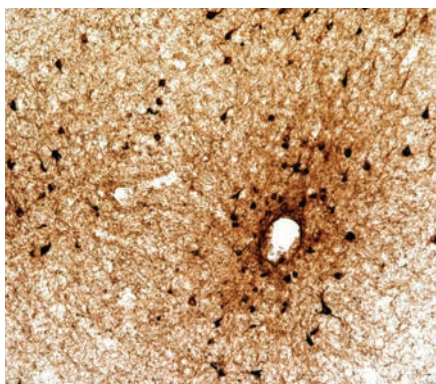


Photo: Ann McKee, MD

**Fig. 1. A focus of perivascular neurofibrillary tangles (black) and neurites at the depth of sulcus in the dorsolateral frontal cortex consistent with stage I/IV CTE, AT8 immunostaining for p-tau, original magnification  $\times 100$ .<sup>63</sup>**

Given the strong prevalence and impact on vision, optometrists should be familiar with the basics of TBI and its management.

## Terminology

The terminology currently employed in brain injury often leads to confusion. The three common terms used to describe brain injury are *concussion*, *mild traumatic brain injury (mTBI)* and, most recently, *chronic traumatic encephalopathy (CTE)*. Concussion and mTBI are used interchangeably in medical literature and by medical professionals (as is the case in this article). However, specialists

**Release Date:** July 2017

**Expiration Date:** July 15, 2020

**Goal Statement:** Because 75% of patients sustaining a traumatic brain injury (TBI) will experience visual symptoms, eye care providers should be familiar with the basics of TBI and its management. This article provides the foundation of knowledge necessary to alleviate any trepidation practitioners may have in diagnosing and managing this patient population.

**Faculty/Editorial Board:** Aaron K. Tarbett, OD

**Credit Statement:** This course is COPE approved for 2 hours of CE credit. Course ID is **54094-NO**. Check with your local state licensing board to see if this counts toward your CE requirement for relicensure.

**Disclosure Statements:**

**Authors:** The author has no relationships to disclose.

**Editorial staff:** Jack Persico, Rebecca Hepp, William Kekevan, Michael Riviello and Michael Iannucci all have no relationships to disclose.





suggest concussion and mTBI should be separate entities with concussion referring to a neurological syndrome involving head trauma and subsequent symptoms, while mTBI is an identifiable injury to brain tissue.<sup>7</sup> Currently, this differentiation is difficult, given our common screening and neuroimaging techniques are not sensitive enough to detect such microstructural and physiological changes in the brain.

### Classification

Following head trauma, clinical diagnosis and classification of severity is typically done by either the Glasgow Coma Scale (*Table 1*) or one or a combination of: loss of consciousness (LOC), alteration of consciousness (AOC) such as disorientation or ‘seeing stars’ or post-traumatic amnesia (PTA).<sup>8</sup> Both concussion and mTBI are often defined as any LOC or AOC less than 30 minutes or amnesia lasting less than 24 hours (*Table 2*).<sup>4,9</sup> More often than not, concussions are without loss of consciousness and diagnosed by the variable degrees of AOC.<sup>10</sup> Any momentary disorientation will qualify as a diagnosis of mTBI, while any identifiable tissue damage or intracranial hemorrhage (subdural, epidural, etc.) on neuroimaging is considered moderate to severe brain injury.<sup>11,12</sup>

CTE has driven much discussion recently due to its notoriety in sports-related concussion.<sup>13</sup> CTE is a progressive, pathological deterioration of the brain caused by repetitive head trauma. It is due only to head trauma with pathognomonic, perivascular accumulations of hyperphosphorylated tau (p-tau) present in neurofibrillary tangles located at the sulcus of brain folds (*Figure 1*). Current theory speculates the sulci absorb the compressive force of brain movement during injury and consequently accumulate p-tau.<sup>14</sup>

**Table 1. Glasgow Coma Scale**

Behavior	Response	Score
Eye opening response	Spontaneously	4
	To speech	3
	To pain	2
	No response	1
Best verbal response	Oriented to time, place and person	5
	Confused	4
	Inappropriate words	3
	Incomprehensible sounds	2
	No response	1
Best motor response	Obeys commands	6
	Moves to localized pain	5
	Flexion withdrawal from pain	4
	Abnormal flexion to pain (also termed decorticate)	3
	Abnormal extension to pain (also termed decerebrate)	2
	No response	1

### Pathophysiology

The pathophysiology in mTBI is complex, not fully understood and involves physiological, structural and vascular processes. Two pathological mechanisms are notable: traumatic axonal injury and microvascular damage.<sup>8</sup>

**Traumatic axonal injury.** During a rapid acceleration of or blow to the head, the brain shifts within the skull, causing stretching and twisting of the axons, which are responsible for signal transmission and can course great distances across the brain. With their viscoelastic nature and large surface-to-volume ratio, the axons are fragile and prone to damage. The axolemma, the outer membrane containing ion channels that create membrane

potential, is often disrupted, as well as other cytoskeletal elements. Possible axon rupture and excitotoxicity (unchecked neurotransmitter release) follow, leading to an interruption in signal transmission.<sup>15,16</sup> Areas commonly affected include the midline regions such as the corpus callosum, brainstem and thalamus—all heavily involved in vision.<sup>17</sup>

**Microvascular damage.** Considering the brain contains 400 miles of capillaries, microvascular damage in mTBI is a primary mechanism of tissue injury.<sup>18</sup> Pial vessels surround and penetrate brain parenchyma, supplying oxygen and other metabolically needed nutrients. Violent head acceleration can shear these vessels or cause rupture during impact with bony protuberances of the cranium.

**Table 2. Severity Rating for TBI**

Severity	Glasgow Coma Scale	Alteration of Consciousness	Loss of Consciousness	Post-traumatic Amnesia
Mild	13-15	≤ 24 hrs	0 to 30 min	≤ 24 hrs
Moderate	9-12	> 24 hrs	> 30 min	> 24 hrs
			< 24 hrs	< 7 days
Severe	3-8	> 24 hrs	≥ 24 hrs	≥ 7 days

Photo: Charles Shindofsky, OD



**Fig. 2. FL-41 tinted lenses can help patients with brain injury cope with photosensitivity.**

The decrease in cerebral autoregulatory capacity, in addition to the physical vessel injury, leads to hypoxia, edema and blood toxicity.<sup>16,19</sup>

### Sequelae and Treatment

Patients with acute concussion or mTBI (within one month post-injury) can experience a variety of physical, emotional and cognitive sequelae that will typically resolve without intervention over three months.

However, approximately 15% of patients will have symptoms that persist beyond one year.<sup>11,20</sup> This group of patients may retain a num-

ber of nonspecific symptoms (fatigue, depression, irritability, etc.) that affect their daily living and quality of life (Table 3). The official ICD-10 diagnosis for this neurological syndrome is postconcussion syndrome (PCS), although patients are anecdotally referred to as the “miserable minority.”<sup>21</sup> Here is a look at the most common mTBI sequelae and the treatment options that can help:

**Headache.** This is the most common symptom following mTBI, and whether the headache is visually related is the primary concern for clinicians.<sup>21,22</sup> The most reliable indication of visual involvement is the association with visually related tasks. Although headaches take on many forms following mTBI, migraine and cervical headache are predominant, and these will be managed medically, surgically or with physical therapy.

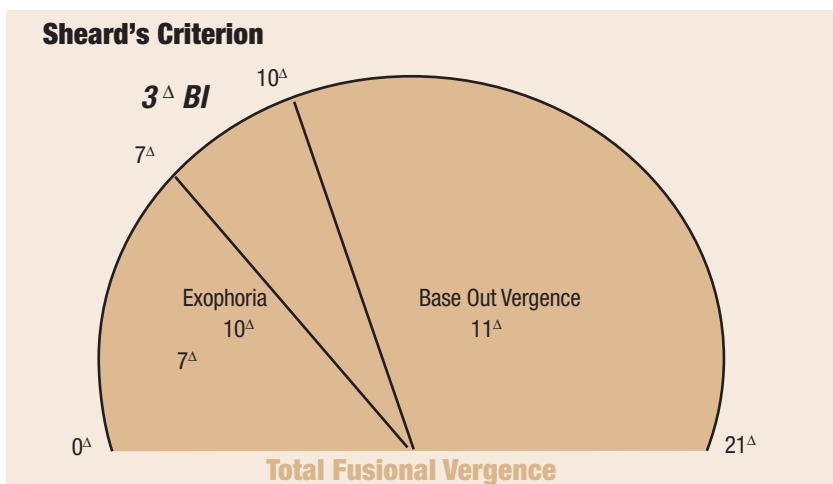
Clinicians must rule out or treat visual etiologies, while continued management for chronic headache is typically handled by other specialists coordinated by the patient’s primary care provider.

**Photosensitivity.** This remains one of the most common and enigmatic symptoms in PCS. Current theory on the pathophysiology involves intrin-

sically photosensitive retinal ganglion cells (ipRGC) and their interaction with the thalamus.<sup>22</sup> The recent discovery of retinal cells, other than rods and cones, that detect light has caused quite a shift in current theory about the detection of light and the perception of vision.<sup>23</sup> Approximately 1% of ganglion cells detect light, thought to be primarily background-related illumination, with the ipRGC axons projecting directly to the thalamus—the primary signal weigh station of the brain that regulates perceptual sensations.<sup>24</sup> Brain injury results in thalamic damage and dysregulation of the incoming signal. Principally, upregulation or poor suppression of light intensity (particularly background lighting) results in an enhanced sensitivity to light, and a threshold of pain stimulus is reached as the sensitivity increases.<sup>24</sup>

Treatment of photosensitivity outdoors logically consists of sunglasses and a brimmed hat; but treatment of debilitating indoor photosensitivity is more controversial. While a patient wearing sunglasses indoors has long been thought to be an indication of non-organic or psychologically related conditions, merit for such a diagnosis may be lacking in the case of brain injury. This patient likely experiences true light sensitivity unrelated to a functional or conversion disorder. However, there is concern that sunglasses for indoor use will establish a “habit-forming tendency” and may actually prevent the resolution of visual or psychological symptoms.<sup>25</sup> In this regard, clinicians could recommend titration of tints over a period of time.

A number of studies indicate the usefulness of different tints, such as FL-41 for patients with migraine and blepharospasm (Figure 2).<sup>26,27</sup> Interestingly, FL-41 filters 480nm light, the peak activation range of photosensitive retinal ganglion cells.<sup>28</sup>



**Fig. 3. This criterion can help ECPs diagnose and manage decompensated exophoria.**

**Oculomotor dysfunction.** This affects approximately 30% to 50% of mTBI patients at some point.<sup>5,29,30</sup> The most common issues are eye tracking (saccades and pursuits), convergence insufficiency and accommodative dysfunction.<sup>31,32</sup>

Accommodative dysfunction is of particular concern for optometrists, as roughly 50% of pre-presbyopic TBI patients show accommodative dysfunction following TBI vs. 6% in the normal population.<sup>33,34</sup> Most clinicians can use Donder's push up method or minus lenses and address those results with Hofstetter's formula to assess age-related accommodative ability. Hofstetter's formula for the minimum amplitude for a given age is defined as:  $15 - 1/4 \text{ age}$ .<sup>35</sup>

Reading glasses are an effective treatment since asthenopic symptoms may be short-lived. Considering latent hyperopia is a concern when dealing with accommodative short-ages, a cycloplegic refraction is an absolute necessity in those with age-remaining accommodative ability.

**Convergence insufficiency (CI).** This occurs when the near exophoria overrides the positive fusional vergence ability of the patient to maintain comfortable binocular vision. Research suggests the prevalence of CI in the non-TBI population ranges up to 7.7%, while it can be 42% or higher in the post-TBI population.<sup>5,33</sup> The disruption of integrated neurologic circuitry following brain injury reduces the ability to compensate for an existing exophoria. Diagnostic criteria for CI is provided by the Convergence Insufficiency Treatment Trial (CITT) (Table 4).<sup>36</sup>

Sheard's criterion, used in the CITT, remains useful in the diagnosis and management of decompensated exophoria (Figure 3).<sup>37</sup> It establishes the needed positive fusional vergence (base out) to control exophoria without symptoms. The criterion is

**Table 3. Postconcussion Symptoms**

Physical	Cognitive	Emotional
Headache	Memory deficits	Irritability
Dizziness	Attention/concentration deficits	Depression
Fatigue	Executive function deficits	Anxiety
Visual disturbance		
Noise sensitivity		
Light sensitivity		
Insomnia		

defined as the presence of a positive fusional ability twice that of the phoria.<sup>38</sup> For example, if a patient presented with near exophoria of 10pd, the positive fusional ability to satisfy Sheard's criterion would be 20pd.

In addition to determining whether an exophoria should be symptomatically relevant, Sheard's criterion also provides a recommendation for judicious use of prism in patients with CI. Prism is a recommended treatment practice, particularly considering postconcussion CI symptoms could be transitory.<sup>39</sup> According to Sheard's criterion, the needed prism to help carry the load of the overburdened vergence system will be equal to the amount of prism to place a patient's phoria within a third of their overall vergence ability. For example, a patient with 10pd exophoria and 11pd base-out vergence at near would need 3pd of base-in prism applied to their spectacles, moving the image toward apex.

This formula will also provide the practitioner with the recommended prism:  $2/3(\text{phoria}) - 1/3(\text{positive fusional vergence})$ .<sup>36</sup>

Resultant prism from Sheard's calculations should be trial framed for patient approval. However, Sheard's criterion is only a recommendation, and they may be successful with less prism than indicated.

Small studies and anecdotal experience attest to the effectiveness of vision therapy/rehabilitation as a treatment modality for TBI-related

visual symptoms.<sup>40</sup> However, without large scale, prospective studies, it is not a universally recommended treatment; clinicians should first consider a brief trial of vision rehabilitation. The 2016 Department of Defense and Veterans Affairs guidelines for traumatic brain injury issues a word of caution for all rehabilitative therapies, including vision rehabilitation.<sup>39</sup> A prolonged course of therapy (three to six months) without significant improvement will considerably influence a patient's perception of their ability to recover from a TBI, fostering negative expectations.<sup>41,42</sup>

**Dizziness, disequilibrium and imbalance.** These commonly occur after mTBI and are an indicator of a potentially long recovery process in PCS.<sup>43,44</sup> Vestibular dysfunction, both peripheral (inner ear) and central (cerebellar), is a common etiology. After ruling out obvious oculomotor deficiencies, (e.g., muscle palsies, decompensated phorias and especially mild vertical phorias) impairment of the vestibulo-ocular reflex (VOR) is one of the leading concerns for optometrists. The vestibulo-ocular system is responsible for gaze stability (non-pursuit) during high frequency and velocity-related head movements. When the VOR is disrupted, oscillopsia and dizziness ensue.<sup>45</sup> Its counterpart, the vestibulospinal system, is responsible for postural control with consequences of disrupted balance.<sup>46,47</sup> The integrity of the vestibulo-ocular system can

#### Table 4. CITT Convergence Insufficiency Criteria

Near exophoria at least 4pd greater than at distance

Plus Additional Signs:

- Insufficient positive fusional convergence meeting Sheard's Criterion
- Failure to reach normative values for positive fusional vergence ( $\leq 15$  pd blur or break)
- Receded near point of convergence ( $\geq 6$  cm)
- CI Symptom Score  $\geq 16$

be evaluated by assessing VOR with dynamic visual acuity (DVA).

When performing DVA testing, clinicians establish a baseline with best-corrected visual acuity and then rotate the head from side to side, managing one complete cycle (left, right and back left) with two cycles per second. At this rate, VOR dysfunction may exist if the patient reads worse than two lines below their baseline acuity.<sup>48</sup>

Research suggests vestibular therapy that involves gaze stabilization exercises is effective in these patients.<sup>49</sup> It is common to work with an interdisciplinary team comprised of neurology, ENT, audiology and physical therapy with patients in need of vestibular rehabilitation.

Visuospatial disruptions in TBI are more perplexing, since they are higher-order dysfunctions of the brain and are poorly understood. A commonly encountered symptom in

mTBI is increased visual motion sensitivity (VMS). With increased VMS, a patient will report imbalance, nausea and disorientation in situations with significant peripheral motion such as walking through a shopping mall or riding in a car.<sup>50</sup>

Research shows binasal occlusion (BNO) is an effective treatment, both subjectively and objectively. Clinicians can add partial occluders to the patient's spectacle lenses to suppress excessive visual motion in the peripheral visual field. The occlusion can be done using scotch tape, bangerter foils or electrical tape placed nasal to the pupillary-limbal margin and oriented with a 15° superior-temporal tilt (*Figure 4*).<sup>51,52</sup>

Patients with TBI may also experience a shift in their perception of midline. Known as abnormal egocentric localization, visual midline shift or optic ataxia (misreaching to visual targets), it can cause a patient to lean to one side, forward or backward, resulting in difficulties with balance during ambulation.

To diagnose and manage these shifts, clinicians must first determine where the shift occurs (right, left, forward or backward) and then attempt to correct the misperception with prism.<sup>53,54</sup> For example, a patient notes when you hold a pen directly in front of them that it appears to the left of center. Shifting the patient's midline back toward the center with base left yoked prism (approximately 2pd to 6pd) may help correct the

perceived imbalance. Similarly, if the patient tends to lean forward, yoked base down prism (also 2pd to 6pd, but could vary depending on the case) could be trialed for improvement in posture.

#### TBI and PTSD

Post-traumatic stress disorder (PTSD) is frequently associated with TBI. While approximately 50% of military service members that have sustained an mTBI have associated PTSD, it is not unique to military members. Those who have sustained an mTBI from motor vehicle accidents also have a 50% chance of developing PTSD.<sup>55,56</sup> Patients with more violent or anxiety-laden brain injury events logically have higher rates of PTSD development.

Current theory suggests damage to the rational thinking medial prefrontal cortex (mPFC) causes an inability to regulate the fear response. Especially damaging is the evolutionary juxtaposition of the amygdala, the center of the brain for fear, and the hippocampus, the region for memory development (*Figure 5*). Situated next to each other, without mPFC tempering, the exaggerated fear response becomes inextricably linked with a memory, thus generating the associated PTSD symptoms.<sup>57</sup>

Post-concussion symptoms such as headache, lack of concentration and poor sleep, among others, may be more related to PTSD than PCS.<sup>58</sup> Although the high rates of anxiety and depressive disorders related to PTSD exacerbate visual symptoms, no studies indicate visual symptoms are directly linked to PTSD.

#### Malingering and Stereotype Threat

Managing a patient with TBI usually goes beyond clinical medicine. The social and psychological ramifications of brain injury can lead to other complications such as malingering



Photo: Marc Raub, OD

**Fig. 4. Binasal occlusion can help TBI patients overcome visual motion sensitivity in the peripheral visual field.**

and stereotype threat.

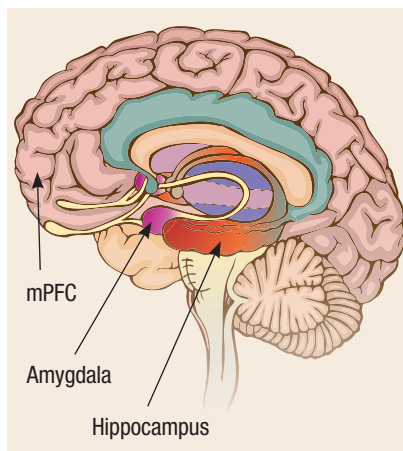
**Malingering.** This is a major dilemma with mTBI since it is difficult to tell if symptoms are truly related to injury. Survey data suggest 20% to 40% of mTBI patients present with exaggerated or fabricated neuropsychological deficits.<sup>59</sup> A number of complicating factors exist with TBI-related malingering, such as the difficult distinction between pre-TBI abilities and post-TBI deficits. Researchers found that, for many patients, complaints following mTBI were more a reflection of a pre-TBI condition that was brought to the fore by the TBI.<sup>60,61</sup>

There is also the matter of volition, or the degree to which a behavior is both conscious and deliberate. Optometrists should look to neuropsychological personnel to assess an individual's volition in malingering and other disorders. In addition, malingering and legitimate neurologic deficit from concussion are not mutually exclusive, possibly compelling providers to attempt to manage nonorganic or fictitious ailments.

**Stereotype Threat.** This social psychology theory purports that a stereotyped individual, when placed in a situation that risks validation of that stereotype, performs poorly due to "performance pressure," thus supporting the stereotype.<sup>62</sup>

Stereotype threat is a proven phenomenon in mTBI patients, as society does hold specific maladaptive beliefs regarding the cognitive effects of brain injury.<sup>61</sup> Thus, patients diagnosed with mTBI may do poorly on cognitive or memory testing simply because they have been diagnosed with mTBI, not due to any associated sequelae.

Optometrists must be aware of this during the exam but, more importantly, on treatment recommendations and patient interaction. Stigmatizing or fostering negative expectations for patients with



**Fig. 5. Because the amygdala and the hippocampus are situated next to each other, the exaggerated fear response becomes inextricably linked with a memory, creating symptoms of PTSD.**

prolonged courses of ineffective treatment or communicating with a despondent bedside manner could set patients back substantially in recovery.

With a high prevalence and an increasing community awareness of brain injury, it is not a question of whether optometrists will see these patients, but when. Having an adequate foundation of understanding will alleviate any trepidation and mystique in managing them. ■

*Dr. Tarbett is the former chief of the Optometry Service at Walter Reed Army Medical Center. He is currently on staff at the Hefner VAMC in Salisbury, NC.*

1. Goldstein M. Traumatic brain injury: a silent epidemic. *Ann Neurol*. 1990;27(3):327.
2. Centers for Disease Control and Prevention. Get the stats on traumatic brain injury in the United States. [www.cdc.gov/traumaticbraininjury/pdf/bluebook\\_factsheet-a.pdf](http://www.cdc.gov/traumaticbraininjury/pdf/bluebook_factsheet-a.pdf). Accessed April 13, 2017.
3. Taylor CA, Bell JM, Breiding MJ, Xu L. Traumatic brain injury-related emergency department visits, hospitalizations, and deaths—United States, 2007 and 2013. *MMWR Surveill Summ*. 2017;66:1-16.
4. Centers for Disease Control and Prevention. Report to Congress on traumatic brain injury in the United States: epidemiology and rehabilitation. National Center for Injury Prevention and Control; Division of Unintentional Injury Prevention. 2015.
5. Brahm KD, Wilgenburg HM, Kirby J, et al. Visual impairment and dysfunction in combat-injured servicemembers with traumatic brain injury. *Optom Vis Sci*. 2009;86(7):817-25.
6. Felleman DJ, Van Essen DC. Distributed hierarchical processing in the primate cerebral cortex. *Cereb Cortex*. 1991;1(1):1-47.
7. Keener AB. Tackling the brain: Clues emerge about the pathology of sports-related brain trauma. *Nat Med*. 2016;22(4):326-9.
8. Kushner D. Mild traumatic brain injury: toward understanding manifestations and treatment. *Arch Intern Med*. 1998;158(15):1617-24.

9. Mild Traumatic Brain Injury Committee of the Head Injury Interdisciplinary Special Interest Group of the American Congress of Rehabilitation Medicine. Definition of mild traumatic brain injury. *J Head Trauma Rehabil*. 1993;8(3):86-87.
10. Collins MW, Grindel SH, Lovell MR, et al. Relationship between concussion and neuropsychological performance in college football players. *JAMA*. 1999;282(10):964-70.
11. Carroll LJ, Cassidy JD, Peloso PM, et al. Prognosis for mild traumatic brain injury: results of the WHO Collaborating Centre Task Force on Mild Traumatic Brain Injury. *J Rehabil Med*. 2004 Feb;(43 Suppl):84-105.
12. Narayan R, Wilberger JE, Povlishock JT, eds. *Neurotrauma*. New York, NY: McGraw-Hill; 1996.
13. Fainaru-Wada M, Avila J, Fainaru S. Doctors: Junior Seau's brain had CTE. January 11, 2013. [www.espn.com/espn/ol/story/\\_/id/8830344/study-junior-seau-brain-shows-chronic-brain-damage-found-other-nfl-football-players](http://www.espn.com/espn/ol/story/_/id/8830344/study-junior-seau-brain-shows-chronic-brain-damage-found-other-nfl-football-players). Accessed April 20, 2017.
14. McKee AC, Stern RA, Nowinski CJ, et al. The spectrum of disease in chronic traumatic encephalopathy. *Brain*. 2013;136(Pt 1):43-64.
15. Bauer D, Tung ML, Tsao JW. Mechanisms of traumatic brain injury. *Semin Neurol*. 2015;35:e14-22.
16. Choe MC. The pathophysiology of concussion. *Curr Pain Headache Rep*. 2016;20:42.
17. Grossman EJ, Inglese M. The role of thalamic damage in mild traumatic brain injury. *J Neurotrauma*. 2016;33(2):163-7.
18. Cipolla M. *The Cerebral Circulation*. San Rafael, CA: Morgan & Claypool Life Sciences; 2009.
19. Junger EC, Newell DW, Grant GA, et al. Cerebral autoregulation following minor head injury. *J Neurosurg*. 1997;86(3):425-32.
20. Alexander MP. Mild traumatic brain injury: pathophysiology, natural history, and clinical management. *Neurology*. 1995;45(7):1253-60.
21. Ruff RM, Crouch JA, Troster AI, et al. Selected cases of poor outcome following a minor brain trauma: comparing neuropsychological and positron emission tomography assessment. *Brain Inj*. 1994;8:297-308.
22. Nosedá R, Constandil L, Bourgeois L, et al. Changes of meningeal excitability mediated by corticotrigeminal networks: a link for the endogenous modulation of migraine pain. *J Neurosci*. 2010;30(43):14420-9.
23. Xue T, Do MT, Riccio A, et al. Melanopsin signalling in mammalian iris and retina. *Nature*. 2011;479(7371):67-73.
24. Digre KB, Brennan KC. Shedding light on photophobia. *J Neuroophthalmol*. 2012;32(1):68-81.
25. Truong JQ, Cifuffreda KJ, Han MH, Suchoff IB. Photosensitivity in mild traumatic brain injury (mTBI): a retrospective analysis. *Brain Inj*. 2014;28(12):1283-7.
26. Good PA, Taylor RH, Mortimer MJ. The use of tinted glasses in childhood migraine. *Headache*. 1991;31(8):533-6.
27. Blackburn MK, Lamb RD, Digre KB, et al. FL-41 tint improves blink frequency, light sensitivity, and functional limitations in patients with benign essential blepharospasm. *Ophthalmol*. 2009;116(5):997-1001.
28. Lucas RJ, Douglas RH, Foster RG. Characterization of an ocular photopigment capable of driving pupillary constriction in mice. *Nat Neurosci*. 2001;4(6):621-6.
29. Lew LH, Otis JD, Tun C, Kerns RD, Clark ME, Cifu DX. Prevalence of chronic pain, posttraumatic stress disorder, and persistent postconcussive symptoms in OIF/OEF veterans: polytrauma clinical triad. *J Rehabil Res Dev*. 2009;46(6):697-702.
30. Kontos AP, Elbin RJ, Schatz P, et al. A revised factor structure for the post-concussion symptom scale: baseline and postconcussion factors. *Am J Sports Med*. 2012;40(10):2375-84.
31. Master CL, Scheiman M, Galloway M, et al. Vision diagnoses are common after concussion in adolescents. *Clin Pediatr (Phila)*. 2016;55(3):260-7.
32. Goodrich GL, Kirby J, Cockerham G, et al. Visual function in patients of a polytrauma rehabilitation center: A descriptive study. *J Rehabil Res Dev*. 2007;44(7):929-36.
33. Porcar E, Martinez-Palomera A. Prevalence of general binocular dysfunctions in a population of university students. *Optom Vis Sci*. 1997;74(2):111-3.
34. Stelmack JA, Frith T, Van Koeveing D, et al. Visual function in patients followed at a Veterans Affairs polytrauma network site: an electronic medical record review. *Optometry*. 2009;80(8):419-24.
35. Scheiman M, Wick B. *Clinical Management of Binocular Vision: Heterophoria, Accommodative and Eye Movement Disorders*. 3rd ed. Philadelphia, PA: Lippincott Williams and Wilkins; 2008.
36. Convergence Insufficiency Treatment Trial Study G. Randomized clinical trial of treatments for symptomatic convergence insufficiency in children. *Arch Ophthalmol*. 2008;126(10):1336-49.
37. Gray L. The prescribing of prisms in clinical practice. *Graefes Arch Clin Exp Ophthalmol*. 2008;5(5):627-9.
38. Sheard C. Zones of ocular comfort. *Am J Optom*. 1930;7:9-25.
39. Heinmiller L, Gunton KB. A review of the current practice in diagnosis and management of visual complaints associated with concussion and postconcussion syndrome. *Curr Opin Ophthalmol*. 2016;27(5):407-12.

40. Thiagarajan P, Ciuffreda KJ. Effect of oculomotor rehabilitation on accommodative responsiveness in mild traumatic brain injury. *J Rehabil Res Dev.* 2014;51(2):175-91.
41. VA/DoD Clinical Practice Guideline for the Management of Concussion-mild Traumatic Brain Injury. 2016. [www.guideline.gov/summaries/summary/50140/vadod-clinical-practice-guideline-for-the-management-of-concussion-mild-traumatic-brain-injury](http://www.guideline.gov/summaries/summary/50140/vadod-clinical-practice-guideline-for-the-management-of-concussion-mild-traumatic-brain-injury). Accessed March 29, 2017.
42. Kay T. Neuropsychological treatment of mild traumatic brain injury. *Journal of Head Trauma Rehabilitation.* 1993;8:74-85.
43. Alsalaheen BA, Mucha A, Morris LO, et al. Vestibular rehabilitation for dizziness and balance disorders after concussion. *J Neurol Phys Ther.* 2010;34(2):87-93.
44. Ellis MJ, Cordingley D, Vis S, et al. Vestibulo-ocular dysfunction in pediatric sports-related concussion. *J Neurosurg Pediatr.* 2015;16(3):248-55.
45. Grossman GE, Leigh RJ, Abel LA, et al. Frequency and velocity of rotational head perturbations during locomotion. *Exp Brain Res.* 1988;70(3):470-6.
46. Cullen KE. The vestibular system: multimodal integration and encoding of self-motion for motor control. *Trends Neurosci.* 2012;35(3):185-96.
47. Khan S, Chang R. Anatomy of the vestibular system: a review. *Neuro-Rehabilitation.* 2013;32(3):437-43.
48. Rakoczy C. Brain Injury Electronic Resource Manual: Vol 1 A: Traumatic Brain Injury. American Optometric Association. 2013.
49. Hall CD, Heusel-Gillig L, Tusa RJ, Herdman SJ. Efficacy of gaze stability exercises in older adults with dizziness. *J Neurol Phys Ther.* 2010;34(2):64-9.
50. Winkler PA, Ciuffreda KJ. Ocular fixation, vestibular dysfunction, and visual motion hypersensitivity. *Optometry.* 2009;80(9):502-12.
51. Padula WV, Argyris S, Ray J. Visual evoked potentials (VEP) evaluating treatment for post-trauma vision syndrome (PTVS) in patients with traumatic brain injuries (TBI). *Brain Inj.* 1994;8(2):125-33.
52. Yadav NK, Ciuffreda KJ. Effect of binasal occlusion (BNO) and base-in prisms on the visual-evoked potential (VEP) in mild traumatic brain injury (mTBI). *Brain Inj.* 2014;28(12):1568-80.
53. Ciuffreda KJ, Ludlam DP, Yadav NK, Thiagarajan P. Traumatic brain injury: visual consequences, diagnosis, and treatment. In: *Advances in Ophthalmol and Optom.* Yanoff M, ed. Philadelphia: Elsevier; 2016:307-33.
54. Padula WV, Nelson CA, Padula WV, et al. Modifying postural adaptation following a CVA through prismatic shift of visuo-spatial egocenter. *Brain Inj.* 2009;23(6):566-76.
55. Hoge CW, McGurk D, Thomas JL, et al. Mild traumatic brain injury in U.S. Soldiers returning from Iraq. *N Engl J Med.* 2008;358(5):453-63.
56. Mayou RA, Ehlers A, Hobbs M. Psychological debriefing for road traffic accident victims. Three-year follow-up of a randomised controlled trial. *Br J Psychiatry.* 2000;176:589-93.
57. Rauch SL, Shin LM, Phelps EA. Neurocircuitry models of posttraumatic stress disorder and extinction: human neuroimaging research—past, present, and future. *Biol Psychiatry.* 2006;60(4):376-82.
58. Schneiderman AI, Braver ER, Kang HK. Understanding sequelae of injury mechanisms and mild traumatic brain injury incurred during the conflicts in Iraq and Afghanistan: persistent postconcussive symptoms and posttraumatic stress disorder. *Am J Epidemiol.* 2008;167:1446-52.
59. Dominic Carone DA, Bush SS, eds. *Mild Traumatic Brain Injury: Symptom Validity Assessment and Malingered.* New York, NY: Springer Publishing Company; 2012.
60. Greiffenstein FM, Baker JW. Comparison of premorbid and postinjury mmpi-2 profiles in late postconcussion claimants. *Clin Neuropsychol.* 2001;15(2):162-70.
61. Kit KA, Mateer CA, Tuokko HA, Spencer-Rodgers J. Influence of negative stereotypes and beliefs on neuropsychological test performance in a traumatic brain injury population. *J Int Neuropsychol Soc.* 2014;20(2):157-67.
62. Steele CM, Aronson J. Stereotype threat and the intellectual test performance of African Americans. *J Pers Soc Psychol.* 1995;69(5):797-811.
63. McKee, et al. The neuropathology of traumatic brain injury. *Handb Clin Neurol.* 2015;127:45–66.

## OSC QUIZ

**Y**ou can obtain transcript-quality continuing education credit through the Optometric Study Center. Complete the test form and return it with the \$35 fee to: Jobson Medical Information, Dept.: Optometric CE, 440 9th Avenue, 14th Floor, New York, NY 10001. To be eligible, please return the card within one year of publication.

You can also access the test form and submit your answers and payment via credit card at *Review of Optometry* online, [www.reviewofoptometry.com/ce](http://www.reviewofoptometry.com/ce).

You must achieve a score of 70 or higher to receive credit. Allow eight to 10 weeks for processing. For each Optometric Study Center course you pass, you earn 2 hours of transcript-quality credit from Pennsylvania College of Optometry and double credit toward the AOA Optometric Recognition Award—Category 1.

Please check with your state licensing board to see if this approval counts toward your CE requirement for relicensure.

- A concussion or mild TBI is a blow or acceleration to the head with:
  - Loss of consciousness for 24 to 36 hours.
  - Loss of consciousness for less than 30 minutes.
  - Alteration of consciousness for less than 30 minutes.
  - Both b and c.
- What is the most common symptom following a TBI?
  - Photophobia.
  - Headache.
  - Diplopia.
  - Blurred vision.
- Following concussion, when should concussion-related symptoms typically

resolve by?

- Two weeks.
- One month.
- Three to six months.
- One year.

4. What are two of the main mechanisms in the pathophysiology of TBI?

- Demyelination and vascular dysregulation.
- Traumatic axonal injury and microvascular damage.
- Microvascular damage and ossification.
- DNA and RNA disruption.

5. Chronic traumatic encephalopathy is characterized by:

- Repetitive head trauma and DNA mutation.
- DNA mutation and vascular dysregulation.
- Repetitive head trauma and perivascular p-tau deposition.
- Neurofibrillary tangles and Alzheimer's disease.

6. Chronic traumatic encephalopathy is differentiated from mTBI by:

- Chronic progressive tissue degeneration.
- Cranial impact trauma.
- Glasgow Coma Scale score of five or less.
- Loss of consciousness.

7. Following acute head trauma, tissue damage on CT imaging indicates:

- Mild TBI.
- Concussion.
- Moderate to severe TBI.
- PTSD.

8. Pathophysiology of TBI-related photosensitivity is associated with disruption of the:

- Hippocampus.
- Medial prefrontal cortex.

- Amygdala.
- Thalamus.

9. Besides photoreceptors, what other retinal cell has been shown to detect light?

- Bipolar.
- Mueller.
- Ganglion.
- Amacrine.

10. What is the Hofstetter's formula for age-related accommodative ability?

- 15 - 1/4 age.
- 12 - 1/4 age.
- 8 + 1/4 age.
- 18 - 1/4 age.

11. Which of the following is not a criterion used in the CITT?

- Near exophoria at least 4pd greater than at distance.
- Insufficient positive fusional convergence meeting Sheard's Criterion.
- Failure to reach normative values for positive fusional vergence ( $\leq 15$ pd blur or break).
- All are used in the CITT.

12. What is an absolute necessity when evaluating refractive error in pre-presbyopic TBI patients?

- Red-green balance.
- Cycloplegic refraction.
- Monocular fogging.
- 1.00D Jackson cross cylinder testing.

13. Sheard's criteria establishes:

- Needed fusional vergence to control heterophoria without symptoms.
- Likelihood of developing photosensitivity.
- Residual accommodative function.
- Needed fusional ability to converge to the nose.

## OSC QUIZ

14. Vestibular dysfunction in TBI can occur:  
 a. Centrally.  
 b. Peripherally.  
 c. Both a and b.  
 d. Vestibular dysfunction does not occur.

15. Vestibular dysfunction commonly involves disruption of the:  
 a. Spinal-cephalic pathway.  
 b. Vestibulo-ocular reflex.  
 c. Babinski reflex.  
 d. King-Smith Purkinje reflex.

16. The vestibulo-ocular reflex can be measured by:  
 a. Dynamic visual acuity.  
 b. Von Graefe vergence assessment.  
 c. Park's three-step test.  
 d. Maddox rod test.

17. Which of the following can be a useful treatment for patient suffering from increased visual motion sensitivity?  
 a. Sunglasses.  
 b. Yoked vertical prism.  
 c. Progressive addition lenses.  
 d. Binasal occlusion.

18. PTSD and TBI commonly occur due to the anatomical position in the brain of the:  
 a. Occipital lobe and hippocampus.  
 b. Corpus callosum and amygdala.  
 c. Cerebellum and occipital lobe.  
 d. Amygdala and hippocampus.

19. Determination of patient malingering is best done by:  
 a. The eye care provider.  
 b. Neuropsychological personnel.  
 c. Family members.  
 d. None of the above.

20. Awareness of stereotype threat is useful:  
 a. In analyzing patient exam data.  
 b. Patient interaction.  
 c. Treatment recommendations.  
 d. All of the above.



TAKE THE TEST ONLINE TODAY!  
[www.reviewofoptometry.com/continuing\\_education/](http://www.reviewofoptometry.com/continuing_education/)

## Examination Answer Sheet

Caring for Patients with Brain Injury  
 Valid for credit through July 15, 2020

**Online:** This exam can be taken online at [www.reviewofoptometry.com/ce](http://www.reviewofoptometry.com/ce). Upon passing the exam, you can view your results immediately and download a real-time CE certificate. You can also view your test history at any time from the website.

**Directions:** Select one answer for each question in the exam and completely darken the appropriate circle. A minimum score of 70% is required to earn credit.

**Mail to:** Jobson Medical Information, Dept.: Optometric CE, 440 9th Avenue, 14th Floor, New York, NY 10001.

**Payment:** Remit \$35 with this exam. Make check payable to Jobson Medical Information LLC.

**Credit:** This course is COPE approved for 2 hours of CE credit. Course ID is **54094-NO**.

**Sponsorship:** This course is joint-sponsored by the Pennsylvania College of Optometry.

**Processing:** There is an eight- to 10-week processing time for this exam.

### Answers to CE exam:

1. (A) (B) (C) (D)
2. (A) (B) (C) (D)
3. (A) (B) (C) (D)
4. (A) (B) (C) (D)
5. (A) (B) (C) (D)
6. (A) (B) (C) (D)
7. (A) (B) (C) (D)
8. (A) (B) (C) (D)
9. (A) (B) (C) (D)
10. (A) (B) (C) (D)
11. (A) (B) (C) (D)
12. (A) (B) (C) (D)
13. (A) (B) (C) (D)
14. (A) (B) (C) (D)
15. (A) (B) (C) (D)
16. (A) (B) (C) (D)
17. (A) (B) (C) (D)
18. (A) (B) (C) (D)
19. (A) (B) (C) (D)
20. (A) (B) (C) (D)

### Post-activity evaluation questions:

Rate how well the activity supported your achievement of these learning objectives:  
 1=Poor, 2=Fair, 3=Neutral, 4=Good, 5=Excellent

21. Improve my clinical ability to diagnose and manage ocular effects of traumatic brain injury. (1) (2) (3) (4) (5)
22. Become familiar with the key definitions related to traumatic brain injury. (1) (2) (3) (4) (5)
23. Increase my understanding of the pathophysiology of traumatic brain injury. (1) (2) (3) (4) (5)
24. Better understand the connection between PTSD, malingering stereotype and brain injury. (1) (2) (3) (4) (5)
25. Increase my knowledge of the signs and symptoms of brain injury. (1) (2) (3) (4) (5)
26. Improve my ability to communicate with patients about the nature of their brain injury and any treatment needed. (1) (2) (3) (4) (5)

Rate the quality of the material provided:  
 1=Strongly disagree, 2=Somewhat disagree, 3=Neutral, 4=Somewhat agree, 5=Strongly agree

27. The content was evidence-based. (1) (2) (3) (4) (5)
28. The content was balanced and free of bias. (1) (2) (3) (4) (5)
29. The presentation was clear and effective. (1) (2) (3) (4) (5)
30. Additional comments on this course:

Please retain a copy for your records. Please print clearly.

First Name

Last Name

E-Mail

The following is your:  Home Address  Business Address

Business Name

Address

City  State

ZIP

Telephone #  -  -

Fax #  -  -

By submitting this answer sheet, I certify that I have read the lesson in its entirety and completed the self-assessment exam personally based on the material presented. I have not obtained the answers to this exam by any fraudulent or improper means.

Signature \_\_\_\_\_ Date \_\_\_\_\_

Lesson 114851

RO-OSC-0717



# Every Picture Tells a Story

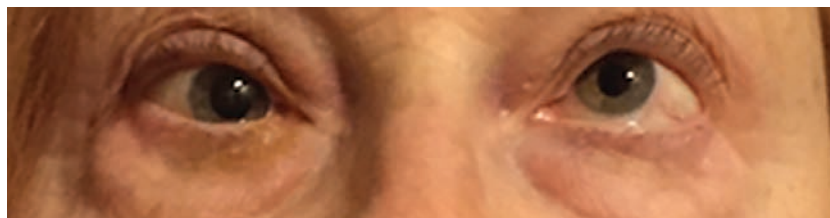
Studies suggest imaging is fruitful in cases of isolated palsies, regardless of whether neurological symptoms are present. **By Michael DelGiodice, OD, and Michael Trottini, OD**

It's debatable whether all acute isolated oculomotor cranial neuropathies, in patients older than 50 with or without vascular factors, should undergo neuroimaging.<sup>1-3</sup> Here, we review cranial nerve (CN) three, four and six palsies and provide reasons for neuroimaging all isolated cranial mononeuropathies.

## CN Three

The major functions of the third nerve are oculomotor and pupilomotor. Partial and complete third nerve palsies (TNPs) can be manifestations of ischemia in the setting of diabetes, hypertension and hyperlipidemia.<sup>4</sup> Non-ischemic pathologies involving the oculomotor nerve include hemorrhagic stroke, primary and secondary neoplasm, aneurysm, cavernous malformation, infection and demyelinating disease.<sup>5</sup>

Third nerve palsies are clinically differentiated as either partial or complete and pupil-sparing vs. pupil-involving. According to one study, aneurysms are likely to affect pupillomotor fibers in complete TNP, but spare its function in superior division palsies.<sup>6</sup> With regards to microvascular TNP, up to 20% of cases had pupil involvement.<sup>6</sup> And, according to a second study, the relative presence of aneurysm as a cause of isolated TNP ranged from 14% to 56%.<sup>7,8</sup> Finally, while evidence supports observation in complete isolated TNP without pupil involvement,



**This patient presented with an acute partial pupil-involved third nerve palsy from an aneurysm. The picture shows complete restriction of the right eye on upgaze.**

numerous case reports exist implicating midbrain infarction, neoplasm, infection, vasculitis, pituitary apoplexy, aneurysm and carotid artery occlusion as causes of isolated and complete TNP.<sup>7</sup>

Our recommendation is to obtain emergent CT/CTA or MRI/MRA in all TNPs. In cases where noninvasive neuroimaging is negative and aneurysm is highly suspected, such as in partial TNP with pupil involvement, cerebral angiography should be performed and interpreted by a neuroradiologist before discounting an aneurysm.

## CN Four

The most common causes of fourth nerve palsies (FNPs) are congenital, traumatic and vasculopathic. While isolated fourth nerve palsies in older individuals, especially with vascular disease, are most often ischemic in nature, additional etiologies include midbrain hemorrhage, pituitary macroadenoma, posterior fossa tumor, dural fistula, schwannoma and cavernoma of the fourth nerve.<sup>9-17</sup>

According to researchers, a small number of patients with

isolated FNPs have trochlear nerve schwannomas.<sup>18</sup> Additionally, one study describes a patient with an isolated FNP secondary to a cavernous meningioma, a second reports a patient with an intracavernous carotid artery aneurysm and a third study describes a patient with a carotid-cavernous fistula.<sup>19,20,13</sup> Given these findings, it is certainly prudent to consider obtaining contrast-enhanced MRI of the brain with special attention to the cavernous sinus, since there seems to be an increased prevalence of cavernous sinus disease in non-ischemic FNPs.

## CN Six

Sixth nerve palsy (SNP) is the most common ocular motor nerve palsy due to its long subarachnoid course.<sup>21</sup> According to researchers, the etiology of unilateral SNP is often attributed to ischemia, trauma, demyelinating disease, metastasis, aneurysm and intracranial hypertension, the latter of which can occur bilaterally.<sup>22</sup>

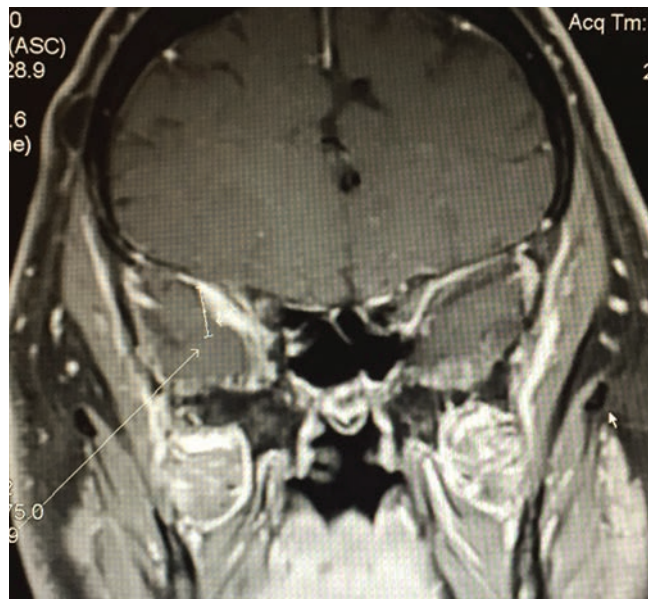
Because hypertension and diabetes are known etiologies of isolated SNPs in up to 35% of patients,



some researchers argue that monthly follow-up is the best approach.<sup>23</sup> The main disadvantage of these studies is the lack of brain MRI conducted during follow-up. Furthermore, one study concludes that significant evidence doesn't exist in the literature to warrant observation-only management.<sup>24</sup> A Medline literature search conducted by researchers reported 199 patients with isolated SNPs; 31 were traumatic, 42 vasculopathic, 43 "idiopathic;" 50 cases were related to tumors and the remainder were from miscellaneous causes (e.g., lumbar puncture, multiple sclerosis, immunization, infection, aneurysm, sarcoidosis, inflammatory, orbital amyloidosis and diverticulum of the cavernous sinus).<sup>25</sup> A second study reported spontaneous recovery of SNPs in the presence of extramedullary compression by a tumor at the base of the brain.<sup>26</sup>

Ultimately, it's our opinion that not enough evidence exists to support observation alone in isolated SNPs. It is reasonable to consider ordering contrast-enhanced MRI of the brain in patients with acute isolated SNPs; a previous study shows CT is not diagnostically beneficial.<sup>27</sup>

Until recently, no well-designed, randomized, prospective, controlled studies or prospective case series have been conducted. One study included patients with acute, non-traumatic, isolated ocular motor nerve palsies. Of the 66 patients followed, nine had significant causes; four patients



**This is an MRI of a 71-year-old white male who presented with an acute isolated right fourth nerve palsy. The MRI shows dural thickening abutting the cavernous sinus and possible compression of the fourth nerve within the cavernous sinus.**

with TNPs, two of which were pupil-involving, one patient with FNP, and four patients with SNPs. Excluding pupil-involving TNP, which is suggestive of aneurysm and routinely imaged, 11% of patients were identified as having a significant etiology, which were defined by the study as neoplasm, brainstem infarct, demyelinating disease and pituitary apoplexy. Subsequently, these patients were offered early medical and surgical management.<sup>28</sup> It's our opinion that sufficient data supports imaging all acute, isolated cranial nerve palsies regardless of the lack of associated neurologic symptoms. ■

1. Patel SV, Mutyala S, Leske DA, et al. Incidence, associations, and evaluation of sixth nerve palsy using a population-based method. *Ophthalmology*. 2004;111:369-75.
2. Bendszus M, Beck A, Koltzenburg M, et al. MRI in isolated sixth nerve palsies. *Neuroradiology*. 2001;43:742-5.
3. Tamhankar MA, Biousse V, Ying GS, et al. Isolated third, fourth, and sixth cranial nerve palsies from presumed microvascular versus other causes: a prospective study. *Ophthalmology*. 2013; 120(11):2264-2269.
4. Jacobson DM, McCanna TD, Layde PM. Risk factors for ischemic ocular motor nerve palsies. *Arch Ophthalmol*. 1994;112:961-6.

5. Bruce BB, Biousse V, Newman NJ. Third nerve palsies. *Semin Neurol* 2007; 27:257-68.
6. Trobe JD. Managing oculomotor nerve palsy. *Arch Ophthalmol*. 1998; 116:798-802.
7. Lee AG, Hayman LA, Brazis PW. The evaluation of isolated third nerve palsy revisited: an update on the evolving role of magnetic resonance, computed tomography, and catheter angiography. *Surv Ophthalmol*. 2002; 47:137-157.
8. Mathew MR, Teasdale E, McFadzean RM. Multidetector computed tomographic angiography in isolated third nerve palsy. Multidetector computed tomographic angiography in isolated third nerve palsy.
9. Galetta SL, Balcer LJ. Isolated fourth nerve palsy from midbrain hemorrhage: case report. *J Neuroophthalmol*. 1998; 18:204-205.
10. Petermann SH, Newman NJ. Pituitary macroadenoma manifesting as an isolated fourth nerve palsy. *Am J Ophthalmol*. 1999; 127:235-236.
11. Krohel GB, Mansour AM, Petersen WL, et al. Isolated trochlear nerve palsy secondary to a juvenile pilocytic astrocytoma. *J Clin Neuroophthalmol*. 1982; 2:119-123.
12. Mielke C, Alexander MS, Anand N. Isolated bilateral trochlear nerve palsy as the first clinical sign of a metastatic [correction of metastatic] bronchial carcinoma. *Am J Ophthalmol*. 2001; 132(4):593-4.
13. Selky AK, Purvin VA. Isolated trochlear nerve palsy secondary to dural carotid-cavernous sinus fistula. *J Neuroophthalmol*. 1994; 14:52-54.
14. Feinberg AS, Newman NJ. Schwannoma in patients with isolated unilateral trochlear nerve palsy. *Am J Ophthalmol*. 1999; 127:183-188.
15. Maurice-Williams RS. Isolated schwannoma of the fourth cranial nerve: case report. *J Neurol Neurosurg Psychiatry*. 1989; 52:1442-1443.2001; 132:593-594.
16. Leibovitch I, Pakrou D, Selva D, et al. Neuro-ophthalmic manifestations of intracranial cavernous hemangiomas. *Eur J Ophthalmol*. 2006; 16:148-152.
17. Surucu O, Sure U, Mittelbronn M, et al. Cavernoma of the trochlear nerve. *Clin Neurol Neurosurg*. 2007; 109:791-793.
18. Feinberg AS, Newman NJ. Schwannoma in patients with isolated unilateral trochlear nerve palsy. *Am J Ophthalmol*. 1999 Feb; 127(2):183-8.
19. Slavin M. Isolated trochlear nerve palsy secondary to cavernous sinus meningioma. *Am J Ophthalmol*. 1987; 104:433-4.
20. Arruga J, de Rivas P, Espinet H, Conesa G. Chronic isolated trochlear nerve palsy produced by intracavernous internal carotid artery aneurysm. *J Clin Neuro-ophthalmol*. 1991; 11:104-8.
21. Rosenberg RN. *Comprehensive Neurology*. New York: Raven Press, 1991.
22. Richards BW, Jones FR Jr, Younger BR. Causes and prognosis in 4,278 cases of paralysis of the oculomotor, trochlear, and abducens cranial nerves. *Am J Ophthalmol*. 1992; 113(5):489-496.
23. Patel S. V., Mutyala S., Leske D. A. et al. Incidence, associations, and evaluation of sixth nerve palsy using a population-based method. *Ophthalmology*. 2004; 111:369-75.
24. Moster ML, Savino PJ, Sergott RC, et al. Isolated sixth-nerve palsies in younger adults. *Arch Ophthalmol*. 1984; 102:1328-30.
25. Miller RW et al. A Practice Pathway for the Initial Diagnostic Evaluation of Isolated Sixth Cranial Nerve Palsies. *Med Decis Making*. 1999; 19:42-48.
26. Volpe NJ, Lessell S. Remitting sixth nerve palsy in skull base tumors. *Arch Ophthalmol*. 1993; 111:1391-5.
27. Nolan J. Diplopia. *Br J Ophthalmol*. 1968; 52:166-71.
28. Volpe N. The Work Up of Isolated Ocular Motor Palsy: Who to Scan and Why. <http://content.lib.utah.edu/utlib/getfile/collection/ehsl-nam/1d/116/filename/7.pdf>. 2009. Accessed Jun7, 2015.

2017

# WEST COAST Optometric Glaucoma Symposium

Up to  
12 CE  
Credits\*

**DECEMBER 15-16, 2017**

Join our faculty of renowned ODs, MDs and PhDs for a highly interactive meeting covering the most up-to-date information in glaucoma care. Up to 12 CE credits for only \$275.

## **HILTON HOTEL HUNTINGTON BEACH**

21100 Pacific Coast Highway  
Huntington Beach, CA 92648

Discounted room rate: \$227/night + applicable taxes and fees. Please call the hotel directly at 714-845-8000 and mention "WCOGS" for group rate.

## **MEETING CO-CHAIRS:**



Murray Fingeret, OD



Robert Weinreb, MD

**SPEAKERS:** Alex Huang, MD      Ben Gaddie, OD  
Sameh Mosaed, MD      Richard Madonna, OD

## **THREE WAYS TO REGISTER**

[www.reviewofoptometry.com/WCOGS2017](http://www.reviewofoptometry.com/WCOGS2017)

Email: [ReviewMeetings@Jobson.com](mailto:ReviewMeetings@Jobson.com)

Call Lois DiDomenico: 877-451-6514

Administered by

**Review of Optometry®**



\*Approval pending

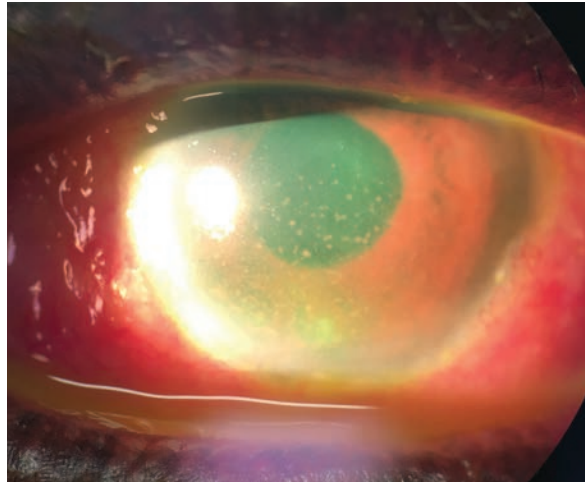


# Lymphocytes on the Loose

Most anterior uveitis arises from systemic causes. Make the connection and you'll be better equipped to quickly and accurately distinguish etiologies. **By Bisant A. Labib, OD**

**W**e all know the classic presentation of uveitis: cells and flare, pain, photophobia and reduced vision. But because a multitude of events can trigger such a response, we sometimes lose sight of how these processes occur and what they signify about our patient. Myriad underlying systemic conditions can cause anterior uveitis (AU); it is often the ocular sequela of an autoimmune condition or infection, and many of the potential causes lead to significant morbidity if left unmanaged.<sup>1-3</sup> The patient's systemic and ocular health rely on you, the optometrist, to carefully and strategically undertake a systemic review and work-up of AU patients, to investigate and potentially uncover, an infectious, autoimmune or inflammatory underlying etiology.

Historically, the majority of AU cases were thought to be idiopathic; now we know that a properly executed work-up, combined with more recent and advanced diagnostic techniques, yields an underlying systemic diagnosis in 70% of cases.<sup>4</sup> The need is clear for a careful ocular evaluation and review of histopathological and immunological mechanisms to further narrow down the systemic work-up. This month, we will focus on the steps to achieve this.



**Deposition of keratic precipitates on the inferior corneal endothelium.**

## AU Common Symptoms

The most commonly reported symptom of AU is blurred vision, caused by the infiltration of cells into the otherwise clear anterior chamber and anterior vitreous cavity.<sup>1,2,5,6</sup> In cases of Fuchs' uveitis syndrome (FUS), blur is often the only reported symptom; this is a key feature to help you differentiate between FUS and other types of AU. For FUS, treatment with corticosteroids is sufficient and work-up is unnecessary.<sup>5,6</sup>

Pain is a common complaint of AU with an as-yet undisclosed systemic etiology. Pain as a response to light, and described as worsening at near, is caused by ciliary and iris sphincter muscle spasms.<sup>1,2</sup> It can vary in severity and may be described as mild as a dull ache or as extreme as referred pain that spans the area supplied by the tri-

geminal nerve.<sup>2</sup>

Tearing, a result of trigeminal nerve stimulation and irritation, is another commonly reported symptom.<sup>2</sup> Other possible symptoms include redness and, less commonly, floaters.<sup>2</sup>

## Exam Intricacies

AU presents, anatomically, in three forms:

- iritis (involving only the iris);
- anterior cyclitis (anterior portion of the ciliary body); and
- iridocyclitis (a combination of iris and anterior ciliary body).<sup>1,3</sup>

Though the clinical findings that lead to a general diagnosis of AU are fairly similar, a few key intricacies exist that can help determine the subsequent systemic questionnaire and work-up, after you've confirmed a case.

**Conjunctival injection.** The dilation of the episcleral blood vessels in response to inflammation causes prominent vasculature and hyperemia to appear around the limbus.<sup>1,4</sup> The conjunctival injection may also be diffuse.<sup>1,2</sup> Both FUS and Posner-Schlossman syndrome (PSS) present with low-grade inflammation, and these diagnoses should be considered in the absence of prominent conjunctival injection.<sup>5-7</sup>

**Keratic precipitates (KPs).** These deposits of various cell

**Table 1. Systemic Etiologies of Uveitis**

Granulomatous	Non-granulomatous
Herpes viruses: simplex, zoster, cytomegalovirus, Epstein-Barr	HLA-B27 conditions: ankylosing spondylitis, Reiter's syndrome, Crohn's disease, ulcerative colitis
Sarcoidosis	Behcet's syndrome
Tuberculosis	Juvenile idiopathic arthritis
Lyme disease	Tubulointerstitial nephritis
Syphilis	
Multiple sclerosis	

**Table 2. Summary of Clinical Features of PSS and FUS**

	Posner-Schlossman	Fuchs' Uveitis Syndrome
Symptoms	Blur or haloes no pain	Blur or haloes no pain
Signs	Unilateral presentation Low grade cells Fine KPs No injection Significantly elevated IOP	Unilateral presentation Low grade cells Diffuse fine or mutton fat KPs Iris hypochromia/diffuse atrophy No injection
Treatment	Anti-hypertensives Corticosteroids No systemic work-up indicated	Not usually responsive to corticosteroids No systemic work-up indicated

types on the surface of the corneal endothelium serve as perhaps the most important clinical finding in narrowing the potential cause of a patient's AU. Fine, stellate and diffuse KPs are made up of lympho-plasmocytic inflammatory cells and indicate a non-granulomatous etiology, which may be allergic inflammatory in nature; on the other hand, medium to large "mutton fat" KPs consist of both lympho-plasmocytic inflammatory and epitheloid cells and point to granulomatous inflammation.<sup>1,2,4,8</sup> Pigmented KPs are often indicative of a previous episode or episodes of AU, in contrast to fresh KPs that appear round, white and fluffy.<sup>1-3</sup>

Paying close attention to the exact location and deposition of

KPs helps distinguish some conditions. The normal convection current of the aqueous is created by a temperature gradient, where cells are moved upwards towards the lens where the temperature is warmer, and then downwards towards the cornea where the temperature is cooler, depositing inferiorly on the endothelium.<sup>2</sup> The pattern of this deposition, known as "Arlt's triangle," is displayed as a base-down triangle at the inferior corneal endothelium.<sup>2,3</sup> KPs deposited outside of this triangle, in a diffuse pattern, are suggestive of FUS and herpetic etiologies.<sup>2,3,5,9</sup>

**Anterior chamber cells and flare.** This clinical manifestation is pathognomonic for AU. Aqueous cells consist of inflammatory cells

(mainly lymphocytes, and neutrophils to a lesser degree) that have leaked into the anterior chamber as a result of the breakdown in the blood-aqueous barrier.<sup>1,2,4</sup> These cells are amelanotic and must be differentiated from the brownish pigment that is released in cases of pigment dispersion syndrome or following pupillary dilation.<sup>4</sup> The exudation of protein (albumin) into the anterior chamber comprises flare.<sup>2</sup>

The quantity of cells and flare in the anterior chamber is helpful in differentiating purely ocular vs. systemic etiologies. Systemic causes of cells or flare are typically more significant, as they are caused by more severe extraocular inflammatory diseases. If seen in trace quantities, PSS and FUS should be excluded before assuming systemic work-up.<sup>5-7</sup> By contrast, if cells are seen in dense quantities, forming a hypopyon or fibrinous clot, these typically suggest AU secondary to HLA-B27-related conditions such as juvenile idiopathic arthritis (JIA) or Behcet's disease.<sup>1,4</sup>

**Iris changes.** Inflammatory cells may also deposit onto the surface of the iris in granulomatous forms of uveitis. When they are located on the pupillary border, they are called Koeppe's nodules. These nodules, when located elsewhere on the iris body stroma, are called Busacca's nodules.<sup>1,4</sup>

Iris atrophy may also be seen in FUS and AU that is secondary to herpetic disease. Diffuse iris atrophy and hypochromia are seen more commonly in FUS, whereas sectoral atrophy is more characteristic of AU caused by the herpes virus.<sup>5,6,9</sup> Though the exact mechanism is unknown, researchers believe that the herpes virus invades the pigment epithelium of the iris, causing these atrophic

patches in previous or active bouts of AU.<sup>10</sup> In contrast, researchers believe the etiology of FUS (also not completely understood) is a sympathetic dysfunction; as such, the hypochromic iris—indicating the affected eye—may be a result of decreased innervation to the iris stroma.<sup>11</sup>

**Intraocular pressure (IOP).** In AU, patients may present with abnormal IOP, which can be either significantly higher or lower than the non-affected eye. Unilateral IOP spikes on initial presentation are characteristic of herpes simplex/zoster or PSS.<sup>4,7,9</sup> Studies show both the herpes virus and PSS to cause damage or inflammation that is localized to the trabecular meshwork, which explains the elevation in IOP.<sup>4,7,9</sup> This is in con-

trast to lower IOP in the affected eye, which is more suggestive of an etiology, such as HLA-B27-related uveitides from ciliary body ischemia and less aqueous production.<sup>4</sup>

### Putting the Pieces Together

Carefully examining the clinical manifestations on initial presentation of AU alone can significantly reduce the clinician's list of differential diagnoses. This also eliminates the "shotgun" approach of non-systematic, overly laborious medical work-up; rather, it promotes a more targeted approach to help determine a management plan. Of course, given the possible, and often probable, systemic underpinnings, anticipate that this plan will be carried out in conjunction with the patient's primary care

physician or rheumatologist. ■

1. Agrawal RV, Murthy S, Sangwan V, et al. Current approach in diagnosis and management of anterior uveitis. *Ind J Ophthalmol.* 2010;58(1):11-19.
2. Kelkar AS, Arora ER, Sowkath B, et al. Uveitis: classification, etiologies, and clinical signs. *Del J Ophthalmol.* 2016;26(4):264-71.
3. Guney E, Tugal-Tutkun I. Symptoms and signs of anterior uveitis. *Touch Medical Media.* 2013;6(1):33-7.
4. Herbert CP. Appraisal, work-up and diagnosis of anterior uveitis: A practical approach. *Middle East Afr J Ophthalmol.* 2009;16(4):159-67.
5. Nalcacioglu P, Ozdel PC, Simsek M. Clinical characteristics of fuchs' uveitis syndrome. *Turk J Ophthalmol.* 2016;46:52-7.
6. Mocan MC, Kadayifcilar S, Irkec M. In vivo confocal microscopic evaluation of keratic precipitates and endothelial morphology in Fuchs' uveitis syndrome. *Eye.* 2012;26(1):119-25.
7. Green RJ. Posner-Schlossman syndrome. *Clin Exp Optom.* 2007;90(1):53-6.
8. Kanavi MR, Soheilian M. Confocal scan features of keratic precipitates in granulomatous versus nongranulomatous uveitis. *J Ophthalmic Vis Res.* 2011;6(4):255.
9. Kardes E, Bozjurt K, Akcay BI, et al. Clinical features and prognosis of herpetic anterior uveitis. *Turk J Ophthalmol.* 2016;46(3):109-13.
10. Marsh RJ, Easty DL, Jones BR. Iritis and iris atrophy in herpes zoster ophthalmicus. *Am J Ophthalmol.* 1974;78(2):255-61.
11. Mohamed Q, Zamir E. Update of Fuchs' uveitis syndrome. *Curr Opin Ophthalmol* 2005;16(6):356-63.

# HIRE THE BEST in Optometry



We provide you with the tools to recruit & hire the best Optometrists in the industry.

Find out how easy recruiting can be.



[localeyesite.com/hire/ods](http://localeyesite.com/hire/ods)



**Local Eye Site**  
JOBS IN EYE CARE



# Not Just Another Headache

Migraine is the most common disabling brain disorder. Are you ready to help these patients? **By Carlo J. Pelino, OD, and Joseph J. Pizzimenti, OD**

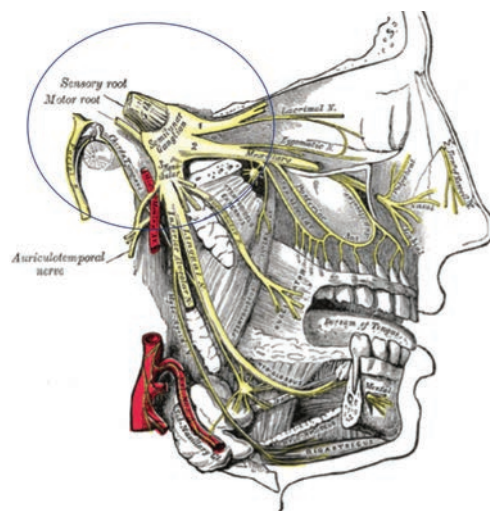
**H**eadache is one of the most common patient symptoms and a frequent condition encountered by optometrists and other health care providers. Millions of Americans are living with the complex, recurrent headache disorder known as migraine.<sup>1</sup> The name migraine is derived from the Greek word *hemikrania*, meaning half of the head, representing one of the most striking features of the condition: In many cases the pain is unilateral.<sup>1,2</sup> Migraine often comes with visual signs and symptoms, and patients will present to your office looking for relief. Knowing what to look for is the first step in properly diagnosing migraine and starting patients on the path to better control.

## Headache Basics

The term *primary headache* describes head pain due to the headache condition itself, and not a result of another cause. A *secondary headache* is one that is present because of another condition such as sinusitis, for example.

The three types of primary headache are migraine, tension and cluster. Migraine headache is recognized as a distinct neurological disease of complex pathophysiology and is considered the most common disabling brain disorder.<sup>1,2</sup>

Migraine is further classified into migraine with aura, migraine without aura and chronic migraine.<sup>1,2</sup>



**Fig. 1. The trigeminovascular system may be a prominent component in the circuitry of migraine.**

The typical chief symptom is a severe, unilateral, throbbing head pain or pulsing sensation, which may be preceded or accompanied by visual alterations, difficulty speaking, numbness of the face, nausea, vomiting and extreme sensitivity to light and sound.<sup>1-3</sup> About 20% of migraine sufferers experience aura—a complex of neurological symptoms that occurs usually before the headache. Most aura is visual, consisting of a combination of positive visual phenomena (floaters, flashes, zig-zag patterns) and negative phenomena (loss of vision causing blind spots).

Some patients experience a prodrome. One or two days before the attack, they may notice subtle changes, including:

- Constipation
- Mood changes, from depression to euphoria
- Food cravings

- Neck stiffness
- Increased thirst and urination
- Frequent yawning

## The Stats

More than 30 million people in the United States experience one or more migraines per year, the majority (75%) of whom are women.<sup>1,2</sup> The overall prevalence of migraine is 18% in women and 6% in men.<sup>2-4</sup> About 70% of patients have a first-degree relative with a history of migraine, suggesting a genetic component exists.<sup>3,4</sup>

The Women's Health Study, which included professional women older than 45, shows that any history of migraine is associated with a higher incidence of major cardiovascular disease.<sup>4,5</sup> Those with a history of migraine with aura have the highest cardiovascular risk with a 2.3-fold risk of cardiovascular death and a 1.3-fold risk of coronary vascularization.<sup>4,5</sup>

Chronic migraine, characterized by the experience of migrainous headache on at least 15 days per month, is highly disabling and may impair a person's ability to accomplish everyday activities.

## The Pathways

Migraine etiology was previously considered a vascular issue resulting from intracranial vasoconstriction followed by rebound vasodilation. However, this contradicts the efficacy of pharmacotherapies that have no effect on blood vessels.<sup>2,3,5</sup>

Image: Grey's Anatomy, Public Domain

**Table 1. When It's Not Migraine: Red Flags<sup>1,2</sup>**

- First or worst headache ever
- New onset
- Onset after age 50
- Change in pattern of headache
- Worsening headache
- Acute or sudden onset
- Sudden onset during exertion (e.g., coughing, sneezing, sexual activity)
- With postural link
- In a setting of malignancy or HIV
- Systemic symptoms (e.g., fever, weight loss, cough)
- Neurologic symptoms or signs

More appropriately, studies suggest the origin of a migraine attack is associated with neuronal activation, during which a series of central and peripheral neural and vascular events initiate the migraine.<sup>3,4</sup> Proponents describe migraine as primarily a neurogenic process with secondary changes in cerebral perfusion.<sup>2,3</sup>

A plexus of largely unmyelinated fibers from the ophthalmic division of the trigeminal nerve and the upper cervical dorsal roots surround the large cerebral vessels, pial vessels, large venous sinuses and dura mater of the meninges (*Figure 1*).<sup>2,3</sup> When the trigeminal fibers innervating these vessels are activated, a stimulation of nociceptive neurons releases plasma proteins and pain-generating substances such as calcitonin gene-related peptide, substance P, vasoactive intestinal peptide and neurokinin A.<sup>2,3</sup> These substances eventually produce blood vessel dilation, protein extravasation and inflammation. Stimulation of these

cranial vessels is quite painful.<sup>2,4</sup>

Researchers now propose that brainstem activation may be the initiating factor.<sup>2,3</sup> Functional brain imaging with positron emission tomography (PET) scans performed during migraine without aura has shown activation of the dorsal mid-brain, including the periaqueductal grey and in the dorsal pons, near the locus coeruleus.<sup>2,3</sup> Investigators believe the most important receptor in the headache pathway is the serotonin receptor (5-hydroxytryptamine [5-HT]). Immunohistochemical studies have detected 5-HT<sub>1D</sub> receptors in trigeminal sensory neurons, while 5-HT<sub>1B</sub> receptors are present on smooth muscle cells found in meningeal vessels.<sup>2,3</sup>

### The Triggers

As there is no known cure for migraine, patients most often rely on avoiding triggers whenever possible.<sup>5</sup> For many patients, anything from stress, caffeine, chocolate and alcohol to hormonal changes during the menstrual cycle and foods that contain nitrates, tyramine, monosodium glutamate or aspartame can initiate or aggravate the migraine.<sup>1,2</sup> Avoiding such triggers may help to reduce their frequency or severity.<sup>5</sup>

### Diagnostic Guidelines

The diagnosis of migraine is based on patient history. The International Classification of Headache Disorders diagnostic criteria is as follows:<sup>6</sup>

1. At least five attacks fulfilling criteria two through four
2. Attacks lasting four to 72 hours (untreated or unsuccessfully treated)
3. At least two of the following four characteristics:
  - a. Unilateral location
  - b. Pulsating quality
  - c. Moderate or severe pain
  - d. Aggravation by or causing avoidance of routine physical activity (e.g., walking or climbing stairs)
4. During headache, at least one of the following:
  - a. Nausea, vomiting or both
  - b. Photophobia/phonophobia
5. Cannot be attributed to another medical condition

Some signs and symptoms, however, should lead you to suspect a secondary headache such as a “thunderclap” or persistent worsening headache caused by a more serious medical problem (*Tables 1 and 2*).

It is not uncommon for patients to exhibit characteristics of more than one subtype of migraine, in which case all subtypes that present should be diagnosed. For example, a patient may have frequent attacks with aura but also some attacks without aura.

Stay tuned for our next column, which will discuss the various management strategies you can employ to help these patients overcome the disabling effects of migraine. ■

**Table 2. Conditions Associated with Secondary Headache<sup>2</sup>**

“Thunderclap” Headache	Persistent Worsening Headache
<ul style="list-style-type: none"> <li>• Subarachnoid hemorrhage</li> <li>• Cerebral venous sinus thrombosis (CVST)</li> <li>• Reversible cerebral vasoconstriction syndrome</li> <li>• Carotid/vertebral artery dissection</li> <li>• Pituitary apoplexy</li> <li>• Intracerebral hemorrhage/hematoma</li> <li>• Hypertensive encephalopathy</li> <li>• Idiopathic thunderclap hemorrhage (Call–Fleming syndrome)</li> </ul>	<ul style="list-style-type: none"> <li>• Raised cerebrospinal fluid (CSF) pressure (tumor, abscess, CVST, idiopathic intracranial hypertension)</li> <li>• Low CSF volume (post-lumbar puncture, spontaneous CSF leak)</li> <li>• Meningitis (acute/chronic)</li> <li>• Hypoxia/hypercapnia</li> <li>• Substance abuse/withdrawal</li> <li>• Systemic inflammatory conditions, including temporal arteritis</li> </ul>

1. Hildreth CJ, Lynn C, Glass RM. Migraine headache. *JAMA*. 2009;301(24):2608.

2. Weatherall MW. The diagnosis and treatment of chronic migraine. *Therapeutic Advances in Chronic Disease*. 2015;6(3):115-23.

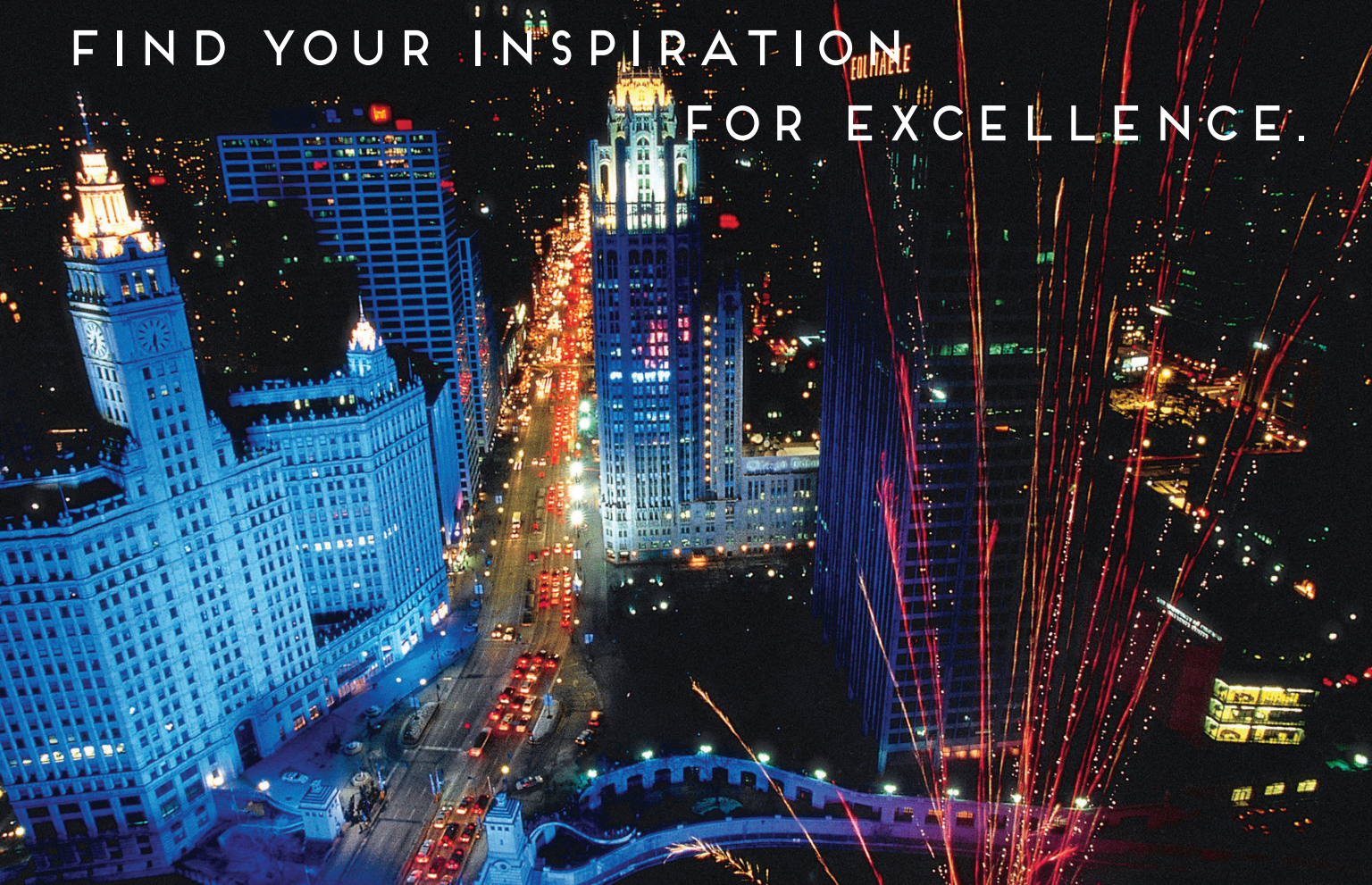3. Goadsby PJ. Pathophysiology of migraine. *Ann Indian Acad Neurol*. 2012;15(Suppl S1):15-22.

4. Van den Maagdenberg AM, Haan J, Terwindt GM, Ferrari MD. Migraine: Gene mutations and functional consequences. *Curr Opin Neurol*. 2007;20:299-305.

5. Estemalik E, Tepper S. Preventive treatment in migraine and the new US guidelines. *Neuropsychiatr Dis Treat*. 2013;9:709-20.

6. Headache Classification Committee of the International Headache Society. The International Classification of Headache Disorders, 3rd edition. 2013. [www.ihc-headache.org/binary\\_data/1437\\_ichd-iii-beta-cephalalgia-issue-9-2013.pdf](http://www.ihc-headache.org/binary_data/1437_ichd-iii-beta-cephalalgia-issue-9-2013.pdf). Accessed June 5, 2017.

FIND YOUR INSPIRATION  
FOR EXCELLENCE.



OCTOBER 11-14, 2017 • MCCORMICK PLACE



Find your inspiration for excellence at Academy 2017 Chicago. Join us in Chicago for four days of brilliant speakers, clinically-relevant CE sessions, the latest products and technology in the exhibit hall, captivating papers and posters and cherished social events.



AMERICAN ACADEMY  
*of* OPTOMETRY

Early bird registration ends August 7! Register today at [www.aaopt.org](http://www.aaopt.org).





# Prescribe with Laser Focus

Know how to pair drugs with associated procedures.

By Alan G. Kabat, OD, and Joseph W. Sowka, OD

**L**aser procedures represent the next frontier in optometric scope expansion for many states. Knowing the risks, benefits and indications for these procedures is critically important for doctors who would perform them. Yet, understanding the periprocedural management of laser surgical patients is equally crucial for success in these endeavors.

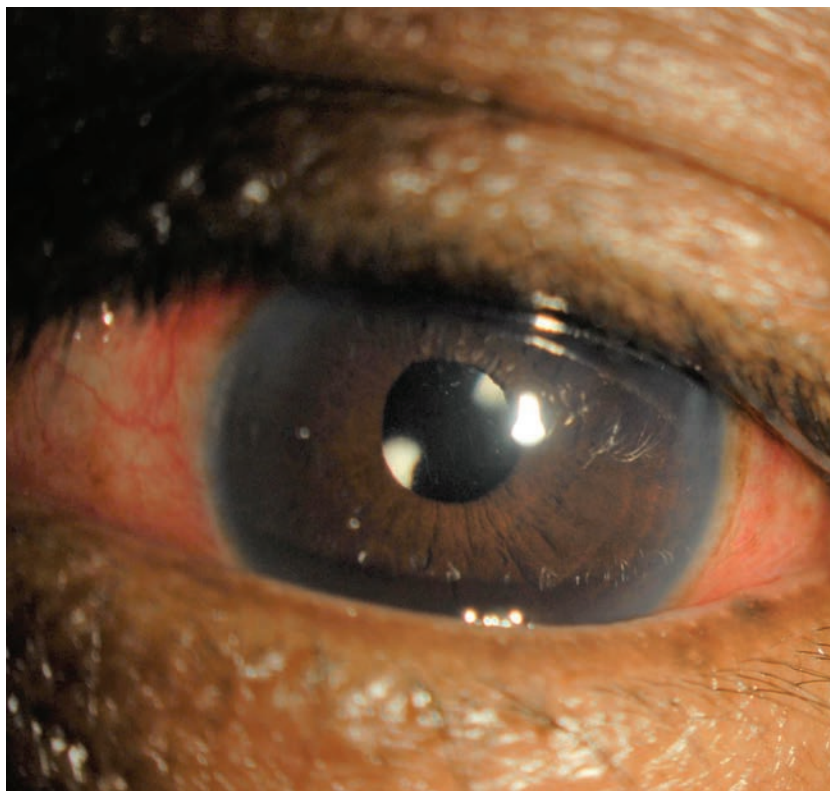
This month, we review some of the more common laser procedures for the anterior segment, focusing on pre- and postoperative care to ensure the best possible outcomes.

## Techniques

Currently, certified optometrists in Kentucky, Louisiana and Oklahoma can perform laser procedures, but only procedures that involve structures of the anterior segment. Three specific techniques account for the vast majority of laser procedures by ODs. They are:

- Laser capsulotomy for posterior capsular fibrosis, sometimes referred to as “after-cataract.”
- Laser peripheral iridotomy (LPI) for those at risk for or suffering from angle closure glaucoma.
- Laser trabeculoplasty using either the argon laser (ALT) or the Nd:YAG laser (selective laser trabeculoplasty or SLT).

Less frequently, lasers may be used to perform iridoplasty on narrow angles, or to remove lesions from the ocular adnexa. Techniques that are expressly forbidden in these states include retinal laser proce-



**This one-day postoperative cataract surgery patient displays redness indicating inflammation, similar to the inflammation laser procedure patients face.**

dures (e.g., focal or panretinal laser photocoagulation), laser *in situ* keratomileusis (LASIK) and other refractive or cosmetic surgeries.

## YAG Capsulotomy

Opacification of the posterior capsule is a common complication of phacoemulsification surgery for cataracts, with estimates as high as 18% of cases.<sup>1</sup> Researchers believe it occurs because of postoperative proliferation and migration of residual lens epithelial cells within the pos-

terior capsular bag.<sup>2,3</sup> Symptoms of posterior capsule opacification (PCO) may not become manifest for months or even years after the initial surgery, but can include such diverse complaints as blurred vision, decreased contrast sensitivity, increased glare and even monocular diplopia.<sup>1</sup> The only remedy for this problem is laser capsulotomy.<sup>2</sup> Essentially, this involves using the Nd:YAG laser to create an opening in the posterior capsule, eliminating obscuration of the visual axis.

## Dr. Sowka's Personal Perspective

We detailed in an earlier column how we encountered a printed brochure extolling that SLT creates no side effect.<sup>1</sup> However, risks are associated with any procedure and laser procedures are no exceptions. I am personally aware of a situation where a patient with ocular hypertension underwent a so-called benign SLT, only to develop an intractable IOP spike into the 40s necessitating bilateral trabeculectomy. I myself recently underwent one of the above-mentioned laser procedures without complications, until I awoke the next morning with hazy vision, steamy corneal edema, and an IOP spike into the 50s! Fortunately, the complication was short-lived and easily managed, but had I been a fragile glaucoma patient, the outcome could have been poor.

1. Sowka J, Kabat A. Irresponsible education. *Rev. of Optom.* 2016 April;153(4):88-9.

Discharging laser energy into the eye can result in a host of undesirable sequelae. These commonly consist of transiently elevated intraocular pressure (IOP), postoperative inflammation (i.e., mild anterior uveitis) and an increase in floaters.<sup>1</sup> Less frequent, but more serious, complications include retinal detachment, cystoid macular edema, pitting or displacement of the lens implant, iris hemorrhage and vitreous prolapse.<sup>1,4</sup> To minimize these complications, the physician must make appropriate use of perioperative medications and perform careful postoperative assessment.

To guard against a pressure spike, it is customary to instill an IOP-lowering agent prophylactically several minutes before or immediately after performing laser capsulotomy.<sup>1,4</sup> Historically, 1% apraclonidine was the drug of choice, but today 0.2% brimonidine is often used in a similar fashion.<sup>5</sup> Studies show these agents can help minimize IOP spikes.<sup>5,6</sup> The greatest incidence of IOP elevation occurs within three hours of the procedure and tends to return to normal within 24 hours.<sup>1</sup> Those in whom higher amounts of laser energy are used during the procedure have a greater tendency toward more severe or prolonged IOP elevation, as do those with a prior diagnosis of glaucoma or ocular hypertension.<sup>7</sup>

For these individuals, recheck the IOP one to four hours after the procedure; if elevated, the continued use of a topical IOP-lowering agent during the postoperative period is recommended.<sup>4</sup>

Corticosteroid drops are also commonly given postoperatively after laser capsulotomy to curb associated inflammation. Prednisolone acetate 1% QID remains the standard for most physicians, although some practitioners prefer loteprednol 0.5% QID or even difluprednate 0.05% BID-TID. Follow-up is usually at one week following surgery, at which point IOP is measured and the anterior chamber assessed. If normal, drops can be discontinued at this point. Obviously, if pain, reduced vision, newly observed flashes or floaters occur at any point postoperatively, urge the patient to return immediately. Routine dilation following capsulotomy is generally not necessary unless symptoms dictate otherwise.

## Peripheral Iridotomy

This procedure, which seeks to alleviate pupil-block, results in deepening of the anterior chamber angle and alleviating or preventing angle-closure glaucoma (ACG) by creating a pathway for aqueous egress from the posterior to the anterior chamber and into the trabecular meshwork (TM). This technique can be per-

formed as a therapeutic measure for those in acute or chronic ACG, or as a prophylactic measure for those determined to be at increased risk (i.e., anatomically narrow angles).<sup>8</sup> The Nd:YAG laser is typically the device of choice for this procedure, although in dark irides both argon and Nd:YAG lasers may be used sequentially.<sup>8</sup>

The risks associated with LPI are similar to those encountered with laser capsulotomy, including postprocedural IOP elevation and anterior uveitis. Less common sequelae include burns to the cornea or retina, or both, macular edema and retinal detachment.<sup>9</sup> To prevent an associated IOP spike, one drop of apraclonidine or brimonidine is instilled about 20 minutes before the procedure.<sup>10</sup> In addition to lowering IOP, pilocarpine is also used to induce miosis, stretching the iris and facilitating penetration of the tissue with less laser energy.<sup>10</sup> IOP should be checked roughly 30 minutes to 60 minutes after the procedure. As with laser capsulotomy, the use of topical corticosteroids is helpful in minimizing post-procedural inflammation. The one-week follow up involves inspection of the iridotomy site to ensure patency, IOP measurement and assessment of intraocular inflammation. Physicians may also complete a one-month follow-up, which includes a dilated fundus examination. If IOP is elevated with dilation after LPI, the clinician should suspect alternative mechanisms of glaucoma (e.g., plateau iris or other non-pupil block conditions).

## Laser Trabeculoplasty

In this procedure, the laser is directed at the pigmented epithelium of the TM via a gonioscopy lens. Although the exact therapeutic mechanism remains incompletely

# Advertisers Index

understood, the successful result is diminished IOP by way of enhanced outflow through Schlemm's canal.<sup>11</sup> ALT acts through thermal alteration of the TM while SLT enhances biologic activity in this structure.<sup>11</sup> Because SLT induces far less structural damage to the TM than ALT, SLT can potentially be repeated once if IOP control falters over time.<sup>12</sup>

As with LPI and YAG capsulotomy, the main complications of SLT include a postprocedural IOP spike and secondary inflammation.<sup>9</sup> This paradoxical IOP spike seems to happen more commonly in heavily pigmented angles such as those encountered in exfoliative and pigmentary glaucoma.<sup>13</sup> The use of apraclonidine or brimonidine before and immediately after SLT helps to blunt this effect.<sup>9,11</sup>

Postoperative corticosteroid use remains controversial, although a symptomatic anterior chamber reaction is not uncommon following SLT. While some continue to advocate for steroids, others suggest that their use may hinder the subsequent IOP-lowering effect.<sup>11</sup> A randomized, controlled study evaluating the use of anti-inflammatory agents following SLT revealed little difference between groups using 1% prednisolone acetate, 0.5% ketorolac or artificial tears QID for five days postoperatively.<sup>14</sup>

An ancient Greek philosopher once proclaimed, "Change is the only constant in life." Our profession has changed dramatically since its inception, and it will continue to evolve. As we prepare for surgical privileges in optometry, we must be certain that we first comprehend the impact of our actions and can manage the potential complications effectively. ■

1. Boucher K, Ellis B, Lighthizer N. Capping off cataract surgery. *Rev of Optom.* 2015 Jun;152(6):44-52.
2. Sharon Y, Livny E, Mimouni M, et al. Laser capsulotomy following cataract surgery: comparing time to capsulotomy with implantation of two broadly used intraocular lenses. *Indian J Ophthalmol.* 2017 Feb;65(2):144-7.
3. Wormstone IM, Eldred JA. Experimental models for posterior capsule opacification research. *Exp Eye Res.* 2016 Jan;142:2-12.
4. Steinert RF. Nd:YAG laser posterior capsulotomy. *American Academy of Ophthalmology. www.aao.org/munnerlyn-laser-surgery-center/ndyag-laser-posterior-capsulotomy-3.* November 4, 2013. Accessed May 20, 2017.
5. Singhal D, Desai R, Desai S, et al. Use of topical brimonidine to prevent intraocular pressure elevations following Nd: YAG-laser posterior capsulotomy. *J Pharmacol Pharmacother.* 2011 Apr-Jun; 2(2):104-6.
6. Kaur M, Singh A, Kailwoo S. Apraclonidine 1% to prevent post Nd:Yag laser capsulotomy rise of intraocular pressure. *JARMS.* 2012;4(3):237-42.
7. Bhargava R, Kumar P, Phogat H, Chaudhary KP. Neodymium-yttrium aluminium garnet laser capsulotomy energy levels for posterior capsule opacification. *J Ophthalmic Vis Res.* 2015 Jan-Mar;10(1):37-42.
8. de Silva DJ, Gazzard G, Foster P. Laser iridotomy in dark irides. *Br J Ophthalmol.* 2007 Feb;91(2):222-5.
9. Van Alstine A, Caruso JM. Managing the post-op glaucoma patient. *Rev of Optom.* 2016 Oct;153(10):58-65.
10. Shetler J, Miller J, Lighthizer N. Breaking down barriers: iridotomy in optometric practice. *Rev of Optom.* 2016 May;153(5):74-82.
11. Leahy KE, White AJ. Selective laser trabeculoplasty: current perspectives. *Clin Ophthalmol.* 2015 May 11;9:833-41.
12. Latina MA, Tumbocon JA. Selective laser trabeculoplasty: a new treatment option for open angle glaucoma. *Curr Opin Ophthalmol.* 2002 Apr;13(2):94-6.
13. Zhou Y, Aref A. A review of selective laser trabeculoplasty: recent findings and current perspectives. *Ophthalmol Ther.* 2017 Mar 3. doi: 10.1007/s40123-017-0082-x. [Epub ahead of print]
14. Jinapriya D, D'Souza M, Hollands H, et al. Anti-inflammatory therapy after selective laser trabeculoplasty: a randomized, double-masked, placebo-controlled clinical trial. *Ophthalmology.* 2014 Dec;121(12):2356-61.

<b>Alcon Laboratories</b> .....	<b>13, 27, 28, 100</b>
Phone .....	(800) 451-3937
Fax.....	(817) 551-4352
<b>Allergan, Inc.</b> .....	<b>25</b>
Phone .....	(800) 347-4500
<b>Bausch + Lomb</b> .....	<b>10, 31, 32, 61, 62-63</b>
Phone .....	(800) 323-0000
Fax.....	(813) 975-7762
<b>Beaver-Visitec International, Inc.</b> .....	<b>9</b>
Phone .....	(866) 906-8080
Fax.....	(866) 906-4304
.....	www.beaver-visitec.com
<b>CooperVision</b> .....	<b>99</b>
Phone .....	(800) 341-2020
<b>Icare USA</b> .....	<b>21</b>
Phone .....	(888) 389-4022
.....	www.icare-usa.com
<b>Katena</b> .....	<b>19</b>
Phone .....	(800) 225-1195
.....	www.katena.com
<b>Keeler Instruments</b> .....	<b>5, 57</b>
Phone .....	(800) 523-5620
Fax.....	(610) 353-7814
<b>Lombart Instruments</b> .....	<b>51</b>
Phone .....	(800) 446-8092
Fax.....	(757) 855-1232
<b>Mentholatum Company</b> .....	<b>7</b>
Phone .....	(877) 636-2677
.....	consumeraffairs@mentholatum.com
.....	www.mentholatum.com
<b>Reichert Technologies</b> .....	<b>41, 43, 45, 47</b>
Phone .....	(888) 849-8955
Fax.....	(716) 686-4545
.....	www.reichert.com
<b>S4OPTIK</b> .....	<b>35, 37, 39</b>
Phone .....	(888) 224-6012
<b>Shire Ophthalmics</b> .....	<b>14-15, 16</b>
.....	www.shire.com
<b>Transitions Optical</b> .....	<b>23</b>
Phone .....	(800) 848-1506
Fax.....	(813) 546-4732
<b>Vistakon</b> .....	<b>2-3</b>
Phone .....	(800) 874-5278
Fax.....	(904) 443-1252

*This advertiser index is published as a convenience and not as part of the advertising contract. Every care will be taken to index correctly. No allowance will be made for errors due to spelling, incorrect page number, or failure to insert.*

## August 2017

■ **3-6.** *VT4. OEP National Headquarters, Baltimore.* Host: Optometric Extension Program Foundation. Key faculty: Robin Lewis. CE hours: 35. To register, email Karen Ruder at [karen.ruder@oep.org](mailto:karen.ruder@oep.org), call (410) 561-3791 or go to [www.oepf.org](http://www.oepf.org).

■ **4-6.** *SWFOA Educational Retreat.* South Seas Island Resort, Captiva Island, FL. Host: Southwest Florida Optometric Association. Key faculty: Nate Lighthizer, Leo Semes, Ron Foreman. CE hours: 16. To register, email Brad Middaugh at [middaugh@att.net](mailto:middaugh@att.net), call (239) 481-7799 or go to [www.swfoa.com](http://www.swfoa.com).

■ **5-6.** *End of Summer Seminar.* IU School of Optometry, Bloomington, IN. Host: IU School of Optometry. CE hours: 16. To register, email Cheryl Oldfield at [coldfiel@indiana.edu](mailto:coldfiel@indiana.edu), call (812) 856-3502 or go to [www.optometry.iu.edu/continuing-education](http://www.optometry.iu.edu/continuing-education).

■ **6.** *Breakfast and Learn — New Technology.* SUNY College of Optometry, New York City. Host: SUNY Office of CE. CE hours: 4. To register, email Betsy Torres at [ce@sunyopt.edu](mailto:ce@sunyopt.edu), call (212) 938-5830 or go to [www.sunyopt.edu/cpe](http://www.sunyopt.edu/cpe).

■ **9.** *Annual Summer Seminar.* Jumping Brook Country Club, Neptune, NJ. Host: NJ Academy of Optometry. Key faculty: Vipul Lahkani. CE hours: 6. To register, email Dennis Lyons at [dhl2020@aol.com](mailto:dhl2020@aol.com) or call (732) 920-0110.

■ **9.** *OD Excellence Information Meeting.* Office of Steve Chander, Chicago. Host: OD Excellence. Key faculty: Steve Chander. CE hours: 2. To register, email Anthony Senander at [asenander@odexcellence.com](mailto:asenander@odexcellence.com), call (707) 433-5542 or go to [www.odexcellence.com](http://www.odexcellence.com).

■ **18-20.** *UABSO CE & Alumni Weekend.* UAB School of Optometry, Birmingham, AL. Host: University of Alabama Birmingham School of Optometry. CE hours: 18. To register, email Katherine Clore at [kclore@uab.edu](mailto:kclore@uab.edu), call (205) 934-5700 or go to [www.uab.edu/optometry/home/uabso-ce](http://www.uab.edu/optometry/home/uabso-ce).

■ **20.** *Annual Optometry Academe.* UMSL JC Penney Conference Center, St. Louis. Host: UMSL College of Optometry. Key faculty: Joseph Pizzimenti, Carlo Pelino. CE hours: 8. To register, email Lis Ellerbusch at [ellerbusch@umsl.edu](mailto:ellerbusch@umsl.edu), call (314) 516-5615 or go to <http://optometry.umsl.edu>.

■ **24-27.** *110th SCOPA Annual Meeting.* Myrtle Beach Marriott Resort and Spa at Grande Dunes, Myrtle Beach, SC. Host: South Carolina Optometric Physicians Association. CE hours: 21. To register, email Jackie Rivers at [jrivers@sceyedocors.com](mailto:jrivers@sceyedocors.com), call (877) 799-6721 or go to [www.sceyedocors.com](http://www.sceyedocors.com).

## September 2017

■ **8-10.** *VOA Fall Conference.* Essex Resort and Spa, Essex, VT. Host: Vermont Optometric Association. CE hours: 17. To register, email Rebecca Hogan at [vtcecoordinator@gmail.com](mailto:vtcecoordinator@gmail.com).

■ **8-10.** *i.CE on the Shore MOA/DOA Fall Conference.* Hyatt Regency Chesapeake Bay, Cambridge, MD. Host: Maryland

Optometric Association and Delaware Optometric Association. CE hours: 14. To register, email Cheryl Frazier at [cfrazier@marylandoptometric.org](mailto:cfrazier@marylandoptometric.org), call (410) 486-9662 or go to [www.marylandoptometry.org](http://www.marylandoptometry.org).

■ **9-10.** *Primary Eye Care Update.* Oklahoma College of Optometry Academic Wing, Tahlequah, OK. Host: Oklahoma College of Optometry. CE hours: 10. To register, email Callie McAtee at [nsuoco\\_ce@nsuok.edu](mailto:nsuoco_ce@nsuok.edu), call (918) 444-4033 or go to [www.optometry.nsuok.edu/continuingeducation.aspx](http://www.optometry.nsuok.edu/continuingeducation.aspx).

■ **9-10.** *MBKU Pathology Conference Featuring USC & VA Faculty.* Marshall B. Ketchum University, Fullerton, CA. Host: Marshall B. Ketchum University. CE hours: 16. To register, email Antoinette Smith at [asmith@ketchum.edu](mailto:asmith@ketchum.edu), call (714) 872-5684 or go to [www.ketchum.edu/ce](http://www.ketchum.edu/ce).

■ **11-13.** *2017 World Congress of Optometry.* Hyderabad International Convention Centre, Hyderabad, India. Host: India Vision Institute & World Council of Optometry. To register, email [executivedirector@worldoptometry.com](mailto:executivedirector@worldoptometry.com) or go to [www.worldcongressofoptometry.org](http://www.worldcongressofoptometry.org).

■ **13.** *OD Excellence Information Meeting.* Office of Terry Chan, San Francisco. Host: OD Excellence. Key faculty: Terry Chan. CE hours: 2. To register, email Anthony Senander at [asenander@odexcellence.com](mailto:asenander@odexcellence.com), call (707) 433-5542 or go to [www.odexcellence.com](http://www.odexcellence.com).

■ **13-16.** *International Vision Expo West.* Sands Expo and Convention Center, Las Vegas. Host: International Vision Expo. Key faculty: Ben Gaddie, Mark Dunbar. CE hours: 310+ total, 27 per OD. To register, email Diane at [dtiberio@reedexpo.com](mailto:dtiberio@reedexpo.com), call (203) 840-5436 or go to [www.visionexpowest.com](http://www.visionexpowest.com).

■ **13-16.** *COVD at Int'l Vision Expo West.* Sands Expo and Convention Center, Las Vegas. Host: College of Optometrists in Vision Development. Key faculty: Robin Price. CE hours: 12. To register, email Penny at [penny@covd.org](mailto:penny@covd.org), call (330) 995-0718 or go to [www.covd.org](http://www.covd.org).

■ **15-16.** *Alumni Weekend.* IU School of Optometry, Bloomington, IN. Host: IU School of Optometry. CE hours: 16. To register, email Cheryl Oldfield at [coldfiel@indiana.edu](mailto:coldfiel@indiana.edu), call (812) 856-3502 or go to [www.optometry.iu.edu/continuing-education](http://www.optometry.iu.edu/continuing-education).

■ **17.** *Central Pennsylvania Optometric Society Annual Meeting.* Hotel Hershey, Hershey, PA. Host: Central Pennsylvania Optometric Society. Key faculty: Ron Melton, Randall Thomas. To register, email [cposrsvp@gmail.com](mailto:cposrsvp@gmail.com).

### To list your meeting, please send the details to:

Michael Iannucci

Associate Editor

Email: [miannucci@jobson.com](mailto:miannucci@jobson.com)

Phone: (610) 492-1043

Up to  
20 CE  
Credits\*



ANNUAL

# WINTER OPHTHALMIC CONFERENCE

A REVIEW OF OPTOMETRY® MEETING OF CLINICAL EXCELLENCE

CE AT ITS PEAK! WORLD CLASS EDUCATION BY LEADING OPTOMETRIC EDUCATORS

## THE LONGEST RUNNING WINTER CE MEETING IN EYE CARE!

February 16-20, 2018

Aspen, Colorado

### LOCATION:

#### WESTIN SNOWMASS CONFERENCE CENTER

100 Elbert Lane  
Snowmass Village, CO 81615  
Phone: (970) 923-8200

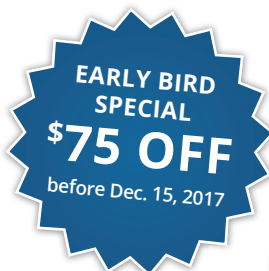Discounted room rates:  
\$219 - \$429 per night

### CONTINUING EDUCATION:

- Earn up to 20 hours of COPE CE\* Credits
- **Registration Cost - \$650**  
**Early Bird Special:** Receive \$75 off before Dec. 15, 2017
- See website for meeting agenda

### MEETING CO-CHAIRS:

Murray Fingeret, OD, FAAO  
Leo Semes, OD, FAAO



## 3 WAYS TO REGISTER

**E-MAIL: [REVIEWMEETINGS@JOBSON.COM](mailto:REVIEWMEETINGS@JOBSON.COM)    PHONE: (866) 730-9257**

**WEBSITE: [WWW.SKIVISION.COM](http://WWW.SKIVISION.COM)**

See event website for all accommodations and rates.

*Review of Optometry*® partners with Salus University for those  
ODs who are licensed in states that require university credit.

Administered by  
**Review of Optometry**®

**cope**  
\*Approval pending

**SALUS**  
UNIVERSITY  
Pennsylvania College of Optometry

Merchandise Offered



**CHANGE YOUR SHOWROOM COLOR ON DEMAND**

Introducing **LED SHELVEING PANELS**

L.E.D. SHELVEING PANELS are attractive floating shelves for lightweight merchandise; including eyewear. The shelf profiles are a mere 9 millimeters in thickness and seamlessly connect to the back panel, creating a serene and charming product display. Recommended is the L.E.D. illumination system which is available in both white and remote adjustable multi-color RGB.

L.E.D. SHELVEING PANELS start at just \$999. Visit us online or call the number listed below for more information.

**1-877-274-9300** [www.framedisplays.com](http://www.framedisplays.com)



Merchandise Offered

# Impressions

*Color Contact Lens*

*Unleash your true color!*



Impressions colored contacts blend naturally with your patients eyes to create a beautiful look. Available in nine dazzling opaque colors of which Brown, Grey, Green, Hazel, Honey, Pure Hazel and True Sapphire are available in RX PL to -8.00.

Impressions are fun, hip, fashionable and very competitively priced to help your bottom line. POP materials and posters are available upon request.

Available Exclusively at



**Contact Lenses**

# National Lens

America's Leading Discount Lens Distributer

1-866-923-5600 Phone

1-866-923-5601 Fax

www.national-lens.com

2017		LOW	LOWER	LOWEST	2017		LOW	LOWER	LOWEST
		1-5	6-10	11 AND OVER			1-5	6-10	11 AND OVER
COLOR	IMPRESSIONS COLOR <i>Available in Rx!</i>	23.95	22.95	21.95	BAUSCH & LOMB	PUREVISION / PUREVISION HD	27.50	26.95	25.95
						PUREVISION 2 MULTIFOCAL	38.50	38.00	37.00
						SOFLENS 38	14.50	13.95	13.50
ALCON	AIR OPTIX AQUA	25.75	24.95	22.95	COOPERVISION	SOFLENS ONE DAY - 90 PACK	33.50	32.50	29.95
	AIR OPTIX AQUA PLUS HYDRAGLYDE - 6 PACK	25.75	24.95	22.95		BIOTRUE - 90 PACK	44.00	42.95	41.95
	AIR OPTIX FOR ASTIGMATISM	36.50	35.95	33.95		ULTRA	34.95	33.95	32.95
	AIR OPTIX MULTIFOCAL	42.95	42.50	41.95		AVAIRA	17.25	16.95	15.00
	AIR OPTIX NIGHT & DAY AQUA	41.25	39.95	38.95		AVAIRA VITALITY - 6 PACK	19.95	18.95	18.50
	AIR OPTIX COLORS - 2 PACK	19.95	19.50	18.95		BIOFINITY	24.50	22.50	21.50
	DAILIES AQUA COMFORT PLUS - 90 PACK	37.95	36.95	35.50		BIOFINITY ENERGYS	33.00	32.00	31.00
	O2 OPTIX	16.50	16.25	15.95		BIOFINITY TORIC	36.00	34.00	32.00
	FRESHLOOK COLORBLENDS - 2 PACK	10.50	9.75	9.25		BIOMEDICS XC, & 38%	15.95	13.95	13.50
	DAILIES TOTAL 1 - 30 PACK	26.00	25.75	24.75		BIOMEDICS PREMIER	15.95	13.95	13.50
JOHNSON & JOHNSON	DAILIES TOTAL 1 - 90 PACK	64.00	63.00	62.00	EXPRESSION OPAQUE-PLANO	25.95	24.95	23.95	
	ACUVUE OASYS - 6 PACK	21.50	20.95	19.95	FREQUENCY 55% & ASPHERICS	14.95	13.95	11.95	
	ACUVUE OASYS - 24 PACK	65.00	63.00	59.00	PROCLEAR 8.2	23.95	22.95	21.95	
	ACUVUE 1 DAY OASYS - 90 PACK	62.00	61.00	59.95	PROCLEAR 8.6	19.95	18.95	17.95	
	ACUVUE 1 DAY TRUE EYES - 90 PACK	55.25	54.25	52.95	PROCLEAR 1 DAY - 30 PACK	16.00	15.50	14.50	
	ACUVUE OASYS FOR ASTIGMATISM - 6 PACK	24.95	24.75	23.95	PROCLEAR 1 DAY - 90 PACK	37.95	37.50	36.25	
	ACUVUE 2 - 6 PACK	16.00	15.75	15.50	MY DAY - 90 PACK	54.95	54.50	54.00	
	ACUVUE VITA - 6 PACK	34.50	34.25	33.95	CLARTI 1 DAY - 90 PACK	40.95	39.95	38.95	
	ACUVUE 1 DAY MOIST - 30 PACK	18.95	18.50	17.95					
	ACUVUE 1 DAY MOIST - 90 PACK	41.95	40.95	39.90					

We'll Meet or Beat Any Competitors Prices on Any Stock Lens • Free Standard Shipping (when available) • Same Day Shipping • We Do Not Backorder Lenses

**FACULTY**



**ASSISTANT PROFESSOR POSITIONS: CONTACT LENSES, PRIMARY CARE, AND PEDIATRICS**

(Full-time non-tenure track faculty positions for the Chicago College of Optometry or Arizona College of Optometry)

**RESPONSIBILITIES:** Candidates are expected to be highly knowledgeable in the field of Cornea and Contact Lenses, Primary Care, or Pediatrics and can develop and teach courses and/or laboratories in the subject area. The candidate must also be able to provide direct patient care and clinical instruction to professional students as well as residents, and be involved in interdisciplinary practice with other educational professionals.

Candidates must be willing to actively participate in curricular assessment, professional development, student counseling and service activities within the college, university and the scientific community. Successful candidates are also expected to be involved in research and scholarly activities, and have a sincere commitment to optometric education, community service and patient care. Primary duties include, but are not limited to:

- a) **Teaching**
  - Developing and delivering lectures and/or laboratories for cornea and contact lenses and related areas, as assigned;
  - Embracing and enhancing the didactic philosophies in the O.D. program;
  - Maintaining and expanding the high quality clinical practice environment for optometry students on rotation;
  - Precepting students on clinical rotation at the Midwestern University Eye Institute;
- b) **Service**
  - Helping to maintain and grow the state of the art optometry program with a strong interdisciplinary focus that meets the needs of patients in the surrounding community; is efficient, patient friendly, and cost-effective;
  - Working closely together with all optometry and ophthalmology faculty to provide a complete range of eye and vision care services;
  - Participating in leadership roles in state, regional, and national optometry organizations;
- c) **Scholarly activity**
  - Engaging in research and scholarly activity, including presentations at scientific meetings, research, and publication in peer reviewed journals sufficient to qualify for academic advancement in a non-tenure track position.

**QUALIFICATIONS:** Candidates must possess a Doctor of Optometry degree from an ACOE-accredited institution, must have completed an ACOE-accredited residency, and must be eligible for an optometric state license in the state in which the college is located. Primary eye care clinical expertise is also required.

**CONTACT INFORMATION:** Interested applicants should apply online at [www.midwestern.edu](http://www.midwestern.edu) and include curriculum vitae and letter of interest specifying the position and college that he/she wishes to be considered for. Inquiries may be directed to Dr. Joshua Baker, Dean, or Dr. Mary Lee, Vice President & Chief Academic Officer, Pharmacy and Optometry Education; Midwestern University: [jbaker@midwestern.edu](mailto:jbaker@midwestern.edu) or [mleexx@midwestern.edu](mailto:mleexx@midwestern.edu).

Midwestern University is an Equal Opportunity/Affirmative Action employer that does not discriminate against an employee or applicant based upon race, color, religion, gender, national origin, disability, or veterans status, in accord with 41 C.F.R. 60-1.4(a), 250.5(a), 300.5(a) and 741.5(a).

**Continuing Education**

**MEDICAL OPTOMETRISTS**

The American Board of Certification in Medical Optometry (ABCMO) is recognized at Joint Commission (JC) accredited medical facilities as issuing board certification in the specialty of medical optometry and those ABCMO certifies are eligible for credentialing at these facilities as specialists rather than general optometry practitioners.<sup>^</sup>

The Joint Commission, the accepted national Gold Standard, reviews and accredits over 21,000 federal, state and local-chartered medical facilities.

**To Be Eligible for ABCMO board certification:**

1. Complete an accredited residency in medical optometry
2. Pass the national Advanced Competence in Medical Optometry Examination
3. Practice in a medical setting for a minimum of two years.<sup>#</sup>




[www.abcmo.org](http://www.abcmo.org)

Visit [www.abcmo.org](http://www.abcmo.org) to understand how JC accredited medical facilities credential specialists and why specialty certification can enhance the careers of optometrists who complete residencies in medical optometry.

For Application procedures see [www.abcmo.org](http://www.abcmo.org) or contact [myers.kenj@gmail.com](mailto:myers.kenj@gmail.com)

<sup>^</sup> At this time, 127 JC accredited hospitals, clinics and teaching institutions recognize ABCMO specialist certification.  
<sup>#</sup> [www.jointcommission.org](http://www.jointcommission.org)  
<sup>#</sup> Waived for two years after residency

**Equipment and Supplies**



It's What the Best Pretest on!  
**(800) 522-2275**  
[www.optinomics.com](http://www.optinomics.com)  
[sales@optinomics.com](mailto:sales@optinomics.com)

Contact us today for classified advertising:  
 Toll free: **888-498-1460**  
 E-mail: [sales@kerhgroup.com](mailto:sales@kerhgroup.com)

**Practice For Sale**



Practice Sales • Appraisals • Consulting  
[www.PracticeConsultants.com](http://www.PracticeConsultants.com)

**PRACTICES FOR SALE NATIONWIDE**

Visit us on the Web or call us to learn more about our company and the practices we have available.

[info@PracticeConsultants.com](mailto:info@PracticeConsultants.com)

**800-576-6935**

[www.PracticeConsultants.com](http://www.PracticeConsultants.com)

**PRACTICE SALES & APPRAISAL**

Expert Services for:

- Buying or Selling a Practice**
- Practice Appraisal**
- Practice Financing**
- Partner Buy-in or Buy-out**

Call for a Free Consultation  
**(800) 416-2055**

[www.TransitionConsultants.com](http://www.TransitionConsultants.com)

**PRACTICE FOR SALE MONTEREY PARK, CA**

PRACTICE FOR SALE LOCATED ON A BUSY SHOPPING CENTER WITH A HIGHLY ASIAN POPULATION IN THE CITY OF MONTEREY PARK, CA. SOLO PRACTITIONER FOR 37 YEARS.

Please call 562-690-7896 or cell # 562-673-7873  
 Email: [lilytd07@gmail.com](mailto:lilytd07@gmail.com)

**Practice Opportunity**

**PRACTICE FOR SALE WAUASU/ WESTON, WI**

TO HIRE OR BUY OUT-WILL FINANCE GREAT RECREATION AREA- LAKES GALORE  
 715-212-8315 Dr. Knutson  
[WWW.VISIONANDLASERCLINIC.COM](http://WWW.VISIONANDLASERCLINIC.COM)

**PRACTICE FOR SALE WHIDBEY ISLAND, WA**

Established practice for sale on beautiful south Whidbey Island WA. Annual gross revenue is **685K**. Owner retiring.

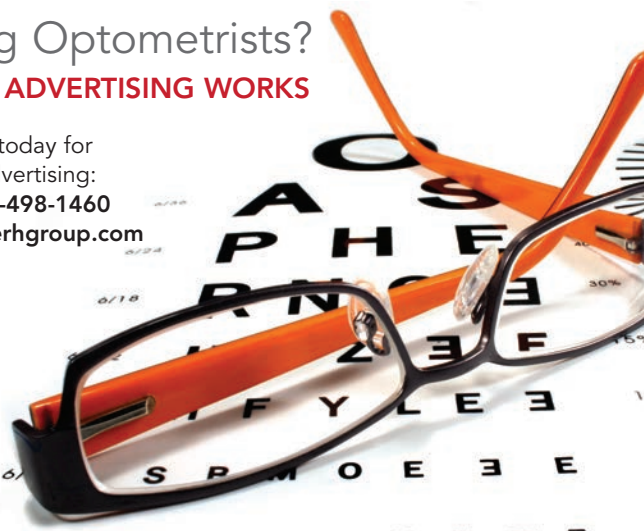PLEASE RESPOND TO [jcolella@aol.com](mailto:jcolella@aol.com)

**REVIEW OF OPTOMETRY**

Targeting Optometrists?

**CLASSIFIED ADVERTISING WORKS**

Contact us today for classified advertising:  
 Toll free: **888-498-1460**  
 E-mail: [sales@kerhgroup.com](mailto:sales@kerhgroup.com)





**Career Opportunities**

**Looking to  
increase  
sales?**

**Place Your  
Ad here.**

Contact us today for  
classified advertising:

**888-498-1460**

E-mail: [sales@kerhgroup.com](mailto:sales@kerhgroup.com)

**REVIEW<sup>®</sup>**  
OF OPTOMETRY

### OPTOMETRIST OPPORTUNITY ANCHORAGE, AK.

Anchorage, AK. - Full time Optometrist Opportunity with Alaska's PREMIER Eye Health Care Practice – Alaska Eye Care Centers, APC – voted Best of Alaska since 2007. A privately owned, two location practice with 7 doctors is seeking a new graduate or experienced O.D. for employment opportunity.

Each location has 4-5 full exam rooms and the appropriate equipment- special testing equipment, optometric pre-testers, and full administrative support. The main office offers full lens manufacturing for both locations. Each office has optical dispensaries consisting of over 2,500 frames and is serviced by licensed opticians. In addition, each office has full contact lens services, including licensed CL technicians.

This opening is for our Wasilla location rotating into Anchorage at least once a week. Wasilla is a semi-rural setting approximately 40 miles from Anchorage, Alaska. The population of the surrounding area is about 98,000 and housing and utilities costs are comparable to West Coast levels. Entertainment, fine dining and the arts are easily available in Anchorage, a city of more than 291,000 residents.

Alaska is one of the most beautiful places to live and practice. For further information, please contact:

Alaska Eye Care Centers  
1345 W. 9th Avenue, Anchorage, AK. 99501  
Contact: Deb Foster, Administrator  
[deb@alaskaeyecare.com](mailto:deb@alaskaeyecare.com)  
(907) 272-2557 X 1604  
(907) 274-4932 (Fax)  
Website: [www.alaskaeyecare.com](http://www.alaskaeyecare.com)

### Staff Optometrist Wanted

Bard Optical is a family owned full-service retail optometric practice with 22 offices (and growing) throughout Central Illinois. Bard Optical prides itself on having a progressive optometric staff whose foundation is based on one-on-one patient service. We are currently accepting CV/resumes for Optometrists to join our medical model optometric practice that includes extended testing. The practice includes but is not limited to general optometry, contact lenses and geriatric care. Salaried, full-time positions are available with excellent base compensation and incentive programs and benefits. Some part-time opportunities may also be available.

Current positions are available in  
Bloomington/Normal, Decatur/Forsyth,  
Peoria, Sterling and Canton as we continue  
to grow with new and established offices.

Please email your information to  
[mhall@bardoptical.com](mailto:mhall@bardoptical.com) or call  
Mick at 309-693-9540 ext 225.  
Mailing address if more convenient is:

**Bard Optical**  
Attn: Mick Hall, Vice President  
8309 N Knoxville Avenue  
Peoria, IL 61615

Bard Optical is a proud  
Associate Member of the  
Illinois Optometric Association.



[www.bardoptical.com](http://www.bardoptical.com)

### FULL TIME OPTOMETRIST AMARILLO, TEXAS

Amarillo, Texas - Full time Optometrist opportunity at Broome Optical. We are a very large privately owned practice with 6 full-time optometrists at one location-all equal partners.

We are seeking a new graduate or experienced O.D. for employment opportunity that may become a partner as we recently expanded our location with more examination rooms.

We have 45 employees, state of the art equipment, optometric technicians and full administrative support.

**Broome Optical**  
3408 Olsen Blvd.  
Amarillo, Texas 79109  
Contact: Dr. Dean Beddow,  
Dr. Jimmy Martin or Dr. Neal Nossaman  
[broomeoptical.com](http://broomeoptical.com)  
806-355-5633  
806-355-9133(fax)

### OPTOMETRY ASSOCIATE Leading to Partnership

Full or Part Time Mid Hudson Valley- Kingston, NY 90 miles North of New York City Skiing, Hiking, Biking and Much More Dr. Chasin and Guarente, Optometrists 240 Lucas Avenue Kingston, NY 12401

EMAIL: [DRMC@EYES-OK.COM](mailto:DRMC@EYES-OK.COM)

**Place Your  
Ad Here!**

Toll free: 888-498-1460

E-mail: [sales@kerhgroup.com](mailto:sales@kerhgroup.com)



## Beginner's Luck

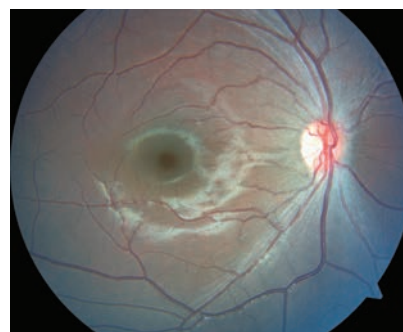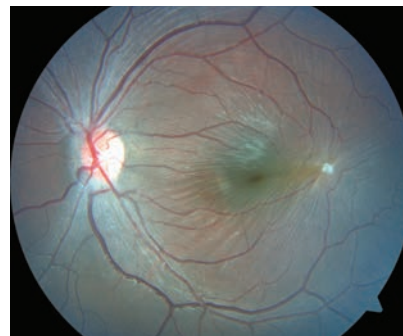
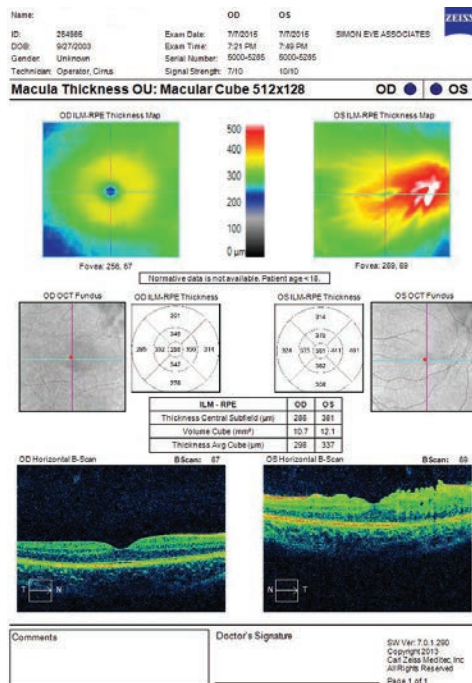
By Andrew S. Gurwood, OD

### History

An 11-year-old Caucasian male reported to the office for a routine eye examination. He explained that his general practitioner wanted him to get his first eye exam after reporting some blur in his left eye over the last month. His systemic and ocular histories were unremarkable and he denied having allergies of any kind.

### Diagnostic Data

His best-corrected entering visual acuities were 20/20 OD and 20/25 OS at distance and near. His external examination was normal with no evidence of afferent pupillary defect. The biomicroscopic examination of the anterior segment was normal in every way. Goldmann applanation tonometry measured 15mm Hg OU. The pertinent fundus finding is demonstrated in the photographs and optical coherence tomography.



**This 11-year-old patient appeared for his first eye exam with blurry vision in his left eye, shown in the bottom fundus image. Can you identify the cause?**

### Your Diagnosis

Does this case require any additional tests? How would you manage this patient? What is your

diagnosis? What is the patient's likely prognosis? To find out, please visit us online at

[www.reviewofoptometry.com](http://www.reviewofoptometry.com). ■

### Next Month in the Mag

In August, *Review of Optometry* is proud to present its 41st annual contact lens report.

Topics include:

- *Fitting Irregular Cornea Patients in Scleral Contact Lenses*
- *Are You Up to Date on the Newer Contact Lens Materials?*
- *The Case for Daily Disposable-only Practice vs. Other Replacement Modalities*

- *What Corneal Topography Reveals About Your Contact Lens Patients*

Also in this issue:

- *Time to Update Your Plaquenil Toxicity Screening Protocol* (earn 2 CE credits)
- *Parsing Dry Eye Symptoms*
- *Horner's Syndrome: So, You've Got A Positive Apraclonidine Drop Test, Now What?*

REVIEW OF OPTOMETRY (ISSN 0147-7633) IS PUBLISHED MONTHLY, 12 TIMES A YEAR BY JOBSON MEDICAL INFORMATION LLC, 440 9TH AVENUE, 14TH FLOOR, NEW YORK, NY 10013-1678. PERIODICALS POSTAGE PAID AT NEW YORK, NY AND ADDITIONAL MAILING OFFICES. POSTMASTER: SEND ADDRESS CHANGES TO REVIEW OF OPTOMETRY, PO BOX 81, CONGERS, NY 10920-0081. SUBSCRIPTION PRICES: US: ONE YEAR \$56; TWO YEARS \$97, CANADA: ONE YEAR \$88, TWO YEARS \$160, INT'L: ONE YEAR \$209, TWO YEARS \$299. FOR SUBSCRIPTION INFORMATION CALL TOLL-FREE (877) 529-1746 (USA); OUTSIDE USA, CALL (845) 267-3065. OR EMAIL US AT REVOPOTOMETRY@CAMBEYWEST.COM. PUBLICATIONS MAIL AGREEMENT NO: 40612608. CANADA RETURNS TO BE SENT TO BLEUCHIP INTERNATIONAL, P.O. BOX 25542, LONDON, ON N6C 6B2.

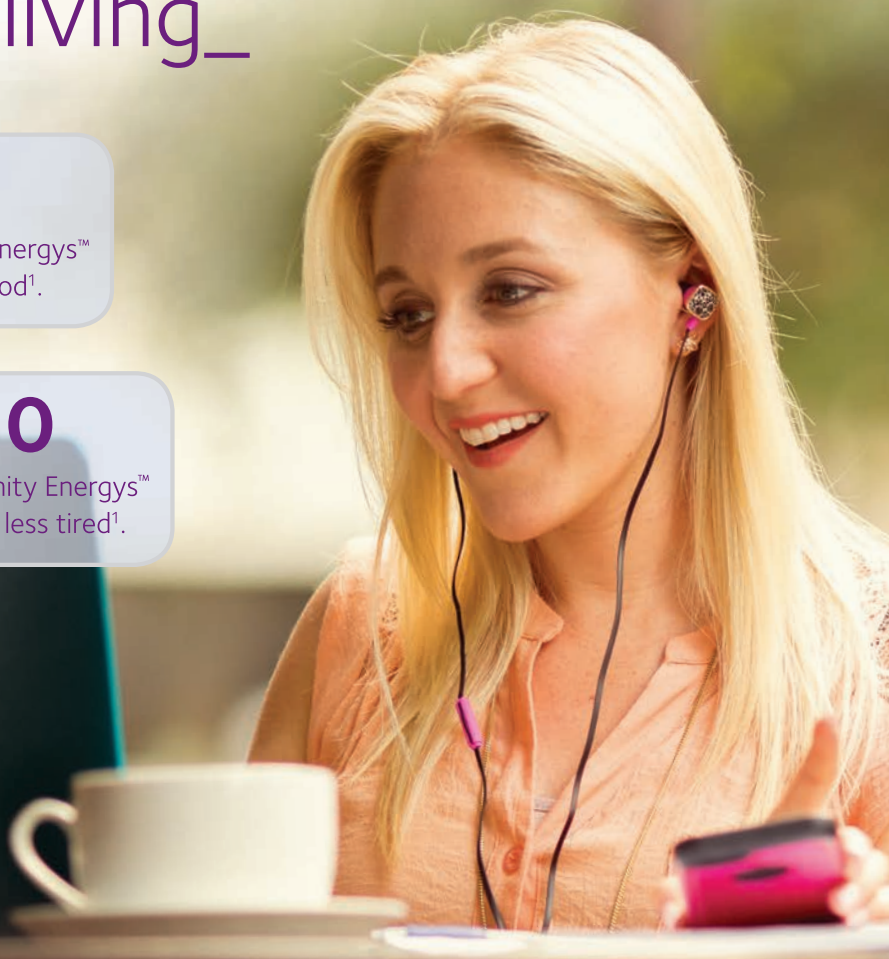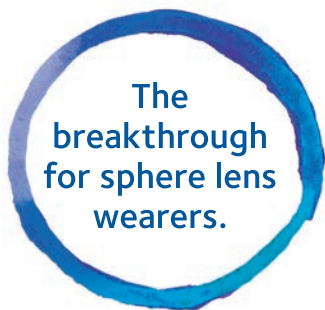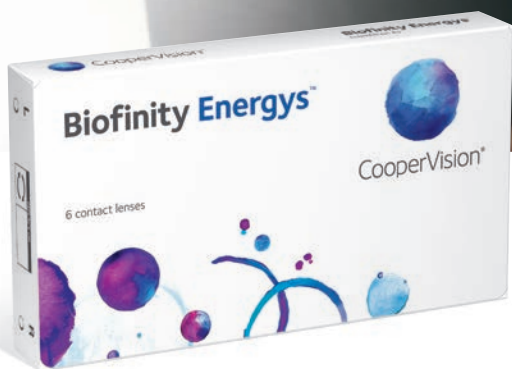# The first contact lens specifically designed for your patients' digital life and everyday living\_

## 9 out of 10

digital device users\* agreed that Biofinity Energys™ contact lenses made their eyes feel good<sup>1</sup>.

## 8 out of 10

digital device users\* agreed that Biofinity Energys™ contact lenses made their eyes feel less tired<sup>1</sup>.



Biofinity Energys™ contact lenses help with eye **tiredness** and **dryness commonly associated with digital device use**. Considering 90 percent of U.S. adults use digital devices more than two hours per day<sup>2</sup>, the opportunity to upgrade your patients is significant. Biofinity Energys™ contact lenses feature a revolutionary Digital Zone Optics™ lens design and Aquaform® Technology.

Energize your practice—prescribe the patent-pending contact lens innovation made for today's digital lifestyle.

Visit [coopervision.com](http://coopervision.com), or talk to your CooperVision® representative for details.

**Biofinity Energys™**

Welcome to the new comfort zone\_

\* Among patients who use digital devices at least 4 hours per day at least 5 days per week and self-report symptoms of eye fatigue at least once per week.

1. After 1 week of wear; data on file.

2. The Vision Council. Eyes overexposed: the digital device dilemma: 2016 digital eye strain report.

©2017 CooperVision 4513\_06/17



# START YOUR PATIENTS ON A HEALTHY ROUTINE TODAY



Now, you can upgrade your weekly and monthly replacement lens wearers with the **ALCON DAILIES® CHOICE PROGRAM**

Recommend a healthy choice for your patients and practice

Reduce the price barrier with \$200 savings\* on a year's supply

A convenient alternative to weekly and monthly replacement lenses

## DAILIESCHOICE.com

\*Via mail-in or online rebate on an annual supply of DAILIES TOTAL1® or DAILIES® AquaComfort Plus® contact lenses. Rebate is in the form of an Alcon Visa Prepaid Card. Must be a new patient to DAILIES TOTAL1® or DAILIES® AquaComfort Plus® contact lenses and must purchase an annual supply of the lenses within 90 days of eye exam and/or contact lens fitting. Applies to purchases from participating retailers only. Visit DAILIESCHOICE.COM for full terms and conditions. Offer ends 12-31-17.



**Alcon** A Novartis Division

See product instructions for complete wear, care and safety information.

© 2016 Novartis 12/16 US-DAL-16-E-4914

Rx only