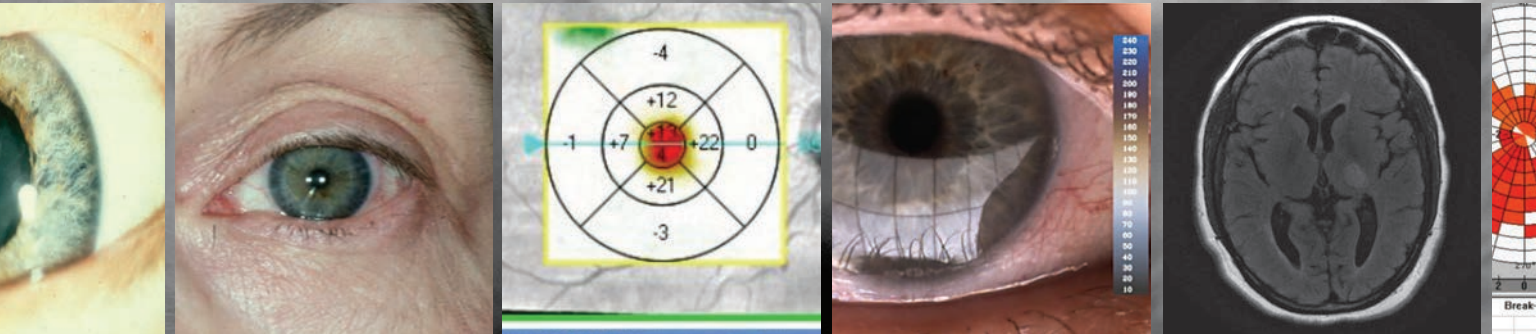


REVIEW[®] OF OPTOMETRY

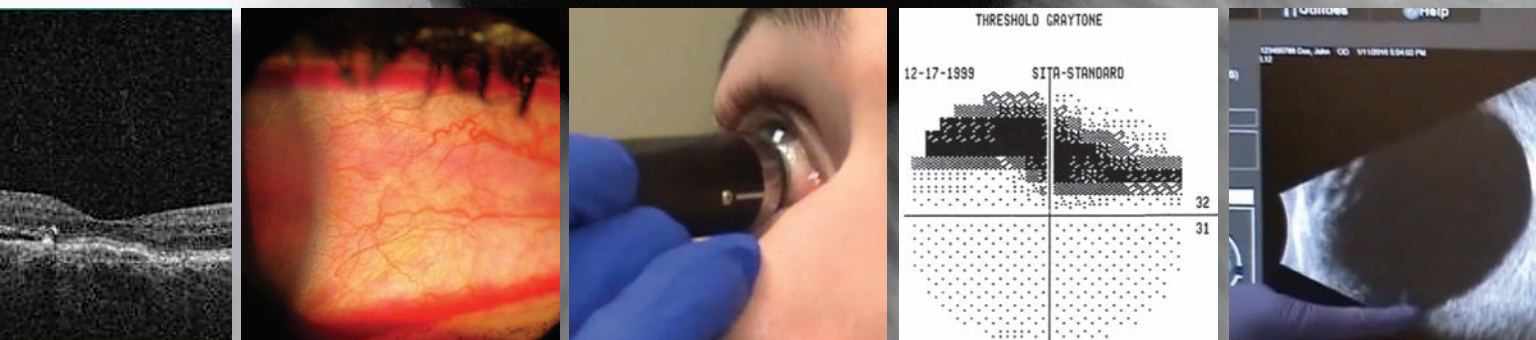
March 15, 2016

www.reviewofoptometry.com



DIAGNOSTIC SKILLS AND TECHNIQUES

*Advice from the experts to help
improve your precision.*



- OCT's Role in an Optometric Practice, p. 44
- Pupil Testing: Implications for Diagnosis, p. 56
- Scoring an A+ on a B-Scan, p. 64
- The How and Why of Diagnosing Dry Eye, p. 75

EARN 2 CE CREDITS

- Automated Perimetry: Visual Field Deficits in Glaucoma and Beyond, p. 84





She doesn't want
her **long days**
to impact her comfort or
long-term
eye health.

PVP=polyvinylpyrrolidone.

*Intense wear=Patients who wear lenses ≥ 14 hours a day, ≥ 5 days a week.

†Comparable to no lens wear on comfort and 5 out of 6 measures of ocular health (limbal hyperemia, corneal vascularization, corneal staining, bulbar conjunctival hyperemia, and papillary conjunctivitis. The sixth measure was conjunctival staining).

ACUVUE® Brand Contact Lenses are indicated for vision correction. As with any contact lens, eye problems, including corneal ulcers, can develop. Some wearers may experience mild irritation, itching or discomfort. Lenses should not be prescribed if patients have any eye infection, or experience eye discomfort, excessive tearing, vision changes, redness or other eye problems. Consult the package insert for complete information. Complete information is also available by visiting www.acuvueprofessional.com or by calling 1-800-843-2020.

For patients who wear their lenses intensely* and put a priority on the long-term health of their eyes

- Embedded PVP mimics the mucin on both the cornea and eyelid, minimizing lens-eye interaction to make 1-DAY ACUVUE® TruEye® Brand Contact Lenses **nearly invisible** to the eye itself
- Clinically shown to be comparable to the natural eye on comfort and 5 of 6 measures of ocular health after 365 days of daily wear^{†1}
- Highest level of UV blocking^{‡§} available in a contact lens

1-DAY ACUVUE®
TruEye®
BRAND CONTACT LENSES



[†]Helps protect against transmission of harmful UV radiation to the cornea and into the eye.

[§]**WARNING:** UV-absorbing contact lenses are NOT substitutes for protective UV-absorbing eyewear such as UV-absorbing goggles or sunglasses, because they do not completely cover the eye and surrounding area. You should continue to use UV-absorbing eyewear as directed. **NOTE:** Long-term exposure to UV radiation is one of the risk factors associated with cataracts. Exposure is based on a number of factors such as environmental conditions (altitude, geography, cloud cover) and personal factors (extent and nature of outdoor activities). UV-blocking contact lenses help provide protection against harmful UV radiation. However, clinical studies have not been done to demonstrate that wearing UV-blocking contact lenses reduces the risk of developing cataracts or other eye disorders. Consult your eye care practitioner for more information.

Reference: 1. Morgan PB, Chamberlain P, Moody K, Maldonado-Codina C. Ocular physiology and comfort in neophyte subjects fitted with daily disposable silicone hydrogel contact lenses. *Cont Lens Anterior Eye.* 2013;36(3):118-125. Study conducted over 365 days.

ACUVUE®, 1-DAY ACUVUE® TruEye®, and HYDRACLEAR® are trademarks of Johnson & Johnson Vision Care, Inc.

© Johnson & Johnson Vision Care, Inc. 2015 ACU-10312345 July 2015

IN THE NEWS

A new study published in the journal *Ophthalmology* suggests nearly five billion people, or **50% of the world's population**, will become **myopic by 2050**. The research, conducted at the Brien Holden Vision Institute in Australia, points to environmental factors as the potential cause of this growth—namely, **less time outdoors and more near-work activities**.

The FDA has acknowledged receipt of the resubmission of the new drug application (NDA) for **lifitegrast** for the treatment of signs and symptoms of **dry eye disease** in adults, according to manufacturer Shire Pharmaceuticals. The FDA has assigned a six-month review period for the NDA and a Prescription Drug User Fee Act (PDUFA) goal date of July 22, 2016.

A new national survey reveals that 74% of Americans don't know **age-related macular degeneration (AMD)** is the **leading cause of blindness**. The survey, commissioned by CentraSight, also found that 66% of respondents are not confident in their ability to care for a loved one should they develop AMD.

A new study published in *BMC Infectious Diseases* has identified **genetic changes** in the early stages of **trachoma** that could **predispose children** to developing the **long-term, severe form**. Comparing samples from children with infection and inflammation with samples from children with healthy conjunctiva, researchers found two microRNAs that have a direct relationship with the degree of inflammation. This suggests the presence of **inflammatory cells** is required to **drive pathological responses** in the conjunctiva, the authors said in a press release.

Statin Treatment Aids in AMD Therapy

A common cholesterol-lowering drug holds promise for some patients with dry age-related macular degeneration. **By Rebecca Hepp, Senior Associate Editor**

Researchers from the Massachusetts Eye and Ear/Harvard Medical School and the University of Crete have discovered that high doses of statins led to the regression of soft lipid deposits for some patients with dry age-related macular degeneration (AMD).

“This is a very interesting study,” says Steven Ferrucci, OD, of the US Department of Veterans Affairs in North Hills, Calif., and professor at the Southern California College of Optometry at Marshall B. Ketchum University in Los Angeles. “For many years, researchers have postulated that stains may be protective in AMD, as AMD and cardiovascular disease share many of the same risk factors.”

The study, recently published in *EBioMedicine*, looked at 23 patients with dry AMD who had soft lipid deposits in the outer retina. The participants were prescribed 80mg of Lipitor (atorvastatin, Pfizer), a drug FDA-approved to

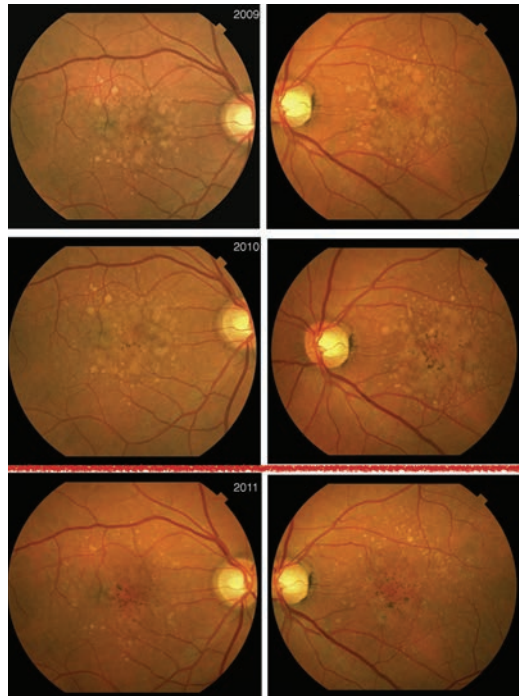


Photo: Yawas DG, Daniels AB, Kapsala ZG, et al

Color fundus images of a 63-year-old man with AMD and large soft drusen and drusenoid pigment epithelial detachments. Upper panel is at presentation, middle panel shows one year later at start of atorvastatin and lower panel shows a year after treatment.

help lower cholesterol, and were monitored every three months with a complete ophthalmologic exam. After a minimum of one year, 10 of the 23 patients experienced an elimination of the deposits under the retina and mild improvement in visual acuity,

(continued on pg. 6)

Tonometry Done Right



D-KAT Digital
Keeler quality.



Pulsair Desktop
Smallest footprint and simple to use!

*Purchase a Pulsair Desktop by
March 31, 2016 and get
a \$1,300 Instant Rebate!*

Intellipuff
The standard for hand held mobility.

Buy Online!
keelerusa.com



Keeler
OPTICS

AMD Treatment on the Horizon

(continued from pg. 4)

and none progressed to advanced neovascular AMD.

“Repurposing current FDA-approved medications such as statins that are very accessible would be huge, as well as represent a huge cost and time saving over discovering a novel drug,” says Dr. Ferrucci. “These drugs are already well studied, with a good safety profile and lots of clinical experience regarding dosing and side effects.”

While the results are promising,

more research is needed to address the study’s limitations and advance the understanding of the possible new treatment option.

“It should be realized that this is a very small study, with only 23 patients,” Dr. Ferrucci says. “More research with a larger study must be done, and even then it seems it may only benefit a percentage of AMD patients [those with soft lipid deposits] and may not help with geographic atrophy or those with pigmentary changes, or hard and reticular drusen.”

“Clinically, we should stay alert of such studies to properly inform our patients of new developments that may be of help, as well as temper those stories that might send false hope,” says Dr. Ferrucci. “Due to the increasing aging population, finding safe and inexpensive strategies for the treatment or management of AMD is paramount.”

Vavvas DG, Daniels AB, Kapsala ZG, et al. Regression of some high-risk features of age-related macular degeneration (AMD) in patients receiving intensive statin treatment. *EBioMedicine*. 2016; DOI: 10.1016/j.ebiom.2016.01.033.

A Call for Expanded Glaucoma Care

The Department of Justice (DOJ) and the Federal Trade Commission (FTC) recently submitted a joint statement encouraging the Massachusetts legislature to consider expanding optometrists’ scope of practice for glaucoma management. The DOJ and FTC

submitted the statement in response to State Representative Bradley H. Jones’ request for views on expanding Massachusetts optometrists’ scope of practice, which could take effect with the passage of House Bill 1973 (HB 1973).

The statement addresses the

potential benefits of enhanced competition among glaucoma care providers, such as greater access to timely and cost-competitive care.

“We note that unnecessarily broad scope of practice restrictions can impose significant competitive costs on health care consumers and other payors,” the DOJ and FTC wrote in the statement. “We write now to highlight the potential competitive costs of a continued prohibition on Massachusetts optometrists’ ability to treat glaucoma and to encourage the legislature to consider the competitive implications of such a restriction in its evaluation of the bill.”

HB 1973 would allow Massachusetts optometrists to treat glaucoma using medications, subject to certain training and referral requirements.

The statement also recommends the legislature maintain only those restrictions on optometrists’ ability to treat glaucoma that are necessary to ensure patient health and safety.

Physics of Pancakes Aids in Glaucoma Surgery

Investigators at the University College London (UCL) have been studying the physics of the perfect pancake—and believe their findings might help UCL scientists improve surgical methods for treating glaucoma. Understanding the physics of the process gives important insights into how flexible sheets, like those found in human eyes, interact with flowing vapor and liquids. In a press release, the study’s co-author, Professor Sir Peng Khaw, director of the NIHR Biomedical Research Centre at Moorfields Eye Hospital and UCL Institute of Ophthalmology, said: “We work on better surgical methods for treating glaucoma, which is a build-up of pressure in eyes caused by fluid. To treat this, surgeons create an escape route for the fluid by carefully cutting the flexible sheets of the sclera. We are improving this technique by working with engineers and mathematicians. It’s a wonderful example of how the science of everyday activities can help us with the medical treatments of the future.”





BON VIVANT
EYEWEAR

Visit us at Vision Expo East • Booth G5834
www.bonvivanteyewear.com • 1.888.560.1060

Visual Clarity of Highway Signs

The U.S. Federal Highway Administration (FHWA) recently announced that, moving forward, highway signs will use the font Highway Gothic, which dates back nearly 70 years, rather than the alternative Clearview font.

The newer font was approved in 2004 in the FHWA's *Interim Approval for Use of Clearview Font for Positive Contrast Legends on Guide Signs* and has since been approved by nearly 30 states, according to an article published in *CityLab*. It was an unfortunate

announcement that will have big implications going forward, said Donald Meeker, co-designer of the Clearview font, in the article.

The FHWA originally supported the new font for its apparent superior legibility for nighttime driving; however, the FHWA now states the font has performed contrary to its intended purpose, the article states. The licensing fees may also be behind the switch, the article says.

Paul Harris, OD, of the Southern College of Optometry says that contrast is key and natural wear-

and-tear may be to blame for the apparent waning of support for the new font. "It is recommended that vision charts be replaced every seven years," says Dr. Harris. "As dirt minimizes the contrast between the white color of the font, and the surface gets worn and loses reflectance, the lack in contrast will take its toll on the visibility on the signs." Dr. Harris also notes highway sign placement as a whole may trump any small font changes, considering the loss of contrast to signs over time. ■

Letter to the Editor

Optometry in Skilled Care Facilities

Editor's note: In December's "Chairside" column, Montgomery Vickers, OD, shared his experiences working with a traveling nursing home practice. You can read this column at www.reviewofoptometry.com/content/c/58445/.

The topic Dr. Vickers selected for his December column, in my view, touched on a huge unmet need and a horribly underserved population: eye care in skilled care facilities. My practice was limited to providing the full scope of eye care for patients in skilled care facilities and, for more than 15 years, I tried to stimulate optometrists to be more involved with this population. Dr. Vickers' personal experience in skilled care facilities has clearly brought into focus (pardon the optometric pun) his appreciation of the problem.

According to 2009 demographic data, approximately 80% of patients in skilled care facilities nationwide were receiving no eye care. We have the most advanced technology in our practices, most of which can be miniaturized and mobilized, but our practices today are driven by chair time and cost effective measures that discourage us from much dialog with our patients and showing them the compassion they so desperately need and deserve. The highest endemic vision problems reported in skilled care facilities can be treated; however, the the medical staff in these facilities simply does not have the skills to provide the care. Eye care is not mandated in skilled care facilities, so most do not offer the service in-house, and patients that have been managed effectively for their entire ambulatory life for diabetic retinopathy, glaucoma, macular degeneration or even cataracts are lost to follow up and are unnecessarily exposed to

catastrophic vision loss.

For 15 years I tried to make a difference one patient at a time, like most eye care providers, and managed to make an impact in my community. However, the problem can only be solved through a public health policy approach that mandates eye care in all skilled care facilities.

We are trying to make a difference now through our Public Health and PhD programs at Salus University, and maybe I will see this change in my professional lifetime—but it will take a broad collaborative approach and professionals like Dr. Vickers, who makes a unique contribution through his humor and insights.

We will keep the fires burning and hopefully, with enough motivated people like Dr. Vickers voicing concern, we will get the attention necessary to help these people before they lose all useful vision.

Thank you, Dr. Vickers, for making our fellow optometrists a little more aware of how important these wonderful patients are and what a difference optometry can make in helping them with the dignity they deserve.

—William A. Monaco, OD, MEd, PhD, associate dean of Biomedical Sciences PhD Program and MPH Programs at Salus University.

Dr. Vickers responds:

I have gained so much as a clinician and healer by joining Dan Shropshire, OD, and his wonderful nursing home mobile practice here in the Dallas/Fort Worth area. As you have said, this is a growing and grossly underserved population. I have a new-found respect for the doctors who dedicate themselves to this mode of practice, and I challenge each of you to find the time to ask these doctors how you can help at least to fill in from time to time. You will be amazed what you learn that you can take back to your own mode of practice.



For patients with decreased tear production presumed to be due to
ocular inflammation associated with Chronic Dry Eye

THE DRY EYE TREATMENT SHE NEEDS TODAY. BECAUSE TOMORROW MATTERS.



RESTASIS® twice a day, every day, helps patients experience increased tear production

Increased tear production was seen at 6 months.¹

Indication and Usage

RESTASIS® (cyclosporine ophthalmic emulsion) 0.05% is indicated to increase tear production in patients whose tear production is presumed to be suppressed due to ocular inflammation associated with keratoconjunctivitis sicca. Increased tear production was not seen in patients currently taking topical anti-inflammatory drugs or using punctal plugs.

Important Safety Information

Contraindications

RESTASIS® is contraindicated in patients with known or suspected hypersensitivity to any of the ingredients in the formulation.

Warnings and Precautions

Potential for Eye Injury and Contamination: To avoid the potential for eye injury and contamination, individuals prescribed RESTASIS® should not touch the vial tip to their eye or other surfaces.

Use With Contact Lenses: RESTASIS® should not be administered while wearing contact lenses. If contact lenses are worn, they should be removed prior to the administration of the emulsion. Lenses may be reinserted 15 minutes following administration of RESTASIS® ophthalmic emulsion.

Adverse Reactions

In clinical trials, the most common adverse reaction following the use of RESTASIS® was ocular burning (upon instillation)—17%. Other reactions reported in 1% to 5% of patients included conjunctival hyperemia, discharge, epiphora, eye pain, foreign body sensation, pruritus, stinging, and visual disturbance (most often blurring).

Please see Brief Summary of the full Prescribing Information on adjacent page.

Reference: 1. RESTASIS® Prescribing Information.



© 2016 Allergan. All rights reserved.
All trademarks are the property of their respective owners.
APC34TC16 160898

RESTASIS® (Cyclosporine Ophthalmic Emulsion) 0.05%

BRIEF SUMMARY—PLEASE SEE THE RESTASIS® PACKAGE INSERT FOR FULL PRESCRIBING INFORMATION.

INDICATION AND USAGE

RESTASIS® ophthalmic emulsion is indicated to increase tear production in patients whose tear production is presumed to be suppressed due to ocular inflammation associated with keratoconjunctivitis sicca. Increased tear production was not seen in patients currently taking topical anti-inflammatory drugs or using punctal plugs.

CONTRAINDICATIONS

RESTASIS® is contraindicated in patients with known or suspected hypersensitivity to any of the ingredients in the formulation.

WARNINGS AND PRECAUTIONS

Potential for Eye Injury and Contamination

To avoid the potential for eye injury and contamination, be careful not to touch the vial tip to your eye or other surfaces.

Use with Contact Lenses

RESTASIS® should not be administered while wearing contact lenses. Patients with decreased tear production typically should not wear contact lenses. If contact lenses are worn, they should be removed prior to the administration of the emulsion. Lenses may be reinserted 15 minutes following administration of RESTASIS® ophthalmic emulsion.

ADVERSE REACTIONS

Clinical Trials Experience

Because clinical trials are conducted under widely varying conditions, adverse reaction rates observed in the clinical trials of a drug cannot be directly compared to rates in the clinical trials of another drug and may not reflect the rates observed in practice.

In clinical trials, the most common adverse reaction following the use of RESTASIS® was ocular burning (17%).

Other reactions reported in 1% to 5% of patients included conjunctival hyperemia, discharge, epiphora, eye pain, foreign body sensation, pruritus, stinging, and visual disturbance (most often blurring).

Post-marketing Experience

The following adverse reactions have been identified during post approval use of RESTASIS®. Because these reactions are reported voluntarily from a population of uncertain size, it is not always possible to reliably estimate their frequency or establish a causal relationship to drug exposure.

Reported reactions have included: hypersensitivity (including eye swelling, urticaria, rare cases of severe angioedema, face swelling, tongue swelling, pharyngeal edema, and dyspnea); and superficial injury of the eye (from the vial tip touching the eye during administration).

USE IN SPECIFIC POPULATIONS

Pregnancy

Teratogenic Effects: Pregnancy Category C

Adverse effects were seen in reproduction studies in rats and rabbits only at dose levels toxic to dams. At toxic doses (rats at 30 mg/kg/day and rabbits at 100 mg/kg/day), cyclosporine oral solution, USP, was embryo- and fetotoxic as indicated by increased pre- and postnatal mortality and reduced fetal weight together with related skeletal retardations. These doses are 5,000 and 32,000 times greater (normalized to body surface area), respectively, than the daily human dose of one drop (approximately 28 mL) of 0.05% RESTASIS® twice daily into each eye of a 60 kg person (0.001 mg/kg/day), assuming that the entire dose is absorbed. No evidence of embryofetal toxicity was observed in rats or rabbits receiving cyclosporine at oral doses up to 17 mg/kg/day or 30 mg/kg/day, respectively, during organogenesis. These doses in rats and rabbits are approximately 3,000 and 10,000 times greater (normalized to body surface area), respectively, than the daily human dose.

Offspring of rats receiving a 45 mg/kg/day oral dose of cyclosporine from Day 15 of pregnancy until Day 21 postpartum, a maternally toxic level, exhibited an increase in postnatal mortality; this dose is 7,000 times greater than the daily human topical dose (0.001 mg/kg/day) normalized to body surface area assuming that the entire dose is absorbed. No adverse events were observed at oral doses up to 15 mg/kg/day (2,000 times greater than the daily human dose).

There are no adequate and well-controlled studies of RESTASIS® in pregnant women. RESTASIS® should be administered to a pregnant woman only if clearly needed.

Nursing Mothers

Cyclosporine is known to be excreted in human milk following systemic administration, but excretion in human milk after topical treatment has not been investigated. Although blood concentrations are undetectable after topical administration of RESTASIS® ophthalmic emulsion, caution should be exercised when RESTASIS® is administered to a nursing woman.

Pediatric Use

The safety and efficacy of RESTASIS® ophthalmic emulsion have not been established in pediatric patients below the age of 16.

Geriatric Use

No overall difference in safety or effectiveness has been observed between elderly and younger patients.

NONCLINICAL TOXICOLOGY

Carcinogenesis, Mutagenesis, Impairment of Fertility

Carcinogenesis: Systemic carcinogenicity studies were carried out in male and female mice and rats. In the 78-week oral (diet) mouse study, at doses of 1, 4, and 16 mg/kg/day, evidence of a statistically significant trend was found for lymphocytic lymphomas in females, and the incidence of hepatocellular carcinomas in mid-dose males significantly exceeded the control value.

In the 24-month oral (diet) rat study, conducted at 0.5, 2, and 8 mg/kg/day, pancreatic islet cell adenomas significantly exceeded the control rate in the low-dose level. The hepatocellular carcinomas and pancreatic islet cell adenomas were not dose related. The low doses in mice and rats are approximately 80 times greater (normalized to body surface area) than the daily human dose of one drop (approximately 28 mL) of 0.05% RESTASIS® twice daily into each eye of a 60 kg person (0.001 mg/kg/day), assuming that the entire dose is absorbed.

Mutagenesis: Cyclosporine has not been found to be mutagenic/genotoxic in the Ames Test, the V79-HGPRT Test, the micronucleus test in mice and Chinese hamsters, the chromosome-aberration tests in Chinese hamster bone-marrow, the mouse dominant lethal assay, and the DNA-repair test in sperm from treated mice. A study analyzing sister chromatid exchange (SCE) induction by cyclosporine using human lymphocytes *in vitro* gave indication of a positive effect (i.e., induction of SCE).

Impairment of Fertility: No impairment in fertility was demonstrated in studies in male and female rats receiving oral doses of cyclosporine up to 15 mg/kg/day (approximately 2,000 times the human daily dose of 0.001 mg/kg/day normalized to body surface area) for 9 weeks (male) and 2 weeks (female) prior to mating.

PATIENT COUNSELING INFORMATION

Handling the Container

Advise patients to not allow the tip of the vial to touch the eye or any surface, as this may contaminate the emulsion. To avoid the potential for injury to the eye, advise patients to not touch the vial tip to their eye.

Use with Contact Lenses

RESTASIS® should not be administered while wearing contact lenses. Patients with decreased tear production typically should not wear contact lenses. Advise patients that if contact lenses are worn, they should be removed prior to the administration of the emulsion. Lenses may be reinserted 15 minutes following administration of RESTASIS® ophthalmic emulsion.

Administration

Advise patients that the emulsion from one individual single-use vial is to be used immediately after opening for administration to one or both eyes, and the remaining contents should be discarded immediately after administration.

Rx Only



Based on package insert 71876US18

© 2014 Allergan, Inc.

Irvine, CA 92612, U.S.A.

® marks owned by Allergan, Inc. APC21XT14

Patented. See www.allergan.com/products/patent_notices

Made in the U.S.A.

News Review

REVIEW® OF OPTOMETRY

BUSINESS OFFICES

11 CAMPUS BLVD., SUITE 100
NEWTOWN SQUARE, PA 19073

CEO, INFORMATION SERVICES GROUP

MARC FERRARA
(212) 274-7062 • MFERRARA@JOBSON.COM

PUBLISHER

JAMES HENNE
(610) 492-1017 • JHENNE@JOBSON.COM

REGIONAL SALES MANAGER

MICHELE BARRETT
(610) 492-1014 • MBARRETT@JOBSON.COM

REGIONAL SALES MANAGER

MICHAEL HOSTER
(610) 492-1028 • MHOSTER@JOBSON.COM

VICE PRESIDENT, OPERATIONS

CASEY FOSTER
(610) 492-1007 • CFOSTER@JOBSON.COM

VICE PRESIDENT, CLINICAL CONTENT

PAUL M. KARPECKI, OD, FAAO
PKARPECKI@JOBSON.COM

PRODUCTION MANAGER

SCOTT TOBIN
(610) 492-1011 • STOBIN@JOBSON.COM

SENIOR CIRCULATION MANAGER

HAMILTON MAHER
(212) 219-7870 • HMAHER@HIHEALTH.COM

CLASSIFIED ADVERTISING

(888) 498-1460

SUBSCRIPTIONS

\$56 A YEAR, \$88 (US) IN CANADA,
\$209 (US) IN ALL OTHER COUNTRIES.

SUBSCRIPTION INQUIRIES

(877) 529-1746 (US ONLY);
OUTSIDE US, CALL (847) 763-9630

CIRCULATION

PO BOX 2025
SKOKIE, IL 60076
TEL: (TOLL FREE) 1-877-529-1746
OUTSIDE US: (847) 763-9630
FAX: (847) 763-9631



CEO, INFORMATION SERVICES GROUP

MARC FERRARA

SENIOR VICE PRESIDENT, OPERATIONS

JEFF LEVITZ

VICE PRESIDENT, HUMAN RESOURCES

TAMMY GARCIA

VICE PRESIDENT, CREATIVE SERVICES & PRODUCTION

MONICA TETTAMANZI

CORPORATE PRODUCTION DIRECTOR

JOHN ANTHONY CAGGIANO

VICE PRESIDENT, CIRCULATION

EMELDA BAREA

For allergic conjunctivitis¹

THE POWER TO CALM THE ITCH



**BEPREVE® — FIRST-LINE, YEAR-ROUND,
WITH BROAD-SPECTRUM ALLERGEN COVERAGE**

INDICATION AND USAGE

BEPREVE® (bepotastine besilate ophthalmic solution) 1.5% is a histamine H₁ receptor antagonist indicated for the treatment of itching associated with allergic conjunctivitis.

IMPORTANT SAFETY INFORMATION

- BEPREVE® is contraindicated in patients with a history of hypersensitivity reactions to bepotastine or any of the other ingredients.
- BEPREVE® is for topical ophthalmic use only. To minimize risk of contamination, do not touch the dropper tip to the eyelids or to any surface. Keep the bottle closed when not in use.
- BEPREVE® should not be used to treat contact lens-related irritation. Remove contact lens prior to instillation of BEPREVE®. Lenses may be reinserted 10 minutes after BEPREVE® administration.
- The most common adverse reaction occurring in approximately 25% of patients was a mild taste following instillation. Other adverse reactions occurring in 2%-5% of patients were eye irritation, headache, and nasopharyngitis.

Please see the accompanying full Prescribing Information for BEPREVE® on the following page.

Reference: 1. BEPREVE [package insert]. Tampa, FL: Bausch & Lomb Incorporated; 2012.

BAUSCH + LOMB

For product-related questions and concerns, call 1-800-323-0000 or visit www.bausch.com.

BEPREVE is a trademark of Bausch & Lomb Incorporated or its affiliates.

© Bausch & Lomb Incorporated. BEP.0014.USA.16

Made by the respected eye-care
specialists at **BAUSCH + LOMB**

BEPREVE®
(bepotastine besilate
ophthalmic solution) 1.5%

BEPREVE® (bepotastine besilate ophthalmic solution) 1.5%

HIGHLIGHTS OF PRESCRIBING INFORMATION

These highlights do not include all the information needed to use BEPREVE® (bepotastine besilate ophthalmic solution) 1.5% safely and effectively. See full prescribing information for BEPREVE®.

BEPREVE® (bepotastine besilate ophthalmic solution) 1.5%

Initial U.S. Approval: 2009

RECENT MAJOR CHANGES

Contraindications (4) 06/2012

INDICATIONS AND USAGE

BEPREVE® is a histamine H₁ receptor antagonist indicated for the treatment of itching associated with allergic conjunctivitis. (1)

DOSAGE AND ADMINISTRATION

Instill one drop into the affected eye(s) twice a day (BID). (2)

DOSAGE FORMS AND STRENGTHS

Solution containing bepotastine besilate, 1.5%. (3)

CONTRAINDICATIONS

Hypersensitivity to any component of this product. (4)

FULL PRESCRIBING INFORMATION: CONTENTS*

1 INDICATIONS AND USAGE

2 DOSAGE AND ADMINISTRATION

3 DOSAGE FORMS AND STRENGTHS

4 CONTRAINDICATIONS

5 WARNINGS AND PRECAUTIONS

- 5.1 Contamination of Tip and Solution
- 5.2 Contact Lens Use
- 5.3 Topical Ophthalmic Use Only

6 ADVERSE REACTIONS

- 6.1 Clinical Trial Experience
- 6.2 Post-Marketing Experience

8 USE IN SPECIFIC POPULATIONS

- 8.1 Pregnancy
- 8.3 Nursing Mothers
- 8.4 Pediatric Use
- 8.5 Geriatric Use

FULL PRESCRIBING INFORMATION

1 INDICATIONS AND USAGE

BEPREVE® (bepotastine besilate ophthalmic solution) 1.5% is a histamine H₁ receptor antagonist indicated for the treatment of itching associated with signs and symptoms of allergic conjunctivitis.

2 DOSAGE AND ADMINISTRATION

Instill one drop of BEPREVE into the affected eye(s) twice a day (BID).

3 DOSAGE FORMS AND STRENGTHS

Topical ophthalmic solution containing bepotastine besilate 1.5%.

4 CONTRAINDICATIONS

Bepreve is contraindicated in patients with a history of hypersensitivity reactions to bepotastine or any of the other ingredients [see *Adverse Reactions* (6.2)].

5 WARNINGS AND PRECAUTIONS

5.1 Contamination of Tip and Solution

To minimize contaminating the dropper tip and solution, care should be taken not to touch the eyelids or surrounding areas with the dropper tip of the bottle. Keep bottle tightly closed when not in use.

5.2 Contact Lens Use

Patients should be advised not to wear a contact lens if their eye is red. BEPREVE should not be used to treat contact lens-related irritation.

BEPREVE should not be instilled while wearing contact lenses. Remove contact lenses prior to instillation of BEPREVE. The preservative in BEPREVE, benzalkonium chloride, may be absorbed by soft contact lenses. Lenses may be reinserted after 10 minutes following administration of BEPREVE.

5.3 Topical Ophthalmic Use Only

BEPREVE is for topical ophthalmic use only.

6 ADVERSE REACTIONS

6.1 Clinical Trials Experience

Because clinical trials are conducted under widely varying conditions, adverse reaction rates observed in the clinical trials of a drug cannot be directly compared to rates in the clinical trials of another drug and may not reflect the rates observed in clinical practice.

WARNINGS AND PRECAUTIONS

- To minimize the risk of contamination, do not touch dropper tip to any surface. Keep bottle tightly closed when not in use. (5.1)
- BEPREVE should not be used to treat contact lens-related irritation. (5.2)
- Remove contact lenses prior to instillation of BEPREVE. (5.3)

ADVERSE REACTIONS

The most common adverse reaction occurring in approximately 25% of patients was a mild taste following instillation. Other adverse reactions which occurred in 2-5% of subjects were eye irritation, headache, and nasopharyngitis. (6)

To report SUSPECTED ADVERSE REACTIONS, contact Bausch & Lomb Incorporated, at 1-800-323-0000, or FDA at 1-800-FDA-1088 or www.fda.gov/medwatch.

See 17 for PATIENT COUNSELING INFORMATION

Revised: 10/2012

11 DESCRIPTION

12 CLINICAL PHARMACOLOGY

- 12.1 Mechanism of Action
- 12.3 Pharmacokinetics

13 NONCLINICAL TOXICOLOGY

- 13.1 Carcinogenesis, Mutagenesis and Impairment of Fertility

14 CLINICAL STUDIES

16 HOW SUPPLIED/STORAGE AND HANDLING

- 17.1 Topical Ophthalmic Use Only
- 17.2 Sterility of Dropper Tip
- 17.3 Concomitant Use of Contact Lenses

*Sections or subsections omitted from the full prescribing information are not listed

The most common reported adverse reaction occurring in approximately 25% of subjects was a mild taste following instillation. Other adverse reactions occurring in 2-5% of subjects were eye irritation, headache, and nasopharyngitis.

6.2 Post Marketing Experience

Hypersensitivity reactions have been reported rarely during the post-marketing use of BEPREVE. Because these reactions are reported voluntarily from a population of unknown size, it is not always possible to reliably estimate their frequency or establish a causal relationship to drug exposure. The hypersensitivity reactions include itching, body rash, and swelling of lips, tongue and/or throat.

8 USE IN SPECIFIC POPULATIONS

8.1 Pregnancy

Pregnancy Category C: Teratogenicity studies have been performed in animals. Bepotastine besilate was not found to be teratogenic in rats during organogenesis and fetal development at oral doses up to 200 mg/kg/day (representing a systemic concentration approximately 3,300 times that anticipated for topical ocular use in humans), but did show some potential for causing skeletal abnormalities at 1,000 mg/kg/day. There were no teratogenic effects seen in rabbits at oral doses up to 500 mg/kg/day given during organogenesis and fetal development (>13,000 times the dose in humans on a mg/kg basis). Evidence of infertility was seen in rats given oral bepotastine besilate 1,000 mg/kg/day; however, no evidence of infertility was observed in rats given 200 mg/kg/day (approximately 3,300 times the topical ocular use in humans). The concentration of radiolabeled bepotastine besilate was similar in fetal liver and maternal blood plasma following a single 3 mg/kg oral dose. The concentration in other fetal tissues was one-third to one-tenth the concentration in maternal blood plasma.

An increase in stillbirths and decreased growth and development were observed in pups born from rats given oral doses of 1,000 mg/kg/day during perinatal and lactation periods. There were no observed effects in rats treated with 100 mg/kg/day.

There are no adequate and well-controlled studies of bepotastine besilate in pregnant

women. Because animal reproduction studies are not always predictive of human response, BEPREVE® (bepotastine besilate ophthalmic solution) 1.5% should be used during pregnancy only if the potential benefit justifies the potential risk to the fetus.

8.3 Nursing Mothers

Following a single 3 mg/kg oral dose of radiolabeled bepotastine besilate to nursing rats 11 days after delivery, the maximum concentration of radioactivity in milk was 0.40 mcg-eq/mL 1 hour after administration; at 48 hours after administration the concentration was below detection limits. The milk concentration was higher than the maternal blood plasma concentration at each time of measurement.

It is not known if bepotastine besilate is excreted in human milk. Caution should be exercised when BEPREVE (bepotastine besilate ophthalmic solution) 1.5% is administered to a nursing woman.

8.4 Pediatric Use

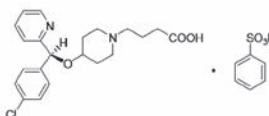
Safety and efficacy of BEPREVE (bepotastine besilate ophthalmic solution) 1.5% have not been established in pediatric patients under 2 years of age. Efficacy in pediatric patients under 10 years of age was extrapolated from clinical trials conducted in pediatric patients greater than 10 years of age and from adults.

8.5 Geriatric Use

No overall difference in safety or effectiveness has been observed between elderly and younger patients.

11 DESCRIPTION

BEPREVE (bepotastine besilate ophthalmic solution) 1.5% is a sterile, topically administered drug for ophthalmic use. Each mL of BEPREVE contains 15 mg bepotastine besilate. Bepotastine besilate is designated chemically as (+)-4-[(S)-p-chloro-alpha-2-pyridylbenzyl]oxy]-1-piperidine butyric acid monobenzenesulfonate. The chemical structure for bepotastine besilate is:



Bepotastine besilate is a white or pale yellowish crystalline powder. The molecular weight of bepotastine besilate is 547.06 daltons. BEPREVE® ophthalmic solution is supplied as a sterile, aqueous 1.5% solution, with a pH of 6.8. The osmolality of BEPREVE (bepotastine besilate ophthalmic solution) 1.5% is approximately 290 mOsm/kg.

Each mL of BEPREVE® (bepotastine besilate ophthalmic solution) 1.5% contains:

Active: Bepotastine besilate 15 mg (equivalent to 10.7 mg bepotastine)

Preservative: benzalkonium chloride 0.005%

Inactives: monobasic sodium phosphate dihydrate, sodium chloride, sodium hydroxide to adjust pH, and water for injection, USP.

12 CLINICAL PHARMACOLOGY

12.1 Mechanism of Action

Bepotastine is a topically active, direct H₁-receptor antagonist and an inhibitor of the release of histamine from mast cells.

12.3 Pharmacokinetics

Absorption: The extent of systemic exposure to bepotastine following topical ophthalmic administration of bepotastine besilate 1% and 1.5% ophthalmic solutions was evaluated in 12 healthy adults. Following one drop of 1% or 1.5% bepotastine besilate ophthalmic solution to both eyes four times daily (QID) for seven days, bepotastine plasma concentrations peaked at approximately one to two hours post-instillation. Maximum plasma concentration for the 1% and 1.5% strengths were 5.1 ± 2.5 ng/mL and 7.3 ± 1.9 ng/mL, respectively. Plasma concentration at 24 hours post-instillation were below the quantifiable limit (2 ng/mL) in 11/12 subjects in the two dose groups.

Distribution: The extent of protein binding of bepotastine is approximately 55% and independent of bepotastine concentration.

Metabolism: *In vitro* metabolism studies with human liver microsomes demonstrated that bepotastine is minimally metabolized by CYP450 isozymes.

In vitro studies demonstrated that bepotastine besilate does not inhibit the metabolism of various

cytochrome P450 substrate via inhibition of CYP3A4, CYP2C9, and CYP2C19. The effect of bepotastine besilate on the metabolism of substrates of CYP1A2, CYP2C8, CYP2D6 was not studied. Bepotastine besilate has a low potential for drug interaction via inhibition of CYP3A4, CYP2C9, and CYP2C19.

Excretion: The main route of elimination of bepotastine besilate is urinary excretion (with approximately 75-90% excreted unchanged in urine).

13 NONCLINICAL TOXICOLOGY

13.1 Carcinogenesis, Mutagenesis and Impairment of Fertility

Long-term dietary studies in mice and rats were conducted to evaluate the carcinogenic potential of bepotastine besilate. Bepotastine besilate did not significantly induce neoplasms in mice receiving a nominal dose of up to 200 mg/kg/day for 21 months or rats receiving a nominal dose of up to 97 mg/kg/day for 24 months. These dose levels represent systemic exposures approximating 350 and 200 times that achieved with human topical ocular use. The no observable adverse effect levels for bepotastine besilate based on nominal dose levels in carcinogenicity tests were 18.7 to 19.9 mg/kg/day in mice and 9.6 to 9.8 mg/kg/day in rats (representing exposure margins of approximately 60 and 20 times the systemic exposure anticipated for topical ocular use in humans).

There was no evidence of genotoxicity in the Ames test, in CHO cells (chromosome aberrations), in mouse hepatocytes (unscheduled DNA synthesis), or in the mouse micronucleus test.

When oral bepotastine was administered to male and female rats at doses up to 1,000 mg/kg/day, there was a slight reduction in fertility index and surviving fetuses. Infertility was not seen in rats given 200 mg/kg/day oral bepotastine besilate (approximately 3,300 times the systemic concentration anticipated for topical ocular use in humans).

14 CLINICAL STUDIES

Clinical efficacy was evaluated in 2 conjunctival allergen challenge (CAC) studies (237 patients). BEPREVE (bepotastine besilate ophthalmic solution) 1.5% was more effective than its vehicle for relieving ocular itching induced by an ocular allergen challenge, both at a CAC 15 minutes post-dosing and a CAC 8 hours post dosing of BEPREVE.

The safety of BEPREVE was evaluated in a randomized clinical study of 861 subjects over a period of 6 weeks.

16 HOW SUPPLIED/STORAGE AND HANDLING

BEPREVE® (bepotastine besilate ophthalmic solution) 1.5% is supplied in a white low density polyethylene plastic squeeze bottle with a white controlled dropper tip and a white polypropylene cap in the following size:

- 5 mL (NDC 24208-629-02)
- 10 mL (NDC 24208-629-01)

STORAGE

Store at 15° – 25°C (59° – 77°F).

17 PATIENT COUNSELING INFORMATION

17.1 Topical Ophthalmic Use Only

For topical ophthalmic administration only.

17.2 Sterility of Dropper Tip

Patients should be advised to not touch dropper tip to any surface, as this may contaminate the contents.

17.3 Concomitant Use of Contact Lenses

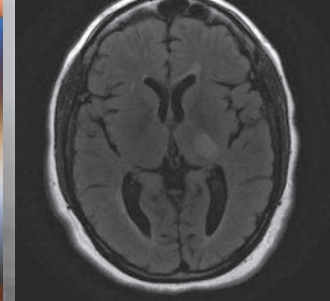
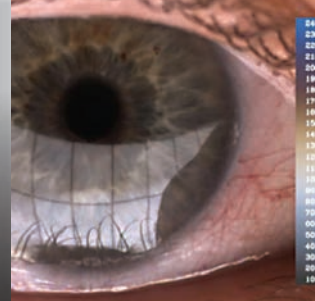
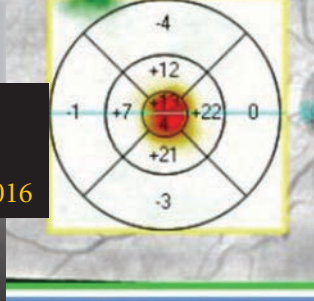
Patients should be advised not to wear a contact lens if their eye is red. Patients should be advised that BEPREVE should not be used to treat contact lens-related irritation.

Patients should also be advised to remove contact lenses prior to instillation of BEPREVE. The preservative in BEPREVE, benzalkonium chloride, may be absorbed by soft contact lenses. Lenses may be reinserted after 10 minutes following administration of BEPREVE.

Manufactured by: Bausch & Lomb Incorporated
Tampa, FL 33637
Under license from:
Senju Pharmaceutical Co., Ltd.
Osaka, Japan 541-0046
®/TM are trademarks of Bausch & Lomb Incorporated or its affiliates
© 2012 Bausch & Lomb Incorporated.

Contents

Review of Optometry March 2016



DIAGNOSTIC SKILLS AND TECHNIQUES

44 OCT's Role in an Optometric Practice

Knowing what you can—and can't—do with this imaging technology helps you provide the best care to patients with common ocular conditions. **By Lee Vien, OD, and David Yang, OD**

64 ESSENTIAL PROCEDURES: Scoring an A+ on a B-Scan

Master the art of this ultrasound technology. **By Derek Urban, OD, Jennifer Ramey, OD, Ryan Bunch, OD, and Nathan Lighthizer, OD**

56 Pupil Testing: Implications for Diagnosis

Diagnosing and managing many retinal and neurological conditions begins with the pupil. These testing techniques and tips can ensure you catch commonly encountered disorders right away. **By Caroline B. Pate, OD**

75 The How and Why of Diagnosing Dry Eye

With new advances in diagnostic technology, the options can be overwhelming. Learn to incorporate and interpret the state of the art in diagnostic technologies. **By Derek N. Cunningham, OD, and Walter O. Whitley, OD, MBA**



84 EARN 2 CE CREDITS Automated Perimetry: Visual Field Deficits in Glaucoma and Beyond

Evaluating the visual pathway can be integral to diagnosing and managing numerous conditions. **By Kristie Draskovic, OD, and John J. McSoley, OD**

96 Vision Expo East 2016: Enrich Your Knowledge Base

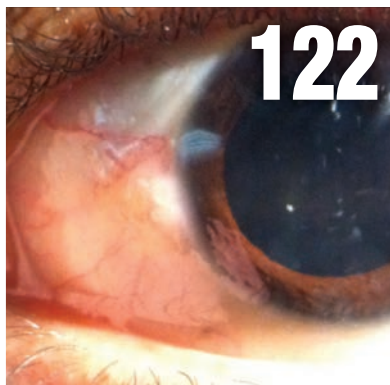
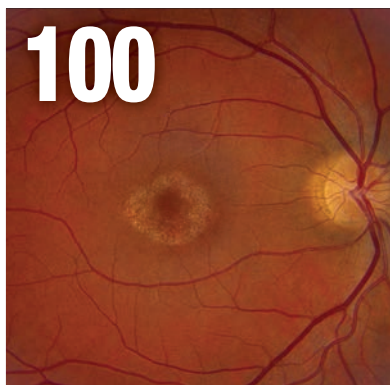
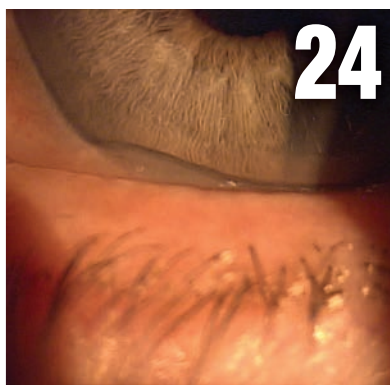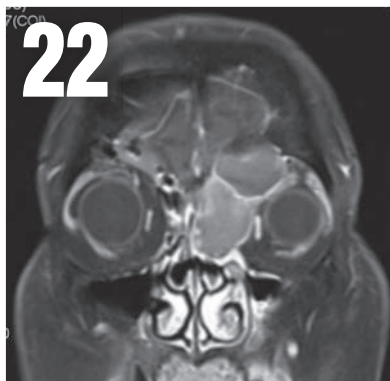The New York meeting is known for its world-class education as well as its exhibits. **By Cheryl G. Murphy, OD, Contributing Editor**



Departments

Review of Optometry March 2016

- 4 News Review**
- 18 Outlook**
The Big Picture
JACK PERSICO
- 20 Chairside**
Become an Optometry Master
MONTGOMERY VICKERS, OD
- 22 Neuro Clinic**
Heal The Burn
**MICHAEL TROTTINI, OD, AND
MICHAEL DELGIODICE, OD**
- 24 Ocular Surface Review**
The Diagnosis Doesn't Add Up
PAUL KARPECKI, OD
- 30 Clinical Quandaries**
Turn On, Tune In, Drop Out
PAUL C. AJAMIAN, OD
- 42 Coding Connection**
Is Technology Replacing Us?
JOHN RUMPAKIS, OD, MBA
- 98 Cornea + Contact Lens Q+A**
Scraping By
JOSEPH P. SHOVLIN, OD
- 100 Retina Quiz**
Dystrophy Mystery
**MARK T. DUNBAR, OD, AND
PAUL C. HAMMOND, OD**
- 106 Review of Systems**
East Meets West: Herbal
Supplements in Health Care
**CARLO J. PELINO, OD, AND
JOSEPH J. PIZZIMENTI, OD**
- 111 Therapeutic Review**
Stye vs. Stye
**ALAN G. KABAT, OD, AND
JOSEPH W. SOWKA, OD**
- 115 Products**
- 116 Meetings + Conferences**
- 117 Advertisers Index**
- 118 Classifieds**
- 122 Diagnostic Quiz**
Not Quite "In The Pink" Yet
ANDREW S. GURWOOD, OD



On The Web >> and more

Check out our multimedia and continuing education online at:
www.reviewofoptometry.com

Digital Edition



Left your copy of *Review of Optometry* at the office? No problem! Access *Review* on your computer or mobile device!

Go to www.reviewofoptometry.com and click on the digimag link for the current issue.

Facebook and Twitter



For daily updates, "Like" our page on Facebook or "Follow" us on Twitter!


- www.facebook.com/revoptom
- <http://twitter.com/#!/revoptom>

Look for augmented content and special offers from *Review* and our advertisers. Specified pages work in conjunction with your smartphone or other mobile device to enhance the experience. With Layar, interactive content leaps off the page!



Step 1: Download the free Layar app for iPhone or Android.



Step 2: Look for pages with the Layar Logo.  INTERACTIVE PRINT



Step 3: Open the Layar app, hold the phone above the page and tap to scan it. Hold the phone above the page to view the interactive content.

The first 150 app downloads and completed forms will be entered into a drawing for a complimentary registration to one of *Review's* 14-hour CE meetings, valued at \$495.



Transitions®

Crizal®

VARILUX®

Xperio^{UV}™

Eyezen™

Give your patients maximum
VISUAL SATISFACTION
and up to a
\$90 REBATE!*

By participating in Power of Vision, new patients will be able to find your practice on Transitions.com, Crizal.com, Varilux.com and XperioUV.com

It all starts April 1, 2016, but you must enroll by March 31 to participate!

ENROLL NOW!

For more information, please speak to your Essilor Sales Consultant.

*Please visit www.PowerOfVision.com for full terms and conditions.

“We pour our heart and soul into helping our colleagues to grow, prosper and embrace the fullness of what the profession can bring to them.”

RON MELTON, OD, +
RANDALL THOMAS, OD,
M.P.H, Educators in Primary
Eye Care, LLC

**INTERNATIONAL
VISION
EXPO
& CONFERENCE**
NEW YORK

30 YEARS OF GIVING BACK

10,500,000 cases of glaucoma, cataracts, AMD, or diabetic retinopathy diagnosed and referred for additional care through the Think About Your Eyes campaign, funded in part by The Vision Council.



CELEBRATING THE

VISIONARIES

IN EDUCATION + FASHION + TECHNOLOGY

REGISTER TODAY! | **NEW YORK THURSDAY, APRIL 14–SUNDAY, APRIL 17** | VisionExpo.com/visionaries

BROUGHT TO YOU BY:  THE VISION COUNCIL

PROUD SUPPORTER OF:  thinkaboutyoureyes.com
AMERICAN OPTOMETRIC ASSOCIATION

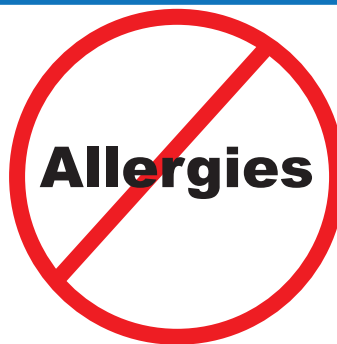PRODUCED BY:  Reed Exhibitions

CONTRIBUTING EDITORS

PAUL C. AJAMIAN, OD, ATLANTA
AARON BRONNER, OD, KENNEWICK, WASH.
MILE BRUJIC, OD, BOWLING GREEN, OHIO
DEREK N. CUNNINGHAM, OD, AUSTIN, TEXAS
MARK T. DUNBAR, OD, MIAMI
ARTHUR B. EPSTEIN, OD, PHOENIX
JAMES L. FANELLI, OD, WILMINGTON, NC
FRANK FONTANA, OD, ST. LOUIS
GARY S. GERBER, OD, HAWTHORNE, NJ
ANDREW S. GURWOOD, OD, PHILADELPHIA
ALAN G. KABAT, OD, MEMPHIS, TENN.
DAVID KADING, OD, SEATTLE
PAUL M. KARPECKI, OD, LEXINGTON, KY.
JEROME A. LEGERTON, OD, MBA, SAN DIEGO
JASON R. MILLER, OD, MBA, POWELL, OHIO
CHERYL G. MURPHY, OD, BABYLON, NY
CARLO J. PELINO, OD, JENKINTOWN, PA.
JOSEPH PIZZIMENTI, OD, FORT LAUDERDALE, FLA.
JOHN RUMPAKIS, OD, MBA, PORTLAND, ORE.
DIANA L. SHECHTMAN, OD, FORT LAUDERDALE, FLA.
JEROME SHERMAN, OD, NEW YORK
JOSEPH P. SHOVLIN, OD, SCRANTON, PA.
JOSEPH W. SOWKA, OD, FORT LAUDERDALE, FLA.
MONTGOMERY VICKERS, OD, ST. ALBANS, W.VA.
WALTER O. WHITLEY, OD, MBA, VIRGINIA BEACH, VA.

EDITORIAL REVIEW BOARD

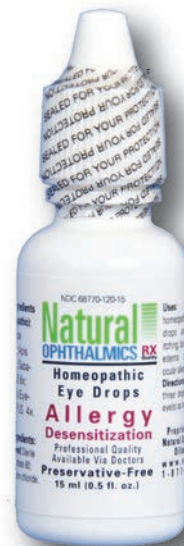JEFFREY R. ANSHEL, OD, CARLSBAD, CALIF.
JILL AUTRY, OD, RPH, HOUSTON
SHERRY J. BASS, OD, NEW YORK
EDWARD S. BENNETT, OD, ST. LOUIS
MARC R. BLOOMENSTEIN, OD, SCOTTSDALE, ARIZ.
CHRIS J. CAKANAC, OD, MURRYSVILLE, PA.
JERRY CAVALLERANO, OD, PHD, BOSTON
WALTER L. CHOATE, OD, MADISON, TENN.
BRIAN CHOU, OD, SAN DIEGO
A. PAUL CHOUS, MA, OD, TACOMA, WASH.
ROBERT M. COLE, III, OD, BRIDGETON, NJ
GLENN S. CORBIN, OD, WYOMISSING, PA.
ANTHONY S. DIECIDUE, OD, STROUDSBURG, PA.
S. BARRY EIDEN, OD, DEERFIELD, ILL.
STEVEN FERRUCCI, OD, SEPULVEDA, CALIF.
MURRAY FINGERET, OD, HEWLETT, NY
IAN BEN GADDIE, OD, LOUISVILLE, KY.
MILTON HOM, OD, AZUSA, CALIF.
BLAIR B. LONSBERRY, MS, OD, MED, PORTLAND, ORE.
THOMAS L. LEWIS, OD, PHD, PHILADELPHIA
DOMINICK MAINO, OD, MED, CHICAGO
KELLY A. MALLOY, OD, PHILADELPHIA
RICHARD B. MANGAN, OD, LEXINGTON, KY.
RON MELTON, OD, CHARLOTTE, NC
PAMELA J. MILLER, OD, JD, HIGHLAND, CALIF.
BRUCE MUCHNICK, OD, COATESVILLE, PA.
MARC MYERS, OD, COATESVILLE, PA.
WILLIAM B. POTTER, OD, FREEHOLD, NJ
CHRISTOPHER J. QUINN, OD, ISELIN, NJ
JOHN L. SCHACHET, OD, ENGLEWOOD, COLO.
JACK SCHAEFFER, OD, BIRMINGHAM, ALA.
MICHAEL C. RADOIU, OD, STAUNTON, VA.
KIMBERLY K. REED, OD, FORT LAUDERDALE, FLA.
LEO P. SEMES, OD, BIRMINGHAM, ALA.
LEONID SKORIN, JR., OD, DO, ROCHESTER, MINN.
JOSEPH W. SOWKA, OD, FORT LAUDERDALE, FLA.
SRUTHI SRINIVASAN, PHD, BS OPTOM, WATERLOO, ONT.
BRAD M. SUTTON, OD, INDIANAPOLIS
LORETTA B. SZCZOTKA, OD, PHD, CLEVELAND
TAMMY P. THAN, MS, OD, BIRMINGHAM, ALA.
RANDALL THOMAS, OD, CONCORD, NC
SARA WEIDMAYER, OD, ANN ARBOR, MI
KATHY C. WILLIAMS, OD, SEATTLE
KAREN YEUNG, OD, LOS ANGELES



Allergy Desensitization Eye Drops

**Professional Quality
Only Available Via Doctors**

- Great with contacts
- Preservative free
- Do not sting
- Work fast & feel great
- Stops itching, burning & watery eyes



Call today
Free Sample Package
877-220-9710



Natural

OPHTHALMICS **RX**

Quality

www.NaturalEyeDrops.com



GP SPECIALISTS
Reshaping the way the world sees.





PRINTED IN USA

FOUNDING EDITOR
FREDERICK BOGER
1891-1913

EDITORIAL OFFICES
11 CAMPUS BLVD., SUITE 100
NEWTOWN SQUARE, PA 19073

EMAIL • REVIEWOFOPTOMETRY@JOBSON.COM

WEBSITE • WWW.REVIEWOFOPTOMETRY.COM

SUBSCRIPTION INQUIRIES
1-877-529-1746

CONTINUING EDUCATION INQUIRIES
1-800-825-4696

EDITOR-IN-CHIEF • JACK PERSICO
(610) 492-1006 • JPERSICO@JOBSON.COM

SENIOR EDITOR • BILL KEKEVIAN
(610) 492-1003 • BKEKEVIAN@JOBSON.COM

SENIOR ASSOCIATE EDITOR • REBECCA HEPP
(610) 492-1005 • RHEPP@JOBSON.COM

SENIOR ASSOCIATE EDITOR • ALIZA BECKER
(610) 492-1043 • ABECKER@JOBSON.COM

SPECIAL PROJECTS EDITOR • JILL HOFFMAN
(610) 492-1037 • JHOFFMAN@JOBSON.COM

ART DIRECTOR • JARED ARAUJO
(610) 492-1032 • JARAUIJO@JOBSON.COM

DIRECTOR OF CE ADMINISTRATION • REGINA COMBS
(212) 274-7160 • RCOMBS@JOBSON.COM

EDITORIAL BOARD

CHIEF CLINICAL EDITOR • PAUL M. KARPECKI, OD

ASSOCIATE CLINICAL EDITORS • JOSEPH P. SHOVLIN, OD;
ALAN G. KABAT, OD; CHRISTINE W. SINDT, OD

DIRECTOR OPTOMETRIC PROGRAMS • ARTHUR EPSTEIN, OD

CLINICAL & EDUCATION CONFERENCE ADVISOR
PAUL M. KARPECKI, OD

CASE REPORTS COORDINATOR • ANDREW S. GURWOOD, OD

CLINICAL CODING EDITOR • JOHN RUMPAKIS, OD, MBA

CONSULTING EDITOR • FRANK FONTANA, OD

COLUMNISTS

CHAIRSIDE • MONTGOMERY VICKERS, OD

CLINICAL QUANDARIES • PAUL C. AJAMIAN, OD

CODING CONNECTION • JOHN RUMPAKIS, OD

CORNEA & CONTACT LENS Q+A • JOSEPH P. SHOVLIN, OD

DIAGNOSTIC QUIZ • ANDREW S. GURWOOD, OD

FOCUS ON REFRACTION • MARC TAUB, OD;
PAUL HARRIS, OD

GLAUCOMA GRAND ROUNDS • JAMES L. FANELLI, OD

NEURO CLINIC • MICHAEL TROTTINI, OD;
MICHAEL DELGIODICE, OD

OCULAR SURFACE REVIEW • PAUL M. KARPECKI, OD

RETINA QUIZ • MARK T. DUNBAR, OD

REVIEW OF SYSTEMS • CARLO J. PELINO, OD;
JOSEPH J. PIZZIMENTI, OD

SURGICAL MINUTE • DEREK N. CUNNINGHAM, OD;
WALTER O. WHITLEY, OD, MBA

THERAPEUTIC REVIEW • JOSEPH W. SOWKA, OD;
ALAN G. KABAT, OD

URGENT CARE • RICHARD B. MANGAN, OD

JOBSON MEDICAL INFORMATION LLC



Outlook

By Jack Persico, Editor-in-Chief



The Big Picture

Relations between ophthalmology and optometry have thawed. Even in frigid Massachusetts.

The theme of last month's SECO conference in Atlanta was, "The Big Picture: Widen Your Perspective." The big picture I came away with? That a broad swath of the medical community finally recognizes the legitimacy of optometric primary eye care.

SECO again featured many of the best and brightest in optometry. To see so many expert optometric clinicians advancing the profession in a collaborative spirit always feels great. But this year's SECO also featured ophthalmologists and other non-OD experts delivering high-profile lectures on cutting-edge topics. Unlike some conferences that tout a single big-name MD as a bit of stunt casting, this was less showy and more truly cooperative.

Eye surgeon John Berdahl, MD, updated attendees on the mechanisms of glaucoma. Oculoplastics specialist Byron Wilkes, MD, gave an overview of lesions and other conditions treatable with eyelid and orbital surgery. Pediatrician Christina Master, MD, partnered with vision therapy guru Michael Galloway, OD, to lecture on concussion injuries. Infectious disease specialist Robert Kalayjian, MD, addressed global healthcare crises like Ebola, HIV, malaria and the Zika virus.

Reaching beyond the traditional field of clinicians, Columbia University's Don Hood, PhD, who has been studying the physiology of the visual system for decades, gave a fascinating two-hour talk on the pathophysiology of macular damage in glaucoma and how it manifests in OCT scans and visual field tests. His

talk was both a high-level discussion of the frontiers in visual science and a didactic lecture on day-to-day clinical practice concerns. Bravo to Dr. Hood for sharing his expertise with the optometric community (and SECO for making it happen).

How refreshing that these interdisciplinary efforts came off without drama. This was, after all, a conference that pushed at the edges of scope-of-practice battles—trailblazer and frequent *Review* contributor Nathan Lighthizer, OD, gave talks on how ODs can perform laser procedures and injections, for instance.

Not long ago, the thought of an ophthalmologist lecturing at an optometric meeting—aside from self-serving ones aimed at boosting referrals of surgical patients—was controversial. For an MD to attend an OD conference is to tacitly condone it. But to educate is to enable. Thankfully, outreach to optometry is no longer the third rail it once was. There will always be friction at the borders, but even the most stalwart ophthalmology traditionalists can't deny that optometrists are central to the delivery of primary eye care.

Meanwhile, up north in Massachusetts, ODs may finally get the right to prescribe glaucoma drugs. "Unwarranted restrictions may be reducing patient access, raising costs, and foreclosing opportunities for early treatment," wrote the Federal Trade Commission to the legislature in late February. It's good to hear such restrictions called *unwarranted* by the FTC. Optometric primary care is now considered the norm, not an anomaly. It's about time. ■

13TH ANNUAL EDUCATION SYMPOSIUM

Optometric Cornea, Cataract and Refractive Society
(Formerly OCRT)



The meeting of the year for ODs involved and interested in advanced ocular disease management, refractive surgery, cataract surgery and innovative technologies

Up to
**11 CE
Credits**
(COPE approval pending)

APRIL 9-10, 2016

Hotel del Coronado • San Diego, CA

AGENDA

SATURDAY APRIL 9TH

9:00am – 9:30am	REGISTRATION – OCCRS Workshop
9:30am – 11:30am	Workshop: Refractive and Cataract Comanagement
10:30am – 11:45am	REGISTRATION – OCCRS
11:45am – 12:45pm	Contemporary Irregular Cornea Management Using Contact Lenses
12:45pm – 2:00pm	OCCRS Multi-Sponsor Lunch
2:00pm – 4:00pm	Keratoconus & Corneal Diseases: Corneal Cross linking and More
4:00pm – 4:30pm	Break
4:30pm – 6:30pm	Ocular Surface Disease Update
6:30pm – 7:15pm	Reception

SUNDAY, APRIL 10TH

7:15am – 8:00am	Breakfast
8:00am – 9:00am	Refractive Surgery Treatment
9:00am – 10:00am	Femtosecond Laser Update
10:00am – 10:40am	Break
10:40am – 12:40pm	Cataract Surgery Update: Diagnosis and Management, and IOL Options

- The Optometric Cornea, Cataract and Refractive Society will sponsor its 13th annual education symposium, bringing together the most notable experts in the field of cornea, cataract and refractive technology to discuss evolving clinical innovations and management of ocular surface disease and other anterior segment complications.
- This interactive meeting encourages questions, comments and audience participation with panel discussion.
- Up to 11 hours of CE* will be awarded to attendees. Registration fee includes education, breakfast, breaks and lunch.
- Featuring key opinion leaders: Drs. Black, Chang, Friess, Geffen, Goodman, Johnston, Karpecki, Morgenstern, Owen, Schroeder Swartz, Seglison, Tullo, and more.

TO REGISTER ONLINE:

www.reviewofoptometry.com/sandiego2016

\$295 for up to 11 hours of CE - \$195 for OCCRS Members

Military Appreciation Discount of \$75 off

For more information, contact Clark Chang, OD, at cchang@vision-institute.com
or Andrew Morgenstern, OD, at andrewmorgenstern@gmail.com, or visit www.occrs.org

Administered by
Review of Optometry®



Become an Optometry Master

It's time to perfect the art of saying the same old thing, but making everyone think we know what we are talking about. **By Montgomery Vickers, OD**

I know a master plumber. I know a computer expert. But doctors? We just practice. Apparently, we never quite get the hang of it like others. Maybe it's because we are always open to suggestion. If pipes are clogged, a master plumber has a solution to the problem. If your pipes are clogged and you see a gastroenterologist, who really knows what the best solution is? After all, the GI doc is still just practicing.

Maybe that's why bureaucrats make up inane rules to see just how much we can take before we run screaming for the hills. To a bureaucrat, "idiopathic" just means "the doctor is an idiot." OK, bad example, considering that is, in fact, what "idiopathic" means. But, you see what I'm saying, right?

We need to quit practicing and move toward perfection. Here's what professionals who have moved beyond practicing can teach us:

1. Never say, "I'm not sure." Instead, say: "Hmm. It's very complicated."
2. Throw away any textbooks lying around the office. They make patients think you have to look stuff up. That is so unprofessional (sneak and use the internet instead).
3. Wear surgical scrubs, take off your rubber gloves as you enter the room, and wear a mask ... a Star Wars mask.
4. Even if you are 20/15, wear big thick glasses. Oh, and speak with an English accent.
5. Hang a bunch of plaques around the office that have your name and some vague award such

as "Top 20 (Anything) In America," "Mensa salutes ..." or "Grand Champion Eye Roper."

6. Have pictures of your family in every room—you, Beyonce and one of those hairless cats hanging around a grand piano listening to the 4-year-old triplets playing Bach.

7. Call your sales reps and tell them their visits are no longer needed because you already have everything any optometrist could ever possibly need ... YOU.

8. During every examination, have a staff member interrupt to tell you the president is on line two. Just smile at the patient and say "I'll call him back." No need to tell them it's the president of the PTA.

9. Buy up old x-ray backlights and hang x-rays of skulls in every room. If not that, at least have screen savers of dreaded diseases on every computer in the building.

10. At the end of the exam, take your patient by the hand and tell them you will do all you can to prevent them from going blind from their meibomian gland dysfunction.

11. If a patient asks about your weekend, tell them you had dinner with Oprah. Don't tell them you took Oprah for a walk and she chewed your slippers.

12. Get fit and eat right—or at least buy Spanx.

13. Wear a suit, so no matter who you see, you can say you just came from a "bored" meeting (spelled differently in writing, of course).

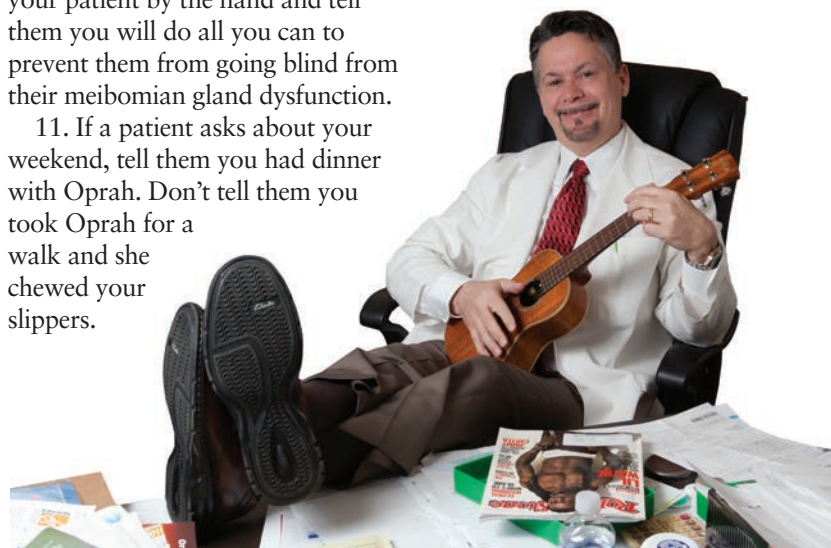
14. Learn everything about everything. That's why they invented Wikipedia.

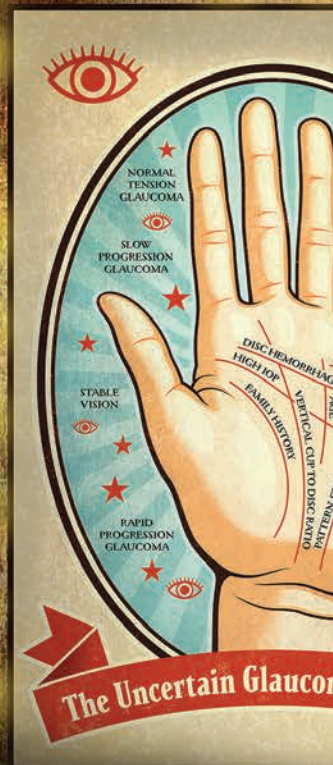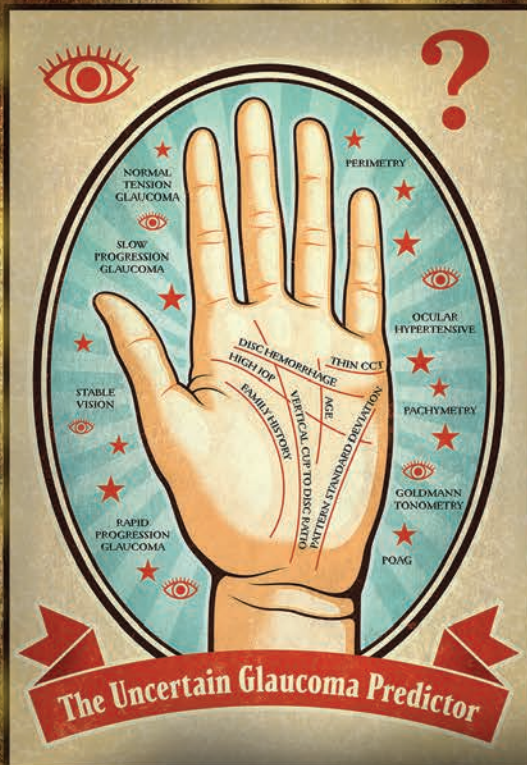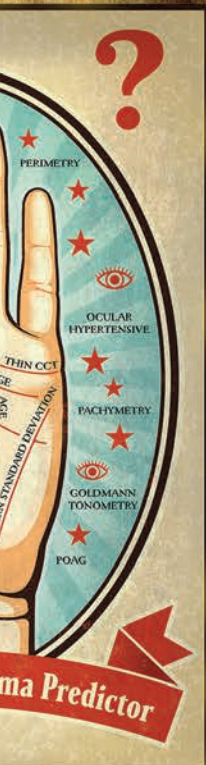
15. Open your mind to new points of view instead of just believing you are the idiot who left the car running with the keys locked inside.

16. Marry somebody smarter than you. That was easy for me.

You are still practicing. I would urge you to shake off the old mantle of "Wow! Now that's a big bump on your eyelid!" and move up to "I've treated a million of those through the years and my best advice is to call a master plumber right away!"

Or maybe we should just be happy practicing, eh? ■





ma Predictor

The Uncertain Glaucoma Predictor

The Uncertain Glaucoma Predictor



TAKE THE UNCERTAINTY OUT OF PREDICTING GLAUCOMA RISK WITH

CORNEAL HYSTERESIS.

You shouldn't have to be a fortune teller to predict glaucoma progression.

Only **Ocular Response Analyzer®** measures **Corneal Hysteresis**, a superior predictor of glaucoma progression, providing you with a more confident glaucoma risk assessment.

Introducing the all-new **Ocular Response Analyzer® G3**, an essential part of your glaucoma workup.

Learn more at www.reichert.com/ora or at **Vision Expo East - Booth MS 6810**



Advancing Eye Care. American Innovation.



Heal the Burn

If you note proptosis, resistance to retropulsion and periorbital burning, be on alert for compressive lesions like mucoceles. **By Michael Trottini, OD, and Michael DelGiodice, OD**

A 66-year-old Asian female presented with a chief complaint of burning in her left eye for the past three months. She spoke limited English, which made it difficult (at least initially) to obtain a thorough history. Her medical history included diabetes, hypertension and high cholesterol, for which she was taking metformin, amlodipine and atorvastatin.

Best-corrected visual acuity was 20/200 OD and 20/60 OS. The reduction in her right eye was attributed to amblyopia, and the reduction in the left eye was attributed to nuclear sclerosis. Pupils were normal, round and equally reactive to light.

Gross observation showed facial asymmetry with the left eye pushed down and out. Extraocular motilities showed a restriction on upgaze (80%) and adduction (50%). Due to the language barrier, she was unable to perform cover test.

Exophthalmometry revealed proptosis in the left eye, which measured 15/19.5mm, and resistance to retropulsion was noted in the left eye. Other than cataracts, her anterior and posterior segments were unremarkable. Neither disc edema nor pallor was noted in either eye.

Upon further and more specific questioning, our patient reported the burning was periorbital—around her left forehead and left nostril. She also reported seeing double for the past few months.

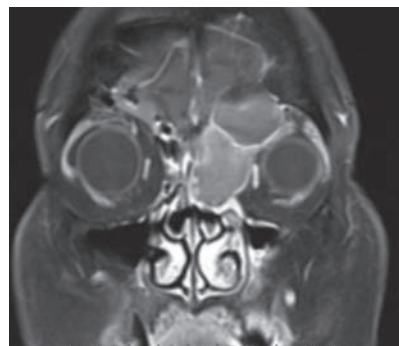
Given our clinical findings and patient history, the most likely etiolo-

gy was a compressive lesion. An orbital MRI was ordered with and without contrast, which revealed a large frontal sinus mass extending into the left orbit and left ethmoid sinus. The mass was hyperintense on T1 and showed minimal peripheral enhancement. Correlating the radiologic and clinical findings, this was most consistent with a mucocele; however, a soft tissue mass could not be excluded.

Our patient was referred to an ENT for further evaluation. A CT was performed to evaluate the extent of bone erosion, which was significant, and included anterior skull base erosion. She underwent endoscopic sinus surgery with ENT and neurosurgery; the surgeon confirmed and drained a mucocele. Two months later our patient showed complete resolution of her diplopia, headache, eye and nose pain. Her eyes were symmetrical, extraocular movements were full and exophthalmometry measured 15/16mm.

Discussion

The paranasal sinuses—air-filled spaces around the nasal cavity—include the frontal, sphenoid, maxillary and ethmoid sinuses. Sinus ostia are openings in the sinus cavities that connect and drain to the nasal cavity. Paranasal sinus mucoceles are mucus-filled cystic masses that result from obstruction of the sinus ostia.¹ As mucoceles expand, they can cause bone erosion and displace surrounding structures.² The frontal sinus is most commonly affected



Post-contrast coronal image shows a large left frontal sinus mass extending into the left orbit and ethmoid sinus, with peripheral enhancement of the lesion.

(approximately 60 to 89%), and because of the close anatomic location, mucoceles can often spread intraorbitally and intracranially.² Mucoceles can occur at any age, but are most commonly seen in patients 40 to 60-years-old.² A pyocele or mucopyocele is an infected mucocele, which can lead to orbital abscess, meningitis or cavernous sinus thrombosis.³

Depending on the location, symptoms of mucoceles can be rhinologic, neurologic or ophthalmologic.¹ Patients will often present with periorbital pain and headache. If the globe becomes displaced, patients will also complain of diplopia. Clinical findings generally include proptosis, restricted extraocular motilities and periorbital swelling. Exophthalmometry is useful in measuring the degree of proptosis. Forced duction testing can help differentiate between a neurogenic or restrictive process, but is often

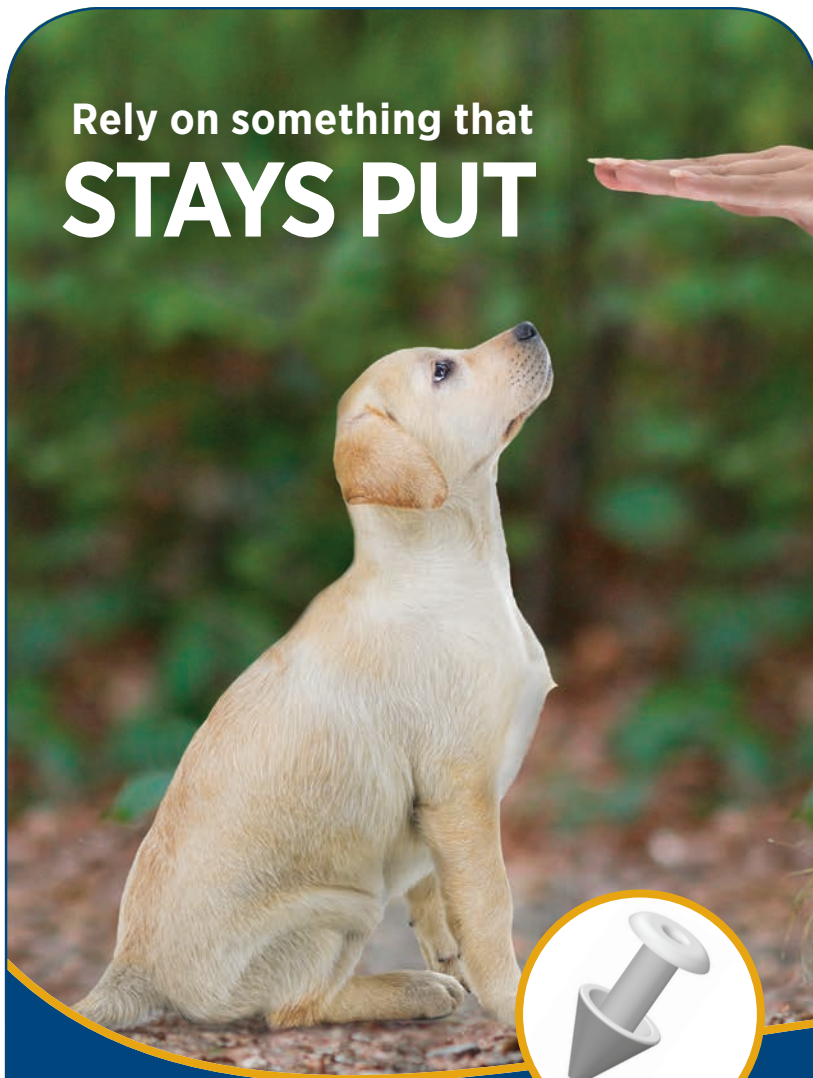Rely on something that **STAYS PUT**

unnecessary in these cases. The presence of proptosis and resistance to retropulsion as seen in our patient is strong evidence of a compressive and restrictive mass. Sphenoid and ethmoid mucoceles can cause divisional oculomotor palsies, and posterior ethmoid and sphenoid mucoceles can cause direct optic nerve compression, causing vision loss and optic atrophy.^{2,4,5} Sinus mucoceles are best observed with MRI and CT imaging, and often both are indicated prior to surgery. MRI allows for better visualization of the mass along with its intracranial and intraorbital extension, while CT allows for better visualization of bone destruction.⁶

Mucocele appearance on MRI can vary depending on their contents. For example, bright signal intensity on T2-weighted images correlates with increased water content while low signal intensity on T2-weighted images correlates with inspissated mucus.⁶ This variability can make it difficult to distinguish a mucocele from a neoplastic process.

The preferred treatment of frontal sinus mucoceles is drainage via endoscopic sinus surgery, which is minimally invasive and yields excellent clinical outcomes.² ■

1. Capra GG, Carbone PN, Mullin DP. Paranasal Sinus Mucocele. *Head Neck Pathol.* 2012 Sep; 6(3):369-72.
2. Aggarwal SK, Bhavana K, Keshri A, et al. Frontal sinus mucocele with orbital complications: management by varied surgical approaches. *Asian J Neurosurg.* 2012 Jul-Sep; 7(3):135-40.
3. Rajan K, Santhi T. Frontoethmoidal mucocele with orbital and intracranial extension. *Indian J Otolaryngol Head Neck Surg.* 2007 Dec;59(4):363-5.
4. Gupta AK, Menon V, Sharma P, et al. A sphenoid sinus mucocele simulating as retro bulbar optic neuritis. *Indian J Ophthalmol.* 2012 May-Jun;60(3):216-18.
5. Kim DW, Sohn HY, Jeon SY et al. Ethmoidal mucocele presenting as oculomotor nerve paralysis. *Clin Exp Otorhinolaryngol.* 2013 Jun;6(2):103-6.
6. Tassel PV, Lee YY, Jing BS, De Pena CA. Mucoceles of the paranasal sinuses: MR imaging with CT correlation. *AJR Am J Roentgenol.* 1989 Aug;153(2):407-12. Accessed Nov 2015. www.cancer.gov/about-cancer/causes-prevention/risk/alcohol/alcohol-fact-sheet.



92%*
RETENTION

We've taken the worry out of plug retention, so you can concentrate on patient retention. The Parasol® Punctal Occluder trumps the competition with an unprecedented 92% retention rate. Use the Parasol® Punctal Occluder, designed for easy insertion and guaranteed to stay put.

TO ORDER: 866-906-8080
customersupport@beaver-visitec.com
odysseymed.com or beaver-visitec.com

bvi Beaver Visitec
Keeping Your Vision in Sight

* "Plugs Reduce Dry Eye Symptoms, Improve Vision", Craig McCabe, M.D., Review of Ophthalmology, 2009. BVI, BVI Logo and all other trademarks (unless noted otherwise) are property of Beaver-Visitec International ("BVI") company © 2016 BVI



The Diagnosis Doesn't Add Up

When signs and symptoms of dry eye disease don't correlate, clinicians must use everything in their toolboxes to determine the correct management strategy.

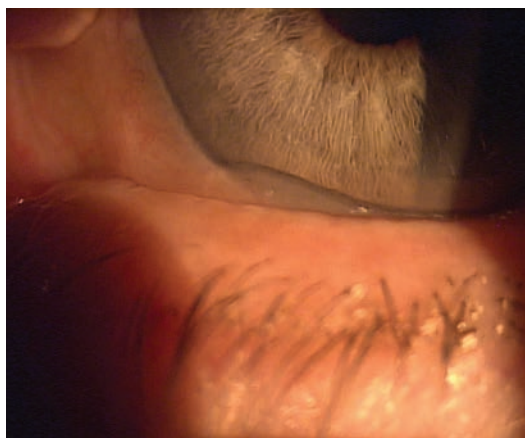By Paul M. Karpecki, OD

Research shows that if a doctor only relies on symptoms to make a diagnosis of dry eye disease (DED), they will likely be wrong about 40% of the time.^{1,2} So how could a patient have symptoms of dryness, grittiness, blurred or fluctuating vision and irritated eyes that typically occur late in the day or after computer use and not have DED?

Diagnostic Dilemma

A patient presents in your office for a dry eye evaluation with the common symptoms of dry eye disease. You measure tear osmolarity at 284 OD and 287 OS. InflammDry (RPS) testing is negative. Meibomian gland expression reveals mild turbid meibum and there is mild truncation of the glands on meibography. The tear film break-up time (TBUT) is four seconds, and there is trace inferior corneal staining with NaFl dye. So now what do you do?

Using symptoms to diagnose this patient could give you the wrong diagnosis, not just because there are times when patients with DED don't experience symptoms, but also because many conditions have symptoms similar to DED.¹ This patient had been on therapies for almost six months before seeking another doctor, stating that his drops weren't working. During



A patient referred for DED was actually diagnosed with conjunctivochalasis.

examination, a cover test revealed exophoria at distance, which was confirmed with Von Graefe, and further testing diagnosed convergence insufficiency. The patient was referred to a vision therapy specialist and returned to the office with no dry eye symptoms and even mentioned that his headaches had resolved.

As this patient illustrates, too often patients are put on dry eye medications and artificial tears simply because their symptoms match that of DED. They also have a test or two, particularly the older, more invasive ones such as TBUT, that appear to confirm dry eye and even trace inferior corneal staining. The patient then uses medications for dry eye expecting relief; instead, they return frustrated and blame the drops (which would have worked if

the patient really had dry eye) or even seek another eye care provider.

DED Differentials

In addition to the aforementioned convergence insufficiency, other dry eye disease differentials include:

- *Conjunctival concretions.*

These may cause gritty eyes or foreign body sensation.

- *Conjunctivochalasis*

(CCH). This eventually may lead to DED and typically causes symptoms of grittiness, foreign body sensation, epiphora and red, irritated eyes.

Patients with CCH usually test positive for corneal and conjunctival staining and a rapid TBUT; typically in mild to moderate cases, osmolarity is normal while MMP-9 testing is elevated.³⁻⁵

The presence of more frequent subconjunctival hemorrhages may point more toward a diagnosis of CCH, but the overlap with dry eye disease represents yet another reason for consideration of advanced testing in ocular surface disease management.⁶

- *Salzmann's nodular degeneration (SND).* This has been shown to mimic dry eye and, like DED, is bilateral in 63% of cases.^{7,8} Histopathologically, the epithelium over the nodules is considerably thinned in SND, resulting in symptoms of dryness, foreign body sensation,



CHOOSE **TRAVATAN Z® Solution:**
A POWERFUL START

Sustained

30% IOP lowering
at 12, 14, and 20 hours post-dose
in a 3-month study^{1,2*}

Not actual patient

TRAVATAN Z® Solution has no FDA-approved therapeutic equivalent available

Help patients start strong and stay on track with **Openings®**

Patient Support Program from Alcon

INDICATIONS AND USAGE

TRAVATAN Z® (travoprost ophthalmic solution) 0.004% is indicated for the reduction of elevated intraocular pressure (IOP) in patients with open-angle glaucoma or ocular hypertension.

Dosage and Administration

The recommended dosage is 1 drop in the affected eye(s) once daily in the evening. TRAVATAN Z® Solution should not be administered more than once daily since it has been shown that more frequent administration of prostaglandin analogs may decrease the IOP-lowering effect.

TRAVATAN Z® Solution may be used concomitantly with other topical ophthalmic drug products to lower IOP. If more than 1 topical ophthalmic drug is being used, the drugs should be administered at least 5 minutes apart.

IMPORTANT SAFETY INFORMATION

Warnings and Precautions

Pigmentation—Travoprost ophthalmic solution has been reported to increase the pigmentation of the iris, periorbital tissue (eyelid), and eyelashes. Pigmentation is expected to increase as long as travoprost is administered. After discontinuation of travoprost, pigmentation of the iris is likely to be permanent, while pigmentation of the periorbital tissue and eyelash changes have been reported to be reversible in some patients. The long-term effects of increased

pigmentation are not known. While treatment with TRAVATAN Z® Solution can be continued in patients who develop noticeably increased iris pigmentation, these patients should be examined regularly.

Eyelash Changes—TRAVATAN Z® Solution may gradually change eyelashes and vellus hair in the treated eye. These changes include increased length, thickness, and number of lashes. Eyelash changes are usually reversible upon discontinuation of treatment.

Use With Contact Lenses—Contact lenses should be removed prior to instillation of TRAVATAN Z® Solution and may be reinserted 15 minutes following its administration.

Adverse Reactions

The most common adverse reaction observed in controlled clinical studies with TRAVATAN Z® Solution was ocular hyperemia, which was reported in 30 to 50% of patients. Up to 3% of patients discontinued therapy due to conjunctival hyperemia. Ocular adverse reactions reported at an incidence of 5 to 10% in these clinical studies included decreased visual acuity, eye discomfort, foreign body sensation, pain, and pruritus. In postmarketing use with prostaglandin analogs, periorbital and lid changes including deepening of the eyelid sulcus have been observed.

Use in Specific Populations

Use in pediatric patients below the age of 16 years is not recommended because of potential safety concerns related to increased pigmentation following long-term chronic use.

For additional information about TRAVATAN Z® Solution, please see the brief summary of Prescribing Information on the adjacent page.

***Study Design:** Double-masked, randomized, parallel-group, multicenter non-inferiority comparison of the efficacy and safety of travoprost 0.004% preserved with benzalkonium chloride (BAK) to TRAVATAN Z® Solution after 3 months of treatment in patients with open-angle glaucoma or ocular hypertension. Baseline IOPs were 27.0 mm Hg (n=322), 25.5 mm Hg (n=322), and 24.8 mm Hg (n=322) at 8 AM, 10 AM, and 4 PM for TRAVATAN Z® Solution. At the end of Month 3, the TRAVATAN Z® Solution group had mean IOPs (95% CI) of 18.7 mm Hg (-0.4, 0.5), 17.7 mm Hg (-0.4, 0.6), and 17.4 mm Hg (-0.2, 0.8) at 8 AM, 10 AM, and 4 PM, respectively. Statistical equivalent reductions in IOP (95% confidence interval about the treatment differences were entirely within ±1.5 mm Hg) were demonstrated between the treatments at all study visits during the 3 months of treatment.

References: 1. Data on file, 2013. 2. Lewis RA, Katz GJ, Weiss MJ, et al. Travoprost 0.004% with and without benzalkonium chloride: a comparison of safety and efficacy. *J Glaucoma*. 2007;16(1):98-103.

TRAVATAN Z®

(travoprost ophthalmic
solution) 0.004%

Alcon®
a Novartis company

© 2015 Novartis 10/15 US-TRZ-15-E-0278

TRAVATAN Z[®]

(travoprost ophthalmic solution) 0.004%

BRIEF SUMMARY OF PRESCRIBING INFORMATION

INDICATIONS AND USAGE

TRAVATAN Z[®] (travoprost ophthalmic solution) 0.004% is indicated for the reduction of elevated intraocular pressure in patients with open-angle glaucoma or ocular hypertension.

DOSAGE AND ADMINISTRATION

The recommended dosage is one drop in the affected eye(s) once daily in the evening. TRAVATAN Z[®] (travoprost ophthalmic solution) should not be administered more than once daily since it has been shown that more frequent administration of prostaglandin analogs may decrease the intraocular pressure lowering effect.

Reduction of the intraocular pressure starts approximately 2 hours after the first administration with maximum effect reached after 12 hours.

TRAVATAN Z[®] Solution may be used concomitantly with other topical ophthalmic drug products to lower intraocular pressure. If more than one topical ophthalmic drug is being used, the drugs should be administered at least five (5) minutes apart.

CONTRAINDICATIONS

None

WARNINGS AND PRECAUTIONS

Pigmentation

Travoprost ophthalmic solution has been reported to cause changes to pigmented tissues. The most frequently reported changes have been increased pigmentation of the iris, periorbital tissue (eyelid) and eyelashes. Pigmentation is expected to increase as long as travoprost is administered. The pigmentation change is due to increased melanin content in the melanocytes rather than to an increase in the number of melanocytes. After discontinuation of travoprost, pigmentation of the iris is likely to be permanent, while pigmentation of the periorbital tissue and eyelash changes have been reported to be reversible in some patients. Patients who receive treatment should be informed of the possibility of increased pigmentation. The long term effects of increased pigmentation are not known.

Iris color change may not be noticeable for several months to years. Typically, the brown pigmentation around the pupil spreads concentrically towards the periphery of the iris and the entire iris or parts of the iris become more brownish. Neither nevi nor freckles of the iris appear to be affected by treatment. While treatment with TRAVATAN Z[®] (travoprost ophthalmic solution) 0.004% can be continued in patients who develop noticeably increased iris pigmentation, these patients should be examined regularly.

Eyelash Changes

TRAVATAN Z[®] Solution may gradually change eyelashes and vellus hair in the treated eye. These changes include increased length, thickness, and number of lashes. Eyelash changes are usually reversible upon discontinuation of treatment.

Intraocular Inflammation

TRAVATAN Z[®] Solution should be used with caution in patients with active intraocular inflammation (e.g., uveitis) because the inflammation may be exacerbated.

Macular Edema

Macular edema, including cystoid macular edema, has been reported during treatment with travoprost ophthalmic solution. TRAVATAN Z[®] Solution should be used with caution in aphakic patients, in pseudophakic patients with a torn posterior lens capsule, or in patients with known risk factors for macular edema.

Angle-closure, Inflammatory or Neovascular Glaucoma

TRAVATAN Z[®] Solution has not been evaluated for the treatment of angle-closure, inflammatory or neovascular glaucoma.

Bacterial Keratitis

There have been reports of bacterial keratitis associated with the use of multiple-dose containers of topical ophthalmic products. These containers had been inadvertently contaminated by patients who, in most cases, had a concurrent corneal disease or a disruption of the ocular epithelial surface.

Use with Contact Lenses

Contact lenses should be removed prior to instillation of TRAVATAN Z[®] Solution and may be reinserted 15 minutes following its administration.

ADVERSE REACTIONS

Clinical Studies Experience

Because clinical studies are conducted under widely varying conditions, adverse reaction rates observed in the clinical studies of a drug cannot be directly compared to rates in the clinical studies of another drug and may not reflect the rates observed in practice. The most common adverse reaction observed in controlled clinical studies with TRAVATAN[®] (travoprost ophthalmic solution) 0.004% and TRAVATAN Z[®] (travoprost ophthalmic solution) 0.004% was ocular hyperemia which was reported in 30 to 50% of patients. Up to 3% of patients discontinued therapy due to conjunctival hyperemia. Ocular adverse reactions reported at an incidence of 5 to 10% in these clinical studies included decreased visual acuity, eye discomfort, foreign body sensation, pain and pruritus. Ocular adverse reactions reported at an incidence of 1 to 4% in clinical studies with TRAVATAN[®] or TRAVATAN Z[®] Solutions included abnormal vision, blepharitis, blurred vision, cataract, conjunctivitis, corneal staining, dry eye, iris discoloration, keratitis, lid margin crusting, ocular inflammation, photophobia, subconjunctival hemorrhage and tearing.

Nonocular adverse reactions reported at an incidence of 1 to 5% in these clinical studies were allergy, angina pectoris, anxiety, arthritis, back pain, bradycardia, bronchitis, chest pain, cold/flu syndrome, depression, dyspepsia, gastrointestinal disorder, headache, hypercholesterolemia, hypertension, hypotension, infection, pain, prostate disorder, sinusitis, urinary incontinence and urinary tract infections.

In postmarketing use with prostaglandin analogs, periorbital and lid changes including deepening of the eyelid sulcus have been observed.

USE IN SPECIFIC POPULATIONS

Pregnancy

Pregnancy Category C

Teratogenic effects: Travoprost was teratogenic in rats, at an intravenous (IV) dose up to 10 mcg/kg/day (250 times the maximal recommended human ocular dose (MRHOD)), evidenced by an increase in the incidence of skeletal malformations as well as external and visceral malformations, such as fused sternebrae, domed head and hydrocephaly. Travoprost was not teratogenic in rats at IV doses up to 3 mcg/kg/day (75 times the MRHOD), or in mice at subcutaneous doses up to 1 mcg/kg/day (25 times the MRHOD). Travoprost produced an increase in post-implantation losses and a decrease in fetal viability in rats at IV doses > 3 mcg/kg/day (75 times the MRHOD) and in mice at subcutaneous doses > 0.3 mcg/kg/day (7.5 times the MRHOD).

In the offspring of female rats that received travoprost subcutaneously from Day 7 of pregnancy to lactation Day 21 at doses of ≥ 0.12 mcg/kg/day (3 times the MRHOD), the incidence of postnatal mortality was increased, and neonatal body weight gain was decreased. Neonatal development was also affected, evidenced by delayed eye opening, pinna detachment and preputial separation, and by decreased motor activity.

There are no adequate and well-controlled studies of TRAVATAN Z[®] (travoprost ophthalmic solution) 0.004% administration in pregnant women. Because animal reproductive studies are not always predictive of human response, TRAVATAN Z[®] Solution should be administered during pregnancy only if the potential benefit justifies the potential risk to the fetus.

Nursing Mothers

A study in lactating rats demonstrated that radiolabeled travoprost and/or its metabolites were excreted in milk. It is not known whether this drug or its metabolites are excreted in human milk. Because many drugs are excreted in human milk, caution should be exercised when TRAVATAN Z[®] Solution is administered to a nursing woman.

Pediatric Use

Use in pediatric patients below the age of 16 years is not recommended because of potential safety concerns related to increased pigmentation following long-term chronic use.

Geriatric Use

No overall clinical differences in safety or effectiveness have been observed between elderly and other adult patients.

Hepatic and Renal Impairment

Travoprost ophthalmic solution 0.004% has been studied in patients with hepatic impairment and also in patients with renal impairment. No clinically relevant changes in hematology, blood chemistry, or urinalysis laboratory data were observed in these patients.

NONCLINICAL TOXICOLOGY

Carcinogenesis, Mutagenesis, Impairment of Fertility

Two-year carcinogenicity studies in mice and rats at subcutaneous doses of 10, 30, or 100 mcg/kg/day did not show any evidence of carcinogenic potential. However, at 100 mcg/kg/day, male rats were only treated for 82 weeks, and the maximum tolerated dose (MTD) was not reached in the mouse study. The high dose (100 mcg/kg) corresponds to exposure levels over 400 times the human exposure at the maximum recommended human ocular dose (MRHOD) of 0.04 mcg/kg, based on plasma active drug levels. Travoprost was not mutagenic in the Ames test, mouse micronucleus test or rat chromosome aberration assay.

A slight increase in the mutant frequency was observed in one of two mouse lymphoma assays in the presence of rat S-9 activation enzymes.

Travoprost did not affect mating or fertility indices in male or female rats at subcutaneous doses up to 10 mcg/kg/day [250 times the maximum recommended human ocular dose of 0.04 mcg/kg/day on a mcg/kg basis (MRHOD)]. At 10 mcg/kg/day, the mean number of corpora lutea was reduced, and the post-implantation losses were increased. These effects were not observed at 3 mcg/kg/day (75 times the MRHOD).

PATIENT COUNSELING INFORMATION

Potential for Pigmentation

Patients should be advised about the potential for increased brown pigmentation of the iris, which may be permanent. Patients should also be informed about the possibility of eyelid skin darkening, which may be reversible after discontinuation of TRAVATAN Z[®] (travoprost ophthalmic solution) 0.004%.

Potential for Eyelash Changes

Patients should also be informed of the possibility of eyelash and vellus hair changes in the treated eye during treatment with TRAVATAN Z[®] Solution. These changes may result in a disparity between eyes in length, thickness, pigmentation, number of eyelashes or vellus hairs, and/or direction of eyelash growth. Eyelash changes are usually reversible upon discontinuation of treatment.

Handling the Container

Patients should be instructed to avoid allowing the tip of the dispensing container to contact the eye, surrounding structures, fingers, or any other surface in order to avoid contamination of the solution by common bacteria known to cause ocular infections. Serious damage to the eye and subsequent loss of vision may result from using contaminated solutions.

When to Seek Physician Advice

Patients should also be advised that if they develop an intercurrent ocular condition (e.g., trauma or infection), have ocular surgery, or develop any ocular reactions, particularly conjunctivitis and eyelid reactions, they should immediately seek their physician's advice concerning the continued use of TRAVATAN Z[®] Solution.

Use with Contact Lenses

Contact lenses should be removed prior to instillation of TRAVATAN Z[®] Solution and may be reinserted 15 minutes following its administration.

Use with Other Ophthalmic Drugs

If more than one topical ophthalmic drug is being used, the drugs should be administered at least five (5) minutes between applications.

Rx Only

U.S. Patent Nos. 5,631,287; 5,889,052; 6,011,062; 6,235,781; 6,503,497; and 6,849,253

Alcon[®]

ALCON LABORATORIES, INC.
Fort Worth, Texas 76134 USA
© 2006, 2010, 2011, 2012 Novartis
10/15 US-TRZ-15-E-0278

gritty eyes and irritation.⁷ The most common symptom is blurred vision.⁸ However, studies show that about 40% of patients with SND also have meibomian gland dysfunction (MGD).^{9,10} Added to that, research has linked it to inflammation and inflammatory systemic conditions such as Crohn's disease.^{9,10}

- **Anterior blepharitis.** Patients with *Staphylococcal* and *Demodex* blepharitis can experience itching, irritation, dryness and blurred vision.

- **Contact lens discomfort.** Discomfort associated with contact lens wear typically results in symptoms of dry eye but dissipates when the contact lens is not worn. The cause of these dry eye symptoms could range from early DED and MGD to issues with the contact lens material, solution or compliance.

Other contact lens complications such as giant papillary conjunctivitis (GPC) can result in DED symptoms as well, ranging from decreased contact lens wearing time to foreign body sensation and irritated eyes.¹¹

- **Conjunctivitis.** Bacterial, viral and allergic conjunctivitis can all present with similar patient complaints as DED. For example, studies show that a large percentage of patients with DED have symptoms of itching, and patients with allergic conjunctivitis complain of dryness.¹² Differentiating conjunctivitis from dry eye disease requires an astute clinician, as the difference often involves a systemic finding such as allergic dermatitis or rhinitis, which occur in allergic conjunctivitis cases but rarely in DED.¹³

Recently, a colleague spent a day in the Advanced OSD clinic to enhance his knowledge of DED management. At the end of the day I apologized because, of the nine new patients that day, only one had a diagnosis of DED. He responded by

saying that learning more about these other potential causes was more valuable to his dry eye clinic than anything else he could have observed.

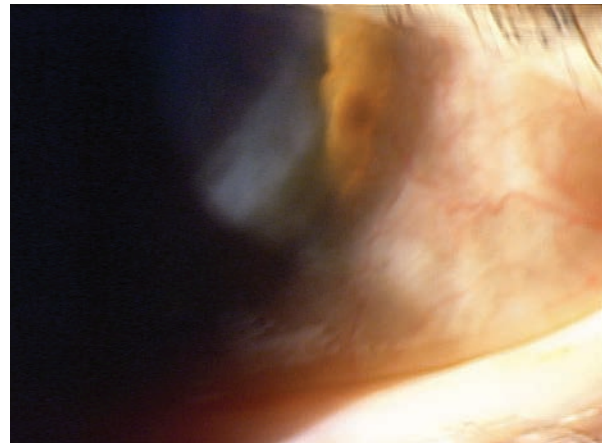
DED Testing

One of the only ways to determine if a patient has a condition other than DED even though symptoms point to dry eye disease is to use advanced testing—such as point-of-care diagnostics—skilled clinical evaluation and newer testing procedures such as meibomian gland expression and meibography.¹⁴

Clinicians should also include a cover test and binocular function testing in their dry eye work-up.¹⁵ Combining tests increases specificity and sensitivity for an accurate diagnosis. Using only traditional testing known to have very low sensitivity to dry eye, such as NaFl staining and Schirmer tear testing, could further mislead the clinician, resulting in months of futile therapy for a diagnosis that isn't truly there.^{1,16-18} ■

Dr. Karpecki is a consultant/advisor to: AMO, Alcon Labs, Allergan, Akorn, Bausch + Lomb/Valeant, BioTissue, Bruder Healthcare, Beaver-Visitec, Cambium Pharmaceuticals, Essilor, Eyemaginations, Eyes4Lives, Focus Laboratories, Glaukos, iCare USA, Ocusoft, Konan Medical, Optometric Medical Solutions, Reichert, Shire Pharmaceuticals, RySurg, Science Based Health, SightRisk, TearLab, TearScience, TLC Vision, Topcon and Vmax.

1. Sullivan BD, Crews LA, Messmer EM, et al. Correlations between commonly used objective signs and symptoms for the diagnosis of dry eye disease: clinical implications. *Acta*



A patient presenting with DED symptoms diagnosed with mild Salzmann's nodular degeneration.

- Ophthalmologica. 2014 Mar;92(2):161-6.
- Bron A, Tomlinson A, Foulks GN, et al. Rethinking dry eye disease: a perspective on clinical implications. *Ocul Surf.* 2014 Apr;12(2 Suppl):S1-31.
- Yamamoto Y, Yokoi N, Higashihara H, et al. Clinical characteristics of short tear film breakup time type dry eye. *Nippon Ganka Gakkai Zasshi.* 2012 Dec;116(12):1137.
- Acera A, Rocha G, Vecino E, et al. Inflammatory markers in the tears of patients with ocular surface disease. *Ophthalmic Res.* 2008 Oct;40(6):315-21.
- Acera A, Vecino E, Duran JA. Tear MMP-9 levels as a marker of ocular surface inflammation in conjunctivochalasis. *Invest Ophthalmol Vis Sci.* 2013 Dec 23;54(13):8285-91.
- Yamamoto Y, Yokoi N, Ogata M, et al. Correlation between recurrent subconjunctival hemorrhages and conjunctivochalasis by clinical profile and successful surgical outcome. *Eye Contact Lens.* 2015 Nov;41(6):367-72.
- Hurmeric V, Yoo SH, Karp CL, et al. In vivo morphologic characteristics of Salzmann nodular degeneration with ultra-high-resolution optical coherence tomography. *Am J Ophthalmol.* 2011 Feb;151(2):248-56.e2.
- Fario AA, Halperin GI, Sved N, et al. Salzmann's nodular corneal degeneration clinical characteristics and surgical outcomes. *Cornea.* 2006 Jan;25(1):11-5.
- Graue-Hernandez EO, Mannis MJ, Eliasieh K, et al. Salzmann nodular degeneration. *Cornea.* 2010 Mar;29(3):283-9.
- Roszkowska AM, Spinella R, Aragona P. Recurrence of Salzmann nodular degeneration of the cornea in a Crohn's disease patient. *Int Ophthalmol.* 2013 Apr;33(2):185-7.
- Forister JF, Forister EF, Yeung KK, et al. Prevalence of contact lens-related complications: UCLA contact lens study. *Eye Contact Lens.* Jul 2009;35(4):176-80.
- Hom MM, Nguyen AL, Bielory L. Allergic conjunctivitis and dry eye syndrome. *Ann Allergy Asthma Immunol.* 2012 Mar;108(3):163-6.
- Ortiz RA, Barnes KC. Genetics of allergic diseases. *Immunol Allergy Clin North Am.* 2015 Feb;35(1):19-44.
- Lemp MA, Bron AJ, Baudouin C. Tear osmolarity in the diagnosis and management of dry eye disease. *Am J Ophthalmol.* 2011 May;151(5):792-8.
- Rueff EM, King-Smith PE, Bailey MD. Can binocular vision disorders contribute to contact lens discomfort. *Optom Vis Sci.* 2015 Sep;92(9):214-21.
- Savini G, Prabhawat P, Kojima T, et al. The challenge of dry eye diagnosis. *Clinical Ophthalmology.* 2008;2(1):31-55.
- Schiffman RM, Christianson MD, Jacobsen G, et al. Reliability and validity of the Ocular Surface Disease Index. *Arch Ophthalmol.* 2000 May;118(5):615-21.
- Nichols KK, Nichols JJ, Mitchell GL. The lack of association between signs and symptoms in patients with dry eye disease. *Cornea.* 2004 Nov;23(8):762-70.



Sun is on the rise

A dedicated team focused solely on eye care professionals.
An innovative pipeline designed to improve the way you treat.
A shared passion for advancing the field of ophthalmics.

With our unique approach and concierge customer care, **Sun Ophthalmics** offers the promise of new beginnings in the ophthalmic landscape.

Discover a brighter eye care community at SunsOnTheRise.com.

Brightening the future of eye care





Turn on, Tune in, Drop Out

Should you abandon the standard post-cataract regimen of topical drops? Injections eliminate many problems, but there are a few limitations. **Edited by Paul C. Ajamian, OD**

Q I send patients out for cataract surgery every month and see all my own post-ops from day one on. Patient after patient comes in not only confused about their three drops, but angry over the price they had to pay for them. Isn't there a better way?

A “Every surgeon has their own eye drop regimen for cataract surgery,” says Paul Mitchell, OD, of Eye Care of Delaware. Most regimens consist of three different eye drops: an antibiotic, steroid and NSAID. The out-of-pocket costs can be as much as \$500, depending on an individual’s insurance, for surgery in both eyes, says Dr. Mitchell. Compliance is an issue, according to Dr. Mitchell. Often the three drops have different dosing schedules, and the pharmacy may switch to a generic that changes the dosing yet again. The tapering schedule—three drops at different rates over three weeks—can be daunting and confusing, he says.

Dropless Surgery

Some surgeons eliminate the pre- and post-op drop regimens by injecting a compounded mixture of the drugs into the vitreous during surgery, just after intraocular lens (IOL) placement, says Dr. Mitchell.

Two choices exist for the dropless procedure: Trimoxi (intravitreal triamcinolone/moxifloxacin, Imprimis), which contains a steroid and an antibiotic, and TrimoxiVanc, which adds a second antibiotic (vancomycin). The cost of Trimoxi, which is what most use, is around \$25. This medication is not covered

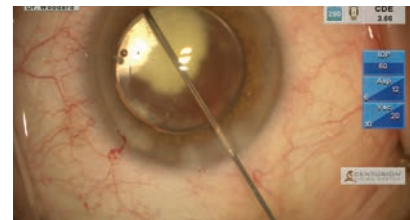
by insurance, nor can patients be billed for it. Despite the relatively low price per vial, the surgeon or surgery center must bear that cost, which can add up in a high volume practice—a likely reason why more surgeons aren’t using it.

The injection is performed off-label, since each of its components is approved for other uses. “Patients sign a separate consent for the injection. When given the choice between drops or dropless, they overwhelmingly choose dropless for convenience and cost,” says Dr. Mitchell. “Because the cocktail exists as a white suspension, the vitreous becomes cloudy; the patient may experience hazy vision with floaters,” says Dr. Mitchell. They usually clear within hours, though patients may continue to notice them for a few days, he says.

Contraindications

Glaucoma patients, steroid responders and patients allergic to any component of the injection are not good candidates for the dropless option, says Dr. Mitchell. Patients with small eyes—which can preclude injection—also may not be good candidates, he says. Further, “some surgeons will not do dropless with a toric IOL, because after injecting the medicine, the red reflex through the pupil turns white, making it difficult to see the IOL’s axis markings to ensure it’s on the correct axis,” says Dr. Mitchell.

The potential side effects include: a rise in IOP; blurred or hazy vision for several hours, which usually



During dropless cataract surgery, a drug mixture is injected into the vitreous, just after IOL placement.

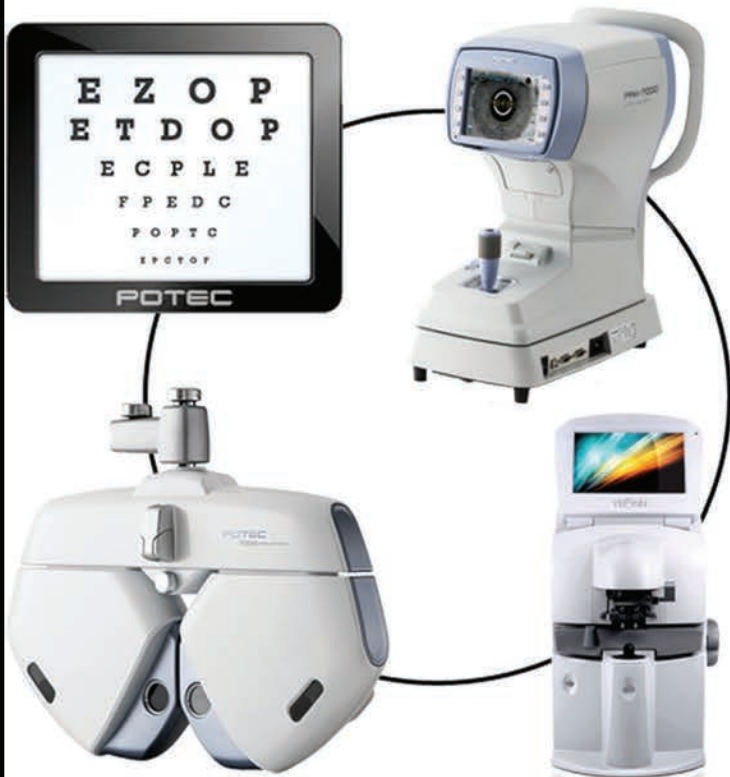clears by the next morning; floaters for two to five days; rebound post-op iritis requiring a rescue steroid eye drop, seen days to four weeks after surgery.

“Post-op exams are the same, regardless of which option—drop or dropless—the patients took,” says Dr. Mitchell. “At the one-day post op visit, I like to look in the inferior vitreous with a 90D lens to see how much medicine is in the eye. If little or no triamcinolone is seen, I start the topical steroid that day. If not enough medicine gets in the eye, then a post-op iritis will ensue.”

Another thing to look for is if some of the medicine has migrated into the anterior chamber. “If so, you may see the white triamcinolone on the posterior cornea or in the anterior chamber,” he says. Always make sure to monitor IOP for the first few months after surgery, he says. “A steroid response can occur in some patients, elevating IOP. This can last for three to four months as the steroid dissolves.”

The bottom line: patients save time, money and angst—post-op visits for the OD are made easier—a better experience for all involved. ■

Your Exam... Only Better!



- Increased efficiency
- Combat reductions in reimbursements
- Enhanced practice image
- EMR integration
- Eliminate back and shoulder pain
- Patient referrals



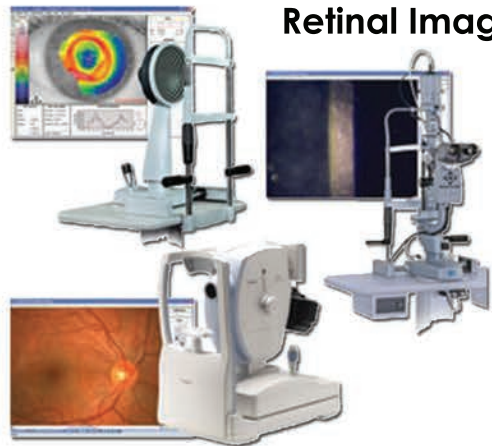
WWW.VOI2020.COM

800.447.7511

A Company with an Eye for Good Service

ReSeeVit

Anterior Segment Imaging
Corneal Wavefront Topography
Retinal Imaging



Additional Offers From Veatch

Exam Lane
Packages
Starting at
\$12,995



**2 CE
Credits**
(COPE Approved)

2015 EAST COAST OPTOMETRIC GLAUCOMA SYMPOSIUM

The annual East Coast Optometric Glaucoma Symposium (ECOGS) brings together preeminent leaders in glaucoma diagnosis and treatment to share their clinical knowledge and personal experiences with colleagues, along with the latest research and best clinical practices. Experts gathered last fall in Bethesda, Md., to discuss everything from what damages the optic nerve in glaucoma to challenges of diagnosis, critical measurements for risk assessment and updates in the treatment algorithm. The following summary of the live event offers highlights from selected presentations. We believe eye care professionals seeking positive patient outcomes in their clinical practices will benefit from this information.

– **Murray Fingeret, OD, and Robert N. Weinreb, MD, Meeting Co-Chairs**

Release Date: March 15, 2016

Expiration Date: March 31, 2017

Goal Statement: This update on glaucoma management will cover key risk factors and considerations for glaucoma diagnosis, assessment and management, along with the latest research and best practices relative to glaucoma therapy.

Faculty/Editorial Board: Derek Welsbie, MD, PhD; Murray Fingeret, OD; Leo Semes, OD; Michael Chaglasian, OD

Credit Statement: This course is COPE approved for 2 hours of CE credit. COPE ID is 48344-GL. Please check your state licensing board to see if this approval counts toward your CE requirement for relicensure.

Joint-Sponsorship Statement: This continuing education course is joint sponsored by the University of Alabama School of Optometry.

Disclosure Statement: **Dr. Chaglasian** is on the advisory boards of Alcon, Allergan and Carl Zeiss Meditec. **Dr. Fingeret** is a consultant to Alcon, Allergan, Carl Zeiss Meditec, Heidelberg Engineering, Topcon and Canon. He is on the advisory boards of Allergan, Alcon, Bausch + Lomb and Carl Zeiss Meditec. **Dr. Semes** is a consultant to Alcon, Allergan, Arctic Dx and Zeiss. He has stock ownership in HPO. **Dr. Welsbie** has no financial relationships to disclose.

Administered by
Review of Optometry®



*Approved

Supported by an unrestricted educational grant from

Alcon

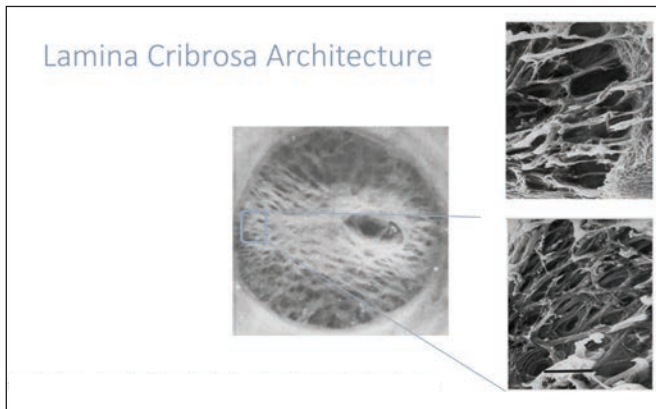
WHAT DAMAGES THE OPTIC NERVE IN GLAUCOMA?

DEREK S. WELSBIE, MD, PhD

Retinal ganglion cell (RGC) death defines a class of diseases called optic neuropathies, the most prevalent of which is glaucoma. The mechanism by which RGCs are injured, and subsequently die, in glaucoma is not perfectly understood, but research over the last 10 years has offered a great deal of insight.

OPTIC NERVE HEAD

It is clear that retinal ganglion cells first sustain injury at the optic nerve head and, more specifically, at the **lamina cribrosa**—the fenestrated connective tissue through which RGC axons exit the eye. RGCs near the center of the retina send axons to opposite poles of the optic nerve head (the site of injury), explaining the characteristic glaucomatous field defects that often respect the horizontal midline.



Scanning electron micrograph of a human lamina cribrosa shows the variation in microarchitecture.

Experimentally, this was confirmed using a primate model in the 1970s. Harry Quigley and Doug Anderson injected a radioactive tracer into the vitreous of primate subjects in order to label RGCs.¹ They showed that the tracer became concentrated at the optic nerve head, specifically at the lamina cribrosa, consistent with the idea that this is the initial site of injury. In 2007, Gareth Howell and Simon John at the Jackson Labs used an axon labeling technique to genetically confirm the hypothesis that RGCs are first injured at the lamina cribrosa, in a mouse model of pigmentary glaucoma.²

CONNECTIVE TISSUE

Since the optic nerve head and lamina cribrosa are key to the pathogenesis of glaucoma, researchers have tried to understand exactly how these structures change in response to glaucoma. Using non-human primates, Claude Burgoyne and J. Crawford Downs have used a technique called 3D histomorphometry to carefully measure the position of all substructures in the optic nerve head, including the lamina cribrosa, in response to experimental glaucoma.³ With this technique, the optic nerve head block is serially sectioned, stained and imaged in order to preserve 3D relationships. This work has revealed that the lamina cribrosa bows back posteriorly, while the peripheral lamina remodels to similarly move the insertion into the sclera posteriorly. These changes are partially responsible for the characteristic “cupping” seen in glaucoma patients.

Remodeling of the lamina in glaucoma might explain another feature seen clinically: the presence of disc hemorrhages. The

capillaries of the optic nerve head, at the level of the lamina, run inside the lamellar beams (as opposed to between the beams, as axons do). It is possible that remodeling of those lamellar beams might disrupt the vessels, leading to small hemorrhages. OCT imaging has shown that areas of the optic disc with more lamellar movement (and presumably remodeling) highly correlate with the development of disc hemorrhages.^{4,5}

AXONAL INJURY

How the remodeling of the lamina damages the axons of RGCs is less certain. Several non-exclusive hypotheses suggest that deformation of the lamina mechanically damages the axons, compromises blood flow to the axons, leads to toxic gene expression by neighboring cells (e.g., glia) and/or interferes with axonal transport. As well, rodent models of glaucoma offer evidence that immune cells may play a role.

An emerging idea is that energy supply/demand mismatch may be a key feature. The axon makes up nearly 90% of a retinal ganglion cell by surface area and about 85% by volume, placing a large energy demand on the cell. This is compounded by the fact that the energetically efficient saltatory conduction of action potentials starts distal to the lamina cribrosa. Finally, because capillaries travel within lamellar beams, astrocytes charged with nourishing RGCs do not have direct access to the capillaries, unlike all other regions of the brain. This high demand/low supply, exacerbated in the setting of glaucoma, could affect mitochondrial physiology. In experimental glaucoma, mitochondria localize (primarily or secondarily) to the lamina, and the Marsh-Armstrong laboratory showed that the optic nerve head is a key site of mitochondrial turnover (called mitophagy).⁶

Providing another clue is the fact that one of the few genes linked to Mendelian cases of glaucoma—*OPTN* (i.e., optineurin)—has been shown to be a key player in the process of mitophagy. A number of labs are now trying to understand the role of mitophagy in glaucoma pathophysiology.

Dr. Welsbie is assistant professor of ophthalmology at the Wilmer Eye Institute at The Johns Hopkins Hospital in Baltimore.

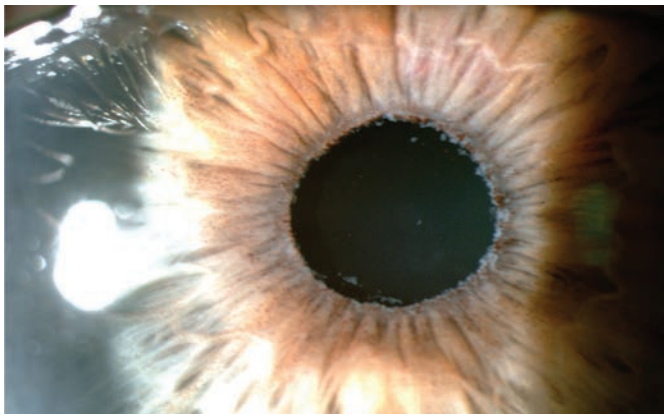
1. Quigley HA, Anderson DR. The dynamics and location of axonal transport blockade by acute intraocular pressure elevation in primate optic nerve. *Invest Ophthalmol Vis Sci.* 1976;15(8):606-16.
2. Howell GR, Libby RT, Jakobs TC, et al. Axons of retinal ganglion cells are insulted in the optic nerve early in DBA/2J glaucoma. *J Cell Biol.* 2007;179(7):1523-37.
3. Yang H, Williams G, Downs JC, et al. Posterior (outward) migration of the lamina cribrosa and early cupping in monkey experimental glaucoma. *Invest Ophthalmol Vis Sci.* 2011;9;52(10):7109-21.
4. Lee KM, Kim TW, Weinreb RN, et al. Anterior lamina cribrosa insertion in primary open-angle glaucoma patients and healthy subjects. *PLoS One.* 2014;9(12):e114935.
5. Lee EJ, Kim TW, Kim M, et al. Recent structural alteration of the peripheral lamina cribrosa near the location of disc hemorrhage in glaucoma. *Invest Ophthalmol Vis Sci.* 2014;55(4):2805-15.
6. Davis CH, Kim KY, Bushong EA, et al. Transcellular degradation of axonal mitochondria. *Proc Natl Acad Sci USA.* 2014;111(26):9633-8.

PSEUDOEXFOLIATION GLAUCOMA

MURRAY FINGERET, OD

Pseudoexfoliation (PXE) glaucoma is a secondary form of the disease associated with elevated intraocular pressure (IOP) and characterized by the presence of extracellular material in the anterior chamber angle, and on the iris and anterior lens capsule. PXE syndrome should be suspected if material can be seen in the anterior chamber but neither elevated IOP nor signs of glaucoma (e.g., optic nerve damage) are present, at least initially. In some individuals, over time the accumulated material will lead to IOP rise and development of glaucomatous damage.

PXE glaucoma is the most common cause of glaucoma throughout the world, and prevalence increases with age. PXE is both an ocular and systemic condition. There is a genetic basis and an in-

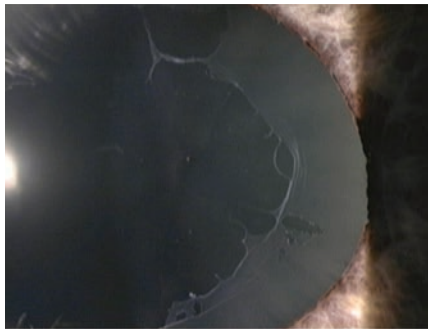


The pupil frill with exfoliative material is seen in an individual with pseudexfoliation glaucoma. Photos: Murray Fingeret, OD

crease in prevalence among individuals of Scandinavian descent, although the etiology is not clear. The condition has not been shown to occur in all races.

DIAGNOSIS

Diagnosis of PXE glaucoma is based on the classic finding of white deposits of exfoliated material



The lens is seen through a dilated pupil in a person with pseudoexfoliation glaucoma. The material is seen depositing on the lens, forming a bulls-eye appearance.

on the anterior lens surface, pupillary border and in the angle structures. A dilated exam is critical to diagnosis. In the absence of dilation, it's easy to overlook the material deposited on the lens. Look for a characteristic bull's-eye-type pattern: accumulations centrally and peripherally with a clear zone in the middle. This characteristic finding occurs as the 'windshield wiper' effect of iris movement throughout the day clears pigment.

Patients who have undergone cataract surgery may develop PXE later in life. To avoid missing diagnosis in these cases, clinicians should be aware that deposits of exfoliated material can be seen on the IOL, but the appearance may be more subtle in pseudophakic patients, appearing as more of a generalized 'glaze,' as the borders of separation are typically absent. This can lead to IOL dislocation, as the weight of the exfoliated material bears on and ruptures the lens zonules.

PRESSURE ELEVATION

Accumulation of the exfoliated material and pigment in the trabecular spaces, juxtacanalicular meshwork and beneath the inner endothelial lining of Schlemm's canal leads to obstruction of the drainage pathways and a rise in IOP. The PXE material is formed by many ocular structures—not just the lens—and deposition occurs in other parts of the eye as well.

CANDIDATES FOR THE CONDITION

Individuals with exfoliation and elevated IOP (i.e., PXE syndrome with ocular hypertension) are twice as likely to develop PXE glaucoma. Exfoliation glaucoma is more severe than primary open-angle glaucoma, and in terms of management, has a far more dif-

ficult course. Usually, when clinicians observe exfoliation syndrome with ocular hypertension (i.e., elevated IOP), they will treat to lower intraocular pressure.

Two-thirds of individuals at the time of presentation have exfoliation material in one eye, and about half will develop it in the second eye over the next 15 years. A conjunctival biopsy will often reveal material in the fellow eye that is nevertheless subclinical: There's no glaucoma, no elevated IOP and no signs of obvious material. Why only one eye is often affected remains a mystery.

Research using genetic mapping, conducted in Iceland and published several years ago, found an association with the *LOXL1* gene.¹ Retrospective analysis of a large managed care group's database, performed at the University of Michigan, looked at geographic and climatic risk factors associated with exfoliation syndrome.² Researchers found the majority of patients with exfoliation syndrome were in northern regions of the United States. Similar work by Louis Pasquale, MD, of Massachusetts Eye and Ear, found that lifelong residents of the middle or southern tiers of the U.S. geography were associated with a reduced risk compared with northern-tier regions.

MANAGEMENT

Clinicians should monitor PXE syndrome every six months. If they see elevated IOP with signs of PXE material, clinicians should heighten vigilance and consider initiating therapy to reduce IOP, even if the optic nerve appears healthy. Patients who develop glaucomatous optic nerve damage will require close monitoring and perhaps a more aggressive approach to management. Medical therapy alone may be suboptimal because the disease course is variable; in short, these patients can get worse quickly. Selective laser trabeculoplasty can bring about IOP lowering in these cases, but is not a panacea. In sum, PXE glaucoma—in all its forms—requires a more nuanced and nimble approach to management than those with primary open-angle glaucoma.

Dr. Fingeret is chief of the Optometry Section, Brooklyn/St. Albans Campus, Department of Veterans Administration New York Harbor Health Care System. He is also a clinical professor at the State University of New York, College of Optometry.

1. Thorleifsson G, Magnusson KP, Sulem P, et al. Common sequence variants in the *LOXL1* gene confer susceptibility to exfoliation glaucoma. *Science*. 2007;317(5843):1397-400.

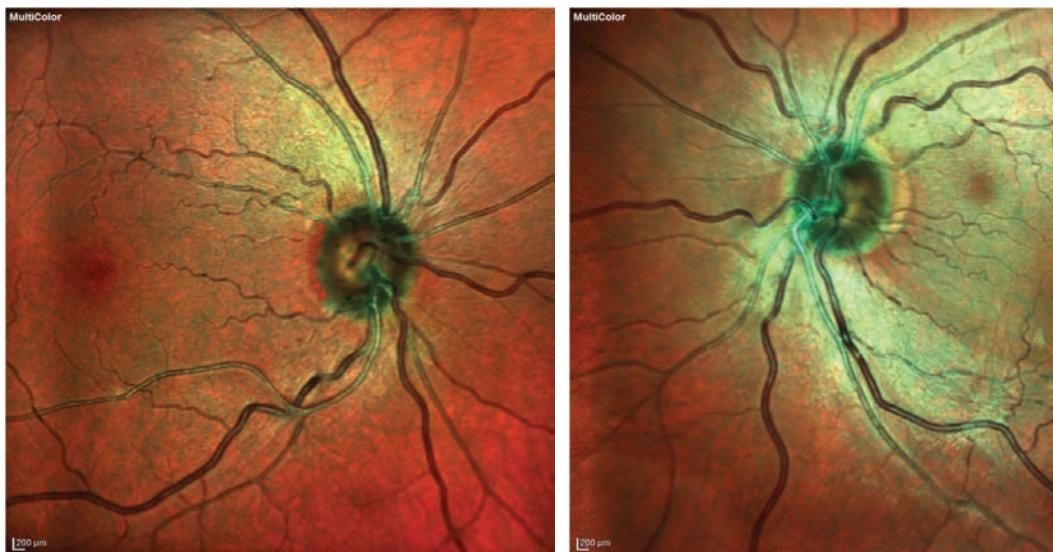2. Stein JD, Pasquale LR, Talwar N, et al. Geographic and climatic factors associated with exfoliation syndrome. *Arch Ophthalmol*. 2011;129(8):1053-60.

WHY IS GLAUCOMA SO EASY, AND YET SO HARD, TO DIAGNOSE?

MURRAY FINGERET, OD

Diagnosing glaucoma requires the clinician to make a series of decisions. Several focused questions about the diagnostic process will help clinicians make the ultimate decision of whether glaucoma is present. They include: which tests to perform, what a positive or negative result means and what criteria should be used for a positive test. Many would say, for instance, IOP greater than 21 or a cup-to-disc ratio greater than 0.6 are significant. Are those cutoffs appropriate? If a given test is positive, is that conclusive for the disease being present? And if disease is present, is it ocular hypertension, primary open-angle glaucoma or a secondary form of glaucoma? Is it mild, moderate or severe?

Performing every test can be costly and time-consuming, and yet clinicians need to use multiple tests to make the diagnosis. A positive test with a high sensitivity is not a guarantee that an individual has the suspected condition, particularly when specificity



The optic nerve and retinal nerve fiber layer is seen in a person with primary open angle glaucoma. The disc size is average; the ISNT rule is not obeyed in the left eye. Retinal nerve fiber layer loss is seen at 1, 4 and 7 o'clock in the left eye with zone beta parapapillary atrophy temporal also in the left eye. Photos/Images: Murray Fingeret, OD

When looking at OCT scans, for instance, some doctors rely too heavily on the red/yellow/green color coding generated by the normative database. In particular, quadrant and sector maps may be misleading because they produce area averages, so small loss may be overlooked. Instead, practitioners must look critically at the scans themselves. And retinal cameras, though valuable for documentation and serial analysis of change, can produce spurious results if, for instance, the light flash “bleaches out” colors and anatomical details. Several new retinal cameras take more nuanced images and can highlight retinal nerve fiber loss if present.

is not very high or the condition is rare. Multiple positive tests offer more conclusive evidence that disease may be present.

A paper I wrote with Drs. Weinreb, Susanna and Medeiros several years ago, “Five Rules to Evaluate the Optic Disc and Retinal Nerve Fiber Layer for Glaucoma,” explains the significance of five entities that should be evaluated during the clinical exam: (1) disc size, (2) rim integrity, (3) nerve fiber layer, (4) parapapillary atrophy and (5) disc hemorrhages.¹

Clearly, disc hemorrhages are significant. Though they may not be pathognomonic for the disease, when you see a hemorrhage—especially in the presence of other risk factors such as elevated IOP—it may indicate that the patient is in the process of converting from ocular hypertension to active glaucoma, or getting worse, if glaucoma is present.

Similarly, retinal nerve fiber layer dropout may not necessarily indicate glaucoma *if seen in isolation*; when paired with one or more other clinical signs, however, the clinician should suspect glaucoma.

Parapapillary atrophy is a weaker signal of disease, as this is present in many healthy individuals. Though it tends to remain stable in unaffected patients, the appearance of parapapillary atrophy can undergo change in someone who may be developing glaucoma. This highlights the need for vigilance in monitoring glaucoma suspects for change as a means of understanding their risk profile.

MIXED SIGNALS

Detecting subtle damage is often difficult, such as recognizing pathologic changes in a small optic disc or when retinal nerve fiber layer loss is present but the nerve looks healthy. Very often, clinicians are presented with overlap between normal and abnormal findings that they must differentiate and interpret.

Overreliance on technology can lead to misdiagnosis, or at least clinical confusion.

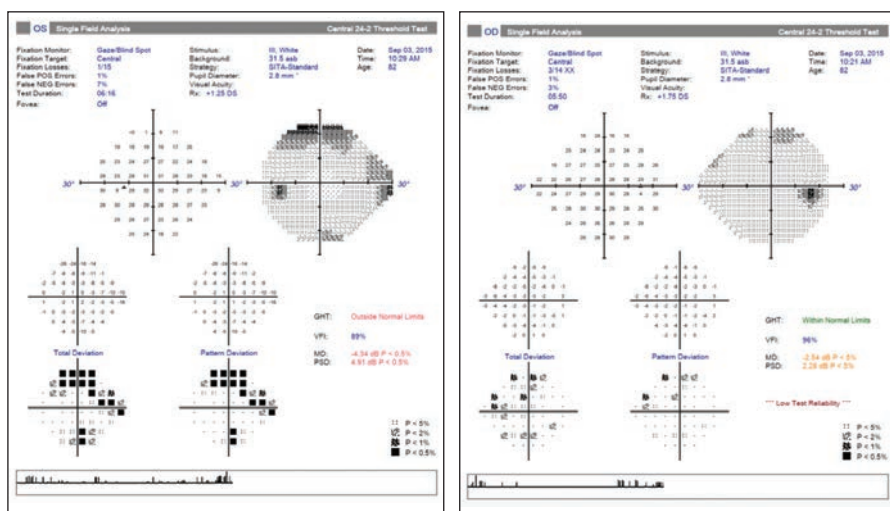
Once clinicians have a clear understanding of the structural data, they must correlate those findings with the functional vision assessment of automated perimetry.

VISUAL FIELD DEFECTS

Although perimetry has been a mainstay of glaucoma care for decades, doctors can be susceptible to patient resistance—and will perform visual field testing only intermittently. However, best practices dictate that clinicians do fields on at least a yearly basis for individuals with glaucoma.

That said, visual field testing is fraught with shortcomings. Early in the course of glaucoma, field defects may not be present. Also, artifacts can occur due to eyelid droop or trial lens defects that make recognizing genuine field loss difficult. Finally, patient inexperience with the test can generate misleading results.

Establish that at least two points are flagged, clustered in one hemifield, with one of the points at the $p < 0.5$ level. Compare



The 24-2 SITA Standard visual fields are seen for the patient in above photos with a superior arcuate scotoma noted OS. Several points are flagged superiorly in the OD that may be representative of an early defect, but repeat testing would be indicated.

the fields to the optic nerve photos and OCT findings to look for correspondence; also compare one eye to the fellow eye. Be alert for false positives: When clinicians see more points on the pattern deviation than the total deviation, they should suspect a “trigger-happy” patient due to the high number of false positives.

CONCLUSION

Remember that no single test or clinical finding is likely to be definitive, so clinicians must consider both structural and functional tests in their professional judgment. What’s surprising is how often the results don’t correlate. And that’s what makes diagnosing glaucoma such an art.

While none of the diagnostic devices are perfect, when used together along with the patient’s risk profile, including IOP, the status will come into focus. If the imaging test is positive but everything else is negative, repeat the test, look at the other findings and question the diagnosis; none of these tests has a perfect sensitivity and specificity. And not every case is a classic presentation.

1. Fingeret M, Medeiros FA, Susanna R, et al. Five rules to evaluate the optic disc and retinal nerve fiber layer for glaucoma. *Optometry*. 2005;76(11):661-8.

WHAT HYSTERESIS TEACHES CLINICIANS: BE FLEXIBLE

LEO SEMES, OD

Because so much of glaucoma management hinges on intraocular pressure readings—figuring heavily in diagnosis as the only modifiable risk factor that responds to medical or surgical intervention—clinicians need to be aware of tonometry’s potential shortcomings. However, the procedure has evolved greatly over its long history, providing greater clarity.

In recent years, clinicians have come to consider IOP findings in the context of **corneal hysteresis**, a biomechanical property relating to the eye’s ability to absorb and respond to pressure. It’s important to recognize, though, that central corneal thickness as a measure of stiffness is not the same as, or equivalent to, corneal hysteresis. Neither is scleral rigidity.

The FDA-cleared **Ocular Response Analyzer** (Reichert Technologies)—the only instrument capable of producing a hysteresis value—uses a puff of air and two detectors to measure not only intraocular pressure, but also the rebound of the cornea to applanation. The cornea’s reaction to that air puff determines its hysteresis value, reflecting the globe’s ability to dissipate energy. Good analogies are the shock absorbers in your car or a memory foam mattress. A similar device, the Corvis ST (Oculus), records a measurement known as the dynamic corneal response.

Both devices quantify the deformation of the cornea in response to applanation by air, which gives clinicians the ability to understand the viscoelastic properties of the cornea. In terms of the biomechanics of the eye and how stress-and-strain forces might relate to glaucoma, it provides an additional risk factor, a novel data point for patients developing glaucoma and potentially one more explanation for risk of progression.

MEASUREMENT

The corneal hysteresis measurement is a reflection of how the cornea specifically, and the globe as an extension of it, absorbs and dissipates energy. The Ocular Response Analyzer will also provide a **Goldmann-equivalent intraocular pressure** (IOPg) and **cornea-compensated intraocular pressure** (IOPcc) values.

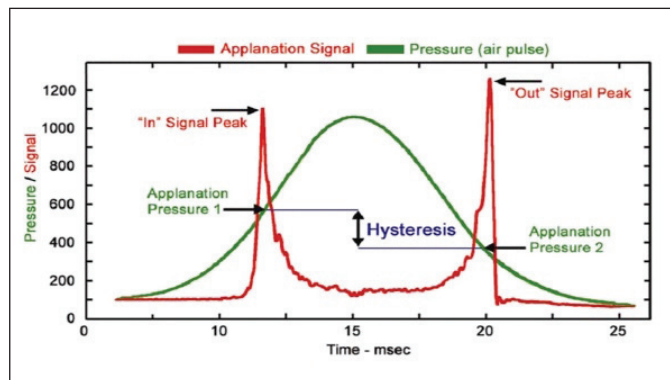
The readout shows two peaks: **deformation** in response to applanation and **rebound**. Think about what happens to a golf ball as it is compressed against the clubface and the ball’s subsequent rebound; hysteresis is the difference between those two measurements. That hysteresis reading varies among patients, and there can also be asymmetry between the eyes.

Just as with any instrument, it’s important to look at the waveform score—an index of the reliability of the measurement. There are those measurements with regard to intraocular pressure—the Goldmann equivalent and the cornea-compensated value—but the key value here is corneal hysteresis. Lower values of hysteresis appear to indicate a greater risk for glaucomatous damage as well as progression. Although clinicians should always be leery of over-reliance on cutoffs, a hysteresis value below 10mm Hg is something that would raise the level of suspicion.

RESEARCH FINDINGS

A study was published in 2006 based on measurement of a number of parameters (Goldmann tonometry, Ocular Response Analyzer tonometry, central corneal thickness, axial length measurements) and their relationship to corneal hysteresis.¹ Lower corneal hysteresis was very strongly associated with progression of glaucoma, as measured by visual field and central corneal thickness, baseline pressure and years with glaucoma, but the strongest association was corneal hysteresis.

Another study looked at patients with normal-tension glaucoma.² We have long been aware of the relationship of a thin central cornea to a greater degree of glaucomatous damage and a much higher likelihood of conversion from ocular hypertension to glaucoma (in concordance with RNFL parameters). Between these, the strongest association, again, was a low value for corneal hysteresis.



Schematic of corneal applanation and rebound curves indicating corneal hysteresis as the difference between the two applanation pressures as measured by the Ocular Response Analyzer. Note the response time (x-axis) and pressure rise and fall (y-axis). Image: Dave Taylor (Ametek).

An evaluation of visual fields in asymmetric glaucoma among a relatively small patient sample found an average corneal hysteresis value at 8.2, notably below that keystone value of 10mm Hg.³ Again, a very strong association—stronger than other parameters measured for asymmetry—was present in glaucoma progression.

Finally, in a retrospective study that looked for an indicator of progression, researchers evaluated subjects within their age cohort on parameters such as central corneal thickness, intraocular pressure and progression of visual fields.⁴ Again, using that cutoff point of 10mm Hg for corneal hysteresis, outcomes for patients with values below that showed a significantly greater likelihood of progression than outcomes in patients who had values above 10mm Hg.

Thinking about the spectrum of glaucoma risk and glaucomatous damage, it's clear there are pressure-independent factors, and corneal hysteresis may enable a better explanation of their role in the pathophysiology of the disease. This additional measure helps refine our ability to diagnose and manage glaucoma.

When presented with a confounding case, it could be illuminating to ask, "What's the corneal hysteresis value? What does it tell us about the patient's risk? What does that indicate for further testing and how we manage the patient?" The answers may pave the way for a more nuanced understanding of intraocular pressure and the ocular biomechanics at work in glaucoma.

REIMBURSEMENT

Hysteresis measurement is now a reimbursable procedure recognized by CMS with **CPT code 92145**. It relates specifically to corneal hysteresis determination by air impulse stimulation. The indication here is also important: for the diagnosis and monitoring of glaucoma.

Dr. Semes is a professor at the University of Alabama at Birmingham School of Optometry.

1. Congdon NG, Broman AT, Bandeen-Roche K, et al. Corneal thickness and age-related biomechanical properties of the cornea measured with the ocular response analyzer. *Invest Ophthalmol Vis Sci.* 2006;47(12):5337-47.
2. Park JH, Jun RM, Choi KR, et al. Significance of corneal biomechanical properties in patients with progressive normal-tension glaucoma. *Br J Ophthalmol.* 2015;99(6):746-51.
3. Anand A, De Moraes GV, Teng CC, et al. Corneal hysteresis and visual field asymmetry in open angle glaucoma. *Invest Ophthalmol Vis Sci.* 2010;51(12):6514-8.
4. Medeiros FA, Meira-Freitas D, Lisboa R, et al. Corneal hysteresis as a risk factor for glaucoma progression: a prospective longitudinal study. *Ophthalmology.* 2013;120(8):1533-40.

MANAGEMENT OF OCULAR HYPERTENSION

MICHAEL CHAGLASIAN, OD

It's nearly impossible to discuss glaucoma without also considering ocular hypertension, a closely related condition that is often quite confusing, and for which it is difficult to elucidate the correct management approach.

The definition of the Ocular Hypertension Treatment Study Group uses a patient with an intraocular pressure greater than 21mm Hg in one or both eyes as measured by applanation tonometry on two or more occasions.¹ Significantly, these patients will have an absence of glaucomatous defects on visual field testing (as determined by threshold perimetry) and a normal appearance of the optic disc and nerve fiber layer. To rule out secondary mechanisms and other causes of elevated intraocular pressure, **gonioscopy** is always performed, even if the angles look open on your Van Herick's lamp examination. Performing gonioscopy is critical to identify the amount of pigment in the trabecular meshwork and any other abnormalities in the angle. Clinicians often avoid it, but learning how to use a 4-mirror gonio prism is critical.

RISK ASSESSMENT

Knowing that many patients with ocular hypertension will never go on to develop disease, clinicians don't begin treatment without further evidence that it is warranted. The best approach is to do a risk assessment that starts with a review of the patient's ocular and systemic history, followed by a careful optic nerve head examination, visual field testing, tonometry and IOP reading, some form of OCT testing and a pachymetry measurement.

Age is a risk factor, particularly after 60, but it doesn't mean clinicians should ignore patients in their 40s and 50s with elevated eye pressure or with a strong family history.

While these trends or statistical pieces of information can be helpful, they may not necessarily apply to each patient. However, family history is critical, as first-degree relatives with glaucoma confer a much stronger risk for developing glaucoma. Other risk factors include elevated IOP, low perfusion pressure, very low hypotension or nocturnal IOP dipping.

OHTS STUDY AND RISK CALCULATOR

The **Ocular Hypertension Treatment Study (OHTS)**, published in 2002, evaluated the safety and efficacy of topical ocular hypertensive medication in delaying or preventing open-angle glaucoma in patients with high IOP.¹ The study identified the baseline demographic and clinical factors that predict development of glaucoma. Researchers followed approximately 1,600 subjects with a goal of lowering eye pressure to 20%. They monitored and did visual field testing frequently until a patient was identified with a reproducible abnormality consistent with glaucoma. Results showed that, at the 60-month mark, treatment reduced risk of developing glaucoma by about 50%—from 9.5% to 4.4%.¹

The following example estimates the 5-year risk of developing POAG using the continuous method:

- 55 year-old
- Whose IOPs are right eye: 22, 23, 21 and left eye: 28, 24, 26
- Whose CCTs are right eye: 530, 536, 530 and left eye: 550, 545, 549
- Whose VCDs are right eye: 0.40 and left eye: 0.40
- Whose PSDs (Humphrey) are right eye: 1.8, 2.6 and left eye: 2.2, 2.2

FACTORS						
Age	RIGHT EYE MEASUREMENTS			LEFT EYE MEASUREMENTS		
55	1 st	2 nd	3 rd	1 st	2 nd	3 rd
Untreated Intraocular Pressure (mm Hg)	22	23	21	28	24	26
Central Corneal Thickness (microns)	530	536	530	550	545	549
Vertical Cup to Disc Ratio by Contour	0.40			0.40		
Pattern Standard Deviation <input checked="" type="radio"/> Humphrey (dB) <input type="radio"/> Octopus loss variance (dB)	1.8	2.6		2.2	2.2	

Close Window 16.9% The patient's estimated 5-year risk (%) of developing early glaucoma in at least one eye.

The OHTS Risk Calculator has been validated to estimate the risk of developing glaucoma over a five-year period for individuals with ocular hypertension.⁴ A free version is available at <http://ohts.wustl.edu/risk/>. An iPhone version is also available for download. The example here shows a 16.9% risk, which is considered moderately high and is suggestive for initiating treatment.

The study reaffirmed the risk factors as well as vertical cup-to-disc ratio and pattern standard deviation—a value from the Humphrey Field Analyzer—and identified central cornea thickness. When incorporating pachymetry as a standard, researchers found that individuals with corneal thickness of less than 555µm and high IOP had a 36% risk of going on to develop glaucoma compared with those with low pressure and thick corneas, or even high pressure and thick corneas; and only a 6% risk of developing glaucoma over a five-year time period.² It's important to remember that risk for the patient can change over their lifetime.

The OHTS Group and others used data from the Ocular Hypertension Treatment Study to create an online **risk calculator**.³ The simple, flowchart/data-entry method has very strong predictive and validated ability to help clinicians identify patients who may develop glaucoma.⁴

TREATMENT

Generally, if the risk is less than 5% for the next five years, treatment is not necessary unless other significant risk factors are present; observation is often recommended. When the risk is between 5% and 15%, clinicians should consider treatment. If the percentage calculation is over 15%, consensus experts would suggest that treatment is warranted, although not necessarily on the initial first visit, as repeat testing and confirmation of elevated IOPs should be taken into consideration. The risk calculator does not include every risk factor for glaucoma, so clinicians should remember to include any extra risk factors they have identified.

Dr. Chaglasian is an associate professor at ICO and chief of staff at the Illinois Eye Institute. He is also a founding member and treasurer of the Optometric Glaucoma Society.

1. Gordon MO, Beiser JA, Brandt JD, et al. The Ocular Hypertension Treatment Study: baseline factors that predict the onset of primary open-angle glaucoma. *Arch Ophthalmol.* 2002;120(6):714-20; discussion 829-30.
2. Kass MA, Heuer DK, Higginbotham EJ, et al. The Ocular Hypertension Treatment Study: a randomized trial determines that topical ocular hypotensive medication delays or prevents the onset of primary open-angle glaucoma. *Arch Ophthalmol.* 2002;120(6):701-13; discussion 829-30.
3. Glaucoma 5-Year Risk Estimator. Available at: <http://ohts.wustl.edu/risk/calculator.html> (last accessed November 4, 2015).
4. Ocular Hypertension Treatment Study (OHTS) Group, European Glaucoma Prevention Study Group, Gordon MO, et al. Validated prediction model for the development of primary open-angle glaucoma in individuals with ocular hypertension. *Ophthalmology.* 2007;114(1):10-9.

AN UPDATED TREATMENT ALGORITHM LEO SEMES, OD

Because the greatest risk factor for developing glaucoma, and converting from ocular hypertension to glaucoma, is elevated intraocular pressure (IOP), lowering IOP is currently the only management strategy for glaucoma or ocular hypertension.

CONSIDERATIONS SURROUNDING INTRAOCULAR PRESSURE

- Elevated IOP is the greatest risk factor for developing glaucomatous damage
- Lowering IOP is the only means currently of managing glaucoma
- Topical drops to lower IOP are the preferred initial means to "treat" glaucoma

Issues in measuring IOP:

- How is baseline IOP established?
- What are the influences on an IOP measurement?
- What is the "sampling rate" of IOP?

Image: Leo Semes, OD

IOP INFLUENCES

With so many possible influences on IOP, any single measurement is perhaps meaningless. Added to that, poor sampling hampers our ability to properly track changes in IOP. For instance, more than 7.7 million seconds elapse over a three-month period between a patient's quarterly follow up, while the **Goldmann** tonometry IOP sampling is only over the course of several seconds; that's really poor sampling, and clinicians would benefit from something better.

One possible solution may be devices such as Eyemate (Implandata Ophthalmic Products GmbH), which can be implanted

during cataract surgery and may be able to provide continuous IOP monitoring in phakic patients in the future.¹ Unfortunately, comparing the device with Goldmann tonometry is incongruous. So, although continuous IOP monitoring looks promising, it may prove unrealistic.

REFERENCE POINTS

It's critical to establish a **baseline** using several measurements versus only the T_{max} (maximum IOP). Clinicians should take three baseline IOP measurements as a minimum, and as many as five, prior to consider initiating IOP-lowering therapy.

Clinicians should then consider the **target intraocular pressure**—the pressure at which the patient no longer shows progression. As a dynamic concept, IOP needs continuous reevaluation to document any trends, and to monitor whether or not a patient is compliant with treatment.

Clinicians can also evaluate the rate of progression with **visual fields**. Rapid progressors are at the highest risk for sight or vision loss, and would likely be the best candidates for aggressive monitoring.

SINGLE AGENT VS. COMBINATION THERAPY

When it comes to advanced therapy, **prostaglandin analogs** are considered the first-line choice for topical IOP reduction. For patients who fail on prostaglandin analogs for one reason or another, clinicians can consider using a different prostaglandin analog, switching to a different class of medication, or discussing surgical options for noncompliant patients. They should also consider other barriers to topical medication.

Should the clinician choose to use a single adjunctive agent, consensus guidelines suggest a **topical carbonic anhydrase inhibitor**. Other options may include the use of multiple drops and fixed combination drops. Clinicians should carefully evaluate the benefits and risks before deciding on the best treatment plan for each patient.

Using a combination drop as adjunctive to a prostaglandin analog when advancing therapy is often considered maximum medical therapy. Clinicians must also take into consideration whether or not to use a combination drop that has a beta-blocker. Beta-blockers may be contraindicated in patients with heart disease, high blood pressure, diabetes and high cholesterol. For many people, a combination drop without a beta-blocker that combines **brimonidine** and **brinzolamide** may work well.

GENERIC

To be FDA approved, ophthalmic generics must contain the same active ingredients as their brand name predecessors. For example, Xalatan (latanoprost 0.005%, Pfizer) is 99.995% something other than the active ingredient of latanoprost. These inactive ingredients may influence many aspects of the generic drug's efficacy, including bioavailability, penetration, buffers, preservatives, tonicity, drop size, bottle composition and pH. Some generics may not provide equivalent bioavailability, and clinicians must take this into account in terms of their management algorithm.

Cost is another significant factor related to generics. Pharmacies can often manipulate the average wholesale price (AWP) so that a generic may be more expensive to the consumer than a branded product. Whether the patient has pharmacy coverage, is on Medicare—specifically Medicare Part D—or is a private payer also adds a layer of complication when prescribing. Clinicians should also consider manufacturers' plans that allow a lowered cost for patients, other classes of drugs or modifying the patient's dosing per day to help alleviate any cost-related compliance issues.

PATIENT MEDICATION ADHERENCE

Generic latanoprost is a fairly recent development that had a surprising impact on patient adherence. Although the generic provides a lower-cost option, a recent study found that a considerable number of patients discontinued glaucoma drug use altogether when generic latanoprost became available.² Such behavior highlights the need for ongoing patient education on the importance of the medication and adhering to the recommended regimen.

1. Eyemate. Available at: <http://my-eyemate.com/en/> (last accessed November 4, 2015).
2. Stein JD, Shekhawat N, Talwar N, et al. Impact of the introduction of generic latanoprost on glaucoma medication adherence. *Ophthalmology*. 2015;122(4):738-47.

AN UPDATE ON GLAUCOMA SURGERY MICHAEL CHAGLASIAN, OD

It is important to stay up to date on ongoing advancements in glaucoma surgery to ensure proper patient education and referral. Here are some of the incisional glaucoma procedures available and where they stand in today's surgical management landscape.

TRADITIONAL PROCEDURES

A **trabeculectomy** with an anti-metabolite-like mitomycin-C remains a gold standard for many glaucoma surgeons and a preferred surgical procedure for patients with moderate to advanced or advancing disease. The outcomes can be quite excellent and long-lasting, with a significant reduction of topical medications for the patient. The procedure still requires bleb management because the filtration bleb is critical. However, researchers continue to search for another glaucoma drainage device or new stent implants due to the long-term complications from filtration blebs and leaking blebs from anti-metabolites.

The **Trabectome**, approved more than 10 years ago, uses an electrocautery device to remove a portion of the trabecular meshwork over the anterior chamber angle to have aqueous gain and easier access to the Schlemm's canal, and thus easier outflow. Some glaucoma surgeons prefer to use this in certain patients who are having cataract procedures in early glaucoma.

For patients with advanced or end-stage disease and complicated secondary glaucomas, drainage devices such as the **Baerveldt implant** (Abbott Medical Optics) or **Ahmed glaucoma valve** (New World Medical) can be placed underneath the conjunctiva, on top of the sclera and back around the equator, with a long silicone tube inserted into the anterior chamber.

The **Express shunt** (Alcon) is a stainless-steel shunt implanted into the anterior chamber angle. This is still a bleb-forming procedure, although a surgical iridectomy is not performed as is done with a traditional trabeculectomy. It is a relatively easy procedure, and has been adopted by many non-glaucoma surgeons and comprehensive ophthalmologists.

MIGS

Several **minimally invasive glaucoma surgery (MIGS)** options have been FDA approved, and a host of other surgical treatment options and devices are under clinical investigation awaiting approval pending submission to the FDA. The **iStent Trabecular Micro-Bypass** (Glaukos)—cleared by the FDA in 2012—is a small stent implanted through the trabecular meshwork and into Schlemm's canal. The key to success with this procedure is getting the aqueous through the trabecular meshwork and Schlemm's

canal and then into the collector channels draining out of the eye. The iStent provides modest IOP reduction, with 1mm to 3mm additional IOP reduction in addition to the cataract procedure with which it is always performed.¹ Clinicians in the United States are only allowed to implant one of these iStents per eye.

Although years away from identifying outcomes and benefits, Glaukos is investigating the **iStent inject** to put into the anterior chamber angle and through the meshwork into Schlemm's canal. This inject device goes straight through, avoiding the angling the surgeon must do with the **iStent Trabecular**. Glaukos is also working on a supraciliary device called the **iStent supra**, designed to get into the aqueous humor, perhaps into another location in the supraciliary space, for better benefit of IOP reduction without bleb formation and lower complications.

The **CyPass Micro-Stent** (Transcend Medical) is a supraciliary procedure implanted across the anterior chamber angle directing aqueous humor into the supraciliary space. It is typically combined with a cataract procedure. Preliminary research indicates outcomes are somewhat favorable, as in the case of one recent publication that documents 65 subjects with the CyPass in cataract removal.²

The **Hydrus** (Ivantis) intracanalicular stent is used to expand and open up the approach into Schlemm's canal via the trabecular meshwork. It is a microinvasive, non-bleb-forming procedure easily done in conjunction with phacoemulsification and cataract extraction. One benefit of this procedure is completing two procedures at once and reducing medication burden on patients.

The **Xen Gel Stent** (Allergan) is a gelatin material injected and delivered across the anterior chamber angle to direct aqueous humor outflow into the subconjunctival space, similar to a bleb-forming procedure. Outcomes in Europe have been quite favorable.^{3,4,5}

1. Le K, Saheb H. iStent trabecular micro-bypass stent for open-angle glaucoma. *Clin Ophthalmol*. 2014;8:1937-45.
2. Craven R, García-Feijóo J, Rau M, et al. Safety and efficacy of stand-alone CyPass Micro-Stent implantation in patients refractory to topical glaucoma therapy: 1 year results. Paper presented at the Association for Research in Vision and Ophthalmology Annual Meeting, May 4-8, 2014; Orlando, FL.
3. Reitsamer R. Early results of a minimally-invasive, ab-interno gelatin stent in combination with a preoperative mitomycin C injection for the treatment of glaucoma. Poster session presented at XXXII Congress of the ESCRS, September 13-17, 2014; London.
4. Rekas M, Lewczuk K, Jablonska J, et al. Two year follow-up data with a soft and permanent, minimally-invasive ab-interno subconjunctival implant in open-angle glaucoma subjects. Poster session presented at XXXII Congress of the ESCRS, September 13-17, 2014; London.
5. Kersten-Gomez I, Dick H. First results of the innovative minimal-invasive glaucoma surgery technique: the AqueSys Aquecentesis procedure. Poster session presented at XXX Congress of the ESCRS, October 8-12, 2012; Milan.

GLAUCOMA THERAPY UPDATE MURRAY FINGERET, OD

A series of drug classes from the **alpha agonists** to the **beta adrenergic antagonists**, **prostaglandin analogs** and **parasympathomimetics** are used to treat individuals with glaucoma.

Although there have been recent changes in the glaucoma drug landscape, many new drugs are reformulations of already approved medications, and some are fixed-dose combinations. Additionally, older drugs are in new places. For example, Akorn purchased the Merck line of drugs: Cosopt preservative free and Zioptan, a prostaglandin. Several other generics have come out recently, and one waiting for approval is a preservative-free version of **latanoprost** (Sun Pharma). Approved generic versions of **travoprost** and **bimatoprost 0.03%** are now available. Allergan shifted from the 0.03% to the 0.01% concentration several years ago, and 0.01% is prescribed as Lumigan.

ON THE HORIZON

Several new drugs are in the pipeline. Bausch + Lomb is working on a latanoprost-butenediol mononitrate medication. It appears to reduce IOP by working on both uveoscleral and trabecular meshwork outflow. A randomized, controlled comparison of latanoprost bunod and latanoprost in the treatment of ocular hypertension showed the study drug lowered IOP approximately 9mm.¹ The drug is with the FDA, waiting for approval.²

Another class of drugs is **Rho kinase (ROCK) inhibitors**. Aerie Pharmaceuticals' Rhopressa, in clinical trials, lowers IOP by enhancing outflow through the trabecular meshwork and inhibiting aqueous production with the norepinephrine transport inhibitor. Research shows the drug was less effective than latanoprost by approximately 1mm in patients with IOP between 22 and 35. The major safety side effect was ocular hyperemia. However, the company was allowed to reanalyze its study results, and found that, for individuals whose pressures are 21 and below, the drug had a far better IOP-reducing response than for patients whose pressures were higher.³

Another drug around the corner is **Roclatan** (Aerie Pharmaceuticals), which includes the Rhopressa molecule in addition to latanoprost.⁴ Aerie has started Phase III trials with this drug, which should be available in the next 18 months.

OTHER STRATEGIES

A host of companies are looking to new delivery systems. Drug-eluting **punctal plugs**, in clinical trials for years, pose the problem of keeping the plug in place and getting the drug to work for 30 days or more. Newer, modified punctal plugs will soon be available, such as the Mati system for sustained delivery. Ocular Therapeutics has been working on a travoprost punctal plug as well. Allergan has been working on Bimatoprost Sustained Release, which would last for four to six months.

1. Bausch + Lomb. (2014). Bausch + Lomb and Nicox's Glaucoma Candidate VESNEO® (latanoprostene bunod) Meets Primary Endpoint in Phase 3 Studies. [Press release]. Retrieved from <http://www.prnewswire.com/news-releases/bausch--lomb-and-nicoxs-glaucoma-candidate-vesneo-latanoprostene-bunod-meets-primary-endpoint-in-phase-3-studies-277033241.html>

2. Bausch + Lomb. (2015). Bausch + Lomb and Nicox Announce FDA Acceptance of New Drug Application for Novel Glaucoma Candidate VESNEO™ (latanoprostene bunod). [Press release]. Retrieved from <http://ir.valeant.com/investor-relations/news-releases/news-release-details/2015/Bausch--Lomb-and-Nicox-Announce-FDA-Acceptance-of-New-Drug-Application-for-Novel-Glaucoma-Candidate-VESNEO-latanoprostene-bunod/default.aspx>

3. Aerie Pharmaceuticals. (2015). Aerie Pharmaceuticals Reports Positive Rhopressa™ Phase 3 Efficacy Results. [Press release]. Retrieved from <http://investors.aeriepharma.com/releasedetail.cfm?releaseid=931967>

4. Bacharach J, Dubiner HB, Levy B, et al. Double-masked, randomized, dose-response study of AR-13324 versus latanoprost in patients with elevated intraocular pressure. *Ophthalmology*. 2015;122(2):302-7.

This enduring activity may contain discussion of published and/or investigational uses of agents and/or devices that are not indicated by the FDA. Off-label use of a medication or a biological is defined as use for an indication, or in a manner for which FDA approval has not yet been obtained and which is therefore not included on the FDA-approved label or product packaging. Please refer to the official prescribing information for each product for discussion of approved indications, contraindications and warnings. Practitioners should critically assess the information herein and are encouraged to consult appropriate resources for any product or device mentioned in this program.

The educational content of this activity has been peer reviewed and validated to ensure that it is a fair and balanced representation of the topic based on the best available evidence.

CE TEST FOR EAST COAST OPTOMETRIC GLAUCOMA SYMPOSIUM 2015

To obtain two hours of continuing education credit, complete the exam by recording the best answer to each self-assessment question online at: http://www.reviewofoptometry.com/continuing_education/. Or, mail the Examination Answer Sheet on the next page to: Optometric CE, P.O. Box 488, Canal Street Station, New York, NY 10013. A minimum score of 70% is required to obtain a certification of completion. There is no fee for this course.

1. In which part of the eye/orbit is the retinal ganglion cell first damaged in glaucoma?

- a. Macula
- b. Lamina cribrosa
- c. Retinal nerve fiber layer
- d. Retrobulbar optic nerve

2. The axon makes up nearly what percent of a retinal ganglion cell by surface area?

- a. 5%
- b. 25%
- c. 50%
- d. 90%

3. Which gene has been implicated in controlling mitochondrial turnover and some rare cases of glaucoma?

- a. MYOC
- b. CYP1B1
- c. OPTN
- d. LOXL1

4. The following is true about pseudoexfoliation (PXE) glaucoma:

- a. It is a secondary form of glaucoma

- b. It is associated with elevated IOP
- c. It is characterized by presence of extracellular material in the anterior chamber angle, and on the iris and anterior lens capsule
- d. All of the above

5. A PXE diagnosis may be missed because:

- a. The clinician does not dilate the eye
- b. The clinician misses the exfoliated material deposits on the anterior lens capsule
- c. In a pseudophakic individual, the exfoliated material appears as a glaze without borders of separation between the clear zone and zone of the material
- d. All of the above

6. Exfoliation glaucoma is considered more severe than primary open-angle glaucoma due to which factor?

- a. Lack of clinician understanding
- b. Management
- c. Slow progression
- d. Lack of treatment options

7. Evidence has shown that many people who have exfoliation have which gene?

- a. *OPN1MW*
- b. *MTND1*
- c. *ELOVL4*
- d. *LOXL1*

8. In "Five Rules to Evaluate the Optic Disc and Nerve Fiber Layer for Glaucoma" what is the first entity to be evaluated during the clinical exam?

- a. Disc size
- b. Nerve fiber layer

- c. Rim
- d. Parapapillary atrophy

9. What strategy can be used to analyze for optic nerve damage?

- a. Establish that at least two points are flagged, clustered in one hemifield, with one of the points at the p<0.5 level
- b. Compare the visual fields to the optic nerve photos and OCT RNFL scan findings to look for correspondence
- c. Compare one eye to the fellow eye
- d. All of the above

10. What makes diagnosing glaucoma an art?

- a. No single test or clinical finding is likely to be definitive
- b. Clinicians must consider both structural and functional tests
- c. Often, test results don't correlate
- d. All of the above

11. What is true about corneal hysteresis?

- a. It is a biomechanical property relating to the eye's ability to absorb and respond to pressure
- b. It is equivalent central corneal thickness
- c. It is equivalent to scleral rigidity
- d. Goldmann tonometry accounts for it in IOP findings

12. What is the strongest predictor of glaucomatous damage and progression?

- a. High corneal hysteresis
- b. Low corneal hysteresis
- c. Thin central cornea
- d. Thick central cornea

13. The CMS CPT code for corneal hysteresis is:

- a. 92145



Is Technology Replacing Us?

Diagnostic tools are changing patient care—but they come with significant practice management dos and don'ts. **By John Rumpakis, OD, MBA, Clinical Coding Editor**

One of the most significant shifts in diagnostic skills and techniques—this issue's focus—is the fact that many of the diagnostic skills we employ today depend on not just clinical techniques, but on technology.

Most ophthalmic technology developed within the last decade is used for special ophthalmic testing; subsequently, the CPT established a proper definition and foundation for them, and we must follow specific rules when performing, recording and coding for them. Special ophthalmic tests are contained in a separate section of the CPT, with the following preamble:¹

- “Describes services in which a special evaluation of the part of the visual system is made, which goes beyond the services included under general ophthalmological services or in which special treatment is given.
- Special ophthalmological services may be reported in addition to the general ophthalmological service or evaluation and management services.”

Any test defined as a separate and distinct procedure by virtue of having its own CPT code is not part of an office visit, whether it's a 920XX or 992XX code. They can be ordered and performed on the same date of service as the office visit, as long as they are performed in accordance with CMS' National Correct Coding Initiative Edits and meet all requirements specific to your geographic location for medical necessity.

Most audit failures for special ophthalmic procedures are generated by not providing adequate or appropriate medical necessity for performing the test in the medical record and simply testing because you want to do the test or are testing to provide a baseline of normalcy.

Getting the Codes Right

Special ophthalmic codes are composed of two distinct components: the professional and technical. If you are performing both the technical and professional component in your practice, you will not separate the code into individual components, but will report the code in its entirety. The two modifiers that separate a code are:

- **-26 Professional Component.**

Use this modifier when the physician component is reported separately.²

- **-TC Technical Component.**

This includes the equipment and technician performing the test.² Billing for staff time and the test is improper and would raise a red flag.

When ordering special ophthalmic tests, in order to meet the coding requirements, you must meet the medical necessity for the tests. You cannot perform a test, code it, bill for it and get paid just because you want to. It has to be necessary to do so, and you must demonstrate in the medical record that it had a role in managing the patient outcome.

Screening vs. Ordered Tests

Many of the new technologies today are used routinely on patients as screening tests. However, this prac-

tice is not always appropriate. With routine fundus imaging, for example, many are inappropriately using a screening image as a substitute for dilating the patient. I am not aware of any circumstance where a routine retina screening image is a legal substitute for dilating the patient.

If you are performing screening tests on patients, the appropriate code to use is S9986 (not a medically necessary service) and you must inform patients that the test is not medically necessary. They should also understand they are financially responsible for the test in all circumstances and that the test should be performed before they see you.

Watch Your Back

With the recent release of the Comparative Billing Reports in October 2015 and the implementation of ICD-10, it is much easier for carriers to analyze your practice patterns. Frequency of testing and correlations with highly specific ICD-10 diagnoses help carriers flag individuals who are causing potential waste and abuse, or worse yet: fraud. Technology is a wonderful tool and can certainly add to our diagnostic and clinical skills—use it appropriately and it's great for both patient and practice; use it to replace rather than augment your clinical skills and you may find yourself in a more challenging situation. ■

Send questions and comments to ROcodingconnection@gmail.com.

1. American Medical Association. CPT Professional Edition. American Medical; 2016:591.
2. American Medical Association. CPT Professional Edition. American Medical; 2016:Appendix A.



Built in purifying filter

Preservative free multi-dose bottle

Over 240 drops



Now there's a clear choice for **preservative free dry eye relief.**



Introducing Clear Eyes® Pure Relief™, a revolutionary first line therapy for your patients:

- Unique glycerin formula with **hyaluronic acid** for advanced comfort
- 90 day open bottle stability
- Low actuation force with 1 drop control
- Up to 12 hours of soothing comfort
- Available over-the-counter

For more information visit www.cleareyes.com/professionals.

OCT'S ROLE IN AN OPTOMETRIC PRACTICE

Knowing what you can—and can't—do with this imaging technology helps you provide the best care to patients with common ocular conditions.

By Lee Vien, OD, and David Yang, OD

Clinical applications for optical coherence tomography (OCT) have expanded exponentially since its commercial introduction approximately 15 years ago. OCT measurements are increasingly used as clinical endpoints and for monitoring various ocular disorders. Numerous clinical studies, including large, multi-centered, prospective clinical trials, are employing OCT findings as study endpoints.¹⁻²

Clinicians are now using OCT in clinical practice for both anterior and posterior segment pathologies, as it provides valuable data that can aid in the detection of ocular pathologies, as well as track progression of the condition and the response to treatment. For example, OCT can help detect optic neuropathies with retinal nerve fiber layer (RNFL) loss, such as in glaucomatous damage. The instrument can also be used to identify disc edema and even buried disc drusen. Analysis of retinal thickness over the macula and posterior pole

can help detect retinal edema or atrophy. The retinal pigment epithelium (RPE) and choroid can also be better visualized with new imaging modalities such as enhanced-depth imaging (EDI). Anterior segment OCT can provide further insight into anterior chamber depth, angle anatomy and corneal pathologies.

OCT is an important diagnostic tool, yet is currently not considered the standard of care for evaluating the retina and is not required to diagnose glaucoma. There is also no publication in peer-reviewed literature that has definitively proven that OCT can serve as a surrogate for functional vision tests such as visual acuity and visual fields. However, large, multi-centered clinical studies have used OCT in the assessment of macular thickness, and there is extensive literature demonstrating that RNFL and ganglion cell analyses are valuable in the diagnosis and management of glaucoma.

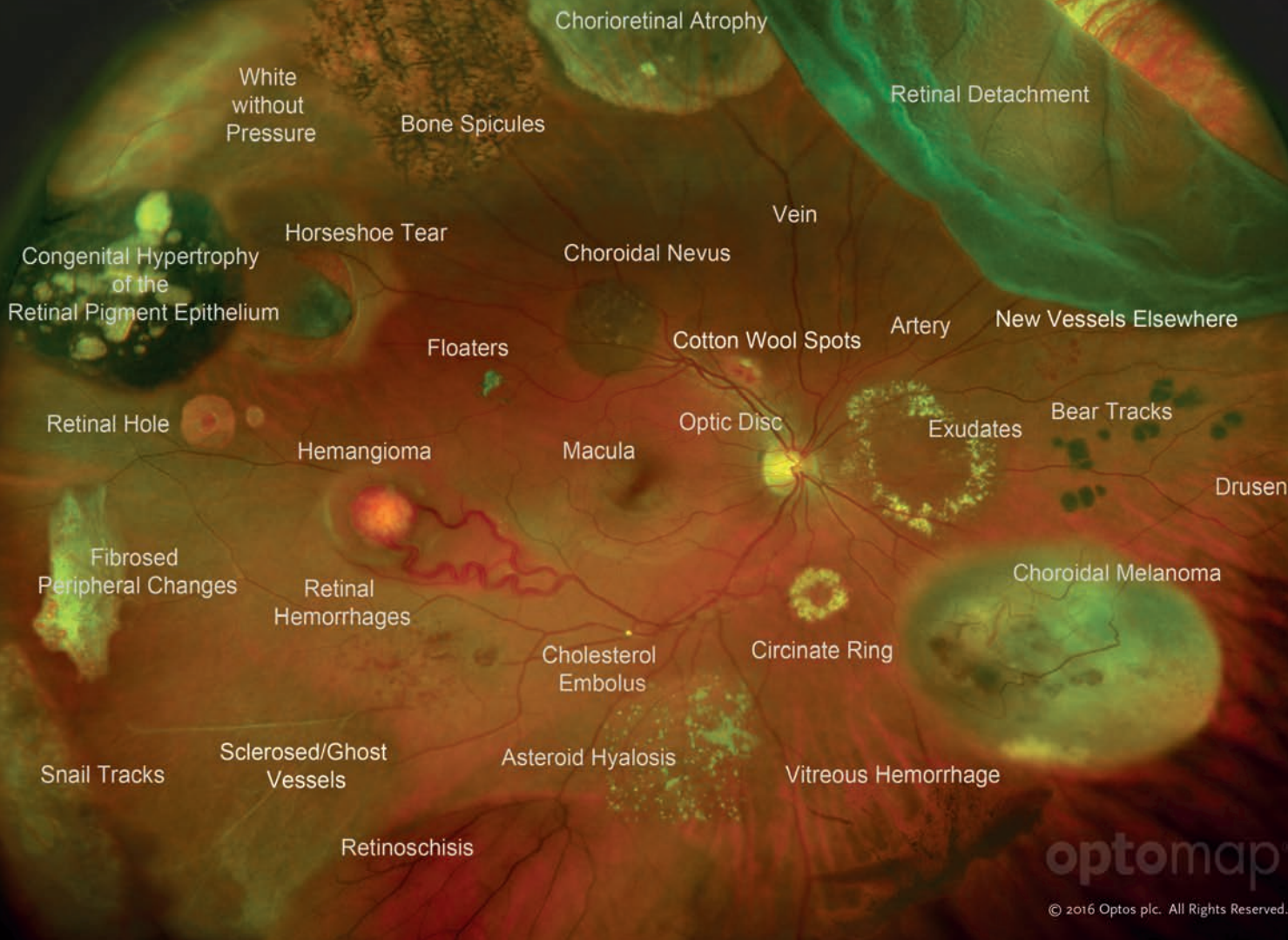
Without any specific guidelines, clinicians vary on the use of OCT

within their practice. The underuse of the instrument can lead to misdiagnosis of visually threatening conditions, while overuse can result in a financial burden to the health care system. This article discusses the role of OCT in clinical practice and looks at the literature for evidence to support its value and limitations. Common ocular pathologies such as age-related macular degeneration (AMD), diabetic macular edema (DME) and glaucoma will be discussed as examples of OCT's use in clinical practice.

Age-related Macular Degeneration

An estimated 80% of AMD patients have non-neovascular, or "dry," AMD. The remaining 20% have neovascular, or "wet," AMD, which accounts for nearly 90% of the severe central visual acuity loss associated with AMD.³⁻⁵ Early detection of neovascular AMD is crucial to prevent permanent vision loss secondary to subretinal fibrosis.⁶ Previous clinical

PUT OPTOMAP IN YOUR DIAGNOSTIC TOOLBOX



© 2016 Optos plc. All Rights Reserved.

See More. Discover More.™

- **Only optomap®** provides up to a 200° view of the retina in a single capture
- **The only** ultra-widefield, ultra-high definition color, autofluorescence, red-free, retinal imaging device
- Simultaneous evaluation of the peripheral and central retina
- Clinically supported by 300+ peer reviewed studies

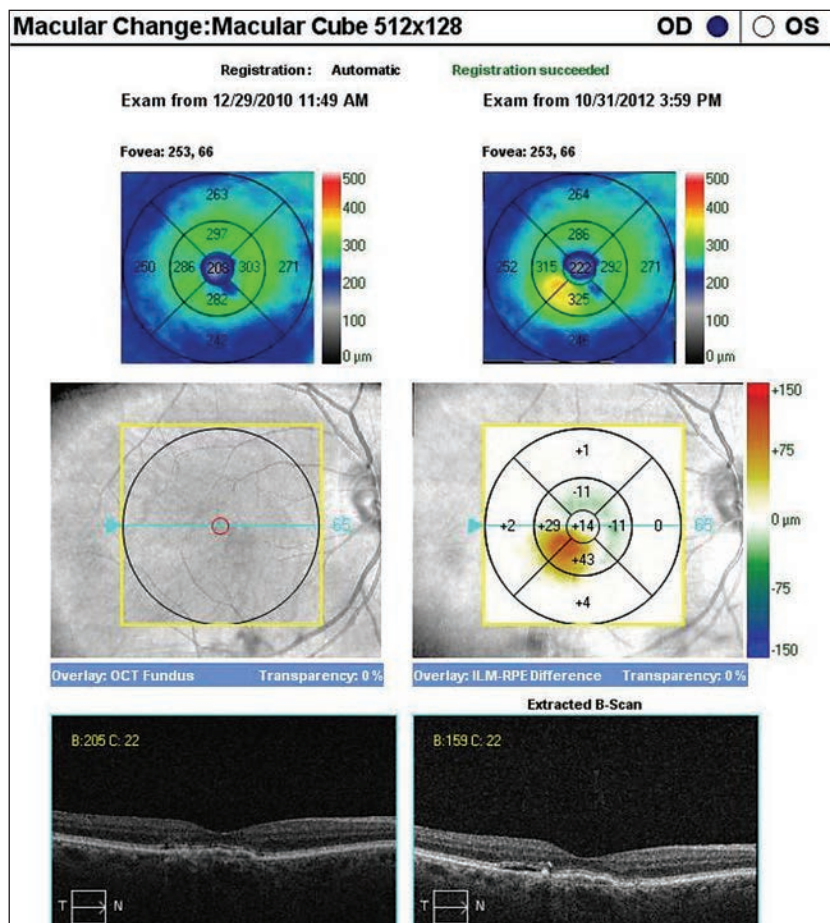
Contact us today **800-854-3039**
or email **BDS@optos.com**

Interested in adding ultra-widefield and ultra-widefield *af* capabilities to your practice?

Connect with us at Vision Expo East!

- **Visit our Booth # MS6848**
- **Attend Course MS33:**
EMERGING UTILITY OF ULTRA-WIDEFIELD IMAGING IN CLINICAL PRACTICE
Rishi Singh, MD - Staff Physician, Cole Eye Institute
April 16, 2016 1:00 - 2:00 pm
Medical and Scientific Theater

 **optos®**
Building *The* Retina Company



OCT in AMD Management

Neovascular AMD

- Detects early CNV in neovascular AMD to prevent permanent vision loss
- Provides objective assessment and quantifies the amount and location of retinal thickening
- Tracks thickness changes and response to treatment, especially for anti-VEGF therapy
- Helps guide when further treatment (anti-VEGF) is necessary

Non-neovascular AMD

- Identifies degenerative changes in non-neovascular AMD
- Tracks drusen enlargement or reabsorption
- May predict areas of progressive chorioretinal atrophy

Limitations

- TD-OCT should not replace the reference standard of FA
- More information is needed to determine the role of SD-OCT

SD-OCT macular change analysis demonstrating the development of a CNV in a patient with AMD over a period of 22 months.

studies emphasize the importance of fluorescein angiography (FA) patterns in neovascular AMD to guide appropriate treatment.^{7,8} Specifically, the ideal treatment choice was dictated by differentiating between choroidal neovascular (CNV) membranes that exhibited classic vs. occult appearance as the type of membrane.^{7,8} However, now that anti-vascular endothelial growth factor (VEGF) agents are preferred for treating patients with all types of neovascular AMD, the CNV lesion type is no longer important.⁹⁻¹⁰

The detection of subtle subretinal fluid in early stages of choroidal neovascularization from neovascular AMD can be difficult to identify on biomicroscopy; however, OCT has proven to be valuable in diag-

nosing and managing neovascular AMD, as choroidal neovascularization is visible on OCT.^{1,11-13} The instrument can identify areas of retinal thickening and track thickness changes. Automated change analysis allows clinicians to compare scans to detect subtle retinal thickening that may have been missed on clinical examination. In one study, fluid detected on OCT, along with the presence of leakage on FA, was used to define active CNV.¹ Foveal thickness determined by the OCT was also a secondary outcome and was used to guide when retreatment was indicated.¹

The widespread use of OCT has minimized the role FA plays in AMD diagnosis and treatment, as many retinal specialists are now using OCT, especially SD-OCT,

instead of FA as a guide when considering further anti-VEGF treatment. The updated 2015 AMD Preferred Practice Pattern guidelines (PPP) from the American Academy of Ophthalmology (AAO) notes that OCT is important in the diagnosis and management of AMD.⁵

OCT is especially helpful in detecting early CNV in patients with new complaints of metamorphopsia or unexplained blurred vision.⁵ However, systematic review of studies from 1995 to March 2013 revealed that, although time-domain (TD) OCT is a relatively sensitive test for the initial diagnosis of neovascular AMD, it is of moderate specificity.^{14,15} The review suggested that TD-OCT should not replace FA in the diagnosis of

OPHTHALMIC CHAIR & STAND

neovascular AMD and that further research is required to evaluate the diagnostic performance of SD-OCT, since there were limited studies in the literature comparing the instrument with FA.^{14,15}

In non-neovascular AMD, OCT has helped identify many features related to the degenerative process and expand our understanding of the condition. Reticular drusen, subretinal drusen deposits, pseudocysts, outer retinal tubulation and drusen-associated acquired vitelliform lesions are only a few of the non-neovascular AMD findings OCT can detect.¹⁶⁻¹⁸ Additionally, change analysis software available on various SD-OCT instruments can be helpful in identifying drusen enlargement or reabsorption. SD-OCT findings identified in association with non-neovascular AMD have also predicted drusen-associated chorioretinal atrophy. This can be important in patient management when predicting the risk and rate of vision loss.¹⁹

Diabetic Macular Edema

The Early Treatment Diabetic Retinopathy Study (ETDRS) emphasized the importance of treating clinically significant macular edema (CSME) to prevent vision loss. This landmark study used stereo contact lens biomicroscopy and stereo photography to define CSME, and FA was used to guide the photocoagulation treatment.²⁰ Now, OCT is routinely used to evaluate DME in clinical practice. Large clinical trials evaluating the efficacy of anti-VEGF treatment, such as the RIDE and RISE studies, have incorporated OCT findings, along with a corresponding decrease in vision, in their definition of DME.²¹ In these studies, researchers used OCT, rather than stereoscopic photographs or clinical examina-

tion, because it allowed for an objective assessment and quantified the amount and location of retinal thickening.²¹⁻²⁴

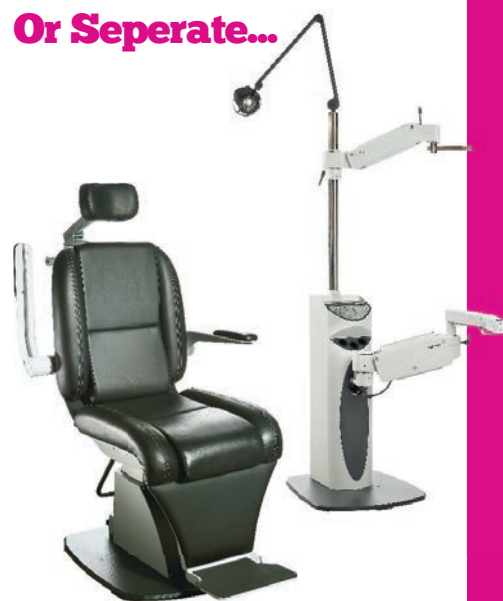In clinical practice, the decision to treat DME is usually based on OCT findings. Added to that, the instrument allows for tracking the response to treatment. The American Academy of Ophthalmology's Preferred Practice Pattern for diabetic retinopathy recognizes the role of OCT in assessing DME, stating that OCT can be used to evaluate unexplained visual acuity loss, identify areas of vitreomacular traction and evaluate patients with difficult or questionable examinations for DME. The PPP does not recommend using OCT to screen a patient with no or minimal diabetic retinopathy.²⁵ A baseline OCT could be obtained as a reference, but routine macular OCT scans are not recommended if there is no suspicion of DME on clinical examination.^{25,26} For patients with subclinical DME detected with OCT, close monitoring is recommended because of the increased risk for developing visually significant CSME. A four to six month follow up interval has been suggested based on the generally slow change in OCT values and delayed time to treatment.²⁶⁻³¹

Glaucoma

Optic nerve head (ONH) evaluation in the management of glaucoma has been traditionally assessed by ophthalmoscopy and color stereo disc photography. Color stereo disc photographs of the optic nerve are still considered the standard for documenting the ONH status for glaucomatous optic neuropathy.³²⁻³⁵ Red-free photographs can be used to enhance the RNFL defects; however, these are limited by the subjectivity of the



Together...



Or Separate...

S4OPTIK provides exceptional durability, functionality, plus flexibility.

S4OPTIK

250 Cooper Ave., Suite 100 Tonawanda NY 14150

www.s4optik.com | 888-224-6012

Sensible equipment. Well made, well priced.

For today's modern office.

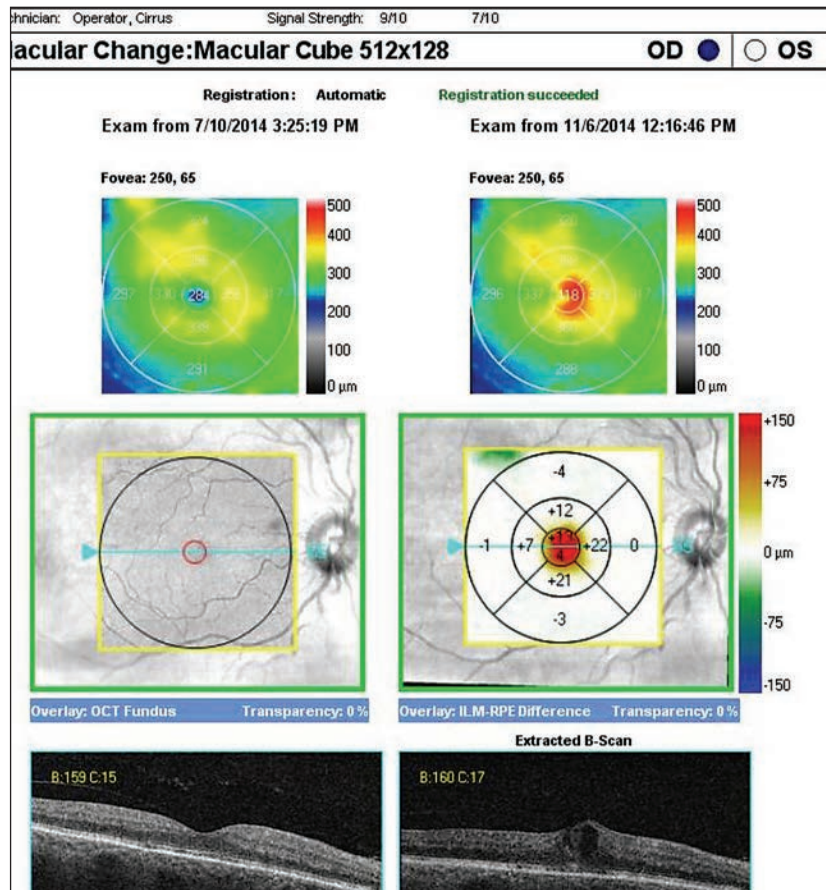
OCT in DME Management

- Provides objective assessment and quantifies the amount and location of retinal thickening
- Tracks thickness changes and response to treatment, especially for anti-VEGF therapy
- Helps guide when further treatment is necessary
- Helps with evaluation of unexplained visual acuity loss
- Identifies areas of vitreomacular traction
- Helps evaluate patients with difficult or questionable DME examinations
- Identifies subclinical DME

Limitations

- Not recommended for routine screenings if there is no suspicion for DME on clinical examination or for patients with no or minimal diabetic retinopathy

SD-OCT macular change analysis demonstrating the development of DME over a period of less than four months.



quantitative analysis and the dependence on the clinician.^{35,36}

Studies have demonstrated measurement of ONH parameters by OCT can aid in the diagnosis of glaucoma.³⁷ OCT imaging can also aid in distinguishing glaucomatous damage from eyes without glaucoma to help facilitate earlier diagnosis and detection of optic nerve damage.³⁸

In addition to assessing the ONH, OCT imaging also allows for evaluation of the peripapillary RNFL (pRNFL). The instrument provides an objective measurement of the structural changes in RNFL thickness and ONH parameters occurring in glaucoma.³⁸ ONH parameters provided by OCT can include optic disc area, optic disc rim area, average cup-to-disc ratio,

vertical cup-to-disc ratio, and cup volume. Patients with early glaucomatous damage can demonstrate preperimetric glaucoma, leading to structural alterations in the ONH, pRNFL and macular areas before functional changes occur.^{37,38}

Peripapillary RNFL thickness as measured by OCT has been extensively studied to distinguish glaucomatous damage and the severity of the disease. The instrument provides average RNFL thickness, which can further be divided into RNFL thickness measures in quadrants and sectors. This separation allows the analysis of RNFL loss into specific patterns that can help distinguish non-glaucomatous optic neuropathies.^{39,40}

Recently, new software has allowed analysis of the macular

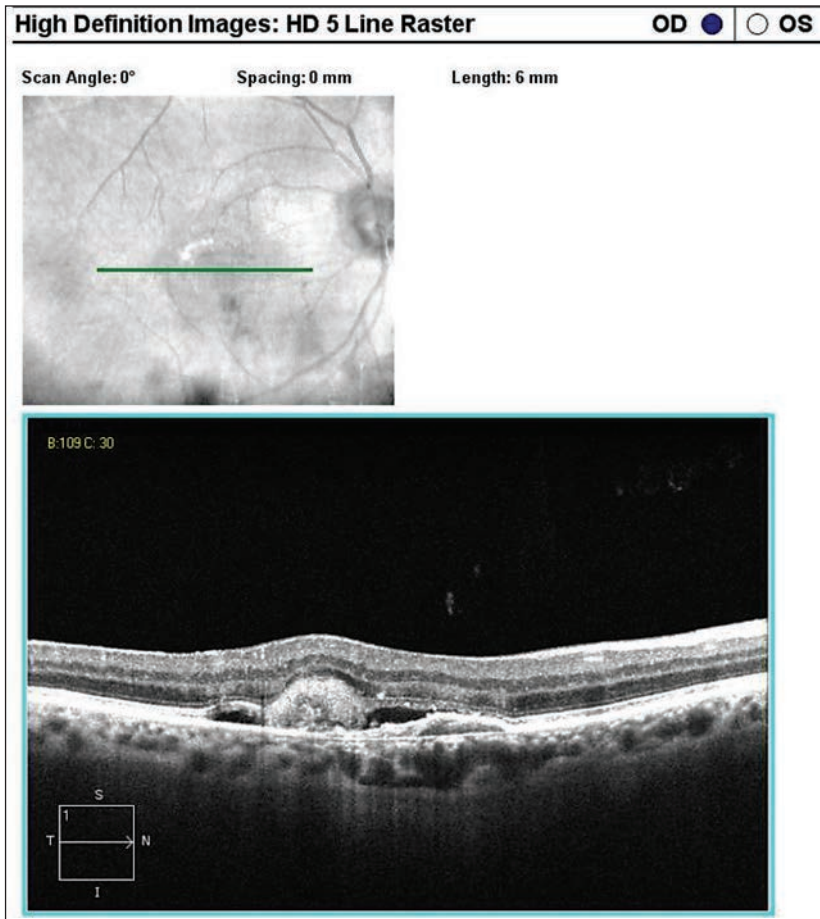
region for detection of glaucomatous damage. Segmentation software specifically evaluating the ganglion cell layer, inner plexiform layer, RNFL over the macula or a combination of all three has emphasized that early glaucomatous damage can involve central vision. Studies on these specific layers in the macular region have identified that these parameters are as sensitive as pRNFL analysis in the detection of glaucoma.⁴¹⁻⁴³ However, the analysis is limited to those patients without macular pathology, and only updated SD-OCT software versions have this capability.

The AAO PPP for primary open-angle glaucoma (POAG) suggests that computer-based image analysis of the ONH and RNFL, such as OCT, are complementary tests.³⁴

S4OPTIK

OPHTHALMIC CHAIR 2000

Precision Engineering



SD-OCT high-definition 5-line raster scan inferior to the fovea over the CNV.

One of the major limitations of OCT is the narrow range of the normative databases for each OCT manufacturer. Each manufacturer has a proprietary normative database that can range from 201 to 480 subjects. The ethnicities of the subjects included in the databases are generally not diverse. The normative data is also limited regarding the included age range and magnitude of refractive error.⁴⁴⁻⁴⁶ When analyzing the printout, clinicians must be cautious if the patient falls outside the normative database, as they may misinterpret the findings based on the colors of green or red that suggest normal or abnormal.⁴⁶ In addition, scans between different OCT instruments cannot be used

for comparison. For example, the pRNFL is measured by a collection of data points in a circle placed around the optic disc, and the diameter of the circle varies with each instrument.

Because glaucoma is a progressive optic neuropathy, reproducible data is important in longitudinal evaluation to track RNFL loss. To track progression, the OCT must have excellent repeatability. Detectable RNFL loss requires a change greater than that expected from usual testing variations.^{47,48} Most instruments have tracking software to recall the baseline scan location. Without active eye tracking technology, pRNFL thickness can vary significantly; thus, the OCT's ability



Effortless cradle tilt recline with perfect counterbalance allows convenient patient positioning with the one-handed release & control mechanism.

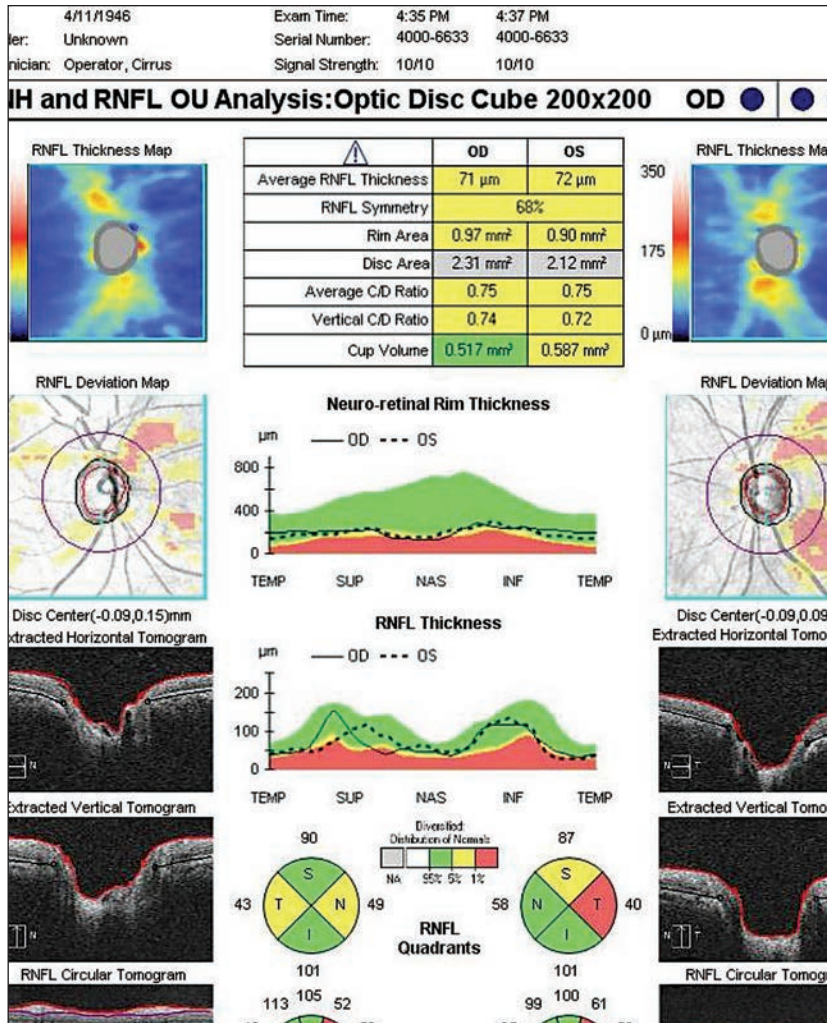
S4OPTIK

250 Cooper Ave., Suite 100 Tonawanda NY 14150

www.s4optik.com | 888-224-6012

Sensible equipment. Well made, well priced.

For today's modern office.



OCT in Glaucoma Management

- Provides objective measurement of the structural changes in pRNFL thickness, ONH parameters and ganglion cell layer
- Facilitates earlier diagnosis and detection of optic nerve damage
- Assists in distinguishing non-glaucomatous optic neuropathies from glaucomatous damage
- Evaluates the ganglion cell layer, inner plexiform layer and RNFL over the macula to detect central vision involvement
- Progression software is a good adjunct for eyes with diffuse RNFL defects or unidentifiable RNFL status

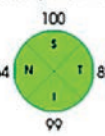
Limitations

- Considered a complementary test according to the AAO's PPP
- The normative database has a narrow range
- Scans are affected by artifacts
- Provides limited benefit in advanced disease

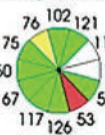
SD-OCT ONH and RNFL analysis in a patient with early POAG. Right eye has movement with motion artifact superiorly. Both eyes have RNFL loss that is borderline or outside normal limits compared with the normative database.

Peripapillary retinal nerve fiber layer thickness of various SD-OCT instruments.

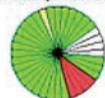
4 sector cpRNFL thickness




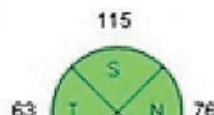
12 sector cpRNFL thickness



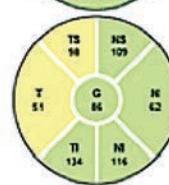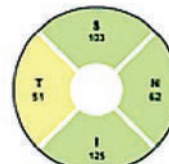36 sector cpRNFL thickness



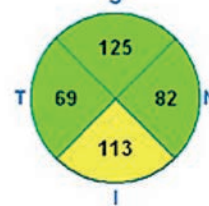
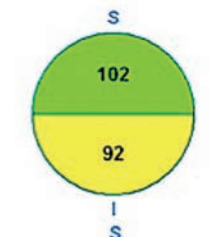
Topcon



Cirrus



Spectralis



RTVue

to track eye movement improves its reliability. However, clinicians are still faced with the challenge of interpreting true progressive RNFL loss from glaucoma, other optic neuropathies, or changes secondary to artifacts.

Artifacts such as vitreous opacities obscuring the scan circle, media opacities reducing the signal strength, vitreopapillary traction and peripapillary atrophy (PPA) can alter the pRNFL thickness and possibly mimic glaucomatous thinning.^{46,49,50} Progression software is a good adjunct for eyes with diffuse RNFL defects or an unidentifiable RNFL status in which photographic assessment is not reliable.⁵¹ However, in patients with advanced glaucomatous optic neuropathy, OCT has limited benefit for identifying progressive optic nerve changes.³⁴

A New View

OCT has proven to be a valuable diagnostic tool, and there is strong evidence for its applications for both retinal pathologies and optic neuropathies. For AMD, OCT can aid in the decision on whether further treatment is necessary. TD-OCT can aid in the initial diagnosis of neovascular AMD, although it should not replace the reference standard of FA yet. Further studies are needed to determine the role of SD-OCT. In DME, OCT can confirm macular edema, and decisions to treat are often based on its findings. However, OCT should not be used to screen diabetic patients with no or minimal retinopathy. Although considered complementary by the AAO PPP, OCT measurements of the pRNFL, ONH parameters and ganglion cell analysis have been shown to assist in the detection and progression of glaucoma. As newer technology

such as swept-source OCT becomes available, it will play an increasing role in the management of glaucoma and other ocular conditions within clinical practice. ■

Dr. Vien practices at the Veterans Affairs Palo Alto Healthcare System and is an assistant clinical professor at University of California Berkeley School of Optometry and Southern California College of Optometry at Marshall B. Ketchum University.

Dr. Yang practices at the Veterans Affairs Palo Alto Healthcare System and is an associate clinical professor at the University of California Berkeley School of Optometry.

1. Martin DF, Maguire MG, Fine SL, et al. Comparison of Age-related Macular Degeneration Treatments Trials (CATT) Research Group. Ranibizumab and bevacizumab for treatment of neovascular age-related macular degeneration: two-year results. *Ophthalmology*. 2012;119:1388-98.
2. Brown DM, Quan DN, Marcus DM, et al. RISE and RIDE Research Group. Long-term outcomes of ranibizumab therapy for diabetic macular edema: the 36-month results from two phase III trials. *Ophthalmology*. 2013;120(10):2013-22.
3. Kahn HA, Leibowitz HM, Ganley JP, et al. The Framingham Eye Study. Outline and major prevalence findings. *Am J Epidemiol*. 1977;106:17-32.
4. Ferris FL III, Fine SL, Hyman L. Age-related macular degeneration and blindness due to neovascular maculopathy. *Arch Ophthalmol*. 1984;102:1640-2.
5. American Academy of Ophthalmology Retina/Vitreous Panel. Preferred Practice Pattern Guidelines. Age-related macular degeneration. San Francisco, CA: American Academy of Ophthalmology; 2015. www.aao.org/ppp.
6. Ramussen A, Brandt S, Fuchs J, et al. Visual outcomes in relation to time to treatment in neovascular age-related macular degeneration. *Acta Ophthalmol*. 2015;93:616-20.
7. Treatment of Age-Related Macular Degeneration With Photodynamic Therapy Study. Photodynamic therapy of subfoveal choroidal neovascularization in age-related macular degeneration with verteporfin: one-year results of 2 randomized clinical trials—TAP Report 1. *Arch Ophthalmol*. 1999;117:1329-45.
8. Azab M, Boyer DS, Bressler NM, et al. Visudyne in Minimally Classic Choroidal Neovascularization Study Group. Verteporfin therapy of subfoveal minimally classic choroidal neovascularization in age-related macular degeneration: 2-year results of a randomized clinical trial. *Arch Ophthalmol*. 2005;123:448-57.
9. Rosenfeld PJ, Brown DM, Heier JS, et al. Ranibizumab for neovascular age-related macular degeneration. *N Engl J Med*. 2006;355:1419-31.
10. Brown DM, Kaiser PK, Michels M, et al. ANCHOR Study Group. Ranibizumab versus verteporfin for neovascular age-related macular degeneration. *N Engl J Med*. 2006;355:1432-44.
11. Khurana RN, Dupas B, Bressler NM. Agreement of time-domain and spectral-domain optical coherence tomography with fluorescein leakage from choroidal neovascularization. *Ophthalmology*. 2010;117:1376-80.
12. Do DV, Gower EW, Cassard SD, et al. Detection of new-onset choroidal neovascularization using optical coherence tomography: the AMD DOC study. *Ophthalmology*. 2012;119:771-8.
13. Wilde C, Patel M, Lakshmanan A, et al. The diagnostic accuracy of spectral-domain optical coherence tomography for neovascular age-related macular degeneration: a comparison with fundus fluorescein angiography. *Eye*. 2015;29:602-9.
14. Castillo MM, Mowatt G, Lois N, et al. Optical coherence

S4OPTIK

OPHTHALMIC CHAIR 2000

KleenTech Lift System®



Enjoy smooth, virtually silent lifting with the Swiss-made KleenTech® lift system.

Benefit from more than 11" of lift for patients up to 560lbs.

S4OPTIK

250 Cooper Ave., Suite 100 Tonawanda NY 14150

www.s4optik.com | 888-224-6012

Sensible equipment. Well made, well priced.

For today's modern office.

Reimbursement for OCT

For billing purposes, OCT is considered a scanning computerized ophthalmic diagnostic imaging (SCODI) test. Anterior segment SCODI is recognized for the evaluation and treatment of diseases affecting the cornea, iris and other anterior chamber structures. The imaging can also provide additional information during planning and follow-up of anterior segment and cataract surgeries. Posterior segment SCODI can assist in the diagnosis and management of retinal and neuro-ophthalmic diseases. It is also used to follow glaucoma suspects, diagnose glaucoma, monitor glaucoma treatment and detect glaucoma progression. Limitations of coverage include the absence of an indication or for screening only.

The Medicare administrative contractor (MAC) found in each contractor's local coverage determination has a comprehensive list of ICD-10 diagnosis codes that are used in conjunction with the CPT codes. The list of ICD-10 diagnoses is grouped into 92132 (anterior segment), 92133 (posterior segment-optic nerve), and 92134 (posterior segment-retina). The patient's medical record must contain documentation that fully supports the medical necessity for the services.

Insurance providers may have an annual frequency limitation

for SCODI billing. In general, diagnostic tests are reimbursed when medically indicated, and clear documentation is necessary for justification. Policies commonly state that diagnosis codes can only be billed one or two times per year for 92133 (posterior segment-optic nerve) for glaucoma, but more often for retinal diseases (92134) such as AMD and DME.

In addition, if multiple diagnostic imaging tests are done the same day, insurers may only reimburse for one diagnostic imaging test, usually the higher-reimbursed test. However, the frequency and number of tests completed on the same day is MAC or carrier-dependent.⁵²

CPT Codes for Anterior and Posterior OCT

92132	SCODI, anterior segment, with interpretation and report, unilateral or bilateral
92133	SCODI, posterior segment, with interpretation and report, unilateral or bilateral; optic nerve
92134	SCODI, posterior segment, with interpretation and report, unilateral or bilateral; retina

tomography for the diagnosis of neovascular age-related macular degeneration: a systemic review. *Eye*. 2014;28:1399-1406.

15. Castillo MM, Mowat G, Elders A, et al. Optical coherence tomography for the monitoring of neovascular age-related macular degeneration. *Ophthalmology*. 2015;122:399-406.

16. Hogg RE, Silva R, Staurengi G, et al. Clinical characteristics of reticular pseudodrusen in the fellow eye of patients with unilateral neovascular age-related macular degeneration. *Ophthalmology*. 2014;121:1748-55.

17. Hariri A, Nittala MG, Sadd SR. Outer retinal tubulation as a predictor of the enlargement amount of geographic atrophy in age-related macular degeneration. *Ophthalmology*. 2015;122:407-13.

18. Lima LH, Laud K, Freund KB, et al. Acquired vitelliform lesion associated with large drusen. *Retina*. 2012;32:647-51.

19. Wu Z, Luu CD, Aytton LN, et al. Optical coherence tomography-defined changes preceding the development of drusen-associated atrophy in age-related macular degeneration. *Ophthalmology*. 2014;121:2415-22.

20. Early Treatment Diabetic Retinopathy Study Research Group. Photocoagulation for diabetic macular edema: Early Treatment Diabetic Retinopathy Study report number 1. *Arch Ophthalmol*. 1985;103:1796-806.

21. Nguyen QD, Brown DM, Marcus DM, et al. Ranibizumab for diabetic macular edema: results from 2 phase III randomized trials: RISE and RIDE. *Ophthalmology*. 2012;119:789-801.

22. Brown DM, Nguyen QD, Marcus DM, et al. Long-term outcomes of ranibizumab therapy for diabetic macular edema: the 36-month results from two phase III trials: RISE and RIDE. *Ophthalmology*. 2013;120:2013-22.

23. Elman MJ, Qin H, Aiello LP, et al. Diabetic Retinopathy Clinical Research Network. Intravitreal ranibizumab for diabetic macular edema with prompt versus deferred laser treatment: three-year randomized trial results. *Ophthalmology*. 2012;119:2312-8.

24. Do DV, Nguyen QD, Khwaja AA, et al. READ-2 Study Group. Ranibizumab for edema of the macula in diabetes study: 3-year outcomes and the need for prolonged frequent treatment. *JAMA Ophthalmol*. 2013;131:139-45.

25. American Academy of Ophthalmology Retina/Vitreous Panel. Preferred Practice Pattern Guidelines. Diabetic retinopathy. San Francisco, CA: American Academy of Ophthalmology; 2014. www.aao.org/ppp.

26. Pires I, Santos AR, Nunes S, et al. Subclinical macular edema as a predictor of progression to clinically significant

macular edema in type 2 diabetes. *Ophthalmologica*. 2013;230:201-6.

27. Davis MD, Bressler SB, Aiello LP, et al. Comparison of time-domain OCT and fundus photographic assessments of retinal thickening in eyes with diabetic macular edema. *Invest Ophthalmol Vis Sci*. 2008;49:1745-52.

28. Virgili G, Menchini F, Casazza G, et al. Optical coherence tomography (OCT) for detection of macular oedema in patients with diabetic retinopathy. *Cochrane Database Syst Rev*. 2015 Jan;1:CD008081.

29. Browning DJ, Fraser CM. The predictive value of patient and eye characteristics on the course of subclinical diabetic macular edema. *Am J Ophthalmol*. 2008;145:149-54.

30. Bressler NM, Miller KM, Beck RW, et al. Observational study of subclinical diabetic macular edema. *Eye*. 2012;26:833-40.

31. Browning DJ. Diabetic retinopathy: evidenced-based management. New York, NY: Springer; 2010.

32. Kass MA, Heuer DK, Higginbotham EJ, et al. The ocular hypertension treatment study: a randomized trial determines that topical ocular hypotensive medication delays or prevents the onset of primary open angle glaucoma. *Arch Ophthalmol*. 2002;120:701-3.

33. Heijl A, Leske MC, Bengtsson B, et al. Reduction of intraocular pressure and glaucoma progression: results from the early manifest glaucoma trial. *Arch Ophthalmol*. 2002;120:1268-79.

34. American Academy of Ophthalmology Glaucoma Panel. Preferred Practice Pattern Guidelines. Primary open-angle glaucoma. San Francisco, CA: American Academy of Ophthalmology; 2014. www.aao.org/ppp.

35. Jonas JB, Budde WM, Panda-Jonas S. Ophthalmoscopic evaluation of the optic nerve head. *Surv Ophthalmol*. 1999;43:293-320.

36. Mills RP. Glaucoma imaging: technology in progress. *J Glaucoma*. 1999;8:87-9.

37. Mwanza JC, Oakley JD, Budenz DL, et al. Ability of cirrus HD-OCT optic nerve head parameters to discriminate normal from glaucomatous eyes. *Ophthalmology*. 2011;118:241-8.

38. Michelessi M, Lucenteforte E, Oddone F, et al. Optic nerve head and fibre layer imaging for diagnosing glaucoma. *Cochrane Database Syst Rev*. 2015;11:CD008803.

39. Gupta PK, Asrani S, Freedman SF, et al. Differentiating glaucomatous from non-glaucomatous optic nerve cupping by optical coherence tomography. *Open Neurol J*. 2011;5:1-7.

40. Pasol J. Neuro-ophthalmic disease and optical coherence

tomography: glaucoma look-alikes. *Curr Opin Ophthalmol*. 2011;22:124-32.

41. Hood DC, Raza AS, de Moraes CG, et al. Glaucomatous damage of the macula. *Prog Retin Eye Res*. 2013;32:1-21.

42. Hood DC, Slobodnick A, Raza AS, et al. Early glaucoma involves both deep local, and shallow widespread, retinal nerve fiber damage of the macular region. *Invest Ophthalmol Vis Sci*. 2014;55:632-49.

43. Padhy D, Rao A. Macular ganglion cell/inner plexiform layer measurements by spectral domain optical coherence tomography for detection of early glaucoma and comparison to retinal nerve fiber layer measurements. *Am J Ophthalmol*. 2014;158:211.

44. Spaeth GL, Reddy SC. Imaging of the optic disc in caring for patients with glaucoma: ophthalmoscopy and photography remains the gold standard. *Surv Ophthalmol*. 2014;59:454-8.

45. Akashi A, Kanamori A, Ueda K, et al. The ability of SD-OCT to differentiate early glaucoma with high myopia from high myopic controls and nonhighly myopic controls. *Invest Ophthalmol Vis Sci*. 2015;56:6573-80.

46. Chong GT, Lee RK. Glaucoma versus red disease: imaging and glaucoma diagnosis. *Curr Opin Ophthalmol*. 2012;23:79-88.

47. Leung CK, Cheung CY, Weinreb RN, et al. Retinal nerve fiber layer imaging with spectral-domain optical coherence tomography: a variability and diagnostic performance study. *Ophthalmology*. 2009;116:1257-63.

48. Wu W, Boer JF, Chen TC. Reproducibility of retinal nerve fiber layer thickness measurements using spectral domain optical coherence tomography. *J Glaucoma*. 2011;20:470-6.

49. Liu Y, Simavil H, Que CJ, et al. Patient characteristics associated with artifacts in Spectralis optical coherence tomography imaging of the retinal nerve fiber layer in glaucoma. *Am J Ophthalmol*. 2015;159:565-76.

50. Asrani S, Essaid L, Alder BD, et al. Artifacts in spectral-domain optical coherence tomography measurements in glaucoma. *JAMA Ophthalmol*. 2014;132:396-402.

51. Lee JR, Sung KR, Na JH, et al. Discrepancy between optic disc and nerve fiber layer assessment and optical coherence tomography in detecting glaucomatous progression. *Jpn J Ophthalmol*. 2013;57(6):546-52.

52. Centers for Medicare and Medicaid Services. Local Coverage Determination: Scanning Computerized Ophthalmic Diagnostic Imaging. Accessed January 3, 2016. www.cms.gov/medicare-coverage-database/details/lcd-details.aspx?LCDId=34380.



Classic beta blocker adjunctive therapy for the right patient at the right time³

The concomitant use of two topical beta-adrenergic blocking agents is not recommended^{4,5}

Indications and Usage

ISTALOL® (timolol maleate ophthalmic solution) is a non-selective beta-adrenergic receptor blocking agent indicated in the treatment of elevated intraocular pressure in patients with ocular hypertension or open-angle glaucoma.

Preservative-free TIMOPTIC® (timolol maleate ophthalmic solution) in OCUDOSE® (dispenser) is indicated in the treatment of elevated intraocular pressure in patients with ocular hypertension or open-angle glaucoma. It may be used when a patient is sensitive to the preservative in TIMOPTIC (timolol maleate ophthalmic solution), benzalkonium chloride, or when use of a preservative-free topical medication is advisable.

Important Safety Information for Istalol® and Timoptic® in Ocudose®

- Both ISTALOL® (timolol maleate ophthalmic solution) and TIMOPTIC® (timolol maleate ophthalmic solution) in OCUDOSE® (dispenser) are contraindicated in patients with: bronchial asthma; a history of bronchial asthma; severe chronic obstructive pulmonary disease; sinus bradycardia; second or third degree atrioventricular block; overt cardiac failure; cardiogenic shock; hypersensitivity to any component of the product.
- **The same adverse reactions found with systemic administration of beta-adrenergic blocking agents may occur with topical administration. Severe respiratory reactions and cardiac reaction, including death due to bronchospasm in patients with asthma, and rarely death in association with cardiac failure, have been reported following systemic or ophthalmic administration of timolol maleate.**
- Patients with a history of atopy or severe anaphylactic reactions to a variety of allergens may be unresponsive to the usual doses of epinephrine used to treat anaphylactic reactions.
- Timolol has been reported rarely to increase muscle weakness in some patients with myasthenia gravis or myasthenic symptoms.
- Beta-adrenergic blocking agents may mask signs and symptoms of acute hypoglycemia or certain clinical signs of hyperthyroidism. Patients subject to spontaneous hypoglycemia, or diabetic patients receiving either insulin or oral hypoglycemic agents, or patients suspected of developing thyrotoxicosis, should be managed carefully, with caution.
- In patients undergoing elective surgery, some authorities recommend gradual withdrawal of beta adrenergic receptor blocking agents because these agents impair the ability of the heart to respond to beta-adrenergically mediated reflex stimuli.
- The most frequently reported adverse reactions have been burning and stinging upon instillation. This was seen in 38% of patients treated with ISTALOL and in approximately one in eight patients treated with TIMOPTIC in OCUDOSE. Additional reactions reported with ISTALOL at a frequency of 4 to 10% include: blurred vision, cataract, conjunctival injection, headache, hypertension, infection, itching and decreased visual acuity.

Please see Brief Summary of Prescribing Information for ISTALOL and TIMOPTIC in OCUDOSE on the following pages.

For the patients who need incremental IOP reduction in a preservative free form⁶



For the patients who need incremental IOP reduction in a once a day form⁶

Istalol[®]
(timolol maleate
ophthalmic solution) 0.5%

References: 1. Alm A, Stjernschantz J. Effects on Intraocular Pressure and Side Effects of 0.005% Latanoprost Applied Once Daily, Evening or Morning. *Ophthalmology*. 1995;102:1743-1752. 2. Brubaker R. Flow of Aqueous Humor in Humans. *IOVS*. 1991;32(13):3145-3166. 3. Obstbaum S, Cioffi GA, Kriegstein GK, et al. Gold Standard Medical Therapy for Glaucoma: Defining the Criteria Identifying Measures for an Evidence-Based Analysis. *Clin Ther*. 2004;26(12):2102-2119. 4. Istalol [package insert]. Bridgewater, NJ: Bausch & Lomb Incorporated; 2013. 5. Timoptic in Ocudose [package insert]. Lawrenceville, NJ: Aton Pharma; 2009. 6. Stewart W, Day DG, Sharpe ED. Efficacy and Safety of Timolol Solution Once Daily vs Timolol Gel Added to Latanoprost. *Am J Ophthalmol*. 1999;128(6):692-696.

Timoptic and Ocudose are trademarks of Valeant Pharmaceuticals International, Inc. or its affiliates. Bausch + Lomb and Istalol are trademarks of Bausch & Lomb Incorporated or its affiliates.

BAUSCH + LOMB

©Bausch & Lomb Incorporated.

US/TOP/14/0017(1)

BRIEF SUMMARY OF PRESCRIBING INFORMATION

This Brief Summary does not include all the information needed to use TIMOPTIC® 0.25% AND 0.5% (timolol maleate ophthalmic solution) in OCUDOSE® (DISPENSER) safely and effectively. See full prescribing information for TIMOPTIC in OCUDOSE.

PRESERVATIVE-FREE STERILE OPHTHALMIC SOLUTION in a Sterile Ophthalmic Unit Dose Dispenser

TIMOPTIC® 0.25% AND 0.5% (TIMOLOL MALEATE OPHTHALMIC SOLUTION) in OCUDOSE® (DISPENSER)

INDICATIONS AND USAGE

Preservative-free TIMOPTIC in OCUDOSE is indicated in the treatment of elevated intraocular pressure in patients with ocular hypertension or open-angle glaucoma.

Preservative-free TIMOPTIC in OCUDOSE may be used when a patient is sensitive to the preservative in TIMOPTIC (timolol maleate ophthalmic solution), benzalkonium chloride, or when use of a preservative-free topical medication is advisable.

CONTRAINDICATIONS

Preservative-free TIMOPTIC in OCUDOSE is contraindicated in patients with (1) bronchial asthma; (2) a history of bronchial asthma; (3) severe chronic obstructive pulmonary disease (see WARNINGS); (4) sinus bradycardia; (5) second or third degree atrioventricular block; (6) overt cardiac failure (see WARNINGS); (7) cardiogenic shock; or (8) hypersensitivity to any component of this product.

WARNINGS

As with many topically applied ophthalmic drugs, this drug is absorbed systemically.

The same adverse reactions found with systemic administration of beta-adrenergic blocking agents may occur with topical administration. For example, severe respiratory reactions and cardiac reactions, including death due to bronchospasm in patients with asthma, and rarely death in association with cardiac failure, have been reported following systemic or ophthalmic administration of timolol maleate (see CONTRAINDICATIONS).

Cardiac Failure: Sympathetic stimulation may be essential for support of the circulation in individuals with diminished myocardial contractility, and its inhibition by beta-adrenergic receptor blockade may precipitate more severe failure.

In Patients Without a History of Cardiac Failure continued depression of the myocardium with beta-blocking agents over a period of time can, in some cases, lead to cardiac failure. At the first sign or symptom of cardiac failure, Preservative-free TIMOPTIC in OCUDOSE should be discontinued.

Obstructive Pulmonary Disease: Patients with chronic obstructive pulmonary disease (e.g., chronic bronchitis, emphysema) of mild or moderate severity, bronchospastic disease, or a history of bronchospastic disease (other than bronchial asthma or a history of bronchial asthma, in which TIMOPTIC in OCUDOSE is contraindicated [see CONTRAINDICATIONS]) should, in general, not receive beta-blockers, including Preservative-free TIMOPTIC in OCUDOSE.

Major Surgery: The necessity or desirability of withdrawal of beta-adrenergic blocking agents prior to major surgery is controversial. Beta-adrenergic receptor blockade impairs the ability of the heart to respond to beta-adrenally mediated reflex stimuli. This may augment the risk of general anesthesia in surgical procedures. Some patients receiving beta-adrenergic receptor blocking agents have experienced protracted severe hypotension during anesthesia. Difficulty in restarting and maintaining the heartbeat has also been reported. For these reasons, in patients undergoing elective surgery, some authorities recommend gradual withdrawal of beta-adrenergic receptor blocking agents.

If necessary during surgery, the effects of beta-adrenergic blocking agents may be reversed by sufficient doses of adrenergic agonists.

Diabetes Mellitus: Beta-adrenergic blocking agents should be administered with caution in patients subject to spontaneous hypoglycemia or to diabetic patients (especially those with labile diabetes) who are receiving insulin or oral hypoglycemic agents. Beta-adrenergic receptor blocking agents may mask the signs and symptoms of acute hypoglycemia.

Thyrotoxicosis: Beta-adrenergic blocking agents may mask certain clinical signs (e.g., tachycardia) of hyperthyroidism. Patients suspected of developing thyrotoxicosis should be managed carefully to avoid abrupt withdrawal of beta-adrenergic blocking agents that might precipitate a thyroid storm.

PRECAUTIONS

General: Because of potential effects of beta-adrenergic blocking agents on blood pressure and pulse, these agents should be used with caution in patients with cerebrovascular insufficiency. If signs or symptoms suggesting reduced cerebral blood flow develop following initiation of therapy with Preservative-free TIMOPTIC in OCUDOSE, alternative therapy should be considered.

Choroidal detachment after filtration procedures has been reported with the administration of aqueous suppressant therapy (e.g., timolol).

Angle-closure glaucoma: In patients with angle-closure glaucoma, the immediate objective of treatment is to reopen the angle. This requires constricting the pupil. Timolol maleate has little or no effect on the pupil. TIMOPTIC in OCUDOSE should not be used alone in the treatment of angle-closure glaucoma.

Anaphylaxis: While taking beta-blockers, patients with a history of atopy or a history of severe anaphylactic reactions to a variety of allergens may be more reactive to repeated accidental, diagnostic, or therapeutic challenge with such allergens. Such patients may be unresponsive to the usual doses of epinephrine used to treat anaphylactic reactions.

Muscle Weakness: Beta-adrenergic blockade has been reported to potentiate muscle weakness consistent with certain myasthenic symptoms (e.g., diplopia, ptosis, and generalized weakness). Timolol has been reported rarely to increase muscle weakness in some patients with myasthenia gravis or myasthenic symptoms.

Information for Patients: Patients should be instructed about the use of Preservative-free TIMOPTIC in OCUDOSE.

Since sterility cannot be maintained after the individual unit is opened, patients should be instructed to use the product immediately after opening, and to discard the individual unit and any remaining contents immediately after use.

Patients with bronchial asthma, a history of bronchial asthma, severe chronic obstructive pulmonary disease, sinus bradycardia, second or third degree

atrioventricular block, or cardiac failure should be advised not to take this product. (See CONTRAINDICATIONS.)

Drug Interactions: Although TIMOPTIC (timolol maleate ophthalmic solution) used alone has little or no effect on pupil size, mydriasis resulting from concomitant therapy with TIMOPTIC (timolol maleate ophthalmic solution) and epinephrine has been reported occasionally.

Beta-adrenergic blocking agents: Patients who are receiving a beta-adrenergic blocking agent orally and Preservative-free TIMOPTIC in OCUDOSE should be observed for potential additive effects of beta-blockade, both systemic and on intraocular pressure. The concomitant use of two topical beta-adrenergic blocking agents is not recommended.

Calcium antagonists: Caution should be used in the coadministration of beta-adrenergic blocking agents, such as Preservative-free TIMOPTIC in OCUDOSE, and oral or intravenous calcium antagonists, because of possible atrioventricular conduction disturbances, left ventricular failure, and hypotension. In patients with impaired cardiac function, coadministration should be avoided.

Catecholamine-depleting drugs: Close observation of the patient is recommended when a beta blocker is administered to patients receiving catecholamine-depleting drugs such as reserpine, because of possible additive effects and the production of hypotension and/or marked bradycardia, which may result in vertigo, syncope, or postural hypotension.

Digitalis and calcium antagonists: The concomitant use of beta-adrenergic blocking agents with digitalis and calcium antagonists may have additive effects in prolonging atrioventricular conduction time.

CYP2D6 inhibitors: Potentiated systemic beta-blockade (e.g., decreased heart rate, depression) has been reported during combined treatment with CYP2D6 inhibitors (e.g., quinidine, SSRIs) and timolol.

Clonidine: Oral beta-adrenergic blocking agents may exacerbate the rebound hypertension which can follow the withdrawal of clonidine. There have been no reports of exacerbation of rebound hypertension with ophthalmic timolol maleate.

Injectable epinephrine: (See PRECAUTIONS, General, Anaphylaxis)

Carcinogenesis, Mutagenesis, Impairment of Fertility: In a two-year oral study of timolol maleate administered orally to rats, there was a statistically significant increase in the incidence of adrenal pheochromocytomas in male rats administered 300 mg/kg/day (approximately 42,000 times the systemic exposure following the maximum recommended human ophthalmic dose). Similar differences were not observed in rats administered oral doses equivalent to approximately 14,000 times the maximum recommended human ophthalmic dose.

In a lifetime oral study in mice, there were statistically significant increases in the incidence of benign and malignant pulmonary tumors, benign uterine polyps and mammary adenocarcinomas in female mice at 500 mg/kg/day (approximately 71,000 times the systemic exposure following the maximum recommended human ophthalmic dose), but not at 5 or 50 mg/kg/day (approximately 700 or 7,000 times, respectively, the systemic exposure following the maximum recommended human ophthalmic dose). In a subsequent study in female mice, in which post-mortem examinations were limited to the uterus and the lungs, a statistically significant increase in the incidence of pulmonary tumors was again observed at 500 mg/kg/day.

The increased occurrence of mammary adenocarcinomas was associated with elevations in serum prolactin which occurred in female mice administered oral timolol at 500 mg/kg/day, but not at doses of 5 or 50 mg/kg/day. An increased incidence of mammary adenocarcinomas in rodents has been associated with administration of several other therapeutic agents that elevate serum prolactin, but no correlation between serum prolactin levels and mammary tumors has been established in humans. Furthermore, in adult human female subjects who received oral dosages of up to 60 mg of timolol maleate (the maximum recommended human oral dosage), there were no clinically meaningful changes in serum prolactin.

Timolol maleate was devoid of mutagenic potential when tested *in vivo* (mouse) in the micronucleus test and cytogenetic assay (doses up to 800 mg/kg) and *in vitro* in a neoplastic cell transformation assay (up to 100 mcg/mL). In Ames tests the highest concentrations of timolol equivalent, 5,000 or 10,000 mcg/plate, were associated with statistically significant elevations of revertants observed with tester strain TA100 (in seven replicate assays), but not in the remaining three strains. In the assays with tester strain TA100, no consistent dose response relationship was observed, and the ratio of test to control revertants did not reach 2. A ratio of 2 is usually considered the criterion for a positive Ames test.

Reproduction and fertility studies in rats demonstrated no adverse effect on male or female fertility at doses up to 21,000 times the systemic exposure following the maximum recommended human ophthalmic dose.

Pregnancy: Teratogenic Effects — Pregnancy Category C. Teratogenicity studies with timolol in mice, rats and rabbits at oral doses up to 50 mg/kg/day (7,000 times the systemic exposure following the maximum recommended human ophthalmic dose) demonstrated no evidence of fetal malformations. Although delayed fetal ossification was observed at this dose in rats, there were no adverse effects on postnatal development of offspring. Doses of 1000 mg/kg/day (142,000 times the systemic exposure following the maximum recommended human ophthalmic dose) were maternotoxic in mice and resulted in an increased number of fetal resorptions. Increased fetal resorptions were also seen in rabbits at doses of 14,000 times the systemic exposure following the maximum recommended human ophthalmic dose, in this case without apparent maternotoxicity.

There are no adequate and well-controlled studies in pregnant women. Preservative-free TIMOPTIC in OCUDOSE should be used during pregnancy only if the potential benefit justifies the potential risk to the fetus.

Nursing Mothers: Timolol maleate has been detected in human milk following oral and ophthalmic drug administration. Because of the potential for serious adverse reactions from timolol in nursing infants, a decision should be made whether to discontinue nursing or to discontinue the drug, taking into account the importance of the drug to the mother.

Pediatric Use: Safety and effectiveness in pediatric patients have not been established.

Geriatric Use: No overall differences in safety or effectiveness have been observed between elderly and younger patients.

ADVERSE REACTIONS

The most frequently reported adverse experiences have been burning and stinging upon instillation (approximately one in eight patients).

The following additional adverse experiences have been reported less frequently with ocular administration of this or other timolol maleate formulations: BODY AS A WHOLE: Headache, asthenia/fatigue, and chest pain. CARDIOVASCULAR: Bradycardia, arrhythmia, hypotension, hypertension, syncope, heart block, cerebral vasospasm, cerebral ischemia, cardiac failure, worsening of angina pectoris, palpitation, cardiac arrest, pulmonary edema, edema, claudication, Raynaud's

phenomenon, and cold hands and feet.

DIGESTIVE: Nausea, diarrhea, dyspepsia, anorexia, and dry mouth.

IMMUNOLOGIC: Systemic lupus erythematosus.

NERVOUS SYSTEM/PSYCHIATRIC: Dizziness, increase in signs and symptoms of myasthenia gravis, paresthesia, somnolence, insomnia, nightmares, behavioral changes and psychic disturbances including depression, confusion, hallucinations, anxiety, disorientation, nervousness, and memory loss.

SKIN: Alopecia and psoriasisiform rash or exacerbation of psoriasis.

HYPERSENSITIVITY: Signs and symptoms of systemic allergic reactions including anaphylaxis, angioedema, urticaria, and localized and generalized rash.

RESPIRATORY: Bronchospasm (predominantly in patients with pre-existing bronchospastic disease), respiratory failure, dyspnea, nasal congestion, cough and upper respiratory infections.

ENDOCRINE: Masked symptoms of hypoglycemia in diabetic patients (see WARNINGS).

SPECIAL SENSES: Signs and symptoms of ocular irritation including conjunctivitis, blepharitis, keratitis, ocular pain, discharge (e.g., crusting), foreign body sensation, itching and tearing, and dry eyes; ptosis; decreased corneal sensitivity; cystoid macular edema; visual disturbances including refractive changes and diplopia; pseudophthalmos; choroidal detachment following filtration surgery (see PRECAUTIONS, General); and tinnitus.

UROGENITAL: Retroperitoneal fibrosis, decreased libido, impotence, and Peyronie's disease.

The following additional adverse effects have been reported in clinical experience with ORAL timolol maleate or other ORAL beta blocking agents, and may be considered potential effects of ophthalmic timolol maleate: Allergic: Erythematous rash, fever combined with aching and sore throat, laryngospasm with respiratory distress; Body as a Whole: Extremity pain, decreased exercise tolerance, weight loss; Cardiovascular: Worsening of arterial insufficiency, vasodilatation; Digestive: Gastrointestinal pain, hepatomegaly, vomiting, mesenteric arterial thrombosis, ischemic colitis; Hematologic: Nonthrombocytopenic purpura; thrombocytopenic purpura; agranulocytosis; Endocrine: Hyperglycemia, hypoglycemia; Skin: Pruritus, skin irritation, increased pigmentation, sweating; Musculoskeletal: Arthralgia; Nervous System/Psychiatric: Vertigo, local weakness, diminished concentration, reversible mental depression progressing to catatonia, an acute reversible syndrome characterized by disorientation for time and place, emotional lability, slightly clouded sensorium, and decreased performance on neuropsychometrics; Respiratory: Rales, bronchial obstruction; Urogenital: Urination difficulties.

OVERDOSAGE

There have been reports of inadvertent overdosage with Ophthalmic Solution TIMOPTIC (timolol maleate ophthalmic solution) resulting in systemic effects similar to those seen with systemic beta-adrenergic blocking agents such as dizziness, headache, shortness of breath, bradycardia, bronchospasm, and cardiac arrest (see also ADVERSE REACTIONS).

Overdosage has been reported with Tablets BLOCADREN® (timolol maleate tablets). A 30 year old female ingested 650 mg of BLOCADREN (maximum recommended oral daily dose is 60 mg) and experienced second and third degree heart block. She recovered without treatment but approximately two months later developed irregular heartbeat, hypertension, dizziness, tinnitus, faintness, increased pulse rate, and borderline first degree heart block.

An *in vitro* hemodialysis study, using ¹⁴C timolol added to human plasma or whole blood, showed that timolol was readily dialyzed from these fluids; however, a study of patients with renal failure showed that timolol did not dialyze readily.

DOSE AND ADMINISTRATION

Preservative-free TIMOPTIC in OCUDOSE is a sterile solution that does not contain a preservative. The solution from one individual unit is to be used immediately after opening for administration to one or both eyes. Since sterility cannot be guaranteed after the individual unit is opened, the remaining contents should be discarded immediately after administration.

Preservative-free TIMOPTIC in OCUDOSE is available in concentrations of 0.25 and 0.5 percent. The usual starting dose is one drop of 0.25 percent Preservative-free TIMOPTIC in OCUDOSE in the affected eye(s) administered twice a day. Apply enough gentle pressure on the individual container to obtain a single drop of solution. If the clinical response is not adequate, the dosage may be changed to one drop of 0.5 percent solution in the affected eye(s) administered twice a day.

Since in some patients the pressure-lowering response to Preservative-free TIMOPTIC in OCUDOSE may require a few weeks to stabilize, evaluation should include a determination of intraocular pressure after approximately 4 weeks of treatment with Preservative-free TIMOPTIC in OCUDOSE.

If the intraocular pressure is maintained at satisfactory levels, the dosage schedule may be changed to one drop once a day in the affected eye(s). Because of diurnal variations in intraocular pressure, satisfactory response to the once-a-day dose is best determined by measuring the intraocular pressure at different times during the day.

Dosages above one drop of 0.5 percent TIMOPTIC (timolol maleate ophthalmic solution) twice a day generally have not been shown to produce further reduction in intraocular pressure. If the patient's intraocular pressure is still not at a satisfactory level on this regimen, concomitant therapy with other agent(s) for lowering intraocular pressure can be instituted taking into consideration that the preparation(s) used concomitantly may contain one or more preservatives. The concomitant use of two topical beta-adrenergic blocking agents is not recommended. (See PRECAUTIONS, Drug Interactions, Beta-adrenergic blocking agents.)

Manuf. for:

ATON Lawrenceville
NJ 08648
P H A R M A USA

By: Laboratories Merck Sharp & Dohme-Chirept
63963 Clermont-Ferrand Cedex 9, France

Based on PI - 5142662/069A-03/09/9689-9690
US/TOP/14/0018 Issued February 2009

* Registered trademark of ATON PHARMA, INC.
COPYRIGHT © 2009 ATON PHARMA, INC.
All rights reserved

BRIEF SUMMARY OF PRESCRIBING INFORMATION

This Brief Summary does not include all the information needed to use ISTALOL® (timolol maleate ophthalmic solution) 0.5% safely and effectively. See full prescribing information for ISTALOL.

Istalol® (timolol maleate ophthalmic solution) 0.5%

Initial U.S. Approval: 1978

STERILE

INDICATIONS AND USAGE

Istalol (timolol maleate ophthalmic solution) 0.5% is a non-selective beta-adrenergic receptor blocking agent indicated in the treatment of elevated intraocular pressure (IOP) in patients with ocular hypertension or open-angle glaucoma.

CONTRAINDICATIONS

4.1 Asthma, COPD: Istalol is contraindicated in patients with bronchial asthma; a history of bronchial asthma; severe chronic obstructive pulmonary disease (see **WARNINGS AND PRECAUTIONS, 5.1, 5.3**).

4.2 Sinus Bradycardia, AV Block, Cardiac Failure, Cardiogenic Shock: Istalol is contraindicated in patients with sinus bradycardia; second or third degree atrioventricular block; overt cardiac failure (see **WARNINGS AND PRECAUTIONS, 5.2**); cardiogenic shock.

4.3 Hypersensitivity Reactions: Istalol is contraindicated in patients who have exhibited a hypersensitivity reaction to any component of this product in the past.

WARNINGS AND PRECAUTIONS

5.1 Potentiation of Respiratory Reactions Including Asthma: Istalol contains timolol maleate; and although administered topically, it can be absorbed systemically. Therefore, the same adverse reactions found with systemic administration of beta-adrenergic blocking agents may occur with topical administration. For example, severe respiratory reactions and cardiac reactions including death due to bronchospasm in patients with asthma, and rarely death in association with cardiac failure, have been reported following systemic or ophthalmic administration of timolol maleate (see **CONTRAINDICATIONS, 4.1**).

5.2 Cardiac Failure: Sympathetic stimulation may be essential for support of the circulation in individuals with diminished myocardial contractility, and its inhibition of beta-adrenergic receptor blockade may precipitate more severe failure. In patients without a history of cardiac failure, continued depression of the myocardium with beta-blocking agents over a period of time can, in some cases, lead to cardiac failure. At the first sign or symptom of cardiac failure, Istalol should be discontinued (see also **CONTRAINDICATIONS, 4.2**).

5.3 Obstructive Pulmonary Disease: Patients with chronic obstructive pulmonary disease (e.g., chronic bronchitis, emphysema) of mild or moderate severity, bronchospastic disease, or a history of bronchospastic disease [other than bronchial asthma or a history of bronchial asthma in which Istalol is contraindicated (see **CONTRAINDICATIONS, 4.2**)] should, in general, not receive beta-blocking agents, including Istalol.

5.4 Increased Reactivity to Allergens: While taking beta-blockers, patients with a history of atopy or a history of severe anaphylactic reactions to a variety of allergens may be more reactive to repeated accidental, diagnostic, or therapeutic challenge with such allergens. Such patients may be unresponsive to the usual doses of epinephrine used to treat anaphylactic reactions.

5.5 Potentiation of Muscle Weakness: Beta-adrenergic blockade has been reported to potentiate muscle weakness consistent with certain myasthenic symptoms (e.g., diplopia, ptosis, and generalized weakness). Timolol has been reported rarely to increase muscle weakness in some patients with myasthenia gravis or myasthenic symptoms.

5.6 Masking of Hypoglycemic Symptoms in Patients with Diabetes Mellitus: Beta-adrenergic blocking agents should be administered with caution in patients subject to spontaneous hypoglycemia or to diabetic patients (especially those with labile diabetes) who are receiving insulin or oral hypoglycemic agents. Beta-adrenergic receptor blocking agents may mask the signs and symptoms of acute hypoglycemia.

5.7 Masking of Thyrotoxicosis: Beta-adrenergic blocking agents may mask certain clinical signs (e.g., tachycardia) of hyperthyroidism. Patients suspected of developing thyrotoxicosis should be managed carefully to avoid abrupt withdrawal of beta-adrenergic blocking agents that might precipitate a thyroid storm.

5.8 Contamination of Topical Ophthalmic Products After Use: There have been reports of bacterial keratitis associated with the use of multiple-dose containers of topical ophthalmic products. These containers had been inadvertently contaminated by patients who, in most cases, had a concurrent corneal disease or a disruption of the ocular epithelial surface (see **PATIENT COUNSELING INFORMATION, 17**).

5.9 Impairment of Beta-adrenergically Mediated Reflexes During Surgery: The necessity or desirability of withdrawal of beta-adrenergic blocking agents prior to major surgery is controversial. Beta-adrenergic receptor blockade impairs the ability of the heart to respond to beta-adrenergically mediated reflex stimuli. This may augment the risk of general anesthesia in surgical procedures. Some patients receiving beta-adrenergic receptor blocking agents have experienced protracted severe hypotension during anesthesia. Difficulty in restarting and maintaining the heartbeat has also been reported. For these reasons, in patients undergoing elective surgery, some authorities recommend gradual withdrawal of beta-adrenergic receptor blocking agents. If necessary during surgery, the effects of beta-adrenergic blocking agents may be reversed by sufficient doses of adrenergic agonists.

5.10 Angle-Closure Glaucoma: In patients with angle-closure glaucoma, the immediate objective of treatment is to reopen the angle. This may require constricting the pupil. Timolol maleate has little or no effect on the pupil. Istalol should not be used alone in the treatment of angle-closure glaucoma.

5.11 Cerebrovascular Insufficiency: Because of potential effects of beta-adrenergic blocking agents on blood pressure and pulse, these agents should be used with caution in patients with cerebrovascular insufficiency. If signs or

symptoms suggesting reduced cerebral blood flow develop following initiation of therapy with Istalol, alternative therapy should be considered.

5.12 Choroidal Detachment: Choroidal detachment after filtration procedures has been reported with the administration of aqueous suppressant therapy (e.g. timolol).

ADVERSE REACTIONS

6.1 Clinical Trials Experience: Because clinical trials are conducted under widely varying conditions, adverse reaction rates observed in the clinical trials of a drug cannot be directly compared to rates in the clinical trials of another drug and may not reflect the rates observed in practice.

The most frequently reported adverse reactions have been burning and stinging upon instillation in 38% of patients treated with Istalol. Additional reactions reported with Istalol at a frequency of 4 to 10% include: blurred vision, cataract, conjunctival injection, headache, hypertension, infection, itching and decreased visual acuity. The following additional adverse reactions have been reported less frequently with ocular administration of this or other timolol maleate formulations.

Timolol (Ocular Administration): *Body as a whole:* Asthenia/fatigue and chest pain; *Cardiovascular:* Bradycardia, arrhythmia, hypotension, syncope, heart block, cerebral vascular accident, cerebral ischemia, cardiac failure, worsening of angina pectoris, palpitation, cardiac arrest, pulmonary edema, edema, claudication, Raynaud's phenomenon and cold hands and feet; *Digestive:* Nausea, diarrhea, dyspepsia, anorexia, and dry mouth; *Immunologic:* Systemic lupus erythematosus; *Nervous System/Psychiatric:* Dizziness, increase in signs and symptoms of myasthenia gravis, paresthesia, somnolence, insomnia, nightmares, behavioral changes and psychic disturbances including depression, confusion, hallucinations, anxiety, disorientation, nervousness and memory loss; *Skin:* Alopecia and psoriasisiform rash or exacerbation of psoriasis; *Hypersensitivity:* Signs and symptoms of systemic allergic reactions, including angioedema, urticaria, and localized and generalized rash; *Respiratory:* Bronchospasm (predominantly in patients with pre-existing bronchospastic disease), respiratory failure, dyspnea, nasal congestion, cough and upper respiratory infections; *Endocrine:* Masked symptoms of hypoglycemia in diabetic patients (see **WARNINGS AND PRECAUTIONS, 5.6**); *Special Senses:* Signs and symptoms of ocular irritation including conjunctivitis, blepharitis, keratitis, ocular pain, discharge (e.g., crusting), foreign body sensation, itching and tearing, and dry eyes; ptosis, decreased corneal sensitivity; cystoid macular edema; visual disturbances including refractive changes and diplopia; pseudophthalmic; choroidal detachment following filtration surgery (see **WARNINGS AND PRECAUTIONS, 5.12**); *Urogenital:* Retroperitoneal fibrosis, decreased libido, impotence, and Peyronie's disease.

6.2 Postmarketing Experience

Oral Timolol/Oral Beta-blockers: The following additional adverse effects have been reported in clinical experience with ORAL timolol maleate or other ORAL beta-blocking agents may be considered potential effects of ophthalmic timolol maleate: *Allergic:* Erythematous rash, fever combined with aching and sore throat, laryngospasm with respiratory distress; *Body as a Whole:* Extremity pain, decreased exercise tolerance, weight loss; *Cardiovascular:* Worsening of arterial insufficiency, vasodilatation; *Digestive:* Gastrointestinal pain, hepatomegaly, vomiting, mesenteric arterial thrombosis, ischemic colitis; *Hematologic:* Nonthrombocytopenic purpura; thrombocytopenic purpura, agranulocytosis; *Endocrine:* Hyperglycemia, hypoglycemia; *Skin:* Pruritus, skin irritation, increased pigmentation, sweating; *Musculoskeletal:* Arthralgia; *Nervous System/Psychiatric:* Vertigo, local weakness, diminished concentration, reversible mental depression progressing to catatonia, an acute reversible syndrome characterized by disorientation for time and place, emotional lability, slightly clouded sensorium and decreased performance on neuropsychometrics; *Respiratory:* Rales, bronchial obstruction; *Urogenital:* Urination difficulties.

DRUG INTERACTIONS

7.1 Beta-Adrenergic Blocking Agents: Patients who are receiving a beta-adrenergic blocking agent orally and Istalol® should be observed for potential additive effects of beta-blockade, both systemic and on intraocular pressure. The concomitant use of two topical beta-adrenergic blocking agents is not recommended.

7.2 Calcium Antagonists: Caution should be used in the co-administration of beta-adrenergic blocking agents, such as Istalol, and oral or intravenous calcium antagonists because of possible atrioventricular conduction disturbances, left ventricular failure, and hypotension. In patients with impaired cardiac function, co-administration should be avoided.

7.3 Catecholamine-Depleting Drugs: Close observation of the patient is recommended when a beta blocker is administered to patients receiving catecholamine-depleting drugs such as reserpine, because of possible additive effects and the production of hypotension and/or marked bradycardia, which may result in vertigo, syncope, or postural hypotension.

7.4 Digitalis and Calcium Antagonists: The concomitant use of beta-adrenergic blocking agents with digitalis and calcium antagonists may have additive effects in prolonging atrioventricular conduction time.

7.5 CYP2D6 Inhibitors: Potentiated systemic beta-blockade (e.g., decreased heart rate) has been reported during combined treatment with CYP2D6 inhibitors (e.g., quinidine) and timolol.

7.6 Clonidine: Oral beta-adrenergic blocking agents may exacerbate the rebound hypertension which can follow the withdrawal of clonidine. There have been no reports of exacerbation of rebound hypertension with ophthalmic timolol maleate.

USE IN SPECIFIC POPULATIONS

8.1 Pregnancy

Teratogenic Effects: Pregnancy Category C: Teratogenicity studies have been performed in animals. Teratogenicity studies with timolol in mice, rats, and rabbits at oral doses up to 50 mg/kg/day (7,000 times the systemic exposure following the maximum recommended human ophthalmic dose) demonstrated no evidence of fetal malformations. Although delayed fetal ossification was observed at this dose

in rats, there were no adverse effects on postnatal development of offspring. Doses of 1000 mg/kg/day (142,000 times the systemic exposure following the maximum recommended human ophthalmic dose) were maternotoxic in mice and resulted in an increased number of fetal resorptions. Increased fetal resorptions were also seen in rabbits at doses of 14,000 times the systemic exposure following the maximum recommended human ophthalmic dose, in this case without apparent maternotoxicity. There are no adequate and well-controlled studies in pregnant women. Istalol should be used during pregnancy only if the potential benefit justifies the potential risk to the fetus.

8.3 Nursing Mothers: Timolol has been detected in human milk following oral and ophthalmic drug administration. Because of the potential for serious adverse reactions from Istalol in nursing infants, a decision should be made whether to discontinue nursing or to discontinue the drug, taking into account the importance of the drug to the mother.

8.4 Pediatric Use: Safety and effectiveness in pediatric patients have not been established.

8.5 Geriatric Use: No overall differences in safety or effectiveness have been observed between elderly and younger patients.

OVERDOSAGE

There have been reports of inadvertent overdosage with Istalol resulting in systemic effects similar to those seen with systemic beta-adrenergic blocking agents such as dizziness, headache, shortness of breath, bradycardia, bronchospasm, and cardiac arrest. An *in vitro* hemodialysis study, using ¹⁴C timolol added to human plasma or whole blood, showed that timolol was readily dialyzed from these fluids; however, a study of patients with renal failure showed that timolol did not dialyze readily.

NONCLINICAL TOXICOLOGY

13.1 Carcinogenesis, Mutagenesis, Impairment of Fertility: In a two-year study of timolol maleate administered orally to rats, there was a statistically significant increase in the incidence of adrenal pheochromocytomas in male rats administered 300 mg/kg/day (approximately 42,000 times the systemic exposure following the maximum recommended human ophthalmic dose). Similar differences were not observed in rats administered oral doses equivalent to approximately 14,000 times the maximum recommended human ophthalmic dose. In a lifetime oral study in mice, there were statistically significant increases in the incidence of benign and malignant pulmonary tumors, benign uterine polyps and mammary adenocarcinomas in female mice at 500 mg/kg/day, (approximately 71,000 times the systemic exposure following the maximum recommended human ophthalmic dose), but not at 5 or 50 mg/kg/day (approximately 700 or 7,000, respectively, times the systemic exposure following the maximum recommended human ophthalmic dose). In a subsequent study in female mice, in which post-mortem examinations were limited to the uterus and the lungs, a statistically significant increase in the incidence of pulmonary tumors was again observed at 500 mg/kg/day. The increased occurrence of mammary adenocarcinomas was associated with elevations in serum prolactin which occurred in female mice administered oral timolol at 500 mg/kg/day, but not at doses of 5 or 50 mg/kg/day. An increased incidence of mammary adenocarcinomas in rodents has been associated with administration of several other therapeutic agents that elevate serum prolactin, but no correlation between serum prolactin levels and mammary tumors has been established in humans. Furthermore, in adult human female subjects who received oral dosages of up to 60 mg of timolol maleate (the maximum recommended human oral dosage), there were no clinically meaningful changes in serum prolactin. Timolol maleate was devoid of mutagenic potential when tested *in vivo* (mouse) in the micronucleus test and cytogenetic assay (doses up to 800 mg/kg) and *in vitro* in a neoplastic cell transformation assay (up to 100 mcg/mL). In Ames tests the highest concentrations of timolol employed, 5,000 or 10,000 mcg/plate, were associated with statistically significant elevations of revertants observed with tester strain TA100 (in seven replicate assays), but not in the remaining three strains. In the assays with tester strain TA100, no consistent dose response relationship was observed, and the ratio of test to control revertants did not reach 2. A ratio of 2 is usually considered the criterion for a positive Ames test. Reproduction and fertility studies in rats demonstrated no adverse effect on male or female fertility at doses up to 21,000 times the systemic exposure following the maximum recommended human ophthalmic dose.

PATIENT COUNSELING INFORMATION

Patients with bronchial asthma, a history of bronchial asthma, severe chronic obstructive pulmonary disease, sinus bradycardia, second or third degree atrioventricular block, or cardiac failure should be advised not to take this product. (see **CONTRAINDICATIONS, 4.1, 4.2**) Patients should also be instructed that ocular solutions, if handled improperly or if the tip of the dispensing container contacts the eye or surrounding structures, can become contaminated by common bacteria known to cause ocular infections. Serious damage to the eye and subsequent loss of vision may result from using contaminated solutions. (see **WARNINGS AND PRECAUTIONS 5.8**) Patients should also be advised that if they have ocular surgery or develop an intercurrent ocular condition (e.g., trauma or infection), they should immediately seek their physician's advice concerning the continued use of the present multidose container. If more than one topical ophthalmic drug is being used, the drugs should be administered at least five minutes apart. Patients should be advised that Istalol® contains benzalkonium chloride which may be absorbed by soft contact lenses. Contact lenses should be removed prior to administration of the solution. Lenses may be reinserted 15 minutes following Istalol® administration.

Rx Only

Manufactured by:
Bausch & Lomb Incorporated
Tampa, FL 33637

Under License from:
SENJU Pharmaceutical Co., Ltd
Osaka, Japan 541-0046

®/TM are trademarks of Bausch & Lomb Incorporated or its affiliates.
© Bausch & Lomb Incorporated

Based on 9401500

US/IST14/0007 Issued 06/2013

Pupil Testing: Implications for Diagnosis

Diagnosing and managing many retinal and neurological conditions begins with the pupil. These testing techniques and tips can ensure you catch commonly encountered disorders right away. **By Caroline B. Pate, OD**

Pupil testing can reveal serious retinal and neuro-ophthalmic disease and therefore should be incorporated into every comprehensive eye examination. With careful clinical examination, this test can aid in the diagnosis and management of many of these conditions at the primary care level. This article addresses the more commonly encountered pupil disorders and how clinicians can detect them through routine pupil testing.

Neuroanatomy

Meaningful interpretation of pupillary findings requires a solid working knowledge of the anatomy of the light reflex and the autonomic innervation of pupillary responses. The pupillary light and near responses are under parasympathetic innervation. The pupillary light response consists of both an afferent and efferent pathway. The afferent pathway is responsible for transmitting the impulse of the incoming light

via the photoreceptors of the retina, through the optic nerve to the chiasm and optic tract, then separate from the tract just anteriorly to the lateral geniculate body (LGN) before traveling to the mid-brain to bilaterally project to the pretectal nuclei.¹ Pupil fibers synapse in the pretectal nuclei of the midbrain and travel to the two Edinger-Westphal nuclei of the oculomotor nerve (CN III), beginning the efferent pathway.¹

Because of this neuroanatomy, we are able to objectively measure the integrity of the afferent pathway by observing the direct and consensual light responses. For example, the

direct response of the right eye (and consensual response of the left eye) indicates the integrity of the afferent pathway on the right side. This is also the reason why a lesion of the optic nerve or optic tract does not result in anisocoria, or difference in pupil size between the two eyes. Efferent pupil fibers then travel with CN III back towards the orbit, where they synapse in the ciliary ganglion, with 3% of post-ganglionic fibers innervating the iris sphincter muscle (which allows for miosis) and the remaining 97% innervating the ciliary body (which allows for accommodation).¹



Fig. 1. Neutral density filters can be useful in grading relative afferent pupillary defects.

Oculo-sympathetic innervation to the eye consists of a three-neuron arc. Originating in the posterior hypothalamus, the first-order

neuron descends through the brainstem to synapse in the ciliospinal center of Budge between the levels of the eighth cervical and fourth thoracic vertebrae (C8-T4). The second-order neuron leaves the spinal cord and passes over the apex of the lung to synapse at the superior cervical ganglion. Third-order neurons give rise to post-ganglionic axons, which leave the superior cervical ganglion and run along the course of the internal carotid artery through the cavernous sinus, where they meet up with the ophthalmic division of the trigeminal nerve (V1) and ophthalmic artery to travel to the eye. Neurons traveling with the ophthalmic artery go on to innervate Mueller's muscle for eyelid control, whereas those traveling with V1 pass through the ciliary ganglion to innervate the iris dilator muscle, which allows for mydriasis.^{2,3}

The Swinging Flashlight Test

Clinicians use the swinging flashlight test to detect an afferent pupillary defect and should conduct the test in a dark room with a transilluminator or the light from the binocular indirect ophthalmoscope, which are preferred over a handheld penlight due to the intensity of the light. The strength of the direct pupillary response is compared with that of the consensual pupillary response in the *same eye*. When the consensual response is greater than the direct response in the affected eye, the patient has a relative afferent pupillary defect (RAPD), also known as

Pharmacologic Testing for Horner's Syndrome¹⁵

Location of Lesion	For Diagnosis		For Localization	
	Cocaine 10%	Apraclonidine 0.5%-1%	Hydroxyamphetamine 1%	Phenylephrine 1%
Normal pupil (no lesion)	Dilates	Will not dilate	Dilates	Will not dilate
First or second order (pre-ganglionic)	Will not dilate	Dilates pupil (and reverses anisocoria)	Dilates	Will not dilate
Third order (post-ganglionic)			Will not dilate	Dilates

an APD or Marcus Gunn pupil, signifying damage at or anterior to the LGN.⁴ To cause an RAPD, the damage must be unilateral or asymmetric, such as in severe retinal disease, optic nerve disease or compromise, or a lesion behind the eye. Severe but bilaterally equal disease will not result in an RAPD, as a bilateral APD does not exist. In addition, an RAPD cannot be caused by disorders of ocular media or refraction, even if extreme.⁴ Visual acuity does not necessarily correlate with an RAPD; however, clinicians should always look carefully for one in cases of significantly reduced acuity in one eye.

RAPDs can also be assigned a grade using a neutral density filter over the good eye to quantify the defect. Neutral density filters are available in a variety of densities, with 0.3, 0.6, 0.9 and 1.2 log units being most helpful in grading an RAPD (*Figure 1*). Grading can be helpful for identifying subtle defects and monitoring for progression. Newer, high-definition technology is available for pupil diagnostics, allowing for objective, detailed and quantitative measurements of both the direct and consensual light responses.⁵

Because of the consensual response, only one functioning pupil is needed to test for an RAPD in either eye. When testing only one pupil, the swinging flashlight test is performed in the same way as you would with two functioning pupils; however, only the reactive pupil is observed. The direct and consensual responses are compared in the reactive pupil, and if the pupil constricts more with direct illumination than with consensual, then the RAPD is present in the opposite eye with the unreactive pupil. If the reactive pupil constricts more with consensual stimulation than with direct illumination, the RAPD exists in the eye with a reactive pupil. This is known as determining an APD by reverse.

Evaluating Pupil Shape and Size

Pupils should be round, symmetrical and centered within the iris. Pupil size is influenced by smooth muscles under control of the autonomic nervous system, with the iris sphincter (parasympathetic innervation) having more powerful control than the iris dilator (sympathetic innervation) in maintaining pupil size and controlling the amount of light that enters the eye.⁶

Pharmacologic Testing for the Dilated Pupil using Pilocarpine

Finding	Pilocarpine 0.125%	Pilocarpine 1%
Normal pupil	Does not constrict	Constricts
Adie's pupil	Constricts	Constricts
CN III palsy	Usually does not constrict	Constricts
Pharmacologic dilation	Does not constrict	Does not constrict

Pupil Testing

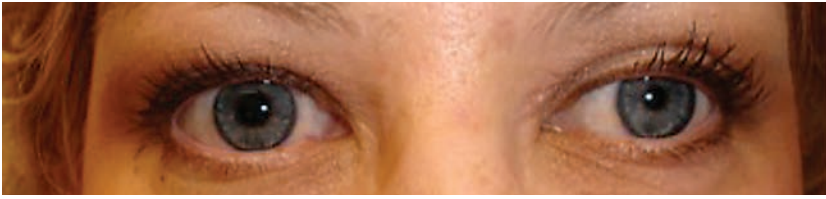

Fig. 2. Horner's syndrome OS with ipsilateral miosis and ptosis.

Due to changes in lighting and accommodation, a patient's pupil size is constantly fluctuating. One of the initial elements of pupil testing should be to measure the patient's pupil diameter to look for any evidence of anisocoria. Under normal illumination, the average adult's pupil size measures around 3.5mm, but can vary from 1.0mm to 10mm and get smaller as one ages due to senile miosis.⁷ A difference of 0.4mm or greater between the two eyes is considered clinically significant.⁸ If a patient has anisocoria, typically only one pupil is abnormal, and the etiology can be either physiologic (which occurs in approximately 20% of normal patients), pharmacologic or pathologic in nature.^{9,10}

Any anisocoria should be further evaluated by re-assessing pupil size in both bright and dark illumination to help isolate the parasympathetic and sympathetic pathways, respectively. If the difference between pupil sizes becomes greater in the bright illumination, the larger pupil is the abnormal one, indicating parasympathetic denervation. If the difference becomes greater in dark illumination, the smaller pupil is the abnormal one due to abnormal sympathetic innervation.

In either situation, a thorough and thoughtful history should accompany any suspected pupil anomaly, which may provide clues to the appropriate diagnosis, such as whether the patient recently took or came into contact with medications or agents that can affect pupil size, or they have a history of recent

trauma or surgery. Clinicians can also look at old photos or a patient's driver's license to better understand the possible onset or duration.

If the anisocoria is physiologic in nature, the difference in pupil size between the two eyes should remain constant in all lighting conditions. Physiologic anisocoria is seldom greater than 1mm, can be variable from day to day and can even switch eyes.^{9,10} No further pharmacologic evaluation is necessary if physiologic anisocoria is suspected, though clinicians should always rule out other neuropathologies.

Pharmacological Pupil Testing

In the presence of a normal pupillary response, pharmacological pupil testing can help differentiate the various causes of anisocoria. First, the clinician will need to determine which pupil is the problematic pupil.

Small Pupil Problems

If the anisocoria is greater in the dark, practitioners should focus on the smaller pupil as the abnormal pupil and investigate impairment of the oculo-sympathetic system. Common causes include:

- **Pharmacologic constriction.** If this is due to systemic drugs such as morphine, heroin or codeine, the miosis is typically bilateral. If the constriction is unilateral, the patient may have used a cholinergic agonist such as pilocarpine or had contact with a specific anticholinesterase agent, such as a flea/tick control product, which can cause a heightened parasympathetic effect.

- **Horner's syndrome.** Also known as oculo-sympathetic paresis, Horner's syndrome represents an interruption somewhere along the long oculo-sympathetic nerve pathway between its origin in the hypothalamus and the eye. The classic triad of symptoms includes unilateral ptosis, ipsilateral miosis and facial anhidrosis—although these findings can be variable in presentation (Figure 2).¹¹ One-third of cases are idiopathic, with no evident underlying cause.⁴ Another 4% to 13% are of congenital etiology and are characterized by iris heterochromia, with the lighter iris being the affected eye.^{4,12}

Congenital cases result from trauma sustained during delivery or an idiopathic cause occurring before age two.¹² Common etiologies of acquired preganglionic Horner's syndrome include, but are not limited to: stroke, trauma, surgery, aortic or carotid artery dissection, Pancoast tumor and tuberculosis. Postganglionic acquired causes include trauma, painful cluster migraine headaches (Raeder's syndrome), giant cell arteritis and neck/thyroid surgery.² A detailed history and diagnostic imaging can help to differentiate between some of the causes of acquired Horner's syndrome.

Looking for evidence of a "dilation lag" in suspected Horner's syndrome can be helpful, as the Horner's pupil will be delayed in its dilation in a dark room. The anisocoria will be most evident about four to five seconds after the lights are turned off, then the abnormal pupil will slowly begin to dilate over the next 10 to 15 seconds, making the anisocoria less evident the longer the patient remains in the dark room.^{13,14} This dilation lag is a classic diagnostic sign of Horner's syndrome and occurs secondary to passive dilation from relaxation of the iris sphincter in the Horner's

Looking deeper

Exploring innovation

Shire's Vision for Ophthalmics

At Shire, we're a leading biotech with a global track record for our work in rare diseases and specialty conditions.

Now we're expanding our vision and bringing the same commitment to ophthalmics. Pursuing the promise of new therapies in ophthalmics to address patients' unmet needs.

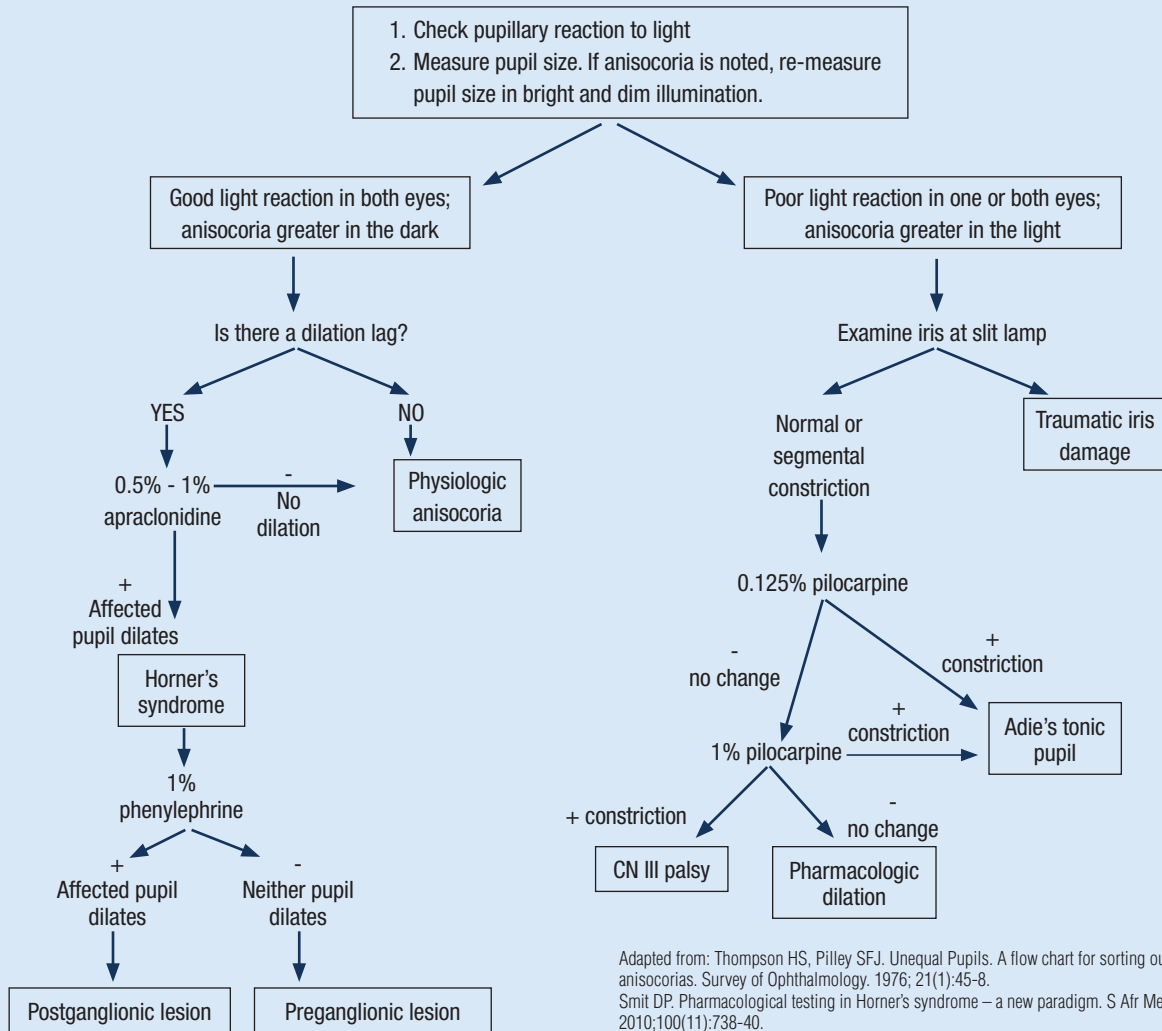
Just watch.

Visit Shire-Eyes.com



Pupil Testing

Anisocoria Evaluation Flow Chart



pupil as opposed to rapid, active dilation of a pupil with intact sympathetic function and a working dilator muscle.¹⁴ Pharmacologic testing will help confirm the diagnosis and further help localize the lesion to narrow down the differentials.

Topical cocaine 4% to 10% was initially used to confirm the diagnosis of Horner's syndrome, as it blocks reuptake of norepinephrine at the nerve ending. The excess norepinephrine will cause a normal pupil to dilate, but a Horner's pupil will fail to dilate because of the absence of norepinephrine at the receptor

site.^{2-4,15} However, cocaine is difficult to obtain due to its scheduling status and has potential adverse side effects to the central nervous system. Recent literature has discussed a more favorable approach to confirming Horner's syndrome using Iopidine (apraclonidine, Alcon).^{15,16} Iopidine is a readily available alpha-adrenergic receptor agonist typically used for its short-acting IOP lowering properties. Instilling one drop of 0.5% or 1% Iopidine results in dilation of a Horner's pupil and the reversal of the anisocoria with the miotic pupil becoming larger than

the normal pupil.^{15,16} Iopidine has little to no effect on a normal pupil.^{15,16} Clinically, dilation of 1mm or more is needed to confirm the presence of Horner's.¹⁶ Clinicians should measure pupil size approximately 30 to 45 minutes after drop instillation.

Following confirmation of the diagnosis of Horner's syndrome, the next clinical step is to differentiate the lesion's location. Twenty-four to 48 hours following testing with Iopidine or topical cocaine, practitioners can use pharmacologic testing with two drops of 1% Paredrine (hydroxyamphetamine, Akorn) to



We've Got Your Back

You Can Rely on M&S for Stellar Service and Support

At M&S, we pride ourselves on having the best and most responsive service in the industry. Every **Smart System**[®] comes with one year of free maintenance, and extended service warranty plans are available beyond the first year. If any issues arise that cannot be resolved over the phone (all our technicians are in-house so you won't be transferred overseas), our "Spare in the Air" program assures that you will be up-and-running with a loaner unit within 24 hours.

We take your business as seriously as you do. If you're looking for a high-quality, comprehensive visual acuity testing system that is not only robust but comes with the best customer service and most attentive technical support in the industry, give us a call.



The Smart System 20/20 USA, shown with optional Glare Lights



MANUFACTURED
IN THE USA

See us in Booth 842 at the Vision Source Exchange!



M&S holds US Patents 7,354,155;
7,926,948; 8,425,040; 8,167,429;
8,419,184 & 8,550,631.
Other Patents Pending.

M&S[®]
TECHNOLOGIES

The First Choice in
Vision Testing Systems

www.mstech-eyes.com
1-877-225-6101

©2016 M&S Technologies, Inc. Smart System and M&S are registered trademarks of M&S Technologies, Inc. All Rights Reserved.

Pupil Testing

Photos: Mark Swanson, OD

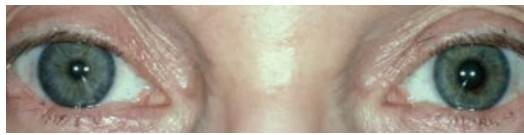

Fig 3. Above, the patient has anisocoria with a suspected left tonic pupil. Below, post-pharmacologic testing with 0.125% pilocarpine shows constriction OS, demonstrating denervation supersensitivity.

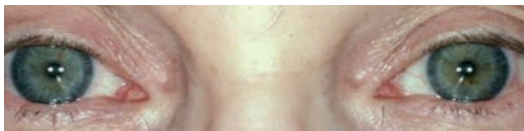

Photo: Mark Swanson, OD

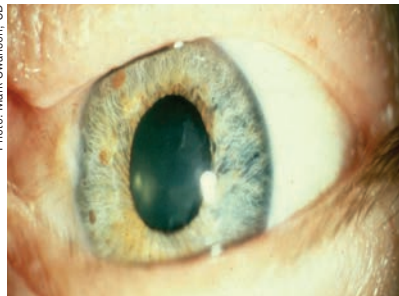


Fig. 4. Segmental iris paralysis noted in tonic pupils, best observed under slit lamp magnification.

identify postganglionic (superior cervical ganglion to pupil) lesions from central or preganglionic lesions. Paredrine dilates a first- or second-order neuron lesion, as well as normal pupils, by releasing stored norepinephrine from the postganglionic axon terminals into the neuromuscular junction at the iris dilator.¹⁵ There is no pharmacological test to differentiate between a first- and second-order neuron lesion. In a Horner's syndrome secondary to a postganglionic lesion, these fibers are damaged and the Paredrine fails to dilate the pupil, causing the degree of anisocoria to remain the same.

Because Paredrine is also difficult to obtain, phenylephrine 1% is often available, which can be diluted if needed from 2.5% solution, and should dilate a postganglionic Horner's syndrome due to denervation super-sensitivity but not those due to central or preganglionic causes.¹⁷ Denervation super-sensitivity takes time to develop, so in acute onset cases, this may not hold true. Although it is recommended that clinicians wait 24 to 48 hours between pharmacological tests, there may be situations in which stat imaging would take precedence over attempting to localize a lesion. The patient's history—whether the Horner's is isolated or if there are associated findings such as diplo-

pia, cranial nerve palsy, numbness, headache or pain—can help guide the management approach.

Prompt imaging would be indicated in situations that point to a life-threatening etiology of Horner's.

- **Other oculo-sympathetic innervation problems.** Sympathetic spasms are rare and can involve the entire pupil (inter-

mittent mydriasis) or any segment of the pupil (tadpole-, or keyhole-shaped pupil). Many of these cases are benign in nature and occur most commonly in young females.¹⁸ Several reported cases have been later found to develop ipsilateral Horner's syndrome, and the initial spasm is attributed to the firing of "sick neurons."¹⁸ Thus, clinicians should test for Horner's in these cases.¹⁸

- **Argyll-Robertson pupils.** Bilaterally small and irregular pupils with a near response markedly better than the light response (also known as "light-near dissociation") are known as Argyll-Robertson pupils.⁴ Although the miosis is bilateral, it is often asymmetric, and these pupils are typically very difficult to dilate, which can help confirm the diagnosis.¹⁵ Because of the association with chronic syphilis, systemic laboratory testing, including FTA-Abs and VDRL, should be included in these

patients' workup.

Big Pupil Problems

If the anisocoria is greater in bright illumination, clinicians should focus on the larger pupil and investigate for parasympathetic denervation. Common causes include:

- **Pharmacologic dilation.** Many pharmacologic agents can result in pupillary dilation, and a careful history is needed to help rule out these causes. Anticholinergics that can result in dilation include agents such as scopolamine found in motion sickness patches or permethrin found in insecticides. Contact with various plant species such as angel's trumpet, jimson weed and belladonna can also result in pupil dilation.¹⁹ Many OTC products containing phenylephrine—including antihistamines, redness relief drops and anti-itch creams—may also be common culprits resulting in pharmacologic dilation. Pharmacologically dilated pupils will not constrict with 1% pilocarpine.

- **Tonic pupils.** Lesions of the ciliary ganglion or short posterior ciliary nerves within the orbit will produce a tonic pupil, characterized by findings such as segmental iris paralysis, light-near dissociation, tonicity to light and accommodation responses and denervation hypersensitivity to dilute cholinergic agents such as pilocarpine.^{1,4,20} Causes of a tonic pupil can include orbital trauma, viral illness, diabetes and syphilis.^{1,4} In older patients, clinicians should obtain an erythrocyte sedimentation rate (ESR) to rule out giant cell arteritis. When the tonic pupil is idiopathic, which is most often the case in 20- to 40-year-old females, the term Adie's tonic pupil is used.^{1,4} Testing of deep tendon reflexes in the knee and ankle is often helpful to diagnose Adie's syndrome, in which these reflexes are markedly diminished or absent.^{1,20}

Due to denervation hypersensitivity of the iris sphincter, tonic pupils will constrict with a weak concentration of 0.125% pilocarpine, whereas this concentration is ineffective in normal pupils (*Figure 3*).^{1,4,15}

Commercially available pilocarpine can be diluted in office using seven drops of saline to one drop of 1% pilocarpine, or 15 drops of saline to one drop of 2% pilocarpine. Clinicians can mix the agents in a contact lens case, using a syringe to ensure equal saline and pilocarpine drop sizes when mixing.

Frequently, tonic pupils are diagnosed behind the slit lamp. Clinicians can use the biomicroscope to look for segmental pupillary sphincter palsies or segmental constriction found in tonic pupils to assist in the diagnosis (*Figure 4*). Turning the rheostat on and off while the light beam is placed at the pupil margin can be helpful to look for these characteristic findings.

There is no definitive treatment for patients with tonic pupils. Mild miotics such as brimonidine, low-dose pilocarpine or specialty iris-simulating contact lenses may be helpful for patients symptomatic for glare caused by the mydriasis.^{1,4} The tonic pupil is usually unilateral, but can become bilateral at a rate of approximately 4% per year.¹ In addition, the amount of anisocoria tends to gradually diminish, as the larger tonic pupil becomes more miotic over time.^{1,4}

• **Cranial nerve III palsy.** The typical presentation in an isolated CN III palsy is ptosis along with exotropia and hypotropia causing the eye to be in a “down and out” position (*Figure 5*). Because the pupillary fibers are located close to the surface of CN III, they are more susceptible to compression via a mass or aneurysm and are more likely to result in a pupil-involving CN III palsy.⁴

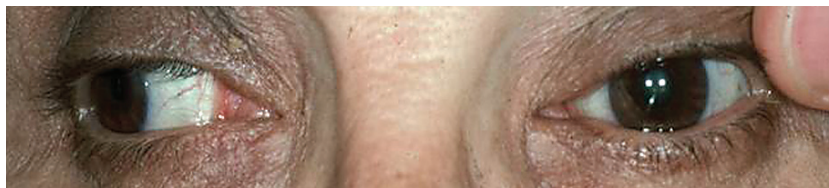

Fig. 5. Pupil involving CN III palsy in the left eye.

In all cases of pupillary involvement, immediate neurosurgical consult with neuroimaging and angiography is indicated. Ensure this occurs by sending the patient to the emergency department immediately and notify the hospital in advance of the incoming patient with the potential for a life-threatening condition.

An aneurysm of the posterior communicating artery presents with a CN III palsy 30% to 60% of the time.²³ In addition, other causes such as tumors and trauma must also be ruled out in pupil-involving CN III palsies.²³ Although pupil-sparing CN III palsies tend to be ischemic in nature, this rule is not absolute, as pupil-sparing may become pupil-involving over time.²¹ Up to 14% of CN III palsies due to aneurysm may not show pupil involvement in the early stages.²³ Careful and close follow up is indicated for all patients in which the pupil is spared—especially if there is no underlying systemic diabetes or hypertension.

Visual acuity tends to be unaffected in these patients, and the pupil will constrict with 1% pilocarpine. Clinicians should always consider consulting with a neurologist, even when they suspect a CN III palsy not caused by an aneurysm.

Careful observation of the pupils can reveal important information about the autonomic nervous system, and further evaluation with pharmacologic testing can help confirm sympathetic or parasympathetic deficits. These clinical observations and tests can ensure ODs provide

patients and comanaging practitioners the information necessary for appropriate treatment, even for those who may not even know they have a neurological condition. ■

Dr. Pate is an associate professor at the UAB School of Optometry in Birmingham, AL.

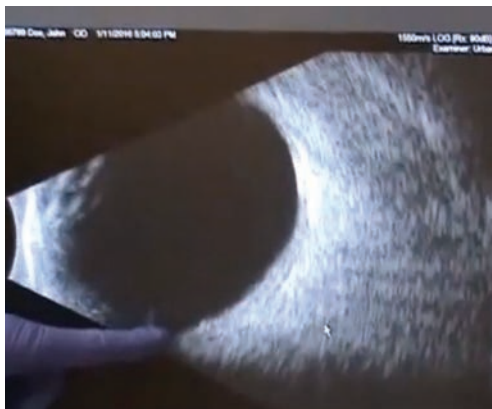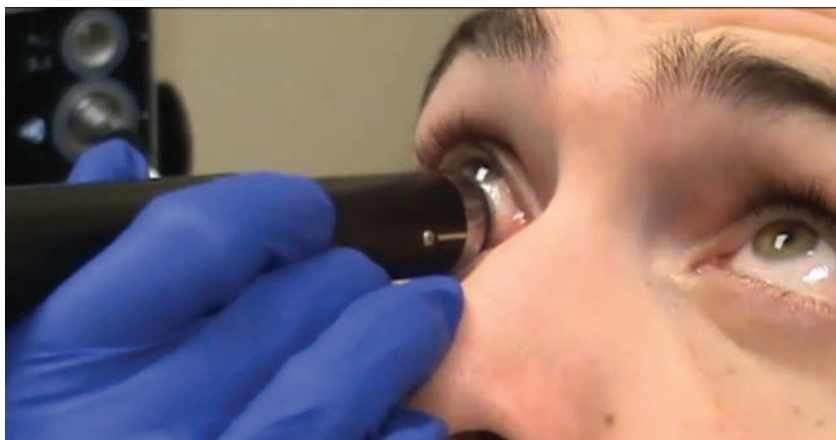1. Gurwood AS, Lehn LE. Tonic Pupils. *Optometry Today*. 1999;39(13):37-9.
2. Patel S, Ilsen PF. Acquired Horner's syndrome: clinical review. *Optometry*. 2003;74(4):245-56.
3. Gurwood AS. Horner's Syndrome. *Optometry Today*. 1999;39(11):36-7.
4. Wilhelm H. Neuro-ophthalmology of pupillary function – practical guidelines. *J Neurol*. 1998;245(9):573-83.
5. Konan Medical USA. RAPDx. Accessed 18 Jan 2016. <http://konanmedical.com/rapid/>.
6. Purves D, Augustine GJ, Fitzpatrick D, et al. *Neuroscience*. 4th ed. Sunderland, MA: Sinauer Associates; 2008:290-1.
7. Pensyl CD, Benjamin WJ. *Ocular Motility*. Borish's Clinical Refraction 2nd ed. St. Louis: Butterworth Heinemann Elsevier; 2006:356-65.
8. Loewenfeld IE. Simple, central anisocoria: A common condition seldom recognized. *Trans Am Acad Ophthalmol Otolaryngol*. 1977;83:832.
9. Lam BL, Thompson HS, Corbett JJ. The prevalence of simple anisocoria. *Am J Ophthalmol*. 1987 Jul 15;104(1):69-73.
10. Rosenberg ML. Physiologic anisocoria: A manifestation of physiologic sympathetic asymmetry. *Neuro-Ophthalmology*. 2008;32:147-9.
11. Walton K, Buono L. Horner syndrome. *Curr Opin Ophthalmol*. 2003;14:357-63.
12. Bell RL, Atweh N, Ivy ME, Possenti P. Traumatic and iatrogenic Horner syndrome: case reports and review of the literature. *J Trauma*. 2001;51(2):400-4.
13. Bremner F. Pupil evaluation as a test for autonomic disorders. *Clin Auton Res*. 2009;19:88-101.
14. Crippa SV, Borrut FX, Kawasaki A. Pupillary dilation lab is intermittently present in patients with a stable oculosympathetic defect (Horner Syndrome). *Am J Ophthalmol*. 2007 Apr;143(4):712-5.
15. Bennetto L, Guly C, Ormerod I, Plant GT. Eye drop neurology. *Pract Neurol*. 2014;14:145-51.
16. Smit DP. Pharmacological testing in Horner's syndrome – a new paradigm. *S Afr Med J*. 2010;100(11):738-40.
17. Danesh-Meyer HV, Savino P, Sergott R. The correlation of phenylephrine 1% with hydroxyamphetamine 1% in Horner's syndrome. *Br J Ophthalmol*. 2004;88:592-3.
18. Balaggon KS, Hugkustone CE, Bremner FD. Episodic segmental iris dilator muscle spasm: The tadpole-shaped pupil. *Arch Ophthalmol*. 2003;121:744.
19. Vunda A, Alcoba G. Mydriasis in the garden. *New Eng J Med*. 2012;367:1341.
20. Leavitt JA, Wayman LL, Hodge DO, Brubaker RF. Pupillary response to four concentrations of pilocarpine in normal subjects: application to testing for Adie tonic pupil. *Am J Ophthalmol*. 2002;133(3):333-6.
21. Kissell JT, Burde RM, Klingele TG, Zeiger HE. Pupil-sparing oculomotor palsies with internal carotid-posterior communicating artery aneurysms. *Ann Neurol*. 1983;13:149-54.
22. Thompson HS, Pillely SFJ. Unequal pupils. A flow chart for sorting out the anisocorias. *Survey of Ophthalmology*. 1976;21(1):45-8.
23. Lemos J, Eggenberger E. Neuro-ophthalmological emergencies. *The Neurohospitalist*. 2015; 5(4):223-33.

Scoring an **A⁺** on a B-scan

Master the art of this ultrasound technology. **By Derek Urban, OD, Jennifer Ramey, OD, Ryan Bunch, OD, and Nathan Lighthizer, OD**

What is an optometrist to do when a patient has a condition that prevents you from examining the internal structures of the eye? We've all had patients with opaque corneas, dense cataracts or vitreous hemorrhages that completely or partially obscure our view of the posterior segment by conventional slit-lamp examination or biomicroscopy. In these cases, the best tool at our disposal is B-scan ultrasonography. Ultrasound has been used in eye care since the 1950s for accurately imaging the internal ocular structures when this information is not obtainable by other methods (*Table 1*).¹

It is capable of providing valuable information about the lens, vitreous, retina, choroid, sclera and orbit. B-scan ultrasonography is a painless, noninvasive method that can be performed easily in the clinic, or at a hospital bedside. It can be done safely on adults and



Above, when performing a basic B-scan, the first image to obtain is a transverse 12 o'clock scan. Have the patient look up—at 12 o'clock—and place the probe at 6 o'clock. Point the probe marker nasally, at 3 o'clock for the right eye. At left, the top part of the scan corresponds to the location of the probe marker. Here, the doctor is pointing to the lower part of the screen, or the 9 o'clock position.

children. It can also be a powerful diagnostic tool even when pathology is clinically visible (*Table 1*).

Principles of Ultrasonography

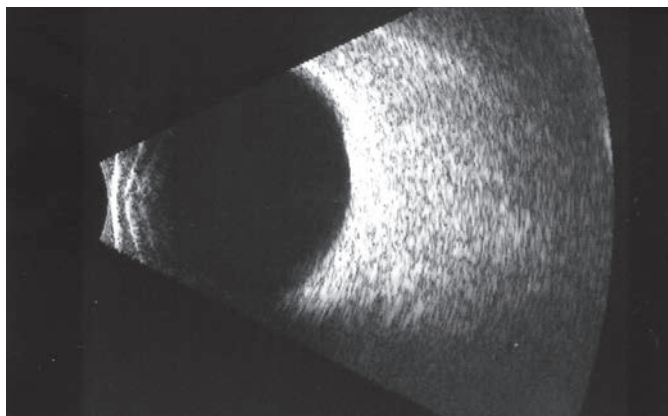
B-scan ultrasound uses high frequency soundwaves that are transmitted from a probe/transducer into the eye. As these soundwaves strike the intraocular structures, an echo is reflected back to the probe and converted into an electrical signal. This signal is then reconstructed into a two-dimensional image on a monitor. The stronger the echo, the brighter the display. This process is repeated 1,000 times per second to produce a real-time display. The soundwaves used are inaudible to human ears because they have a frequency greater than 20KHz. Ophthalmic ultrasound most commonly uses a frequency of 10MHz. This allows for the best combination of tissue penetration and image resolution.

Another important aspect of all ultrasound instruments is the ability to adjust the amplification of echo signals. This is known as the gain control. The gain control is similar to the volume control on a radio. It changes the intensity of the returning echo displayed on the screen. It does not change the amount of energy emitted from the probe. A higher gain level allows for the capture of weaker echoes, such as those caused by vitreous opacities. A lower gain level will filter the weaker echoes, leaving only the strongest echoes, such as optic nerve drusen, the retina and the sclera. Lowering the gain effectively improves the resolution of the display, but in turn will also decrease the depth of the sound beam penetration.

Most ultrasound machines have the ability to use measurement calipers to assess lesion size, depth

Table 1. Indications for B-Scan Ultrasonography

When Direct Visualization is Impossible	When Ocular Structures are Visible
Lid abnormalities	Differentiating iris and ciliary body lesions
Corneal opacities	Ruling out ciliary body detachments
Hyphema/hypopyon	Differentiating intraocular tumors
Miosis	Differentiating serous vs. hemorrhagic choroidal detachments
Dense cataracts	Rhegmatogenous vs. exudative retinal detachments
Vitreous opacities	Differentiating disc drusen vs. disc edema



This B-scan image portrays a normal, healthy eye.

and distances within the eye. Some can zoom in and out, change image position, vary image contrast, save images as movies or pictures, use an A-scan cross vector overlay and generate final reports.

Getting to know all the features of your machine will enhance your ability to perform and interpret a B-scan properly.

Probe Orientations

The B-scan can be used in three different orientations for the eye: transversal, longitudinal and axial.

In a transverse scan, the probe is oriented tangential to the limbus with the probe marker pointing superiorly for vertical scans and oblique scans, or nasally for horizontal scans. You designate

the meridian being scanned by the clock hour in the center of the scan. A transverse scan is used to determine the lateral extent of a lesion.

In a longitudinal scan, the probe is oriented perpendicular to the limbus with the probe marker pointing to the center of the cornea. The scanned meridian is designated by the clock hour opposite of where the marker is placed. A longitudinal scan is used to determine the length (anterior to posterior) of the lesion, or to identify the insertion of mem-



To see a narrated video of this procedure and additional sample B-scan images, visit www.reviewofoptometry.com, or scan this QR code.

Essential Procedures

branes. The imaging of longitudinal scans always displays the anterior eye superiorly and the posterior eye inferiorly.

In an axial scan, the probe is placed on the center of the cornea with the patient looking straight ahead. Although this results in poor resolution of scans due to imaging through the dense media of the natural lens, axial scans are useful for locating lesions in the posterior pole and determining where lesions are in relation to anatomical markers such as the optic nerve and macula. Axial scans can be done horizontally, vertically or obliquely.

Basic Screening Examination Protocol

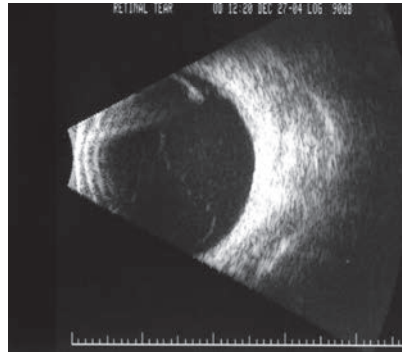
Here is how to perform a B-scan on a patient:

Step 1. Prior to beginning, make sure to disinfect the probe according to the manufacturer's instructions.

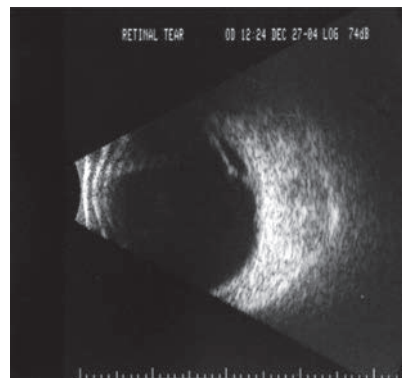
Step 2. Begin by having the patient seated comfortably. The patient can be seated upright or reclined, with the head securely resting on the headrest.

Step 3. Instill one drop of topical anesthetic in each eye. This is especially important if you place the probe on the patient's cornea or conjunctiva.

Step 4. Apply a coupling agent to the probe tip. Often, artificial tear gel or 2.5% methylcellulose



B-scan of a retinal tear on high gain.



B-scan of a retinal tear on low gain.

are used; however, be sure to avoid using abdominal ultrasound gel, as it is considered an ocular irritant.

Step 5. Scan through the different meridians: transverse, longitudinal and axial, moving the probe tip from limbus to the conjunctiva. Make sure to observe the image on the screen while you are recording. (Table 2).

Step 6. Save images as you go (For example, a tangential scan at

12 o'clock on the right eye can be saved as "OD-T12"). This will be beneficial when performing topographical evaluation of the images after completing all the scans.

B-scan Pearls

Here are several tips on high quality scanning images:

- Be sure to direct the patient's gaze away from the probe and toward the meridian being scanned.
- The probe can either be placed on the patient's closed eyelid or, for better resolution and certain globe position, place the probe directly on the conjunctiva.
- Remember that the top of the displayed image always correlates to the mark on the probe.
- Try to keep the probe perpendicular to the tissue being imaged, as doing so will improve resolution.
- Depending on what you are trying to image, developing a routine can be beneficial. For example, start with a tangential scan at 12 o'clock on the right eye, then perform a longitudinal scan at 12 o'clock on the right eye. Move clockwise through the meridians, alternating between transverse and longitudinal. Finish with vertical and horizontal axial scans. Then repeat the pattern on the left eye.
- The center of the scan offers the best resolution; try to center the area of interest in the scans.¹

Topographic Evaluation

Topographic evaluation is performed once a lesion is found; this allows for detailed analysis regarding various aspects of the lesion. Typically, a standard sequence of steps is followed in this process. The transverse orientation is classically done first. The probe is placed on the opposite side of the globe as the lesion and moved from limbus to fornix. Following


Table 2. Basic Screening Protocol Notes

1. **Transverse scans:** Perform transverse scans of the 3, 6, 9, and 12 o'clock meridians. Maneuver the probe into the fornix to image more anterior regions.
2. At minimum, perform **longitudinal scans** of 9 o'clock OD and/or 3 o'clock OS. These scans provide images of the macula. More meridians can be done if indicated.
3. **Axial scans** can be performed vertically or horizontally, or both. Axial scans are good for imaging the posterior pole.

*"The ETDRS chart is a gold standard for work in vision rehabilitation. Until recently, changing charts was a cumbersome task of sliding the plastic chart sheets in and out of the light box. Using Acuity Pro, combined with a 40 inch LCD monitor, we can change charts with the **push of a button**. The optotypes are sharp with no detectable pixelation, even at 1 meter test distance. The brightness of the monitor can be adjusted to match the recommended luminance so testing is truly identical to the original light box method.*

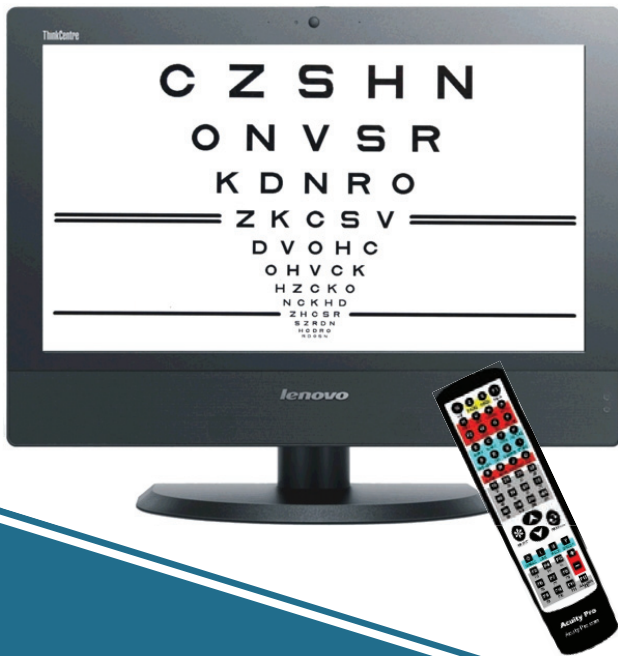*After using Acuity Pro, **I can't imagine practicing without it.**"*

David Lewerenz, OD, FAAO
Clinical Diplomate in Low Vision, American Academy of Optometry
Northeastern State University Oklahoma College of Optometry



EXAM ROOM AT THE
NEW OKLAHOMA
COLLEGE OF
OPTOMETRY LOW
VISION CENTER IN
BROKEN ARROW, OK

LESLIE L. WALLS
LOW VISION CENTER



LARGE SCREEN LED TESTING

The 40" monitor will allow the entire top 20/200 row to be displayed at 4 meters. Plus all the rows down to 20/40 are visible in one view.



MOVABLE TARGET

By mounting the LED monitor on a table with wheels, testing can be done at 4 meters, 2 meters, and 1 meter



ALL ETDRS CHARTS INSTANTLY

Just press the "1" button to cycle through the three original and the three 2000 Series ETDRS charts in their true optotype sequence

- Acuity Pro Digital Acuity Software Suite Version 9 for Windows
- Software only or all in one systems available
- Includes custom remote, pathology images, Looney Tunes clips, Macro app, and Marco TRS compatible

Essential Procedures

this pattern, sound beams gather information regarding the lateral extent of a lesion from posterior to anterior. Following this step, the lesion's anterior to posterior extent is assessed using the longitudinal approach. Again, the probe is placed on the eye opposite the lesion; however, the marker is oriented toward the center of the cornea. Both of these scans together provide valuable information regarding the shape and dimensions of a lesion.

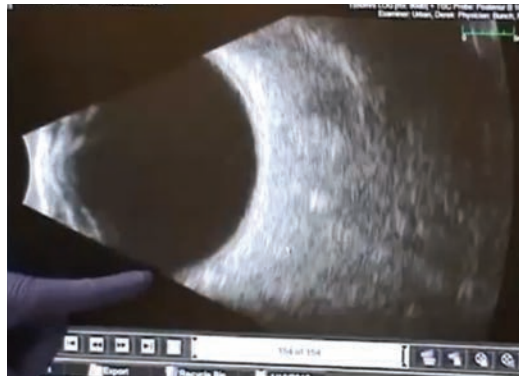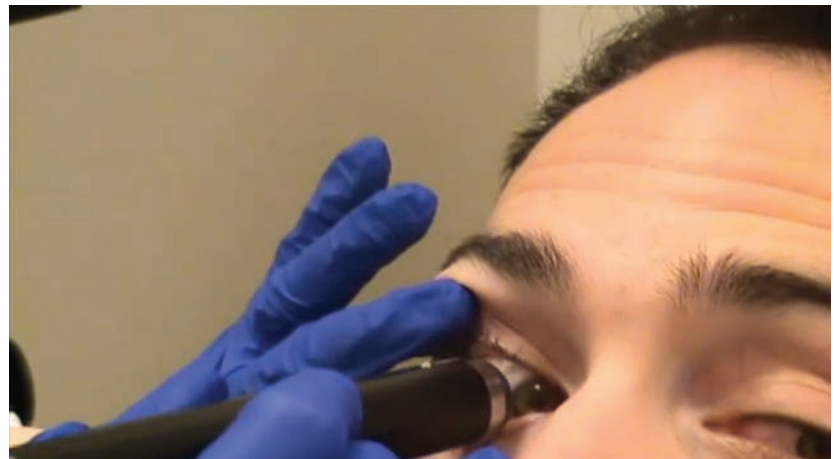Axial scans may be performed to give a three-dimensional feel for the lesion. This additional approach is oriented to include both the lesion and the optic nerve in the same scan. Having multiple orientations is extremely valuable in the diagnosis and description of various ocular conditions. For example, by combining separate axial and transverse scans, a clinician can differentiate whether a funnel-shaped retinal detachment is open or closed.¹

It is also valuable to perform a simultaneous A-scan to gain additional topographical information of lesions such as a choroidal mass.

B-Scan Interpretation

Any review of B-scan ultrasound would be incomplete without discussing proper interpretation of the scan results. This brief review covers the most common findings in different ocular structures:

- **Vitreous.** When examining the vitreous cavity on a B-scan, common conditions, such as a posterior vitreous detachment, can be evaluated and easily differentiated from more serious abnormalities such as a vitreous hemorrhage. In a young, healthy eye, the vitreous is mostly echolucent. When vitreous degeneration occurs, the cholesterol crystals within the liquefied vitreous will float and move within the vitre-



Above, the patient undergoes a transverse 3 o'clock scan. The patient looks nasally while the probe is placed at the 9 o'clock position with the probe marker oriented at 12 o'clock. At left, the top of this scan is the 12 o'clock position, the middle is the 3 o'clock position and the bottom is the 9 o'clock position.

ous cavity. On B-scan, these crystals will show as hyper-reflective foci within the vitreous cavity. If viewed dynamically, they will actually move as the eye moves. When a vitreous detachment occurs, the B-scan will show a reduced volume of the vitreous gel, with a clear delineation between the gel and liquid vitreous.

Vitreous hemorrhage—a result of tearing due to conditions such as vitreoretinal traction, diabetic retinopathy and blunt trauma—will appear in a B-scan as low-intensity echoes within the vitreous cavity. This too will have movement with dynamic scanning. The echographic pattern of a vitreous hemorrhage will depend on its age and severity. Fresh mild hemorrhages appear as small dots or linear areas of low reflective mobile vitreous opacities, whereas in more severe older hemorrhages, blood organizes and

forms membranes. Vitreous hemorrhages may also layer inferiorly, due to gravitational forces.

Asteroid hyalosis is a benign condition wherein calcium salts accumulate in the vitreous cavity. The calcium is relatively dense and produces multiple pinpoint, highly reflective vitreous opacities. Intraocular foreign bodies can be easily detected using ultrasound.

Ultrasound has the advantage of more precisely localizing the foreign object than other imaging modalities, such as CT or MRI. This can be extremely useful information for the surgeon removing the foreign body.

- **Retina.** When examining the retina on B-scan, conditions such as a retinal tear, retinal detachment and retinoschisis can be clearly differentiated. A retinal tear will appear on longitudinal scans as a

NEW YEAR, NEW DEALS, LET'S WORK SIDE BY SIDE

2016 SHOW SPECIAL PRICE

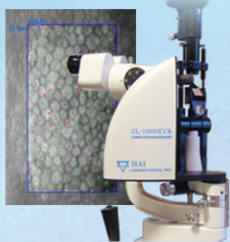
	LIST PRICE	SHOW PRICE
Basic Exam Lane Package	\$12,998	\$12,500
SL-5000LED Slit Lamp	-\$5,500	\$3,500
SL-5000p Plus Slit Lamp	-\$6,300	\$4,500
SL-5000s Standard Lamp	-\$4,800	\$2,990
SL-5000bx Basic Slit Lamp	-\$3,800	\$1,990
SL-5000h Handheld Slit Lamp	-\$3,150	\$2,380
VC-170 17" LED Vision Chart	-\$2,500	\$1,500
A/B-6100 A/B Ultrasonic Scan	\$12,000	\$8,000
CL-1000eva Specular Attachment	\$14,500	\$13,500

Visit us at
Vision East
Booth
#MS6502

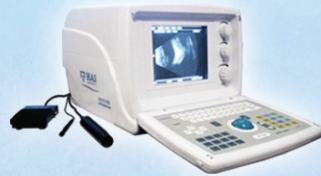

**Basic
Exam
Lane
Package**

*Basic Exam Lane Package including: HAI SL-5000bx, HAI VC-170 LED Vision Chart, S4OPTIK CB-1800 Chair/Stand Combo and SL-Y100 Refractor



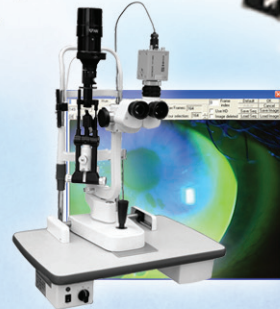**HAI CL-1000eva Endothelium
Viewing Attachment**



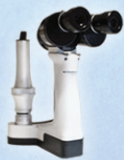**HAI AB-6100
A/B Ultrasonic Scan**



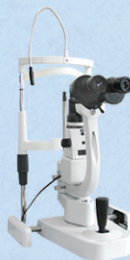**VC-170"
LED Vision Chart**



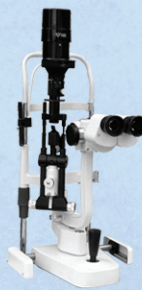**HAI SL-5000
Digital Video Slit Lamp**



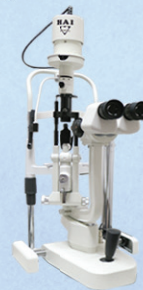**HAI SL-5000h
Handheld Slit Lamp**



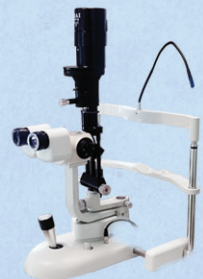**HAI SL-5000bx
Basic Slit Lamp**



**HAI SL-5000s
Standard Slit Lamp**



**HAI SL-5000p
Plus Slit Lamp**



**HAI SL-5000e
Elevate Slit Lamp**

Slit lamps • Specular microscopes • Corneal topographers • Keratometers • Ultrasounds • Vision charts and testers • Autorefractors
Lensmeters • Pachymeters • Tonometers • Trial lens sets • Chairs and stands • Digital imaging solutions



HAI Ophthalmic is a division of HAI Laboratories, Inc., an ISO 13485-certified US manufacturer.

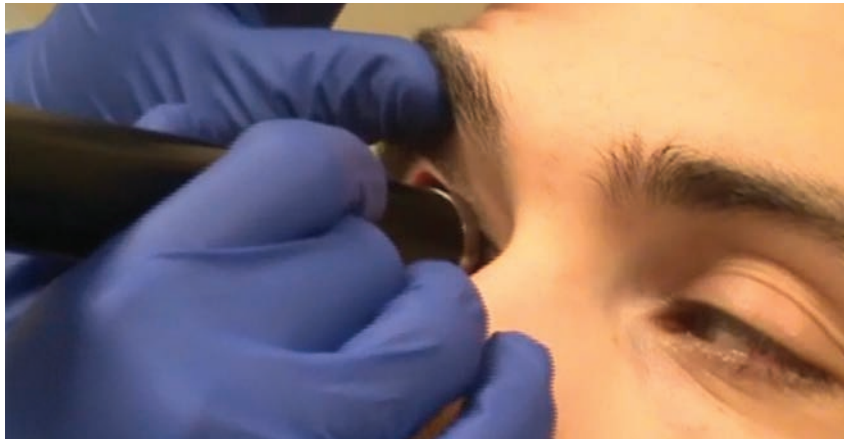Visit us at www.hailabs.com and www.haiophthalmic.com

Call (781) 862-9884 or e-mail sales@hailabs.com for a free consultation.

“flap.” On occasion, the flap will still be connected to the posterior vitreous surface or membrane. Subretinal fluid may form beneath the flap, elevating it further. A retinal detachment will show a highly reflective, undulating membrane (if viewed dynamically) on the B-scan. If it is a total retinal detachment, typically a funnel shape will be observed as the retina is still attached at the ora serrata and the optic nerve, typically. Retinoschisis, while difficult to differentiate from a retinal detachment on funduscopy, can be further evaluated using a B-scan. On B-scan, retinoschisis will appear dome-shaped, rigid and thin (it will not undulate like a retinal detachment if viewed dynamically).

- **Choroid.** When viewing a B-scan, the choroid appears much thicker than the retina. This is true for normal eyes or when looking at conditions such as a choroidal detachment. A choroidal detachment will appear with a dome-shaped contour; larger detachments may consist of multiple domes that ‘kiss’ in the middle of the vitreous. Traumatic causes of choroidal detachments are often hemorrhagic, rather than serous. The subchoroidal space of a hemorrhagic detachment will show a host of dots, as opposed to a hollow area.

Differentiating between choroidal nevi and melanomas is another useful application for B-scan. Typically, melanomas arising from the choroid appear as smooth, dome-shaped lesions with low to medium internal reflectivity and a regular internal structures. Internal vascularity can also be detected. A classic collar button or mushroom-shaped lesion is evident in tumors that have broken through Bruch’s membrane. Occasionally, choroidal evacuation is seen at the base of the



The patient undergoes a longitudinal 9 o'clock scan. The patient looks temporally, the probe is placed opposite at 3 o'clock and the probe marker is pointed toward the 9 o'clock meridian.

tumor, which represent the tumor invading further into the choroid. A melanoma can progress still further and extend through the scleral wall, known as extrascleral extension.

A choroidal nevus may appear to have a dome-shaped appearance as well; however, it differs from a melanoma in that it has high reflectivity and lacks internal vascularity.

Unfortunately, small melanomas may show an absence of low internal reflectivity and, therefore, may be difficult to differentiate from a small benign nevus.

Metastatic tumors have a much different echographic appearance. These tumors usually have an irregular, lumpy contour, an irregular internal structure, a medium-to-high internal reflectivity and little evidence of internal vascularity. Although exudative detachments occur with choroidal melanomas, similar-sized metastatic tumors typically have more extensive detachments. Extrascleral extension also can be seen with these tumors and is generally not helpful in the differentiation of the tumor.

- **Ciliary Body.** The ciliary body is visualized best with high-resolution scanning; however, a ciliary body detachment can extend into

the peripheral choroid and can be seen on contact B-scan. A low-to-medium reflective cleft can be seen in the subciliary space. Ciliary body tumors are similar to those seen in the choroid and have similar echographic characteristics. Although most ciliary body tumors are melanomas, a variety of other tumors do arise in the ciliary body, including metastatic tumors, medulloepitheliomas and leiomyomas.

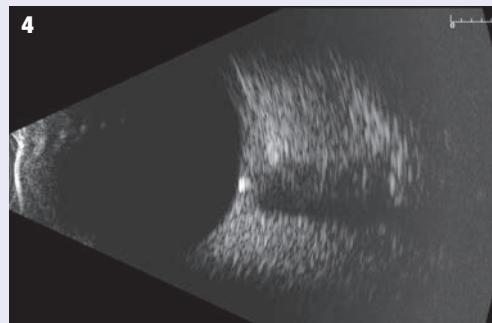
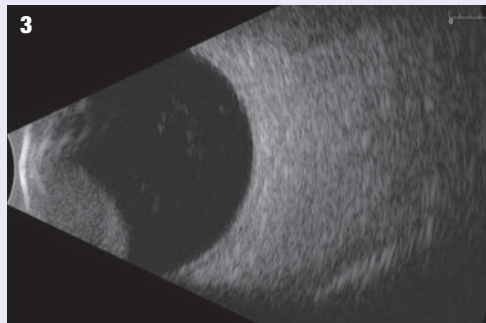
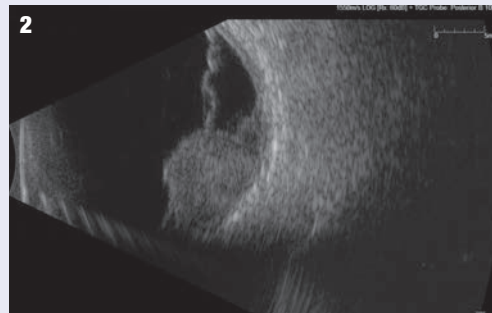
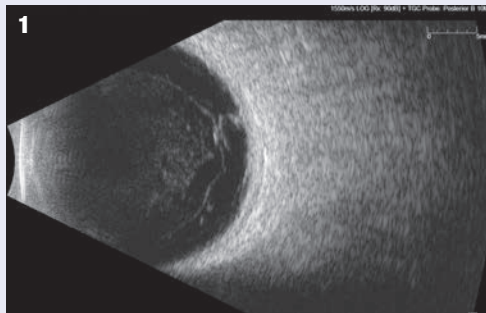
- **Optic Nerve.** Without interference of media opacities, the shape of the optic nerve, including the cup, is detectable with ultrasound. Differentiating the cause of a swollen optic nerve is a common clinical indication for B-scan. Papilledema, which is the result of increased intracranial pressure, will show a slightly widened optic nerve. With more elevated pressure, a black, empty-appearing area within the optic nerve sheath is apparent. This is known as a crescent sign and signifies the separation of sheath from optic nerve. Optic disc drusen, which can simulate papilledema, appear as highly reflective entities at the base of the optic nerve head.

Ultrasound can also be used to detect and differentiate optic nerve

Disease Scans

These are a few examples of the pathologies that can be imaged using B-scan ultrasonography.

1. Posterior vitreous detachment with macular traction.
2. Choroidal melanoma with overlying retinal detachment.
3. Ciliary body tumor.
4. Optic nerve drusen.



tumors, such as gliomas and meningiomas. An optic nerve glioma is a neoplasm that infiltrates the optic nerve parenchyma. On ultrasound, this is a smooth, fusiform mass with low-to-medium and regular internal reflectivity. An optic nerve sheath meningioma is a tumor of the optic nerve sheath. In contrast to a glioma, this tumor typically has a medium-to-high, irregular internal reflectivity with potential areas of calcification.

Know the Norm

It is vital to have a good grasp of what a normal ultrasound looks like. Not only are there minor differences in normal findings from patient to patient, but variation can exist within the same eye, due to the heterogenous nature of a normal eye. It is highly recommended that you gain as much experience as possible examining a normal eye to better evaluate patients with suspected eye disease.

With increased experience, you will gain the confidence to evaluate a variety of ocular conditions.

As you become more experienced, you can expand your abilities to include more advanced techniques—such as examining the orbit and extraocular muscles. Your practice and, most importantly, your patients will benefit. ■

Dr. Urban is a staff optometrist at the Veterans Health Care System of the Ozarks in Fayetteville, AR.

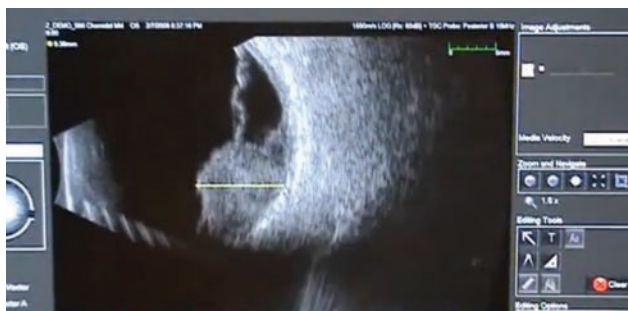Dr. Bunch is currently completing an optometry residency in ocular disease at the Veterans Health

Care System of the Ozarks in Fayetteville, AR.

Dr. Ramey is currently completing an optometry residency in ocular disease at the Veterans Health Care System of the Ozarks in Fayetteville, AR.

Dr. Lighthizer is assistant dean for clinical care services, director of continuing education, and chief of both the specialty care clinic and the electrodiagnostics clinic at NSU Oklahoma College of Optometry.

1. Byrne SF, Green RL. Ultrasound of the eye and orbit, 2nd ed. Philadelphia, PA: Mosby, 2002:544.



Software that accompanies ultrasound devices—such as the caliper tools being employed here—can measure any lesions discovered.

★ ★ ★ THE MAIN EVENT ★ ★ ★

ZYLET[®]

"A ONE-TWO COMBO"

VS

BLEPHARITIS

**HELP PUT RELIEF
IN YOUR CORNER**

INDICATIONS AND USAGE

ZYLET[®] (loteprednol etabonate 0.5% and tobramycin 0.3% ophthalmic suspension) is a topical anti-infective and corticosteroid combination for steroid-responsive inflammatory ocular conditions for which a corticosteroid is indicated and where superficial bacterial ocular infection or a risk of bacterial ocular infection exists.

Please see additional Indications and Usage information on adjacent page, including list of indicated organisms.

INDICATIONS AND USAGE (continued)

Ocular steroids are indicated in inflammatory conditions of the palpebral and bulbar conjunctiva, cornea and anterior segment of the globe such as allergic conjunctivitis, acne rosacea, superficial punctate keratitis, herpes zoster keratitis, iritis, cyclitis, and where the inherent risk of steroid use in certain infective conjunctivides is accepted to obtain a diminution in edema and inflammation. They are also indicated in chronic anterior uveitis and corneal injury from chemical, radiation or thermal burns, or penetration of foreign bodies.

The use of a combination drug with an anti-infective component is indicated where the risk of superficial ocular infection is high or where there is an expectation that potentially dangerous numbers of bacteria will be present in the eye.

The particular anti-infective drug in this product (tobramycin) is active against the following common bacterial eye pathogens: *Staphylococci*, including *S. aureus* and *S. epidermidis* (coagulase-positive and coagulase-negative), including penicillin-resistant strains. *Streptococci*, including some of the Group A-beta-hemolytic species, some nonhemolytic species, and some *Streptococcus pneumoniae*, *Pseudomonas aeruginosa*, *Escherichia coli*, *Klebsiella pneumoniae*, *Enterobacter aerogenes*, *Proteus mirabilis*, *Morganella morganii*, most *Proteus vulgaris* strains, *Haemophilus influenzae*, and *H. aegyptius*, *Moraxella lacunata*, *Acinetobacter calcoaceticus* and some *Neisseria* species.

IMPORTANT SAFETY INFORMATION

- ZYLET® is contraindicated in most viral diseases of the cornea and conjunctiva including epithelial herpes simplex keratitis (dendritic keratitis), vaccinia, and varicella, and also in mycobacterial infection of the eye and fungal diseases of ocular structures.
- Prolonged use of corticosteroids may result in glaucoma with damage to the optic nerve, defects in visual acuity and fields of vision. Steroids should be used with caution in the presence of glaucoma. If this product is used for 10 days or longer, intraocular pressure should be monitored.
- Use of corticosteroids may result in posterior subcapsular cataract formation.
- The use of steroids after cataract surgery may delay healing and increase the incidence of bleb formation. In those diseases causing thinning of the cornea or sclera, perforations have been known to occur with the use of topical steroids. The initial prescription and renewal of the medication order should be made by a physician only after examination of the patient with the aid of magnification such as a slit lamp biomicroscopy and, where appropriate, fluorescein staining.
- Prolonged use of corticosteroids may suppress the host response and thus increase the hazard of secondary ocular infections. In acute purulent conditions, steroids may mask infection or enhance existing infections. If signs and symptoms fail to improve after 2 days, the patient should be re-evaluated.
- Employment of corticosteroid medication in the treatment of patients with a history of herpes simplex requires great caution. Use of ocular steroids may prolong the course and exacerbate the severity of many viral infections of the eye (including herpes simplex).
- Fungal infections of the cornea are particularly prone to develop coincidentally with long-term local steroid application. Fungus invasion must be considered in any persistent corneal ulceration where a steroid has been used or is in use.
- Most common adverse reactions reported in patients were injection and superficial punctate keratitis, increased intraocular pressure, burning and stinging upon instillation.

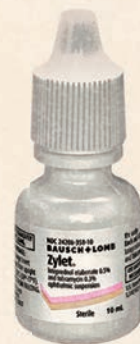Please see Brief Summary of Prescribing Information on the following page.

With a one-two combo in
the treatment of blepharitis
and other steroid-responsive
ocular conditions with the
risk of bacterial infection,
PRESCRIBE ZYLET® TODAY.

BAUSCH + LOMB

©/™ are trademarks of Bausch & Lomb Incorporated or its affiliates.
© 2015 Bausch & Lomb Incorporated. All rights reserved. Printed in USA. US/ZYL/15/0013a

Zylet®
loteprednol etabonate
0.5% and tobramycin 0.3%
ophthalmic suspension



BRIEF SUMMARY OF PRESCRIBING INFORMATION

This Brief Summary does not include all the information needed to use Zylet safely and effectively. See full prescribing information for Zylet.

Zylet[®] (loteprednol etabonate 0.5% and tobramycin 0.3% ophthalmic suspension)
Initial U.S. Approval: 2004

DOSE AND ADMINISTRATION

2.1 Recommended Dosing

Apply one or two drops of Zylet into the conjunctival sac of the affected eye every four to six hours. During the initial 24 to 48 hours, the dosing may be increased, to every one to two hours. Frequency should be decreased gradually as warranted by improvement in clinical signs. Care should be taken not to discontinue therapy prematurely.

2.2 Prescription Guideline

Not more than 20 mL should be prescribed initially and the prescription should not be refilled without further evaluation [see *Warnings and Precautions* (5.3)].

CONTRAINDICATIONS

4.1 Nonbacterial Etiology

Zylet, as with other steroid anti-infective ophthalmic combination drugs, is contraindicated in most viral diseases of the cornea and conjunctiva including epithelial herpes simplex keratitis (dendritic keratitis), vaccinia, and varicella, and also in mycobacterial infection of the eye and fungal diseases of ocular structures.

WARNINGS AND PRECAUTIONS

5.1 Intraocular Pressure (IOP) Increase

Prolonged use of corticosteroids may result in glaucoma with damage to the optic nerve, defects in visual acuity and fields of vision. Steroids should be used with caution in the presence of glaucoma.

If this product is used for 10 days or longer, intraocular pressure should be monitored.

5.2 Cataracts

Use of corticosteroids may result in posterior subcapsular cataract formation.

5.3 Delayed Healing

The use of steroids after cataract surgery may delay healing and increase the incidence of bleb formation. In those diseases causing thinning of the cornea or sclera, perforations have been known to occur with the use of topical steroids. The initial prescription and renewal of the medication order should be made by a physician only after examination of the patient with the aid of magnification such as a slit lamp biomicroscopy and, where appropriate, fluorescein staining.

5.4 Bacterial Infections

Prolonged use of corticosteroids may suppress the host response and thus increase the hazard of secondary ocular infections. In acute purulent conditions of the eye, steroids may mask infection or enhance existing infection. If signs and symptoms fail to improve after 2 days, the patient should be re-evaluated.

5.5 Viral Infections

Employment of a corticosteroid medication in the treatment of patients with a history of herpes simplex requires great caution. Use of ocular steroids may prolong the course and may exacerbate the severity of many viral infections of the eye (including herpes simplex).

5.6 Fungal Infections

Fungal infections of the cornea are particularly prone to develop coincidentally with long-term local steroid application. Fungus invasion must be considered in any persistent corneal ulceration where a steroid has been used or is in use. Fungal cultures should be taken when appropriate.

5.7 Aminoglycoside Hypersensitivity

Sensitivity to topically applied aminoglycosides may occur in some patients. If hypersensitivity develops with this product, discontinue use and institute appropriate therapy.

ADVERSE REACTIONS

Adverse reactions have occurred with steroid/anti-infective combination drugs which can be attributed to the steroid component, the anti-infective component, or the combination.

Zylet:

In a 42 day safety study comparing Zylet to placebo, ocular adverse reactions included injection (approximately 20%) and superficial punctate keratitis (approximately 15%). Increased intraocular pressure was reported in 10% (Zylet) and 4% (placebo) of subjects. Nine percent (9%) of Zylet subjects reported burning and stinging upon instillation.

Ocular reactions reported with an incidence less than 4% include vision disorders, discharge, itching, lacrimation disorder, photophobia, corneal deposits, ocular discomfort, eyelid disorder, and other unspecified eye disorders.

The incidence of non-ocular reactions reported in approximately 14% of subjects was headache; all other non-ocular reactions had an incidence of less than 5%.

Loteprednol etabonate ophthalmic suspension 0.2% - 0.5%:

Reactions associated with ophthalmic steroids include elevated intraocular pressure, which may be associated with infrequent optic nerve damage, visual acuity and field defects, posterior subcapsular cataract formation, delayed wound healing and secondary ocular infection from pathogens including herpes simplex, and perforation of the globe where there is thinning of the cornea or sclera.

In a summation of controlled, randomized studies of individuals treated for 28 days or longer with loteprednol etabonate, the incidence of significant elevation of intraocular pressure (≥ 10 mm Hg) was 2% (15/901) among patients receiving loteprednol etabonate, 7% (11/164) among patients receiving 1% prednisolone acetate and 0.5% (3/583) among patients receiving placebo.

Tobramycin ophthalmic solution 0.3%:

The most frequent adverse reactions to topical tobramycin are hypersensitivity and localized ocular toxicity, including lid itching and swelling and conjunctival erythema. These reactions occur in less than 4% of patients. Similar reactions may occur with the topical use of other aminoglycoside antibiotics.

Secondary Infection:

The development of secondary infection has occurred after use of combinations containing steroids and antimicrobials. Fungal infections of the cornea are particularly prone to develop coincidentally with long-term applications of steroids.

The possibility of fungal invasion must be considered in any persistent corneal ulceration where steroid treatment has been used.

Secondary bacterial ocular infection following suppression of host responses also occurs.

USE IN SPECIFIC POPULATIONS

8.1 Pregnancy

Teratogenic effects: Pregnancy Category C. Loteprednol etabonate has been shown to be embryotoxic (delayed ossification) and teratogenic (increased incidence of meningocele, abnormal left common carotid artery, and limb fixtures) when administered orally to rabbits during organogenesis at a dose of 3 mg/kg/day (35 times the maximum daily clinical dose), a dose which caused no maternal toxicity. The no-observed-effect-level (NOEL) for these effects was 0.5 mg/kg/day (6 times the maximum daily clinical dose). Oral treatment of rats during organogenesis resulted in teratogenicity (absent innominate artery at ≥ 5 mg/kg/day doses, and cleft palate and umbilical hernia at ≥ 50 mg/kg/day) and embryotoxicity (increased post-implantation losses at 100 mg/kg/day and decreased fetal body weight and skeletal ossification with ≥ 50 mg/kg/day). Treatment of rats at 0.5 mg/kg/day (6 times the maximum daily clinical dose) during organogenesis did not result in any reproductive toxicity. Loteprednol etabonate was maternally toxic (significantly reduced body weight gain during treatment) when administered to pregnant rats during organogenesis at doses of ≥ 5 mg/kg/day.

Oral exposure of female rats to 50 mg/kg/day of loteprednol etabonate from the start of the fetal period through the end of lactation, a maternally toxic treatment regimen (significantly decreased body weight gain), gave rise to decreased growth and survival and retarded development in the offspring during lactation; the NOEL for these effects was 5 mg/kg/day. Loteprednol etabonate had no effect on the duration of gestation or parturition when administered orally to pregnant rats at doses up to 50 mg/kg/day during the fetal period.

Reproductive studies have been performed in rats and rabbits with tobramycin at doses up to 100 mg/kg/day parenterally and have revealed no evidence of impaired fertility or harm to the fetus. There are no adequate and well controlled studies in pregnant women. Zylet should be used during pregnancy only if the potential benefit justifies the potential risk to the fetus.

8.3 Nursing Mothers

It is not known whether topical ophthalmic administration of corticosteroids could result in sufficient systemic absorption to produce detectable quantities in human milk. Systemic steroids that appear in human milk could suppress growth, interfere with endogenous corticosteroid production, or cause other untoward effects. Caution should be exercised when Zylet is administered to a nursing woman.

8.4 Pediatric Use

Two trials were conducted to evaluate the safety and efficacy of Zylet[®] (loteprednol etabonate and tobramycin ophthalmic suspension) in pediatric subjects age zero to six years; one was in subjects with lid inflammation and the other was in subjects with blepharoconjunctivitis.

In the lid inflammation trial, Zylet with warm compresses did not demonstrate efficacy compared to vehicle with warm compresses. Patients received warm compress lid treatment plus Zylet or vehicle for 14 days. The majority of patients in both treatment groups showed reduced lid inflammation.

In the blepharoconjunctivitis trial, Zylet did not demonstrate efficacy compared to vehicle, loteprednol etabonate ophthalmic suspension, or tobramycin ophthalmic solution. There was no difference between treatment groups in mean change from baseline blepharoconjunctivitis score at Day 15.

There were no differences in safety assessments between the treatment groups in either trial.

8.5 Geriatric Use

No overall differences in safety and effectiveness have been observed between elderly and younger patients.

NONCLINICAL TOXICOLOGY

13.1 Carcinogenesis, Mutagenesis, Impairment of Fertility

Long-term animal studies have not been conducted to evaluate the carcinogenic potential of loteprednol etabonate or tobramycin.

Loteprednol etabonate was not genotoxic *in vitro* in the Ames test, the mouse lymphoma TK assay, a chromosome aberration test in human lymphocytes, or in an *in vivo* mouse micronucleus assay.

Oral treatment of male and female rats at 50 mg/kg/day and 25 mg/kg/day of loteprednol etabonate, respectively, (500 and 250 times the maximum clinical dose, respectively) prior to and during mating did not impair fertility in either gender. No impairment of fertility was noted in studies of subcutaneous tobramycin in rats at 100 mg/kg/day (1700 times the maximum daily clinical dose).

PATIENT COUNSELING INFORMATION

This product is sterile when packaged. Patients should be advised not to allow the dropper tip to touch any surface, as this may contaminate the suspension. If pain develops, redness, itching or inflammation becomes aggravated, the patient should be advised to consult a physician. As with all ophthalmic preparations containing benzalkonium chloride, patients should be advised not to wear soft contact lenses when using Zylet.

MANUFACTURER INFORMATION

BAUSCH & LOMB INCORPORATED

TAMPA, FLORIDA 33637 USA

©Bausch & Lomb Incorporated

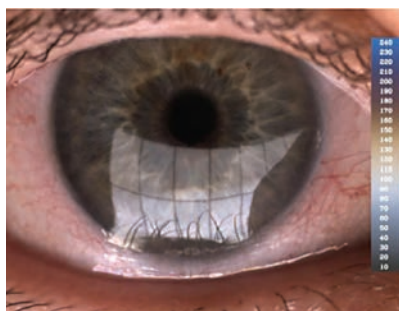Zylet is a registered trademark of Bausch & Lomb Incorporated.

The How and Why of Diagnosing Dry Eye

The differential etiology of dry eye disease confounds diagnosis. Here are a dozen clinical tools—a mix of old and new—essential for identifying its hallmarks and healing your patients. **By Derek N. Cunningham, OD, and Walter O. Whitley, OD, MBA**

No definitive test for dry eye disease (DED) currently exists, and it is likely that we will never see a “magic bullet” of this sort. In fact, the current prevailing definition of dry eye from the DEWS report in 2007 is very broad, encompassing a multitude of symptoms and signs.¹ Dry eye is actually much more complicated than we have historically given it credit for. The term more accurately describes a diverse group of distinct conditions with unique etiologies; as such, several different pathologies lead to the same signs and symptoms in our patients. The search for a single, simple, absolute test for dry eye has given rise to an ever-expanding clinical armament of tests that measure specific hallmarks of dry eye disease.

But why? Likely this is because our rapidly changing understanding



The Lipiview II uses interferometry to assess lipid layer integrity.

of dry eye pathology has driven the development of new DED diagnostic technologies. We have seen the dry eye paradigm shift several times as new theories have supplanted their predecessors. After first relying on the concept of primary aqueous deficiency, we adopted a theory of primary lipid deficiency, before moving to a combined aqueous-lipid deficiency model and finally the current

tear composition and comorbidity paradigm. New advances in knowledge have shifted the diagnostic goal post several times. Importantly, however, the tenet that inflammation is a key component of all dry eye has remained intact throughout these regime changes in theory.⁸

It can be overwhelming to look at the entirety of new technologies, each of which focuses on distinct aspects of DED. Taken individually, the scientific rationale and clinical application of each diagnostic test is relatively straightforward. However, no clear map exists to help differentiate between tests and understand how one test’s interpretation affects another.

Dry eye centers throughout the country have incorporated most—and in many cases all—of the technologies highlighted here, and development of algorithms

Dry Eye Diagnosis

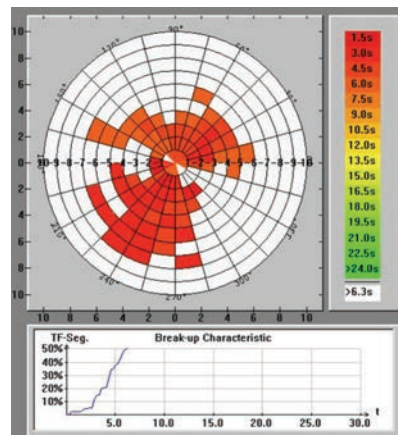
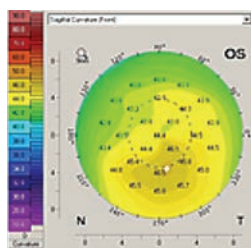
and protocols for diagnosis are in the works. Here, we will walk you through how to incorporate and interpret the current dry eye diagnostic technologies.

1. Questionnaires

While validated dry eye questionnaires remain staples of clinical research, for the most part they remain underused in general optometric practice. The two most commonly used questionnaires—OSDI and SPEED—are still commonly used in many dry eye centers.^{1,2} Although we do not use a validated dry eye questionnaire on our routine eye care patients, we do find use in all our dedicated ocular surface disease evaluations. Currently, the SPEED questionnaire is the prime choice; its brevity makes it quick for patients to fill out and for clinicians to evaluate. Whether you choose a validated questionnaire or develop one to fit your practice needs, be sure to use simple, real-world scenarios for patients to think about how dryness impacts their daily activities, how frequently they experience it and how severe their condition may be.

As a part of our routine eye exams, we screen for dry eye with verbal questions rather than questionnaires. The three quick screening questions published by the 2014 Dry Eye Summit have been incorporated into every initial patient encounter we have.³ Although not validated, these questions have proven helpful to us in identifying dry eye quickly

Corneal topography can identify ocular surface changes stemming from dry eye.



Keratograph 5M evaluation of TBUT.

and in a minimally disruptive manner during our surgical evaluations.

1. *Do your eyes ever feel dry or uncomfortable?*
2. *Are you bothered by changes in your vision throughout the day?*
3. *Do you ever use or feel the need to use drops?*

2. Corneal Topography

Topography, which can detect subtle irregularities to the ocular surface, is an excellent tool for the detection of dry eye.⁴ However, note that a diagnosis must be based on medical necessity (e.g., keratoconus or corneal dystrophy) to bill for topography in this context; otherwise, the patient is required to pay out of pocket for the test. Regardless, the information gleaned can be very useful in DED detection. We frequently perform the test on many of our patients, especially those who are considering cataract surgery, elective procedures like LASIK or PRK, or contact lens wear. Topography can be included as part of the elective procedure or contact lens fitting fees for obvious reasons.

Due to the impact of dry eye on refractive outcomes and successful contact lens wear, it is critical to determine the presence or absence of DED in surgical patients. For

instance, in refractive cataract surgery, an inaccurate keratometry measurement with biometry can lead to a +/- 1D change in postsurgical refraction. Additionally, contact lens wearers need a robust tear film and healthy ocular surface to ensure successful wear and optimal vision.

A thorough evaluation of the patient's corneal surface and shape can provide information about the presence and state of DED. Missing or patchy information on topography is often an indicator of early tear break-up time (TBUT). Inferior steepening is also a common result of dry eye, which can become so severe as to mimic keratoconus. The inferior cornea will often steepen in dry eye because of epithelial dehydration.⁵ One will often see superficial punctate keratitis in the inferior cornea as well. The presence of significant inferior steepening causes us to focus more on exposure-related causes of dry eye such as incomplete blink or nocturnal lagophthalmos.

As dry eye improves, so too will topography. Other topographical findings of dry eye disease include irregularly shaped placido discs and differences in average keratometry readings between eyes.^{4,5}

3. Lipid Layer Analysis

Recent research suggests that 86% of dry eye patients suffer from the evaporative form of the disease.⁶ Thus, it is important that we fully assess the lids, meibomian glands and lipid layer—whose evaluation is now a necessity for determining the presence and severity of dry eye. Fluctuating vision is a hallmark of dry eye and an insufficient lipid layer is believed to be the most likely cause.¹ Several automated devices are available on the market to evaluate the lipid layer. If none are available at your clinic, however, fluorescein TBUT is still an excellent

alternative. Contrary to conventional wisdom, no ‘magic number’ for TBUT exists. Rather, look to see if the lipid layer is breaking up between routine blinks.

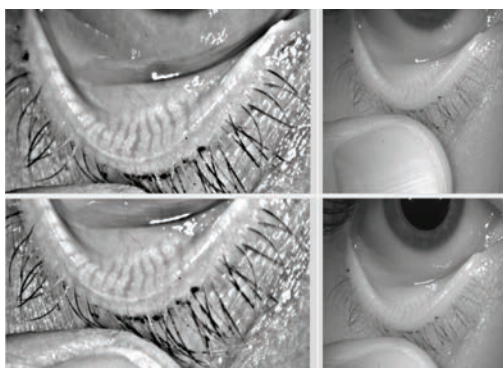
Automated assessments of the lipid layer help us understand its importance. Lipiview II (Tear-Science) and the Keratograph 5M (Oculus) are two of the most readily available technologies for evaluating the lipid layer. The Lipiview II employs interferometry to evaluate the lipid layer thickness; a thickness of roughly 100nm is considered normal.⁷ The test is valuable on initial ocular surface disease exams, but we do not yet use it to track the efficacy of dry eye treatments because of interscan variability.

The Keratograph 5M evaluates noninvasive TBUT: no fluorescein is needed in the eye, and the natural lipid layer is evaluated for its break-up patterns. This data is useful in tracking patients. The drawback: the numbers are not standardized or validated for diagnosing DED.

A deficient lipid layer will turn treatment focus toward using lipid-containing artificial tears and therapies that increase meibomian gland expression.

4. Automated Blink Analysis

Lipiview II tracks and evaluates patients’ routine blink characteristics, including blink rate and partial or incomplete closure. The test is run with the lipid layer analysis, and we review this data before every dedicated dry eye evaluation. For patients who exhibit incomplete blinks, this is an opportunity to educate them on how this contributes to their condition. They can be shown video of their blink patterns and as such may be more inclined to understand the need for treatment compliance or lifestyle changes. Blinking exercises can be prescribed for



Keratograph 5M image showing healthy meibomian glands.

incomplete blinkers, but the efficacy of these exercises is debatable.

5. Objective Red Eye Scaling

Chronic red eyes is a common sign of DED. Objectively measuring conjunctival injection allows the symptom to be used as a metric to diagnose, educate and monitor treatment. This can be accomplished with Keratograph 5M, which scores conjunctival redness. The automated software uses a repeatable metric to measure redness, minimizing observer variability. Although causes of red eye are endless, this test may provide a valuable baseline for assessing treatment efficacy.

6. Tear Osmolarity

This may be the single most accurate diagnostic test for dry eye—and the most widely misunderstood.⁸ Because DED signs and symptoms often do not correlate, having an objective metric generated by the TearLab device improves our ability to rapidly diagnose and treat dry eye. Just as the disease itself may fluctuate (e.g., unstable tears, blurred and fluctuating vision), high osmolarity readings in a dry eye patient will be increased and fluctuate when the tear film is unstable (greater than 308mOsm/L).

Additionally, inter-eye variability

is a characteristic of dry eye not seen in normal subjects (greater than 8mOsm/L difference between eyes).⁹ In combination with the slit lamp exam, doctors can better select therapies based on the mechanism of disease and severity. As we know, tear osmolarity will be altered by any disruption in the tear film; however, the numbers don’t always fit into our conventional thinking of dry eye. Normal

patients will exhibit low and stable osmolarity (less than 308mOsm/L), which indicates proper tear homeostasis.⁹ As the body struggles to maintain homeostasis in dry eye, however, tear osmolarity numbers will become variable and inconsistent. Once we improve the tear film composition, tear osmolarity numbers in DED patients become less variable and more consistent. We use these readings to help us to treat and manage our dry eye patients.

Although tear osmolarity has a high positive predictive value, we do not rely on it as a standalone test—we find it is more valuable to track dry eye therapy over time. As tear osmolarity normalizes (280 to 300mOsm/L), we adjust and monitor our treatment and management accordingly.⁹ Once we have a patient that is symptomatic or diagnosed with dry eye, we evaluate tear osmolarity at every evaluation thereafter.

Because of the low cost—evaluation units are free of charge—and significant clinical value, we see tear osmolarity as the baseline new technology for evaluating tear film stability. This point-of-care test takes only seconds and can be done by a technician. It is also one of the few dry eye diagnostic tests (e.g., meibography and MMP-9) that is

Dry Eye Diagnosis

reimbursable by medical insurance.

7. Matrix Metalloproteinase-9 (MMP-9) Analysis

MMP-9 is a proteolytic enzyme released by compromised epithelium, and has been shown to increase in dry eye patients.¹⁰ MMP-9 analysis (InflammaDry, RPS) is a point-of-care diagnostic test that provides both qualitative and quantitative information that may aid the diagnosis of DED. Positive readings indicate the presence of inflammation in the eye. A positive result indicates the sample contains more than 40ng/ml, and has been correlated with dry eye of DED.¹²

MMP-9 is helping us to catch patients we otherwise would have been missing. For instance, we have found presurgical or contact lens patients with a missed DED diagnosis. Additionally, this test is useful for determining the optimal time to use punctal occlusion, since we do not want to put plugs in a patient with an already inflamed ocular surface. The test only takes a few minutes to perform and is reimbursable by most insurers.

8. Schirmer Tear Test

We do not routinely perform this test on all patients, as it is highly variable and does not account for the tear composition or the evaporative nature of dry eye.¹² When performing this test, be sure to measure basal tearing—we always perform this test with topical anesthetic.



Lipiview II combines reflected and transilluminated light to produce dynamic meibomian imaging.

After applying the drop, remove any excess with a cotton swab prior to measurement.

A variation of this test is the phenol red test, which many practitioners find useful. Phenol red is performed without anesthetic and takes about 15 seconds. If the results show less than 10mm of wetting, the patient is considered dry. One area where we find both tests useful is in new dry eye patients and in cases of suspected autoimmune conditions such as Sjögren's syndrome. If the patient has a low Schirmer score due to aqueous deficiency, we often initiate punctal plugs sooner and order further testing for autoimmune conditions such as Sjögren's (i.e., Sjögren + Bausch + Lomb).

9. Lissamine Green/Rose Bengal Staining

These stains are the most diagnostic for early to moderate dry eye. When evaluating the interpalpebral conjunctiva, positive staining with lissamine green helps to detect the earliest signs of the disease prior to

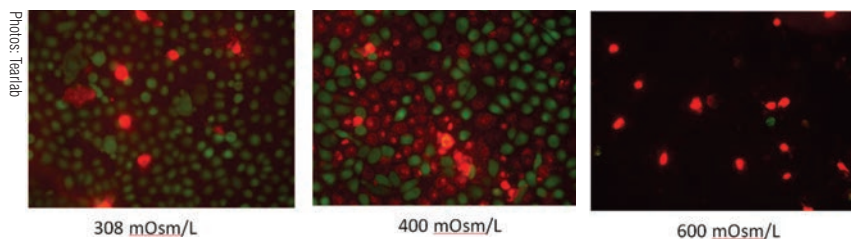
corneal staining. Lissamine green is the vital dye of choice used in symptomatic patients who have not yet started to show corneal fluorescein staining.

Rose bengal staining is analogous to lissamine green, but because it can burn upon instillation, it is used less than its green-colored counterpart.¹³ Unlike fluorescein and lissamine green, rose bengal staining is not a "vital" dye, as it stains normal, healthy, living cells in addition to dead or dying ones.^{14,15}

10. Sodium Fluorescein (NaFl) Staining

NaFl staining is the most commonly used stain in dry eye evaluation due to its wide availability.¹² It is important to remember that NaFl only sufficiently stains the cornea, and only in moderate to severe dry eye. When it comes to diagnosing dry eye, it is critically important to identify DED patients earlier in the disease state. If you are only using NaFl to screen for dry eye, you may be missing most mild to moderate dry eye patients.

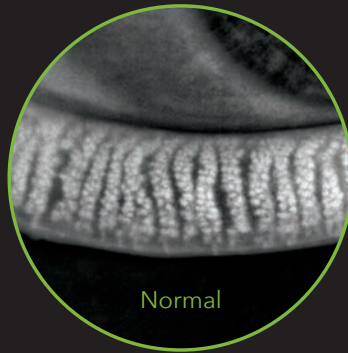
The pattern of staining can also play a role in our diagnosis of the condition. Often, patients with dry eye disease have diffuse staining; however, some will only have significant inferior staining. In these cases, always take a look at the lids, lid position and blink to identify other causes of their symptoms.



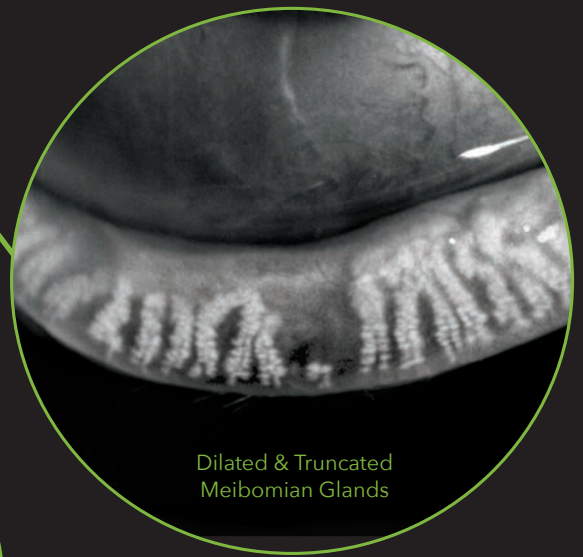Effect of high osmolarity on corneal epithelial cells (200x magnification).

MGD Now in Plain Sight

Dry Eye from previously hidden Meibomian Gland Disease impacts quality of vision and ocular comfort.



Normal



Dilated & Truncated Meibomian Glands

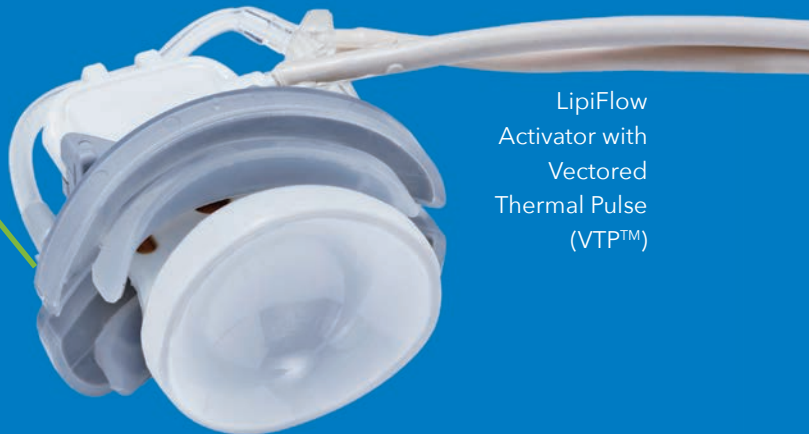Dynamic Meibomian Imaging (DMI™)

LIPIFLOW[®]
BY TEARSCIENCE

Now affordable for your patients.

Start treating for as low as \$484/mo,
full system as low as \$1,275/mo

Based on Mar. 2016 financing estimate with approved credit.
Tax not included. Restrictions may apply.



LipiFlow
Activator with
Vectored
Thermal Pulse
(VTP™)

LipiFlow inner-lid technology has
been rigorously studied.*

* 31 peer reviewed reports, including 5 large multi-centered, randomized, controlled studies.

919-459-4880 | tearscience.com | info@tearscience.com

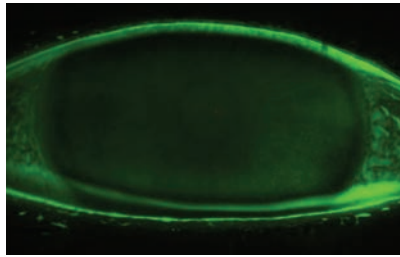
11. Tear Lake/Meniscus Evaluation

Clinicians interested in obtaining precise measurements of the tear layer thickness or tear lake size can make use of anterior segment OCT. This data can be valuable in certain dry eye evaluations, but is not routinely used to diagnose dry eye due to a lack of standardization.¹⁶ It is also typically not reimbursable by insurance. Conventional evaluation at the slit lamp will suffice for most routine cases. However, one area where OCT testing may be useful is in the evaluation of scleral contact lenses for dry eye relief.

12. Meibography

Given our current understanding of how important lipid layer interaction is in almost all presentations of dry eye, meibography has become an essential DED test. As is the case with glaucoma, where we look at structure and function of the optic nerve, our ability to image the meibomian glands has significantly changed how we understand and treat DED.

Although we do not use meibography as a standalone diagnostic test—it does not tell us how much lipid is expressed from each gland—it does give us a general understanding of patients' gland health, and which patients may benefit from various meibomian gland-based treatments. Meibography also improves our ability to educate patients on the progressive nature of their condition if left untreated. Through years of imaging, we have learned the gland will initially plug, then swell, then become serpiginous; finally, it will truncate and atrophy.¹⁷ Knowing the state of patients' meibomian gland health is invaluable for the long-term management of their dry eye.



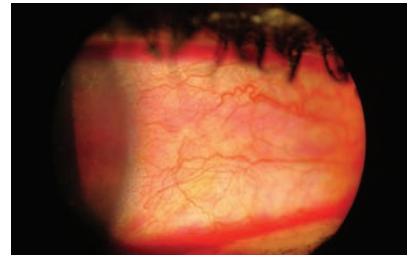
Fluorescein staining of the cornea.

We perform meibography during all dry eye evaluations, and have started to image the glands of all patients scheduled for LASIK or cataract surgery. Meibography is becoming a valuable screening tool for identifying people at risk for postsurgical dry eye due to poor meibomian gland health. We are also performing meibography on many of our glaucoma patients due to the comorbidity rate associated with glaucoma and DED.

The cost to entry associated with meibography (Keratograph 5M or Lipiview II) is significant, but this imaging technique is becoming increasingly important as we discover more about dry eye. If neither the Keratograph 5M or Lipiview II is available, a rudimentary evaluation of the meibomian glands can be performed by transillumination of the eyelid with a small light source.

Diagnostic Wrap-Up

The expansive technology available to diagnose dry eye yields no single definitive test. Traditional dry eye testing (i.e., history, Schirmer's, TBUT) is a start; however, the objective tests mentioned here will help not only to identify patients but also to treat and manage DED. Consistency is the key to building your dry eye practice while finding the dry eye protocols that work for your clinic. Asking the right questions, examining the lids, using the stains and assessing tear stability are essential.

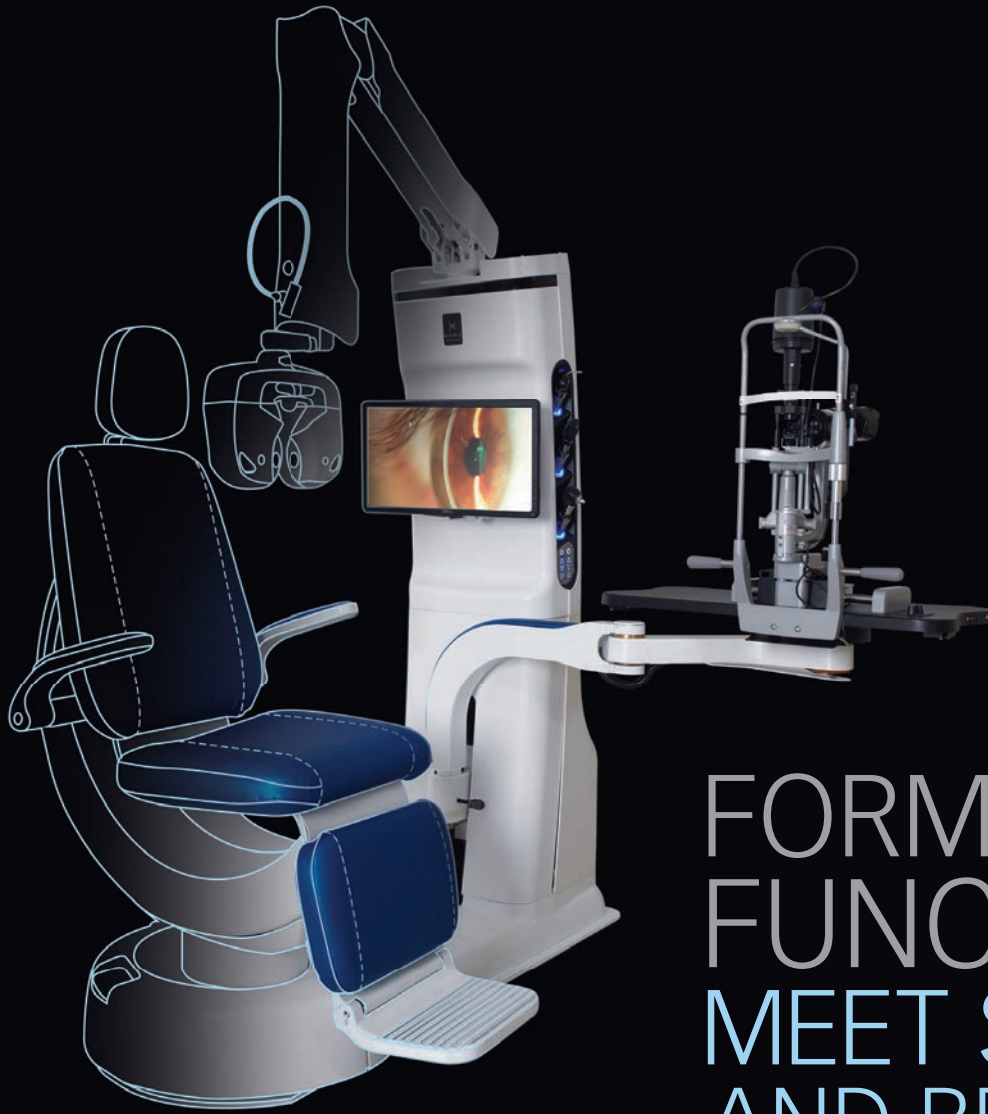


Rose bengal conjunctival staining.

Dry eye is the most common ocular disease that you will see. Therefore, it should take its appropriate priority in your clinic. ■

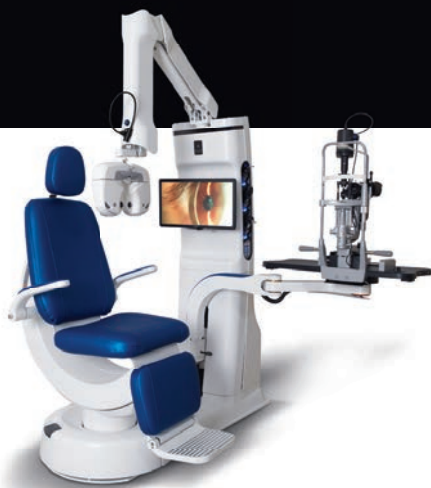The authors wish to thank Cecelia Koetting, OD, for her assistance with this article.

1. The definition and classification of dry eye disease: report of the Definition and Classification Subcommittee of the International Dry Eye WorkShop (2007). *Ocul Surf.* 2007 Apr;5(2):75-92.
2. Ngo W, Situ P, Keir N, et al. Psychometric properties and validation of the Standard Patient Evaluation of Eye Dryness questionnaire. *Cornea.* 2013;32(9):1204-10.
3. Grubbs JR, Tolleson-Rinehart S, Huynh K, Davis RM. A review of quality of life measures in dry eye questionnaires. *Cornea.* 2014 Feb;33(2):215-8.
4. 2014 Dry Eye Summit. Accessed from www.reviewofoptometry.com/supplement_toc/s/367.
5. Liu Z, Pflugfelder S. Corneal surface regularity and the effect of artificial tears in aqueous tear deficiency. *Ophthalmology.* 1999;106(5):939-43.
6. dePaiva, CS, Harris, L, Pflugfelder, S. Keratoconus-like Topographic Changes in Keratoconjunctivitis Sicca. *Cornea.* 2003;22(1):22-4.
7. Lemp MA, Crews LA, Bron AJ, et al. Distribution of aqueous deficient and evaporative dry eye in a clinic-based patient cohort: a retrospective study. *Cornea.* 2012;31(5):472-8.
8. Finis D, Pischel N, Schrader S, Geerling G. Evaluation of lipid layer thickness measurement of the tear film as a diagnostic tool for Meibomian gland dysfunction. *Cornea.* 2013;32:1549-53.
9. Tomlinson A. IOVS 2006. DEWS Ocular Surf 2007.
10. Lemp MA, Bron AJ, Baudouin C et al. Tear osmolarity in the diagnosis and management of dry eye disease. *Am J Ophthalmol.* 2011 May;151(5):792-8.
11. Chotikavanich S, de Paiva CS, Li de Quan, et al. *Invest Ophthalmol Vis Sci* 2009; 50(7):3203-9.
12. Sambursky R, Davitt WF 3rd, Friedberg M, Tauber S. Prospective, multicenter, clinical evaluation of point-of-care matrix metalloproteinase-9 test for confirming dry eye disease. *Cornea.* 2014;33:812-28.
13. Nichols KK, Mitchell GL, Zadnik K. The Repeatability of Clinical Measurements of Dry Eye. *Cornea.* 2004;23(3): 272-85.
14. Machado LM, Castro RS, Fontes, BM. Staining Patterns in Dry Eye Syndrome: Rose Bengal Versus Lissamine Green. *Cornea.* 2009;28(7):732-4.
15. Abelson M, Ingerman, A. The dye-namics of dry-eye diagnosis. *Review of Ophthalmology.* Access from www.reviewofophthalmology.com/content/d/therapeutic_topics/i/1311/c/25254/#sthash.AxbyGJdn.dpuf.
16. Feenstra RPG, Tseng SCG. Comparison of fluorescein and Rose Bengal staining. *Ophthalmology* 1992;99:4:605-17.
17. Shizuka Koh, S. Tung, C. Aquavella, J. et al. Simultaneous measurement of tear film dynamics using wavefront sensor and optical coherence tomography. *Invest Ophthalmology Visual Science.* 2010 Jul; 51(7):3441-8.
18. Nichols JJ, Bernstein DA, Mitchell GL, Nichols KK. An assessment of grading scales for meibography images. *Cornea.* 2005; 24(4):382-8.
19. Patterson M, Vogel H, Prenner EJ. Biophysical characterization of monofilament model systems composed of selected tear film phospholipids. *Biochim Biophys Acta.* 2016 Feb;1858(2):403-14. doi: 10.1016/j.bbmem.2015.11.025. Epub 2015 Nov 30.



FORM AND FUNCTION MEET STYLE AND BEAUTY.

The XOMA® Exam Room System.



There's so much to appreciate in our Xoma Exam Room System, it's difficult to know where to begin. XOMA's unique and beautifully designed, all-in-one, patient positioning and instrument delivery system is truly a sight to behold. Its exciting design displays stunning lines while maximizing efficiency through extraordinary functionality. XOMA...the all-in-one innovation from the one-and-only Reliance.

800.735.0357
xomasystem.com

© 2016 Haag-Streit USA. All Rights Reserved.

 **RELIANCE
INTERNATIONAL**

REMARKABLE. RELIABLE. RELIANCE.

The End of Compromise

Each successive generation of soft contact lenses has brought with it the promise of improved patient comfort. Despite decades of new lens offerings, however, discomfort (especially at the end of the day) remains a continual challenge. The research on contact lens dropout bears this out: according to a 2010 survey, more than 1 in 6 contact lens wearers—6 million Americans—drop out of lens use every year, half of them due to discomfort.¹ The costs of dropout are enormous, both in terms of patient satisfaction and the impact on eye care professionals' practices. It is estimated that each patient who drops out of contact lens use represents more than \$21,000 in lost practice revenue over that patient's lifetime.¹

With so many advances in contact lens technology being introduced over the years, why is the dropout rate still so high? A major problem with lens development had been the "one size fits all" mentality—the assumption that a single type of lens material used throughout the entire lens could provide all the characteristics, including lubricity and wettability, essential for an optimal lens-wearing experience.

DAILIES TOTAL1® contact lenses, with their unique Water Gradient Technology, represent the end of compromise. Water Gradient Technology starts at the core of the lens, which is made of a silicone hydrogel material with a low water content. Attached to this core is a network of ultrasoft, hydrophilic polymers. These water-loving polymers,

which are not a lens treatment or coating but a unique and different material from the silicone hydrogel core, create a gradual transition in water content, from 33% at the core to 80% at the surface, and approaching 100% at the outer surface.^{2,4}

The result is a contact lens unlike any other. The silicone hydrogel core of the DAILIES TOTAL1® contact lens, combined with its low water content, creates a lens that is 6 times more breathable^{***} than the leading daily disposable contact lens, for white, healthy-looking eyes.⁶ In fact, DAILIES TOTAL1® lenses have the highest Dk/t^{****} among any daily disposable contact lenses.⁹ In addition, the almost 100% water content at the outer surface^{*} of the lens gives DAILIES TOTAL1® long-lasting lubricity that is superior to competitive contact lenses.^{4,7,8,10}

The unique science behind DAILIES TOTAL1® contact lenses provides extraordinary performance for end-of-day comfort and an unsurpassed lens-wearing experience. In a recent survey, over 90% of patients agreed that they could comfortably wear DAILIES TOTAL1® all day long, and 3 times as many patients agreed that DAILIES TOTAL1® contact lenses were comfortable at the end of the day compared to their previous lenses.¹¹

The outstanding level of comfort that DAILIES TOTAL1® contact lenses offer is critical to patients, because comfort, especially comfort at the end of the day, is at a premium in today's world that is dominated by technology and digital devices. With DAILIES TOTAL1®, the

According to a
2010 survey,
more than 1 in
6 contact lens
wearers—6
million
Americans—
drop out of lens
use every year,
half of them due
to discomfort.¹

first and only Water Gradient Technology contact lens, eye care professionals can finally recommend a lens that offers the comfort patients demand.

Say good-bye to compromise, and say hello to DAILIES TOTAL1® contact lenses, all-day comfort, and white, healthy-looking eyes.⁹

**Based on laboratory measurement of unworn lenses.*

***Dk/t = 156 @ -3.00D.*

****High oxygen transmissible lenses: DAILIES TOTAL1 (delefilcon A) contact lenses: Dk/t = 156 @ -3.00D. Other factors may impact eye health. Ask your eye care practitioner for complete wear, care, and safety information.*

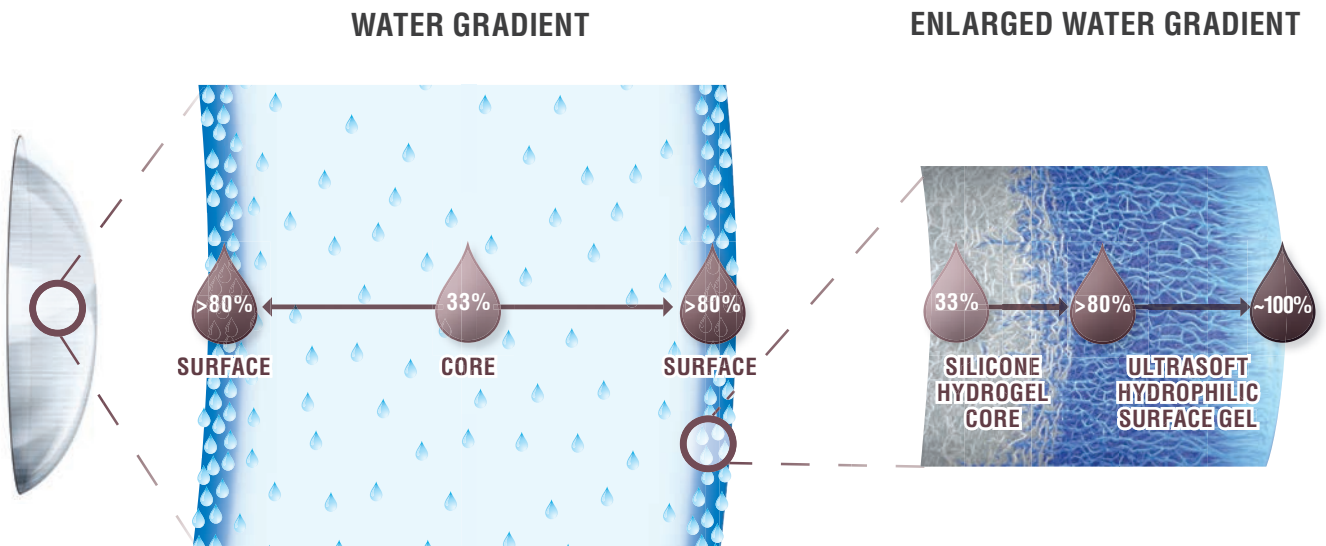
*****Among daily disposable lenses; Dk/t at center of -3.00D lens and Dk are based on manufacturer-published values.*

1. Rumpakis J. New data on contact lens dropouts: an international perspective. *Rev Optom.* 2010;147:37-42.

Three times as many patients agreed that DAILIES TOTAL1® contact lenses were comfortable at the end of the day compared to their previous lenses.¹¹

2. Thekveli S, Qui Y, Kapoor Y, et al. Structure-property relationship of delefilcon A lenses. *Cont Lens Anterior Eye.* 2012;35(suppl1):e14.
3. Alcon data on file, 2011.
4. Angelini TE, Nixon RM, Dunn AC, et al. Viscoelasticity and mesh-size at the surface of hydrogels characterized with microrheology. *Invest Ophthalmol Vis Sci.* 2013;54:E-Abstract 500.
5. Atomic force microscopy image of fully hydrated lens cross section, Alcon data on file, 2011.
6. Based on the ratio of lens oxygen transmissibilities, Alcon data on file, 2010.
7. Based on critical coefficient of friction measured by inclined plate method; significance demonstrated at the 0.05 level; Alcon data on file, 2011, 2013.
8. Alcon data on file, 2011.
9. Based on the ratio of lens oxygen transmissibilities, among daily disposable lenses; Alcon data on file, 2010.
10. Alcon data on file, 2011.
11. Alcon data on file, 2014.

See product instructions for complete wear, care, and safety information.



CONTACT LENS CROSS-SECTION WITH WATER CONTENT VALUES

Image is for illustrative purposes only

The Water Gradient Technology in DAILIES TOTAL1® contact lenses creates a lens with unsurpassed breathability** and superior lubricity for outstanding comfort that lasts all day.^{4,8}

© 2016 Novartis 1/16 US-DAL-15-E-0359

AUTOMATED PERIMETRY: VISUAL FIELD DEFICITS IN GLAUCOMA AND BEYOND

Evaluating the visual pathway can be integral to diagnosing and managing numerous conditions. **By Kristie Draskovic, OD, and John J. McSoley, OD**

Examining the visual field is essential when considering potential vision loss from conditions affecting the visual pathway. Standard automated perimetry is a useful tool for identifying and following many neurological conditions, as well as glaucoma and glaucoma suspects. While several devices are currently available, the following discussion will consider the use of the Humphrey Field Analyzer (HFA, Zeiss) as an example.

Anatomy and Physiology

Due to the anatomy of the visual pathway, clinicians can detect areas of concern with many conditions that cause visual impairment (*Figure 1*). Because light traveling from the

temporal visual field falls on the nasal retina, retinal lesions are seen in the exact opposite quadrant of the visual field. All pre-chiasmal lesions, including those on the retina and optic nerve, will give rise to defects isolated to the affected eye.¹

Since nasal fibers are responsible for the temporal visual field, a lesion at the optic chiasm will result in a visual field defect that affect the temporal field of both eyes, and gives rise to the classic bitemporal hemianopsia, which respects the vertical midline.¹ Lesions of the optic chiasm can be the result of pituitary adenomas, suprasellar meningiomas, craniopharyngiomas or aneurysms. In some cases, visual field defects may reverse after treating the cause.²

Fibers responsible for the visual field to the right of the midline are found on the left side of the brain, and vice versa. As a result of this crossover, all post-chiasmal lesions, including lesions of the optic tract and optic radiations, cause a homonymous hemianopsia.¹ These defects are on the same side of the visual field in each eye and respect the vertical midline. When the defects are only seen superior or inferior, it is referred to as a quadranopsia. In the case of incomplete hemianopsia defects, anterior lesions are usually more incongruous, whereas posterior lesions will be more congruous between the two eyes.¹

Glaucomatous visual field loss represents damage to the axons

Release Date: March 2016

Expiration Date: March 1, 2019

Goal Statement: Examining the visual fields using automated perimetry can help clinicians evaluate lesions that affect the visual pathway, establish baselines and screen for certain medication-induced optic neuropathies. It can also help monitor progression or recurrence of diseases, guide treatment decisions and aid in localizing lesions. This article will help clinicians better understand and interpret visual fields in glaucomatous and non-glaucomatous disease processes.

Faculty/Editorial Board: Kristie Draskovic, OD, and John J. McSoley, OD

Credit Statement: COPE approval for 2 hours of CE credit is pending for this course. Check with your local state licensing board to see if this counts toward your CE requirement for relicensure.

Joint-Sponsorship Statement: This continuing education course is joint-sponsored by the Pennsylvania College of Optometry.

Disclosure Statement: Drs. Draskovic and McSoley have no financial relationships to disclose.

Common Visual Field Defects

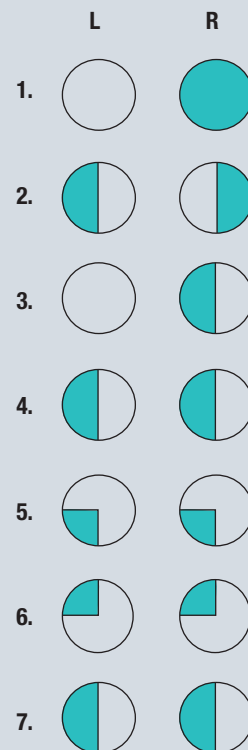
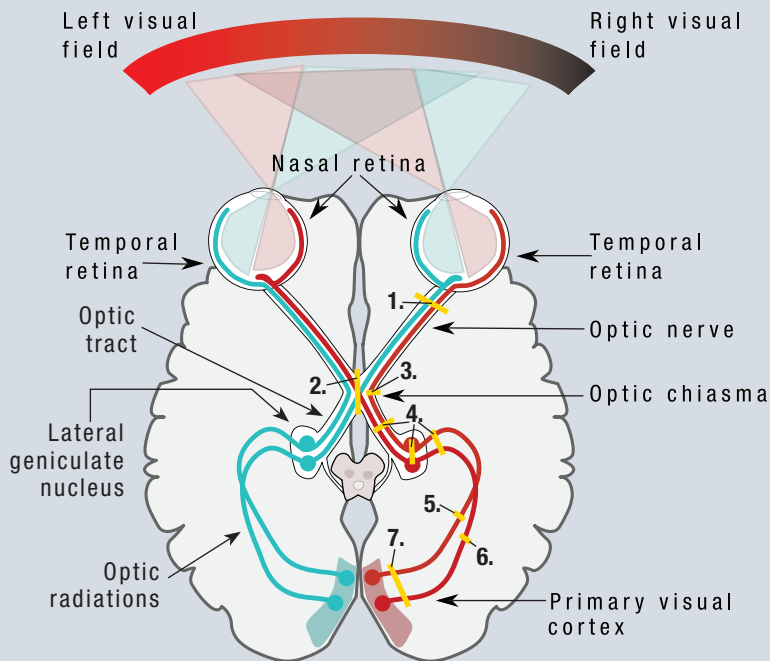


Fig. 1. A simplified schematic of the visual pathway is shown. Lesions which interrupt the visual pathway lead to visual field defects. (1) A complete right optic nerve lesion results in complete loss of the right visual field. (2) A lesion in the midline of the optic chiasm leads to a bitemporal hemianopsia. (3) A lesion of the uncrossed fibers of the right optic nerve at the optic chiasm leads to a nasal hemianopsia of the right eye. (4) A complete lesion of the right optic tract, lateral geniculate nucleus, or optic radiations results in a complete left homonymous hemianopsia. (5) A lesion of the right upper optic radiations results in a left inferior quadrantanopsia. (6) A lesion at the right lower optic radiations causes a left superior quadrantanopsia. (7) A lesion of both the superior and inferior right optic radiations causes a left homonymous hemianopsia.

traveling along the retinal nerve fiber layer and usually follows an arcuate pattern to the optic nerve. Damage to these axons will give rise to localized visual field defects, most commonly arcuate scotomas, nasal steps and paracentral scotomas. A normal field of vision extends farthest temporally to 90 degrees, 70 degrees both superiorly and inferiorly and 60 degrees nasally and from fixation. The most valuable information for neurological deficits and glaucoma management is obtained within 30 degrees from fixation.²

Test Strategy

Automated static perimetry—and

threshold perimetry specifically—presents a stimulus of fixed size but of variable intensity. The sensitivity of the different test locations is recorded based on the patient's responses to these stimuli. A size III stimulus (which is 4mm² when projected on a 30cm bowl) is commonly used in clinical practice.

There are different threshold test patterns available. The 30-2 test pattern tests 76 locations within 30 degrees from fixation, while a 24-2 test pattern tests 54 locations removing for the ring of points at 30 degrees (except the two points which straddle the horizontal meridian nasally). These most peripheral

points are more prone to variability, and 24-2 shortens test time by removing these peripheral points from the test. Spacing between test point locations is six degrees.

In addition, the 10-2 test pattern targets 64 points within 10 degrees from fixation separated by two degrees. This option is preferable when central or paracentral defects arise with the 24-2 and 30-2 or when the field becomes so constricted the peripheral points are not clinically useful. Clinicians can also choose to increase the stimulus size to V, which may afford higher sensitivity values and a larger dynamic range through which to follow patients for change.

However, currently there is no SITA type test algorithm, nor is there an available comparison to a normative database or progression analysis.

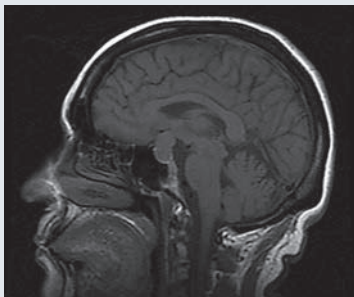
Recent studies show that 10-2 visual fields may be useful for identifying more than advanced glau-

coma.^{3,4} One study revealed that some glaucoma patients had significant central cluster defects seen on 10-2 testing patterns despite normal central 30-2 visual field.⁴ The study suggests that, due to poor spatial sampling, glaucomatous central field

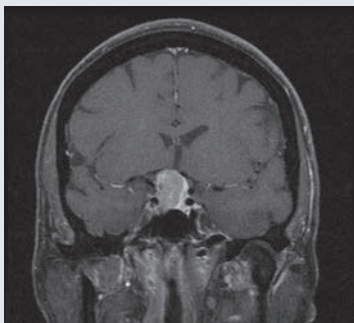
deterioration could not be picked up by the 30-2 test grid alone, and denser estimation of the central 10 degrees was required.⁴ It also suggests that modifying the conventional visual field test pattern might improve detection of early glaucoma-

Case 1. Pituitary Macroadenoma





A patient presented for consultation in the setting of atypical, progressive normal tension glaucoma.



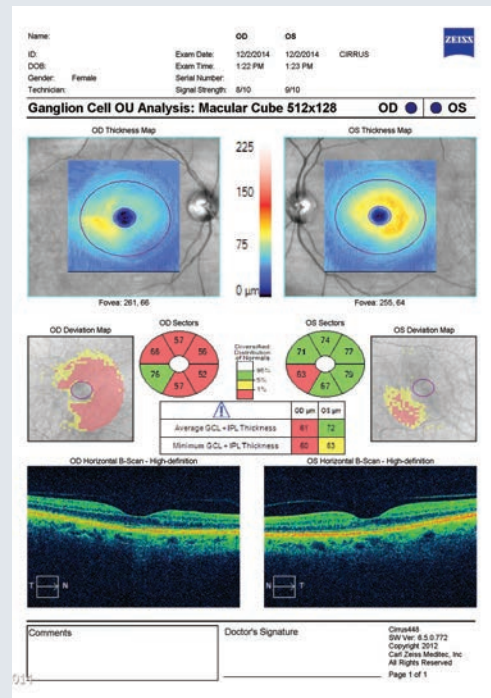
At right, the patient's 24-2 visual field demonstrates bitemporal visual field loss.



In the MRIs at left, the T1 sagittal without gadolinium and T1 coronal views with gadolinium reveal a large sellar mass with slight enhancement and compressive effect on chiasm. This finding is consistent with pituitary macroadenoma.



After the patient underwent transsphenoidal surgery to remove the sellar mass, the visual field, above, shows improvement of the visual field defect in the right eye and resolution of the defect in the left eye.



Above, the ganglion cell complex reveals nasal thinning in both eyes, which correlates to the temporal visual field loss.

tous defects in the central 10 degrees.⁴

In daily practice, doctors often perform 10-2 fields when small central or paracentral scotomas appear on 30-2 and 24-2 testing, or when acuity is suspected or threatened to be depressed as a result of field loss. Also, a 10-2 test pattern may be a useful adjunct when there is high inter-test variability of paracentral points on a 24-2 pattern. The growing attention to ganglion cell function in the macular region could also increase attention to the area of the visual field tested by the 10-2 pattern.

Reliability

Indications of reliability of visual field performance include fixation losses and both false positive and false negative responses.

Fixation can be monitored by periodic presentation of a stimulus to the physiologic blindspot (Heijl-Krakau method) or by monitoring the position of the corneal light reflex. On the HFA, upward deflection indicates change in position or fixation; downward deflection indicates the corneal light reflex cannot be located, such as during a change in head or eyelid position.

False positives occur when a patient responds at a time when there is no associated stimulus or when a response is physiologically not possible. Patients with high false positives are often described as “trigger happy.” This can reveal a visual field that appears more sensitive or more normal than expected or can lead to abnormally high threshold sensitivity values.

False negatives occur when a patient fails to respond to a stimulus brighter than one already seen or

when the response is not consistent with the pattern of responses in that region. The false negative value may be an indication of reliability or a reflection of the disease process. Abnormal regions of the visual field are associated with more intra-test and inter-test variability. As a result, regions of the visual field with low sensitivity are not included in the calculation of the false negative value.

The threshold sensitivity is raw data with values recorded in decibels. The numbers indicate the degree of attenuation from maximum possible stimulus. Values of < 0 response indicate that the patient did not respond to the brightest stimulus available. The grayscale uses shaded symbols to describe the level of sensitivity, with the darker areas on the map corresponding to more reduced sensitivity.

The total deviation represents

the deviation from expected values based on the age-matched normal database. The pattern deviation corrects for overall sensitivity of field by removing generalized depressions (e.g., from cataracts) to identify any areas of localized abnormalities. Both total and pattern deviation have associated probability (*p*) values calculated based on distribution within a normal population. The range of normal values is wider peripherally than centrally. *P* symbols indicate the frequency of the tested value occurring in a normal age-matched population. Deviations are shown on the map if the tested threshold is worse than the bottom 5% of normal for that age.² For example, if *p* < 0.5%, then fewer than 0.5% of reliable normal fields had a sensitivity value at a given point less than or equal to that recorded threshold.

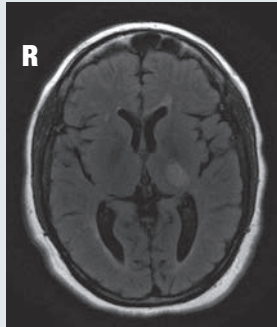
Table 1. Optic Neuropathies Commonly Detected with Visual Field Testing

Idiopathic intracranial hypertension	Early: enlarged blind spot Late: generalized constriction ^{5,6} (can improve with treatment)
Optic neuritis	- Diffuse visual field loss (in almost half of cases) - Other: altitudinal defect, central or cecentral scotomas, arcuate or double arcuate defects and hemianopic defects ^{5,7}
Non-arteritic anterior ischemic optic neuropathy	- Altitudinal defects that respect the horizontal midline are most common - Other: central scotomas, arcuate defects and quadransias ^{5,8}
Posterior ischemic optic neuropathy	- Central field defect ^{5,9}
Hereditary optic neuropathies - Leber's hereditary optic neuropathy - Dominant optic atrophy	- Cecentral and central visual field loss ⁵
Optic nerve head drusen	- May mimic a glaucomatous pattern
Thyroid ophthalmopathy	- Large variability - May partially or fully resolve after treatment ²
Medication-induced toxic optic neuropathy	- Ethambutol (for tuberculosis treatment) toxicity may cause central scotomas and, less commonly, peripheral constriction and altitudinal defects ⁵ - Vigabatrin (an anti-epileptic drug), may cause field defects that begin as bilateral nasal defects and later progress to concentric field defects while the central field remains intact ¹²



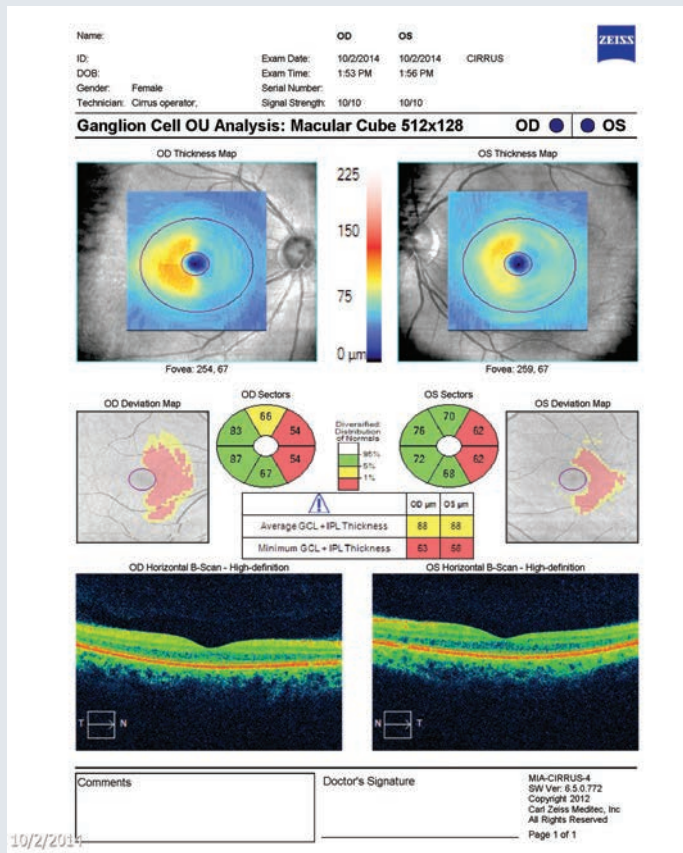
Case 2. Multiple Sclerosis

A patient diagnosed with multiple sclerosis (MS) presented with vision loss.

At right, in the MRI, T2 flair axial view reveals a focal hyperintense lesion just posterior to the left lateral geniculate nucleus in the thalamus, which is responsible for the visual field defect seen. The lesion seen, as well other multiple hyperintense lesions, are typical characteristics of demyelinative disease such as MS.



Below, the ganglion cell analysis reveals nasal thinning in the right eye and temporal thinning in the left eye, which is consistent with the visual field findings.



Above, the visual field demonstrates an incomplete right homonymous hemianopia.

Pattern standard deviation (PSD) is a weighted standard deviation from the value expected based on age-matched normal values and the mean deviation (MD) index. The PSD reveals the distance between different points within the field. PSD is sensitive for both early and focal glaucoma defects. A low PSD value can be seen with normal visual

fields, a visual field that is uniformly depressed or a completely blind field. An associated *p* value is the likelihood of the value occurring. The MD is a weighted average of values in the total deviation numerical plot. MD may be influenced by a diffuse decrease in overall sensitivity or by a localized defect. An MD of 0 indicates a normal value, while a

negative value represents deviation or loss from the normal database. Mean deviation weighs central points more heavily. Visual field index (VFI) is another age-corrected assessment, expressed as a percentage, where perimetrically normal is 100% and perimetrically blind is 0%. When calculating VFI, central points are weighted stronger

than peripheral points. It provides a score for an individual visual field and is used in progression analysis.²

The glaucoma hemifield test (GHT) compares the relative sensitivity of pattern deviation values of five zones in the superior and inferior hemifields. Each of these zones is compared with its mirror zone in the opposite hemifield, and both zones are compared with the normative database. GHT can detect glaucomatous visual field loss with high sensitivity and high specificity through five possible categories: outside normal limits, borderline, general reduction of sensitivity, abnormally high sensitivity and within normal limits.

Interpretation

Establishing a reliable baseline visual field is crucial in glaucoma management and future monitoring for possible progression. Clinicians should obtain at least two reproducible baseline visual fields to detect smaller increments of change. Recognizing progression, particularly after escalation of therapy at times of progression, will require the clinician to establish a new baseline.

Visual fields done prior to the current medical or surgical treatment, or during an extended period of being lost to follow up off treatment, should not be used for the purpose of determining progression. Clinicians should use the new baseline visual fields performed after these treatment changes, and any visual field thereafter in judging progression.

A reliable and representative baseline is also important for progression analysis programs. Visual fields tend to have higher variability with more

eccentric location and mid-range sensitivities, and long-term fluctuation makes judging progression more challenging. Mid-level sensitivity points tend to be variable, whereas test values in upper and lower sensitivity ranges are more stable. Establishing a reliable, reproducible baseline visual field can help remove some of these challenges.

Non-glaucomatous Optic Neuropathies

Visual fields can help evaluate lesions that affect the visual pathway, establish baselines and act as screening tools for certain drugs associated with optic neuropathies. They can also monitor progression or recurrence of diseases while helping guide treatment decisions and even aid in localizing lesions.⁵ The most common visual field manifestation of a non-glaucomatous optic neuropathy is a central defect. The larger the scotoma, the greater the likelihood that visual acuity is reduced (*Table 1*).

Retinal Disease

Visual field defects caused by retinal

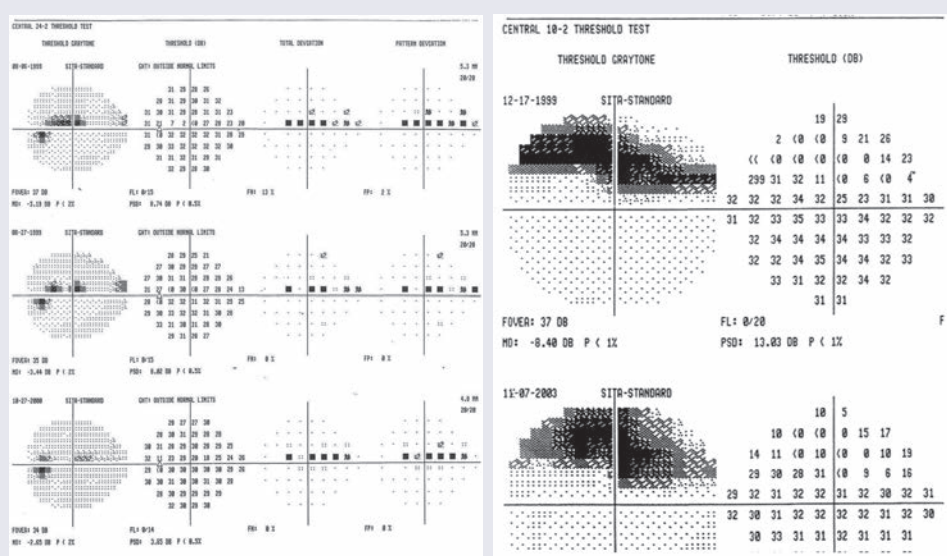
disease tend to have well-defined, sharp borders that appear deeper than most glaucoma defects with less variability.² Common conditions affecting the macular area, such as age-related macular degeneration and central serous chorioretinopathy, can give rise to central scotomas which can be seen on 10-2 as well as some 24-2 and 30-2 testing, depending on the extent of damage.

Retinitis pigmentosa gives rise to peripheral visual field defects, which may lead to tunnel vision with only a central island in advanced disease.

Arterial occlusions typically show absolute areas of defect whereas venous occlusions can be more shallow and diffuse.² These often coexist with glaucoma, making interpretation more challenging.

Chorioretinitis, or associated scars, can mask glaucomatous defects with an arcuate or wedge-like defect. A retinal detachment will give rise to a relative defect while retinoschisis will have an absolute defect. These conditions are often much more peripheral than what would appear on conventional central testing using 24-2 or 30-2.

Case 3. Paracentral Glaucoma Defect



An example of variable points in superior paracentral scotoma on 24-2 with a focal deep defect on 10-2.

Glaucoma Defects

A defect can be a generalized or localized depression of sensitivity compared to the normalized database. General depressions are seen most commonly with cataracts, but can also arise from uncorrected refractive error or miosis. Localized defects can be further described by size, depth and location to help with diagnosis. A relative defect occurs when sensitivity is less than normal, or may be reduced relative to other areas of the field, but vision remains. An absolute defect is when the stimulus is presented at maximum brightness and not seen.

Glaucomatous visual field loss may first occur in the nasal or in the arcuate region (Bjerrum area). These defects may extend from the blind spot, around the macular region, ending abruptly at the horizontal meridian nasally. Early glaucomatous defects are often localized relative scotomas (Table 2).

Considerable test-retest variability is the hallmark of visual field areas affected by glaucomatous visual field loss. Variable sensitivity reductions occurring in the same area, but not always in the same test point locations, commonly precede consistent glaucomatous field defects.² Variability, as is seen with false negatives, may indicate reliability, but larger amounts of variability are often seen due to the disease itself.

When visual fields are unreliable, they should be repeated to establish baselines, confirm a defect or confirm suspected progression. Usually, visual fields are not repeated on the

same day due to patient fatigue, which can affect reliability. It is rarely urgent to have the visual field repeated immediately, as glaucoma is generally a slowly progressive optic neuropathy, and treatment decisions are driven by rate of change.² Each practice should standardize a preferred test strategy and pattern and repeat the same test to enable more accurate comparisons on follow up testing.¹⁰

Progression

Evaluating change allows the practitioner to determine if the condition is stable, progressing or improving. Progression in a visual field may be due to a diffuse decrease in sensitivity, existing defects may get deeper or expand or new defects may arise. Depressed areas most commonly progress before new areas of visual field are affected. An initial increase in visual field variability is sometimes seen before a change or progression becomes constant. It is important to differentiate if evidence shows long-term fluctuation or a worsening trend. Once clinicians establish that the visual field is worse, they must decide if the change is due to glaucoma or another disease entity. Statistically and clinically significant changes on the visual field allow the practitioner to make the necessary changes to the patient's treatment and management plan.

Practitioners must also evaluate how the rate of progression may alter the patient's quality of life.² For example, clinicians must be more

cautious treating younger patients with faster progression and monocular patients (Table 3).

While it is difficult to predict which patients will progress slowly vs. rapidly, once a rate of progression is evaluated over time, the patient's management should be altered accordingly. The younger patient who shows signs of rapid progression of visual field defects, for example, will need a more aggressive management plan than an elderly patient with slow progression of an early field defect. It is reasonable that patients' treatment and management be personalized based on their specific clinical picture, including their field loss and rate of progression. Research shows if rate of progression is determined and no treatment change is initiated, past rates of progression can be predictive of future rates.^{10,11} At the same time, rates of decline can be altered by escalating therapy. Once an intervention is made, a new baseline should be established.

Evaluating change over time is critical in glaucoma management. With the guided progression analysis (GPA) software found on HFA, two baseline visual field tests are identified. Subsequent visual field tests are then compared with the averaged baseline using the pattern deviation values. When follow-up values decline to a degree larger than the variability of an age and defect matched population of stable glaucoma patients, the point is identified. If the change persists on consecutive repeat testing, points are marked as possibly (two consecutive) or likely (three or more consecutive fields).

GPA uses both trend and event analysis to aid practitioners in identifying and quantifying progression of the visual field. Event analysis looks for a statistically significant change of a point or group of points, while trend analysis quantifies the direction

Table 2. Criteria for Glaucomatous Visual Field Defect with High Specificity and Sensitivity^{13,14}

- Cluster of three or more non-edge points on the pattern deviation with $p < 5\%$ with one point at $p < 1\%$ over two consecutive fields
- GHT outside normal limits on two consecutive fields
- PSD $< 5\%$ over two consecutive fields
- Asymmetry of MD $> 1.50\text{dB}$ that is repeatable and in the setting of clinical suspicion^{15,16}

Table 3. Suggestions for Judging Progression

- Three points in an abnormal region decrease by 10dB*
- Two new points, near a defect reduced by 10dB*
OR
- Two points in central 15 degrees or three outside 15 degrees down by 10dB*
OR
- Statistical comparisons ($p < 5\%$)*

*On two or more consecutive fields^{14,17}

of change over time, or the rate of change, including future projections. Clinicians can direct their attention to the potential underestimation of diffuse loss, subtle artifacts that may be associated with pattern deviation and the need for a sufficient number of high quality visual fields (minimum five) for optimal analysis. However, GPA is less influenced by cataract than other analysis tools. Each test strategy uses its own normative database.² An additional goal is to identify a rate of progression and separate out the patients who are progressing rapidly and need increasingly aggressive therapy.

Progression of Non-glaucomatous Optic Neuropathies

Because GPA was established specifically for glaucoma management, clinicians must take a different approach when evaluating for possible progression in non-glaucomatous conditions. Regression analysis of VFI or mean deviation, as well as series overview report, can be helpful when evaluating other conditions.²

Follow Up

Use the same test strategy and pattern to allow easier comparison and monitoring for progression. Following established glaucoma patients with perimetry is essential in determining if the current management is adequate or if treatment changes are needed based on the stability or progression of the visual field.

The frequency of follow up will depend on the extent of the disease

and the clinical course. Patients who demonstrate stability could reasonably increase their follow up interval.

Artifacts

There are several artifacts that may arise, imposing further challenges to interpreting visual fields. Clinicians must discern true visual field defects from pathology that correlate to the clinical picture vs. artifacts that may arise. At times when it is not clear if the visual field defect is real or an artifact, the visual field should be repeated in an appropriate timeline based on your level of suspicion and the clinical picture. Artifacts to look out for include:

- **Eyelid and brow ptosis.** This can cause a dense superior defect along the superior edge points. Patients with visually significant ptosis may benefit from having their eyelids taped for testing.

- **Rim artifacts.** The positioning of the trial lens holder can lead to a rim artifact if it is too far from the patient's eye, creating a full or partial ring scotoma.

- **Incorrect refractive error.** This can lead to a generalized depression in sensitivity that may mimic that of a cataract. High refractive error can create a magnification or minification effect and require proper vertex distance calculations. Using the wrong lens power sign or not using the new refractive error after a patient has cataract surgery are two common errors.

- **Patient fatigue.** This may manifest with longer test times, high

false negative value or preferentially abnormal peripheral sensitivity. Peripheral points are tested later in the course of the test and may be markedly reduced in cases of fatigue or waning attention, resulting in a darker, lobular ring or cloverleaf pattern on the grayscale.

A learning curve exists for both patients and those administering testing. Awareness of these commonly encountered artifacts allows for improved visual field interpretation and recognition of limitations of the reliability and quality of test results.

Why We Test

Understanding the visual pathway can give a provider valuable insight to localizing lesions. Each practice should standardize a preferred test strategy and pattern and repeat the same test on follow-up visits to enable more accurate comparisons throughout follow-up testing.¹⁸

Glaucoma management should be focused on preventing the loss of visual fields to the degree that it affects a patient's quality of life. It is important to evaluate the entire clinical picture to make sure variables correlate and coincide. Tests should be repeated if uncertainty exists to establish more reliable baseline measurements and confirm possible progression. ■

Drs. Draskovic and McSoley are staff optometrists at the Bascom Palmer Eye Institute.

1. Lens A, Langley T, Nemeth SC, Shea C. Visual Pathway. In: Ocular Anatomy and Physiology. Thorofare, NJ: SLACK; 1999:90-5.
2. Heijl A, Patella VM, Bengtsson B. The Field Analyzer Primer: Effective Perimetry, 4th ed. Carl Zeiss Meditec; 2012.
3. Park HY, Hwang BE, Shin HY, Park CK. Clinical clues to predict the presence of parafoveal scotoma on Humphrey 10-2 visual field using a Humphrey 24-2 visual field. *Am J Ophthalmol.* 2016;161:150-9.
4. Ehrlich AC, Raza AS, Ritch R, et al. Modifying the conventional visual field test pattern to improve the detection of early glaucomatous defects in the central 10°. *Transl Vis Sci Technol.* 2014 Oct;3(6):6.
5. Kedar S, Ghate D, Corbett JJ. Visual Fields in Neuro-Ophthalmology. *Indian Journal of Ophthalmology.* 2011;59(2):103-9.
6. Wall M, George D. Idiopathic intracranial hypertension. A prospective study of 50 patients. *Brain.* 1991;114:155-80.
7. Keltner JL, Johnson CA, Spurr JO, Beck RW. Baseline visual field profile of optic neuritis. The experience of the optic neuritis treatment trial. Optic Neuritis Study Group. *Arch Ophthalmol.* 1993;111:231-4.

8. Hayreh SS, Zimmerman B. Visual field abnormalities in nonarteritic anterior ischemic optic neuropathy: their pattern and prevalence at initial examination. *Arch Ophthalmol*. 2005;123:1554-62.
9. Hayreh SS. Posterior ischaemic optic neuropathy: clinical features, pathogenesis, and management. *Eye (Lond)*. 2004;18:1188-206.
10. Bengtsson B. Prediction of glaucomatous visual field loss by extrapolation of linear trends. *Arch Ophthalmol*. 2009;127(12):1610-5.
11. Heijl A. Reduction of intraocular pressure and glaucoma progression. *Arch Ophthalmol*. 2002;120(10):1268-79.

12. Willmore LJ, Abelson MB, Ben-Menachem E, et al. Vigabatrin: 2008 update. *Epilepsia*. 2009;50:163-73.
13. Katz J, Sommer A, Gaasterland DE, Anderson DR. A comparison of analytic algorithms for detecting glaucomatous visual field loss. *Arch Ophthalmol*. 1991;109(12):1017-25.
14. Hodapp E, Parrish RK II, Anderson DR. Clinical decisions in glaucoma. St. Louis: The CV Mosby Co;1993:52-61.
15. Feuer WJ, Anderson DR. Static threshold asymmetry in early glaucomatous visual field loss. *Ophthalmology*. 1989;96:1285-97.

16. Brenton RS, Phelps CD, Rojas P, Woolson RF. Interocular differences of the visual field in normal subjects. *Invest Ophthalmol Vis Sci*. 1986;27:799-805.
17. Anderson DR, Chauhan B, Johnson C, et al. Criteria for progression of glaucoma in clinical management and in outcome studies. *Am J Ophthalmol*. 2000;130(6):827-29.
18. Weinreb RN. Progression of Glaucoma: The 8th Consensus Report of the World Glaucoma Association. Amsterdam: Kugler Publications; 2011.

OSC QUIZ

You can obtain transcript-quality continuing education credit through the Optometric Study Center. Complete the test form (page 93), and return it with the \$35 fee to: Optometric CE, P.O. Box 488, Canal Street Station, New York, NY 10013. To be eligible, please return the card within one year of publication.

You can also access the test form and submit your answers and payment via credit card at *Review of Optometry* online, www.reviewofoptometry.com.

You must achieve a score of 70 or higher to receive credit. Allow eight to 10 weeks for processing. For each Optometric Study Center course you pass, you earn 2 hours of transcript-quality credit from Pennsylvania College of Optometry and double credit toward the AOA Optometric Recognition Award—Category 1.

Please check with your state licensing board to see if this approval counts toward your CE requirement for relicensure.

- Which of the following lesions may give rise to bitemporal hemianopsia?
 - Early normal tension glaucoma.
 - Lesions at the optic chiasm.
 - Idiopathic intracranial hypertension.
 - End stage chronic angle closure glaucoma.
- A visual field with a diffuse depressed total deviation and normal pattern deviation can be the result of:
 - A cataract.
 - Lens rim artifact.
 - Patient fatigue.
 - An optic tract lesion.
- Which is not considered a reliability indicator for visual fields?
 - False negative.
 - Fixation loss.
 - False positive.
 - PSD.
- If a patient is fatigued during the visual field test, which would be an unlikely finding?
 - High false negative.
 - Cloverleaf pattern visual field defect.

- Longer test time than expected.
- Shorter test time.

- The glaucoma hemifield test compares:
 - Superior and inferior sensitivity.
 - Nasal and temporal sensitivity.
 - Total deviation and pattern deviation.
 - Grayscale and total deviation.

- The minimal criteria with high specificity and sensitivity for a glaucomatous defect include each of the following *except*:
 - Three points in location reduced to $p < 5\%$ on PD, one of which is $p < 1\%$.
 - PSD $< 5\%$.
 - GHT outside normal limits.
 - False negative value $< 5\%$.

- A right homonymous hemianopsia can occur as a result of:
 - Ethambutol toxicity.
 - Lesion along the right optic radiations.
 - Lesions along the left optic tract.
 - A non-arteritic anterior ischemic optic neuropathy.

- Which is true regarding visual field defects caused by an arterial occlusion?
 - Defect is only seen in the affected eye.
 - Defect is seen in both eyes.
 - Retinal defects respect the horizontal midline.
 - Retinal defects respect the vertical midline.

- The total deviation represents:
 - The deviation from expected values based on the age-matched normals.
 - The average of two baseline visual fields.
 - The reliability parameters.
 - Color representation of sensitivity.

- Which of the following is *false* regarding the visual field index:
 - VFI of 0% is perimetrically blind.
 - VFI of 100% is perimetrically normal.
 - Peripheral points are weighted stronger than central points.
 - It is an index that can be plotted over time to identify a trend.

- Which is accurate with respect to the gaze tracker?
 - Upward deflections represent deviations of fixation, and downward deflections indicate periods when fixation could not be determined.
 - Upward deflections indicate times when fixation is not determined and downward deflections represent deviations of fixation.
 - Upward deflections are recorded when patients respond to a stimulus presented to the blind spot.
 - The gaze tracker primarily serves as a border to frame the printout but does not contain test information.

- The separation of test point locations on the 24-2 and 30-2 test patterns is:
 - The same for both, six degrees.
 - Two degrees separation for both.
 - Eight to 10 degrees for the 30-2 and four to six degrees for the 24-2.
 - Randomly assigned and blankets the central visual field.

- Which is an accurate statement with respect to the 10-2 test pattern?
 - It is a much faster test than the 24-2.
 - Test points are separated by two degrees.
 - Test points are separated six degrees.
 - It is the only way to avoid lens rim artifact.

- Which is *false* regarding the 10-2 test pattern?
 - Test points are located within a 10-degree radius of fixation.
 - Test points are separated by two degrees.
 - This test pattern is often useful to closely monitor paracentral visual field defects.
 - This test pattern is universally contraindicated in glaucoma patients.

- The mean deviation is a global index that represents:
 - A weighted average of the visual field as it deviates from expected values.
 - A number assigned to represent the color of the grayscale.
 - A complicated reliability index.
 - A projection factor for future progression.

OSC QUIZ

16. Which is accurate regarding the GPA?
 a. Two visual field tests are selected to represent a baseline.
 b. Baseline fields are calculated from age-matched normals.
 c. A single visual field serves as baseline.
 d. No baseline visual field is required for this type of progression analysis.

17. Which is accurate regarding follow-up visual fields and the GPA?
 a. Follow-up visual fields are compared with baseline fields.
 b. All fields are compared with the normal age-matched database.
 c. Follow-up fields are put in random order to see if any trends emerge.
 d. Fields are ranked based on reliability factors but progression cannot be evaluated.

18. Which statement is correct with respect to repeat visual field testing?
 a. Peripheral points tend to be less variable than central points on repeat testing.
 b. Test points that have sensitivities in the normal range tend to be the most variable.
 c. Points with abnormal sensitivities, especially those in the middle ranges, tend to be the most variable on repeat testing.
 d. All points are uniformly highly consistent on repeat testing.

19. Which is incorrect with respect to non-arteritic ischemic optic neuropathy?
 a. Inferior or superior defects may occur
 b. Visual field loss that respects the horizontal midline is common.
 c. Visual field loss that respects the vertical midline is common.
 d. Altitudinal defects are most common.

20. Which is accurate regarding follow-up testing?
 a. It is most useful to compare similar test methods to detect change.
 b. All structural and functional tests are complementary.
 c. There is no practical difference among the various test methods and test patterns.
 d. All devices are universally compatible.

Examination Answer Sheet

Valid for credit through March 1, 2019

This exam can be taken online at www.revoptom.com/continuing_education. Upon passing the exam, you can view your results immediately and download a real-time CE certificate. You can also view your test history at any time from the website.

Automated Perimetry: Visual Field Deficits in Glaucoma and Beyond

Directions: Select one answer for each question in the exam and completely darken the appropriate circle. A minimum score of 70% is required to earn credit.

Mail to: Jobson - Optometric CE, PO Box 488, Canal Street Station, New York, NY 10013

Payment: Remit \$35 with this exam. Make check payable to Jobson Medical Information LLC.

COPE approval for 2 hours of CE credit is pending for this course.

This course is joint-sponsored by the Pennsylvania College of Optometry

There is an eight-to-ten week processing time for this exam.

1 = Excellent 2 = Very Good 3 = Good 4 = Fair 5 = Poor

1. (A) (B) (C) (D)
2. (A) (B) (C) (D)
3. (A) (B) (C) (D)
4. (A) (B) (C) (D)
5. (A) (B) (C) (D)
6. (A) (B) (C) (D)
7. (A) (B) (C) (D)
8. (A) (B) (C) (D)
9. (A) (B) (C) (D)
10. (A) (B) (C) (D)
11. (A) (B) (C) (D)
12. (A) (B) (C) (D)
13. (A) (B) (C) (D)
14. (A) (B) (C) (D)
15. (A) (B) (C) (D)
16. (A) (B) (C) (D)
17. (A) (B) (C) (D)
18. (A) (B) (C) (D)
19. (A) (B) (C) (D)
20. (A) (B) (C) (D)

Rate the effectiveness of how well the activity:

21. Met the goal statement: (1) (2) (3) (4) (5)
22. Related to your practice needs: (1) (2) (3) (4) (5)
23. Will help you improve patient care: (1) (2) (3) (4) (5)
24. Avoided commercial bias/influence: (1) (2) (3) (4) (5)
25. How would you rate the overall quality of the material presented? (1) (2) (3) (4) (5)
26. Your knowledge of the subject was increased:
 Greatly Somewhat Little
27. The difficulty of the course was:
 Complex Appropriate Basic

How long did it take to complete this course?

Comments on this course:

Suggested topics for future CE articles:

Please retain a copy for your records. Please print clearly.

First Name _____

Last Name _____

E-Mail _____

The following is your: Home Address Business Address

Business Name _____

Address _____

City _____ State _____

ZIP _____

Telephone # _____ - _____ - _____

Fax # _____ - _____ - _____

By submitting this answer sheet, I certify that I have read the lesson in its entirety and completed the self-assessment exam personally based on the material presented. I have not obtained the answers to this exam by any fraudulent or improper means.

Signature _____ Date _____

Lesson 112401

RO-OSC-0316



TAKE THE TEST ONLINE TODAY!
www.reviewofoptometry.com/continuing_education

2016

MEETINGS

REVIEW OF OPTOMETRY®

EDUCATIONAL MEETINGS OF CLINICAL EXCELLENCE



SAVE THESE DATES!

3 WAYS TO REGISTER

www.reviewofoptometry.com/conferences

Email **Lois DiDomenico**:
ReviewMeetings@Jobson.com

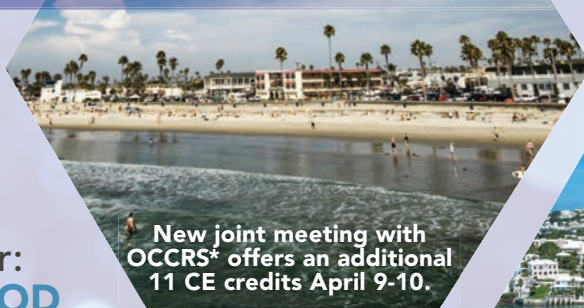Call: **866-658-1772**

REGISTER EARLY!

*OCCRS - Optometric Cornea, Cataract and Refractive Society (Formerly OCRT)

San Diego

Hotel del Coronado
April 7 - 9, 2016



New joint meeting with OCCRS* offers an additional 11 CE credits April 9-10.



Program Chair:
Paul Karpecki, OD



San Antonio

Marriott Riverwalk
May 20 - 22, 2016

Image courtesy of Hamilton Princess & Beach Club, A Fairmont Managed Hotel



Bermuda


The Fairmont Hamilton Princess & Beach Club
June 9 - 12, 2016

Philadelphia

Philadelphia Marriott Downtown
October 7 - 9, 2016



Interactive
CE Workshops



16-19 CE Credits

(COPE approval pending)

San Diego

Up to
**16 CE
Credits**
(COPE approval pending)

REVIEW OF OPTOMETRY®
EDUCATIONAL MEETINGS OF CLINICAL EXCELLENCE



April 7-9, 2016

Superior Education with 2 Interactive Workshops

Hotel del Coronado

A Legendary Beachside Getaway

1500 Orange Avenue | Coronado, California 92118 | 619-435-6611

Discounted room rate \$279/NIGHT

Program Chair: **Paul Karpecki, OD**



REGISTER NOW!

www.ReviewofOptometry.com/SanDiego2016

Or Email **Lois DiDomenico**: ReviewMeetings@Jobson.com | Call: 866-658-1772

REGISTRATION: **3 DAYS - 16 CE CREDITS* - \$495**



Administered by
Review of Optometry®


*Approval pending

Vision Expo East

Vision Expo East 2016:

Enrich Your Knowledge Base

The New York meeting is known for its world-class education as well as its exhibits.

By Cheryl G. Murphy, OD, Contributing Editor

With its diverse list of topics and wealth of experienced speakers, Vision Expo East (VEE) is arguably one of the most valuable CE events eye care professionals can attend. Returning to New York City from April 14th to April 17th, conference organizers pledge to deliver a healthy portfolio of continuing education classes covering all aspects of the trade and include a robust education curriculum.

Beyond Ocular Disease

“I believe the Vision Expos [East and West] have the most complete and comprehensive educational curriculum anywhere,” says Mark Dunbar, OD, co-chair of Vision Expo’s Conference Advisory Board. “Where most CE programs focus on ocular disease, Vision Expo has that and more. Indeed, there is a rich ocular disease curriculum but [there is] also an emphasis on other key areas such as business solutions, contact lenses and optical technology.” Dr. Dunbar adds the event includes “having Ritz Carlton come in to do a two-hour long program on Excellence in



This year’s meeting offers more than 330 hours of CE.

the Patient Experience,” he says.

Attendees can also boost their bottom dollar with a host of seminars on business solutions.

What’s New in Medicine

Keeping up with the latest in medicine includes updates on current prescribing, diagnostic and treatment philosophies. “We have brought back some of our core programs that continue to be huge in attendance and are well received by attendees such as ‘The Greatest Series’ which includes The Greatest Anterior Segment Disease and Medical Management of Contact

Lens Complications Course—Ever! hosted by Jack Schaeffer, OD, Charlie Ficco, OD, and Marc Bloomenstein, OD, as well as The Greatest Posterior Segment Disease Course—Ever! with Dr. Dunbar, Diana Shechtman, OD and Jay Haynie, OD,” says Dr. Dunbar.

Ron Melton, OD, and Randall Thomas, OD, will return to host Current Trends in Medical Management and Reducing the Pressure on Glaucoma Decision Making.

Procedures

In addition to fostering business ideas and obtaining disease updates, if one wants to widen their skill set toward the ever-expanding edge of the optometric profession, investing in one of the two classes on amniotic membranes, “Amniotic Membranes in the Optometric Practice” or “Crash Course: Amniotic Membranes, Why, How and When?” may be a wise decision. The former course, taught by Drs. Douglas Devries and Walter Whitley, is a workshop in which practitioners will gain hands-on experience with amniotic membranes as well as knowl-

edge on how to bill and code for the procedure and its follow ups. Also of interest may be the “Injections Workshop” held on Friday afternoon in which Nathan Lighthizer, OD, will teach injection techniques applicable to the optometric setting such as subcutaneous, subconjunctival, intralesional and intramuscular injections as well as venipuncture for fluorescein angiography. Dr. Lighthizer will also review the indications, contraindications, possible complications and proper management for each technique.

Fast Solutions for CE Fun

To keep things fast and fun this year, for the first time, VEE will be adding COPE-approved half-hour long classes to its format as well as a couple of classes with a revolving door of rotating lecturers.

“New this year is our debut of the Crash Courses, which are 30-minute, topic intensive courses designed to grasp and hold the attention of the audience,” says Dr. I. Ben Gaddie, co-chair of Vision Expo’s Conference Advisory Board. These six, shortened classes held at the end of the day on Friday and Saturday allow participants to squeeze in a bit more CE while still leaving plenty of time to experience the excitement of the exhibit hall and other classes during the day as well as networking events in the evening. Some of the Crash Course topics include: “Amniotic Membranes: Why, How and When?,” “Google Contact Lens and Other Future Technologies” and “Is This *Acanthamoeba*?”

Another way CE at VEE is changing things up this year is with its two “lightning round” classes on glaucoma and anterior segment disease. Each lightning round is held at the same time on Saturday morning (9:45am to 11:45am), but similar to the new “Crash Courses,” the

lightning round’s format has been created to keep things upbeat and interesting. “In that same spirit of our Crash Courses, we are introducing our ‘lightning rounds,’ which are one-hour long courses where the audience stays in one room and the faculty rotate to multiple classrooms to present for 15-minute intervals on a given disease topic,” says Dr. Gaddie. This should help attendees fight the in-classroom fatigue that some may experience after being in a lecture for an extended period of time.

Expertise In and Out of the Classroom

At the end of the day, classes and the expansive exhibit hall are not the only ways to gain knowledge at Vision Expo East. Conversations and interactions with fellow ODs and eyewear professionals can help broaden one’s perspective and knowledge base. Evidence of this can be seen in the ever-growing popularity of OD social media groups such as ODs on Facebook. According to Dr. Dunbar, “ODs on Facebook has emerged as the industry’s largest and most active internet forum for eye care professionals, and so to capitalize on its popularity, we have developed two courses around it: “Best of ODs on Facebook: Practice Management Pearls” with Drs. Gary Gerber, April Jasper, Neil Gailmard, Mark Wright and Alan Glazier [as well as the] “Best of ODs on Facebook: Clinical Tales from the Trenches” with Drs. Ben Gaddie, Diana Shechtman, Andrew Morgenstern, Mark Dunbar and Scot Morris.”

Cutting Loose

Chances for additional social exchanges—not for CE credit, but for further inspiration from other ODs—can be acquired in even more casual settings such as networking at Alcon’s free lunchtime Vision



Drs. Jerome Sherman, Jay Haynie and Mark Dunbar will all return to teach at VEE classes this April.

Series course on Friday afternoon (pre-registration required), the ODs on Facebook Party at B.B. King’s on Friday night, NYSOA’s World Yacht Cruise around Manhattan on Saturday evening (pre-register, for NYSOA members only) and the Young Professionals Club lunch on Friday afternoon or Party on Saturday night. Also, the benefits of sharing ideas and networking can be reaped online through Vision Expo’s Eyecare and Eyewear Community, Visionaries, which premiered in 2015 and is continuing this year (to learn more, visit <http://visionaries.visionexpo.com>).

Attendees can register for classes online or by fax, phone or mail. Note that the new, COPE-approved 30-minute Crash Courses are priced at \$54 per half hour. Other registration packages, discounts and a la carte pricing are available. Be sure to sign up early for the best class selection, as some of the popular lectures do tend to “sell out” quickly.

Taking advantage of the education opportunities at Vision Expo East may be one of the wisest investments ODs make for themselves and it may even help them “grow a little more green” from their practice.

Visit www.visionexpoeast.com to see the full program. ■



Scraping By

Let's consider when corneal debridement is a good option.

Edited by Joseph P. Shovlin, OD

Q In what cases of corneal infection should regular debridement be used for better delivery of topical medication or other therapeutic benefits? That is, when should debridement be performed, and when should it not be?

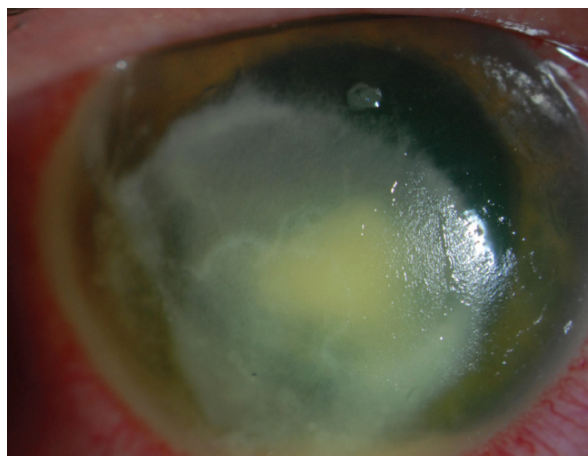
A “Drug delivery to a corneal lesion is dependent on several factors,” explains James V. Aquavella, MD, of the University of Rochester Medical Center. “Lipid solubility is necessary to traverse the tight epithelial junction while hydrophilic drugs more readily traverse stromal collagen.”

For severe bacterial lesions, frequent instillation of fortified antibiotics is the technique of choice, Dr. Aquavella says, adding that general drug delivery can be accelerated by application of a collagen shield pre-soaked in the appropriate antibiotic solution. As the collagen bonds in the shield dissolve, the drug is delivered to the corneal surface over time. Dr. Aquavella cautions that a toxicity reaction to the fortified antibiotics or related preservative substances can disrupt the epithelial junction bonds to increase the permeability of the antibiotics, even if it is hydrophilic in nature.

Aaron Bronner, OD, of the Pacific Cataract and Laser Institute, points out there are two primary recognized conditions in which scraping the epithelium to allow drug penetration may be suitable. “The first, most cited indication is

in cases of fungal keratitis, primarily due to poor penetrance of topical antifungals,” he says. “Stromal concentrations of natamycin 5% and compounded amphotericin B are reduced to ineffective levels by an intact epithelium. The newer antifungal voriconazole is not as significantly limited as others; however, stromal concentrations of this drug are typically reduced by 50% in the case of an intact epithelium.”

Dr. Bronner points out that exacerbating the issue of poor drug penetration is the fact that fungal pathogens often form deep keratitis that worsens despite an intact epithelium, which can lead to the unique possibility of penetration into the anterior chamber even without perforation. He recommends debriding cases of fungal keratitis during treatment to enhance drug delivery, but adds that this practice should only be completed in confirmed cases of fungal disease rather than presumed cases, as removing epithelial tissue unnecessarily in the setting of an infiltrate can perpetuate inflammation and even increase risk of corneal melt in other forms of both



Fungal keratitis is one case in which debridement may be indicated.

infectious and inflammatory keratitis. In effect, in most other cases of keratitis, “we are trying to encourage epithelial healing as much as possible.”

Epithelial debridement may also be helpful in cases of herpes simplex keratitis, as it can shorten the course of infection by removing the epithelial cells that surround the ulceration. This “edge” is a reservoir of active virus that can proliferate to adjacent cells and gradually increase the size of the ulceration. Dr. Bronner cautions that this approach, however, should only be applied in certain specific infectious corneal manifestations of HSV keratitis (i.e., dendritic and geographic ulcerations), not stromal, endothelial or neurotrophic keratitis. This technique should also only be used in initial episodes; more caution is necessary in recurrent cases. ■

Photo: Natalie C. Cheung, MD and Kristin M. Hammersmith, MD

LOMBART CS-5 CHAIR & STAND

Quality, Style & Value

Package includes:

- The *Lombart CS-5*
Chair & Stand 
- *Topcon VT-10* Refractor
- *Topcon SL-2G* Slit Lamp



- *Lombart CVS Essential*
Visual Acuity System
with RF Remote Control
- Additional upgrades
& configurations available.

\$13,995

Or lease for \$277/mo.
for 60 months*

*Lease rate subject to credit approval, 1st payment is due at signing with 59 remaining rental payments of \$265 and a \$1.00 purchase option. Taxes, freight and installation additional. Hand Instruments optional. Subject to change without notice.

1-800-566-2278

Call 1-800-Lombart

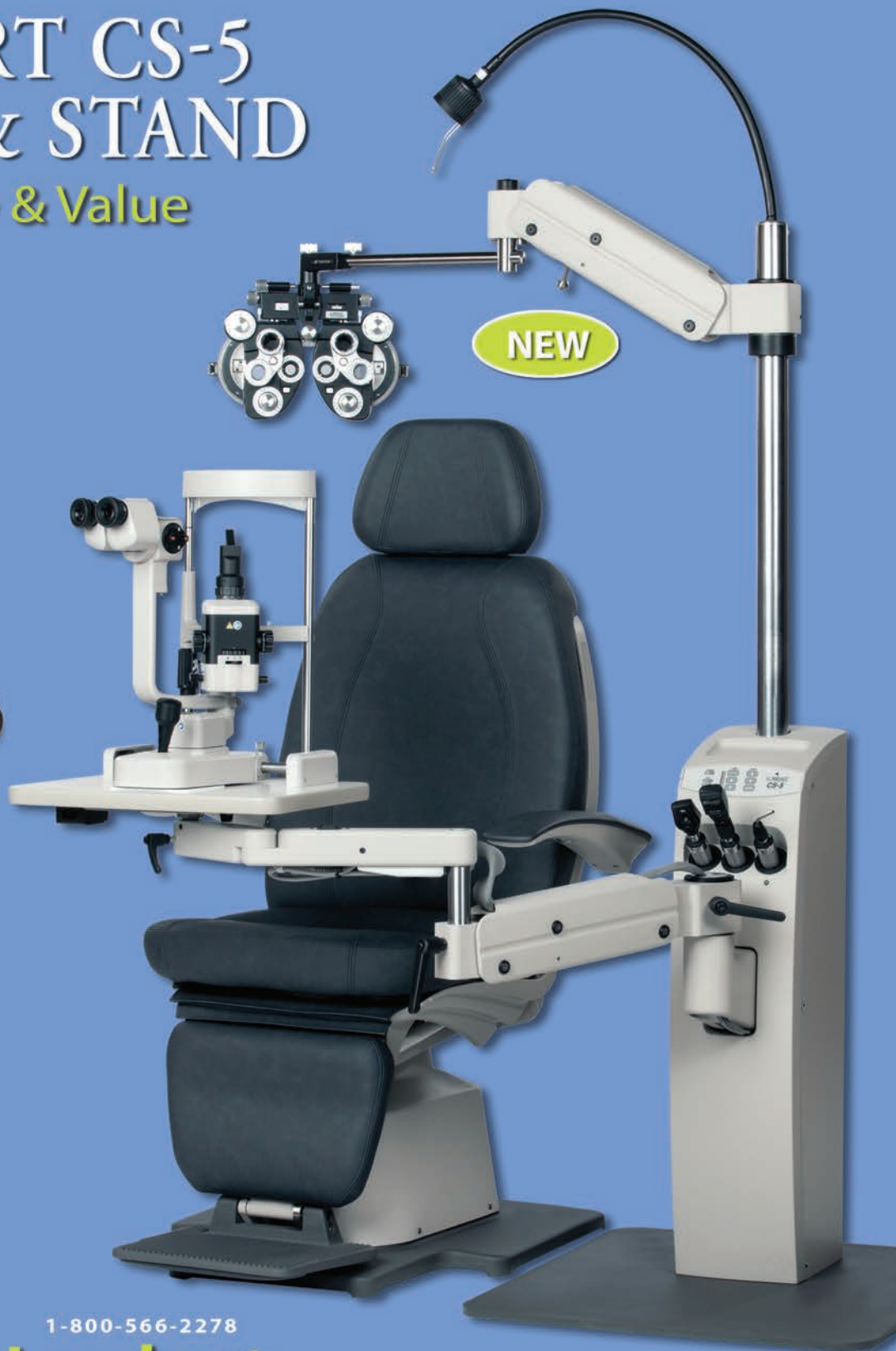Or Your Local Lombart Representative

Corporate Office - 5358 Robin Hood Road, Norfolk, VA 23513-2430
757-853-8888 | FAX 757-855-1232 | 800-566-2278

www.lombartinstrument.com
lombart@lombartinstrument.com

Sales and Service Centers Coast to Coast

ATLANTA • BALTIMORE/WASHINGTON D.C. • BOSTON • BOYNTON BEACH/MIAMI • BRADENTON • CHARLOTTE • CHICAGO • CINCINNATI • DALLAS • DENVER • DETROIT • GREENSBORO • HOUSTON
JACKSON • KANSAS CITY • KNOXVILLE • LOS ANGELES • MILWAUKEE • MINNEAPOLIS • NEW JERSEY/NEW YORK/PENNSYLVANIA • NORFOLK • PORTLAND • SAN ANTONIO • SAN DIEGO • SAN FRANCISCO





Dystrophy Mystery

When testing rules out your suspected diagnosis, it's time to re-evaluate the clues.

By Mark T. Dunbar, OD, and Paul Hammond, OD

A 35-year-old Caucasian female presented to our clinic seeking a second opinion for gradual, progressive, painless loss of vision in both eyes, which started about six years earlier. She provided exam notes from her initial exam six years earlier, and at that time, her vision was documented at 20/30 OD and 20/25 OS. She was taking no medications, had no known systemic medical conditions. Her past ocular history was otherwise unremarkable and there was no family history of ocular disease.

Upon examination, her best-corrected visual acuity was 20/100 in each eye. Confrontation visual fields were full to finger counting

in both eyes; pupils were equally round and reactive to light with no afferent pupillary defect. The slit lamp exam was unremarkable, and intraocular pressure was 16mm Hg OD and 14mm Hg OS.

On dilated fundus exam the optic nerve, retinal vasculature and peripheral retina were within normal limits in both eyes. In the central macula of each eye was a circular, well-circumscribed area of granular-appearing atrophy, with no drusen, edema or flecks (*Figures 1a and 1b*).

A fundus autofluorescence of the macula is available for review (*Figures 2a and 2b*). An SD-OCT image is also provided (*Figures 3a and 3b*).

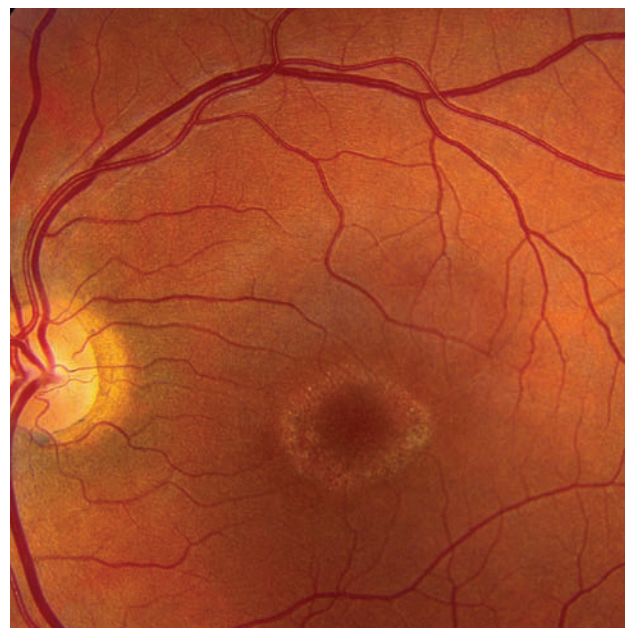
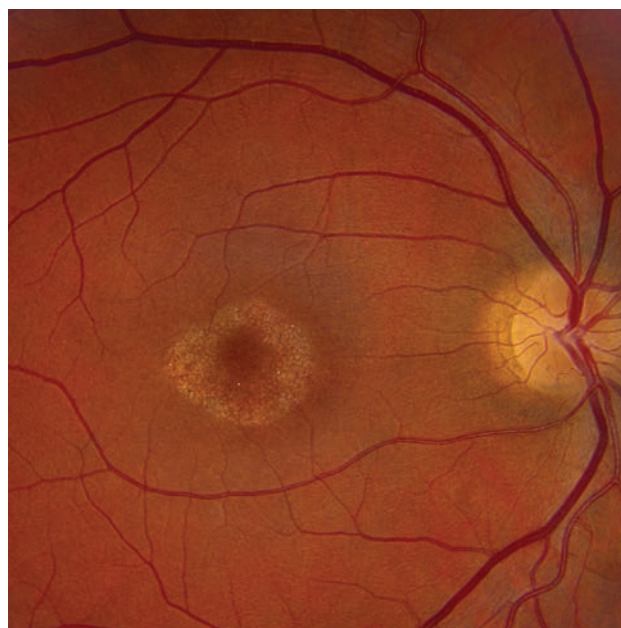
Take the Quiz

1. How do the fundus photos correlate to the OCT images?

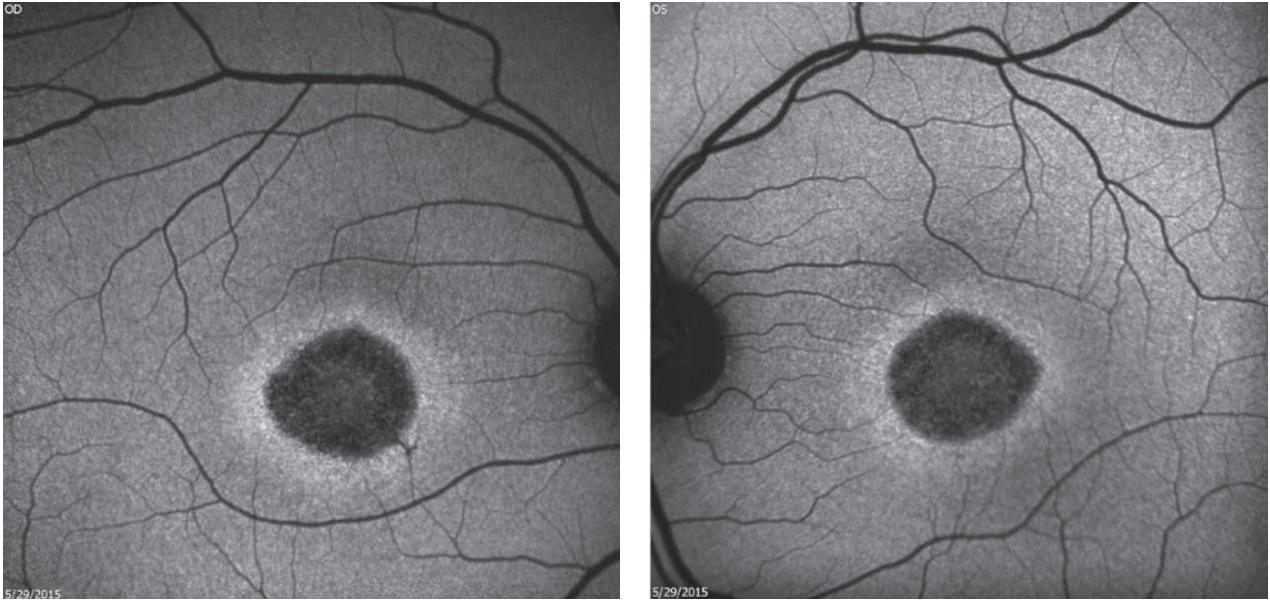
- The OCT images show parafoveal atrophy of the outer retina and RPE in the areas of hypopigmented geographic atrophy.
- The OCT images show subretinal deposits correlating to vitelliform lesions in the photos.
- The OCT images show collapsed drusen in areas of choroidal atrophy in the photos.
- The OCT shows blockage of the choroid.

2. What is the likely etiology?

- Stargardt's macular dystrophy.
- Geographic atrophy from macular degeneration.



Figs. 1a and 1b. Fundus photos of the right and left eye of our patient. What do the changes in her macula represent?



Figs. 2a and 2b. Fundus autofluorescence of the right and left eye. How do these correlate with the fundus images?

- c. Central areolar choroidal dystrophy.
 - d. North Carolina macular dystrophy.
3. What is the typical inheritance pattern of this condition?
- a. Autosomal dominant.
 - b. Autosomal recessive.
 - c. X-linked recessive.
 - d. Sporadic.
4. What additional testing would be most helpful to establish the correct diagnosis?
- a. Fluorescein angiography.
 - b. Electrooculogram.
 - c. Genetic testing.
 - d. Macula risk test.

Diagnosis

The maculas in both eyes have a characteristic “beaten metal” appearance. As a result, the initial doctors who saw her had a high suspicion for Stargardt’s disease. An electroretinogram (ERG) was done and showed normal rod response and mixed cone-rod response, while the multifocal

ERG was depressed centrally, indicating localized retinal dysfunction. In an attempt to confirm the diagnosis of Stargardt’s disease, genetic testing was conducted, looking specifically for the ABCA4 gene mutation. Surprisingly, the test came back negative. The negative ABCA4 result coupled with the clinical absence of “flecks” made the diagnosis of Stargardt’s less likely, but still possible.

ABCA4 gene mutation is the most common cause of autosomal recessive (AR) retinal disease, accounting for 95% of Stargardt’s disease, 30% to 50% of cone-rod dystrophy and 8% of AR retinitis pigmentosa.¹ There have been more than 250 different disease-causing alleles identified in ABCA4, though other locations have been implicated for Stargardt’s, including ELOVL4, PRPH2 and BEST1.¹

With the negative ABCA4 gene mutation, we made the tentative diagnosis of central areolar choroidal dystrophy (CACD) based

on the clinical appearance of the lesions, age of onset, normal full-field electroretinogram and negative genetic testing for Stargardt’s disease.

The gradual decrease in vision with CACD usually begins in the third decade of life, with characteristic bilateral, solitary, well-circumscribed central lesions that have nonspecific granularity within them.² The central geographic atrophy that is seen in CACD is also distinguished by the absence of surrounding drusen and flecks which are seen in similar macular diseases.² Often, patients will stabilize at 20/100 to 20/200 until the seventh or eighth decade of life.²

CACD was first described in 1884 and it is primarily inherited in an autosomal dominant fashion, though autosomal recessive cases have been occasionally reported.³ The most commonly associated mutation occurs on the PRPH2/RDS gene, and a wide range of disease severity and nonpenetrance can be observed,

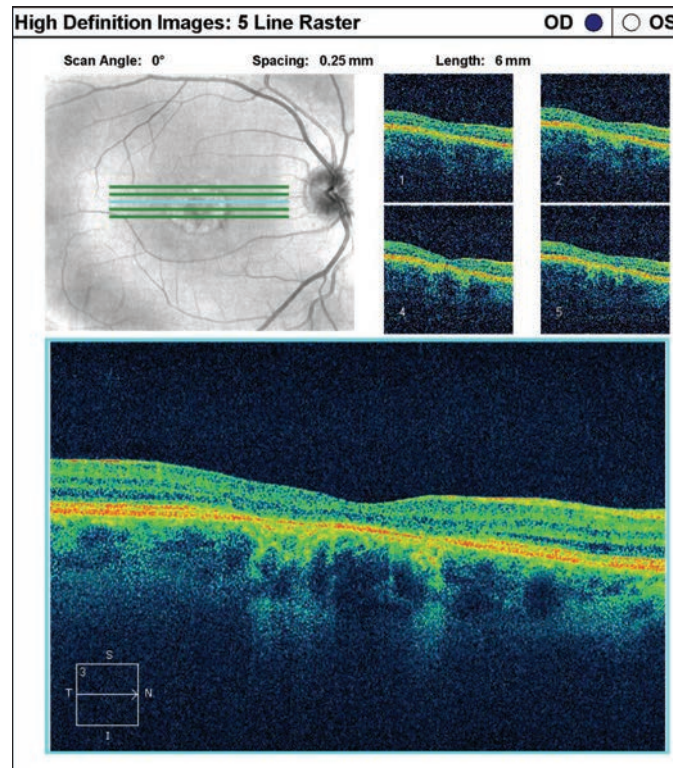
Retina Quiz

perhaps representing variants of AR or sporadic inheritance.⁴ These cases of low penetrance and milder disease can be found in 20% of CACD patients, often resulting in a misdiagnosis of geographic atrophy secondary to early-onset AMD, which enlarges much more quickly than CACD-related atrophy.⁴

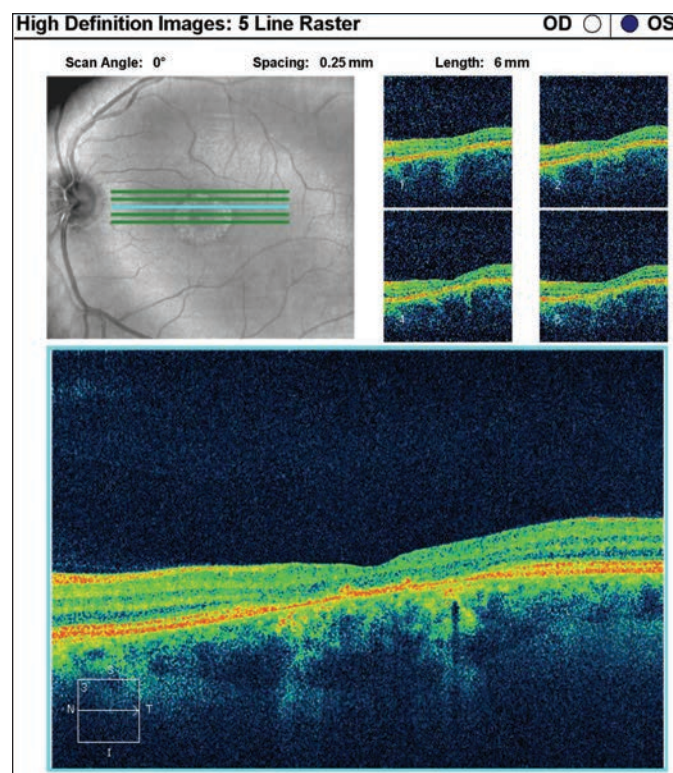
In cases such as this, with symmetrical and bilateral geographic atrophy in the absence of drusen in a young patient, genetic testing may be beneficial to establish the correct diagnosis and possibly provide an opportunity for genetic counseling.

After discussing these findings with our patient, she expressed an interest in testing for as many possible inherited macular dystrophies as possible with the hopes of obtaining a conclusive diagnosis. She was also interested in possibly joining any future clinical trials on potential treatments.

The patient's blood was drawn and sent for the comprehensive 127 gene Retinal Dystrophy Panel through the Casey Eye Institute Laboratory at Oregon Health and Science University. The test is listed at \$2,500 and is almost always paid



Figs. 3a and 3b. SD-OCT images show the patient's retinal state in both the right and left eye.



out of pocket, but for patients seeking a definitive cause for their visual impairment, this option is attractive to attain answers and closure.

A full list of available tests is available at ohsu.edu, along with instructions for specimen requisition and the relevant consent and payment forms. In most cases, the test results are available within one to three months.

The PRPH2/RDS and GUCY2D genes have been implicated in CACD and are included in the panel that will be run for this patient.^{4,5} She will be contacted with the results and notified of any clinical trials for which she may qualify. We plan to monitor her condition yearly for progression and updates on possible trials. ■

Dr. Hammond is an optometric resident at the Bascom Palmer Eye Institute in Miami.

1. Sohn E, Mullins R, Stone E. Macular Dystrophies. In: Ryan SJ ed. Retina. Vol 2, ed. V. St Louis: Mosby; 2013:864-74.
2. Yannuzzi LA. Central Areolar Choroidal Dystrophy. The Retinal Atlas. 1st ed. Saunders Elsevier; 2010. 80.
3. Genead M, Fishman G, Grover S. Hereditary Choroidal Diseases. In: Ryan SJ ed. Retina. Vol 2, ed. V. St Louis: Mosby; 2013:891-2.
4. Boon C, Klevering B, Cremers F, et al. Central areolar choroidal dystrophy. Ophthalmology. 2009;116:771-82.
5. Hughes A, Meng W, Lotery A, Bradley D. A Novel GUCY2D Mutation, V933A, causes central areolar choroidal dystrophy. Invest Ophthalmol Vis Sci. 2012;53:4748-53.



SHIFT YOUR **EHR** INTO GEAR

DRIVE PRACTICE EFFICIENCY
WITH PHOROPTOR® VRx



You've spent time and money implementing your practice's EHR system. Now take it out of neutral. Let the all-new Reichert® **Phoroptor® VRx** Digital Refraction System accelerate your exam time and drive practice efficiency.

Effortless EHR and prescreen device integration. Thinnest and most compact design. Incredibly fast. Ultra-quiet. Made in the USA.

www.reichert.com/vrx

Limited time offer: Free ClearChart® 2

Take a **test drive** with an authorized Reichert® distributor or at Vision Expo East - Booth MS 6810.



San Antonio

Up to
**19 CE
Credits**
(COPE approval pending)

REVIEW OF OPTOMETRY®
EDUCATIONAL MEETINGS OF CLINICAL EXCELLENCE



May 20-22, 2016

Superior Education with 3 Interactive Workshops

San Antonio Marriott Riverwalk

In the Heart of Downtown San Antonio

889 East Market Street | San Antonio, Texas 78205 | 210-224-4555

Discounted room rate \$189/NIGHT

Program Chair: **Paul Karpecki, OD**



REGISTER NOW!

www.ReviewofOptometry.com/SanAntonio2016

Or Email **Lois DiDomenico**: ReviewMeetings@Jobson.com | Call: 866-658-1772

3 DAYS/\$495 EARLY BIRD SPECIAL **\$100 OFF** UNTIL APRIL 1ST

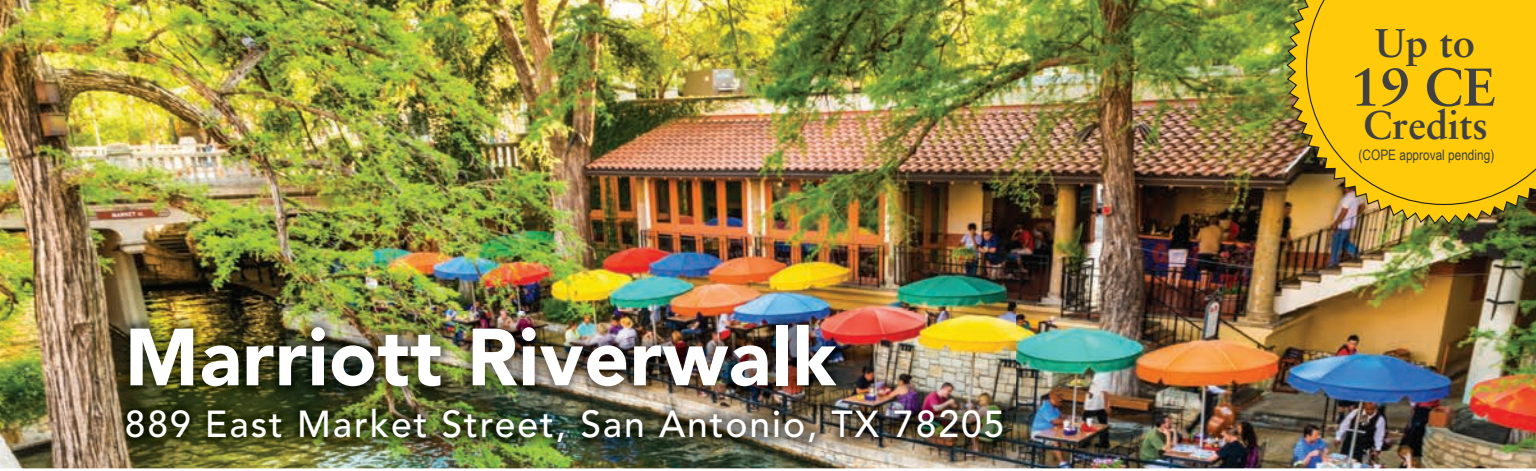

Photo: Dan Ham Photography

Administered by
Review of Optometry®

cope®
Approval pending

Up to
19 CE
Credits
(COPE approval pending)



Marriott Riverwalk

889 East Market Street, San Antonio, TX 78205

For hotel reservations call 800-648-4462
Discounted room rates limited.
Identify yourself as a participant of
"Review of Optometry" for group rate.

Registration Information

NAME		NPI # (NPI numbers will only be used for Sunshine reporting purposes)		OE TRACKER #
PRACTICE AFFILIATION				
MAILING ADDRESS		CITY	STATE	ZIP CODE
TELEPHONE	FAX	E-MAIL		

Name Badge Information (please print clearly)

MY NAME	MY GUEST	ADDITIONAL GUESTS
---------	----------	-------------------

Payment Information

	RATE PER PERSON	NO. IN PARTY	SUBTOTAL
OD Registration - \$495 (\$100 off if registered by April 1 st) <small>(includes up to 19 hours of CE, breakfasts, reception) Call or visit registration website for daily and student rates.</small>	\$495	x _____	= \$ _____
Additional Guest(s) - \$45 (12 years and older, includes reception)	\$45	x _____	= \$ _____
Concurrent Optional Workshop Sessions (Saturday, May 21 st - Earn 2 additional CE credits) <small>Select only one if interested in additional session and credits.</small>			Complimentary

- Retina Workshop (2:00pm-3:40pm)
- Glaucoma Workshop (2:00pm-3:40pm)
- Ocular Surface Disease Workshop (4:00pm - 5:40pm)

Check enclosed (make checks payable to *Review of Optometry*)

Charge my: American Express Mastercard Visa

CREDIT CARD NUMBER	EXP DATE
CARDHOLDER (PRINT NAME)	
SIGNATURE	

CONFERENCE CANCELLATION POLICY
Full refund on registration fee until April 2, 2016
50% Refund of registration fee until April 21, 2016
No refund past April 22, 2016

For more information or to register,
contact Lois DiDomenico at 866-658-1772
or at ReviewMeetings@Jobson.com.

MAIL FORM:
Review Group Meetings c/o Jobson
11 Campus Blvd, Ste. 100
Newtown Square, PA 19073

FAX FORM:
Review Meetings Group
610-492-1039



East Meets West: Herbal Supplements in Health Care


The use of herbal supplements for health and wellness is rapidly increasing worldwide. What does this mean for eye care? **By Alicia Kim, OD**

A 65-year-old black male presented with acute, painless redness of his left eye for one day. He denied any history of chronic medical conditions, although he admitted to not visiting his primary care provider (PCP) in a few years. He also denied previous episodes of ocular redness, trauma, Valsalva maneuver, contact lens wear or regular aspirin use. The patient reported using Tienchi (*Panax notoginseng*), an herbal remedy, for two weeks after reading claims that it prevents hypertension.

Clinical examination was remarkable for an acute subconjunctival hemorrhage in the left eye. Dilated fundus exam was unremarkable. Blood pressure in office measured 195/100mm Hg. A diagnosis of subconjunctival hemorrhage in the left eye was established, the likely cause of which was systemic hypertension with possible additive effects from the herbal supplement.

He was referred to his PCP for immediate re-evaluation and management of hypertension, as well as a complete physical exam and serology to rule out comorbidities such as diabetes and heart disease.

We advised the patient to discontinue his use of *Panax notoginseng* due to its potential anticoagulant and antiplatelet properties, as well as risks of systemic complications.



For centuries in Eastern medicine, herbal therapies have played a major role in the management of a host of conditions.



Photo: ©Stock.com/JabsonHealthcare

Tienchi is typically taken as a liquid herbal extract or in a tablet form.

He was advised to consult with his PCP and us before embarking on additional high-dose vitamins, herbs and supplements. We indicated that a return to *Panax notoginseng* at a lower dose can be considered after resolution of the subconjunctival hemorrhage,

as part of a physician-supervised blood pressure treatment program. Unfortunately, he was lost to follow up.

The Facts on Herbs

Botanists describe an herb as a small, seed-bearing plant with fleshy, rather than woody, parts (from which we get the term ‘herbaceous’). In addition to herbaceous perennials, herbs may include trees, shrubs, annuals, vines and more primitive plants such as ferns, mosses, algae, lichens and fungi.^{1,2} Herbs are valued for their flavor, fragrance, economic and industrial uses, pesticidal properties, coloring (dyes) and medicinal qualities.

Herbal supplements in Western health care are increasing in popularity, as many are purported to augment one’s wellbeing. Typically categorized as complementary and alternative medicine (CAM), they represent a group of health practices and products not part of standard medical care.¹ Research suggests about 38% of adults and 12% of children in the United States use some form of CAM.¹

Researchers estimate that more than 15 million Americans today take herbs, vitamins or both, along with their prescription medications.² These numbers are expected to rise with easy access to unfiltered information from nutraceutical companies and the Internet.

Most herbal supplements are available over-the-counter (OTC) and easily found online, at local stores and in pharmacies. They come in all forms (dried, chopped, powdered, capsule or liquid) and can be used in a variety of ways, including:

- Swallowed as pills
- Brewed as tea
- Applied to the skin as gels
- Added to bath water

The FDA currently considers herbal supplements as food products, and as such they are not subject to the same clinical trials, manufacturing standards and regulations as drugs.^{1,2}

Many prescription drugs and OTC medicines are also made from plant derivatives, but these products contain only purified ingredients and are regulated by the FDA.

What is Tienchi?

Panax notoginseng is prescribed in traditional Chinese medicine to improve circulation and resolve blood stasis.³ It is often used in an attempt to decrease blood pressure and slow the heart rate, as it exhibits antiplatelet and anticoagulant properties.³

Researchers demonstrated significant inhibition of platelet aggregation using both raw and steamed forms of *Panax notoginseng*.⁴ Results overall demonstrated samples that were steamed for two hours (3.3mg/ml) had similar partial thromboplastin time as heparin (0.033U/ml).⁴ An oral dose of 500mg/kg of steamed *Panax notoginseng* also had a similar percentage of platelet inhibition as 25mg/kg of aspirin.⁴

Adverse effects include bleeding complications, herb-drug interactions and vasodilation and vasoconstriction, depending on the dose and the targeted blood vessels.^{3,4}

Information on Herbal Supplements

Office of Dietary Supplements (ODS), National Institutes of Health (NIH)

<https://ods.od.nih.gov/>

- The ODS evaluates scientific information, stimulates and supports research, disseminates research results and educates the public on issues regarding dietary supplements.

National Center for Complementary and Integrative Health (NCCIH), NIH

<https://nccih.nih.gov/>

- The NCCIH is the federal government's lead agency for scientific research on the diverse medical and health care systems, practices and products that are not generally considered part of conventional medicine.

National Registry of Drug-induced Ocular Side Effects

www.eyedrugregistry.com

- This registry is an international clearinghouse of information on adverse ocular events associated with drugs, chemicals and herbals.

Natural Medicines Comprehensive Database

<http://naturaldatabase.therapeuticresearch.com/home.aspx>

- This is a database providing information on herbal remedies, dietary supplements, vitamins, minerals and other natural products. The information is evidence-based and unbiased, using current peer-reviewed research.

Other Common Herbs

Patients are beginning to use several common herbal supplements more frequently for the prevention, treatment or both of ocular and systemic conditions:

- *Allium sativum*, or garlic supplement, is often taken for cardiovascular conditions or infectious disease prevention.^{5,6} It may reduce plaque formation, inhibit platelet aggregation, increase fibrinolysis and reduce blood pressure.^{5,6,7} Adverse effects associated with high doses include hypotension, herb-drug interactions, nausea and bleeding complications.^{5,6}

- *Ginkgo biloba*, also known as just ginkgo or the maidenhair tree, is among the most widely used herbs for conditions ranging from memory loss to poor blood circulation, and even glaucoma.⁷ The chemical components may have anti-inflammatory and neuroprotective properties and may improve blood flow.⁸

Recent studies on *Ginkgo biloba* as an alternative treatment for



Photo: ©Stock.com/JobsonHealthcare

Although the precise mode of *Ginkgo biloba*'s action is not fully understood, it is a potent antioxidant and free-radical scavenger, nitric oxide inhibitor, vasodilator, platelet-activating factor inhibitor and glutamate NMDA receptor inhibitor.

glaucoma have shown improvement in visual fields. The theory is that the herb reduces peripheral vasospasm, subsequently improving ocular perfusion.^{9,10}

Ginkgo biloba was shown to increase the survival of retinal

ganglion cells in experimental models of glaucoma in a dose-dependent manner.¹¹ However, only limited data are available to support its clinical use in glaucoma prevention and treatment.^{7-10,12}

Adverse effects include herb-drug interactions and bleeding disorders, which may result in ocular hemorrhage or hyphema.^{7,12} *Ginkgo biloba* should be avoided by patients using anticoagulant therapies such as Coumadin (warfarin sodium, Bristol-Myers Squibb), heparin, Plavix (clopidogrel bisulfate, Bristol-Myers Squibb) and aspirin. It may also increase the risk of bleeding disorders in those on high-dose omega-3 fish oil.

- *Cannabis sativa*, or marijuana, is used for various conditions including muscle spasms, seizure disorder, Crohn's disease, chronic pain, nausea and vomiting caused by chemotherapy and loss of appetite and weight in people with AIDS.^{1,2,5,7} It has also been used to lower IOP by reducing aqueous humor production.^{7,13} A recent study suggests some efficacy in IOP lowering, but the effects are short-term, and both oral and inhaled preparations were not tolerated for more than a few months due to significant adverse effects.

Adverse effects include short-term memory loss, drowsiness, euphoria and dependency.¹³

- *Vaccinium myrtillus*, or bilberry, is often used for atherosclerotic conditions, diarrhea and protection of retinal tissue.⁷ Bilberry contains antioxidants such as resveratrol and a class of chemical compounds known as anthocyanosides, which may maintain rhodopsin levels essential for night vision.¹⁴

Research suggests bilberry has antioxidative and antiangiogenic properties that may help decrease blood vessel permeability in dia-

betin retinopathy and age-related macular degeneration.^{15,16}

Adverse effects include bleeding, constipation and nausea.^{16,17}

Tips for Clinicians

A 2006 survey evaluated whether herbal medicines interfere with the effects of anticoagulant and antiplatelet therapies.¹⁸ Among the 250 patients, 42.4% used herbal medicines, and 21% of those patients co-ingested herbal supplements with antiplatelet and anticoagulant therapy. About 50% of patients who co-ingested were at risk for potential drug-herb interaction. More than 90% did not reveal the use of herbal supplements to their health care providers, highlighting the need for proper history taking and communication, as well as a greater practitioner awareness.¹⁸

Because patients may not disclose the use of herbal supplements to their health care providers without specifically being asked, it is critical that optometrists include questions about vitamins, minerals and herbal supplements when conducting a pharmacologic history. Patients may ask your opinion on the efficacy and safety of herbal remedies and other types of CAM for ocular conditions, and you should not dismiss them; instead, look to the scientific evidence available and advise accordingly.

Fortunately, we are not alone. Clinical pharmacists, registered dietitians and certified nutritionists are frequently well versed on herbal remedies. Find one whose philosophies align with yours, keeping patient health and wellness as the paramount goal. If you recommend a particular vitamin, herb or supplement for your patients, send a courtesy letter to their PCPs describing the specific therapy, dosing and rationale for treatment.

Because herbal remedies and supplements are commonly prescribed by Eastern medicine, other health care providers and even patients themselves, knowing the most frequently used agents will permit better understanding of their benefits and possible adverse sequelae and aid in proper management. ■

Dr. Kim practices at LakeRidge Vision Source, a private practice located in Virginia, and is a fellow of the American Academy of Optometry.

1. Barnes PM, Bloom B, Nahin R. The Use of Complementary and Alternative Medicine in the United States. 2008. http://nccam.nih.gov/news/camstats/2007/camsurvey_fs1.htm. Accessed January 2, 2015.
2. Eisenberg DM, Davis RB, Ettner SL, et al. Trends in alternative medicine use in the United States, 1990-1997: results of a follow-up national survey. *JAMA*. 1998;280:1569-75.
3. Lei XL, Chiou GC. Cardiovascular pharmacology of Panax notoginseng (Burk) F.H. Chen and Salvia miltiorrhiza. *Am J Chin Med*. 1986;14(3-4):145-52.
4. Lau AJ, Toh DF, Chua TK, et al. Antiplatelet and anticoagulant effects of Panax notoginseng: comparison of raw and steamed Panax notoginseng with Panax ginseng and Panax quinquefolium. *J Ethnopharmacol*. 2009;125(3):380-6.
5. Anastasi JK, Chang M, Capili B. Herbal supplements: Talking with your patients. *Journal for Nurse Practitioners*. 2011;7(1):29-35.
6. Wong A, Townley SA. Herbal medicines and anesthesia. *Cont Edu Anaesth Crit Care and Pain*. 2011;11(1):14-17.
7. Schwartz S, Chavis P. Dietary supplements and the ophthalmologist. *Compr Ophthalmol Update*. 2005;6(3):153-9.
8. DeFeudis FV, Drieu K. Ginkgo biloba extract (EGb 761) and CNS functions: basic studies and clinical applications. *Curr Drug Targets*. 2000;1(1):25-58.
9. Quaranta L, Bettelli S, Uva MG, et al. Effect of Ginkgo biloba extract on preexisting visual field damage in normal tension glaucoma. *Ophthalmology*. 2003;110:359-62.
10. Guo X, Kong X, Huang R, et al. Effect of Ginkgo biloba on visual field and contrast sensitivity in Chinese patients with normal tension glaucoma: a randomized, crossover clinical trial. *Invest Ophthalmol Vis Sci*. 2014;55:110-6.
11. Ma K, Xu L, Zhan H, et al. Dosage dependence of the effect of Ginkgo biloba on the rat retinal ganglion cell survival after optic nerve crush. *Eye*. 2009;23:1598-1604.
12. Schneider C, Bord C, Misse P, et al. Spontaneous hyphema caused by Ginkgo biloba extract. *J Fr Ophthalmol*. 2002;25(7):731-2.
13. Flach AJ. Delta-9-tetrahydrocannabinol (THC) in the treatment of end-stage open-angle glaucoma. *Trans Am Ophthalmol Soc*. 2002;100:215-22.
14. Canter PH, Ernst E. Anthocyanosides of *Vaccinium myrtillus* (bilberry) for night vision—a systematic review of placebo-controlled trials. *Surv Ophthalmol*. 2004;49:38-50.
15. Roy S, Khanna S, Alessio HM, et al. Anti-angiogenic property of edible berries. *Free Radic Res*. 2002;36:9:1023-31.
16. Izzo AA, Ernst E. Interactions between herbal medicines and prescribed drugs: an updated systematic review. *Drugs*. 2009;69(13):1777-98.
17. Ulbricht C, Basch E, Basch S, et al. An evidence-based systemic review of bilberry (*Vaccinium myrtillus*) by the Natural Standard Research Collaboration. *J Diet Suppl*. 2009;6(2):162-200.
18. Saw JT, Bahari MB, Ang HH, Lim YH. Potential drug-herb interaction with antiplatelet/anticoagulant drugs. *Complement Ther Clin Pract*. 2006;12(4):236-41.

VISION FOR TOMORROW BECOMES REALITY – TODAY!

For a quarter of a century Vision Source® has been committed to enriching the lives of independent optometrists by enabling them to reach their full potential. This commitment remains stronger than ever as evidenced by our latest introduction – **The Vision Source® Practice of the Future**.

The Vision Source® Practice of the Future — Created By Optometrists, For Optometrists

This state-of-the-art model will change how independent optometrists engage with their patient universe. A seamless 360° solution delivers a world-class patient experience that will be in sync with consumer expectations for years to come.

Vision Source® staff member trained on one of 70,000 courses taken to date on vslearning.com

Vision Source® doctor recently certified in diabetes mellitus care

Vision Source® optical staff participant in The Optical DreamSM as she implements world class patient presentation skills

New Vision Source® patient acquired through 100+ managed care relationships

Virtual Frame-On-Face technology providing a seamless patient experience, online and in office

New Vision Source® patient attracted through national Vision Source® TV advertising



Today, 25 years and 4,000+ members since our inception, we train our vision on forging an even brighter future for our network members that promises:



MORE PATIENTS



MORE PROFITS



MORE TIME

For more information on joining Vision Source®, go to www.VisionSourcePlan.com



BERMUDA

Up to
18 CE
Credits
(COPE approval pending)

Image courtesy of Hamilton Princess & Beach Club, A Fairmont Managed Hotel

REVIEW OF OPTOMETRY®
EDUCATIONAL MEETINGS OF CLINICAL EXCELLENCE



JUNE 9-12, 2016

Superior Education with 3 Interactive Workshops

Hamilton Princess & Beach Club

A Fairmont Managed Hotel

76 Pitts Bay Road | Hamilton, BERMUDA HM 08 | 441-295-3000

Discounted room rate **\$299-\$329/NIGHT**

Program Chair: **Paul Karpecki, OD**



REGISTER NOW!

www.ReviewofOptometry.com/Bermuda2016

Or Email **Lois DiDomenico**: ReviewMeetings@Jobson.com | Call: 866-658-1772

4 DAYS / \$595 EARLY BIRD SPECIAL \$100 OFF UNTIL APRIL 1ST



Administered by
Review of Optometry®

cope®
Approval pending



Stye vs. Stye

Tips on managing both external and internal hordeola.

By Alan G. Kabat, OD, and Joseph W. Sowka, OD

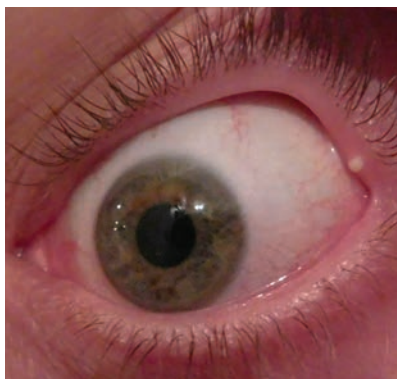One of the greatest things about being an optometric educator is the constant challenge of young, inquisitive minds. While may old, weathered practitioners like ourselves may sometimes “just know” how to manage certain conditions, clinicians-in-training often need to understand the “why” of therapeutic interventions. And so, when a student recently questioned our traditional, conservative management for hordeola, commonly referred to as a “stye,” we decided it was time to review the literature and consider the why of our ways.

Hordeola represent acute bacterial infection and subsequent abscess formation of the eyelid’s sebaceous glands.¹⁻³ Two forms are recognized clinically:

1. External hordeola, which involve the more superficial Zeis glands situated at the base of the lashes.

2. Internal hordeola, which affect the deeper meibomian glands within the tarsal plate.¹⁻³

Most often, hordeola present as tender or painful eyelid papules with associated erythema of the involved skin. External hordeola, if large or superficial enough, may demonstrate purulent material within the gland through thinning of the overlying epidermis. When this occurs, the hordeolum is “pointing.” Internal hordeola create a more diffuse eyelid swelling due to the infected gland expanding within the tarsus, although the presentation is still



An external hordeolum on the left upper eyelid, with classic “pointing” at the lid margin.

consistent with a firm, tender subcutaneous nodule. Pointing may also be seen with internal hordeola, but because of its deeper location, the lesion must be of substantial size and severity before this occurs. Additionally, internal hordeola pointing can occur at either the skin or conjunctival surface.¹

Traditional Therapy

Historically, we were taught that most hordeola are self-limiting, and do not require aggressive therapy. The use of heated compresses, applied for five to 10 minutes several times a day with concurrent digital massage can hasten pointing and subsequent drainage of the abscess. Topical antibiotic ointments may be prescribed for associated blepharitis, but typically will not achieve sufficient concentrations in deeper lid tissue to eliminate the infection; hence, these agents are considered to be of little benefit. We

were cautioned against attempting to express or “pop” a hordeolum (unless it was superficial and already pointing). Such vigorous manipulation can be extremely painful for the patient, but more importantly it can potentiate the spread of infection to adjacent glands and tissue, resulting in a more serious preseptal cellulitis. Should secondary chalazia (granulomatous formation within the meibomian gland following resolution of the infectious hordeolum) develop, intralesional corticosteroid injection or surgical incision and curettage can be performed.

Reviewing the Literature

In an attempt to gather more unbiased, peer-reviewed and evidence-based information on this topic, we conducted a PubMed search using the term “hordeolum.” Only 26 English-language articles were published in the last 10 years and, of those, only seven were review articles. This paucity of reports on relatively common clinical entities is often the rule, rather than the exception. Many conditions are regarded as so familiar and straightforward that they simply do not warrant much scientific attention in true clinical studies.

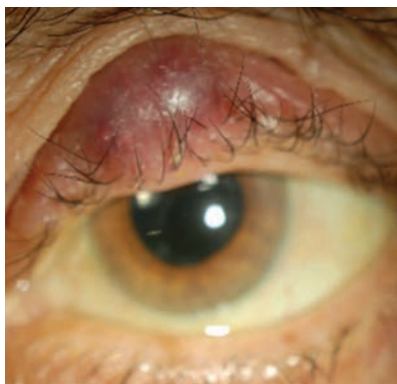
To gain additional perspective about the current prevailing attitudes toward hordeolum management, we resorted to referenced works on known medical websites, such as Medscape, EyeWiki, Merck Manual and Family Practice Notebook.⁴⁻⁸ While these sources do

Therapeutic Review

not offer the most rigorous scientific evidence, they do provide information regarding expert opinion and practice, presented below.

Conservative Therapies

Most current resources for both internal and external hordeola advise the use of warm or hot compresses in five to 20 minute durations, two to four times daily.⁴⁻⁸ One report recommended concurrent massage of the hordeolum.⁵ A few sources mentioned daily eyelid and lid margin cleansing for associated blepharitis.^{5,8} Interestingly, a recent meta-analysis of 944 potentially relevant references found no credible evidence regarding the effectiveness of the aforementioned treatments for acute internal hordeolum.^{1,3} The authors concluded that, while warm compresses and lid scrubs are not unsafe, they show no measurable benefit as compared with simple observation.³



An internal hordeolum of the upper eyelid in a 75-year-old woman. This patient required a course of oral cephalixin to achieve resolution.

Medical Treatment

Investigators advocate topical antibiotic ointments for cases of external hordeola, primarily as a prophylactic measure to protect against infection of adjacent glands.¹ The majority of medical websites we surveyed also suggest topical antibiotic (or com-

bination antibiotic-corticosteroid) ointment as a potential option, primarily for hordeola that are actively draining.^{4-6,8}

However, one source specifically states “topical antibiotics are usually ineffective” in the treatment of internal hordeola.⁷

All of the websites except one advocated the use of oral antibiotics (e.g., dicloxacillin or erythromycin 250mg PO QID) in recalcitrant cases, recurrent hordeola or in those with suspected preseptal cellulitis.^{4,5,7,8}

Surgical Management

In cases of external hordeola, mechanical epilation of the associated lash follicle may allow spontaneous drainage of the affected gland.^{1,4} Incision and drainage of acute hordeola is generally not advocated as a first-line therapy; however, it may be advantageous in cases where:

Your Next Patient Is
Just a *Click* Away

With help from comprehensive online marketing services from iMatrix.

Act now to receive **40% off initial product setup.**

1. The hordeolum is pointing at the time of initial presentation.

2. The hordeolum proves refractory to more conservative medical therapy.^{1,5,7-10}

Incision and drainage of external hordeola may be performed at the slit lamp using topical anesthesia and an 18-gauge or 20-gauge needle.

Incision and drainage of internal hordeola requires a local anesthetic delivered by injection to the involved eyelid. It is customary to employ a stab incision with a #11 blade, ideally using a transconjunctival approach, to avoid potential scarring of the external lid.^{4,6} A topical antibiotic should be applied to the incision site for 24 hours following the procedure.

We also routinely advocate a course of oral antibiotics if surgical incision and drainage is performed for internal hordeola, as this procedure has the potential to liberate

pathogenic bacteria into surrounding tissue and also the bloodstream.

Aged Wisdom

From time to time, it's important to review and reconsider our therapeutic approaches, even to the most seemingly mundane and straightforward ocular conditions. Medical science often advances faster than we realize, leaving us citing and employing outdated and dogmatic management strategies. Fortunately, in the case of acute hordeola, it would seem that our instinctive philosophies based on 50+ years of combined practice experience aren't too far off the mark. To summarize:

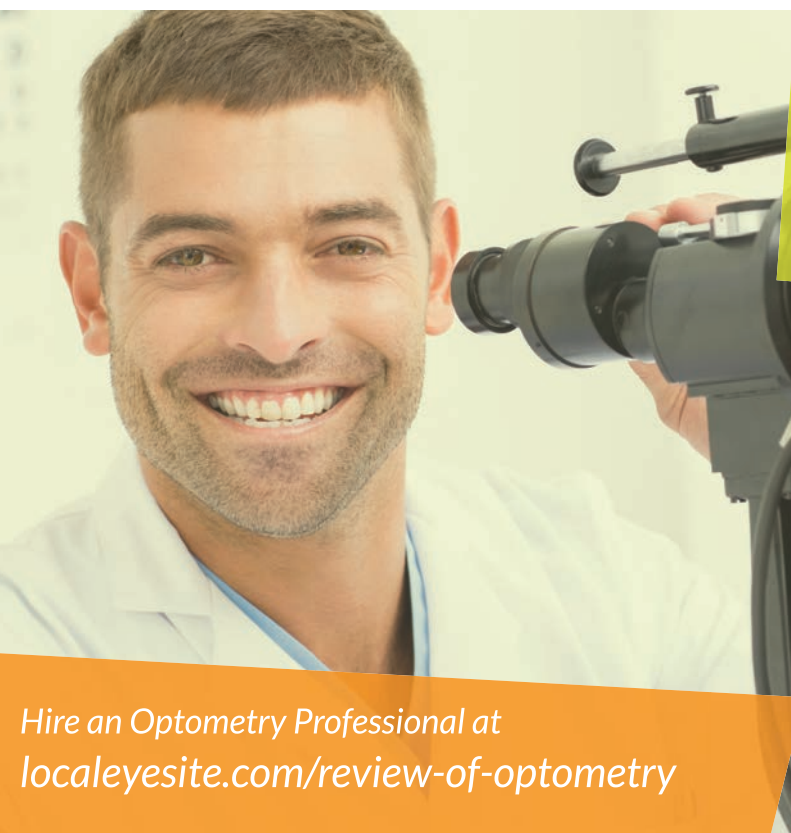1. Hot compresses are still widely advocated, although little scientific evidence demonstrates a benefit in acute hordeola cases.

2. Topical antibiotics appear to be equivocal in these cases, in both recommendation and effect.

3. Oral antibiotics are strongly recommended for recalcitrant or severe cases of hordeola.

4. Surgical incision and drainage may likewise be indicated in hordeola that have reached advanced stages. ■

1. Olson MD. The common stye. *J Sch Health*. 1991 Feb;61(2):95-7.
2. Wald ER. Periorbital and orbital infections. *Pediatr Rev*. 2004 Sep;25(9):312-20.
3. Lindsley K, Nichols JJ, Dickersin K. Interventions for acute internal hordeolum. *Cochrane Database Syst Rev*. 2013 Apr 30;4:CD007742.
4. Bessette MJ. Hordeolum and Stye in Emergency Medicine. *Medscape*. 2015. Available at: <http://emedicine.medscape.com/article/798940>. Accessed February 5, 2016.
5. Ehrenhaus MP. Hordeolum. *Medscape*. 2015. Available at: <http://emedicine.medscape.com/article/1213080>. Accessed February 5, 2016.
6. Baharestani S, Nguyen Burkat C, Marcet MM, et al. Stye. *EyeWiki*. 2015. Available at: <http://eyewiki.aaopt.org/stye>. Accessed February 5, 2016.
7. Garrity J. Chalazion and Hordeolum (Stye). *Merck Manual*. 2014. Available at: [http://www.merckmanuals.com/professional/eye-disorders/eyelid-and-lacrimal-disorders/chalazion-and-hordeolum-\(stye\)](http://www.merckmanuals.com/professional/eye-disorders/eyelid-and-lacrimal-disorders/chalazion-and-hordeolum-(stye)). Accessed February 5, 2016.
8. Hordeolum. *Family Practice Notebook*. Available at: <http://www.fpnotebook.com/eye/lid/hrdlm.htm>. Accessed February 5, 2016.
9. Cheng K, Wang X, Guo M, et al. Acupuncture for acute hordeolum. *Cochrane Database Syst Rev*. 2014 Apr 19;2014: pii: CD011075.
10. Mueller JB, McStay CM. Ocular infection and inflammation. *Emerg Med Clin North Am*. 2008 Feb; 26(1):57-72, vi.



Hire the Best in Optometry

“We have been extremely pleased with everything Local Eye Site has done in streamlining our search for hiring qualified candidates. This should be the only source needed for all eye care job openings!”

Tracey Glendenning, OD

Doctors Vision Center
Wilmington, NC



Optometry's
meeting®

LEARN. LEAD. CONNECT.

Registration is Now Open!

**JOIN US FOR OPTOMETRY'S MEETING®
IN BOSTON, JUNE 29 – JULY 3, 2016**

LEARN. LEAD. CONNECT.

Three words that not only represent the essence of Optometry's Meeting®, but also the boundless opportunities to make a positive impact on your career and our profession.

LEARN. Expanded continuing education programming means five full days of the best continuing education in our industry. Earn 30+ hours of accredited education from a vast selection of new and unique courses.

LEAD. Optometry's Meeting allows every participant to make our association an even stronger and more effective advocate for our profession and our practices. Attend the House of Delegates, optometry's governing body that has helped lead the advancement of our profession for more than a century, during public sessions on Thursday and Saturday.

CONNECT. Optometry's Meeting brings it all together—in one place—for you. This is your one-stop shop for meeting with industry leaders in the exhibit hall and connecting with your colleagues across five full days of events.

Register now for Optometry's Meeting, the only event that brings the optometry community together to shape the future of the profession. Make a difference in your profession, connect with peers and get the best CE only at Optometry's Meeting.

Register today at
optometrymeeting.org

REGISTER BY MAY 2 FOR BEST RATES



Product Review

Contact Lenses

New Monthly SiHy Multifocal Launched

Bausch + Lomb recently added a new multifocal option to its Ultra contact lens line, called Ultra for Presbyopia.

The monthly replacement lens combines the Ultra material's high wettability with the three-zone progressive design found in Bausch + Lomb's daily disposable multifocals. The lens uses polyvinylpyrrolidone, allowing it the highest Dk/t (163) and lowest modulus (70) on the market, Bausch + Lomb says. The lens also has aspheric optics for better vision in low light conditions, according to B+L.

Visit www.bausch.com/our-products.

New Packaging Option

Optometrists can now offer presbyopes a convenient 90-day pack of CooperVision's Clariti 1-Day multifocal contact lenses. The Clariti 1-Day lenses provide presbyopia patients with the benefits of silicone hydrogels and the advantages of a daily modality, resulting in a healthier contact lens-wearing experience, according to CooperVision. The lenses feature a base curve of 8.6mm, a diameter of 14.1mm, and a Dk/t (@-3.00D) of 86, with a power range of +5.00D to -6.00D (0.25 steps) with add powers of low (up to +2.25D) and high (+2.50 to +3.00D), according to CooperVision.



Visit coopervision.com.

Ophthalmic Lenses

New Lens Material to Debut

At Vision Expo East, FastGrind will launch VisionAir 1.56 index, a material for use with its digital progressive and single vision lenses. It allows practices to accommodate a wider Rx range without concern for thick, bulky lenses or limited frame options, the manufacturer says. Single vision lenses can be surfaced to a -10.00 and up to a +9.00 prescription with ease. Visit FastGrind at Vision Expo East, Booth #LP7558.

Practice Management

Redesigned Virtual Education Website

EyePromise has redesigned its Eye Care Support Program (ESP), to provide practitioners additional opportunities for education on topics related to ocular nutrition, according to EyePromise's parent company

ZeaVision. The new education portal now includes EyePromise University and the EyePromise rewards program. The program allows optometrists to earn reward points, redeemable in ESP's rewards center, in exchange for course enrollment and product purchases within the portal.

Visit www.eyepromise.com.



Diagnostic Technology

New OCT Angiography System

Optovue now offers a new imaging system, the AngioVue, that allows optometrists to view abnormal retinal vasculature noninvasively. Unlike FA, AngioVue does not require the use of dye injections, which can often obscure the target anatomy, leading to side effects and other complications, according to the company.

In less than three seconds, the AngioVue system acquires a single image that complements fluorescein angiography, Optovue says.

Visit www.optovue.com/products/angiovue.

Oculus Adds New Pentacam Model

The Pentacam's new AXL model integrates axial length measurement, allowing optometrists to make accurate IOL calculations using one device with one measurement procedure, Oculus says. The network-compatible IOL calculation software offers standard, ray-tracing and post-surgical cornea formulas.



The new model also includes a comprehensive IOL database with IOL constants. With IOL constant optimization, surgical data and post-refractive exam findings are secured with a few clicks, Oculus says.

Some of the Pentacam AXL's features include:

- Fast screening report
- Belin/Ambrósio enhanced ectasia display
- Densitometric evaluation
- Cataract pre-op display: select premium IOL in four steps. Calculations for toric IOLs use total corneal refractive power.

Visit www.pentacamaxl.com. ■

March 2016

■ **17-20.** *VT/Strabismus and Amblyopia.* OEP National Education Center, Timonium, MD. Hosted by: OEP Foundation. Key faculty: Robert A. Hohendorf. CE hours: 28. To register, email Karen Ruder at karen.ruder@oep.org, call (410) 561-3791 or go to www.oepf.org/oepf_calendar.

■ **17-22.** *Symposium on Ocular Disease.* Crowne Plaza Hotel, Tyson's Corner, VA. Hosted by: PSS EyeCare. Key faculty: Ron Melton, Randall Thomas, Mile Brujic, William Jones, Elliot Kirstein, Deepak Gupta. CE hours: 18. To register, email Sonia Kumari at education@psseyecare.com, call (203) 415-3087 or go to www.psseyecare.com.

■ **18.** *Binocular Vision and Pediatrics Forum.* Ohio State University College of Optometry, Columbus, Ohio. Hosted by: Ohio State University College of Optometry. Key faculty: Suzanne Wickum. CE hours: 7. To register, email Catherine McDaniel at mcdaniel.547@osu.edu, call (614)688-1425 or go to <http://optometry.osu.edu/CE/BVPforum.cfm>.

■ **18-20.** *Primary Eye Care Update.* UAB School of Optometry, Birmingham, AL. Hosted by: UAB School of Optometry. CE hours: 18. To register, email Amanda Kachler at uabsoce@uab.edu, call (205) 934-5701 or go to www.uab.edu/optometry/ce.

■ **20.** *Cornea Symposium.* The Colonnade Hotel, Boston. Hosted by: New England College of Optometry. CE hours: 7. To register, email Tony Cavallerano at cavalleranot@neco.edu, call (617) 587-5687 or go to www.neco.edu/academics/continuing-education.

■ **31-Apr. 4.** *Art + Science of Optometric Care.* South Kent Vision Center, Grand Rapids, MI. Hosted by: OEP Foundation. Key faculty: Robert A. Hohendorf. CE hours: 35. To register, email Karen Ruder at karen.ruder@oep.org, call (410) 561-3791 or go to www.oepf.org/oepf_calendar.

April 2016

■ **1.** *ICO Resident Grand Rounds.* Illinois College of Optometry, Chicago. Hosted by: Illinois College of Optometry. CE hours: 4. To register, email Elizabeth Grantner at continuinged@ico.edu, call (312) 949-7426 or go to www.ico.edu/alumni/continuing-education.

■ **2-3.** *Miami Nice Educational Symposium.* Coral Gables Country Club, Coral Gables, FL. Hosted by: Miami Dade Optometric Physicians Association. Key faculty: Anthony Litwak, Brian DenBeste, Kim Reed, Albert Woods, Tim Underhill. CE hours: 17. To register, email Stephen Morris at mdopa.board@gmail.com or go to miamieyes.org.

■ **2-3.** *MOS Annual Spring Conference.* Cincinnati Marriott Northeast, Cincinnati, OH. Hosted by: Midwest Optometric Society and The Ohio State College of Optometry. Key faculty: Elliot Kirstein, Todd Zelczak, Pinakin Davey. CE hours: 16. To

register, go to www.midwestoptometricsociety.com, or for more info, call Marcy at (513) 321-2020.

■ **3.** *Retinal Dilemmas: What Now?* New England College of Optometry, Boston. Hosted by: New England College of Optometry. Key faculty: Steven Ferrucci, Baharak Asefzadeh. CE hours: 5. To register, email Tony Cavallerano at cavalleranot@neco.edu, call (617) 587-5687, or go to www.neco.edu/academics/continuing-education.

■ **7-10.** *New Technologies and Treatments in Vision Care, OCCRS Joint Meeting.* Hotel del Coronado, San Diego. Hosted by: *Review of Optometry*. Key faculty: Paul Karpecki. CE hours: 25. To register, email Lois DiDomenico at reviewmeetings@jobson.com, call (866) 658-1772 or go to www.reviewofoptometry.com/sandiego2016.

■ **9-10.** *Optometric CE Annual Symposium.* Marriott Las Vegas, Las Vegas. Hosted by: Optometric CE. Key faculty: William Jones, Bryan Wolynski, Michael Santarlas, Michael Samuel. CE hours: 12. To register, email Joel Rothschild at admin@OptometricCE.org, call (909) 255-0464 or go to www.OptometricCE.org.

■ **9-10.** *OCCRS Annual Education Symposium.* Hotel Del Coronado, Coronado, CA. Hosted by: Optometric Cornea, Cataract and Refractive Society. Key faculty: Paul Karpecki, Andy Morgenstern, Marc Bloomenstein, David Geffen, Jim Owen, Bill Tullo. CE hours: 12. To register, email Andrew Morgenstern at andrewmorgenstern@gmail.com, call (202) 423-3500 or go to www.occrs.org.

■ **9-10.** *IX Annual Ocular Nutrition Symposium.* University of Missouri-St. Louis, St. Louis, MO. Hosted by: University of Missouri-St. Louis and Ocular Nutrition Society. Key faculty: Aron Barbey, Liz Johnson, Lisa Renzi Hammond (tentative). CE hours: 12. To register, email Lis Ellerbusch at ellerbusch@umsl.edu or call (314) 516-5615.

■ **9-10.** *RSO Spring Seminar.* Rosenberg School of Optometry, San Antonio, TX. Hosted by: Rosenberg School of Optometry. CE hours: 16. To register, email Sandra Fortenberry at rsoce@uiwtx.edu, call (210) 283-6856 or go to www.uiw.edu/optometry/continuing-education.

■ **10.** *Cornea & Contact Lens CE Program.* Marshall B. Ketchum University, Fullerton, CA. Hosted by: Marshall B. Ketchum University. Key faculty: Timothy Edrington. CE hours: 8. To register, email Antoinette Smith at ce@ketchum.edu, call (714) 449-7495 or go to www.ketchum.edu/index.php/ce.

■ **12-16.** *COVD 46th Annual Meeting.* Hyatt Regency St. Louis at the Arch, St. Louis, MO. Hosted by: College of Optometrists in Vision Development. Key faculty: Dominick Maino, Sherry Bass, Susan Cotter, Kia Eldred, Philip Bugaiski, Derek Tong. CE hours: 86 total, 32 per OD. To register, email Penny at penny@covd.org, call (330) 995-0718 or go to www.covd.org.

Advertisers Index

For advertising opportunities contact:

Michele Barrett (215) 519-1414 or mbarrett@jobson.com

James Henne (610) 492-1017 or jhenne@jobson.com

Michael Hoster (610) 492-1028 or mhoster@jobson.com

- **13-14.** *2016 Spring Seminar.* Hyatt on Main, Green Bay, WI. Hosted by: Wisconsin Optometric Association. CE hours: 14. To register, email Joleen Breunig at joleen@woa-eyes.org, call (608) 824-2200 or go to www.woa-eyes.org.
- **13-23.** *AEA Cruises Mediterranean Optometric Cruise Seminar.* Barcelona to Athens, aboard Silversea and Silverwind. Hosted by: AEA Cruises. CE hours: 10. To register, email Marge McGrath at aeacruises@aol.com, call (888) 638-6009 or go to www.optometriccruiseseminars.com.
- **14-17.** *Vision Expo East.* Jacob Javits Center, New York. Hosted by: International Vision Expo & Conference. CE hours: 320 total, 40 per OD. To register, email Leigh Mann at LMann@reedexpo.com, call (203) 840-5452 or go to www.visionexpoeast.com.
- **15-16.** *2016 Coeur d'Alene CE.* Coeur d'Alene Resort and Spa, Coeur d'Alene, ID. Hosted by: Pacific University. Key faculty: Mark Andre, Fraser Horn, Spokane VA optometry residents. CE hours: 10. To register, email Jeanne Oliver at jeanne@pacificu.edu, call (503) 352-2740 or go to www.pacificu.edu.
- **15-17.** *New Mexico Optometric Association Annual Convention.* Isleta Pueblo Resort, Albuquerque, NM. Hosted by: New Mexico Optometric Association. Key faculty: Steve Ferruci, Jeff Walline, Greg Schultz, Doug Devries, Kim Reed, John Pitcher III. CE hours: 22. To register, email Richard Montoya at newmexicooptometry@gmail.com, call (575) 751-7242 or go to www.newmexicooptometry.org.
- **15-17.** *Indiana Optometry's Meeting—the 119th Annual Convention.* Westin Hotel Downtown Indianapolis, Indianapolis. Hosted by: Indiana Optometric Association. CE hours: 16. To register, email Bridget Sims at blsims@ioa.org, call (317) 237-3560 or go to www.ioa.org.
- **16-17.** *24th Annual Suncoast Seminar.* Hyatt Regency Clearwater Beach Resort & Spa, Clearwater, FL. Hosted by: Pinellas Optometric Association. CE hours: 14, including 6 TQ, jurisprudence and medical errors. To register, call (727) 446-8186 or email idoc1@aol.com.
- **17.** *OptoWest North.* Walnut Creek, CA. Hosted by: California Optometric Association. Key faculty: Leo Semes, Todd Severin, Tami Hagemeyer. CE hours: 12 total, 6 per OD and 6 per staff. To register, email Sarah Harbin at sharbin@coavision.org or go to www.coavision.org. ■

To list your meeting, please send the details to:

Jack Persico
 Editor-in-Chief
Email: jpersico@jobson.com
Phone: (610) 492-1006

- Acuity Pro/VisionScience Software, Inc.** **67**
 Phone (877) 228-4890
 or (580) 243-1301
 Fax..... (580) 243-1377
 info@acuitypro.com
- Alcon Laboratories** **25, 26**
 **82-83, 124**
 Phone (800) 451-3937
 Fax..... (817) 551-4352
- Allergan, Inc.** **9, 10**
 Phone (800) 347-4500
- Bausch + Lomb** **11, 12**
 **18 A-D, 53, 54-55, 72-73, 74**
 Phone (800) 323-0000
 Fax..... (813) 975-7762
- Clear Eyes** **43**
 Phone (877) 274-1787
 www.cleareyes.com
- CooperVision** **123**
 Phone (800) 341-2020
- Essilor of America**..... **15**
 www.essilorusa.com
- HAI Laboratories** **69**
 Phone (781) 862-9884
 Fax..... (781) 860-7722
- Keeler Instruments**..... **5**
 Phone (800) 523-5620
 Fax..... (610) 353-7814
- Lombart Instruments** **99**
 Phone (800) 446-8092
 Fax..... (757) 855-1232
- M&S Technologies**..... **61**
 Phone (877) 225-6101
 Fax..... (847) 763-9170
- Natural Ophthalmics, Inc.**..... **17**
 Phone (877) 220-9710
 info@natoph.com
 www.natoph.com
- Odyssey Medical (now part of Beaver-Visitec International, Inc.)** **23**
 Phone (866) 906-8080
 www.odysseymed.com
- OGI Eyewear** **7**
 Phone (888) 560-1060
 www.ogieyewear.com
- Optos North America** **45**
 Phone (877) 455-8855 x 100
 Fax..... (508) 486-9310
- Reichert Technologies** .. **21, 103**
 Phone (888) 849-8955
 Fax..... (716) 686-4545
 www.reichert.com
- Reliance Medical** **81**
 Phone (800) 735-0357
 Fax..... (513) 398-0256
- S4OPTIK** **47, 49, 51**
 Phone (888) 224-6012
- Shire Ophthalmics** **59**
 www.shire.com
- Sun Ophthalmics**..... **28-29**
 SunIsOnTheRise.com
- TearScience** **79**
 Phone (919) 459-4891
 Fax..... (919) 467-3300
- Veatch** **31**
 Phone (800) 447-7511
 Fax..... (602) 838-4934
- Vision Source** **109**
 Phone (281) 312-1111
 Fax..... (281) 312-1153
 www.visionsource.com
- Vistakon** **2-3**
 Phone (800) 874-5278
 Fax..... (904) 443-1252

This advertiser index is published as a convenience and not as part of the advertising contract. Every care will be taken to index correctly. No allowance will be made for errors due to spelling, incorrect page number, or failure to insert.

Merchandise Offered



EYEDESIGNS
 CUSTOM INTERIORS + FURNITURE *group*
**BUILDING YOU A
 BETTER BUSINESS**
 WWW.EYEDESIGNS.COM // 800.346.8890
 opticaldisplays.com DRVOJ LUM

Software



**QuikEyes
 Optometry EHR**

- \$198 per month after low cost set-up fee
- Quick Set-Up and Easy to Use
- No Server Needed
- Corporate and Private OD practices
- 14 Day Free Demo Trial
- Email/Text Communications

www.quikeyes.com



Practice For Sale



Practice Sales • Appraisals • Consulting
www.PracticeConsultants.com

**PRACTICES FOR SALE
 NATIONWIDE**

Visit us on the Web or call us to learn more about our company and the practices we have available.

info@PracticeConsultants.com

800-576-6935

www.PracticeConsultants.com

**PRACTICE SALES
 & APPRAISAL**

Expert Services for:

- Buying or Selling a Practice**
- Practice Appraisal**
- Practice Financing**
- Partner Buy-in or Buy-out**

Call for a Free Consultation

(800) 416-2055

www.TransitionConsultants.com

IT STILL EXISTS!

Delaware private practice with like new 3,500 square foot **free standing building**, custom designed and built to be an eye care facility. Immediate sale or partnership leading to purchase in a unique state with **no corporate practice** (OD's can't practice in Pearl Vision or LensCrafters per state law). Large concentration of Glaucoma and Ocular Disease. **Grossing \$700K plus** with high net and phenomenal growth. **Will sell or lease building.** Extensive website with e-commerce included. Only 1/2 hour to Philadelphia or Baltimore, and 1 hour to the beach.

Call 302-994-2299 or e-mail confidentially

privpracticeopportunity@gmail.com



Do you have CE Programs?

**CONTACT US TODAY
 FOR CLASSIFIED ADVERTISING**

Toll free: 888-498-1460

E-mail: sales@kerhgroup.com

Merchandise Offered

ALUMINA™

DESIGNED TO SHOW, NOT TO BE SEEN.

YOUR COLLECTION DESERVES
THE ABSOLUTE BEST
PRESENTATION!



1121 mm ~1452 mm (15-18 inches)

Logo Plate

- Easy to change
- Create sections in the panel and organize collections easily

Alumina key

- The strongest key for optical displays.
- Ergonomic design of the lock allows for easy opening and closing.

Lockable



Flexible Mounting Option

- On a panel or wall
- Easy assembly

 on a panel with holes	 on a panel or wall
 rotating on a panel or wall	 in a cabinet or frame





An Essilor Company 

1-877-274-9300

Certification



Put
your vision
to work for you.

Become Board Certified by the

AMERICAN BOARD
OF OPTOMETRY



Exam held each January & July

Apply at americanboardofoptometry.org

The American Board of Optometry Board Certification program is certified by the National Commission for Certifying Agencies, and its Maintenance of Certification process is approved by the Centers for Medicare and Medicaid Services.

Continuing Education



SOUTHWEST FLORIDA EDUCATIONAL RETREAT

August 5-7, 2016

SOUTH SEAS ISLAND RESORT

CAPTIVA ISLAND, FLORIDA

Education

Transcript Quality - 6 Hours Continuing Education - 14 hours
Total Hours 20 - 18 Hours COPE approved

Program/ Speakers

Bruce Onofrey, O.D., F.A.A.O.	6 hours TQ/CE
Kim Reed, O.D., F.A.A.O.	8 hours CE
Exhibits	2 hours
April Jasper O.D., F.A.A.O.	2 hours CE/PM & 2 Hrs Medical Errors
Ron Foreman O.D., F.A.A.O.	2 hours CE Optometric Jurisprudence

Information

Visit Our Website:

www.swfoa.com

or

E-mail swfoa@att.net

Registration

Prior to July 10, 2016

AOA members \$435

Non members \$535

Register online at:
www.swfoa.com

Special convention rates will only be
in effect after registering for the meeting

Continuing Education


Dr. Travel Seminars, LLC
In Partnership With The NJ Society of Optometric Physicians

Greek Isles Cruise


12 Hours with Ron Melton, O.D., F.A.A.O.

NCL's Norwegian Jade - Sailing Roundtrip From Venice, Italy
July 23 - 30, 2016


Optional Private
Group Tours



All Programs Are in Partnership
With the New Jersey Society of
Optometric Physicians



Optional Pre & Post Cruise
Venice Hotel Stay



Dr. TRAVEL SEMINARS, LLC
is a COPE approved provider
Course approved for 12 CE

Special Group Pricing
Continuing Education

Therapeutic Advances in Ocular Disease 2016 - by Ron Melton, O.D., F.A.A.O.

Additional Seminar Cruises (12-16 CE):

Mediterranean Cruise - July 3 - 10, 2016 - Leo Semes, O.D., F.A.A.O.
Roundtrip Barcelona - Royal Caribbean's New Ship - Harmony Of The Seas

Christmas Week - December 24 - 31, 2016 - Jay Haynie - O.D., F.A.A.O. - Free Drinks

President's Week - February 18 - 25, 2017 - Royal Caribbean's New Ship - Harmony Of The Seas

www.DrTravel.com 800-436-1028

Continuing Medical Education

**American Academy of Optometry
New Jersey Chapter**
14th Annual Educational Conference
April 13-17, 2016
Myrtle Beach, South Carolina
Hilton Embassy Suites at Kingston Plantation

Dr. Joseph Sowka, O.D., F.A.A.O. **16 HOURS**
Dr. Mile Brujic, O.D., F.A.A.O. **COPE CE**

Registration: \$475.00
One, Two or Three Bedroom Suites
Accommodations Include a Daily Breakfast Buffet
and Evening Cocktail Reception
PACK YOUR CLUBS!
Golf details to follow.
For Accommodation and Additional Information, contact:
Dennis H. Lyons, OD, F.A.A.O.
Phone: (732) 920-0110
E-Mail: dhl2020@aol.com




Equipment and Supplies








OPTINOMICS
Pretesting Solutions

It's What the Best
Pretest on!
(800) 522-2275
www.optinomics.com
sales@optinomics.com

OCULAR SYMPOSIUM

Lectures in Ocular Diagnosis and Treatment

Formal Lectures for Optometrists
by Noted Subspecialists in Ophthalmology

Friday, Saturday, Sunday, June 3-5, 2016
24 hours CE credits (8 hours each day) - COPE APPROVAL PENDING

SAN FRANCISCO, CALIFORNIA

- | | | |
|---------------------|-----------------|-------------------|
| Refractive Surgery | Glaucoma | Cataract Surgery |
| Oculoplastics | Inflamations | Corneal Disease |
| Neuro-Ophthalmology | Retinal Disease | Ocular Pediatrics |

For information call or write:
Ocular Symposium • P.O. Box 640327 • San Francisco • CA • 94164
(415) 278-9940 • FAX (415) 345-1165
e-mail: ocularsymp@aol.com

Do you have Equipment
and Supplies for Sale?



Contact us today for classified advertising:
Toll free: 888-498-1460 • E-mail: sales@kerhgroup.com

Place Your
Ad Here!

Toll free: 888-498-1460

E-mail: sales@kerhgroup.com

Career Opportunities**Vogue Optical****OPTOMETRIST**NEWFOUNDLAND, NOVA SCOTIA, NEW BRUNSWICK
AND SOUTH WESTERN ONTARIO

Vogue Optical is a Canadian owned and operated Optical Company. We take tremendous pride in our long term relationships with associate doctors and staff. Rewarding opportunities are available in well-established practices alongside supportive Optical dispensaries. Our clinics utilize state of the art equipment. Space, staff assistance, and strong support are provided with minimal overhead. We currently have opportunities in Newfoundland, Nova Scotia, New Brunswick and South Western Ontario. For further information please email the following address.

ajoseph@vogueoptical.com

Contact us today
for classified advertising:
Toll free: **888-498-1460**
E-mail: sales@kerhgroup.com

STAFF OPTOMETRIST

Bard Optical is a leading Midwest vision care organization in business for over 70 years and we are still growing. The company is based in Peoria, IL with 20 retail offices throughout the central Illinois area, as far north as Sterling and as far south as Jacksonville. Once again this year we were named to the Top 50 Optical Retailers in the United States by Vision Monday – currently ranking 37th. A progressive optometric staff is vital to the continued growth of our organization whose foundation is based on one-on-one patient service. We are currently accepting CV/resumes for optometrists focused on full scope primary medical patient care. The candidate must have an Illinois license with therapeutics. The practice includes (but is not limited to) general optometry, contact lenses, and geriatric care. Salaried, full-time positions are available with excellent growth programs and benefits. Some part-time opportunities may be available also. Please email your information to hr@bardoptical.com or fax to 309-693-9754. Mailing address if more convenient is Bard Optical, Attn: HR, 8309 N Knoxville Avenue, Peoria, IL 61615. Ask about opportunities within Bard Optical. *We have openings in several existing and new offices opening soon in central Illinois.*

Bard Optical is a proud
Associate Member of the
Illinois Optometric Association.

www.bardoptical.com*Here we grow again!***TWO MOTIVATED OPTOMETRISTS
ILLINOIS**

One of the largest eye care providers to extended care and assisted living residents in our great state of Illinois needs two motivated Optometrists to join our practice!

Both positions are in the Springfield and Central Illinois areas. One position is full time and one position is part time.

Our physicians are proficient in refracting, diagnosing & treating ocular pathology, and dispensing spectacles on-site. If you are proficient in these areas and you are comfortable driving, here are your benefits: Excellent Pay + bonuses (=145K+), travel bonuses that will exceed expenses incurred, new optical equipment, a personal assistant, but most important helping people in need of our professional services.

Interested? Contact Michael at
Michael@ovitskyvisioncare.com
or at 773-588-3090.

*Only serious inquiries please. We will help
with relocation expenses, if necessary.*

REVIEW[®]
of OphthalmologyTargeting
Ophthalmologists?**CLASSIFIED ADVERTISING WORKS**

- JOB OPENINGS
- CME PROGRAMS
- PRODUCTS & SERVICES
- AND MORE...

Contact us today for classified advertising:

Toll free: **888-498-1460**

E-mail: sales@kerhgroup.com





Not Quite “In The Pink” Yet

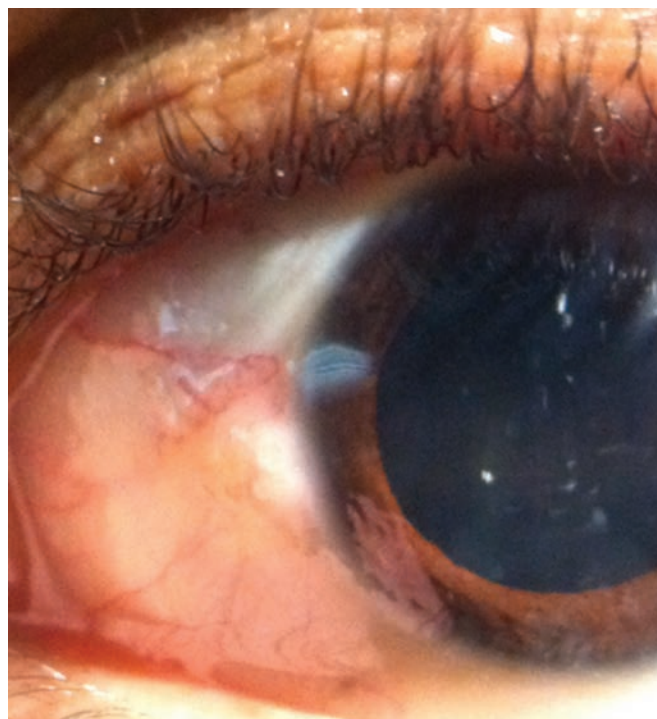By Andrew S. Gurwood, OD

History

A 27-year-old Caucasian male reported to the office with a chief complaint of “pink eye.” He explained that his eyes became red following a cold two weeks ago and that Visine (tetrahydrozoline, Johnson & Johnson) made them less red, but didn’t stop the discharge. His systemic and ocular histories were unremarkable and he denied any allergies or chemical exposure.

Diagnostic Data

His best-corrected entering visual acuities were 20/20 OU at distance and near. His external examination was normal with no evidence of afferent pupillary defect. The biomicroscopic examination of the anterior segment is demonstrated in the photograph. Goldmann applanation tonometry measured 15mm Hg OU. The dilated fundus findings were normal peripherally and centrally with normal nerves and maculae.



This 27-year-old patient presented with ocular discharge. He says his eyes became red following a cold. Can you explain what’s causing his symptoms?

Your Diagnosis

Does this case require any additional tests? What is your diagnosis? How would you manage this

patient? What’s the likely prognosis? To find out, please visit *Review of Optometry* online at www.reviewofoptometry.com.

Retina Quiz Answers (from page 100): 1) a; 2) c; 3) a; 4) c.

Next Month in the Mag

In April, *Review of Optometry* will focus on corneal disease.

Topics include:

- *Managing Superficial Corneal Dystrophies*
- *Using Amniotic Membranes to “Jump Start” Corneal Wound Healing*

- *Corneal Abrasions and Foreign Bodies: Presentations and Management*
- *Essential Procedures: How to Perform Corneal Culturing*
- *Optometric Study Center: Are You Clear on Your Macular Screening Responsibilities?* (earn 2 CE credits)
- *Glaucoma: Hone Your Differential Diagnostic Skills*

REVIEW OF OPTOMETRY (ISSN 0147-7633) IS PUBLISHED MONTHLY, 12 TIMES A YEAR BY JOBSON MEDICAL INFORMATION LLC, 100 AVENUE OF THE AMERICAS, NEW YORK, NY 10013-1678. PERIODICALS POSTAGE PAID AT NEW YORK, NY AND ADDITIONAL MAILING OFFICES. POSTMASTER: SEND ADDRESS CHANGES TO REVIEW OF OPTOMETRY, PO BOX 81, CONGERS, NY 10920-0081. SUBSCRIPTION PRICES: US: ONE YEAR \$56; TWO YEARS \$97, CANADA: ONE YEAR \$88, TWO YEARS \$160, INT’L: ONE YEAR \$209, TWO YEARS \$299. FOR SUBSCRIPTION INFORMATION CALL TOLL-FREE (877) 529-1746 (USA); OUTSIDE USA, CALL (845) 267-3065. OR EMAIL US AT REVOPTOMETRY@CAMBEYWEST.COM. PUBLICATIONS MAIL AGREEMENT NO: 40612608. CANADA RETURNS TO BE SENT TO BLEUCHIP INTERNATIONAL, P.O. BOX 25542, LONDON, ON N6C 6B2.

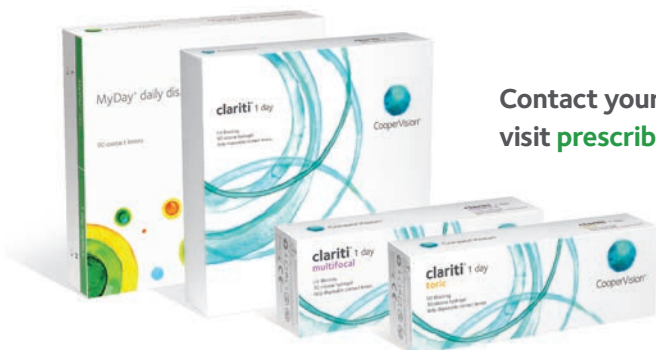

Ready to be your patients' most trusted expert? **Prescribe oxygen.**

 MyDay® daily disposable  clariti® 1 day  clariti® 1 day multifocal  clariti® 1 day toric

With CooperVision's largest portfolio of silicone hydrogel 1-day contact lenses you can fit virtually all patients into a 1-day lens that provides high oxygen, comfort and convenience. From the uncompromising performance of MyDay® to the breadth of the clariti® 1 day family, CooperVision is the only one you need to serve your 1-day patients.

For brighter, healthier eyes ready to take on the world, the prescription is oxygen. And the opportunity is yours.



Contact your CooperVision sales representative or visit prescribeoxygen.com for more information.



CooperVision®
Live Brightly.™

THIS IS WHY the SmartShield™ Technology of AIR OPTIX® brand contact lenses makes the difference

SMARTSHIELD™
TECHNOLOGY



EXCELLENT SUPERIOR LIPID DEPOSIT RESISTANCE¹*

protects for less lipid deposition throughout the lens



SUPERIOR WETTABILITY²**

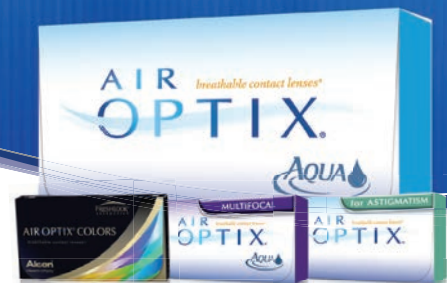provides a hydrophilic environment with minimal exposed silicone³,⁴

Clear Vision and Consistent Comfort all month long



To learn more about SmartShield™ Technology, ask your Alcon Sales Representative. Visit MYALCON.COM for additional information.

PERFORMANCE DRIVEN BY SCIENCE®



*Superior lipid deposit resistance compared to ACUVUE® OASYS®, ACUVUE® ADVANCE®, PureVision®, Biofinity® and Avaira® contact lenses. **Compared to ACUVUE® OASYS®, ACUVUE® ADVANCE®, PureVision®, Biofinity® and Avaira® contact lenses. ^Trademarks are the property of their respective owners.

Important information for AIR OPTIX® AQUA (lotrafi Icon B), AIR OPTIX® AQUA Multifocal (lotrafi Icon B), and AIR OPTIX® for Astigmatism (lotrafi Icon B) contact lenses: For daily wear or extended wear up to 6 nights for near/far-sightedness, presbyopia and/or astigmatism. Risk of serious eye problems (i.e. corneal ulcer) is greater for extended wear. In rare cases, loss of vision may result. Side effects like discomfort, mild burning or stinging may occur.

Important information for AIR OPTIX® COLORS (lotrafi Icon B) contact lenses: For daily wear only for near/far-sightedness. Contact lenses, even if worn for cosmetic reasons, are prescription medical devices that must only be worn under the prescription, direction and supervision of an eye care professional. Serious eye health problems may occur as a result of sharing contact lenses. Although rare, serious eye problems can develop while wearing contact lenses. Side effects like discomfort, mild burning or stinging may occur. To help avoid these problems, patients must follow the wear and replacement schedule and the lens care instructions provided by their eye doctor.

References: 1. Nash W, Gabriel M, Mowrey-McKee M. A comparison of various silicone hydrogel lenses; lipid and protein deposition as a result of daily wear. *Optom Vis Sci.* 2010; 87:E-abstract 105110. 2. In vitro measurement of contact angles on unworn spherical lenses; significance demonstrated at the 0.05 level; Alcon data on file, 2009. 3. Alcon data on file, 2013. 4. Alcon data on file, 2013. 5. EdenSB, Davis R, Bergenske P. Prospective study of lotrafilcon B lenses comparing 2 versus 4 weeks of wear for objective and subjective measures of health, comfort, and vision. *Eye & Contact Lens.* 2013; 39(4):290-294.

Alcon
a Novartis company

See product instructions for complete wear, care and safety information.

Rx only

© 2015 Novartis 11/15 US-AOA-15-E-0955