

REVIEW[®] OF OPTOMETRY

October 15, 2016

www.reviewofoptometry.com

22ND ANNUAL GLAUCOMA REPORT

EARN 2 CE CREDITS

Controversies IN GLAUCOMA

*In optometry, it's always debate season.
A look at some hot-button issues that
challenge conventional wisdom. p. 66*

— PLUS —

- Angle-closure Glaucoma: Are You Ready?, p. 40 • Zoom in on Gonioscopy, p. 50
- Managing the Post-op Glaucoma Patient, p. 58





it's time for some



eyelove™

What's eyelove? Eyelove is all about taking care of eyes—especially now. Eyes need more love than ever, because they've never been asked to do so much. That's why Shire has entered the world of eye care. Shire is committed to educating patients about Dry Eye Disease—so let's start with some eyelove.

Feel the love at sharesomeeyelove.com

The Shire logo consists of a stylized white 'S' shape followed by the word 'Shire' in a bold, white, sans-serif font.

IN THE NEWS

Researchers have identified the first **cellular model of exfoliation glaucoma**, which could lead to improved treatment. Investigators grew cells using tissue samples from trabeculectomy procedures and compared them with other cells without exfoliation glaucoma. The cells were much larger than normal and contained an abundance of disorganized vesicles—leading to the discovery of a **defect in the autophagy system**.

Want A, Gillespie SR, Wang Z, et al. Autophagy and mitochondrial dysfunction in tenon fibroblasts from exfoliation glaucoma patients. *PLoS One*. July 8, 2016. [Epub].

New research on the effectiveness of **Humira** (adalimumab, AbbVie) for **noninfectious uveitis** suggests it is an **effective, nonsteroid alternative for eye inflammation**. The study included 217 adults with active, noninfectious intermediate or posterior uveitis, or panuveitis. The researchers found that median time to treatment failure was 24 weeks in the Humira group and 13 weeks in a placebo group. Treatment failure was based on the assessment of new inflammatory lesions, best-corrected visual acuity, anterior chamber cell grade and vitreous haze grade.

Jaffe GJ, Dick AD, Brézín AP, et al. Adalimumab in patients with active noninfectious uveitis. *N Engl J Med*. 2016;375(10):932.

Johnson & Johnson recently announced an agreement to **acquire Abbott Medical Optics** for \$4.325 billion, which includes ophthalmic products in **cataract surgery, laser refractive surgery and consumer eye health**. The acquisition will allow Johnson & Johnson to enter the cataract surgery market, the company said in a release. The transaction is expected to close in early 2017.

Updated Eye Drops on the Horizon

A new drug delivery system might solve many of your topical medication woes.

By **Rebecca Hepp, Senior Associate Editor**

Topical drops have always been a blessing and a curse for eye care providers. While they provide some form of treatment for patients, they come with a host of problems as well.

“The current use of topical drops for the treatment of ocular disease is certainly an issue,” says Jill Autry, OD, a partner at the Eye Center of Texas ophthalmology center. “There are concerns regarding compliance, convenience, concentration and toxicity—not to mention the poor pharmacokinetic profiles.”

Researchers have developed a possible solution to some of these age-old problems. Engineers at McMaster University in Ontario, Canada, created microscopic packets designed to sit in the base of the tear film and dissolve gradually—causing a slow release of medication. The researchers believe the new drops could make it possible for patients with conditions such as dry eye and glaucoma to receive the same amount of therapeutic effect from using drops once a week instead of daily.

“Using micelle polymers (miniature dissolvable drug packets), scientists are able to increase contact time and decrease drug concentration while still being easy on the ocular surface,” says Dr. Autry. “This could potentially en-

able medications to be delivered less frequently and with less systemic and ocular side effects than we have ever known.”

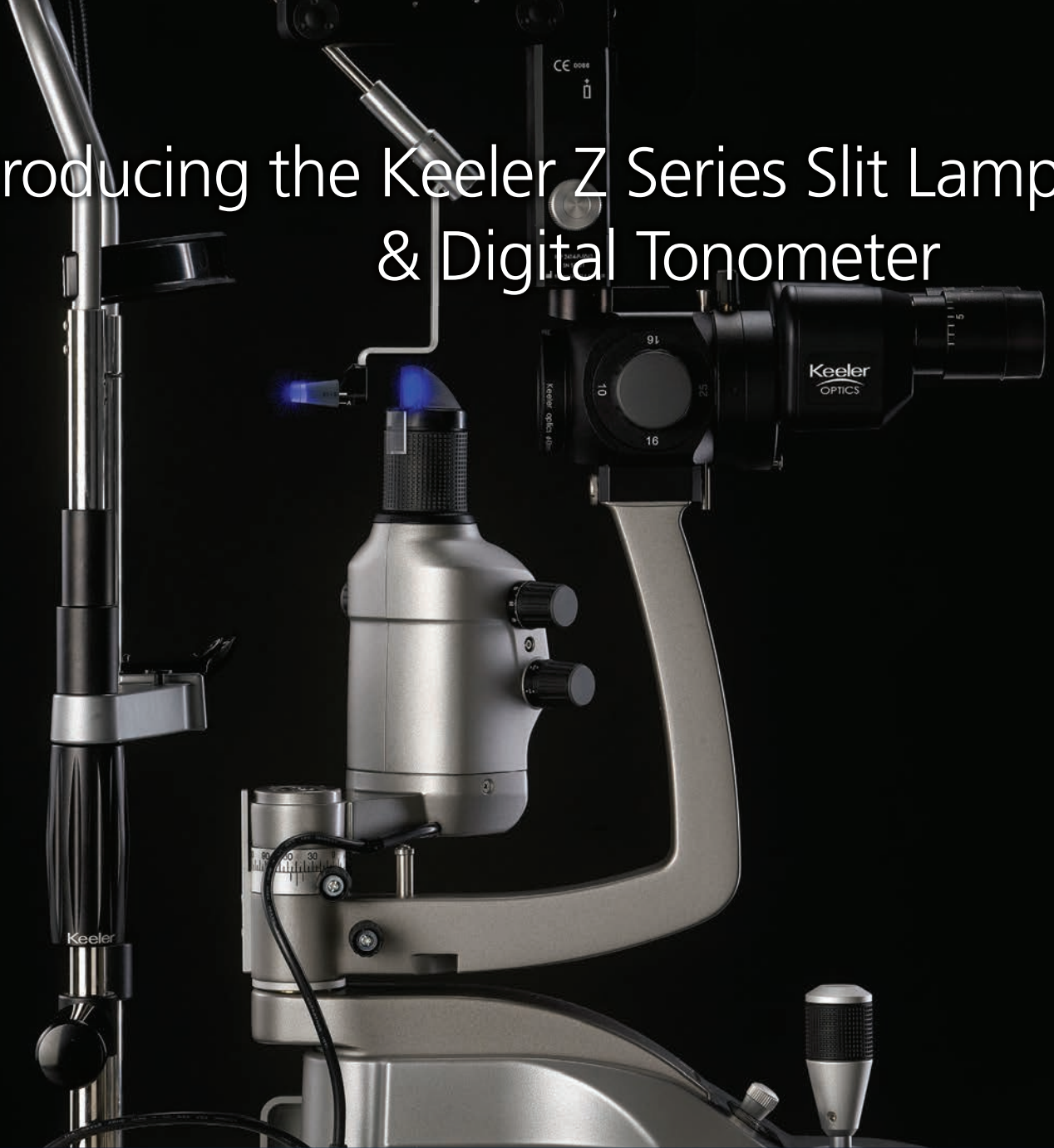The team’s mucoadhesive drug delivery system, recently described in the journal *Biomacromolecules*, is comprised of phenylboronic-acid-based polymeric micelles that show low in vitro cytotoxicity against human corneal epithelial cells and undetectable acute in vivo ocular irritation in rats.

“My concerns are how this technology would be patented,” Dr. Autry says. “Would all companies have access to this delivery system for medications or would it be proprietary and only used in the newest, branded products? I am also concerned about how the delivery system would be affected by ocular conditions such as epiphora, dry eye, corneal scarring, artificial tear use, other drop use, etc., which can alter how the micelles are activated or retained.”

The researchers are in the final stages of investigating the safety and effectiveness of the new technology, hopefully answering many of these concerns. They aim to have it on the market in the near future.

Prosperi-Porta G, Kedzior S, Muirhead B, Sheardown H. Phenylboronic-Acid-Based Polymeric Micelles for Mucoadhesive Anterior Segment Ocular Drug Delivery. *Biomacromolecules*. 2016;17(4):1449.

Introducing the Keeler Z Series Slit Lamp & Digital Tonometer



Keeler Optics...says it all.

The Z Series Slit Lamp is the latest line from Keeler featuring legendary Keeler optics housed in a stylish, contemporary design.

Your choice of 3 or 5 step magnification option in a standard, digital ready, or comprehensive digital capture system.

Check out some of these great features:

- Converging or parallel binoculars
- 14mm Slit length / maximum aperture
- X 6 to x 40 (5 step) or X 10 to X 25 (3 step) magnifications
- Blue, red-free, clear, neutral density and diffuser filters
- 360 degree continuous slit rotation
- Integrated yellow barrier filter
- 1m Square aperture for Uveitis assessment
- LED illumination
- Illumination control mounted next to joystick
- 3 year warranty



Order now and receive a limited edition bronze D-KAT tonometer.

Contact your preferred Keeler distributor for details.

Keeler

Learn more at www.keelerusa.com

Keeler Instruments, Inc. • 456 Parkway • Broomall, PA 19008
Tel: (800) 523-5620 • Fax: (610) 353-7814 • email: keeler@keelerusa.com

CE: The Winning Act at VEW in Vegas

By Jane Cole, Contributing Editor

Education held the spotlight at the recent Vision Expo West (VEW), held from Sept. 14-17 in Las Vegas. This year's annual meeting boasted the second all-time highest CE attendance in Expo's history, with preliminary numbers coming in at 4,542, according to International Vision Expo. Total attendance figures for the entire conference were not available at press time, but will be released in a few weeks, International Vision Expo said.

Top-notch Learning

In total, VEW 2016 offered more than 320 hours of education, with clinical sessions covering everything from ocular disease diagnosis and treatment, contact lenses and therapeutics to the very latest in imaging.

"Our comprehensive and inclusive education programming, combined with our extensive exhibits, came together to offer a high value, impactful experience in Las Vegas," said Ben Gaddie, OD, co-chair of the Vision Expo conference advisory board. "Vision Expo provides a unique and innovative approach to all aspects of clinical care education including refractive care, contact

lenses, anterior segment disease, specialty dry eye management, glaucoma and retinal disease. It's why more eye care professionals choose International Vision Expo for their education than any other conference."

New Perspectives

VEW served up several new courses this year, including a scleral lens track with five hours of CE credit. Scleral lenses provide new opportunities and challenges for practices, and this track featured presentations by Melissa Barnett, OD, Stephanie Woo, OD, and Barry Eiden, OD, on subjects such as fitting, lens design, patient selection, specialized testing and problem solving for both full and mini-sclerals.

Another new track, "CAB Chairman Top Picks," provided up to 21 hours of CE credit. Some of the highlights from this track included:

- *The Best and the Worst Ocular Emergencies and Urgencies*, presented by Vincent Young, MD, and Marc Myers, OD
- *Neuro For the Rest of Us*, by William Marcolini, OD
- *What Do You Do If?... Diagnosis and Treatment of Ante-*

rior Segment Disease You Meet Every Day! by Dr. Eiden and Andrew Morgenstern, OD

- *Cloak and Dagger Retinal Clues to Systemic Disease*, presented by Steven Ferrucci, OD

During the new "Lightening Rounds" five key opinion leaders offered their different perspectives in a speed-dating type of setting. Topics included glaucoma and anterior segment diseases.

"We recognize that doctors and staff are taking time away from the office to attend Vision Expo, which is why we offer a comprehensive didactic curriculum that is rich in ocular disease and contact lens education sessions catered to bringing back actionable solutions that can be immediately implemented," said Mark Dunbar, OD, co-chair of the Vision Expo conference advisory board. "Our continuing education is increasingly focused on the practical elements of providing vision care while running a successful business, or those wishing to open a practice."

In the Hall

In addition to CE, the conference had 183,000 square feet of exhibit space in the Medical & Scientific Pavilion. The hall showcased the latest ophthalmic technologies and innovations, including 178 companies—24 of which were first-time exhibitors this year.

Mark your calendar for more CE in Sin City next year, as VEW will be back in Las Vegas from Sept. 13-16, 2017. For more information about VEW 2017, go to west.visionexpo.com.




The Global Contact Lens Forum—and this "State of the Contact Lens Industry in 2016" course in particular—was a hit at this year's Vision Expo West.

Cast me Marchon

Do you want to be the next face of Marchon Eyewear's 2017 Corporate Advertising campaign?

Visit www.marchonme.com to submit an application and enter for a chance to star in our "Marchon me" ad campaign. All entries must be submitted between September 1st – November 1st 2016.



MARCHON
FOCUSED ON YOU

Internal Astigmatism Exposed

Internal astigmatism does not compensate for changes in the structure of the eye, according to new research. Investigators looked at 14 years of measurements and refractive error evaluations on 367 myopic patients and compared the data with one-time measurements of 204 non-myopic individuals.

Optometrists typically consider internal astigmatism a constant, yet the researchers found evidence suggesting otherwise. Internal astigmatism was greater in non-myopes who proved better able to compensate for corneal astigmatism, and internal astigmatism remained stable over time, not changing as the shape of the eye changed.

“This work finds that internal astigmatism varies by refractive error, ethnicity and the magnitude of corneal astigmatism,” says Ruth E. Manny, OD, PhD, of University of

Houston College of Optometry, and lead author of the study. “Therefore, internal astigmatism should not be thought of as a constant.”

“Predicting patients who have high internal astigmatism could be important when considering sending a patient for refractive surgery or cataract surgery since neglecting this component of the refraction could produce unwanted outcomes,” Dr. Manny says.

“Using new technologies may provide a better understanding of the sources of internal astigmatism,” Dr. Manny says. “Direct measurement of internal astigmatism may also allow us to understand what is responsible for the differences in internal astigmatism by refractive error, ethnicity and corneal astigmatism.”

Manny RE, Deng L, Gwiazda J, et al. Internal astigmatism in myopes and non-myopes. *Optom Vis Sci.* 2016;93(9):1079.

Pediatric Eye Care Linked to Affluence, Study Shows

Children from less affluent homes are considerably less likely to obtain eye care services, according to a recent study published in *Health Affairs*.¹ This results in approximately 12,800 missed strabismus diagnoses and 5,400 missed amblyopia diagnoses, researchers say.¹

The 10-year study divided subjects into groups based on household income.¹ The findings show that children from the highest earning households (more than \$500,000) had 19% more visits to eye care professionals (ECPs) than those from the middle-income

group (between \$150,000 and \$250,000).¹ Children from the lowest earning households (less than \$25,000), however, had 16% fewer visits to ECPs than children from the middle-income group.¹

“Most children aren’t asked or required to get a full dilated eye exam until they fail a screening either with their school nurse or pediatrician,” says Luis Trujillo, OD, who specializes in pediatric and binocular vision at The Eye Institute in Philadelphia. “Children of underserved populations may not have access to a pediatrician

(continued on pg. 10)

REVIEW[®] OF OPTOMETRY

BUSINESS OFFICES

11 CAMPUS BLVD., SUITE 100
NEWTOWN SQUARE, PA 19073

CEO, INFORMATION SERVICES GROUP

MARC FERRARA
(212) 274-7062 • MFERRARA@JOBSON.COM

PUBLISHER

JAMES HENNE
(610) 492-1017 • JHENNE@JOBSON.COM

REGIONAL SALES MANAGER

MICHELE BARRETT
(610) 492-1014 • MBARRETT@JOBSON.COM

REGIONAL SALES MANAGER

MICHAEL HOSTER
(610) 492-1028 • MHOSTER@JOBSON.COM

VICE PRESIDENT, OPERATIONS

CASEY FOSTER
(610) 492-1007 • CFOSTER@JOBSON.COM

VICE PRESIDENT, CLINICAL CONTENT

PAUL M. KARPECKI, OD, FAAO
PKARPECKI@JOBSON.COM

PRODUCTION MANAGER

SCOTT TOBIN
(610) 492-1011 • STOBIN@JOBSON.COM

SENIOR CIRCULATION MANAGER

HAMILTON MAHER
(212) 219-7870 • HMAHER@IHHEALTH.COM

CLASSIFIED ADVERTISING

(888) 498-1460

SUBSCRIPTIONS

\$56 A YEAR, \$88 (US) IN CANADA,
\$209 (US) IN ALL OTHER COUNTRIES.

SUBSCRIPTION INQUIRIES

(877) 529-1746 (US ONLY)
OUTSIDE US CALL: (845) 267-3065

CIRCULATION

PO Box 81
CONGERS, NY 10920
TEL: (TOLL FREE): (877) 529-1746
OUTSIDE US: (845) 267-3065



CEO, INFORMATION SERVICES GROUP

MARC FERRARA

SENIOR VICE PRESIDENT, OPERATIONS

JEFF LEVITZ

VICE PRESIDENT, HUMAN RESOURCES

TAMMY GARCIA

VICE PRESIDENT, CREATIVE SERVICES & PRODUCTION

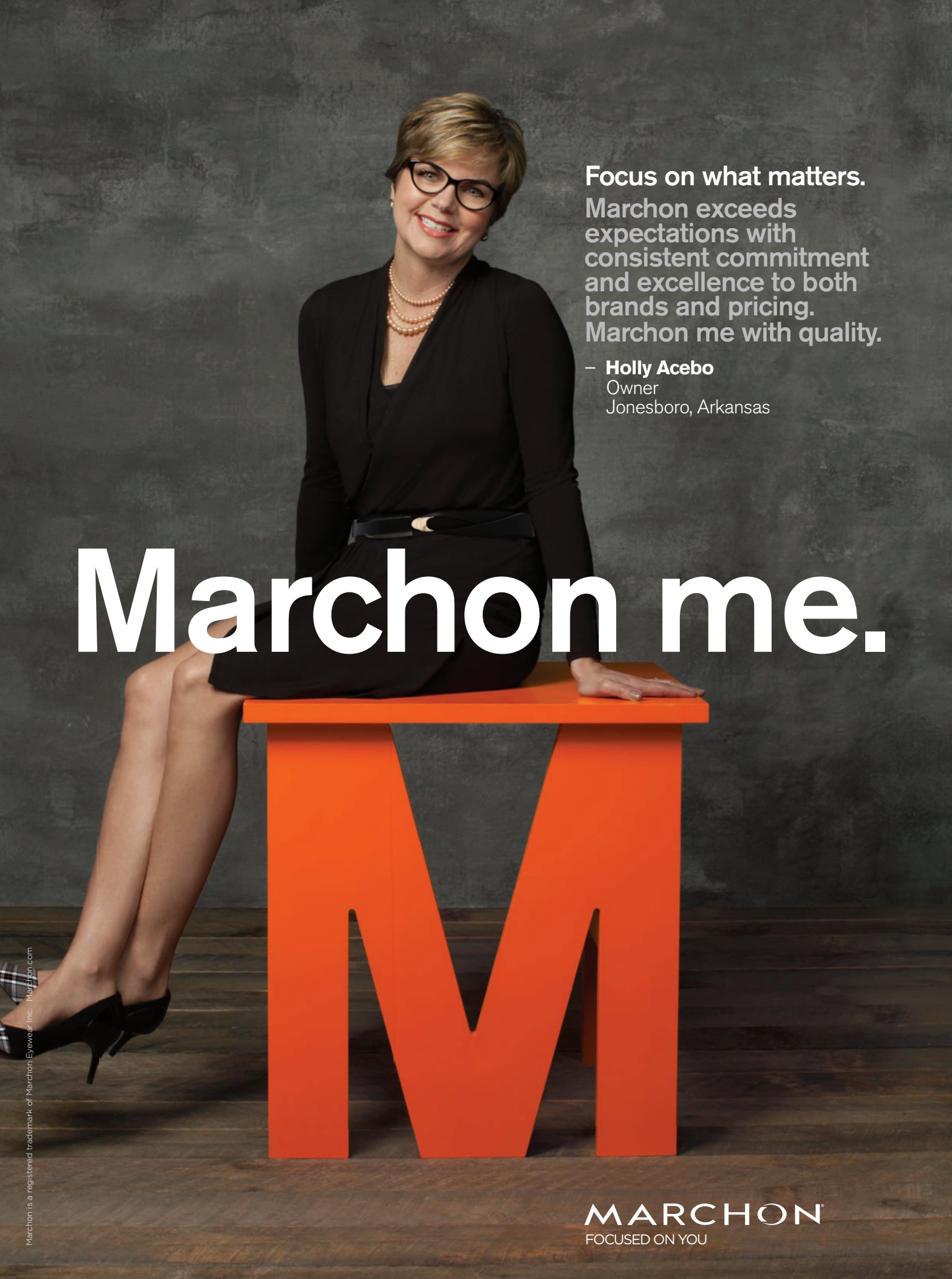MONICA TETTAMANZI

CORPORATE PRODUCTION DIRECTOR

JOHN ANTHONY CAGGIANO

VICE PRESIDENT, CIRCULATION

EMELDA BAREA



Focus on what matters.
Marchon exceeds expectations with consistent commitment and excellence to both brands and pricing.
Marchon me with quality.

– **Holly Acebo**
Owner
Jonesboro, Arkansas

Marchon me.

Marchon is a registered trademark of Marchon Eyewear Inc. | Marchon.com

MARCHON
FOCUSED ON YOU

Peds Eye Care

(continued from pg. 8)

(depending on insurance status) and, at least here in the Philadelphia area, I have found that nurses are asked to cover more than one school within the district. This can delay when a child gets screened, to say nothing of when they will actually get an exam.”

“More attention should be directed to overcoming economic barriers that keep children from obtaining necessary eye care services,” the report concludes.¹

There are ways optometrists can help level the playing field, according to Dr. Trujillo, who suggests contributing to programs, such as Infant-See, which allows patients within a certain age range access to an exam at any participating provider’s office. Another option is to reach out to your local school district. “As an assistant professor and practicing pediatric optometrist at Salus University, I have been given the opportunity and privilege over the last three years to go into the schools in the Norristown school district and give full eye exams to students who have failed their nurse’s screening. These students do not have health insurance or access to eye care, period. Along with the exam, these students get two pairs of glasses, and the entire program is funded through donations from the community,” says Dr. Trujillo.

Government funded programs, such as Head Start, also allow ODs to provide screenings to preschool-aged children.

Dr. Trujillo also recommends doctors lobby lawmakers to push for mandatory eye exams for all children. ■

1. Stein J, Andrews C, Musch D, et al. Sight-threatening ocular diseases remain underdiagnosed among children of less affluent families. *Health Affairs*. 2016;35(8):1359-66.



You're
leaving me...
aren't you?



Parasol®

Trust us. We're not like the others.

Patients shouldn't fear their tears will disappear because their plugs up and left. Help them face life with eyes wide open and comfortably moist. Trust the Parasol Punctal Occluder; it's the perfect fit for your patients — and guaranteed to stay put.

TO ORDER: 866-906-8080
customersupport@beaver-visitec.com
odysseymed.com or beaver-visitec.com

Visit us at
AAO Booth 2515

bvi Beaver Visitec
Keeping Your Vision in Sight

Beaver-Visitec International, Inc., 411 Waverley Oaks Road, Waltham, MA 02452.
BVI, BVI Logo and all other trademarks (unless noted otherwise) are property of a
Beaver-Visitec International ("BVI") company © 2016 BVI



YOUR ROLE IN THE CATARACT PATIENT'S JOURNEY

Alcon A Novartis
Division

- 🛡️ **EDUCATE** your patients on their condition and steps needed for cataract surgery
- 🛡️ **WORK** with your surgeon for a better patient experience
- 🛡️ **KNOW** what technologies your surgeon uses and why
- 🛡️ **DEVELOP** an open communication protocol
- 🛡️ **DIFFERENTIATE** yourselves as a team by working together for the best patient outcome



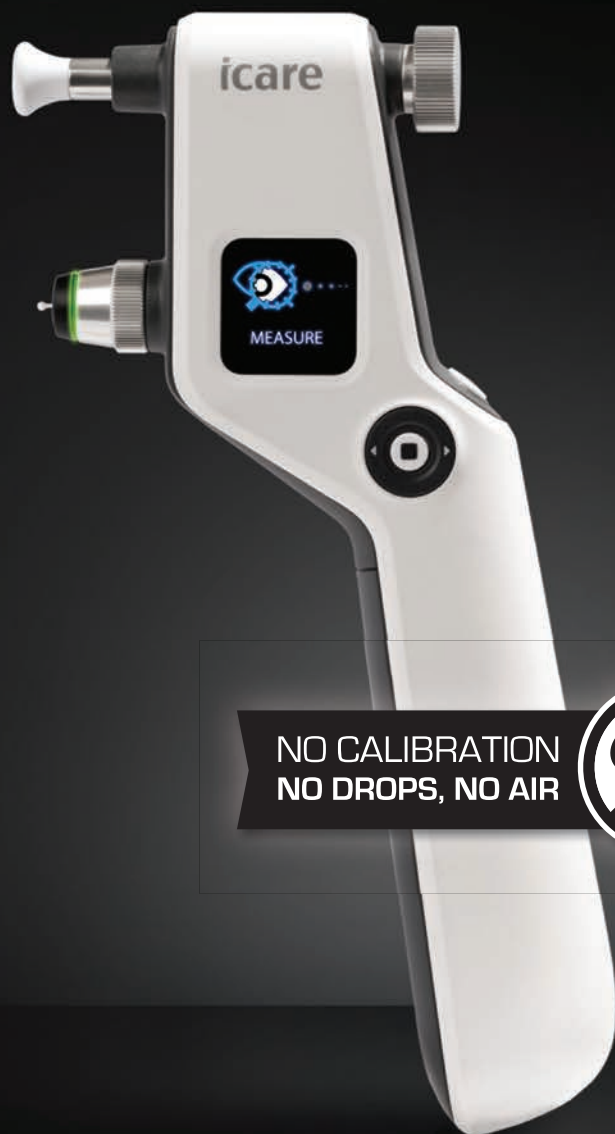FOR FURTHER EDUCATION PLEASE VISIT MYCATARACTS.COM

Alcon A Novartis
Division

New!

icare

ic100



NO CALIBRATION
NO DROPS, NO AIR



THE INTELLIGENT CHOICE

Learn more: info@icare-usa.com or www.icare-usa.com

Contents

Review of Optometry October 2016



22nd Annual Glaucoma Report

40 Angle-closure Glaucoma: Are You Ready?

Diagnosing and managing these challenging cases is inevitable. Be prepared with these clinical pearls. **By Michael Cymbor, OD**

58 Managing the Post-op Glaucoma Patient

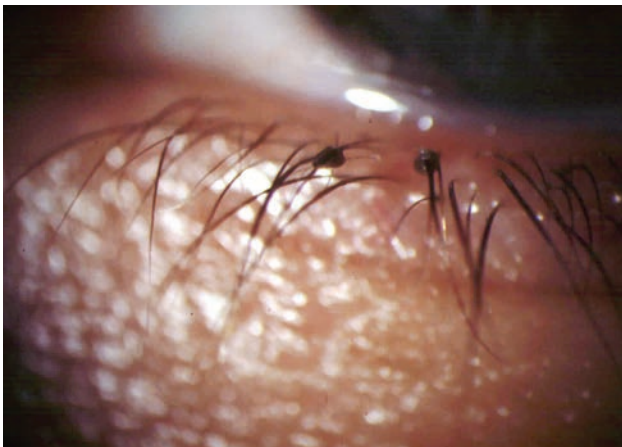As minimally invasive surgeries and laser procedures become more commonplace, learn the basics to stay ahead of the comanagement curve. **By Anthony Van Alstine, MS, OD, and James M. Caruso, OD**

50 Zoom In on Gonioscopy

Take a closer look at how to properly perform this simple and valuable procedure **By Emily Bruce, OD, Rodney Bendure, OD, Sarah Krein, OD, and Nathan Lighthizer, OD**

66 Earn 2 CE Credits: Controversies in Glaucoma Management

In optometry, it's always debate season. This article looks at some hot topic issues and challenges conventional wisdom. **By Bruce Onofrey, OD**



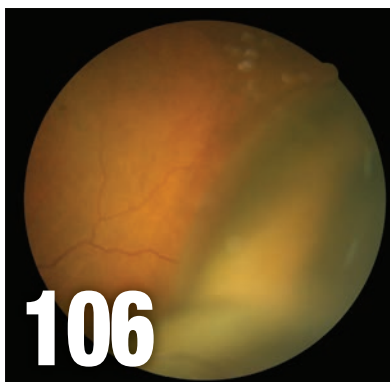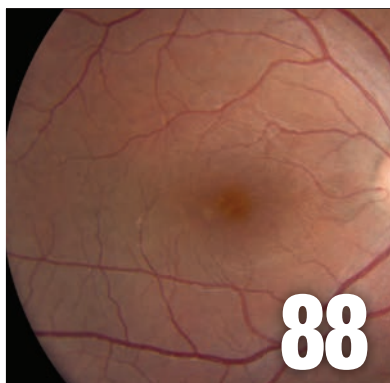
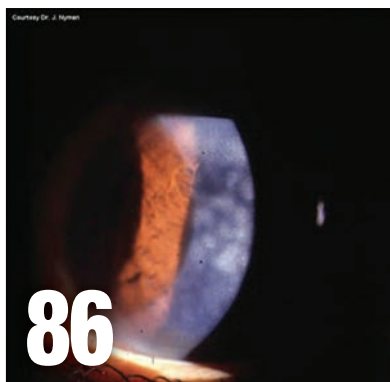
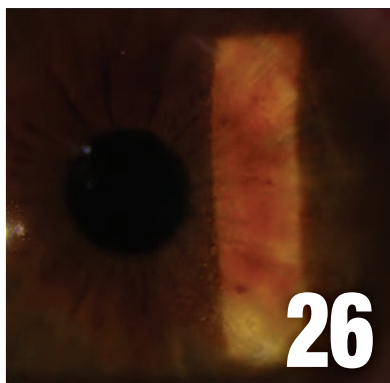
78 Spotlight on *Demodex*: Eliminating the Mite-y Menace

The oft overlooked *Demodex* diagnosis is elemental to setting patients on the path to relief, if you know what to look for. **By Victoria Roan, OD**

Departments

Review of Optometry October 2016

- 4 News Review**
- 20 Letters to the Editor**
- 22 Outlook**
Technical Difficulties
JACK PERSICO
- 24 Chairside**
20 Tips to Think Through
MONTGOMERY VICKERS, OD
- 26 Urgent Care**
Preventing A Total Melt Down
**RICHARD MANGAN, OD, AND
JUSTIN SCHWEITZER, OD**
- 28 Clinical Quandaries**
When Your Patient's Expecting
PAUL C. AJAMIAN, OD
- 30 Focus on Refraction**
Eye on the Ball
**PAUL HARRIS, OD, AND
MARC B. TAUB, OD, MS**
- 36 Coding Connection**
Feeling The Pressure
JOHN RUMPAKIS, OD, MBA
- 86 Cornea + Contact Lens Q+A**
Adenoviral Dominos
JOSEPH P. SHOWLIN, OD
- 88 Retina Quiz**
Out, Damned Spot
**MARK T. DUNBAR, OD, AND
LESLIE SMALL, OD**
- 92 Glaucoma Grand Rounds**
Rethinking the Ratio
JAMES L. FANELLI, OD
- 94 Therapeutic Review**
Where's the Culture?
**JOSEPH W. SOWKA, OD, AND
ALAN G. KABAT, OD**
- 98 Advertisers Index**
- 99 Surgical Minute**
Say Goodbye to Readers
**WALTER WHITLEY, OD, MBA,
DEREK N. CUNNINGHAM, OD, AND
SONDRA BLACK, OD**
- 100 Classifieds**
- 104 Products**
- 106 Diagnostic Quiz**
Vision Going Down the Drain
ANDREW S. GURWOOD, OD



On The Web >> and more

Check out our multimedia and continuing education online at:
www.reviewofoptometry.com

Digital Edition



Left your copy of *Review of Optometry* at the office? No problem! Access *Review* on your computer or mobile device!

Go to www.reviewofoptometry.com and click on the digimag link for the current issue.

Facebook and Twitter



For daily updates, "Like" our page on Facebook or "Follow" us on Twitter!


- www.facebook.com/revoptom
- <http://twitter.com/#!/revoptom>

Look for augmented content and special offers from *Review* and our advertisers. Specified pages work in conjunction with your smartphone or other mobile device to enhance the experience. With Layar, interactive content leaps off the page!



Step 1: Download the free Layar app for iPhone or Android.



Step 2: Look for pages with the Layar Logo.  INTERACTIVE PRINT



Step 3: Open the Layar app, hold the phone above the page and tap to scan it. Hold the phone above the page to view the interactive content.

The first 150 app downloads and completed forms will be entered into a drawing for a complimentary registration to one of *Review's* 14-hour CE meetings, valued at \$495.



Classic beta blocker adjunctive therapy for the right patient at the right time³

The concomitant use of two topical beta-adrenergic blocking agents is not recommended^{4,5}

Indications and Usage

ISTALOL® (timolol maleate ophthalmic solution) is a non-selective beta-adrenergic receptor blocking agent indicated in the treatment of elevated intraocular pressure in patients with ocular hypertension or open-angle glaucoma.

Preservative-free TIMOPTIC® (timolol maleate ophthalmic solution) in OCUDOSE® (dispenser) is indicated in the treatment of elevated intraocular pressure in patients with ocular hypertension or open-angle glaucoma. It may be used when a patient is sensitive to the preservative in TIMOPTIC (timolol maleate ophthalmic solution), benzalkonium chloride, or when use of a preservative-free topical medication is advisable.

Important Safety Information for Istalol® and Timoptic® in Ocudose®

- Both ISTALOL® (timolol maleate ophthalmic solution) and TIMOPTIC® (timolol maleate ophthalmic solution) in OCUDOSE® (dispenser) are contraindicated in patients with: bronchial asthma; a history of bronchial asthma; severe chronic obstructive pulmonary disease; sinus bradycardia; second or third degree atrioventricular block; overt cardiac failure; cardiogenic shock; hypersensitivity to any component of the product.
- **The same adverse reactions found with systemic administration of beta-adrenergic blocking agents may occur with topical administration. Severe respiratory reactions and cardiac reaction, including death due to bronchospasm in patients with asthma, and rarely death in association with cardiac failure, have been reported following systemic or ophthalmic administration of timolol maleate.**
- Patients with a history of atopy or severe anaphylactic reactions to a variety of allergens may be unresponsive to the usual doses of epinephrine used to treat anaphylactic reactions.
- Timolol has been reported rarely to increase muscle weakness in some patients with myasthenia gravis or myasthenic symptoms.
- Beta-adrenergic blocking agents may mask signs and symptoms of acute hypoglycemia or certain clinical signs of hyperthyroidism. Patients subject to spontaneous hypoglycemia, or diabetic patients receiving either insulin or oral hypoglycemic agents, or patients suspected of developing thyrotoxicosis, should be managed carefully, with caution.
- In patients undergoing elective surgery, some authorities recommend gradual withdrawal of beta adrenergic receptor blocking agents because these agents impair the ability of the heart to respond to beta-adrenergically mediated reflex stimuli.
- The most frequently reported adverse reactions have been burning and stinging upon instillation. This was seen in 38% of patients treated with ISTALOL and in approximately one in eight patients treated with TIMOPTIC in OCUDOSE. Additional reactions reported with ISTALOL at a frequency of 4 to 10% include: blurred vision, cataract, conjunctival injection, headache, hypertension, infection, itching and decreased visual acuity.

Please see Brief Summary of Prescribing Information for ISTALOL and TIMOPTIC in OCUDOSE on the following pages.

For the patients who need incremental IOP reduction in a preservative free form⁶



For the patients who need incremental IOP reduction in a once a day form⁶

Istalol[®]
(timolol maleate
ophthalmic solution) 0.5%

References: 1. Alm A, Stjernschantz J. Effects on Intraocular Pressure and Side Effects of 0.005% Latanoprost Applied Once Daily, Evening or Morning. *Ophthalmology*. 1995;102:1743-1752. 2. Brubaker R. Flow of Aqueous Humor in Humans. *IOVS*. 1991;32(13):3145-3166. 3. Obstbaum S, Cioffi GA, Kriegstein GK, et al. Gold Standard Medical Therapy for Glaucoma: Defining the Criteria Identifying Measures for an Evidence-Based Analysis. *Clin Ther*. 2004;26(12):2102-2119. 4. Istalol [package insert]. Bridgewater, NJ: Bausch & Lomb Incorporated; 2013. 5. Timoptic in Ocudose [package insert]. Lawrenceville, NJ: Aton Pharma; 2009. 6. Stewart W, Day DG, Sharpe ED. Efficacy and Safety of Timolol Solution Once Daily vs Timolol Gel Added to Latanoprost. *Am J Ophthalmol*. 1999;128(6):692-696.

Timoptic and Ocudose are trademarks of Valeant Pharmaceuticals International, Inc. or its affiliates. Bausch + Lomb and Istalol are trademarks of Bausch & Lomb Incorporated or its affiliates.

BAUSCH + LOMB

©Bausch & Lomb Incorporated.

US/TOP/14/0017(1)

BRIEF SUMMARY OF PRESCRIBING INFORMATION

This Brief Summary does not include all the information needed to use ISTALOL® (timolol maleate ophthalmic solution) 0.5% safely and effectively. See full prescribing information for ISTALOL.

Istalol® (timolol maleate ophthalmic solution) 0.5%

Initial U.S. Approval: 1978

STERILE

INDICATIONS AND USAGE

Istalol (timolol maleate ophthalmic solution) 0.5% is a non-selective beta-adrenergic receptor blocking agent indicated in the treatment of elevated intraocular pressure (IOP) in patients with ocular hypertension or open-angle glaucoma.

CONTRAINDICATIONS

4.1 Asthma, COPD: Istalol is contraindicated in patients with bronchial asthma; a history of bronchial asthma; severe chronic obstructive pulmonary disease (see WARNINGS AND PRECAUTIONS, 5.1, 5.3).

4.2 Sinus Bradycardia, AV Block, Cardiac Failure, Cardiogenic Shock: Istalol is contraindicated in patients with sinus bradycardia; second or third degree atrioventricular block; overt cardiac failure (see WARNINGS AND PRECAUTIONS, 5.2); cardiogenic shock.

4.3 Hypersensitivity Reactions: Istalol is contraindicated in patients who have exhibited a hypersensitivity reaction to any component of this product in the past.

WARNINGS AND PRECAUTIONS

5.1 Potentiation of Respiratory Reactions Including Asthma: Istalol contains timolol maleate; and although administered topically, it can be absorbed systemically. Therefore, the same adverse reactions found with systemic administration of beta-adrenergic blocking agents may occur with topical administration. For example, severe respiratory reactions and cardiac reactions including death due to bronchospasm in patients with asthma, and rarely death in association with cardiac failure, have been reported following systemic or ophthalmic administration of timolol maleate (see CONTRAINDICATIONS, 4.1).

5.2 Cardiac Failure: Sympathetic stimulation may be essential for support of the circulation in individuals with diminished myocardial contractility, and its inhibition of beta-adrenergic receptor blockade may precipitate more severe failure. In patients without a history of cardiac failure, continued depression of the myocardium with beta-blocking agents over a period of time can, in some cases, lead to cardiac failure. At the first sign or symptom of cardiac failure, Istalol should be discontinued (see also CONTRAINDICATIONS, 4.2).

5.3 Obstructive Pulmonary Disease: Patients with chronic obstructive pulmonary disease (e.g., chronic bronchitis, emphysema) of mild or moderate severity, bronchospastic disease, or a history of bronchospastic disease [other than bronchial asthma or a history of bronchial asthma in which Istalol is contraindicated (see CONTRAINDICATIONS, 4.2)] should, in general, not receive beta-blocking agents, including Istalol.

5.4 Increased Reactivity to Allergens: While taking beta-blockers, patients with a history of atopy or a history of severe anaphylactic reactions to a variety of allergens may be more reactive to repeated accidental, diagnostic, or therapeutic challenge with such allergens. Such patients may be unresponsive to the usual doses of epinephrine used to treat anaphylactic reactions.

5.5 Potentiation of Muscle Weakness: Beta-adrenergic blockade has been reported to potentiate muscle weakness consistent with certain myasthenic symptoms (e.g., diplopia, ptosis, and generalized weakness). Timolol has been reported rarely to increase muscle weakness in some patients with myasthenia gravis or myasthenic symptoms.

5.6 Masking of Hypoglycemic Symptoms in Patients with Diabetes Mellitus: Beta-adrenergic blocking agents should be administered with caution in patients subject to spontaneous hypoglycemia or to diabetic patients (especially those with labile diabetes) who are receiving insulin or oral hypoglycemic agents. Beta-adrenergic receptor blocking agents may mask the signs and symptoms of acute hypoglycemia.

5.7 Masking of Thyrotoxicosis: Beta-adrenergic blocking agents may mask certain clinical signs (e.g., tachycardia) of hyperthyroidism. Patients suspected of developing thyrotoxicosis should be managed carefully to avoid abrupt withdrawal of beta-adrenergic blocking agents that might precipitate a thyroid storm.

5.8 Contamination of Topical Ophthalmic Products After Use: There have been reports of bacterial keratitis associated with the use of multiple-dose containers of topical ophthalmic products. These containers had been inadvertently contaminated by patients who, in most cases, had a concurrent corneal disease or a disruption of the ocular epithelial surface (see PATIENT COUNSELING INFORMATION, 17).

5.9 Impairment of Beta-adrenergically Mediated Reflexes During Surgery: The necessity or desirability of withdrawal of beta-adrenergic blocking agents prior to major surgery is controversial. Beta-adrenergic receptor blockade impairs the ability of the heart to respond to beta-adrenergically mediated reflex stimuli. This may augment the risk of general anesthesia in surgical procedures. Some patients receiving beta-adrenergic receptor blocking agents have experienced protracted severe hypotension during anesthesia. Difficulty in restarting and maintaining the heartbeat has also been reported. For these reasons, in patients undergoing elective surgery, some authorities recommend gradual withdrawal of beta-adrenergic receptor blocking agents. If necessary during surgery, the effects of beta-adrenergic blocking agents may be reversed by sufficient doses of adrenergic agonists.

5.10 Angle-Closure Glaucoma: In patients with angle-closure glaucoma, the immediate objective of treatment is to reopen the angle. This may require constricting the pupil. Timolol maleate has little or no effect on the pupil. Istalol should not be used alone in the treatment of angle-closure glaucoma.

5.11 Cerebrovascular Insufficiency: Because of potential effects of beta-adrenergic blocking agents on blood pressure and pulse, these agents should be used with caution in patients with cerebrovascular insufficiency. If signs or

symptoms suggesting reduced cerebral blood flow develop following initiation of therapy with Istalol, alternative therapy should be considered.

5.12 Choroidal Detachment: Choroidal detachment after filtration procedures has been reported with the administration of aqueous suppressant therapy (e.g. timolol).

ADVERSE REACTIONS

6.1 Clinical Trials Experience: Because clinical trials are conducted under widely varying conditions, adverse reaction rates observed in the clinical trials of a drug cannot be directly compared to rates in the clinical trials of another drug and may not reflect the rates observed in practice.

The most frequently reported adverse reactions have been burning and stinging upon instillation in 38% of patients treated with Istalol. Additional reactions reported with Istalol at a frequency of 4 to 10% include: blurred vision, cataract, conjunctival injection, headache, hypertension, infection, itching and decreased visual acuity. The following additional adverse reactions have been reported less frequently with ocular administration of this or other timolol maleate formulations.

Timolol (Ocular Administration): *Body as a whole:* Asthenia/fatigue and chest pain; *Cardiovascular:* Bradycardia, arrhythmia, hypotension, syncope, heart block, cerebral vascular accident, cerebral ischemia, cardiac failure, worsening of angina pectoris, palpitation, cardiac arrest, pulmonary edema, edema, claudication, Raynaud's phenomenon and cold hands and feet; *Digestive:* Nausea, diarrhea, dyspepsia, anorexia, and dry mouth; *Immunologic:* Systemic lupus erythematosus; *Nervous System/Psychiatric:* Dizziness, increase in signs and symptoms of myasthenia gravis, paresthesia, somnolence, insomnia, nightmares, behavioral changes and psychic disturbances including depression, confusion, hallucinations, anxiety, disorientation, nervousness and memory loss; *Skin:* Alopecia and psoriasisiform rash or exacerbation of psoriasis; *Hypersensitivity:* Signs and symptoms of systemic allergic reactions, including angioedema, urticaria, and localized and generalized rash; *Respiratory:* Bronchospasm (predominantly in patients with pre-existing bronchospastic disease), respiratory failure, dyspnea, nasal congestion, cough and upper respiratory infections; *Endocrine:* Masked symptoms of hypoglycemia in diabetic patients (see WARNINGS AND PRECAUTIONS, 5.6); *Special Senses:* Signs and symptoms of ocular irritation including conjunctivitis, blepharitis, keratitis, ocular pain, discharge (e.g., crusting), foreign body sensation, itching and tearing, and dry eyes; ptosis, decreased corneal sensitivity; cystoid macular edema; visual disturbances including refractive changes and diplopia; pseudophthalmic; choroidal detachment following filtration surgery (see WARNINGS AND PRECAUTIONS, 5.12); *Urogenital:* Retroperitoneal fibrosis, decreased libido, impotence, and Peyronie's disease.

6.2 Postmarketing Experience

Oral Timolol/Oral Beta-blockers: The following additional adverse effects have been reported in clinical experience with ORAL timolol maleate or other ORAL beta-blocking agents may be considered potential effects of ophthalmic timolol maleate: *Allergic:* Erythematous rash, fever combined with aching and sore throat, laryngospasm with respiratory distress; *Body as a Whole:* Extremity pain, decreased exercise tolerance, weight loss; *Cardiovascular:* Worsening of arterial insufficiency, vasodilatation; *Digestive:* Gastrointestinal pain, hepatomegaly, vomiting, mesenteric arterial thrombosis, ischemic colitis; *Hematologic:* Nonthrombocytopenic purpura; thrombocytopenic purpura, agranulocytosis; *Endocrine:* Hypertglycemia, hypoglycemia; *Skin:* Pruritus, skin irritation, increased pigmentation, sweating; *Musculoskeletal:* Arthralgia; *Nervous System/Psychiatric:* Vertigo, local weakness, diminished concentration, reversible mental depression progressing to catatonia, an acute reversible syndrome characterized by disorientation for time and place, emotional lability, slightly clouded sensorium and decreased performance on neuropsychometrics; *Respiratory:* Rales, bronchial obstruction; *Urogenital:* Urination difficulties.

DRUG INTERACTIONS

7.1 Beta-Adrenergic Blocking Agents: Patients who are receiving a beta-adrenergic blocking agent orally and Istalol® should be observed for potential additive effects of beta-blockade, both systemic and on intraocular pressure. The concomitant use of two topical beta-adrenergic blocking agents is not recommended.

7.2 Calcium Antagonists: Caution should be used in the co-administration of beta-adrenergic blocking agents, such as Istalol, and oral or intravenous calcium antagonists because of possible atrioventricular conduction disturbances, left ventricular failure, and hypotension. In patients with impaired cardiac function, co-administration should be avoided.

7.3 Catecholamine-Depleting Drugs: Close observation of the patient is recommended when a beta blocker is administered to patients receiving catecholamine-depleting drugs such as reserpine, because of possible additive effects and the production of hypotension and/or marked bradycardia, which may result in vertigo, syncope, or postural hypotension.

7.4 Digitalis and Calcium Antagonists: The concomitant use of beta-adrenergic blocking agents with digitalis and calcium antagonists may have additive effects in prolonging atrioventricular conduction time.

7.5 CYP2D6 Inhibitors: Potentiated systemic beta-blockade (e.g., decreased heart rate) has been reported during combined treatment with CYP2D6 inhibitors (e.g., quinidine) and timolol.

7.6 Clonidine: Oral beta-adrenergic blocking agents may exacerbate the rebound hypertension which can follow the withdrawal of clonidine. There have been no reports of exacerbation of rebound hypertension with ophthalmic timolol maleate.

USE IN SPECIFIC POPULATIONS

8.1 Pregnancy

Teratogenic Effects: Pregnancy Category C: Teratogenicity studies have been performed in animals. Teratogenicity studies with timolol in mice, rats, and rabbits at oral doses up to 50 mg/kg/day (7,000 times the systemic exposure following the maximum recommended human ophthalmic dose) demonstrated no evidence of fetal malformations. Although delayed fetal ossification was observed at this dose

in rats, there were no adverse effects on postnatal development of offspring. Doses of 1000 mg/kg/day (142,000 times the systemic exposure following the maximum recommended human ophthalmic dose) were maternotoxic in mice and resulted in an increased number of fetal resorptions. Increased fetal resorptions were also seen in rabbits at doses of 14,000 times the systemic exposure following the maximum recommended human ophthalmic dose, in this case without apparent maternotoxicity. There are no adequate and well-controlled studies in pregnant women. Istalol should be used during pregnancy only if the potential benefit justifies the potential risk to the fetus.

8.3 Nursing Mothers: Timolol has been detected in human milk following oral and ophthalmic drug administration. Because of the potential for serious adverse reactions from Istalol in nursing infants, a decision should be made whether to discontinue nursing or to discontinue the drug, taking into account the importance of the drug to the mother.

8.4 Pediatric Use: Safety and effectiveness in pediatric patients have not been established.

8.5 Geriatric Use: No overall differences in safety or effectiveness have been observed between elderly and younger patients.

OVERDOSAGE

There have been reports of inadvertent overdosage with Istalol resulting in systemic effects similar to those seen with systemic beta-adrenergic blocking agents such as dizziness, headache, shortness of breath, bradycardia, bronchospasm, and cardiac arrest. An *in vitro* hemodialysis study, using ¹⁴C timolol added to human plasma or whole blood, showed that timolol was readily dialyzed from these fluids; however, a study of patients with renal failure showed that timolol did not dialyze readily.

NONCLINICAL TOXICOLOGY

13.1 Carcinogenesis, Mutagenesis, Impairment of Fertility: In a two-year study of timolol maleate administered orally to rats, there was a statistically significant increase in the incidence of adrenal pheochromocytomas in male rats administered 300 mg/kg/day (approximately 42,000 times the systemic exposure following the maximum recommended human ophthalmic dose). Similar differences were not observed in rats administered oral doses equivalent to approximately 14,000 times the maximum recommended human ophthalmic dose. In a lifetime oral study in mice, there were statistically significant increases in the incidence of benign and malignant pulmonary tumors, benign uterine polyps and mammary adenocarcinomas in female mice at 500 mg/kg/day, (approximately 71,000 times the systemic exposure following the maximum recommended human ophthalmic dose), but not at 5 or 50 mg/kg/day (approximately 700 or 7,000, respectively, times the systemic exposure following the maximum recommended human ophthalmic dose). In a subsequent study in female mice, in which post-mortem examinations were limited to the uterus and the lungs, a statistically significant increase in the incidence of pulmonary tumors was again observed at 500 mg/kg/day. The increased occurrence of mammary adenocarcinomas was associated with elevations in serum prolactin which occurred in female mice administered oral timolol at 500 mg/kg/day, but not at doses of 5 or 50 mg/kg/day. An increased incidence of mammary adenocarcinomas in rodents has been associated with administration of several other therapeutic agents that elevate serum prolactin, but no correlation between serum prolactin levels and mammary tumors has been established in humans. Furthermore, in adult human female subjects who received oral dosages of up to 60 mg of timolol maleate (the maximum recommended human oral dosage), there were no clinically meaningful changes in serum prolactin. Timolol maleate was devoid of mutagenic potential when tested *in vivo* (mouse) in the micronucleus test and cytogenetic assay (doses up to 800 mg/kg and *in vitro* in a neoplastic cell transformation assay (up to 100 mcg/mL). In Ames tests the highest concentrations of timolol employed, 5,000 or 10,000 mcg/plate, were associated with statistically significant elevations of revertants observed with tester strain TA100 (in seven replicate assays), but not in the remaining three strains. In the assays with tester strain TA100, no consistent dose response relationship was observed, and the ratio of test to control revertants did not reach 2. A ratio of 2 is usually considered the criterion for a positive Ames test. Reproduction and fertility studies in rats demonstrated no adverse effect on male or female fertility at doses up to 21,000 times the systemic exposure following the maximum recommended human ophthalmic dose.

PATIENT COUNSELING INFORMATION

Patients with bronchial asthma, a history of bronchial asthma, severe chronic obstructive pulmonary disease, sinus bradycardia, second or third degree atrioventricular block, or cardiac failure should be advised not to take this product. (see CONTRAINDICATIONS, 4.1, 4.2) Patients should also be instructed that ocular solutions, if handled improperly or if the tip of the dispensing container contacts the eye or surrounding structures, can become contaminated by common bacteria known to cause ocular infections. Serious damage to the eye and subsequent loss of vision may result from using contaminated solutions. (see WARNINGS AND PRECAUTIONS 5.8) Patients should also be advised that if they have ocular surgery or develop an intercurrent ocular condition (e.g., trauma or infection), they should immediately seek their physician's advice concerning the continued use of the present multidose container. If more than one topical ophthalmic drug is being used, the drugs should be administered at least five minutes apart. Patients should be advised that Istalol® contains benzalkonium chloride which may be absorbed by soft contact lenses. Contact lenses should be removed prior to administration of the solution. Lenses may be reinserted 15 minutes following Istalol® administration.

Rx Only

Manufactured by:
Bausch & Lomb Incorporated
Tampa, FL 33637

Under License from:
SUNU Pharmaceutical Co., Ltd
Osaka, Japan 541-0046

®/TM are trademarks of Bausch & Lomb Incorporated or its affiliates.
© Bausch & Lomb Incorporated

Based on 9401500

US/IST/14/0007 Issued 06/2013

CONTRIBUTING EDITORS

PAUL C. AJAMIAN, OD, ATLANTA
AARON BRONNER, OD, KENNEWICK, WASH.
MILE BRUJIC, OD, BOWLING GREEN, OHIO
DEREK N. CUNNINGHAM, OD, AUSTIN, TEXAS
MARK T. DUNBAR, OD, MIAMI
ARTHUR B. EPSTEIN, OD, PHOENIX
JAMES L. FANELLI, OD, WILMINGTON, NC
FRANK FONTANA, OD, ST. LOUIS
GARY S. GERBER, OD, HAWTHORNE, NJ
ANDREW S. GURWOOD, OD, PHILADELPHIA
ALAN G. KABAT, OD, MEMPHIS, TENN.
DAVID KADING, OD, SEATTLE
PAUL M. KARPECKI, OD, LEXINGTON, KY.
JEROME A. LEGERTON, OD, MBA, SAN DIEGO
JASON R. MILLER, OD, MBA, POWELL, OHIO
CHERYL G. MURPHY, OD, BABYLON, NY
CARLO J. PELINO, OD, JENKINTOWN, PA.
JOSEPH PIZZIMENTI, OD, FORT LAUDERDALE, FLA.
JOHN RUMPAKIS, OD, MBA, PORTLAND, ORE.
DIANA L. SHECHTMAN, OD, FORT LAUDERDALE, FLA.
JEROME SHERMAN, OD, NEW YORK
JOSEPH P. SHOVLIN, OD, SCRANTON, PA.
JOSEPH W. SOWKA, OD, FORT LAUDERDALE, FLA.
MONTGOMERY VICKERS, OD, ST. ALBANS, W.VA.
WALTER O. WHITLEY, OD, MBA, VIRGINIA BEACH, VA.

EDITORIAL REVIEW BOARD

JEFFREY R. ANSHEL, OD, CARLSBAD, CALIF.
JILL AUTRY, OD, RPH, HOUSTON
SHERRY J. BASS, OD, NEW YORK
EDWARD S. BENNETT, OD, ST. LOUIS
MARC R. BLOOMENSTEIN, OD, SCOTTSDALE, ARIZ.
CHRIS J. CAKANAC, OD, MURRYSVILLE, PA.
JERRY CAVALLERANO, OD, PHD, BOSTON
WALTER L. CHOATE, OD, MADISON, TENN.
BRIAN CHOU, OD, SAN DIEGO
A. PAUL CHOUS, MA, OD, TACOMA, WASH.
ROBERT M. COLE, III, OD, BRIDGETON, NJ
GLENN S. CORBIN, OD, WYOMISSING, PA.
ANTHONY S. DIECIDUE, OD, STROUDSBURG, PA.
S. BARRY EIDEN, OD, DEERFIELD, ILL.
STEVEN FERRUCCI, OD, SEPULVEDA, CALIF.
MURRAY FINGERET, OD, HEWLETT, NY
IAN BEN GADDIE, OD, LOUISVILLE, KY.
MILTON HOM, OD, AZUSA, CALIF.
BLAIR B. LONSBERRY, MS, OD, MED, PORTLAND, ORE.
THOMAS L. LEWIS, OD, PHD, PHILADELPHIA
DOMINICK MAINO, OD, MED, CHICAGO
KELLY A. MALLOY, OD, PHILADELPHIA
RICHARD B. MANGAN, OD, LEXINGTON, KY.
RON MELTON, OD, CHARLOTTE, NC
PAMELA J. MILLER, OD, JD, HIGHLAND, CALIF.
BRUCE MUCHNICK, OD, COATESVILLE, PA.
MARC MYERS, OD, COATESVILLE, PA.
WILLIAM B. POTTER, OD, FREEHOLD, NJ
CHRISTOPHER J. QUINN, OD, ISELIN, NJ
MOHAMMAD RAFIETARY, OD, MEMPHIS, TN
JOHN L. SCHACHET, OD, ENGLEWOOD, COLO.
JACK SCHAEFFER, OD, BIRMINGHAM, ALA.
MICHAEL C. RADOIU, OD, STAUNTON, VA.
LEO P. SEMES, OD, BIRMINGHAM, ALA.
LEONID SKORIN, JR., OD, DO, ROCHESTER, MINN.
JOSEPH W. SOWKA, OD, FORT LAUDERDALE, FLA.
SRUTHI SRINIVASAN, PHD, BS OPTOM, WATERLOO, ONT.
BRAD M. SUTTON, OD, INDIANAPOLIS
LORETTA B. SZCZOTKA, OD, PHD, CLEVELAND
TAMMY P. THAN, MS, OD, BIRMINGHAM, ALA.
RANDALL THOMAS, OD, CONCORD, NC
SARA WEIDMAYER, OD, ANN ARBOR, MI
KATHY C. WILLIAMS, OD, SEATTLE
KAREN YEUNG, OD, LOS ANGELES

TECHNOLOGY, INC.
DGI

THE ULTRASOUND SPECIALIST

The Scanmate Flex

Flexible, so you don't have to be.



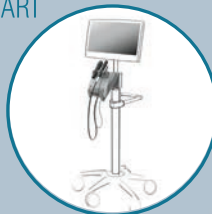DESK



WALL



CART



-B-SCAN

-A-SCAN

UBM



Visit us at **Booth #3100** (AAO Ophthalmology, Chicago)
or **Booth #701** (AAO Optometry, Anaheim)

Pending 510(k) clearance, the Scanmate Flex is
not available for sale within the United States.

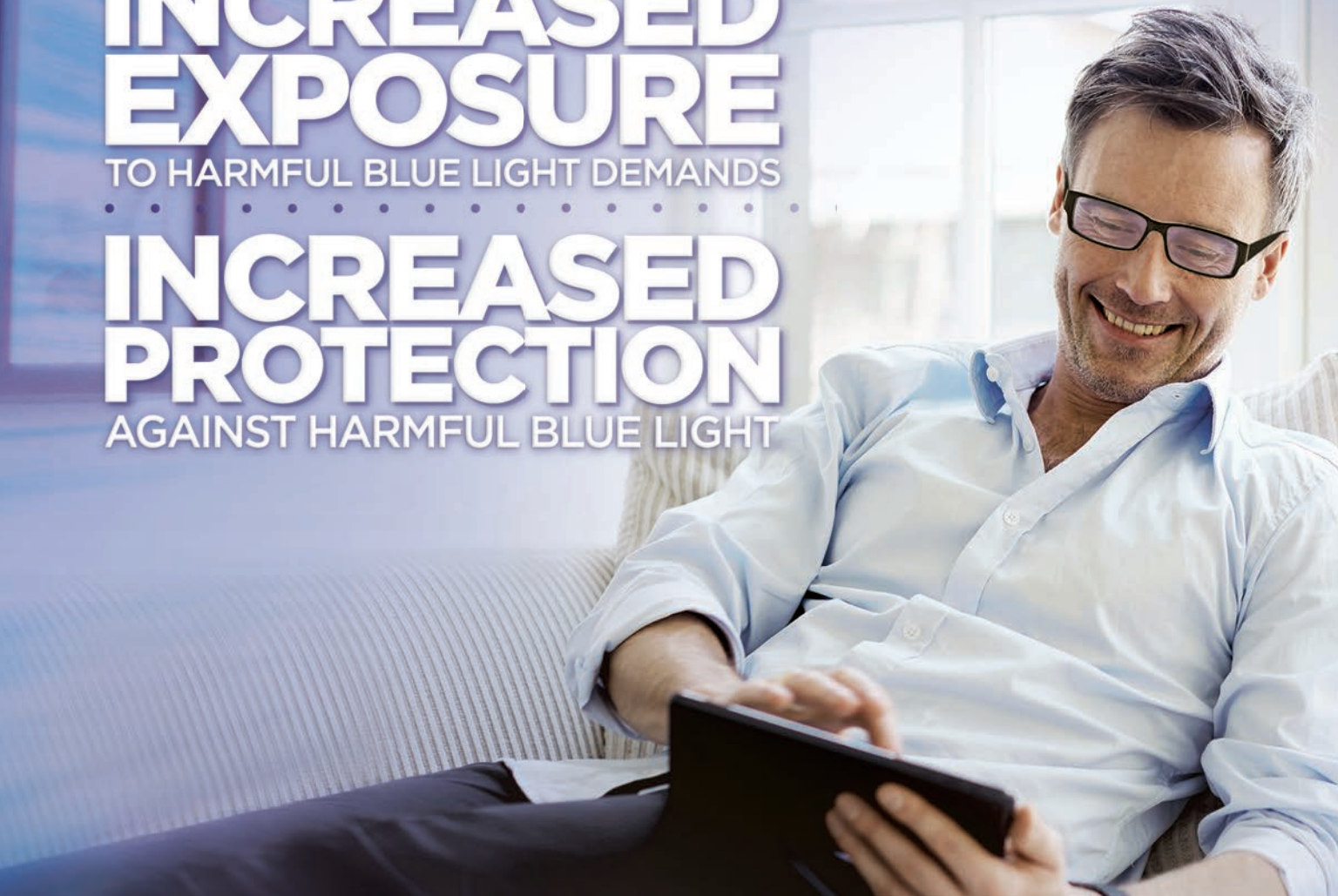

INCREASED EXPOSURE

TO HARMFUL BLUE LIGHT DEMANDS

INCREASED PROTECTION

AGAINST HARMFUL BLUE LIGHT



Now give your patients even more protection against Harmful Blue Light¹.

Crizal Previncia lenses have always been an effective way to protect your patients against Harmful Blue Light. *Crizal Previncia+*, the next evolution of protection, is created when you apply *Crizal Previncia* to any design with the *Smart Blue Filter* feature. By reflecting **and** absorbing, *Crizal Previncia+* filters out at least 30%² of Harmful Blue Light, giving your patients enhanced protection and even greater peace-of-mind.

Crizal[®] PREVENCIA⁺

WITH SMART BLUE FILTER[™]

Visit us at Crizal.com

Smart Blue Filter feature is available in Transitions[®], Eyezen[™]+ and Varilux[®] Digital lenses.

¹Harmful Blue Light falls between 415-455nm on the light spectrum and is suspected to be most toxic to retinal cells. See Arnault E, Barrau C, Nanteau C, Gondouin P, Bigot K, et al. (2013). Phototoxic Action Spectrum on a Retinal Pigment Epithelium Model of Age-Related Macular Degeneration Exposed to Sunlight Normalized Conditions. PLoS ONE 8(8): e71398. doi:10.1371/journal.pone.0071398. Harmful Blue Light is the blue-violet wavelengths believed most toxic to retinal cells, which lie between 415-455nm on the light spectrum. ²Combining a Smart Blue Filter[™] lens with Crizal[®] Previncia[®] No-glare coating reduces exposure to Harmful Blue Light by at least 30% and provides UV protection.

High Praise

I read the 125th anniversary issue (July 2016) on planes to and from Nova Scotia. I think your staff did a superb job in the coverage. They really did.

The profession of optometry has made miraculous strides in the 70 or so years since I started practicing. The changes in goals and in scope of practice, in my opinion, have been greater than any other healthcare profession. I do hope that the younger generation does not forget the early years.

I have been a friend of Frank Fontana for years and years, and both Drs. Gurwood (the father and the son) are on my list of colleagues. It was a pleasure to see them featured in the issue.

Thank you for taking the time, and making the effort, to construct the theme of this issue. Congratulations to you and your colleagues for a job well done.

—Irving Bennett, OD
Sarasota, FL

Sight Gags By Scott Lee, OD



Optometry's changes in goals and in scope of practice have been greater than any other healthcare profession. I do hope that the younger generation does not forget the early years.

Out With the New, In With the Old

“Speaking Frankly: A Conversation with Frank D. Fontana, OD” (July 2016) was priceless! For us “old geezers,” who’ve been practicing for more than 50 years, hearing Dr. Fontana relate to the old days is something we greatly appreciate.

— Stan Pugh, OD
Tacoma, WA

Son of A. Fitch

Congratulations on 125 years of your eminent magazine. While reading about optometry’s evolution, I saw many prominent optometric names mentioned, including that of Albert Fitch. I attended the Pennsylvania State College of Optometry (1958-1962). This unique institution required a total of six years of education (about a third of the class had BA/BS degrees). All the other institutions required five years. PSCO included full courses in organic chemistry, biochemistry, neuroanatomy, human anatomy (dissected cadaver), mammalian anatomy (dissected cat), general pathology, ocular histopathology, ocular pathology and public health. In addition, all courses were appropriately instructed by individuals with PhD and MD degrees. Think of it! Sixty years later and today’s colleges have curricula patterned from PSCO’s model. That is why, in my humble opinion, Dr. Fitch’s name, for his many important contributions, should be more prominently recognized.

—Nathan Solat, OD
Staten Island, NY
PSCO 1962

Physician, Eat Thy Vitamins

I read with great interest the nutrition and roundtable discussion in the February issue (“Transforming Eye Health Through Proven Ocular Nutrition Strategies,” sponsored by MacuHealth). The discussion regarding the benefits of nutritional supplementation, and the role of optometrists, was very insightful. It was especially enlightening to read about the benefits of improved nutrition, even for apparently young and healthy people, regarding the increase in macular pigment optical density, correlating to improved mental acuity.

I have taken a multivitamin and 500mg of time-

released vitamin C daily for 33 years. I take no prescription medications and only have mildly elevated LDL cholesterol, which I have reduced to normal levels with natural plant sterols and stanols supplementation.

We humans need a well-balanced diet that includes supplementation with all vitamins, minerals and carotenoids; foods are not enough.

After 40 years as a practicing optometrist, I have observed a definite change for the worse in the ocular and general health of us “Baby Boomers.” I believe this is due to poor nutrition and exposure to toxic chemicals in our foods and environment.

I do provide and sell nutritional supplements in my office, so that patients get what I think is best for them. The array of vitamins on the shelf in stores can be very confusing. Generic vitamins in stores are often low quality in the raw materials they are extracted from. Plus, generic vitamin pills often contain dyes and fillers, which are not needed and can even be toxic.

Thanks to the authors for a truly enlightening article, and their advice that optometrists and ophthalmologists need to get involved in specifically recommending what all patients need to improve their vision and general health.

—R. Thomas McHugh, OD
Morehead, KY

In Defense of Retinal Scanning

Response to “The Dilation Dilemma,” June 2016:

When debating the value of retinal screening vs. dilated fundus exams (DFE), don’t underestimate the impact retinal scans have on patient education. *Figure 1* demonstrates what the results of a DFE looks like to a patient with diabetic retinopathy. *Figures 2* and *3* demonstrate what the results of an Optomap (Optos) scan, without DFE, look like for the same patient. The images speak for themselves.

I routinely dilated eyes for 25 years before I obtained an Optos retinal scanner for my practice in 2006. What I found that I—as well as other respected practices in my area—had been missing most by relying on DFE was mid-peripheral lesions. In addition, some prior DFE records from my own and other practices had the lesions in different locations than they actually were. These “clerical” errors of position simply do not happen with Optos.

Although I still have my indirect ophthalmoscope

and lenses, Optos has been the one technology in 36 years of practice that has most dramatically improved my ability to diagnose and educate patients. It has allowed for immediate consultations with retinal specialists, even on Saturday

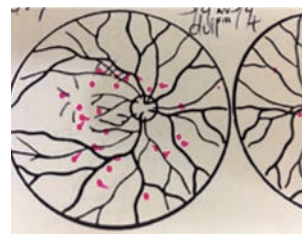
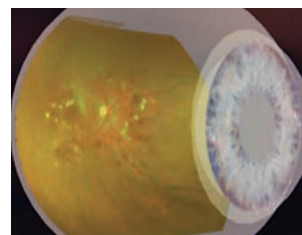
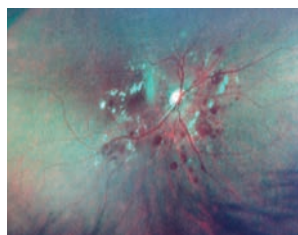


Fig. 1. Hand-drawn DFE documentation.



Figs. 2 and 3. Optomap images of the same pathology.

afternoons. It provides the opportunity for that all-important “second look” by yourself or a colleague.

In the minute it takes to explain an Optomap image to a patient, I see conditions that I may have missed during a DFE.

I began practicing when it was illegal to dilate. I remember opposing camps in optometry regarding retinoscopy and autorefraction. I remember seeing my first OCT.

Standards of care in health care are always evolving, and each step in this technological evolution faces its critics. It is not mercenary of us to embrace these technologies—it is visionary and vital for the future of our profession. Optometry needs these new methods of examining eyes. We need engineers to create these technologies and practitioners that have the courage to adopt them.

The insurance coverage a patient does or does not have should not determine what we feel is the most comprehensive level of care. If insurance companies only covered a routine eye exam every three years, should that be the new standard of care?

Dilation and Optos each have their advantages and disadvantages. Please don’t refer to Optos as “a crutch” while our current standard of care provides no permanent record, of a fleeting image of a small part of the retina that we only see upside down and backwards.

— Robert Conway, OD
Rochester, NY



PRINTED IN USA

FOUNDING EDITOR, FREDERICK BOGER
1891-1913

EDITORIAL OFFICES

11 CAMPUS BLVD., SUITE 100
NEWTOWN SQUARE, PA 19073

WEBSITE • WWW.REVIEWOFOPTOMETRY.COM

SUBSCRIPTION INQUIRIES

1-877-529-1746

CONTINUING EDUCATION INQUIRIES

1-800-825-4696

EDITOR-IN-CHIEF • JACK PERSICO

(610) 492-1006 • JPERSICO@JOBSON.COM

SENIOR EDITOR • BILL KEKEVIAN

(610) 492-1003 • BKEKEVIAN@JOBSON.COM

SENIOR ASSOCIATE EDITOR • REBECCA HEPP

(610) 492-1005 • RHEPP@JOBSON.COM

ASSOCIATE EDITOR • MICHAEL RIVIELLO

(610) 492-1021 • MRIVIELLO@JOBSON.COM

ASSOCIATE EDITOR • ADRIENNE TARON

(610) 492-1005 • ATARON@JOBSON.COM

SPECIAL PROJECTS EDITOR • JILL HOFFMAN

(610) 492-1037 • JHOFFMAN@JOBSON.COM

ART DIRECTOR • JARED ARAUJO

(610) 492-1032 • JARAUIJO@JOBSON.COM

DIRECTOR OF CE ADMINISTRATION • REGINA COMBS

(212) 274-7160 • RCOMBS@JOBSON.COM

EDITORIAL BOARD

CHIEF CLINICAL EDITOR • PAUL M. KARPECKI, OD

ASSOCIATE CLINICAL EDITORS • JOSEPH P. SHOVLIN, OD;

ALAN G. KABAT, OD; CHRISTINE W. SINDT, OD

DIRECTOR OPTOMETRIC PROGRAMS • ARTHUR EPSTEIN, OD

CLINICAL & EDUCATION CONFERENCE ADVISOR

PAUL M. KARPECKI, OD

CASE REPORTS COORDINATOR • ANDREW S. GURWOOD, OD

CLINICAL CODING EDITOR • JOHN RUMPAKIS, OD, MBA

CONSULTING EDITOR • FRANK FONTANA, OD

COLUMNISTS

CHAIRSIDE • MONTGOMERY VICKERS, OD

CLINICAL QUANDARIES • PAUL C. AJAMIAN, OD

CODING CONNECTION • JOHN RUMPAKIS, OD

CORNEA & CONTACT LENS Q+A • JOSEPH P. SHOVLIN, OD

DIAGNOSTIC QUIZ • ANDREW S. GURWOOD, OD

FOCUS ON REFRACTION • MARC TAUB, OD;

PAUL HARRIS, OD

GLAUCOMA GRAND ROUNDS • JAMES L. FANELLI, OD

NEURO CLINIC • MICHAEL TROTTINI, OD;

MICHAEL DELGODICE, OD

OCULAR SURFACE REVIEW • PAUL M. KARPECKI, OD

RETINA QUIZ • MARK T. DUNBAR, OD

REVIEW OF SYSTEMS • CARLO J. PELINO, OD;

JOSEPH J. PIZZIMENTI, OD

SURGICAL MINUTE • DEREK N. CUNNINGHAM, OD;

WALTER O. WHITLEY, OD, MBA

THERAPEUTIC REVIEW • JOSEPH W. SOWKA, OD;

ALAN G. KABAT, OD

URGENT CARE • RICHARD B. MANGAN, OD

JOBSON MEDICAL INFORMATION LLC



Outlook

By Jack Persico, Editor-in-Chief



Technical Difficulties

High-tech diagnostic screening tools only help if you prioritize education and attentiveness.

Imagine this scenario: You bring your car in for routine maintenance. The basic services are covered under your warranty, so you don't expect to lay out any cash unless there's a repair needed. The car's in good shape, so you figure you'll be out of there without much hassle. But before you've even gotten your complimentary cup of coffee, the receptionist hands you some intimidating forms. Apparently, there are several optional tests the mechanic can do if you're willing to pay. One detects engine problems sooner. Another could make your steering more responsive. A third will get you out the door today faster—and might also reveal wear and tear better. But maybe these tests do nothing. It's confusing. And the decision is on your shoulders.

You study the forms quizzically, trying to parse the technical jargon, and worry about making the wrong call. It feels like a lose-lose situation: either you waste money on unnecessary tests or risk missing out on valuable information.

Sound familiar? This is exactly how some patients feel when presented with the array of options for elective diagnostic screening tests.

This didn't really dawn on me until a few weeks ago when my wife needed an eye exam, her first in several years. After checking in with the receptionist, she was asked to make three decisions about her own care—and wallet—while still in the waiting room. Like many practices, this one offered wavefront scanning, visual field screening and ultra-widefield retinal imaging.

Other offices might offer OCT and macular pigment optical density too, either bundled into a “wellness package” or offered a la carte.

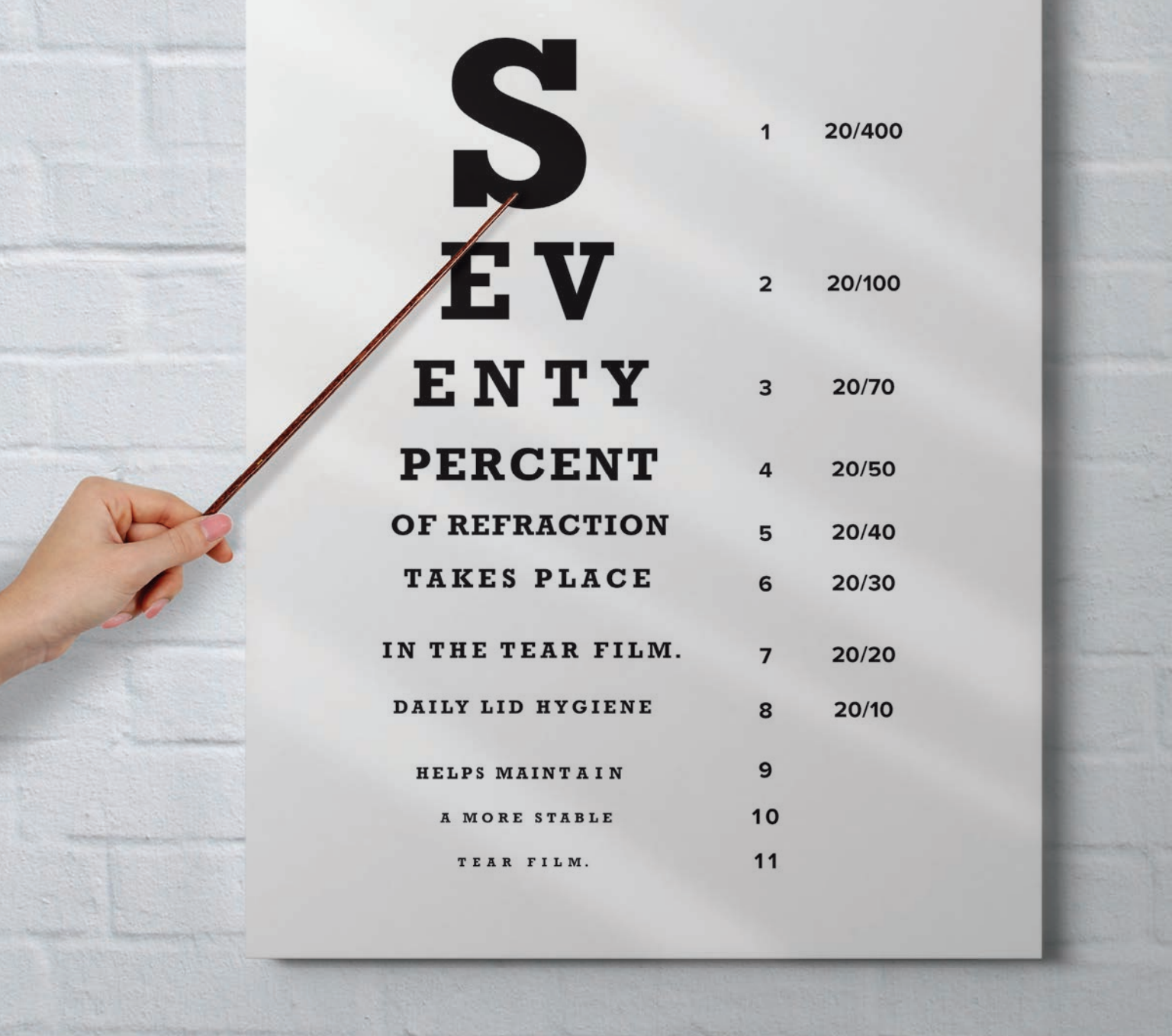It's a lot of info to absorb, especially before the patient has spoken to anyone with clinical expertise.

I know this is common practice. That doesn't make it *good* practice, however. Shouldn't the patient be able to discuss these procedures with the doctor or a well-informed tech, to make a better decision or at least put their mind at ease? My wife was busy texting me for advice instead of having a conversation with a health-care professional.

There's nothing wrong with offering elective services or out-of-pocket charges. Many patients are happy to pay top dollar for high-fashion eyewear, multifocal contact lenses, “spa-like” dry eye treatments and other lifestyle enhancements. But when an optional fee concerns diagnostic data, it's harder for patients to gauge the value on their own, especially if the handouts imply a possible missed diagnosis for those who decline the test. They need personal attention, not form letters.

Give patients the courtesy of a conversation. Look at their history. Talk about their goals. Make recommendations. Let them know they have an advocate at the practice; otherwise, they may consider it a stressful, “hard-sell” experience instead of the chance to take advantage of some cutting-edge technology to learn more about their eyes.

New technology enables many great things. Make sure good patient communication is one of them. ■



Visit NovaBay at EastWest Eye Conference, booth 317!

Add Avenova® with Neutrox® (Pure Hypochlorous Acid 0.01% as a preservative), the only Rx lid hygiene product with pure hypochlorous acid, to the lid & lash hygiene regimen for all your patients.

NovaBay®

Avenova®
Daily lid and lash hygiene.



20 Tips to Think Through

My mind wanders when faced with a big decision. Here's where it goes, and what it has learned. **By Montgomery Vickers, OD**

Optometrists are thinkers. We sit around chewing on the least important issues as if our entire world will most certainly collapse if we choose the wrong side dish at Taco Bell. So, imagine the turmoil the poor OD faces when a sales rep wants him to order a lens bank. What to do!?

I have developed a few random thoughts that might help you gain the confidence to make weighty decisions such as this:

1. Tackle every computer decision with the clear understanding that you will eventually drop the monitor onto your arthritic big toe. Choose accordingly.
2. When you think, "that was the stupidest idea I've ever had," know that you'll top that someday, I promise.
3. Studies show that, if you decide your answer is *no* you will be right 87.45% of the time.
4. No decision you make will make sense to your spouse.
5. If "just say yes!" pops into your head, it's the Holy Spirit talking—unless it's a weight loss infomercial at 3am.
6. Never make your final decision based on how much it costs *you* because your patients are paying for it! They will not be happy unless it benefits *them*.
7. Try new lenses on every candidate as your first choice. Only keep the fitting set if eight of every 10 patients love it.
8. If you are deciding what multifocal contact lens to choose for a

patient, you are already in over your head, my friend.

9. A written policy gives you confidence in tricky situations. If a patient's phone rings, my policy is to leave the room for at least an hour for their privacy.

10. Once you de-cide on a new phone system, unload and remove all firearms from your house to prevent some other kind of "-cide."

11. Never decide that patients are snotty-heads based on their front desk interactions. They are probably just mad at their spouse, running late for a tennis lesson—or maybe they are, in fact, snotty-heads.

12. Each day wake up and decide to be at peace. Smile and laugh, enjoy each moment and, if all else fails, there is always tequila.

13. One theory is that the more you learn about your profession the better decisions you will make. Or you can stay stupid and be just as successful.

14. If in doubt, trust #2 more than #1.

15. There's a good reason that restaurant's parking lot is empty.

16. When buying a new car, test drive it to a lumberyard and compare it with all the

other vehicles. Still like it? Buy it.

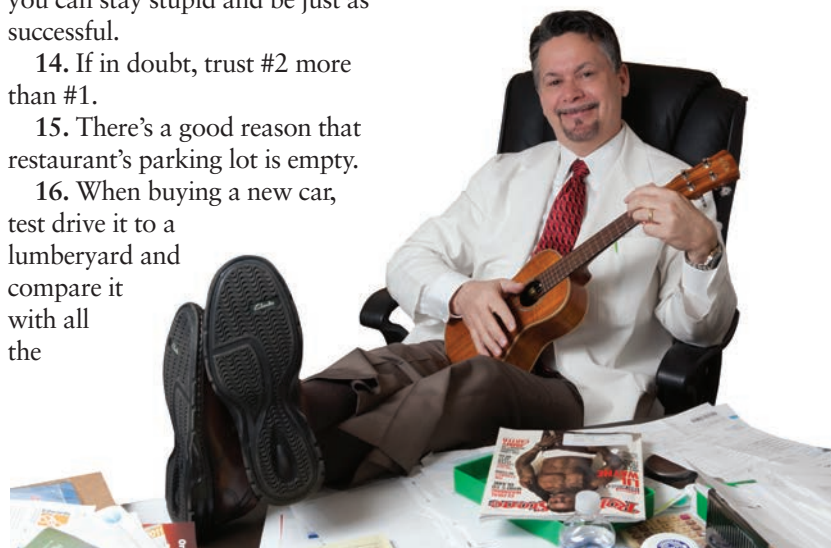17. Always refer to the wisdom of the punk band, The Clash. If I can't decide, *Should I Stay or Should I Go*, my fallback position is *Rock the Casbah*. It works for me.

18. Nancy Reagan was correct: just say no.

19. When the decision has the potential to be a life game changer, I look at all the facts, carefully research the alternatives, lay out the myriad sequelae—and then I do what my wife says.

20. Drink tons of water. The quiet times my kidneys have afforded me have contributed so much to my decision making process.

You are now prepared to make outstanding decisions—or at least have something to do while you procrastinate: Google The Clash. That will give you a break in the action as you *Rock the Casbah*. ■



COMING SOON

FROM SUN OPHTHALMICS

***Brom*SITE™**
(bromfenac ophthalmic solution) 0.075%

Announcing BromSite, the first product from Sun Ophthalmics.

Visit bromsite.com to find out more.

Sun Ophthalmics is a division of Sun Pharmaceutical Industries, Inc.
© 2016 Sun Pharmaceutical Industries, Inc. All rights reserved.
BromSite is a trademark of Sun Pharma Global FZE.
SUN-OPH-BRO-001 06/2016





Preventing a Total Melt Down

Keratolysis is a significant complication that demands immediate attention. Here's a primer on monitoring and treating it. **By Justin Schweitzer, OD, and Richard Mangan, OD**

The vast majority of refractive surgery cases go according to plan, but when patients do experience complications, optometrists are there to play an integral role in comanagement. Corneal melting, or keratolysis, is one such complication that may occur after LASIK. It can lead to scarring, irregular astigmatism, photophobia and decreased vision. Improvements in surgical techniques and technology have reduced the incidence of postoperative complications after LASIK, but corneal melt remains an emergent threat to a patient's vision. Prompt recognition and aggressive treatment can prevent permanent visual loss. In this column, we review the pathophysiology and treatment of this potentially vision-threatening condition.

Pathophysiology

The incidence of a corneal melt following LASIK is difficult to quantify accurately, as reports in published literature are often small series or case reports discussing a single event.¹ The melting process often starts at the rim of the flap and is commonly associated with a variety of conditions, such as epithelial ingrowth.¹ The migration of epithelial cells under the LASIK flap increases following enhancement surgery, specifically following lifting of the flap.^{1,2} Patients with certain preexisting corneal conditions present a greater risk of developing ingrowth and are at a greater risk for corneal melting after LASIK flap

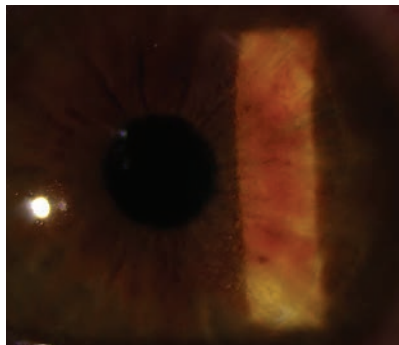


Fig. 1. This patient's corneal condition put him at greater risk for the corneal melt he eventually developed.

creation (Figure 1).^{3,4} These conditions include epithelial basement membrane dystrophy, collagen vascular diseases and autoimmune diseases.^{3,4} Additionally, dry eye disease creates a poor healing environment of the cornea, which may potentially make corneal melt more likely. These conditions should be resolved before LASIK surgery is performed.

Topical NSAIDs are commonly used for reduction of postoperative inflammation following ocular surgeries. NSAIDs have been associated with corneal toxicity, which is believed to be associated with corneal melting.^{5,6}

Diffuse lamellar keratitis (DLK), which is characterized by diffuse infiltrates at the flap margin, can lead to pain, photophobia, blurred vision and, eventually, corneal melting. Clinically, patients with DLK will present with progressive hyperopia and irregular astigmatism. The stages of DLK, based on clinical appearance relative to the intensity

of inflammation, are broken down as follows:⁷

- **Stage I** includes an infiltrate in the periphery of the flap.
- **Stage II** is when the infiltrate involves the periphery and visual axis.
- **Stage III** is identified by a cluster of inflammatory cells in the central cornea.
- **Stage IV** is severe inflammation and the beginning of corneal melting, followed by corneal scarring, loss of visual acuity and irregular astigmatism (Figure 2).

Treatment

The goal of treatment is to remove the agent contributing to the corneal melt process. The cause can be multifactorial and will demand a variable approach.

One approach to treatment is observation only. If the corneal melt is not progressing or causing visual complications, the process may be self-limiting.¹ Obtaining accurate slit lamp photographs of the corneal melt will aid in deciding if progression is occurring. If the condition progresses or causes degradation in vision, surgical intervention may be necessary.

Epithelial ingrowth can be aggressive, so the need for treatment is immediate. Since it is more common following LASIK, these patients require careful observation. If the epithelial ingrowth involves 30% of the flap, or is associated with corneal melting proven by clinical or topographical examination, consider treatment.⁸

If a patient is having changes in vision or if topographical changes are noted, consider surgical intervention. The general procedure for removing epithelial ingrowth requires a surgeon to lift the flap and scrape the epithelial cells from the stromal bed and undersurface of the flap.^{2,9-11} At the conclusion of the procedure, a bandage contact lens is typically placed and the patient is started on topical antibiotics and steroids.

Other treatments, such as ethanol, mitomycin and phototherapeutic keratectomy, have been suggested for epithelial ingrowth, but adverse events are possible.^{2,8,10,12} These should all be considered secondary options, if the risk associated with scraping is too great.

DLK treatment in the early stages (I or II) involves a topical steroid to reduce the inflammatory event and decrease the likelihood of a corneal melt process. If a patient presents with advanced stage III or IV DLK, surgical intervention of lifting the LASIK flap, cleaning the interface, and treatment with both a topical corticosteroid and an antibiotic will be necessary.

Before treating post-LASIK patients who have autoimmune disorders, corneal dystrophies or dry eye syndrome—all conditions that can lead to a corneal melt or have led to a corneal melt episode—you must address the underlying condition first. This may involve consultation with the patient's rheumatologist in regards to more specifically targeted control of the patient's autoimmune disorder. In the case of dry eye syndrome and other corneal ocular surface diseases, treatment may include artificial tears, punctal plugs, topical cyclosporine drops, topical corticosteroid drops, autologous serum topical drops, meibomian gland

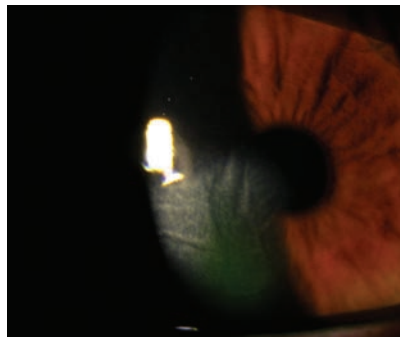


Fig. 2. Stage IV inflammation is the most severe DLK classification and shows the beginning of corneal melt.

dysfunction treatment or the use of amniotic membrane grafts.

Corneal melting following LASIK is a significant complication that requires prompt recognition. A detailed preoperative examination for refractive surgery patients is necessary to identify underlying systemic and ocular conditions that can predispose a patient to a corneal melt process. Patients who have undergone refractive surgery and have conditions that predispose them to corneal melting should have close follow up. Early identification and prompt treatment can

prevent permanent vision loss from this rare but serious refractive complication. ■

Dr. Schweitzer is a cornea, glaucoma, cataract and refractive surgery specialist at Vance Thompson Vision in Sioux Falls, SD.

1. Guell J, Gris O, Gaytan J, Marero F. Melting. In: Alió JL, Azar DT, eds. *Management of Complications in Refractive Surgery*. New York:Springer;2008.
2. Wang M, Maloney R. Epithelial ingrowth after laser in situ keratomileusis. *Am J Ophthalmol* 2000;129:746-51.
3. Dastgheib K, Clinch T, Manche E, et al. Sloughing of corneal epithelium and wound healing complications associated with laser in situ keratomileusis in patients with epithelial basement membrane dystrophy. *Am J Ophthalmol* 2000 Sep;130(3):297-303.
4. Seiler T, Wollensak J. Myopic photorefractivekeratectomy with the excimer laser. One-year follow-up. *Ophthalmology* 1991;98(8):1156-63.
5. Congdon N, Schein O, von Kullajta P, et al. Corneal complications associated with topical ophthalmic use of nonsteroidal anti-inflammatory drugs. *J Cataract Refract Surg* 2001;27(4):622-31.
6. Flach A. Corneal melts associated with topically applied non-steroidal anti-inflammatory drugs. *Trans Am Ophthalmol Soc*. 2001;99:205-12.
7. Linebarger E, Hardten D, Lindstrom R. Diffuse lamellar keratitis: diagnosis and management. *J Cataract Refract Surg*. 2000;26(7):1072-7.
8. Haw W, Manche E. Treatment of progressive or recurrent epithelial ingrowth with ethanol following laser in situ keratomileusis. *J Refract Surg*. 2001;17(1):63-8.
9. Walker M, Wilson S. Incidence and prevention of epithelial growth within the interface after laser in situ keratomileusis. *Cornea*. 2000 Mar;19(2):170-3.
10. Helena M, Meisler D, Wilson S. Epithelial growth within the lamellar interface after laser in situ keratomileusis (LASIK) *Cornea*. 1997 May;16(3):300-5.
11. Lahners W, Hardten D, Lindstrom R. Alcohol and mechanical scraping for epithelial in-growth following laser in situ keratomileusis. *J Refract Surg*. 2005 Mar-Apr;21(2):148-51.
12. Vroman D, Karp C. Complication from use of alcohol to treat epithelial ingrowth after laser-assisted in situ keratomileusis. *Arch Ophthalmol*. 2001 Sep;119(9):1378-9.

A Corneal Melt Case Report

A 28-year-old female presented to clinic urgently with a complaint of an irritated right eye for about three days. Her ocular history was significant for LASIK in both eyes in 2012, and a LASIK enhancement in the right eye in 2015. Her general medical history was unremarkable. Visual acuity uncorrected was 20/40 OD and pinhole visual acuity was 20/20 OD. Examination of the anterior segment identified a small amount of epithelial ingrowth superior to the nasal, along the flap edge, as well as an inferior temporal corneal melt along the flap edge with a small amount of epithelial ingrowth present.

Treatment options discussed with the patient included lifting the flap and removing the epithelial ingrowth or, a

more conservative approach, aggressive ocular surface treatment with close observation. Ultimately, an initial conservative approach was decided on and a treatment of topical corticosteroid, topical cyclosporine, punctal plugs and preservative artificial tears was initiated.

The patient was monitored on a weekly basis for six weeks. No changes of the epithelial ingrowth or corneal melt were noted. Her vision improved from 20/40 OD uncorrected to 20/20 OD uncorrected after six weeks. The foreign body sensation resolved and the patient was tapered off the topical steroid.

Topical cyclosporine was continued and no changes of the cornea melt process or epithelial ingrowth has been noted in four months.



When Your Patient's Expecting

Pregnancy changes things—especially IOP. But when an expectant mom has glaucoma, how to do you proceed before and after baby? **Edited by Paul C. Ajamian, OD**

Q I just diagnosed early open angle glaucoma in a 34-year-old patient who is six months pregnant. What are my options on drops, and does anything change after she has the baby and begins nursing?

A With 6.3 million pregnancies reported in the U.S. each year, doctors face the prospect of tailoring therapy to both mother and baby during an especially vulnerable time, says Caroline Pate, OD, Associate Professor at University of Alabama School of Optometry.¹

Address potential concerns early and let patients know which ocular changes may be in store, she says. Among these changes: a natural reduction in IOP. “It’s rare to make a diagnosis of glaucoma during pregnancy, because of a natural decrease in intraocular pressure (IOP),” says Dr. Pate. She explains that the increased uveoscleral outflow pathway and decreased episcleral venous pressure, thought to be governed hormonally, typically results in a 19.6% IOP reduction in healthy patients and a 24.4% decrease in ocular hypertensives.² “We often set a target IOP 20% to 30% lower than baseline when initiating glaucoma treatment. Pregnant patients’ IOP may actually drop this amount without therapy!” This may persist several months postpartum.

Risk vs. Reward


Though a need for IOP reduction is rare in these patients, carefully consider the benefits and risks of drugs in the pregnant patient, she advises. The FDA’s risk categories,

though recently abandoned, can still help. “Medications in Category A or B are generally accepted safe to use during pregnancy, whereas Category C are prescribed only when the benefit justifies potential risks to the patient and baby,” says Dr. Pate. “Categories D and X are unsafe during pregnancy.”

Drugs approved after June 30, 2015, no longer use this classification system. “Doctors must now read the package inserts and analyze the safety data to make an informed decision,” she says. Drugs approved on or after June 30, 2001 will be phased-in, Dr. Pate explains.

Since no new topical agents have been approved since the new labeling system was initiated, “we can still refer to the more familiar pregnancy category labeling,” says Dr. Pate. Alphagan (brimonidine, Allergan) is the only available drop that falls into the Category B, she explains. “Generally considered safe during pregnancy, avoid Alphagan during lactation since it’s been linked to CNS depression and sleep apnea in breastfeeding infants.”^{3,4}

Oral prostaglandins are sometimes used to induce labor.⁵ Though it’s not proven that ocular topical prostaglandins result in a similar effect, it is probably wise to avoid them, she notes. Topical β -blockers should be also be avoided, due to the risk of fetal cardiac arrhythmias.⁶ Oral carbonic anhydrase inhibitors given during pregnancy have been linked to congenital malformations, so it’s best to avoid the topical counterparts as well, Dr. Pate explains.⁷



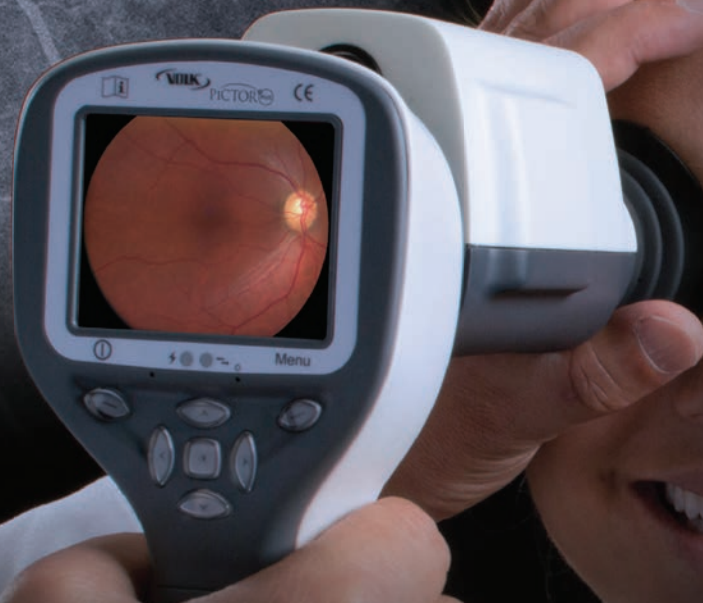New FDA labeling is more sensitive to risk profiles but puts the onus on ODs.

What is considered safe during pregnancy may not be safe during lactation and vice-versa, says Dr. Pate, and she recommends a free, peer-reviewed online database of from the US National Library of Medicine. “The LactMed database includes helpful information such as levels of a particular drug in breast milk, infant levels in blood, potential effects in breastfeeding infants and on lactation itself. Useful apps also exist for ease of use.”⁸

Though topical IOP-lowering drugs generally pose little risk to the fetus, one must still consider the risks and benefits when prescribing, says Dr. Pate. “Treating these glaucoma patients can be challenging. If in doubt, consult the patient’s OB/gyn or PCP prior to treatment.” ■

1. CDC. Pregnancy Rates for U.S. Women Continue to Drop. CDC Website. www.cdc.gov/nchs/data/databriefs/db136.htm. Accessed 9/15/16.
 2. Omoti AE, Waziri-Erameh JM, Okeigbemen VW. A review of the changes in the ophthalmic and visual system during pregnancy. Afr J Reprod Health. 2008 Dec;12(3):185-96.
 3. Trad MJ. Some ophthalmic drugs not safe for use in lactating or pregnant women. Heliö. Primary Care Optometry News. 2008 September.
 4. Autry J. Pregnancy precautions: how to prescribe safely for new and expectant mothers. Review of Optometry. 2016 Jan;153(1):28-33.
 5. O'Brien WF. The role of prostaglandins in labor and delivery. Clin Perinatol. 1995 Dec;22(4):973-84.
 6. Wagenvoort AM, van Vugt JM, Sobotka M, van Geijn HP. Topical timolol therapy in pregnancy: is it safe for the foetus? Teratol. 1998;58:258-62.
 7. Al-Saleem AL, Al-Jobair AM. Possible association between acetazolamide administration during pregnancy and multiple congenital malformations. Drug Des Devel Ther. 2016 Apr 15;10:1471-6.
 8. National Institutes of Health. LactMed Database. NIH. toxnet.nlm.nih.gov/newtoxnet/lactmed. Accessed 9/15/2016.

[Making Portable **Possible**]




VOLK[®]
IMAGING

PICTOR⁺ PLUS
Retina | FA | Anterior

Portable Technology Expands Your Practice

Pictor Plus allows you to easily image limited mobility patients in or out of the exam room.

FREE 2-Week Trial Offer
volk.com/pictorplus



Eye on the Ball

When an athlete presents with significant refractive error, how do we bring his vision up to par? **By Marc B. Taub, OD, MS, and Paul Harris, OD**

We consider the challenge of providing excellent vision care to be vital for all of our patients. But in athletes, the stakes are especially high: their performance in the chair often correlates directly with their performance on the field. And in dangerous contact sports, sharp vision can keep them free of injury or incident. Sports vision cases are illuminating in helping us understand the unique challenges athletes face and teach us valuable lessons applicable to everyone.

This installment of Focus on Refraction draws from our recent experiences in sports vision at Southern College of Optometry (SCO), which now provides comprehensive sports vision care for athletes attending the University of Memphis (UM).

We recently screened the first one-third of the student athletes—147 athletes—and identified roughly one-third of these 147 to be in need of comprehensive sports vision evaluations. Vision correction and vision therapy was then provided, if determined necessary.

One athlete, J.D., noted on the screening questionnaire that he has a refractive prescription but hasn't worn glasses or contacts for more than one year. In response to the question, "Do you ever feel yourself making visual errors?" he responded, "Yes, when finding the football." J.D. plays an inside posi-



Defensive and offensive linemen in battle.

tion on the football team's defensive line and has two more years of time left in his college career.

J.D.'s unaided visual acuities were 20/22 OD and 20/40 OS. He saw nothing on the Random Dot 3 stereo test and had some intermittent suppression Brock String. When he did see the two strings, they met closer to him when he looked at the bead furthest away from him, but they met further away from him on the near and intermediate beads. Based on the results of this screening, J.D. was brought into SCO's University Eye Care center where the UM athletic vision program (AVP) is being conducted.

Player's Stats

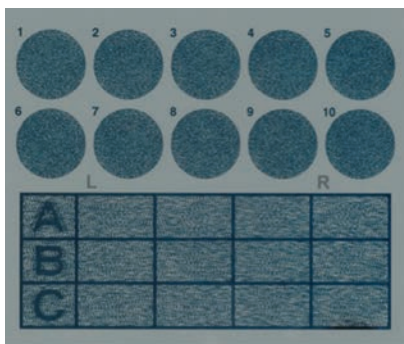

During our 90-minute AVP evaluation, we took a thorough history. We found that J.D., an interdisciplinary studies major with an emphasis in health, holds a GPA in the high twos. During the evaluation, he noted that he reads slowly

and he has to reread many things to come away with full comprehension. When asked about the strongest aspect of his play on the field, he said it was getting to the quarterback. He denied having suffered from TBI but stated that, on at least four separate occasions, he wondered if he had sustained injury following hard hits on the field.

He denied seeing double. He did not have his glasses with him; he hadn't worn them for more than a year. He never wore contact lenses. His last comprehensive visual evaluation occurred in 2013 in his home state, prior to college.

We performed our refractive workup on J.D. (Table 1). His visual acuities were found to be nearly identical to what was found at the visual screening: 20/21 OD and 20/39 OS. At near, he showed 20/20 in all conditions, but he held the target much closer than normal working distance—nine inches. His cover test varied at times, which showed near-ortho and moderate to high exophoria. His near point of convergence showed an eight-inch break and a 14-inch recover; his left eye went out objectively, though he never reported seeing double.

After a battery of tests, the most significant finding was this patient's performance with the Readalyzer (Compevo), an infrared eye movement recording device. We had to drop to an eighth grade level reading card in order for J.D. to score the minimum 70% on the comprehen-



Large shapes are graded from 600 to 400 seconds of arc. These 10 circles on the top grade down to 12.5 seconds of arc. The three lower rows have Lea symbols with intermediate stereo values.

sion test. In fact, he performed much higher—90%—on the eighth grade scorecard.

His reading speed was 140 words per minute—one-half the speed expected for an adult-level reader. He stopped 123 times to read 100 words, 37% more than expected—a fifth grade level. He showed only six regressions (going backward within a line of text to reread it), which is actually better than what we expect for an adult-level reader. His average duration of fixation was 0.34 seconds, the expected value for a first grader. This usually signals that the person discusses the story and data (to themselves) during the reading to help them remember.

The Game Plan

Herein lies the primary dilemma:

Table 1. Refractive Workup

Distance retinoscopy:

OD +0.50 -1.75 x 180

OS +3.25 -2.00 x 175

Binocular balance (most plus to the first good 20/20 done binocularly):

OD +0.50 -1.00 x 180

OS +2.75 -2.50 x 180 20/20 OU

Second refractive endpoint**—i.e., the lens through which he saw the 20/20 letters to be perceptually the largest:

OD plano -1.00 x 180 20/14

OS +2.25 -2.50 x 180 20/19 VA OU 20/14

Following this, we did the rest of our binocular testing. The key findings included:

Distance base out: x / 18 / 2

Distance base in: x / 12 / 4

Near base out: x / ?? (he never reported it doubling)

Near base in: x / 30 / 12

PRA: -0.50

NRA: +1.50

Stress point retinoscopy: +1.50

What do we prescribe? We had a conundrum, and a thorny one at that. The patient shows very poor binocularity. We cannot correlate the cause and effect because this patient was new and we did not have access to his previous exam data. Thus, whether or not the poor binocularity led to his suppression and blurring of the left eye's input or vice versa did not weigh into what was prescribed.

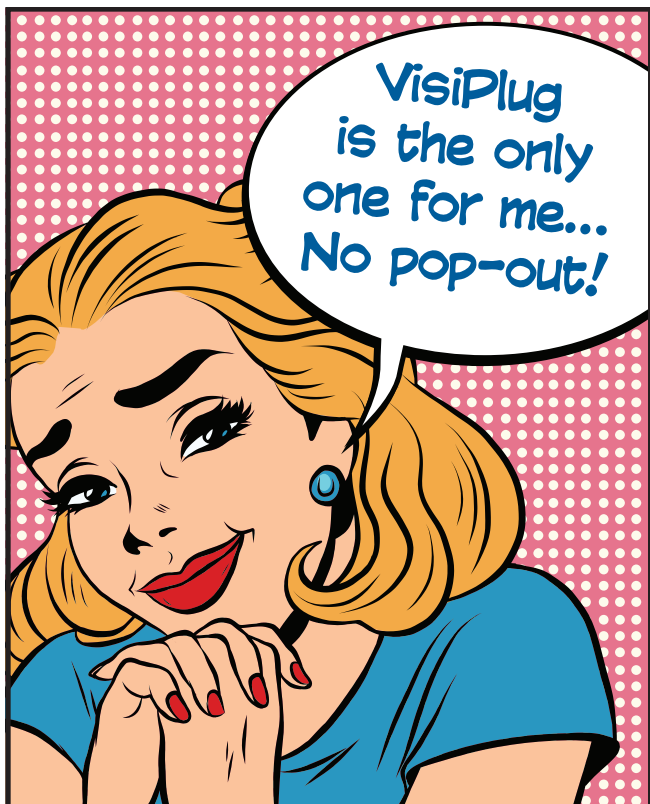We do know from experience, however, that if all of a sudden he gets two clean streams of data, he doesn't have the software to use them seamlessly. And that's not taking into account the spatial changes one gets with cylinders like that.

Fortunately, we were at least three months from the football season, and the patient is in his junior year. A third member of our sports vision team, Christina Newman, OD, will fit him with contact lenses for maximum visual acuity as we simultaneously commence a vision therapy program.

The contact lenses alone will not address J.D.'s severe binocular dysfunction, which manifests as dual convergence and accommodative insufficiencies. We initiated an intensive vision therapy program, to help J.D. learn to balance use of his two eyes together and to make quick spatial adjustments on the field and in the classroom.

We considered whether or not it would suffice to prescribe one contact lens on his left eye. However, we felt the jump from 20/21 unaided to 20/14 with the cylinder in place would be quite significant in high-level, division I NCAA sports, so we elected to fit contacts for both eyes.

Lastly, we considered whether to prescribe glasses at all or opt only for contact lenses. Of course, we recognize that all patients who wear contact lenses will face circumstances when they should not wear their contacts, in which case their glasses become an emergency backup. At this point in his care, the spatial distortions caused by glasses



Lacrimedics' VisiPlug is not like the "other" punctum plugs. We have *no* reported "pop-outs" since VisiPlug's introduction in 2003... and it's distributed in over forty countries!

Don't let your patients become a victim of PPP (Punctum Plug Pop-out) Syndrome *in addition* to their Dry Eye Disease.

**VisiPlug® –
a visibly better plug
to treat dry eye!**

RECEIVE 15% OFF YOUR ORDER!¹
Mention Promo Code PPP2016



Lacrimedics

(800) 367-8327

E-mail: info@lacrimedics.com
www.lacrimedics.com

¹Dramatization. Not a real patient. ²Valid through 12/31/16. Restrictions apply.
UPS Ground shipments in U.S. only. \$50 minimum order.

©2016 Lacrimedics, Inc.

Focus on Refraction



Performing the Random Dot 3 (left) and Brock string tests (right).

could amplify the binocular issues too much to be practical for J.D.

4th and Goal

This clinical experience tells us two important things. First, when working with athletes it is important to instill confidence that we can and will help them from the get-go. In this light, prescribing glasses that would amplify J.D.'s problems was not conducive to a good working relationship. Second, this case tells us that once the binocular problems have been addressed sufficiently, glasses can be prescribed, which will be adapted to rather easily.

Note: The visual acuities reported here have finer gradations than are part of normal charts. We use the M&S Technologies Smart System with a program that allows for continuously variable-sized Sloan letters; the user employs a step program to find thresholds which are quite accurate and repeatable. ■

***For more on refractive targets, see our prior column "The Endpoint Endgame," December 2015, p. 28.*



The ReadAlyzer saccadic test being used on a student athlete.



SCO students screening athletes from a local college.



STOP BY AT ACADEMY 2016 ANAHEIM

AKORN BOOTH

#207

Introducing Our New RxDirect Service

Patients save significantly on their prescription and have it delivered directly to their door at no extra charge



100% PRESERVATIVE-FREE


ZIOPTAN[®]
(tafluprost ophthalmic
solution) 0.0015%


Cosopt[®] PF
(dorzolamide HCl - timolol maleate
ophthalmic solution) 2% / 0.5%

Cosopt is a registered trademark of Merck Sharp & Dohme Corp and is used under license. ZIOPTAN is a registered trademark of Merck Sharp & Dohme Corp and is used under license.

Santen ZIOPTAN is licensed by Santen Pharmaceutical Co., Ltd.

 **AKORN**

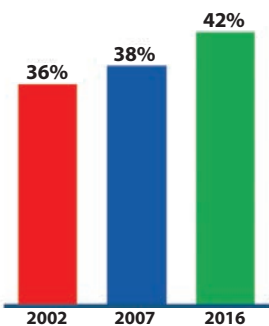
©2016 Akorn, Inc. All rights reserved. P667 REV 09/16

Natural Eye Care and You, a patient education magazine focusing on natural eye care products and solutions, appears here. Please remove and place in your waiting room. If your copy has already been removed, call 877-220-9710 to receive your copy or to order more.



FIND YOUR COPY FACING THIS PAGE

42% of Your Patients Want Natural Medicines*



NATURAL MEDICINE USE

*According to the National Health Interview Survey

Natural products—from foods to health and beauty aids to medicines—are of heightened interest to Americans in all walks of life. If you'd like to discuss incorporating natural eye care products in your practice, contact Linda Axelrod at Natural Ophthalmics at 877-220-9710 or info@natoph.com.

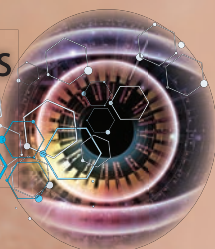
Brought to you by



www.NaturalEyeDrops.com

Up to
16-20 CE
Credits*

NEW TECHNOLOGIES
& TREATMENTS IN
2017 EYE CARE



REVIEW OF OPTOMETRY
EDUCATIONAL MEETINGS OF CLINICAL EXCELLENCE

2017 MEETINGS



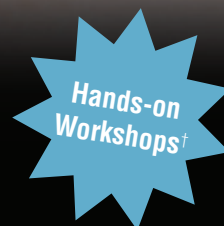Aspen, CO
February 17-21, 2017

Program Chairs:
Murray Fingeret, OD & Leo P. Semes, OD



Charleston, SC
March 24-26, 2017

Program Chair:
Paul Karpecki, OD



San Diego, CA
April 20-23, 2017

Program Chair: Paul Karpecki, OD



Orlando, FL
June 8-11, 2017

Program Chair: Paul Karpecki, OD



Philadelphia, PA
November 3-5, 2017

Program Chair: Paul Karpecki, OD

**CHECK OUR WEBSITE
FOR THE LATEST INFORMATION**

Online: www.reviewofoptometry.com/events

E-mail: reviewmeetings@jobson.com

Call: 866-658-1772

†Workshops not available for "Aspen, CO" meeting. See Review website for any meeting schedule changes or updates. Stock Images: ©iStock.com/JobsonHealthcare

Administered by

Review of Optometry®



*Approval pending



Feeling The Pressure

Understand the when and why of diagnostic testing in glaucoma.

By John Rumpakis, OD, MBA, Clinical Coding Editor

Nothing can ruin a day faster than being notified you have been referred to an insurance carrier's Special Investigations Unit because of over-use of special ophthalmic tests. This is particularly prevalent in glaucoma testing. Understanding a few key rules will help protect yourself, your patient and your practice.

Rule #1 – Medical Necessity Rules The Day

When ordering any special ophthalmic test you will submit to a third party for payment, clearly establish why you ordered the test and why it's necessary in this patient's case. Each test you order and perform must individually meet the requirement for medical necessity, which is based upon a clinical finding discovered during the patient exam. Your medical record must contain a written statement of this necessity.

Rule #2 – Individual I/R

Each ophthalmic test you perform requires its own interpretation and report (I/R) to be considered complete or billable. Each test and I/R must stand on its own, and be reflected in the medical record. An I/R should contain:

- Clinical findings: pertinent findings regarding the test results
- Reliability of the test
- Comparative data: comparison to previous results, if applicable
- Clinical management: how the results will affect management of the condition/disease, i.e.:
 - Change, increase or stop

medication

- Recommendation for surgery
- Recommendation for further diagnostic testing
- Referral to a specialist for additional treatment

Rule #3 – Choose Tests Wisely

You should not apply a standard battery of tests on every glaucoma suspect patient. Choose your tests based upon their individual validity in that specific case, since you must demonstrate necessity for each test that you order and perform.

Rule #4 – Understand Your Provider Contracts

When you became a participating provider with a third party carrier, you received a document typically called a provider agreement—essentially a contract defining the parameters of what you can and cannot do with a patient with respect to covered services under that carrier's plans. Policies and requirements are contained within this document or are tied to other references used by the carrier. Keep yourself up to date with current contract requirements, as they change frequently.

Rule #5 – Don't Fudge A Diagnosis To Get Coverage

The number of times I am contacted by doctors asking what diagnosis to use to get a particular test paid for would amaze you. The ICD-10 is quite unforgiving—it is specific enough you can accurately report the diagnosis to the carrier, and it should support the necessity for the

specific test in question. Take the time to learn the ICD rules—they are not just codes to get reimbursed.

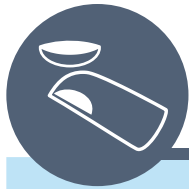Rule #6 – Love Your Sales Reps, Know Your Carrier Rules

Often, equipment manufacturers feel a test should be reimbursable for a specific disease state. They will have literature and studies that look impressive clinically, yet a carrier may not have a policy or reimburse you for the test. Manufacturers can make a clinical case to the carrier's medical directors and demonstrate their technology's efficacy in the diagnosis of disease, but they don't always do this. It's important to know your carriers' specific policies.

Overtesting is a big concern today and is contributing to carriers' rising costs.¹ The CMS comparative billing reports highlight how carriers are looking at the frequency of testing and the combination of tests used on individual patients and in the aggregate within your practice. Outcome-based care rewards those who demonstrate the best outcomes in the most efficient manner. If you were paid a fixed fee per year for a patient with a specific diagnosis, would you still test to the same level, even without compensation for each test? The answer is important today, and will be for years to come. ■

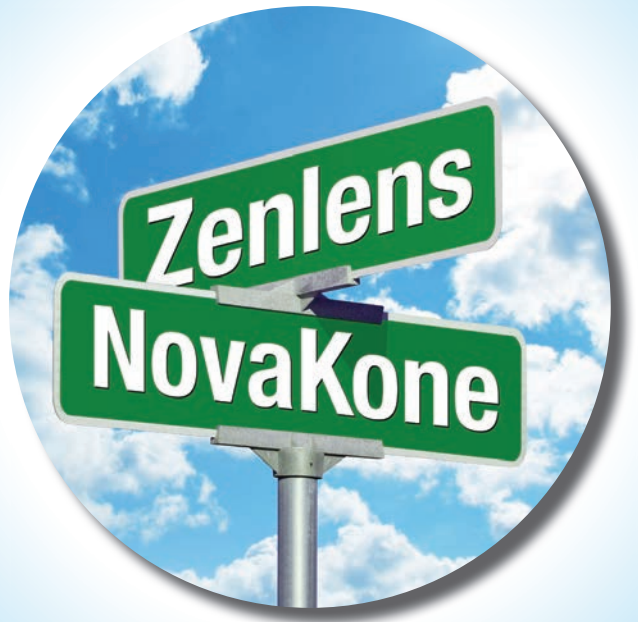Send questions and comments to ROcodingconnection@gmail.com.

1. Weaver C, Jones C. Big driver of medicare spending: doctors doing more tests in their offices. The Wall Street Journal. August 9, 2016. Available at www.wsj.com/articles/big-driver-of-medicare-spending-doctors-doing-more-tests-in-their-offices-1470762389. Accessed September 8, 2016.



Customized Lenses

**When fitting
irregular
corneas, you
have finally
reached your
destination.**



Zenlens™ Scleral Lens

- Lens diameters of 16.0mm and 17.0mm enable you to fit a wide range of corneas
- SmartCurve™ technology allows you to change the parameters you want, not the ones you don't
- Comprehensive 28-lens diagnostic set
- Expertise from FCLSA* consultants with decades of in-office fitting experience

NovaKone® Soft Lens

- Dual Elliptical Stabilization™ and cylinder powers to -10.00D, to help address residual astigmatism in patients with keratoconus
- Variable lens center thickness to help neutralize irregular astigmatism

* Fellow of Contact Lens Society of America

**Your “go to” scleral lens and soft lens
options can now be found in one place.**

Learn more about Zenlens™ and NovaKone®
by calling or visiting:



800 253-3669

www.bausch.com/svp

BAUSCH + LOMB

Specialty
VISION PRODUCTS



Your dreams came true.

The perfect OCT for your practice is here.

MEET THE MAESTRO.

With its space-saving design, fully automated operation, built-in non-mydratic fundus camera, 50K A Scans/sec, and wide 12x9mm scan that captures the optic nerve and macula in one scan—the MAESTRO is everything you've been wishing for and then some. No wonder it's one of the best selling SD OCTs in the world.

Simple, precise and surprisingly affordable. Learn more at newsgram.topconmedical.com/maestro.



ACADEMY OF OPTOMETRY BOOTH 733

 **TOPCON**

Angle-closure Glaucoma: Are You Ready?

Diagnosing and managing these challenging cases is inevitable. Be prepared with these clinical pearls. **By Michael Cymbor, OD**

On a fine, spring Sunday evening about 17 years ago, I was on call at our eye care group and on the phone with the daughter of an 82-year-old who had complained of eye pain early that morning. The daughter said her mother's eye was red, vision seemed cloudy and she felt nauseous and had a headache. I remember giving her a directive: "Look at your mom's pupils and see if they look different." She returned and said, "Yes, the eye that's red has a larger pupil." Individually, each symptom could take the clinician down many paths. Taken together, an acute angle closure must be strongly considered. I told her to meet me at the office in 15 minutes.

Fortunately, with a prompt diagnosis we were able to break that patient's angle-closure attack and get her in for a laser peripheral iridotomy (PI) quickly.

Because most optometrists will see an angle-closure attack similar to this at some point, an understanding of the current thinking in the management of narrow-angle and angle-closure glaucoma and how optometrists are poised to stabilize and manage these patients is vital.




Fig. 1. The ciliary body (CB) is the most posterior structure visible, followed by the scleral spur (SS), posterior trabecular meshwork (PTM), anterior trabecular meshwork (ATM) and, finally, Schwalbe's line (SL).

Angle-closure Up Close

Angle-closure glaucoma (ACG) affects 20 million people worldwide, and about four million are bilaterally blind.¹ Reports suggest the total number of people between the ages of 40 and 80 affected by angle-closure glaucoma will increase to 23 million by 2020 and 32 million by 2040.² ACG causes nearly half of all glaucoma blindness worldwide.³

Even though there are three times more people worldwide with primary open-angle glaucoma (POAG) than ACG, angle-closure's increased morbidity causes blindness in about the same number.⁴

Patients undergoing an acute symptomatic angle-closure attack present with symptoms of ocular or periocular pain, reduced vision with halos, eye redness and nausea

or vomiting. Ocular signs include elevated intraocular pressure (IOP), corneal edema, mid-dilated pupil, shallow anterior chamber and conjunctival injection with ciliary flush.³

There are three currently accepted categories for angle-closure disease: primary angle-closure suspect, primary angle-closure and angle-closure glaucoma.⁵⁻⁷ An ACG suspect has an angle where the trabecular meshwork cannot be seen for half or more of the angle gonioscopically, indicating at least 180 degrees of iridotrabecular contact. These patients will not have peripheral anterior synechiae, which are the result of long-term iridotrabecular contact.⁸ A primary angle-closure patient will have a closed angle with a rise in IOP, possibly with peripheral anterior synechiae. Patients with ACG will have a closed angle, peripheral anterior synechiae and evidence of glaucomatous damage in either the disc or field. The glaucomatous damage of the nerve in patients with ACG is similar in nature to glaucomatous damage in patients from POAG, while the field defect may be more diffuse in ACG.⁹

Demographic risk factors include female gender, advanced age and Asian ancestry.¹⁰⁻¹² Ocular risk factors include narrow angles, shallower axial and limbal anterior chamber depth, thicker lens, shorter axial length, more anteriorly positioned lens, smaller corneal diameter and hyperopic refraction.³ Population-based studies suggest a genetic component, but the exact genetic pattern remains elusive.¹³

Anatomy

Although an underused procedure, gonioscopy remains the standard for viewing the angle and making the diagnosis of angle-closure. One study found that less than half of all eye care providers performed goni-

scopy on their glaucoma patients.¹⁴ Understanding the anatomy is crucial to help identify variances associated with ACG (*Figure 1*).

In an open angle, the most posterior structure visible is the ciliary body (CB), which is found between the iris root and the scleral spur. It can vary from light gray to brown and may reduce complete visualization. The second most posterior structure, the scleral spur, is found in the posterior margin of the scleral sulcus, between the CB and the trabecular meshwork (TM). It is made up of collagen tissue, serves as the anchor for the ciliary muscle and can vary in color from white to gray. The TM is next, found between the scleral spur and Schwalbe's line. It can be subdivided into anterior and posterior TM. It is typically light gray in younger patients and becomes more pigmented over time. The anterior third of the TM is non-functional, while the posterior two-thirds filters aqueous into Schlemm's canal. Schwalbe's line is the most anterior angle structure and represents the end of a clear cornea.

There are three main classification systems—Scheie, Shaffer and Spaeth (*Tables 1-3*) for ACG—each with its own strengths and weaknesses.¹⁵⁻¹⁷ In general, using these grading systems may complicate comanagement between clinicians, as a grade 1 can mean two vastly different angle configurations. A good rule is always to describe the last structure seen.

Mechanisms

Angle-closure refers to the appositional closure of the anterior chamber angle, resulting in aqueous obstruction. The most common underlying mechanism of primary angle-closure is pupillary block, in which the aqueous forces the pupil forward.¹⁸ The term *primary* means there is no detectable cause. Ninety

percent of all US patients presenting with angle-closure have pupillary block.⁶ Pupillary block occurs when the pressure of the posterior chamber exceeds the pressure of the anterior chamber, pushing the peripheral and midperipheral iris forward and blocking the TM. The second mechanism of primary angle-closure is plateau iris, which occurs when the CB is anterior or rotated forward, displacing the peripheral iris into the TM.⁶

Secondary angle-closure occurs by a known pathology. An example of a secondary angle-closure is phacomorphic glaucoma, which occurs when the lens pushes the iris forward and closes the angle.¹⁹ This may also occur in subluxation. Uveitis may cause a secondary pupil block, which is characterized by iris bombe and posterior synechiae. Other secondary causes include neovascularization, malignant glaucoma, retinopathy of prematurity, posterior scleritis, acquired immunodeficiency syndrome, Vogt-Koyanagi-Harada syndrome, leukemia, orbital or carotid cavernous fistula and neuropathia epidemica.²⁰

Clinicians should also be aware of masqueraders such as: glaucomatocyclitic crisis, steroid-induced glaucoma, phacolytic glaucoma, ghost cell glaucoma, hemolytic glaucoma, hemorrhagic glaucoma and exfoliation glaucoma.²⁰

Pharmacologic Causes

Numerous prescription and OTC medications may induce angle narrowing or angle closure. Such medications may cause up to 33% of all angle-closure attacks.²¹ Some of these drugs, including cholinergics such as Salagen (pilocarpine HCl, Pfizer) and Evoxac (cevimeline hydrochloride, Daiichi Sankyo), move the lens-iris diaphragm forward. Iris dilation may occur from

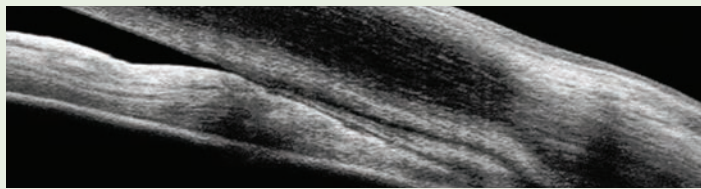


Fig. 2. The patient's initial angle OCT shows angle closure.

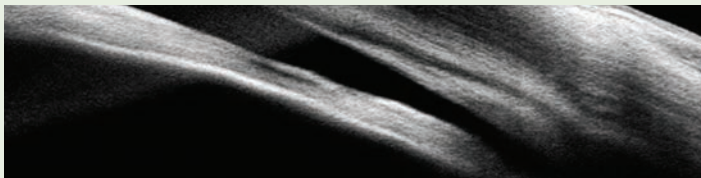


Fig. 3. After topical treatment, the patient's repeat angle OCT still shows an unacceptably narrow angle.

We instilled one drop of lolidine (0.5% apraclonidine hydrochloride, Alcon), followed a few minutes later by one drop of Cosopt (dorzolamide HCL/0.5% timolol maleate ophthalmic solution, Merck). This was repeated 20 minutes later. We also gave the patient 500mg acetazolamide PO. Approximately one and a half hours after diagnosis, the patient's IOP was 47mm Hg. Lacking isosorbide, we performed compression gonioscopy, which lowered IOP to 34mm Hg.

A repeat OCT angle was still quite narrow, but open (*Figure 3*). We scheduled the patient for immediate laser PI OS with subsequent cataract surgery a few days later. Her pressure is now stable in the 15mm Hg to 17mm Hg range OS.

antidepressants such as Paxil (paroxetine, GlaxoSmithKline) and Prozac (fluoxetine, Eli Lilly), incontinence medications such as Ditropan (oxybutynin, Janssen), Detrol (tolterodine tartrate, Pfizer) and Sanctura (trospium chloride, Allergan), and antihistamines such as Tagamet (cimetidine, Prestige), Zantac (ranitidine HCl, Boehringer Ingelheim) and Benadryl (diphenhydramine, Johnson & Johnson). There are safer non-sedating H1 blocking antihistamines such as loratadine, cetirizine and fexofenadine that are less likely to cause ACG.²²

Another potential inducer of secondary angle-closure is Topamax (topiramate, Janssen). Topamax is indicated for the treatment of epilepsy and migraines; it is also used off-label to treat post-traumatic stress disorder and alcohol addiction. It can cause swelling of the ciliary body and lens, anterior rotation of the lens-iris diaphragm and bilateral angle closure, as well as uveitis and sudden myopia shift.²³

Up to 89% of Topamax-induced angle closures occur in women.²⁴ Management of a Topamax angle-closure consists of immediately discontinuing the medication, as well as initiating medical IOP reduction, cycloplegics, topical and intravenous steroids and intravenous Osmitrol (mannitol, Baxter Healthcare Corporation). Usually it resolves in one week with this treatment.²⁵ Unlike in primary angle-closure, laser PI is ineffective, as Topamax angle-closure does not involve pupillary block.

When an astute primary care provider calls to discuss putting a mutual patient with glaucoma on one of these medications, bring the patient in for gonioscopy and OCT angle imaging prior to the initiation of the new medication. Educate the patient on the signs and symptoms of angle-closure glaucoma and repeat testing three to four weeks after initiating the medication to ensure it has not induced angle-closure glaucoma.

Case 1

A 55-year-old white female presented with intense pain in the left eye. She reported it began the previous night shortly before bed and has progressed since. She now reports the pain as 11 on a scale of one to 10. Her ocular history is significant for an optic nerve coloboma in the left eye.

Visual acuity was 20/20 OD and light perception (LP) OS because of the coloboma. She reported seasonal allergies controlled with Claritin (loratadine, Bayer). Goldmann tonometry was 20mm Hg OD and 56mm Hg OS. Biomicroscopy OS revealed corneal edema, grade 1 cells in anterior chamber, grade 1 Van Herick and a dense, grade 4 nuclear sclerotic cataract. Gonioscopy revealed a closed angle with no view of TM and no peripheral anterior synechiae. Anterior segment angle OCT confirmed angle closure (*Figure 2*). We diagnosed her with phacomorphic acute angle closure.

Diagnostic Tools

While gonioscopy remains the standard for diagnosing angle-closure, angle OCT and ultrasound biomicroscopy (UBM) are playing an increasingly important role. Both of those technologies can give an objective assessment of the angle width.²² Angle OCT is non-contact, is more tolerable to the patient and provides better resolution. UBM can image the CB more clearly because of deeper sound wave penetration. In the same way that posterior segment OCT imaging may not be optimal for visualizing characteristics such as small drance-type optic nerve hemorrhages, angle OCT and UBM may not be adequate for distinguishing between peripheral anterior synechiae and iridotrabecular contact. While these imaging technologies may eventually become a replacement for gonioscopy, currently they are more of an adjunct.

Treatment

The first goal in the management of

ACG is IOP reduction. The second goal is reversing the mechanism of angle closure.

Topical

Often used as initial treatment, eye drops that can quickly reduce IOP include beta blockers, alpha agonists, carbonic anhydrase inhibitors and pilocarpine.²⁶ Beta blockers, alpha agonists and carbonic anhydrase inhibitors all quickly reduce aqueous production, making them ideal to use when rapid IOP reduction is desired. Pilocarpine constricts the pupil, which is helpful for subsequent laser PI. Even though pilocarpine increases the angle width in patients with narrow angles, it may actually narrow the angle in eyes with phacomorphic glaucoma, pseudoexfoliation and vitreous block glaucoma.²⁷⁻²⁹ Prostaglandins may not be as effective because of delayed onset and may increase anterior chamber inflammation.

Oral or intravenous acetazolamide or hyperosmotics can also help relieve elevated IOP. Because quick reduction is warranted, acetazolamide sequels are less effective, as they reduce pressure slowly.

Topical steroids are helpful to relieve inflammation, and topical osmotic agents such as glycerin can reduce corneal edema and clear the cornea quickly if corneal edema is present and the anterior chamber and iris structures are difficult to clinically visualize.

Optometrists should be aware of medication contraindications, including: asthma and COPD for beta blockers; severe cardiac and cerebrovascular disease for alpha agonists; and kidney disease or sulfa allergies for carbonic anhydrase inhibitors. Clinicians must always weigh the treatment risks with the risks of nontreatment with conditions such as ACG that can rapidly

cause irreversible blindness.

If medical management is unsuccessful in returning IOP to a safe level, clinicians should consider indentation or compression gonioscopy.³⁰ When performing indentation gonioscopy, use a small footprint gonio lens and apply a significant amount of pressure. The force transferred to the angle may move the peripheral iris away from the TM, suddenly reducing IOP. This will also help determine the extent of peripheral anterior synechiae. Angles with higher amounts of peripheral anterior synechiae are more likely

to fail IOP reduction attempts with medical treatment and laser PI because of the iris mechanically adhering and blocking the trabecular meshwork.³¹ Paracentesis may help to quickly reduce IOP and pain, but clinicians must use caution, as the anterior chamber will be shallow. Paracentesis is effective in primary angle-closure but may not be as successful in secondary angle-closure.³²

Surgical

Laser PI is the mainstay of angle-closure treatment. Creating an alternate outflow pathway allows the aqueous

Table 1. Scheie Classification System¹⁵

Grade	Description
Wide Open	All structures visible
Grade I	Iris root visible, difficult to see into recess
Grade II	Narrow ciliary band
Grade III	Only anterior trabeculum visible, posterior trabeculum obscured
Grade IV	Only Schwalbe's line visible = closed angle

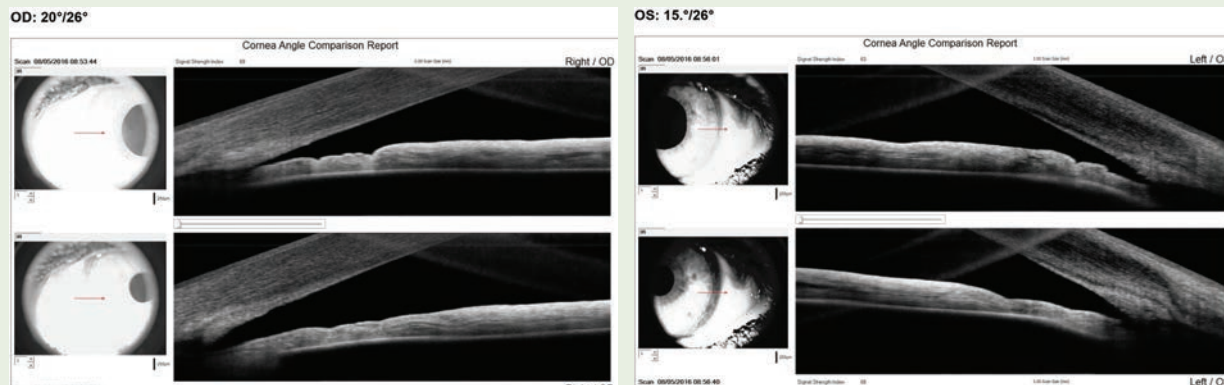
Table 2. Shaffer Classification System¹⁶

Grade	Angle Width	Description	Risk of Closure
4	45-35	Wide open	Impossible
3	35-20	Wide open	Impossible
2	20	Narrow	Possible
1	≥10	Extremely narrow	Probable
Slit	Slit	Narrowed to slit	Probable

Table 3. Spaeth Classification System¹⁷

Level of iris insertion	A: Anterior: iris inserts anterior to SL B: Behind Schwalbe's line: anterior to posterior limit of the TM, or between SL and SS C: Sclera: posterior to SS. SS is visible D: Deep: deep into the CB E: Extremely deep: very deep into the CB
Angular width	Estimated angle in degrees
Iris configuration	B: (steep) bowing anteriorly, graded on a 1-4+ scale P: plateau configuration F: flat configuration C: concave, posterior bowing
Pigment grading	Pigment in PTM at 12 o'clock position graded on a 0-4+ scale

Case 2



Figs. 4 and 5. Angle OCT shows a 20 degree angle OD and a 15 degree OS.

We examined a 47-year-old female with presbyopia who wears contact lenses on occasion. She reported that her mother is being followed for narrow angles. During the course of our evaluation, we graded her angle via Van Herick as grade 2. Her intraocular pressures were 21 mm Hg OD and 22 mm Hg OS. Her post-dilation IOPs were 22 mm Hg and 23 mm Hg. Her visual fields were unremarkable, and her optic nerves had a c/d ratio of 0.2/0.2 OD and OS. Her neuroretinal rims were pink and well-perfused. The angle OCT taken under scotopic conditions shows an angle graded at 20 degrees OD and 15 degrees OS (Figures 4 and 5). We performed gonioscopy and were able to see anterior ciliary body OU (Figure 6).

It was a bit surprising that gonioscopy showed the angle more open than expected, considering the narrow OCT angle. Because of the discrepancy, we repeated the OCT, but this time under photopic conditions. The OCT angle was significantly wider at 26 degrees. This underscores the importance of reducing illumination during gonioscopy to avoid artificially causing pupil constriction. We educated her on the signs and symptoms of angle closure, and she understands the need to contact us immediately if she notices any of them. We have decided against a laser PI and are monitoring her angles every six months.



Fig. 6. Gonioscopy helped clarify a surprising OCT result.

to bypass the pupil, thus eliminating the pressure differential between the anterior and posterior chambers. The iris will then return from a convex configuration in the midperipheral and peripheral area to neutral, thus opening the angle.³³ While laser PI is often successful at reducing IOP and successfully treating angle-closure glaucoma, subsequent treatment with eye drops, surgery or both is often necessary.³⁴ Clinicians should also perform a laser PI on the fellow eye, as roughly half will have an angle-closure event within five years if left untreated.^{35,36} The patient should be evaluated at least one day, one week and one month after a PI procedure for angle-closure.

Many clinicians recommend cata-

ract surgery within a few weeks of a patient successfully treated for an acute angle-closure for two reasons. First, cataract surgery opens the angle more than a laser PI.³⁷ Second, the patient typically requires fewer pressure-lowering medications after cataract surgery.³⁸ In fact, several studies indicate clinicians should be recommending cataract surgery in lieu of laser peripheral iridotomy.³⁹⁻⁴¹ Cataract surgery may be helpful at each and every stage of angle-closure treatment. Though controversial, some are advocating refractive lens exchange in angle-closure patients with clear lenses.⁴² The EAGLE study (Effectiveness in Angle-closure Glaucoma of Lens Extraction) may soon give additional insight to this

alternate treatment option.⁴³

If patients are unresponsive to medical therapy or laser PI, or if the cornea prevents adequate visualization for a laser iridotomy, some clinicians recommend iridoplasty—a procedure that uses a laser to contract the peripheral iris stroma away from the angle.^{44,45} While there may be a role for iridoplasty in the treatment of phacomorphic and plateau iris, its overall place in the treatment of angle-closure is currently in question.^{7,46-48}

Borderline Cases

The challenge is deciding whether or not to recommend laser PI for all patients with narrow angles. Clinicians may be tempted to do

SIMBRINZA[®]

(brinzolamide/brimonidine tartrate ophthalmic suspension)
1%/0.2%



Aim for Target IOP

Consider Adding SIMBRINZA[®] Suspension to a PGA

SIMBRINZA[®] Suspension should be taken at least five (5) minutes apart from other topical ophthalmic drugs

Up to **7.1 mm Hg** additional IOP reduction from baseline when added to a PGA¹

5.6 mm Hg* additional mean diurnal IOP lowering observed from baseline when added to a PGA¹

*Treatment difference (mm Hg) and P value at Week 6 was -3.7, P<0.0001.

IOP Daily Time Points (mm Hg) ^{††}					
Treatment Arm		8 AM	10 AM	3 PM	5 PM
PGA + SIMBRINZA [®] Suspension (N=88)	Baseline [†]	24.5	22.9	21.7	21.6
	Week 6	19.4	15.8	17.2	15.6
PGA + Vehicle (N=94)	Baseline [†]	24.3	22.6	21.3	21.2
	Week 6	21.5	20.3	20.0	20.1

[†]Differences (mm Hg) and P values at Week 6 time points between treatment groups were -2.14, P=0.0002; -4.56, P<0.0001; -2.84, P<0.0001; -4.42, P<0.0001.
^{††}Baseline (PGA Monotherapy).

Mean Diurnal IOP (mm Hg) ^{†§}		
Treatment Arm		
PGA + SIMBRINZA [®] Suspension (N=83)	Baseline [†]	22.7
	Week 6	17.1
PGA + Vehicle (N=92)	Baseline [†]	22.4
	Week 6	20.5

[§]Difference (mm Hg) and P value at Week 6 between treatment groups were -3.44, P<0.0001.
[†]Baseline (PGA Monotherapy).

Study Design: A prospective, randomized, multicenter, double-blind, parallel-group study of 189 patients with open-angle glaucoma and/or ocular hypertension receiving treatment with a PGA. PGA treatment consisted of either travoprost, latanoprost, or bimatoprost. Patients in the study were randomized to adjunctive treatment with SIMBRINZA[®] Suspension (N=88) or vehicle (N=94). The primary efficacy endpoint was mean diurnal IOP (IOP averaged over all daily time points) at Week 6 between treatment groups. Key secondary endpoints included IOP at Week 6 for each daily time point (8 AM, 10 AM, 3 PM, and 5 PM) and mean diurnal IOP change from baseline to Week 6 between treatment groups.¹

PGA=prostaglandin analog.

24-hour IOP-lowering coverage, including the night — nocturnal efficacy established through an 8 AM time point²

INDICATIONS AND USAGE

SIMBRINZA[®] (brinzolamide/brimonidine tartrate ophthalmic suspension) 1%/0.2% is a fixed combination indicated in the reduction of elevated intraocular pressure (IOP) in patients with open-angle glaucoma or ocular hypertension.

Dosage and Administration

The recommended dose is one drop of SIMBRINZA[®] Suspension in the affected eye(s) three times daily. Shake well before use. SIMBRINZA[®] Suspension may be used concomitantly with other topical ophthalmic drug products to lower intraocular pressure. If more than one topical ophthalmic drug is being used, the drugs should be administered at least five (5) minutes apart.

IMPORTANT SAFETY INFORMATION

Contraindications

SIMBRINZA[®] Suspension is contraindicated in patients who are hypersensitive to any component of this product and neonates and infants under the age of 2 years.

Warnings and Precautions

Sulfonamide Hypersensitivity Reactions—Brinzolamide is a sulfonamide, and although administered topically, is absorbed systemically. Sulfonamide attributable adverse reactions may occur. Fatalities have occurred due to severe reactions to sulfonamides. Sensitization may recur when a sulfonamide is readministered irrespective of the route of administration. If signs of serious reactions or hypersensitivity occur, discontinue the use of this preparation.

Corneal Endothelium—There is an increased potential for developing corneal edema in patients with low endothelial cell counts.

Severe Hepatic or Renal Impairment (CrCl <30 mL/min)—SIMBRINZA[®] Suspension has not been specifically studied in these patients and is not recommended.

References: 1. Data on file, 2014. 2. SIMBRINZA[®] Suspension Package Insert.

Alcon
a Novartis company

© 2016 Novartis 4/16 US-SMB-16-E-1229

Contact Lens Wear—The preservative in SIMBRINZA[®] Suspension, benzalkonium chloride, may be absorbed by soft contact lenses. Contact lenses should be removed during instillation of SIMBRINZA[®] Suspension but may be reinserted 15 minutes after instillation.

Severe Cardiovascular Disease—Brimonidine tartrate, a component of SIMBRINZA[®] Suspension, had a less than 5% mean decrease in blood pressure 2 hours after dosing in clinical studies; caution should be exercised in treating patients with severe cardiovascular disease.

Adverse Reactions SIMBRINZA[®] Suspension

In two clinical trials of 3 months' duration with SIMBRINZA[®] Suspension, the most frequent reactions associated with its use occurring in approximately 3-5% of patients in descending order of incidence included: blurred vision, eye irritation, dysgeusia (bad taste), dry mouth, and eye allergy. Adverse reaction rates with SIMBRINZA[®] Suspension were comparable to those of the individual components. Treatment discontinuation, mainly due to adverse reactions, was reported in 11% of SIMBRINZA[®] Suspension patients.

Drug Interactions

Consider the following when prescribing SIMBRINZA[®] Suspension:

Concomitant administration with oral carbonic anhydrase inhibitors is not recommended due to the potential additive effect. Use with high-dose salicylate may result in acid-base and electrolyte alterations. Use with CNS depressants may result in an additive or potentiating effect. Use with antihypertensives/cardiac glycosides may result in additive or potentiating effect on lowering blood pressure. Use with tricyclic antidepressants may blunt the hypotensive effect of systemic clonidine and it is unknown if use with this class of drugs interferes with IOP lowering. Use with monoamine oxidase inhibitors may result in increased hypotension.

Learn more at myalcon.com/simbrinza

For additional information about SIMBRINZA[®] Suspension, please refer to the brief summary of the full Prescribing Information on the following page.

so, although management of these patients is not clear cut, as fewer than one in 20 gonioscopically narrow eyes will develop angle-closure.⁷ Additionally, laser PI may hasten the development of cataracts.⁴⁹

We don't we have better guidelines on when to prophylactically treat because we still have very little insight on who will and who won't have an angle-closure attack. Unfortunately, clinicians must rely on gonioscopy—which is an imperfect test because of subjectivity—and inconsistent results with different testing variables such as illumination. Additionally, we still don't completely understand all the variables that lead to angle-closure, and the variables we do understand have little predictive value. One variable that may hold promise in helping to better understand the mechanism of angle-closure lies in the fact that the iris squeezes aqueous from its stroma when the pupil dilates.⁵⁰ The iris that holds more water upon dilation may be at a higher risk for an angle-closure attack.⁵¹ This may eventually prove to be an important measurement in clinical practice.

Although angle-closure glaucoma can be challenging, optometrists are in an optimal position to manage these patients. Timely diagnosis using gonioscopy is critical, as is IOP control. The optometrist must then either perform the laser PI (in states that permit such treatment) or promptly refer the patient for laser PI or cataract surgery. ■

Dr. Cymbor is a partner with Nittany Eye Associates in State College, PA, and is a member of the Optometric Glaucoma Society. He is a speaker for Optovue. Dr. Cymbor would like to thank Isaac Linder-muth, fourth-year Salus student, for compiling tables 1-3 and taking figures 1, 4, 5 and 6.

1. Tham YC, Li X, Wong TY, et al. Global prevalence of glaucoma and projections of glaucoma burden through 2040: a systematic review and meta-analysis. *Ophthalmology*. 2014;121(11):2081-90.
2. Quigley H, Broman A. The number of people with glaucoma worldwide in 2010 and 2020. *Br J Ophthalmol*. 2006;90:262-7.
3. Weinreb RN, Friedman DS, eds. *Angle Closure and Angle Closure Glaucoma - Consensus Series Book 3*. Amsterdam: Kugler Publications; 2006:1-61.
4. Quigley HA. Angle-Closure glaucoma: concepts and epidemiology. *Glaucoma Today*. July/August 2009;34-6.
5. Foster PJ, Buhrmann R, Quigley HA, Johnson GJ. The definition and classification of glaucoma in prevalence surveys. *Br J Ophthalmol*. 2002;86(2):238-42.
6. Ritch R, Lowe RF, Reyes A. Angle-closure glaucoma: therapeutic overview. *The Glaucomas*. 1996;2:1521-31.
7. Quigley HA. Understanding the Problem of Angle-Closure Glaucoma. *Glaucoma Today*. March/April 2015;30-1.
8. Mizoguchi T, Ozaki M, Wakiyama H, et al. Peripheral iris thickness and association with iridotrabecular contact after laser peripheral iridotomy in patients with primary angle-closure and primary angle-closure glaucoma. *Clinical Ophthalmology*. 2014;8:517.
9. Boland MV, Zhang L, Broman AT, et al. Comparison of optic nerve head topography and visual field in eyes with open-angle and angle-closure glaucoma. *Ophthalmology*. 2008 Feb 29;115(2):239-45.
10. Yamamoto T, Iwase A, Araie M, et al. The Tajimi Study report 2: prevalence of primary angle closure and secondary glaucoma in a Japanese population. *Ophthalmology*. 2005;112(10):1661-9.
11. Bonomi L, Marchini G, Marrafa M, et al. Epidemiology of angle-closure glaucoma. Prevalence, clinical types, and association with peripheral anterior chamber depth in the Egna-Neumark Glaucoma Study. *Ophthalmology*. 2000;107(5):998-1003.
12. Dandona L, Dandona R, Mandal P, et al. Angle-closure glaucoma in an urban population in southern India. The Andhra Pradesh Eye Disease Study. *Ophthalmology*. 2000(9);107:1710-6.
13. Khor CC, Do T, Jia H, et al. Genome-wide association study identifies five new susceptibility loci for primary angle closure glaucoma. *Nature Genetics*. 2016;48(5):556-62.
14. Fremont AM, Lee PP, Mangione CM, et al. Patterns of care for open-angle glaucoma in managed care. *Arch Ophthalmol*. 2003;121(6):777-83.
15. Scheie HG. Width and pigmentation of the angle of the anterior chamber: a system of grading by gonioscopy. *AMA Archives of Ophthalmology*. 1957;58(4):510-2.
16. Becker B, Shaffer RN. *Diagnosis and Therapy of the Glaucomas*. St. Louis: CV Mosby; 1965:42-53.
17. Spaeth GL. The normal development of the human anterior chamber angle: a new system of descriptive grading. *Transactions of the Ophthalmological Societies of the United Kingdom*. 1970 Dec;91:709-39.
18. Kumar G, Ichhpurani P, Bhartiya S, et al. The lens and angle closure. *J Curr Glaucoma Practice*. 2010;4(1):13-20.
19. Hung T, Chou LH. Provocation and mechanism of angle-closure glaucoma after iridectomy. *Arch Ophthalmol*. 1979;97(10):1862-4.
20. Tello C, Rothman R, Ishikawa H, Ritch R. Differential diagnosis of the angle-closure glaucomas. *Ophthalmology Clinics*. 2000;13(3):443-53.
21. Lachkar Y, Bouassida W. Drug-induced acute angle closure glaucoma. *Curr Opin Ophthalmol*. 2007;18(2):129-33.
22. Than T, Hardie, E. Meds that don't mix with glaucoma patients. *Rev Optom*. 2002;139(10).
23. Acharya N, Nithyanandam S, Kamat S. Topiramate-associated bilateral anterior uveitis and angle closure glaucoma. *Indian J Ophthalmol*. 2010;58(6):557-9.
24. Thambi L, Kapcala LP, Chambers W, et al. Topiramate-associated secondary angle-closure glaucoma: a case series. *Arch Ophthalmol*. 2002;120:1108.
25. Brandão MN, Fernandes IC, Barradas FF, et al. Acute myopia and angle closure glaucoma associated with topiramate in a young patient. *Arq Bras Oftalmol*. 2009;72(1):103-5.
26. Sakai H, Shinjio S, Nakamura Y, et al. Comparison of latanoprost monotherapy and combined therapy of 0.5% timolol and 1% dorzolamide in chronic primary angle-closure glaucoma (CACG) in Japanese patients. *Journal of Ocular Pharmacology & Therapeutics*. 2005;21(6):483-9.
27. Kobayashi H, Kobayashi K, Kiryu J, Kondo T. Pilocarpine induces an increase in the anterior chamber angular width in eyes with narrow angles. *British journal of ophthalmology*. 1999;83(5):553-8.
28. Hung L, Yang C, Chen M. Effect of pilocarpine on anterior chamber angles. *Journal of Ocular Pharmacology and Therapeutics*. 1995;11(3):221-6.
29. Quigley HA. Angle-closure glaucoma—simpler answers to complex mechanisms: LXVI Edward Jackson Memorial Lecture. *Am J Ophthalmol*. 2009;148(5):657-69.
30. Forbes M. Indentation gonioscopy and efficacy of iridectomy in angle-closure glaucoma. *Trans Am Ophthalmol Soc*. 1974;72:488-515.
31. Salmon JF. Long-term intraocular pressure control after Nd:YAG laser iridotomy in chronic angle-closure glaucoma. *Journal of Glaucoma*. 1993;2(4):291-6.
32. Ciobota M, Anghelie A, Chiotan C, et al. Benefits of anterior chamber paracentesis in the management of glaucomatous emergencies. *Journal of Medicine and Life*. 2014;7(2):5.
33. Jin JC, Anderson DR. The effect of iridotomy on iris contour. *Am J Ophthalmol*. 1990;110(3):260-3.
34. Rosman M, Aung T, Ang LP, et al. Chronic angle-closure with glaucomatous damage: long-term clinical course in a North American population and comparison with an Asian population. *Ophthalmology*. 2002 Dec;109(12):2227-31.
35. Snow JT. Value of prophylactic iridectomy on the second eye in angle-closure glaucoma. *Trans Ophthalmol Soc UK*. 1997;97:189-91.
36. Henrietta H, Chew P, Sng C, et al. A comparison of two approaches to managing acute primary angle closure in Asian eyes. *Clin Ophthalmol*. 2013;7(7):1205-10.
37. Hayashi K, Hayashi H, Nakao F, et al. Changes in anterior chamber angle width and depth after intraocular lens implantation in eyes with glaucoma. *Ophthalmology*. 2000;107(4):698-703.
38. Hata H, Yamane S, Hata S, et al. Preliminary outcomes of primary phacoemulsification plus intraocular lens implantation for primary angle-closure glaucoma. *Journal of Medical Investigation*. 2008;55(3):287-91.
39. Lam DS, Leung DY, Tham CC, et al. Randomized trial of early phacoemulsification versus peripheral iridotomy to prevent intraocular pressure rise after acute primary angle closure. *Ophthalmology*. 2008;115(7):1134-40.
40. Tham CC, Kwong YY, Leung DY, et al. Phacoemulsification versus combined phacotrabeculectomy in medically uncontrolled chronic angle closure glaucoma with cataracts. *Ophthalmology*. 2009;116(4):725-31.
41. Zhuo YH, Wang M, Li Y, et al. Phacoemulsification treatment of subjects with acute primary angle closure and chronic primary angle-closure glaucoma. *Journal of Glaucoma*. 2009;18(9):646-51.
42. Brown RH, Zhong L, Lynch MG. Clear lens extraction as treatment for uncontrolled primary angle-closure glaucoma. *J Cataract Refract Surg*. 2014;40(5):840-841.
43. Azuara-Blanco A, Burr JM, Cochran C, et al. The effectiveness of early lens extraction with intraocular lens implantation for the treatment of primary angle-closure glaucoma (EAGLE): study protocol for a randomized controlled trial. *Trials*. 2011;12(1):1.
44. Ritch R, Clement CY, Lam DSC, et al. Surgical techniques. Argon laser peripheral iridoplasty (ALPI): an update. *Surv Ophthalmol*. 2007;52(3):279-88.
45. Agarwal HC, Kumar R, Kalra VK, et al. Argon laser iridoplasty: a primary mode of therapy in primary angle closure glaucoma. *Indian J Ophthalmol*. 1991;39(3):87.
46. Tham CC, Lai JS, Poon AS, et al. Immediate argon laser peripheral iridoplasty (ALPI) as initial treatment for acute phacomorphic angle-closure (phacomorphic glaucoma) before cataract extraction: a preliminary study. *Eye*. 2005;19(7):778-83.
47. Ritch R, Tham CC, Lam DS. Long-term success of argon laser peripheral iridoplasty in the management of plateau iris syndrome. *Ophthalmology*. 2004;111(1):104-8.
48. Friedman D, Lin S, Leibman D. Managing narrow angles and glaucoma. *Rev Ophthalmol*. 2013;20(6):23-32.
49. Lim LS, Husain R, Gazzard et al. Cataract progression after prophylactic laser peripheral iridotomy: potential implications for the prevention of glaucoma blindness. *Ophthalmology*. 2005;112(8):1355-9.
50. Quigley HA, Friedman DS, Congdon NG. Possible mechanisms of primary angle-closure and malignant glaucoma. *J Glaucoma*. 2003;12(2):167-80.
51. Barkana B, Tham CC, Dorairaj SK, et al. Angle-closure glaucoma: posterior (pushing) mechanisms without pupillary block. In: Tombran-Tink J, Barnstable CJ, Shields MB, eds. *Ophthalmology Research: Mechanisms of the Glaucomas*. Totowa, NJ: Humana Press/Springer; 2008:173-87.

Up to
14 CE
Credits*

REGISTER TODAY!



THE OPTOMETRIC RETINA SOCIETY AND *REVIEW OF OPTOMETRY* PRESENT: **RETINA UPDATE 2016**

DECEMBER 2-4, 2016
SCOTTSDALE, ARIZONA

The Westin Kierland Resort

6902 E. Greenway Pkwy.
Scottsdale, Arizona 85254

Room rate: \$189/night

Reservations: (480) 624-1000 or (800) 354-5892

Alaska and Hawaii: (800) 228-1212

Course Topics

- Posterior Segment Technology **Workshop**
- Dr. Larry Alexander Memorial Lecture
- Technology for the Posterior Segment
- Angiography With and Without the Dye
- Hospital-based Retina Grand Rounds
- Retinal Diseases You Don't Want to Miss
- Inherited Retinal Disease
- Co-Management in the ICD-10 Era
- Medical Coding and Compliance Issues

Registration Cost:

ORS Members \$445

Non-members \$495

3 Ways to Register

Online:

www.reviewofoptometry.com/ORSRETUPDATE2016

Email Lois DiDomenico:

ReviewMeetings@Jobson.com

Phone:

(800) 999-0975

ORS Mission Statement

"The mission of the Optometric Retina Society (ORS) is to promote the advancement of vitreoretinal knowledge for clinicians, ophthalmic educators, residents, and students. The ORS is dedicated to posterior segment disease prevention, diagnosis, management and co-management."

Co-Chairs



Brad Sutton, OD



Joseph Pizzimenti, OD

Faculty

Pravin Dugel, MD

Steven Ferrucci, OD

Len Koh, OD, PhD

Blair Lonsberry, OD

Mohammad Rafieetary, OD

John Rumpakis, OD

Leo Semes, OD

Chris Suhr, OD

Gay Tokumaru, OD

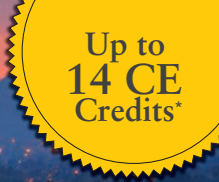Administered by
Review of Optometry[®]





The Optometric Retina Society and *Review of Optometry*® present:

RETINA UPDATE 2016 DECEMBER 2-4



THE WESTIN KIERLAND RESORT

6902 E. GREENWAY PKWY. - SCOTTSDALE, ARIZONA 85254

Discounted room rate: \$189 per night, plus applicable taxes and fees.

For reservations call the hotel directly and identify yourself as a participant of "Retina Update 2016" for group rate. Discounted room rates available 3 days pre- and post- conference, based on hotel availability.

Registration Information

Name _____		NPI # (NPI numbers will only be used for Sunshine reporting purposes) _____		OE Tracker # _____	
Practice Affiliation _____					
Mailing Address _____			City _____	State _____	Zip Code _____
Telephone _____	Fax _____	Email _____			

Name Badge Information (please print clearly)

My Name _____	My Guest(s) _____
---------------	-------------------

Payment Information

	Rate per person		No. in party		Subtotal
OD Registration - \$495 <small>(includes up to 14 hours of CE, breakfasts, lunches, reception) Call for daily and student rates.</small>	\$495	x	_____	=	\$_____
Additional Guest(s) - \$45 (12 years and older, reception only)	\$45	x	_____	=	\$_____
Complimentary Workshop (Friday, December 2, 5:45pm - 7:45pm) <input type="checkbox"/> Posterior Segment Technology Workshop - (2 CE credits*)					

Check enclosed (make checks payable to Review of Optometry)
 Charge my: American Express Mastercard Visa

Credit Card Number _____	Exp Date _____
Cardholder (print name) _____	
Signature _____	

CONFERENCE CANCELLATION POLICY

Full refund on registration fee until
October 14, 2016

50% refund on registration fee until
November 4, 2016

No refund past
November 4, 2016

For more information or to register, contact Lois DiDomenico at 800-999-0975 or at ReviewMeetings@Jobson.com.

MAIL FORM : Review Group Meetings c/o Jobson
11 Campus Blvd, Ste. 100
Newtown Square, PA 19073

FAX FORM: Review Meetings Group
610-492-1039

Administered by: *Review of Optometry*®



*Approval pending

Images courtesy of
The Westin Kierland Resort

Zoom in on GONIOSCOPY

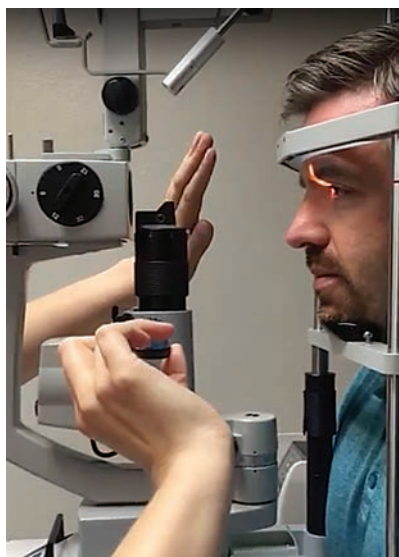Take a closer look at how to properly perform this simple and valuable procedure.

By Emily Bruce, OD, Rodney Bendure, OD, Sarah Krein, OD, and Nathan Lighthizer, OD

A great debate seems to rage in optometry circles concerning the pronunciation of gonioscopy. Whether you say “go-knee-ah-scopy” or “gah-knee-ah-scopy” largely depends on your particular geographical location or optometry school alma mater. Regardless of which side of this great schism you find yourself, the examination technique itself remains one of the most illuminating available for optometrists.

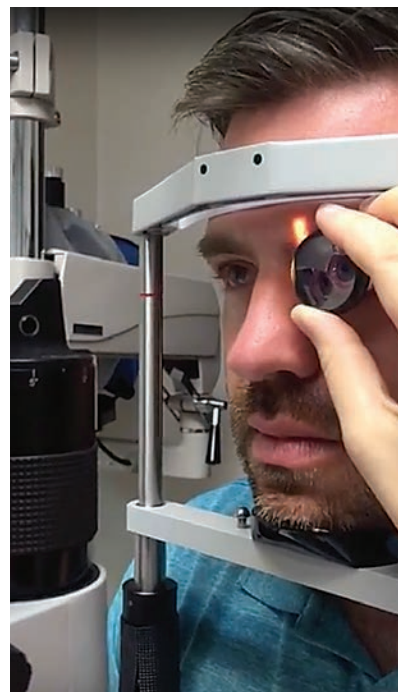It is essential in differentiating glaucoma subtype and determining proper medical or surgical treatment interventions. In addition to its use in the classification of glaucoma, gonioscopy aids in evaluation of iris cysts and tumors, examination of neovascularization of the anterior chamber angle, and in the search for intraocular foreign bodies.

Although the value of gonios-



To get a good view, make sure your patient has his chin on the chin rest and forehead up against the forehead rest.

copy is evident, two separate studies reviewing patient records show that less than half of primary open angle glaucoma (POAG) patients had a single gonioscopy procedure during their initial glaucoma workup.^{1,2} Perhaps, clinicians find it difficult to obtain adequate



Make sure to explain to the patient that you're going to contact the eye. Don't be afraid to use a little gentle pressure to suction the lens onto the eye. Make sure the lens you're using is the proper lens for the angle you're trying to visualize.

views due to improper technique,



To see a narrated video of this procedure, visit www.reviewofoptometry.com, or scan this QR code.

Tonometry Done Right



new



D-KAT Digital
Keeler quality.

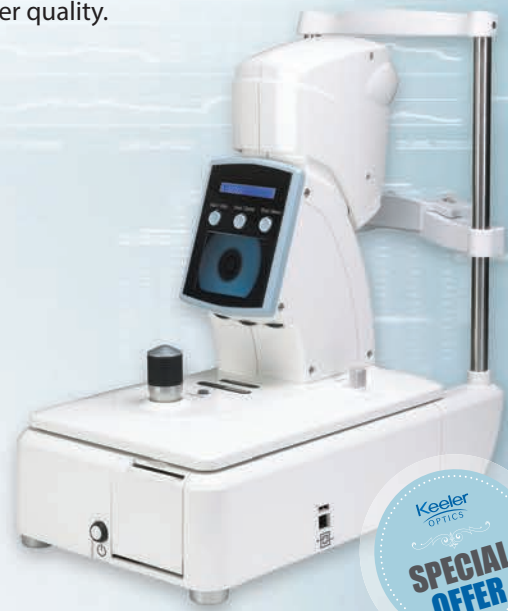

Keeler
OPTICS
**SPECIAL
OFFER**



Intellipuff
The standard for
hand held mobility.

*Trade in any
Tonometer from
July 1, 2016 and
Receive \$600 Off
the Purchase of a
Pulsair Intellipuff*




Keeler
OPTICS
**SPECIAL
OFFER**

Pulsair Desktop
Smallest footprint and simple to use!

*Purchase a Pulsair Desktop
from July 1, 2016 and get a
\$1,300 Instant Rebate!*

Keeler
OPTICS

Keeler Instruments, Inc.
456 Parkway • Broomall, PA 19008
Tel: (800) 523-5620 • Fax: (610) 353-7814
email: keeler@keelerusa.com

 **Buy Online!**
Keelerusa.com

Learn more at www.keelerusa.com

Gonioscopy helps doctors see, from posterior to anterior, the iris, ciliary body band, scleral spur, posterior pigmented trabecular meshwork, anterior less-pigmented trabecular meshwork and Schwalbe's line.



When Good Angles Go Bad

Examining patients using gonioscopy can reveal these potential concerns.

Hyperpigmentation. Patients with hyperpigmentation need to be monitored for the development of pigment dispersion syndrome or glaucoma, pseudoexfoliation syndrome or glaucoma, or angle recession since it is likely the result of trauma which can liberate pigment into the angle.

Posterior embryotoxon. This is an anteriorly displaced Schwalbe's line. Under slit lamp examination you will see a thin, white line usually at the temporal limbus. This junction between the trabecular meshwork and cornea can form a ridge that follows the curve of the limbus. A posterior embryotoxon can be present in up to 24% of the population and is a benign finding in isolation, but it can be associated with conditions with a high prevalence of glaucoma.^{9,10} Occasionally you will find small iris strands, or iris processes, that will reach forward and adhere to the posterior embryotoxon. Again, in mild cases this is not a concern, but severe cases of iris processes can impede the outflow of aqueous.

Sampaolesi's line. When pigment is found anterior to or along Schwalbe's line, it is called a Sampaolesi's line. Although this can be idiopathic, the presence of a Sampaolesi's line can be associated with both pigmentary syndrome and glaucoma and pseudoexfoliation syndrome and glaucoma. If you are seeing a Sampaolesi's line, you will typically have hyperpigmentation throughout the angle, especially in the trabecular meshwork.

Are you seeing red? There will come a time when you will see blood in Schlemm's canal. This is a sign of elevated pressure in the eye or increased episcleral venous pressure, which could even be from your gonio lens. Other etiologies of increased episcleral venous pressure may come from Sturge-Weber syndrome, a dural or carotid cavernous sinus fistula, superior vena cava obstruction or thyroid ophthalmopathy.¹¹ Of course, other red views could include a hyphema from a recent ocular injury or the dreaded neovascularization. You are likely aware of the possibility of neovascularization because retinal pathology can precede the new vessel growth within the angle due to relative ischemia, but this is still an alarming finding because it can lead to sight-threatening neovascular glaucoma.


poor patient cooperation or lack of practice. This could be due, in part, to increased use of newer technologies such as anterior chamber OCT, ultrasound biomicroscopy or an over-reliance on Van Herick angle estimation. New technologies enable us to evaluate patients in new ways, and even allow optometric physicians to delegate more to technicians. As beneficial as new techniques are, only gonioscopy allows us to visualize the entire anterior chamber angle. Gonioscopy is the only technique which permits clinicians to see the angle in true color, as opposed to cross-sectional images interpolated and presented on a screen.

Because light rays from the anterior chamber angle undergo total internal reflection at the cornea-air interface, it is impossible to view the angle unaided. This is why we need a gonioscopy lens. Light rays are able to pass directly into the lens because of its higher index of refraction, then continue through the lens to be viewed by the clinician. This ability to see the angle *in vivo* assists in evaluating angle pigmentation, recognizing blood in Schlemm's canal and quickly differentiating between apositional and synechial angle closure.

This article provides a review of proper gonioscopy techniques and strategies to be successful, even with your most apprehensive patients. So sit back, relax and enjoy your favorite carbonated beverage, be it a soda, cola or pop. No matter where you live, what school you went to or what you call it, the techniques and skills required for successful gonioscopy are the same.

The Lenses

Direct or indirect? Goldmann or Sussman? Three-mirror or four-mirror or six-mirror? Flange or no-



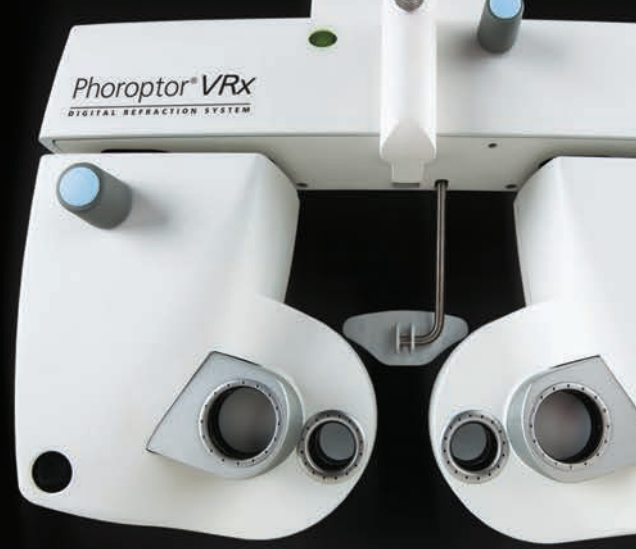In interpreting the view, note how open the angle is, the most posterior structure you can see (in this case it's the ciliary body band) and how much pigment is in the trabecular meshwork.

flange? There are many types of gonioscopy lenses to view the angle, and the one you should use depends on what you're trying to view.

Direct lenses are typically only used by glaucoma surgeons. These are thick convex lenses used in the operating room on sedated, supine patients. Direct lenses are quite impractical in the optometric clinical setting. In contrast, indirect gonioscopy lenses have a concave contact surface and use a mirror to reflect light from the angle to the observer. This method of gonioscopy is practical and easy to perform with an upright patient seated at a slit lamp.

Indirect lenses use a mirror to reflect light rays exiting the angle towards the examiner and provide a mirror image of the angle opposite the mirror. Numerous styles of indirect lenses exist, with variable numbers of mirrors and radii of curvature of the portion which contacts the cornea. They can generally be classified as large-diameter lenses, which do not compress the cornea, and small-diameter lenses capable of compression gonioscopy.

The Goldmann three-mirror lens is a common, large-diameter indirect lens and, likely, the first one you encountered as an optometry student. The smallest and steepest mirror is used for gonioscopy, while the other two mirrors and the central lens are used for evaluation of the retina. This makes the three-mirror lens a particularly valuable multipurpose tool. Because of its larger diameter, and steeper curvature



The most advanced Phoroptor® ever built.

Phoroptor® VRx Digital Refraction System

Thinnest & most compact. Incredibly fast.
Ultra-quiet. Effortless integration. Made in the USA.

www.reichert.com/vrx · AAO Anaheim #604

Reichert
TECHNOLOGIES

AMETEK © 2016 AMETEK, Inc. & Reichert, Inc. (9-2016) · Made in USA

Phoroptor is a registered trademark of Reichert, Inc. · www.reichert.com



Indications for Peripheral Iridotomy

The classic indication for laser peripheral iridotomy (LPI) is a primary acute angle closure attack, in which case the signs may be obvious. Less severe cases may present to the office with symptoms of intermittent angle closure such as pain, redness and blurred vision after pupil dilation or when they are in a dimly lit room. However, many occludable, and thus at-risk eyes, present asymptotically, but with signs observable on gonioscopy, which, if seen, can prevent an angle closure attack in the first place. This is where gonioscopy is particularly useful. We believe LPI is useful for eyes in which TM is not visible in at least two quadrants, particularly when signs—such as patchy pigmentation, signifying likely prior intermittent closure—are present. Other factors such as age over 60, female gender, hyperopia and a family history may also bolster the decision for prophylactic treatment.

than the human cornea, it requires a coupling substance to fill the gap between the lens and cornea. The Goldmann lens provides an excellent view of the angle and usually produces some amount of suction on the cornea, aiding in maintaining the lens on the subject's eye. Because of its outstanding optics and ease of handling, this lens is particularly useful for beginners.³

Smaller-diameter lenses, such as the Sussman or Posner four-mirror lenses, are shallow and have a curvature similar to that of the human cornea, so they do not require a coupling agent. These lenses are valuable in indentation gonioscopy—also known as compression gonioscopy—which is very useful in the differentiation of angle closure pathologies.⁴ Many glaucoma specialists prefer the Posner lens as the handle makes for a convenient



If it's difficult to tell between the ciliary body band and the pigmented trabecular meshwork, or in a particularly stubborn angle where all structures are difficult to identify, you can use the corneal wedge technique to help find your landmarks. When you use the wedge, make your beam as bright and narrow as possible. The place where the two beams come together to form the wedge will always be Schwalbe's line. The pointer exposes the wedge in this picture.

and smooth “pivot” of the lens onto the cornea.

Both types of lenses have a place in the primary care setting for your glaucoma patients, and we would suggest you have one of each in your toolbox.

Getting Your Gonioscopy View

Before we begin a stepwise approach to successful gonioscopy, we want to stress that what you see in the slit lamp is not a static picture. Examiners must remain cognizant that they are dealing with living, responsive and deformable tissues. Normal pupil responses (and their subsequent effects on iris conformation) and ocular tissue and fluid dynamics are completely in play during the procedure. Room illumination, slit lamp light entering the pupil, too much pressure exerted on the examination lens or, in the case of a lens requiring coupling solution, suction on the cornea accompanied by pressure away from the cornea all can change the appearance of the angle.

Step 1: Explain the procedure to the patient. Patients invariably express some degree of apprehension when having anything near their eyes. Patients are much more likely to cooperate if they understand what procedures are being performed and why. Let the patient know that the lens will touch the eye, but will not cause significant discomfort. For those of you who may struggle with how to discuss this procedure with your patients, we've provided a video demonstrating our technique as well as our typical conversation with patients.

Step 2: Instill one or two drops of topical ophthalmic anesthetic, such as 0.5% proparacaine, into both eyes. Even if you plan to do the procedure only on one eye, it helps slow the blink rate, which can aid in ease of the procedure.

Step 3: When using the Goldmann three-mirror lens, fill the lens half way with a coupling solution, such as 2.5% methylcellulose or 1% carboxymethylcellulose. There are advantages to each type of

medium. Methylcellulose provides a much sharper, high definition image compared with carboxymethylcellulose. However, methylcellulose is much more toxic to the cornea and must be irrigated from the patient's eye. The Sussman lens does not require coupling solution.

Step 4: Situate the patient comfortably in the slit lamp and ensure they're at an appropriate level with the lateral canthus marking on the lamp. This will allow easy movement between mirrors without having to readjust the patient after the lens is placed on the eye. Ideally, the patient's back will be straight and they are not straining to keep their forehead against the headrest. Advise your patient to keep their forehead against the strap, chin in the chinrest and both eyes open—but always keep their teeth together.

Step 5: Dim the ambient lights such that the room is almost dark. Ensure that the slit beam is in click. A good starting point for your slit lamp settings is to use a magnification of 10x and a narrow and short light beam that does not enter the pupil and artificially open the iridocorneal angle.

Step 6: Apply the lens. For the Goldmann three-mirror, there are a couple of different ways to do this. For less experienced clinicians, a two-handed approach is in order. Tell the patient to look up. Gently pull down the patient's lower eyelid with your left thumb while you pin the upper lid against the brow using your forefinger. With your right hand, place the gonioscopy lens slightly tilted so as to keep from spilling the coupling solution into the inferior fornix and then quickly tilt the lens onto the cornea. Have the patient look straight ahead, release the upper lid, and exchange hands. Alternatively—and somewhat more efficiently, though difficult for beginners—use your left hand alone to hold the gonioscopy lens while your third finger pulls down the lower eyelid and your second finger pins the upper lid as the patient is looking up. Tilt the lens into the lower cul-de-sac and then pivot onto the cornea. Ask the patient to look straight ahead and release the eyelids. To balance the hand, rest the fingers against the forehead rest and the heel of the hand against the patient's cheek.

Step 7: Removing the lens usually requires the patient to squeeze his eyes closed. Sometimes gentle pressure from the examiner's forefinger against the globe is required to break suction.^{5,6} As with all things, practice makes perfect.

With the Sussman four-mirror, the procedure is less complicated. To examine the patient's right eye,



Corneal Hysteresis: The vital glaucoma risk factor.

Ocular Response Analyzer® G3

Make a more confident glaucoma risk assessment.
Corneal Hysteresis: CPT code 92145

www.reichert.com/ora · AAO Anaheim #604

Reichert
TECHNOLOGIES

AMETEK © 2016 AMETEK, Inc. & Reichert, Inc. (9-2016) · Made in USA

Ocular Response Analyzer is a registered trademark of Reichert, Inc. · www.reichert.com



Essential Procedures


hold the Sussman lens with your thumb and forefinger. Instruct the patient to look down. Pin the upper lid with your second finger. Next, instruct the patient to look straight ahead. Use your third finger to gently depress the patient's lower eyelid. Next, place the lens gently against the cornea. Depending on patient cooperation, you may release the lids at this point. To balance the hand, rest your fingers against the patient's forehead and the heel of your hand against the patient's cheek.

Gonioscopy can be difficult for clinicians with short arms. Using the goniolens case or a tissue box on which to rest the elbow can be helpful. In addition, commercially available elbow rests can also be used.

Interpreting Your Gonioscopy View

The key to correctly interpreting and recording your view is to always perform the procedure in the same manner so you have consistent results. We recommend always starting your gonioscopy by viewing the inferior angle. This is typically the widest angle and the easiest to identify structures due to the increased pigmentation. Remember that, with indirect gonioscopy, your mirror is 180° away from the angle you are viewing.

To view the inferior angle, start with the mirror at 12 o'clock. Rotating clockwise will help you to remember the location of any abnormal findings. Begin with low magnification and increase as necessary to obtain more detail. Sometimes, especially in lightly pigmented patients, details are difficult to ascertain. In these cases, we employ a special technique called a "corneal wedge." The corneal wedge is a very bright, razor thin slit beam, with the light source



At this angle, the iris, ciliary body band, scleral spur, posterior pigmented trabecular meshwork, anterior nonpigmented trabecular meshwork and Schwalbe's line are all visible. Visualizing these structures can provide invaluable information in open angle glaucoma, narrow angle glaucoma and other anterior segment pathologies.

moved approximately 10 to 20 degrees off-axis. The corneal wedge will reveal Schwalbe's line as the point at which two prominent corneal reflections come together.

Structures

The anterior limit of the trabeculum, where it meets the posterior termination of Descemet's membrane, creates an irregular, opaque line called Schwalbe's line. This line may be difficult to view in young people who typically have less pigmentation in the angle. The corneal wedge technique is helpful in identifying an inconspicuous Schwalbe's line.

The trabeculum lies posterior to Schwalbe's line and ends at the scleral spur. It has two parts, an anterior, nonfunctional part and a posterior, functional aspect. As a person ages, the posterior portion becomes increasingly pigmented due to trabecular outflow and the associated pigment debris. Pigmentation is unusual prior to puberty, and a patchy pigment dis-

tribution should raise suspicion of intermittent iris contact. Deep to the trabecular meshwork lies Schlemm's canal, which should appear as a dark line. Blood in the canal indicates a higher than normal episcleral venous pressure.

The ciliary body presents as the most posterior angle structure, and pigmentation varies from no pigment (pink) to dark brown to slate gray.⁶⁻⁸

Tips for Difficult Angles

Sometimes, the angle structures are difficult to view, either because of little-to-no pigmentation, or because the view of the angle is obscured by a forward bowing iris, as seen with iris bombe.

In the case of a lightly pigmented angle, it helps to start with the inferior angle, as it will be the widest and most pigmented. Once you've identified the structures here, you will be familiar with the anatomy of the particular patient and comfortable identifying structures in the other quadrants. In addition, the

corneal wedge technique comes in handy in these situations. Note that this technique can only be performed successfully in the superior and inferior quadrants, as it requires the light source to be off-axis.

When the angle is obscured by a steep mid-peripheral iris, tilting the lens in the direction of the angle you want to view or having the patient look slightly in the direction of the observation mirror will allow the light rays to pass over the obstructing iris and into the angle, allowing a view.

To distinguish between synechial and appositional angle closure, use the small-diameter gonio-lens to apply gentle pressure against the patient's cornea. There should be enough pressure to cause wrinkling of the cornea. This pressure should push anterior chamber aqueous against the iris/lens diaphragm, and widen an appositional angle closure. In the case of a synechial closure or plateau iris, the angle will not widen with pressure. This compression gonioscopy technique is helpful in considering whether a patient would benefit from a laser peripheral iridotomy (LPI). If there is no significant improvement/opening of the angle with compression, then an LPI probably wouldn't help in a narrow angle patient.

With an aging population, the incidence of glaucoma is likely to increase. As primary eye care providers, we want to make sure we employ all the tools available to provide the highest quality of care possible.

Gonioscopy is an easy to perform—and invaluable—procedure. Don't let the angle get the best of you. ■

1. Fremont, AM. Patterns of care for open-angle glaucoma in managed care. *Archives of Ophthalmology*. 2003 June;121(6):777-83.
2. Hertzog, LH, Albrecht KG, LaBree L, Lee PP. Glaucoma care and conformance with preferred practice patterns. Examination of the private, community-based ophthalmologist. *Ophthalmology*. 1996 July;103(7):1009-13.
3. Casser L, Murray F, Woodcome HT. Gonioscopy: Three-mirror Lens. In: *Atlas of Primary Eyecare Procedures*. 2nd Ed. Norwalk, Connecticut: Appleton & Lange;1997:74-87.
4. Casser L, Murray F, Woodcome HT. Gonioscopy: Four-mirror lens. In: *Atlas of Primary Eyecare Procedures*. 2nd Ed. Norwalk, Connecticut: Appleton & Lange;1997:88-92.
5. Faschinger C, Hommer A. How to Perform Gonioscopy. In: *Gonioscopy*. 1st ed. Springer;2012:5-10.
6. Kanski JJ, Bowling B. Glaucoma. In: *Clinical ophthalmology: A systematic approach*. 7th ed. Elsevier-Saunders;2011:316-23.
7. Faschinger C, Hommer A. Anatomical structures of the chamber angle. In: *Gonioscopy*. 1st ed. Springer;2012:11-23.
8. Remington LA. Anterior chamber angle. In: *Clinical anatomy of the visual system*. 2nd ed. Elsevier;2005:103-8.
9. Ozeki H, Shirai S, Majima A, et al. Clinical evaluation of posterior embryotoxon in one institution. *Japanese J Ophthalmol*. 1997;41(6):422-25.
10. Rennie CA, Chowdhury S, Khan J, et al. The prevalence and associated features of posterior embryotoxon in the general ophthalmic clinic. *Eye (London)*. 2005 April;19(4):396-9.
11. Greenfield DS. Glaucoma associated with elevated episcleral venous pressure. *Journal of Glaucoma*. 2000;9(2):190-94.

Vc
VisionChek™
 Digital Exam Suite

Sc
SightChek™
 Digital Phoropter®

Oc
OptoChek™ Plus
 Auto Refractor +
 Keratometer

Ac
AcuityChek™
 Digital Acuity Chart

Lc
LensChek™ Pro
 Digital Lensometer®
 PD + UV

Lc
LensChek™ Plus
 Digital Lensometer®



The elements of refraction.

VisionChek™ Digital Exam Suite

Reichert® combines technology, simplicity, and value at the core of your exam.

Coming soon! · AAO Anaheim #604

Reichert
 TECHNOLOGIES

AMETEK © 2016 AMETEK, Inc. & Reichert, Inc. (9-2016)

www.reichert.com   

22nd Annual Glaucoma Report

Managing the Post-op Glaucoma Patient

As minimally invasive surgeries and laser procedures become more commonplace, learn the basics to stay ahead of the comanagement curve.

By Anthony Van Alstine, OD, MS, and James M. Caruso, OD

Glaucoma is the second leading cause of blindness worldwide, projected to affect nearly 80 million people by 2020.¹ While several different forms of treatment are available for this debilitating disease, all modalities share the same goal: to preserve vision by lowering intraocular pressure (IOP). The remarkable advancements in surgical techniques, particularly in the areas of glaucoma laser procedures and minimally invasive surgeries, means glaucoma specialists increasingly rely upon the primary care optometrist for pre- and postoperative support.

This article reviews important concepts to better equip optometrists in appropriately managing patients who require glaucoma surgery. We will discuss considerations for surgical intervention, introduce common and emerging surgical procedures and provide expectations of postoperative management. The objective: solidify the optometrist's understanding to better comanage post-op glaucoma patients.

Surgical Indications

Once considered a last resort, surgery is increasingly viable, even preferable, earlier in the course of the

disease. Here are a few reasons to consider surgery for your glaucoma patients.

- **Therapeutic failure.** Reaching an appropriate target IOP for a glaucoma patient may be unobtainable with medical therapy alone, especially if the patient first presents with more advanced disease. The Ocular Hypertension Treatment Study (OHTS) determined that 39% of eyes required two or more medications to achieve a 20% reduction from baseline IOP.² Since most patients are initially treated with prostaglandin analogs, practitioners conventionally use β -blockers, α -agonists, carbonic anhydrase inhibitors or a combination of these to further lower IOP. However, most of these second-line drugs show reduced efficacy when used as additive treatments compared with their use as monotherapies.²

Bottom line: If target IOP is not achieved, or your patient is showing progressive structural or visual field loss on maximum drug therapy, surgical intervention is required.

- **Poor compliance.** Achieving medication compliance can be a major hurdle for glaucoma patients. Noncompliance with

glaucoma regimens is reported to be quite high, ranging anywhere from 25% to 80%.³ In addition, as the dosing schedule becomes more complex, compliance wanes. In an effort to determine how compliance is affected when an additional medication is added to the regimen, researchers investigated the refill intervals of 4,930 patients using latanoprost before and after adding a second medication. Once the second drug was added, these patients refilled their latanoprost less frequently compared with monotherapy alone.⁴

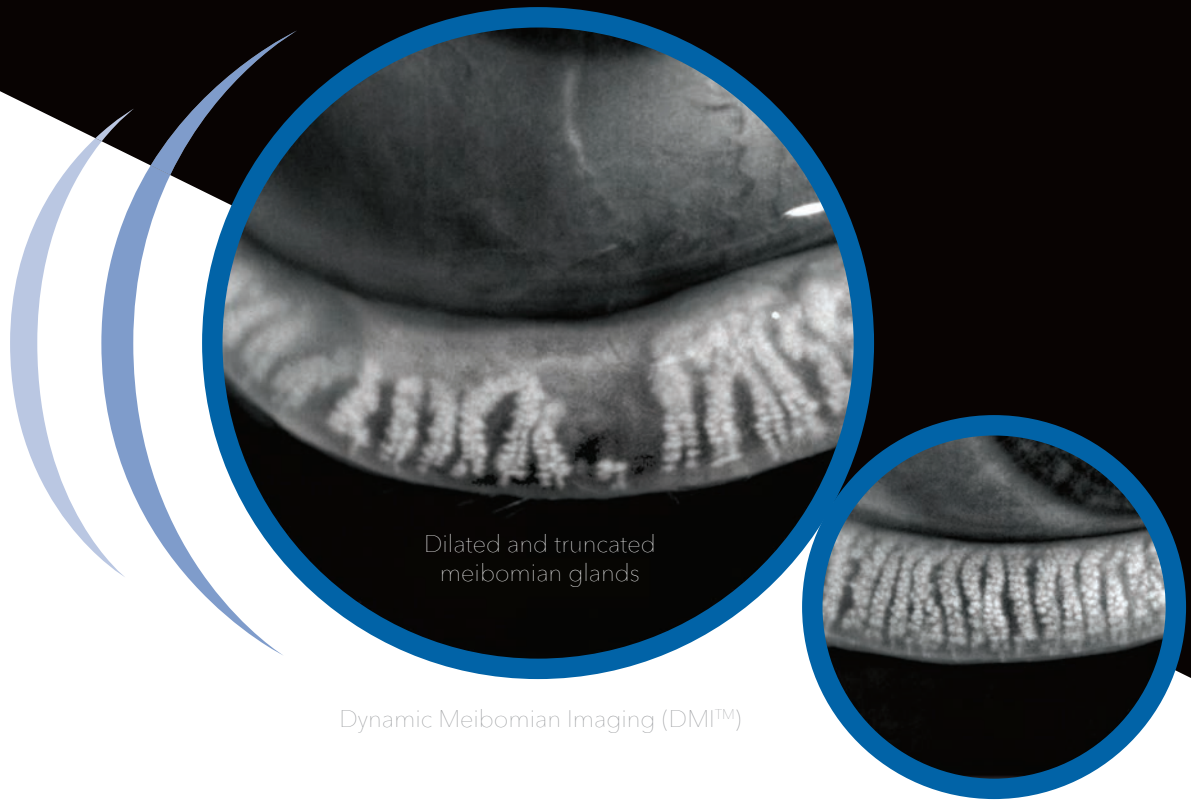
From a pragmatic standpoint, a glaucomatous eye can be treated with three different drug classes, using as few as three drops per day if a prostaglandin and one of the combination drugs available on the market are used (i.e., brimonidine-timolol, dorzolamide-timolol and brinzolamide-brimonidine). However, adding a fourth drug can complicate the dosing schedule too much, affecting compliance.

Bottom line: If your patient has a protracted history of noncompliance with drops or if you face the prospect of adding a fourth drug class, it may be time to consider surgery.

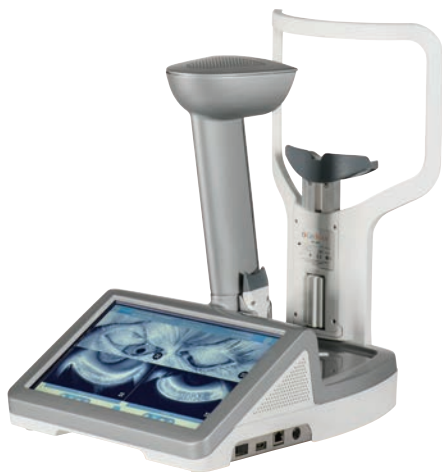Call TearScience today

New. Fast. Affordable.

Reveal meibomian glands in HD



Rapid HD Meibomian Imaging



Pre-test workup imaging to fit your workflow.

- Images fast, in 10 seconds
- Under normal lighting
- User friendly
- Small footprint
- Pretest and satellite locations

LIPISCAN™

Treat MGD with **LIPI**FLOW®
BY TEARSCIENCE

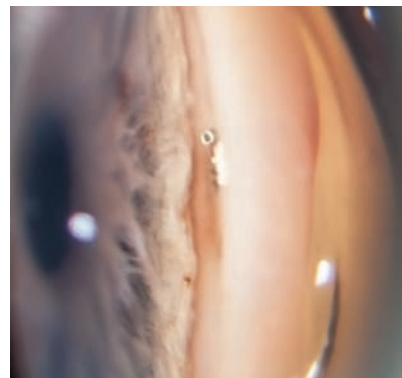

Post-op Care

• **Expense.** The cost of medications can complicate, and often limit, how we treat our patients. With glaucoma affecting more than three million Americans—overwhelmingly in the senior citizen cohort, who mostly rely on a fixed income—the United States spends an estimated \$2.9 billion annually on glaucoma drugs. The annual cost of care per patient is projected to range from \$623 to \$2,511, depending on the severity of the disease.⁵ Pharmaceutical treatments for glaucoma can be a serious financial burden to our patients—drug cost is among the top barriers to medication adherence.⁶ Adding to the problem, several glaucoma drugs remain unavailable as generics. Insurance plans may require evidence of therapeutic failure or intolerance to cheaper medications before approving coverage for brand-name drugs.

Bottom line: If your patient is having difficulty affording their glaucoma medications, surgical options may provide a long-term cost savings, depending on their medical insurance coverage.

• **Adverse effects.** Intolerance to topical medications can limit our ability to medically manage glaucoma patients. Optometrists should always be mindful of the side effects associated with the staple glaucoma drugs, such as the cardio and pulmonary effects of β -blockers and the cosmetic changes associated with prostaglandins that include pigmentary darkening around the eyelids, eyelash growth, iris color darkening and periorbital fat loss.

Carbonic anhydrase inhibitors are sulfa drugs and, though they differ in composition from sulfonamide antimicrobials, may cause adverse effects in patients with sulfa allergies. Researchers found that up to 25.7% of patients using 0.2% brimonidine



At left, an intraoperative photo of the Trabectome employing electrocautery and aspiration to remove tissue of the trabecular meshwork within the anterior chamber angle. At right, a postoperative gonioscopic photo shows the iStent device through the trabecular meshwork into Schlemm's canal. Used during the time of cataract surgery, the iStent requires no additional port incisions to be implanted.

develop an allergic conjunctivitis in response to their drops.⁷ Furthermore, repeated exposure to high amounts of preservatives, such as benzalkonium chloride (BAK), has been associated with ocular surface changes, especially for patients with pre-existing ocular surface disease.⁸

Bottom line: If patients are intolerant to one or more glaucoma medications, surgery to lower IOP may be necessary.

• **Narrow angles.** It's essential to assess the iridocorneal angle of all glaucoma patients with gonioscopy. A recent epidemiological study estimates angle closure glaucoma affects 16 million people worldwide, rendering up to 25% of these patients bilaterally blind.¹⁰ If left untreated, an angle-closure attack in one eye means a 40% to 80% chance of developing an attack in the fellow eye in five to 10 years.⁹

Bottom line: If your patient is at risk for angle closure or has developed one, surgical intervention is indicated.

Minimally Invasive Surgeries

After decades of stagnation, the options for surgical management

have diversified in recent years. Minimally invasive glaucoma surgery (MIGS) options are the hot topic in interventional glaucoma, as these less effective but more patient-friendly alternatives find an appropriate place in the glaucoma management hierarchy.

The more invasive surgeries, such as trabeculectomy and ab-externo glaucoma drainage implants, are associated with significant risk of postoperative complications.¹⁰ In contrast, MIGS procedures are performed through small incisions, often during cataract surgery using the same incision, and demonstrate excellent safety profiles.¹¹ Optometrists will find themselves referring for and comanaging these procedures more frequently in the coming years; therefore, it is essential to be familiar with these options. Here, we cover a few of the more popular MIGS procedures.

• **Trabectome (Neomedix).** FDA approved in 2004, this procedure is performed with a handheld device inserted into the anterior chamber through a small corneal incision. The Trabectome is positioned through the trabecular meshwork (TM) into Schlemm's canal, where it employs

MIGS Key Points

Indications: MIGS procedures are typically used in patients with mild to moderate glaucoma who are candidates for cataract surgery.

The Post-Op Evaluation: Since many MIGS procedures are performed in conjunction with cataract surgery, the post-surgical course is often quite similar to that of cataract surgery alone. Patients should continue their regular glaucoma medications immediately after surgery as the IOP reduction from the procedure does not fully manifest for six to eight weeks.

Pros: The hallmark of MIGS is the high safety profiles. These procedures possess minimal risk of adverse effects and complications. They may be a safe means of reducing or eliminating glaucoma medications in many of our patients.

Cons: Since the IOP-reducing effect with MIGS is not as substantial as the more invasive glaucoma surgeries, such as trabeculectomy and ab-externo glaucoma drainage implants, MIGS is not indicated for patients with severe disease requiring very low (often in the single-digit) IOP profiles.

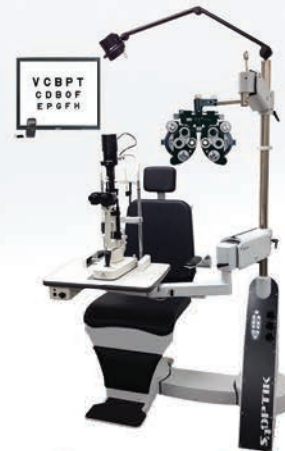electro-cautery and aspiration functions to remove strips of tissue within the angle. This mechanism reduces resistance and aids aqueous drainage.¹² Surgeons can use the Trabectome in isolation or during cataract surgery. It should be noted that adding the Trabectome to cataract surgery has not been reported to increase complications compared to cataract surgery alone.^{12,13}

Does it work? In 2015, researchers followed 82 treated eyes and found a 23% reduction from pre-treatment IOP at the two-year mark. Other studies estimate the IOP reduction can range from 16% to 44% during the one- to two-year period after treatment.¹³

Although the postoperative medication schedule can vary by surgeon, patients are typically prescribed topical fluoroquinolones QID for one week and topical steroids QID tapered over the next one to two months. Additionally, pilocarpine 1% to 2% is applied BID to QID and tapered along with the steroid drops; this prevents peripheral anterior synechiae and concomitantly lowers IOP.¹²⁻¹⁴

The Trabectome procedure comes with the risk for postoperative IOP spike and hyphema; however, these adverse events are rare and usually resolve quickly. Preoperative glaucoma medications should be continued immediately following the Trabectome procedure and adjusted appropriately as the IOP profile stabilizes in six to eight weeks. The preoperative glaucoma medications will not alter the probability of a post-op IOP spike, but will reduce its severity if it occurs.

- *iStent (Glaukos)*. In 2012, the iStent was FDA approved for use in combination with cataract surgery.



Exam Lane Packages

*Opening a new practice?
Looking to upgrade your equipment?*

**Veatch exam lanes are an investment
in your patients, your equipment
and your business.**

Bundled Packages: Save Time and Money

- Visual acuity system
- Manual or Digital Refractor
- Exam chair & stand

The Quality Tools You Need At A Price You Can Afford

Don't Get Left Behind

IT'S TIME TO GO DIGITAL

Contact Us Today

Veatch Ophthalmic Instruments

www.VOI2020.com | 800.447.7511

The heparin-coated titanium device measures 1mm by 0.3mm, making it the smallest FDA-approved device for implantation in the human body. During cataract surgery, the device is implanted into Schlemm's canal where it remains permanently to improve aqueous outflow.

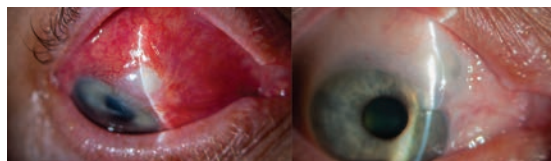
The iStent is non-magnetic and thus compatible with magnetic resonance imaging (MRI).¹⁵

Does it work? In December 2015, researchers published exciting results after following 41 eyes implanted with a single iStent over three years. The average preoperative IOP for the subjects was 24.1mm Hg; on average, the patients were taking 1.8 glaucoma medications. At the three-year post-op interval, the average IOP was 14.9mm Hg with medications being eliminated in 74% of eyes.¹⁶

However, not all studies have found such optimistic results. A meta-analysis published in July 2015, which evaluated 37 studies reporting on 2,495 patients, concluded that cataract surgery alone reduced IOP by 4% while the combined phacoemulsification/iStent procedure reduced IOP by 9%.¹⁷

A second generation of the iStent is currently available in Europe. With a modified design, it comes pre-loaded with two iStents. When researchers conducted a meta-analysis of cases involving two iStents implanted in a single eye, they showed IOP was reduced by 27% from baseline.¹⁷ With the possibility of approval in the United States for the dual iStent design, there is hope for even greater IOP reduction for American glaucoma patients.

It is recommended to wait six to eight weeks before observing the new postoperative IOP state. Patients should therefore continue



Photos: Trey Sullivan, MD

Blebitis (left) and over-filtration of a bleb (right) are among complications associated with more invasive surgeries such as trabeculectomy. MIGS, in contrast, provide better safety profiles, fewer complications and faster recovery times.

their glaucoma medications immediately after surgery, and clinicians can discontinue meds as the IOP improves. Similar to the postoperative course in cataract surgery, patients are prescribed a topical fluoroquinolone QID for seven days. Steroids starting at QID after surgery should be tapered over the next one to two months, and a topical NSAID QID should be given to supplement the steroid. Some clinicians may choose to taper the steroids more quickly than with the average postoperative cataract patient, as glaucoma patients can be more vulnerable to an IOP steroid response.

• *Cypass (Transcend Medical/Alcon)*. Cypass is the newest MIGS device to hit the market, having just recently achieved its FDA approval for use in conjunction with cataract surgery on July 29th, 2016. Unique from the other devices we have discussed, Cypass targets the suprachoroidal space to increase aqueous outflow.

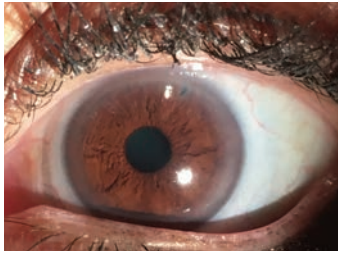
The device is a tube shunt made of polyamide material that measures 6.35mm long and a mere 510 microns in diameter. It is carefully placed in the angle between the ciliary body and the sclera and terminates in the suprachoroidal space. The Cypass has openings at each end and micro-holes along its exterior to allow aqueous to flow into the shunt from the anterior chamber and exit the shunt into the suprachoroidal space.

Does it work? One study in particular is responsible for the device's FDA approval. The COMPASS Trial, a multicenter, randomized clinical trial, was published in August 2016.¹⁸ COMPASS trial followed 505 subjects. One hundred and thirty-one subjects were randomized

into the control group to receive phacoemulsification alone; the remaining 347 received phacoemulsification and Cypass placement. All subjects had primary open-angle glaucoma with entering unmedicated IOP ranging from 21mm Hg to 33mm Hg. The study found that mean IOP was reduced by 7.4mm Hg for the Cypass group and 5.4mm Hg for the control group at the two-year postoperative checkpoint.¹⁸ Although the difference between groups was only 2.0mm Hg, this was statistically significant enough for the study to conclude that Cypass provided long-term IOP reduction.¹⁸

At the two-year mark, medications were completely eliminated in 85% of the Cypass group, vs. 59% of the control.¹⁸ No severe or visually threatening events occurred throughout the study. The mild adverse events reported were iritis, corneal edema, hypotony and IOP elevation. However, these events were quite rare.

The COMPASS trial followed patients in the immediate post-op period at day one, week one, month one and month three. Patients were put on topical antibiotic drops for one week, topical NSAID drops for three weeks, and topical steroid drops, tapered over one month. During the clinical trial, patients were left off of their glaucoma medications postoperatively; they were restarted on glaucoma



External photo of the patient's eye after the laser peripheral iridotomy.

medications on a case-by-case basis if IOP remained elevated for two consecutive visits.

- **Endoscopic cyclophotocoagulation (ECP)** aims to lower IOP by diminishing production of the aqueous by the epithelium of the ciliary processes. ECP

is performed in conjunction with cataract surgery and uses a curved endoscopic laser probe. The surgeon applies laser energy to between 270 and 360 degrees of the ciliary processes, thereby reducing aqueous production.

Does it work? The results vary between studies. In 2016, researchers followed a cohort of 91 eyes for one year and report an IOP reduction of 19% from baseline.¹⁹ Two years prior, scientists studied 80 eyes over the course of two years and report an average IOP reduction of only 10%.²⁰ Then, in 2015 another set of researchers published a retrospective study of 261 eyes with results three years postoperatively; their research shows a 14.5% average reduction in IOP.²¹

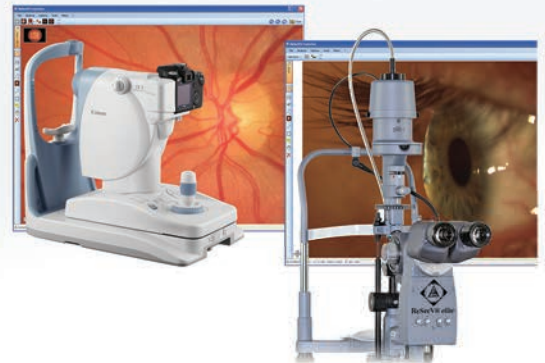
In each of these studies, no increase exists in the rate of complications for combined ECP and phacoemulsification compared with phacoemulsification alone. Although the results do not always yield a dramatic reduction in IOP, the Early Manifest Glaucoma Trial shows the risk of progression decreases by 10% for every 1mm Hg reduction of IOP.²² With minimal risks involved, ECP is a procedure worth considering for glaucoma patients concomitantly in need of cataract surgery.

Glaucoma Laser Procedures

These mainstays are familiar to practicing optometrists and remain viable in our long-term glaucoma management efforts.

- **Laser trabeculoplasty** using an argon laser (ALT) was first introduced in 1979. In this procedure, thermal energy is applied to the trabecular meshwork (TM), which induces contracture of the affected tissue. These focal alterations allow adjacent areas of the TM to expand, decreasing outflow resistance.²³ Due to its limited repeatability over time, ALT's role has not historically been found to be superior to medical therapy.

Since its approval in 2001, selective laser trabeculoplasty (SLT) has taken over as the preferred means of laser trabeculoplasty. SLT uses a frequency-doubled (532nm), Q-switched Nd:YAG laser to deliver laser pulses over 180



Imaging Solutions:

Serve Your Patients Further

**ReSeeVit: The latest technology,
Built specifically for ophthalmic
professionals**

Leaders of Our Industry

Choose from our suite of imaging solutions, including:

- Anterior segment imaging
- Endothelium cell imaging
- Corneal topography
- Retinal imaging

**Imaging Solutions:
Providing For Your Patients.**

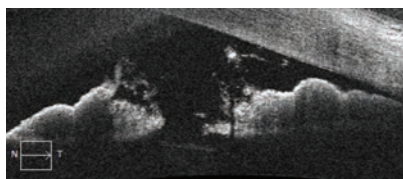
Don't Get Left Behind

IT'S TIME TO GO DIGITAL

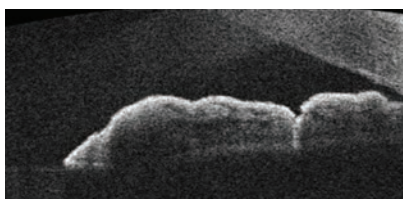
Contact Us Today

Veatch Ophthalmic Instruments

www.VOI2020.com | 800.447.7511



OCT of the angle following LPI treatment. Observe the more direct channel that is created, which relieves the risk of angle-closure.



OCT images of the anterior segment demonstrating relative pupillary block. Note the apposition of the posterior pigmented epithelium of the iris with the anterior lens capsule. The obstruction of aqueous flow causes a fixed, mid-dilated pupil and bowing of the peripheral iris at the angle.

to 360 degrees of TM. These pulses selectively target the pigmented cells of the TM, which increase photolysis and cytokinetic activity, causing a healthy restructuring of the TM.

The limited structural damage seen in SLT allows for SLT to be repeated in the same eye if efficacy wanes or if further IOP reduction is needed. This has ultimately allowed clinicians to use this procedure as an initial treatment option in mild to moderate cases of primary and secondary open-angle glaucoma.²³ Selective laser trabeculoplasty's success rate—defined as 20% IOP reduction—was found to be between 55% and 82% in certain studies.²³ SLT typically shows greater efficacy in patients who have higher pre-treatment IOP values.

Alpha-agonist drops, such as brimonidine or apraclonidine, are usually instilled immediately before and after SLT. IOP should

be checked one hour after SLT is performed to rule out a transient postoperative spike, which has been reported to occur in 4.5% to 27% of patients.²⁴ Patients should continue their glaucoma regimen; topical anti-inflammatory drops are typically applied for five to seven days.

In a recent study that compared artificial tears, prednisolone acetate and ketorolac, each dosed QID following SLT, there was no significant difference in the IOP-lowering outcome or effect on failure rates of the procedure after one year.²⁶ It is common for patients to report varying levels of postoperative discomfort, and up to 50% can present with postoperative anterior chamber reactions at the standard one-week followup. Therefore, the post-op management should focus not only on evaluating IOP, but also maximizing patient comfort with appropriate anti-inflammatory drops.²³⁻²⁵ Patients should remain on their glaucoma medications after the procedure and be re-evaluated at one and three months. It's recommended to wait at least six to eight weeks before adjusting a patient's glaucoma medications, as SLT reaches its steady-state at this time.

• **Laser peripheral iridotomy (LPI)** is indicated for the treatment of (1) angle-closure glaucoma (ACG) associated with relative or absolute pupillary block and (2) prophylactic management of patients with narrow anterior chamber angles who may be at risk for ACG. This procedure uses an argon or Nd:YAG laser to create a full-thickness opening of the peripheral iris. This allows the aqueous humor to bypass its normal course through the pupil, and gives the fluid a direct pathway from the posterior chamber into the anterior chamber and ultimately to the trabecular meshwork. It

effectively eliminates iridolenticular obstruction to aqueous flow.

IOP should always be checked approximately one hour after the applied laser to rule out a transient IOP spike. Patients should be given a topical steroid QID for five to seven days and should continue any glaucoma medications they are taking. A one-week postoperative visit should entail an IOP evaluation, a check for patency of the iridotomy with direct and retroillumination, and should address the presence of any post-procedural inflammation. Patients should be re-examined at one month to ensure stable IOP; a further evaluation of the anterior chamber angle should be conducted via gonioscopy and, if available, anterior segment optical coherence tomography (AS-OCT). If a dilated fundus exam is indicated, post-dilation IOP should be documented to help provide evidence of a properly functioning LPI.

Although the risk is low, there are potential adverse effects associated with laser iridotomies. A marked increase in IOP and mild iritis following the procedure may occur in up to 30% to 35% of cases.²⁶ Intraocular inflammation is usually observed within the first 24 hours and resolves either spontaneously or with topical anti-inflammatory drops. Structural damage to the cornea and lens is possible, along with the later development of peripheral anterior synechiae and hyphema. Less common, but more visually threatening, complications such as retinal and choroidal detachments, focal retinal burns and macular edema can occur.

Summary

Although most of our glaucoma patients can be medically managed using topical IOP-lowering drugs,



MIGS and glaucoma laser procedures offer numerous benefits for those battling progressive disease, medication cost, difficulty with compliance or intolerance to eye drops. These procedures will become ever more popular for our mild to moderate stage glaucoma patients in the years to come. Familiarity with the key principles of appropriate comanagement will help you provide the best care to patients who have undergone these surgical techniques. ■

Dr. Van Alstine practices at the WJB Dorn VA Medical Center in Columbia, SC. He also serves as the president of the South Carolina chapter of the American Academy of Optometry.

Dr. Caruso practices within the Ralph H. Johnson VA Medical Center at the outpatient clinic in Myrtle Beach, SC.

1. Quigley HA, Broman AT. The number of people with glaucoma worldwide in 2010 and 2020. *Br J Ophthalmol*. 2006 Mar;90(3):262-7.
2. Kass MA, Heuer DK, Higginbotham EJ, et al. The Ocular Hypertension Treatment Study: a randomized trial determines that topical ocular hypotensive medication delays or prevents the onset of primary open-angle glaucoma. *Arch Ophthalmol*. 2002 Jun;120(6):701-13; discussion 829-30.
3. Olthoff CM, Schouten JS, Van De Borne BW, et al. Noncompliance with ocular hypotensive treatment in patients with glaucoma or ocular hypertension: An evidence-based review. *Ophthalmology*. 2005;112:953-61.
4. Robin A, Covert D. Does adjunctive glaucoma therapy affect adherence to the initial primary therapy? *Ophthalmology*. 2005;112:863-8.
5. Chan P, Li EY, Tham CC. Cost-effectiveness in the treatment of glaucoma. *US Ophthalmic Review*. 2014;7(2):131-6.
6. Newman-Casey PA, Robin AL, Blachley T, et al. Most common barriers to glaucoma medication adherence: A Cross-Sectional Survey. *Ophthalmology*. 2015;122(7):1308-16.
7. Blondeau P, Rousseau JA. Allergic reactions to brimonidine in patients treated for glaucoma. *Can J Ophthalmol*. 2002 Feb;37(1):21-6.
8. Broadway DC, Grierson I, O'Brien C, Hitchings RA. Adverse effects of topical antiglaucoma medication. *Arch Ophthalmol*. 1994;112:1437-45.
9. Cumba RJ, Nagi KS, Bell NP, et al. Clinical outcomes of peripheral iridotomy in patients with the spectrum of chronic primary angle closure. *ISRN Ophthalmology*. 2013 Jun 26;2013:828972.
10. Gedde S, Herndon L, Brandt J, et al. Tube Versus Trabeculectomy Study Group. Postoperative complications in the tube versus trabeculectomy (TVT) study during five years of follow-up. *Am J Ophthalmol*. 2012;153(5):804-14.
11. Wellik SR, Dale EA. A review of the iStent trabecular micro-bypass stent: safety and efficacy. *Clinical Ophthalmology*. 2015 April;2015(9):677-84.
12. Richter GM, Coleman AL. Minimally invasive glaucoma surgery: current status and future prospects. *Clinical Ophthalmology*. 2016;10:189-206.
13. Mizoguchi T, Nishigaki S, Sato T, Wakiyama H, et al. Clinical results of trabectome surgery for open-angle glaucoma. *Clinical Ophthalmology*. 2015;9:1889-94.
14. Bussell II, Kaplowitz K, Schuman JS, Loewen NA. Trabectome Study Group. Outcomes of ab interno trabeculectomy with the trabectome by degree of angle opening. *Br J Ophthalmol*. 2015;99(7):914-9.
15. Resende AF, Patel NS, Waisbourd M, Katz LJ. iStent trabecular microbypass stent: An Update. *J Ophthalmol*. 2016;2016:2731856.
16. Neuhann TH. Trabecular micro-bypass stent implantation during small-incision cataract surgery for open-angle glaucoma or ocular hypertension: Long-term results. *J Cataract Refract Surg*. 2015 Dec;41(12):2664-71.
17. Malvankar-Mehta MS, Iordanous Y, Chen YN, et al. iStent with phacoemulsification versus phacoemulsification alone for patients with glaucoma and cataract: A meta-analysis. *PLoS ONE*. 2015;10(7):e0131770.
18. Vold S, Ahmed II, Craven ER, et al; CyPass Study Group. Two-year COMPASS trial results: Supraciliary microstenting with phacoemulsification in patients with open-angle glaucoma and cataracts. *Ophthalmology*. 2016 Aug 6. pii: S0161-6420(16)30500-0. [Epub ahead of print].
19. Roberts SJ, Mulvihill M, Soohoo JR, et al. Efficacy of combined cataract extraction and endoscopic cyclophotocoagulation for the reduction of intraocular pressure and medication burden. *Inter J Ophthalmol*. 2016;9(5):693-8.
20. Francis BA, Berke SJ, Dustin L, et al. Endoscopic cyclophotocoagulation combined with phacoemulsification versus phacoemulsification alone in medically controlled glaucoma. *J Cataract Refract Surg*. 2014 Aug;40(8):1313-1321.
21. Seigal, Boling WS, Faridi OS, et al. Combined endoscopic cyclophotocoagulation and phacoemulsification versus phacoemulsification alone in the treatment of mild to moderate glaucoma. *Clin Exper Ophthalmol*. 2015 Aug;43(6):531-9.
22. Heijl A, Leske MC, Bengtsson B, et al. Early Manifest Glaucoma Trial Group. Reduction of intraocular pressure and glaucoma progression: Results from the Early Manifest Glaucoma Trial. *Arch Ophthalmol*. 2002 Oct;120(10):1268-79.
23. De Keyser M, De Belder M, De Groot V. Where does selective laser trabeculectomy stand now? A review. *Eye and Vision*. 2016;3:10. doi:10.1186/s40662-016-0041-y.
24. Song J. Complications of selective laser trabeculectomy: a review. *Clin Ophthalmol*. 2016;10:137-43.
25. Jinapriya D, D'Souza M, Hollands H, et al. Anti-inflammatory therapy after selective laser trabeculectomy: A randomized, double-masked, placebo-controlled clinical trial. *Ophthalmology*. 2014 Dec;121(12):2356-61.
26. Krupin T, Stone RA, Cohen BH, et al. Acute intraocular pressure response to argon laser iridotomy. *Ophthalmology*. 1985;92:922-6.



The Future Is **Now**
The Ophthalmic Industry
Is Going Digital
And for Good Reason.

1. Greater Efficiency & Accuracy.
2. Large Return on Investment.
3. Increased Capabilities, Integration and Connectivity.

Focus on the Patient,
Not Repetitive Data Entries

- Dual cross cylinder
- Programmable sequences
- Wireless interface with pre-test equipment.

Don't Get Left Behind

IT'S TIME TO GO DIGITAL

Contact Us Today

Veatch Ophthalmic Instruments

www.VOI2020.com | 800.447.7511

Controversies in Glaucoma Management

In optometry, it's always debate season. This article looks at some hot topic issues and challenges conventional wisdom. **By Bruce Onofrey, OD**

The rational management of ocular disease is simple. First, know the disease. Get acquainted with the pathophysiology—or altered physiology—that leads to functional or structural loss. Second, know the patient. Consider the risk factors for, and consequences of, the disease, as well as the patient's individual considerations for drug therapy. Finally, know the drug. Get familiar with the pharmacology of the many therapies available. Understand the mechanism of action, the drug's indications, relative and absolute contraindications, proper dosages, dosage forms and proper warnings for counseling the patient, including the likelihood of adherence. This three-pronged approach ensures both safe and

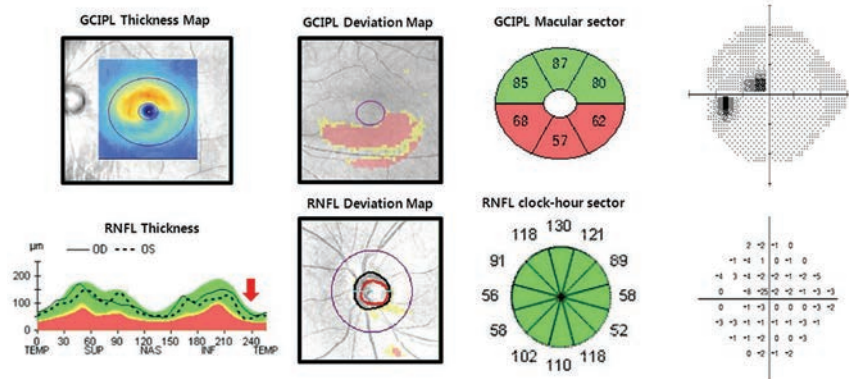


Fig. 1. Correlation between retinal nerve fiber layer and ganglion cell loss and visual field loss in glaucoma. Preperimetric glaucoma demonstrates retinal nerve fiber layer and ganglion cell loss with normal visual fields.

effective use of therapeutic agents.

While all physicians can agree upon these principles, many of the

specifics associated with glaucoma management remain up for debate. With today's evolving understand-

Release Date: October 2016

Expiration Date: October 15, 2019

Goal Statement: From making a judgment about the appropriate point at which to begin treatment, to monitoring progression, to creating a treatment plan, optometry has yet to provide a standardized approach to glaucoma patient care. This course highlights points of contention and relies on published literature to help ODs target care

for individual patients.

Faculty/Editorial Board: Bruce Onofrey, OD

Credit Statement: COPE approval for 2 hours of CE credit is pending for this course. Check with your local state licensing board to see if this counts toward your CE requirement for relicensure.

Disclosure Statement: The author has no relationships to disclose.

**Table 1. Major Glaucoma Clinical Studies and Select Results**

STUDY	SIGNIFICANT RESULTS
Ocular Hypertensive Treatment Study ¹	<ul style="list-style-type: none"> • Quantification of risk of conversion from ocular hypertension to glaucoma over a five-year period. • Importance of central corneal thickness, IOP and vertical cup-to-disc ratio in assessing risk of conversion from ocular hypertension to POAG.
Early Manifest Glaucoma Trial ²	<ul style="list-style-type: none"> • Lowering IOP reduces risk of glaucoma progression. • Visual field more sensitive than evaluation of disc changes in identifying progression.
Advanced Glaucoma Intervention Study ³	<ul style="list-style-type: none"> • A treated IOP of less than 18mm Hg, at all visits, significantly reduces the statistical risk of progression.
Diurnal Fluctuations in IOP ⁴	<ul style="list-style-type: none"> • Large diurnal fluctuations in IOP are an independent risk factor in POAG.
Collaborative Normal Tension Glaucoma Study ⁵	<ul style="list-style-type: none"> • Initial IOP must be lowered significantly (30%) to reduce risk of progression in normal tension glaucoma.
Los Angeles Latino Eye Study ⁶	<ul style="list-style-type: none"> • Large vertical cup-to-disc ratio greater than 0.6 is strongly associated with risk of POAG in this ethnic group.

1. Kass M, Heuer D, Higgenbotham E, et al. The ocular hypertensive treatment study: a randomized trial determines that topical ocular hypotensive medication delays or prevents the onset of primary open angle glaucoma. *Arch. Ophthalmol.* 2002 Jun;120 (6):701-13.

2. Heijl A, Leske C, Bengtsson B, et al. Reduction of intraocular pressure and glaucoma progression. *Arch Ophthalmol.* 2002;120(10):1268-79.

3. VanVeldhuisen PC, Ederer F, Gaasterland DE, et al. The advanced glaucoma intervention study (AGIS): The relationship between control of intraocular pressure and visual field deterioration. *Am J Ophthalmol.* 2000 Oct;130(4):429-40.

4. Asrani S, Zeimer R, Wilensky J, et al. Large diurnal fluctuations in intraocular pressure are an independent risk factor in patients with glaucoma. *J. Glaucoma.* 2000 April;9(2):134-42.

5. Anderson DR. Collaborative normal tension glaucoma study. *Curr Opin Ophthalmol.* 2003, April;14(2):86-90.

6. Kim E, Varma R. Glaucoma in Latinos/Hispanics. *Curr Opin Ophthalmol.* 2010 Mar;21(2):100-5.

ing of how glaucoma works, some wonder if fundus images are as valuable as we once believed and what metrics we should use to target medical treatment. Optometrists also face challenges when individualizing drug therapy in a way that maximizes efficacy and minimizes adverse effects. Questions concerning whether unilateral drug trials are worth the effort also persist.

This article explores the current management of primary open-angle glaucoma (POAG) and unpacks some of the controversies within optometry concerning glaucoma management.

Controversy 1: How Do You Target a Stealthy Disease?

POAG is a progressive anterior optic neuropathy that, if left untreated, can produce profound vision loss. The primary risk factor for developing damage from glaucoma is elevated intraocular pressure (IOP). As of 2010, 44.7 million people worldwide, 2.8 million of whom are

in the United States, are diagnosed with POAG.¹

When we apply our first rule of disease management—know the disease—to glaucoma, we unfortunately come up short. In spite of the work of many dedicated scientists over the decades, understanding the cause of POAG eludes us, as does a cure.

Without a complete understanding of the pathophysiology of POAG, we must apply the skills of risk management to provide proper care for this patient population. A series of pivotal clinical studies have determined relative risk, and we can determine, with a high level of statistical confidence, who will develop disease and who will progress (*Table 1*).²⁻⁴ Specifically, the Ocular Hypertension Treatment Study evaluated individuals who, in spite of demonstrating no evidence of structural or functional loss, have a measurable, statistical risk of developing glaucomatous nerve damage.² This study and others help to quantify the relative risk of progression and give us

insight into which patients can be observed and which patients require treatment.²⁻⁴

A fascinating subset of POAG patients present with no clinical evidence of disease—at least, no evidence observable with standard observation.⁵ Their visual fields (VF) are normal, and clinical observation of the optic nerve may not show evidence of structural damage. However, when their retinal nerve fiber layer (RNFL) or ganglion cells are evaluated using optical coherence tomography (OCT), loss of nerve fiber layer, ganglion cell damage or both, is observable. I refer to this group as preperimetric glaucoma (*Figure 1*). At initial evaluation, it is impossible to determine if the tissue alteration is progressive. This form of glaucoma was predicted in a 1979 study indicating that structural loss (nerve fiber layer damage) precedes functional loss (VF defects), and nerve fiber layer loss occurs prior to detection of field defects.⁶

Table 2. HPA Perimetric Staging

STAGE	DESCRIPTION
Early defect	<ul style="list-style-type: none"> • MD less than -6dB. • Fewer than 25% (18) of the points are depressed below the 5% level and fewer than 10 points are depressed below the 1% level on the pattern deviation plot. • All points in the central 5° must have a sensitivity of at least 15dB.
Moderate defect	<ul style="list-style-type: none"> • MD less than -12dB. • Fewer than 50% of the points (37) are depressed below the 5% level and fewer than 20 points are depressed below the 1% level on pattern deviation plot. • No points in the central 5K can have a sensitivity of 0dB. • Only one hemifield may have a point with the sensitivity of less than 15dB within 5K of fixation.
Severe defect	<ul style="list-style-type: none"> • MD greater than -12dB. • More than 50% of the points (37) are depressed below the 5% level or more than 20 points are depressed below the 1% level on the pattern deviation plot. • At least one point in the central 5K has a sensitivity of 0dB. • There are points within the central 5K with sensitivity less than 15dB in both hemifields.

Controversy 2: Do You Still Need Disc Photos and Visual Fields?

Quick answer: Yes and no. Not everyone will agree, but in my estimation, it's a big "no" to disc photos. Why not, you may ask? Because high-resolution OCT has revolutionized our ability to detect structural nerve/RNFL damage and progression in a way that no individual, even a glaucoma specialist, could hope to detect by evaluating disc photos (*Figure 2*). Most clinicians think they are much better at evaluating optic nerves than they really are.⁷ This is particularly important in diagnosing preperimetric glaucoma. The goal of therapy is to minimize RNFL loss. Since functional changes present themselves after structural changes, waiting to treat until patients experience a VF defect sacrifices a significant amount of RNFL.⁶ Furthermore, research shows imaging the macular ganglion cell layer can help physi-

cians detect POAG and its progression.⁸ Temporal hemifield defects of the ganglion cell layer can be detected quite early in the disease and represent a dependable sign of progression (*Figure 1*).⁹

Visual fields are a source of major frustration. They take time, are highly subjective and patients, for good reason, don't like to do them. However, they are necessary in assessing the stage of disease and, if performed properly, are extremely sensitive in predicting disease progression. In the Early Manifest Glaucoma Trial 86% of progression was detected by VF changes, as opposed to 1% by disc changes detected using flicker chromoscopy.¹⁰

Controversy 3: Can Glaucoma Treatment Wait?

Glaucomatous damage is currently classified under the broad categories of mild, moderate and severe.¹¹ The purpose of these identifiers is

to encourage consistency in documentation. It enables us to make a more accurate prognosis and inform patients of their relative risk of vision loss. Certainly, it should encourage compliance in patients who show evidence of progression. It can also justify the frequency of visits and tests performed. We generally consider glaucoma a slow process. However, patients in any of these broad categories have the potential to experience significant progression of their disease if they fail to use their medications as directed.

The degree of glaucomatous damage can be quantified by using optic nerve damage (structural) and VF loss (perimetric). The most accepted methods use perimetric testing. This recognizes that disability is most directly related to VF loss, whereas structural loss is generally used by clinicians to assess disease progression.¹²

Perimetric staging of POAG.

Automated static perimetry is the benchmark for evaluating visual loss from POAG. It detects and quantifies damage, identifies the pattern loss associated specifically with POAG and helps to determine the success of therapy. Patients with perimetric glaucoma may be staged on their VF sensitivities as measured by standard automated perimetry (SAP) based on the number and depth of defective points, mean deviation (MD) or, most recently, the visual field index. While these parameters are all Humphrey perimeter based, other perimeter manufacturers have software that offers similar information.

An ideal method to classify functional damage in glaucoma should: be objective, reproducible and user-friendly; supply useful information on the characteristics of VF defects (shape, type, location and depth);

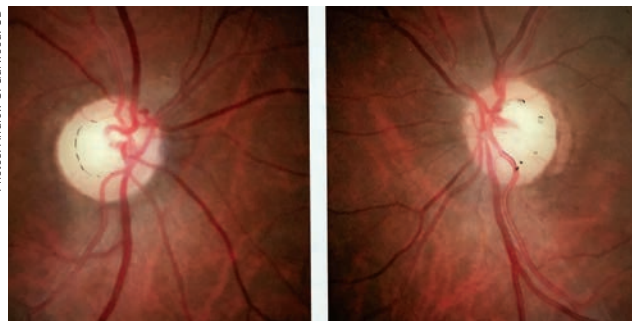
provide a classification which is consistent with structural damage data; be widely accepted and used; and able to monitor even relatively small changes in functional loss over time.

The most common criteria used to stage glaucoma is that of Hodapp, Parish and Anderson (HPA).¹³ The HPA classification system is a clinically useful method that considers two criteria: the overall extent of damage using the MD value and the number of defective points in the Humphrey Statpac-2 pattern deviation probability map of the 24-2, SITA-standard test. In addition, the method takes into consideration the proximity of the defect or defects to fixation (*Table 2*).

Despite its popularity, this classification has some disadvantages. Staging the VF defect requires time-consuming analysis of every visual field test, reducing its day-to-day clinical usefulness—not to mention it provides no information about the location and depth of the defects.¹³

Simplified optic nerve/perimetric staging. The American Academy of Optometry and the American Glaucoma Society work group recently developed a new glaucoma staging system to evaluate and test the accuracy of the severity levels, using real-world cases (*Table 3*).¹² This system's strengths are its simplicity and incorporation of both structural and perimetric data. The most important component is location of the VF defect. The system is particularly biased toward VF defects that approach fixation. One factor it does not take into account is superior vs. inferior VF loss. Studies show inferior hemifield defects are more disabling than superior defects due to the effect inferior field loss has on a person's ability to read.¹⁵

Photos: Andrew S. Gunwood, OD



Figs 2a and 2b. Above, optic nerve images can help identify glaucomatous damage, but the high-resolution OCT images of the same patient below provide a greater level of detail that can help identify structural changes resulting from glaucoma earlier.

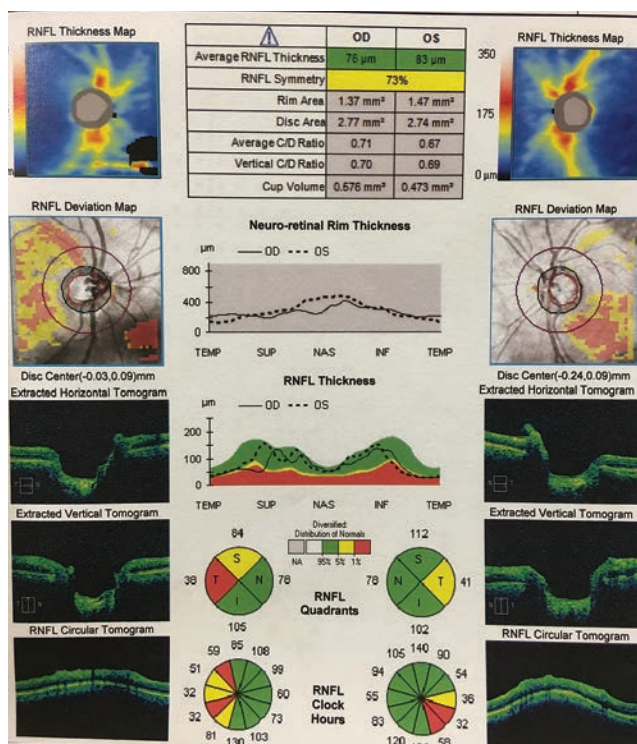


Table 3. AAO Glaucoma Severity Staging Descriptions

STAGE	DESCRIPTION
Mild/early	Structural optic nerve changes consistent with glaucoma with no evidence of visual field changes with standard automated perimetry (preperimetric glaucoma).
Moderate	Optic nerve changes consistent with glaucoma and glaucomatous visual field changes in one hemifield and not within five degrees of fixation.
Severe	Optic nerve changes consistent with glaucoma and glaucomatous visual field changes in both hemifields or loss within five degrees of fixation in at least one hemifield, or both.
Indeterminate	Field not done, or patient unable to perform visual field testing.
Unspecified	Stage not recorded in chart.

Controversy 4: Should You Set IOP Goals?

The ultimate target IOP is the one that prevents development or progression of the disease; however, our initial treatment goal is to lower IOP to a number or by a percentage that significantly lowers the statistical risk of progression. The Advanced Glaucoma Intervention Study demonstrated that a treated IOP below 18mm Hg lowered the risk of progression to just more than 20%, and an additional decrease in IOP further reduces the risk of glaucoma.⁴ The Early Manifest Glaucoma Trial determined that the risk of progression of POAG dropped by 10% for every 1mm Hg of IOP reduction, and a 25% drop in IOP halved the risk of progression.¹⁰ Any clinician involved in the management of glaucoma must set IOP targets that are, in part, based on these important evidence-based studies.

Controversy 5: Which Targeted Medical Management Should You Use?

Reduction of IOP remains the cornerstone of the management of POAG. Commonly used topical IOP-lowering drugs can be divided into four major classes: prostaglandin analogs (PGAs), beta-blockers, alpha-agonists and carbonic anhydrase inhibitors (CAIs). Also available are fixed combinations of topical IOP-lowering drugs. In the United States, we typically see three drug combinations: one that includes a beta-blocker and a CAI, one that includes a beta-blocker with an alpha-agonist and an alpha-agonist with a CAI. The FDA has not approved any prostaglandin combinations. A benefit of fixed-combination formulations is the intent to maximize efficacy and improve adherence.

The introduction of PGAs 20

years ago shifted the management of glaucoma; at the time, only filtering surgery could reliably produce the same degree of IOP lowering. PGAs quickly became the drugs of choice for glaucoma, while the use of other medications, as well as surgery, dropped dramatically.¹⁶

PGAs are the most popular first-line agents for glaucoma treatment for good reason. In addition to their efficacy, PGAs are notable for the paucity of significant systemic (cardiovascular or pulmonary) side effects associated with their use. Mild ocular side effects, however, are not uncommon, including irreversible darkening of the iris and periocular skin, growth of lashes, stinging and conjunctival hyperemia. Although most of these effects are cosmetic, some patients find them worrisome or unacceptable, making it important to counsel patients about the potential ocular effects of PGAs beforehand.¹⁷

Beta-blockers were once the mainstay medical treatment for glaucoma. These agents lower IOP by decreasing aqueous production; the effect—at least a 25% pressure reduction—occurs primarily during the day.¹⁸ Although highly effective and generally well tolerated, in susceptible individuals beta-blockers can produce severe and sometimes life-threatening cardiovascular and respiratory side effects, including bradycardia, arrhythmia, heart block and bronchiolar constriction.¹⁸ Adverse central nervous system effects are also common, ranging from weakness and depression to hallucinations.¹⁸ In patients with diabetes, use of beta-blockers can mask hypoglycemic signs and symptoms, sometimes resulting in dangerously low blood sugar. Additionally, beta-blockers have the potential to raise serum triglycerides and thereby increase the risk of

cardiovascular disease.¹⁸ If used in patients who are highly allergic to substances such as peanuts or insect venom, beta-blockers can reduce the efficacy of injected epinephrine.¹⁸

Clinically, it is vital to identify patients who may be susceptible to these potential dangers. Contradictions to beta-blocker use include asthma, chronic obstructive pulmonary disease, bradycardia and congestive heart failure. A careful clinical history is often helpful in recognizing patients at risk. When a topical beta-blocker is prescribed, patients should be told of its potential systemic side effects and instructed to measure blood pressure and pulse regularly. It is not uncommon to prescribe beta-blockers once daily in the morning to maximize efficacy and avoid issues such as nocturnal hypotensive events.¹⁹

In spite of systemic side effects, beta-blocker use has remained strong, possibly due to cost, predictability of side effects and excellent efficacy. Additionally, the drug works extremely well in combination with all other agents.

Selective alpha-agonists, such as alpha-2 agonists, lower IOP by about 20% to 25%, although the dosing schedule for monotherapy—three times daily—is inconvenient. These agents can, however, be used in combination with other drugs, allowing for twice daily dosing. Alpha-2 agonists are generally well tolerated but may stimulate alpha-2 receptors of the central nervous system and produce adverse systemic reactions such as low blood pressure and orthostatic hypotension. Alpha-2 agonists can also cause allergic responses at rates ranging from 12% to 25%.²⁰

The two selective alpha-agonists available today are apraclonidine and brimonidine. Apraclonidine, the first relatively selective alpha-2 ago-

nist available, was initially used to treat open-angle glaucoma. Allergy and diminution of therapeutic effect with repeated use (tachyphylaxis) have limited its usefulness to short-term applications, such as preventing pressure spikes after anterior segment laser procedures. Brimonidine, which is more alpha-2 selective than apraclonidine, is more appropriate for chronic therapy.²¹

Carbonic anhydrase inhibitors reduce IOP by about 20%—less IOP-lowering efficacy than PGAs.²² Because they reduce IOP by decreasing aqueous production, these sulfonamide agents are often used adjunctively with PGAs, which lower IOP by increasing non-trabecular aqueous outflow. Like PGAs, topical CAIs have no effect on blood pressure, heart rate or pulmonary function.

Because they are sulfonamides, CAIs can cause allergic reactions in sensitive patients. Oral CAIs, such as acetazolamide, are also associated with a number of serious systemic side effects, including metabolic acidosis, renal calculus formation, hematologic abnormalities and sickle cell crisis.²³ Since topical CAIs (dorzolamide and brinzolamide) have become available, the use of oral CAIs is generally limited to angle-closure glaucoma and secondary forms of glaucoma such as uveitic glaucoma.

There are two key factors in selecting any medication: efficacy and safety. The PGAs are today's preferred choice for initial therapy owing to their greater IOP-lowering efficacy and systemic safety. Before initiating treatment, clinicians should obtain a thorough history and determine whether the drug of choice is safe for that particular patient. In the case of a PGA, the side effects are, as noted, mainly local and cosmetic. But when an

alternative or a second agent is warranted, systemic risks such as cardiovascular or pulmonary disease or allergy become important considerations.

A review of clinical evidence and expert opinions suggests that a PGA coupled with a topical CAI may be the best combination to lower IOP.^{24,25} The pair synergistically reduces IOP with minimal systemic risk. My own primary choice is a PGA followed by a topical CAI. After that, I add either an alpha-agonist or a beta-blocker. If three medications cannot bring the patient to target IOP, the patient should be referred for laser or surgical intervention.²⁶ Because IOP reduction from monotherapy and multi-drug therapy can vary greatly among individuals, some clinicians prefer to use individual monotherapy regimens to detect the most effective treatment combination for their patients.

Patient compliance is critical to the success of chronic medical therapy for glaucoma. Patients must understand that glaucoma is a lifetime disease, and the success of therapy requires commitment to the medication regimen and continuing assessment. In addition to teaching the importance of adherence, clinicians can help patients by selecting agents that are safe and comfortable to use on a regular basis. One study demonstrates that, over a period of approximately 18 months, the compliance level of glaucoma medications dropped by approximately 60% to 80%.²⁷ Therapy with latanoprost had the least reduction in compliance; the use of all other classes dropping by 80%.²⁷ The most significant find was that the most dramatic decline in compliance occurs approximately six to seven months after initiating therapy.²⁷

Most glaucoma eye drops, espe-

cially preserved ones, have a deleterious effect on the ocular surface that can exacerbate dry eye signs and symptoms. Treating preexisting dry eye and other ocular surface conditions may help improve tolerability and reduce noncompliance.

Controversy 6: Are Unilateral Drug Trials Worth the Effort?

Murray Fingeret, OD, noted in 2009 the positive aspects of unilateral drug trials, stating that "IOP, while often different between the two eyes, will rise and fall over the day to a similar degree. Also, the response to a medication should be similar in both eyes. Since non-responder rates vary from 8% to 25% depending on the class of medication, a monocular trial is one way to ensure the medication is effective, as well as determine if side effects are occurring."²⁸ This point of view is countered by a 2014 study that suggests the pressure lowering effect crosses over to the other eye with a large degree of variability, thereby underestimating the actual efficacy of the drug. This lack of reliability and accurate predictability put the value of monocular drug trials in doubt.²⁹

New medications. Bausch + Lomb's prostaglandin analog latanoprostene bunod recently completed phase III trials. The results indicate that the efficacy was "non-inferior" to timolol with an IOP reduction range of 7.5mm Hg to 9.1mm Hg. The study included 800 patients and was conducted over a period of 12 weeks. The suggested benefit of this new agent is a dual action. Latanoprostene bunod decreases IOP, like other prostaglandin analogs, by increasing uveoscleral outflow. It's designed to increase optic nerve blood flow via nitric oxide donation.³⁰

Rho-kinase inhibitors are another option currently under development.

These pharmacological agents are designed to target the cells of the trabecular meshwork to facilitate aqueous outflow.³¹ Their mechanism inhibits Rho GTPase proteins—in particular, RhoA, which may be associated with glaucoma's pathophysiology since RhoA is significantly elevated in glaucomatous optic nerve heads.^{31,32}

Generics, sampling and assistance programs. As a pharmacist, I am commonly asked, “How can the pharmacist dispense a generic when I wrote the prescription for the brand-name product?” The simple answer is, they can't. Writing for a branded product does not ensure that a generic will not be dispensed. You must check the box or write on the prescription “no generic substitution allowed.” When this statement is included, the pharmacist cannot legally dispense a generic version of your prescription.

The real reason substitution occurs is based on health plan limits and the high cost of branded products. Some plans will only pay for the generic, if available. Insurance companies may also only pay for the generic of a class of drug. For example, if you write an Rx for Travatan Z (travoprost, Alcon), the patient's drug plan may only cover generic Xalatan (latanoprost). The patient then is faced with accepting the covered generic or paying out-of-pocket for the non-covered brand product.

The final scenario is the patient who has no drug coverage and is asked to pay, sometimes hundreds of dollars, for the branded product, something they may be unwilling or unable to afford. This certainly can affect compliance. The patient may not fill the prescription, or even worse, may not use the drug as often as directed. When it comes to generics, a patient cannot use a drug they cannot afford. I always start with a

generic and upgrade to a brand only if the generic fails to meet my treatment goals.

Drug assistance programs are something every clinician should consider for patients who have limited resources. Most of the major companies have a fairly direct process of evaluating the financial eligibility for these programs. The patient must be willing and able to submit proof of their income as well as possess proper identification—usually a social security card. Once approved, the medication is usually shipped to the prescribing clinician to be dispensed to the patient.

Drug companies hate sampling, period, and I agree up to a point. I don't sample acute care medications such as antibiotics or steroids. However, when it comes to chronic medications for glaucoma or allergy, for example, I thoroughly believe in a sample trial to evaluate the efficacy of the drug. I generally give a one-month supply and write an Rx if, after the first follow up, the drug has shown adequate efficacy without evidence of ocular or systemic side effects.

Invest in the Future

The modern, rational management of glaucoma requires a major investment on our part. We must invest financially in new technologies, which is not cheap. SD-OCT, SAP, Goldmann tonometry, pachymetry, gonioscopy and posterior segment lenses with a good slit lamp are basic tools needed to ethically and professionally manage glaucoma.

Aside from the monetary investment, we must also invest time in reviewing and understanding the pharmacology of treatment agents to safely and effectively prescribe them to our glaucoma patients. Finally, we must be familiar with the major clinical studies that are

necessary to guide our clinical decisions. ■

Dr. Onofrey is a clinical professor and the executive director of continuing education programs at the University of Houston.

1. Quigley HA, Broman AT. The number of people with glaucoma worldwide in 2010 and 2020. *Br J Ophthalmol.* 90(3):262-7.
2. Kass MA, Heuer DK, Higgenbotham EJ, et al. The Ocular Hypertensive Treatment Study: a randomized trial determines that topical ocular hypotensive medication delays or prevents the onset of primary open angle glaucoma. *Arch Ophthalmol.* 2002 Jun;120(6):701-13.
3. Heijl A, Leske C, Bengtsson Bo, et al. Reduction of intraocular pressure and glaucoma progression. *Arch Ophthalmol.* 2002;120(10):1268-79.
4. VanVeldhuisen P, Ederer F, Gaasterland D, et al. The advanced glaucoma intervention study (AGIS): The relationship between control of intraocular pressure and visual field deterioration. *Am J Ophthalmol.* 2000 Oct;130(4):429-40.
5. Toy B, Krishnadev N, Indaram M, et al. Drusen regression is associated with local changes in fundus autofluorescence in intermediate age-related macular degeneration. *Am J Ophthalmol.* 2013 Sep;156(3):532-42.
6. Quigley HA, Green WR. The histology of human glaucoma cupping and optic nerve damage: Clinicopathologic correlation in 21 eyes. *Ophthalmol.* 1979 Oct;86(10):1803-27.
7. MacKenzie PJ, Mikelberg FS. Evaluating optic nerve damage: pearls and pitfalls. *Open Ophthalmol J.* 2009;3:54-58.
8. Hwang YH, Jeong YC, Kim HK, Sohn YH. Macular ganglion cell analysis for the early detection of glaucoma. *Ophthalmol.* 2014 Aug;121(8):1508-15.
9. Spaeth G. Glaucoma testing: too much of a good thing. *Rev Ophthalmol.* 2013 April;20(4):100-3
10. Leske M, Heijl A, Hussein M, et al. Factors for glaucoma progression and the effect of treatment: the early manifest glaucoma trial. *Arch Ophthalmol.* 2003 Jan;121(1):48-56.
11. Remo S, Vessani RM. Staging glaucoma patient: why and how. *The Open Ophthalmology Journal.* 2009;3:59-64.
12. Brusini P. Clinical use of a new method for visual field damage classification in glaucoma. *Eur J Ophthalmol.* 1996;6:402-7.
13. Hodapp E, Parish R, Anderson DR. Clinical decisions in glaucoma. St. Louis: The CV Mosby Co. 1993:52-61.
14. Fellman RL, Mattox CG, Ross KM, Vicchirilli S. Know the new glaucoma staging codes. *Eye Net.* October 2011. Available: www.aao.org/eyenet/article/know-new-glaucoma-staging-codes?october-2011.
15. Hui-Chen Cheng, Chao-Yu Guo, Mei-Ju Chen, et al. Patient-reported vision-related quality of life differences between superior and inferior hemifield visual field defects in primary open-angle glaucoma. *JAMA Ophthalmol.* 2015;133(3):269-75.
16. Alm A, Stjernschantz J. Effects on intraocular pressure and side-effects of 0.005% latanoprost applied once daily, evening or morning. A comparison with timolol. *Scandinavian Latanoprost Study Group. Ophthalmol.* 1995;102(12):1743-52.
17. Camras CB. Comparison of latanoprost and timolol in patients with ocular hypertension and glaucoma: a six month masked, multicenter trial in the United States. *The United States Latanoprost Study Group. Ophthalmol.* 1996;103(1):138-47.
18. Liu J, Kripke D, Weinreb R. Comparison of the nocturnal effects of once daily timolol and latanoprost on intraocular pressure. *Am J Ophthalmol.* 2004;138(3):389-95.
19. Hayreh S, Podhajsky P, Zimmerman M. Beta-blocker eyedrops and nocturnal arterial hypotension. *Am J Ophthalmol.* 1999 Sep;128(3):301-9.
20. Blondeau PI, Rousseau JA. Allergic reactions to brimonidine in patients treated for glaucoma. *Canadian Journal of Ophthalmology.* 2002 Feb;37(1):21-6.
21. Burke J, Schwartz M. Preclinical evaluation of brimonidine. *Surv Ophthalmology.* 1996;41 Suppl 1:S9-18.
22. Lippa EA, Carlson LE, Ehinger B, et al. Dose response and duration of action of dorzolamide, a topical carbonic anhydrase inhibitor. *Arch Ophthalmology.* 1992;110(4):495-9.
23. Onofrey BE, Holdeman NR, Skorin L. *The Ocular Therapeutics Handbook, A clinical manual.* 3rd edition. Lippincott Publishers. 2014.
24. Singh K, Lee BL, Wilson MR. Glaucoma modified Rand-like methodology Group. A panel assessment of glaucoma management: modification of existing Rand-like methodology for consensus in ophthalmology. Part II. Results and interpretation. *Am J Ophthalmol.*

2008;145(3):575-81.

25. Bateman DN, Clark R, Azuara-Blanco A. The effects of new glaucoma treatments on management of glaucoma in Scotland: an examination of ophthalmological health care. *Br J of Ophthalmol*. 2002 May; 86(5): 551-4.

26. The Glaucoma Laser Trial Research Group: The Glaucoma Laser Trial (GLT) 2. Results of argon laser trabeculoplasty vs topical medications. *Ophthalmology* 1990;97:1403-13.

27. Spooner J, Bullano MF, Ikeda LI, et al. Rates of discontinuation

and change of glaucoma medications in a managed care setting. *The American J of Managed Care*. Aug. 2002. Vol. 8(10). Supplement.

28. Fingeret M. The management of glaucoma. *Review of Optometry*. September 10, 2009. Available: www.reviewofoptometry.com/article/the-management-of-glaucoma

29. Rao HL, Senthil S, Garudadri CS. Contralateral intraocular pressure lowering effect of prostaglandin analogues. *Indian J Ophthalmol*. 2014 May; 62(5): 575-9.

30. Nicox exercises option to co promote latanoprostene bunod with

Bausch + Lomb in the US. Available: www.nicox.com/news-media/news/nicox-exercises-option-to-co-promote-latanoprostene-bunod-with-bausch-lomb-in-the-us/

31. Challa P, Arnold J. Rho-kinase inhibitors offer a new approach in the treatment of glaucoma. *Expert Opin Investig Drugs*. 2014;23(1):81-95.

32. Goldhagen B, Prola A, Epstein D, Rao P. Elevated levels of RhoA in the optic nerve head of human eyes with Glaucoma. *J Glaucoma*. 2012;21:530-8.

OSC QUIZ

You can obtain transcript-quality continuing education credit through the Optometric Study Center. Complete the test form (page 74), and return it with the \$35 fee to: Optometric CE, P.O. Box 488, Canal Street Station, New York, NY 10013. To be eligible, please return the card within one year of publication.

You can also access the test form and submit your answers and payment via credit card at *Review of Optometry* online, www.reviewofoptometry.com. You must achieve a score of 70 or higher to receive credit. Allow eight to 10 weeks for processing. For each Optometric Study Center course you pass, you earn 2 hours of transcript-quality credit from Pennsylvania College of Optometry and double credit toward the AOA Optometric Recognition Award—Category 1.

Please check with your state licensing board to see if this approval counts toward your CE requirement for relicensure.

1. Preperimetric glaucoma is characterized by structural damage to the optic nerve and a normal ____:

- Visual field.
- Ganglion cell layer.
- Nerve fiber layer.
- IOP.

2. Rational management of disease requires an understanding of all these except:

- The drug.
- The patient.
- The disease.
- The patient's hobbies.

3. According to the HPA staging of glaucoma, early visual field defects are characterized by all of the following except:

- MD less than 12dB.
- Central 5° has a sensitivity of at least 15dBs.
- Fewer than 25% of points are depressed

below 5% level on the pattern deviation plot.
d. Fewer than 10 points are depressed below the 1% level on the pattern deviation plot.

4. The Ocular Hypertension Treatment Study determined that all of the following factors were important in predicting that the patient would convert from ocular hypertension to glaucoma except:

- Family history of glaucoma.
- Corneal thickness.
- IOP.
- Vertical cup-to-disc ratio.

5. Latino patients with cup-to-disc ratios greater than ____ vertically have a greater than 90% chance of having POAG.

- 0.1.
- 0.6.
- 0.4.
- None of the above.

6. Perimetry is useful for all of the following reasons except:

- To determine the degree of functional loss.
- As a subjective test.
- To determine severity classification.
- To demonstrate loss in an effort to help motivate patient compliance.

7. Monocular glaucoma drug trials may lack reliability due to the drug's effect crossing over to the other eye, causing _____ of the drug's impact.

- Overestimation.
- No impact.
- Underestimation.
- A false sense of security.

8. The major problem with interpretation of disc photos is:

- Underestimation of cup size.
- Overestimation of cup size.

c. Variability among observers.
d. All of the above.

9. The AAO system of the staging of glaucoma severity is biased towards scotomas that:

- Touch on fixation.
- Are in the superior hemifield.
- Are in the inferior hemifield.
- Are in the temporal visual field.

10. Beta blockers have maintained their popularity due to all of the following except:

- 25% efficacy.
- Very low risk of systemic side effects.
- Low cost generics.
- Ease of use.

11. Which statement regarding prostaglandin analogs is false?

- They have a very high efficacy.
- They have a significant effect on heart rate and blood pressure.
- They can produce irreversible darkening of the iris.
- They work well in combination with all other classes of glaucoma medications.

12. The new prostaglandin analog latanoprostene bunod increases extra-trabecular outflow and:

- Decreases aqueous production by parasympathetic activity.
- Has intrinsic sympathomimetic activity.
- Releases nitric oxide which produces vasodilation.
- Decreases aqueous production by parasympatholytic activity.

13. Which patients should avoid oral carbonic anhydrase inhibitors?

- Sulfonamide sensitive patients.
- Renal disease patients.
- Patients prone to kidney stones.
- All of the above.

OSC QUIZ

14. The most common use of oral acetazolamide today is for:
 a. Acute angle-closure glaucoma.
 b. POAG.
 c. Normal tension glaucoma.
 d. In sickle cell patients with POAG.
15. Apraclonidine use in treating POAG has been largely discontinued due to a risk of:
 a. Drug hypersensitivity.
 b. Drug toxicity.
 c. Tachyphylaxis.
 d. a and c.
16. Which drug combination has very few systemic side-effects?
 a. PGA and timolol.
 b. PGA and CAI.
 c. CAI and beta blocker.
 d. Beta-blocker and alpha agonist.
17. Which agent can produce bradycardia and heart block?
 a. Brimonidine.
 b. Bimatoprost.
 c. Timolol.
 d. Brinzolamide.
18. Which is classified as a sulfonamide?
 a. Brinzolamide.
 b. Dorzolamide.
 c. Apraclonidine.
 d. a and b.
19. One study of glaucoma drug compliance found that after six months of treatment, the prescribed use of the drugs:
 a. Remained stable.
 b. Improved dramatically.
 c. Fell sharply for all agents.
 d. Fell only for latanoprost.
20. The pharmacist can only substitute a generic drug for a brand drug:
 a. If the patient asks them to.
 b. If the doctor gives their permission.
 c. When insurers will only pay for generics.
 d. At their own discretion.



TAKE THE TEST ONLINE TODAY!
www.reviewofoptometry.com/continuing_education/

Examination Answer Sheet

Valid for credit through October 1, 2019

This exam can be taken online at www.revoptom.com/continuing_education. Upon passing the exam, you can view your results immediately and download a real-time CE certificate. You can also view your test history at any time from the website.

Controversies in Glaucoma Management

Directions: Select one answer for each question in the exam and completely darken the appropriate circle. A minimum score of 70% is required to earn credit.

Mail to: Jobson - Optometric CE, PO Box 488, Canal Street Station, New York, NY 10013

Payment: Remit \$35 with this exam. Make check payable to Jobson Medical Information LLC.

COPE approval for 2 hours of CE credit is pending for this course.

This course is joint-sponsored by the Pennsylvania College of Optometry

There is an eight-to-ten week processing time for this exam.

1 = Excellent 2 = Very Good 3 = Good 4 = Fair 5 = Poor

Rate the effectiveness of how well the activity:

1. (A) (B) (C) (D)
2. (A) (B) (C) (D)
3. (A) (B) (C) (D)
4. (A) (B) (C) (D)
5. (A) (B) (C) (D)
6. (A) (B) (C) (D)
7. (A) (B) (C) (D)
8. (A) (B) (C) (D)
9. (A) (B) (C) (D)
10. (A) (B) (C) (D)
11. (A) (B) (C) (D)
12. (A) (B) (C) (D)
13. (A) (B) (C) (D)
14. (A) (B) (C) (D)
15. (A) (B) (C) (D)
16. (A) (B) (C) (D)
17. (A) (B) (C) (D)
18. (A) (B) (C) (D)
19. (A) (B) (C) (D)
20. (A) (B) (C) (D)

21. Met the goal statement: (1) (2) (3) (4) (5)
22. Related to your practice needs: (1) (2) (3) (4) (5)
23. Will help you improve patient care: (1) (2) (3) (4) (5)
24. Avoided commercial bias/influence: (1) (2) (3) (4) (5)
25. How would you rate the overall quality of the material presented? (1) (2) (3) (4) (5)
26. Your knowledge of the subject was increased:
 Greatly Somewhat Little
27. The difficulty of the course was:
 Complex Appropriate Basic

How long did it take to complete this course?

Comments on this course:

Suggested topics for future CE articles:

Please retain a copy for your records. Please print clearly.

First Name _____

Last Name _____

E-Mail _____

The following is your: Home Address Business Address

Business Name _____

Address _____

City _____ State _____

ZIP _____

Telephone # _____ - _____ - _____

Fax # _____ - _____ - _____

By submitting this answer sheet, I certify that I have read the lesson in its entirety and completed the self-assessment exam personally based on the material presented. I have not obtained the answers to this exam by any fraudulent or improper means.

Signature _____ Date _____

LOMBART CS-5 CHAIR & STAND

Quality, Style & Value

Package includes:

- The *Lombart CS-5*
Chair & Stand 
- *Topcon VT-10* Refractor
- *Topcon SL-2G* Slit Lamp



- *Lombart CVS Essential*
Visual Acuity System
with RF Remote Control
- Additional upgrades
& configurations available.

\$13,995

Or lease for \$277/mo.
for 60 months*

*Lease rate subject to credit approval,
1st payment is due at signing with 59
remaining rental payments of \$265 and
a \$1.00 purchase option. Taxes, freight
and installation additional. Hand Instru-
ments optional. Subject to change
without notice.

1-800-566-2278

Call 1-800-Lombart

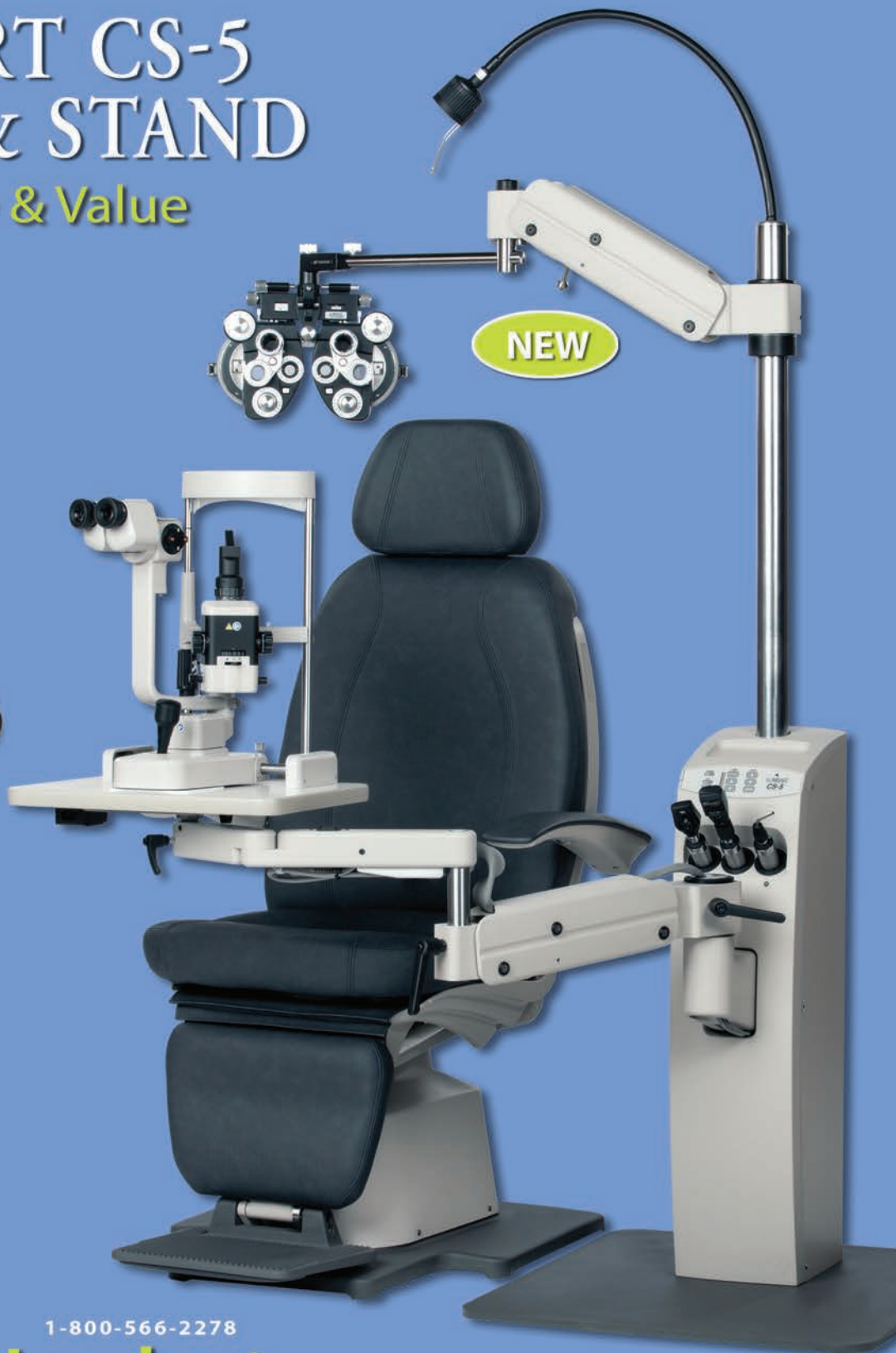Or Your Local Lombart Representative

Corporate Office - 5358 Robin Hood Road, Norfolk, VA 23513-2430
757-853-8888 | FAX 757-855-1232 | 800-566-2278

www.lombartinstrument.com
lombart@lombartinstrument.com

Sales and Service Centers Coast to Coast

ATLANTA • BALTIMORE/WASHINGTON D.C. • BOSTON • BOYNTON BEACH/MIAMI • BRADENTON • CHARLOTTE • CHICAGO • CINCINNATI • DALLAS • DENVER • DETROIT • GREENSBORO • HOUSTON
JACKSON • KANSAS CITY • KNOXVILLE • LOS ANGELES • MILWAUKEE • MINNEAPOLIS • NEW JERSEY/NEW YORK/PENNSYLVANIA • NORFOLK • PORTLAND • SAN ANTONIO • SAN DIEGO • SAN FRANCISCO





OCULAR • SURFACE • DISEASE

New Innovative Solutions for your Practice...

As the industry leader in innovative non RX treatments for Dry Eyes, Blepharitis and Ocular Surface Disease treatment, Lunovus is proud to introduce the Next-Generation therapy: Blephadex Heated Warming Wipes. When combined with our Eyelid Foam Cleanser and traditional Eyelid Wipes, it's easy to see why Lunovus leads the field in Ocular Surface Disease Treatment.



LUNOVUS
WHERE LIFE IMPROVES

1-800-980-6551  Blephadex.com

Introducing Heating Blephadex Warming Wipes

**OSD
Treatment**

Redefined



Jeffery McAnnally
Founder

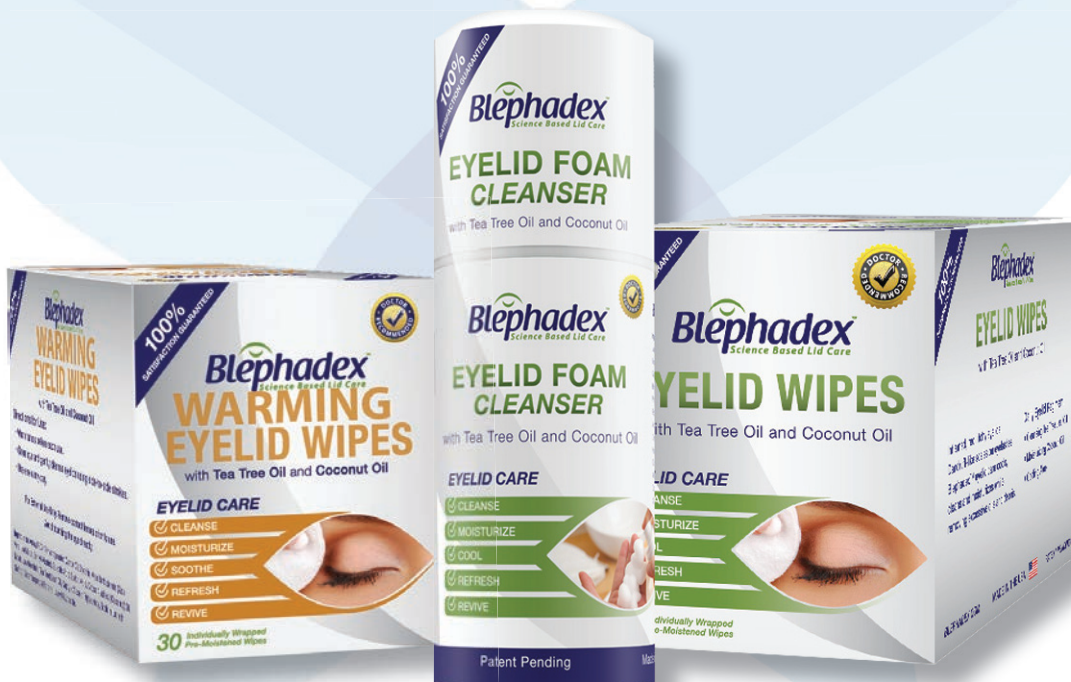(Advertisement)

Lunovus Founder Introduces New Treatment

Heated Warming Wipes By Lunovus - *Coollest Treatment Ever for Blepharitis, Dry Eyes & Other Ocular Surface Diseases*

At Lunovus, preserving, protecting and promoting healthy vision is our passion. We're innovators in neutraceutical development, pioneering non RX treatments for chronic recurring conditions like Dry Eyes, Blepharitis and other Ocular Surface Disease. That's why more optometrists and ophthalmologist trust Lunovus to serve as their preferred partner.

Our unique patented formulas with Tea Tree Oil and Coconut Oil are proven to not only effectively treat OSD and Demodex, but do so without patients experiencing a burning sensation. We look forward to partnering with your practice and introducing our latest innovation: Heated Blephadex Warming Eyelid Wipes: the ONLY heated eyelid wipe in the industry.

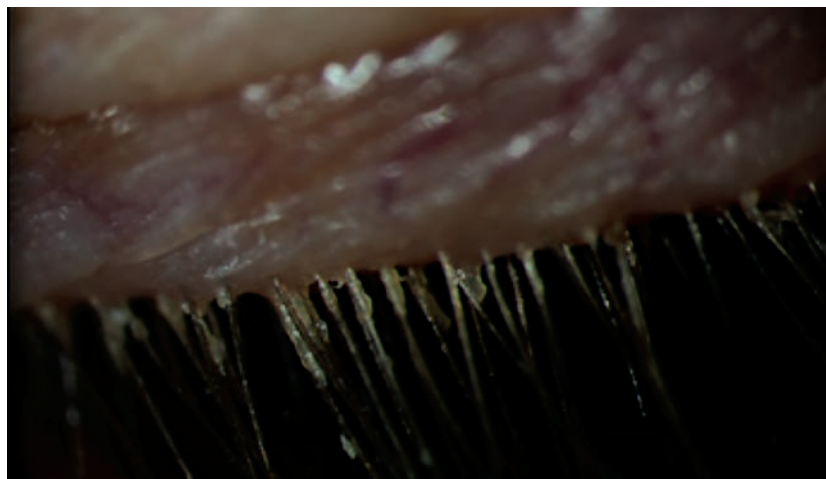

SPOTLIGHT ON *DEMODEX*: ELIMINATING THE MITE-Y MENACE

The oft overlooked *Demodex* diagnosis is elemental to setting patients on the path to relief, if you know what to look for. **By Victoria Roan, OD**

D*emodex* management may be dismissed by some as a mere “fad” in optometric practice, but with more and more patients reporting refractory dry eye symptoms, it’s time to consider it an actual ocular concern that can impact any patient, especially those older than 50.¹ *Demodex* is typically not difficult to manage, but its treatment in optometric offices remains uncommon. The majority of *Demodex* patients have mild to moderate symptoms that include itching and burning of the eyes and lids, foreign body sensation and fluctuating blurry vision.¹⁻⁵ These symptoms can be swiftly managed with artificial tears, but if *Demodex* is the culprit, artificial tears will offer only temporary relief. As symptoms are similar to ocular surface disease, it is easy to assume dry eye syndrome and prescribe over-the-counter artificial tears rather than evaluate for the contributing factor, *Demodex*.

This article urges doctors to consider this diagnosis while explain-



Cuffing, seen here, is a classic symptom of *Demodex* overpopulation, which can lead to dry eye symptoms that artificial tears simply can't address.

ing how to differentiate between *Demodex* and other causes of dry eye symptoms.

Meet the Mites

More than 100 species of *Demodex* mites have been identified.⁶ *Demodex folliculorum* and *Demodex brevis* are the two main species that inhabit the human skin. *D. folliculorum* typically range from 0.3mm to 0.4mm long and tend to

reside within the hair follicles while *D. brevis* mites are about half the length (0.186mm) and reside within the sebaceous and meibomian glands.^{3,4,7}

Both parasites are half the diameter of a grain of table salt and worm-shaped with four legs. *D. folliculorum* consume and damage epithelial cells at the hair follicle, resulting in a weakened lash root and the eventual loosening and

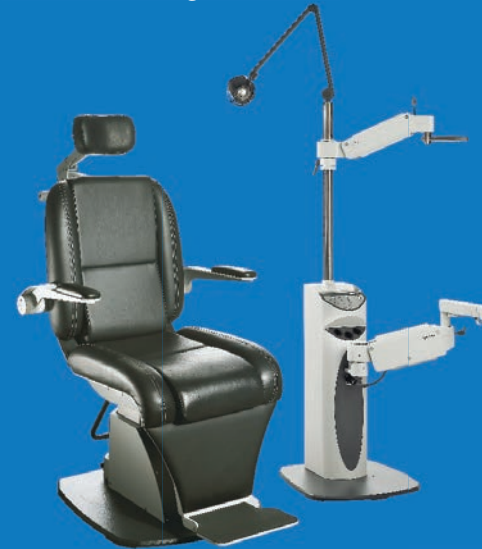S4OPTIK OPHTHALMIC CHAIR & STAND

The Pros and Cons of <i>Demodex</i> Therapies		
Product	Pros	Cons
Avenova (Novabay)	<ul style="list-style-type: none"> • No stinging sensation • Proven effective against <i>Demodex</i> despite not containing active tea tree oil • three year shelf life 	<ul style="list-style-type: none"> • Only available through prescription • Not covered by all insurers
BlephEx (RySurg)	<ul style="list-style-type: none"> • Disposable, rotating microsponge • Mechanical removal of lid debris via a handheld device • Performed in clinic by OD or staff 	<ul style="list-style-type: none"> • Requires patient compliance • Frequent return visits to office • Patients currently need to pay out of pocket
Cliradex, Cliradex Complete, (Bio-Tissue)	<ul style="list-style-type: none"> • Comes with a microexfoliator for in-office use for cases with severe debris to allow better penetration of T40 • High concentration Cliradex Advanced Care gel (50% T40) in Cliradex Complete Kit for in-office use allows more effective initial dose • Lower concentration (10% T40) for home maintenance between visits • Lid scrubs available OTC for mild to moderate cases 	<ul style="list-style-type: none"> • Strong menthol-like sensation (can be described as a stinging sensation)
Eye Eco Tea Tree Oil Eyelid & Facial Cleanser (Eye Eco)	<ul style="list-style-type: none"> • 2-in-1 face and lid wash • An effective make-up remover • Foam dispensing bottle • Available OTC 	<ul style="list-style-type: none"> • Strong menthol-like sensation (can be described as a stinging sensation) • Removal of accumulated debris depends on patient's attention to lids while applying
Ocusoft Lid Scrub (Ocusoft)	<ul style="list-style-type: none"> • Available in lid scrub pads or a foam to be used with a cotton applicator • Contains active tea tree oil ingredients • Removes debris and excessive oils • Available OTC 	<ul style="list-style-type: none"> • Strong menthol-like sensation (can be described as a stinging sensation)
SteriLid (Theratears)	<ul style="list-style-type: none"> • Contains tea tree oil ingredients • Removes accumulated debris and excessive oils from lid margin • Available OTC 	<ul style="list-style-type: none"> • Detergent-based product
Blephadex lid scrubs (Lunovus)	<ul style="list-style-type: none"> • Available in lid scrub pads or a foam to be used with a cotton applicator • Contains tea tree oil ingredients • Removes accumulated debris and excessive oils from lid margin • Available OTC 	<ul style="list-style-type: none"> • Strong menthol-like sensation (can be described as a stinging sensation)
Baby Shampoo	<ul style="list-style-type: none"> • Cost efficient • Will address any bacterial component of blepharitis • No stinging sensation 	<ul style="list-style-type: none"> • Typically no tea tree oil

Together...



Or Side by Side...



S4OPTIK
exceptional durability,
functionality, and
flexibility.

S4OPTIK

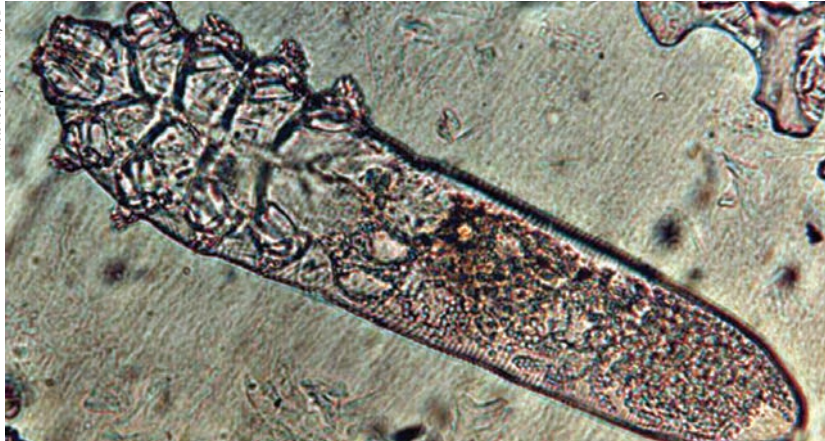250 Cooper Ave., Suite 100 Tonawanda NY 14150

www.s4optik.com | 888-224-6012

Sensible equipment. Well made, well priced.

For today's modern office.

Photo: Joseph Showlin, OD



This microscopic image shows a *Demodex folliculorum* mite. While they can likely be found in everybody, an overpopulation of these critters can cause ocular discomfort and require targeted treatment.

misdirection of the lash.^{3,5,7} Their appendages create microabrasions that cause epithelial hyperplasia and reactive hyperkeratinization, which we see as cylindrical dandruff. *D. brevis*, on the other hand, tend to burrow deep into the sebaceous glands, physically blocking the orifice.^{5,7} In addition, its chitinous

exoskeleton acts as a foreign body, inducing granulomatous reactions that can lead to hordeola or chalazia.⁵⁻⁷ Due to the *D. brevis*' proximity to the ocular surface, it is more likely the cause of refractory corneal lesions than *D. folliculorum*.⁶

Under scrutiny of a slit lamp, *D. folliculorum* can sometimes be seen

orienting themselves face down toward the follicle bed with a small portion of their tail protruding from the opening. Though more difficult, rotating the lash (without epilation) has also been effective in encouraging mites to travel to the follicle opening for easier observation behind a slit lamp.⁸

For those with easy access to a microscope, the presence of *Demodex* can also be enhanced with the addition of fluorescein or alcohol on the glass slide; they cause the cylindrical dandruff to become semitransparent to reveal mites hiding within the debris.³ Due to their photosensitivity, *Demodex* tend to avoid the bright lights and can be difficult to observe under plain biomicroscopy. For the same reason, most mating and movement occurs at night. Their lifespan is about one to two weeks for adults.³⁻⁶

Patients may note increased lid irritation first thing in the morning as a result of the increased activity at night.

Demodex and Rosacea

Demodex has been implicated as a causative agent in rosacea since 1932.⁶ The affliction affects about 16 million Americans, mostly those older than age 30 who have fair skin.¹⁵ Those affected present with erythema, flushing and transient papules along the cheeks, chin, nose and central forehead.^{15,21} Considered an inflammatory condition, patients suffering from rosacea have increased levels of interleukin-1a and -1b, as well as a greater activity of metalloproteinases (MMP-9 and MMP-8) in the tear film.¹⁵ These markers support the benefits of doxycycline, which acts to decrease both MMP-8 and MMP-9 expression.¹⁵

There is a large discrepancy (6% to 72%) in the prevalence of ocular involvement in those with rosacea.^{15,21} Investigators have found *Demodex* pres-

ence in 60% of patients clinically and up to 80% when detected via skin biopsy.²¹ Since not all rosacea patients presented with *Demodex* infestation, researchers believe these mites are aggravators or symptomatic, but not the causative agent. Rosacea patients had an average of 12.8 mites per square centimeter of skin, significantly greater than the 0.7 mites per square centimeter in nonrosacea subjects.³

Increased UV exposure and warmer seasons are correlated with increased rosacea flare-ups.^{6,15,21} In addition, *Demodex* colonization increases in the spring and summer and, as a result, UV treatments may be contraindicated as a treatment option against *Demodex* mites.⁶ Other triggers for rosacea include: spicy foods, alcohol consumption, extreme temperatures, physical exercise, emotional distress and menopause.¹⁵

Invasion of the Body Snackers

Because these ectoparasites are susceptible to desiccation, they require a host to survive.⁶ In addition, the mite population increases with age.^{1,3,4,6,7,9} An overpopulation of mites can lead to an imbalance of tear cytokine levels, particularly an influx of interleukin 17, which is proinflammatory, leading to blepharitis.^{8,10} A recent study found that 84% of those older than age 60 have *Demodex*, and 100% of those older than 70 are infested.⁴ Several studies found that the average healthy patient will likely have a small population of *Demodex*, but also confirmed a marked increase (two to six mites infesting each follicle) in mite population in patients older than 50.⁶ One study found

S4OPTIK OPHTHALMIC CHAIR 2000

Precision Engineering



Effortless cradle tilt recline with perfect counterbalance; allow convenient patient positioning with one-handed release & control mechanism.

S4OPTIK

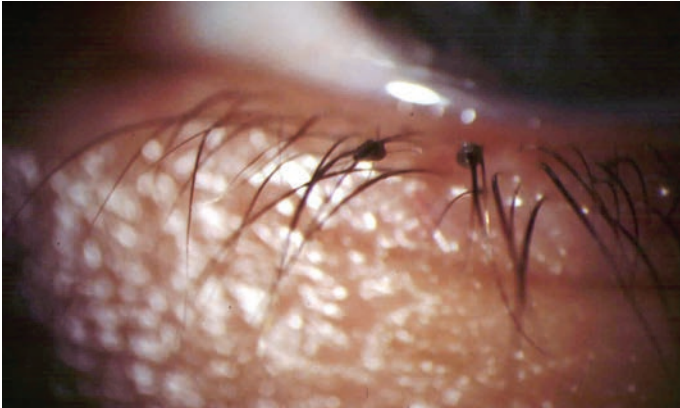250 Cooper Ave., Suite 100 Tonawanda NY 14150

www.s4optik.com | 888-224-6012

Sensible equipment. Well made, well priced.

For today's modern office.

Photo: Joseph Shovlin, OD



This patient displays collarettes resulting from blepharitis, a condition that can be caused by *Demodex*.

Diagnosing *Demodex* Blepharitis

1. Clinical Hx: refractory blepharitis, conjunctivitis or keratitis in adults and blepharoconjunctivitis or recurrent chalazia in younger patients
2. Cylindrical cuffing observed along lash base with slit lamp examination (pathognomonic)
3. (Optional) Detection of *Demodex* eggs, larvae and adult mites on epilated lashes with microscopy

an average count of 12.9 mites per patient seen with cylindrical dandruff, whereas those without had an average of 0.35 mites—that's a considerable difference.⁷ Individuals with compromised immune systems, such as those with poor systemic health and those taking immunosuppressive agents, have a higher level of *Demodex*, although contradicting research postulates that mites may thrive better in healthy, normal tears as opposed to tear deficient states.³

Interestingly, a 2014 study based the presence of *Demodex* on amplification of *Demodex* DNA rather than visual observation.¹¹ They found that, although only 14% of subjects older than 18 years visually presented with *Demodex*, they were able to detect *Demodex* 16D rDNA in up to 70% of those subjects.¹¹ We can presume that *Demodex* may actually just be part of the natural human bioflora and does not become a problem until

they are allowed to overpopulate and tip the natural equilibrium of the skin flora.

Patient Presentation

In addition to dry eye symptoms, *Demodex* patients often complain of irritation along the lid margin. Blepharitis can be caused by bacterial or parasitic etiologies. Numerous studies, including one meta-analysis, have found a strong correlation between bacterial blepharitis and *Demodex* blepharitis.¹²⁻¹⁴ *Demodex* mites act as vectors, carrying bacteria such as *Staphylococci* and *Streptococci* as they travel between lashes.^{6,7,10} The superantigens produced by these bacteria are implicated in anterior blepharitis and the induction of stubborn skin conditions such as rosacea, *pityriasis folliculorum*, *pustular folliculitis*, perioral granulomatous dermatitis and permanently hyperpigmented patches on the skin.^{1,4-6,10}



Strength in Numbers

THINK ABOUT YOUR EYES

1.5 Million Newly Diagnosed Eye Diseases

Think About Your Eyes (TAYE) is helping win the war against eye disease! The program has been instrumental in driving impressive increases in annual comprehensive eye exams, resulting in a significant increase in detecting previously undiagnosed eye diseases like glaucoma, macular degeneration, cataracts, and diabetic retinopathy. And we're just getting started!

thinkabout
youreyes.com

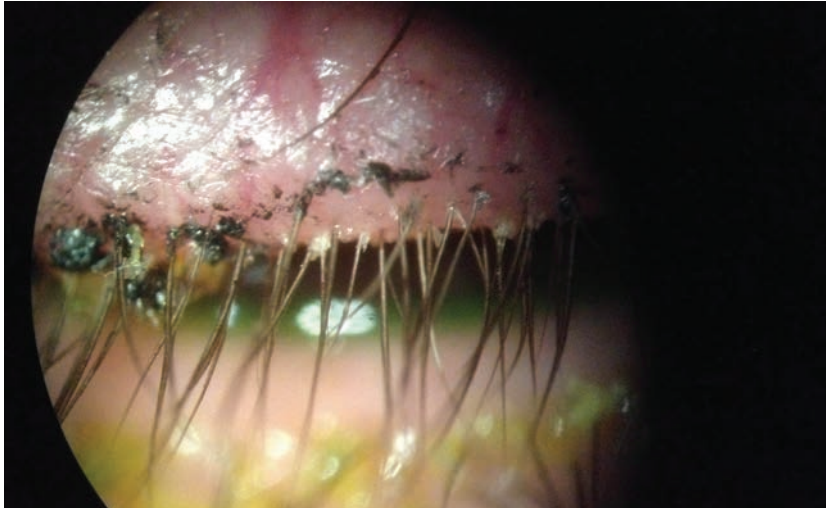
Brought to you by the AOA
 AMERICAN OPTOMETRIC ASSOCIATION

Is your company supporting this important campaign?

If you are interested in joining, contact jtorrey@thinkaboutyoureyes.com

Demodex

Photo: Tressa Larson, OD



A patient whose lid margins display *Demodex* infestation at the base of the lashes.

Cylindrical cuffing along the base of lashes is a pathognomonic finding for *Demodex* infestation.^{6,7} Researchers believe this conical buildup is the combination of the saprophytes' chitinous exoskeleton, in addition to other keratin and lipid debris naturally sloughed from the skin's epithelial layer.^{6,8} If the materials are not removed from the lid margin, irritation results in lid inflammation, demodicosis (blocked follicles and follicular distention) and madarosis.^{1,4-8,15}

Since the presentation of cylindrical dandruff indicates a significant increase in mites along the lash line, proper lid hygiene and stabilization of the *Demodex* population should be initiated upon the first signs of cuffing to prevent additional sequelae. If the patient has already been using lid scrubs in treating misdiagnosed dry eye syndrome and bacterial blepharitis, it's fairly common to not observe any conical cuffing. However, even after proper lid hygiene and complete resolution of lash cuffing, mites can still be hidden within the hair follicle. In fact, one study found that *Demodex* can be left in the follicle even

upon epilation of lashes, which would greatly underestimate the true severity of parasitic infestation under microscopic observation.⁸

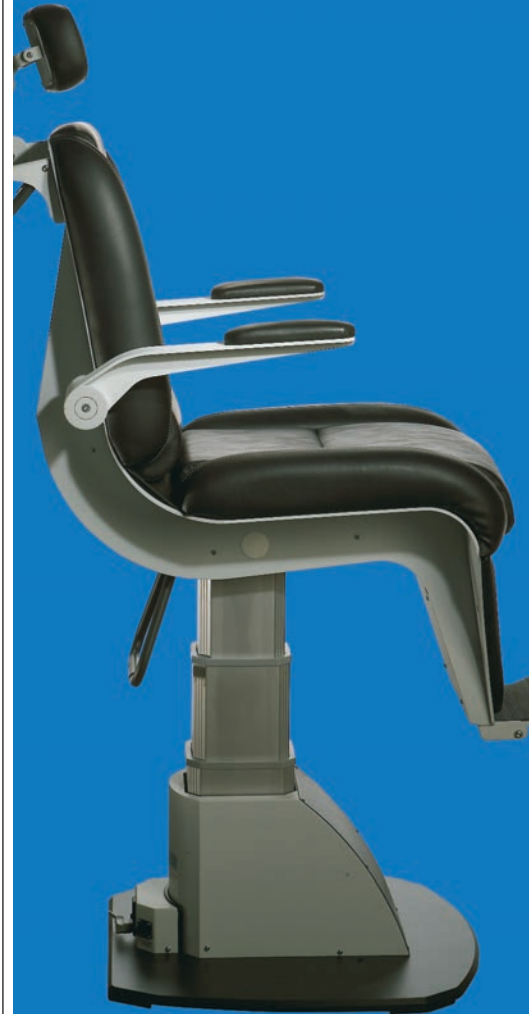Still, a strong indicator of *Demodex* infestation is past unresponsiveness to conventional dry eye treatment. As most dry eye cases are typically due to meibomian gland dysfunction (MGD), careful observation of the eyelid and tear film under slit lamp examination are the key to differentiating between *Demodex* and decreased meibum secretion. Ineffective treatments for removing *Demodex* include ATs, cyclosporine, antihistamines, doxycycline, lid hygiene and baby shampoo—though these treatments may be added to the management plan against bacterial agents that are also contributing to lid inflammation.^{3,6,16}

Delayed proper management can also lead to the progression of more chronic symptoms, such as trichiasis, MGD, chalazia, conjunctivitis and corneal pathologies such as corneal neovascularization, marginal corneal infiltration, phlyctenule-like lesions, superficial corneal opacities and nodular scars.^{4,6-8,15,17}

S4OPTIK

OPHTHALMIC CHAIR 2000

KleenTech Lift System®



Enjoy smooth, virtually
silent lifting with the
Swiss-made KleenTech®
lift system.

Benefit from more than
11" of lift for patients
up to 560lbs.

S4OPTIK

250 Cooper Ave., Suite 100 Tonawanda NY 14150

www.s4optik.com | 888-224-6012

Sensible equipment. Well made, well priced.

For today's modern office.

Treatments

By understanding the natural life cycle of the *Demodex* mites, treatments aimed at eradicating the infestation will be more efficient. Because these ectoparasites are more nocturnal, it is important to limit their ability to reproduce and migrate when they are most active. Ophthalmic ointments, such as erythromycin or Tobradex (tobramycin-dexamethasone, Alcon), along the lid margin, therefore, have been used as a solution to keep *Demodex* from reaching the surface to reproduce or migrate at night. In addition, practitioners often advise patients to start washing their bed-sheets and pillowcases regularly in hopes of preventing reinoculation. In severe cases, patients may even need to consider replacing their pillows altogether.

Combined with a tea tree oil therapy along the lash line, the treatment not only hinders proliferation of mites, but also actively eradicates *Demodex* adults, larvae and eggs.^{16,18,19}

Tea tree oil has been a widely accepted treatment for mite infestation; it offers anti-inflammatory, antimicrobial and antifungal properties to effectively manage not only parasitic but also bacterial blepharitis.^{16,18,19} If *Demodex* truly only acts as a mode for bacterial migration, tea tree oil should still be considered to directly destroy the symbiotic bacteria and parasitic relationship.^{5,6} Investigators found that *D. folliculorum* was resistant to not only antiseptic treatments, including 75% alcohol and 10% povidone-iodine, but also some antimicrobials such as erythromycin and metronidazole.^{4,20}

Tea tree oil, specifically the active ingredient terpinen-4-ol (T4O), was found to be the most effective in both cleaning cylindrical

cal debris from the roots of lashes and stimulating the migration of hidden mites to the surface for eradication.^{4,20} The current option with the highest concentration of terpinen-4-ol is Cliradex (Bio-Tissue).^{4,20} In mild cases, at-home treatments such as Cliradex, Steri-Lid (TheraTears), Blephadex (Lunovus) and Ocusoft scrubs BID are sufficient to decrease the *Demodex* population. These products are available over the counter.

For more stubborn cases, Cliradex Complete (Bio-Tissue) offers a higher concentration (50% T4O) solution for in-office use two to three times in 10-minute intervals. The patient then uses the lower concentration wipes (10% T4O) twice a day at home.⁴ If you note considerable debris and cylindrical dandruff, it may be prudent to mechanically remove the debris prior to treating with tea tree oil. Although the Cliradex Complete pack comes with a microblepharoexfoliator, the BlephEx (RySurg) handheld device may provide a more thorough and efficient removal process in severe cases.

Newer products, such as Avenova (Novabay), for which the main ingredient is Neutrox (pure 0.01% HOCl) rather than tea tree oil, also effectively decrease symptoms, according to a company study.²²

Simply put, the diagnosis of *Demodex* associated eye disease is clinical and relies on observation and the correct interpretation of both ocular surface and accompanying skin manifestations. Though the focus of optometrists is primarily on the health of the eyes and adnexa, it is becoming more evident that we should also be prudent in taking a step back to observe and learn more about the patient's overall condition to collect all pertinent

information for proper diagnosis and treatment. ■

Dr. Roan is a staff optometrist at the Pacific Cataract and Laser Institute in western Washington.

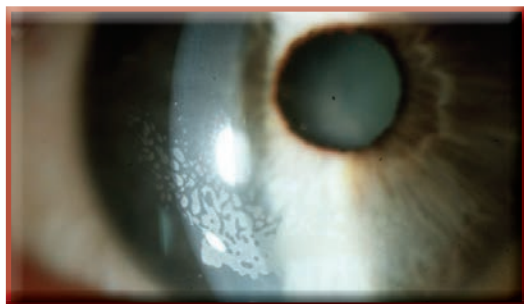

1. Wesolowska M, Knysz B, Reich A, et al. Prevalence of *Demodex* spp. in eyelash follicles in different populations. *Archives of Medical Science*. 2014 May 12;10(2):319-24.
2. Sadowska-Przytocka A, Czarnecka-Operacz M, Jenerowicz D, Grzybowski A. Ocular manifestations of infectious skin diseases. *Clinics in Dermatology*. 2016;34(2):124-8.
3. Hom M, Mastrotta K, Schachter S. *Demodex*. *Optom Vis Sci*. 2013 Jul;90(7):e198-205.
4. Cheng A, Sheha H, Tseng S. Recent advances on ocular *Demodex* infestation. *Curr Opin Ophthalmol*. 2015 Jul;26(4):295-300.
5. Liu J, Sheha H, Tseng S. Pathogenic role of *Demodex* mites in blepharitis. *Curr Opin Allergy Clin Immunol*. 2010 Oct;10(5):505-10.
6. Lacey N, Kavanagh K, Tseng S. Under the lash: *Demodex* mites in human diseases. *Biochem (Lond)*. 2009 Aug 1;31(4):2-6.
7. Gao Y, Di Pascual M, Li W, et al. High prevalence of *Demodex* in eyelashes with cylindrical dandruff. *Invest Ophthalmol Vis Sci*. 2005 Sep;46(9):3089-94.
8. Mastrotta K. Method to identify *Demodex* in the eyelash follicle without epilation. *Optom Vis Sci*. 2013 Jun;90(6):e172-4.
9. Post C, Juhlin E. *Demodex folliculorum* and blepharitis. *Arch Dermatol*. 1963 Sep;88:298-302.
10. Elston D. *Demodex* mites: facts and controversies. *Clin Dermatol*. 2010 Sep-Oct;28(5):502-4.
11. Thoemmes M, Fergus D, Urban J. Ubiquity and diversity of human-associated *Demodex* mites. *PLoS ONE* 2014 Aug 27;9(8):e106265.
12. Zhao Y, Li-Ping W, Li H, Xu J. Association of blepharitis with *Demodex*: a meta-analysis. *Ophthalmic Epidemiol*. 2012 Apr;19(2):95-102.
13. Turk M, Ozturk I, Sener A, et al. Comparison of incidence of *Demodex folliculorum* on the eyelash follicle in normal people and blepharitis patients. *Turkiye Parazitoloj Derg*. 2007;31(4):296-7.
14. Rodriguez A, Ferrer C, Alio J. Chronic blepharitis and *Demodex*. *Arch Soc Esp Oftalmol*. 2005 Nov;80(11):635-42.
15. Vieira A, Mannis M. Ocular rosacea: common and commonly missed. *J Am Acad Dermatol*. 2013 Dec;69(6 Suppl 1):S36-41.
16. Cox S, Mann C, Markham J. Interactions between components of the essential oil of *Melaleuca alternifolia*. *J Appl Microbiol*. 2001 Sep;91(3):492-7.
17. Kheirkhah A, Casas V, Li W, et al. Corneal manifestations of ocular *Demodex* infestation. *Am J Ophthalmol*. 2007 May;143(5):743-9.
18. Hart P, Brand C, Carson C, et al. Terpinen-4-ol, the main component of the essential oil of *Melaleuca alternifolia* (tea tree oil), suppresses inflammatory mediator production by activated human monocytes. *Inflamm Res*. 2000 Nov;49(11):619-26.
19. Thomsen N, Hammer K, Riley T, et al. Effect of habituation to tea tree (*Melaleuca alternifolia*) oil on the subsequent susceptibility of *Staphylococcus* spp. to antimicrobials triclosan, tea tree oil, terpinen-4-ol and carvacrol. *Int J Antimicrob Agents*. 2013 Apr;41(4):343-51.
20. Tighe S, Gao Y, Tseng S. Terpinen-4-ol is the most active ingredient of tea tree oil to kill *Demodex* mites. *Transl Vis Sci Technol*. 2013 Nov;2(7):2.
21. Wollina U. Recent advances in the understanding and management of rosacea. *F1000Prime Rep*. 2014 Jul 8;6:50.
22. Debabov D, Noorbakhsh C, Wang L, et al. Avenova with Neutrox (pure 0.01% HOCl) compared with OTC product (0.02% HOCl). NovaBay Pharmaceuticals, Inc. <http://novabay.com/wp-content/uploads/2015/05/avenova-with-neutrox-first-and-only-product-in-ophthalmology-containing-pure-hypochlorous-acid-compared-with-otc-product.pdf> Accessed: September 14, 2016

*“Educate Patients,
Inspire Positive Behaviors!”*

TelScreen

EyeResTM

Digital Imaging Systems
for slit lamps.



A versatile system:

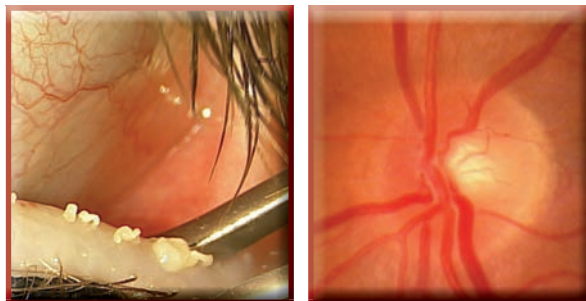
Anterior-segment imaging,
Retinal imaging, and
Infrared imaging from a slit lamp.

Save time, money, and space.

Enhance the patient's experience.

Reap the many benefits of owning
an **EyeRes**TM imaging system.

Call 800.769.4933 today.



Focused on Slit Lamp Digital Imaging since 1993

www.TelScreen.com



Adenoviral Dominos

When doctor becomes patient, how do we mitigate infectious interactions?

Edited by Joseph P. Shovlin, OD

Q My associate contracted a bad adenoviral infection from a patient last week. He's into the second week with multiple subepithelial infiltrates (SEIs) over the visual axis and is symptomatic with blur and discomfort. He also has a conjunctival membrane. How might we have avoided this response and, now that he has it, what treatment do you recommend?

A "The somewhat flippant answer," says Daniel G. Fuller, OD, of Southern College of Optometry, "is by practicing safety precautions and appropriate infection control." Aaron Bronner, OD, of Pacific Cataract and Laser Institute agrees, stating that, "clean examination, proper hand washing and disinfection protocol are the keystones for preventing clinic-based transmission."

An Ounce of Prevention

When examining a patient suspicious for epidemic keratoconjunctivitis (EKC), "gloving up and using a cotton-tipped applicator to manipulate lids rather than ungloved hands is wise," says Dr. Bronner.

"Adenovirus is a hardy virus and, absent appropriate cleaning of the exam room surfaces, it remains a source of potential infection long after the patient has left the clinic," he says. In fact, they can survive for up to 28 days on surfaces, fostering easy contamination and spread.^{1,2}

"Using disposable tonometer tips, using bleach in a 1:10 dilution and isolating infected patients from others prevents spread," Dr. Fuller

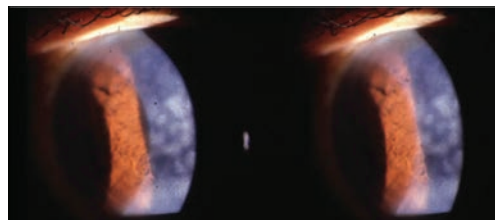
says.² Both ammonia and bleach are effective against adenovirus, but "isopropyl alcohol, while a common office disinfectant, is likely ineffective against adenovirus," Dr. Bronner points out.³ ODs should consider dedicating an exam room for red eyes and disinfect it after each red eye patient.

A Pound of Cure

With EKC, you can treat with supportive therapy (i.e., cool compresses, preservative-free tears and time), or "you could employ one of several off-label approaches in hopes that it may hasten resolution of the infection and reduce late sequelae," says Dr. Bronner.

Adenoviruses are medium-sized (90nm to 100nm), non-enveloped icosahedral viruses with double-stranded DNA, notes Dr. Fuller.¹ "There are more than 50 known serotypes responsible for causing conjunctivitis and upper respiratory, gastrointestinal, cystic and neurological illness, while only a limited number have proven responsible for EKC, pharyngoconjunctival fever and acute hemorrhagic conjunctivitis.^{1,4} Serotypes 8, 19 and 37 are more prevalent in severe presentations of EKC."^{2,4,6}

EKC presents in adults as watery discharge, hyperemia, chemosis, follicles and ipsilateral lymphadenopathy. The more severe forms, says Dr. Fuller, "include SEIs (50%) with concomitant decrease in vision,



Subepithelial infiltrates from a viral conjunctivitis.

Photo: Jeffrey Nymann, OD

petechial hemorrhages, pseudomembrane formation and symblepharon with true membrane formation.^{2,5-8} The infection is considered biphasic with symptoms of inflammation appearing seven to 10 days after infection and a usual course of two to three weeks," he explains.⁹

There is a dearth of FDA-approved interventions, notes Dr. Fuller.¹⁰ "Treatment is supportive for mild forms, and infection control is critical." Multiple off-label interventions have been tried with limited success, including steroids, antiseptics, antivirals, immunosuppressants and interferon.²

Dr. Bronner credits Mark Maraman, OD, for suggesting hypochlorous acid may be an avenue worth considering. Dr. Bronner explains that a group of 14 cases treated with ultrapure hypochlorous acid (0.008%) QID had rapid clearing of signs and symptoms.¹¹ Of all the off-label treatments for EKC, "hypochlorous acid has the least research," he notes, "though I feel it may be a compelling option because, as with povidone-iodine (PI), hypochlorous acid is a potent disinfectant and, as with PI, would only theoretically be effective in the

extracellular phase. But hypochlorous acid is available by prescription and can be dosed at home.”

Both doctors caution against the use of steroids without weighing the risks against the benefits. Several studies show that routine use of steroids for symptomatic relief should be avoided, as they can prolong the time to achieve viral clearance, Dr. Fuller says.¹²⁻¹⁵ However, the doctor mentioned in the question is indeed a severe case, and management with steroids seems the best treatment option, especially considering infiltrates are affecting his vision and membranous changes are causing discomfort. In addition, topical ganciclovir may aid in minimizing spread to the other eye and lessen dry eye complaints.

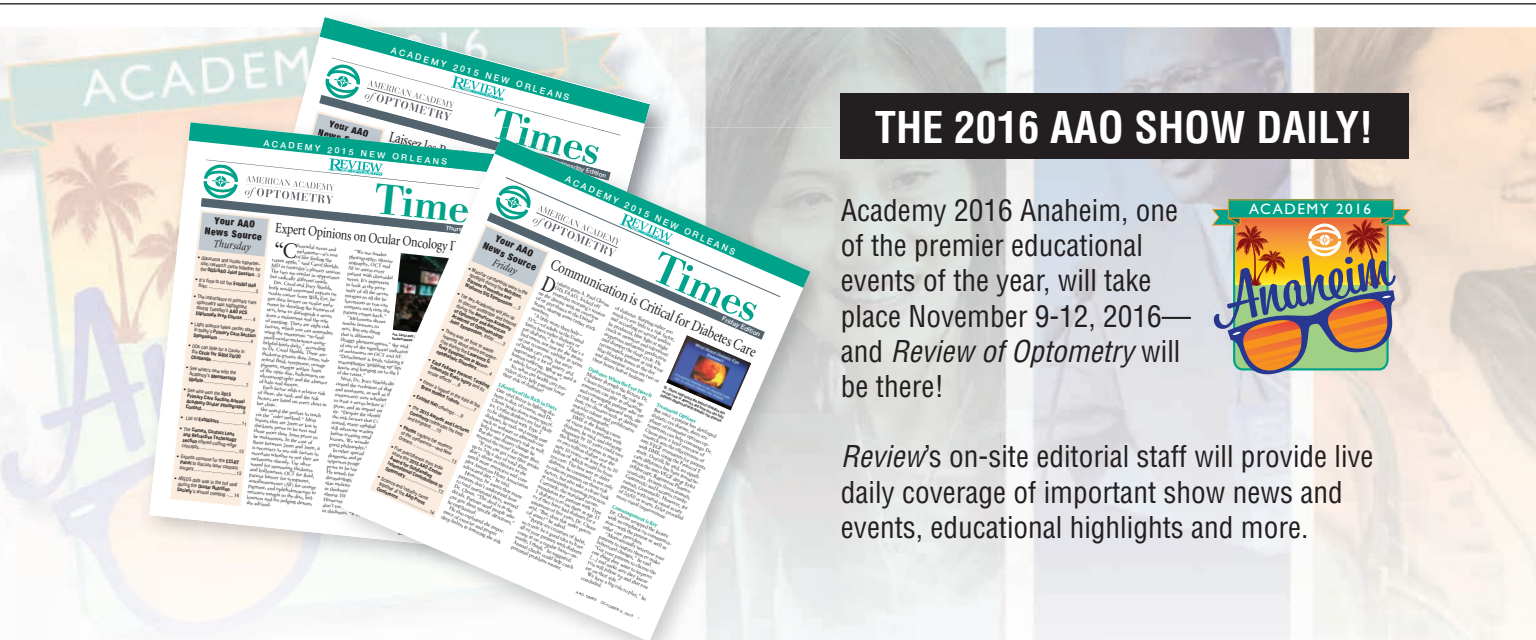“Since your associate has multiple SEIs, any steroid that effectively

penetrates the corneal epithelium is a good way to diminish the lesion,” Dr. Bronner suggests, citing prednisolone acetate 1%, difluprednate and loteprednol etabonate as options. Start steroid treatment “at the first sign of SEIs rather than when multiple lesions are present and the visual axis is heavily involved,” says Dr. Bronner, “to reduce their downstream severity and hasten resolution.”

As a doctor, he should refrain from patient care for 10 to 12 days, and if his eye remains red or there is active tearing, discharge or both, he should stay home. While at home, he should also avoid sharing anything that could transmit the virus, such as towels and washcloths, to avoid intra-familial spread. ■


- Centers for Disease Control. Adenovirus. Clinical Overview. Available at www.cdc.gov/adenovirus/hcp/clinical-overview.html.
- Jhanji V, Chan TCY, Li EYM, et al. Adenoviral keratoconjunctivitis. *Surv Ophthalmol*. 2015;60:435-43.

- Rutala W, Peacock JE, Gergen MF, et al. Efficacy of hospital germicides against adenovirus 8, a common cause of epidemic keratoconjunctivitis in health care facilities. *Antimicrob Agents Chemother*. 2006;50:1419-24.
- Zhang L, Zhao N, Sha J, et al. Virology and epidemiology analyses of global adenovirus-associated conjunctivitis outbreaks, 1953-2013. *Epidemiol Infect*. 2016;144:1661-72.
- Tabbara KF, Omar N, Hammouda E, et al. Molecular epidemiology of adenoviral keratoconjunctivitis in Saudi Arabia. *Molecular Vis*. 2010;16:2132-6.
- González-López JJ, Morcillo-Laiz R, Muñoz-Negrete FJ. Quera-toconjunctivitis adenoviricas: actualización. *Arch Soc Esp Oftalmol*. 2013;88:108-15.
- Chodosh J, Miller D, Stroop WG, Pflugfelder SC. Adenovirus epithelial keratitis. *Cornea*. 1995;14:167-74.
- Dawson CR, Hanna L, Togni B. Adenovirus type 8 infections in the United States. IV. Observations on the pathogenesis of lesions in severe eye disease. *Arch Ophthalmol*. 1972;87:258-68.
- Kaufman HE. Adenovirus advances: new diagnostic and therapeutic options. *Curr Opin Ophthalmol*. 2011;22:290-3.
- Meyer-Rüsenberg B, Loderstädt U, Richard G, et al. Epidemic keratoconjunctivitis: the current situation and recommendations for prevention and treatment. *Dtsch Arzteblatt Int*. 2011;108:475-80.
- Adamson P, Roos H, von Holdt J. Treatment of bacterial and viral conjunctivitis with topical ultrapure stable hypochlorous acid (HCCL): a clinical evaluation and treatment response in 79 cases. Poster presented at ARVO 2015.
- Romanowski EG, Yates KA, Gordon YJ. Topical corticosteroids of limited potency promote adenovirus replication in the Ad5/NZW rabbit ocular model. *Cornea*. 2002;21:289-91.
- Laibson PR, Dhiri S, Oconer J, Ortolan G. Corneal infiltrates in epidemic keratoconjunctivitis. Response to double-blind corticosteroid therapy. *Arch Ophthalmol*. 1970;84:36-40.
- Laibson PR, Green WR. Conjunctival membranes in epidemic keratoconjunctivitis. *Arch Ophthalmol*. 1970;83:100-2.
- Romanowski EG, Roba LA, Wiley L, et al. The effects of corticosteroids of adenoviral replication. *Arch Ophthalmol*. 1996;114:581-5.



THE 2016 AAO SHOW DAILY!

Academy 2016 Anaheim, one of the premier educational events of the year, will take place November 9-12, 2016—and *Review of Optometry* will be there!



Review's on-site editorial staff will provide live daily coverage of important show news and events, educational highlights and more.

Attendees on-site can pick up the *AAO Times* each morning for the latest news and highlights. Those at home can stay in touch, too—a digital edition of the *AAO Times* will be emailed and posted online at www.reviewofoptometry.com.

Show copies will also be available at *Review of Optometry* booth #915.

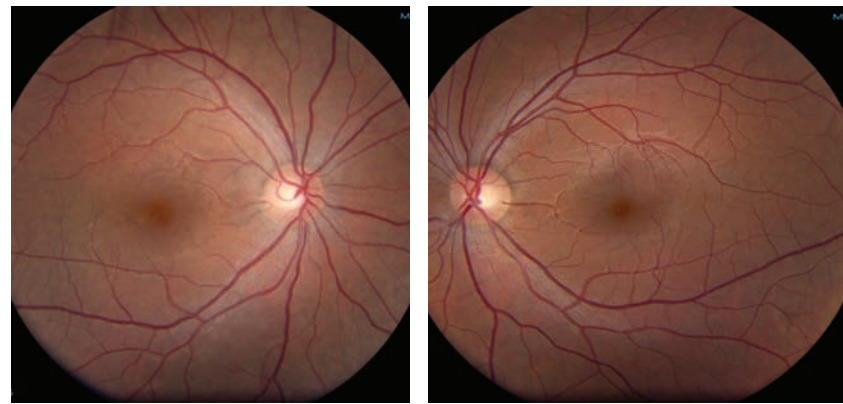


Out, Damned Spot

A young female patient noted missing vision. What do you make of her presentation and test results? **By Leslie Small, OD, and Mark Dunbar, OD**

A 26-year-old female presented with a chief complaint of missing spots in her vision in the right eye, which she first noticed while watching television. She had a two-year history of one to two headaches a week that was unchanged. She had no ocular pain and no headache at the time of her vision loss. Her vitals at the time of exam included a blood pressure of 151/90 and a pulse of 95 BPM. Her general health and previous ocular history was noncontributory.

On examination, her visual acuity measured 20/200 OD and 20/20 OS. Her pupils were equally round and reactive to light. An afferent pupillary defect was seen in the

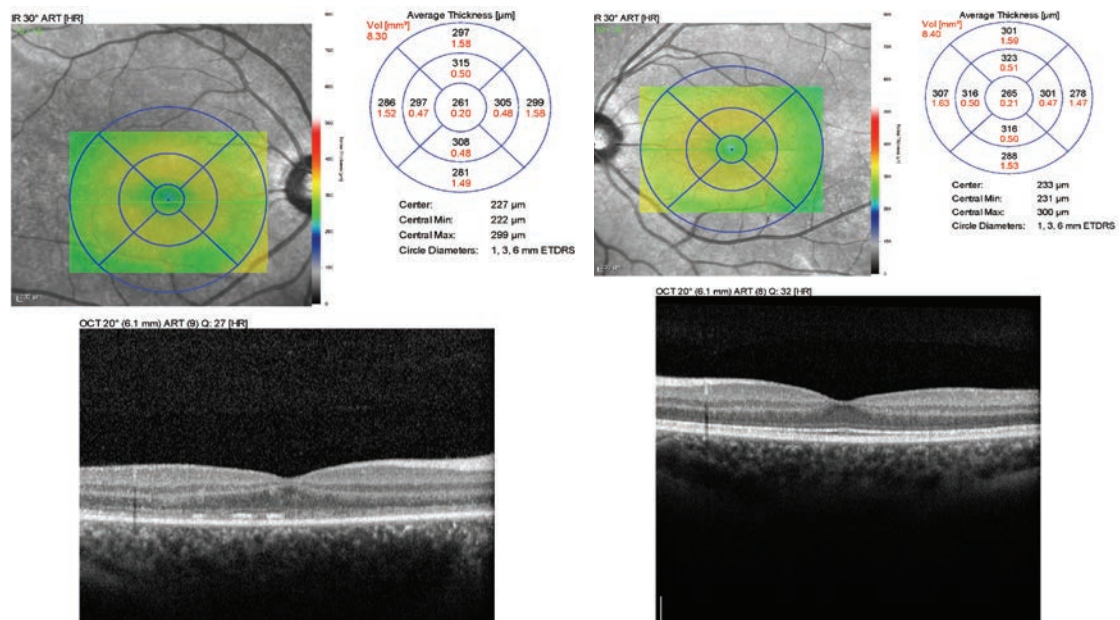



Figs. 1a and 1b. Fundus photos of our 26-year-old female patient's right and left eyes at clinical presentation.

right eye. On color vision testing, she had red desaturation in the right eye by 50%, compared with her left eye, and had decreased light

brightness compared with the left eye. She was unable to decipher the test plate on Ishihara with the right eye and had normal color vision in

Fig. 2. Can you identify any significant findings in either the patient's right (at left) or left macula using these SD-OCT images and data?





Figs. 3. Our patient's visual field test results at initial clinical presentation. Note the findings in the left eye (at right).

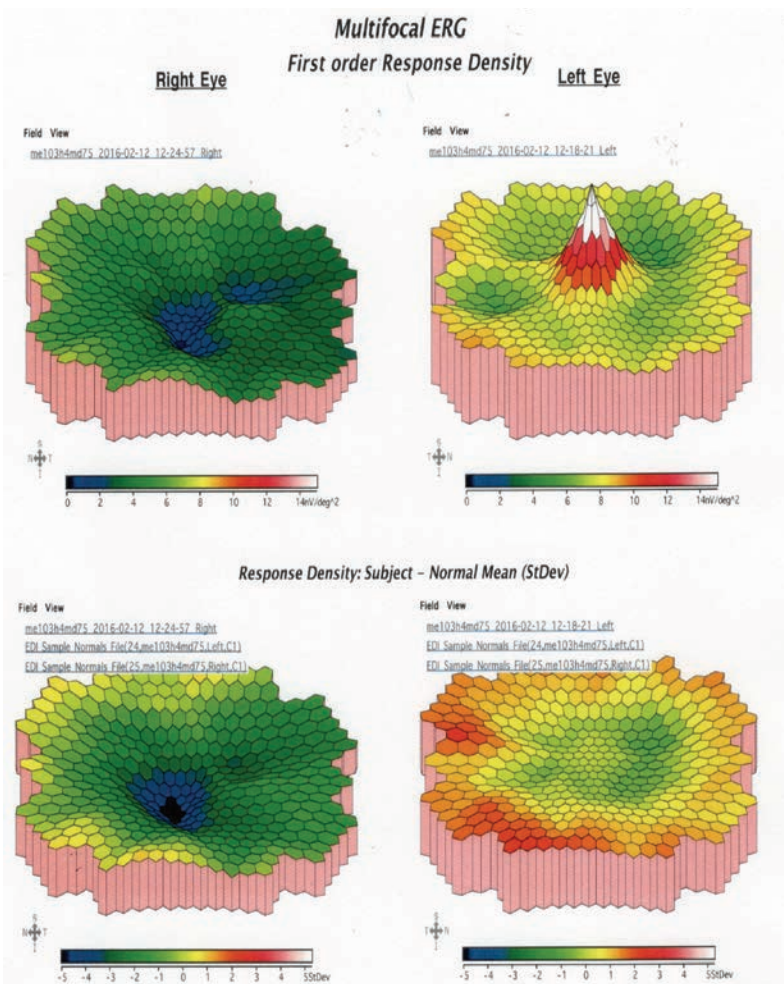


Fig. 4. What information about the macula's health can be gleaned from these multifocal ERG graphics of the right and left eyes?

the left eye. Her extraocular motility was normal, and confrontation visual fields in the right eye were significant for a central scotoma with preserved peripheral vision. The left confrontation visual field was full. The slit lamp exam was unremarkable and intraocular pressure was normal.

On dilated fundus exam, the optic nerves appeared normal. There was no disc edema in either eye, and the macula also looked normal, although there was a reduced fovea light reflex in the right eye (Figure 1).

An OCT (Figure 2), visual field (Figure 3) and multifocal electroretinography (ERG) (Figure 4) and fundus autofluorescence (FAF) (Figure 5) are available for review.

Take the Retina Quiz

- What is the significant OCT finding?
 - Loss of foveal contour.
 - Thickening of the nerve fiber layer in the macula and optic nerve.
 - Disruption of inner segment/outer segment junction and thinning of outer nuclear layer.
 - Accumulation of fluid.
- What does the multifocal ERG show?
 - It is normal.
 - A choroidal excavation.
 - A central depression in the right and normal foveal peak in the left.
 - A normal right eye and hypersensitivity of the left.
- What is the likely diagnosis?
 - Maligner.
 - Cone-rod dystrophy.
 - Acute zonal outer occult retinopathy.
 - Stargardt's macular dystrophy.
- What is the expected prognosis?

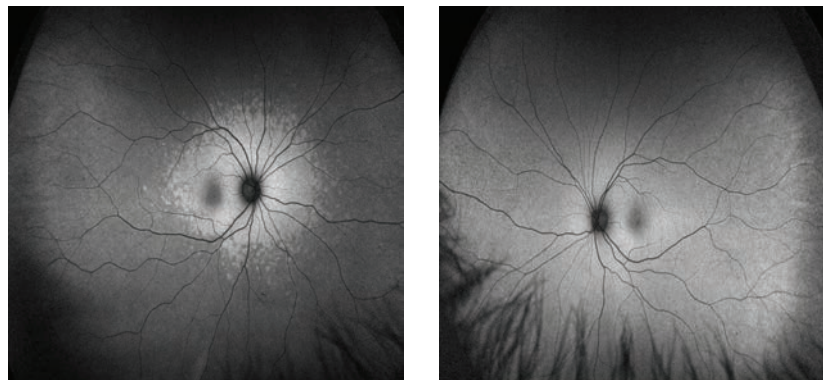


Fig. 5. Note that the right eye (at left) shows patchy hyperautofluorescence around the optic nerve and macula, while the left shows the normal uniformly diffuse autofluorescence in these FAF images.

- Stabilization of the visual field by six months.
- Some improvement of the inner segment/outer segment integrity.
- Persistent visual defect, including scotoma, usually persists.
- All of the above.

Diagnosis

Based on the patient's symptoms and testing, we suspected she had acute zonal occult outer retinopathy (AZOOR). This condition has an unconfirmed etiology, but investigators suspect either a viral or autoimmune cause.¹ AZOOR, first described in 1992, shows a predominance in young women and is characterized by acute photopsias, scotomas and ERG abnormalities with minimal or no fundus findings, minimal or no vitreous cell and normal fluorescein angiography (FA).^{1,2} Investigators found 20% of patients had a viral prodrome.¹ A majority of these patients have vision 20/40 or better, with only 5% of eyes presenting with 20/200 or worse.¹ Changes can be detected on FAF and on OCT that correlate with the field loss and diminished ERG. Due to our suspicion, we acquired mfERG, FAF and FA. Our patient had significant visual field loss in the right eye that correlated with a

central depression on her mfERG (Figure 3). The FAF also showed corresponding increased hyperautofluorescence around the optic nerve and macula (Figure 4). This is common in AZOOR, indicating damage to the RPE.³ The OCT showed marked disruption of the inner segment/outer segment junction in the right eye, suggesting photoreceptor involvement, a consistent finding in AZOOR (Figure 5).³ These abnormalities were all in the setting of a normal fundus exam (Figure 1) and FA. This testing confirmed the diagnosis of AZOOR. As in this case, multimodal imaging is critical for establishing diagnosis.

Management

There is no established treatment for AZOOR, and the natural course of AZOOR is highly variable. Only 26% of cases show visual improvement, and 13% had visual deterioration, according to researchers.¹ Most cases reported had visual field defects that stabilized by six months.^{1,4}

Treatment options include steroid therapy, antiviral therapy and noncorticosteroid immunosuppression. All therapies show limited success.^{1,5} The most commonly used treatment that has shown possible

benefits is steroid therapy.^{1,5} Some studies show that early initiation is critical.⁵ These studies suggest that AZOOR has an inflammatory component involving the photoreceptors and that early initiation of steroid therapy may have a better potential to reverse the natural course.^{1,5}

The difficulty with steroid therapy is that confirmation of the diagnosis often takes significant time and the results become less beneficial with delayed treatment.⁵

With our patient, steroid treatment (40mg oral prednisolone daily) and antiviral therapy of 1g Valtrex (valacyclovir HCL, GlaxoSmithKline) daily was initiated seven days after the start of symptoms. At her six month follow-up from presentation, her exam findings were stable with the exception of visual acuity improvement in the right eye to 20/30 from 20/200, and resolution of her RAPD. She still has a persistent central scotoma, but the patient appreciated subjective significant field improvement. Her FAF showed improvement as well with a decrease in hyperautofluorescence around the macula and nerve. On OCT of the macula, the integrity of her inner segment/outer segment junction had improved. ■

Leslie Small, OD, practices at the Bascom Palmer Eye Institute.

- Monson DM, Smith JR. Acute zonal occult outer retinopathy. *Surv Ophthalmol.* 2011;56:23-35.
- Gass JD. Acute zonal occult outer retinopathy. Donders Lecture: The Netherlands Ophthalmological Society, Maastricht, Holland, June 19, 1992. *J Clin Neuroophthalmol.* 1993;13:79-97.
- Fujiwara T, Imamura Y, Giovinazzo VJ, Spaide RF. Fundus autofluorescence and optical coherence tomographic findings in acute zonal occult outer retinopathy. *Retina.* 2010;30:1206-16.
- Gass JD, Agarwal A, Scott IU. Acute zonal occult outer retinopathy: a long-term follow-up study. *Am J Ophthalmol.* 2002;134:329-39.
- Chen SN, Yang CH, Yang CM. Systemic corticosteroids therapy in the management of acute zonal occult outer retinopathy. *J Ophthalmol.* 2015;2015:793026.
- Matsui Y, Matsubara H, Ueno S, et al. Changes in outer retinal microstructures during six month period in eyes with acute zonal occult outer retinopathy-complex. *PLoS One.* 2014;9:e110592.

Up to
20 CE
Credits*



ANNUAL

WINTER OPHTHALMIC CONFERENCE

A REVIEW OF OPTOMETRY® MEETING OF CLINICAL EXCELLENCE

CE AT ITS PEAK! WORLD CLASS EDUCATION BY LEADING OPTOMETRIC EDUCATORS

Early Bird Special:
\$75 OFF
REGISTRATION
Until Nov. 30, 2016

THE LONGEST RUNNING WINTER CE MEETING IN EYE CARE!

February 17-21, 2017

Aspen, Colorado

LOCATION:

WESTIN SNOWMASS

ALPINE CONFERENCE ROOM

100 Elbert Lane

Snowmass Village, CO 81615

Phone: (970) 923-8200

CONTINUING EDUCATION:

- Earn up to **20** hours of **COPE CE*** Credits
- **Registration Cost - \$575**
- See website for meeting agenda

SPEAKERS:

Andrew Archila, OD

Jack Cioffi, MD

Fred Edmunds, OD

Murray Fingeret, OD

John Flanagan, OD, PhD, FCOptom

Ben Gaddie, OD

Howard Purcell, OD

Jack Schaeffer, OD

Leo Semes, OD



3 WAYS TO REGISTER

E-MAIL: REVIEWMEETINGS@JOBSON.COM **PHONE:** (866) 730-9257

WEBSITE: WWW.SKIVISION.COM

Discounted room rates: \$199-\$389/night

See website for all accommodations and rates

Also available on website: non-educational information including discounted lift tickets and Nastar racing opportunities.

Administered by
Review of Optometry®





Rethinking the Ratio

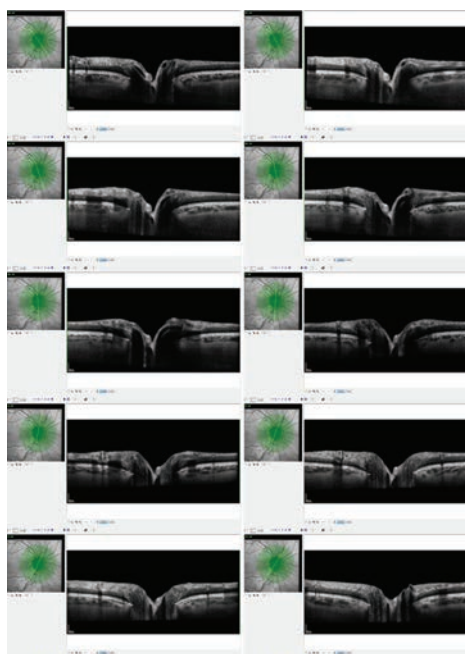Our reliance on cup-to-disc measurements may become a thing of the past once new imaging techniques come to market. **By James L. Fanelli, OD**

In July, *Review of Optometry* celebrated its 125th anniversary. Upon the occasion, I took a look back at decades of published articles on glaucoma and evaluated their clinical relevance today. Now, I'm taking some time to reflect upon the 30 years that I personally have spent in practice. In that era, we've witnessed tremendous changes in glaucoma care—and it's not over yet.

Here, I discuss how glaucoma care has changed in 30 years and what developments currently in the pipeline will become the norm in monitoring these patients in the future.

The Way We Were

When I began practice in 1985, the diagnosis and management of glaucoma was simple. In hindsight, this was probably due to lack of knowledge about the disease's nuances and risk factors complicating matters. Back then, we initiated treatment on patients who had elevated IOPs, suspicious disc findings and visual field defects. In cases where field defects were not detected, we often deferred treatment until an IOP threshold—usually 30mm Hg—was reached. Research already showed black patients generally had larger optic nerves and, therefore, larger optic cups. We also thought that normal tension glaucoma was relatively rare. We didn't yet know the role that corneal thickness played, especially in black patients,



These OCT images show radial scanning of the optic nerve and identify the edge of Bruch's membrane. High resolution of Bruch's membrane opening gives us a true picture of the actual optic canal, and subsequent measurements of the rim with in these areas is precise and repeatable.

nor were we fully on board with the concept of preperimetric glaucoma (glaucomatous damage that was present before visual field aberrations). In fact, the earlier definition of glaucoma as proffered by the American Academy of Ophthalmology included references to elevated IOP, optic nerve damage and visual field defects.¹

Treatment options were limited at that time. Timolol was the workhorse of topical therapy, and Propine (dipivefrin, Allergan) had

only recently been approved. Of course, pilocarpine and other cholinergics were available, although accompanied by associated side effects. Often, patients we treated ended up undertreated, and those we only monitored eventually developed field defects detectable with standard automated perimetry.

Eventually, we recognized that glaucomatous optic neuropathy did occur in the early stages without identifiable visual field loss and, subsequently, the Academy of Ophthalmology changed its definition of glaucoma by removing the recommendation that field defects be present.¹ Given that field testing was subjective and variable in reliability, we tended to rely more on structural appreciation of optic nerve nuances and IOP in determining the presence or absence of glaucoma. Stereoscopic optic nerve photography was considered the gold standard in optic nerve imaging, and it served us well.

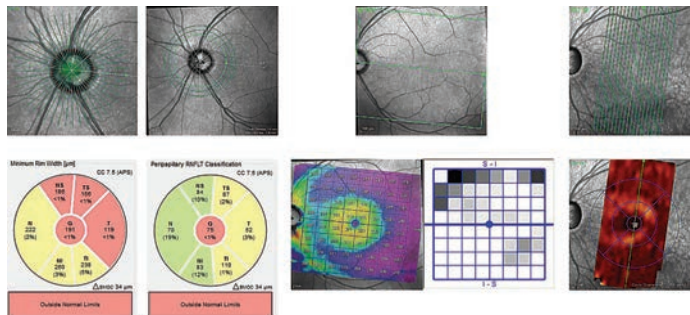
We Have the Technology

The early 90s saw a movement to develop more precise instruments to measure optic nerve characteristics. Visual field testing modifications remained relatively stagnant. Also, when these newer imaging instruments were becoming more common, the results of several well-designed glaucoma risk factor studies began to trickle in. These are now commonly referred to as the "alphabet soup" studies

of glaucoma, due to their names—“The Ocular Hypertension Study (OHTS),” “Advanced Glaucoma Intervention Study (AGIS)” and the “Collaborative Initial Glaucoma Treatment Study (CIGTS),” for example. Further studies on the data they presented have left us with good guidelines on how to evaluate a patient with glaucoma and predict their likelihood of progression.

While the imaging technology began to take on a more precise, objective nature, we as clinicians tended to describe the optic nerve in simple terms related to the relationship between the optic disc and the optic cup; the all too familiar cup-to-disc ratio. While the use of the cup-to-disc ratio was a simple tool to describe some characteristics of the optic disc, we relied too heavily on its documentation. We’ve all had patients for whom we document a cup-to-disc ratio widely different from one visit to another. We may see a nerve and call it 2x2 then, the next time we see the same nerve, call it 1x1. Of course, inter observer variation is even greater. So while we’ve realized that the cup-to-disc ratio has limited practical value, we continue to use it. And even objective instrumentation, whether it’s scanning laser tomography or optical coherence tomography (OCT), usually has some reference to a ‘cup’ and ‘disc’ in one form or another.

With the advent of high resolution OCT technology, some researchers have suggested modify-



This image shows several scanning strategies of the optic nerve useful in glaucoma. Early structural loss can occur in several areas, including the disc itself, in various distances from the optic nerve in the RNFL and the macula. Vertical macular scans may give us a better appreciation for hemispheric asymmetry, and RNFL circle scans of varying diameters may isolate early defects sooner than one RNFL circle scan.

ing our approach to evaluating the optic nerve by including different markers of optic nerve structure, such as Bruch’s membrane opening.

The World of Tomorrow

At the end of the day, anatomy is anatomy. Knowing normal anatomy, and the finer nuances thereof, makes identifying abnormal anatomy much easier.

When we look at a cross section of the optic nerve, all individual ganglion cells (whether there are a million of them or only 100,000), pass from the retinal ganglion cell layer into the optic nerve by passing medial to Bruch’s membrane opening.

So where does this lead the clinician in a glaucoma practice? One study shows rather exquisitely the relationship between the Bruch’s membrane opening (BMO), the internal limiting membrane and the neuroretinal rim of ganglion cells that lies between these two readily identifiable structures.² By identifying the BMO, and the adjacent neuroretinal rim in a series of cross sections through the optic nerve, a viable picture begins to emerge of the volumetric characteristics of the

very ganglion cells we are trying to salvage.

Furthermore, retinal nerve fiber layer (RNFL) circle scans centered around the optic nerve can identify areas of nerve fiber layer thinning corresponding to preferential areas affected in glaucoma.

Likewise, studies show defects in the ganglion cell layer in the macula, indicating early glaucomatous structural loss.

But the central question remains unanswered: where does the structural loss initially occur? In the macula? In the peripapillary RNFL? How far away from the center of the optic disc should we measure the RNFL? Does it occur first in the neuroretinal rim in the optic disc adjacent to Bruch’s membrane opening? We don’t know the precise answer yet—my guess is that it can occur in any of these locations first, probably governed by individual patient characteristics. With that being the case, we need to image all these areas.

Functionally, some newer perimetry strategies and instruments better correlating with early detection are evolving. We will be seeing more developments in the next few years, as more data comes in pertaining to new, more reliable scanning techniques. Eventually, we will begin easing away from the cup-to-disc terminology that we’ve held on to for decades. ■

1. Glaucoma Research Foundation. What is the definition of glaucoma? Available at: www.glaucoma.org/q-a/what-is-the-definition-of-glaucoma.php. Updated: August 27, 2012. Accessed: September 1, 2016.

2. Reis A, Sharpe G, Yang H, et al. Optic disc margin anatomy in patients with glaucoma and normal controls with spectral domain optical coherence tomography. *Ophthalmology*. 2012 Apr;119(4):738-47.



Where's the Culture?

Practical recommendations for managing keratitis.

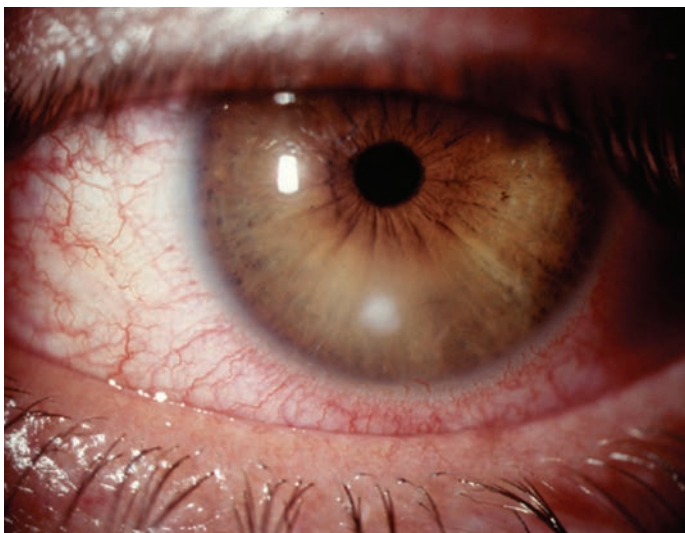By **Joseph W. Sowka, OD, and Alan G. Kabat, OD**

Infectious keratitis is a common condition that carries a high risk of visual morbidity. Often, these patients present with a painful red eye and varying vision loss following an injury to the cornea or, perhaps, a contact lens related mishap. Epithelial disruption and focal stromal infiltration with edema are hallmark findings of infectious keratitis.

Optometrists and comprehensive ophthalmologists have grown accustomed to success with fluoroquinolone antibiotics in managing mild and moderate cases. Unfortunately, things don't always go according to plan, even with these superior antibiotics. Patterns of bacterial resistance have begun to develop.

While bacteria are the most common cause of infectious keratitis, fungal and protozoan infections do occur, and delays in diagnosis often result in a poorer visual outcome, especially if topical corticosteroids are used adjunctively with an ineffective antibiotic. In the past several years, one of the most common causes of malpractice litigation against optometrists that we have seen is alleged mismanagement of infectious keratitis.

There are various approaches to managing suspected bacterial keratitis. Some use fluoroquinolones,



Small noncentral corneal ulcers such as this are typically treated successfully empirically, while larger or more sight-threatening lesions may require culturing.

while others use fortified antibiotics. Some rely on topical steroid adjuncts, while others opt for no steroids. While some use microbiologic studies, others employ empiric therapy.

Of course, few can argue against a good outcome. When the outcome is poor, such as in the case of resistant bacteria, or a fungal or protozoan cause, litigation becomes a possibility.

In cases where we have defended our colleagues in these situations, invariably the plaintiff's attorney will ask at some point in the deposition, "where are the culture results?"

In this column, we look at practical management of infectious keratitis.

Treatment Methods

Historically, bacterial keratitis management involved the combined use of two fortified antibiotics, usually an alternating regimen of cefazolin 10% and an aminoglycoside, such as tobramycin 1.5%. These medications are developed from parenteral forms in a compounding pharmacy and used off-label. They can be challenging to obtain, have a limited shelf

life and can be quite corneotoxic.

Unquestionably we have become comfortable with the success of the newer fluoroquinolone antibiotics. Many have replaced fortified antibiotic use with later generation fluoroquinolones due to their availability, tolerability and effectiveness. In a study comparing gatifloxacin 0.3% with fortified tobramycin and cefazolin in treating bacterial keratitis, investigators report that fluoroquinolone monotherapy was equivalent to fortified combination therapy.¹ A similar study individually comparing both moxifloxacin 0.5% and gatifloxacin 0.3% with combined fortified cefazolin and tobramycin in bacterial corneal ulcers ranging in size from 2mm to 8mm found

no difference in clinical cure rates, with fluoroquinolone monotherapy performing as successfully as fortified polytherapy.² Moxifloxacin 0.5% was also seen in another report to have the same healing success as fortified polytherapy.³ While no data from prospective, controlled, human clinical trials is available regarding the specific use of besifloxacin for bacterial keratitis, several publications advocate for this agent as a safe and effective therapy.^{4,5}

In the Literature

The success of later generation fluoroquinolone monotherapy has changed how practitioners approach cases of suspected bacterial keratitis. A report surveying ophthalmologists in a four-state area found that most respondents initiate empiric therapy with the newer fluoroquinolone antibiotics for corneal ulcers, forgoing Gram staining and culturing.⁶

In another survey, a minority of corneal ulcers were Gram stained or cultured, though cornea specialists were more likely to perform both. The most popular antibiotic for the treatment of less severe ulcers was moxifloxacin, while the most popu-

lar treatment of more severe ulcers was a fortified broad-spectrum antibiotic. Cornea specialists were more likely than noncornea specialists to prescribe fortified antibiotics instead of later generation fluoroquinolones for more severe corneal ulcers.⁷

Despite longstanding recommendations to stain and culture cases of presumed infectious keratitis, approximately half of all comprehensive ophthalmologists have long forgone microbiologic study in favor of empiric treatment.⁸

Formal microbiologic evaluation of microbial keratitis involves multiple corneal scrapings for samples to culture on various growth media such as chocolate agar, 5% sheep blood agar with Columbia agar base (SBA), Gram stain, Sabouraud agar, thioglycolate broth and brain heart infusion broth.⁹ This culturing method increases the probability of recovering a responsible pathogen from corneal tissue, which has a relatively low microbial load. It is not, however, cost effective for most eye care practitioners.

Obtaining and maintaining fresh, unexpired media, storing and transporting it properly is costly and can be a deterrent for many.

Other Methods

An alternative to directly plating corneal scrapings involves commercially available swab systems that employ a transport medium designed to keep organisms viable until a lab can inoculate appropriate media. With this method, a rayon swab is rolled or rubbed across the infiltrate in order to collect organisms. It is then placed into a tube containing transport media such as Amies agar gel or modified Stuart's medium. The transport medium presumably now carrying the organism is then sent to a lab and plated onto the appropriate substrates.

One such commercially available device is the BD CultureSwab (Becton-Dickinson).¹⁰ Another is the ESwab (Copan Diagnostics). Whichever brand you choose, the nylon-tipped swab uses spray-on flocked fiber technology, improving sample collection and specimen release, with less entrapment than dacryon, rayon and cotton tips. The swab uses modified Amies medium, which maintains sample viability for 48 hours and has a shelf-life of 18 months.⁹ These swab-based transport media are inexpensive and an account with a local lab can easily be set up to facilitate pick up of specimens with subsequent analysis.

Of course, it is incumbent upon the practitioner to know which cultures or other tests are standard for their given lab, and which additional tests may be pertinent to the case, such as a fungal culture or antimicrobial sensitivities. *Table 1* lists some of the more common options for corneal specimens.

Despite their ease of use, these devices have been historically avoided due to a perception of ineffectiveness and low recovery or organisms in a condition that typically yields extremely few inocula

Table 1. Culture Testing Options

CPT Code	Description
87070	Culture, bacterial; any other source except urine, blood or stool, with isolation and presumptive identification of isolates.
87076	Anaerobic isolate, additional methods required for definitive identification of isolates.
87081	Culture, presumptive, pathogenic organisms, screening only.
87106	Culture, fungi, definitive identification, each organism; yeast.
87107	Culture, fungi, definitive identification, each organism; mold.
87118	Culture, mycobacterial, definitive identification, each isolate.
87184	Susceptibility studies, disk method, per plate (12 or fewer agents).
87205	Smear, primary source with interpretation; Gram or Giemsa stain for bacteria, fungi or cell types.

Therapeutic Review

even when using corneal scrapings. However, these fears may be unfounded. Investigators report transport media using these commercially available kits are quite successful in identifying infectious organisms in cases of keratitis, in some cases matching that seen with traditional culturing methods.⁹⁻¹¹

Even with the ease and effectiveness of the simplified microbiological specimen collection devices, many cases of suspected infectious keratitis will still be treated empirically. Most do not advocate microbiologic study on every case of suspected infectious keratitis, but those with the greatest potential for vision loss should be considered for evaluation. A guide to identifying ulcers at risk of vision loss is the “1, 2, 3” rule. To identify potentially

sight-threatening ulcers, any one of the following characteristics must be present:

1. > Cells 1+ in the anterior chamber (10 cells or greater in 1mm beam);
2. Dense infiltrate greater than 2mm in greatest linear dimension (by slit-lamp light measurement);
3. Edge of infiltrate smaller than 3mm from the center of cornea.¹²

Infectious keratitis is a potentially sight-threatening issue with several diagnostic and therapeutic approaches. Commercially available later generation fluoroquinolones and one-step culturing devices can help obtain a successful outcome for patients. ■

1. Sharma N, Arora T, Jain V, et al. Gatifloxacin 0.3% versus fortified tobramycin-cefazolin in treating nonperforated bacte-

rial corneal ulcers: randomized, controlled trial. *Cornea*. 2016;35(1):56-61.

2. Shah V, Tandon R, Satpathy G, et al. Randomized clinical study for comparative evaluation of fourth-generation fluoroquinolones with the combination of fortified antibiotics in the treatment of bacterial corneal ulcers. *Cornea*. 2010;29(7):751-7.

3. Sharma N, Goel M, Bansal S, et al. Evaluation of moxifloxacin 0.5% in treatment of nonperforated bacterial corneal ulcers: a randomized controlled trial. *Ophthalmology*. 2013;120(6):1173-8.

4. Mah F, Santilippo C. Besifloxacin: efficacy and safety in treatment and prevention of ocular bacterial infections. *Ophthalmol Ther*. 2016 June;5(1):1-20.

5. Schechter B, Parekh J, Trattler W. Besifloxacin ophthalmic suspension 0.6% in the treatment of bacterial keratitis: a retrospective safety surveillance study. *J Ocul Pharmacol Ther*. 2015 Mar;31(2):114-21.

6. Hsu H, Nacker R, Song J, et al. Community opinions in the management of corneal ulcers and ophthalmic antibiotics: a survey of four states. *Eye Contact Lens*. 2010;36(4):195-200.

7. Park J, Lee K, Zhou H, et al. Community practice patterns for bacterial corneal ulcer evaluation and treatment. *Eye Contact Lens*. 2015;41(1):12-8.

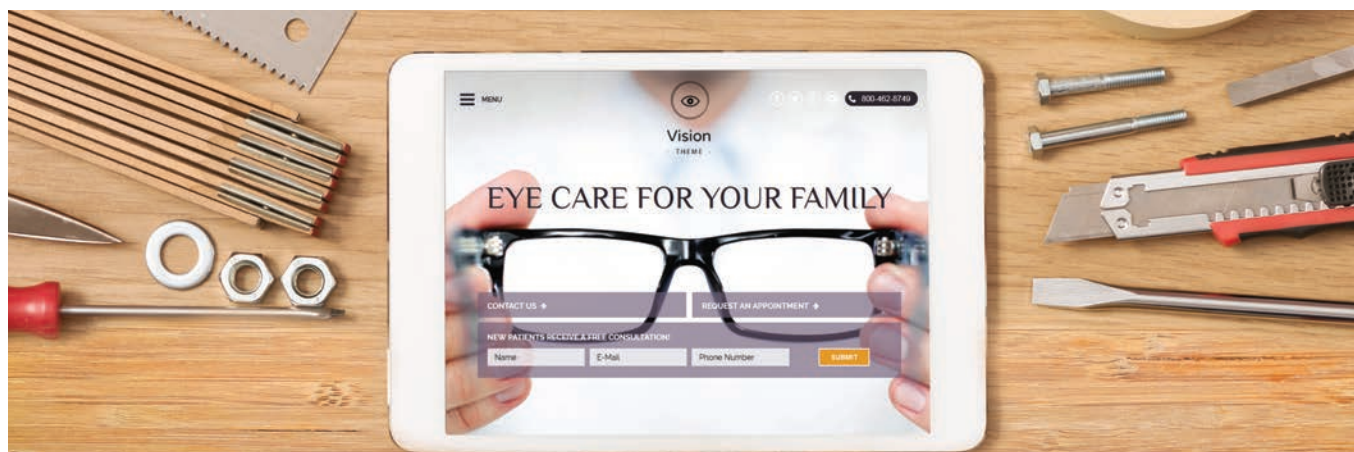8. McDonnell P, Nobe J, Gauderman W, et al. Community care of corneal ulcers. *Am J Ophthalmol*. 1992;114(5):531-8.

9. Pakzad-Vaezi K, Levasseur S, Schendel S, et al. The corneal ulcer one-touch study: a simplified microbiological specimen collection method. *Am J Ophthalmol*. 2015;159(1):37-43.

10. Epley K, Katz H, Herling I, Lasky J. Platinum spatula versus mini-tip culturette in culturing bacterial keratitis. *Cornea*. 1998;17(1):74-8.

11. McLeod S, Kumar A, Cevallos V, et al. Reliability of transport medium in the laboratory evaluation of corneal ulcers. *Am J Ophthalmol*. 2005;140(6):1027-31.

12. Vital M, Bellosso M, Prager T, Lanier J. Classifying the severity of corneal ulcers by using the “1, 2, 3” rule. *Cornea*. 2007;26(1):16-20.



iMatrix Gives You the Tools for Success

📄 Paid Advertising

📺 HD Video

🔍 SEO

📊 Reputation Tracking

Thanks to iMatrix online marketing solutions, you can have all the tools you need to rank highly on Google's first page and get more new patients through your practice doors.

Bonus! Receive 40% off initial setup!

📞 877.424.8014 or visit us at
🌐 go.imatrix.com/RO_Print

imatrix™

ACCREDITED BUSINESS

Google Partner



It's not too late to still support the Challenge



Your gift,
her vision
for life

Photo courtesy Brian Holden Vision Institute

✓ Make a donation by October 30th

Visit givingsight.org or call 888-OGS-GIVE



OPTOMETRYGIVINGSIGHT

Transforming lives through the gift of vision

proud supporters of



givingsight.com

Advertisers Index

For advertising opportunities contact:

Michele Barrett (215) 519-1414 or mbarrett@jobson.com
 James Henne (610) 492-1017 or jhenne@jobson.com
 Michael Hoster (610) 492-1028 or mhoster@jobson.com

Alcon Laboratories 11, 45
 46, 105, 108
 Phone (800) 451-3937
 Fax (817) 551-4352

Akorn Pharmaceuticals 33
 Phone (800) 932-5676
 www.akorn.com

Bausch + Lomb 15
 16-17, 37
 Phone (800) 323-0000
 Fax (813) 975-7762

CooperVision 107
 Phone (800) 341-2020

DGH Technology, Inc. 18
 Phone (800) 722-3883
 Fax (610) 594-0390
 info@dghkoi.com
 www.dghkoi.com

Essilor of America 19
 www.essilorusa.com

Icare USA 12
 Phone (888) 389-4022
 www.icare-usa.com

Keeler Instruments 5, 51
 Phone (800) 523-5620
 Fax (610) 353-7814

Lacrimedics, Inc 32
 Phone (800) 367-8327
 Fax (253) 964-2699
 info@lacrimedics.com
 www.lacrimedics.com

Lombart Instruments 75
 Phone (800) 446-8092
 Fax (757) 855-1232

Macular Health 76-77
 Phone (800) 980-6551
 Fax (205) 608-0955
 www.MacularHealth.com
 customerservice@macularhealth.com

Marchon 7, 9
 Phone (800) 645-1300
 Fax (800) 544-1334

Natural Ophthalmics, Inc.
 35 A-P
 Phone (877) 220-9710
 info@natoph.com
 www.natoph.com

NovaBay Pharmaceuticals, Inc. 23
 Phone (800) 890-0329
 sales@avenova.com
 www.avenova.com

Odyssey Medical (now part of Beaver-Visitec International, Inc.) 10
 Phone (866) 906-8080
 www.odysseymed.com

Reichert Technologies 53
 55, 57
 Phone (888) 849-8955
 Fax (716) 686-4545
 www.reichert.com

S4OPTIK 79, 81, 83
 Phone (888) 224-6012

Shire Ophthalmics 2-3
 www.shire.com

Sun Ophthalmics 25
 SunIsOnTheRise.com

TearScience 59
 Phone (919) 459-4891
 Fax (919) 467-3300

TelScreen 85
 www.TelScreen.com
 DryEye@TelScreen.com

Topcon Medical Systems
 38-39
 Phone (800) 223-1130
 Fax (201) 599-5250

Veatch 61, 63, 65
 Phone (800) 447-7511
 Fax (602) 838-4934

Volk Optical, Inc. 29
 Phone (800) 345-8655
 Fax (440) 942-2257

This advertiser index is published as a convenience and not as part of the advertising contract. Every care will be taken to index correctly. No allowance will be made for errors due to spelling, incorrect page number, or failure to insert.

UNITED STATES POSTAL SERVICE® Statement of Ownership, Management, and Circulation (Requester Publications Only)

1. Publication Title: *Review of Optometry*
 2. Publication Number: *087-350*
 3. Filing Date: *9/16/2016*
 4. Issue Frequency: *Monthly*
 5. Number of Issues Published Annually: *12*
 6. Annual Subscription Price (Per copy): *\$56.00*
 7. Complete Mailing Address of Known Office of Publication (Not printer) (Street, city, county, state, and ZIP+4®):
*Jobson Medical Information
 100 Avenue of the Americas, 9th Floor
 New York, NY 10013*
 Contact Person: *Hamilton Meher*
 Telephone (include area code): *212-274-7038*
 8. Complete Mailing Address of Headquarters or General Business Office of Publisher (Not printer):
*Jobson Medical Information
 100 Avenue of the Americas, 9th Floor
 New York, NY 10013*
 9. Full Names and Complete Mailing Addresses of Publisher, Editor, and Managing Editor (Do not leave blank):
 Publisher (Name and complete mailing address):
*James Henne, Publisher
 Jobson Medical Information
 11 Campus Blvd, Suite 100, Newtown Square, PA 19073*
 Editor (Name and complete mailing address):
*Jack Pericco, Editor-in-Chief
 Jobson Medical Information
 11 Campus Blvd, Suite 100, Newtown Square, PA 19073*
 Managing Editor (Name and complete mailing address):
*William Kekeviyan, Senior Editor
 Jobson Medical Information
 11 Campus Blvd, Suite 100, Newtown Square, PA 19073*
 10. Owner (Do not leave blank. If the publication is owned by a corporation, give the name and address of the corporation immediately followed by the names and addresses of all stockholders owning or holding 1 percent or more of the total amount of stock. If not owned by a corporation, give the names and addresses of the individual owners. If owned by a partnership or other unincorporated firm, give its name and address as well as those of each individual owner. If the publication is published by a nonprofit organization, give its name and address.)
 Full Name: *Jobson Medical Information*
 Complete Mailing Address: *100 Avenue of the Americas
 New York, NY 10013*
 11. Known Bondholders, Mortgagees, and Other Security Holders Owning or Holding 1 Percent or More of Total Amount of Bonds, Mortgages, or Other Securities. If none, check box None
 Full Name: _____ Complete Mailing Address: _____
 12. Tax Status (For completion by nonprofit organizations authorized to mail at nonprofit rates) (Check one)
 The purpose, function, and nonprofit status of this organization and the exempt status for federal income tax purposes:
 Has Not Changed During Preceding 12 Months
 Has Changed During Preceding 12 Months (Publisher must submit explanation of change with this statement)
 PS Form 3526-R, July 2014 (Page 1 of 4) (See instructions page 4) PSN: 7530-09-000-8855 PRIVACY NOTICE: See our privacy policy on www.usps.com

13. Publication Title: *Review of Optometry*
 14. Issue Date for Circulation Data Below: *August 2016*
 15. Extent and Nature of Circulation: *Monthly*

		Average No. Copies Each Issue During Preceding 12 Months	No. Copies of Single Issue Published Nearest to Filing Date
a. Total Number of Copies (Net press run)		43,510	43,260
b. Legitimate Paid and/or Requested Distribution (By mail and outside the mail)	(1) Outside County Paid/Requested Mail Subscriptions stated on PS Form 3541. (Include direct written request from recipient, telemarketing, and internet requests from recipient, paid subscriptions including nominal rate subscriptions, employer requests, advertiser's proof copies, and exchange copies.)	38,919	39,202
	(2) In-County Paid/Requested Mail Subscriptions stated on PS Form 3541. (Include direct written request from recipient, telemarketing, and internet requests from recipient, paid subscriptions including nominal rate subscriptions, employer requests, advertiser's proof copies, and exchange copies.)	0	0
	(3) Sales Through Dealers and Carriers, Street Vendors, Counter Sales, and Other Paid or Requested Distribution Outside USPS®	451	604
	(4) Requested Copies Distributed by Other Mail Classes Through the USPS (e.g., First-Class Mail®)	0	0
c. Total Paid and/or Requested Circulation (Sum of 15b (1), (2), (3), and (4))		39,370	39,806
d. Non-requested Distribution (By mail and outside the mail)	(1) Outside County Nonrequested Copies Stated on PS Form 3541 (include sample copies, requests over 3 years old, requests induced by a premium, bulk sale and requests including association requests, names obtained from business directories, lists, and other sources)	3,601	3,120
	(2) In-County Nonrequested Copies Stated on PS Form 3541 (include sample copies, requests over 3 years old, requests induced by a premium, bulk sales and requests including association requests, names obtained from business directories, lists, and other sources)	0	0
	(3) Nonrequested Copies Distributed Through the USPS by Other Classes of Mail (e.g., First-Class Mail, nonrequester copies mailed in excess of 10% limit mailed at Standard Mail® or Package Services rate)	253	90
	(4) Nonrequested Copies Distributed Outside the Mail (include pickup stands, trade shows, showrooms, and other sources)	0	0
e. Total Nonrequested Distribution (Sum of 15d (1), (2), (3) and (4))		3,853	3,210
f. Total Distribution (Sum of 15c and e)		43,223	43,016
g. Copies not Distributed (See Instructions to Publishers #4, (page 43))		286	244
h. Total (Sum of 15f and g)		43,510	43,260
i. Percent Paid and/or Requested Circulation (15c divided by 15f times 100)		91.08%	92.54%

* If you are claiming electronic copies, go to line 16 on page 3. If you are not claiming electronic copies, skip to line 17 on page 3.

UNITED STATES POSTAL SERVICE® Statement of Ownership, Management, and Circulation (Requester Publications Only)

16. Electronic Copy Circulation

		Average No. Copies Each Issue During Preceding 12 Months	No. Copies of Single Issue Published Nearest to Filing Date
a. Requested and Paid Electronic Copies			
b. Total Requested and Paid Print Copies (Line 15c) + Requested/Paid Electronic Copies (Line 16a)			
c. Total Requested Copy Distribution (Line 15f) + Requested/Paid Electronic Copies (Line 16a)			
d. Percent Paid and/or Requested Circulation (Both Print & Electronic Copies) (16b divided by 15f x 100)			

I certify that 50% of all my distributed copies (electronic and print) are legitimate requests or paid copies.

17. Publication of Statement of Ownership for a Requester Publication is required and will be printed in the *October 15, 2016* issue of this publication.

18. Signature and Title of Editor, Publisher, Business Manager, or Owner: *James P. Henne Group Publisher* Date: *9/19/2016*

I certify that all information furnished on this form is true and complete. I understand that anyone who furnishes false or misleading information on this form or who omits material or information requested on the form may be subject to criminal sanctions (including fines and imprisonment) and/or civil sanctions (including civil penalties).



Say Goodbye to Readers

Your presbyopes looking for something better than monovision should consider the Kamra corneal inlay. **By Sondra Black, OD**

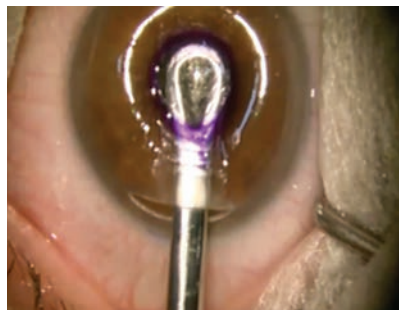Presbyopes are always looking for options to eliminate the need for reading glasses. Historically, there were very limited surgical options for the presbyope with a clear lens until the advent of the Kamra corneal inlay (AcuFocus).

The device uses pinhole optics to increase a patient's depth of focus, improving vision at intermediate and near while still maintaining distance vision. It is a donut shaped disc 3.8mm in diameter with a 1.6mm aperture and a thickness of roughly 5 μ m. It has 8400 micro perforations for corneal nutrient flow and is made of PVDF. Placement is approximately 250 μ m deep in the corneal stroma of the patient's non-dominant eye using a femtosecond-created pocket and is centered on the visual axis.¹

The Right Patient Population

The ideal candidate is emmetropic in the dominant eye and mildly myopic in the nondominant. Around -0.50D to -0.75D is ideal, according to FDA data.¹ Patients may be naturally emmetropic, post-refractive, pseudophakic with a monofocal implant or have refractive surgery to achieve the ideal target.

A Kamra patient needs to have a clear lens, healthy cornea and a good tear film. Patients who are not good candidates for any other type of refractive surgery are likely not



The surgeon places the Kamra corneal inlay and then waits for it to settle and adhere to the corneal stroma.

good candidates for this procedure. As with any type of refractive surgery, stabilizing the tear film prior to surgery is crucial, as it affects visual outcome and patient satisfaction.

Surgical Process

Prior to surgery, the patient will be measured on the Acutarget HD (AcuFocus) to check for optical scatter (lens dysfunction), provide a dynamic tear film assessment and determine proper placement.

Using a surgical microscope, the surgeon will mark the Purkinje, create the pocket using a femtosecond laser and insert the inlay centering around the marking.

Postop

After the procedure, patients are placed on an antibiotic, a three-month minimum course of steroids and regular use of artificial tears. At three months if the patient is healing well and vision is good, the drops may be discontinued. If any issues persist, drops may be continued for an extended period of time. Every

surgeon has a different drop regime, so comanaging optometrists should check with the surgery center on its protocol. We have found putting patients on a cyclosporine drop preoperatively and postoperatively helps speed up visual recovery.

Patients should expect a slow visual recovery, with the majority of patients comfortably reading and seeing well at distance by one month. Roughly 20% of our patients notice immediate near vision improvement, while the remaining 80% take a few weeks to a few months to read comfortably.

Advantages

With the Kamra inlay, the patient is fully binocular at distance. Even though the average patient is mildly myopic, the pinhole effect improves vision, giving them distance vision, as well as near. This eliminates the imbalance monovision patients often complain about. Additionally, as the inlay is based on small-aperture optics, the reading will maintain as presbyopia progresses.

The Kamra inlay is an excellent option for well-selected presbyopic patients who are not ready for a lens-based procedure. I've had it for more than three years and have yet to use reading glasses. ■

Dr. Black is vice president and clinical director at Crystal Clear Vision in Toronto, where she examines and counsels patients seeking refractive surgery, including laser, corneal and lenticular procedures.

1. Kamra Inlay. AcuFocus. Available at www.acufocus.com/us/products/kamra-inlay. Accessed September 16, 2016.



To see a video of this procedure, visit www.reviewofoptometry.com, or scan the QR code.

Merchandise Offered

☰

**CREATE
BUILD
INSPIRE**

EYEDESIGNS
CUSTOM INTERIORS + FURNITURE *group*

WWW.EYEDESIGNS.COM
800.346.8890

AAOPT BOOTH 524
AAO

LUM
ORVOJ opticaldisplays.com



Contact Lenses

Impressions

Color Contact Lens

Unleash your true color!

Amethyst	* Brown	* Grey	* Green	
Turquoise	* Hazel	* Honey	* Pure Hazel	* True Sapphire

Impressions colored contacts blend naturally with your patients eyes to create a beautiful look. Available in nine dazzling opaque colors of which Brown, Grey, Green, Hazel, Honey, Pure Hazel and True Sapphire are available in RX PL to -8.00. Impressions are fun, hip, fashionable and very competitively priced to help your bottom line. POP materials and posters are available upon request.

Available Exclusively at
National Lens
1-866-923-5600
1-866-923-5601 Fax
www.national-lens.com

Merchandise Offered

0% Interest

\$0 Deposit

\$0 Down

* for well qualified applicants only. Restrictions apply. Call for details.

Frame Displays
.com

An Essilor Company



877-274-9300

For your free consultation visit www.framedisplays.com



Merchandise Offered

National Lens

America's Leading Optical Distributor

OUR MISSION STATEMENT

National Lens is dedicated to fulfilling the needs of the optical profession by providing the Guaranteed Lowest Prices on Contact Lenses, Frames, and Finished Spectacle Lenses.

Know how to profit and thrive in today's environment!

CONTACT LENSES
TREVI COLISEUM 100% ITALIAN FRAMES
FINISHED SPECTACLE LENSES
FREE FIRST CLASS SHIPPING*

Call for our current price list or visit our website to register

866.923.5600 • 866.923.5601 FAX

www.national-lens.com

*in stock products (when available)

We are always looking for Top Notch Sales Reps!

Clark


 COTTON CLUB


 Coliseum



K973 C1

Continuing Education

Dr. Travel Seminars, LLC
 In Partnership With The NJ Society of Optometric Physicians
12 Hours with Randall Thomas, O.D., F.A.A.O.
British Isles Cruise
 Princess Cruises - Sailing Roundtrip From London, England
 July 24 - August 5, 2017 (12 Night Cruise)
 Sailing to England, Scotland, Ireland, Northern Ireland, France


Optional Private
Group Tours



All Programs Are in Partnership
With the New Jersey Society of
Optometric Physicians



Optional Pre & Post Cruise
London Hotel Stay



Dr. TRAVEL SEMINARS, LLC
is a COPE approved provider
Course approved for 12 CE

Special Sale Pricing Through Nov. 15 **+ Free Gratuities & \$200 Onboard Credit**

“A Comprehensive Update on Contemporary Eye Care”

Additional Seminar Cruises (12-16 CE):
Christmas Week - December 24 - 31, 2016 - Jay Haysie - O.D., F.A.A.O. - Free Drinks
President's Week - February 18 - 25, 2017 - Royal Caribbean's New Ship - Harmony Of The Seas
Baltic Sea Northern Capatials Cruise - July 23 - 30, 2017 - Ron Melton, O.D., F.A.A.O.
Roundtrip Copenhagen, Denmark - NCL's Norwegian Getaway - Free Drinks

www.DrTravel.com **800-436-1028**

Practice For Sale



Practice Sales • Appraisals • Consulting
www.PracticeConsultants.com

**PRACTICES FOR SALE
NATIONWIDE**

Visit us on the Web or call us to learn
more about our company and the
practices we have available.
info@PracticeConsultants.com
800-576-6935

www.PracticeConsultants.com

PRACTICE FOR SALE: ABERDEEN, WA

Ophthalmology/optometry office and practice for sale (including Broadway Optical shop) in Aberdeen, WA. Appraised value for practice and equipment \$300,000. Office building separately appraised \$358,000. Both together are offered \$499,000. Practice and equipment can be purchased separately, with rental lease on the building. Aberdeen is the western gateway to Olympic NP, a paradise for the outdoorsman/sportsman. Address: Aberdeen Cataract & Laser, 118 W. 1st St., Aberdeen, WA 98520.

Contact owner Dr. William Hoot (817) 925-6918 (wrhoot@att.net) or office manager Joanne Watters at (360) 590-4636, (jkwttrs@comcast.net) or at office phone (360) 533-5800 Monday or Tuesday

Equipment and Supplies

**Motorized Pretesting
Tables FOR LESS!**

Save hundreds for just shopping on line.

Go to EBAY and search the words
PRETESTING TABLES and start
saving on all your pretesting needs
or
EMail: eyecareauctions@gmail.com

Products and Services



**COMPLETE PM AND
CERTIFIED EHR
SOFTWARE**
- 2014 Edition

All inclusive solution to enrich patient
care and increase profitability for
unlimited devices and users.

**GET A FREE DEMO AT
WWW.ODONLINE.NET**

**PRACTICE SALES
& APPRAISAL**

Expert Services for:

- Buying or Selling a Practice**
- Practice Appraisal**
- Practice Financing**
- Partner Buy-in or Buy-out**

Call for a Free Consultation
(800) 416-2055
www.TransitionConsultants.com

ARIZONA PRACTICE FOR SALE

Thriving 25-year-old, full-time low vision rehabilitation practice for sale.

TWO LOCATIONS, Sun City, AZ and Mesa, AZ. Practice is still growing, current gross \$2 million. Owner is retiring but willing to stay through the transition.

For more information, please inquire at info@ViewFinderLowVision.com




**Looking to
increase sales?**

Place Your Ad here.

Contact us today for
classified advertising:
888-498-1460
 E-mail: sales@kerhgroup.com

Career Opportunities

Anchorage, AK.

Full time Optometrist

opening with Alaska's premier eye care practice – **Alaska Eye Care Centers, APC**. A privately owned, two location practice with 7 doctors is seeking a new graduate or experienced O.D. for employment opportunity.

Each location has 4-5 full exam rooms and the appropriate equipment, special testing equipment, optometric pre-testers, and full administrative support. The main office offers full lens manufacturing for both locations. Each office has optical dispensaries consisting of over 2,500 frames and is serviced by licensed opticians. In addition, each office has full contact lens services, including licensed CL technicians.

This opening is for our Wasilla location which is a semi-rural setting approximately 40 miles from Anchorage with rotation into our Anchorage office once a week, more when other providers are on vacation. The population of the surrounding area is 50,000+ and most services are offered. Housing and utilities are comparable to West Coast levels. Entertainment, fine dining and the arts are easily available in Anchorage, a city of more than 298,000 residents.

Alaska is one of the most beautiful places to live and practice. **For further information about this GREAT opportunity, please contact:**



Alaska Eye Care Centers

1345 W. 9th Avenue, Anchorage, AK. 99501

Contact: Deb Foster, Business Administrator

deb@alaskaeyecare.com

(907) 272-2557 X 1604 • (907) 274-4932 (Fax)

www.alaskaeyecare.com

STAFF OPTOMETRIST

Bard Optical is a leading Midwest vision care organization in business for over 70 years and we are still growing. The company is based in Peoria, IL with 20 retail offices throughout the central Illinois area, as far north as Sterling and as far south as Jacksonville. Once again this year we were named to the Top 50 Optical Retailers in the United States by Vision Monday – currently ranking 37th. A progressive optometric staff is vital to the continued growth of our organization whose foundation is based on one-on-one patient service. We are currently accepting CV/resumes for optometrists focused on full scope primary medical patient care. The candidate must have an Illinois license with therapeutics. The practice includes (but is not limited to) general optometry, contact lenses, and geriatric care. Salaried, full-time positions are available with excellent growth programs and benefits. Some part-time opportunities may be available also. Please email your information to hr@bardoptical.com or fax to 309-693-9754. Mailing address if more convenient is **Bard Optical, Attn: HR, 8309 N Knoxville Avenue, Peoria, IL 61615**. Ask about opportunities within Bard Optical. *We have openings in several existing and new offices opening soon in central Illinois.*

Bard Optical is a proud Associate Member of the Illinois Optometric Association.



www.bardoptical.com

IT STILL EXISTS!

Delaware private practice with like new 3,500 square foot **free standing building**, custom designed and built to be an eye care facility. Immediate opening for an Associate or Partnership leading to purchase in a unique state with **no corporate practice** (OD's can't practice in Pearl Vision or LensCrafters per state law). Large concentration of Glaucoma and Ocular Disease. **Grossing \$700K plus** with high net and phenomenal growth. **Will sell or lease building**. Extensive website with e-commerce included. Only 1/2 hour to Philadelphia or Baltimore, and 1 hour to the beach.

Call 302-994-2299 or e-mail **confidentially** privpracticeopportunity@gmail.com

OPTOMETRIST

Busy Ophthalmology Practice in Bronx, NY seeking highly-skilled, seasoned Optometrist, part-time. Experience in post-operative care, dry eye, allergies and pediatrics preferred.

Contact:

gscalera@nyeye.com
or fax (718) 405-3808

Software



QuikEyes

Optometry EHR

- \$198 per month after low cost set-up fee
- Quick Set-Up and Easy to Use
- No Server Needed
- Corporate and Private OD practices
- 14 Day Free Demo Trial
- Email/Text Communications

www.quikeyes.com



REVIEW OF OPTOMETRY

Targeting Optometrists?

CLASSIFIED ADVERTISING WORKS

Contact us today for classified advertising:

Toll free: 888-498-1460

E-mail: sales@kerhgroup.com



Product Review

Diagnostic Technology

OCTA, Better Scleral Lens Fitting

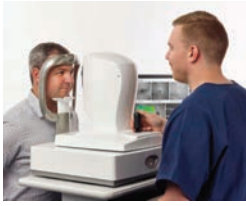Optovue's iSeries OCT devices can help with scleral lens fitting now that the company offers a new software package called Vault Mapping. Traditional corneal clearance imaging uses a fluorescein solution and a slit lamp, which yields one cross-sectional view. With this new software, Optovue says, a clearance assessment map is created to help determine if the lens is tilting or fitting improperly.

The company also recently brought its Angiovue imaging system to optometry, giving ODs a more precise way to view the retinal vasculature, Optovue says. The system provides conventional OCT as well as OCT angiography (OCTA) to quickly visualize the retinal microvasculature without dye. Optometrists can integrate vascular structure assessment with other imaging to form a more complete picture of retinal health.

Visit optovue.com.

Confocal Scanner Autofluorescence

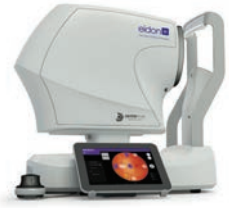Centervue now offers fundus autofluorescence capabilities



on its Eidon line of confocal scanners. The new model, the Eidon AF, obtains the same range of information from multiple imaging modalities as the original while adding fundus autofluorescence, allowing you to assess the retinal pigment epithelial layer, according to the company.

The new model captures a 60° autofluorescence image with a single flash of light. The Eidon AF also offers wide-field views of the retina up to 110°, according to Centervue.

Visit centervue.com.



Eyefficient, Mediworks Go Digital

Optometrists interested in going high tech with their slit lamp imaging and vision testing charts can look forward to checking out a new line of equipment from Mediworks that's now being distributed by Eyefficient.

Eyefficient is also working to provide installation and service to equipment within the continental US.

Visit eyefficient.com. ■



Local Eye Site Assessment

Hiring? Use an assessment tool that is scientifically proven to predict performance in eye care jobs.

localeyesite.com/assessment



Local Eye Site
JOBS IN EYE CARE

TRAVATAN Z[®]

(travoprost ophthalmic solution) 0.004%

BRIEF SUMMARY OF PRESCRIBING INFORMATION

INDICATIONS AND USAGE

TRAVATAN Z[®] (travoprost ophthalmic solution) 0.004% is indicated for the reduction of elevated intraocular pressure in patients with open-angle glaucoma or ocular hypertension.

DOSAGE AND ADMINISTRATION

The recommended dosage is one drop in the affected eye(s) once daily in the evening. TRAVATAN Z[®] (travoprost ophthalmic solution) should not be administered more than once daily since it has been shown that more frequent administration of prostaglandin analogs may decrease the intraocular pressure lowering effect.

Reduction of the intraocular pressure starts approximately 2 hours after the first administration with maximum effect reached after 12 hours.

TRAVATAN Z[®] Solution may be used concomitantly with other topical ophthalmic drug products to lower intraocular pressure. If more than one topical ophthalmic drug is being used, the drugs should be administered at least five (5) minutes apart.

CONTRAINDICATIONS

None

WARNINGS AND PRECAUTIONS

Pigmentation

Travoprost ophthalmic solution has been reported to cause changes to pigmented tissues. The most frequently reported changes have been increased pigmentation of the iris, periorbital tissue (eyelid) and eyelashes. Pigmentation is expected to increase as long as travoprost is administered. The pigmentation change is due to increased melanin content in the melanocytes rather than to an increase in the number of melanocytes. After discontinuation of travoprost, pigmentation of the iris is likely to be permanent, while pigmentation of the periorbital tissue and eyelash changes have been reported to be reversible in some patients. Patients who receive treatment should be informed of the possibility of increased pigmentation. The long term effects of increased pigmentation are not known.

Iris color change may not be noticeable for several months to years. Typically, the brown pigmentation around the pupil spreads concentrically towards the periphery of the iris and the entire iris or parts of the iris become more brownish. Neither nevi nor freckles of the iris appear to be affected by treatment. While treatment with TRAVATAN Z[®] (travoprost ophthalmic solution) 0.004% can be continued in patients who develop noticeably increased iris pigmentation, these patients should be examined regularly.

Eyelash Changes

TRAVATAN Z[®] Solution may gradually change eyelashes and vellus hair in the treated eye. These changes include increased length, thickness, and number of lashes. Eyelash changes are usually reversible upon discontinuation of treatment.

Intraocular Inflammation

TRAVATAN Z[®] Solution should be used with caution in patients with active intraocular inflammation (e.g., uveitis) because the inflammation may be exacerbated.

Macular Edema

Macular edema, including cystoid macular edema, has been reported during treatment with travoprost ophthalmic solution. TRAVATAN Z[®] Solution should be used with caution in aphakic patients, in pseudophakic patients with a torn posterior lens capsule, or in patients with known risk factors for macular edema.

Angle-closure, Inflammatory or Neovascular Glaucoma

TRAVATAN Z[®] Solution has not been evaluated for the treatment of angle-closure, inflammatory or neovascular glaucoma.

Bacterial Keratitis

There have been reports of bacterial keratitis associated with the use of multiple-dose containers of topical ophthalmic products. These containers had been inadvertently contaminated by patients who, in most cases, had a concurrent corneal disease or a disruption of the ocular epithelial surface.

Use with Contact Lenses

Contact lenses should be removed prior to instillation of TRAVATAN Z[®] Solution and may be reinserted 15 minutes following its administration.

ADVERSE REACTIONS

Clinical Studies Experience

Because clinical studies are conducted under widely varying conditions, adverse reaction rates observed in the clinical studies of a drug cannot be directly compared to rates in the clinical studies of another drug and may not reflect the rates observed in practice. The most common adverse reaction observed in controlled clinical studies with TRAVATAN[®] (travoprost ophthalmic solution) 0.004% and TRAVATAN Z[®] (travoprost ophthalmic solution) 0.004% was ocular hyperemia which was reported in 30 to 50% of patients. Up to 3% of patients discontinued therapy due to conjunctival hyperemia. Ocular adverse reactions reported at an incidence of 5 to 10% in these clinical studies included decreased visual acuity, eye discomfort, foreign body sensation, pain and pruritus. Ocular adverse reactions reported at an incidence of 1 to 4% in clinical studies with TRAVATAN[®] or TRAVATAN Z[®] Solutions included abnormal vision, blepharitis, blurred vision, cataract, conjunctivitis, corneal staining, dry eye, iris discoloration, keratitis, lid margin crusting, ocular inflammation, photophobia, subconjunctival hemorrhage and tearing.

Nonocular adverse reactions reported at an incidence of 1 to 5% in these clinical studies were allergy, angina pectoris, anxiety, arthritis, back pain, bradycardia, bronchitis, chest pain, cold/flu syndrome, depression, dyspepsia, gastrointestinal disorder, headache, hypercholesterolemia, hypertension, hypotension, infection, pain, prostate disorder, sinusitis, urinary incontinence and urinary tract infections.

In postmarketing use with prostaglandin analogs, periorbital and lid changes including deepening of the eyelid sulcus have been observed.

USE IN SPECIFIC POPULATIONS

Pregnancy

Pregnancy Category C

Teratogenic effects: Travoprost was teratogenic in rats, at an intravenous (IV) dose up to 10 mcg/kg/day (250 times the maximal recommended human ocular dose (MRHOD)), evidenced by an increase in the incidence of skeletal malformations as well as external and visceral malformations, such as fused sternbrae, domed head and hydrocephaly. Travoprost was not teratogenic in rats at IV doses up to 3 mcg/kg/day (75 times the MRHOD), or in mice at subcutaneous doses up to 1 mcg/kg/day (25 times the MRHOD). Travoprost produced an increase in post-implantation losses and a decrease in fetal viability in rats at IV doses > 3 mcg/kg/day (75 times the MRHOD) and in mice at subcutaneous doses > 0.3 mcg/kg/day (7.5 times the MRHOD).

In the offspring of female rats that received travoprost subcutaneously from Day 7 of pregnancy to lactation Day 21 at doses of \geq 0.12 mcg/kg/day (3 times the MRHOD), the incidence of postnatal mortality was increased, and neonatal body weight gain was decreased. Neonatal development was also affected, evidenced by delayed eye opening, pinna detachment and preputial separation, and by decreased motor activity.

There are no adequate and well-controlled studies of TRAVATAN Z[®] (travoprost ophthalmic solution) 0.004% administration in pregnant women. Because animal reproductive studies are not always predictive of human response, TRAVATAN Z[®] Solution should be administered during pregnancy only if the potential benefit justifies the potential risk to the fetus.

Nursing Mothers

A study in lactating rats demonstrated that radiolabeled travoprost and/or its metabolites were excreted in milk. It is not known whether this drug or its metabolites are excreted in human milk. Because many drugs are excreted in human milk, caution should be exercised when TRAVATAN Z[®] Solution is administered to a nursing woman.

Pediatric Use

Use in pediatric patients below the age of 16 years is not recommended because of potential safety concerns related to increased pigmentation following long-term chronic use.

Geriatric Use

No overall clinical differences in safety or effectiveness have been observed between elderly and other adult patients.

Hepatic and Renal Impairment

Travoprost ophthalmic solution 0.004% has been studied in patients with hepatic impairment and also in patients with renal impairment. No clinically relevant changes in hematology, blood chemistry, or urinalysis laboratory data were observed in these patients.

NONCLINICAL TOXICOLOGY

Carcinogenesis, Mutagenesis, Impairment of Fertility

Two-year carcinogenicity studies in mice and rats at subcutaneous doses of 10, 30, or 100 mcg/kg/day did not show any evidence of carcinogenic potential. However, at 100 mcg/kg/day, male rats were only treated for 82 weeks, and the maximum tolerated dose (MTD) was not reached in the mouse study. The high dose (100 mcg/kg) corresponds to exposure levels over 400 times the human exposure at the maximum recommended human ocular dose (MRHOD) of 0.04 mcg/kg, based on plasma active drug levels. Travoprost was not mutagenic in the Ames test, mouse micronucleus test or rat chromosome aberration assay.

A slight increase in the mutant frequency was observed in one of two mouse lymphoma assays in the presence of rat S-9 activation enzymes.

Travoprost did not affect mating or fertility indices in male or female rats at subcutaneous doses up to 10 mcg/kg/day [250 times the maximum recommended human ocular dose of 0.04 mcg/kg/day on a mcg/kg basis (MRHOD)]. At 10 mcg/kg/day, the mean number of corpora lutea was reduced, and the post-implantation losses were increased. These effects were not observed at 3 mcg/kg/day (75 times the MRHOD).

PATIENT COUNSELING INFORMATION

Potential for Pigmentation

Patients should be advised about the potential for increased brown pigmentation of the iris, which may be permanent. Patients should also be informed about the possibility of eyelid skin darkening, which may be reversible after discontinuation of TRAVATAN Z[®] (travoprost ophthalmic solution) 0.004%.

Potential for Eyelash Changes

Patients should also be informed of the possibility of eyelash and vellus hair changes in the treated eye during treatment with TRAVATAN Z[®] Solution. These changes may result in a disparity between eyes in length, thickness, pigmentation, number of eyelashes or vellus hairs, and/or direction of eyelash growth. Eyelash changes are usually reversible upon discontinuation of treatment.

Handling the Container

Patients should be instructed to avoid allowing the tip of the dispensing container to contact the eye, surrounding structures, fingers, or any other surface in order to avoid contamination of the solution by common bacteria known to cause ocular infections. Serious damage to the eye and subsequent loss of vision may result from using contaminated solutions.

When to Seek Physician Advice

Patients should also be advised that if they develop an intercurrent ocular condition (e.g., trauma or infection), have ocular surgery, or develop any ocular reactions, particularly conjunctivitis and eyelid reactions, they should immediately seek their physician's advice concerning the continued use of TRAVATAN Z[®] Solution.

Use with Contact Lenses

Contact lenses should be removed prior to instillation of TRAVATAN Z[®] Solution and may be reinserted 15 minutes following its administration.

Use with Other Ophthalmic Drugs

If more than one topical ophthalmic drug is being used, the drugs should be administered at least five (5) minutes between applications.

Rx Only

U.S. Patent Nos. 5,631,287; 5,889,052; 6,011,062; 6,235,781; 6,503,497; and 6,849,253

Alcon[®]

ALCON LABORATORIES, INC.
Fort Worth, Texas 76134 USA
© 2006, 2010, 2011, 2012 Novartis
10/15 US-TRZ-15-E-0278



Vision Going Down the Drain

By Andrew S. Gurwood, OD

History

A 57-year-old black female reported to the office with a chief complaint of dimmed vision in her left eye for a week. She noticed the change in vision after a procedure to treat her glaucoma. A phone call to that practice revealed that the patient had a drainage valve implanted in her left eye to augment a failing trabeculectomy.

She was placed on topical antibiotics, topical steroids and topical nonsteroidal anti-inflammatory medications QID and removed from all topical glaucoma medications.

Her systemic history was remarkable for hypertension, for which she was properly medicated. She denied allergies of any kind.

Diagnostic Data

Her best corrected entering visual acuities were 20/30 OD and 20/20 OS at distance and near with no improvement upon pinhole. Her external examination was normal with no evidence of afferent pupil defect. The biomicroscopic examination of the anterior segment was normal with a well placed drainage device and no evidence of complications. Goldmann applanation tonometry measured 15mm Hg in

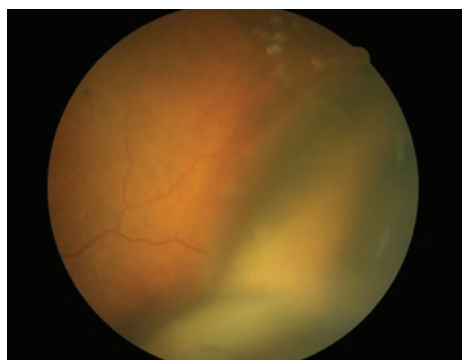
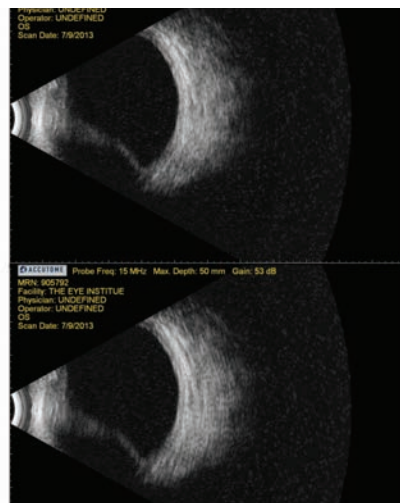
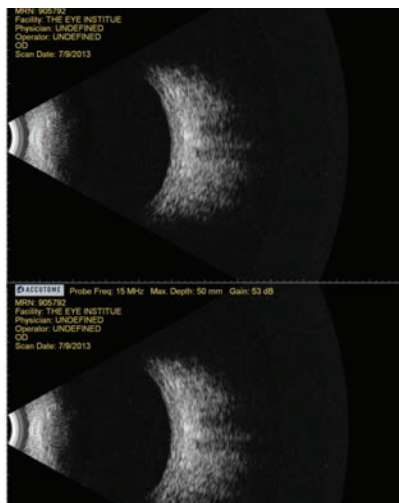


Fig. 1. Above, this B-scan ultrasonography shows test results from a patient who complained of diminished vision for a week. She had recently had a drainage valve implanted to help with her glaucoma.

Fig. 2. At left, this fundus photo shows the pertinent clinical findings. Can you identify it?

both eyes. Studies included stereobiomicroscopic examination of the fundus, photodocumentation and B-scan ultrasonography (*Figure 1*). Pertinent clinical findings in the posterior segment of the left eye are demonstrated (*Figure 2*).

Your Diagnosis

Does this case require additional tests? How would you manage this patient? What is the likely prognosis?

To find out, please visit www.reviewofoptometry.com. ■

Retina Quiz Answers (from page 88): 1) c; 2) c; 3) c; 4) d.

REVIEW OF OPTOMETRY (ISSN 0147-7633) IS PUBLISHED MONTHLY, 12 TIMES A YEAR BY JOBSON MEDICAL INFORMATION LLC, 100 AVENUE OF THE AMERICAS, NEW YORK, NY 10013-1678. PERIODICALS POSTAGE PAID AT NEW YORK, NY AND ADDITIONAL MAILING OFFICES. POSTMASTER: SEND ADDRESS CHANGES TO REVIEW OF OPTOMETRY, PO BOX 81, CONGERS, NY 10920-0081. SUBSCRIPTION PRICES: US: ONE YEAR \$56; TWO YEARS \$97, CANADA: ONE YEAR \$88, TWO YEARS \$160, INT'L: ONE YEAR \$209, TWO YEARS \$299. FOR SUBSCRIPTION INFORMATION CALL TOLL-FREE (877) 529-1746 (USA); OUTSIDE USA, CALL (845) 267-3065. OR EMAIL US AT REVOPOTOMETRY@CAMBEYWEST.COM. PUBLICATIONS MAIL AGREEMENT NO: 40612608. CANADA RETURNS TO BE SENT TO BLEUCHIP INTERNATIONAL, P.O. BOX 25542, LONDON, ON N6C 6B2.



YOUR PRACTICE IS YOUR FOCUS.

THAT'S WHAT MAKES IT ONE OF THE BEST.

Share your story and show your peers and patients why your eye care practice is one of the best. Receive the recognition you deserve and help elevate excellence in the profession.

Submit your practice for a chance to be named one of the 2016 Best Practices at eyecarebestpractices.com



AN INITIATIVE OF  CooperVision®



CHOOSE **TRAVATAN Z[®] Solution:**
A POWERFUL START

Sustained

30% IOP lowering at 12, 14, and 20 hours post-dose in a 3-month study^{1,2*}

Not actual patient

TRAVATAN Z[®] Solution has no FDA-approved therapeutic equivalent available

Help patients start strong and stay on track with **Openings[®]**

Patient Support Program from Alcon

INDICATIONS AND USAGE

TRAVATAN Z[®] (travoprost ophthalmic solution) 0.004% is indicated for the reduction of elevated intraocular pressure (IOP) in patients with open-angle glaucoma or ocular hypertension.

Dosage and Administration

The recommended dosage is 1 drop in the affected eye(s) once daily in the evening. TRAVATAN Z[®] Solution should not be administered more than once daily since it has been shown that more frequent administration of prostaglandin analogs may decrease the IOP-lowering effect.

TRAVATAN Z[®] Solution may be used concomitantly with other topical ophthalmic drug products to lower IOP. If more than 1 topical ophthalmic drug is being used, the drugs should be administered at least 5 minutes apart.

IMPORTANT SAFETY INFORMATION

Warnings and Precautions

Pigmentation—Travoprost ophthalmic solution has been reported to increase the pigmentation of the iris, periorbital tissue (eyelid), and eyelashes. Pigmentation is expected to increase as long as travoprost is administered. After discontinuation of travoprost, pigmentation of the iris is likely to be permanent, while pigmentation of the periorbital tissue and eyelash changes have been reported to be reversible in some patients. The long-term effects of increased

pigmentation are not known. While treatment with TRAVATAN Z[®] Solution can be continued in patients who develop noticeably increased iris pigmentation, these patients should be examined regularly.

Eyelash Changes—TRAVATAN Z[®] Solution may gradually change eyelashes and vellus hair in the treated eye. These changes include increased length, thickness, and number of lashes. Eyelash changes are usually reversible upon discontinuation of treatment.

Use With Contact Lenses—Contact lenses should be removed prior to instillation of TRAVATAN Z[®] Solution and may be reinserted 15 minutes following its administration.

Adverse Reactions

The most common adverse reaction observed in controlled clinical studies with TRAVATAN Z[®] Solution was ocular hyperemia, which was reported in 30 to 50% of patients. Up to 3% of patients discontinued therapy due to conjunctival hyperemia. Ocular adverse reactions reported at an incidence of 5 to 10% in these clinical studies included decreased visual acuity, eye discomfort, foreign body sensation, pain, and pruritus. In postmarketing use with prostaglandin analogs, periorbital and lid changes including deepening of the eyelid sulcus have been observed.

Use in Specific Populations

Use in pediatric patients below the age of 16 years is not recommended because of potential safety concerns related to increased pigmentation following long-term chronic use.

For additional information about TRAVATAN Z[®] Solution, please see the brief summary of Prescribing Information on the adjacent page.

***Study Design:** Double-masked, randomized, parallel-group, multicenter non-inferiority comparison of the efficacy and safety of travoprost 0.004% preserved with benzalkonium chloride (BAK) to TRAVATAN Z[®] Solution after 3 months of treatment in patients with open-angle glaucoma or ocular hypertension. Baseline IOPs were 27.0 mm Hg (n=322), 25.5 mm Hg (n=322), and 24.8 mm Hg (n=322) at 8 AM, 10 AM, and 4 PM for TRAVATAN Z[®] Solution. At the end of Month 3, the TRAVATAN Z[®] Solution group had mean IOPs (95% CI) of 18.7 mm Hg (-0.4, 0.5), 17.7 mm Hg (-0.4, 0.6), and 17.4 mm Hg (-0.2, 0.8) at 8 AM, 10 AM, and 4 PM, respectively. Statistical equivalent reductions in IOP (95% confidence interval about the treatment differences were entirely within ±1.5 mm Hg) were demonstrated between the treatments at all study visits during the 3 months of treatment.

References: 1. Data on file, 2013. 2. Lewis RA, Katz GJ, Weiss MJ, et al. Travoprost 0.004% with and without benzalkonium chloride: a comparison of safety and efficacy. *J Glaucoma*. 2007;16(1):98-103.

TRAVATAN Z[®]

(travoprost ophthalmic solution) 0.004%

Alcon
a Novartis company

© 2015 Novartis 10/15 US-TRZ-15-E-0278