

Earn 2 CE Credits: Recognize Distinctions in Women's Eye Health, *Page 79*

REVIEW[®] OF OPTOMETRY

May 15, 2015

www.reviewofoptometry.com

TAKE CHARGE OF DIABETIC CARE

Eye care is on the front lines of this public health crisis. Arm yourself with the latest advice to keep patients healthy. **Page 32**

PLUS:

» **The Do's and Don'ts of Measuring IOP, *Page 43***

16th Annual DRY EYE REPORT

- » **Getting a Grip on Anterior Blepharitis, *Page 26***
- » **Subjective vs. Objective Mismatch—Who's Right: The Patient or the Test?, *Page 53***
- » **Whet Your Appetite for New Dry Eye Drugs, *Page 61***
- » **How to Impress (and Express) Your MGD Patients, *Page 67***
- » **Clarifying Dry Eye Coding, *Page 92***

NATURAL
BEAUTY

EN

Danielle is wearing NATURAL SPARKLE™

HANCED

A **NEW CATEGORY** of contact lenses that accentuates **NATURAL BEAUTY**. Based on the **PROVEN DESIGN** of 1-DAY ACUVUE® MOIST, the **#1 DAILY DISPOSABLE BRAND**

WITHOUT

WITH



The iris-inspired design of **NEW 1-DAY ACUVUE® DEFINE™ Brand Contact Lenses** uniquely complements every iris pattern to help make your patients' eyes look whiter and brighter.



TRY 1-DAY ACUVUE® DEFINE™ BRAND CONTACT LENSES TODAY TO PUT YOUR PRACTICE ON THE CUTTING EDGE OF NATURAL-LOOKING EYE ENHANCEMENT.

1-DAY ACUVUE® DEFINE™ Brand Contact Lenses are available with and without vision correction. As with any contact lens, eye problems including corneal ulcers can develop. Some wearers may experience mild irritation, itching or discomfort. Lenses should not be prescribed if patients have any eye infection, or experience eye discomfort, excessive tearing, vision changes, redness, or other eye problems. Consult the package insert for complete information, available from Johnson & Johnson Vision Care, Inc., by calling 1-800-843-2020 or by visiting www.acuvueprofessional.com.

1-DAY ACUVUE® DEFINE™, NATURAL SPARKLE™, 1-DAY ACUVUE® MOIST, and LACREON® are trademarks of Johnson & Johnson Vision Care, Inc.

© Johnson & Johnson Vision Care, Inc. 2015 ACU-10336942-C May 2015

IN THE NEWS

After reviewing the results of three clinical trials, the FDA has approved the **Kamra inlay**, an opaque, ring-shaped device

implanted in the cornea of one eye to improve near vision in certain patients with presbyopia.



Kamra inlay compared to a contact lens.

It is the first implantable device for correction of near vision in patients who have not had cataract surgery, the FDA said in a press release.

Melvin D. Wolfberg, OD, passed away on April 21 at the age of 88. He served as president of the American Optometric Association from 1969 to 1970, president of the Pennsylvania College of Optometry from 1979 to 1989, and president of the American Academy of Optometry from 1985 to 1986.

Alfred A. Rosenbloom, OD, a leader in low-vision rehabilitation and an educator for more than 50 years, passed away at the age of 94. He helped found the Low Vision Clinic at The Chicago Lighthouse in 1954, and was former professor, dean and president of the Illinois College of Optometry. He co-wrote several major textbooks and was a contributing author to nine others.

The American Optometric Association and Optometry Cares—The AOA Foundation announced three new inductees to the National Optometry Hall of Fame:

Paul C. Ajamian, OD, of Georgia; **Kenji Hamada, OD**, of Oregon; and **Earl L. Smith III, OD, PhD**, of Texas.

Study Forecasts Future Myopia in Children

One test before first grade predicts myopia by eighth grade. **By Rebecca Hepp, Senior Associate Editor**

Results from a 20-year study suggest measuring children's refractive error as early as age six could help predict those who will become nearsighted by the eighth grade.

Researchers for the Collaborative Longitudinal Evaluation of Ethnicity and Refractive Error (CLEERE) study followed 4,500 children with normal vision between the ages of six and 11 years, evaluating at this range of baseline ages and at least two additional annual visits using cycloplegic autorefractometry.

The researchers initially set out to see “what measures could we have done in first grade to predict who was going to need glasses by the eighth grade?” said lead author Karla Zadnik, OD, PhD, professor and dean of the College of Optometry at The Ohio State University.

The final answer? Screen children to evaluate whether they have more or less hyperopia. Children who grow up to have normal vision are actually somewhat hyperopic in first grade, so those who have little to no hyperopia at an early age are likely to develop myopia as their eyes continue to grow, the study found.

The results are applicable across all ethnicities, too. The study's racial composition included white, Hispanic, African American, Na-

tive American and Asian American children.

“The prevalence of nearsightedness differs among ethnicities, but the mechanism is the same,” Dr. Zadnik said. “If you become nearsighted, it's because your eyeball has grown too long. This prediction model works.”

The study also contradicts the notion that near work—such as frequent reading, playing electronic devices or sitting too close to the TV—can bring on myopia. “In this large dataset from an ethnically representative sample of children, we found no association,” Dr. Zadnik said.

The researchers hope these results will eventually lead to mandated eye exams before kids enter school, giving parents the opportunity to better plan for their child's future vision needs.

“At an eye examination as early as first grade, an optometrist can provide parents with an idea of how likely their child is to develop myopia by eighth grade,” Dr. Zadnik says. “This might be of particular interest to parents who are themselves myopic and worried about their child in that regard, and the information could be used to guide the eye exam schedule for a given child.”

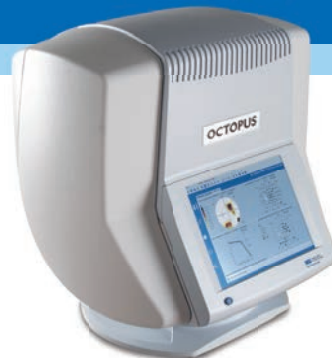Zadnik K, Sinnott LT, Cotter SA, et al. Prediction of juvenile-onset myopia. *JAMA Ophthalmol*. 2015 Apr 2. [Epub ahead of print].

THE ROCK 'EM SOCK 'EM GLAUCOMA INSTRUMENT.

The Octopus 600® Perimeter

It's working. Thanks to doctors like you and early diagnosis, the risk of blindness due to glaucoma has been cut by 50%. But Octopus can do better. It's the all-in-one early detection and management device with the most accurate and reproducible data. Take your best shot at one soon.

Call Haag-Streit for an online demo at 800-787-5426.



800.787.5426
haag-streit-usa.com



© 2015 Haag-Streit USA. All Rights Reserved.

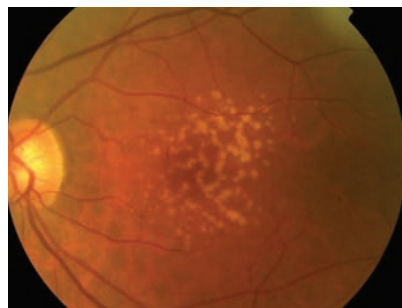
 **HAAG-STREIT
USA**

Medium Drusen May Indicate AMD Progression

A new study found that patients are four times more likely to develop sight-threatening age-related macular degeneration (AMD) if they show signs of medium drusen (63µm to 124µm) plus retinal pigment epithelium (RPE) abnormalities, according to investigators at the University of Sydney in Australia. Their findings were published online in *JAMA Ophthalmology*.

The team looked at 3,654 participants, 49 years or older, over a span of 15 years. Among the 1,317 participants at risk, the 15-year cumulative incidence of medium drusen was 13.9%.

“In general, the larger the drusen, the higher the risk of progression to late AMD. RPE changes with drusen, whether medium or large, increase the risk further,” explained Carl D. Regillo, MD, director of Retina Service at Wills Eye Hospital and professor of ophthalmology at Thomas Jefferson



Follow patients with medium drusen more closely.

son University in Philadelphia.

Although this study’s results alone probably won’t impact the way doctors follow and treat patients, its implications could nudge optometrists to “potentially follow patients with medium size drusen and pigmentary changes a bit closer, similar to the way we now follow those with large drusen,” Dr. Regillo said.

For Mark T. Dunbar, OD, director of optometry at the Bascom Palmer Eye Institute in Miami,

one particular aspect of the study stood out. “Patients who had genetic risk factors [CFH and ARMS2 risk alleles] were even more likely to progress,” he said. “Clinicians can assume that even without genetic testing, the presence of medium drusen and RPE abnormalities signifies a considerably high risk for progression. Therefore, these patients need to be followed more closely with advanced imaging technologies such as SD-OCT and fundus autofluorescence.”

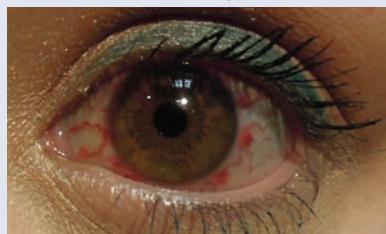
“Patients with medium and large drusen should supplement their diets with an AREDS2 formula [supplement],” Dr. Regillo said. “They should also self-monitor their vision at home on a regular basis and know to report any vision changes promptly.”

Joachim ND, Mitchell P, Kifley A, Wang JJ. Incidence, progression, and associated risk factors of medium drusen in age-related macular degeneration: Findings from the 15-year follow-up of an Australian cohort. *JAMA Ophthalmol*. 2015 Apr 2. [Epub ahead of print].

Pink Eye Hits Primetime

Optometrists are supposed to treat pink eye, not give it out.

But that’s what Jonathan Gording, OD, was asked to do for an episode of ABC’s



“The Goldbergs,” which aired April 29.

Dr. Gording, who is in private practice in Los Angeles, fitted Erica (Hayley Orrantia) and Dana (Natalie Lind) Goldberg with 22mm theatrical scleral lenses hand-painted with tiny blood vessels to simulate pink eye.

“It was a fun change from Tobradex and follow up in 48 hours,” Dr. Gording joked.





All eyes deserve clariti.



clariti 1 day—now available for practices everywhere.

The world's first and only family of silicone hydrogel daily disposable contact lenses designed *for every patient type*—sphere, toric and multifocal.

**High Oxygen
Transmissibility**

**High Water
Content**

**Low
Modulus**

**UV
Protection**

**Affordable
Upgrade**

Now you can prescribe all of your patients with healthy, comfortable, affordable silicone hydrogel 1 day lenses—which will make all eyes very happy indeed.

To learn more, contact your CooperVision representative today or visit **CooperVision.com/practitioner**.



CooperVision®
Live Brightly.®

Virtual Reality Used to Identify Risk of Falls Due to Glaucoma

People with glaucoma have a higher risk of falls, and a new high-tech test might help clinicians better understand the role balance control plays in this increased risk.

Using virtual reality goggles and a platform that measures balance and movement, a multidisciplinary team based at the University of California San Diego (UCSD) studied 42 patients with open-angle glaucoma and 38 healthy subjects. The researchers recorded the subjects' balance without stimulation, with a black screen using the goggles, and when presented with simulated movement. During simulated movement, they found balance adjustments for the glaucoma patients were an average of 30% to 40% more pronounced than the healthy subjects.¹

In addition to the balance adjustment findings, they also found that "the degree to which balance was lost was strongly linked to a history of falls, which validated the study's methods and metrics." The results were published online in *Ophthalmology*.



Patient being evaluated with the virtual reality-based balance assessment test at the University of California San Diego Visual Performance Laboratory.

"Measures from traditional static visual field tests do not mimic the visual conditions that occur day-to-day," explained Felipe A. Medeiros, MD, senior author and director of the Visual Performance Laboratory at UCSD. "With further refinement of this method, we hope that the approach could one

day be used to identify patients at high risk of falling so that preventative measures can be employed at an earlier stage."

They were looking for a better way to document the correlation between visual field results and risk of falls in glaucoma patients. Previous research only shows a weak correlation, even though glaucoma patients' risk of falling is more than three times greater than those without glaucoma.²

The researchers speculate that balance control issues in patients with glaucoma are related to the loss of retinal ganglion cells caused by the disease, leading to slower visual processing and impaired motion perception. They hope this testing method will spur new studies, ultimately helping eye care professionals better understand the relationship between risk of falls and retinal ganglion cell loss in people with glaucoma. ■

1. Diniz-Filho A, Boer ER, Gracitelli CPB, et al. Evaluation of postural control in patients with glaucoma using a virtual reality environment. *Ophthalmology*. 2015 April 15. [Epub ahead of print].

2. Haymes SA, Leblanc RP, Nicoleta MT, et al. Risk of falls and motor vehicle collisions in glaucoma. *Invest Ophthalmol Vis Sci*. 2007 Mar;48(3):1149-55.

Objections to Amniotic Membrane Use in Texas

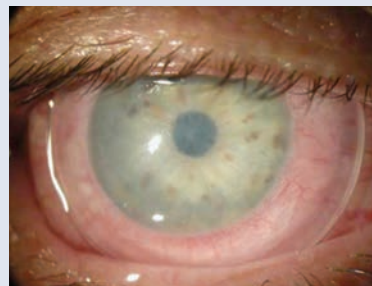The Texas Optometry Board recently proposed a new rule clarifying optometrists' authority to use amniotic membranes, such as Prokera (Bio-Tissue).

But the Texas Medical Association (TMA) and the Texas Ophthalmological Association (TOA), wrote a letter to the Texas Board of Optometry stating their concern that amniotic membrane use is beyond optometrists' scope of practice

because applying the membrane is considered surgery within Texas statute.

Optometrists' current scope of practice includes prescribing lenses, contact lenses and ocular pharmaceutical agents. Prokera should not be classified under these categories, Austin I. King, MD, TMA president, said in the letter.

The Texas Optometry Board has not publicly responded to the letter.



A Prokera amniotic membrane graft placed on the ocular surface.

Photo: Bio-Tissue



For patients with decreased tear production presumed to be due to
ocular inflammation associated with Chronic Dry Eye

THE DRY EYE TREATMENT SHE NEEDS TODAY. BECAUSE TOMORROW MATTERS.



RESTASIS® twice a day, every day, helps patients experience increased tear production

Increased tear production was seen at 6 months.¹

Indication and Usage

RESTASIS® (cyclosporine ophthalmic emulsion) 0.05% is indicated to increase tear production in patients whose tear production is presumed to be suppressed due to ocular inflammation associated with keratoconjunctivitis sicca. Increased tear production was not seen in patients currently taking topical anti-inflammatory drugs or using punctal plugs.

Important Safety Information

Contraindications

RESTASIS® is contraindicated in patients with known or suspected hypersensitivity to any of the ingredients in the formulation.

Warnings and Precautions

Potential for Eye Injury and Contamination: To avoid the potential for eye injury and contamination, individuals prescribed RESTASIS® should not touch the vial tip to their eye or other surfaces.

Use With Contact Lenses: RESTASIS® should not be administered while wearing contact lenses. If contact lenses are worn, they should be removed prior to the administration of the emulsion.

Adverse Reactions

In clinical trials, the most common adverse reaction following the use of RESTASIS® was ocular burning (upon instillation)—17%. Other reactions reported in 1% to 5% of patients included conjunctival hyperemia, discharge, epiphora, eye pain, foreign body sensation, pruritus, stinging, and visual disturbance (most often blurring).

Please see Brief Summary of the full Prescribing Information on adjacent page.

Reference: 1. RESTASIS® Prescribing Information.



©2014 Allergan, Inc., Irvine, CA 92612
® marks owned by Allergan, Inc.
APC20AF14 141005

RESTASIS® (Cyclosporine Ophthalmic Emulsion) 0.05%

BRIEF SUMMARY—PLEASE SEE THE RESTASIS® PACKAGE INSERT FOR FULL PRESCRIBING INFORMATION.

INDICATION AND USAGE

RESTASIS® ophthalmic emulsion is indicated to increase tear production in patients whose tear production is presumed to be suppressed due to ocular inflammation associated with keratoconjunctivitis sicca. Increased tear production was not seen in patients currently taking topical anti-inflammatory drugs or using punctal plugs.

CONTRAINDICATIONS

RESTASIS® is contraindicated in patients with known or suspected hypersensitivity to any of the ingredients in the formulation.

WARNINGS AND PRECAUTIONS

Potential for Eye Injury and Contamination

To avoid the potential for eye injury and contamination, be careful not to touch the vial tip to your eye or other surfaces.

Use with Contact Lenses

RESTASIS® should not be administered while wearing contact lenses. Patients with decreased tear production typically should not wear contact lenses. If contact lenses are worn, they should be removed prior to the administration of the emulsion. Lenses may be reinserted 15 minutes following administration of RESTASIS® ophthalmic emulsion.

ADVERSE REACTIONS

Clinical Trials Experience

Because clinical trials are conducted under widely varying conditions, adverse reaction rates observed in the clinical trials of a drug cannot be directly compared to rates in the clinical trials of another drug and may not reflect the rates observed in practice.

In clinical trials, the most common adverse reaction following the use of RESTASIS® was ocular burning (17%).

Other reactions reported in 1% to 5% of patients included conjunctival hyperemia, discharge, epiphora, eye pain, foreign body sensation, pruritus, stinging, and visual disturbance (most often blurring).

Post-marketing Experience

The following adverse reactions have been identified during post approval use of RESTASIS®. Because these reactions are reported voluntarily from a population of uncertain size, it is not always possible to reliably estimate their frequency or establish a causal relationship to drug exposure.

Reported reactions have included: hypersensitivity (including eye swelling, urticaria, rare cases of severe angioedema, face swelling, tongue swelling, pharyngeal edema, and dyspnea); and superficial injury of the eye (from the vial tip touching the eye during administration).

USE IN SPECIFIC POPULATIONS

Pregnancy

Teratogenic Effects: Pregnancy Category C

Adverse effects were seen in reproduction studies in rats and rabbits only at dose levels toxic to dams. At toxic doses (rats at 30 mg/kg/day and rabbits at 100 mg/kg/day), cyclosporine oral solution, USP, was embryo- and fetotoxic as indicated by increased pre- and postnatal mortality and reduced fetal weight together with related skeletal retardations. These doses are 5,000 and 32,000 times greater (normalized to body surface area), respectively, than the daily human dose of one drop (approximately 28 mL) of 0.05% RESTASIS® twice daily into each eye of a 60 kg person (0.001 mg/kg/day), assuming that the entire dose is absorbed. No evidence of embryofetal toxicity was observed in rats or rabbits receiving cyclosporine at oral doses up to 17 mg/kg/day or 30 mg/kg/day, respectively, during organogenesis. These doses in rats and rabbits are approximately 3,000 and 10,000 times greater (normalized to body surface area), respectively, than the daily human dose.

Offspring of rats receiving a 45 mg/kg/day oral dose of cyclosporine from Day 15 of pregnancy until Day 21 postpartum, a maternally toxic level, exhibited an increase in postnatal mortality; this dose is 7,000 times greater than the daily human topical dose (0.001 mg/kg/day) normalized to body surface area assuming that the entire dose is absorbed. No adverse events were observed at oral doses up to 15 mg/kg/day (2,000 times greater than the daily human dose).

There are no adequate and well-controlled studies of RESTASIS® in pregnant women. RESTASIS® should be administered to a pregnant woman only if clearly needed.

Nursing Mothers

Cyclosporine is known to be excreted in human milk following systemic administration, but excretion in human milk after topical treatment has not been investigated. Although blood concentrations are undetectable after topical administration of RESTASIS® ophthalmic emulsion, caution should be exercised when RESTASIS® is administered to a nursing woman.

Pediatric Use

The safety and efficacy of RESTASIS® ophthalmic emulsion have not been established in pediatric patients below the age of 16.

Geriatric Use

No overall difference in safety or effectiveness has been observed between elderly and younger patients.

NONCLINICAL TOXICOLOGY

Carcinogenesis, Mutagenesis, Impairment of Fertility

Carcinogenesis: Systemic carcinogenicity studies were carried out in male and female mice and rats. In the 78-week oral (diet) mouse study, at doses of 1, 4, and 16 mg/kg/day, evidence of a statistically significant trend was found for lymphocytic lymphomas in females, and the incidence of hepatocellular carcinomas in mid-dose males significantly exceeded the control value.

In the 24-month oral (diet) rat study, conducted at 0.5, 2, and 8 mg/kg/day, pancreatic islet cell adenomas significantly exceeded the control rate in the low-dose level. The hepatocellular carcinomas and pancreatic islet cell adenomas were not dose related. The low doses in mice and rats are approximately 80 times greater (normalized to body surface area) than the daily human dose of one drop (approximately 28 mL) of 0.05% RESTASIS® twice daily into each eye of a 60 kg person (0.001 mg/kg/day), assuming that the entire dose is absorbed.

Mutagenesis: Cyclosporine has not been found to be mutagenic/genotoxic in the Ames Test, the V79-HGPRT Test, the micronucleus test in mice and Chinese hamsters, the chromosome-aberration tests in Chinese hamster bone-marrow, the mouse dominant lethal assay, and the DNA-repair test in sperm from treated mice. A study analyzing sister chromatid exchange (SCE) induction by cyclosporine using human lymphocytes *in vitro* gave indication of a positive effect (i.e., induction of SCE).

Impairment of Fertility: No impairment in fertility was demonstrated in studies in male and female rats receiving oral doses of cyclosporine up to 15 mg/kg/day (approximately 2,000 times the human daily dose of 0.001 mg/kg/day normalized to body surface area) for 9 weeks (male) and 2 weeks (female) prior to mating.

PATIENT COUNSELING INFORMATION

Handling the Container

Advise patients to not allow the tip of the vial to touch the eye or any surface, as this may contaminate the emulsion. To avoid the potential for injury to the eye, advise patients to not touch the vial tip to their eye.

Use with Contact Lenses

RESTASIS® should not be administered while wearing contact lenses. Patients with decreased tear production typically should not wear contact lenses. Advise patients that if contact lenses are worn, they should be removed prior to the administration of the emulsion. Lenses may be reinserted 15 minutes following administration of RESTASIS® ophthalmic emulsion.

Administration

Advise patients that the emulsion from one individual single-use vial is to be used immediately after opening for administration to one or both eyes, and the remaining contents should be discarded immediately after administration.

Rx Only



Based on package insert 71876US18

© 2014 Allergan, Inc.

Irvine, CA 92612, U.S.A.

® marks owned by Allergan, Inc. APC21XT14

Patented. See www.allergan.com/products/patent_notices

Made in the U.S.A.



BUSINESS OFFICES

11 CAMPUS BLVD., SUITE 100
NEWTOWN SQUARE, PA 19073

CEO, INFORMATION SERVICES GROUP

MARC FERRARA
(212) 274-7062 • MFERRARA@JOBSON.COM

PUBLISHER

JAMES HENNE
(610) 492-1017 • JHENNE@JOBSON.COM

REGIONAL SALES MANAGER

MICHELE BARRETT
(610) 492-1014 • MBARRETT@JOBSON.COM

REGIONAL SALES MANAGER

MICHAEL HOSTER
(610) 492-1028 • MHOSTER@JOBSON.COM

VICE PRESIDENT, OPERATIONS

CASEY FOSTER
(610) 492-1007 • CFOSTER@JOBSON.COM

VICE PRESIDENT, CLINICAL CONTENT

PAUL M. KARPECKI, OD, FFAO
PKARPECKI@JOBSON.COM

PRODUCTION MANAGER

SCOTT TOBIN
(610) 492-1011 • STOBIN@JOBSON.COM

SENIOR CIRCULATION MANAGER

HAMILTON MAHER
(212) 219-7870 • HMAHER@JHIHEALTH.COM

CLASSIFIED ADVERTISING

(888) 498-1460

SUBSCRIPTIONS

\$56 A YEAR, \$88 (US) IN CANADA,
\$209 (US) IN ALL OTHER COUNTRIES.

SUBSCRIPTION INQUIRIES

(877) 529-1746 (US ONLY);
OUTSIDE US, CALL (847) 763-9630

CIRCULATION

PO Box 2025
SKOKIE, IL 60076
TEL: (TOLL FREE) 1-877-529-1746
OUTSIDE US: (847) 763-9630
FAX: (847) 763-9631



CEO, INFORMATION SERVICES GROUP

MARC FERRARA

SENIOR VICE PRESIDENT, OPERATIONS

JEFF LEVITZ

SENIOR VICE PRESIDENT, HUMAN RESOURCES

LORRAINE ORLANDO

VICE PRESIDENT, CREATIVE SERVICES & PRODUCTION

MONICA TETTAMANZI

VICE PRESIDENT, CIRCULATION

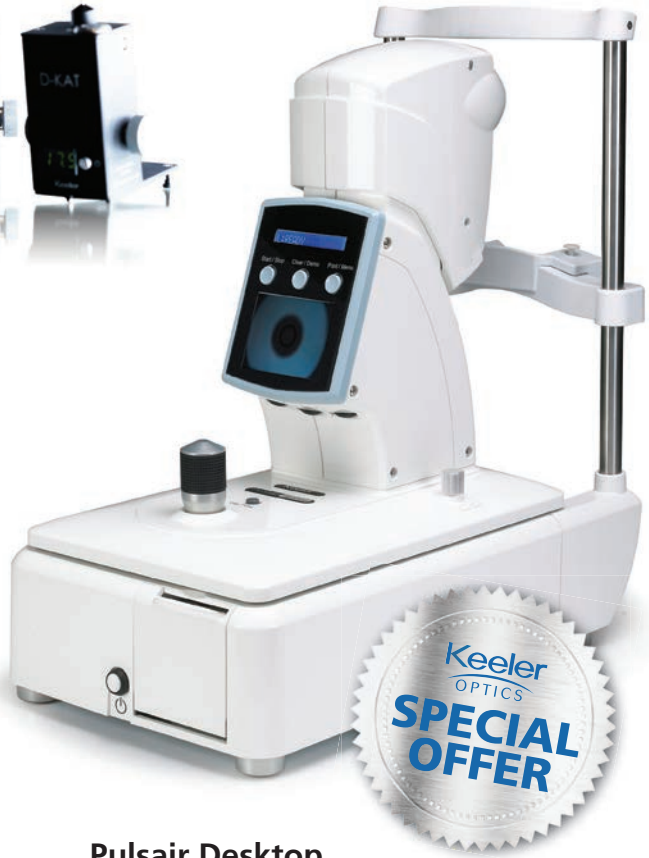EMELDA BAREA

Tonometry Done Right

new



D-KAT Digital
Keeler quality.



Pulsair Desktop
Smallest footprint and simple to use!

*Purchase a Pulsair Desktop
by June 30, 2015 and get
a \$1,300 Instant Rebate!*

Intellipuff
The standard for hand held mobility.

Buy Online!
keelerusa.com



Keeler
OPTICS



Hello Miru. Bye, bye blister pack.

Introducing Miru 1day, the world's thinnest package for daily disposable contact lenses.

Miru's ultra lightweight 1mm thin package is about 1/8th the thickness of a traditional blister pack and was specifically developed to reduce the risk of microbial contamination. When opened, the lens is presented on a special disk, oriented correctly for proper insertion.

To learn more and request trials, please visit: miru.meniconamerica.com

Contents

Review of Optometry May 2015

32 Take Charge of Diabetic Care

Eye care is on the front lines of this public health crisis. Arm yourself with the latest advice to keep patients healthy.

By A. Paul Chous, MA, OD

16th Annual Dry Eye Report

53 Who's Right: The Patient or the Test?

What do you do when a patient complains of severe dry eye symptoms but objective testing doesn't agree? Or vice versa?

By Whitney Hauser, OD

61 Whet Your Appetite for New Dry Eye Drugs

Doctors have few choices to treat this growing diagnosis, but that may change soon. Here's 10 medications in the pipeline.

By I. Ben Gaddie, OD

67 Essential Procedures at the Slit Lamp: How to Impress (and Express) Your Patients

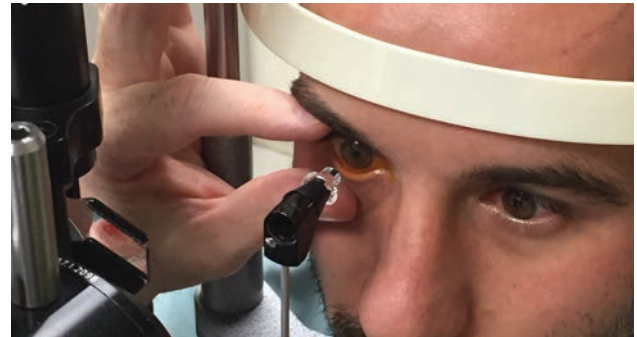Want to express meibomian glands like a pro? Here's a step-by-step tutorial.

By Jonathan Hatley, OD, and Nathan Lighthizer, OD

43 The Do's and Don'ts of Measuring IOP

Obtaining an accurate IOP reading can be challenging. Try these tonometry tips to help you develop a trustworthy technique.

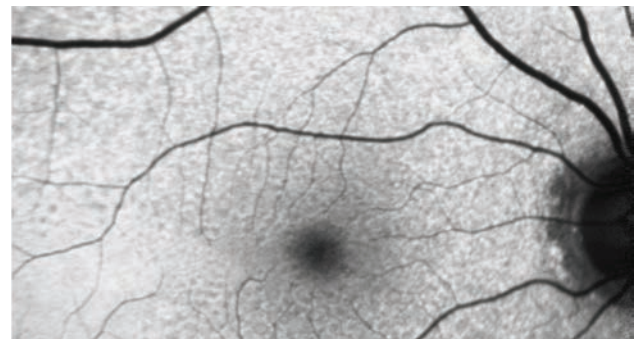
By Natalie A. Townsend, OD, and John J. McSoley, OD



79 Recognize Distinctions in Women's Eye Health

Some issues, both ocular and systemic, have a greater impact on women than men. Learn to identify when the difference can affect how you practice.

By Jill Autry, OD, RPh, Diana Shechtman, OD, Susan A. Cotter, OD, and Louise Sclafani, OD



88 Vision Expo East Emphasizes Tech

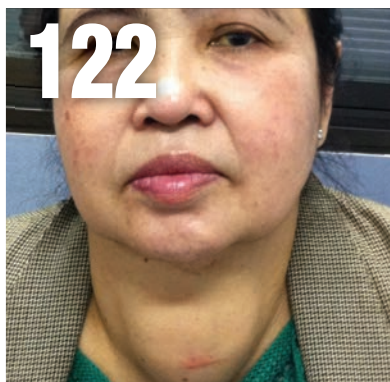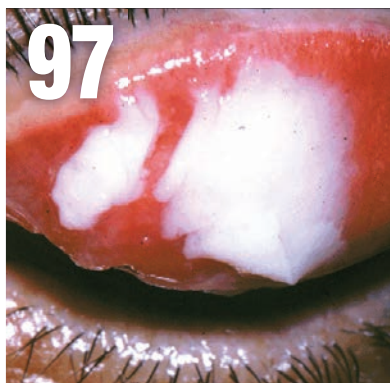
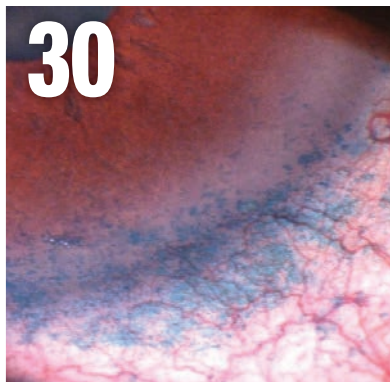
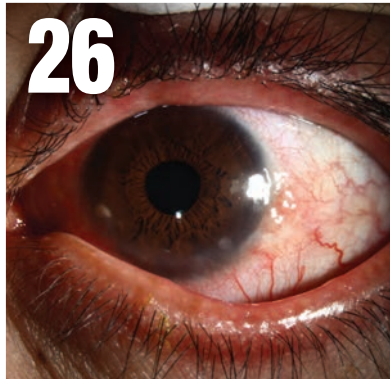
Technology continues to revolutionize how you learn and care for patients—but it can also be harmful in some situations.

By Cheryl G. Murphy, OD, Contributing Editor

Departments

Review of Optometry May 2015

- 4 News Review**
- 18 Outlook**
FDA, Heal Thyself
JACK PERSICO
- 20 Chairside**
Chillin' Like a Grandma
MONTGOMERY VICKERS, OD
- 22 Neuro Clinic**
Optic Pallor Prompts VEP Test
**MICHAEL TROTTINI, OD, AND
MICHAEL DELGIODICE, OD**
- 26 Ocular Surface Review**
Getting a Grip on Blepharitis
PAUL KARPECKI, OD
- 30 Clinical Quandaries**
Eye Acts Up as IOP Goes Down
PAUL C. AJAMIAN, OD
- 92 Coding Connection**
Clarifying Dry Eye Coding
JOHN RUMPAKIS, OD, MBA
- 94 Cornea + Contact Lens Q+A**
Blood, Tears and Albumin
JOSEPH P. SHOVLIN, OD
- 97 Review of Systems**
Red Eye Gone (Adeno) Viral
**CARLO J. PELINO, OD,
JOSEPH J. PIZZIMENTI, OD, AND
BISANT A. LABIB, OD**
- 103 Retina Quiz**
Pick Your Poison
MARK T. DUNBAR, OD
- 107 Therapeutic Review**
Give Patients a Recovery Roadmap
**JOSEPH W. SOWKA, OD, AND
ALAN G. KABAT, OD**
- 111 Surgical Minute**
Femto Surgery: A Cut Above?
**DEREK N. CUNNINGHAM, OD, AND
WALTER O. WHITLEY, OD, MBA**
- 115 Product Review**
- 116 Meetings + Conferences**
- 117 Advertisers Index**
- 118 Classifieds**
- 122 Diagnostic Quiz**
The Loitering Lump
ANDREW S. GURWOOD, OD



On The Web >> and more

Check out our multimedia and continuing education online at:
www.reviewofoptometry.com

Digital Edition



Left your copy of *Review of Optometry* at the office? No problem! Access *Review* on your computer or mobile device!

Go to www.reviewofoptometry.com and click on the digimag link for the current issue.

Facebook and Twitter



For daily updates, "Like" our page on Facebook or "Follow" us on Twitter!


- www.facebook.com/revoptom
- <http://twitter.com/#!/revoptom>

Look for augmented content and special offers from *Review* and our advertisers. Specified pages work in conjunction with your smartphone or other mobile device to enhance the experience. With Layar, interactive content leaps off the page!



Step 1: Download the free Layar app for iPhone or Android.



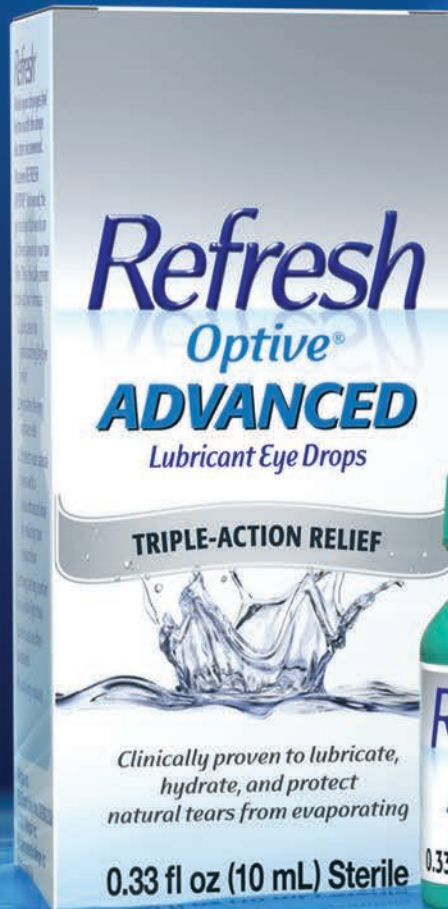Step 2: Look for pages with the Layar Logo.  INTERACTIVE PRINT



Step 3: Open the Layar app, hold the phone above the page and tap to scan it. Hold the phone above the page to view the interactive content.

The first 150 app downloads and completed forms will be entered into a drawing for a complimentary registration to one of *Review's* 14-hour CE meetings, valued at \$495.

Stock Images: ©iStock.com/JobsonHealthcare



Shaking
Required



No Shaking
Required



A brilliantly simple choice.

REFRESH OPTIVE® *Advanced* is formulated so that it doesn't separate in the bottle. This means your patients don't need to shake it prior to use.

refreshbrand.com/doc

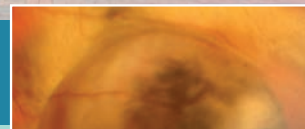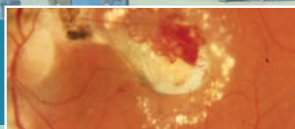
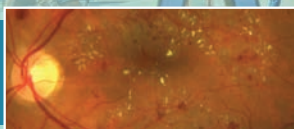
Up to
12 CE
Credits
(COPE approval pending)

REGISTRATION OPEN:
DECEMBER 4-5, 2015
ANAHEIM, CA



**THE OPTOMETRIC RETINA SOCIETY
AND REVIEW OF OPTOMETRY PRESENT:**

RETINA UPDATE 2015 | CALIFORNIA



Co-Chairs



Joseph Pizzimenti, OD



Brad Sutton, OD

Featured Faculty



Hajir Dadgostar, MD, PhD
Distinguished Retinal Surgeon



Stuart Richer, OD



Blair Lonsberry, OD



Jeffry Gerson, OD



Steve Ferrucci, OD

ORS Mission Statement

“The mission of the Optometric Retina Society (ORS) is to promote the advancement of vitreoretinal knowledge for clinicians, ophthalmic educators, residents, and students. The ORS is dedicated to posterior segment disease prevention, diagnosis, management and co-management.”

Sheraton Park Hotel

At the Anaheim Resort
1855 S. Harbor Boulevard
Anaheim, CA 92802

For hotel reservations call: 866-837-4197
Standard Room Rate: \$149/night

3 Ways to Register

Online:

www.revoptom.com/ORSRETUPDATE2015

Email Lois DiDomenico:

ReviewMeetings@Jobson.com

Phone:

877-451-6510

Stock Image: ©iStock.com/JobsonHealthcare

Course Topics

- Nutrition and Genetics in Retinal Wellness
- New Paradigms in Retinal Vascular Disease
- Vitreoretinal Grand Rounds
- Medical and Surgical Retina Update
- Macular Holes and Epiretinal Membranes
- What's New in Retinal Imaging

Administered By
Review of Optometry[®]


Approval pending

CONTRIBUTING EDITORS

PAUL C. AJAMIAN, OD, ATLANTA
AARON BRONNER, OD, KENNEWICK, WASH.
MILE BRUJIC, OD, BOWLING GREEN, OHIO
DEREK N. CUNNINGHAM, OD, AUSTIN, TEXAS
MARK T. DUNBAR, OD, MIAMI
ARTHUR B. EPSTEIN, OD, PHOENIX
JAMES L. FANELLI, OD, WILMINGTON, NC
FRANK FONTANA, OD, ST. LOUIS
GARY S. GERBER, OD, HAWTHORNE, NJ
ANDREW S. GURWOOD, OD, PHILADELPHIA
ALAN G. KABAT, OD, MEMPHIS, TENN.
DAVID KADING, OD, SEATTLE
PAUL M. KARPECKI, OD, LEXINGTON, KY.
JEROME A. LEGERTON, OD, MBA, SAN DIEGO
JASON R. MILLER, OD, MBA, POWELL, OHIO
CHERYL G. MURPHY, OD, BABYLON, NY
CARLO J. PELINO, OD, JENKINTOWN, PA.
JOSEPH PIZZIMENTI, OD, FORT LAUDERDALE, FLA.
JOHN RUMPAKIS, OD, MBA, PORTLAND, ORE.
DIANA L. SHECHTMAN, OD, FORT LAUDERDALE, FLA.
JEROME SHERMAN, OD, NEW YORK
JOSEPH P. SHOVLIN, OD, SCRANTON, PA.
JOSEPH W. SOWKA, OD, FORT LAUDERDALE, FLA.
MONTGOMERY VICKERS, OD, ST. ALBANS, W.VA.
WALTER O. WHITLEY, OD, MBA, VIRGINIA BEACH, VA.

EDITORIAL REVIEW BOARD

JEFFREY R. ANSHEL, OD, CARLSBAD, CALIF.
JILL AUTRY, OD, RPH, HOUSTON
SHERRY J. BASS, OD, NEW YORK
EDWARD S. BENNETT, OD, ST. LOUIS
MARC R. BLOOMENSTEIN, OD, SCOTTSDALE, ARIZ.
CHRIS J. CAKANAC, OD, MURRYSVILLE, PA.
JERRY CAVALLERANO, OD, PHD, BOSTON
WALTER L. CHOATE, OD, MADISON, TENN.
BRIAN CHOU, OD, SAN DIEGO
A. PAUL CHOUS, MA, OD, TACOMA, WASH.
ROBERT M. COLE, III, OD, BRIDGETON, NJ
GLENN S. CORBIN, OD, WYOMISSING, PA.
ANTHONY S. DIECIDUE, OD, STROUDSBURG, PA.
S. BARRY EIDEN, OD, DEERFIELD, ILL.
STEVEN FERRUCCI, OD, SEPULVEDA, CALIF.
MURRAY FINGERET, OD, HEWLETT, NY
IAN BEN GADDIE, OD, LOUISVILLE, KY.
MILTON HOM, OD, AZUSA, CALIF.
BLAIR B. LONSBERRY, MS, OD, MED, PORTLAND, ORE.
THOMAS L. LEWIS, OD, PHD, PHILADELPHIA
DOMINICK MAINO, OD, MED, CHICAGO
KELLY A. MALLOY, OD, PHILADELPHIA
RICHARD B. MANGAN, OD, LEXINGTON, KY.
RON MELTON, OD, CHARLOTTE, NC
PAMELA J. MILLER, OD, JD, HIGHLAND, CALIF.
BRUCE MUCHNICK, OD, COATESVILLE, PA.
MARC MYERS, OD, COATESVILLE, PA.
WILLIAM B. POTTER, OD, FREEHOLD, NJ
CHRISTOPHER J. QUINN, OD, ISELIN, NJ
JOHN L. SCHACHET, OD, ENGLEWOOD, COLO.
JACK SCHAEFFER, OD, BIRMINGHAM, ALA.
MICHAEL C. RADOIU, OD, STAUNTON, VA.
KIMBERLY K. REED, OD, FORT LAUDERDALE, FLA.
LEO P. SEMES, OD, BIRMINGHAM, ALA.
LEONID SKORIN, JR., OD, DO, ROCHESTER, MINN.
JOSEPH W. SOWKA, OD, FORT LAUDERDALE, FLA.
SRUTHI SRINIVASAN, PHD, BS OPTOM, WATERLOO, ONT.
BRAD M. SUTTON, OD, INDIANAPOLIS
LORETTA B. SZCZOTKA, OD, PHD, CLEVELAND
TAMMY P. THAN, MS, OD, BIRMINGHAM, ALA.
RANDALL THOMAS, OD, CONCORD, NC
KATHY C. WILLIAMS, OD, SEATTLE
KAREN YEUNG, OD, LOS ANGELES

LacriPro®

PUNCTUM PLUG



**PROVEN
OCCLUSION
THERAPY.
ENOUGH SAID.**

**CALL 800-367-8327
FOR INTRODUCTORY PRICING**



Lacrimedics®

(800) 367-8327

E-mail: info@lacrimedics.com

www.lacrimedics.com

©2015 Lacrimedics, Inc.



PRINTED IN USA

FOUNDING EDITOR
FREDERICK BOGER
1891-1913

EDITORIAL OFFICES

11 CAMPUS BLVD., SUITE 100
NEWTOWN SQUARE, PA 19073

EMAIL • REVIEWOFOPTOMETRY@JOBSON.COM

WEBSITE • WWW.REVOPTOM.COM

SUBSCRIPTION INQUIRIES

1-877-529-1746

CONTINUING EDUCATION INQUIRIES

1-800-825-4696

EDITOR-IN-CHIEF • JACK PERSICO

(610) 492-1006 • JPERSICO@JOBSON.COM

EXECUTIVE EDITOR • JOHN MURPHY

(610) 492-1021 • JMURPHY@JOBSON.COM

SENIOR EDITOR • BILL KEKEVIAN

(610) 492-1003 • BKEKEVIAN@JOBSON.COM

SENIOR ASSOCIATE EDITOR • REBECCA HEPP

(610) 492-1005 • RHEPP@JOBSON.COM

ASSOCIATE EDITOR • ALIZA MARTIN

(610) 492-1043 • AMARTIN@JOBSON.COM

DIRECTOR ART/PRODUCTION • JOE MORRIS

(610) 492-1027 • JMORRIS@JOBSON.COM

ART DIRECTOR • JARED ARAUJO

(610) 492-1032 • JARAUIO@JOBSON.COM

DIRECTOR OF CE ADMINISTRATION • REGINA COMBS

(212) 274-7160 • RCOMBS@JOBSON.COM

EDITORIAL BOARD

CHIEF CLINICAL EDITOR • PAUL M. KARPECKI, OD
ASSOCIATE CLINICAL EDITORS • JOSEPH P. SHOVLIN, OD;
ALAN G. KABAT, OD; CHRISTINE W. SINDT, OD
DIRECTOR OPTOMETRIC PROGRAMS • ARTHUR EPSTEIN, OD
CLINICAL & EDUCATION CONFERENCE ADVISOR
PAUL M. KARPECKI, OD
CASE REPORTS COORDINATOR • ANDREW S. GURWOOD, OD
CLINICAL CODING EDITOR • JOHN RUMPAKIS, OD, MBA
CONSULTING EDITOR • FRANK FONTANA, OD

COLUMNISTS

CHAIRSIDE • MONTGOMERY VICKERS, OD
CLINICAL QUANDARIES • PAUL C. AJAMIAN, OD
CORNEA & CONTACT LENS Q+A • JOSEPH P. SHOVLIN, OD
DIAGNOSTIC QUIZ • ANDREW S. GURWOOD, OD
GLAUCOMA GRAND ROUNDS • JAMES L. FANELLI, OD
OCULAR SURFACE REVIEW • PAUL M. KARPECKI, OD
URGENT CARE • RICHARD B. MANGAN, OD
RETINA QUIZ • MARK T. DUNBAR, OD
REVIEW OF SYSTEMS • CARLO J. PELINO, OD;
JOSEPH J. PIZZIMENTI, OD
SURGICAL MINUTE • DEREK N. CUNNINGHAM, OD;
WALTER O. WHITLEY, OD, MBA
THERAPEUTIC REVIEW • JOSEPH W. SOWKA, OD;
ALAN G. KABAT, OD
NEURO CLINIC • MICHAEL TROTTINI, OD;
MICHAEL DELGODICE, OD
FOCUS ON REFRACTION • MARC TAUB, OD;
PAUL HARRIS, OD

JOBSON MEDICAL INFORMATION LLC



FDA, Heal Thyself

Bold new legislation might make this famously sclerotic agency more agile. **By Jack Persico, Editor-in-Chief**

Retooling the FDA is overdue. The pace of drug and device approvals is glacial, and the rules prohibiting discussion of off-label uses are heavy-handed. Just recently, we saw the agency turn down Avedro's NDA for collagen crosslinking—even though it had been recommended for approval by the FDA's advisory committee and similar technology has been used in Europe for a decade. Did that benefit, or constrain, the public good? No one wants to ease up on safeguards, but there are clearly ways in which the current system falls short.

Fixing the FDA is but one aspiration of ambitious new legislation called the 21st Century Cures Act introduced in late April. It's loaded with admirable goals—some big, some small (see sidebar). But delivering on them is far from guaranteed; how likely is improved EHR interoperability, for instance?

Highlights of the Act

- Increase funding for the NIH and provide student loan forgiveness for its researchers.
- Build a global pediatric clinical trial network.
- Accelerate “the discovery, development, and delivery” of therapy for rare diseases via a partnership among FDA, NIH and industry.
- Improve patient access to drugs for compassionate use.
- Expand the FDA's Patient-Focused Drug Development program, which takes patient's real-world experiences into account.
- Encourage development of biomarkers.
- Improve the design of clinical trials and access to trial data.
- Improve EHR interoperability.
- Encourage antibiotic drug development to combat bacterial resistance.
- Many FDA approval revisions (see text).

Specific to the FDA, the package contains many good ideas for prodding the agency to accelerate new drug approvals. Three notable ones: (1) allow more use of intermediate study endpoints that suggest viability of an investigational drug, (2) collaborate with European regulatory agencies and (3) streamline review of an existing approved product that's being considered for a new indication (this last one, while a great idea, is limited to cancer treatment.) Medical device approvals would also get a boost, as the bill would allow priority review for breakthrough technologies deemed genuinely new and broaden the definition of “valid scientific evidence” to include, among other things, international data, which is often in abundance.

But the bill's authors backed off from one long-hoped-for update: less Draconian rules for discussion of off-label uses. An earlier draft had a placeholder for efforts to encourage “responsible communication of scientific and medical developments” beyond label indications, but it has been cut. The current draft would allow manufacturers to inform insurers about the *economic* benefits of off-label uses, but not doctors about *clinical* benefits—a telling choice of priorities by legislators. I don't see how you can have the one without the other. The instinct to prevent bias or weak science from influencing the discussion of medical products is admirable, but we shouldn't let that justify a gag rule that keeps doctors in the dark. Still, there are many welcome “cures” here—if Congress is willing to write the Rx. ■

NOW APPROVED

Pazeo[™]

(olopatadine hydrochloride
ophthalmic solution) 0.7%



ANTICIPATED RETAIL AVAILABILITY MARCH 10

From Alcon, committed to providing new treatment options for patients.

Alcon[®]
a Novartis company

Olopatadine is licensed from Kyowa Hakko Kirin Co., Ltd. Japan
©2015 Novartis 01/15 PAZ15017JAD

Pazeo[™]
(olopatadine hydrochloride
ophthalmic solution) 0.7%



Chillin' Like a Grandma

Maybe my grandmother Mimi had it all figured out: just chill. But good luck doing that in our line of work. **By Montgomery Vickers, OD**

Mimi, my grandmother, used to say, “charge it to the sand and let the rain settle it.” She didn’t worry about anything that I recall. When boys came to court her four girls, she let them shoot at the bannister in the house with her BB gun so they wouldn’t be bored. (The marks are still there.)

When an evangelist came to her door (she was 87) and asked her, “Ma’am, are you a Christian?” Mimi answered, “Hell, no, I’m a Presbyterian!”

When she was 89, she told me her goal was to live to be “a hundred” [*sic*] and then she wanted me to throw her under the train “up Montgomery.” She lived to 99 and 11 months. I was 30 days away from the penitentiary when she let me off the hook!

I wish I had inherited that kind of devil-may-care attitude. Instead, I have to consciously feed my frantic life with calm words, thoughts and deeds. It’s been a tussle, but I am actually pretty chill about life at this point. It only took 61 years.

To navigate the next 20 years of medical care change in this country, you’d better get on board with how Mimi lived; you all need to find your happy place.

The hardest part is when a life-long diabetic comes in after skipping his eye exams for 10 years and, when you look in his eye, you see a large pepperoni pizza instead of a retina. Me? I wanna smack the tar out of him. Instead I just smile, tell him the truth and do whatever

I can to help. OK, sometimes I do smack ‘em. Whatever works.

Mentally, almost all optometrists are usually somewhere between catatonic and freaked out. It’s our nature, education and genetics. And it’s also our choice. The question is, are you chill or not? Take this simple test to find out:

1. After a patient misses his third scheduled appointment, you:

- a. Send him a get-well card.
- b. Refuse to reschedule him.
- c. Wet your pants.
- d. Wet *his* pants.

2. A patient has owed you \$12 for six years. You:

- a. Write it off and move on.
- b. Key his new car.
- c. Plan to write it off after hell freezes over.
- d. Take it out of your office manager’s paycheck.

3. When a patient calls Saturday night about last Monday’s eye injury, you:

- a. Meet him at the office that evening.
- b. Meet him the next morning.
- c. Direct him to the nearest ER.
- d. Suggest he flush his eye with river water.

4. When your aunt asks why you didn’t become a *real* doctor, you:

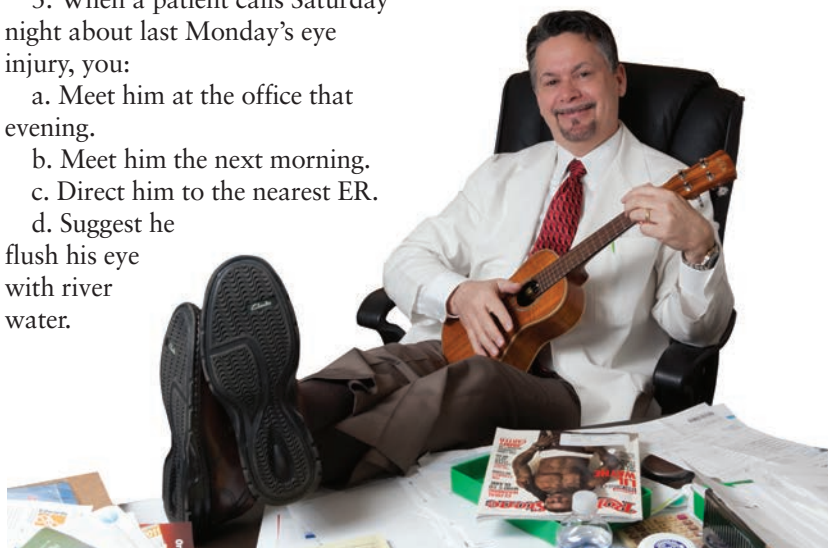- a. Tell her *real* doctors are slime.
- b. Explain D is for doctor.
- c. Ask her why her dog is so ugly.
- d. Laugh and give her a big hug.

5. When you finally go for CE in Hawaii and it rains the whole weekend, you:

- a. Put on a coconut bra and grass skirt and hula in the rain.
- b. Actually show up for the CE.
- c. Plan your next CE in the Sahara Desert.
- d. Thank God for his healing rains.

If you chose the angry and sarcastic options, you need to chill before your brain explodes.

If you answered with nothing but sweetness, you may not be a perfectly calm optometrist, but you certainly are an excellent liar. ■



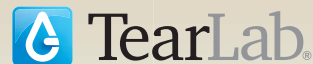“MR. HYPEROSMOLARITY IS MY NAME.
**UNDERMINING
VISUAL OUTCOMES
IS MY GAME.**”

MR.
HYPEROSMOLARITY



Hyperosmolarity is not your friend.

He is a meddlesome troublemaker who undermines your effort to achieve great vision. Discover how the TearLab® Osmolarity Test provides a fast and accurate osmolarity measurement to uncover and manage hyperosmolarity.



Visit www.tearlab.com
to find out why.



Optic Pallor Prompts VEP Test

When the visual field and SD-OCT were normal, VEP helped solve the mystery of a patient's optic nerve pallor. **By Michael Trottni, OD, and Michael DelGiodice, OD**

A 40-year-old white male presented for a LASIK evaluation with a complaint of blurry distance vision related to myopia in both eyes. His medical and ocular histories were unremarkable and he was not taking any medication. He reported no drug allergies and his past family and social histories were unremarkable.

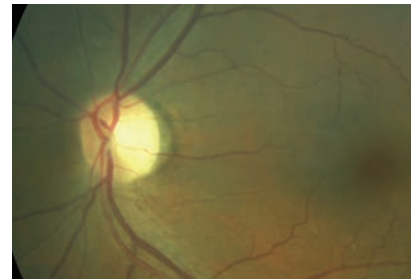
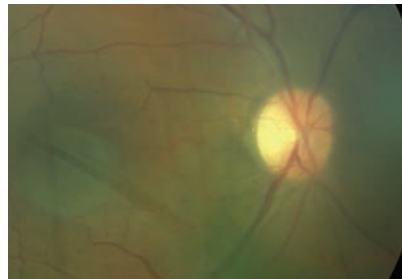
His best-corrected visual acuity was 20/20 in each eye. Ocular motility was full with no limitation and pupils were equal and reactive to light with no afferent defect. Ocular alignment was normal with an orthophoric position in primary and lateral gazes. Additionally, he noted 10 out of 10 color plates in each eye.

Intraocular pressure measured 13mm Hg OU. The anterior segment exam was unremarkable. Fundus exam showed healthy lenticular, vitreous, vascular and retinal structures. The optic nerves showed a cup-to-disc ratio of 0.20 with mild temporal disc pallor (OD>OS) and strong spontaneous venous pulsations.

Although he was asymptomatic, the disc pallor raised a red flag. So we ordered spectral-domain optical coherence tomography (SD-OCT) and visual field testing. But the SD-OCT showed a normal retinal nerve fiber layer and the visual field was full without defect in either eye.

That, too, raised a red flag.

The presence of temporal optic nerve pallor, normal retinal exami-



An asymptomatic patient presented with mild temporal optic disc pallor in both eyes. Normal SD-OCT and visual fields led us to order visual-evoked potential testing.

nation, normal SD-OCT and a full visual field prompted us to order a visual-evoked potential (VEP) test. The VEP test revealed a mild delay in amplitude and latency of both eyes, which confirmed our clinical suspicion of optic atrophy. In this case, the differential diagnosis included space-occupying lesion, demyelinating disease, nutritional optic neuropathy, autoimmune-related optic neuropathy and dominant optic atrophy. Consequently, we scheduled him for magnetic resonance imaging (MRI) of the brain and orbits with and without contrast and fat suppression.

Imaging studies revealed multiple periventricular white matter (PWM) lesions. Causes of PWM lesions are extensive but most commonly include normal senescent changes, hypertension, focal cerebrovascular accidents, demyelination, migraine, vitamin B6 (pyridoxine) deficiency and infectious or inflammatory-related vasculitis.¹

Subsequently, we ordered the following serologies: complete blood count; vitamin B6, B12 and folate; erythrocyte sedimentation rate;

comprehensive metabolic panel; angiotensin converting enzyme; lysozyme; Lyme titre; fluorescent treponemal antibody absorption; rapid plasma reagin; human immunodeficiency virus; antinuclear antibody and anti-neutrophil cytoplasmic antibody—all of which were normal.

Accordingly, we referred the patient to neurology for evaluation. The abnormal VEP test and PWM lesions on MRI prompted an additional MRI of the neck and spine, which was unremarkable.

Given the patient's age, segmental pattern of pallor, abnormal VEP test and the specific location (i.e., periventricular and juxtacortical) of MRI lesions, he was diagnosed with multiple sclerosis and started on Avonex (interferon beta-1a, Biogen).

To date, the patient is doing well.

Discussion

This case illustrates two very important points: (1) pseudopallor of the disc must be differentiated from asymptomatic optic nerve atrophy, and (2) VEP should be

A white plastic bottle of ALREX eye drops with a pink cap sits on a grassy hillside. The background is a vibrant field of wildflowers and green hills under a clear blue sky. The bottle label reads: Bausch & Lomb, Alrex, loteprednol etabonate ophthalmic suspension 0.2%.

ALREX®:

TREATS THE ITCH AND MORE.

SHORT-TERM TREATMENT FOR
THE FULL SPECTRUM OF SAC*
SIGNS AND SYMPTOMS¹⁻³

*Seasonal allergic conjunctivitis.

INDICATION

ALREX® (loteprednol etabonate ophthalmic suspension) is indicated for the temporary relief of the signs and symptoms of seasonal allergic conjunctivitis.

IMPORTANT SAFETY INFORMATION

ALREX® is contraindicated in most viral diseases of the cornea and conjunctiva, including epithelial herpes simplex keratitis (dendritic keratitis), vaccinia, and varicella, and also in mycobacterial infection of the eye and fungal diseases of the ocular structures. ALREX® is also contraindicated in individuals with known or suspected hypersensitivity to any of the ingredients of this preparation and to other corticosteroids.

Prolonged use of ALREX® is associated with several warnings and precautions, including glaucoma with optic nerve damage, defects in visual acuity, cataract formation, secondary ocular infections, and exacerbation or prolongation of viral ocular infections (including herpes simplex).

If this product is used for 10 days or longer, intraocular pressure should be monitored. The initial prescription and renewal of the medication order beyond 14 days should be made by a physician only after reexamination of the patient with the aid of magnification. Fungal infections of the cornea may develop with prolonged use of corticosteroids.

Ocular adverse reactions occurring in 5-15% of patients treated with loteprednol etabonate ophthalmic suspension (0.2%-0.5%) in clinical studies included abnormal vision/blurring, burning on instillation, chemosis, discharge, dry eyes, epiphora, foreign body sensation, itching, infection, and photophobia.

Please see brief summary of full Prescribing Information on the following page.

References: 1. ALREX [package insert]. Tampa, FL: Bausch & Lomb Incorporated; 2013. 2. Dell SJ, Lowry GM, Northcutt JA, Howes J, Novack GD, Hart K. A randomized, double-masked, placebo-controlled parallel study of 0.2% loteprednol etabonate in patients with seasonal allergic conjunctivitis. *J Allergy Clin Immunol.* 1998;102(2):251-255. 3. Shulman DG, Lothringer LL, Rubin JM, et al. A randomized, double-masked, placebo-controlled parallel study of loteprednol etabonate 0.2% in patients with seasonal allergic conjunctivitis. *Ophthalmology.* 1999;106(2):362-369.

BAUSCH + LOMB

ALREX is a trademark of Bausch & Lomb Incorporated or its affiliates.
©Bausch & Lomb Incorporated. US/ALX/15/0001a

Alrex®

loteprednol etabonate
ophthalmic suspension 0.2%

BRIEF SUMMARY OF PRESCRIBING INFORMATION

This Brief Summary does not include all the information needed to use Alrex® (loteprednol etabonate ophthalmic suspension 0.2%) safely and effectively. See full prescribing information for Alrex.

Alrex®

loteprednol etabonate
ophthalmic suspension 0.2%

Sterile Ophthalmic Suspension

Rx only

INDICATIONS AND USAGE

ALREX Ophthalmic Suspension is indicated for the temporary relief of the signs and symptoms of seasonal allergic conjunctivitis.

CONTRAINDICATIONS

ALREX, as with other ophthalmic corticosteroids, is contraindicated in most viral diseases of the cornea and conjunctiva including epithelial herpes simplex keratitis (dendritic keratitis), vaccinia, and varicella, and also in mycobacterial infection of the eye and fungal diseases of ocular structures. ALREX is also contraindicated in individuals with known or suspected hypersensitivity to any of the ingredients of this preparation and to other corticosteroids.

WARNINGS

Prolonged use of corticosteroids may result in glaucoma with damage to the optic nerve, defects in visual acuity and fields of vision, and in posterior subcapsular cataract formation. Steroids should be used with caution in the presence of glaucoma.

Prolonged use of corticosteroids may suppress the host response and thus increase the hazard of secondary ocular infections. In those diseases causing thinning of the cornea or sclera, perforations have been known to occur with the use of topical steroids. In acute purulent conditions of the eye, steroids may mask infection or enhance existing infection.

Use of ocular steroids may prolong the course and may exacerbate the severity of many viral infections of the eye (including herpes simplex). Employment of a corticosteroid medication in the treatment of patients with a history of herpes simplex requires great caution.

PRECAUTIONS

General: For ophthalmic use only. The initial prescription and renewal of the medication order beyond 14 days should be made by a physician only after examination of the patient with the aid of magnification, such as slit lamp biomicroscopy and, where appropriate, fluorescein staining. If signs and symptoms fail to improve after two days, the patient should be re-evaluated.

If this product is used for 10 days or longer, intraocular pressure should be monitored.

Fungal infections of the cornea are particularly prone to develop coincidentally with long-term local steroid application. Fungus invasion must be considered in any persistent corneal ulceration where a steroid has been used or is in use. Fungal cultures should be taken when appropriate.

Information for Patients: This product is sterile when packaged. Patients should be advised not to allow the dropper tip to touch any surface, as this may contaminate the suspension. If redness or itching becomes aggravated, the patient should be advised to consult a physician.

Patients should be advised not to wear a contact lens if their eye is red. ALREX should not be used to treat contact lens related irritation. The preservative in ALREX, benzalkonium chloride, may be absorbed by soft contact lenses. Patients who wear soft contact lenses **and whose eyes are not red**, should be instructed to wait at least ten minutes after instilling ALREX before they insert their contact lenses.

Carcinogenesis, Mutagenesis, Impairment of Fertility: Long-term animal studies have not been conducted to evaluate the carcinogenic potential of loteprednol etabonate. Loteprednol etabonate was not genotoxic *in vitro* in the Ames test, the mouse lymphoma tk assay, or in a chromosome aberration test in human lymphocytes, or *in vivo* in the single dose mouse micronucleus assay. Treatment of male and female rats with up to 50 mg/kg/day and 25 mg/kg/day of loteprednol etabonate, respectively, (1500 and 750 times the maximum clinical dose, respectively) prior to and during mating did not impair fertility in either gender.

Pregnancy: Teratogenic effects: Pregnancy Category C. Loteprednol etabonate has been shown to be embryotoxic (delayed ossification) and teratogenic (increased incidence of meningocele, abnormal left common carotid artery, and limb flexures) when administered orally to rabbits during organogenesis at a dose of 3 mg/kg/day (85 times the maximum daily clinical dose), a dose which caused no maternal toxicity. The no-observed-effect-level (NOEL) for these effects was 0.5 mg/kg/day (15 times the maximum daily clinical dose). Oral treatment of rats during organogenesis resulted in teratogenicity (absent innominate artery at ≥ 5 mg/kg/day doses, and cleft palate and umbilical hernia at ≥ 50 mg/kg/day) and embryotoxicity (increased postimplantation losses at 100 mg/kg/day and decreased fetal body weight and skeletal ossification with ≥ 50 mg/kg/day). Treatment of rats with 0.5 mg/kg/day (15 times the maximum clinical dose) during organogenesis did not result in any reproductive toxicity. Loteprednol etabonate was maternally toxic (significantly reduced body weight gain during treatment) when administered to pregnant rats during organogenesis at doses of ≥ 5 mg/kg/day.

Oral exposure of female rats to 50 mg/kg/day of loteprednol etabonate from the start of the fetal period through the end of lactation, a maternally toxic treatment regimen (significantly decreased body weight gain), gave rise to decreased growth and survival, and retarded development in the offspring during lactation; the NOEL for these effects was 5 mg/kg/day. Loteprednol etabonate had no effect on the duration of gestation or parturition when administered orally to pregnant rats at doses up to 50 mg/kg/day during the fetal period.

There are no adequate and well controlled studies in pregnant women. ALREX Ophthalmic Suspension should be used during pregnancy only if the potential benefit justifies the potential risk to the fetus.

Nursing Mothers: It is not known whether topical ophthalmic administration of corticosteroids could result in sufficient systemic absorption to produce detectable quantities in human milk. Systemic steroids appear in human milk and could suppress growth, interfere with endogenous corticosteroid production, or cause other untoward effects. Caution should be exercised when ALREX is administered to a nursing woman.

Pediatric Use: Safety and effectiveness in pediatric patients have not been established.

ADVERSE REACTIONS

Reactions associated with ophthalmic steroids include elevated intraocular pressure, which may be associated with optic nerve damage, visual acuity and field defects, posterior subcapsular cataract formation, secondary ocular infection from pathogens including herpes simplex, and perforation of the globe where there is thinning of the cornea or sclera.

Ocular adverse reactions occurring in 5-15% of patients treated with loteprednol etabonate ophthalmic suspension (0.2% - 0.5%) in clinical studies included abnormal vision/blurring, burning on instillation, chemosis, discharge, dry eyes, epiphora, foreign body sensation, itching, injection, and photophobia. Other ocular adverse reactions occurring in less than 5% of patients include conjunctivitis, corneal abnormalities, eyelid erythema, keratoconjunctivitis, ocular irritation/pain/discomfort, papillae, and uveitis. Some of these events were similar to the underlying ocular disease being studied.

Non-ocular adverse reactions occurred in less than 15% of patients. These include headache, rhinitis and pharyngitis.

In a summation of controlled, randomized studies of individuals treated for 28 days or longer with loteprednol etabonate, the incidence of significant elevation of intraocular pressure (≥ 10 mm Hg) was 2% (15/901) among patients receiving loteprednol etabonate, 7% (11/164) among patients receiving 1% prednisolone acetate and 0.5% (3/583) among patients receiving placebo. Among the smaller group of patients who were studied with ALREX, the incidence of clinically significant increases in IOP (≥ 10 mm Hg) was 1% (1/133) with ALREX and 1% (1/135) with placebo.

DOSAGE AND ADMINISTRATION

SHAKE VIGOROUSLY BEFORE USING.

One drop instilled into the affected eye(s) four times daily.

Revised: August 2013.

Bausch & Lomb Incorporated, Tampa, Florida 33637

©Bausch & Lomb Incorporated

Alrex® is a registered trademark of Bausch & Lomb Incorporated

Based on 9007904-9005504

US/ALX/15/0004

Issued: 02/2015

measured in suspected cases of optic nerve pallor when SD-OCT and visual field are unremarkable.

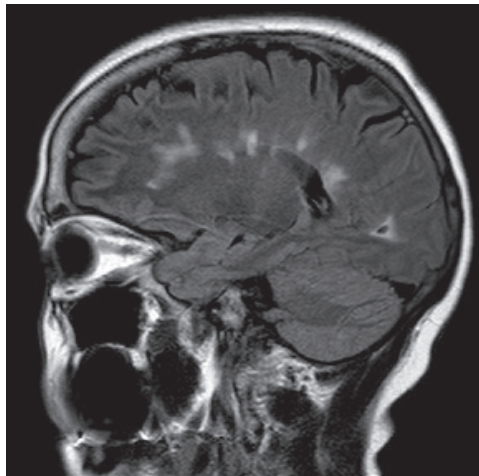
The normal color of the disc is a manifestation of the interaction between the superficial nerve fiber layer and the deeper intraretinal vascular plexus. The hue of the disc is fairly subjective, and the temporal portion is often lighter in color than the rest of the disc because there are fewer densely packed capillaries at this location. This is why crowded discs appear hyperemic and large myopic discs often appear pale temporally. However, in pathologic pallor, loss of nerve fiber layer results in light reflecting off glial cells on the surface of the disc.

Subsequently, there are certain conditions that can create the illusion of pallor. Mimickers of optic atrophy include physiologic myopic temporal pallor, aphakia, pseudophakia, tilted discs, optic nerve hypoplasia and myelinated nerve fibers.²

Optic atrophy can clinically present as diffuse or segmental, the latter of which may be altitudinal, temporal or bowtie (band) in configuration. Although diffuse optic atrophy is non-specific, segmental pallor often yields a specific disease entity based on a pattern:

- *Altitudinal pallor* is often observed in vascular disease such as anterior ischemic optic neuropathy.
- *Temporal pallor*, as seen in our patient, is typical of optic neuritis, toxic/nutritional, and hereditary optic neuropathies.³
- *Band atrophy* is observed in chiasmal syndromes and optic tract lesions.⁴

Additional clinical findings that may help support true optic nerve atrophy include identifying the



MRI revealed white matter lesions, which indicated a demyelinating condition.

presence of a segmental pattern and the presence of collateral venous vessels, macular exudates, attenuated arterioles and high water mark sign.² Formal VF testing, OCT and electrophysiological tests (i.e., VEP) are also helpful. In our patient, the VF and SD-OCT were unremarkable, but the VEP showed a decrease in amplitude and latency, which confirmed our suspicion of mild optic nerve atrophy.

VEPs are electrical signals that are a measure of the electrophysiological activity at the visual cortex and are part of the total electrical brain activity, as measured by electroencephalogram. VEPs are a representation of the visual pathway function from the anterior segment to the visual cortex.

The VEP will elicit waveform, amplitude and latency responses based on a delivered stimulus to the visual system. Amplitude indicates how much information is reaching the visual cortex whereas latency (peak time) indicates the time the electrical signal takes to travel from the retina to the visual cortex. Latency measurements can reveal issues affecting vision if it takes more time than usual for the

electrical signals to reach the visual cortex.⁵ A large number of clinical studies have shown that VEP tests can reveal demyelinating lesions in the optic nerve and are more sensitive in confirming both clinical and subclinical optic neuropathy when compared to optical coherence tomography.⁶

In this particular case, temporal pallor of the disc was the only questionable clinical finding. Since the patient's visual acuity was normal and ancillary findings were unremarkable, we believed this was representative of a chronic intracranial process.

After MRI revealed PWM lesions and serology discounted additional pathology, we were highly suspicious of a chronic demyelinating condition. Because the patient had no prior occurrence of acute or subacute vision loss, the most likely cause was a slow, chronic conduction deficit from demyelination of the optic nerve. This explains why the OCT and VF were unremarkable and the VEP test was abnormal. If demyelination were to continue to affect the nerve, we would expect to find papillomacular bundle field defects and associated nerve fiber layer loss.

Ultimately, we advocate for testing VEP to differentiate pseudopallor from asymptomatic optic atrophy if the visual field and SD-OCT are normal. ■

1. Barkhof F, Scheltens P. Imaging of white matter lesions. *Cerebrovasc Dis.* 2002;13 Suppl 2:21-30.
2. Digre KB, Corbett JJ. *Practical Viewing of the Optic Disc.* Massachusetts: Butterworth-Heinemann, 2002.
3. Rath EZ, Rehany U, Linn S, Rumelt S. Correlation between optic disc atrophy and aetiology: anterior ischaemic optic neuropathy vs optic neuritis. *Eye (Lond).* 2003 Nov;17(9):1019-24.
4. Miller NR, Newman NJ, Bioussé V, Kerrison JB, Walsh & Hoyt's *Clinical Neuro-Ophthalmology: The Essentials.* 2nd ed. Philadelphia: Lippincott; 2007.
5. Odom JV, Bach M, Brigell M, et al. ISCEV standard for clinical visual evoked potentials (2009 update). *Doc Ophthalmol.* 2010 Feb;120(1):111-9.
6. Naismith RT, Tuttlam NT, Xu J, et al. Optical coherence tomography is less sensitive than visual evoked potentials in optic neuritis. *Neurology.* 2009 Jul;73(1):46-52.



Getting a Grip on Blepharitis

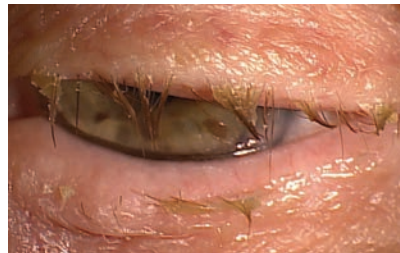Are you customizing treatment to the specific form of anterior blepharitis present? You should be. Here's why. **By Paul M. Karpecki, OD**

One of the biggest challenges in ocular surface disease is that the term itself is a misnomer: in very many cases, although the effects manifest on the ocular surface, the disease process takes place on the eyelids. So, when managing dry eye, it is imperative that you begin your clinical and diagnostic assessment with the eyelids and the problems that can occur there.

This concept was first emphasized in the International Task Force's Dysfunctional Tear Syndrome Delphi Approach Report, and most recently as a primary recommendation from the Dry Eye Summit held in Dallas-Fort Worth this past December.¹ It helps you realize the part blepharitis plays in dry eye disease—whether it's anterior blepharitis affecting the eyelashes and eyelids or the posterior blepharitis at work in meibomian gland dysfunction (MGD). Blepharitis affects all ages and all ethnic groups; in one survey ophthalmologists and optometrists reported that 37% to 47% of all patients they saw had blepharitis.²

Not All Blepharitis Cases are the Same

I started my first dry eye clinic almost 20 years ago, and I have to admit that in the early days I treated all blepharitis as if it were the same. Not only did I fail to differentiate between the types of anterior blepharitis, at the time I truly didn't know to look for posterior blepharitis or MGD. No wonder I struggled for so many years in managing these



The debris on these eyelashes indicates **Staphylococcal blepharitis**.

patients, despite my practice's focus on dry eye disease management.

Fortunately, newer research has paved the way for a better understanding of the disease. That, combined with chronic clinical defeat or frustration, forces you to solve these problems and uncover insights worth implementing in clinical practice. One of those insights is to diagnose not simply "anterior blepharitis" but also the *type* of anterior blepharitis, and then customize your treatments accordingly.

Blepharitis is simply defined as inflammation of the eyelids. Because of this overly broad definition, many forms of lid disease qualify as "blepharitis," including some—such as periorbital eczema in cases of atopic keratoconjunctivitis—that we wouldn't normally feel inclined to define that way. Below, we'll focus on three common anterior blepharitis types and discuss their key symptoms, signs and treatment options.

Staphylococcal Blepharitis

The organisms *Staphylococcus epidermidis* and *Staphylococcus aureus* are ubiquitous on the human body.

For multifactorial reasons, certain patients develop an overabundance of these bacteria, leading to complaints that typically include:

- matting/crusting
- debris on the lashes
- irritated or swollen eyelids and eyelash margins
- hordeola development
- eyelid ulceration, in severe cases
- potential conjunctival involvement

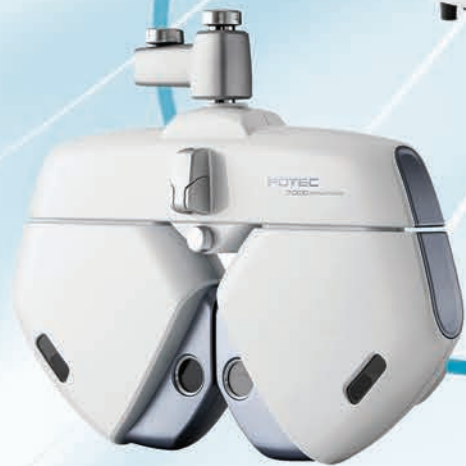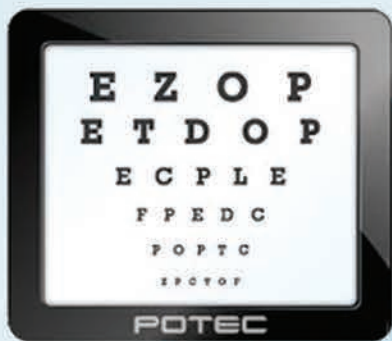The classic appearance of *Staph.* blepharitis is described as yellowish debris or collarettes, matter or discharge and erythema and hyperemia of the eyelid margins.³ This condition can lead to damage of the eyelid margins, including ductal metaplasia, tear film instability and even primary and postsurgical infections.

Treatment for *Staph.* blepharitis should include eyelid hygiene involving commercial foam surfactant cleansers, warm compresses and hypochlorous acid-based cleansers for more severe forms. Topical antibiotics are effective in acute cases where the bacterial component is the primary cause.⁴ In chronic cases, the condition becomes more inflammatory, and combination agents (antibiotic/steroid drops and ointments) seem to work well in treating the infection and inflammation.^{5,6} You can also provide in-office mechanical treatments to reduce the bacterial colonization to a proper level.

Long-term maintenance is best achieved with patient education about the chronic nature of the disease and that there is no known cure,

YOUR EXAM... ONLY BETTER!

The Veatch Digital Refraction System eliminates costly inefficiencies, enhances your practice, and makes the exam process more enjoyable for you and your patients.



FREE
Visual Acuity System*
with purchase of
Digital Refractor

- Increased efficiency • Combat reductions in reimbursements
- Enhanced practice image • EMR integration • Patient referrals
- Increased optical sales • Competitive advantage
- Eliminate back and shoulder pain and bursitis

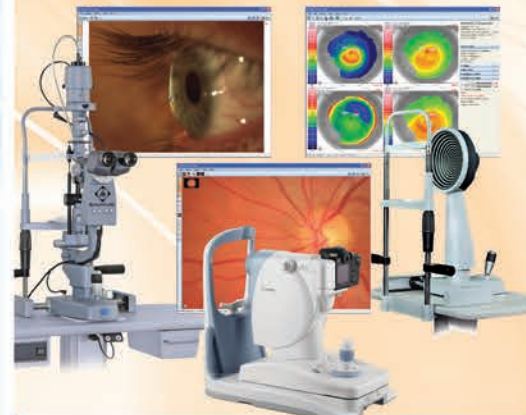
ADDITIONAL OFFERS FROM VEATCH

Exam Lane Packages
Starting at \$12,995



ReSeeVit™

- Anterior Segment Imaging
- Retinal Imaging
- Corneal Wavefront Topography

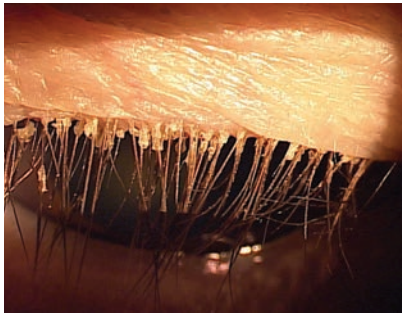

Insight Visual Acuity System
ONLY \$1,295



TOLL FREE: 800.447.7511 E-MAIL: ad@voi2020.com www.voi2020.com





Collarettes around the base of the lashes is a sign this blepharitis is caused by *Demodex*.

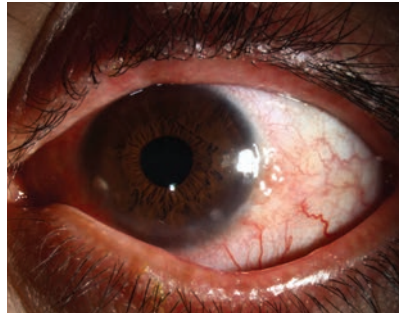


Photo: Christine Smith, OD

It's also common for patients to have both anterior and posterior blepharitis simultaneously, as seen here.

along with routine use of commercial eyelid cleansers.⁷

Demodex Blepharitis

The eyelid mites *Demodex brevis* and *Demodex folliculorum* become more prevalent as we age, and studies have shown that the majority of blepharitis cases in patients above age 60 are caused by *Demodex*.⁸ Patients with rosacea are much more likely to experience *Demodex* blepharitis as well. The average healthy person has over 2,000 *Demodex* mites on their body at any given time.⁹ Overabundance results in a presentation of clear 'sleeves' and debris that appear to be focused primarily at the base of the lashes.

The most common complaint of patients is itching of the lid margins and, in longstanding cases, madarosis or loss of lashes. Perhaps the most common way that it has traditionally been diagnosed is as a last resort, when the presentation is unresponsive to other treatments.¹⁰ As clinicians, we should raise our level of suspicion and awareness in at-risk patients rather than allowing it to be a diagnosis of exclusion.

Treatment requires the use of tea tree oil, and most effective treatments are usually approaching a concentration of 50%. Formulations above 50% are often too strong for the ocular surface and can be

uncomfortable to the patient. There are a number of commercial in-office 'kits' available to treat this form of blepharitis and appear to be superior or at least less uncomfortable than creating a 50% tea tree oil solution on your own.

High concentrations or impurities in tea tree oil can be uncomfortable for patients, so companies have found novel ways to minimize that concentration or the toxins that could be present. The Ocusoft *Demodex* kit adds buckthorn seed oil to the tea tree oil, as both ingredients have been shown to be effective against *Demodex* mites. Cliradex (BioTissue) isolates the active ingredient in tea tree oil, known as 4-terpineol, in its Cliradex Complete kits, thus avoiding many of the potential toxins that could be present in commercial tea tree solutions.

In addition to the tea tree oil, these kits often contain a double-sided brush—one side for applying the solution and the other side for scrubbing the lid margins. You could also use a mechanical in-office cleaner. This treatment should be performed after applying topical anesthetic to the upper eyelid margins. Wait three to five minutes and then repeat the anesthetic and treatment. Most patients require multiple treatments and should be advised to use the other products in the kits at home

each night. Patients will typically mention burning or tingling during or after the procedure. Be sure that during treatment, patients keep their eyes closed at all times to avoid corneal abrasion.

This form of blepharitis is chronic, and patients must expect it to return, but hopefully not for months or years. Maintenance may help and can involve Cliradex pads periodically or commercial cleansers such as Oust Demodex Cleanser (Ocusoft) or SteriLid (TheraTears) that have a small amount of tea tree oil present, not likely sufficient for a primary treatment but perhaps for maintenance after the in-office treatments used on a consistent daily basis.

Seborrheic Blepharitis

A third form of blepharitis is the dermatologic condition known as seborrheic blepharitis. This is often described as oily or greasy eyelid deposits, mild conjunctival injection and inferior punctate epithelial erosions; however, it rarely produces any effects on the eyelashes.¹¹ Patients with this form of blepharitis will often present with complaints that focus on the eyelids themselves, including irritation, redness and occasionally itching.

This condition is best treated with a topical corticosteroid such as triamcinolone cream 0.1% or, if you are concerned about the patient getting the product in the eyes, an ophthalmic steroid such as Lotemax (loteprednol, Bausch + Lomb) or fluorometholone ointment (FML, Allergan). Patients should use corticosteroids on the eyelids for no more than two to three weeks. Fluorinated steroids, for example, have been shown to cause eyelid thinning or discoloration with long-term use.¹²

This form of blepharitis is also chronic and will return. Patients may be able to keep it maintained with

daily use of commercial lid scrub surfactant cleansers.

Each of these forms of blepharitis has a different presentation, and each also has a different approach to treatment. Maintenance therapies (lid hygiene) are similar among the subgroups, yet various options exist depending on presentation and severity. Finally, it is important for patients to understand that blepharitis, like arthritis, is a condition that cannot currently be cured.¹³ But like arthritis, if under the good care of a doctor and with steady compliance, patients can go months or years with few symptoms. Understanding the types of anterior blepharitis in presentation and treatment will better help you manage this common ocular surface disease that affects millions of patients. ■

1. Behrens A, Doyle JJ, Stern L, et al. Dysfunctional tear syndrome: a delphi approach to treatment recommendations. *Cornea*. 2006;25:900-7.
2. Lemp MA, Nichols KK. Blepharitis in the United States 2009: a survey-based perspective on prevalence and treatment. *Ocul Surf*. 2009;7(2 suppl):S1-14.
3. Oto S, Aydin P, Ciftcioglu N, Durson D. Slime production by coagulase-negative staphylococci isolated in chronic blepharitis. *Eur J Ophthalmol*. 1998;8:1-3.
4. Yactayo-Miranda Y, Ta CN, He L, et al. A prospective study determining the efficacy of topical 0.5% levofloxacin on bacterial flora of patients with chronic blepharoconjunctivitis. *Graefes Arch Clin Exp Ophthalmol*. 2009;247:993-8.
5. Chen M, Gong L, Sun X, et al. A multicenter, randomized, parallel-group, clinical trial comparing the safety and efficacy of loteprednol etabonate 0.5%/tobramycin 0.3% with dexamethasone 0.1%/tobramycin 0.3% in the treatment of Chinese patients with blepharokeratoconjunctivitis. *Curr Med Res Opin*. 2012;28:385-94.
6. White EM, Macy JI, Bateman KM, Comstock TL. Comparison of the safety and efficacy of loteprednol 0.5%/tobramycin 0.3% with dexamethasone 0.1%/tobramycin 0.3% in the treatment of blepharokeratoconjunctivitis. *Curr Med Res Opin*. 2008;24:287-96.
7. Lindsley K, Matsumura S, Hatf E, Akpek EK. Interventions for chronic blepharitis (review). *Cochrane Database Syst Rev*. 2012;16:5.
8. Zhao YE, Wu LP, Hu L, Xu JR. Association of blepharitis with Demodex: a meta-analysis. *Ophthalmic Epidemiol*. 2012;19:95-102.
9. Szkaradkiewicz A, Chudzicka-Strugala I, Karpinski TM, et al. *Bacillus oleronius* and *Demodex* mite infestation in patients with chronic blepharitis. *Clin Microbiol Infect*. 2012;18:1020-5.
10. Zhao YE, Wu LP, Hu L, Xu JR. Association of blepharitis with Demodex: a meta-analysis. *Ophthalmic Epidemiol*. 2012;19:95-102.
11. Pflugfelder SC, Karpecki PM, Perez VL. Treatment of blepharitis: recent clinical trials. *The Ocular Surface*. 2014 October;12(4).
12. Shilvko IL, Kamensky VA, Donchenko EV, Agrba P. Morphological changes in skin of different phototypes under the action of topical corticosteroid therapy and tacrolimus. *Skin Res Technol*. 2014 May;20(2):136-40.
13. Lindsley K, Matsumura S, Hatf E, Akpek EK. Interventions for chronic blepharitis (review). *Cochrane Database Syst Rev*. 2012;16:5.

Rely on something that **STAYS PUT**



Parazol®

92%*
RETENTION

We've taken the worry out of plug retention, so you can concentrate on patient retention.

The Parazol® Punctal Occluder trumps the competition with an unprecedented 92% retention rate. Use the Parazol® Punctal Occluder, designed for easy insertion and guaranteed to stay put.

TO ORDER: 866-906-8080
customersupport@beaver-visitec.com
odysseymed.com or beaver-visitec.com

bvi Beaver Visitec
Keeping Your Vision in Sight

* "Plugs Reduce Dry Eye Symptoms, Improve Vision", Craig McCabe, M.D., Review of Ophthalmology, 2009.
BVI, BVI Logo and all other trademarks (unless noted otherwise) are property of a Beaver-Visitec International ("BVI") company © 2015 BVI



Eye Acts Up as IOP Goes Down

When a patient gets an allergic reaction to glaucoma drops, it's time to BAK off.

Edited by Paul C. Ajamian, OD

Q I have an advanced glaucoma patient who seems to be allergic to every drop I put her on. She also has cataracts. What are my options?

A First, you need to determine whether this is a true allergy to the medicine itself or if it's toxicity or intolerance to the preservatives in the bottle, says Michael Chaglasian, OD, associate professor at Illinois College of Optometry and chief of staff of the Illinois Eye Institute, in Chicago.

"Quite often, what seems to be an allergy to glaucoma drops is really irritation and toxicity due to the BAK preservative, which is an ingredient in those medications," he says. "Also, we know that about 60% of our glaucoma patients have concomitant ocular surface disease, which can be exacerbated by the BAK preservative."¹

Compounding the problem, many glaucoma patients are on two or more medications, which ups the total amount of BAK going into their eyes, Dr. Chaglasian says.

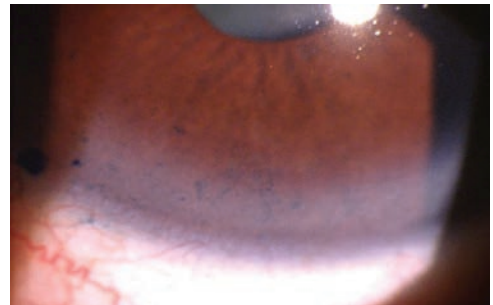
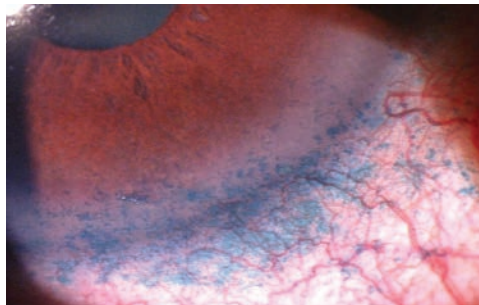
So, your first option is to address the ocular surface disease. "If it's not a true allergy—if it's a sensitivity or intolerance to the preservative—then treat the underlying dry eye disease and that may improve the patient's tolerability to the glaucoma meds," he says.

(On a side note, be sure not to mistake hyperemia, which is often caused by prostaglandins, for an allergy or toxicity. Corneal sensitivity and irritation are the hallmarks of the latter; if they're not present, it's likely just hyperemia.)

If treating the underlying dry eye doesn't do the trick, your next option is to switch the patient to a

A third option for this particular patient is the iStent (Glaukos), a tiny stent device inserted into Schlemm's canal that allows aqueous humor to bypass the blocked trabecular meshwork—a procedure performed only in combination with cataract surgery.

"The iStent is a great option for the right candidate," Dr.



Lissamine green staining of the conjunctiva and cornea identifies BAK toxicity from a prostaglandin. This patient was switched to a preservative-free prostaglandin analog. His signs and symptoms of dry eye improved over the next three months.

drop that uses a different preservative or is preservative-free:

- **Travatan Z** (travoprost, Alcon), a prostaglandin analog preserved with Sofzia.
- **Alphagan P** (brimonidine, Allergan), an alpha-agonist preserved with Purite.
- **Zioptan** (tafluprost, Akorn), a preservative-free unit-dose prostaglandin analog.
- **Cosopt PF** (dorzolamide/timolol, Akorn) a preservative-free combination of a carbonic anhydrase inhibitor and a beta blocker.

(Timolol is also available in preservative-free unit-dose vials, but it can cost up to four times the amount of these other drugs.)

Chaglasian says. "It's not for everyone, but it's a simple, safe procedure that helps to lower intraocular pressure even further than cataract surgery alone."²

If none of the above options succeed or if the patient is not a cataract candidate, the last option would be selective laser trabeculoplasty to reduce the patient's number of glaucoma medications and therefore reduce the patient's reaction, Dr. Chaglasian says. ■

1. Leung EW, Medeiros FA, Weinreb RN. Prevalence of ocular surface disease in glaucoma patients. *J Glaucoma*. 2008 Aug;17(5):350-5.

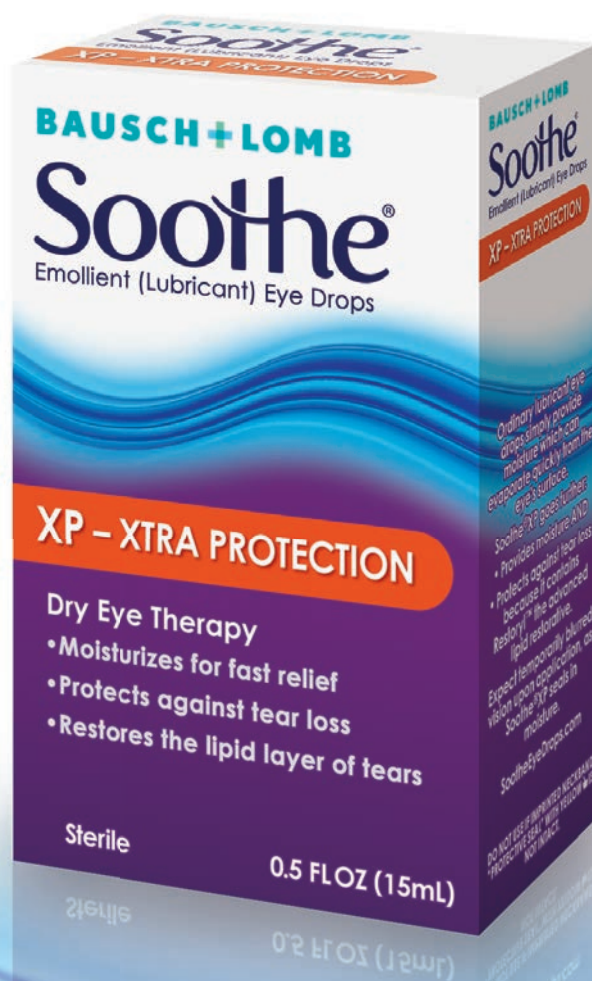2. Samuelson TW, Katz LJ, Wells JM, et al; US iStent Study Group. Randomized evaluation of the trabecular micro-bypass stent with phacoemulsification in patients with glaucoma and cataract. *Ophthalmology*. 2011 Mar;118(3):459-67.

RELIEF AT THE MAIN SOURCE of dry eye symptoms

Target Lipid Layer Deficiency:

Soothe[®] XP

With Restoryl[®] Mineral Oils



**Recommend Soothe XP as your first choice for dry eye patients.
To request samples, please call 1-800-778-0980.**

Now available at major retailers nationwide.

Distributed by Bausch + Lomb, a Division of Valeant Pharmaceuticals North America LLC, Bridgewater, N.J. © 2015 Bausch & Lomb Incorporated. Soothe and Restoryl are trademarks of Bausch & Lomb Incorporated or its affiliates. All other brand/product names are trademarks of their respective owners. PNS07412 US/SXP/14/0006

BAUSCH + LOMB
See better. Live better.

Take Charge of DIABETIC CARE

Eye care is on the front lines of this public health crisis. Arm yourself with the latest advice to keep patients healthy. **By A. Paul Chous, MA, OD**

Despite effective prevention and treatment, the twin epidemics of diabetes and diabetic retinopathy (DR) continue to flourish throughout most of the world.

The Centers for Disease Control (CDC) now estimates 40% of all American adults will be affected by diabetes.¹ Of adults with the disease, 28.5% are now diagnosed with DR or diabetic macular edema (DME), or both.² That's more than eight million Americans.

Luckily, doctors today are better prepared to face these challenges, with a collection of preventative strategies, diagnostic devices and treatment modalities our predecessors could only imagine. This article reviews the latest thinking and technological advancements in preventing, diagnosing and treating these connected conditions.

Understand Your Goals

Optometrists are the primary eye care providers for a majority of Americans with, and at risk for, diabetes. Of course, not all diabetic retinopathy is created equal; our goal as physicians is to prevent patients with diabetic eye disease from progressing to the level of

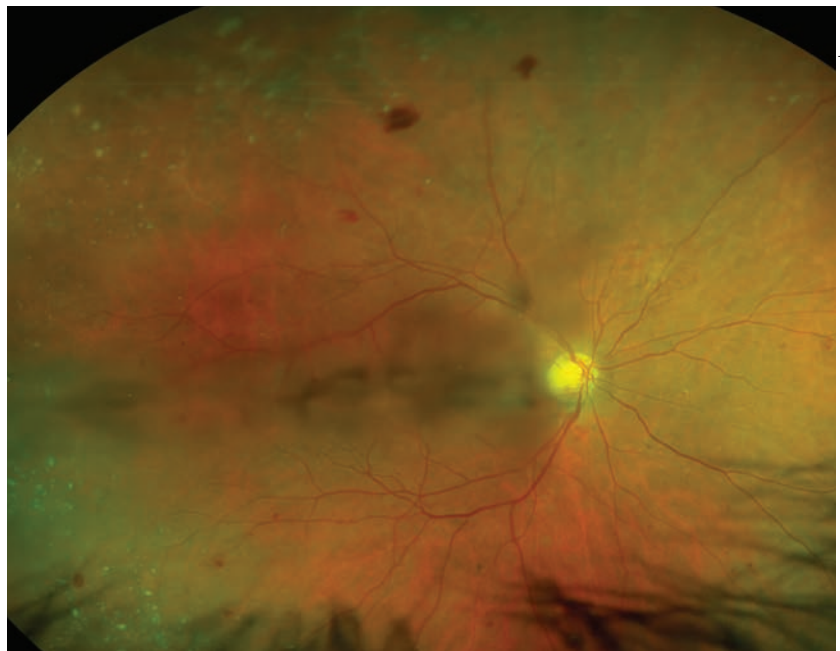

Photo: Optos

Primarily peripheral lesions in a patient with moderately severe nonproliferative diabetic retinopathy. This patient has high risk of progression and proliferative disease, based on recent analysis.

sight-threatening retinopathy (STR).

Disease duration and metabolic control of diabetes are the two primary factors affecting development and progression of DR. The longer we delay (or, ideally, prevent) disease onset, and the more we help patients maintain optimal blood

glucose, pressure and lipids, the more likely we are to reduce the burden of DR on individuals, communities and our economy.

Focus on Prevention

Obviously, patients won't develop STR, or go blind from diabetes-related eye disease, if they never

develop diabetes in the first place. Surveys show that patients fear vision loss as much as or more than any other disability.³ Optometrists are often an entry point for patients who otherwise may not receive routine health care and can influence patient attitudes and behaviors by explicitly linking prevention of vision loss to prevention of diabetes through healthy lifestyle choices. The Diabetes Prevention Program (DPP) showed that 150 minutes of walking per week significantly reduces the risk of developing type 2 diabetes in high-risk patients by 58% over four years, and by 38% at 10 years.⁴ Given that diabetes care cost the US economy \$245 billion in 2012, pushing diabetes onset 10 years into the future is estimated to save our economy \$8 trillion (in 2012 dollars) over the next decade.⁵

Recommending use of a pedometer with a daily goal of 5,000 to 10,000 steps is a great way to help prevent diabetes, and has been shown to lower hemoglobin A1c about one point.⁶

Environmental Factors

In addition to the positive influences that healthy lifestyle choices confer, there are of course other environmental factors with negative associations linked to diabetes risk. Notable culprits include added dietary sugars (1.1% increased population prevalence of diabetes—equivalent to 3.5 million additional cases of type 2 diabetes in the United States for every per capita can of sugar-sweetened beverage consumed, according to the International Diabetes Federation), short sleep cycle (threefold increased risk for developing impaired glucose tolerance, a fundamental marker of insulin resistance, when sleep duration is

less than six hours and twice the risk with sleep duration above nine hours) and vitamin D insufficiency (studies show an 80% risk reduction when vitamin D blood levels are 53ng/ml vs. 22ng/ml).⁷⁻⁹

In addition to significantly increasing risk of severe age-related macular degeneration, cigarette smoking has also been linked to a 53% increased risk of type 2 diabetes by the US Surgeon General, independent of age, body weight, hypertension and family history.¹⁰ Consistently across all studies, greater adherence to a healthy (predominantly plant-based) diet, regular physical activity, avoidance of smoking and moderate consumption of alcohol reduce the risk of developing type 2 diabetes (16% risk reduction for each lifestyle factor).¹¹

The Vigilant Optometrist

Eight million Americans have undiagnosed diabetes and another 86 million are at significant risk. Optometrists can assist in the early identification of diabetes by being vigilant for ophthalmic

symptoms and signs like refractive fluctuation, ocular surface disease, recurrent staphylococcal lid disease, dermatologic changes like acanthosis nigricans and, of course, unexplained retinopathy. Other strategies include use of simple, validated in-office screening tools for undiagnosed diabetes like that available from Weill-Cornell Medical College (go to www.ncbi.nlm.nih.gov/pmc/articles/PMC3633111/figure/F2/) and use of new technology to measure advanced glycation endproducts (AGEs) in the crystalline lens, a biomarker for long-term glucose toxicity that portends diabetes onset as well as complications.^{12,13}

Of note, any random blood glucose value >100mg/dl, an oft-ignored result in patients' medical records, was recently shown to increase the risk of undiagnosed diabetes 20-fold.¹⁴ In-office measurement of spot blood glucose or A1c is another way ODs can help with earlier detection in high-risk patients, depending on each state's scope-of-practice rulings.

New Diabetes Medications

Many new diabetes medications are now available, so doctors have more choices than ever for correcting hyperglycemia and preventing STR. Examples include:

- **Glucagon-like peptide-1 (GLP-1) analogs**, Byetta and Bydureon (exenatide, AstraZeneca) Victoza (liraglutide, Novo Nordisk) and Trulicity (dulaglutide, Eli Lilly) are injected, non-insulin medications that not only lower A1c but also promote weight loss and may reduce cardiovascular risk.
- **Dipeptidyl peptidase-4 (DPP-4) inhibitors** are oral medications that block the enzyme that degrades endogenous GLP-1, but don't cause weight loss. Januvia (sitagliptin, Merck), Onglyza (saxagliptin, AstraZeneca) and Tradjenta (linagliptin, Boehringer Ingelheim Pharmaceuticals) are examples of DPP-4 inhibitors.
- **Sodium glucose transporter-2 (SGLT2) inhibitors** are oral agents that prevent reabsorption of serum glucose in the kidneys, thereby promoting urinary excretion as well as weight loss and reduction in blood pressure. Examples of SGLT2 inhibitors include Invokana (canagliflozin, Janssen Pharmaceuticals) and Farxiga (dapagliflozin, AstraZeneca).

In addition to lowering blood glucose, the weight-loss benefit of these drugs may assist in prevention of STR, as proliferative diabetic retinopathy (PDR) rates are significantly increased when body mass index is above 30kg/m² (conversely, insulin and sulfonylureas increase weight).^{18,19}

Preventing STR

We can also help our patients who are already diagnosed with diabetes to avoid vision loss by reducing the risk of DR incidence and progression.

Improved blood sugar control has a major impact on diabetic retinopathy, as does improved control of hypertension and, to a lesser extent, dyslipidemia.

Optometrists should extol the “ABCs” of good diabetes management:

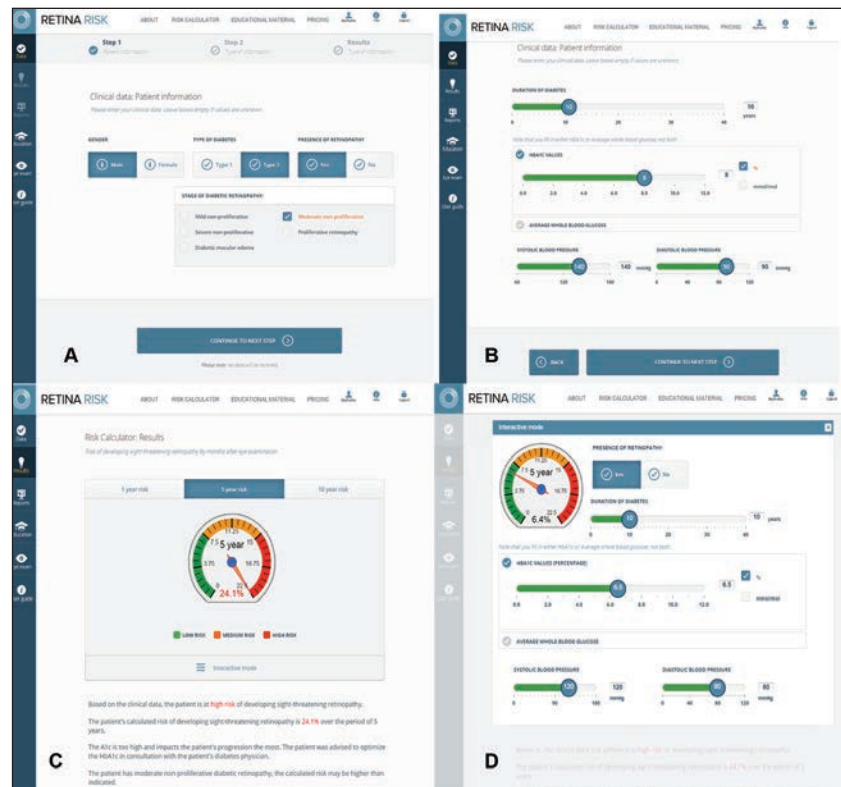
- A1c
- Blood pressure
- Cholesterol
- Smoking avoidance (and assessment for sleep apnea)

We also need to recognize the new mantra of diabetes care: individualization of glucose targets. While an A1c value of less than 6.5% might be appropriate for younger adults with no heart disease and long life expectancy, it can actually put older patients with long diabetes duration and cardiovascular disease at substantial risk of death.¹⁶

The best time to optimize blood sugar levels is as soon after diagnosis as possible, as this promotes protective metabolic memory (the so-called “legacy effect”) over time that lowers the risk of retinopathy progression, development of STR and other potential complications from diabetes.^{16,17}

Monitoring

We can help patients on insulin therapy achieve better blood glucose control by discussing the advantages of continuous glucose monitoring systems (CGMS). These measure and plot interstitial glucose every five minutes and have audible and vibratory threshold alarms when blood glucose levels are too high or too low. Stud-



(A, B) Male patient with type 2 diabetes for 10 years, moderate NPDR, A1c=8% and BP=140/90. (C) Five-year risk for STR is high at 24.1%. (D) This patient's five-year risk for STR drops dramatically to 6.4% when A1c drops to 6.5% and BP drops to 120/80 using the interactive mode.

ies show that CGMS results in improved A1c values for patients with type 1 diabetes, and these may also help prevent fatalities in hypoglycemia-unaware patients such as children, longstanding diabetes patients, the elderly and patients living alone.²⁰

Newer CGMS deliver data to patients' insulin pumps and suspend delivery of insulin if blood glucose drops below a predetermined threshold, and a dual chamber insulin and glucagon pump is in clinical trials. Also, Google has partnered with Novartis to develop a continuous tear-glucose sensing contact lens.

As the presence of any DR increases the odds of developing sight-threatening retinopathy, early

diagnosis of nonproliferative diabetic retinopathy (NPDR) affords us the chance to collaborate with both patients and their other doctors to mitigate that risk. In addition to improved metabolic control, research shows that use of angiotensin converting enzyme (ACE) inhibitors and angiotensin receptor blocker (ARB) drugs (-prils and -sartans) lowers progression of DR in hypertensive patients and that the triglyceride lowering drug fenofibrate (found in the brands Tricor, Trilipix and Lipidil) not only lowers risk of DR progression but also the need for laser or anti-vascular endothelial growth factor (anti-VEGF) treatments in type 2 diabetes patients with pre-existing NPDR.^{21,22} In fact, fenofibrate has



Dry eye relief starts with restoring balance

Elevated tear film osmolarity (osmolarity imbalance or hyperosmolarity) is one of the primary causes of dry eye symptoms¹.

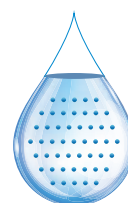
TheraTears® Dry Eye Therapy with Osmo-Correction™ corrects osmolarity imbalance to restore comfort with a unique hypotonic and electrolyte balanced formula that replicates a healthy tear.

WITH
OSMO-CORRECTION™
HYPOTONIC & ELECTROLYTE
BALANCED



HYPEROSMOLARITY

Increased concentration of the tears leads to irritation and potential damage to the ocular surface.



HEALTHY TEAR

TheraTears® Dry Eye Therapy replicates the electrolyte balance of natural tears to restore comfort.



RESTORE

+



CLEANSE

+



NOURISH



thera tears

THERAPY FOR YOUR EYES™

DRY EYE THERAPY

Restores Eyes Natural Balance™

theratears.com



Reference: 1. Research in dry eye report of the Research Subcommittee of the International Dry Eye WorkShop (2007). *Ocul Surf.* Apr 2007; 5(2): 179-193.

© 2015 Akorn Consumer Health | A Division of Akorn, Inc. | M15-006

now been approved as first-line therapy for NPDR in Australia for this group of patients.²³

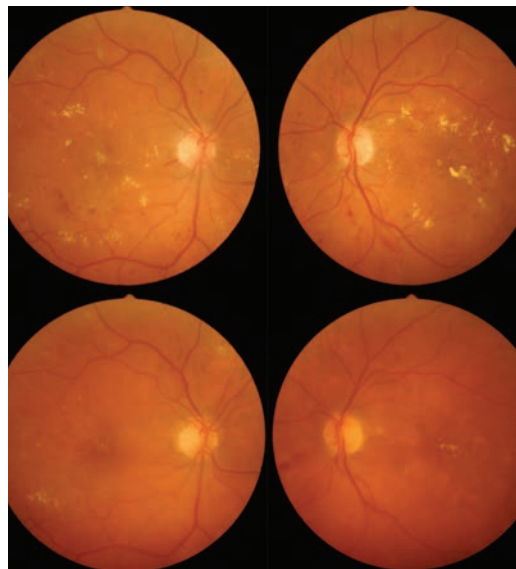
Nutritional Supplements

A number of studies show that diabetes affects visual function (contrast and visual field sensitivity, color vision, multifocal ERG) long before the appearance of DR, and that macular pigment optical density (MPOD) is reduced in diabetes and even more so in DR.²⁴⁻²⁹

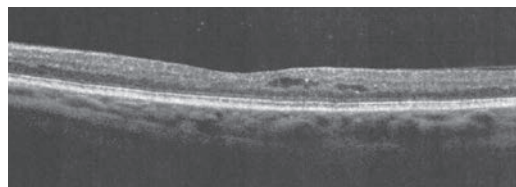
Considerable work with animal models shows specific micronutrients (such as vitamins B, C, D, E, lipoic acid, lutein and zeaxanthin, resveratrol, curcuminoids, benfotiamine and pycnogenol) improve visual function and reduce cellular damage. Recently, a six-month randomized clinical trial (called the Diabetes Visual Function Supplement Study, or DiVFuSS) was conducted to assess possible benefits of a multi-component nutritional supplement in human subjects with diabetes and early NPDR.³⁰ Results of DiVFuSS show that the test formula significantly improved contrast sensitivity, visual field, color vision, MPOD, symptoms of diabetic peripheral neuropathy and high-sensitivity C-reactive protein (hsCRP) compared with placebo, without affecting A1c levels.³⁰

Improved Detection

Evidence shows that even retina specialists may fail to detect cases of early NPDR, using ETDRS seven-field stereoscopic fundus photography as the gold standard.³¹ This makes a strong case for use of digital retinal photography and red-free viewing to increase detection of subtle changes. Moreover, an estimated 30% of patients with NPDR have retinal abnormalities primarily outside the posterior pole, a finding that underscores the



A 52-year-old patient with type 2 diabetes diagnosed five years ago presenting with center-involved DME, moderate NPDR and 20/200 BCVA in both eyes had received focal laser 16 months prior, but failed to follow-up with retinal specialist claiming Tx “didn’t help” (top panels). Five injections of ranibizumab over 10 months resulted in 200µm reduction in central macular thickness, significant reduction in hard exudate and retinal hemorrhage and 20/60 BCVA in both eyes (bottom panels). At initial exam, A1c was 10.2%. The patient was referred to endocrinology with A1c reduction to 7.5% on insulin therapy. A sleep study confirmed obstructive sleep apnea.



A 52-year-old patient diagnosed with type 2 diabetes eight years ago, with 20/20 BCVA in both eyes and SD-OCT showing subclinical DME with perifoveal cysts.

importance of examining the mid-peripheral and peripheral retina for retinopathy in every patient with known or suspected diabetes, and the additional value of ultrawide-field imaging.^{32,33} Of high significance, a recent analysis found that patients with NPDR lesions (intra-retinal hemorrhage/microaneurysm,

vein beading, IRMA) predominantly in the periphery (outside the standard ETDRS fields) were 3.2 times more likely to have a two-step worsening and 4.7 times more likely to progress to proliferative retinopathy in the course of four years.³⁴

We concentrate on the posterior pole because of the perception that “that’s where the action is”—but we need to focus outside the poles as well.

Buying In

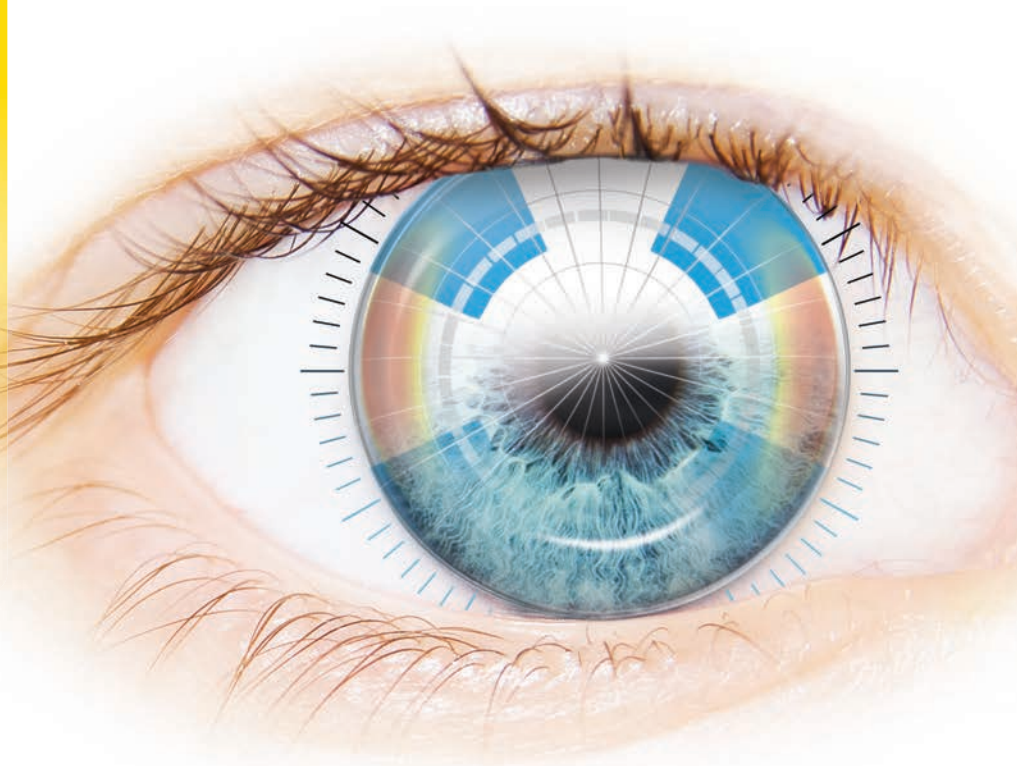
Of course, we can give diabetes patients the best eye examination and treatment plan in the galaxy, but the real question is: How do we get patients to “buy in” to our recommendations for improved self-care?

A clinically validated, visually evocative risk calculator for progression to STR is now available.³⁵ The calculator allows us to demonstrate to patients how better control of their diabetes, both blood glucose and blood pressure, reduces the risk of severe retinopathy (www.RetinaRisk.com). Entering a few key variables that modulate roughly 80%

of total risk (diabetes duration and type, presence of any DR, mean blood glucose, blood pressure, gender) provides individualized risk over one, five and 10 years. Using the interactive mode allows us to demonstrate immediately how improved metabolic control lowers each patient’s risk.

NEW!

-2.75 cyl now available



Unsurpassed in **COVERAGE** | Unbeaten in **COMFORT**

THE WIDEST PARAMETER COVERAGE FOR SPHERICAL
AND ASTIGMATIC EYES

Now with the **first** and **only** silicone hydrogel toric lens with -2.75 cyl readily available,* ACUVUE OASYS® Brand Contact Lenses provides coverage for 98% of astigmatic and spherical patients.

NEVER BEEN BEATEN ON COMFORT BY ANY LEADING MONTHLY LENS

Based on a review of published clinical studies and those registered on clinicaltrials.gov with comfort as an end point.



Feel confident that more of your patients
are covered and comfortable with
ACUVUE OASYS® Brand

ACUVUE® Brand Contact Lenses are indicated for vision correction. As with any contact lens, eye problems, including corneal ulcers, can develop. Some wearers may experience mild irritation, itching or discomfort. Lenses should not be prescribed if patients have any eye infection, or experience eye discomfort, excessive tearing, vision changes, redness or other eye problems. Consult the package insert for complete information. Complete information is also available from VISTAKON® Division of Johnson & Johnson Vision Care, Inc., by calling 1-800-843-2020 or by visiting www.acuvueprofessional.com.

*Available without needing to place a special order. Contact Lens Manufacturer Published Parameters, June 2014.

ACUVUE®, ACUVUE OASYS®, HYDRACLEAR®, and VISTAKON® are trademarks of Johnson & Johnson Vision Care, Inc.
© Johnson & Johnson Vision Care, Inc. 2015 ACU-A44363-B April 2015

ACUVUE®
OASYS
BRAND CONTACT LENSES
FOR ASTIGMATISM

New Concepts in Diagnosis and Treatment

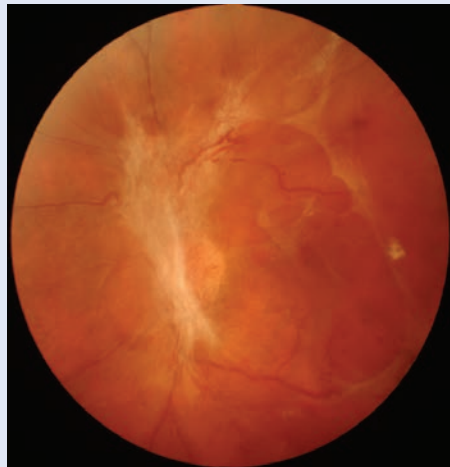
We're familiar with the landmark clinical trials that inform how we diagnose and manage severe diabetic eye disease (DRS, ETDRS, DRVS, WESDR). More recently, results emerging from the Diabetic Retinopathy Clinical Research Network (DRCR.net) have significantly changed some of what doctors are doing to preserve and improve vision.

Careful clinical exam and, sometimes, grading of ETDRS stereo photographs are still the mainstays for diagnosing PDR. Florid neovascularization, fibrovascular proliferation and preretinal or vitreous hemorrhage are generally easy to detect, but detecting subtle disc, retinal or iris neovascularization can be quite challenging. That conundrum has prompted interest in probability-based, automated detection software paired with enhanced digital imaging or OCT.^{39,40} Hyperreflective neovascular complexes on spectral domain optical coherence tomography (SD-OCT) have been described in subclinical neovascularization of the disc and neovascularization elsewhere, and may soon assist us with identifying proliferative disease in its earliest stages, when treatment is most effective.⁴¹

Researchers are looking into using micro-RNA analysis to identify early proliferative disease. The expectation is that serum proteins can be used as biomarkers to detect proteins specific to pathologic retinal neovascularization. Emerging evidence suggests hyperoxygenation of retinal circulation, particularly retinal venules, also is a harbinger of PDR.^{42,43}

Though SD-OCT is the most sensitive instrument for detection of DME, results do not always indicate which patients do and don't require therapy. However, patients identified with subclinical DME by SD-OCT are three times more likely to develop clinically significant macular edema over two years.⁴⁴ About one in five patients with DME evaluated by OCT are thought to have vitreomacular adhesion (VMA) that may aggravate the condition.⁴⁵ These patients may achieve poor visual outcomes with anti-VEGF injections and may benefit from vitrectomy or, anecdotally and off-label, the injected, vitreolytic enzyme Jetrea (ocriplasmin, ThromboGenics).^{46,47}

The evidence suggests our diabetes patients will benefit from routine OCT examination.



Early detection and treatment of proliferative diabetic retinopathy greatly lowers the risk of fibrovascular proliferation and tractional retinal detachment. This patient presenting with hand-motion vision in the left eye refused treatment for early PDR one year prior.

Several colleagues and I have found this tool extremely effective for patient understanding and motivation. Combined with retinal imaging and a motivational interviewing strategy, it is now rare for patients to not “buy in” to any of my recommendations.

STR Detection and Referral

To detect sight-threatening retinopathy, doctors must start with a thorough clinical examination through dilated pupils. Our index of suspicion should be elevated when patients have a higher risk profile (high A1c, long diabetes

duration, type 1 diabetes, uncontrolled hypertension, untreated sleep apnea, clinical depression, and presence of other diabetes complications).³⁶ Though reports suggest the risk of DME increases for those using insulin-sensitizing thiazolidinediones (Actos and Avandia), it appears to be a dose-related phenomenon and is magnified in patients on concomitant insulin therapy.³⁷ Of note, use of ACE inhibitors also significantly attenuates this specific risk.

Therapies

Panretinal photocoagulation remains the therapy of choice for PDR, though anti-VEGF therapies and intravitreal steroids show promise as adjunct treatments.⁴⁸

Both Lucentis (ranibizumab, Genentech) and Eylea (aflibercept, Regeneron) recently gained FDA approval for prevention of NPDR progression in patients with DME.

Anti-VEGF agents have revolutionized care of patients with center-involved DME and clinically significant macular edema (CSME as defined by ETDRS). These agents are now standard of care.⁴⁹ Though grid and focal laser photocoagulation reduces the risk of further vision loss from CSME, they rarely improve vision. By contrast, anti-VEGF drugs, more often than not, significantly improve vision and reduce intraretinal edema characteristic of DME. Patients almost always require a series of injections and solid evidence shows that earlier treatment results in larger gains in vision.⁵⁰


Two anti-VEGF drugs are FDA-approved for DME, Lucentis and Eylea, but off-label use of Avastin (bevacizumab, Genentech) is commonplace due to its significantly lower cost. A recently published one-year, head-to-head comparison

LET'S KEEP SOMETHING STRAIGHT ABOUT AREDS2

Only PreserVision® AREDS 2 Formula

contains the exact ingredient dosages recommended by the National Eye Institute[†] based on the evidence from the AREDS2 study.^{1,2*}

Get patient samples and education materials at **1-844-BL-VITES.**



PreserVision. Exactly.

BAUSCH + LOMB

SEE BETTER. LIVE BETTER.

[†]For patients with moderate to advanced age-related macular degeneration.

***This statement has not been evaluated by the Food and Drug Administration. This product is not intended to diagnose, treat, cure, or prevent any disease.**

References: 1. Yong JJ, Scott IU, and Greenberg PB. Ocular nutritional supplements. *Ophthalmology*. 2014;1-5. 2. Chew EY, Clemens TE, SanGiovanni JP, et al. Lutein and zeaxanthin and omega-3 fatty acids for age-related macular degeneration. *JAMA*. 2013;309(19):1-11.

PreserVision is a trademark of Bausch & Lomb Incorporated or its affiliates. AREDS2 is a registered trademark of the United States Department of Health and Human Services (HHS). ©2015 Bausch & Lomb Incorporated. PREV-56994 US/PV2/15/0006

of these agents for center-involved DME shows that all three improve visual acuity between 10 to 13 ETDRS letters and with equivalent safety.⁵¹ Interestingly, Eylea improved vision about five to seven letters more than both Lucentis and Avastin when entering visual acuity was 20/50 or worse, and subjects randomized to the former required one fewer injection and were 19% to 33% less likely to require rescue laser per pre-specified criteria. Note these are one-year data points only.

Five-year follow up of patients receiving Lucentis plus prompt laser vs. deferred laser therapy, shows slightly better acuity with the latter protocol (mean benefit of +2.6 letters, $p=0.09$) but patients required more injections (17 vs. 13 over five years, with few treatments required after year three).⁵²

DME has a definite inflammatory component, so intravitreal steroids have long been employed, despite cataract formation in phakic patients and substantial risk of glaucoma. Two sustained-release intravitreal steroid implants are FDA-approved for DME—Ozurdex (dexamethasone, Allergan) and Iluvien (fluocinolone, Alimera)—and evidence of cost and efficacy benefit exists with combination therapy (steroid, anti-VEGF, laser or some combination thereof), especially in recalcitrant cases.⁵³

Finally, mounting evidence shows that obstructive sleep apnea syndrome (OSAS) is causally linked to both DR and DME, that patients with OSAS respond less favorably to anti-VEGF treatments, and that treatment with CPAP improves visual acuity in patients with CSME.^{54,55}

Playing Our Part

We can reduce the burdens of diabetes, diabetic eye disease, vision

loss and other complications by focusing on prevention of diabetes, prevention of sight-threatening retinopathy, early detection of DR and especially STR with timely referral for appropriate treatment.

Our understanding and discussion of these ‘game-changing’ advancements with both patients and other physicians will help us secure our vital position on the diabetes care team. ■

Dr. Chous is in private practice with an emphasis on diabetes eye care and education in Tacoma, Wash. He has been a consultant to Bausch + Lomb, Children with Diabetes, dLife—Your Diabetes Life, Freedom Meditech, Kestrel DiabetesSource, Kowa, Optos, Regeneron, Risk Medical Solutions, Vision Service Plan and ZeaVision. Dr. Chous currently serves as the AOA representative to the National Diabetes Education Program, NIH.

1. Lipscombe LL. The US diabetes epidemic: tip of the iceberg. *Lancet Diabetes Endocrinol.* 2014 Nov;2(11):854-5.
2. Centers for Disease Control and Prevention. National diabetes statistics report, 2014. Atlanta, GA: US Department of Health and Human Services, Centers for Disease Control and Prevention, 2014. <http://www.cdc.gov/diabetes/pubs/statsreport14/national-diabetes-report-web.pdf>. Accessed February 28, 2015, 2014.
3. Prevent Blindness America Vision Problems in the US, 2008 Update to Fourth Edition 2. The Economic Impact of Vision Problems Prevent Blindness America 3. 2010
4. Hoskin M, Bray G, Hattaway K, et al. Prevention of Diabetes Through the Lifestyle Intervention: Lessons Learned from the Diabetes Prevention Program and Outcomes Study and its Translation to Practice. *Curr Nutr Rep.* 2014 Dec 1;3(4):364-378.
5. Anderson J. Achievable cost saving and cost-effective thresholds for diabetes prevention lifestyle interventions in people aged 65 years and older: a single-payer perspective *J Acad Nutr Diet.* 2012 Nov;112(11):1747-54. doi: 10.1016/j.jand.2012.08.033.
6. Funk M, Taylor E. Pedometer-based walking interventions for free-living adults with type 2 diabetes: a systematic review. *Curr Diabetes Rev.* 2013 Nov;9(6):462-71.
7. Basu S, Yoffe P, Hills N, Lustig R. The relationship of sugar to population-level diabetes prevalence: an econometric analysis of repeated cross-sectional data. *PLoS One.* 2013;8(2):e57873.
8. Shan Z, Ma H, Xie M, et al. Sleep Duration and Risk of Type 2 Diabetes: A Meta-analysis of Prospective Studies. *Diabetes Care.* 2015 Mar;38(3):529-537.
9. Diabetes Prevention with Vitamin D? Grassroots Health, accessed at www.grassrootshhealth.net/index.php/diabetes-prevention-with-vitamin-d. February 28, 2015
10. US Dept. of Health and Human Services, The Health Consequences of Smoking – 50 Years of Progress: a report of

the Surgeon General 2014. Accessed at <http://www.surgeon-general.gov/library/reports/50-years-of-progress/full-report.pdf>, February 28, 2015

11. Ardisson Korat A, Willett W, Hu F. Diet, lifestyle, and genetic risk factors for type 2 diabetes: a review from the Nurses' Health Study, Nurses' Health Study 2, and Health Professionals' Follow-up Study. *Curr Nutr Rep.* 2014 Dec 1;3(4):345-54
12. Bang H, Edwards A, Bomback A, et al. A patient self-assessment diabetes screening score: development, validation, and comparison to other diabetes risk assessment scores. *Ann Intern Med.* 2009 Dec 1;151(11):775-83.
13. Cahn F, Burd J, Ignatz K, Mishra S. Measurement of Lens Autofluorescence Can Distinguish Subjects With Diabetes From Those Without. *J Diabetes Sci Technol.* 2014 Jan 1;8(1):43-9.
14. Bowen M, Xuan L, Lingvay I, Halm E. Random Blood Glucose: A Robust Risk Factor For Type 2 Diabetes. *J Clin Endocrinol Metab.* 2015 Feb 4;je20144116. [Epub ahead of print]
15. Ismail-Beigi F, Moghissi E, Tiktin M, et al. Individualizing glycemic targets in type 2 diabetes mellitus: implications of recent clinical trials. *Ann Intern Med.* 2011 Apr 19;154(8):554-9.
16. Ranjit U, Anjana R, Mohan V. Importance of controlling diabetes early—the concept of metabolic memory, legacy effect and the case for early insulinisation. *Assoc Physicians India.* 2011 Apr;59 Suppl:8-12.
17. Pirola L, Balcerczyk A, Okabe J, El-Osta A. Epigenetic phenomena linked to diabetic complications. *Nat Rev Endocrinol.* 2010 Dec;6(12):665-75.
18. Kaštelan S, Salopek Rabatic J, Tomic M, et al. Body mass index and retinopathy in type 1 diabetic patients. *Int J Endocrinol.* 2014;2014:387919.
19. Kaštelan S, Tomic M, Gverovic Antunica A, et al. Body mass index: a risk factor for retinopathy in type 2 diabetic patients. *Mediators Inflamm.* 2013; 2013:436329.
20. Walker T, Yucha C. Continuous glucose monitors: use of waveform versus glycemic values in the improvements of glucose control, quality of life, and fear of hypoglycemia. *J Diabetes Sci Technol.* 2014 May;8(3):488-93.
21. Wang B, Wang F, Zhang Y, et al. Effects of RAS inhibitors on diabetic retinopathy: a systematic review and meta-analysis. *Lancet Diabetes Endocrinol.* 2015 Feb 5
22. Simó R, Hernández C. Prevention and treatment of diabetic retinopathy: evidence from large, randomized trials. The emerging role of fenofibrate. *Rev Recent Clin Trials.* 2012 Feb;7(1):71-80.
23. Pharmacy News (Australia). New indication for Lipidil for diabetic retinopathy, available at www.pharmacynews.com.au/news/latest-news/new-indication-for-lipidil-for-diabetic-retinopathy. Accessed March 1, 2015.
24. Sukha A, Rubin A. High, medium, and low contrast visual acuities in diabetic retinal disease. *Optometry & Vision Science.* 2009;86(9):1086-95.
25. Nittala M, Gella L, Raman R, Sharma T. Measuring retinal sensitivity with the microperimeter in patients with diabetes. *Retina.* 2012 Jul;32(7):1302-9.
26. Andrade L, Souza G, Lacerda E. Influence of retinopathy on the achromatic and chromatic vision of patients with type 2 diabetes. *BMC Ophthalmol.* 2014 Aug 31;14:104.
27. Bearse M, Adams A, Han Y. A multifocal electroretinogram model predicting the development of diabetic retinopathy. *Prog Retin Eye Res.* 2006 Sep;25(5):425-48.
28. Davies N, Morland A. Color Matching in Diabetes: Optical Density of the Crystalline Lens and Macular Pigments. *Invest Ophthalmol Vis Sci.* 2002;43(1):281-9.
29. Lima V, Rosen R, Maia M, et al. Macular pigment optical density measured by dual-wavelength autofluorescence imaging in diabetic and nondiabetic patients: a comparative study. *Sallium J. Invest Ophthalmol Vis Sci.* 2010 Nov;51(11):5840-5.
30. Chous A, Richer S, Gerson J, Kowluru R. The Diabetes Visual Function Supplement Study (DIVFUS): Beneficial effects of a novel, multi-component nutritional supplement evaluated in a double masked, double blind, placebo con-

trolled clinical trial. *Br J Ophthalmol*, publication pending.

31. Vujosevic S, Benetti E, Massignan F, et al. Screening for diabetic retinopathy: 1 and 3 nonmydriatic 45-degree digital fundus photographs vs 7 standard early treatment diabetic retinopathy study fields. *Am J Ophthalmol*. 2009 Jul;148(1):111-8. doi: 10.1016/j.ajo.2009.02.031. Epub 2009 May 5.

32. Silva P, Cavallerano J, Sun J, et al. Peripheral lesions identified by mydriatic ultrawide field imaging: distribution and potential impact on diabetic retinopathy severity. *Ophthalmology*. 2013 Dec;120(12):2587-95.

33. Shi L, Wu H, Dong J, et al. Telemedicine for detecting diabetic retinopathy: a systematic review and meta-analysis. *Br J Ophthalmol*. 2015 Jan 6. pii: bjophthalmol-2014-305631.

34. Silva P, Cavallerano J, Haddad N, et al. Peripheral Lesions Identified on Ultrawide Field Imaging Predict Increased Risk of Diabetic Retinopathy Progression over 4 Years. *Ophthalmology*. 2015 Feb 19. pii: S0161-6420(15)00046-9.

35. Aspelund T, Thorngórsdóttir O, Ólafsdóttir E, et al. Individual risk assessment and information technology to optimise screening frequency for diabetic retinopathy. *Diabetologia*. 2011 Oct;54(10):2525-32. doi: 10.1007/s00125-011-2257-7. Epub 2011 Jul 27.

36. Yau J, Rogers S, Kawasaki R, et al. Global Prevalence and Major Risk Factors of Diabetic Retinopathy. *Diabetes Care*. 2012 March;35(3):556-64.

37. Idris I, Warren G, Donnelly R. Association between thiazolidinedione treatment and risk of macular edema among patients with type 2 diabetes. *Arch Intern Med*. 2012 Jul 9;172(13):1005-11. doi: 10.1001/archinternmed.2012.1938.

38. Karperien A, Jelinek H, Jorge J, et al. Automated detection of proliferative retinopathy in clinical practice. *Clin*

Ophthalmol. 2008 Mar;2(1):109-22.

39. Welikala R, Dehmeshki J, Hoppe A, et al. Automated detection of proliferative diabetic retinopathy using a modified line operator and dual classification. *Comput Methods Programs Biomed*. 2014 May;114(3):247-61.

40. Miura M, Hong Y, Yasuno Y, et al. Three-dimensional Vascular Imaging of Proliferative Diabetic Retinopathy by Doppler Optical Coherence Tomography. *Am J Ophthalmol*. 2015 Mar;159(3):528-38.e3.

41. Muqit M, Stanga P. Fourier-domain optical coherence tomography evaluation of retinal and optic nerve head neovascularisation in proliferative diabetic retinopathy. *Br J Ophthalmol*. 2014 Jan;98(1):65-72. doi: 10.1136/bjophthalmol-2013-303941. Epub 2013 Oct 24.

42. Qing S, Yuan S, Yun C, et al. Serum miRNA biomarkers serve as a fingerprint for proliferative diabetic retinopathy. *Cell Physiol Biochem*. 2014;34(5):1733-40.

43. Jørgensen C, Hardarson S, Bek T. The oxygen saturation in retinal vessels from diabetic patients depends on the severity and type of vision-threatening retinopathy. *Acta Ophthalmol*. 2014 Feb;92(1):34-9.

44. Pires I, Santos A, Nunes S, et al. Subclinical macular edema as a predictor of progression to clinically significant macular edema in type 2 diabetes. *Ophthalmologica*. 2013;230(4):201-6.

45. Jackson T, Nicod E, Angelis A, et al. Vitreous attachment in age-related macular degeneration, diabetic macular edema, and retinal vein occlusion: a systematic review and meta-analysis. *Retina*. 2013 Jun;33(6):1099-108.

46. Yoon D, Rusu I, Barbazetto I. Reduced effect of anti-vascular endothelial growth factor agents on diabetics with vitreomacular interface abnormalities. *Int Ophthalmol*. 2014 Aug;34(4):817-23.

47. de Smet, Castilla M. Ocriplasmin for diabetic retinopathy.

Expert Opin Biol Ther. 2013 Dec;13(12):1741-7.

48. Bressler S, Qin H, Melia M, et al. Exploratory Analysis of Effect of Intravitreal Ranibizumab or Triamcinolone on Worsening of Diabetic Retinopathy in a Randomized Clinical Trial. *JAMA Ophthalmol*. 2013 August; 131(8):1033-40.

49. Boyer D, Hopkins J, Sorof J, Ehrlich J. Anti-vascular endothelial growth factor therapy for diabetic macular edema. *Ther Adv Endocrinol Metab*. 2013 Dec;4(6):151-69.

50. Brown D., Nguyen Q, Marcus D, et al. Long-term outcomes of ranibizumab therapy for diabetic macular edema: the 36-month results from two phase III trials: RISE and RIDE. RISE and RIDE Research Group. *Ophthalmology*. 2013;120:2013-22.

51. The Diabetic Retinopathy Clinical Research Network. Aflibercept, Bevacizumab, or Ranibizumab for Diabetic Macular Edema. *N Engl J Med*. 2015 Feb 18. [Epub ahead of print]

52. Elman M, Ayala A, Bressler N, et al. Intravitreal Ranibizumab for Diabetic Macular Edema with Prompt versus Deferred Laser Treatment: 5-Year Randomized Trial Results. *Ophthalmology*. 2015 Feb;122(2):375-81.

53. Ciulla T, Harris A, McIntyre N, Jonescu-Cuypers C. Treatment of diabetic macular edema with sustained-release glucocorticoids: intravitreal triamcinolone acetonide, dexamethasone implant, and fluocinolone acetonide implant. *Expert Opin Pharmacother*. 2014 May;15(7):953-9.

54. Nesmith B, Ihnen M, Schaal S. Poor responders to bevacizumab pharmacotherapy in age-related macular degeneration and in diabetic macular edema demonstrate increased risk for obstructive sleep apnea. *Retina*. 2014 Dec;34(12):2423-30.

55. Mason R, Kiire C, Groves D, et al. Visual improvement following continuous positive airway pressure therapy in diabetic subjects with clinically significant macular oedema and obstructive sleep apnoea: proof of principle study. *Respiration*. 2012;84(4):275-82.

Icare is a trusted portable device for

QUICK & EASY IOP MEASUREMENTS



RANDALL THOMAS, OD
& RON MELTON, OD

“As soon as we had the Icare tonometry performed on ourselves, our skepticism turned to amazed acceptance and we couldn’t wait to use it on our patients. It is indeed asymptomatic in virtually all instances and certainly atraumatic in all cases.”



Come see what you’ve been missing! Visit **AOA Booth 2518**

LEARN MORE: **888.422.7313**

icare-usa.com



**NO CALIBRATION
NO DROPS, NO AIR**

Do you have the right contact lens options for your astigmatic patients?

Those who fit SynergEyes hybrid contact lenses are *significantly* more likely to agree that they do!*

Transform your astigmatic patients' vision with Duette.

- Uncompromised GP Optics
- Vision Not Affected by Lens Rotation
- SoftCushion™ Comfort Technology
- Ocular Health
- 100% Retention of Annual Supply Sales

Duette
CONTACT LENSES

"The Duette lens really helps me take care of my astigmatic patients... the RGP center can rotate 360 degrees and it still can be used to deliver the fantastic optics that we would want out of an astigmatic lens...and for me, that is very comforting as a practitioner."

— Dr. Pfeil,
Eye Care Specialties



Learn More about Duette

SynergEyes.com/Professional
877-733-2012 option 5

*vs. those who don't fit SynergEyes lenses.
Data on file.

SynergEyes



The Do's and Don'ts of Measuring IOP

Obtaining an accurate IOP reading can be challenging. Try these tonometry tips to help you develop a trusty technique. **By Natalie A. Townsend, OD, and John J. McSoley, OD**

Although a connection between eye firmness and blindness was recorded as far back as the 1600s, we still have no perfect method to measure intraocular pressure (IOP); all current methods are influenced by various ocular and non-ocular factors and can only give us an estimate of the intraocular pressure.

Accurate and precise IOP readings are imperative to evaluate a patient's risk of progressive optic nerve damage. Inaccurate or inconsistent IOP measurements prevent the clinician from making accurate treatment and management decisions and may put the patient at risk for visual field loss. Clinicians need to develop a consistent, reproducible and reliable technique for obtaining IOP measurements so that they can be compared with confidence over time.

Here are some helpful recommendations to keep in mind when measuring a patient's IOP (unless otherwise noted, recommendations relate to Goldmann applanation tonometry, GAT):



When holding the patient's lids open, don't inadvertently apply pressure to the globe.

DO consider the patient's position, comfort and clothing prior to checking IOP.

Make sure to position the patient correctly in the slit lamp without discomfort. The head and chin should be in contact with the forehead and chin rests and the lateral

canthi should be aligned with the line on the slit lamp's frame.

Encourage the patient to breathe normally. It's common for patients to hold their breath out of anxiety, poor positioning, or both, during an IOP measurement. This may increase venous pressure from the

Common Types of Tonometry

Applanation tonometry is based on the Imbert-Fick principle, which asserts that the pressure (P) inside a sphere equals the force (F) necessary to flatten its surface divided by the area (A) of flattening, $P=F/A$.¹ In practice, multiple methods use this concept of flattening the cornea to measure intraocular pressure. Physical properties of the ocular surface—particularly corneal resistance and surface tension of the tears—have a practical influence on applanation measurements.⁷ Various methods of IOP measurement employ applanation tonometry, including:

- **Goldmann applanation tonometry (GAT)**, introduced in the 1950s, is currently regarded as the reference standard. The method involves contacting an anesthetized cornea with a tonometer tip approximately 3.06mm in diameter and using fluorescein dye in the precorneal tear film to determine the force necessary to flatten the cornea. The size of the tonometer tip is deliberate to minimize the impact of the corneal resistance and the surface tension of the tear film.⁷ Two semicircles are visible through the bi-prism. The examiner turns the tension knob that alters the force applied to the cornea, and the IOP is determined in mm HG when the internal aspect of the two semicircles are in contact with each other.

- A **Perkins tonometer** resembles a GAT and uses the same applanating prism, but is portable and can be used on patients who are not being tested with a slit lamp in the office, those with

physical limitations preventing them from positioning in a slit lamp and those being tested in the supine position.

- **Non-contact tonometry (NCT)**, also known as the “air puff test,” uses increasing air intensities to flatten the apex of the non-anesthetized cornea. The force used to flatten the cornea is detected by sensors, recorded and converted to mm Hg. The benefit to NCT is that no anesthetic is required since the cornea is not contacted during the procedure.

- **The Tono-Pen** (Reichert) is a handheld electronic device that uses a small plunger to gauge the resistance of an anesthetized cornea when in contact. It has a known area of flattening and correlates well with GAT in “normal” IOP ranges. The device is easily portable and is most advantageous when used on scarred or edematous corneas. However, it uses a disposable latex tip and is contraindicated if the patient has a latex allergy.

- **Rebound tonometry** assumes that harder eyes (those with a high IOP) will induce a more rapid deceleration of a probe than a softer eye (those with a low IOP). The rebounding velocity is then converted into mm Hg.

- **Icare** (Icare), the newest handheld device in this category, measures the induction current created when the plastic-tipped metal probe rebounds off the cornea and is driven back into the device. This method measures the IOP relatively quickly and doesn't require anesthesia.

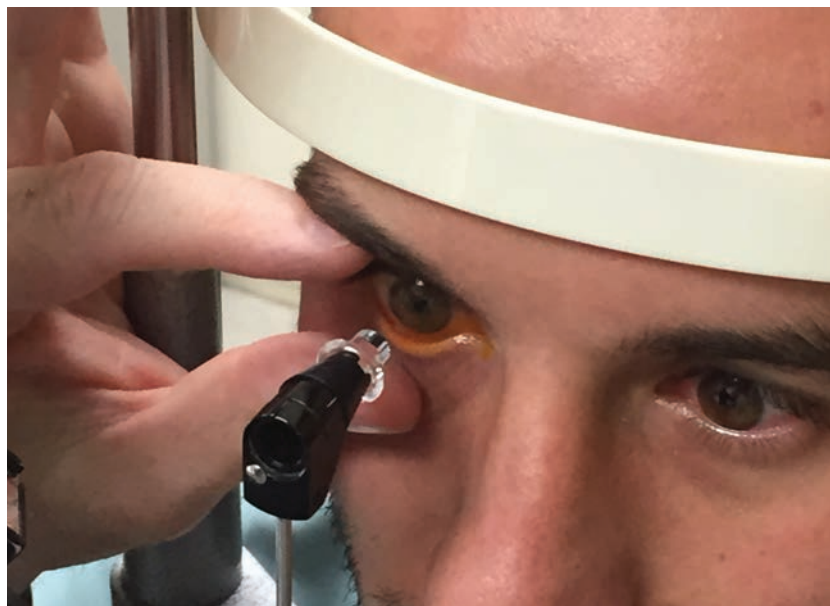Valsalva maneuver, resulting in an inaccurately high reading.¹

Lastly, studies have found tight collars, ties or other restrictive clothing around the neck may cause an increase in venous pressure when the patient extends his or her neck forward, resulting in an inaccurately high IOP reading.² Have the patient loosen any collars or neckties that may be too restrictive to obtain an accurate measurement.

DON'T apply pressure to the globe. DON'T let patients squeeze their eyes shut.

External pressure to the globe can influence the measurement. This can occur from the patient squeezing his or her eyes or the examiner inadvertently applying pressure to the globe.

Many patients need assistance adequately opening their eye during tonometry. Small fissure sizes, dermatochalasis, long eyelashes,



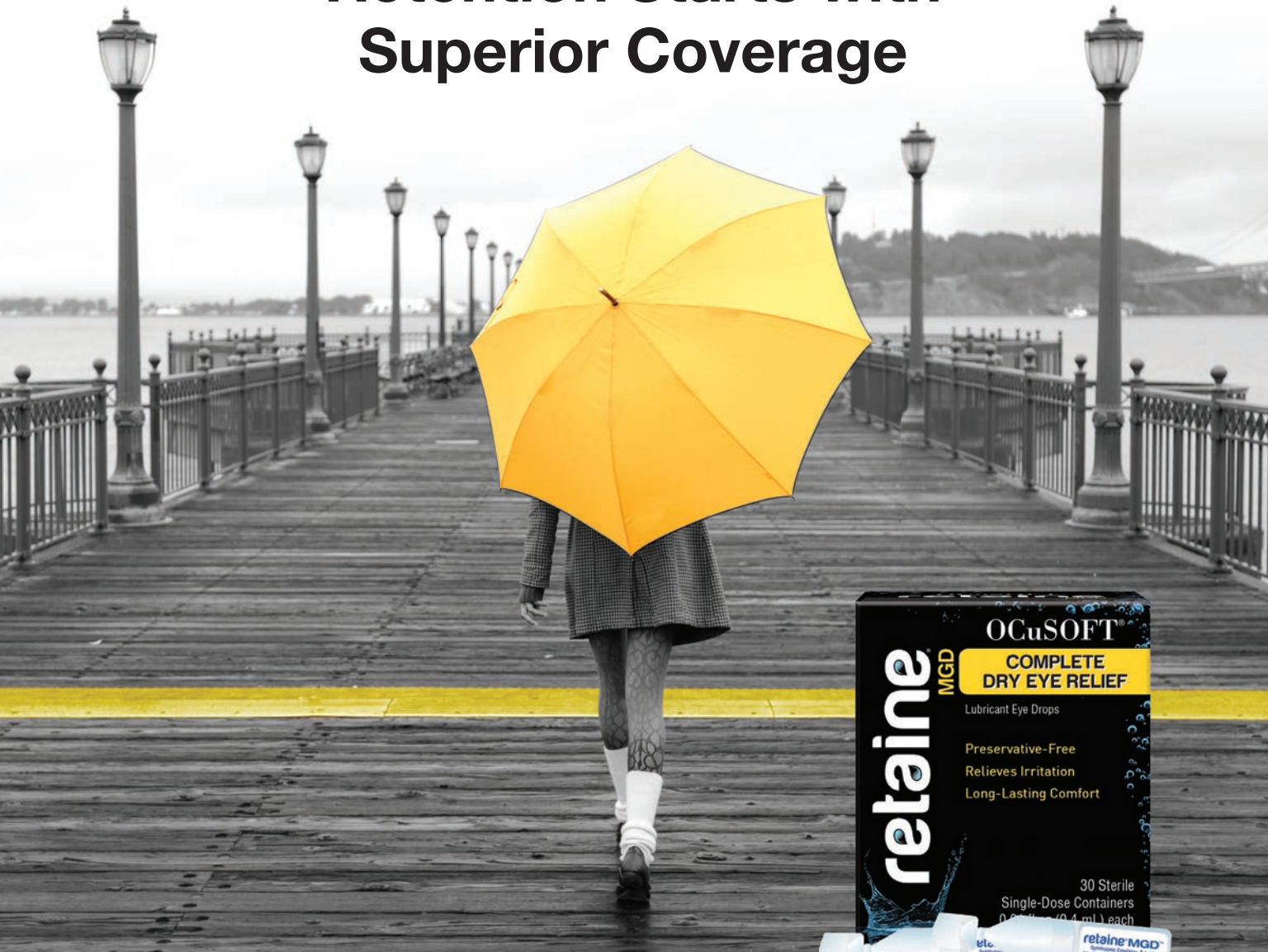Make sure the contact area is free of eyelashes and the patient doesn't squeeze his eyelids shut. Hold the patient's lids open gently to avoid any pressure on the eye.

blepharospasm and the reflex or fear of an object close to the eye can all make obtaining a pressure reading difficult and artificially high.

Avoid applying pressure to the globe when holding the lids open, and make sure the contact area is free of eyelashes. Lift the upper lid

retaine[®] MGD

Retention Starts with
Superior Coverage



Triple Action Tear Film Enhancement
Lipid Restoration | Epithelial Healing | Osmocorrection

For more information and to order, call (800) 233-5469 or visit www.ocusoft.com

CCT's Impact on IOP and Glaucoma

By Robert J. Murphy, Contributing Writer

Two recent studies explore the link between central corneal thickness (CCT) and glaucoma, underscoring the need to perform baseline CCT readings before and during glaucoma treatment.^{1,2}

Researchers at the Kaiser Permanente Northern California health plan system looked at data from 81,082 patients and found that female sex, increased age and black race were associated with thinner corneas in those with or without glaucoma.¹ The gender and age connections weren't statistically significant; but the fact that blacks, and to some extent Hispanics, tended to have thinner corneas was notable, especially considering these groups are known to have a higher prevalence of glaucoma. In these patients, CCT thinning accounted for almost 30% of the increased risk of glaucoma compared with whites.

Researchers are still unsure whether there's a direct causal link between a thin cornea and the pathophysiological mechanisms of glaucoma—or whether these factors are simply coinherited.

"I would think it's coinherited," says Theodore Perl, MD, medical director at Corneal Associates of New Jersey in Fairfield, NJ, and The Keratoconus Center of New Jersey. "It doesn't cause it, and it's not directly related. It may serve as a marker or mediator. If your cornea is thinner, then look for a possible second association, which might be susceptibility to glaucoma."

Corneal thinning has further clinical relevance for glaucoma in that the use of prostaglandin analogs (PAs) and other topical glaucoma medications have been associated with reduced CCT. A recent study from Germany sought to determine whether long-

term treatment using these agents had a significant effect on CCT as measured by partial coherence interferometry.² The researchers found that over a mean of 4.2 years, CCT decreased for those treated with PAs and combination therapies with PAs, CAIs and beta blockers.

Additionally, corneal thinning has been shown to result in underestimated IOP readings—a 25 μ m reduction of CCT can lead to about a 1 mm underestimation of pressure. Thus, the researchers warn, "follow-up intraocular pressure measurements may be underestimated for eyes treated with the aforementioned treatment regimens if central corneal thickness is not measured on a regular basis."

For the typical person with no risk factors and with normal IOP, there's no need to be too concerned about the corneal thickness, Dr. Perl says. But the clinical picture changes for a patient with a history of, or risk for, glaucoma. "In those cases, you really want to be sure that you do the central corneal thickness measurement as part of the intraocular pressure assessment, so you can put it in perspective and say, 'Ah, his pressure is normal today, it's 18mm Hg; but that's kind of borderline, and maybe that 18mm really is 22mm because his cornea is thinner.'" Dr. Perl says. "So the optometrist who's managing these kinds of problems should at least have that in the back of their minds in terms of when it's important to do it and what the [patient's situation] is."

1. Wang SY, Melles R, Lin SC. The impact of central corneal thickness on the risk of glaucoma in a large multiethnic population. *J Glaucoma* 2014;23:606-612.

2. Schrems WA, Schrems-Hoesl LM, Mardin CY, et al. The effect of long-term antiglaucomatous drug administration on central corneal thickness. *J Glaucoma* 2014 Nov. [Epub ahead of print].

with your index or middle finger without pinning the eyelid against the eyeball. Alternatively, use a cotton-tip swab to roll or hold the upper eyelid against the superior orbital bone. The lower lid may need to be stabilized as well with the clinician's thumb.

Be sure to obtain the pressure reading on the central cornea with the eye in primary gaze. Instruct patients to keep both eyes open and concentrate on a distant target (such as a fixation light or a point past your ear).

Lastly, patients may find it easier to keep their eyes open if they concurrently open their mouth. This may not be practical in the slit lamp, but it can be helpful when using handheld devices like the Tono-Pen or Icare.

DO use the appropriate amount of fluorescein.

During GAT and Perkins tonometry, it is important to instill the correct amount of fluorescein in the eye, using either Fluress (fluorescein sodium and benoxinate hydrochloride, Akorn) or fluorescein strips with a topical anesthetic.

Placing too much fluorescein into the eye will make the mires too thick, causing the IOP reading to be overestimated. Have the patient blink and wipe his or her eyes if too much fluorescein is present.

Instill additional fluorescein if an inadequate amount is in the tear film; otherwise, the mires will appear thin and the measurement will be underestimated.

When measuring the IOP, the light source is also important. The

cobalt blue light source should be bright, diffuse and obliquely directed toward the tonometer tip.

DON'T use contact tonometry on those with active corneal disease.

Use non-contact methods, like Tono-Pen, Icare or NCT, on patients with active corneal infections or corneal epithelial defects. Also, take care with patients who have recently suffered from an ocular chemical burn or have a history of recurrent epithelial erosions.

While IOP measurements are important, you must consider whether it's necessary in the balance of causing more corneal insult, delaying healing or increasing a patient's chances of corneal infection. It is important the instrument



Exclusive Optical Shop Distribution
**The New Non-Rx, 1st Step to Longer, Lusher,
 Fuller Looking Lashes and Brows**

#1 Recommended Among Eyecare Professionals



2 Special LASH ADVANCE offers — Choose 1 or Both:

PROFESSIONAL COURTESY PRICING OFFER :

provides you and your staff an opportunity to try new Lash Advance at a very low price (just \$10 + S & H — 80% off the regular retail price). Visit www.mediniche.com/LAprofessionalpricing.html or call MediNiche at 1-888-325-2395 for more details.

TRY IT!

INTRODUCTORY PURCHASE OFFER :

buy a dozen (12) packages of Lash Advance at the regular wholesale price of \$24/package and receive a 25% discount, two (2) free packages, free shipping, a free counter display, customer/staff materials and more. Visit www.mediniche.com/lashadvanceoffer.html or call MediNiche at 1-888-325-2395 for more details.

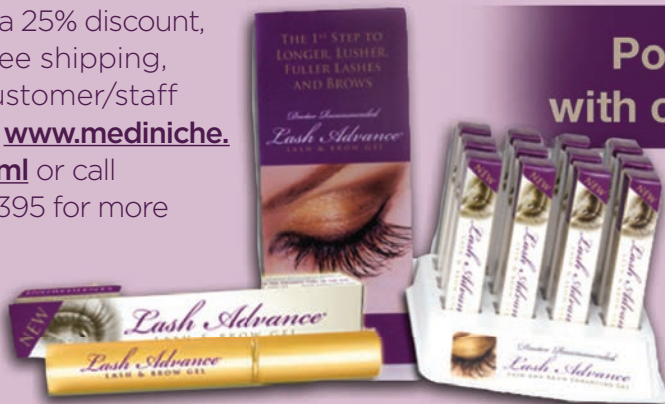BUY IT!



Introduced exclusively for eyecare professionals, new LASH ADVANCE® is a non-prescription cosmeceutical developed in conjunction with a female optometrist as a sensible start to healthier lashes and brows. LASH ADVANCE is suggested for use prior to expensive prescription products.

- Natural; no drugs or known sensitizers.
- Contains PeptiPlex®, advanced peptide complex, supports the growth cycle of lashes and brows.
- Unlike other lash products, not sold at major drug and food retailers.
- Easy application; will not run, clear gel absorbs with no residue.
- Reasonably priced; affordable.

Positive RESULTS with one tube of use!

1





Don't place too much fluorescein into the eye, which will make the mires too thick (left) and cause the IOP reading to be too high. Use the appropriate amount of fluorescein (right) to keep the mires in line.

of choice is clean and disinfected.

Take note of the location and size of the corneal disease and choose the best method. Remember, if the Tono-Pen device is used on a non-central corneal location, the IOP reading will likely measure higher due to differences in corneal properties of the peripheral cornea.

Tonosafe disposable prisms should be considered when using GAT and Perkins tonometers. Tonosafe disposable prisms reduce the risk of spreading infection to the other eye or another patient. While some clinicians use the disposable prisms on every patient, these prisms are especially good to use on patients with non-central corneal disease or an ocular infection that does not involve the cornea. These disposable prisms can also eliminate the need to disinfect the tonometer prism between each patient and decreases the risk of spreading infection.

DO document and consider corneal characteristics.

It is important to evaluate the cornea prior to IOP measurement to rule out contraindications to tonometry or note findings that may influence the measurement.

Corneal properties that affect resistance to applanation can influence the measurement; for example, scarring can result in an artificially high reading, while edema can cause a lower reading. Lastly, look for signs of prior refractive surgery, as the cornea will be thinner than prior to surgery, and IOP readings may be artificially low.

Take into consideration the central corneal thickness, as this can influence common forms of tonometry. Specifically, GAT assumes the central cornea is approximately 520 μ m in thickness. The more the central corneal thickness measurement deviates from this assumption, the less accurate the measurement—thicker corneas will be overestimated and thinner

corneas will be underestimated. Several nomograms are available to adjust the reading based on the central corneal thickness, but none have been validated and universally endorsed. Often it is useful to qualitatively consider the cornea as thin, thick or average. Understanding the general principle is most important; assigning a specific number value to adjust the IOP measurement is not.

DON'T forget to take into account corneal astigmatism.

With Goldmann applanation tonometry, corneal astigmatism greater than three diopters may influence the IOP measurement. One study found the IOP was best measured at a different angle, approximately 43° from the major axis of astigmatism (in minus cylinder), which is marked on the Goldmann tonometer prism holder with a red line.³ If the prism orientation adjustment is not made, the different curvatures of the cornea will influence the IOP reading; low IOP readings will be recorded with with-the-rule astigmatism, and higher readings will be recorded with against-the-rule astigmatism.¹ Take note, the mires will appear obliquely oriented and may be

Factors That Can Influence IOP Readings

- Respiration
- Heartbeat
- Corneal properties
- Patient posture
- Location of fixation
- Eyelid retraction
- Valsalva
- Inadvertent pressure on the globe
- Refractive surgery

A sea change in glaucoma care.

The tide is changing. A superior test for the
evaluation of glaucoma risk is rising to the surface.

Corneal Hysteresis is more associated
with visual field progression than CCT or IOP.


NEW Corneal Hysteresis (CH) CPT® Code 92145 published January 1, 2015

Reichert® Ocular Response Analyzer® is the only
tonometer that measures Corneal Hysteresis.

www.reichert.com/ch



© 2015 AMETEK, Inc. & Reichert, Inc. (4-2015) · All rights reserved · Ocular Response Analyzer is a registered trademark of Reichert, Inc. · www.reichert.com



CPT is a registered trademark of the American Medical Association.

more difficult to adjust because the slit lamp does not have the capability to adjust the mires diagonally.

Instead of using GAT for patients with astigmatism, consider using the Tono-Pen, a pneumotonometer or other devices if a patient's cornea is significantly irregular (from refractive error, scarring, ectasia, etc.).

DO make sure your instrument is calibrated.

Miscalibration of the instrument can result in systematic IOP measurement inaccuracies even with flawless technique. Check the device's operator's manual to learn how to calibrate it.

You should calibrate your instruments at least yearly and preferably twice per year. Tono-Pen requires more regular calibration and will remind the user that calibration is needed.

DON'T make significant treatment changes based on one IOP measurement.

Because IOP fluctuates over diurnal and nocturnal periods, you should rarely base significant changes in the management or treatment of a patient on one pressure reading alone. Repeat the IOP measurement at different times of day or on a different day to account for the normal IOP changes, which can fluctuate 2mm Hg to 6mm Hg in a 24-hour period.^{4,5}

Factors impacting IOP fluctuations are not well understood, and artifacts can potentially contribute to the IOP measurements. Even experienced clinicians repeat a measurement if accuracy is suspect.

Multiple measurements are recommended to obtain an accurate estimate of the mean IOP in tonometry devices other than Goldmann applanation. For instance,

non-contact tonometers (NCT), as compared with GAT, may underestimate high IOPs and overestimate low IOPs. Ideally, take an average of two to three readings depending on the NCT model; then if IOPs are considered high, low or not reproducible, perform GAT.

Similarly, the Tono-Pen and Icare devices provide relatively accurate measurements when IOP is within normal ranges; but when possible, use GAT to confirm high or low readings.

DO consider new methods.

Researchers and clinicians are constantly trying to develop better methods than are currently available to record intraocular pressures. Other devices to consider include:

- **The Ocular Response Analyzer** (Reichert) is similar to NCT, but accounts for the cornea's viscoelastic properties, or corneal hysteresis. Mathematical equations are then used to "correct" the IOP based on the elasticity of the cornea.

- **The Pascal Dynamic Contour Tonometer** (Ziemer) uses a curved probe, larger than a GAT tip, to measure IOP via hydrostatic coupling; it has demonstrated exceptionally accurate measurements compared with other current methods.⁶ This method also takes into account corneal properties, but does take longer to perform (approximately 2.5 minutes) than other methods.⁶

- **Twenty-four hour monitoring devices** would allow clinicians to analyze IOP fluctuations throughout the day, rather than momentary "snapshots" taken during office hours. For example, the Triggerfish (Sensimed) contact lens contains sensors to monitor changes in the curvature of the cornea, which researchers presume is affected by IOP changes; however, the findings

have yet to be validated.

- **Surgically-implanted IOP sensors** are also being studied, particularly for patients already undergoing ocular surgery. The accuracy and precision of these devices is currently under investigation.

Intraocular pressure is an important exam element when evaluating a patient, and it should be done carefully and accurately when warranted. Different methods and technologies have recently been introduced or are in development to help clinicians obtain more precise measurements.

Still, IOP should not be the only finding that determines a patient's likelihood for progressive disease. Many other findings—family history, central corneal thickness, other corneal properties, optic nerve head appearance, visual field findings, among others—should also be considered when assessing a patient's risk for glaucoma. ■

Dr. Townsend is a staff optometrist at Bascom Palmer Eye Institute, Miller School of Medicine at the University of Miami in Miami, Fla. Dr. Townsend sees patients with both the glaucoma service and comprehensive service.

Dr. McSoley is a staff optometrist at the Bascom Palmer Eye Institute.

1. Whitacre MM, Stein R. Sources of error with use of Goldmann-type tonometers. *Surv Ophthalmol.* 1993 Jul-Aug;38(1):1-30.

2. Bain WE, Maurice DM. Physiological variations in the intraocular pressure. *Trans Ophthalmol Soc UK.* 1959;79:249-60.

3. Goldmann VH, Schmidt T. Uber applanationtonometrie. *Ophthalmologica.* 1961;141:441-56.

4. Health Quality Ontario. Diurnal Tension Curves for Assessing the Development or Progression of Glaucoma: An Evidence-Based Analysis. *Ontario Health Technology Assessment Series.* 2011;11(2):1-40.

5. Drance SM. The significance of the diurnal tension variations in normal and glaucomatous eyes. *Arch Ophthalmol.* 1960;64(4):494-501.

6. Okafor KC, Brandt JD. Measuring intraocular pressure. *Curr Opin Ophthalmol.* 2015 Mar;26(2):103-9.

7. Gloster J, Perkins ES. The validity of the Imbert-Fick law as applied to applanation tonometry. *Exp Eye Res.* 1963 Jul;2:274-83.

As your dedicated partner in eye care
We Re-Envision Vision



Meeting the need. An increasing aging and diabetic population gives way to an increased number of patients diagnosed with retinal diseases. Regeneron is committed to delivering targeted therapies that can impact your patients' vision.

Learn more about our *science to medicine* approach at Regeneron.com.

REGENERON
science to medicine[®]

science to medicine is a registered trademark of Regeneron Pharmaceuticals, Inc.

©2015, Regeneron Pharmaceuticals, Inc.,
777 Old Saw Mill River Road, Tarrytown, NY 10591

All rights reserved

02/2015
RGN-0237



Always Evolving

Move Forward and Thrive with Robust Technology

We've been working with eyecare professionals for 25 years and we know how important it is to be on the forefront of vision testing developments. Modern technology in your clinic can increase throughput while offering the most advanced testing methods.

Smart System® 20/20 interfaces with the automated refractors from the major brands and we are constantly collaborating with leaders in the industry to keep us on the cutting edge. Your investment in our computerized visual acuity system will grow with you and give you peace of mind as you move forward.

We take your business as seriously as you do. If you're looking for a high-quality, comprehensive visual acuity testing system that is not only robust but comes with the best customer service and most attentive technical support in the industry, give us a call.



The Smart System 20/20 USA, shown with optional Glare Lights



MANUFACTURED
IN THE **USA**

See us at the AOA Meeting in Seattle, Booth 2322



M&S holds US Patents 7,354,155;
7,926,948; 8,425,040; 8,167,429;
8,419,184 & 8,550,631.
Other Patents Pending.

M&S
TECHNOLOGIES®

**The First Choice in
Vision Testing Systems**

www.mstech-eyes.com
1-877-225-6101

©2015 M&S Technologies, Inc. Smart System and M&S are registered trademarks of M&S Technologies, Inc. All Rights Reserved.

16th Annual Dry Eye Report

Who's Right: The Patient or the Test?

What do you do when a patient complains of severe dry eye symptoms but objective testing doesn't agree? Or vice versa? **By Whitney Hauser, OD**

Dry eye disease can be a frustrating and perplexing illness for both patient and doctor. Many patients present with bags full of artificial tears and other medications that have failed to bring them lasting relief. They are often desperate for answers, comfort and solutions. Doctors are eager to help, but may struggle to offer a novel treatment for a patient who has been disappointed by fruitless previous efforts. But consider a different, perhaps less common, scenario: a patient has no complaints, no bag of drops and no exasperation, but has all the signs of severe dry eye.

Research shows fewer than 60% of dry eye patients are symptomatic—which can make things tricky.¹ What do you do? To treat or not to treat, that is the question.

A Symptom-Driven Illness

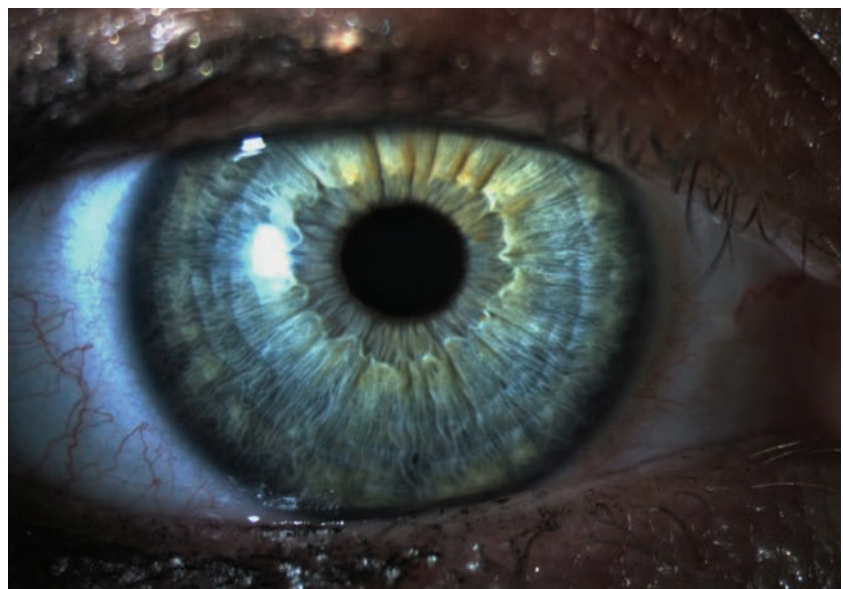
While a debatable concept to some, dry eye disease is essentially a symptom-driven illness. Patients often present to the office reporting discomfort ranging from mild irritation to agony. They present with visual complaints that can range from intermittent fluctuations to substantial decreases in functional acuity. Impact on their activities of

daily living may vary from limiting time at the computer to the inability to drive a car.

Considering an estimated 40% of patients are prompted to visit their primary care provider based on the complaint of pain, it should come as no surprise that dry eye patients are likewise propelled into our office because of symptoms.²

Addressing subjective ailments is an essential part of being a doctor—showing empathy for our patient's

plight builds a strong sense of rapport. Almost all eye care providers at some point in their career have considered if the patient is 20/20 or "20/happy"—sometimes, there is a big difference. But treating subjective complaints, particularly when few objective ones reinforce a dry eye diagnosis, can be exceptionally frustrating for doctors, considering optometry is a data-driven profession. While providing relief for patients is paramount, quantitative



No corneal defects are found in this symptomatic patient.

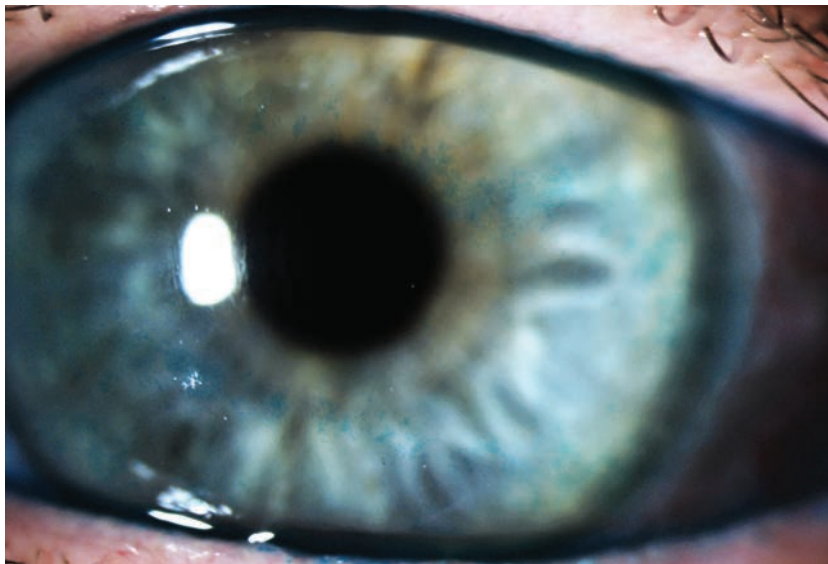diagnostic testing should support our treatment decisions, and in dry eye care it regularly does not.

Objective Testing

Dry eye surveys and questionnaires offer some objectivity to symptoms. The Ocular Surface Disease Index (OSDI) has excellent reliability and validity, as well as good sensitivity and specificity.³ It discriminates well between normal, mild to moderate and severe cases. Unfortunately, it has some limitations. OSDI has consistently failed to correlate well with traditional objective dry eye testing, namely Schirmer's test type 1, in studies.⁴ Of course, this may speak more to the diversity of the diagnosis than the accuracy of the OSDI.³

Another limitation is that OSDI is designed to evaluate ocular surface disease (OSD), which is a much broader term encompassing many diagnoses, not just dry eye. For example, patients with evaporative dry eye due to meibomian gland dysfunction could have a poor OSDI with essentially normal Schirmer's testing; similarly, a patient with conjunctivochalasis may score high on the OSDI with no form of dry eye disease at all.

Use of vital dyes like 2% sodium fluorescein and 1% lissamine green are useful in analyzing the ocular surface. Some practitioners choose one or the other, but both are required to get a detailed picture. Fluorescein is used to identify desiccated or injured cells and to perform a fluorescein tear break-up time (FTBUT). Lissamine green, on the other hand, stains dead or devitalized cells.⁵ Lissamine green is useful in evaluating conjunctival damage, conjunctivochalasis and the line of Marx along the lid margin. A combination drop, Fluramene (lissamine green 0.5% and sodium fluorescein 1.0%, EyeSupply USA), is conve-



Diffuse lissamine green staining is evident in this asymptomatic patient.

nient because it requires only one instillation vs. multiple strips. However, it stains the eyelids and can be difficult to remove once applied.⁶ The vital dyes may be the first indicator that the patient's signs and symptoms don't match up.

The Emotion Factor

Lack of clinical signs doesn't mean there isn't a problem. Managing a patient's symptoms may not be exclusively an ocular health concern either. Research shows patients with dry eye disease are more vulnerable to anxiety and depression. Self-rated anxiety scores correlated with OSDI and education level, and self-rated depression scores correlated with OSDI alone.⁷ Neither anxiety nor depression showed a connection to age, gender, household income, tear break-up time (TBUT), Schirmer's test 1, fluorescein staining or visual acuity.⁷ How patients view their condition and report symptoms may create a clinical mismatch, yet it makes the obstacle no less real. The emotional component of dry eye disease tends to make the patient's care even more delicate and complicated.

The Symptomatic Patient

Let's consider Laura, a 64-year-old white female who presented for a dry eye evaluation several months ago. Laura was miserable. She was unable to work on her iPad for more than five minutes at a time and could no longer drive a car. The pain was palpable for both her and her husband, who served as her constant companion and chauffeur. Laura's subjective complaints and dry eye history were extremely lengthy—she had tried it all. A multitude of artificial tears, ophthalmic medications and punctal cautery brought no relief. Her complaints were profound, but the apparently insignificant objective findings left me scratching my head. Laura's complaints could be psychosomatic; however, after nearly 15 years of practice, I consider psychosomatosis a diagnosis of exclusion.

Laura's acuity was 20/20 (though not 20/"happy"). Her OSDI score was 100 (out of 100). Her tear osmolarity was 290/306 OD/OS. Lipiview measured both lipid layer thickness (LLT) at 81/79 OD/OS and partial blinks at 6/12 OD/

OS. Her non-invasive keratograph break-up time (NIKBUT) was 6.63/7.87 OD/OS. ZoneQuick was 15/15mm OD/OS. Infrared meibography showed modest meibomian gland atrophy but no frank fallout. At the slit lamp, she had no blepharitis or lagophthalmos and did not exhibit increased lid laxity relative to her age. No lissamine green or fluorescein stain was identified on the conjunctiva or cornea. None of the additional testing was outside of normal limits.

While some of Laura's objective testing pointed to the diagnosis of dry eye disease with likely a mixed-mechanism origin, none of the findings appeared to warrant the extreme symptoms she reported. With incompatible subjective and objective testing, what is a doctor to do? Without the luxury of knowing

her lengthy and failed history with artificial tears, one might be tempted to throw a lipid-based tear on the problem and schedule a follow-up. But that was not going to cut it for Laura or her husband, who wanted her to find relief as much as she did.


Thus began our winding journey through Laura's dry eye treatment. In search of solace, we have tried a plethora of artificial tears, cyclosporine, nonsteroidal anti-inflammatories, cellulose ophthalmic inserts, scleral contact lenses and, finally, thermal pulsation with Lipiflow. She was tested for Sjögren's syndrome and had a complete rheumatology work-up. All tests were negative. We are still on the journey with only bouts of short-lived relief.

Most recently, Laura elected to have intense pulsed light (IPL) therapy for dry eye. Ideally, her

mild rosacea will regress with treatment, which offers benefits for both cutaneous and ocular rosacea. IPL shuts down blood vessels that bring inflammatory mediators to the lid margin and decreases the amount of bacteria on the skin. IPL may also decrease the presence of parasites on the skin. As the rosacea subsides and the telangiectasias are minimized, symptoms may also diminish. It is too soon to know the outcome, but I'm still optimistic that she will find relief.^{8,9}

Preventative Medicine

Symptomatic patients like Laura are easily persuaded to try various treatments, but what about the patient who thinks all is well—until testing reveals otherwise? Although “asymptomatic” means without symptoms, it certainly doesn't mean



Focused on eyes. Inspired by life.



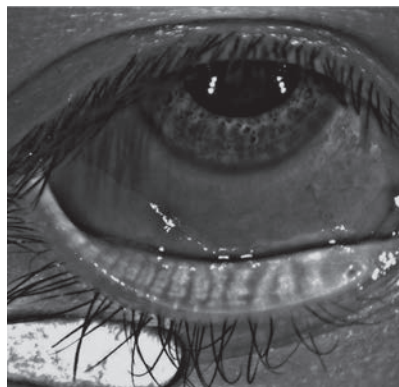OPHTHALMICS

without illness or disease. People regularly walk through life with undiagnosed conditions that range in severity from benign to life-threatening. Treatment for hypertension, for example, has increased since 1999 due to an increased public awareness, yet an estimated 20% of adults in the United States have hypertension and still don't know it.¹⁰ Untreated high blood pressure can contribute to heart attack, stroke, chronic heart failure and kidney disease.³ Similarly in eye care, glaucoma is an insidious disease that offers few, if any, red flags to patients before diagnosis.

Preventative medicine, as defined by the American Board of Preventative Medicine, is health care “focusing on the health of individuals, communities and defined populations. Its goal is to protect, promote and maintain health and well-being and to prevent disease, disability and death.”⁵ Public awareness of preventative medicine is on the rise, and patients are more likely than ever before to pursue cholesterol screenings, mammograms and the like. They seek these results not because they have symptoms, but rather because they acknowledge that earlier diagnosis and treatment often leads to better prognosis.

Historically, dentistry has done an exceptional job of prioritizing preventative care, recommending patients return twice a year for cleaning and evaluation. Likewise, eye care professionals should recommend biannual evaluation for patients who are more susceptible to OSD under the notion of preventative care. Ultimately, alerting patients to potential symptoms may head off their future frustrations and give the doctor a leg up on initiating early treatment.

It's clear to see the motivations to treat asymptomatic hypertensive and



In this symptomatic patient, essentially normal meibography reveals no atrophy or tortuosity of the glands.

glaucoma patients, but should dry eye disease—which is rarely sight-threatening—be addressed as aggressively? Research supports improved objective and subjective results with treatment; however, most studies acknowledge some element of patient-reported symptoms.¹¹ When it comes to asymptomatic patients, some may consider the adage: “if it ain't broke, don't fix it.” Still others may fancy themselves cowboys, and try to “head it off at the pass.” Neither approach is absolute.

Education

If patients don't have symptoms to motivate them, perhaps patient education will. If you elect to treat the asymptomatic patient, proper education is essential. Most doctors readily acknowledge that ocular surface disease does not always mean that the predominant symptom is dryness. In fact, “dry eye” is often a misnomer to patients. They require education to embrace the fact that ocular surface disease may manifest as a decrease in quality and quantity of vision, as well as comfort-related symptoms. The patient must understand the chronic, multifactorial nature of dry eye disease, and that the symptoms, though absent now, cannot be outrun forever. Carefully

drawing parallels to silent diseases like hypertension may prove beneficial, but don't sound too dramatic. Let objective diagnostic testing provide the most persuasive argument. After all, a picture, whether it's meibography or external photography, is worth a thousand words. Once the chronicity of the condition is appreciated, some patients may be won over. For others, slowly chipping away with more conventional educational means such as emails and mailings may help. Often there can be an additive effect to gradual education and patients eventually reach that “ah-ha” moment.

The Asymptomatic Patient

Consider Sarah, a 60-year-old white female, who had mild dry eye symptoms that were identified at a yearly comprehensive eye examination. As a college professor, she reads voraciously for both work and pleasure. Additionally, she spends hours researching for a novel she is writing. Near demands for Sarah were exceptionally high, but she was only aware of occasional fluctuations in vision. Upon examination, her visual acuity was 20/20 in each eye. Her OSDI score was 28/100 and SPEED was 4/28. Tear osmolality was 325/333 OD/OS. Lipiview revealed excellent blink performance but a staggeringly low LLT of 30/28 ICUs OD/OS. RPS InflammDry was faintly positive, and ZoneQuick was over 30mm OD/OS. NIKBUT was 7.58sec and 6.76sec, respectively. At the slit lamp, Sarah had no blepharitis or lagophthalmos. However, she did present with moderate conjunctival staining with lissamine green in both eyes.

The signs that Sarah exhibited were remarkable compared to those of our patient, Laura. However, she thought little of the diagnosis. In fact, none of this was news to her.



Down, Boy.

Help Tame Postoperative Ocular Inflammation
and Pain With **LOTEMAX[®] GEL**

Indication

LOTEMAX[®] GEL (loteprednol etabonate ophthalmic gel) 0.5% is indicated for the treatment of post-operative inflammation and pain following ocular surgery.

Important Safety Information about LOTE[®]MAX[®] GEL

- LOTE[®]MAX[®] GEL is contraindicated in most viral diseases of the cornea and conjunctiva including epithelial herpes simplex keratitis (dendritic keratitis), vaccinia, and varicella, and also in mycobacterial infection of the eye and fungal diseases of ocular structures.
- Prolonged use of corticosteroids may result in glaucoma with damage to the optic nerve, defects in visual acuity and fields of vision. If this product is used for 10 days or longer, IOP should be monitored.
- Use of corticosteroids may result in posterior subcapsular cataract formation.
- Use of steroids after cataract surgery may delay healing and increase the incidence of bleb formation and occurrence of perforations in those with diseases causing corneal and scleral thinning. The initial prescription and renewal of the medication order should be made by a physician only after examination of the patient with the aid of magnification, and where appropriate, fluorescein staining.
- Prolonged use of corticosteroids may suppress the host response and thus increase the hazard of secondary ocular infection. In acute purulent conditions, steroids may mask infection or enhance existing infection.
- Use of a corticosteroid medication in the treatment of patients with a history of herpes simplex requires great caution. Use of ocular steroids may prolong the course and exacerbate the severity of many viral infections of the eye (including herpes simplex).
- Fungal infections of the cornea are particularly prone to develop coincidentally with long-term local steroid application. Fungus invasion must be considered in any persistent corneal ulceration where a steroid has been used or is in use.
- Patients should not wear contact lenses when using LOTE[®]MAX[®] GEL.
- The most common ocular adverse drug reactions reported were anterior chamber inflammation (5%), eye pain (2%) and foreign body sensation (2%).

Please see brief summary of Prescribing Information on adjacent page.



LOTEMAX[®] GEL

loteprednol etabonate
ophthalmic gel 0.5%

LOTEMAX[®]loteprednol etabonate
ophthalmic gel 0.5%

Brief Summary: Based on full prescribing information.

To report SUSPECTED ADVERSE REACTIONS, contact Bausch & Lomb at 1-800-323-0000 or FDA at 1-800-FDA-1088 or www.fda.gov/medwatch

INDICATIONS AND USAGE

LOTEMAX is a corticosteroid indicated for the treatment of post-operative inflammation and pain following ocular surgery.

DOSAGE AND ADMINISTRATION

Invert closed bottle and shake once to fill tip before instilling drops.

Apply one to two drops of LOTE MAX into the conjunctival sac of the affected eye four times daily beginning the day after surgery and continuing throughout the first 2 weeks of the post-operative period.

CONTRAINDICATIONS

LOTE MAX, as with other ophthalmic corticosteroids, is contraindicated in most viral diseases of the cornea and conjunctiva including epithelial herpes simplex keratitis (dendritic keratitis), vaccinia, and varicella, and also in mycobacterial infection of the eye and fungal diseases of ocular structures.

WARNINGS AND PRECAUTIONS**Intraocular Pressure (IOP) Increase**

Prolonged use of corticosteroids may result in glaucoma with damage to the optic nerve, defects in visual acuity and fields of vision. Steroids should be used with caution in the presence of glaucoma. If this product is used for 10 days or longer, intraocular pressure should be monitored.

Cataracts

Use of corticosteroids may result in posterior subcapsular cataract formation.

Delayed Healing

The use of steroids after cataract surgery may delay healing and increase the incidence of bleb formation. In those diseases causing thinning of the cornea or sclera, perforations have been known to occur with the use of topical steroids. The initial prescription and renewal of the medication order should be made by a physician only after examination of the patient with the aid of magnification such as slit lamp biomicroscopy and, where appropriate, fluorescein staining.

Bacterial Infections

Prolonged use of corticosteroids may suppress the host response and thus increase the hazard of secondary ocular infections. In acute purulent conditions of the eye, steroids may mask infection or enhance existing infection.

Viral Infections

Employment of a corticosteroid medication in the treatment of patients with a history of herpes simplex requires great caution. Use of ocular steroids may prolong the course and may exacerbate the severity of many viral infections of the eye (including herpes simplex).

Fungal Infections

Fungal infections of the cornea are particularly prone to develop coincidentally with long-term local steroid application. Fungus invasion must be considered in any persistent corneal ulceration where a steroid has been used or is in use. Fungal cultures should be taken when appropriate.

Contact Lens Wear

Patients should not wear contact lenses during their course of therapy with LOTE MAX.

ADVERSE REACTIONS

Adverse reactions associated with ophthalmic steroids include elevated intraocular pressure, which may be associated with infrequent optic nerve damage, visual acuity and field defects, posterior subcapsular cataract formation, delayed wound healing and secondary ocular infection from pathogens including herpes simplex, and perforation of the globe where there is thinning of the cornea or sclera.

The most common adverse drug reactions reported were anterior chamber inflammation (5%), eye pain (2%), and foreign body sensation (2%).

USE IN SPECIFIC POPULATIONS**Pregnancy****Teratogenic Effects: Pregnancy Category C.**

Loteprednol etabonate has been shown to be embryotoxic (delayed ossification) and teratogenic (increased incidence of meningocele, abnormal left common carotid artery, and limb flexures) when administered orally to rabbits during organogenesis at a dose of 3 mg/kg/day (35 times the maximum daily clinical dose), a dose which caused no maternal toxicity. The no-observed-effect-level (NOEL) for these effects was 0.5 mg/kg/day (6 times the maximum daily clinical dose). Oral treatment of rats during organogenesis resulted in teratogenicity (absent innominate artery at ≥ 5 mg/kg/day doses, and cleft palate and umbilical hernia at ≥ 50 mg/kg/day) and embryotoxicity (increased post-implantation losses at 100 mg/kg/day and decreased fetal body weight and skeletal ossification with ≥ 50 mg/kg/day). Treatment of rats with 0.5 mg/kg/day (6 times the maximum clinical dose) during organogenesis did not result in any reproductive toxicity. Loteprednol etabonate was maternally toxic (significantly reduced body weight gain during treatment) when administered to pregnant rats during organogenesis at doses of ≥ 5 mg/kg/day.

Oral exposure of female rats to 50 mg/kg/day of loteprednol etabonate from the start of the fetal period through the end of lactation, a maternally toxic treatment regimen (significantly decreased body weight gain), gave rise to decreased growth and survival, and retarded development in the offspring during lactation; the NOEL for these effects was 5 mg/kg/day. Loteprednol etabonate had no effect on the duration of gestation or parturition when administered orally to pregnant rats at doses up to 50 mg/kg/day during the fetal period.

There are no adequate and well controlled studies in pregnant women. LOTE MAX should be used during pregnancy only if the potential benefit justifies the potential risk to the fetus.

Nursing Mothers

It is not known whether topical ophthalmic administration of corticosteroids could result in sufficient systemic absorption to produce detectable quantities in human milk. Systemic steroids appear in human milk and could suppress growth, interfere with endogenous corticosteroid production, or cause other untoward effects. Caution should be exercised when LOTE MAX is administered to a nursing woman.

Pediatric Use

Safety and effectiveness in pediatric patients have not been established.

Geriatric Use

No overall differences in safety and effectiveness have been observed between elderly and younger patients.

NONCLINICAL TOXICOLOGY**Carcinogenesis, Mutagenesis, Impairment Of Fertility**

Long-term animal studies have not been conducted to evaluate the carcinogenic potential of loteprednol etabonate. Loteprednol etabonate was not genotoxic *in vitro* in the Ames test, the mouse lymphoma tk assay, or in a chromosome aberration test in human lymphocytes, or *in vivo* in the single dose mouse micronucleus assay. Treatment of male and female rats with up to 50 mg/kg/day and 25 mg/kg/day of loteprednol etabonate, respectively, (600 and 300 times the maximum clinical dose, respectively) prior to and during mating did not impair fertility in either gender.

PATIENT COUNSELING INFORMATION**Administration**

Invert closed bottle and shake once to fill tip before instilling drops.

Risk of Contamination

Patients should be advised not to allow the dropper tip to touch any surface, as this may contaminate the gel.

Contact Lens Wear

Patients should be advised not to wear contact lenses when using LOTE MAX.

Risk of Secondary Infection

If pain develops, redness, itching or inflammation becomes aggravated, the patient should be advised to consult a physician.

FOR MORE DETAILED INFORMATION, PLEASE READ THE PRESCRIBING INFORMATION.

Bausch & Lomb Incorporated

Tampa, Florida 33637 USA

US Patent No. 5,800,807

©Bausch & Lomb Incorporated

®/™ are trademarks of Bausch & Lomb Incorporated or its affiliates.

She was previously diagnosed with dry eye and prescribed cyclosporine. Sarah discontinued the drops several years ago after only a few weeks of reported compliance because she felt nothing in her life had changed. It was difficult to argue with her. Cyclosporine is indicated to increase tear production, but not necessarily decrease near vision fluctuations, which was the patient's only aggravation from the diagnosed dry eye disease. Lack of education probably set up both Sarah, and the medication she was prescribed, for failure.

Can, or should, Sarah be re-engaged as an active participant in her dry eye maintenance? I chose to pull her back into the fold. With gentle persuasion and education, she has dutifully returned for follow-up exams and maintained moderate compliance with recommended therapies. We started with lipid-based artificial tears and a warm, silicone-beaded mask used two times per day. While the objective testing points toward an evaporative dry eye disease and Lipiflow would be warranted, I elected to stick with a more basic course. The thermal pulsation treatment would have expedited improvement in her testing; yet, I tend to proceed with conservatism and caution in asymptomatic patients especially when it comes to presenting an elective procedure. Her modest dedication to her own condition satisfies me for now. The dry eye disease is likely to progress as the years go on and, hopefully, Sarah will recognize that she has a partner in piecing together this ever-changing puzzle.

When You Should Treat, and When You Shouldn't

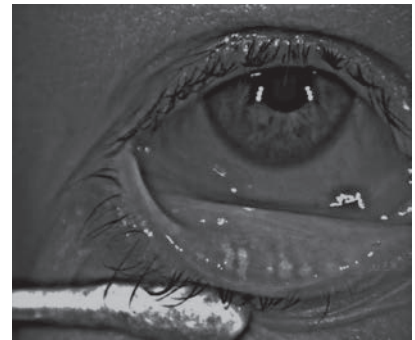
Did I make the right choice for Sarah? All practitioners have to answer that question for themselves when a similar patient presents. And

the answer may change. Some may be more easily enrolled in preventative care while others won't appreciate the value or flat out consider it unnecessary. We often coach our staff not to prejudge how much a patient is willing to pay for frames and lenses. Equally, we should proceed with caution and not assume which patients will and won't "buy in" to preventative care. Patients who list a multitude of supplements may be your prime candidates, but a patient who recently had a heart attack may be turning over a new leaf in his or her life and may be just as willing to listen.

A detailed case history is the key to choosing the best testing that finally provides the most accurate diagnosis. Consider occupation and avocation in addition to medications, typical environmental conditions and failed therapies. Special attention should also be paid to patient populations predisposed to dry eye disease like those with thyroid eye disease, autoimmune disease and diabetes.

There are occasions when asymptomatic patients must be treated to prevent greater risk: if vision is consistently compromised; the ocular surface has significant irregularities, increasing susceptibility to bacterial invasion; or if patients have decreased corneal sensitivity or a neurotrophic cornea, because they may never elicit a response.

Dry eye disease is a confounder on many levels. The multifactorial nature of it casts slings and arrows from every direction. What relieves symptoms may not improve signs, and what works in June is a failure in January. We can succumb to the frustration that there are no quick fixes or easy answers, or accept the challenges that dry eye disease presents. There are millions of sufferers across the United States, and



Significant meibomian gland atrophy in an asymptomatic patient.

numbers are only expected to climb as baby boomers age. Doctors will likely encounter more puzzling patients in their practices, and they will have to make the decision to go "all in" or "let it ride." ■

Dr. Hauser is an assistant professor at Southern College of Optometry in Memphis, Tenn., clinical development consultant for Tear-Well Advanced Dry Eye Treatment Center and founder of Signal Ophthalmic Consulting. She serves as a consultant for TearScience.

1. Bron AJ, Tomlinson A, Foulks GN. Rethinking dry eye disease: a perspective on clinical implications. *Ocul Surf.* 2014 Apr;12(2 Suppl):S1-31.
2. Mantyselka P, Kumpusalo A, Kauhanen J, et al. Pain as a reason to visit a doctor's office: a study in Finnish primary healthcare. *Pain.* 2001 Jan;89(2-3):175-80.
3. Schiffman RM, Jacobsen CG, Hirsch J. Reliability and validity of ocular surface disease index. *Arch Ophthalmol.* 2000 May;118(5):615-21.
4. Lemp MA. Report of the national eye institute/industry workshop on clinical trials in dry eyes. *CLAO J.* 1995;21:221-32.
5. Abelson M, Ingerman A. The dye-namics of dry-eye diagnosis. *Review of Ophthalmology.* 2005 Nov;12(11). www.reviewofophthalmology.com/content/1/1311/c/25254/.
6. Bowling E. Double vital dye staining. *Vision Care Professional.* 2012 March. www.visioncareprofessional.com/emails/managingdryeye/newsletter21.asp.
7. Wen W, Wu Y, Chen Y, et al. Dry eye disease in patients with depressive and anxiety disorders in Shanghai. *Cornea.* 2012 Jun;31(6):686-92.
8. Kent C. Intense pulsed light: for treating dry eye. *Review of Ophthalmology.* 2010 Nov;17(11). www.reviewofophthalmology.com/content/1/1353/c/25857/.
9. Elmnesser N, et al. Bacterial inactivation using pulsed light. *Acta Alimentaria.* 2007;36:3:401-8.
10. High Blood Pressure Facts. Centers for Disease Control and Prevention.
11. Greiner J. Long-term (12-month) improvement in meibomian gland function and reduced dry eye symptoms with a single thermal pulsation treatment. *Clin Experiment Ophthalmol.* 2013 Aug;41(6):524-30.

COST OF GOODS SAVINGS CAN ONLY HELP YOU GROW SO MUCH

IN THE NEW ERA OF
POPULATION HEALTH MANAGEMENT,
WHAT'S YOUR PLAN
TO WIN:

- More Patients
- More Profits
- More Time
- All of the Above

Go To **VisionSourcePlan.com** and
We'll Give You Ours



© Vision Source L.P. 2015. All Rights Reserved.

**VISION
SOURCE**
SIGNATURE EYE CARE

16th Annual Dry Eye Report

Whet Your Appetite for New Dry Eye Drugs

Doctors have few choices to treat this growing diagnosis, but that may change soon. Here's 10 medications in the pipeline. **By I. Ben Gaddie, OD**

Dry eye disease is one of the most common clinical entities optometrists encounter today. However, our discipline has yet to reach a consensus on the rationale for diagnosis and treatment. In addition, it is well established that the signs and symptoms of this condition are not congruent, and missed or false diagnosis remains a critical hurdle in the long-term management of this chronic disease.¹

Dry eye disease is a complex dysfunction of the ocular surface and is characterized by sometimes-painful symptoms, increased tear evaporation, inflammation and reduced tear production.² Research suggests the activation of T-cell mediated pro-inflammatory immune responses lead to cytokine release, inflammation and a hyperosmolar state.³ For this reason, most therapies target the disease's inflammatory nature.

The market, like nature, abhors a vacuum and with so few available dry eye treatments (and an ever-growing number of dry eye patients), a vacuum certainly exists. The pharmaceutical industry is on

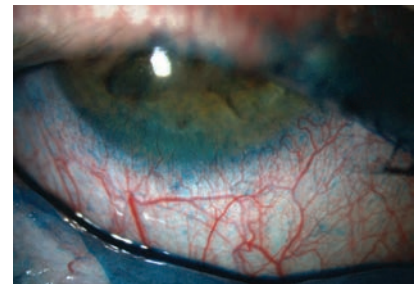
the cusp of offering several new formulations to the market.

This article provides a look at what treatments are in development, possibly on their way to our offices and how they work.

What's the Hold Up?

Before reviewing drugs not yet available, consider that, to date, the only FDA-approved medication for the management of dry eye is Restasis (topical cyclosporine 0.05%, Allergan). Restasis was the first agent to target the T-cell related inflammatory pathways in dry eye disease. In particular, it is approved for the reduction in inflammation of the lacrimal gland. That was approved 13 years ago. You may be wondering 'what's the hold up?'

On a basic level, the disease's complexity is to blame. Based on previous FDA approvals and subsequent denials of new drug applications (NDAs), it appears that a candidate dry eye drug in pivotal trials should demonstrate statistical significance in the reduction of both signs and symptoms of dry eye—no small task. Are we making any



Severe staining with lissamine green on the conjunctiva and, particularly, on the inferior cornea.

headway? Let's take a look at the efforts to find the next blockbuster drug for dry eye disease.

1. Cyclosporine

While the current formulation of Restasis dominates the market, the next generation of cyclosporine could be just around the corner. Allergan has enjoyed an exclusive position in the dry eye pharmaceutical area and, indeed, is working on its own update in Restasis X. In the future it may have to compete with Ikervis (cyclosporin A 0.1%, Santen), which was recently approved in Europe. In addition to a higher concentration, Ikervis

employs new delivery methods, such as new vehicle technology that may make cyclosporine more tolerable and perhaps more efficacious. The proof will be in the clinical trials currently underway.

Ikervis is approved throughout Europe for the treatment of severe keratitis in adults with dry eye that has not improved, despite treatment with tear substitutes. It appears, via clinicaltrials.gov, that Restasis X (also a 1% concentration) is under review by European regulators too.

2. Lifitegrast

When considering mechanisms of action for potential new drugs in the dry eye arena, most efforts have been devoted to inflammation, tear production, tear film movement and tear chemistry; specifically, lipid layer chemistry. Additionally, drug delivery platforms remain a viable development goal in terms of increased efficacy, convenience and compliance for patients.

Lifitegrast is an agent that its parent company, Shire, hopes to move expediently toward the commercialization process. The agent itself mimics lymphocyte function antigen-1 (LFA-1), thereby preventing activation of intercellular adhesion molecule-1 (ICAM-1) which is expressed on the inflamed epithelial cell surface. Activation and migra-

tion of free lymphocytes to the ocular surface are key steps in the chronic inflammatory process leading to dry eye disease. This process is influenced and initiated by the binding of the T-cell integrin LFA-1 to ICAM-1. The drug influences the activation and homing of activated T-cells or cytokines. Lifitegrast acts as an ICAM-1 decoy and subsequently prevents binding of LFA-1 to ICAM-1, breaking the cycle of T-cell mediated inflammatory response on the ocular surface.

3. EBI-005

Eleven Biotherapeutics has developed an agent it is currently calling EBI-005 that targets the inflammatory pathway in a much different way, via the IL-1 system.

IL-1 is a cardinal mediator of inflammatory responses and likely plays a key role in the modulation of signs and symptoms of dry eye disease. There are two IL-1 cytokines, IL-1 alpha and IL-1 beta, the latter of which regulates immune function and T-helper differentiation involved in the inflammatory cascade. IL-1 also mediates pain from the corneal nerve plexus implicated in the symptoms of dry eye disease.

EBI-005 is currently in Phase II clinical trials for the treatment of dry eye. These trials will look to

demonstrate whether EBI-005 can block both inflammation and pain associated with dry eye.

4. Anakinra

Another IL-1 antagonist significantly reduced symptoms and corneal epitheliopathy in dry eye patients, according to research published in 2013.⁴ That study looked at 75 patients using Kineret (anakinra, Amgen) and measured dry eye-related symptoms by using the Ocular Surface Disease Index, tear film break-up time and meibomian gland secretion quality. After 12 weeks, the study showed significant reductions in dry eye symptoms of 30% in patients who received topical anakinra (2.5%) and 35% in patients who received a higher dose anakinra (5%).⁴

The study showed no reports of serious adverse reactions attributable to the therapy.⁶

5. MIM-D3

MIM-D3 (Mimitogen Pharmaceuticals) is a topical drug in the dry eye pipeline that is different in its approach to dry eye therapy. It is a molecule that has multiple activities, including survival and differentiation of neuronal cells, stimulation of mucus secretion and participation in the repair of corneal epithelial cell damage. It partially mimics nerve growth factor, which research shows may improve the clinical outcome of neurotrophic keratitis and corneal ulcers.^{7,8}

The molecule that nerve growth factors work through is tyrosine kinase (TrkA) which is found in human conjunctival epithelial cells. MIM-D3 also serves to mimic TrkA. Phase II clinical trials have concluded and a multicenter Phase III clinical study for the treatment of dry eye syndrome is currently underway.

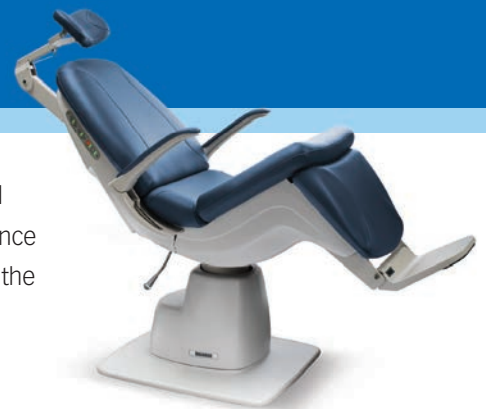Lifitegrast Data Undergoing FDA Review

Published Phase III studies in pursuit of FDA approval for lifitegrast have demonstrated mixed results for the "signs and symptoms" measures expected for FDA approval, but ultimately yielded enough positive clinical evidence to receive fast-track review designation from the FDA. The OPUS-1 trial, which looked at the primary outcome measure of inferior corneal staining, demonstrated the superiority of lifitegrast in reducing ocular surface punctate epithelial lesions when compared with placebo. In addition to improvement in fluorescein staining, the drug also showed improvement in total conjunctival staining with lissamine green.⁴ The OPUS-2 study showed a significant reduction in dryness symptoms with the use of lifitegrast.⁵ In early March, lifitegrast's developer, Shire Pharmaceuticals, submitted an application to the FDA for approval based on the totality of the two Phase III pivotal trials as well as a Phase III safety trial.



Boxer Randall Jones comments on the strength of Reliance arms.

Reliance chairs are built to take a beating. The armrests, footrest, chair back and apron can all withstand a patient's full weight. It's not surprising, then, that Reliance chairs last longer, and require very little maintenance. This is why they're one of the world's best-selling brand of chairs and stools. Call today for the name of your nearest authorized dealer.



800.787.5426
haag-streit-usa.com



 **RELIANCE**
INTERNATIONAL

© 2015 Haag-Streit USA. All Rights Reserved.

6. Rebagen

Rebagen (rebamipide, Otsuka Pharmaceuticals) was originally researched for the treatment of gastric ulcers in rats and later marketed as a tablet for gastric ulcer therapy.

However, it was later found that the drug also has the ability to reduce inflammation and promote epithelial mucin secretion. Research shows its ability to increase the secretion of corneal and conjunctival mucins and to increase the number of goblet cells in rabbits.⁹ Currently, it's only available for dry eye treatment in Japan.

7. Tofacitinib

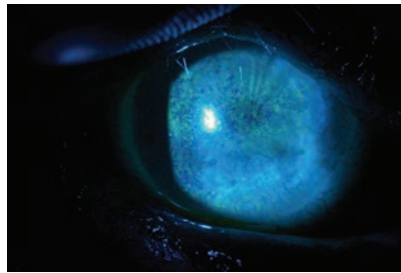
Tofacitinib (Pfizer), a topical ophthalmic Janus kinase (JAK), may also act as an immunomodulator in dry eye patients. This medication essentially blocks signaling that leads to inflammation. In a clinical trial that looked at 327 patients for eight weeks, doctors observed clinically significant improvements to signs and symptoms of dry eye.¹⁰

One study, albeit a small one with only 82 patients, showed a promising reduction of conjunctival cell surface HLA-DR expression and tear levels of proinflammatory cytokines and inflammation markers after eight weeks of treatment.¹¹

A 2014 animal study showed tofacitinib treatment decreased corneal infiltration of the CD45+, Gr-1+ and CD11b+ cells on days one and three of treatment.¹²

Tofacitinib and other kinase inhibitors are known for their ability to treat rheumatoid arthritis.¹³

Nicox acquired several kinase inhibitors last year in a deal with Acix Therapeutics. That deal included a small molecule dual Syk/JAK inhibitor for potential topical treatments, a drug being developed for allergic conjunctivitis (AC-170), and another for postoperative



Fluorescein staining pattern of a patient with severe punctate epithelial keratopathy secondary to dry eye, associated with Sjögren's syndrome and exposure keratopathy.

inflammation and pain (AC-155), according to a press release.

8. EGP-437

EyeGate Pharmaceuticals' take on dexamethasone phosphate formulated for ocular iontophoresis is useful as a tool against both uveitis and dry eye, according to the company's website. But does the science pan out? According to a 2011 study published in *Clinical Ophthalmology*, EGP-437 can demonstrate statistically and clinically significant improvements in both signs and symptoms of dry eye in a controlled adverse environment model.¹⁴ The randomized clinical trial looked at 103 patients. Unspecified treatment-emergent adverse events were experienced by 87% of patients and were consistent across all treatment groups. Most, however, were mild and none were severe, according to the study.

9. RGN-259

Perhaps the most recent addition to this list, RegeneRx's thymosin β 4 0.1% eye drops, RGN-259, was the topic of a study published in the May 2015 issue of *Cornea*. That study showed the results of a Phase II randomized trial in which the drug demonstrably improved both signs and symptoms of dry eye.¹⁵

Nanotechnologies and Other Novel Delivery Methods

Not only are new therapeutic agents needed to meet the gaps around diagnosis and management, but new delivery options too. Nanotechnology has emerged as a promising platform for many areas of biomedical research. The field of nanotechnology involves matter less than 100nm in diameter. Liposomes are small particles that can be easily delivered in aerosol form or in a targeted manner, allowing for more precise and deeper penetration to target tissues. One example of a currently available ophthalmic drop is Tears Again Hydrate Liposomal Spray (Ocusoft) for the treatment of MGD-related tear film evaporation. The MGD Workshop treatment guidelines recommended this product as an option.

EyeGate is investigating another drug delivery system to deliver dexamethasone via iontophoresis. This technology works by applying a small electrical current to the ocular surface to increase drug concentration and enhance conjunctival and scleral absorption.

Other, more familiar technologies include punctal plug drug-eluting devices containing agents ranging from dexamethasone to cyclosporine.

Researchers have already seen that thymosin β 4 upregulates the expression of laminin-5, a component of the basement membrane region of the skin, cornea, conjunctiva and other tissues.¹⁵ These and other biological activities of thymosin β 4 are important to corneal repair, according to a 2004 study.¹⁶

The results of the 2015 study show significant improvement in tear film break-up time at 28 days after the last treatment with RGN-259. Tear production was also shown to significantly increase at various points throughout treatment—at day 7 ($P = 0.0001$)

and day 21 ($P = 0.0449$)—and continued improvement was observed at a 28-day follow up. None of the patients studied reported any adverse events.¹⁵

10. KPI-121

Kala Pharmaceuticals recently announced results from a Phase II trial of KPI-121, a nanoparticle formulation of loteprednol etabonate that uses the company's mucus-penetrating particle technology. Loteprednol etabonate is an anti-inflammatory corticoid known as the active ingredient in Lotemax (loteprednol, Bausch + Lomb). But that mucus-penetrating particle technology is the star of the show. Mucus-penetrating particles are a variation of nanotechnology. They allow diffusion of small particle size medications to the mucin layer.

As the demographic suffering from dry eye skyrockets over the next decade, new treatments will be crucial for managing this burdensome disease. Clearly, there is a gap between today's needs and effective, broad-based treatments and the gap can be expected to widen without new therapeutic options. ■

Dr. Gaddie is the owner and director at Gaddie Eye Center in Louisville, Ky.

1. Nichols K, Nichols J, Mitchell G. The lack of association between signs and symptoms in patients with dry eye disease. *Cornea*. 2004 Nov;23(8):762-70.
2. The definition and classification of dry eye disease: report of the Definition and Classification Subcommittee of the International Dry Eye Workshop (2007). *Ocul Surf*. 2007 Apr;5(2):75-92.
3. Stevenson W, Chauhan S, Dana R. Dry eye disease: an immune-mediated ocular surface disorder. *Arch Ophthalmol*. 2012 Jan;130(1):90-100.
4. Sheppard J, Torkildsen G, Lonsdale J, et al. Lifitegrast ophthalmic solution 5.0% for treatment of dry eye disease: results of the OPUS-1 phase 3 study. *Ophthalmology*. 2014 Feb;121(2):475-83.
5. Karpecki P, Tauber J, Raychaudhuri A, Semba C. Lifitegrast ophthalmic solution 5.0% vs. placebo for treatment of

- dry eye disease: results of a Phase III, randomized, controlled trial (Opus-2). Paper presented at American Academy of Optometry Meeting 2014, November 13; Denver.
6. Amparo F, Dastjerdi M, Okanobo A. Topical interleukin 1 receptor antagonist for treatment of dry eye disease: a randomized clinical trial. 2013 Jun;131(6):715-23.
 7. Sacchetti M, Lambiase A. Diagnosis and management of neurotrophic keratitis. *Clin Ophthalmol*. 2014;8:571-9.
 8. Lambiase A, Rama P, Bonini S, et al. Topical treatment with nerve growth factor for corneal neurotrophic ulcers. *N Engl J Med* 1998;338:1174-80.
 9. Kashima T, Itakura H, Akiyama H, Kishi S. Rebamipide ophthalmic suspension for the treatment of dry eye syndrome: a critical appraisal. *Clin Ophthalmol*. 2014;8:1003-10.
 10. Liew S, Nichols K, Klamerus K, et al. Tofacitinib (CP-690,550), a janus kinase inhibitor for dry eye disease: results from a Phase 1/2 trial. *Ophthalmology*. 2012;119(7):e43-e50.
 11. Huang J, Yafawi R, Zhang M. Immunomodulatory effect of the topical ophthalmic Janus kinase inhibitor tofacitinib (CP-690,550) in patients with dry eye disease. *Ophthalmology*. 2012 Jul;119(7):e43-50.
 12. Stevenson W, Sadrai Z, Hua J, et al. Effects of topical Janus kinase inhibition on ocular surface inflammation and immunity. *Cornea*. 2014 Feb;33(2):177-83.
 13. Fleischmann R, Kremer J, Cush J, et al. Placebo-controlled trial of tofacitinib monotherapy in rheumatoid arthritis. *N Engl J Med*. 2012 Aug 9;367(6):495-507.
 14. Patane M, Cohen A, From S. Ocular iontophoresis of EGP-437 (dexamethasone phosphate) in dry eye patients: results of a randomized clinical trial. *Clin Ophthalmol*. 2011;5:633-43.
 15. Sosne G, Dunn S, Steven P, Chaesik K. Thymosin β 4 significantly improves signs and symptoms of severe dry eye in a Phase II randomized trial. *Cornea*. 2015 May;34:491-6.
 16. Sosne G, Xu L, Prach L, et al. Thymosin β 4 stimulates laminin-5 production independent of TGF- β . *Exp Cell Res*. 2004;293:175-183.

Is Your Website Stuck in the '90s?



The '90s were great. Funny TV shows and memorable music were created. The World Wide Web, personal computers, email, and cellular phones were introduced. Many people created websites... and some of these websites haven't changed a bit.

**GET
50% OFF
SETUP**



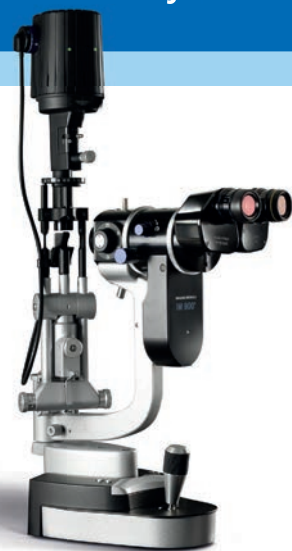If your website is stuck in a past decade, call 855.976.3008 or visit offers.imatrix.com/Stuck-in-the-90s-Half-Off.html to get **50% OFF SETUP** of a website for 2015.



Imaging With Depth-of-field. Just Dandy.

What if none of your slit images or video had blurry edges? You would have a Haag-Streit, of course. Invest in one and submerge yourself into our extreme world of depth of field.

Visit haag-streit-usa.com to learn about our entire range of slit lamps and imaging systems.



800.787.5426
haag-streit-usa.com



© 2015 Haag-Streit USA. All Rights Reserved.

 **HAAG-STREIT**
USA



16th Annual Dry Eye Report

Essential Procedures at the Slit Lamp:

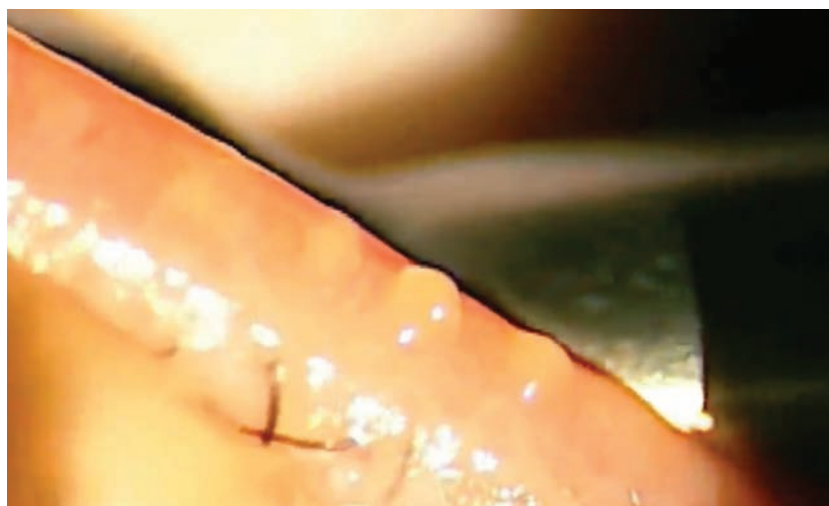How to Impress (and Express) Your Patients

Want to express meibomian glands like a pro? Here's a step-by-step tutorial.

By Jonathan Hatley, OD, and Nathan Lighthizer, OD

You know the situation: It's Friday afternoon with one last exam to do, and you're home free. And then you notice the last patient's chief complaint: dry eye. Does this complaint fill you with dread or make you wish for a four-day work week? Or, does it excite you about the many future appointments you and this patient will share?

If you're like most eye care professionals, you recognize dry eye disease as a challenging problem, not easily fixed with over-the-counter tears at your local big box store. Dry eye disease is also extremely common in our profession. By one estimate, 47% of patients visiting



Because the majority of patients with dry eye have meibomian gland dysfunction, most dry eye patients can benefit from meibomian gland expression.

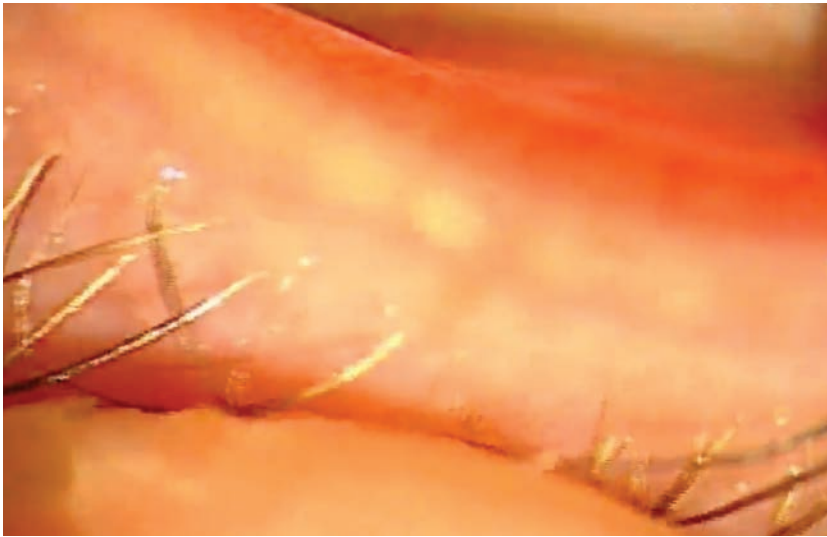an optometrist's office have complaints of dry eye.¹

One of the more prevalent forms of dry eye disease is meibomian gland dysfunction (MGD).² In fact,

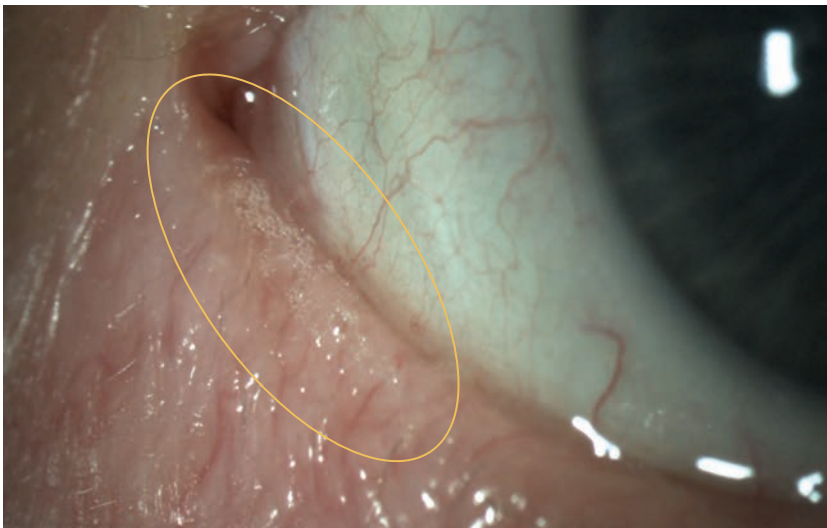
dry eye and MGD are viewed by many experts as essentially synonymous. Although warm compresses, lipid-based artificial tears and oral doxycycline, among others, can



To see a narrated video of this procedure, visit www.reviewofoptometry.com, or scan this QR code.



Meibomian glands that are capped with a white sebaceous material point toward the diagnosis of meibomian gland dysfunction.



Another common sign of meibomian gland dysfunction is frothy or foamy tears in the tear lake or meniscus.

within the glands produce enzymes that aggravate and incite keratinization of the gland epithelium. These enzymes also cause the lipids to be more viscous, which may lead to obstruction. Once the ducts are obstructed, the glands themselves may atrophy.³

Ophthalmic factors that may contribute to increased MGD include anterior blepharitis, *Demodex* infection and contact lens wear. Systemic factors, such as menopause or aging, and medications such as antihistamines, antidepressants, certain acne treatments and postmenopausal hormone therapy also have been shown to play a role in MGD.²

On top of all these factors, the evolution of technology—including smartphones, tablets, computers and video games—may be increasing the prevalence of MGD. Studies show we blink less often and less fully when on the computer, which can lead to MGD.⁴

Who Needs Their Glands Expressed?

The first step is to identify which patients will most benefit from MG expression. In our opinion, nearly all patients who have dry eye symptoms or who are being worked up for dry eye disease could benefit from this easy procedure. Paul Karpecki, OD—who was instrumental in guiding us in setting up our dry eye clinic at the Oklahoma College of Optometry—recommends three items you'll need if you want to get started in managing ocular surface disease and dry eye:

1. A good questionnaire
2. Vital dyes or stains
3. Meibomian gland expression

Most patients who present with MGD complain of dry or gritty eyes that are worse in the morning and may become less noticeable

help, you should also consider meibomian gland (MG) expression as a critical part of your regimen when diagnosing and treating this disease.

Fortunately, expression of the meibomian glands is one of the easiest procedures to perform and can produce lasting, noticeable results. This article—the fifth article in a six-part, print-and-video, instructional series—will show you how it's done.

Understand the Gland

Before you grab your cotton-tip applicators or Mastrotta paddle (Ocusoft), let's discuss the causes of MGD.

The recently-completed International Workshop on Meibomian Gland Dysfunction identified hyperkeratinization of the meibomian gland duct as a primary cause of MGD.³ They found that bacteria located on the lid margin and

Photo: Alan G. Kahar, OD



What we do every day matters.



Avenova™ with Neutrox™ (pure hypochlorous acid) removes microorganisms and debris from the lids and lashes. Avenova is an ideal addition to any daily lid and lash hygiene regimen, including for use by patients with Blepharitis and Dry Eye. Avenova may also be used after make-up removal as well as pre and post contact lens wear.

NovaBay®

Avenova™

Daily lid and lash hygiene.



OPHTHALMOLOGIST AND OPTOMETRIST TESTED | RX ONLY

AVENOVA.COM | 1-800-890-0329

Slit Lamp Essentials

throughout the day.¹ They may also complain of red, inflamed eyes. Fortunately, MGD is fairly easy to diagnose, often requiring only a quick slit lamp exam of the meibomian gland pores and instillation of fluorescein to determine the tear break-up time. Meibomian glands that are capped with a white sebaceous material, a cornea that exhibits a decreased tear break-up time, or both, are common signs pointing toward the diagnosis of MGD.

One of the other common signs of MGD is frothy or foamy tears in the tear lake or meniscus. In our clinical experience, there is nothing else that causes this foam other than MGD. While the exact mechanism that produces frothy tears is unknown, some experts believe that MGD causes the secretion of a foamy, surfactant-like material

rather than healthy meibomian gland oil. Others hypothesize that the frothy presentation results from saponification, where bacterial enzymes react with tear lipids to form a soapy discharge. Regardless, both theories attribute the fundamental cause of frothy or foamy tears to MGD.

Other signs of MGD include increased tear film osmolarity, ocular surface staining, meibum that has a turbid or toothpaste-like consistency, and fluctuating visual acuity.²

Traditionally, MGD was treated with warm compresses, lid scrubs and artificial tears. But a recent report from the International Workshop on Meibomian Gland Dysfunction recommends performing meibomian gland expression at the earliest clinical signs of

MGD.² This critical step will help you understand the severity of the patient's MGD and will guide you in your treatment approach.

Gland Anatomy and Meibum Appearance

Now that you're convinced you should be performing MG expression on your patients, let's talk about where to express the glands—and to do that, we need to review the anatomy.

The meibomian glands are sebaceous or oil-producing glands located in the tarsal plate of the eyelid. The gland lobes or acini are grouped together and are attached to a large central duct that terminates in a pore on the eyelid margin, posterior to the eyelid cilia. These glands receive parasympathetic innervation to make meibum

GET THE 2015 HIRING GUIDE FOR

OPTOMETRY
OPHTHALMOLOGY
OPTICAL

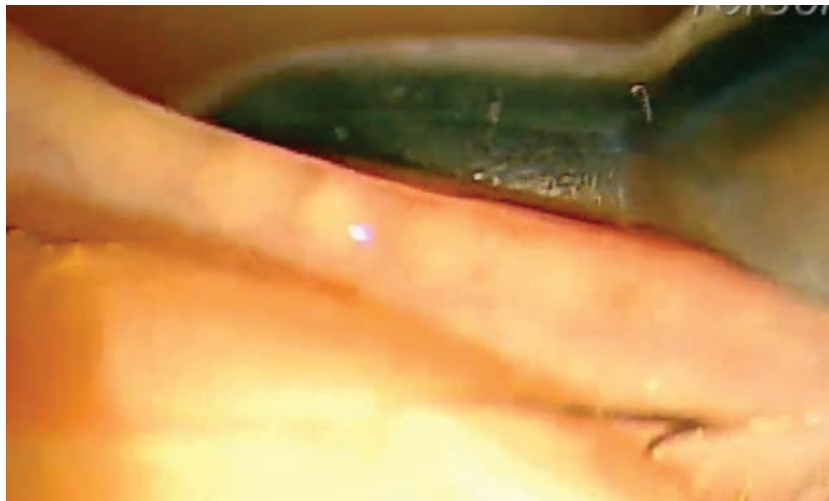Download Your
Free Hiring Guide Online at
localeyesite.com/guide

 Local Eye Site
JOBS IN EYE CARE

and, under normal circumstances, eyelid contraction aids in secretion and distribution of the meibum across the surface of the eye.⁵ This simple fact helps to explain why today's technology could be contributing to MGD because we not only blink less often but also less fully when viewing phones, computers or tablets.⁴

Meibum comprises the most anterior aspect of the tear film and stabilizes the tear film by preventing evaporation of the aqueous layer. Under healthy conditions, meibum consistency is similar to olive oil or baby oil in color and viscosity.

If it's turbid or cloudy in color, that's an early sign of MGD. If it becomes cheesy or toothpaste-like in texture, that is an indication of more advanced MGD. Severely plugged, non-functioning or atro-



Healthy meibomian glands produce meibum that appears like olive oil or baby oil. But the cloudy meibum seen here is an early sign of MGD.

phic glands are the most advanced signs of MGD. In these cases, pushing on the glands reveals no expression.³

Types of MG Expression

Meibomian gland expression can be divided into two groups: *diagnostic* and *therapeutic*.



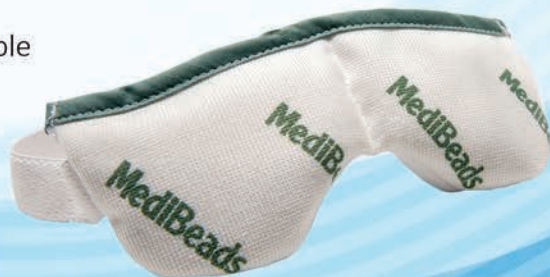Bruder®

OPHTHALMIC PRODUCTS

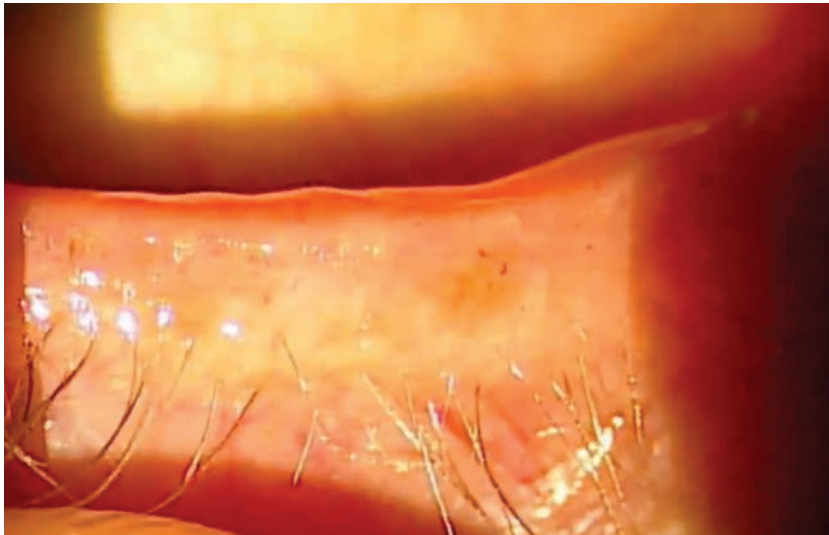DRY EYE SYNDROME IS A PROBLEM.
WE HAVE A **SIMPLE & NATURAL** SOLUTION.

The Bruder Eye Hydrating Compress is the new and natural way to treat the MGD associated with dry eye. After just seconds in the microwave, this patented compress delivers a deeply penetrating moist heat treatment in the prescribed temperature range. Because there is no need to ever add water, no waiting and no mess ... it is easy for patients to comply with instructions for daily use.

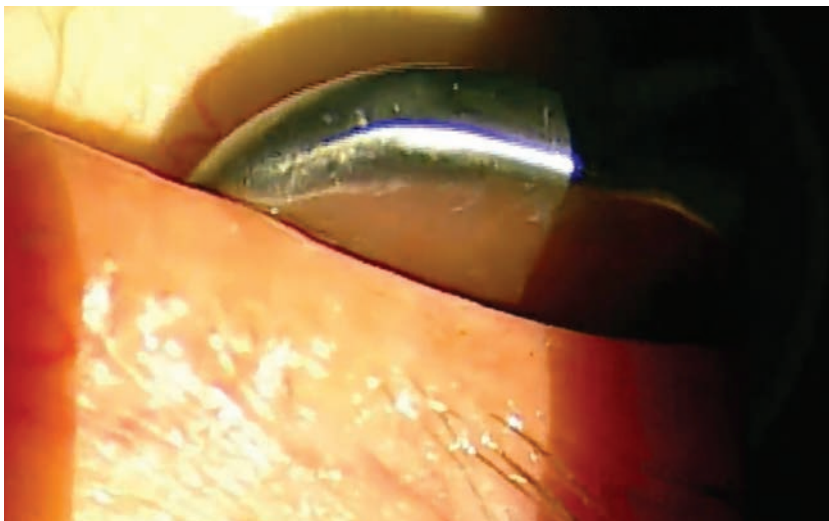
To try the Bruder Compress, request a sample at eyes@bruderophthalmic.com or call 888-827-8337 x218.



www.bruderophthalmic.com



To express the inferior meibomian glands, pull the nasal aspect of the lower lid inferiorly to expose the meibomian gland pores and palpebral conjunctiva.



Apply the expressor paddle (or cotton-tip applicator) to the palpebral conjunctiva at a point midway between the fornix and the lashes.

• *Diagnostic expression* is generally performed before therapeutic expression and is used to determine if the patient has MGD and, more specifically, to determine the stage of severity. It requires only a finger or cotton-tip applicator pressed and held against the inferior eyelid adnexa for approximately five to 15 seconds. In your busy practice, expressing lateral, central and medial aspects of all four eyelids

may seem time-consuming and daunting. Fear not, as clinical experience shows it's the central to nasal inferior lids that are the most important to express to get an idea of the severity of the patient's MGD.² A larger tool such as a Mastrota paddle also helps increase efficiency.

After a few seconds, you should see meibum excreting from the glands. Oil that is clear with little

color indicates healthy meibomian glands. Thick or discolored meibum indicates MGD and proceeding with therapeutic expression is probably a viable treatment option. However, if no meibum is excreted and the pores are clear, the glands may have atrophied. In this case, therapeutic expression produces little, if any, results.

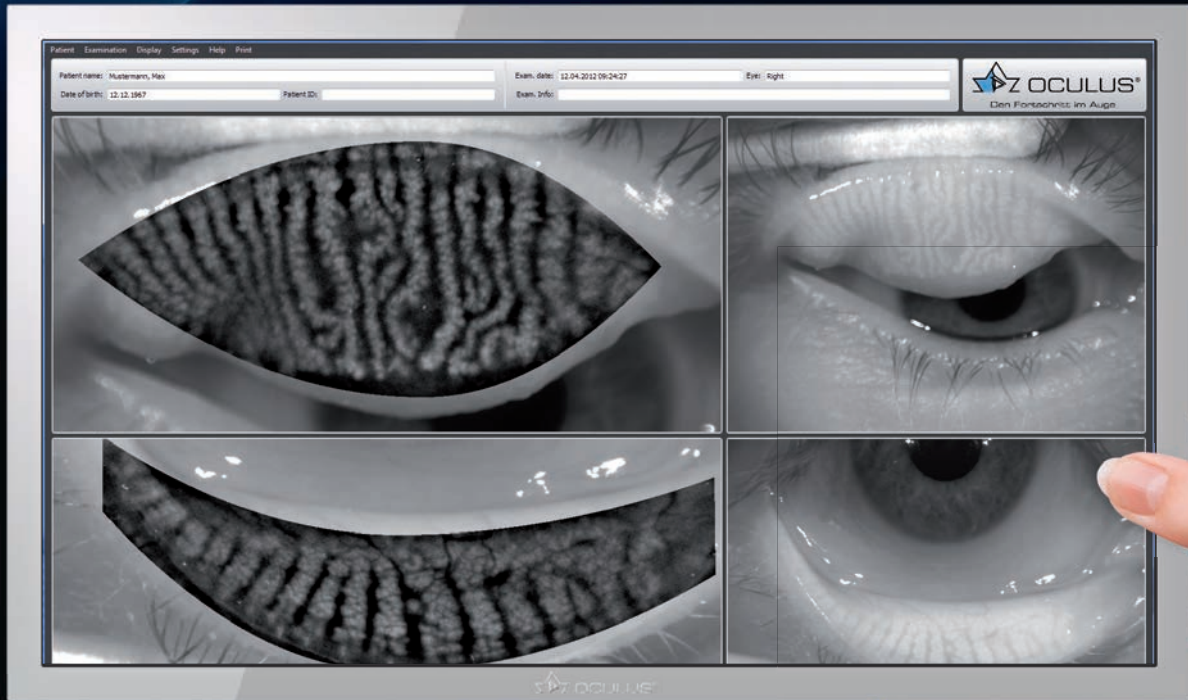• *Therapeutic expression* is a more complete expression of the glands and can increase quality meibum production and decrease dry eye symptoms. While similar to diagnostic expression, therapeutic expression is more thorough and performed to promote healthy meibum production. The steps for proper therapeutic gland expression are outlined below.

Equipment

Meibomian gland expression requires few specialized tools. Positive results can be had with just a cotton-tip applicator and your finger. However, we recommend at least one Mastrota paddle or similar expressor paddle for more complete gland expression and enhanced patient comfort. Or, use two expressor paddles—one inside the lid and one outside the lid.

Besides the Mastrota paddle, other instruments are available for MG expression. The MG Expressor Kit (Gulden Ophthalmics) uses a flat paddle and a small roller to express the glands. The Arita MG Expressor (OcuSci), Collins Expressor Forceps (Bruder) and Maskin Meibum Expressor (Rhein Medical) are all types of forceps expressors that allow for one-handed use. The Thermal Pulsation System (Lipiflow) applies both heat and gentle pressure to express the meibomian glands. Finally, intense pulsed light (IPL) therapy, while not solely for meibomian gland

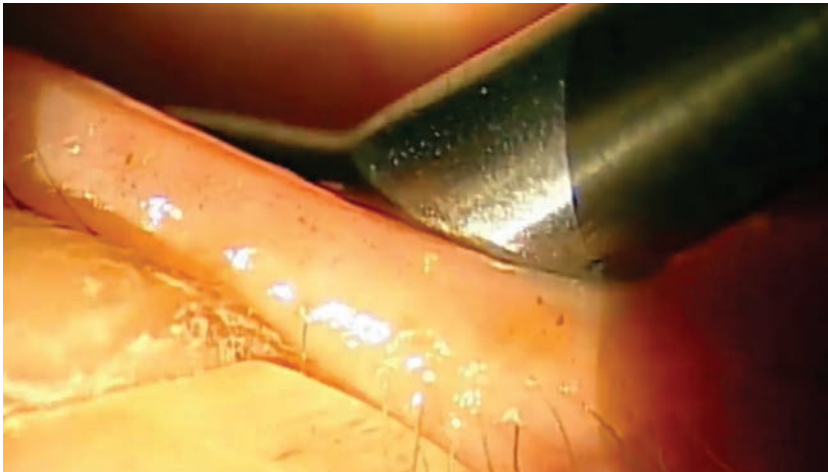OCULUS Keratograph® 5M



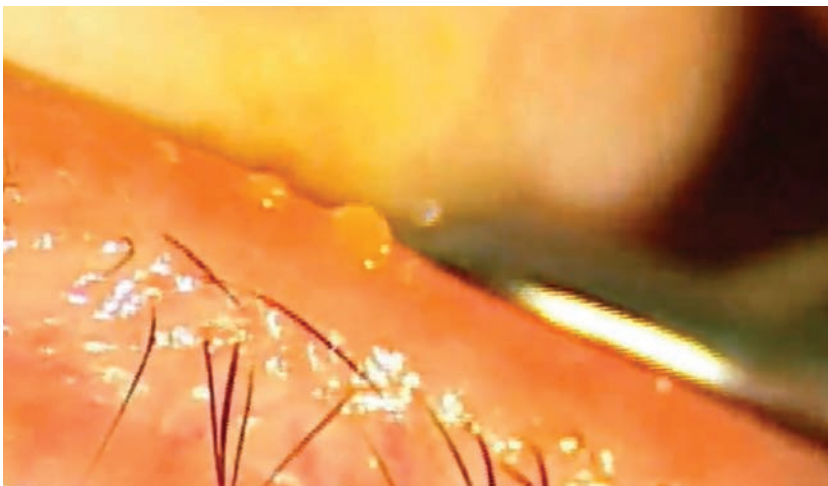Topography and advanced external imaging for dry eye screening



- High-resolution color camera
- Imaging of the upper and lower meibomian glands
- Non-invasive tear film break-up time and tear meniscus height measurements
- Assessment of the lipid layer and tear film particles



When you apply pressure to the inferior eyelid adnexa, meibum should soon emerge. However, if no meibum is excreted and the pores are clear, as shown here, the glands may have atrophied.



The thicker the meibum, the more advanced the MGD. This sludgy excretion indicates the meibomian glands are losing function.

expression, uses a specific wavelength of light to heat the blood vessels around the meibomian glands and liquefy the stagnant meibum. IPL is not new in the beauty/cosmetology industry, but recent ocular studies have found it to be effective for treating MGD and ocular rosacea.⁶

While magnification is necessary to diagnose MGD, you may find that performing gland expression outside of the slit lamp provides greater freedom of movement.

Set Up

Begin by instilling a drop of topical anesthetic, such as proparacaine, into both eyes. This is not usually needed for quick diagnostic expression, but it may be warranted, depending on the patient, for more extensive therapeutic expression.

Consider applying hot compresses for approximately 10 minutes prior to therapeutic expression. The heat softens or liquefies meibum, which improves the effectiveness of expression. Many types

of heating masks are available, but we recommend the Bruder mask because it retains heat for 10 to 15 minutes.

To prevent corneal abrasions, have the patient look up for lower lid expression and down for upper lid expression.

How to Perform MG Expression

To express the inferior meibomian glands:

- Starting on the nasal aspect of the lower lid, pull the lid inferiorly to expose the meibomian gland pores and palpebral conjunctiva.
- Apply the expressor paddle or cotton-tip applicator (pre-moistened with saline) to the palpebral conjunctiva at a point midway between the fornix and the lashes.
- Release the lid and apply pressure to the inferior eyelid adnexa with a second cotton-tip applicator or expressor paddle.
- Roll the cotton-tip applicator or rock the paddle from the base of the meibomian glands to the pores on the eyelid margin.
- Pull the lower lid inferiorly and move the cotton-tip applicator or paddle to the next section of meibomian glands to be expressed.
- Follow the same maneuver for the remaining inferior meibomian glands.

To express the superior meibomian glands:

- With the patient looking down, lift the upper lid slightly off the globe.
- Insert the cotton-tip applicator or paddle under the lid, approximately midway between the superior fornix and lashes.
- Roll the cotton-tip applicator or rock the paddle inferiorly to express the glands.
- Repeat this process for the remaining superior glands.

EyeRes

Digital Imaging

*Hardware
&
Software
for slit lamps.*

EyeRes

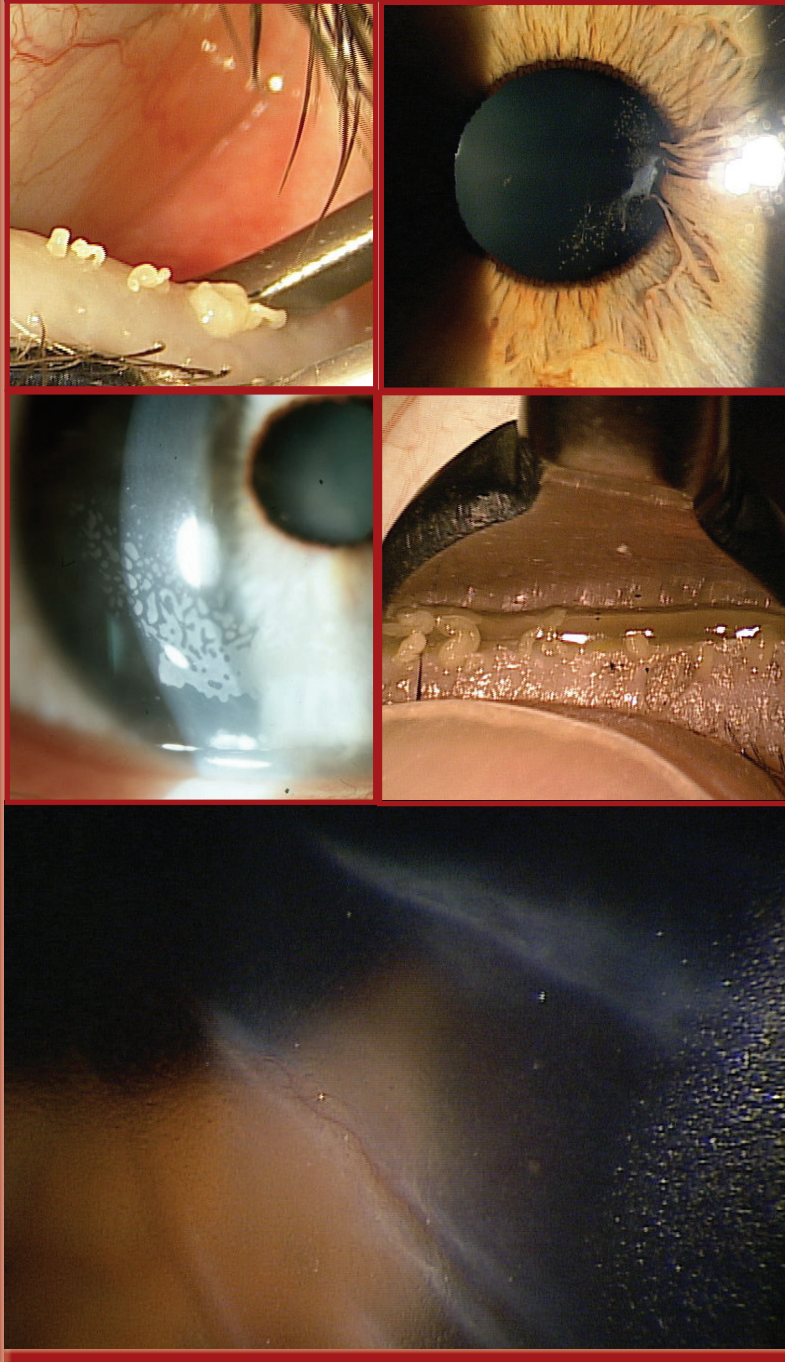


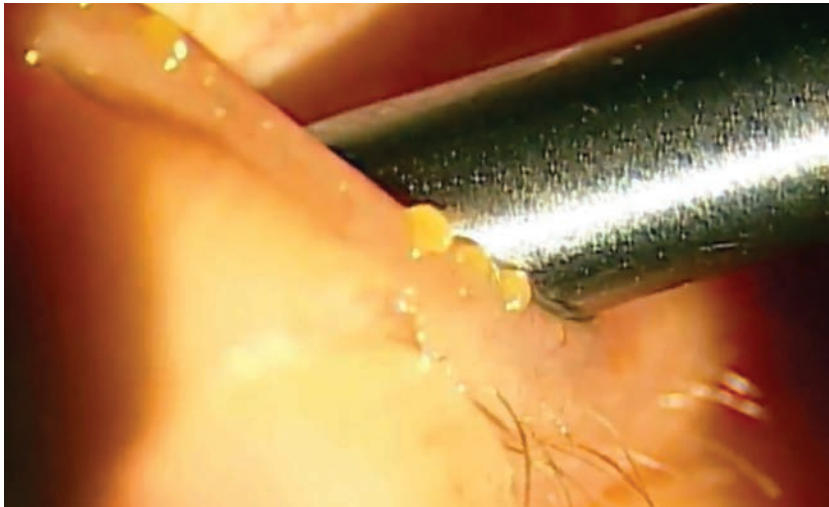*“Educate Patients,
Change Behaviors!”*

TelScreen

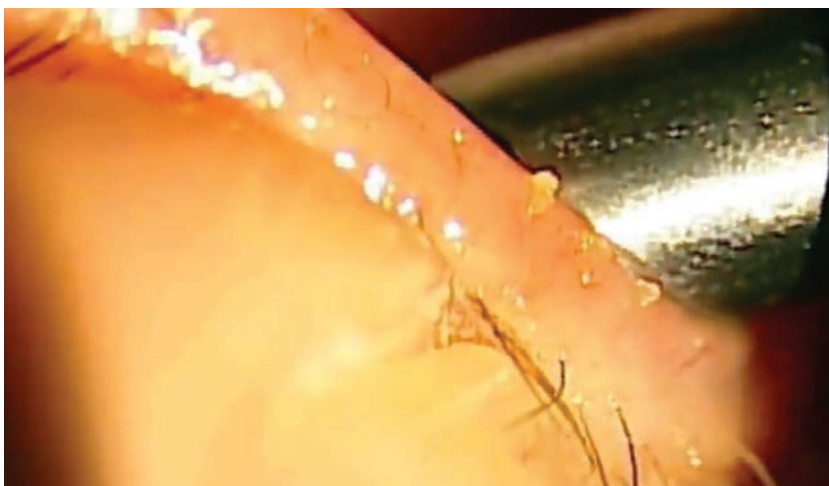
email: DryEye@TelScreen.com

www.TelScreen.com





This thick meibum has a goeey, cheesy consistency, indicating more advanced MGD.



This very thick meibum was difficult to express and secreted from the glands with a dense, waxy consistency.

After the Procedure

Consider instilling one to two drops of artificial tears per eye in the office immediately after expression. Prescribe your patient an artificial tear gel for use at home after MG expression. This provides some relief to the irritated palpebral conjunctiva.

After diagnostic or therapeutic meibomian gland expression has taken place in office, explain to the patient that long-term management of the MGD needs to be undertaken, as a one-time expression of

the glands will not be a permanent cure. Strongly consider the following options in the long-term management of MGD:

1. Bruder mask or some type of warm compress mask that retains heat for 10 to 15 minutes, performed one to two times per day to continue evacuation of viscous meibum from the glands. In our clinical experience, patients note significant improvement with long-term use of these masks.

2. Recommend lipid-based tears such as Systane Balance (Alcon),

Refresh Optive Advanced (Allergan), Retaine MGD (Ocusoft), or Soothe XP (Bausch + Lomb) to supplement the tear film and meibomian gland secretions.

3. Prescribe short-term steroid therapy in patients who exhibit signs and symptoms of posterior blepharitis (often caused by MGD).⁷ In our clinical experience, overnight use of Lotemax ointment (loteprednol 0.5%, Bausch + Lomb) or FML ointment (fluorometholone alcohol 0.1%, Allergan) has shown significant improvement in patient symptoms when used over the course of two to four weeks.

4. Prescribe tetracyclines to inhibit inflammation and stabilize the lipid layer of the tear film by decreasing free fatty acids. The International Workshop on Meibomian Gland Dysfunction recommends tetracyclines at all but the mildest stage of MGD.⁸

We typically use doxycycline 50mg BID for one to two months, then QD for one to two months. However, emerging research has shown that a short, five-day treatment of oral azithromycin may be more effective than doxycycline at treating MGD.⁹

5. Recommend an omega-3 fatty acid supplement to provide proper nutrition for meibum production. (Note: the American Heart Association recommends no more than 3g of omega fatty acids per day.)

Another supplement containing eicosapentaenoic acid (EPA), docosahexaenoic acid (DHA) and gamma linolenic acid (GLA) has been studied specifically for meibomian gland dysfunction and was shown to significantly improve signs and symptoms in MGD patients.¹⁰

Meibomian gland expression is both an easy and highly effective

procedure for reducing symptoms and improving signs in MGD. Because MGD represents a significant portion of dry eye disease, proper management and treatment are essential for improving your patient's ocular health.

With a little practice, you can put your patients on the road to producing viable meibum, increase their ocular comfort, and reduce your own dread of seeing another chief complaint of dry eyes. ■

Dr. Hatley is a clinical assistant professor at the Oklahoma College of Optometry and practices at the Cherokee Nation AMO Health Center in Salina, Okla.

Dr. Lighthizer is the assistant dean for clinical care services, director of continuing education, and chief of both the specialty care clinic and the electrodiagnostics clinic at the Oklahoma College of Optometry.

1. Fahmy A, Hauswirth SG, Hardten DR. Treatments for meibomian gland dysfunction. *Ophthalmol Management*. 2012;16(9):25-6.
2. Nichols KK, Foulks GN, Bron AJ, et al. The International Workshop on Meibomian Gland Dysfunction: Executive Summary. *Invest Ophthalmol Vis Sci*. 2011 Mar 30;52(4):1922-9.
3. Knop E, Knop N, Millar T, et al. The International Workshop on Meibomian Gland Dysfunction: Report of the subcommittee on anatomy, physiology, and pathophysiology of the meibomian gland. *Invest Ophthalmol Vis Sci*. 2011 Mar 30;52(4):1938-78.
4. Patel S, Henderson R, Bradley L, et al. Effect of visual display unit use on blink rate and tear stability. *Optom Vis Sci*. 1991 Nov;68(11):888-92.
5. Remington LA. *Clinical Anatomy of the Visual System*. 2nd ed. St. Louis, MO: Elsevier; 2005.
6. Toyos R, McGill W, Briscoe D. Intense pulsed light treatment for dry eye disease due to meibomian gland dysfunction; a 3-year retrospective study. *Photomed Laser Surg*. 2015 Jan;33(1):41-6.
7. Nelson JD, Shimazaki J, et al. The International Workshop on Meibomian Gland Dysfunction: Report of the Definition and Classification Subcommittee. *Invest Ophthalmol Vis Sci*. 2011 Mar 30;52(4):1930-37.
8. Geerling G, Tauber J, Baudouin C, et al. The International Workshop on Meibomian Gland Dysfunction: Report of the Subcommittee on Management and Treatment of Meibomian Gland Dysfunction. *Invest Ophthalmol Vis Sci*. 2011 Mar 30;52(4):2050-64.
9. Kashkoui MB, Fazel AJ, Kivavash V, et al. Oral azithromycin versus doxycycline in meibomian gland dysfunction: a randomized double-masked open-label clinical trial. *Br J Ophthalmol*. 2015 Feb; 99(2):199-204.
10. Sheppard J, Pflugfelder S. Long-term supplementation with n-6 and n-3 PUFAs improves moderate-to-severe keratoconjunctivitis sicca: a randomized double-blind clinical trial. *Cornea*. 2013 Oct;32(10):1297-1304.

It's all about
comfort.



Effective dry eye treatment meets
unprecedented comfort in the **VeraPlug**.
Your patients won't feel anything but relief.

Visit lacrivera.com/challenge for your free sample

A FRESH PERSPECTIVE™


LACRIVERA

lacrivera.com (855) 857-0518

2500 Sandersville Rd • Lexington KY 40511 USA

© 2015 Lacrivera, a division of Stephens Instruments. All rights reserved.



Go Further—Without Leaving Home



Expand your clinical skills and catch up on your CE requirements, all from the comfort of your own home.

Review offers **nearly 100 hours** of COPE-approved continuing education — right now! It's **just a click away**. Our extensive library of exams runs the gamut from keratoconus to fundus autofluorescence, and everything in between.



www.reviewofoptometry.com/continuing_education

Download a QR scanner app. Launch app and hold your mobile device over the code to view www.reviewofoptometry.com/continuing_education.

REVIEW[®]
OF OPTOMETRY

2 CE
Credits
(COPE approval pending)



Recognize Distinctions in Women's Eye Health

Some issues, both ocular and systemic, have a greater impact on women than men. Learn to identify when the difference can affect how you practice.

By Jill Autry, OD, RPh, Diana Shechtman, OD, Susan A. Cotter, OD, and Louise Sclafani, OD

Women often have different medical needs than men, even in eye care. Skeptics may insist women's and men's eyes are essentially the same biological structure, but what they're not taking into account are the experiences that impact women's eyes. For example, pregnancy affects the types of medications women can take. Certain ophthalmic medications are also contraindicated for use with diseases that affect more women than men. In addition, research shows women with noticeable ocular

conditions such as strabismus face greater workplace challenges than their "straight-eyed" colleagues. Eye makeup also puts women's eyes in harm's way.

This article reviews, in four parts, the ocular health challenges women face and how eye care professionals can take these distinctions into account.

Prescription Challenges Eye Drying Drugs

Certain medications with known ocular side effects are more commonly prescribed to women. For

example, women are twice as likely to develop dry eye—one of the most common ocular conditions—and female patients are more likely to be taking medications that can exacerbate underlying dry eye.^{1,2}

Exogenous hormones, once thought to decrease the risk of eye dryness in women, have instead been found to contribute to the development of dry eye and to increase the severity of associated signs and symptoms.³ Hormone replacement therapies such as Premarin (estrogen, Pfizer) for the perimenopausal woman, as well as birth control pills

Release Date: May 2015

Expiration Date: May 1, 2018

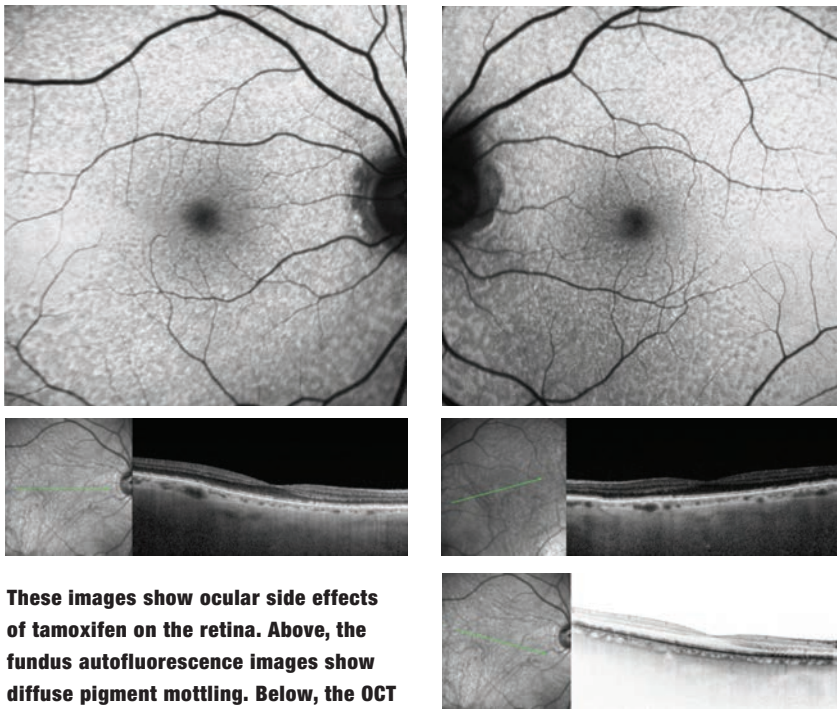
Goal Statement: Since female patients are at a greater risk for some conditions relevant to visual health, optometrists should consider gender in diagnosis and treatment. This article reviews ocular concerns for common systemic pharmaceuticals, Plaquenil-related macular toxicity, psychosocial issues and management options for strabismus, and the impact of cosmetics on ocular surface disease and lid hygiene.

Faculty/Editorial Board: Jill Autry, OD, RPh, Diana Shechtman, OD, Susan A. Cotter, OD, and Louise Sclafani, OD

Credit Statement: COPE approval for 2 hours of CE credit is pending for this course. Check with your local state licensing board to see if this counts toward your CE requirement for relicensure.

Joint-Sponsorship Statement: This continuing education course is joint-sponsored by the Pennsylvania College of Optometry.

Disclosure Statement: Dr. Autry is a consultant and speaker for Allergan. Dr. Sclafani has served as a consultant for Alcon, Abbott Medical Optics, Bausch + Lomb, Allergan, Coopervision and Vistakon. Her husband is an employee of Optos, North America. Drs. Cotter and Shechtman have no relationships to disclose.



These images show ocular side effects of tamoxifen on the retina. Above, the fundus autofluorescence images show diffuse pigment mottling. Below, the OCT images show alteration of the retinal pigment epithelium with multiple parafoveal deposits at the level of the retinal pigment epithelium.

for childbearing-age patients, have been shown to worsen dry eye, often pushing asymptomatic patients into symptomatic disease.³⁻⁵

Women take antidepressants, known for their anticholinergic drying effects, at a rate of more than twice that of men, investigators say.^{1,6} In fact, 23% of women in their 40s and 50s take these medications at a time when they are most susceptible to the development of ocular surface disease.^{1,6}

When possible, and only after discussion with the prescribing physician, medications known to cause or worsen dry eye may be lowered, eliminated or substituted.

Topamax

Outside of dry eye, women use other medications that can have severe ocular side effects. For example, Topamax (topiramate, Janssen Pharmaceuticals), was originally

approved for partial or primary tonic-clonic seizures. Although this type of epilepsy is not specific to women, additional approved (migraine) and off-label (weight loss, depression) indications have increased the use of this medication in the female population. Topamax is also used to lower intracranial pressure in patients with idiopathic intracranial hypertension or pseudotumor cerebri, a condition seen more frequently in women who are young and overweight.

In the eye, Topamax is associated with acute myopia and non-pupillary block, secondary angle closure.⁷ The mechanism is related to Topamax's sulfonamide chemical structure, which has been known to create supraciliary effusions resulting in zonular relaxation, anterior displacement of the iris and lens, a myopic shift of up to 10D and a non-pupillary block angle closure.^{8,9} The syndrome occurs most likely within the first month of initiation of topiramate; the myopic shift precedes the increased intraocular pres-

sure (IOP) and it has been reported in hyperopes, myopes and even pseudophakes.^{10,11}

Initial treatment requires prompt recognition of the syndrome, hopefully after myopia presents, but before the IOP elevates. Then, cessation of the medication can halt the secondary angle closure complications. In patients presenting with a myopic shift, elevated IOP and a shallow anterior chamber, topical atropine (to tighten the zonules and deepen the anterior chamber) and anti-glaucoma agents (to decrease IOP) should be started and Topamax should be discontinued. A peripheral iridotomy (PI) is not indicated in this situation because the angle closure is not due to pupillary block but to ciliochoroidal effusion.

More recently, Topamax was implicated in the development of homonymous visual field defects unrelated to the angle closure syndrome.¹³ The mechanism of action is not well understood, but case reports suggest a depression in retinal function.¹³ The defects tend to develop after two to three months of topiramate use and seem to be partially or completely reversible upon discontinuation of the drug.¹²

Tamoxifen

Tamoxifen is used predominantly in women for the treatment or prevention of breast and ovarian cancers, and may cause ocular side effects.¹⁴ Although a rare complication, this medication has been associated with a crystalline maculopathy and associated cystoid macular edema with higher dosages.¹⁴ Patients generally use tamoxifen for a five-year treatment period and should have annual dilated fundus exams and optical coherence tomography (OCT).

Gilenya

Women are approximately three times more likely to develop mul-

tiple sclerosis (MS) than men.¹⁵ Gilenya (fingolimod, Novartis), one of the new oral medications for the treatment of MS, is linked to the development of macular edema.¹⁶ The incidence is only 0.4% of patients, unless the patient has had previous episodes of uveitis, which can increase the risk to 20%.¹⁶ Baseline OCT examination and a repeat exam three to four months later is recommended.

Medications and Pregnancy

Not only does sex play a role in susceptibility, but it also can alter treatment decisions in women of childbearing age, or those who are pregnant or nursing. Treating the pregnant patient always requires an increased level of caution. For most optometric conditions, however, a variety of medications approved by the obstetric community exist.

For oral antibiotics, Augmentin (amoxicillin/clavulanate potassium, Dr. Reddy's Laboratories), erythromycin, azithromycin and amoxicillin are used routinely during pregnancy.^{17,18} All of these choices provide the gram-positive coverage we generally seek in treating ocular infections. The use of topical fluoroquinolones during pregnancy has not been well studied. As in children, avoid the tetracycline and ciprofloxacin derivatives when treating pregnant patients to prevent pneumococcal resistance.^{19,20} While undisputed in terms of efficacy for corneal ulcers the benefits of use must be weighed against the risk.

Acetaminophen with codeine is also routinely used short-term for painful conditions, such as corneal abrasions, although prolonged and heavy use has been shown to affect the fetus.²¹

In treating glaucoma during pregnancy, oral carbonic anhydrase inhibitors (CAIs), such as Diamox (acetazolamide, Lederle), are con-

traindicated. Although adverse effects on the fetus are unproven, try to avoid topical CAIs—Trusopt (dorzolamide, Merck) and Azopt (brinzolamide, Alcon)—and the prostaglandins—Xalatan (latanoprost, Pfizer), Lumigan (bimatoprost, Allergan) and Travatan (travoprost, Alcon).

Non-topical treatment options include beta-blockers, such as labetalol used orally during pregnancy for the treatment of hypertension, or Alphagan (brimonidine, Allergan), which is the only topical hypotensive agent with the more preferable Category B pregnancy rating. Also, consider surgical options such as trabeculectomy or selective laser trabeculoplasty.

Sometimes the best treatment is no treatment. Many eye care providers and their patients choose close observation without drug therapy because IOP is naturally lower during pregnancy.^{25,26}

As always, carefully weigh the benefit of treatment for any condition in a pregnant patient against the possible risks to the developing fetus.

Plaquenil Toxicity Update Autoimmune Diseases

Out of the 50 million Americans diagnosed with an autoimmune disease, more than 75% are women.²⁷ Plaquenil (hydroxychloroquine, Covis Pharmaceuticals) is a disease-modifying antirheumatic drug commonly used to treat autoimmune conditions such as systemic lupus erythematosus, Sjögren's syndrome and rheumatoid arthritis. Although the drug is effective and systemically safe, continuous use may lead to irreversible damage and potential blindness due to macular toxicity.²⁷⁻²⁹

Macular Findings

The associated classic macular finding is described as a bull's eye

maculopathy—a ring of retinal pigment epithelium (RPE) depigmentation, sparing the central fovea. The correlated OCT shows a complete loss of the photoreceptor integrity line, including the subfoveal area. This often correlates with significant vision loss.

The initial stage of Plaquenil toxicity does not show any apparent maculopathy. The moderate stage of the disease may only show subtle macular mottling, which may be overlooked. Central visual acuity is unaffected until the late stage of the disease, although paracentral scotomas may be present. Over time, the scotomas involve the foveal area, resulting in deterioration of central vision. Vision loss is likely permanent and may progress years after drug cessation.³⁰

The American Academy of Ophthalmology revised ocular examination guidelines for screening patients on Plaquenil therapy in 2011. A dilated fundus examination is critical to detect and document established retinal disease (including macular health integrity); however, it should not be used alone. Although fundus photography can be used for baseline documentation of any retinal/maculopathy disease, it is not sensitive enough to identify early findings associated with Plaquenil toxicity. Although a baseline photograph can be considered, it cannot be used as a screening marker.³¹

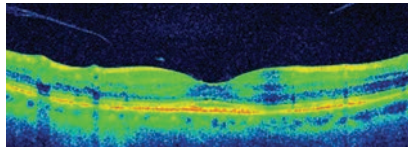
Diagnostic Modalities

Various diagnostic modalities increase the likelihood of early detection of Plaquenil toxicity. However, color vision defects are not pathognomonic to Plaquenil-related macular toxicity and are often observed in a number of macular and optic nerve diseases. Additionally, Amsler grid has shown lack of sensitivity in picking up early macular defects. Due to the disagreement

of specificity and sensitivity of these two tests, both may be considered as adjunct to the examinations but are no longer recommended for screening. The 10-2 visual field test continues to be recommended as a functional assessment of macular damage, but only a white stimulus should be used.

More recent diagnostic modalities can objectively document structural and functional changes for the assessment of early Plaquenil-related macular damage. When available, routine testing should include one of the following: spectral domain optical coherence tomography (SD-OCT), mfERG or fundus autofluorescence (FAF). SD-OCT is likely the most common test, given the fact that it is readily available. Early Plaquenil-related macular toxicity is often described as localized parafoveal thinning associated with disruption of the IS/OS line. This is further described as the “flying saucer” or “sinkhole” sign.³² In regard to FAF, damage associated with localized areas of RPE defects is characterized as a reduction of autofluorescence. Earlier photoreceptor damage is linked to a pericentral ring of autofluorescence. Finally, mfERG can serve as a sensitive objective test of functional damage, which correlates well with paracentral 10-2 visual field defects. Moreover, patients may differ in apparent sensitivity for various tests; therefore, careful screening with multiple tests may be warranted.

Baseline testing should be initiated within the first year of starting the medication to establish any pre-existing retinal/macular condition and document pre-existing structural or functional damage, or both. Baseline data may also uncover high-risk patients, as certain risk factors may promote the development of related macular toxicity. Because both the kidneys and liver clear the



SD-OCT of the photoreceptor integrity line showing small disruption.

drug, caution needs to be taken in patients with renal or hepatic disease. In addition, toxic maculopathy has been reported to be dose dependent, with increased risk of toxicity associated with dosages over the standard (200mg/400mg), as well as longer-term use. Other risk factors include advanced age and pre-existing retinal/macular disease, short status and high body mass index (BMI). Patients with any of the aforementioned findings are considered high risk and should be monitored closely.

Published Research

A sharp increase in the prevalence of Plaquenil toxicity is noted following five to seven years of medication use. Recent literature emphasizes the risk of cumulative dosing occurring when a dosage reaches 1,000g. Therefore, a high-risk patient should be evaluated at baseline and annually thereafter. On the other hand, annual screening is recommended only after five years for any non-high-risk patients.³³

Previous incidence of Plaquenil-related macular toxicity was reported to be about 1% with standard dosage of 200mg to 400mg per day. Recent literature, however, has reported an increase associated with long-term use.³⁴ A 2014 study reported a 7.5% prevalence of Plaquenil toxicity using some of today's objective testing standards (FAF< SDOCT, 10-2 VF).³⁵ Factors such as higher dosage, longer duration and kidney dysfunction likely contribute to the increased prevalence reported in this study.³⁵

Current reports also established continuous damage even after drug cessation. In 2014, a study reported characteristic progressive findings, correlating to the stage of macular toxicity among patients who discontinue the drug one to three years prior.³⁰

Mild progressive SD-OCT foveal thinning was associated with the mild to moderate stage of the disease. The more severe stage of macular toxicity displayed a loss of the ellipsoid zone line, averaging to 100µm/year.

Many women are at risk for permanent vision loss due to the prevalence of autoimmune diseases, which may necessitate the use of Plaquenil. For this reason, carefully evaluate and monitor these patients for the early findings associated with macular toxicity.

Strabismus and Social Prejudice Stars and Their Eyes

Strabismus is often thought of as a childhood disorder, but with an estimated prevalence of 4% in the United States, adult strabismus is fairly common.³⁶ Adult strabismus can result from an uncorrected or incompletely corrected childhood strabismus or it can present during adulthood in a person with previously normal binocular vision.

Purportedly, celebrities Kate Moss, Heidi Klum, Kesha and Kristen Bell all have strabismus. Their ocular misalignment (likely intermittent exotropia), however, has certainly not been an impediment to their successful careers and celebrity status. In fact, Kristen Bell generated a lot of laughs on the “Late Late Show with Craig Ferguson,” explaining that when filming late at night, she has the cameramen alert her when her “wonky eye” starts to drift out by yelling “wonky wonky.”³⁷

Sequelae

Life is not always so easy for strabismic adults who are not well-known celebrities, and they report a spectrum of concerns related to their strabismus.

Common problems related to function include diplopia, blur, asthenopia and stereopsis issues.

In addition, concerns regarding physical appearance, either the conspicuousness of the eye turn itself or an associated anomalous head position in cases of noncomitant strabismus, are common.

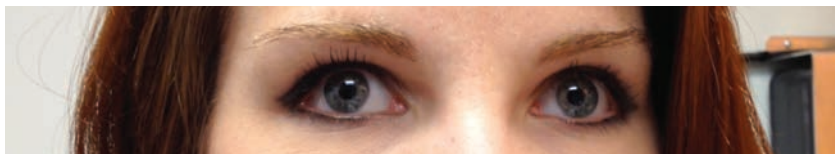
Quality of Life

As eye care providers, our main concerns regarding strabismus often center on function and loss of binocularity; however, cosmetic appearance is often the primary worry of our patients. Even the most empathetic of clinicians don't always appreciate the psychosocial implications of a cosmetically noticeable strabismus on a person's life. In fact, eye care providers typically underestimate the impact of ocular disorders on a person's quality of life.³⁸

Strabismus is often more than a trivial problem. Adults with strabismus have poorer health-related quality of life than visually normal adults.^{39,40} Many report a history of difficulty with interpersonal relationships, school, work and sports.⁴¹

Cosmetically visible strabismus can cause a host of psychosocial issues including poor self-esteem, low self-confidence and negative self-image.⁴¹⁻⁴³ Adults with strabismus are reported to experience increased rates of social phobia and social anxiety as well as higher levels of anxiety and depression.⁴⁴

A visible strabismus is even reported to make it more difficult to find a partner and to limit employment opportunities and career advancement. When shown digitally altered photographs of persons



Although this strabismus patient is an optometry student, many women with the condition face discrimination in the job market.

with seven facial disfigurements, the majority of dating agency personnel felt that the presence of a strabismus would make it more difficult to find a partner.⁴⁵

Economic Impact

Difficulties with social functioning are not the only problems experienced by persons with strabismus. There appears to be negative social prejudice toward those with cosmetically noticeable strabismus. In one study, judgments were made on personality characteristics from viewing photographs of the same person with straight eyes and with an esotropia or exotropia. Overall, the strabismic faces were viewed more negatively in terms of intelligence and communication skills.⁴⁶ Those with esotropia were deemed to be less successful and less competent and to have worse emotional stability and leadership ability.

Research also shows vocational consequences may be associated with strabismus. One study found that women with large-angle horizontal strabismus were ranked lower in terms of hiring preference for a marketing manager position than straight-eyed controls with equal qualifications, albeit the presence of strabismus did not influence the ranking of the male applicants.⁴⁷

Another study reported that 72.5% of job recruiters judged strabismic persons to be perceived less favorably by potential employers, suggesting that people with strabismus would have more difficulty in obtaining a job than their straight-eyed peers.⁴⁵

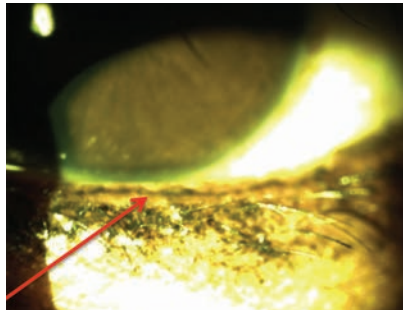
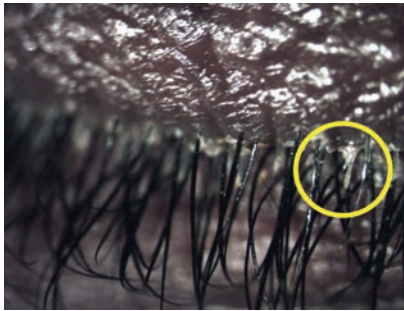
One of the criteria used for the United States Army system of promotion is an evaluation of a standard military photograph to assess the appropriate wear of the uniform and military bearing. When military officers ranked official photographs of women and men in uniform with the rank of captain, those with digitally altered eye alignment that made them esotropic were rated less favorably than their straight-eyed colleagues.⁴⁸

Overall, women were rated more negatively than men, so it was a double burden for a woman who had an esotropia.

Optometry's Job

Nearly all optometrists see women with strabismus and should be cognizant that socially apparent strabismus is a significant issue. Clinicians may want to use the recently introduced Adult Strabismus (AS-20) questionnaire, a validated tool that can be used to quantitatively assess health-related quality of life in adults with strabismus. It's available free of charge on the Pediatric Eye Disease Investigator Group (PEDIG) website at publicfiles.jaeb.org/pedig/Misc/AS-20%20Questionnaire.pdf.^{39, 40, 49-51}

It is important that adult patients with strabismus receive a comprehensive eye examination, including a cycloplegic refraction for those with esotropia who are not true presbyopes. For patients with recent-onset strabismus, particularly those with cranial nerve palsies, a thorough investigation regarding potential systemic and neurological etiologies is warranted. After any general health



At left, glue on the eyelashes attracts debris and *Demodex*. At right, makeup can infiltrate the glands when applied too close to the line.

issues have been addressed, the patient should be given the option of undergoing a sensorimotor evaluation to determine the most appropriate treatment options.

Restorative Measures

Elimination of diplopia, asthenopia or an anomalous head posture; improved binocular function; and expansion of the binocular visual field for esotropic patients are all goals that can be achieved for many adults with strabismus. Treatment modalities can include: lenses, prisms, occlusion, vision therapy and muscle surgery. A patient does not need to achieve perfectly straight eyes and a high level of stereoacuity to be considered successfully treated.

For all of the aforementioned reasons, treatment of adult strabismus should not be considered cosmetic, but restorative. Treatment attempts to reestablish normal eye alignment and function may have, in turn, wide-ranging psychosocial benefits for those of us who are not Heidi Klum, Kate Moss, Keshia or Kristen Bell.

Cosmetic Considerations Beauty and Hygiene

Health care professionals may avoid the topic of makeup hygiene for fear of insulting our female patients. That thinking needs to change. If we don't comment on the effects of makeup we're seeing from behind

the slit lamp, patients may assume their routine is acceptable, even when it is dangerous (which happens too often).

This section reviews the threat of misusing makeup, proper use for ocular health and how to tactfully communicate these tips to patients.

Brush Up on Makeup

Every girl should have learned the basics when she made her first trip to the makeup counter, but when she's in your chair, take the opportunity to brush up on these basics. Many optometrists issue contact lens instruction sheet with a list of "do's and don'ts." Maybe it's time to implement one for cosmetics and eye hygiene. Here's a start:

Don'ts:

1. Don't share makeup with anyone (and be wary of public cosmetic counters, where applicators may be re-used).
2. Don't primp when you drive.
3. Don't "top-off" dry mascara with water. A dry tube is an old one and could harbor bacteria or bio-films, just like a contact lens case. Water acts as a breeding ground and can also introduce more bugs.
4. Don't use eye shadows with glitter for daily use. These metallic substances can get trapped under lenses or even in the glands, causing foreign body sensation.
5. Don't use lip liners for the eyes.

Prostaglandin Analogs

Products that work to increase thickness and growth of eyelashes have become popular and can be effective. Prostaglandin analogs and polypeptides work at different points in the life cycle of eyelashes to prolong the growth phase, stimulate the transition from resting phase, or protect and strengthen those follicles in transition. Patients should be aware of the rare but potential side effects such as changes in iris freckles, darkening of the lid margin, lowering of IOP if it enters the eye, or atrophy of the surrounding lid tissue. These are ocular changes that should be discussed and monitored by an eye care professional. We should be aware of our patients' desires to enhance their appearance and offer them options.

Doing so could introduce oral mucosal bacteria to the lid margin and result in a nasty conjunctivitis.

6. Don't tug or be too aggressive with eyelash curlers because they can damage the follicle, which can take months to regenerate.

Do's:

1. Do replace products every three months as recommended by the manufacturers.

2. Do introduce new cosmetic products one at a time to determine your sensitivity to specific components, especially if you are prone to allergy. Don't be fooled by so-called "hypo-allergenic" products—because the FDA doesn't regulate cosmetics, this term is no guarantee of an allergen-free formulation.

3. Do respect the mucosal line. Makeup can aggregate here and plug up the glands. Stay distal to the lash margin to avoid introducing bacteria to the ocular surface.

4. Do put makeup on before soft contact lens insertion. Hyperopic patients who struggle with this rule should consider using a high magnification mirror.

5. Do not put rigid lenses on after makeup, and use caution to avoid smearing the lens upon insertion.

6. Do not remove mascara at bedtime using lid scrub pads or liquid eye makeup remover to clean debris and remove dead skin. Simple soap and water won't do the job. When mascara dries, it gets stiff and can cause the natural eyelash to break, possibly leading to lid disease, ocular surface disease and contact lens intolerance as it interferes with the normal tear production, plugs the glands and acts as an irritant.

Eyelash Extensions

Long eyelashes have seen a resurgence in the fashion scene. They are achieved with extensions or serums. Extensions can be applied at home or in the salon. The home version benefit is that they can be easily removed at night (use baby oil to loosen before pulling off), followed by the usual makeup removal.

However, lashes that are applied in the salon are often glued on in bands, individually or even weaved on. The problem is that they are expensive and, as such, the patient will leave them on for an extended period, sometimes even months.

At this point, they can become a bacterial breeding ground. They prevent makeup removal and even though customers are supposedly instructed not to wear mascara over them, we know they do. The mascara and glue attracts debris as well as bacteria.

It can be difficult to differentiate what is glue and what is, say, cylindrical dandruff resulting from a *Demodex* infestation.

A better option might be to suggest that patients promote their own lash growth and thickness. Lashes benefit from conditioners and many serums contain conditioners designed to maintain healthy lashes, rather than promoting growth.

Brightening and Whitening

Patients want their eyes to look whiter and more alluring. Age and years of sun exposure create inflamed vessels, pinguecula and pigmentary changes on the sclera. Obviously, doctors need to treat the problem if there is one. For instance, hyperemia can indicate ocular surface disease, pterygium, hypoxia, or even systemic disease such as liver cirrhosis.⁵²

For strictly aesthetic purposes, cool compresses can vasoconstrict, temporarily improving the appearance of the areas surrounding the eyes. Chilled artificial tears can also have a dramatic effect on the conjunctival vessels. Of course, many will rely on OTC "whitening" drops. These are definitely effective on a casual basis, but the main ingredient of these drops is often naphazoline. The risks of these drops include rebound hyperemia from the loss of flexibility of the vasculature.

Most optometrists wouldn't be able to tell if, say, a cadaver eye separated from its donor belonged to a man or woman. But just because the basic anatomy is indistinguishable, that doesn't mean our patients all live or use their eyes in identical manners. These different experiences must be compensated for within the optometrist's office to elevate our patients' quality of life, provide the best possible treatment options and deliver the expert care they've come to expect. ■

1. Schaumberg D, Dana R, Buring J, Sullivan D. Prevalence of dry eye disease among US women. *Arch Ophthalmol*. 2003 Aug;136(2):318-26.

2. Schaumberg D, Dana R, Buring J, Sullivan D. Prevalence of dry eye disease among US men: estimates from the Physicians' Health Studies. *Arch Ophthalmol*. 2009 Jun;127(6):763-8.

3. Schaumberg D, Buring J, Sullivan D, Dana M. Hormone Replacement Therapy and Dry Eye Syndrome. *JAMA*. 2001;286(17):2114-19.

4. Schaumberg D, Buring J, Sullivan D, Dana R. Hormone Replacement Therapy and Dry Eye Syndrome. *JAMA*. 2001;286(17):2114-9.

5. Chen S, Massaro-Giordano G, Pistilli M, Schreiber C, Bunya V. Tear osmolarity and dry eye symptoms in women using oral contraception and contact lenses. *Cornea*. 2013 Apr;32(4):423-8.

6. Pratt L, Brody D, Gu Q. Antidepressant Use in Persons Aged 12 and Over: United States, 2005–2008. NCHS data brief, no 76. Hyattsville, MD: National Center for Health Statistics. 2011. Accessed: March 13, 2015.

7. Natesh S, Rajashekara S, Rao A, Shetty B. Topiramate-induced angle closure with acute myopia, macular striae. *Oman J Ophthalmol*. 2010 Jan-Apr;3(1):26-8.

8. Postel E, Assalian A, Epstein D. Drug-induced transient myopia and angle-closure glaucoma associated with supraciliary choroidal effusion. *Am J Ophthalmol*. 1996 Jul;122(1):110-2.

9. Pai S, Pai A, Kamath G, et al. Topiramate Induced Acute Secondary Angle Closure Glaucoma And Myopic Shift: A Case Review. *The Internet Journal of Pharmacology*. 2010;9:2. DOI: 10.5580/a4320

10. Adipex-P prescribing information. Sellersville, PA: Gate Pharmaceuticals; Jul 2005. Available at: www.adipex.com/contents/pdf/Adipex_pi.pdf.

11. Lee G, Tam C, Danesh-Meyer H, et al. Bilateral angle closure glaucoma induced by sulfonamide-derived medications. *Clin Experiment Ophthalmol*. 2007 Jan-Feb;35(1):55-8.

12. Mandal A, Chatterjee S, Bose S, Ganguly G. Ocular adverse effects of Topiramate: Two case reports. *Indian J Pharmacol*. 2008 Nov-Dec; 40(6): 278–80.

13. Kjellstrom S, Bruun A, Isaksson B, et al. Retinal function and histopathology in rabbits treated with Topiramate. *Doc Ophthalmol*. 2006;113:179–86.

14. Zafeiropoulos P, Nanos P, Tsigoulis E, Stefanidou M. Bilateral Macular Edema in a Patient Treated with Tamoxifen: A Case Report and Review of the Literature. *Case Rep Ophthalmol*. 2014 Sep-Dec;5(3):451–4.

15. Kingwell E, Marriott J, Jetté N, et al. Incidence and prevalence of multiple sclerosis in Europe: a systematic review. *BMC Neurol*. 2013;13:128.

16. 4. European Medicines Agency SmPC for Gilenya: EPAR Product Information - Gilenya - EMEA/H/C/002202 - PSUV/0023 - Section 4.4. March 2011 Available from URL: http://www.ema.europa.eu/docs/en_GB/document_library/EPAR_-_Product_Information/human/002202/WC500104528.pdf. Accessed: March 13, 2015

17. Lynch C, Herold A, Sinnott J, Holt D. Use of antibiotics during pregnancy. *Am Fam Physician*. 1991 Apr; 43(4):1365-8.

18. Miller K. Diagnosis and treatment of Chlamydia trachomatis infection. 2006 Apr 15;73(8):1411-6.

19. Berman B, Perez OA, Zeli D. Update on rosacea and anti-inflammatory-dose doxycycline. *Drugs Today*. 2007 Jan;43(1):27-34.

20. Leibovitz E. The use of fluoroquinolones in children. *Curr Opin Pediatr*. 2006 Feb;18(1):64-70.

21. Silberstein S. Migraine and pregnancy. *Neurol Clin*. 1997 Feb;15(1):209-31.

22. Leung DT, Sacks SL. Current recommendations for the treatment of genital herpes. *Drugs*. 2000 Dec;60(6):1329-52.

23. Baker D. Antiviral therapy for genital herpes infections in pregnancy. *Expert Rev Anti Infect Ther*. 2005 Jun;3(3):385-92.

24. Chung C, Kwok A, Chung K. Use of ophthalmic medications during pregnancy. *Hong Kong Med J*. Jun 2004;10(3):191-5.

25. Brauner S, Chen T, Hultchinson M, et al. The course of glaucoma during pregnancy: a retrospective case series. *Arch Ophthalmol*. 2006 Aug;124(8):1089-94.

26. Vaideanu D, Fraser S. Glaucoma management in pregnancy: a questionnaire survey. *Eye Mar 2007;21(3):341-3.*

27. American autoimmune related disease association. <http://www.aarda.org/autoimmune-information/autoimmune-disease-in-women>. Last accessed 2/20/15.

28. Elman A, Gullberg R, Nilsson E, et al. Chloroquine retinopathy in patients with rheumatoid arthritis. *Scand J Rheumatol*. 1976;5(3):161-66. Hobbs HE, Sorby A, Freedman A. Retinopathy following chloroquine therapy. *Lancet*. 1959 Oct 3;2(7101):478-80.

29. Marmor MF, Carr RE, Easterbrook M, et al. Recommendations on screening for chloroquine and hydroxychloroquine retinopathy: a report by the American Academy of Ophthalmology. *Ophthalmology*. 2002 Jul;109(7):1377-82.

30. Marmor MF & Hu J. Effect of Disease Stage on Progression of Hydroxychloroquine Retinopathy. *JAMA 2014*; doi:10.1001/jamaophthalmol (published on line) 2014

31. Marmor MF, Kellner U, Lai TY, et al. Revised recommendations on screening for chloroquine and hydroxychloroquine retinopathy. *Ophthalmology*. 2011 Feb;118(2):415-22.

32. Chen E, Brown DM, Benz M, et al. Spectral domain optical coherence tomography as an effective screening test for hydroxychloroquine retinopathy. *Clin Ophthalmol*. 2010; 4: 1151–1158.

33. Browning D, Lee C. Relative sensitivity and specificity of 10-2 visual fields, multifocal electroretinography, and spectral domain optical coherence tomography in detecting hydroxychloroquine and chloroquine retinopathy. *Clin Ophthalmol*. 2014;8:1389–99.

34. Levy GD, Munz SJ, Paschal J, et al. Incidence of hydroxychloroquine retinopathy in a large multicentered outpatient practice. *Arthritis Rheum*. 1997 Aug;40(8):1482-6.

35. Melles R, Marmor M. The Risk of Toxic Retinopathy in Patients on Long-term Hydroxychloroquine Therapy. *JAMA 2014 Dec;132(12):1453-60*

36. Beauchamp G, Black B, Coats D, et al. The management of strabismus in adults—I. Clinical characteristics and treatment. *J AAPOS 2003;7(4):233-40.*

37. <https://www.youtube.com/watch?v=ObbidZpeMt>, Accessed February 26 2015.

38. Stein J. Disparities between ophthalmologists and their patients in estimating quality of life. *Curr Opin Ophthalmol* 2004;15(3):238-43.
 39. Hatt S, Leske D, Kirgis P, et al. The effects of strabismus on quality of life in adults. *Am J Ophthalmol* 2007;144(5):643-7.
 40. Hatt S, Leske D, Bradley E, et al. Development of a quality-of-life questionnaire for adults with strabismus. *Ophthalmology* 2009;116(1):139-144 e5.
 41. Satterfield D, Keltner J, Morrison T. Psychosocial aspects of strabismus study. *Arch Ophthalmol* 1993;111(8):1100-5.
 42. Durman J, Noonan C, Marsh I. The psychosocial effects of adult strabismus: a review. *Br J Ophthalmol* 2011;95(4):450-3.
 43. Nelson B, Gunton K, Lasker J, et al. The psychosocial aspects of strabismus in teenagers and adults and the impact of surgical correction. *J AAPOS*

2008;12(1):72-76 e1.
 44. Bez Y, Coskun E, Erol K, et al. Adult strabismus and social phobia: a case-controlled study. *J AAPOS* 2009;13(3):249-52.
 45. Mojon-Azzi S, Potnik W, Mojon D. Opinions of dating agents about strabismic subjects' ability to find a partner. *Br J Ophthalmol* 2008;92(6):765-9.
 46. Beauchamp G, Felius J, Stager D, Beauchamp C. The utility of strabismus in adults. *Trans Am Ophthalmol Soc* 2005;103:164-71; discussion 171-2.
 47. Olitsky S, Sudesh S, Graziano A, et al. The negative psychosocial impact of strabismus in adults. *J AAPOS* 1999;3(4):209-11.
 48. Coats D, Paysse E, Towler A, Dipboye R. Impact of large angle

horizontal strabismus on ability to obtain employment. *Ophthalmology* 2000;107(2):402-5.
 49. Goff M, Suhr A, Ward J, et al. Effect of adult strabismus on ratings of official U.S. Army photographs. *J AAPOS* 2006;10(5):400-3.
 50. Hatt S, Leske D, Bradley E, et al. Comparison of quality-of-life instruments in adults with strabismus. *Am J Ophthalmol* 2009;148(4):558-62.
 51. Leske D, Hatt S, Holmes J. Test-retest reliability of health-related quality-of-life questionnaires in adults with strabismus. *Am J Ophthalmol* 2010;149(4):672-6.
 52. Leske D, Hatt S, Liebermann L, Holmes J. Evaluation of the Adult Strabismus-20 (AS-20) questionnaire using Rasch analysis. *Invest Ophthalmol Vis Sci* 2012;53(6):2630-9.

OSC QUIZ

You can obtain transcript-quality continuing education credit through the Optometric Study Center. Complete the test form (page 87), and return it with the \$35 fee to: Optometric CE, P.O. Box 488, Canal Street Station, New York, NY 10013. To be eligible, please return the card within one year of publication.

You can also access the test form and submit your answers and payment via credit card at *Review of Optometry* online, www.reviewofoptometry.com.

You must achieve a score of 70 or higher to receive credit. Allow eight to 10 weeks for processing. For each Optometric Study Center course you pass, you earn 2 hours of transcript-quality credit from Pennsylvania College of Optometry and double credit toward the AOA Optometric Recognition Award—Category 1.

Please check with your state licensing board to see if this approval counts toward your CE requirement for relicensure.

1. Which of the following medications can cause or exacerbate dry eye and is equally prescribed in females and males?
 a. Hormone replacement therapy.
 b. Antidepressants.
 c. Oral contraceptives.
 d. Decongestants.

2. Topamax is associated with serious ocular side effects, which include all of the following except:
 a. Crystalline maculopathy.
 b. Increased intraocular pressure.
 c. Myopic shift.
 d. Secondary angle closure.

3. Gilenya is an oral medication linked to macular edema. For what systemic condition is it indicated?
 a. Hypertension.
 b. Multiple sclerosis.
 c. Migraine.
 d. Diabetes mellitus.

4. Which of the following antibiotics is con-

traindicated in pregnancy?

- Amoxicillin.
- Erythromycin.
- Tetracycline.
- Azithromycin.

5. Which of the following ocular hypotensive agents has a pregnancy Category B designation?

- Brimonidine.
- Bimatoprost.
- Timolol.
- Dorzolamide.

6. When evaluating an OCT, which of the following areas is more commonly affected in a patient taking Plaquenil?

- PIL (photoreceptor integrity line).
- Inner retinal layer.
- Internal limiting membrane.
- Outer nuclear layer.

7. After baseline testing for any pre-existing retinal/macular condition, if a patient is NOT a high-risk patient, when should Plaquenil macular toxicity screening test be performed?

- Six months.
- One year.
- Three years.
- Five years.

8. Which one of the following is not a risk factor for developing Plaquenil-related macular toxicity?

- Age.
- High BMI.
- Kidney dysfunction.
- Family history of diabetes.

9. Previous reported prevalence of Plaquenil macular toxicity has been:

- 1%.
- 10%.
- 33%.
- 50%.

10. Which of the following is not a test used

in today's evaluation of Plaquenil macular toxicity?

- 10-2 visual field.
- Time domain OCT.
- Fundus autofluorescence.
- mFERG.

11. Compared with nonstrabismic individuals, adults with cosmetically noticeable strabismus have been found to have increased rates of all of the following except:

- Social phobia.
- Anxiety.
- Depression.
- Suicide.

12. The Adult Strabismus (AS-20) questionnaire is designed to quantify adult patients':

- Self esteem.
- Quality of life.
- Potential for normal sensorimotor fusion.
- Suitability for strabismus surgery.

13. Which of the following is not considered a possible benefit of treating adult strabismus?

- Elimination of diplopia.
- Elimination of an anomalous head posture.
- Expansion of binocular field of view for patients with esotropia.
- Decreased photophobia in patients with intermittent exotropia.

14. Which of the following is not usually tested in a sensorimotor evaluation for an adult patient with intermittent strabismus?

- Correspondence.
- Comitancy.
- Ocular deviation.
- Stereopsis.

15. Which of the following is not a treatment option for adult strabismus?

- Lenses.
- Surgery.
- Vision therapy.
- All of the above are considered options.

OSC QUIZ

16. Regarding contact lenses and eye cosmetics, which statement is true?

- Insertion of a soft contact lens after eye makeup, regardless of the refractive error, is always recommended.
- Makeup removers are never recommended because they alter the fit of the lens.
- Eye care professionals need to discuss cosmetic hygiene with their patients as it can lead to contact lens complications.
- Rigid lenses should always be inserted prior to eye makeup.

17. Regarding the use of cosmetics near the eye, which statement is false?

- The mucosal line should be respected to avoid plugging of the meibomian glands.
- "Topping off" of mascara is suggested to increase the longevity of the product.
- Some components in eye shadows, such as glitter, have the potential for disturbing the natural tear layer.
- Cosmetics used near the eye should be replaced on a regular basis.

18. Regarding the eyelash growth cycle, which statement is false?

- Prostaglandin analogs have been shown to increase the eyelash growth cycle.
- Eyelash extensions can affect the normal growth cycle of lashes due to breakage.
- Eyelash extensions can interfere with a patient's recommended lid hygiene.
- Eyelash extensions and glues are do not attract debris or bacteria.

19. Methods to "whiten the eye" on a daily basis include all except:

- Treat the underlying etiology.
- Chilled artificial tears.
- OTC products containing naphazoline.
- Adequate sleep.

20. Known causes for hyperemia include all except the following:

- Liver disease.
- Hearing deficits.
- Ocular surface disease.
- Pterygium.



TAKE THE TEST ONLINE TODAY!
www.reviewofoptometry.com/continuing_education/

Examination Answer Sheet

Valid for credit through May 1, 2018

This exam can be taken online at www.revoptom.com/continuing_education. Upon passing the exam, you can view your results immediately and download a real-time CE certificate. You can also view your test history at any time from the website.

Recognize Distinctions in Women's Eye Health

Directions: Select one answer for each question in the exam and completely darken the appropriate circle. A minimum score of 70% is required to earn credit.

Mail to: Jobson - Optometric CE, PO Box 488, Canal Street Station, New York, NY 10013

Payment: Remit \$35 with this exam. Make check payable to Jobson Medical Information LLC.

COPE approval for 2 hours of CE credit is pending for this course.

This course is joint-sponsored by the Pennsylvania College of Optometry

There is an eight-to-ten week processing time for this exam.

1 = Excellent 2 = Very Good 3 = Good 4 = Fair 5 = Poor

- (A) (B) (C) (D)
- (A) (B) (C) (D)
- (A) (B) (C) (D)
- (A) (B) (C) (D)
- (A) (B) (C) (D)
- (A) (B) (C) (D)
- (A) (B) (C) (D)
- (A) (B) (C) (D)
- (A) (B) (C) (D)
- (A) (B) (C) (D)
- (A) (B) (C) (D)
- (A) (B) (C) (D)
- (A) (B) (C) (D)
- (A) (B) (C) (D)
- (A) (B) (C) (D)
- (A) (B) (C) (D)
- (A) (B) (C) (D)
- (A) (B) (C) (D)
- (A) (B) (C) (D)

Rate the effectiveness of how well the activity:

- Met the goal statement: (1) (2) (3) (4) (5)
- Related to your practice needs: (1) (2) (3) (4) (5)
- Will help you improve patient care: (1) (2) (3) (4) (5)
- Avoided commercial bias/influence: (1) (2) (3) (4) (5)
- How would you rate the overall quality of the material presented? (1) (2) (3) (4) (5)
- Your knowledge of the subject was increased:
 Greatly Somewhat Little
- The difficulty of the course was:
 Complex Appropriate Basic

How long did it take to complete this course?

Comments on this course:

Suggested topics for future CE articles:

Please retain a copy for your records. Please print clearly.

First Name | | | | | | | | | | | | | | | | | | | | | |

Last Name | | | | | | | | | | | | | | | | | | | | | |

E-Mail | | | | | | | | | | | | | | | | | | | | | |

The following is your: Home Address Business Address

Business Name | | | | | | | | | | | | | | | | | | | | | |

Address | | | | | | | | | | | | | | | | | | | | | |

City | | | | | | | | | | | | | | | | | | | | | | State | | |

ZIP | | | | |

Telephone # | | | | | - | | | | | - | | | | |

Fax # | | | | | - | | | | | - | | | | |

By submitting this answer sheet, I certify that I have read the lesson in its entirety and completed the self-assessment exam personally based on the material presented. I have not obtained the answers to this exam by any fraudulent or improper means.

Signature _____ Date _____

Lesson 111434

RO-OSC-0515

Vision Expo East Emphasizes Tech

Technology continues to revolutionize how you learn and care for patients—but it can also be harmful in some situations. **By Cheryl G. Murphy, OD, Contributing Editor**

An estimated 22,000 attendees from over 90 countries gathered at this year's Vision Expo East, where the emphasis was on technology to educate, treat and enhance patient care and communication.

Classroom Tech

Twenty-one hours of crowd-sourced learning classes proved to be insightful and entertaining to those who attended. "Anterior Segment and Contact Lenses," hosted by Marc Bloomenstein, OD, and Louise Sclafani, OD, encouraged attendees to use their smartphones or tablet devices to actively participate in the session and voice their opinions on the cases presented. This type of audience engagement led to interesting discussions on differences in the determination of diagnosis and treatment protocols.

Drs. Bloomenstein and Sclafani welcomed comments on pictures of ailments displayed on screens. Some



Friday at Vision Expo, Drs. Jerome Sherman, Jay Haynie and Mark Dunbar rallied the crowd to agree that their class, "Greatest Posterior Segment Course Ever!" really lived up to its name.

participants made educated guesses at a likely diagnosis, while others lent a bit of humor to an already lively class. Although a limited number of classes at VEE offered this level of participation, educators anticipate that the use of this audience response system (ARS) technology will expand for future Vision Expos East and West.

Advancing Care

"What's New in Eye Care," presented by optometrists Kirk Smick, Mark Dunbar, Craig Thomas and Peter Shaw-McMinn, reviewed the latest in diagnostic technology, treatments and surgical techniques pertaining to vision and eye health.

Among the topics discussed was the comanagement of patients who have had micro-invasive glaucoma surgery (MIGS). This new technique is performed in conjunction with cataract surgery and involves the placement of an L-shaped microstent into Schlemm's

canal through the same corneal incision made for the intraocular lens. iStent Glaukos is the first and only MIGS stent currently available in the US and is FDA approved for the reduction of intraocular pressure in adult patients with mild to moderate open-angle glaucoma currently treated with ocular hypotensive medication.



Audience feedback proved both fun and insightful during the lecture hosted by Drs. Marc Bloomenstein and Louise Sclafani where attendees could take polls, make comments and ask questions using their mobile devices.

Besides surgical advancements, diagnostic advancements in optometric care were also discussed, including the use of OCT. Dr. Dunbar cleverly punned the OCT as being “instrumental” to one’s practice. He noted that although newer, swept-source OCTs are faster and give the practitioner more info, spectral-domain OCTs remain “good for most practices.” Also, spectral-domain OCTs certainly provide greater detail than earlier time-domain OCT models.

Later, on a more serious note in “The Greatest Posterior Segment Disease Course Ever!” Dr. Dunbar added “the development of the OCT has forever changed and elevated eye care.”

Wearable Tech in Healthcare

Besides technological advances in eye care and communication, VEE also showcased the latest in eyewear and eye care technologies. Andrew Karp, group editor of lenses and technology for *Vision Monday* and *20/20 Magazine*, spoke about the latest in wearable tech. He explained that

wearable tech devices, such as smart glasses and smart contact lenses, are not only used for virtual reality and augmented reality applications but also for medical reasons. In his course, “Eyewear and Eye Care’s Pivotal Role in Wearable Tech,” he emphasized, “there are many sensor-based systems geared towards health and wellness.”

Some devices, such as the Eyes-On Glasses System by Epson and Evena Medical, allow nurses and phlebotomists to see a patient’s veins through the skin, which makes it easier to draw blood. Other smart glasses applications can aid surgeons during delicate procedures by displaying information, such as the patient’s vital signs, in the doctor’s field of vision so that they don’t have to take their focus away from the procedure to check a monitor across the room for information.

How Much Tech is Too Much?

“Digital Eyestrain, Blue Light and UV,” presented by Dr. Smick, Pete Hanlin, LDO, ABOM, and Diana Shechtman, OD, educated eye care professionals on how the ever-changing world of technology can negatively impact our eyes. For instance, overexposure to blue-violet light, like that emitted from LED screens on electronic devices and CFL light bulbs, has the potential to cause retinal damage. Eye care professionals need to know how to protect patients and themselves from the dangers of blue-violet and ultraviolet light as well as the discomfort of digital eyestrain incited by overexposure to the

blue light of tablets, smartphones, computer screens and swirly light bulbs. Increasing physical distance away from devices that emit blue light, decreasing screen brightness, limiting time on devices, and taking frequent breaks from them can help to lessen exposure to blue light from artificial sources, the presenters said. Also, lenses that selectively filter some blue light may be worn to further protect patients.

Natural sources of light like the sun also can impose harmful effects on our eyes and our skin. Like other health care providers, eye care professionals are on the front lines of educating patients on the negative impacts of overexposure to UV radiation; optometrists should give patients the necessary tools they need in order to protect their eyes, the presenters concluded. ■



Gary Gerber, OD, rocks the “keytar” at the EyeRock Benefit Concert held in conjunction with Vision Expo East.

DOWNLOAD LAYAR APP
FOR INTERACTIVE EXPERIENCE



layar
INTERACTIVE PRINT

First 150 app downloads & completed forms will be entered into a drawing for FREE MEETING & REGISTRATION VALUED AT \$495

REGISTRATION OPEN!

REVIEW OF OPTOMETRY EDUCATIONAL MEETINGS OF CLINICAL EXCELLENCE



MAUI, HAWAII JULY 23-26

WAILEA BEACH MARRIOTT RESORT & SPA
3700 WAILEA ALANUI DRIVE, MAUI, HI 96753

**\$100 OFF BY
MAY 23RD**

CE COURSE TOPICS:

- New Advances in the Management of Lid Margin Disease
- Clinical Management of Ocular Surface Disease
- Technological Innovations in Eye Care
- Cancer and the Eye: Ocular Tumors, Malignancies and Neoplasms
- Expert Panel on Glaucoma Diagnosis and Treatment
- What the Primary Care Optometrist Should Never Miss
- Don't Let Swollen Optic Nerves Make You Nervous
- Conquering Therapeutic Dilemmas



Watch video with meeting chair, Paul Karpecki for more reasons to attend!

FACULTY



Paul Karpecki, OD
Program Chair



Ron Melton, OD



Brad Sutton, OD



Randall Thomas, OD

3 WAYS TO REGISTER

ONLINE: WWW.REVOPTOM.COM/MAUI2015

EMAIL LOIS DIDOMENICO: REVIEWMEETINGS@JOBSON.COM

PHONE: 866-658-1772

Administered By

Review of Optometry®



Up to
**14 CE
Credits**
(COPE approval pending)

WAILEA BEACH MARRIOTT RESORT & SPA

3700 WAILEA ALANUI DRIVE, MAUI, HI 96753

Discounted Room Rates: \$295/night standard, \$325/night ocean view; plus applicable taxes & fees.

Discounted room rates limited.
For hotel reservations, call 877-622-3140.

Identify yourself as a participant of
"Review of Optometry" for group rate.

www.revoptom.com/Maui2015

Registration Information

Name _____		NPI # (NPI numbers will only be used for HCP reporting purposes) _____	
Practice Affiliation _____			
Mailing Address _____	City _____	State _____	Zip Code _____
Telephone _____	Fax _____	Email _____	

Name Badge Information (please print clearly)

My Name _____	My Guest _____	Additional Guests _____
---------------	----------------	-------------------------

Payment Information

	Rate per person	No. in party	Subtotal
OD Registration - \$595 (\$100 off if registered by May 23rd) (includes 14 hours of CE, breakfasts, reception) <small>Call for daily and student rates.</small>	\$495	x _____	= \$ _____
Additional Guest(s) - \$45 (12 years and older, includes reception)	\$45	x _____	= \$ _____
Optional Catamaran/Snorkeling Activity, Saturday July 25 - \$125 (includes lunch)	\$125	x _____	= \$ _____
<small>This 3.5-hour trip includes round trip transportation from Wailea Marriott to Maalaea Harbor, all snorkel gear, expert instruction, plus a barbecue lunch and open bar! Not that into the snorkeling scene? No worries, take your pick of flotation devices—including an oversized boogie board with built-in viewing port—or use the onboard waterslide to take a dip in the Pacific Ocean. But that's not all—the Four Winds II features a glass bottom for 180° of underwater viewing!</small>			
		TOTAL	= \$ _____

Check enclosed (make checks payable to *Review of Optometry*)

Charge my: American Express Mastercard Visa

Credit Card Number _____	Exp Date _____
Cardholder (print name) _____	
Signature _____	

CONFERENCE CANCELLATION POLICY

- Full refund on registration fee until June 23, 2015
- 50% refund on registration fee until July 9, 2015
- No refund past July 10, 2015

For more information or to register,
contact Lois DiDomenico at 866-658-1772
or at ReviewMeetings@Jobson.com.

MAIL FORM : Review Group Meetings c/o Jobson
11 Campus Blvd, Ste. 100
Newtown Square, PA 19073

FAX FORM: Review Meetings Group
610-492-1039



Clarifying Dry Eye Coding

Don't get confused by the vision vs. medical coverage dilemma.

By **John Rumpakis, OD, MBA, Clinical Coding Editor**

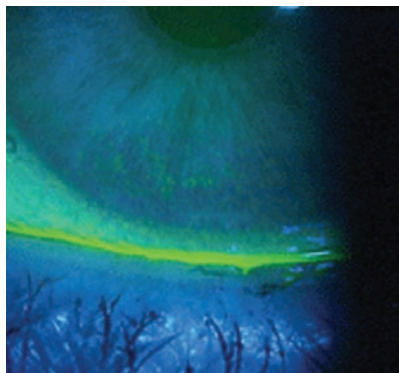
Recently, during dinner with two colleagues, the topic of the billing dilemma surrounding dry eye arose. I found the conversation both intriguing and bewildering, as I didn't see the dilemma in quite the same way that they did.

Dry eye, depending on how it is classified, could be considered at epidemic levels within the United States. Well over half of the patients that an OD sees on any given day have some component of ocular surface disease. It may manifest itself differently with every patient: the contact lens patient who isn't getting her full day of wear, the computer programmer with fluctuating vision that gets better when he blinks, the fifty-something patient who's eyes are always red and irritated, etc. So what's the dilemma? How the practitioner defines the services related to dry eye and who is financially responsible for them.

While I understand there are exceptions to every rule, the constructs for defining and delineating our services are fairly straightforward. I'm not talking about the clinical side of things, but more from the perspective of how the patient presents to the office. Let's discuss two common scenarios:

Scenario One

A patient schedules an eye examination and has a managed vision care plan that covers their "annual eye examination and refraction." During the course of the examination, you discover she has some



Corneal staining revealing dry eye.

clinical signs of dry eye. She also has medical coverage for which you are a participating provider.

Because she didn't present with "complaints or symptoms of an eye disease or injury," her medical insurance benefits won't get involved with respect to your professional services on that day. The examination and refraction fall under the managed vision care contract, and the appropriate benefit structure is applied.

You direct the patient to return to the office for a full dry eye workup or ask her to return for evaluation of the topical agents you prescribed or recommended on the date of her visit; these additional office visits, and any procedures that you deem medically necessary and document in the record, could be covered by her medical plan. That may mean that she pays you in full because she has a high deductible that she hasn't yet met, or she could simply be paying you a copay for the visit. In any case, it's your responsibility to apply her

contracted benefits accurately and in accordance with your contract agreement for that specific carrier.

Scenario Two

A patient calls the office and complains of fluctuating vision and irritated eyes. He has managed vision care and medical insurance.

In this scenario, the patient presented with frank symptoms of dry eye and therefore has met the chief complaint requirements of the medical carrier. You would code the encounter with either a 920X2 or a 992XX, depending on the status of the patient and the actual services provided and recorded in his file. This visit comes under the coverage umbrella of the medical carrier and, again, it's your responsibility to follow the contractual guidelines for that specific carrier. The vision carrier is generally not involved, and the patient can't use his managed vision care benefit for this visit even if it costs him less.

In each of these scenarios, if you follow the basic rules of the chief complaint and medical necessity, the party responsible for the economics of the encounter is readily apparent. Don't let your emotions or feelings get in the way of you following the rules. Dry eye is exceedingly prevalent within our population, and you need to prepare your office to properly handle the diagnosis and long-term management. ■

Send questions and comments to ROcodingconnection@gmail.com.

NEW
Lombart CS-5 Package
Quality, Style & Value

Package includes:

- The Lombart CS-5 Chair & Stand 
- Topcon VT-10 Refractor
- Topcon SL-2G Slit Lamp
- Reichert LongLife Chart Projector  with mount, slide & screen
- Upgrade to the Lombart CVS-PC for only \$1500 or to the CVSi21 for only \$2000 more
- Additional upgrades & configurations available.

\$13,995

Or lease for \$277/mo.
for 60 months*

*Lease rate subject to credit approval, 1st payment is due at signing with 59 remaining rental payments of \$265 and a \$1.00 purchase option. Taxes, freight and installation additional. Hand Instruments optional. Subject to change without notice.

1-800-566-2278

Call 1-800-Lombart

Or Your Local Lombart Representative

Corporate Office - 5358 Robin Hood Road, Norfolk, VA 23513-2430
757-853-8888 | FAX 757-855-1232 | 800-566-2278

www.lombartinstrument.com
lombart@lombartinstrument.com

Sales and Service Centers Coast to Coast

ATLANTA • BALTIMORE/WASHINGTON D.C. • BOSTON • BOYNTON BEACH/MIAMI • BRADENTON • CHARLOTTE • CHICAGO • CINCINNATI • DALLAS • DENVER • DETROIT • GREENSBORO • HOUSTON
JACKSON • KANSAS CITY • KNOXVILLE • LOS ANGELES • MILWAUKEE • MINNEAPOLIS • NEW JERSEY/NEW YORK/PENNSYLVANIA • NORFOLK • PORTLAND • SAN ANTONIO • SAN DIEGO • SAN FRANCISCO





Blood, Tears and Albumin

In the case of filamentary keratitis, should one eye drop be used over the other?

Edited by Joseph P. Shovlin, OD

Q I have a patient with severe ocular surface disease with corneal filaments that might benefit from additional echelon measures. However, I'm not sure how to decide between albumin and serum tears. Can you provide indications and preparation protocols?

A “Experts would agree that because autologous serum (AS) more closely mimics one’s own natural tears—offering not only proteins like albumin, but growth factors, lysozymes and vitamin A, which further support ocular surface health—AS drops would be preferred over albumin drops,” says Richard B. Mangan, OD, of Bennett & Bloom Eye Centers in Kentucky.

Various studies have been conducted on the efficacy of both types of drops, he notes. In one study, albumin drops improved vital dye staining but not tear break-up times or ocular symptoms in Sjögren’s syndrome patients.¹ In comparison, patients with Sjögren’s syndrome treated with 20% AS showed improvement in vital dye staining, tear break-up times and symptoms in two to four weeks of treatment.²

Paul M. Karpecki, OD, of Koffler Vision Group in Kentucky, agrees, saying that the extra ingredients in AS are the reason he prefers using them. Typically, he adds, the protocol for preparing them involves a laboratory, compounding pharmacist or sometimes a local eye bank.

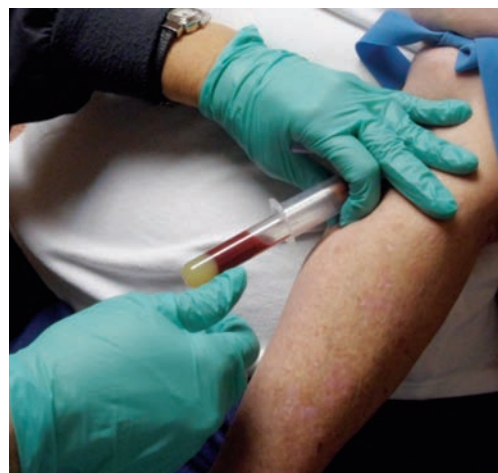“The patient’s blood is drawn and centrifuged down so the serum is separated. The serum is then mixed with an artificial tear—typically in a 50% concentration, but it could be

lower as well,” Dr. Karpecki explains. “Depending on how much blood is drawn, the patient can obtain anywhere from eight to 15 vials. The one being used is placed in the refrigerator while the others remain in the freezer.”

In some cases, however, 5% albumin drops should be recommended over AS drops, Dr. Mangan says.

“The [production] process from start to finish in supplying preservative-free AS drops to patients is complex,” he explains. “From blood draw and lab testing, to centrifugation, then compounding and ultimately dispensing, the AS process can be somewhat daunting for both patient and prescriber.” Albumin drops, he says, can be shipped directly to a patient’s home from a compounding pharmacy familiar with formulating 5% drops from commercially available stock.

Cost is another factor that could sway a patient. “A 10ml bottle of 5% albumin drops costs roughly \$50, while AS can cost two to two and a half times more, not including copays required for the blood draw and any necessary lab work,” Dr. Mangan says. “The upfront costs for a three-month supply of serum tear (standard for a single draw) can be a barrier for some patients.” While true, this is not always the case, says Dr. Karpecki. Some eye banks can make a year’s supply of AS for the price of artificial tears.



The patient’s blood is collected to make AS eye drops.

Patients who are unable to give blood due to an existing condition that contraindicates it (i.e., poor vein integrity or a vasovagal history), have abnormal labs (i.e., hepatitis, HIV, syphilis) or a history of active infection may also be more suited for albumin eye drop use, Dr. Mangan says.

Regardless, both serum and albumin tears are options to treat the long-term underlying condition, Dr. Karpecki notes. To treat the filaments themselves, he suggests mechanical debridement, topical corticosteroids, compounded acetylcysteine 10%, bandage contact lenses and amniotic membranes such as Prokera. ■

1. Shimmura S, Ueno R, Matsumoto Y, et al. Albumin as a tear supplement in the treatment of severe dry eye. *Br J Ophthalmol.* 2003 Oct;87:1279-83.

2. Tsubota K, Goto E, Fujita H, et al. Treatment of dry eye by autologous serum application in Sjögren’s syndrome. *Br J Ophthalmol.* 1999 Apr;83(4):390-5.

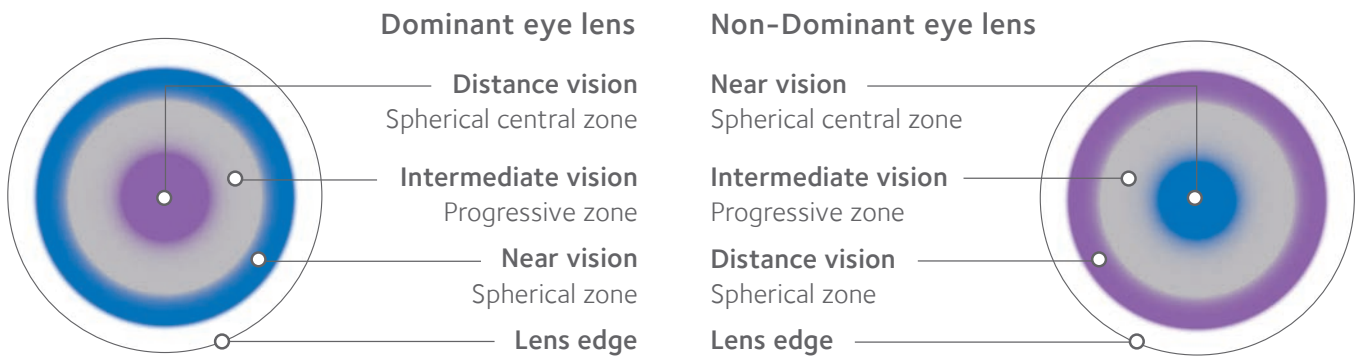
An easy fit

for you and your presbyopic patients.

CooperVision Biofinity® multifocal lenses combine a high-performing 3rd generation material with a streamlined fitting process. Now even your most challenging presbyopic patients can enjoy the freedom of **all-distance clarity and lasting comfort.**



Balanced Progressive™ Technology enhances vision near, far and intermediate. It also allows for an individualized fitting for each wearer and each eye.



Biofinity & Biofinity XR Biofinity toric **Biofinity multifocal**

Download your Biofinity multifocal 3-step fitting guide at coopervision.com/fitting-guide

DOWNLOAD LAYAR APP FOR INTERACTIVE EXPERIENCE



First 150 app downloads and completed forms will be entered into a drawing for FREE MEETING AND REGISTRATION VALUED AT \$495




REVIEW OF OPTOMETRY

EDUCATIONAL MEETINGS OF CLINICAL EXCELLENCE


PAUL KARPECKI, OD
PROGRAM CHAIR



REGISTRATION OPEN



CHARLESTON, SC
JUNE 12-14



MAUI, HI*
JULY 23-26



Includes hands-on workshops



PHILADELPHIA, PA
NOVEMBER 6-8

For more information visit www.reviewofoptometry.com

Administered By
Review of Optometry®



**Up to
17 CE
Credits**
(COPE approval pending)

* Workshops not available - See website for information about snorkeling catamaran activity



Red Eye Gone (Adeno) Viral

When you see follicular conjunctivitis, adenovirus should be near the top of your diagnosis list. **By Carlo J. Pelino, OD, Joseph J. Pizzimenti, OD, and Bisant A. Labib, OD**

Adenoviruses have a variety of clinical effects on the body. Though most frequently associated with respiratory infections, they can also cause gastroenteritis, cystitis and rash illness—not to mention red eye.

Virology of Adenoviridae

Adenoviruses are non-enveloped, icosahedral shaped and contain a double-stranded DNA genome. They are categorized into four genera: Aviadenovirus (infects birds), Mastadenovirus (infects mammals), Atadenovirus and Siadenovirus (infect a variety of organisms).^{1,2}

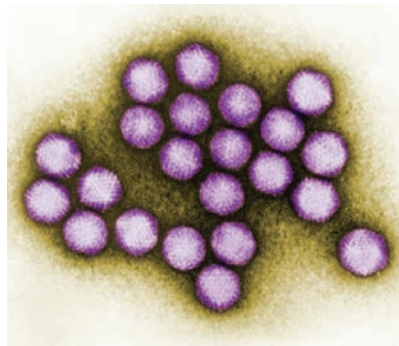
The virus enters the host by directly penetrating the cytoplasm or being engulfed into the cytoplasm through a membrane-bound vesicle, a process called endocytosis.

Transcription occurs in immediate-early, early and late stages. The virus sheds its DNA into the host nucleus, resulting in infection and the induction of the innate and cell mediated immune responses.³

Clinical presentation varies and depends on both the serotype and the degree to which the infected host is immunocompromised.

Populations at Risk

Adenovirus infections are prevalent worldwide and are a significant cause of febrile respiratory illness in young children.² Epidemics occur frequently in areas with infants or young children. Transmission occurs through different modes such as aerosol droplets, fecal-oral and contact with ocular secretions.



Adenovirus is so insidious that it's being used as a viral vector in gene therapy.

Cervical secretions at birth can also transmit the virus from mother to neonate. Evidence that adenoviruses can be transmitted through organ transplantation suggests organs may harbor a latent form of the virus.^{1,2} Adenovirus can survive for long periods on environmental surfaces, contributing to its highly contagious nature.^{1,2,4}

Treatment

Adenoviral systemic infection management generally consists of supportive therapy, as they are self-limiting conditions in healthy hosts. Treatment should only be considered in immunocompromised individuals. Using antiviral medications can pose a risk because of the associated drug toxicities. When treatment is warranted, ribavirin and Vistide (cidofovir, Gilead Sciences) therapies have variable success in immunosuppressed hosts.²

Adenoviral Eye Disease

Ocular manifestations of adenovirus are quite common and account

for 65% to 90% of reported viral conjunctivitis cases worldwide.⁵ Symptoms of redness and irritation usually begin and predominate in one eye and may spread to the fellow eye within a few days. Patients frequently report a burning or foreign body sensation, and examination findings may include a watery, mucoid discharge. The lids may become red and edematous, and morning crusting is common. Preauricular lymphadenopathy is also commonly present.

A history of antecedent upper respiratory tract infection or close contact with someone with a “red eye” is common. The severity of infection is variable in clinical presentation and may consist of follicular conjunctivitis (especially on the inferior palpebral conjunctiva), keratoconjunctivitis and (rarely) acute hemorrhagic conjunctivitis. Occasionally, pinpoint subconjunctival hemorrhages may develop.

The incubation period ranges from four to 10 days before the infection is clinically observable,

Common Adenoviral Conditions in Humans

- Pharyngitis
- Acute respiratory disease
- Pneumonia
- Conjunctivitis
- Pharyngoconjunctival fever
- Epidemic keratoconjunctivitis
- Genitourinary infections (cervicitis, urethritis, hemorrhagic cystitis)
- Gastroenteritis
- Neoplasm (Kaposi sarcoma)

Review of **Systems**

which is due to the amount of time it takes for the virus to shed.⁵

Medical treatment of mild adenoviral conjunctivitis is not warranted, as it typically resolves within days to two weeks.^{5,6} Management is supportive, with cool compresses and artificial tears several times a day for comfort.

Epidemic Keratoconjunctivitis

Epidemic keratoconjunctivitis (EKC) is the term used when these highly contagious adenoviral eye infections further involve the cornea. EKC has the potential to impact long-term visual function.

Aside from the symptoms and signs consistent with a milder viral conjunctivitis, EKC may also present with more pronounced subconjunctival hemorrhages, moderate to severe lid edema and membrane or pseudomembrane formation. These

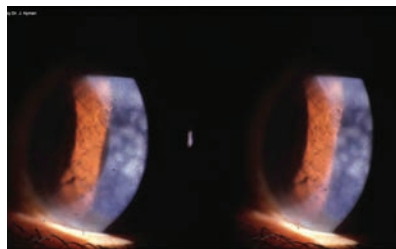


Photo: Jeffrey Nyman, OD

Subepithelial infiltrates from a viral conjunctivitis.

membranes occur as a result of the inflammatory response and consist of leukocytes, fibrin and fibroblasts.

The course of corneal involvement in EKC begins with punctate epitheliopathy within the first week, progressing to subepithelial infiltrates (SEIs) by week two. This accounts for symptoms of irritation and pain. It's also the reason for decreased visual acuity, with SEIs that may last months to years after the infection subsides.^{5,7}

EKC Detection and Treatment

Confirming adenovirus on the ocular surface is possible through rapid assay (AdenoPlus, RPS), cell culture combined with confirmatory immunofluorescence (CCIFA) or polymerase chain reaction (PCR). The latter two tests are not readily accessed by most optometrists. However, AdenoPlus is an in-office test with high sensitivity and specificity for adenovirus detection through a conjunctival swab sample. Results are available in 10 minutes, aiding in timely diagnosis.⁸

EKC is usually self-limiting, and treatment is reserved for cases of severe signs and symptoms, and for those who need the clearance of dense SEIs. Zirgan (ganciclovir gel 0.15%, Bausch + Lomb) showed significant inhibitory activity against some human adenoviruses (HAdV) that include EKC, suggest-

Your own custom App

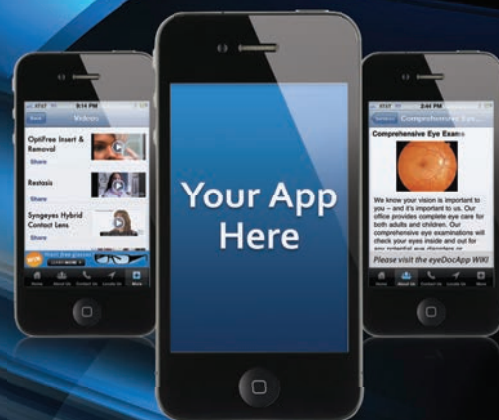for iPhone, Android, iPad and Mobile Website!

EyeDocApp makes it easy for Individuals and Businesses to have their own custom App for iPhone, Android and iPad. Now you can use the same technology that Fortune 500 companies are using, for a fraction of the cost!

Apps are the most powerful mobile marketing tools in the world! Your custom App can be downloaded by anyone in the world via the iTunes and Android Marketplace. Now all your customers can have your business in their pocket, and at their fingertips. You can even send PUSH Notifications which instantly pop up on their phone, just like a text message.

Unlimited upgrades, push notifications, features and a user friendly interface –
All for \$49.99/month

Learn more at EyeDocApp.com



EyeDocApp

Exclusively Marketed
by Jobson Optical's
IECP
BUSINESS SERVICES
Understand, Manage, Grow.



THE RICK BAY FOUNDATION

for Excellence in Eyecare Education

www.rickbayfoundation.org

Support the Education of Future Healthcare & Eyecare Professionals



About Rick

Rick Bay served as the publisher of *The Review* Group since 1991.

To those who worked for him, he was a leader whose essence was based in a fierce and boundless loyalty.



To those in the industry and the professions he served, he will be remembered for his unique array of skills and for his dedication to exceeding the expectations of his customers, making many of them fast friends.

Scholarships are awarded to advance the education of students in both **Optometry** and **Ophthalmology**, and are chosen by their school based on qualities that embody Rick's commitment to the profession, including integrity, compassion, partnership and dedication to the greater good.

Interested in being a partner with us?

Visit www.rickbayfoundation.org

(Contributions are tax-deductible in accordance with section 170 of the Internal Revenue Code.)



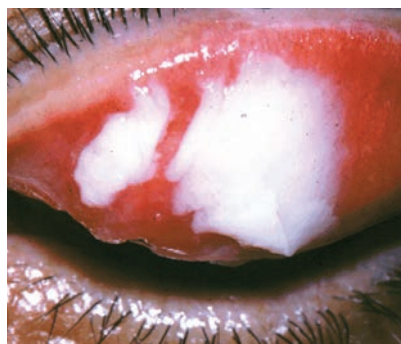
THE RICK BAY FOUNDATION
for Excellence in Eyecare Education

(The Rick Bay Foundation for Excellence in Eyecare Education is a nonprofit, tax-exempt organization under section 501(c)(3) of the Internal Revenue Code.)

ing it could be a candidate for the treatment of HAdV keratoconjunctivitis in the future.⁹ Corticosteroids are effective in the elimination of SEIs, but have the potential for adverse effects (such as IOP rise) with long-term therapy.¹⁰ Researchers have demonstrated success using Restasis (cyclosporine A 0.05%, Allergan) in the clearance of SEIs with one month of use on average.¹¹ Cyclosporine did not result in any ocular or systemic effects.

Due to the infectious nature of the virus and ease of transmission, you may implement Betadine 5% Sterile Ophthalmic Prep Solution (povidone-iodine, Alcon) to hasten resolution and reduce the likelihood of spread.¹² Pseudomembranes should be manually peeled every two to three days. Topical corticosteroids may help prevent scarring.

Educate patients on the precautions they should take to prevent contagious spread, such as washing sheets and pillowcases, washing hands and taking a temporary leave of absence for those who work with the public and have active infection. In your office, thoroughly clean instruments and surfaces.

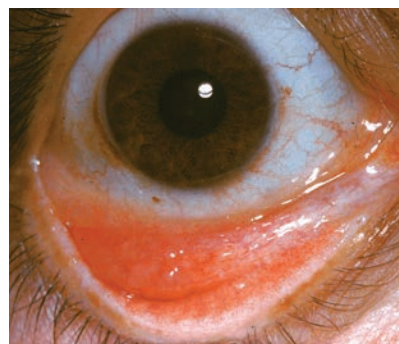


Large pseudomembrane in an eye with EKC.

Good News About Adenovirus

While adenoviruses are associated with systemic and ocular infection, they may, in time, serve a beneficial role. They have the ability to affect several cell types to incorporate manufactured DNA into the host and have shown immense potential to function as gene vectors for vaccination and to treat a host of genetic diseases and cancers.¹³ Early clinical trials have demonstrated the use of this technique for the treatment of retinal disease, specifically in age-related macular degeneration and retinoblastoma.¹⁴

Adenoviral ocular infection is frequently encountered in the primary



Adenoviral conjunctivitis typically presents with inferior palpebral follicles.

eye care practice. Proper detection and timely diagnosis of severe follicular conjunctivitis and EKC is essential in both treatment and prevention of transmission, as failure to do so can result in outbreak. ■

Dr. Labib is a resident at the Eye Institute, Salus University, Philadelphia.

EKC's Pediatric Cousin

Pharyngoconjunctival fever (PCF) is an acute and highly infectious illness characterized by fever, pharyngitis, acute follicular conjunctivitis and regional lymphoid hyperplasia with tender, enlarged preauricular adenopathy. Systemic symptoms include sweats, sore throat and headache. Myalgia, malaise and GI disturbances frequently are associated with fever.

PCF is seen predominantly in children and institutionalized individuals, with epidemics occurring within families, schools, prisons, ships and military organizations. Upper respiratory tract symptoms may precede ocular findings or may be absent. Acute conjunctivitis may occur with or without pharyngitis or a respiratory syndrome.

Conjunctivitis usually begins in one eye and then spreads to the other, although both eyes may be affected simultaneously. Severe pain is atypical, but mild pain or discomfort, tearing, pruritus and morning crusting are common.

Because PCF usually is a self-limited disease, ocular treatment is mainly supportive similar to that of mild to moderate adenoviral conjunctivitis. Corneal infiltrates are rare.

Treatment with topical anti-inflammatory agents is reserved for cases with severe signs and symptoms.

1. Zhou X, Robinson CM, Rajaiya J, et al. Analysis of human adenovirus type 19 associated with epidemic keratoconjunctivitis and its reclassification as adenovirus type 64. *Invest Ophthalmol Vis Sci.* 2012 May;53(6):2804-11.
2. Flomenberg P, Kojaoghlanian T. Epidemiology and clinical manifestations of adenovirus infections. *UpToDate.* 2015:1-8.
3. Muruve DA. The innate immune response to adenovirus vectors. *Hum Gene Ther.* 2004 Dec;15(12):1157-66.
4. Russell W. Adenovirus: update on structure and function. *J Gen Virol.* 2009 Jan;90(1):1-20.
5. Yanoff M, Duker J, Augsburger J. Adenovirus. In: *Ophthalmology* 4th ed. St. Louis, MO: Mosby, 2004.
6. Bialasiewicz A. Adenoviral keratoconjunctivitis. *Sultan Qaboos Med J.* 2007 April;7(4):15-21.
7. Kanski, JJ. *Clinical Ophthalmology.* London: Butterworths; 1984. Print.
8. Sambursky R, Trattler W, Tauber S, et al. Sensitivity and specificity of the AdenoPlus test for diagnosing adenoviral conjunctivitis. *JAMA Ophthalmol.* 2013;131(1):17-21.
9. Huang J, Kadonosono K, Uchio E. Antiadenoviral effects of ganciclovir in types inducing keratoconjunctivitis by quantitative polymerase chain reaction methods. *Clin Ophthalmol.* 2014;8:315-2.
10. Pihos A. Epidemic keratoconjunctivitis: a review of current concepts in management. *Illinois college of optometry.* 2012;1(9):69-74.
11. Okumus S, Coskun E, Tatar MG, et al. Cyclosporine a 0.05% eye drops for the treatment of subepithelial infiltrates after epidemic keratoconjunctivitis. *BMC Ophthalmol.* 2012 Aug;12:42.
12. Monnerat N, Bossart W, Thiel MA. Povidone-iodine for treatment of adenoviral conjunctivitis: an in vitro study. *Klin Monbl Augenheilkd.* 2006 May;223(5):349-52.
13. Flomenberg P, Kojaoghlanian T. Adenovirus and vector applications. *UpToDate.* 2015:1-7.
14. Sweigard JH, Cashman SM, Kumar-Singh R. Adenovirus vectors targeting distinct cell types in the retina. *Invest Ophthalmol Vis Sci.* 2010 Apr;51(4):2219-28.

DOWNLOAD LAYAR APP
FOR INTERACTIVE EXPERIENCE



First 150 app downloads & completed forms will be entered into a drawing for FREE MEETING & REGISTRATION VALUED AT \$495

REGISTRATION OPEN!

REVIEW OF OPTOMETRY EDUCATIONAL MEETINGS OF CLINICAL EXCELLENCE



PHILADELPHIA, PA

NOVEMBER 6-8

SHERATON PHILADELPHIA DOWNTOWN HOTEL

201 NORTH 17TH STREET PHILADELPHIA, PA

**\$100 OFF BY
SEPTEMBER 6TH**

SAVE THE DATE

Our New Technologies and Treatments faculty of thought leaders captivate attendees as they share their expertise on cutting edge technology and the latest pharmaceuticals.

NEW! DRY EYE AND GLAUCOMA WORKSHOPS AVAILABLE



Watch video with meeting chair, Paul Karpecki for more reasons to attend!

FACULTY



Paul Karpecki, OD
Program Chair



Douglas Devries, OD



Jeffrey Gerson, OD



Blair Lonsberry, OD

3 WAYS TO REGISTER

ONLINE: WWW.REVOPTOM.COM/PHILADELPHIA2015

EMAIL LOIS DIDOMENICO: REVIEWMEETINGS@JOBSON.COM

PHONE: 866-658-1772

Administered By

Review of Optometry®



Up to
17 CE
Credits
(COPE approval pending)

EDUCATION SESSION ST

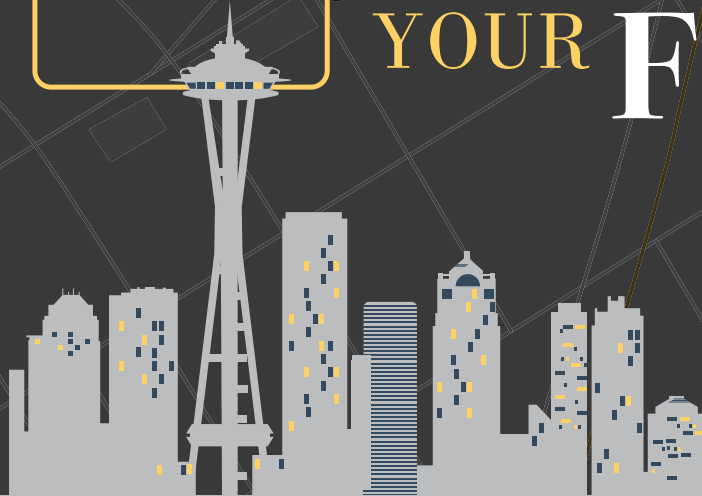EXHIBITOR RD

FUTURE AVE



Optometry's
meeting®

MAPPING YOUR FUTURE



GPS: GUIDING PEOPLE TO SOLUTIONS


Looking for the right tools to help guide your practice to the solutions that will drive future success? Optometry's Meeting® has the broadest array of technology-based exhibitors, cutting-edge education sessions, and brilliant professionals that can help you and your staff find the solutions to move your practice forward.

Learn more about Optometry's Meeting at optometrymeeting.org today. Or download the free app today at Google Play or the iTunes store to see how Optometry's Meeting® can help guide your future success.

OPPORTUNITY ROAD

CONNECTION AVE

SUCCESS ST

 SEATTLE, WA
JUNE 24-28, 2015





Pick Your Poison

Life-saving drugs can have detrimental effects. Are you aware of which medicines can complicate vision? **By Mark T. Dunbar, OD**

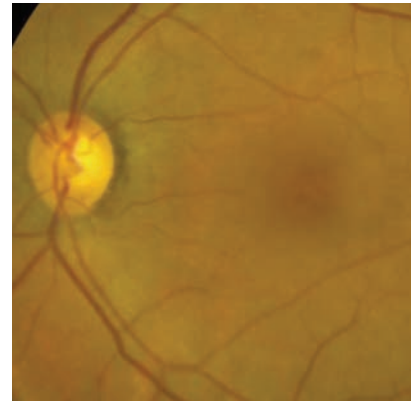
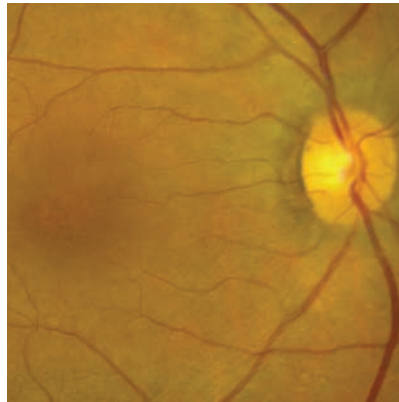
A 64-year-old Hispanic female presented with complaints of blurred vision in both eyes for approximately six months. She explained that it was difficult to focus and her vision was hazy.

Her last eye exam was approximately three years ago, and she was given glasses at that time. She felt she was seeing well until about six months ago when she noticed her vision declining.

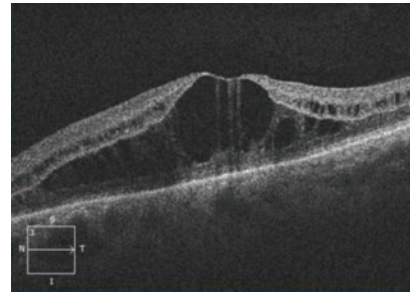
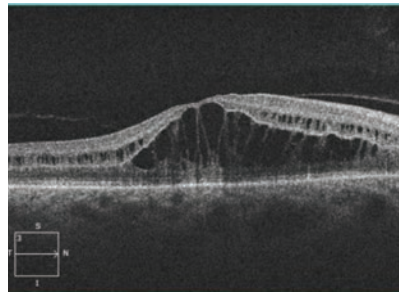
Her medical history is significant for pancreatic cancer, diagnosed seven months ago. She was on a course of chemotherapy with Abraxane (paclitaxel, Celgene) and Gemzar (gemcitabine, Eli Lilly).

On examination, her best-corrected visual acuity measured 20/80 in her right eye and 20/200 in the left. Her pupils were equally round and reactive to light; no afferent defect was seen. Confrontation visual fields were full to careful finger counting in both eyes, and ocular motility was normal. The anterior segment was significant for nuclear sclerosis in each eye. Intraocular pressure by applanation tonometry measured 17mm Hg in both eyes.

On dilated fundus exam, her optic nerves appeared healthy with small cups and good rim coloration and perfusion in both eyes. The vessels were normal caliber and her peripheral retinas were unremarkable. Of interest was the macula in each eye, which appeared thickened (see *fundus photos above*). Fundus autofluorescence (FAF),



Fundus photos (OD left, OS right) of our patient—what do you see in the macula?



SD-OCT images (OD left, OS right)—what do these reveal?

spectral domain optical coherence tomography (SD-OCT) and fluorescein angiogram (FA) were obtained (see page 104 for the FAF and FA images).

Take the Quiz

1. What does the SD-OCT show?

- Cystoid macular edema (CME).
- Vitreomacular traction (VMT) and CME.
- Neurosensory retinal detachment.
- Stage I macular hole development.

2. What do the fluorescein angiogram findings reveal?

- Diffuse retinal thickening.
- Essentially normal.
- Cystoid macular edema.
- VMT.

3. What is the correct diagnosis?

- CME
- Non-staining CME.
- Diffuse macular edema.
- VMT.

4. What is the likely etiology?

- Metastasis from her pancreatic cancer.
- Secondary to chemotherapy

medications.

- c. VMT.
- d. Idiopathic.

5. How should this patient be managed?

- a. Intravitreal anti-VEGF injection.
- b. Topical steroid/NSAID.
- c. Pars plana vitrectomy.
- d. Change/discontinue chemotherapy medications.

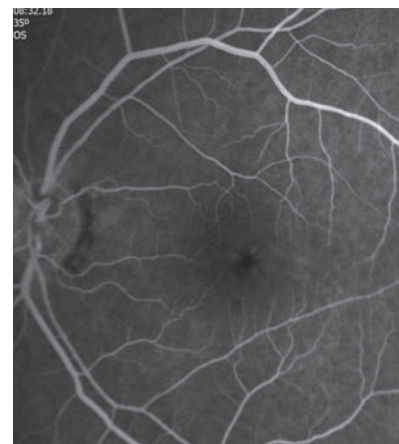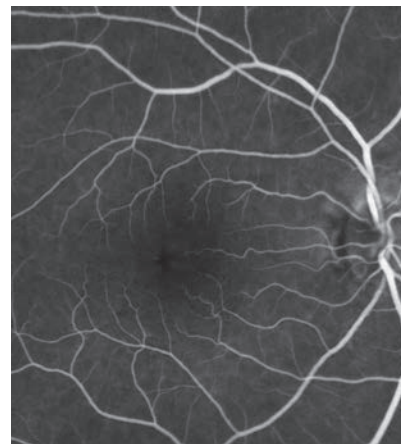
For answers, turn to page 122.

Diagnosis

It was readily apparent on the clinical exam that our patient had macular thickening due to CME. In patients with CME, it is often difficult to see the cystic changes in the macula, but in our patient they were easily visible. We ordered an SD-OCT, FAF and FA to confirm the clinical diagnosis to provide baseline information for follow-up.

The SD-OCT shows clearly visible cystoid macular edema with the individual cystic spaces clearly delineated. These are highlighted on the FAF images, which show hyper-fluorescence of the cystic spaces surrounding areas of hypo-fluorescence.

What is particularly interesting is the FA. On the FA, we expected



Late fluorescein angiogram images (OD left, OS right).

to see late staining of the cystic spaces, which is what is seen with CME. However, in our patient, no such staining exists. This “non-staining” CME is most unusual and seen in rare conditions such as juvenile X-linked retinoschisis, Goldmann-Favre syndrome and niacin toxicity.

So what is going on with our patient?

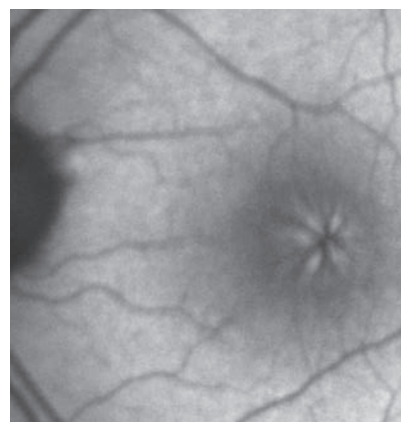
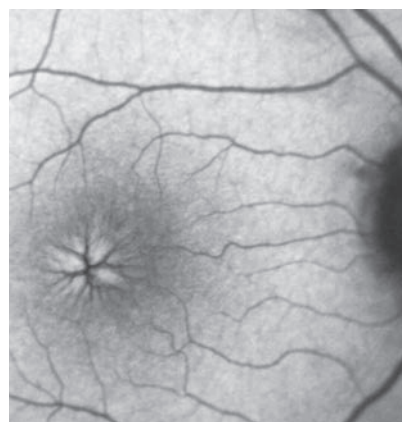
The etiology of the non-staining CME is due to one of her chemotherapy agents, likely Abraxane. Abraxane is a member of the taxane family of microtubule stabilizing agents that has demonstrated clinical efficacy in multiple human malignancies.¹ Toxic effects to bone marrow are the predominant

dose-limiting adverse effect; however, ophthalmic adverse effects include decreased vision, scintillating scotomas and abnormal visual evoked potentials.

Non-staining CME from this drug was first reported in a 2007 publication, and others have since been reported.^{1,2}

Advances in chemotherapeutic drug agents have improved survival for cancer patients. As a result, eye care providers may see more adverse ocular side effects from these antineoplastic medications. Because these side effect complications are so rare, it can be difficult to attribute ocular toxicity to a particular medication. It becomes even more difficult when patients are on combination chemotherapeutic agents, which is common in the management of cancer patients.

We explained our findings to the patient and notified her physician. Her chemotherapy medications were stopped and she was put on a different regimen. We saw her a month later and her CME had resolved and her vision improved to 20/30 in each eye. ■



Fundus autofluorescence images (OD left, OS right).

1. Joshi M, Garretson B. Paclitaxel maculopathy. Arch Ophthalmol. 2007;125:709–10.
 2. Koo N, Kim Y. A Case of Paclitaxel-induced Maculopathy treated with methazolamide. Korean J Ophthalmol. 2012 Oct;26(5):394–7.

PHILADELPHIA TASTE FOR SIGHT

*A wine tasting event benefitting the
Foundation Fighting Blindness*



You are invited

**Tuesday, June 2, 2015
6:00 P.M. ~ 9:00 P.M.**

**The Union League
The Grant Room
140 South Broad Street, Philadelphia, PA 19102**

Business attire. RSVP by Friday, May 29th.

**For questions or to register, please visit
www.FightBlindness.org/PhiladelphiaTasteforSight
or contact Katie Van Benschoten at (212) 244-1470
or KVanBenschoten@FightBlindness.org**



Wine Tasting Committee

**Ed Babin • Pam Babin • Michele Barrett • David Beccaria
Andy Grossman • Barbara Moffatt • Marie Raquet • Lou Tilley**

Please join us for a night out at The Union League where you will taste fine wines and scrumptious foods, participate in our silent and live auctions with exciting prizes and place your own stamp on retinal research history!

The Foundation Fighting Blindness, as a result of outstanding medical research and development, is on the cusp of saving and restoring sight to millions of people who are affected by retinal degenerative diseases. Thanks to generous donors like you, treatments have already begun. Please continue to help us find a cure!

20TH ANNUAL

OPHTHALMIC PRODUCT GUIDE



Innovative products to
enhance your practice

The **future**
is in your
hands. One
tap, many
possibilities.

Experience the digital edition on your handheld device.
Use your smart device to scan the code below or visit:



www.reviewofoptometry.com/supplements/

Download a QR scanner app. Launch app and hold your mobile device over
the code to view <http://www.reviewofoptometry.com/supplements>

REVIEW
OF OPTOMETRY



Give Patients a Recovery Roadmap

When you discover a pituitary tumor, the patient will turn to you to explain what comes next. Here's what to tell them. **By Joseph W. Sowka, OD, and Alan G. Kabat, OD**

A 56-year-old woman was referred for ongoing glaucoma management. She had been diagnosed with glaucoma in Jamaica five years earlier. She reported progressively worsening vision in her right eye for the past 10 years. Her best-corrected visual acuity was light perception in the right eye and 20/30 in the left. A relative afferent pupil defect was present in the right eye. She ran out of her glaucoma medication and had not instilled the drops for several months. Her intraocular pressure was 19mm Hg OD and 18mm Hg OS. Her central corneal thickness was 560 μ m and 544 μ m OD and OS, respectively. She was normal biomicroscopically, and her optic nerves demonstrated significant rim compromise bilaterally. Additionally, the remaining optic rim tissue appeared pale in each eye.

The painless progressive vision loss combined with optic disc pallor concerned us. Was something developing in addition to her glaucoma? Threshold perimetry could not be performed in her right eye due to her poor acuity. However, the results of her left eye showed a dense left vertical visual field defect. She was counseled about the implications of these findings and referred for MRI of the orbits and chiasm, which subsequently revealed a pituitary macroadenoma.

Optometrists are well versed in compressive lesions that impact the visual system. While most ODs are comfortable in recogniz-

ing the signs of chiasmal tumors and ordering the appropriate neuroimaging, it is important to understand what comes next for the patient. Once the diagnosis is made, it is incumbent upon the optometrist making the diagnosis to know the current management routine of such tumors so he or she can

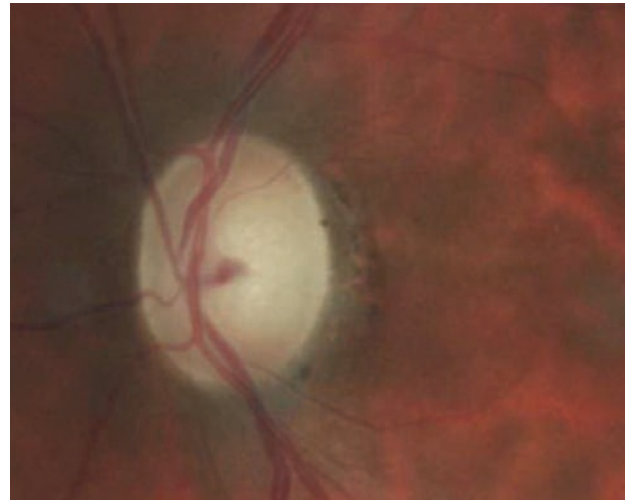
properly counsel anxious patients.

In this column, we review pituitary tumor management.

Presentation

Pituitary adenomas are common intracranial tumors. The prevalence in the general population is about 17%. Many cases are asymptomatic.¹ Pituitary tumors demonstrate a peak incidence between the ages of 30 and 60 and are considered rare in individuals younger than 20; women tend to be affected at an earlier age than men.²⁻⁴

Patients may present with visual symptoms, including diminished acuity, color desaturation, visual field loss and even diplopia if the cavernous sinus is involved.⁵ The classic visual field defect is a bi-temporal hemianopia that is denser superior than inferior, although a



A fundus image shows the eye of a 56-year-old woman with glaucoma experiencing progressive visual loss.

junctional scotoma with optic nerve involvement and visual acuity loss is also possible. Patients with pituitary adenoma may initially display a normal optic nerve, though longstanding chiasmal compression may lead to optic atrophy and disc pallor.⁵

Signs and Symptoms

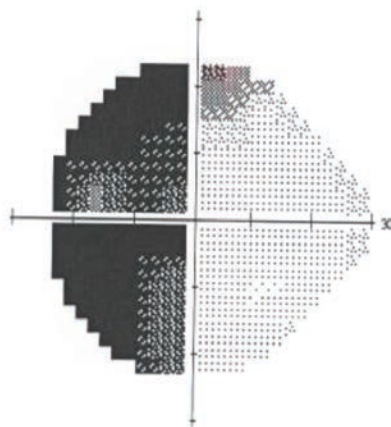
Systemic signs and symptoms can accompany pituitary adenomas. Effects of the expanding neoplasm include headache, seizures or cerebrospinal fluid rhinorrhea.⁶ Hormonal changes may also occur. Prolactinomas producing excessive levels of prolactin are the most common form of pituitary adenoma and cause amenorrhea, galactorrhea and infertility in females. Males may experience decreased libido and impotence.⁶

Tumors that secrete excess growth hormone cause gigantism in children and acromegaly in adults.^{4,6} Adrenocorticotrophic hormone (ACTH)-secreting adenomas produce Cushing's disease (hyperadrenalism).⁴ Despite this array of signs and symptoms, a significant amount of pituitary adenomas are silent and are discovered only by chance during unrelated brain imaging.^{6,7}

Pituitary adenomas are typically benign, slow-growing neoplasms of epithelial origin.⁸ In most cases, they arise from the adenohypophysis. The optic chiasm is situated approximately 8mm to 13mm above the pituitary gland. Upwardly growing pituitary tumors can impinge on the anterior notch of the chiasm at its lowest lying aspect, producing the classic bitemporal hemianopsia with increased density superiorly. Since tumor growth is usually asymmetrical, the field loss between two eyes is also typically asymmetrical. Pituitary adenomas are differentiated clinically by size and hormonal hypersecretion. Microadenomas are 10mm or less in diameter without sellar enlargement and have little impact on the visual system or gland function and may remain undetected throughout a patient's life. Macroadenomas are 10mm or larger and have the capacity to expand beyond the sella turcica and induce mass effect symptoms such as headache and visual disturbances.⁹

When It's An Emergency

Patients with known or unknown tumors may experience pituitary apoplexy. This is a potentially life-threatening infarcted or hemorrhagic expansion of a pre-existing pituitary adenoma. The accumulation of blood and edema produces a sudden increase in sella turcica



Our patient's left eye visual field. We could not perform perimetry in her right eye due to her poor acuity. However, the results of her left eye showed a dense left vertical visual field defect.

contents, compressing vessels and surrounding structures. This often results in acute, severe headache, visual loss, ophthalmoplegia, altered consciousness and potentially life-threatening diencephalic compression and hypopituitarism.

In most cases of pituitary apoplexy, the patient is unaware of the pituitary tumor. It is important to transport a patient with pituitary apoplexy to the emergency room to be stabilized with intravenous fluids and high-dose corticosteroids to replace endogenous hormone deficiency and prevent edema on parasellar structures.

Patients who do not improve will require urgent surgical decompression. Fortunately, patients with pituitary apoplexy who receive treatment fare quite well, with marked improvement in visual and neurological function.¹⁰

Treating Pituitary Tumors

Treatment modalities include surgery, radiation and medical therapy. The preferred treatment in any given case depends upon the

patient's age and health—as well as the tumor's size, invasiveness and degree of hormone production.

Medical therapy is primarily limited to prolactinomas and somatotrophic tumors. Medical therapies include dopamine agonists such as bromocriptine, cabergoline and quinagolide for hyperprolactinemia, while somatostatin analogs such as octreotide and lanreotide, and GH antagonists like pegvisomant, are used for acromegaly. The dopamine agonists, while effective, have substantial adverse effects, including nausea and vomiting, postural hypotension and dizziness, headache, constipation and depressive reactions.² Long-term use of these drugs is often intolerable.

Surgical Intervention

Pituitary tumors that cause visual effects will most likely be treated surgically, not medically or radiologically. A trans-sphenoidal approach is most often used.^{9,11} This is an in-patient procedure performed under general anesthesia. An incision is made in the buccal mucosa under the upper lip with blunt submucosal dissection along the nasal septum to the sphenoid sinus. The anterior wall of the sphenoid sinus is opened and the mucosa is removed. The anteroinferior wall of the pituitary fossa is opened and the tumor is removed. The surgical defect is packed with a graft of the patient's abdominal fat, the anterior wall of the fossa is reconstituted with bone and cartilage and the lip incision is closed.

Recently, surgery has been modified to avoid the need for an incision under the lip or in the front part of the nose. The tumor is reached by making a hole through the back of one nostril into the bottom of the skull. Through this hole,

the surgeon can see the bottom of the pituitary gland and the tumor.

The endonasal procedure reduces operating room time by as much as two hours and minimizes the discomfort associated with the surgery, allowing for a quicker recovery compared with older techniques.^{12,13}

Visual improvement following treatment is often dramatic, with the greatest degree of improvement occurring in the first few months.

Our Diagnosis

The patient was told of her diagnosis and likely treatment. Coincidentally, her sister, who accompanied her to the appointment, recognized some of our discussion and relayed that she also had a pituitary tumor and was being treated with bromocriptine. She asked if it would be acceptable to share her medicine with her sister in light of her sister's new diagnosis. She was emphatically told that such a course was unacceptable and, further, due to the visual compromise, surgery and not medications would be necessary.

The patient was referred for surgery with an understanding of the procedure and prognosis. ■

The authors would like to thank Dr. Jessica Steen for suggesting this month's topic.

1. Ezzat S, Asa SL, Couldwell WT, et al. The prevalence of pituitary adenomas: A systematic review. *Cancer*. 2004;101(3):613-9.
2. Davis JR, Farrell WE, Clayton RN. Pituitary tumours. *Reprod*. 2001;121(3):363-71.
3. Faglia G. Epidemiology and pathogenesis of pituitary adenomas. *Acta Endocrinol (Copenh)*. 1993;129(Suppl 1):S1-S5.
4. Monson JP. The epidemiology of endocrine tumours. *Endocr Relat Cancer*. 2000;7(1):29-36.
5. Kitthaweesin K, Ployprasith C. Ocular manifestations of suprasellar tumors. *J Med Assoc Thai*. 2008;91(5):711-5.
6. Chanson P, Salenave S. Diagnosis and treatment of pituitary adenomas. *Minerva Endocrinol* 2004;29(4):241-75.
7. Chanson P, Young J. Pituitary incidentalomas. *Endocrinologist*. 2003;13(2):124-35.
8. Minniti G, Esposito V, Piccirilli M, et al. Diagnosis and management of pituitary tumours in the elderly: A review based on personal experience and evidence of literature. *Eur J Endocrinol* 2005;153(6):723-35.

9. Kallsas GA, Nomikos P, Kontogeorgos G, et al. Clinical review: Diagnosis and management of pituitary carcinomas. *J Clin Endocrinol Metab*. 2005;90(5):3089-99.

10. Murad-Kejbou S, Eggenberger E. Pituitary apoplexy: evaluation, management, and prognosis. *Curr Opin Ophthalmol*. 2009;20(6):456-61.

11. Ahmed S, Elsheikh M, Stratton IM, et al. Outcome of transphenoidal surgery for acromegaly and its relationship to surgical

experience. *Clin Endocrinol (Oxf)*. 1999;50(5):561-7.

12. Ishikawa M, Ota Y, Yoshida N, et al. Endonasal ultrasonography-assisted neuroendoscopic transsphenoidal surgery. *Acta Neurochir (Wien)*. 2015 Mar 13. [Epub ahead of print].

13. Cappabianca P, Cavallo LM, Solari D, et al. Endoscopic endonasal surgery for pituitary adenomas. *World Neurosurg*. 2014;82(6 Suppl):S3-11.

VisiPlug[®] provides approximately 180 days of occlusion therapy.



The market-leading synthetic dissolvable plug for the treatment of Dry Eye caused by:

- Seasonal Allergies.....
- Contact Lens Wear.....
- Aging.....
- Medications.....
- Computer/Cell Phone Use.....
- LASIK/Refractive Surgery.....



Lacrimedics[®]

(800) 367-8327

E-mail: info@lacrimedics.com

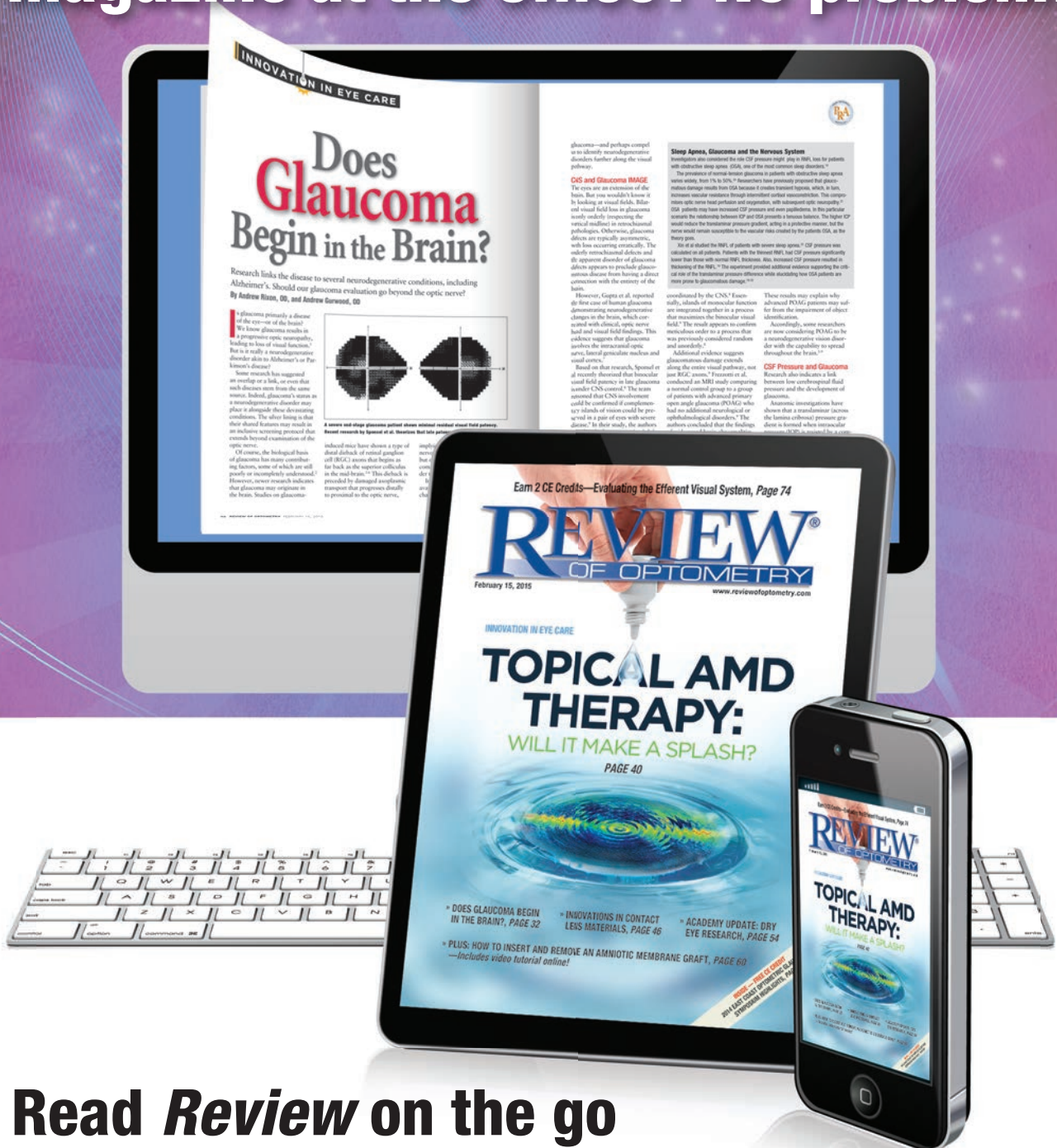www.lacrimedics.com

©2015 Lacrimedics, Inc.

Stop by booth #820 at
Optometry's Meeting, Seattle, WA



Left your *Review of Optometry* magazine at the office? No problem!



Read *Review* on the go
from any mobile device!

Just simply go to www.reviewofoptometry.com and click on the digimag link to get your current issue.



DOWNLOAD LAYAR APP
FOR INTERACTIVE EXPERIENCE



By Derek N. Cunningham, OD, and Walter O. Whitley, OD, MBA

Femto Surgery: A Cut Above?

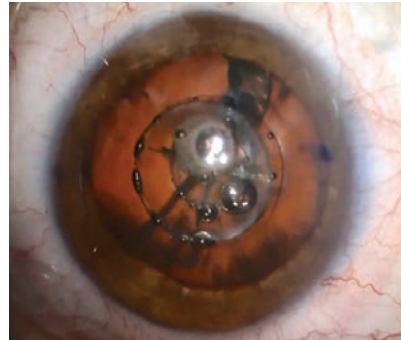
Clinicians wonder if this much-touted advance in cataract surgery has proven itself yet.

The advent of femtosecond laser cataract surgery brought a host of raised expectations about better, safer procedures. The laser can create the capsulorhexis, fragment the lens, create the clear corneal incision and help treat corneal astigmatism, allowing surgeons to rely less on manual techniques. Many optometrists who work closely with femto-equipped surgeons have seen its precision in action. But the question remains: what tangible impact has this advance had on our patients and our practices?

A Perfect Circle

Candidates for femto often include those who choose multifocal IOLs or astigmatism management with either limbal relaxing incisions or toric IOLs; the goal is to achieve post-op uncorrected visual acuities that reduce or (ideally) eliminate reliance on corrective lenses.

Despite our surgeons' exceptional talents, traditional cataract surgery may not be meeting the target standard of $\pm 0.50D$ —in fact, only 71% of procedures reach that goal.¹ Preliminary research shows that femtosecond cataract surgery, when combined with premium IOL technology, can improve these outcomes. One study found that femto cataract cases, compared with a control group, had a statistically better percentage of unaided visual acuity $>20/25$ (68.6% vs. 56.3%;



A femto-created capsulorhexis. Note the perfect uniformity of the cut.

$P < 0.0001$) and mean refractive spherical equivalent, although mean absolute error was not significant.²

In our own practice, we examined 200 patients who underwent laser cataract surgery and found that we achieved the intended target 92% of the time, which we attribute to the ability to create uniformly round and centered capsulorhexes. The capsulorhexis is a critical aspect of the cataract procedure, and a uniform size and shape allows for IOL predictability, centration and more effective lens position.

Safety Gains?

As with any new instrumentation, it is important that we evaluate and determine the impact on surgical outcomes in regards to safety.

The fragmentation of the lens with the femtosecond laser allows the surgeon to use less phacoemulsification power and phaco time, which is believed to be more gentle to the eye, reducing the likelihood of inflammation and corneal swelling. The laser creates clear corneal incisions that are well formed and water tight, reducing the extent of surgically induced astigmatism

and potentially lessening the risk of infection and hypotony. Not all of these have been conclusively borne out in the literature yet; they continue to be investigated by surgeons and comanaging optometrists. Studies have documented reduced effective phaco time, for instance, but not an associated decrease in complications as a result.

However, according to one study, the outcomes and safety of laser cataract surgery improved significantly with greater surgeon experience, development of modified techniques and technological improvements. The study evaluated one surgeon's 1,500 femto patients, comparing the first 200 cases to the subsequent 1,300 procedures. The rate of major capsular complications decreased from 7.5% to 0.6% with no cases of dropped nucleus or capsular block syndrome.³

More to Come

Many studies are underway to investigate the procedure's real-world benefits and safety. As comanaging ODs, we must educate our patients on all available cataract options and initiate the discussion of elective surgical options. Doing so demonstrates our ability to provide state-of-the-art care and serves as an opportunity to discuss our role in the pre- and post-op care. ■

1. Hill W, Behndig A, et al. Aiming for emmetropia after cataract surgery: Swedish National Cataract Register study. *J Cataract Refract Surg.* 2012;38(7):1181-6.

2. Chee SP, Yang Y, Ti SE. Clinical outcomes in the first two years of femtosecond laser-assisted cataract surgery. *Am J Ophthalmol.* 2015 Apr;159(4):714-9.

3. Roberts TV, Lawless M, Bali SJ, et al. Surgical outcomes and safety of femtosecond laser cataract surgery: a prospective study of 1500 consecutive cases. *Ophthalmology.* 2013 Feb;120(2):227-33.



To see a narrated video of this procedure, visit www.reviewofoptometry.com, or scan the QR code.

DOWNLOAD LAYAR APP
FOR INTERACTIVE EXPERIENCE



First 150 app downloads & completed forms will be entered into a drawing for FREE MEETING & REGISTRATION VALUED AT \$495

REGISTRATION OPEN!

REVIEW OF OPTOMETRY EDUCATIONAL MEETINGS OF CLINICAL EXCELLENCE



CHARLESTON, SC

JUNE 12-14

FRANCIS MARION HOTEL

387 KING STREET CHARLESTON, SC 29403

CE COURSE TOPICS:

New Developments in Cornea and Contact Lenses

Innovations in Eye Care

Management of Ocular Surface Disease

Grand Rounds in Anterior Segment Disease

Modern Management of Periocular Malignancies

Ocular Urgencies and Emergencies

Ocular Occlusive Disease

HSV, HZO, EKC: Viral Eye Disease Alphabet Soup

Beyond Glaucoma: A Primer for Retinal OCT Interpretation

NEW! Dry Eye and Glaucoma Workshops



Watch video with meeting chair, Paul Karpecki for more reasons to attend!

FACULTY

Paul Karpecki, OD
Program Chair



Doug Devries, OD



Andrew Gurwood, OD



Nathan Lighthizer, OD



Marc Myers, OD



Jack Schaeffer, OD



3 WAYS TO REGISTER

ONLINE: WWW.REVOPTOM.COM/CHARLESTON2015

EMAIL LOIS DIDOMENICO: REVIEWMEETINGS@JOBSON.COM

PHONE: 866-658-1772

Stock Image: ©iStock.com/JobsonHealthcare



Administered By
Review of Optometry®



Up to
17 CE Credits
(COPE approval pending)

FRANCIS MARION HOTEL

387 KING STREET-CHARLESTON, SC 29403

Discounted Room rate: Standard room \$239; Deluxe room \$269

Only a limited number of hotel rooms are still available - 877-756-2121

**Up to
17 CE
Credits**
(COPE approval pending)

Additional Rooms have been reserved at:

Embassy Suites Historic Charleston

337 Meeting Street, Charleston, SC 29403

Call 800.362.2779 and identify yourself as a participant

of "Review of Optometry" for group rate.

Discounted Room rate: Standard room \$309

www.revoptom.com/Charleston2015

Stock Images: ©iStock.com/JobsonHealthcare

Registration Information

Name		NPI # (NPI numbers will only be used for HCP reporting purposes)	
Practice Affiliation			
Mailing Address		City	State Zip Code
Telephone	Fax	Email	

Name Badge Information (please print clearly)

My Name	My Guest	Additional Guests
---------	----------	-------------------

Payment Information

	Rate per person	No. in party	Subtotal
OD Registration - \$495 (includes 15 hours of CE, breakfasts, reception) <small>Call for daily and student rates.</small>	\$495	x _____	= \$ _____
Additional Guest(s) - \$45 (12 years and older, includes reception)	\$45	x _____	= \$ _____
Concurrent Optional Workshop Sessions (Saturday, June 13, 2:00pm - 4:00pm) <small>Select only one if interested in additional session and credits.</small>			
Dry Eye Workshop - \$35 (Earn 2 additional CE Credits)	\$35	x _____	= \$ _____
Glaucoma Workshop - \$35 (Earn 2 additional CE Credits)	\$35	x _____	= \$ _____
		TOTAL	= \$ _____

Check enclosed (make checks payable to *Review of Optometry*)

MAIL: Review Group meetings c/o Jobson
11 Campus Blvd, Ste 100
Newtown Square, PA 19073
FAX: 610-492-1039

Charge my: American Express Mastercard Visa

Credit Card Number	Exp Date
Cardholder (print name)	
Signature	

CONFERENCE CANCELLATION POLICY

- Full refund on registration fee until April 10, 2015
- 50% refund on registration fee until June 1, 2015
- No refund past June 1, 2015

For more information or to register,
contact Lois DiDomenico at 866-658-1772
or at ReviewMeetings@Jobson.com.

MAIL FORM: Review Group Meetings c/o Jobson
11 Campus Blvd, Ste. 100
Newtown Square, PA 19073

FAX FORM: Review Meetings Group
610-492-1039



KEEP YOUR EYE ON NEW ORLEANS



SAVE THE DATE!
October 7 – 10, 2015



ACADEMY
2015
NEW ORLEANS



The Academy meeting is traveling to the culturally and historically rich city of New Orleans for four days of exceptional education. Join us for another year of research-based and clinically relevant CE, top-notch speakers, captivating papers and posters, and memorable social events. We hope to see you there!

New Orleans Convention Center



October 7 – 10, 2015

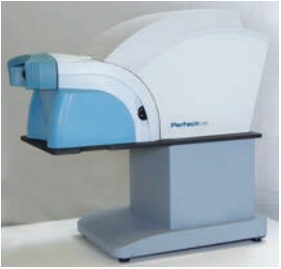Registration and housing now open! www.aaopt.org/regsite

Product Review

Diagnostic Equipment

New Refractor/Autorefractor

A new diagnostic instrument combines wavefront autorefractometry and subjective refraction in one space-saving unit, according to Vmax Vision.



The Perfectus raises the gold standard from 20/20 to 20/12 and, in many cases, can be achieved in less than one minute per eye, the company says.

The Perfectus measures a patient's subjective visual response to a point spread function target, enabling

a highly precise refraction to 0.05D—five times more precise than a traditional phoropter, the company says. The refraction corrects for higher-order aberrations and helps prevent over-minus in prescriptions.

Visit www.vmaxvision.com.

Phoropter Digital Refraction System

A new phoropter digital refraction system offers fast and quiet lens exchanges, as well as motorized prism compensators and a split cylinder lens to improve testing time for astigmatic correction, according to Reichert Technologies.

The logically arranged keypad and knob, coupled with an intuitive user interface and tilting touchscreen, provide the flexibility to easily access any tests during the exam process. The system also offers integration with both EMR and pre-test equipment, the company says.

Visit www.reichert.com.



Contact Lenses

Progressive Lenses for Digital Eye Strain

Your patients with presbyopia who use digital devices can combat the symptoms of digital eyestrain with a new family of progressive lenses, introduced by Zeiss.

The new lenses account for both the shorter reading distance and increased convergence common when using digital devices, so wearers have a clear and comfortable view of a digital screen, Zeiss says. The new family includes Precision Pure, Precision Plus, Precision Superb and an upgrade to the Individual 2.

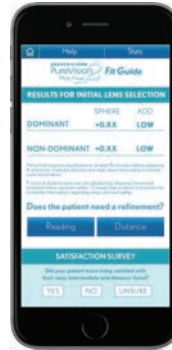
Visit www.zeiss.com/vision.

Contact Lens Technology

App for Fitting Multifocal Contact Lenses

Fitting patients with PureVision2 contact lenses for

Presbyopia just became a little easier with the new PureVision2 Multifocal Fit Guide mobile app from Bausch + Lomb. The app enables you to calculate the initial lens selection by entering the patient's sphere and cylinder information, including add, based on their most recent refraction, according to the company. Following evaluation, you can determine if further refinement is needed, and the app will provide you feedback and an updated lens recommendation.



It will be extended later this year to include Biotrue Oneday contact lenses for presbyopia.

Visit www.bausch.com.

Mobile Contact Lens Ordering

Some New York and California optometry practices can now offer patients the option of ordering contact lenses for home delivery through a mobile device with WebSystem3's LensFerry service.

The service includes contact lenses from all manufacturers at your practice's specified prices, and you receive the sales revenue as if they had been ordered in-office, the company says. All communications are customized for each practice, and you can send the wearer custom-branded email and text reorder reminders through the service, according to WebSystem3.

WebSystem3 plans to introduce the service to additional geographic markets over the coming months.

Visit www.LensFerry.com.

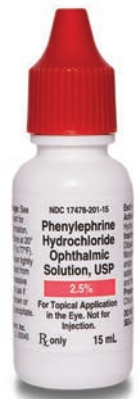Dilating Solution

Phenylephrine HCl Ophthalmic Solution

A new ophthalmic solution for pupil dilation that is shelf-stable and does not require refrigeration has hit the market. Akorn launched phenylephrine HCl ophthalmic solution 2.5% and 10%, after receiving the product's New Drug Application (NDA) approval from the FDA in January.

Phenylephrine hydrochloride ophthalmic solution 2.5% is available in 2ml and 15ml fill sizes. The 10% solution is available as a 5ml fill size.

Visit www.akorn.com.



Meetings + Conferences

May 2015

■ **15-17.** *Arizona Optometric Association 2015 Spring Congress.* Hilton Tucson El Conquistador Golf & Tennis Resort, Tucson, AZ. Hosted by: Arizona Optometric Association. To register, go to: <http://arizona.aoa.org>.

■ **29-31.** *CE 2015.* University of Waterloo School of Optometry and Vision Science, 200 Columbia Street West, Waterloo, Ontario, Canada. Hosted by: University of Waterloo School of Optometry and Vision Science. CE Hours: 19. To register, go to <http://uwaterloo.ca/optometry>.

June 2015

■ **5-7.** *June "Summer" Conference.* Harborside Hotel & Marina, Bar Harbor, ME. Hosted by: Maine Optometric Association. To register, call (207) 288-5033 or toll-free (800) 328-5033.

■ **12-14.** *2015 Annual Meeting.* Myrtle Beach, SC. Hosted by: North Carolina State Optometric Society. To register, email Adrienne Drollette at adrienne@nceyes.org.

■ **19-21.** *2015 VOA Annual Conference.* Hilton, McLean, VA. Hosted by: Virginia Optometric Association. To register, call Bo Keeney at (804) 643-0309.

■ **24-28.** *Optometry's Meeting 2015.* Washington State Convention Center, Seattle, WA. Hosted by: American Optometric Association and American Optometric Student Association. To register, go to <http://optometrismeeing.org>.

■ **26-July 5.** *A Comprehensive Update on Contemporary Eye Care.* Northern European Capitals Cruise, departs Copenhagen, Denmark. Hosted by: Dr. Travel Seminars/The New Jersey Society of Optometric Physicians. Key Faculty: Randall Thomas. CE Hours: 12. To register, email Robert Pascal at info@DrTravel.com or go to DrTravel.com.

July 2015

■ **4-11.** *Tropical CE Puerto Rico.* El Conquistador-Waldorf Astoria, Puerto Rico. Hosted by: Tropical CE. Key Faculty: Jimmy Bartlett, Kim Reed. CE Hours: 20. To register, call Stuart Autry at (281) 808-5763, email sautry@tropicalce.com or go to www.tropicalce.com.

■ **10-12.** *21st Conference on Clinical Vision Care.* Southern College of Optometry, Memphis, TN. Hosted by: OEP Foundation. CE Hours: 17. To register, email Theresa Krejci at theresakrejciOEP@verizon.net or go to www.oepf.org.

■ **16-19.** *2015 Victoria Conference.* Inn at Laurel Point, Victoria, British Columbia, Canada. Hosted by: Pacific University. Key Faculty: Terry Burriss, Danica Marelli, Curtis Baxstrom, Tad Buckingham. CE Hours: 20. To register, go to www.pacificu.edu.

■ **16-19.** *Florida Optometric Association Annual Convention.* The Breakers, Palm Beach, FL. Hosted by: Florida Optometric

Association. Key Faculty: William Marcolini, Ian Gaddie, Mark Dunbar, Christian Guier, Paul Palmber, April Jasper. CE Hours: 30 Total, 22 per OD. To register, call Jessica Brewton at (805) 877-4697, email jessica@floridaeyes.org or go to www.floridaeyes.org.

■ **17-18.** *OOPA Summer CE Event.* The Resort at the Mountain, Welches, OR. Hosted by: Oregon Optometric Physicians Association. Key Faculty: Gordon Johns, Beth Kinoshita, Lorne Yudcovitch, Rebecca Uhlig, Robert Egan, Stan Teplick. CE Hours: 13. To register, email Lynne Olson at lynne@oregonoptometry.org or go to www.oregonoptometry.org.

■ **22-25.** *Northern Rockies Optometric Conference.* Snow King Hotel, Jackson, WY. Hosted by: Northern Rockies Optometric Conference. Key Faculty: Ben Gaddie, Mark Dunbar, Rebecca Wartman. CE Hours: 16. To register, email Kari Cline at director@nrocmeeting.com, or go to www.nrocmeeting.com.

■ **23-26.** *New Technologies and Treatments in Vision Care.* Wailea Beach Marriott Resort & Spa, Wailea, HI. Hosted by: Review of Optometry. Key Faculty: Paul Karpecki, Brad Sutton, Randall Thomas, Ron Melton. CE Hours: 14. To register, email Lois DiDomenico at ReviewMeetings@jobson.com, call (866) 658-1772 or visit www.reviewofoptometry.com.

■ **23-26.** *CE in the Rockies.* Rocky Mountain Park Inn, Estes Park, CO. Hosted by: University of Houston College of Optometry. Key Faculty: Danica Marrelli. CE Hours: 21. To register, email optce@uh.edu, call (713) 743-1900 or go to www.ce.opt.uh.edu.

■ **26-Aug. 2.** *Getting Comfortable with Retinal Care: An Optometric View.* Alaska Glacier Bay Cruise, departs Seattle, WA. Hosted by: Dr. Travel Seminars/The New Jersey Society of Optometric Physicians. Key Faculty: Diana Shechtman. CE Hours: 16. To register, email Robert Pascal at info@DrTravel.com or go to DrTravel.com.

■ **31-Aug. 2.** *Southwest Florida Educational Retreat.* South Seas Island Resort, Ft. Myers, FL. Hosted by: Southwest Florida Optometric Association. Key Faculty: Jimmy Bartlett, Tammy Than, Ron Foreman. CE Hours: 18. To register, email Brad Middaugh at swfoa@att.net or go to www.swfoa.com.

■ **31-Aug. 2.** *Colorado Vision Summit.* Crown Plaza DIA, Denver. Hosted by: Colorado Vision Summit. Key Faculty: John Neal, John Winton, Doug Devries, Dominick Maino. CE Hours: 40 Total, 17 per OD. To register, email Lindsay Wright at lwright@visioncare.org or go to www.visioncare.org.

August 2015

■ **3-10.** *AEA Cruises Baltic Cruise Seminar.* Silversea Silver Whisper, departs Copenhagen. Hosted by: AEA Cruises. Key Faculty: Louise Sciafani. CE Hours: 10. To register, email

Advertisers Index

For advertising opportunities contact:

Michele Barrett (215) 519-1414 or mbarrett@jobson.com

James Henne (610) 492-1017 or jhenne@jobson.com

Michael Hoster (610) 492-1028 or mhoster@jobson.com

Marge McGrath at aeacruises@aol.com or go to www.optometriccruiseseminars.com.

■ **6-10.** *Art & Science of Optometric Care—A Behavioral Perspective.* Michigan College of Optometry, Big Rapids, MI. Hosted by: OEP Foundation. Key Faculty: Robert A. Hohendorf. CE Hours: 35. To register, email Theresa Krejci at TheresaKrejciOEP@verizon.net or go to www.oepf.org.

■ **14-16.** *1st World Congress of Optometry.* Plaza Mayor Convention and Exhibition Centre, Medellin, Columbia. Hosted by: The World Council of Optometry and La Federación Colombiana de Optómetras. To register, go to www.worldcongressofoptometry.org.

■ **15-16.** *IU Cornea & Contact Lens Conference.* IU School of Optometry. Bloomington, IN. Hosted by: IU School of Optometry. Key Faculty: Jason Jedlicka, Pete Kollbaum, Sue Kovacich, Tony Van Alstine, Carolyn Begley. CE Hours: 14. To register, email Cheryl Oldfield at coldfiel@indiana.edu or go to www.opt.indiana.edu/ce/seminars.htm.

■ **16-17.** *Glaucoma: Grand Rounds.* Marshall B. Ketchum University, Fullerton, CA. Hosted by: SCCO at MBKU. Key Faculty: George Comer, John Nishimoto, Mark Sawamura, Judy Tong. CE Hours: 16. To register, email ce@ketchum.edu or go to www.ketchum.edu/ce.

■ **19.** *AAO-NJ Conference.* Jumping Brook Country Club, Neptune, NJ. Hosted by: American Academy of Optometry New Jersey Chapter. CE Hours: 6. To register, email Dennis Lyons at Dhl2020@aol.com or call (732) 920-0110.

■ **20-23.** *108th SCOPA Annual Meeting.* Westin Hilton Head Island Resort and Spa, Hilton Head Island, SC. Hosted by: SC Optometric Physicians Association. CE Hours: 21. To register, email Jackie Rivers at jrivers@sceyedocitors.com, call (803) 799-6721 or go to www.sceyedocitors.com.

■ **27-29.** *International Vision Conference.* Hyatt Manchester, San Diego. Hosted by: OD Excellence and PFO Global. Key Faculty: John McGreal, Jim Grue, Bob Schultz, Jim Riverson, Nathan Lightizer. CE Hours: 17. To register, go to www.ivisionconf.org.

■ **28-30.** *Alumni Weekend.* UAB School of Optometry, Birmingham, AL. Hosted by: UAB School of Optometry. Key Faculty: Ian Gaddie, Marie Bodack, Diana Shechtman, Scot Morris, Sunny Sanders. CE Hours: 18. To register, email Katherine Clore at kclore@uab.edu, call (205) 934-5700 or go to www.uab.edu/optometry.

To list your meeting, please send the details to:

Rebecca Hepp, Senior Associate Editor

Email: rhepp@jobson.com

Phone: (610) 492-1005

Akorn Consumer Health 35 Phone (800) 579-8327 www.akorn.com	NovaBay Pharmaceuticals, Inc. 69 Phone (800) 890-0329 sales@avenova.com www.avenova.com
Alcon Laboratories 19, 124 Phone (800) 451-3937 Fax (817) 551-4352	Oculus, Inc. 73 Phone (888) 284-8004 Fax (425) 867-1881
Allergan, Inc. 9, 10, 15 Phone (800) 347-4500	Ocusoft 45 Phone (800) 233-5469 Fax (281) 232-6015
Bausch + Lomb 39 Phone (866) 246-8245 www.bausch.com	Odyssey Medical (now part of Beaver-Visitec International, Inc.) 29 Phone (866) 906-8080 www.odysseymed.com
Bausch + Lomb 23, 24, 31 57, 58, 123 Phone (800) 323-0000 Fax (813) 975-7762	Regeneron Pharmaceuticals, Inc. 51 Phone (914) 847-7000 www.regeneron.com
Bruder Ophthalmic Products 71 Phone (888) 827-8337 eyes@bruderophthalmic.com	Reichert Technologies 49 Phone (888) 849-8955 Fax (716) 686-4545 www.reichert.com
CooperVision 7, 95 Phone (800) 341-2020	Reliance Medical 63 Phone (800) 735-0357 Fax (513) 398-0256
Haag-Streit 5, 66 Phone (800) 627-6286 Fax (603) 742-7217	Shire Ophthalmics 55 www.shire.com
Icare USA 41 Phone (888) 389-4022 www.icare-usa.com	SynergEyes, Inc. 42 Phone (877) 733-2012 Marketing@SynergEyes.com www.SynergEyes.com
Keeler Instruments 11 Phone (800) 523-5620 Fax (610) 353-7814	TearLab Corporation 21 Phone (888) 677-8327 Fax (858) 812-0540
Lacrimedics, Inc 17 Phone (800) 367-8327 Fax (253) 964-2699 info@lacrimedics.com www.lacrimedics.com	TelScreen 75 www.TelScreen.com DryEye@TelScreen.com
Lacrivera 77 Phone (855) 857-0518 www.lacrivera.com	Veatch 27 Phone (800) 447-7511 Fax (602) 838-4934
Lombart Instruments 93 Phone (800) 446-8092 Fax (757) 855-1232	Vision Source 60 Phone (281) 312-1111 Fax (281) 312-1153 www.visionsource.com
M&S Technologies 52 Phone (877) 225-6101 Fax (847) 763-9170	Vistakon 2-3, 37 Phone (800) 874-5278 Fax (904) 443-1252
MediNiche 47 Phone (888) 325-2395 info@mediniche.com www.mediniche.com	
Menicon 12 Phone (800) MENICON information@menicon.com www.meniconamerica.com	

This advertiser index is published as a convenience and not as part of the advertising contract. Every care will be taken to index correctly. No allowance will be made for errors due to spelling, incorrect page number, or failure to insert.

Merchandise Offered

NEW!
MODULAR SOLUTIONS
FOR EVERY PART
OF YOUR PRACTICE



Optical Dispensary



Pre-Testing / Eye Exam Room



Contact Lens Room



Business Office

frame displays.com

An Essilor Company

1-877-274-9300



Software

Take a closer look...
at EyeCom for your electronic health record needs!

tablet compliant
share patient data securely
over 25 years experience
cloud-based access anytime, anywhere



EyeCom³ EHR
WEB-BASED OPTOMETRIC SOFTWARE

800.788.3356 www.eyecom3.com



QuikEyes Optometry EHR

- \$198 per month after low cost set-up fee
- Quick Set-Up and Easy to Use
- No Server Needed
- Corporate and Private OD practices
- 14 Day Free Demo Trial
- Email/Text Communications

www.quikeyes.com

Merchandise Offered

EYEDESIGNS

BUILDING YOU A BETTER BUSINESS

SPACE PLANNING

INTERIOR DESIGN

DISPLAY INNOVATION

MANUFACTURING

WWW.EYEDESIGNS.COM

800.346.8890



FREE GIFT for the first 25 people to contact us.
Ref code OPT0515 exp. 05/31/15



**FORM
FUNCTION**

Style

opticaldisplays.com™

INFO@OPTICALDISPLAYS.COM TO REQUEST OUR CATALOG & DESIGN SERVICES CALL 610.489.7620

FREE GIFT for the first 25 people to contact us. Ref code: OPT0515 exp. 05/31/15

Continuing Education

EYE-SIGHT 20/20, Inc.
Presents Spring 2015

Saturday/Sunday, June 6-7, 2015
16 hours of Advanced COPE Approved CE for Optometrists

Our Respected Presenters:
JEROME SHERMAN, OD, FAAO
SHERRY BASS, OD, FAAO
JIMMY BARTLETT, OD, FAAO
ANTHONY LITWAK, OD, FAAO

Join US.

"Where Doctors Gather to Share Knowledge & Experience"

FOXWOODS CASINO- Ledyard, CT
Contact:
Dr. Antoinette D. Parvis 508-987-9679
or visit the website for all details:

www.eyesightce.com

Upcoming Events
All 8 hours in Natick, Mass
April 19th
Sept 27th
Oct 18th
and Nov 15th

Dr. Travel SEMINARS, LLC
In Partnership With The NJ Society of Optometric Physicians

New Year's Seminar Cruise

Special Pricing & Beverage Package Included

NCL Spirit - Sailing From Orlando (Port Canaveral) FL - W. Caribbean Cruise
December 26, 2015 - January 2, 2016

Deluxe Ship



All Programs Are in Partnership With the New Jersey Society of Optometric Physicians



Celebrating 20 years

Special Group Pricing



Dr. TRAVEL SEMINARS, LLC is a COPE approved provider

Continuing Education

OD Success Through Clinical Excellence - by Edward Paul, Jr., OD, Ph.D.

Additional Seminar Cruises (12-16 C.E.):

Alaska Glacier Bay Cruise - July 26 - Aug. 2, 2015 - D. Shechtman, OD, FAAO

President's Week - Feb. 13 - 20, 2016 - RCCL's Oasis - R. Wooldridge - OD, FAAO

Mediterranean Cruise - July 3 - 10, 2016 - Leo Semes, OD, FAAO

Danube River Cruise - July 24 - 31, 2016 - Ron Melton, OD, FAAO

www.DrTravel.com

800-436-1028

Certification



Put
your vision

to work for you.

Become Board Certified by the
**AMERICAN BOARD
OF OPTOMETRY**



Exam held each January & July

Register at americanboardofoptometry.org

The American Board of Optometry Board Certification program is certified by the National Commission for Certifying Agencies, and its Maintenance of Certification process is approved by the Centers for Medicare and Medicaid Services.

Continuing Education

**FOUNDATION FOR
OCULAR HEALTH**

20th Annual Key West Educational Conference
August 7th & 8th, 2015

FRIDAY, AUGUST 7, 2015

KENNETH W. LAWSON, O.D.
*Medical Record Audit Results-
Where Do We Go From Here?*
1 Hr CE

JOHN MCSOLEY, O.D.
*Foundations for Building
Solid Glaucoma Care*
2 Hr CE/TQ
*Glaucoma Case Discussions
(and Things I Learned From Them)*
2 Hr CE/TQ

SATURDAY, AUGUST 8, 2015

STEVE HOLBROOK, O.D.
Clinical Updates 2015
2 Hr CE/TQ

IAN BEN GADDIE, O.D.
Lid Margin All Stars
Featuring: MGD and Demodex
2 Hr CE/TQ

CASA MARINA

THE WALDORF ASTORIA COLLECTION
1500 Reynolds Street
Key West, FL 33040
1.888.318.4237

For more information contact:
Gloria Ayan @ 786.405.9723
E-Mail: ocularhealthfoundation@gmail.com

9 CE Hours / 8 TQ

Equipment and Supplies



It's What the Best
Pretest on!
(800) 522-2275
www.optinomics.com
sales@optinomics.com

SOFT CONTACTS • SOFT PRICES
Bradford Optical, Inc.

800.435.5535

www.BradfordOpticalInc.com

Practice For Sale

**PRACTICE SALES
& APPRAISAL**

Expert Services for:

- ✓ **Buying or Selling a Practice**
- ✓ **Practice Appraisal**
- ✓ **Practice Financing**
- ✓ **Partner Buy-in or Buy-out**

Call for a Free Consultation
(800) 416-2055
www.TransitionConsultants.com

PRACTICE FOR SALE - Williston, ND

Excellent corporate based optometric practice available for complete buy-out. The practice is located in the middle of North Dakota's oil boom in Williston, ND.

The practice is a side by side environment and a turn-key opportunity. No immediate capital improvements needed. Current owner doctor will assist with the transfer of lease to the new owner. High net to gross ratios with excellent free cash flows available after debt service.

This is not a partnership situation, but owner looking for complete sale. Owner doctor relocating and will assist with the transition.

Please send serious inquires to Amanda M. Lee OD at dr.amanda.lee@gmail.com or 971-404-7853.

Place Your Ad Here!

Toll free: 888-498-1460

E-mail: sales@kerhgroup.com

Career Opportunities / Continuing Education / Practice For Sale / Products and Services

Medical Facility Optometrists

The American Board of Certification in Medical Optometry is utilized at accredited medical facilities to verify specialist-level competence in medical optometry. ABCMO certifies specialized competence of a higher level than that required for licensure and general practice.

Visit www.abcmo.org to learn why medical facilities require board certification of specialists and why only ABCMO board certification in the specialty of medical optometry is accepted. Questions? myers.kenj@gmail.com.

NOTICE: After August 1, 2003, all applicants for ABCMO board certification must have completed an ACOE residency in medical optometry and passed the Advanced Competence in Medical Optometry examination of the NBEO.



www.abcmo.org

Scientia est Potentia



ASSOCIATE OPTOMETRIST

LAREDO, TEXAS

5000-sq.ft, state-of-the-art facility with an emphasis on contact lenses and pathology.

New Grads Welcome!

EXCELLENT starting salary and benefit package:

- SIX-FIGURE starting salary
- Three weeks of paid time off.
- Paid medical, dental, vision and malpractice insurance
- Paid continuing education with one week off paid
- Paid major holidays
- Paid relocating expense

Our office hours are terrific for our industry! Opportunities for career development are also available.

Please email your resume and/or inquiry to
Dr. Paul K. Tran at contact@tranvisioncenter.com.

STAFF OPTOMETRIST

Bard Optical is a leading Midwest vision care organization in business for over 70 years and we are still growing. The company is based in Peoria, IL with 20 retail offices throughout the central Illinois area, as far north as Sterling and as far south as Jacksonville. Once again this year we were named to the Top 50 Optical Retailers in the United States by Vision Monday – currently ranking 37th. A progressive optometric staff is vital to the continued growth of our organization whose foundation is based on one-on-one patient service. We are currently accepting CV/resumes for optometrists focused on full scope primary medical patient care. The candidate must have an Illinois license with therapeutics. The practice includes (but is not limited to) general optometry, contact lenses, and geriatric care. Salaried, full-time positions are available with excellent growth programs and benefits. Some part-time opportunities may be available also. Please email your information to hr@bardoptical.com or fax to 309-693-9754. Mailing address if more convenient is Bard Optical, Attn: HR, 8309 N Knoxville Avenue, Peoria, IL 61615. Ask about opportunities within Bard Optical. *We have openings in several existing and new offices opening soon in central Illinois.*

Bard Optical is a proud Associate Member of the Illinois Optometric Association.



www.bardoptical.com

Here we grow again!

TWO MOTIVATED OPTOMETRISTS ILLINOIS

One of the largest eye care providers to extended care and assisted living residents in our great state of Illinois needs two motivated Optometrists to join our practice!

Both positions are in the Springfield and Central Illinois areas. One position is full time and one position is part time.

Our physicians are proficient in refracting, diagnosing & treating ocular pathology, and dispensing spectacles on-site. If you are proficient in these areas and you are comfortable driving, here are your benefits: Excellent Pay + bonuses (=145K+), travel bonuses that will exceed expenses incurred, new optical equipment, a personal assistant, but most important helping people in need of our professional services.

Interested? Contact Michael at
Michael@ovitskyvisioncare.com
or at 773-588-3090.

Only serious inquiries please. We will help with relocation expenses, if necessary.



Practice Sales • Appraisals • Consulting
www.PracticeConsultants.com

PRACTICES FOR SALE NATIONWIDE

Visit us on the Web or call us to learn more about our company and the practices we have available.

info@PracticeConsultants.com

800-576-6935

www.PracticeConsultants.com

PACKAGE DEAL

EAST CENTRAL FLORIDA, long established optometric practice located in 100 year old historic building.

PRACTICE GROSS 276K.

Building worth about 150k.

Will sell both for 189k or practice alone for 79k.

I'M RETIRING AND MOTIVATED.

For more info email

floridapractice@yahoo.com.

ACCESS HEALTHCARE CAPITAL

The key to making Professional Healthcare Practice Financing simple. Whether you are buying, starting, or updating your practice, Access Healthcare capital is here to help you with your financing needs with one common goal. We want to help you maximize your cash flow. Let us help you unleash your Entrepreneurial Spirit:

Easy App Up To \$250,000

- 100% Financing plus working capital
- Simplified Processing for loans up to \$350,000
- Partnership Buy-In Programs
- Terms up to 15 years
- Application Only for equipment and technology purchases

www.accesshealthcarecapital.com • info@narxeye.com

Access Healthcare Capital • 1-888-727-4470 • P.O. Box 349, Gladwyne, PA 19035



The Loitering Lump

By Andrew S. Gurwood, OD

History

A 55-year-old Cambodian female reported to the office with a chief complaint of decreased vision at near in both eyes. Her ocular history was unremarkable.

Her systemic history was remarkable for a lump in her neck, which was biopsied four years earlier.

She stopped going to the doctor when she became scared following the diagnosis of cancer.

She takes no medications and denies allergies of any kind.

Diagnostic Data

The patient's best-corrected entering visual acuities were 20/20 in both eyes at distance and near through her PL/+2.50 bifocals. Refraction was stable with negligible differences.

The pertinent external examina-



This 55-year-old patient has a cancer diagnosis, but no remarkable ocular history. Now, she's presenting with decreased vision at near in both eyes. Can you offer a diagnosis?

tion is demonstrated in the photograph (left).

The biomicroscopic examination of the anterior segment was normal. Goldmann applanation tonometry measured 13mm Hg in both eyes. The dilated fundus findings uncovered normal posterior poles, normal nerves and maculae with normal peripheral grounds.

Your Diagnosis

Does this case require any additional tests? What is your diagnosis? How would you manage this patient? What do you think is the likely prognosis?

To find out, please visit *Review of Optometry* online at www.reviewofoptometry.com. Click on the cover icon for this month's issue and select "Diagnostic Quiz" from the table of contents. ■

Retina Quiz Answers (from page 103): 1) a; 2) b; 3) b; 4) b; 5) d.

Next Month in the Mag

June will be *Review of Optometry's* Annual Retina Report. Topics in our retina coverage include:

- *EDI-OCT For Better Chorioretinal Exams*

This new application of OCT technology helps doctors visualize the choroid to better diagnose posterior segment problems.

- *Make Ocular Nutrition and Retinal Wellness a Priority*
Practical advice on how to incorporate promotion of healthy living into your patient work-up to prevent or limit retinal disease.

- *Optometric Study Center: Sizing Up Retinal Tears, Breaks and Holes* (earn 2 CE credits)

You don't need to be a retinal specialist to recognize structural damage. This CE course walks you through typical presentations.

Also in June, look for these notable feature articles:

- *Slit Lamp Essentials: Yes, ODs Can Perform YAG Capsulotomy*
- *Spectacle Dispensing: Savvy Tips to Avoid Remakes*
- *Improving Aesthetics with Oculoplastic Efforts: An OD's Guide*

REVIEW OF OPTOMETRY (ISSN 0147-7633) IS PUBLISHED MONTHLY, 12 TIMES A YEAR BY JOBSON MEDICAL INFORMATION LLC, 100 AVENUE OF THE AMERICAS, NEW YORK, NY 10013-1678. PERIODICALS POSTAGE PAID AT NEW YORK, NY AND ADDITIONAL MAILING OFFICES. POSTMASTER: SEND ADDRESS CHANGES TO REVIEW OF OPTOMETRY, PO BOX 81, CONGERS, NY 10920-0081. SUBSCRIPTION PRICES: US: ONE YEAR \$56; TWO YEARS \$97, CANADA: ONE YEAR \$88, TWO YEARS \$160, INT'L: ONE YEAR \$209, TWO YEARS \$299. FOR SUBSCRIPTION INFORMATION CALL TOLL-FREE (877) 529-1746 (USA); OUTSIDE USA, CALL (845) 267-3065. OR EMAIL US AT REVOPTOMETRY@CAMBEYWEST.COM. PUBLICATIONS MAIL AGREEMENT NO: 40612608. CANADA RETURNS TO BE SENT TO BLEUCHIP INTERNATIONAL, P.O. BOX 25542, LONDON, ON N6C 6B2.

Best-in-class properties for best-in-class performance¹

Bausch + Lomb ULTRA[®] contact lenses with MoistureSeal[®] technology combine best-in-class physical properties for a revolutionary silicone hydrogel lens.¹

	Dk/t	MODULUS	ASPHERIC OPTICS	THIN EDGE DESIGN
Bausch + Lomb ULTRA [®] contact lenses	163	70	✓	✓
ACUVUE OASYS	147	73		✓
AIR OPTIX AQUA	138	102		
Biofinity	160	82	✓	

Patient preferred for end-of-day comfort over the leading silicone hydrogel lenses²

2 to 1
vs.
ACUVUE OASYS

3 to 1
vs.
AIR OPTIX AQUA

4 to 1
vs.
Biofinity

Retains moisture for a full 16 hours.¹



Go to www.blultra.com or contact a Bausch + Lomb sales representative today

REFERENCES: 1. Data on file. Bausch & Lomb Incorporated. Rochester NY; 2013. 2. Results from a 22-investigator, multi-site study of Bausch + Lomb Ultra contact lenses with MoistureSeal technology, on 327 current silicone hydrogel lens wearers. After 7 days of wear, subjects completed an online survey. Subjects rated performance across a range of attributes. Preference comparisons represent only those subjects expressing a preference. Ratio is based on the average across the silicone hydrogel lenses represented in the study.

®/™ are trademarks of Bausch & Lomb Incorporated or its affiliates. All other product/brand names are trademarks of their respective owners. ©2014 Bausch & Lomb Incorporated. US/ZUS/14/0149

BAUSCH + LOMB
See better. Live better.

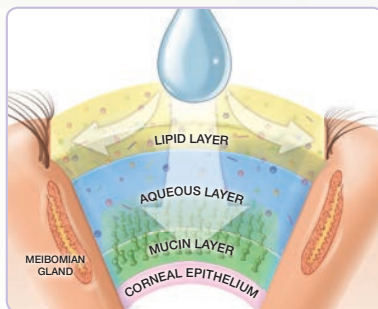
For the 75% of dry eye patients worldwide with evaporative dry eye (MGD) symptoms¹...

DRY EYE CAN BE RELENTLESS

CALM THE STORM WITH LASTING RELIEF

SYSTANE® BALANCE Lubricant Eye Drops:

Protecting the Ocular Surface by Increasing Lipid Layer Thickness (LLT)



SYSTANE® BALANCE Lubricant Eye Drops forms a protective matrix that is designed to replenish the lipid layer for long-lasting relief from the symptoms associated with evaporative dry eye (MGD). This unique formulation is designed to work on all 3 layers of the tear film, specifically increasing LLT. This helps create a protective environment for the ocular surface.²

SYSTANE® Brand products are formulated for the temporary relief of burning and irritation due to dryness of the eye.

References: 1. Akpek EK, Smith RA. Overview of age-related ocular conditions. *Am J Manag Care*. 2013;19 (5 suppl):S67-S75. 2. Korb DR, Blackie CA, Meadows DL, Christensen M, Tudor M. Evaluation of extended tear stability by two emulsion based artificial tears. Poster presented at: 6th International Conference on the Tear Film and Ocular Surface: Basic Science and Clinical Relevance; September 22-25, 2010; Florence, Italy.

Your recommendation counts.

Make sure your patients get the lasting symptom relief they need by offering them SYSTANE® BALANCE Lubricant Eye Drops.²



Alcon
a Novartis company

© 2014 Novartis 05/14 SYS14005JAD-B

Systane
Family of Products

Relief that lasts