

REVIEW[®] OF OPTOMETRY

April 15, 2015

www.reviewofoptometry.com

CORNEAL DISEASE
REPORT

EARN 2 CE CREDITS

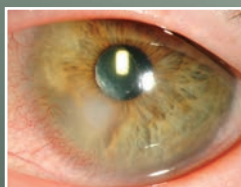
Corneal Harbingers OF SYSTEMIC DISEASE

A routine slit lamp exam may reveal telltale findings of health concerns elsewhere in the body. Here are the most common to look for. **PAGE 53**

» **Firm Up Your Approach to Corneal Ectasia**, **PAGE 28**

» **Slit Lamp Essentials: Perform DBD with ASP for Stubborn RCE**, **PAGE 36**

» **Seeing Red: How Ocular Rosacea Impacts the Cornea**, **PAGE 46**



» **PLUS — Beat These Modern Day Prescribing Challenges**, **PAGE 70**

NATURAL
BEAUTY **EN**

Yasmin is wearing NATURAL SHIMMER™

HANCED


A **NEW CATEGORY** of contact lenses that accentuates **NATURAL BEAUTY**. Based on the **PROVEN DESIGN** of 1-DAY ACUVUE® MOIST, the **#1 DAILY DISPOSABLE BRAND**

WITHOUT

WITH



The iris-inspired design of **NEW 1-DAY ACUVUE® DEFINE™ Brand Contact Lenses** uniquely complements every iris pattern to help make your patients' eyes look whiter and brighter.



TRY 1-DAY ACUVUE® DEFINE™ BRAND CONTACT LENSES TODAY TO PUT YOUR PRACTICE ON THE CUTTING EDGE OF NATURAL-LOOKING EYE ENHANCEMENT.

1-DAY ACUVUE® DEFINE™ Brand Contact Lenses are available with and without vision correction. As with any contact lens, eye problems including corneal ulcers can develop. Some wearers may experience mild irritation, itching or discomfort. Lenses should not be prescribed if patients have any eye infection, or experience eye discomfort, excessive tearing, vision changes, redness, or other eye problems. Consult the package insert for complete information available from Johnson & Johnson Vision Care Companies by calling 1-800-843-2020 or by visiting www.acuvueprofessional.com.

1-DAY ACUVUE® DEFINE™, 1-DAY ACUVUE® MOIST, NATURAL SHIMMER™, and LACREON® are trademarks of Johnson & Johnson Vision Care Companies.

© Johnson & Johnson Vision Care Companies 2015 ACU-10336938 April 2015

IN THE NEWS

A thousand-year-old Anglo-Saxon remedy for eye infections, taken from a medieval medical “leech book,” has been found to kill the modern-day superbug MRSA, according to microbiologists at the **University of Nottingham** in the UK. The researchers demonstrated that “Bald’s eye salve” kills up to 90% of MRSA bacteria in wound biopsies from in vivo mouse models. They believe the bactericidal effect of the recipe is not due to a single ingredient but a combined effect, along with the brewing methods and the container material used. The researchers are continuing to investigate how and why the ancient formula works.

The **FDA** decided not to approve **Avedro’s** new drug application for its **riboflavin/KXL System for corneal crosslinking**. This came as something of a surprise because an FDA advisory panel had recommended the corneal crosslinking platform for approval in February. “We are disappointed with the outcome of the review and the implications this has for patients in the US suffering from keratoconus or corneal ectasia who remain in need of a therapeutic treatment for these sight-threatening conditions,” said Avedro’s CEO David Muller, PhD.

The **FDA** expanded the approved use for **Eylea** intravitreal injection (aflibercept, **Regeneron Pharmaceuticals**) to treat **diabetic retinopathy** in patients with diabetic macular edema. Eylea is already approved to treat wet age-related macular degeneration, as well as diabetic macular edema and macular edema secondary to retinal vein occlusions.

Azithromycin Better Than Doxy for MGD

A new study says azithromycin better improves signs and symptoms—at a lower price. **By John Murphy, Executive Editor**

Oral doxycycline has been a mainstay for treating meibomian gland dysfunction (MGD), but now a head-to-head clinical trial has found that oral azithromycin works better, faster, cheaper and with fewer side effects.

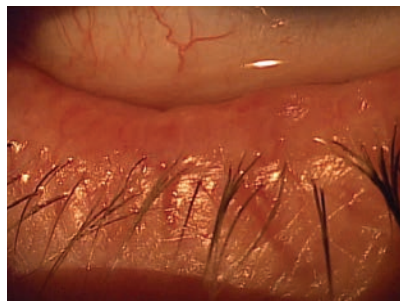

Photo: Paul Karpicki, OD

When conservative treatment doesn’t work, what’s the best medicine for MGD? A new study finds it’s azithromycin.

The study, published in February’s *British Journal of Ophthalmology*, found that both oral azithromycin and doxycycline improved symptoms of MGD. However, patients on azithromycin had relatively better improvement in symptoms and signs along with fewer side effects.

The researchers randomly assigned 110 patients with MGD to receive either a five-day course of oral azithromycin (500mg on day one, then 250mg/day) or one month of oral doxycycline (200mg/day). Patients continued eyelid warming/cleaning and artificial tears.

After two months, both treatment groups showed a significant

improvement of clinical signs and symptoms. But, the percentage of clinical improvement was significantly better in the azithromycin group, with particularly more improvement in conjunctival redness and ocular surface staining.

In addition, patients in the doxycycline group had more gastrointestinal side effects (26%) than those in the azithromycin group (4%).

Azithromycin is also much less expensive. “Since MGD is a chronic disease, multiple five-day pulse treatment with azithromycin would be cheaper than long-term daily oral doxycycline,” the authors wrote.

Alan Kabat, OD, medical director for the TearWell Advanced Dry Eye Treatment Center in Memphis, Tenn., says the study’s findings are welcome news. “I’d rather tell my patients to do something once a day for a week than twice a day for a month, especially if the outcome will be the same,” he says. “Going forward, I will certainly consider using azithromycin one week per month in my recalcitrant MGD patients.”

He emphasizes that oral treatment is not the go-to therapy for patients with MGD, but rather it’s for patients in whom conservative treatment proves insufficient or ineffective.

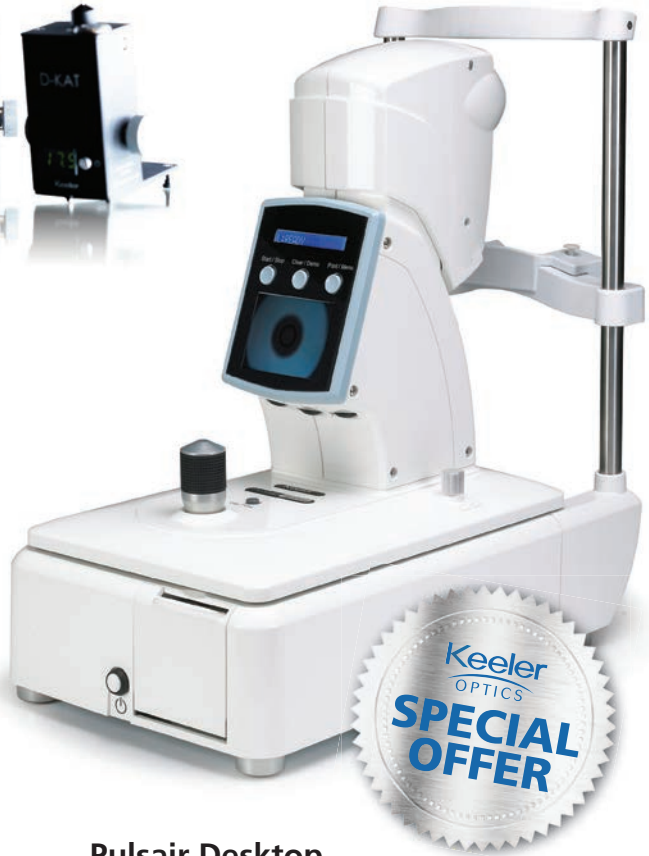Kashkoui MB, Fazel AJ, Kiavash V, et al. Oral azithromycin versus doxycycline in meibomian gland dysfunction: a randomised double-masked open-label clinical trial. *Br J Ophthalmol.* 2015 Feb;99(2):199-204.

Tonometry Done Right

new



D-KAT Digital
Keeler quality.



Pulsair Desktop
Smallest footprint and simple to use!

*Purchase a Pulsair Desktop
by June 30, 2015 and get
a \$1,300 Instant Rebate!*

Intellipuff
The standard for hand held mobility.

Buy Online!
keelerusa.com



Keeler
OPTICS

Visual Fixation in Newborns Predicts Childhood Cognitive Development

Catching a baby's eye is more than one of the joys of early parenthood. It's also a sign of brain development. A new study in *The Journal of Neuroscience* found that early visual fixation predicts neurocognitive development.

"For many years, we have suspected that such links exist," says Glen T. Steele, OD, FCOVD, professor of Pediatric Optometry at Southern College of Optometry, and chair of the InfantSee program and Children's Vision Committee of the American Optometric Association.



A baby's visual fixation holds clues to brain development as a child.

In particular, the study sheds light on the scientific relevance of the eye contact of newborns. Researchers at the University of Helsinki and Helsinki University Central Hospital in Finland investigated the relationship between newborn visual fixation (VF) and gaze behavior to performance in visuomotor and visual reasoning tasks in two cohorts with cognitive follow-up at two (n=57) and five (n=1,410) years of age.

They determined that newborn VF is significantly related to visual-motor performance at both two and five years, as well as to visual rea-

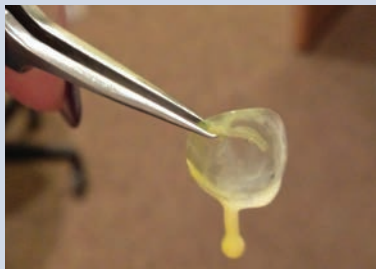soning at five years of age.

According to the authors, their findings suggest that newborn VF is supported by brain-wide subcortical networks and represents an early building block for the developmental cascades of cognition. Their study highlights the need to develop objective and quantitative measures of newborn eye contact to help recognize developmental risks early on.

To Dr. Steele, this is a very important article that joins a growing body of work linking visual fixation ability to overall development, even including autism. He has lectured on the development and importance of looking behavior, and he says the article further emphasizes the need for earlier identification and intervention in all aspects of visual fixation and function. "We can't wait until they are three or five years old to get involved, as much of their future abilities are already determined in these early years," he says.

Stjerna S, Sairanen V, Gröhn R, et al. Visual fixation in human newborns correlates with extensive white matter networks and predicts long-term neurocognitive development. *J Neurosci*. 2015 Mar 25;35(12):4824-9.

Patient Takes 'Contact Lens Adherence' to a New Level



Optometrist Monika Marczak, of McMurray, Pa., found this contact lens that was "lost" under a patient's lid for two and a half months. The patient hadn't complained of any foreign body sensation, photophobia or decreased vision. But she did report mucus discharge the night before and a slight swelling of the top lid.

"Once I stained the eye with a fluorescein sodium strip and inverted the top lid, there was a thick layer of mucus deep in the upper fornix," Dr. Marczak says. "I removed the strand of mucus with jeweler's forceps, and only then was I able to see there was a contact lens that was even deeper within the fornix."

Scope Bill in New Mexico

Optometrists in New Mexico may have reason to celebrate soon, as a bill expanding their scope of practice passed in the state legislature with a unanimous vote on March 25.

Specifically, the bill allows ODs to prescribe hydrocodone and hydrocodone-combination medications. It also permits optometrists to administer epinephrine auto-injectors to counter anaphylaxis.

In addition to prescribing powers, the bill gives the board of optometry the "sole authority to determine what constitutes the practice of optometry in accordance with the provisions of the Optometry Act" and "sole jurisdiction to exercise any other powers and duties under that act."

At press time, the bill was on the desk of Gov. Susanna Martinez awaiting her signature.

Don't just meet the needs of your patients— exceed them.



Bausch + Lomb PeroxiClear® - the most advanced* peroxide solution.

	PeroxiClear®	Clear Care
Kills 99.9% of Germs ¹	✓	✓
Preservative Free	✓	✓
Provides Superior All-Day Comfort ^{1*}	✓	
Lenses Feel Cleaner and Moister for Longer ^{1*}	✓	
Lenses Are Ready to Wear in Only 4 Hours	✓	

Switch your patients to the most advanced* peroxide solution.
Request your care kits today at Bausch.com/Peroxiclear.

*Compared to Clear Care

Reference: 1. Bausch + Lomb Data on File.

Distributed by Bausch + Lomb, a Division of Valeant Pharmaceuticals North America LLC, Bridgewater, N.J. PeroxiClear is a trademark of Bausch & Lomb Incorporated or its affiliates. All other brand/product names are trademarks of their respective owners. ©2015 Bausch & Lomb Incorporated. BLS07386 US/OCD/14/0002a

BAUSCH + LOMB
See better. Live better.

Highlights of SECO 2015

In treating glaucoma patients, don't focus only on findings such as high IOP. Also consider the impact that glaucoma has on quality of life, said David Friedman, MD, during the "New Angles in Glaucoma" special session, which he presented with Murray Fingeret, OD, at SECO 2015 in Atlanta in early March.

"The people across the chair are not just people who need to be told that they have so many ganglion cells. That's such a small part of what we're doing in the clinic for our patients," said Dr. Friedman, who is the director of the Dana Center for Preventive Ophthalmology at Johns Hopkins University School of Medicine. "We talk a lot about quality of life, but we do very little about it."

Focusing on quality of life helps patients achieve the best outcomes possible, Dr. Friedman said. "Rehabilitation needs to be part of how we care for patients."



Outgoing SECO president Jim Herman, OD, passed the gavel to incoming president Stan Dickerson, OD.

Other Special Sessions

Also at SECO 2015, speakers Eric Sigler, MD, and Mohammad Rafieetary, OD, focused in part on the technologies that have made sweeping changes in diagnostics in the "Spectrum of Retinal Detach-

ments" special session. Widefield angiography, for instance, gives doctors a better view of the retina, allowing them to identify tears along the periphery—possibly dispelling the "misconception that vitreous detachment only includes the posterior pole," Dr. Rafieetary said. Ignoring changes in the periphery, he added, could lead to the development of horseshoe tears.

The "Cutting Edge Cornea" course offered a look at recent advancements in corneal surgeries, including a sneak peek at corneal inlays. According to speaker Terry Kim, MD, corneal surgeon and professor at Duke University School of Medicine, recent breakthroughs in the safety and design of these devices could lead to their use for presbyopia management.

And the Award Goes To...

In addition to continuing education, eye care professionals also came together to honor colleagues who have contributed significant advancements to the profession.

SECO's highest honor, Optometrist of the South, was awarded to Richard Phillips, OD, of Germantown, Tenn., for his nearly three decades of practice and countless leadership roles.

Rob Pate, OD, of Hoover, Ala., was awarded Young Optometrist of the South for the significant impact he has made in less than 10 years of practice.

Last but certainly not least was the award for Paraoptometric of the South, presented to Caroline Riggins, CPO, of Enoree, SC. As president of the South Carolina Paraoptometric Association from 2008 to 2011, she helped revitalize its lecture program. ■

REVIEW[®] OF OPTOMETRY

BUSINESS OFFICES
11 CAMPUS BLVD., SUITE 100
NEWTOWN SQUARE, PA 19073

CEO, INFORMATION SERVICES GROUP
MARC FERRARA
(212) 274-7062 • MFERRARA@JOBSON.COM

PUBLISHER
JAMES HENNE
(610) 492-1017 • JHENNE@JOBSON.COM

REGIONAL SALES MANAGER
MICHELE BARRETT
(610) 492-1014 • MBARRETT@JOBSON.COM

REGIONAL SALES MANAGER
MICHAEL HOSTER
(610) 492-1028 • MHOSTER@JOBSON.COM

VICE PRESIDENT, OPERATIONS
CASEY FOSTER
(610) 492-1007 • CFOSTER@JOBSON.COM

VICE PRESIDENT, CLINICAL CONTENT
PAUL M. KARPECKI, OD, FAAO
PKARPECKI@JOBSON.COM

PRODUCTION MANAGER
SCOTT TOBIN
(610) 492-1011 • STOBIN@JOBSON.COM

SENIOR CIRCULATION MANAGER
HAMILTON MAHER
(212) 219-7870 • HMAHER@JHIHEALTH.COM

CLASSIFIED ADVERTISING
(888) 498-1460

SUBSCRIPTIONS
\$56 A YEAR, \$88 (US) IN CANADA,
\$209 (US) IN ALL OTHER COUNTRIES.

SUBSCRIPTION INQUIRIES
(877) 529-1746 (US ONLY);
OUTSIDE US, CALL (845) 267-3065

CIRCULATION
PO Box 81
CONGERS, NY 10920-0081
OUTSIDE THE US, CALL 845-267-3065



CEO, INFORMATION SERVICES GROUP
MARC FERRARA

SENIOR VICE PRESIDENT, OPERATIONS
JEFF LEVITZ

SENIOR VICE PRESIDENT, HUMAN RESOURCES
LORRAINE ORLANDO

VICE PRESIDENT, CREATIVE SERVICES & PRODUCTION
MONICA TETTAMANZI

VICE PRESIDENT, CIRCULATION
EMELDA BAREA



THE TRAINING YOU NEED TO GROW YOUR MEDICAL PRACTICE


Attention all Optometrists

Attend a boot camp to learn the latest techniques for practicing **full-scope optometry**. Get a step-by-step implementation plan that includes:

- Understanding and implementing *ICD-10* codes
- Improving billing and medical record compliance
- Differentiating vision plan visits vs medical plan visits
- Gaining access to insurance panels
- Maximizing practice productivity and performance
- Motivating and training your staff

Expert faculty:

Scot Morris, OD, FAAO
John Rumpakis, OD, MBA
Allergan Eye Care Business Advisors



Upcoming PATHWAYS IN MEDICAL OPTOMETRY™ Courses	
Location	Date
Houston, TX	Saturday, 1/31/2015
Orange County, CA	Saturday, 2/28/2015
Las Vegas, NV	Saturday, 3/14/2015
Ft Lauderdale, FL	Saturday, 4/11/2015
Ledyard, CT	Saturday, 4/18/2015
Memphis, TN	Saturday, 5/9/2015
Teaneck, NJ	Saturday, 5/16/2015
St Louis, MO	Saturday, 9/12/2015
Chicago, IL	Saturday, 10/24/2015
Atlanta, GA	Saturday, 11/14/2015

Each boot camp consists of 1 full-day course.

Cost per course:

First OD registration per practice **\$399 per course***

All additional practice registrations **\$199 per course***

*Cost required per PhRMA guidelines.

Register today at: AllerganODPathways.com

Questions? Call 1-844-750-2020



What we do every day matters.



Avenova™ with Neutrox™ (pure hypochlorous acid) removes microorganisms and debris from the lids and lashes. Avenova is an ideal addition to any daily lid and lash hygiene regimen, including for use by patients with Blepharitis and Dry Eye. Avenova may also be used after make-up removal as well as pre and post contact lens wear.

NovaBay®

Avenova™

Daily lid and lash hygiene.



OPHTHALMOLOGIST AND OPTOMETRIST TESTED | RX ONLY

AVENOVA.COM | 1-800-890-0329

Contents

Review of Optometry April 2015

Corneal Disease Report

28 Firm Up Your Approach to Corneal Ectasia

Optometrists must see these patients “through thick and thin.”
By Karen Yeung, OD, and Sally Wu

36 Essential Procedures at the Slit Lamp: Perform DBD with ASP for Stubborn RCE

If anterior stromal puncture doesn't do the job for recalcitrant recurrent corneal erosion, here's a more aggressive option.
By Jason Ellen, OD, and Nathan Lighthizer, OD

46 Seeing Red: How Ocular Rosacea Impacts the Cornea

Don't forget that this condition can affect more than just the eyelids. Here's what you need to know. By Sara Weidmayer, OD

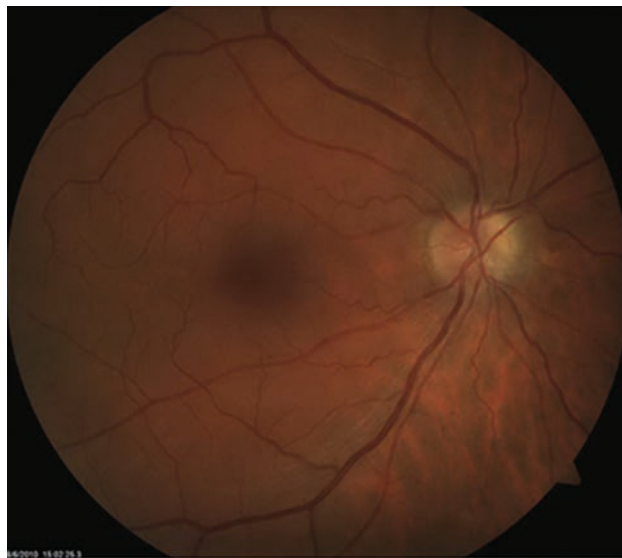53 Earn 2 CE Credits: Corneal Harbingers of Systemic Disease



A routine slit lamp exam may reveal telltale findings of health concerns elsewhere in the body. Here are the most common to look for. By Aaron Bronner, OD

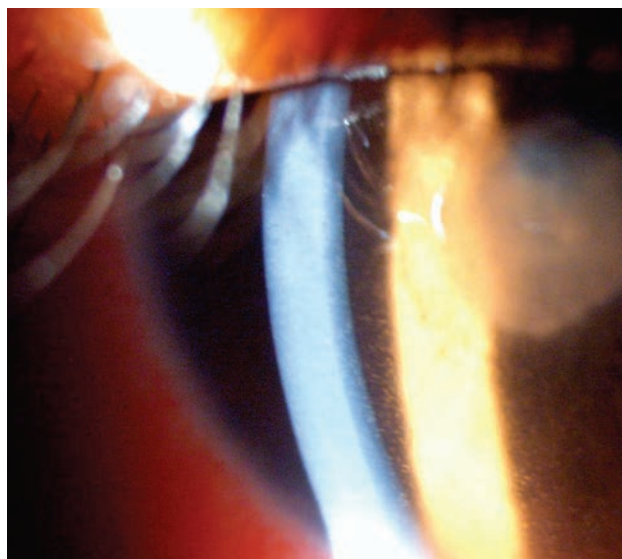
62 10 Tips For Improving Visual Fields

Perimetry may seem like second nature, but these recommendations can help you obtain better results by refining your understanding of the technology. By Matt Horton, OD



70 Beat These Modern Day Prescribing Challenges

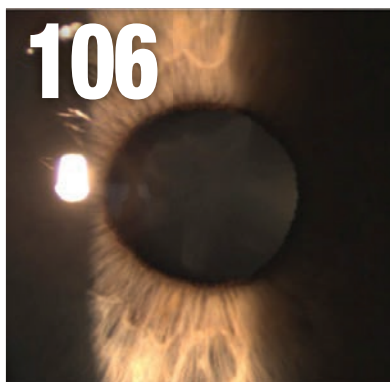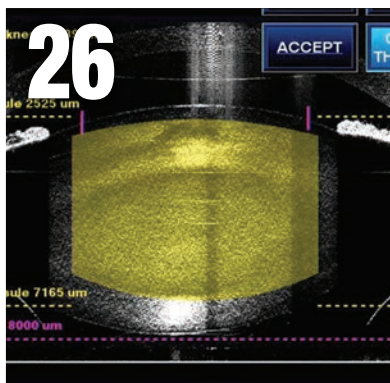
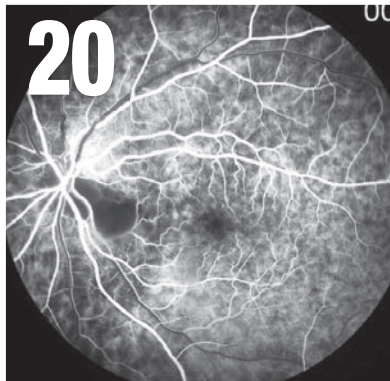
Today's optometrists face difficult Rx decisions—from managing pregnant patients to deciding whether a generic can be substituted for a brand. By Jane Cole, Contributing Editor



Departments

Review of Optometry April 2015

- 4 News Review**
- 16 Outlook**
The Societal Network
JACK PERSICO
- 18 Chairside**
Friends and Family Discount
MONTGOMERY VICKERS, OD
- 20 Urgent Care**
Giant Cell Arteritis Warnings
RICHARD MANGAN, OD
- 24 Focus on Refraction**
As Flexible as an Oak
**PAUL HARRIS, OD, AND
MARC B. TAUB, OD, MS**
- 26 Clinical Quandaries**
Open Season on Closed Angles
PAUL C. AJAMIAN, OD
- 40 Coding Connection**
Coding for RCE and ASP
JOHN RUMPAKIS, OD, MBA
- 82 Cornea + Contact Lens Q+A**
Navigating the Slippery Slope
JOSEPH P. SHOVLIN, OD
- 84 Glaucoma Grand Rounds**
Get Your Priorities in Order
JAMES L. FANELLI, OD
- 88 Retina Quiz**
Vision Loss with Wet AMD
MARK T. DUNBAR, OD
- 92 Therapeutic Review**
Wearable Therapy for Dry Eye
**ALAN G. KABAT, OD AND
JOSEPH W. SOWKA, OD**
- 97 Surgical Minute**
Caution! Traumatic Cataracts Ahead
**DEREK N. CUNNINGHAM, OD, AND
WALTER O. WHITLEY, OD, MBA**
- 99 Product Review**
- 100 Meetings + Conferences**
- 101 Advertisers Index**
- 102 Classifieds**
- 106 Diagnostic Quiz**
Head First Into the Exam Room
ANDREW S. GURWOOD, OD



Stock Images: ©iStock.com/JobsonHealthcare

On The Web >> and more

Check out our multimedia and continuing education online at:
www.reviewofoptometry.com

Digital Edition



Left your copy of *Review of Optometry* at the office? No problem! Access *Review* on your computer or mobile device!

Go to www.reviewofoptometry.com and click on the digimag link for the current issue.

Facebook and Twitter



For daily updates, "Like" our page on Facebook or "Follow" us on Twitter!


- www.facebook.com/revoptom
- <http://twitter.com/#!/revoptom>

Look for augmented content and special offers from *Review* and our advertisers. Specified pages work in conjunction with your smartphone or other mobile device to enhance the experience. With Layar, interactive content leaps off the page!



Step 1: Download the free Layar app for iPhone or Android.



Step 2: Look for pages with the Layar Logo.  INTERACTIVE PRINT

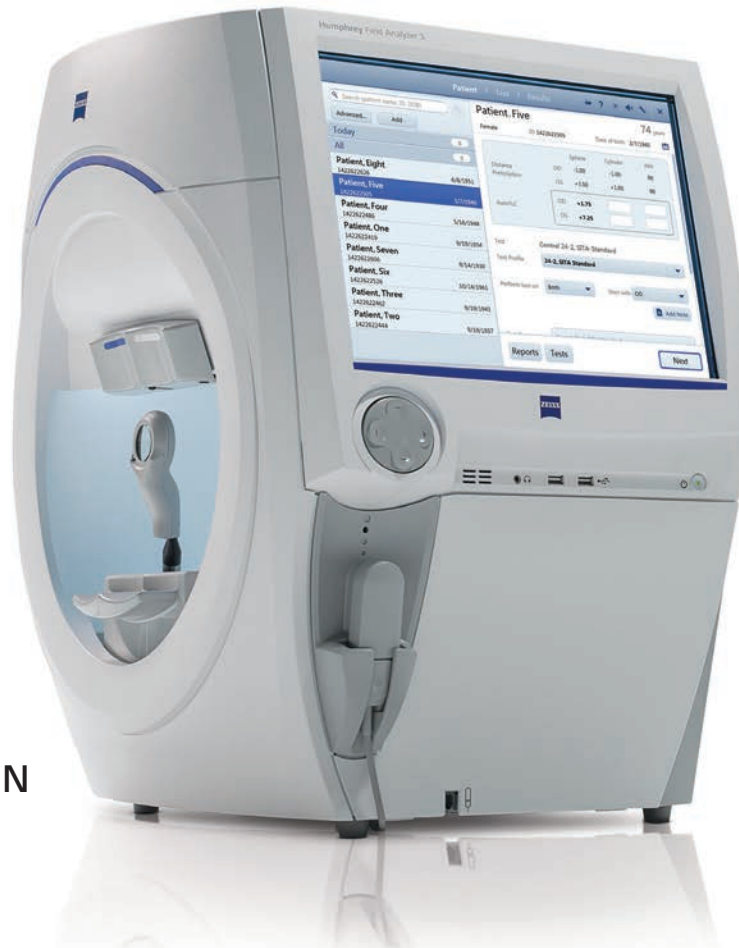

Step 3: Open the Layar app, hold the phone above the page and tap to scan it. Hold the phone above the page to view the interactive content.

The first 150 app downloads and completed forms will be entered into a drawing for a complimentary registration to one of *Review's* 14-hour CE meetings, valued at \$495.

The moment your perimeter accelerates clinic flow. The **NEW Humphrey Field Analyzer 3.**

NEW!
Liquid Lens
Technology



// **INNOVATION**
MADE BY ZEISS

ZEISS introduces the NEW HFA3 with Liquid Lens technology that combines the power of many lenses into one.*
Discover how the new HFA3 is faster, easier and more reliable than ever – and see how Liquid Lens technology works.

- Accelerate clinic flow
- Reduce setup time
- Improve confidence in test result
- Basic to advanced models available

For more information, call 800-342-9821 or visit www.zeiss.com/HFA3.



Annual winner of the
NorthFace ScoreBoard
Award for service
excellence since 2003

Carl Zeiss Meditec, Inc. 800.342.9821 www.meditec.zeiss.com
HFA.6832 Rev C ©2015 Carl Zeiss Meditec, Inc. All rights reserved. Specification subject to change.

*Some patients may require a separate lens. Liquid Trial Lens available on the HFA3 model 860.



We make it visible.

CONTRIBUTING EDITORS

PAUL C. AJAMIAN, OD, ATLANTA
AARON BRONNER, OD, KENNEWICK, WASH.
MILE BRUJIC, OD, BOWLING GREEN, OHIO
DEREK N. CUNNINGHAM, OD, AUSTIN, TEXAS
MARK T. DUNBAR, OD, MIAMI
ARTHUR B. EPSTEIN, OD, PHOENIX
JAMES L. FANELLI, OD, WILMINGTON, NC
FRANK FONTANA, OD, ST. LOUIS
GARY S. GERBER, OD, HAWTHORNE, NJ
ANDREW S. GURWOOD, OD, PHILADELPHIA
ALAN G. KABAT, OD, MEMPHIS, TENN.
DAVID KADING, OD, SEATTLE
PAUL M. KARPECKI, OD, LEXINGTON, KY.
JEROME A. LEGERTON, OD, MBA, SAN DIEGO
JASON R. MILLER, OD, MBA, POWELL, OHIO
CHERYL G. MURPHY, OD, HOLBROOK, NY
CARLO J. PELINO, OD, JENKINTOWN, PA.
JOSEPH PIZZIMENTI, OD, FORT LAUDERDALE, FLA.
JOHN RUMPAKIS, OD, MBA, PORTLAND, ORE.
DIANA L. SHECHTMAN, OD, FORT LAUDERDALE, FLA.
JEROME SHERMAN, OD, NEW YORK
JOSEPH P. SHOVLIN, OD, SCRANTON, PA.
JOSEPH W. SOWKA, OD, FORT LAUDERDALE, FLA.
MONTGOMERY VICKERS, OD, ST. ALBANS, W.VA.
WALTER O. WHITLEY, OD, MBA, VIRGINIA BEACH, VA.

EDITORIAL REVIEW BOARD

JEFFREY R. ANSHEL, OD, CARLSBAD, CALIF.
JILL AUTRY, OD, RPH, HOUSTON
SHERRY J. BASS, OD, NEW YORK
EDWARD S. BENNETT, OD, ST. LOUIS
MARC R. BLOOMENSTEIN, OD, SCOTTSDALE, ARIZ.
CHRIS J. CAKANAC, OD, MURRYSVILLE, PA.

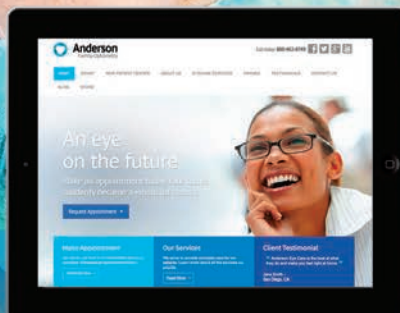JERRY CAVALLERANO, OD, PHD, BOSTON
WALTER L. CHOATE, OD, MADISON, TENN.
BRIAN CHOU, OD, SAN DIEGO
A. PAUL CHOUS, MA, OD, TACOMA, WASH.
ROBERT M. COLE, III, OD, BRIDGETON, NJ
GLENN S. CORBIN, OD, WYOMISSING, PA.
ANTHONY S. DECIDUE, OD, STROUDSBURG, PA.
S. BARRY EIDEN, OD, DEERFIELD, ILL.
STEVEN FERRUCCI, OD, SEPULVEDA, CALIF.
MURRAY FINGERET, OD, HEWLETT, NY
IAN BEN GADDIE, OD, LOUISVILLE, KY.
MILTON HOM, OD, AZUSA, CALIF.
BLAIR B. LONSBERRY, MS, OD, MED, PORTLAND, ORE.
THOMAS L. LEWIS, OD, PHD, PHILADELPHIA
DOMINICK MAINO, OD, MED, CHICAGO
KELLY A. MALLOY, OD, PHILADELPHIA
RICHARD B. MANGAN, OD, LEXINGTON, KY.
RON MELTON, OD, CHARLOTTE, NC
PAMELA J. MILLER, OD, JD, HIGHLAND, CALIF.
BRUCE MUCHNICK, OD, COATESVILLE, PA.
MARC MYERS, OD, COATESVILLE, PA.
WILLIAM B. POTTER, OD, FREEHOLD, NJ
CHRISTOPHER J. QUINN, OD, ISELIN, NJ
JOHN L. SCHACHET, OD, ENGLEWOOD, COLO.
JACK SCHAEFFER, OD, BIRMINGHAM, ALA.
MICHAEL C. RADOIU, OD, STAUNTON, VA.
KIMBERLY K. REED, OD, FORT LAUDERDALE, FLA.
LEO P. SEMES, OD, BIRMINGHAM, ALA.
LEONID SKORIN, JR., OD, DO, ROCHESTER, MINN.
BRAD M. SUTTON, OD, INDIANAPOLIS
LORETTA B. SZCZOTKA, OD, PHD, CLEVELAND
TAMMY P. THAN, MS, OD, BIRMINGHAM, ALA.
RANDALL THOMAS, OD, CONCORD, NC
KATHY C. WILLIAMS, OD, SEATTLE

You Help Patients See. We Help New Patients See You.



A strong web presence helps new patients find you.

- ✔ Appointment requests make it easy for new patients to contact you.
- ✔ Online forms streamline first time visits and reduce paperwork.
- ✔ An interactive Google map gets patients to your door.
- ✔ Blogs, social media, and video improve patient retention and referrals.
- ✔ Educate patients about medical procedures with unlimited web pages.



Get the solution you need to create a powerful web presence.



All eyes deserve clariti.



clariti 1 day—now available for practices everywhere.

The world's first and only family of silicone hydrogel daily disposable contact lenses designed *for every patient type*—sphere, toric and multifocal.

**High Oxygen
Transmissibility**

**High Water
Content**

**Low
Modulus**

**UV
Protection**

**Affordable
Upgrade**

Now you can prescribe all of your patients with healthy, comfortable, affordable silicone hydrogel 1 day lenses—which will make all eyes very happy indeed.

To learn more, contact your CooperVision representative today or visit **CooperVision.com/practitioner**.



CooperVision®
Live Brightly.®



PRINTED IN USA

FOUNDING EDITOR
FREDERICK BOGER
1891-1913

EDITORIAL OFFICES

11 CAMPUS BLVD., SUITE 100
NEWTOWN SQUARE, PA 19073

EMAIL • REVIEWOFOPTOMETRY@JOBSON.COM

WEBSITE • WWW.REVOPTOM.COM

SUBSCRIPTION INQUIRIES

1-877-529-1746

CONTINUING EDUCATION INQUIRIES

1-800-825-4696

EDITOR-IN-CHIEF • JACK PERSICO

(610) 492-1006 • JPERSICO@JOBSON.COM

EXECUTIVE EDITOR • JOHN MURPHY

(610) 492-1021 • JMURPHY@JOBSON.COM

SENIOR EDITOR • BILL KEKEVIAN

(610) 492-1003 • BKEKEVIAN@JOBSON.COM

ASSOCIATE EDITOR • ALIZA MARTIN

(610) 492-1043 • AMARTIN@JOBSON.COM

DIRECTOR ART/PRODUCTION • JOE MORRIS

(610) 492-1027 • JMORRIS@JOBSON.COM

ART DIRECTOR • JARED ARAUJO

(610) 492-1032 • JARAJO@JOBSON.COM

DIRECTOR OF CE ADMINISTRATION • REGINA COMBS

(212) 274-7160 • RCOMBS@JOBSON.COM

SPECIAL PROJECTS/E-PRODUCTS MANAGER • KAREN ROMAN

(610) 492-1037 • KRROMAN@JOBSON.COM

EDITORIAL BOARD

CHIEF CLINICAL EDITOR • PAUL M. KARPECKI, OD

ASSOCIATE CLINICAL EDITORS • JOSEPH P. SHOVLIN, OD;

ALAN G. KABAT, OD; CHRISTINE W. SINDT, OD

DIRECTOR OPTOMETRIC PROGRAMS • ARTHUR EPSTEIN, OD

CLINICAL & EDUCATION CONFERENCE ADVISOR

PAUL M. KARPECKI, OD

CASE REPORTS COORDINATOR • ANDREW S. GURWOOD, OD

CLINICAL CODING EDITOR • JOHN RUMPAKIS, OD, MBA

CONSULTING EDITOR • FRANK FONTANA, OD

COLUMNISTS

CHAIRSIDE • MONTGOMERY VICKERS, OD

CLINICAL QUANDARIES • PAUL C. AJAMIAN, OD

CORNEA & CONTACT LENS Q+A • JOSEPH P. SHOVLIN, OD

DIAGNOSTIC QUIZ • ANDREW S. GURWOOD, OD

GLAUCOMA GRAND ROUNDS • JAMES L. FANELLI, OD

OCULAR SURFACE REVIEW • PAUL M. KARPECKI, OD

URGENT CARE • RICHARD B. MANGAN, OD

RETINA QUIZ • MARK T. DUNBAR, OD

REVIEW OF SYSTEMS • CARLO J. PELINO, OD;

JOSEPH J. PIZZIMENTI, OD

SURGICAL MINUTE • DEREK N. CUNNINGHAM, OD;

WALTER O. WHITLEY, OD, MBA

THERAPEUTIC REVIEW • JOSEPH W. SOWKA, OD;

ALAN G. KABAT, OD

NEURO CLINIC • MICHAEL TROTTINI, OD;

MICHAEL DELGODICE, OD

FOCUS ON REFRACTION • MARC TAUB, OD;

PAUL HARRIS, OD

JOBSON MEDICAL INFORMATION LLC



The Societal Network

A new shared database lets ODs pool their clinical data, for the benefit of everyone. **By Jack Persico, Editor-in-Chief**

“Imagine every optometrist in the country being able to collaborate on outcomes for glaucoma management, amblyopia treatment, contact lens-induced ulcers, myopia progression and more using evidence-based outcomes to improve our patient’s care instead of waiting years for clinical trials,” said Jeff Michaels, OD, in an announcement about the AOA’s new clinical data registry. “As the primary eye care profession, this is a huge opportunity for optometry and the millions of patients we serve every year.”

Treat Locally, Act Globally

That tantalizing prospect is how the AOA describes the Measures and Outcomes Registry for Eyecare, or MORE for short. It’s a good pitch. Doctors by their very nature want to help people—so, here’s a chance to join in a project that helps *all* patients, not just the one in your chair right now. Your patient base is then no longer just your own community, it’s society at large.

It’s a logical extension of the increasingly interconnected way of things nowadays. With online access ubiquitous and social networking a routine part of everyday life, doctors are sharing information and advice about patient care all the time. But discussions online can get wild and woolly, and privacy is always a concern. Plus, there’s no systematic way to analyze the data. Services like the MORE registry will crunch the numbers, helping you gauge the success of your patient care by creating profession-

wide statistics and benchmarks. It’s optometry’s foray into the world of so-called “big data,” a trendy phrase for the mining of massively large databases to improve knowledge.

It’ll also help you with the mundane and often frustrating work of satisfying EHR meaningful use requirements and reporting to Medicare’s Physician Quality Reporting System. The AOA is working with EHR vendors to pull relevant data on patient care without compromising the privacy of patients or doctors. The Academy of Ophthalmology has a similar registry, called IRIS. Hopefully, there will come a day when the two databases can be merged or at least connected.

In the meantime, look for MORE to launch at the AOA’s annual meeting in Seattle this June.

A Registry on Your Wrist

Patients are getting connected, too. Apple’s new initiative called ResearchKit puts software on phones and, soon, watches that lets patients register for medical studies and enter health information directly into a clinical trial database.

When everyone is walking around with, in effect, a Star Trek tricorder in their hand or strapped to their wrist, ambitious stuff becomes possible. Of course, not *everyone* has these popular but inessential gadgets. Income and age disparities could skew the results mightily if not controlled for in data analysis. But connecting patients, doctors and medical statisticians today puts the infrastructure in place for groundbreaking advances to come. ■



Dry eye relief starts with restoring balance

Elevated tear film osmolarity (osmolarity imbalance or hyperosmolarity) is one of the primary causes of dry eye symptoms¹.

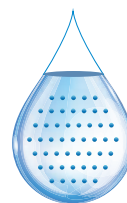
TheraTears® Dry Eye Therapy with Osmo-Correction™ corrects osmolarity imbalance to restore comfort with a unique hypotonic and electrolyte balanced formula that replicates a healthy tear.

WITH
OSMO-CORRECTION™
HYPOTONIC & ELECTROLYTE
BALANCED



HYPEROSMOLARITY

Increased concentration of the tears leads to irritation and potential damage to the ocular surface.



HEALTHY TEAR

TheraTears® Dry Eye Therapy replicates the electrolyte balance of natural tears to restore comfort.



RESTORE

+



CLEANSE

+



NOURISH



thera tears®

THERAPY FOR YOUR EYES™

DRY EYE THERAPY

Restores Eyes Natural Balance™

theratears.com



Reference: 1. Research in dry eye report of the Research Subcommittee of the International Dry Eye WorkShop (2007). *Ocul Surf.* Apr 2007; 5(2): 179-193.

© 2015 Akorn Consumer Health | A Division of Akorn, Inc. | M15-006

Friends and Family Discount

Where's the worst place to find your loved ones? In poverty? In prison? In trouble? Nope, it's in your exam chair. **By Montgomery Vickers, OD**

Nothing on earth is more important than family. I want my family to be happy, happy, happy all of the time! Therefore, I avoid them whenever possible.

Just kidding. The fact that my family spreads from Texas to California to Ohio actually creates a buffer that allows me to spend quality time on the phone or Facetime with each and every one of them. I always make sure that I tell each of them something meaningful.

More often than not, I say this: "Here's your mother."

That always cheers them up.

It Isn't Chair Time, It's Quality Time

But as lovely as family may be, family also may cause our most palpable distress.

Nowhere is this more true than in the office. Young optometrists, please listen. Do not believe for one minute that your family will be your first and best patients. Oh, they'll probably come to you for eye care and eyewear. After all, the price is right, right? But, they will not lead to a profitable practice. That's not their problem. It is yours and yours alone.

I've been in practice for 35 years. That means my family includes people I would have never met if it wasn't for the office. I love them. They (mostly) love or at least kindly tolerate me. It's a family.

Sure, we squabble. I fuss at them for saying asinine things like, "My insurance won't let me come for

an exam this year." Folks, you can have your eyes examined any damn time you want. Suppose your insurance only pays every other year; that just means you get 50% off EVERY YEAR—but only if you show up every year.

And they ask, "Are your glasses cheap?" Yes, *my* glasses are free! But *your* glasses, purchased right here, will NEVER be CHEAP. Inexpensive? I can do that. Worth it? I can do that, too. Cheap? No.

"Can you tell Mom she can't drive any more?" How would I know? She never drove me anywhere. But I can tell you whether she does or does not meet the legal visual requirement for driving in the state of West Virginia. So, tell you what... If you'll call *my* Mom and tell her *she* can't drive, I will call yours. Deal?

When You're Here, You're Family

It's just family stuff—things we all face as sons and daughters and spouses and parents and grandparents. Now, for me, I still think spanking can be a good teaching tool. However, my glaucoma patients who swear they take their meds every day

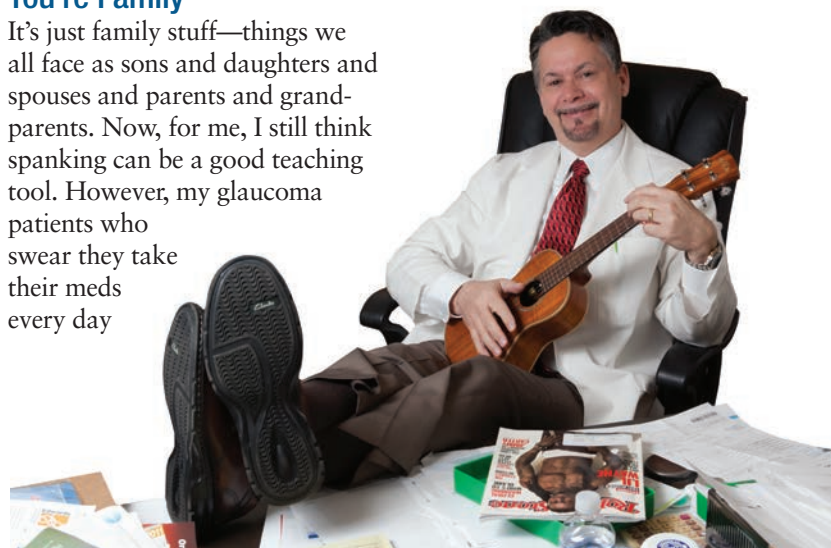but they're still on the same sample bottle I gave them last summer may disagree, smack me back, or, more likely, prosecute.

A jury of my OD peers would never convict me.

But if you don't believe in spanking, how about a "time out"? Next time your patient's cell phone goes off during the exam, try stepping out of the room for a while. An hour or so should do it.

Also, the next time a long-lost cousin comes up at the family barbecue and asks you about his eyes, just smile and "remind him" that you're a dentist. And don't forget to tell him you moved your office to Canada.

Treat the patients like family, that's all I'm saying. That means listen to them. Teach them and learn from them. Respect them. And, when you need to, send them outside to cut their own switch. ■



As your dedicated partner in eye care
We Re-Envision Vision



Meeting the need. An increasing aging and diabetic population gives way to an increased number of patients diagnosed with retinal diseases. Regeneron is committed to delivering targeted therapies that can impact your patients' vision.

Learn more about our *science to medicine* approach at Regeneron.com.

REGENERON
science to medicine[®]

science to medicine is a registered trademark of Regeneron Pharmaceuticals, Inc.

©2015, Regeneron Pharmaceuticals, Inc.,
777 Old Saw Mill River Road, Tarrytown, NY 10591

All rights reserved

02/2015
RGN-0237



Giant Cell Arteritis Warnings

Don't miss the subtle signs of this potentially sight-robbing condition.

By Richard Mangan, OD

Giant cell arteritis (GCA), also known as temporal arteritis, is the most common vasculitis in adults older than 50 years, with an incidence of approximately 18 per 100,000 per year.¹ It affects women four times more often than it affects men and has a prevalence that is highest in caucasians, especially those of Scandinavian or Northern European descent.²⁻⁴

The disease is a vasculitis affecting medium and large-sized vessels that commonly, although not exclusively, develop in the superficial temporal artery and other extracranial branches of the carotid artery. This explains why a headache is the most common symptom associated with GCA.⁵

Often, GCA can develop into sudden vision loss and is considered a true ocular emergency. This article reviews the sequelae, diagnosis and treatment of GCA.

AAION

A highly-feared sequelae of GCA involves sudden, painless and profound vision loss in one or both eyes secondary to arteritic anterior

ischemic optic neuropathy (AAION).^{6,7} A study estimates that one out of five patients diagnosed with GCA will develop monocular vision loss related to AAION, with more than one-third experiencing one or more episodes of transient vision loss prior to the event.⁶ Vision is often count fingers or worse and is accompanied by a pronounced afferent pupillary defect. If left untreated, approximately 50% will go on to lose vision in the fellow eye within days to weeks of onset.⁸ AAION secondary to GCA is considered a true ocular emergency.

In the acute phase, the optic nerve will appear swollen and pale (*figure 1*), often associated with flame-shaped hemorrhages.

Later, as the swelling subsides, optic atrophy sets in. Other signs that may be associated with AAION include cotton wool spots, central retinal artery occlusion, branch retinal artery occlusion and cranial nerve involvement (especially CN VI). The affected eye will often show an altitudinal visual field defect, but arcuate and cecentral scotoma's have also been reported.

Case History

Perform a thorough and careful case history when confronted with an acute ischemic optic neuropathy.

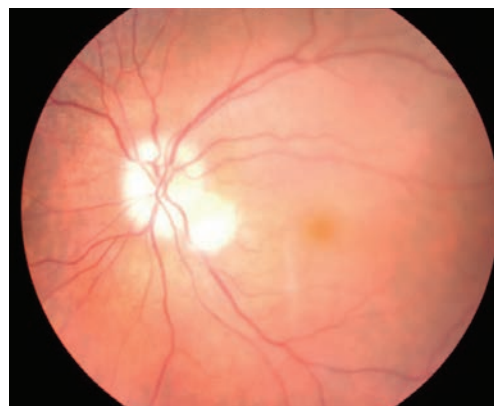

Fig. 1. Optic nerve and retinal ischemia consistent with AAION and GCA.

While GCA most commonly affects patients older than 65 years, be on the lookout for this condition in any patients older than 50 years who complain of antecedent or simultaneous temporal head pain, scalp tenderness and jaw claudication (pain with chewing). Proximal muscle and joint pain (polymyalgia rheumatica), as well as constitutional symptoms such as fatigue, sweating, fever and weight loss, should raise suspicion for GCA. It is important to note, however, that approximately one out of every five patients who present with visual loss secondary to AAION do so without any systemic complaints.

Diagnosis

How important is it to confirm the diagnosis through temporal artery biopsy before starting treatment?

Initiation of oral or IV steroids can adversely affect the results of a temporal artery biopsy, the gold-

Table 1. Physical Examination

- Examination of the temporal artery to detect prominence, noularity, or tenderness of a palpation of the artery and the surrounding skin.
- Evaluate the strength of the tempoal artery pulse.
- Perform auscultation of the carotid artery for bruits.
- Check blood pressure.

Transform your irregular cornea patients' vision with UltraHealth.

Thousands are experiencing straightforward, intuitive fitting, lens stability, good centration and comfort from the most advanced hybrid lens.

GP Optics with Ideal Centration from the Soft Skirt

64%* of UltraHealth patients experienced vision **two or more** lines better than their previous modality.

Straightforward, Dependable, Efficient

68%** of new fitters rate UltraHealth "much more straightforward" to fit than other irregular cornea lenses.

Excellent Ocular Health

130 Dk GP and 84 Dk SiHy skirt provide oxygen permeability
UV blocker protects from the sun's harmful rays

2nd Generation Design with SoftCushion™ Comfort Technology

Enhances tear exchange and lens movement.

Hassle-Free Wear

Soft lens-size makes them familiar to handle.
Debris entrapment and other GP hassles minimized.

ULTRAHEALTH
CONTACT LENSES



Review of Optometry Special Offer!

Contact Your UltraHealth Specialist
Offer Code: R02015

SynergEyes.com/Professional
877.733.2012 option 5
Intl.: +1 760.476.9410 option 1

SynergEyes

*New UltraHealth fitters compared fitting UltraHealth to other irregular cornea lenses: 68% found lens fitting much more straightforward, 28% found the fitting to be the same and 3% found the fitting not to be straightforward.
**Compared to their previous modality, 64% of new hybrid wearers experienced vision two lines or better, 17% one line better, 14% the same and 5% worse.

standard diagnostic procedure in confirming GCA.¹⁰ However, when dealing with visual symptoms or sudden severe vision loss in one eye related to AAION, waiting for a biopsy result is not an option. Given the potentially devastating consequences of delaying treatment, order bloodwork (CBC, ESR, CRP, FBS, FTA-ABS and ANA) and initiate treatment immediately, ideally in cooperation with a specialist in internal medicine or rheumatology.

Studies show that if aggressive steroid treatment is initiated within the first 24 hours of the onset of visual symptoms, the patient has a better than 50% chance of obtaining some improvement in vision. A delay in treatment drops these odds to approximately 5%.¹¹

A temporal artery biopsy should still be ordered and ideally performed within one week of starting steroids. Evidence suggests that immediate treatment does not usually confound biopsy results within this time frame and in some cases for as long as three weeks out.¹²

False Negatives

Note that not all patients with GCA will have abnormal labs. Fifteen percent to 30% of patients with positive temporal artery biopsies have a normal ESR.¹³⁻¹⁵ It is also important to note that biopsy of the temporal artery carries a significant false negative rate (5% to 9%) due to skip lesions.¹⁶

The American College of Rheumatology (ACR) has developed a five-point scoring system with equal weighting for each of the following five parameters for GCA diagnosis:¹⁷

- Age more than 50 years.
- A Westergren ESR greater than 50.
- Temporal artery tenderness or abnormality on exam (*table 1*).

- New-onset headache.

- Positive temporal artery biopsy.

If three out of five are considered positive, this carries a sensitivity (93.5%) and specificity (91.2%) that distinguishes GCA from other forms of vasculitis.¹⁸ Therefore, even in cases where the ESR and biopsy results are inconclusive, patients that present with an AAION and have the other risk factors listed here should be treated promptly.

IV vs. Oral Steroid Delivery

Research has yet to clearly establish the benefits of IV methylprednisolone vs. oral steroids with respect to improved visual recovery. Some studies report improved visual recovery with IV delivery while others report no difference.¹⁹⁻²⁰

The case for IV administration of methylprednisolone instead of oral administration of steroids is based more on the importance of prompt initiation of treatment and control of side-effects from treatment rather than better outcomes. First, compliance is 100% when medication is given intravenously. Also, drugs are typically more potent and act faster when delivered intravenously. Studies suggest that patients started on a three-day induction dose of IV methylprednisolone, 15mg/kg/d (about 1g per day), followed by oral prednisolone therapy (40 to 60mg/d) are able to be weaned off oral steroids faster than when placed on oral treatment alone.²⁰ Patient tolerance of IV methylprednisolone is similar to that found with oral administration.

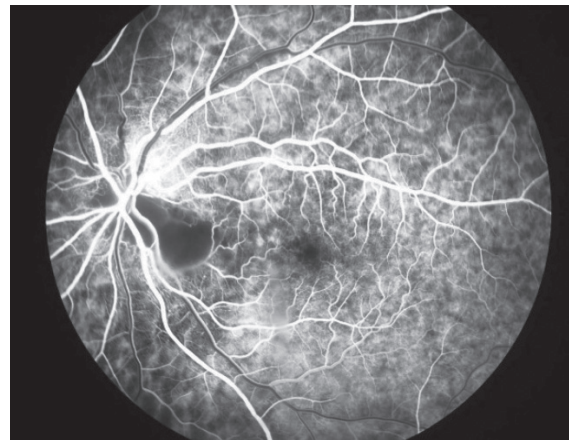


Fig. 2. Fluorescein angiography typically shows delayed choroidal and central retinal artery filling, with possible choroidal nonperfusion, especially in the peripapillary area.

What is generally agreed upon is that patients with transient or persistent vision loss need immediate treatment by either delivery method, whichever will be most timely. In general, therapy with high-dose oral steroids is necessary for several weeks and is then followed by a slow taper and maintenance dosing to maintain a low ESR and CRP.²¹

Prognosis

The main goal of treatment is to prevent involvement of the fellow eye and other systemic vascular complications such as stroke or myocardial infarction. While some anecdotal cases report significant visual improvement with prompt treatment, the prognosis for visual recovery from AAION is generally poor. In fact, 30% of patients will continue to suffer visual decline despite aggressive IV methylprednisolone treatment.²²

Risk factors for progressive visual loss despite steroid therapy include an elevated CRP, older age, and significant optic disc swelling.²³

Giant cell arteritis is a severe inflammatory condition that can lead to stroke, blindness, and heart

attack. Two thirds of patients with GCA offer a chief complaint of headache or temporal head pain. Knowing the other signs, symptoms, and risk factors for GCA may allow you to act in time so as to avoid serious complications, like blindness, from happening on your watch. ■

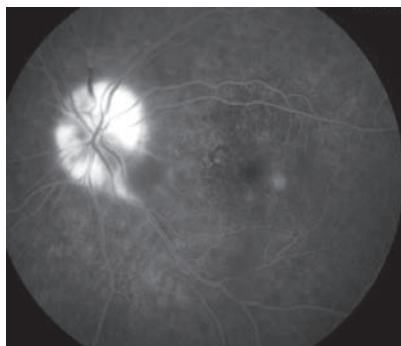


Fig. 3. In the late phase of the angiogram, leakage of dye is bound by the area of optic disc swelling.

1. Unwin B, Williams C, Gilliland W. Polymyalgia rheumatica and giant cell arteritis. *Am Fam Physician* 2006;74:1547-54.
2. Eberhardt R, Dhadly M. Giant cell arteritis: diagnosis, management, and cardiovascular implications. *Cardiol Rev* 2007;15:55-61.
3. Smith C, Fidler W, Pinals R. The epidemiology of giant cell arteritis: report of a ten-year study in Shelby County, Tennessee. *Arthritis Rheum* 1983;26:1214-19.
4. Wernick C, Duvey M, Bonafede P. Familial giant cell arteritis: report of an HLA-typed sibling pair and review of the literature. *Clin Exp Rheumatol* 1994;12:63-6.
5. Salvarani C, Cantini F, Bolardi L, Hunder G. Polymyalgia rheumatica and giant-cell arteritis. *N Engl J Med* 2002;347:261-71.
6. Gonzales-Gay M, Blanco R, Rodriguez-Valverde V, et al. Permanent visual loss and cerebrovascular accidents in giant cell arteritis: predictors and response to treatment. *Arthritis Rheum* 1998;41:1497-504.
7. Liozon E, Ly K, Robert P. Ocular complications of giant cell arteritis. *Rev Med Interne*. Jul 2013;34(7):421-30.

8. Weyand C, Goronzy J. Giant-cell arteritis and polymyalgia rheumatica. *Ann Intern Med* 2003;139:505-15.
9. Hayreh SS, Podhajsky PA, Zimmerman B. Occult giant cell arteritis: ocular manifestations. *Am J Ophthalmol* 1998;125:521-26.
10. Ray-Chaudhuri N, Kine D, Tijani SO, et al. Effect of prior steroid treatment on temporal artery biopsy findings in giant cell arteritis. *Br J Ophthalmol* 2002;86:530-2.
11. Fraser J, Weyand C, Newman N, Biousse V. The Treatment of Giant Cell Arteritis. *Rev Neurol Dis*. 2008;5(3):140-52.
12. Achkar AA, Lie JT, Hunder GG, et al. How does previous corticosteroid treatment affect the biopsy findings in giant cell

- (temporal) arteritis? *Ann Intern Med* 1994;120:987-92.
13. Huston K, Hunder G, Lie J, et al. Temporal arteritis: a 25-year epidemiologic, clinical, and pathologic study. *Ann Intern Med* 1978;88:162-67.
14. Smetana G, Shmerling R. Does this patient have temporal arteritis? *JAMA* 2002;287:92-101.
15. Hayreh S, Podhajsky P, Raman R, Zimmerman B. Giant cell arteritis: validity and reliability of various diagnostic criteria. *Am J Ophthalmol* 1997;123:285-96.
16. Gonzalez EB. Arteritis associated with systemic disease. *Coron Artery Dis* 1995;6:207-12.
17. Hunder G, Bloch D, Michel B, et al. The American College of Rheumatology 1990 criteria for the classification of giant cell arteritis. *Arthritis Rheum* 1990;33:1122-8.
18. Haist S. Stroke after temporal artery biopsy. *Mayo Clin Proc* 1985;60:538.
19. Chevalet P, Barrier J, Pottier P, et al. A randomized, multicenter, controlled trial using intravenous pulses of methylprednisolone in the initial treatment of simple forms of giant cell arteritis: a one-year follow-up study of 164 patients. *J Rheumatol* 2000;27:1484-91.
20. Mazlumzadeh M, Hunder G, Easley K, et al. Treatment of giant cell arteritis using induction therapy with high-dose corticosteroids: a double-blind, placebo-controlled, randomized prospective clinical trial. *Arthritis Rheum* 2006;54:3310-18.
21. Hayreh S, Zimmerman B. Management of giant cell arteritis. Our 27-year clinical study. New light on old controversies. *Ophthalmologica* 2003; 217: 239-59.
22. Danesh-Meyer H, Savino P, Gamble G. Poor prognosis of visual outcome after visual loss from giant cell arteritis. *Ophthalmology* 2005;112:1098-103.
23. Loddenkemper T, Sharma P, Katzan I, Plant GT. Risk factors for early visual deterioration in temporal arteritis. *J Neurol Neurosurg Psychiatry*. Nov 2007;78(11):1255-9.

Introducing SECO University


JOIN THE CLASS OF
20/20

SECO 2015
courses coming soon!

SECO University - the new online Education Resource Center from SECO International - is built on a decade of experience providing online optometric CE.

Enroll today and get access to more than 50 hours of COPE-approved online CE credit along with dozens of more exclusive learning and training tools.





As Flexible as an Oak

A professional pilot's 'muscle-building glasses' do nothing for his dangerous double vision problem. **By Paul Harris, OD and Marc B. Taub, OD, MS**

A colleague recently asked me to take a look at a friend of hers, a professional pilot for private jet services. One year prior, the pilot needed his glasses remade three times by yet another optometric colleague, and he was still unhappy.

He had his first symptom of double vision in 1994 and recalled getting his first prism in 1996 after suffering a concussion as a firefighter. He was given what he was told were "muscle-building glasses."

We were immediately sworn to secrecy to not call up the FAA because he had been flying a plane for 23 of the past 24 hours. Upon final approach to the airport, he clearly saw two runways, one next to the other, and wondered on which one should he land the plane. How to pick? He closed one eye and said, "That must be the one." When he opened his other eye, he looked harder and harder to move the second one over to the first one, and then brought the plane down.

He knew that he had pushed himself beyond his limits and never wanted to do that again.

History

In October 1999, he had sustained another concussion in a motorcycle accident. In February 2000, he had fusion of his C4-C6 vertebrae. In 2010, he underwent fusion of L4-L5-S1 vertebrae.

We laughed when he proudly stated that he was "as flexible as an oak tree," but this actually raised a red flag because of the likely connec-



Our patient, a professional pilot, saw two runways while trying to land a plane.

tion between posture and movement with vision and refractive conditions.^{1,2} With his restricted back movement, we expected some interesting asymmetries in his visual system—and we weren't disappointed.

We have to admit that we don't neutralize a new patient's glasses until we're done with the exam because we don't want to be biased by the prior data. And this patient had optometric data going back to 2009 for comparison.

Diagnostic Data

Visual acuity with his current glasses was quite good at 20/19 OD, 20/14 OS and 20/13 OU. A cover test over his glasses, which he said had prism in them, revealed 10Δ exophoria, 3Δ right hyper at distance and 4Δ exophoria, 3Δ right hyper at near.

His refraction was pretty straightforward: +2.75 OD and +3.00 -0.75 x 180 OS. With his glasses, near point of convergence was 4"/6" OD out, and he reported diplopia spontaneously.

The Worth 4-dot test was quite

revealing. He saw five dots, which indicates that his eyes are out of alignment relative to the lights whenever he looked 20° or more downward or 35° to his right or left. This clearly showed that his binocularity was fragile, to say the least.

In the phoropter, with his new refraction, we performed vertical ranges with prism moving in front of the left eye with the right eye as the reference eye and found:

- Left infra duction showed a break at 13.5Δ and a recovery of 12.0Δ
- Left supra duction showed a break at -10.0Δ and a recovery of -11.5Δ

This means that he has a total vertical range of half a prism diopter at distance and needed between 11.5Δ and 12.0Δ of vertical prism. He also needed at least 3Δ more over his glasses. At near, he had the same half a prism diopter of range, but this range increased to 14.0Δ to 14.5Δ of vertical prism.

Although patients with these verticals can function with less prism

in their glasses, they'll compensate with a head tilt. In some cases, the glasses themselves have gotten out of adjustment. Induced vertical prism can occur when one lens is high and the other is low relative to the visual axes. This patient's glasses were slightly out of kilter and he had a small head tilt, but nothing extraordinary.

What about his horizontal ranges, you ask? At distance, his base-in range was a respectable break at 9Δ with recovery at 6Δ, but his base-out was non-existent. At -4Δ or 4Δ of base-in, he broke into seeing double vision while moving toward base-out. He had to go back to 5Δ of base-in to recover fusion again. So, based on the recoveries, his zone of comfortable binocular vision should be a range of 1Δ horizontally and a half a prism diopter vertically. Yes indeed, as flexible as an oak tree!

Previous Data

Now it was time to see what was in his glasses as determined by his previous eye care providers. His habitual glasses were:

- +3.00 -0.50 x 30 +2.50 add 3Δ base-down
- +3.00 -1.00 x 167 +2.50 add 3Δ base-up

He had been prescribed only 6Δ of vertical prism, yet his testing showed he needed a minimum of 11.5Δ to not have to tilt his head or "work" at it.

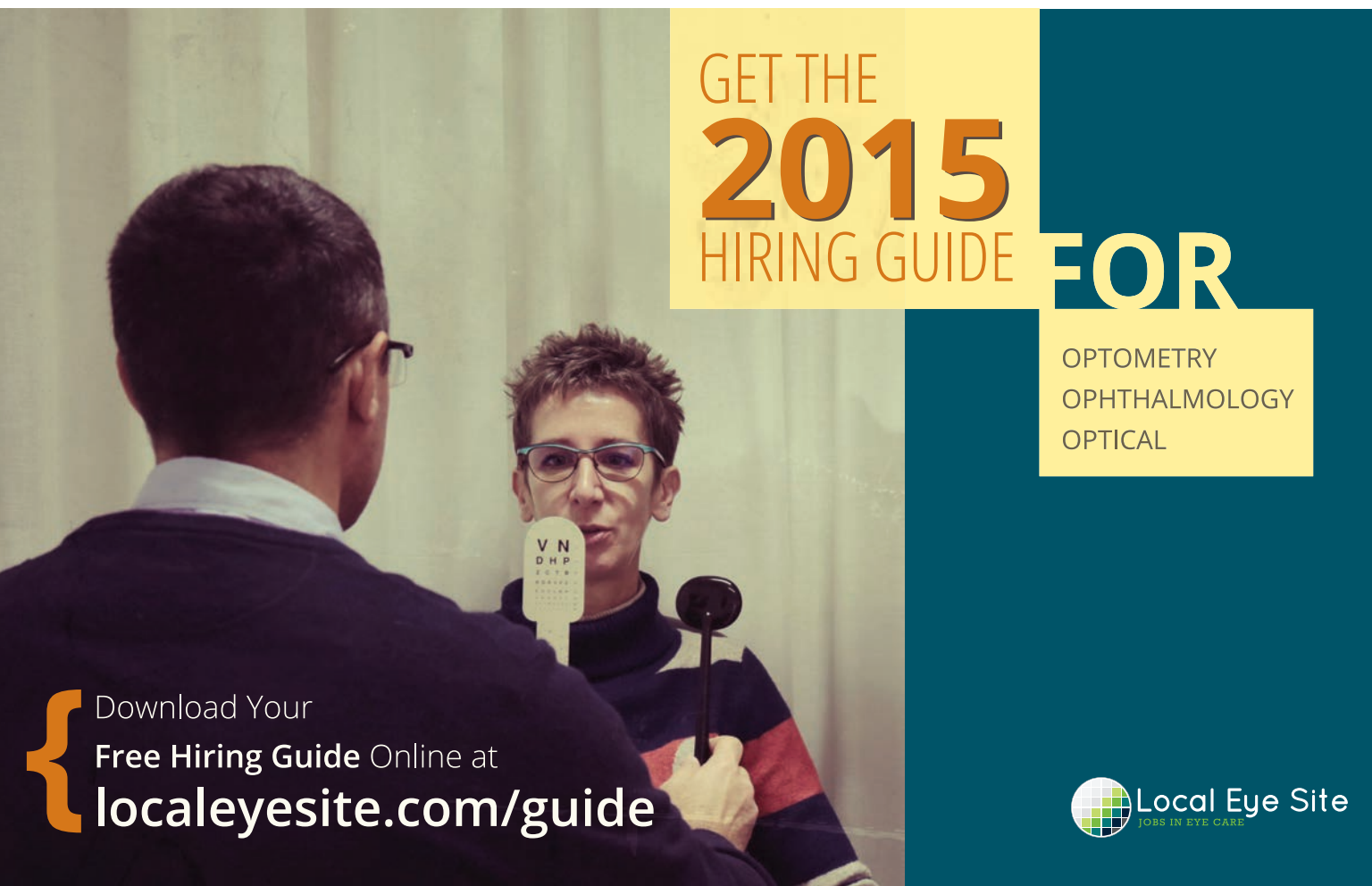
Most concerning was that his binocular testing from the previous optometric records was limited to a cover test and, in one or two instances, a phoria measure, which is only a central tendency measurement. This is not sufficient, so be sure to investigate vergence ranges.

By digging deeper than the basic

sight-based examination, you'll find the source of the patient's visual issue, which will allow you to finally address it. In this patient's case, giving more and more prism, or giving the prism he had before simply because he had it before without doing the requisite testing, was just not solving his problem.

Fortunately, he was no longer flying commercially, so we didn't have to "ground" him. He will begin vision therapy soon after receiving his new glasses with a goal to reduce the amount of the prism needed for fusion and to improve his control over his visual system.^{3,4} ■

1. Harmon DB. Notes on a Dynamic Theory of Vision. Santa Ana, CA: Optometric Extension Program Foundation; 1958.
2. Kraskin RA. Lens Power in Action. Santa Ana, CA: Optometric Extension Program Foundation; 1982.
3. Robertson KM, Kuhn L. Effect of visual training on the vertical vergence amplitude. Am J Optom Physiol Opt. 1985 Oct;62(10):659-68.
4. Cooper J. Orthoptic treatment of vertical deviations. J Am Optom Assoc. 1988 Jun;59(6):463-8.



GET THE 2015 HIRING GUIDE FOR

OPTOMETRY
OPHTHALMOLOGY
OPTICAL

Download Your
Free Hiring Guide Online at
localeyesite.com/guide

 Local Eye Site
JOBS IN EYE CARE



Open Season on Closed Angles

Which comes first in a patient with narrow angles: peripheral iridotomy or cataract extraction? **Edited by Paul C. Ajamian, OD**

Q A 68-year-old Asian female came in for a cataract evaluation, but her angles were so narrow by gonioscopy that I was afraid to dilate her. Do I send her out for a laser peripheral iridotomy first, and then dilate her to assess the cataract?

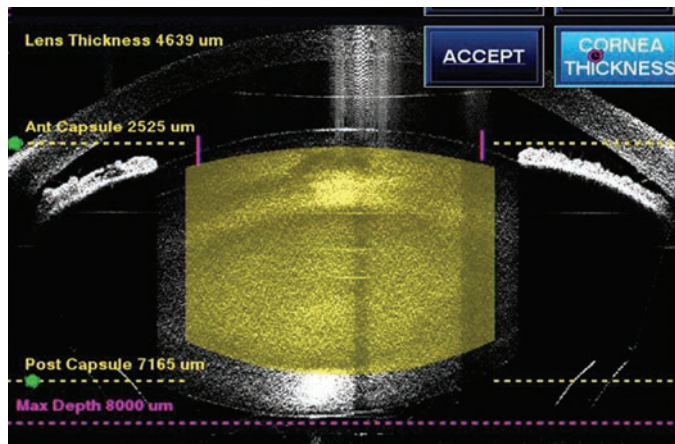
A “Ideal care involves a dilated peripheral exam before cataract surgery,” says David Friedman, MD, PhD, professor of ophthalmology at the Wilmer Eye Institute and director of the Dana Center for Preventive Ophthalmology at Johns Hopkins University School of Medicine. But, this patient’s case is *not* an ideal situation. “It’s a difficult problem and one that requires some judgment. And you’ll get a lot of different responses from different doctors,” Dr. Friedman says.

In his opinion, “I think the risk of an acute attack is very low, even if the angles are closed.”

The question boils down to whether the patient appears ripe for cataract surgery.

• *Cataract surgery is likely.*
 “If you think this is a visually-significant cataract and surgery is imminent, it’s reasonable to refer to your cataract surgeon. Be sure to get a look at the nerve and macula through an undilated pupil before you refer, to alleviate any fundus concerns,” Dr. Friedman says.

The surgeon will dilate the eye at the time of surgery and take out the



When dilating a cataract patient with narrow angles, such as this one, the risk of acute angle-closure attack is very low.

cataract. “The likelihood that the patient will have an acute angle-closure attack when dilated at the time of surgery is really low,” he says. “I even know some surgeons who will use dilation as a provocative test to see if an iridotomy is needed. I don’t personally do that but, because this is an area with limited evidence to support what we do, it’s a fairly reasonable approach.”

Furthermore, “once the cataract is out, there’s pretty much no risk of an acute attack. It would be incredibly unlikely,” Dr. Friedman says. Cataract surgery is essentially the cure for angle closure. “Taking out the lens will open the angle permanently in virtually anyone,” he says.

• *Cataract surgery is not likely.*
 “If the patient doesn’t have a visually significant cataract, and therefore surgery is unlikely in the near future, then I would refer the patient for an iridotomy and moni-

tor for cataract over time,” Dr. Friedman says. “When you do an iridotomy, the angle opens up in about three-quarters of people. So it definitely does alter angle configuration in the majority of patients in whom it’s done.”

Again, this is the case in which the patient does not have visual symptoms. “I wouldn’t

insist that the lens should come out just because there’s angle closure or residual angle closure after an iridotomy,” Dr. Friedman says. “I think that’s going a little too far, because there certainly are risks with cataract surgery—low risks, but risks all the same.”

Q Does the consideration that the patient is Asian factor into the decision of whether to dilate?

A No, says Dr. Friedman, who has researched the epidemiology of angle-closure glaucoma in Asian populations.

“While Asians may have a slightly higher rate of angle closure and angle-closure glaucoma, I still think the risk of acute attack with dilation is very, very small,” he says. Make gonioscopy part of your routine on all patients with shallow chambers, Asian or otherwise, and document your results clearly and carefully. ■



MANUFACTURED
IN THE **USA**

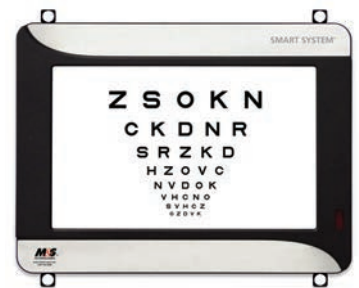Quality Comes Standard

At M&S Technologies, we understand that a quality product makes for a quality customer experience.

But there's more to a quality product than just what comes out of the box. There's service, there's support, there's reliability. M&S provides all of that. Our sales team is available to walk you through the many features and functions of the Smart System[®], and our in-house technical team is standing by to respond to all of your service issues or questions.

We've been in business for almost 25 years and we take your business as seriously as you do. "Good enough" isn't good enough. If you're looking for a high-quality, comprehensive visual acuity testing system that comes with the best customer service and most attentive technical support in the industry, give us a call.

**See us at the COVD Annual Meeting, Booth 27!
Demo our new Sports Vision Performance Test**



*The Smart System 20/20 USA,
shown with optional Glare Lights*



M&S holds US Patents 7,354,155; 7,926,948; 8,425,040;
8,167,429; 8,419,184 & 8,550,631. Other Patents Pending.

©2015 M&S Technologies, Inc. Smart System and M&S are registered
trademarks of M&S Technologies, Inc. All Rights Reserved.

M&S
TECHNOLOGIES

**The First Choice in
Vision Testing Systems**

**www.mstech-eyes.com
1-877-225-6101**

Firm Up Your Approach to Corneal Ectasia

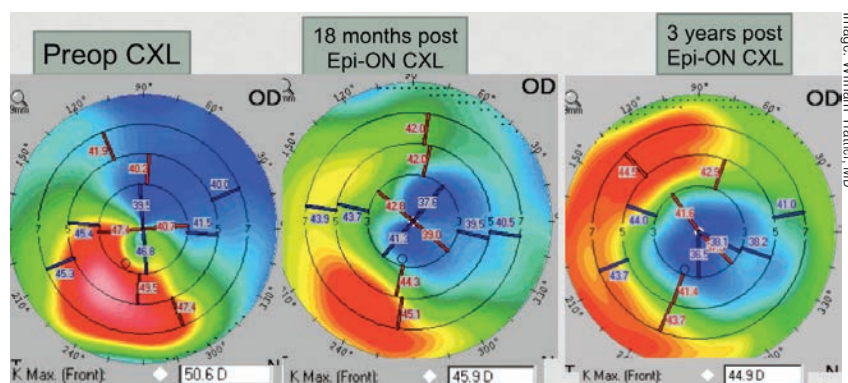
Optometrists must see these patients “through thick and thin.”

By Karen Yeung, OD, and Sally Wu

Corneal ectasia can severely impair vision, especially in the progressive form caused by the inherent structural instability of the cornea. The clinical signs can challenge your detection skills—corneas with subclinical keratoconus are clinically normal in appearance but have subtle irregularities on corneal topography. These cases are especially important to identify because they can easily develop into iatrogenic keratoconus post refractive surgery.¹

Advanced corneal imaging systems are detecting earlier stages of genetically caused ectasias and also minimizing iatrogenic causes of ectasias from LASIK and other corneal surgery procedures.²

Ectasias can also present from contact lens-induced corneal warpage and, while distortion is sometimes permanent, usually these are temporary and return to normal once the CLs are removed. Vision correction for ectasias has been improving through advanced gas permeable/scleral CLs and medically through collagen crosslinking and lamellar surgeries. Regardless of the



Pentacam imaging of a 68-year-old male patient with keratoconus.

cause, treatments to improve the vision of ectasias are similar.

Although treatments are numerous, those within optometry’s purview are mostly limited to corrective lenses; still, we are called upon to diagnose and manage these patients throughout the course of the disease, which can span decades.

For these reasons and more, all optometrists should be well versed in the causes and consequences of corneal ectasia. This article will review current technology for detection, CL corrections for visual symptoms and the range of medical and surgical treatments available.

Causes of Ectasias

Ectasias are either genetically or iatrogenically caused. The most prevalent and most understood genetically caused ectasia is keratoconus. Affecting approximately 50 to 230 per 100,000, keratoconus is a non-inflammatory corneal disease with clinical signs of inferior corneal progressive stromal thinning, scissor reflex upon retinoscopy, corneal protrusion and irregular astigmatism.³⁻⁵ Histopathologically, there is iron deposition in the epithelial basal layer and breaks in Bowman’s layers.⁶ Though typically they present bilaterally asymmetrical, reports

of unilateral keratoconus cases exist.⁷ The second eye of unilateral keratoconus is still considered a suspect for developing keratoconus and is hence contraindicated for LASIK.

Iatrogenic ectasias occur primarily through post-corneal refractive surgery. They are rare, but debilitating when they occur. Studies have reported incidence rates of 0.04% to 0.66%, with higher complications post LASIK as compared to photorefractive keratectomy (PRK).^{1,8-10} Iatrogenic ectasias are generally found in refractive surgery patients that are younger, have high myopia, have thinner corneas or have had multiple refractive surgery enhancements.^{1,11} Thicker flaps, which compromise residual stromal thickness, excessive tissue removal from high refractive errors and/or undiagnosed forme-fruste keratoconus during LASIK, or both, ultimately causes thinner corneas. The thinned corneal biomechanical strength wanes while the intraocular pressure causes forward corneal bowing, resulting in ectasia.¹²

One study found that all patients who develop iatrogenic ectasia post LASIK had at least one predictable

Table 1. Treatment Options for Keratectasia

Ectasia Severity	Early	Moderate	Advanced
CL Treatments	Glasses Soft CLs	Corneal GPs Piggyback CLs Hybrid CLs Scleral lenses	Corneal GPs Scleral lenses
Surgical Treatments	CXL Intracorneal rings	CXL Intracorneal rings	Lamellar keratoplasty PKP

risk factor.¹⁰ Studies have reported post-LASIK ectasia development from three to 57 months after the surgical procedure.^{10,13}

Detection of Ectasia

Whereas moderate and severe ectasias are easily diagnosed with biomicroscopy, retinoscopy and traditional placido disc-based corneal topographies linked to programmed indices and algorithms specifically designed for keratoconus detection and diagnosis, subclinical keratoconus is more difficult to detect.¹⁴⁻¹⁸ The popularity of LASIK and other forms of corneal refractive surgery in the 1990s and the risk of iatrogenic ectasia spurred the development of corneal tomography, which has revolutionized the detection of subclinical keratoconus.

Corneal tomography produces

three-dimensional images of the cornea from two-dimensional cross sections. The modality includes slit scanning, Scheimpflug imaging, OCT and very high frequency (VHF) ultrasound imaging. Each of these devices, when used independently, gathers different information about the cornea. They each evaluate the anterior and posterior corneal elevations and their pachymetric distribution, which is important for detecting any ectasia or predisposition to ectasia. When the information from different devices is used together, the accuracy of ectasia detection is even greater.

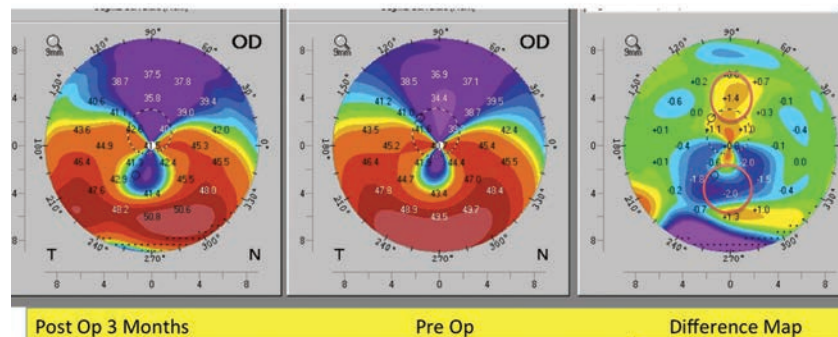
- *Slit scanning* involves slits projected on the cornea. The anterior and posterior edges of the slits are analyzed and presented as three-dimensional topographic maps. Research shows this is more sensitive than earlier devices for detection of keratoconus since it takes images of the entire cornea.¹⁹⁻²¹ The latest slit scanning systems, including the Orbscan II, actually use both slit scanning and placido technology.

- The rotating *Scheimpflug imaging* devices such as the Pentacam (Oculus) measures the anterior and posterior corneal surfaces, as well as corneal volume and spatial profiles from three-dimensional models. Researchers found that keratoconus has thinner corneas with less corneal volume.²²

- *Optical coherence tomography* creates an optical cross sectional scan of the specific layers of the cornea. This could be important for

OD	UCVA	Refraction	BSCVA
Pre Op	200	-3.50+6.50x180	30
3 Months	50	-0.75+1.75x175	25

Image: William Truller, MD



Pentacam imaging of a 38-year-old male with post-LASIK ectasia. The three images detail changes post epi-on crosslinking treatment.

detecting epithelial thickness irregularities, which may be early indicators of early keratoconus.²³

- **VHF ultrasound** measures the thickness of individual corneal layers by a series of scans in different meridians in an arc that matches the curvature of the cornea. Researchers used this to measure the mean thickness of LASIK flaps and found that those with a mean thickness of 163.6µm had greater risks of ectasia, especially in patients with greater ablation depth.²⁴

Treatment of Ectasias

The first-line treatment for visual disturbance due to corneal ectasia is corrective lenses, but recent surgical advances offer the promise of more permanent solutions.

- **Contact lenses.** In early stages of ectasia, spectacles, soft CLs and even custom aberration-correcting soft CLs may be adequate to correct for vision changes. But as the ectasia progresses, the optically smooth surface from a rigid gas permeable (GP) lens is necessary to ameliorate the irregular corneal surface of the ectatic eye to provide clearer vision. Corneal GPs, and now more popularized scleral lenses, are the mainstay visual treatments for these eyes.²⁵ GPs comprise 65% of con-

tact lens correction for keratoconus and has delayed the need for surgery in approximately 80% to 98.9% of all fittings.^{3,26,27}

Corneal GPs range in size from 8mm to 10mm in diameter and are ideal for small central cones or mild keratoconic eyes.²⁸ With increased ectasia severity, larger diameters improve lens centration. Intralimbal lenses are slightly larger at 10.5mm to 12mm in diameter. Though corneal GPs provide crisper vision than soft lenses, dropout occurs from discomfort. Piggyback CLs can improve comfort, but can be inconvenient for patients because of their need to clean and care for both soft and GP contact lenses. Hybrid CLs may also improve the comfort; however, their variable clinical performance, high giant papillary conjunctivitis rates and breakage at the GP and soft lens junction may limit their use.^{29,30} The very recent surge of scleral lens options and popularity has provided a more comfortable option for ectatic eyes.

Scleral lenses are generally reserved for moderate to advanced stages of ectasia as well as those who have failed in comfort from traditional GPs. Whereas corneosclerals (12.9mm to 14.9mm) rest on both the cornea and sclera,

minisclerals (15.0mm to 18.0mm) and full scleral lenses (18.1mm to 24.0mm) rest entirely on the conjunctiva and vault over the cornea.^{28,31} Larger lenses are more comfortable especially for those with focally steep cones or those with sensitive corneal epithelium since vaulted lenses reduce friction with the cornea.^{28,32} Scleral lenses should be fit with the highest Dk material possible and without excessive corneal clearance, to minimize hypoxia from the combination lens and tear film thickness.³³

- **Medical/surgical treatment.** For ectatic patients who are intolerant of CLs, medical and surgical treatments are available. Traditional treatments have been limited to contact lenses and full-thickness penetrating keratoplasty (PKP). Though graft survival rates usually extend up to 20 years and sometimes beyond, reasons to defer doing PKPs for as long as possible include the generally young age of keratoconic patients (and thus the challenge of achieving life-long graft survival), graft rejection and failure, surgical complications and the risks of developing secondary cataracts and glaucoma from long-term steroid use. Visual rehabilitation after PKP is also difficult.

- **Intrastromal corneal ring segment implantation.** For mild to moderate ectasias with little to no corneal scarring, intrastromal corneal ring (Intacs) use is an option. It involves the insertion of one or two polymethylmethacrylate segments into the corneal stroma to flatten the irregular anterior corneal shape and hence improve uncorrected visual acuity.³⁴ Segments of varying thickness can be implanted; the thicker the segment, the more significant the flattening effect. They are generally inserted on the inferior cornea to flatten the steep

FDA Approval Pending for US Launch of Crosslinking for Keratoconus

Though its advisory panel recommended approval, the FDA recently requested additional information before giving the go-ahead to Avedro's drug/device combination of Photrexa (riboflavin) and KXL System (UVA light) for the treatment of progressive keratoconus and corneal ectasia following refractive surgery. The company is working to address the questions and move forward with FDA approval.

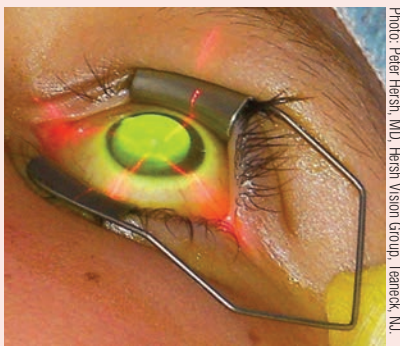


Photo: Peter Hersh, MD, Hersh Vision Group, Teaneck, NJ

A keratoconic patient undergoing a collagen crosslinking procedure.

areas of inferiorly located cones. Intrastromal corneal rings do not stop the progression of keratoconus and the residual refractive errors are often more challenging to treat with corneal GP contact lenses due to the sharp topography differences at the junction of the intrastromal corneal ring segment.³⁵ Complications many include patient dissatisfaction with visual outcomes, discomfort and ring segment extrusion.³⁶

• **Collagen crosslinking (CXL).**

Whereas the current treatments for ectasias revolve around visual rehabilitation, CXL is a promising treatment to actually delay and potentially halt the progression of many ectasias, including keratoconus, pellucid marginal degeneration and post-LASIK ectasias.³⁷⁻⁴⁰ It is a procedure that increases corneal rigidity and biomechanical stabil-

Clinical Pearls

- Consider using multiple corneal imaging technologies along with clinical judgment to best identify early ectasias.
- For early and moderate ectasias, including the “normal” eye of a keratoconic patient, CXL is a viable option to preserve and ideally prevent progression.
- For moderate to advanced ectasias, or patients who are intolerant of GP lenses, consider a scleral lens. Fit a high Dk material without excessive corneal clearance to prevent hypoxia.
- Expect to see more CXL procedures performed in tandem with other corneal surgeries.

ity by forming new chemical bonds between the collagen strands of the corneal stroma. This is a procedure

that would most benefit early to moderate ectasias.

CXL involves the application of riboflavin on epithelialized or de-epithelialized central corneas, depending upon protocol treatment. The cornea is then exposed to ultraviolet A light, which activates the riboflavin and creates new crosslinks within the collagen and intrastromal matrix of the stroma.⁴⁰ CXL on de-epithelialized corneas is more effective than on epithelialized corneas, but there is a longer recovery time, more patient discomfort and increased risk of infections.^{37,41}

Accelerated CXL uses a higher intensity UV light for shorter periods of time. Studies are evaluating the effectiveness and safety profile of accelerated vs. non-accelerated CXL. Evidence may show that the accelerated CXL is as effective and

A Successful Specialty Contact Lens Practice Starts With An Experienced Specialty Lens Partner



If you want fitting specialty lenses to be a great experience, demand a partner that has great experience. Alden Optical® has been making outstanding specialty lenses for over 45 years. Just as important, our team has a combined 324 years of contact lens experience—a remarkable average of 18 years per employee.

From lenses designed to ensure great success, to service and support that intuitively meet your needs, to a small company ethos that knows and empathizes with your challenges, partnering with Alden Optical is an experience that delivers unparalleled value.

- Every single lens is backed by our exclusive 90-day EZ-Exchange™ warranty, including full cancellation privileges—even on Zenlens™
- All lenses manufactured in three days* or less
- Expert consultation and customer service



aldenoptical.com
800.253.3669
info@aldenoptical.com

* Please add 2-3 days for prosthetics and enhancement tints. Alden Optical, ASTERA, EZ-Exchange, NovaKone, and Zenlens are trademarks or registered trademarks of Alden Optical Laboratories.

safe as conventional CXL, but more research is needed.⁴² Though rare, risks of complications post CXL include corneal haze, keratitis, endothelial cell loss and CXL ineffectiveness.^{39,40}

Long-term studies are limited, but show promise in achieving ectasia stability in many patients. Researchers found the standard CXL method improved visual acuities and stabilized the progression of post-LASIK induced ectasias over 42 months.⁴⁰ In a retrospective case series, another study found that accelerated CXL was able to halt the progression of keratoconus, in addition to improving their patients' visual acuities, keratometry values and corneal aberrations after 24 months.³⁹ Overall, CXL is a novel treatment to stabilize the progression of both keratoconus and post-LASIK ectasia.

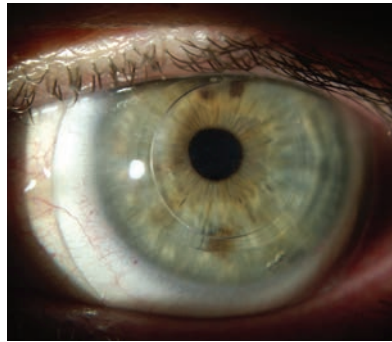


Photo: William Trattler, MD

Intacs in an eye with keratoconus.

Combining other interventions with CXL offers a new frontier in treatment that addresses both structural and refractive needs. While intrastromal corneal rings improve the visual acuity, CXL performed after intrastromal corneal ring implantation stabilizes the cornea to slow down future progression.⁴³ One study showed the addition of the corneal crosslinking after

intrastromal corneal ring insertion improved the keratoconic outcomes more than corneal crosslinking alone.⁴⁴ But caution is warranted since keratoconus can still progress years after corneal crosslinking.^{45,46}

• **Lamellar keratoplasty.** When the above treatments fail, severe ectasias may require surgical intervention. Lamellar procedures such as deep anterior lamellar keratoplasty (DALK) and crescentic lamellar keratoplasty are options. DALK involves removing the corneal stroma down to Descemet's membrane and replacing it with donor cornea with or without Descemet's membrane. Compared to PKP, DALK offers a lower risk of graft rejection, early visual rehabilitation, better wound strength and limited endothelial cell loss. It is a complicated procedure, but one with the same rate of graft survival and final visual acuity outcomes as PKP.⁴⁷

For ectasias that involve the far periphery of the cornea, such as in pellucid marginal degeneration, large-diameter PKPs are discouraged as their proximity to the limbus and its blood vessels make grafts more prone to rejections.

Semilunar, crescentic and annular lamellar keratoplasty use donor grafts that spare the central cornea. The central vision is minimally affected even if the graft is rejected and becomes opaque. These grafts decrease the overall corneal astigmatism, but the results can be short-lived because thinning and ectasia can recur.^{48,49}

Advancements in ectasia detection, prevention and treatment are constantly emerging. Improved technologies, especially in the form of corneal tomography, can now identify genetically caused ectasias at early stages. The combination of the different tomography systems provides complementary views of

A Consensus on Keratoconus


Thirty-six experts from around the world recently came to a consensus on definitions and recommendations related to keratoconus and other ectatic diseases.¹ A few of the key items agreed upon include:

- Abnormal posterior ectasia, abnormal corneal thickness distribution and clinical noninflammatory corneal thinning are mandatory findings for a keratoconus diagnosis.
- Ectatic disorders include keratoconus, pellucid marginal degeneration (PMD), keratoglobus and postrefractive surgery progressive corneal ectasia.
- True unilateral keratoconus "does not exist."
- Keratoconus, PMD and keratoglobus are distinguished by the thinning location and pattern.
- The best and most widely used test to diagnose early keratoconus is corneal tomography (Scheimpflug imaging or anterior segment OCT).
- Visual rehabilitation and halting disease progression are the two main goals of nonsurgical management of keratoconus.
- Contact lenses do not slow or halt disease progression, but are important for visual rehabilitation.
- Patients should pursue surgical intervention only if they are not satisfied with their vision with contact lenses or glasses.
- Corneal crosslinking (CXL) is very important for patients with documented progression of keratoconus.

To read more about the consensus report, visit www.reviewofoptometry.com/web_exclusives/.

1. Gomes JA, Tan D, Rapuano CJ, et al. Global consensus on keratoconus and ectatic diseases. *Cornea*. 2015;34(4):359-69.


LOTEMAX® GEL—UNIQUE FORMULATION DESIGNED TO CONTROL INFLAMMATION

 **MUCOADHESIVE TECHNOLOGY—**
Engineered to adhere to the ocular surface¹⁻³

 **DOSE UNIFORMITY—**
No shaking required to resuspend drug^{1,4,5}

 **LOW PRESERVATIVE AND TWO
KNOWN MOISTURIZERS^{1,2,4,6}**

 **PROVEN EFFICACY AND
ESTABLISHED SAFETY^{1,2,7}**



Indications and Usage

- LOTE MAX® GEL is a corticosteroid indicated for the treatment of post-operative inflammation and pain following ocular surgery

Important Risk Information about LOTE MAX® GEL

- LOTE MAX® GEL is contraindicated in most viral diseases of the cornea and conjunctiva including epithelial herpes simplex keratitis (dendritic keratitis), vaccinia, and varicella, and also in mycobacterial infection of the eye and fungal diseases of ocular structures
- Intraocular pressure (IOP) increase—Prolonged use of corticosteroids may result in glaucoma with damage to the optic nerve, defects in visual acuity and fields of vision. If this product is used for 10 days or longer, IOP should be monitored
- Cataracts—Use of corticosteroids may result in posterior subcapsular cataract formation
- Delayed healing—Use of steroids after cataract surgery may delay healing and increase the incidence of bleb formation and occurrence of perforations in those with diseases causing corneal and scleral thinning. The initial prescription and renewal of the medication order should be made by a physician only after examination of the patient with the aid of magnification
- Bacterial infections—Prolonged use of corticosteroids may suppress the host response and thus increase the hazard of secondary ocular infection. In acute purulent conditions, steroids may mask infection or enhance existing infections
- Viral infections—Use of corticosteroid medication in the treatment of patients with a history of herpes simplex requires great caution. Use of ocular steroids may prolong the course and exacerbate the severity of many viral infections of the eye (including herpes simplex)
- Fungal infections—Fungal infections of the cornea are particularly prone to develop coincidentally with long-term local steroid application. Fungus invasion must be considered in any persistent corneal ulceration where a steroid has been used or is in use
- Contact lens wear—Patients should not wear contact lenses when using LOTE MAX® GEL
- The most common ocular adverse drug reactions were anterior chamber inflammation (5%), eye pain (2%) and foreign body sensation (2%)

Please see brief summary of full prescribing information on adjacent page.

References: 1. LOTE MAX GEL Prescribing Information, September 2012. 2. Fong R, Leitritz M, Siou-Mermet R, Erb T. Loteprednol etabonate gel 0.5% for postoperative pain and inflammation after cataract surgery: results of a multicenter trial. *Clin Ophthalmol*. 2012;6:1113-1124. 3. Shaikh R, Singh TRR, Garland MJ, Woolfson AD, Donnelly RF. Mucoadhesive drug delivery systems. *J Pharm Bioallied Sci*. 2011;3(1):89-100. 4. Data on file, Bausch & Lomb Incorporated. 5. Coffey MJ, Davio SR. Viscoelastic and sedimentation characterization of loteprednol etabonate ophthalmic gel, 0.5%. Poster presented at: Association for Research in Vision and Ophthalmology (ARVO); May 6-10, 2012; Fort Lauderdale, FL. Poster #6283/D1143. 6. Lotemax Prescribing Information, April 2006. 7. Rajpal RK, Roel I, Siou-Mermet R, Erb T. Efficacy and safety of loteprednol etabonate 0.5% gel in the treatment of ocular inflammation and pain after cataract surgery. *J Cataract Refract Surg*. 2013;39:158-167.

®/™ are trademarks of Bausch & Lomb Incorporated or its affiliates. ©2013 Bausch & Lomb Incorporated. US/LGX/13/0049 [4/13]

BAUSCH + LOMB



LOTE MAX® GEL
loteprednol etabonate
ophthalmic gel 0.5%

DISCOVER THE POWER OF GEL

BAUSCH + LOMB

LOTEMAX[®]

loteprednol etabonate
ophthalmic gel 0.5%

Brief Summary: Based on full prescribing information.

To report SUSPECTED ADVERSE REACTIONS, contact Bausch & Lomb at 1-800-323-0000 or FDA at 1-800-FDA-1088 or www.fda.gov/medwatch

INDICATIONS AND USAGE

LOTEMAX is a corticosteroid indicated for the treatment of post-operative inflammation and pain following ocular surgery.

DOSAGE AND ADMINISTRATION

Invert closed bottle and shake once to fill tip before instilling drops.

Apply one to two drops of LOTEMAX into the conjunctival sac of the affected eye four times daily beginning the day after surgery and continuing throughout the first 2 weeks of the post-operative period.

CONTRAINDICATIONS

LOTEMAX, as with other ophthalmic corticosteroids, is contraindicated in most viral diseases of the cornea and conjunctiva including epithelial herpes simplex keratitis (dendritic keratitis), vaccinia, and varicella, and also in mycobacterial infection of the eye and fungal diseases of ocular structures.

WARNINGS AND PRECAUTIONS

Intraocular Pressure (IOP) Increase

Prolonged use of corticosteroids may result in glaucoma with damage to the optic nerve, defects in visual acuity and fields of vision. Steroids should be used with caution in the presence of glaucoma. If this product is used for 10 days or longer, intraocular pressure should be monitored.

Cataracts

Use of corticosteroids may result in posterior subcapsular cataract formation.

Delayed Healing

The use of steroids after cataract surgery may delay healing and increase the incidence of bleb formation. In those diseases causing thinning of the cornea or sclera, perforations have been known to occur with the use of topical steroids. The initial prescription and renewal of the medication order should be made by a physician only after examination of the patient with the aid of magnification such as slit lamp biomicroscopy and, where appropriate, fluorescein staining.

Bacterial Infections

Prolonged use of corticosteroids may suppress the host response and thus increase the hazard of secondary ocular infections. In acute purulent conditions of the eye, steroids may mask infection or enhance existing infection.

Viral Infections

Employment of a corticosteroid medication in the treatment of patients with a history of herpes simplex requires great caution. Use of ocular steroids may prolong the course and may exacerbate the severity of many viral infections of the eye (including herpes simplex).

Fungal Infections

Fungal infections of the cornea are particularly prone to develop coincidentally with long-term local steroid application. Fungus invasion must be considered in any persistent corneal ulceration where a steroid has been used or is in use. Fungal cultures should be taken when appropriate.

Contact Lens Wear

Patients should not wear contact lenses during their course of therapy with LOTEMAX.

ADVERSE REACTIONS

Adverse reactions associated with ophthalmic steroids include elevated intraocular pressure, which may be associated with infrequent optic nerve damage, visual acuity and field defects, posterior subcapsular cataract formation, delayed wound healing and secondary ocular infection from pathogens including herpes simplex, and perforation of the globe where there is thinning of the cornea or sclera.

The most common adverse drug reactions reported were anterior chamber inflammation (5%), eye pain (2%), and foreign body sensation (2%).

USE IN SPECIFIC POPULATIONS

Pregnancy

Teratogenic Effects: Pregnancy Category C.

Loteprednol etabonate has been shown to be embryotoxic (delayed ossification) and teratogenic (increased incidence of meningocele, abnormal left common carotid artery, and limb flexures) when administered orally to rabbits during organogenesis at a dose of 3 mg/kg/day (35 times the maximum daily clinical dose), a dose which caused no maternal toxicity. The no-observed-effect-level (NOEL) for these effects was 0.5 mg/kg/day (6 times the maximum daily clinical dose). Oral treatment of rats during organogenesis resulted in teratogenicity (absent innominate artery at ≥ 5 mg/kg/day doses, and cleft palate and umbilical hernia at ≥ 50 mg/kg/day) and embryotoxicity (increased post-implantation losses at 100 mg/kg/day and decreased fetal body weight and skeletal ossification with ≥ 50 mg/kg/day). Treatment of rats with 0.5 mg/kg/day (6 times the maximum clinical dose) during organogenesis did not result in any reproductive toxicity. Loteprednol etabonate was maternally toxic (significantly reduced body weight gain during treatment) when administered to pregnant rats during organogenesis at doses of ≥ 5 mg/kg/day.

Oral exposure of female rats to 50 mg/kg/day of loteprednol etabonate from the start of the fetal period through the end of lactation, a maternally toxic treatment regimen (significantly decreased body weight gain), gave rise to decreased growth and survival, and retarded development in the offspring during lactation; the NOEL for these effects was 5 mg/kg/day. Loteprednol etabonate had no effect on the duration of gestation or parturition when administered orally to pregnant rats at doses up to 50 mg/kg/day during the fetal period.

There are no adequate and well controlled studies in pregnant women. LOTEMAX should be used during pregnancy only if the potential benefit justifies the potential risk to the fetus.

Nursing Mothers

It is not known whether topical ophthalmic administration of corticosteroids could result in sufficient systemic absorption to produce detectable quantities in human milk. Systemic steroids appear in human milk and could suppress growth, interfere with endogenous corticosteroid production, or cause other untoward effects. Caution should be exercised when LOTEMAX is administered to a nursing woman.

Pediatric Use

Safety and effectiveness in pediatric patients have not been established.

Geriatric Use

No overall differences in safety and effectiveness have been observed between elderly and younger patients.

NONCLINICAL TOXICOLOGY

Carcinogenesis, Mutagenesis, Impairment Of Fertility

Long-term animal studies have not been conducted to evaluate the carcinogenic potential of loteprednol etabonate. Loteprednol etabonate was not genotoxic *in vitro* in the Ames test, the mouse lymphoma tk assay, or in a chromosome aberration test in human lymphocytes, or *in vivo* in the single dose mouse micronucleus assay. Treatment of male and female rats with up to 50 mg/kg/day and 25 mg/kg/day of loteprednol etabonate, respectively, (600 and 300 times the maximum clinical dose, respectively) prior to and during mating did not impair fertility in either gender.

PATIENT COUNSELING INFORMATION

Administration

Invert closed bottle and shake once to fill tip before instilling drops.

Risk of Contamination

Patients should be advised not to allow the dropper tip to touch any surface, as this may contaminate the gel.

Contact Lens Wear

Patients should be advised not to wear contact lenses when using LOTEMAX.

Risk of Secondary Infection

If pain develops, redness, itching or inflammation becomes aggravated, the patient should be advised to consult a physician.

FOR MORE DETAILED INFORMATION, PLEASE READ THE PRESCRIBING INFORMATION.

Bausch & Lomb Incorporated

Tampa, Florida 33637 USA

US Patent No. 5,800,807

©Bausch & Lomb Incorporated

®/™ are trademarks of Bausch & Lomb Incorporated or its affiliates.

the cornea to hopefully provide a better understanding of the predictors of iatrogenic ectasia and ultimately eliminate that as well. Ectasia patients are fortunate to have growing visual rehabilitation treatment options in the advancing areas of contact lenses, collagen crosslinking, intrastromal corneal ring implantation and lamellar surgeries. Future combination treatments with CXL will hopefully one day eliminate the need for corneal transplantation. ■

Dr. Yeung is a diplomate in the Cornea, Contact Lenses, and Refractive Technologies section of the American Academy of Optometry. She is the senior optometrist at UCLA Arthur Ashe Student Health and Wellness and a clinical assistant professor of Western University of Health Sciences College of Optometry.

Sally Wu is a pre-optometry student getting a BA in psychology at UCLA, class of 2015.

A New Organization Focused on Keratoconus

The International Keratoconus Academy of Eye Care Professionals (IKA) was recently established to promote ongoing education and scientific development in the area of keratoconus and other forms of corneal ectasia. It will also promote the awareness and understanding of treatment strategies.

IKA will provide an array of educational initiatives, including live events, web-based education, social media activities and publications in the professional literature. It will cooperate with other organizations—such as the National Keratoconus Foundation—to advance knowledge, awareness and quality of care.

The founding executive board includes Barry Eiden, OD, Andrew Morgenstern, OD, Timothy McMahon, OD, Joseph Barr, OD, William Tullo, OD, Clark Chang, OD, Eric Donnenfeld, MD, and Yaron Rabinowitz, MD. Professionals interested in membership in IKA should email the group: info@keratoconusacademy.com.

- Randleman JB, Woodward M, Lynn M, et al. Risk assessment for ectasia after corneal refractive surgery. *Ophthalmol*. 2008;115:37-50.
- McMonnies CW. Screening for keratoconus suspects among candidates for refractive surgery. *Clin & Exp Optom*. 2014;97:492-8.
- Kennedy RH, Bourne WM, Dyer JA. A 48-year clinical and epidemiologic study of keratoconus. *Am J Ophthalmol*. 1986;101:267-73.
- Rabinowitz YS. Keratoconus: major review. *Survey of Ophthalmol*. 1998;42(4):297-319.
- Romero-Jimenez M, Santodomingo-Rubido J, Woffsohn JS. Keratoconus: a review. *Cont Lens Anterior Eye*. 2010;33:157-66.
- Sherwin T, Brookes, NH. Morphological changes in keratoconus: pathology or pathogenesis. *Clin Experiment Ophthalmol*. 2004;32(2):211-7.
- Li X, Rabinowitz YS, Rasheed K, et al. Longitudinal study of the normal eyes in unilateral keratoconus patients. *Ophthalmology*. 2004;111(3):440-6.
- Rad AS, Jabbarvand M, Saifi N. Progressive keratectasia after laser in situ keratomileusis. *J Refract Surg*. 2004;20(5):S718-22.
- Pallikaris IG, Kymionis GD, Astyrakakis NI. Corneal ectasia induced by laser in situ keratomileusis. *J Cataract Refract Surg*. 2001;27(11):1796-802.
- Randleman JB, Russell B, Ward MA, et al. Risk factors and prognosis for corneal ectasia after LASIK. *Ophthalmology*. 2003;110:267-75.
- Holland SP, Srivannaboon S, Reinsteinst DZ. Avoiding serious corneal complications of laser assisted in situ keratomileusis and photorefractive keratectomy. *Ophthalmol*. 2000;107:640-52.
- Ambrosio R Jr, Nogueira LP, Caldas DL, et al. Evaluation of corneal shape and biomechanics before LASIK. *Int Ophthalmol Clin*. 2011;51:11-39.
- Said A, Hamade JH, Tabbara KF. Late onset corneal ectasia after LASIK surgery. *Saudi J Ophthalmol*. 2011;25:225-30.
- Kalin NS, Maeda N, Klyce SD, et al. Automated topographic screening for keratoconus in refractive surgery candidates. *CLAO J*. 1996;22:164-7.
- Maeda N, Klyce SD, Smolek MK, et al. Automated keratoconus screening with corneal topography analysis. *Invest Ophthalmol Vis Sci*. 1994;35:2749-57.
- Maeda N, Klyce SD, Smolek MK. Comparison of methods for detecting keratoconus using videokeratography. *Arch Ophthalmol*. 1995;113(7):870-4.
- Rabinowitz YS, McDonnell PJ. Computer-assisted corneal topography in keratoconus. *Refract Corneal Surg*. 1989;5:400-8.
- Rabinowitz YS, Rasheed K. KISA% index: a quantitative videokeratography algorithm embodying minimal topographic criteria for diagnosing keratoconus. *J Cataract Refract Surg*. 1999;25(10):1327-35.
- Lim L, Wei RH, Chan WK, et al. Evaluation of keratoconus in Asians: role of Orbscan II and Tomey TMS-2 corneal topography. *Am J Ophthalmol*. 2007;143(3):390-400.
- Reddy JC, Rapuano CJ, Cater JR, et al. Comparative evaluation of dual Scheimpflug imaging parameters in keratoconus, early keratoconus, and normal eyes. *J Cataract Refract Surg*. 2014;40:582-92.
- Sahin A, Yildirim N, Basmak H. Two-year interval changes in Orbscan II topography in eyes with keratoconus. *J Cataract Refract Surg*. 2008;34(8):1295-9.
- Ambrosio R, Alonso RS, Luz A, et al. Corneal-thickness spatial profile and corneal-volume distribution: tomographic indices to detect keratoconus. *J Cataract Refract Surg*. 2006;32:1851-9.
- Kanellopoulos AJ, Asimellis G. OCT corneal epithelial topographic asymmetry as a sensitive diagnostic tool for early and advancing keratoconus. *Clin Ophthalmol*. 2014;18(8):2277-87.
- Reinsteinst DZ, Sutton HF, Srivannaboon S, et al. Evaluating microkeratome efficacy by 3D corneal lamellar flap thickness accuracy and reproducibility using Artemis VHF digital ultrasound Arc-Scanning. *J Refract Surg*. 2006;22:431-40.
- Weed KH, MacEwen CJ, McGhee CN. The Dundee University Scottish Keratoconus Study II: a prospective study of optical and surgical correction. *Ophthalmic Physiol Opt*. 2007;27(6):561-7.
- Wagner H, Barr JT, Zadnik K. Collaborative Longitudinal Evaluation of Keratoconus (CLEK) Study: methods and findings to date. *Cont Lens Anterior Eye*. 2007;30(4):223-32.
- Bilgin LK, Yilmaz S, Araz B, et al. 30 years of contact lens prescribing for keratoconic patients in Turkey. *Contact Lens Ant Eye*. 2009;32:16-21.
- Barnett M, Mannis J. Contact lens in the management of keratoconus. *Cornea*. 2011;30(12):1510-6.
- Maguen E, Caroline P, Rosner IR, et al. The use of the SoftPerm lens for the correction of irregular astigmatism. *CLAO J*. 1992;18(3):173-6.
- Abdalla YF, Elsahn AF, Hammersmith KM, et al. SynergEyes lenses for keratoconus. *Cornea*. 2010;29(1):5-8.
- Worp EVD, Bornman D, Ferreira DL, et al. Modern scleral contact lenses: A review. *Contact Lens & Anterior Eye*. 2014;37:240-50.
- Schormack MM, Patel SV. Scleral lenses in the management of keratoconus. *Eye & Contact Lens*. 2010;36(1):39-44.
- Jaynes JM, Edrington TB, Weissman BA. Predicting scleral GP lens entrapped tear layer oxygen tensions. *CLAE*. 2015;44:7.
- Zare MA, Hashemi H, Salari MR. Intracorneal ring segment implantation for the management of keratoconus: safety and efficacy. *J Cataract Refract Surg*. 2007;33:1886-91.
- Hladun L, Harris M. Contact lens fitting over intrastromal corneal rings in a keratoconic patient. *Optometry*. 2004;75(1):48-54.
- Pinero DP, Alio JL, Uceda-Montanes A, et al. Intracorneal ring segment implantation in corneas with post-laser in situ keratomileusis keratectasia. *Ophthalmol*. 2009;116(9):1665-74.
- Lesniak SP, Hersh PS. Transepithelial corneal collagen crosslinking for keratoconus: Six-month results. *J Cataract Refract Surg*. 2014;40:1971-9.
- Moshirfar M, Edmonds JN, Behunin NL, et al. Current options in the management of pellucid marginal degeneration. *Journal of Refractive Surgery*. 2014;30(7):474-85.
- Ozgurhan EB, Kara N, Cankaya KI, et al. Accelerated corneal cross-linking in pediatric patients with keratoconus: 24-Month Outcomes. *Journal of Refractive Surgery*. 2014;30(12):843-9.
- Yildirim A, Cakir H, Kara, et al. Corneal collagen crosslinking for ectasia after laser in situ keratomileusis: Long-term results. *J Cataract Refract Surg*. 2014;40:1591-6.
- Hashemiman H, Jabbarvand M, Khodaparast M, et al. Evaluation of corneal changes after conventional versus accelerated corneal cross-linking: A randomized controlled trial. *Journal of Refractive Surgery*. 2014;30(12):837-42.
- Konstantopoulos A, Mehta JS. Conventional versus accelerated collagen cross-linking for keratoconus. *Eye & Contact Lens*. 2014. (E-pub ahead of print).
- Ferial MZ, Jawkhab AA, Al-Tuwairiqi W, et al. Visual rehabilitation in low-moderate keratoconus: intracorneal ring segment implantation followed by same-day topography-guided photorefractive keratectomy and collagen cross linking. *Int J Ophthalmol*. 2014;7(5):800-6.
- Chan CC, Sharma M, Wachler BS. Effect of inferior-segment Intacs with and without C3-R on keratoconus. *J Cataract Refract Surg*. 2007;33(1):75-80.
- Kymionis GD, Kontadakis GA, Kounis GA, et al. Simultaneous topography-guided PRK followed by corneal collagen cross-linking for keratoconus. *J Refract Surg*. 2009;25(9):s807-11.
- Kymionis GD, Karavitaki AE, Grentzelos MA, et al. Topography based keratoconus progression after corneal cross-linking. *Cornea*. 2014;33(4):419-21.
- Keane M, Coster D, Ziaei M, et al. Deep anterior lamellar keratoplasty versus penetrating keratoplasty for treating keratoconus. *Cochrane Database Syst Rev*. 2014;22(7):CD009700.
- Maccheron LJ, Daya SM. Wedge resection and lamellar dissection for pellucid marginal degeneration. *Cornea*. 2012;31(6):708-15.
- Rasheed K, Rabinowitz YS. Surgical treatment of advanced pellucid marginal degeneration. *Ophthalmol*. 2000;107:1836-40.



Essential Procedures at the Slit Lamp:

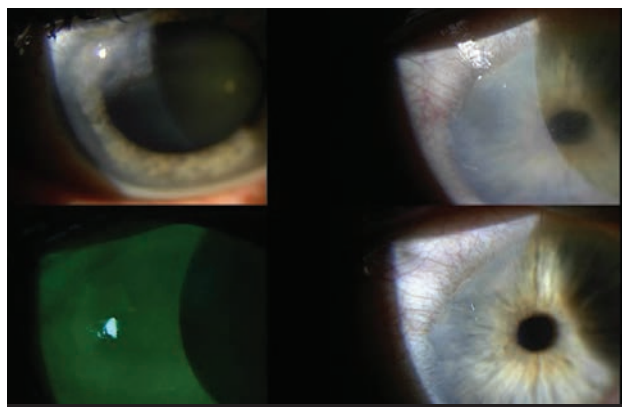
Perform DBD with ASP for Stubborn RCE

If anterior stromal puncture doesn't do the job for recalcitrant recurrent corneal erosion, here's a more aggressive option. **By Jason Ellen, OD, and Nathan Lighthizer, OD**

“**D**oc, I'm afraid to open my eyes in the morning.” It's a complaint that's both shocking and severe in nature. But, it's one that we've heard several times in our clinical experience.

These were extremely frustrated patients who had a long history of recurrent corneal erosions. They had already tried medical therapy, including doxycycline, Muro 128 (Bausch + Lomb), FreshKote (Focus Labs), topical steroids and even bandage contact lenses—all without success.

In these severe cases, is there another surgical option that could benefit such patients? How and when do you perform these more aggressive procedures?



Top left: a patient with Salzmans nodular degeneration and epithelial basement membrane dystrophy prior to debridement. Top right: post-treatment day one with amniotic membrane ring in place. Bottom left: day one with fluorescein stain and filter. Bottom right: at one month out, the eye has almost fully healed.

and recurrent symptoms—but difficult to treat, especially when it's recalcitrant RCE.

Previous articles have discussed numerous conservative treatment modalities that are very effective in managing most cases of RCE, including hypertonic ointment, bandage soft contact lenses, oral doxycycline, topical steroids and anterior stromal puncture (ASP).¹ (See “Simple ASP at the Slit Lamp,” facing page.)

However, many of the cases seen in our surgical referral center are patients with more stubborn RCE who have failed combinations of these nonsurgical therapeutic regimens. Difficult and recalcitrant cases seem to be a result of traumatic RCE coupled with a history of EBMD. (In our clinical experience of treating recalcitrant cases that have failed conservative

In this article—the fourth in a six-part, print-and-video instructional series—we'll show you how we do it.

DBD and ASP for Tough Cases

Recurrent corneal erosion (RCE) not only can be difficult to diagnose—due to its usual presentation of few clinical signs yet debilitating



To see a narrated video of this procedure, visit www.reviewofoptometry.com, or scan this QR code.

therapy, many seem to have concurrent EBMD that may involve the entire cornea, which likely contributes to the poorer adhesion of the epithelium in the area of previous trauma.) So, the therapeutic goal is to not only treat the current area of erosion, but also to help prevent future complications/erosions in other areas due to the underlying EBMD.

If the patient with EMBD has failed aggressive topical and oral therapy for RCE, consider surgical treatment with or without ASP. Surgical treatments include diamond burr debridement (DBD) and phototherapeutic keratectomy (PTK).

- **DBD.** Studies have shown that removal of the affected area of epithelium combined with polishing Bowman's layer using a diamond burr decreases the recurrence rate (6%) when compared with debridement alone (18% recurrence).²

- **PTK.** This is also an excellent option to smooth the corneal surface after epithelial debridement; however, the cost to the patient is usually higher because reimbursement for use of the laser is rarely covered under insurance. Furthermore, research has shown that PTK has a slightly higher incidence of postsurgical haze and recurrence when compared with DBD.³

Accordingly, here's a step-by-step method for DBD with ASP.

1. Discuss the Procedure

In most cases, these patients have reached the point where they're ready for a treatment that is more aggressive because conservative therapy has failed and they're miserable.

Discuss the risks and benefits of the procedure, and have the patient sign a consent form. (The risks include mild scarring of the cornea in the treated area, possible

Simple ASP at the Slit Lamp

If a patient has simple recurrent erosion from previous trauma (such as a fingernail to the cornea) and no underlying sign of epithelial basement membrane dystrophy (EBMD), anterior stromal puncture at the slit lamp can provide adequate adherence of the epithelium to the stroma. (This is assuming all other complicating factors of dry eye disease and posterior blepharitis are currently being treated and controlled as well.)

The idea behind ASP is that the punctures—no more than 250µm of penetration into the corneal surface—facilitate a slight inflammatory event that leads to minor scarring and essentially serves as a “spot weld” to better anchor the epithelium to the stroma.

The procedure is best performed using an anterior stromal puncture needle rather than a bent syringe. An ASP needle comes pre-packaged and pre-bent at the tip to prevent the point from going too deep into the stroma, penetrating no more than 0.1 mm. This takes the guesswork out of bending your own needle, which you could bend too much or too little.

Here's how ASP is performed:

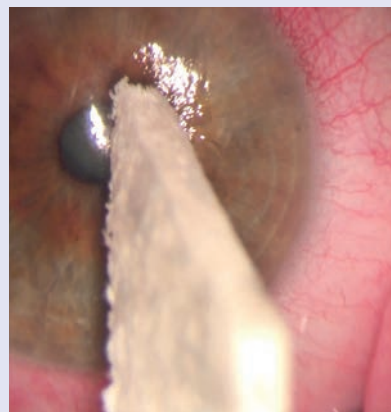
- Apply one drop topical anesthetic (proparacaine 0.5%).
- Apply one drop of topical fluoroquinolone each minute for three minutes.
- Test the surrounding area for poor adhesion with a Weck-Cel sponge to determine the

area of treatment. Areas affected by EBMD or prior trauma—in which the epithelium is loosely adherent to the underlying basement membrane and stroma—will feel loose and will more easily separate from healthy cornea with light pressure and force from the Weck-Cel.

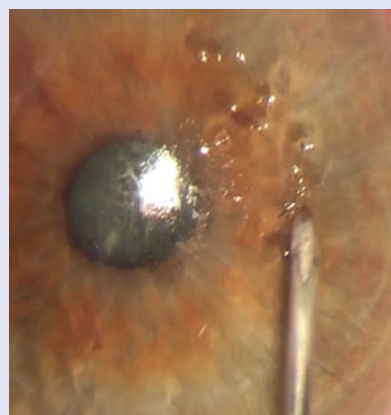
- Using the ASP needle, apply punctures 0.25mm to 0.5mm apart to the area of loose epithelium, as well as a 0.5mm ring into the area of adherent epithelium. The punctures should be deep enough to penetrate into the anterior stroma. Scarring in the visual axis has the potential to reduce best-corrected visual acuity, so stay clear of the central visual axis when performing anterior stromal puncture.

- Next, apply a bandage soft contact lens for comfort and to facilitate healing. Patients may experience mild to moderate pain in the first one to two days after the procedure, even with the bandage lens in place, due to the dozens of small punctures from the ASP procedure. Proper education usually helps alleviate the patient's immediate concerns, and most patients feel much better one or two days later.

ASP may not cure the underlying problem, so patients may still need to continue topical therapy to help control symptoms. Yet, it should significantly reduce the episodes of recurrent erosion and severe pain upon waking.

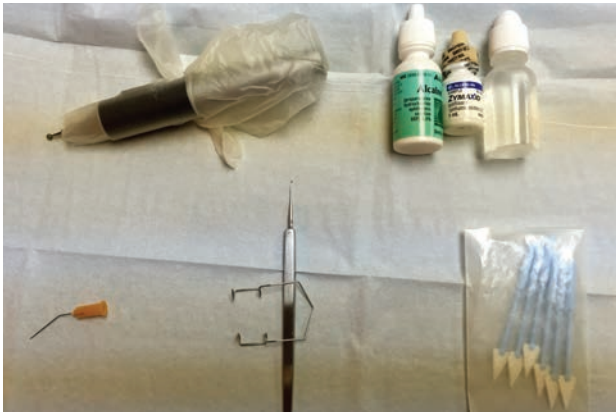

Use a Weck-Cel sponge to find and dislodge areas of loose epithelium.

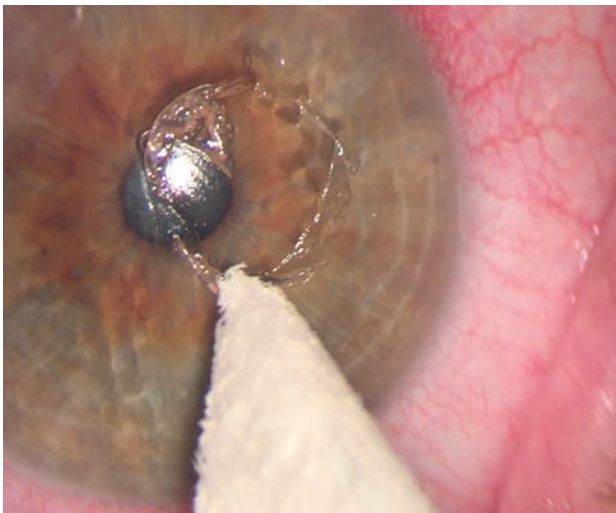


With the ASP needle, puncture both loose and adherent epithelium, penetrating the anterior stroma.

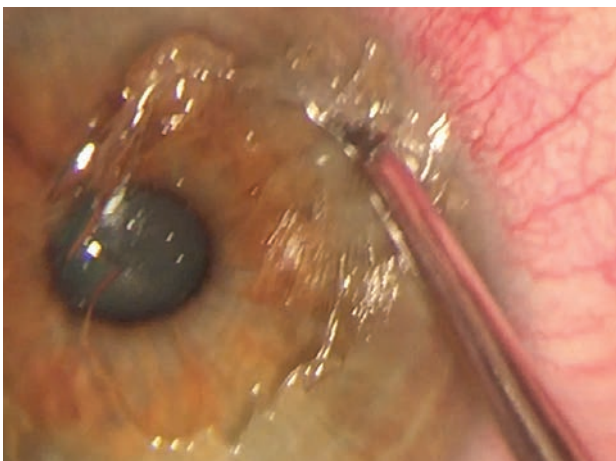
Slit Lamp Essentials



Prepare your instrument tray ahead of time. Treat this procedure as a sterile surgery.



First, apply mild pressure with a Weck-Cel sponge to remove areas of loose epithelium. Slide them off the corneal surface.



For areas that don't come loose as easily, use a golf club spud. Leave at least 1mm of epithelium adhered to the limbus.

decreased vision if the affected area is within the visual axis, infection, pain and discomfort during healing, and recurrence—all of which are complications of not treating. Benefits include reduction or elimination of recurrence of erosions, and possibly decreasing the burden of current topical/oral treatment.)

Explain that the first couple of nights after the procedure may be more uncomfortable than the episodes of erosion, and that the patient may need oral narcotics for a couple of days.

Visual ability will be significantly reduced for a period of a week or more depending on rate of healing area and size of treatment, and whether a bandage soft contact lens or an amniotic membrane graft (e.g., Prokera, Bio-Tissue) will be used. Tell patients they can expect their vision to return to pre-surgical levels within two to three weeks.

2. Prep the Patient

Having a surgical microscope and surgical chair makes the procedure much easier because the stability of the eye is much greater and sterility is easier to maintain during the procedure. However, it can certainly be performed at the slit lamp.

Stock your surgical tray for the procedure beforehand: Weck-Cels; golf club spud; lid speculum; ASP needle; and Alger brush with diamond burr tip.

Treat this as a sterile surgery—clean the entire ocular adnexa with a swab of Betadine 5% (povidone-iodine sterile ophthalmic prep solution, Alcon), and let the patient sit for three minutes. During this time, instill a topical fluoroquinolone and proparacaine—one drop of each every minute for three minutes.

Cover the non-sterile areas of the patient's forehead, nose and cheek with a sterile drape to allow you to rest your hands during the procedure. Insert a lid speculum to keep the eyelids and lashes away from the surgical field. Also, wear gloves and a mask to maintain sterility.

3. Debride the Epithelium

To test for the areas of debridement, use a Weck-Cel sponge to dislodge and remove the areas of loose epithelium. Mild pressure will cause the affected epithelium to slide easily and freely from the corneal surface (and usually in a much larger area than the area of erosion).


Also, you may need a spud to remove small islands of adherent tissue or to dissect the edge of the affected epithelium in order to leave 1mm of epithelium adhered to the limbus. Removal of the epithelium up to or beyond the limbus can slow the re-epithelialization

LET'S KEEP SOMETHING STRAIGHT ABOUT AREDS2

Only PreserVision® AREDS 2 Formula

contains the exact ingredient dosages recommended by the National Eye Institute[†] based on the evidence from the AREDS2 study.^{1,2*}

Get patient samples and education materials at **1-844-BL-VITES.**



PreserVision. Exactly.

BAUSCH + LOMB

SEE BETTER. LIVE BETTER.

[†]For patients with moderate to advanced age-related macular degeneration.

***This statement has not been evaluated by the Food and Drug Administration. This product is not intended to diagnose, treat, cure, or prevent any disease.**

References: 1. Yong JJ, Scott IU, and Greenberg PB. Ocular nutritional supplements. *Ophthalmology*. 2014;1-5. 2. Chew EY, Clemens TE, SanGiovanni JP, et al. Lutein and zeaxanthin and omega-3 fatty acids for age-related macular degeneration. *JAMA*. 2013;309(19):1-11.

PreserVision is a trademark of Bausch & Lomb Incorporated or its affiliates. AREDS2 is a registered trademark of the United States Department of Health and Human Services (HHS). ©2015 Bausch & Lomb Incorporated. PREV-56994 US/PV2/15/0006

Coding Connection

By John Rumpakis, OD, MBA, Clinical Coding Editor



Coding for RCE and ASP

A major procedure can be reported separately from the office visit, but a minor procedure cannot.

As surgical procedures become more common in optometry practices, medical coding and record compliance can become areas of concern and exposure. From a medical record standpoint, major and minor surgical procedures require a separate narrative, often referred to as a surgical report. This report describes several key items: the surgical procedure; preparation of the surgical field; instruments and approach used by the surgeon; and a statement of patient status at the end of the procedure.

Coding a surgical procedure first involves recognizing whether it is designated as minor (a global period of 0 or 10 days) or major (a global period of 90 days). Perhaps the most common mistake ODs make is to bill for an office visit on the same day as a minor surgical procedure. By definition, a minor surgical procedure already includes an office visit, so it should not be billed in conjunction with an office visit on the same date, unless it had nothing to do with the decision to perform the minor surgery.

In managing a patient with recurrent corneal erosion (RCE), both types of procedures are performed: major surgery (65600—multiple punctures of anterior cornea, 90 days), as well as minor surgery (65435—removal of corneal epithelium with or without chemocauterization, 0 days; and 65778—placement of amniotic membrane on the ocular surface; without sutures, 10 days). This distinction is important to know because of the medical coding convention that must be followed for each type of procedure.

The National Correct Coding Initiative (NCCI) Policy Manual for Medicare Services clearly defines this.¹ For a major surgical procedure, you can separately report the office visit performed on the same date of service as the procedure using modifier -57.¹ A minor procedure, though, cannot be reported separately from the office visit. The same holds true for a visit with a new patient—the fact that the patient is “new” to the provider doesn’t justify reporting an office visit on the same date of service as a minor procedure.

However, a significant and separately identifiable E&M service unrelated to the minor surgical procedure is separately reportable with modifier -25. The E&M service and minor surgical procedure do not require different diagnoses.

The problem arises when ODs improperly use these modifiers to get reimbursed for the office visit. The Office of Inspector General

has taken a particular interest in the improper and fraudulent use of modifier -25.

Also consider the NCCI rules when performing multiple procedures on the same day. All of these procedures are allowed on the same day without conflict, with the exception of 92071 (fitting of a contact lens for ocular surface disease) and performing debridement (65435) on the same day as placement of the amniotic membrane (65778).^{2,3} (While federal rules allow you to perform certain combinations of procedures together, check with your specific local carrier if its rules vary from the federal standards.)

The coding for these two RCE situations may look something like this based upon these procedures:

Clinical Situation	Codes Performed	Codes Allowed
Office visit	992XX-57	992XX-57
Anterior stromal puncture	65600-RT/LT	65600-RT/LT
Fitting of a bandage contact lens	92071	
Office visit	992XX-57	992XX-57
Anterior stromal puncture	65600-RT/LT	
Debridement of the cornea	65435-51-RT/LT	65600-51-RT/LT
Fitting of a bandage contact lens	92071-RT/LT	
Placement of amniotic membrane	65778-RT/LT	65778-RT/LT

Providing these surgical services at the slit lamp highlights just how far optometry has come in providing state-of-the-art care. But with increased privileges comes increased responsibility for understanding the rules and regulations for medical coding and medical record compliance of these surgical procedures. ■

Send questions and comments to ROcodingconnection@gmail.com.

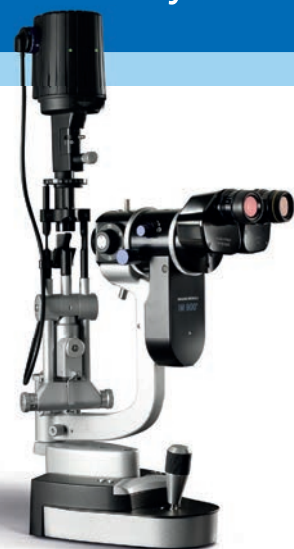1. Centers for Medicare & Medicaid Services. The National Correct Coding Initiative Policy Manual for Medicare Services. Jan 2015:1-17.
 2. CCIPlus Module. www.CodeSAFEPLUS.com.
 3. Centers for Medicare & Medicaid Services. The National Correct Coding Initiative Policy Manual for Medicare Services. Jan 2015:XI-12.



Imaging With Depth-of-field. Just Dandy.

What if none of your slit images or video had blurry edges? You would have a Haag-Streit, of course. Invest in one and submerge yourself into our extreme world of depth of field.

Visit haag-streit-usa.com to learn about our entire range of slit lamps and imaging systems.



800.787.5426
haag-streit-usa.com



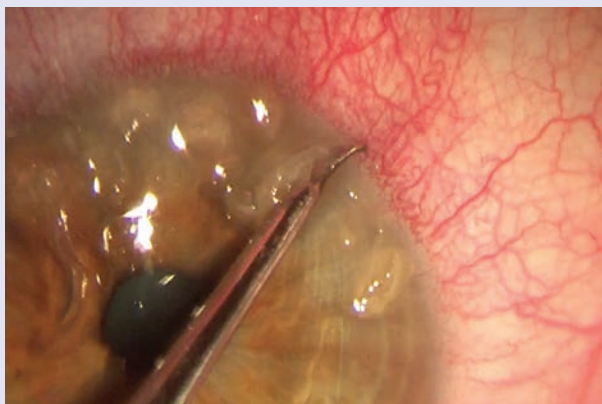 **HAAG-STREIT**
USA

© 2015 Haag-Streit USA. All Rights Reserved.

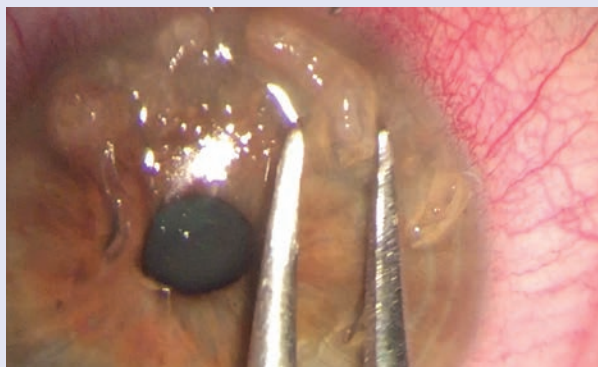
Two Other Indications for DBD with ASP: Preoperative Corneal Irregularity and Salzmann's Nodular Degeneration

Our referral center performs a large number of cataract surgeries and occasionally patients' EBMD and/or Salzmann's is significant enough that preoperative corneal measurements are too distorted to allow for proper IOL selection, especially in patients who elect toric or premium IOLs.

If you notice Salzmann's nodules, use the spud to lift the leading edge. While grabbing and lifting the leading edge of the nodule with small-toothed forceps, use the spud to dissect the nodule from the



Using the golf club spud, roll and lift the leading edge of the Salzmann's nodule. Try to leave the limbal edge intact.



Here, forceps were needed to isolate the nodule, allowing use of the spud to dissect the nodule from corneal stroma.

corneal stroma back to the limbus. The nodule should "peel" off with the consistency of removing Velcro.

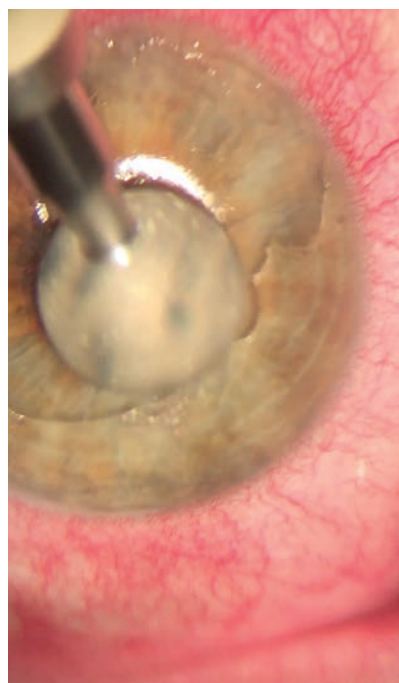
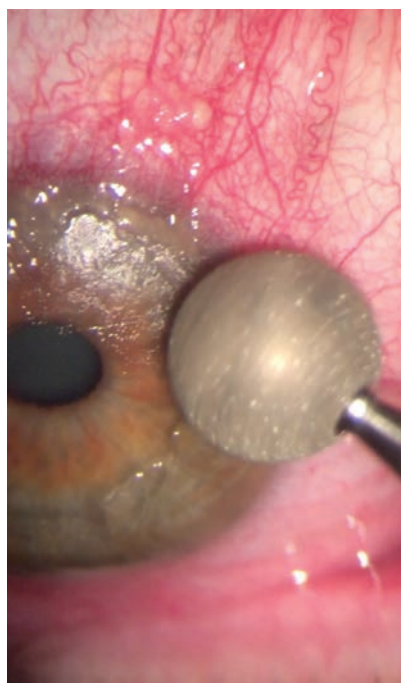
In cases where concurrent EBMD is present, consider performing DBD with or without ASP to allow a better adhesion of the epithelium after debridement. Once the eye is healed, better preoperative keratometry and regular topography are achievable. In some cases, the procedure actually improves the patient's vision to a point that cataract surgery isn't necessary.

process. (See "Two Other Indications for DBD with ASP: Preoperative Corneal Irregularity and Salzmann's Nodular Degeneration," above.)

4. DBD and Polishing

Next, use an Alger brush with a diamond burr tip to gently smooth the exposed corneal surface and remove the uneven basement membrane. Be sure to hold the handle of the Alger brush so that the burr always spins toward the center of the cornea. This also allows you to smooth the edges of the remaining limbal epithelium. Only mild pressure, using smooth broad strokes, needs to be applied.

Remove any residual epithelial cells with a moistened Weck-Cel sponge. Instill a drop of topical antibiotic and a drop of NSAID on the exposed surface.



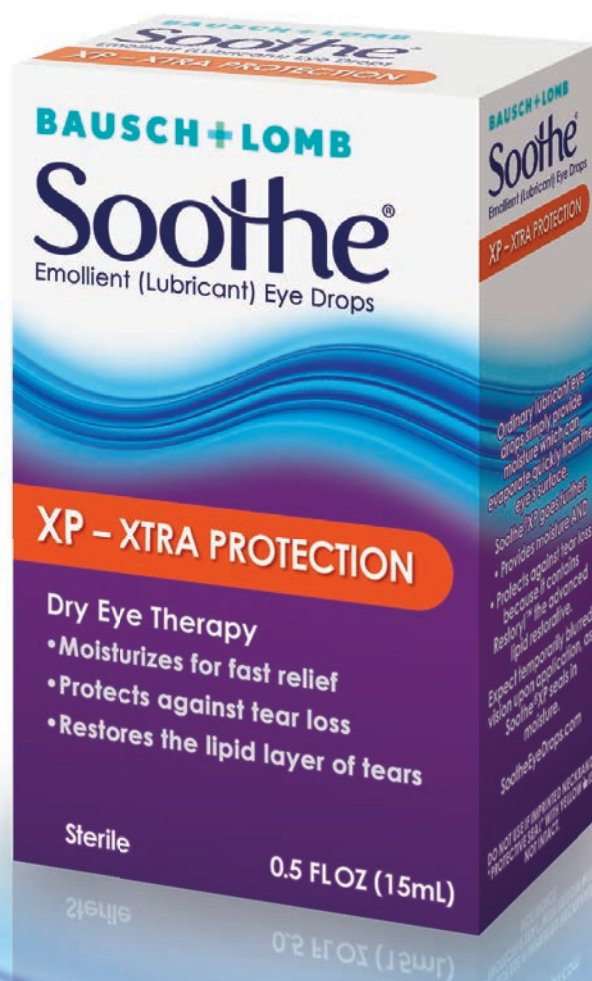Use the diamond burr (with rotation toward the center of the cornea) to smooth the exposed cornea. Take care to preserve the limbal cells. Roll the edge of the epithelium toward the pupil, but don't overdo the pressure or you risk scarring in the visual axis.

RELIEF AT THE MAIN SOURCE of dry eye symptoms

Target Lipid Layer Deficiency:

Soothe[®] XP

With Restoryl[®] Mineral Oils



**Recommend Soothe XP as your first choice for dry eye patients.
To request samples, please call 1-800-778-0980.**

Now available at major retailers nationwide.

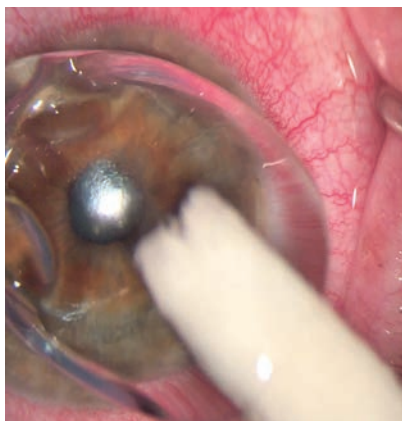
Distributed by Bausch + Lomb, a Division of Valeant Pharmaceuticals North America LLC, Bridgewater, N.J. © 2015 Bausch & Lomb Incorporated. Soothe and Restoryl are trademarks of Bausch & Lomb Incorporated or its affiliates. All other brand/product names are trademarks of their respective owners. PNS07412 US/SXP/14/0006

BAUSCH + LOMB
See better. Live better.

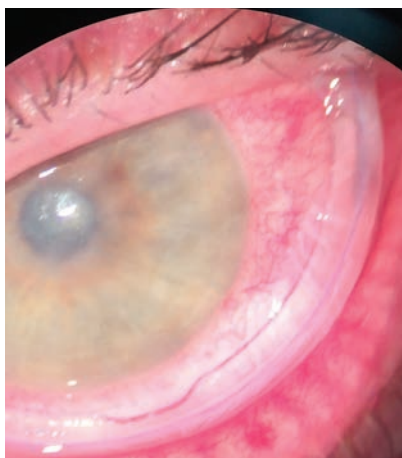
5. Add ASP

Although not conventional, performing ASP at this stage can maximize adherence of the epithelium to the stroma in severe cases of RCE, in our experience.

So, once you've completely removed the loose epithelium and any nodules, use the ASP needle to treat the entire exposed surface. Make a grid of punctures about 1mm apart, but stay clear of the central visual axis. Apply enough pressure to deform the corneal surface in order to penetrate the anterior stroma.



To enhance patient comfort and promote re-epithelialization, apply a bandage contact lens soaked in fluoroquinolone.



If possible, use an amniotic membrane ring, which can be a better option than a bandage contact lens.

Keep in mind that because epithelium is now removed, the punctures will be slightly deeper than ASP performed with the epithelium intact. Use caution in patients who may have severe corneal thinning due to keratoconus or post-op LASIK. Preoperative pachymetry may be needed in these cases, as the ASP needle could theoretically penetrate a cornea that is 250µm or thinner.

6. Place the BSCL or AMG

At this point, place either a bandage soft contact lens or amniotic membrane graft on the surface to allow for re-epithelialization and comfort during the healing process.

We prefer to use a Prokera in our clinic if insurance allows—this provides anti-inflammatory coverage during this healing process without using a topical steroid, which can slow re-epithelialization. We've also noted that the Prokera seems to inhibit corneal postoperative haze formation better than use of a BSCL.

However, in instances when an amniotic membrane cannot be used due to cost or insurance coverage, a bandage contact lens is appropriate.

7. Post-op Regimen

Prescribe a topical fluoroquinolone TID or QID to prevent infection during healing, and an NSAID QD or BID to aid patient comfort until the defect is healed. If the patient received a bandage soft contact lens, add a topical steroid TID to QID to the regimen as well. Also, Norco (hydrocodone/acetaminophen 5mg/325mg or 10mg/325mg, Watso Pharmaceuticals) will help the patient through the first couple of nights of discomfort.

Schedule the patient to return on day one to check for amniotic ring or BSCL position and healing, and

then again every one to two days until complete re-epithelialization occurs. Use of sodium fluorescein stain will diffuse through the amniotic membrane graft and allow you to monitor the healing of the defect.

Once the epithelium has healed completely, remove the Prokera ring or BSCL and discontinue the antibiotics and NSAID. If the central visual axis was treated with diamond burr polishing, then continue the steroid (or add one if an amniotic membrane was used) for an additional two weeks to help reduce formation of central corneal haze. (Corneal haze is less significant when using an amniotic membrane, in our experience.)

With a small investment in time and surgical equipment, you can employ these techniques to expand the corneal treatment options for patients with RCE, EBMD and Salzmann's degeneration. Your patient who was afraid to open her eyes in the morning will truly have an "eye opening" experience from all that you can do for them, and you'll gain a patient for life. ■

Dr. Ellen is the clinical director of BVA Advanced Eye Care in Tulsa, Okla., where he specializes in the diagnosis and treatment of ocular disease.

Dr. Lighthizer is the assistant dean for clinical care services, director of continuing education, and chief of both the specialty care clinic and the electrodiagnostics clinic at the Oklahoma College of Optometry.

1. Bronner A. Peeling back the layers of RCE. *Rev Optom.* 2013 Jan;150(1):42-9.
2. Wong VW, Chi SC, Lam DS. Diamond burr polishing for recurrent corneal erosions: results from a prospective randomized controlled trial. *Cornea.* 2009 Feb;28(2):152-6
3. Sridhar MS, Rapuano CJ, Cosar CB, et al. Phototherapeutic keratectomy versus diamond burr polishing of Bowman's membrane in the treatment of recurrent corneal erosions associated with anterior basement membrane dystrophy. *Ophthalmology.* 2002 Apr;109(4):674-9.

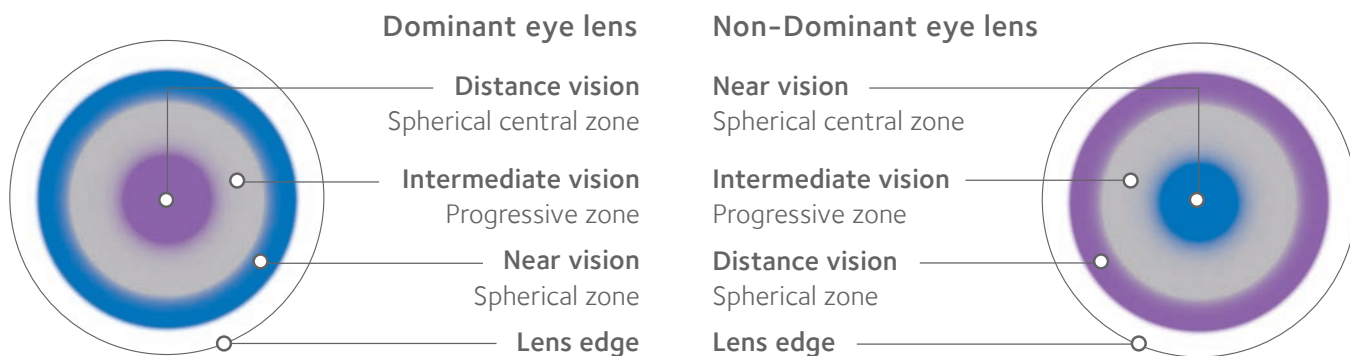
An easy fit

for you and your presbyopic patients.

CooperVision Biofinity® multifocal lenses combine a high-performing 3rd generation material with a streamlined fitting process. Now even your most challenging presbyopic patients can enjoy the freedom of **all-distance clarity and lasting comfort.**



Balanced Progressive™ Technology enhances vision near, far and intermediate. It also allows for an individualized fitting for each wearer and each eye.



Biofinity & Biofinity XR Biofinity toric **Biofinity multifocal**

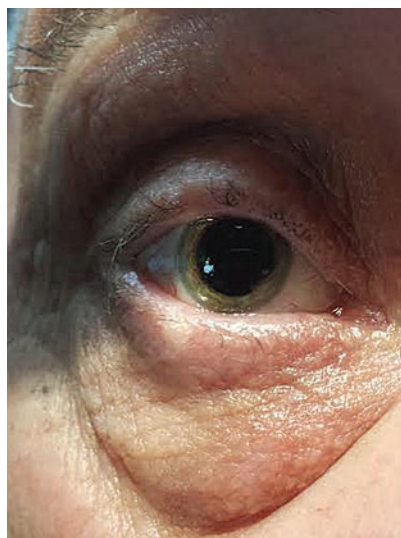
Download your Biofinity multifocal 3-step fitting guide at coopervision.com/fitting-guide

SEEING RED: How Ocular Rosacea Impacts the Cornea

Don't forget that this condition can affect more than just the eyelids. Here's what you need to know. **By Sara Weidmayer, OD**

The ruddy cheeks and prominent facial vessels that characterize rosacea are as obvious as they are distinctive. From W.C. Fields to Prince William to Bill Clinton, these patients are easy to identify. Less obvious, though, are the ocular signs—especially those that signal corneal involvement.

Rosacea is a relatively common disorder, affecting up to 10% of the adult population; it's most frequently seen in those with fair skin and tends to manifest around facial folds.¹⁻⁴ Middle-aged adults are most commonly affected, though children can also have this disorder.^{3,5} As many as 58% to 72% of rosacea patients have ocular involvement, and 45% to 85% have ocular complaints.^{1,3,4,6} The most frequently reported ocular signs are blepharitis and meibomian gland dysfunction, followed by conjunctival hyperemia—particularly interpalpebrally—eyelid margin telangiectasias, punctate epithelial



Ocular rosacea patient with typical eyelid findings, but also note the irregular corneal light reflex due to marked inferior corneal dryness.

keratopathy, corneal vascularization and infiltrates with corneal scarring and opacity.^{1,5} Ocular manifestations of rosacea may precede dermatologic signs in 20% of patients.^{1,3,6,7}

While our thoughts of ocular rosacea often end with the eyelids, corneal disease is often concomitant. It's rare that ocular rosacea leads to marked or blinding corneal damage, but corneal involvement has been noted in up to 33% of patients with rosacea, and severe sequelae are possible.^{1,5} Be sure to look critically at the cornea and conjunctiva in these patients.

This article provides an overview of rosacea and how it affects the ocular surface.

An Uncertain Pathogenesis

Researchers have proposed many theories regarding the pathogenesis of rosacea, though none have been confirmed. The prevailing wisdom points to a mix of vascular and immunologic dysfunction.^{3,5} An increase in bacterial eyelid flora appears to have a strong contributory effect on ocular manifestations.

Bacteria produce several lipolytic exoenzymes—including cholesteryl esterase, triglyceride lipase and

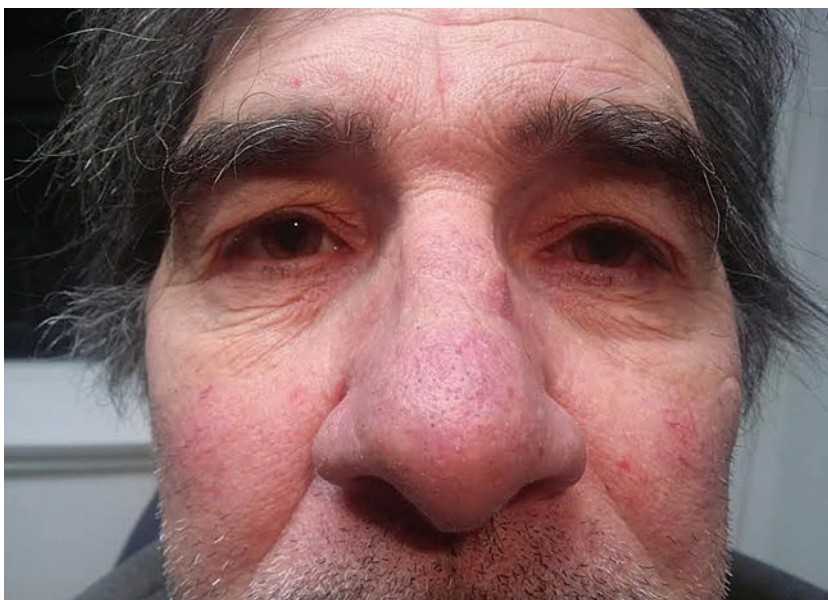fatty wax esterase—that act on the lipid-based meibum by hydrolyzing its sterol esters and wax, thus increasing glycerides and free fatty acids.^{5,8} The latter are irritating and toxic to the ocular surface and adnexa.^{9,10} This process also alters the meibum's solubility, causing it to thicken.⁹ Inadequate and solidified meibum destabilizes the lipid layer of the tear film, allowing the aqueous to evaporate more quickly, increasing tear osmolarity and stimulating the inflammatory cascade.^{4,5} Chronic inflammation causes atrophy of the meibomian glands themselves, decreasing meibum production.^{5,8,9} Symptoms associated with this process include burning or stinging, conjunctival and eyelid margin redness, foreign body sensation and often watery eyes from reflexive aqueous production.

Ocular rosacea patients also characteristically have an increased eyelid margin density of *Demodex*.¹¹ An immune response to *Demodex* infestation on eyelash follicles and within meibomian glands also appears to contribute to chronic eyelid and meibomian gland inflammation and dysfunction.^{5,9} *Demodex* mites carry bacteria that produce proteins which stimulate an increased expression of matrix metalloproteinase (MMP) activity.⁹

Ocular rosacea is readily associated with blepharitis, eyelid margin telangiectasias, meibomian gland dysfunction and symptoms associated with dryness. Along with eyelid disease, researchers have also reported associations with conjunctivitis, chalazia, episcleritis, iritis, scleritis and scleral perforation.¹

Corneal Complications

Up to 40% of patients with ocular rosacea may also display punctate epithelial erosions.⁵ This alone can cause a notable decline in vision and



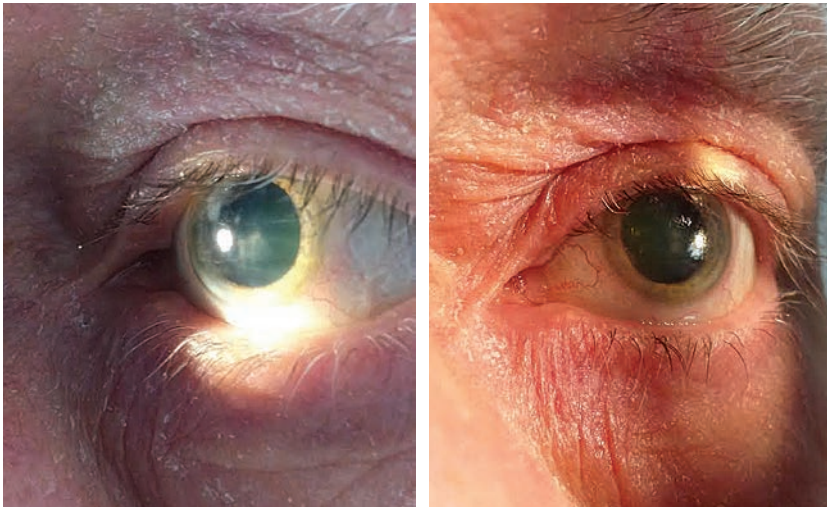
Typical facial presentation with cutaneous rosacea; note rhinophyma, facial telangiectasias and eyelid findings.

patient comfort. Peripheral stromal infiltrates are commonly seen with ocular rosacea; recurrent corneal erosions, ulcers, edema, stromal keratitis, opacification or scarring, neovascularization, pannus or phlyctenules may also occur.^{2,3,5,6} Limbal stem cell deficiency due to chronic inflammation may occur, resulting in inadequate corneal epithelial regeneration. Inflammation causes corneal epithelial cells to produce fibroblast growth factors and pro-angiogenic factors such as vascular endothelial growth factor (VEGF).¹² In response, conjunctival endothelial cells produce more MMPs, and the limbal epithelial cells, which are capable of producing neovascularization and opacification, migrate beyond their normal limbal location onto the cornea.^{11,13} Additional immunologic cells are recruited, and this all contributes to triggering angiogenesis and corneal neovascularization.¹²

Ocular rosacea patients can have significantly increased tear concentrations of interleukin-1 α (IL-1 α),

a pro-inflammatory cytokine, and matrix metalloproteinase 9 (MMP-9), a collagen matrix-degrading enzyme secreted by devitalized epithelial cells.^{5,14-17} Tear volume drops as IL-1 α increases, and dry eye symptoms can worsen in the presence of elevated MMP-9 levels.¹⁴⁻¹⁶ InflammDry (RPS), an in-office test that samples tears for elevated levels of MMP-9, could be a good confirmatory tool to help with early diagnosis and treatment. MMP-9 also overpowers inhibitory metalloproteinase proteins found naturally in the eye, leading to MMP-9's degrading activity on the cornea, its epithelial basement membrane and stromal extracellular matrix, resulting in stromal thinning.^{14,15}

In ocular rosacea, the inferior and intrapalpebral regions of the cornea are more susceptible to damage, particularly the 3- and 9- o'clock positions, due to the position of the tear meniscus inferiorly at rest and during a blink.⁵ Progressive corneal thinning and loss of stromal tissue can precipitate the formation of



Another ocular rosacea patient with severe corneal involvement. Note the irregular corneal surface and corneal scarring.

descemetocoele; this herniation of Descemet's membrane increases the risk of perforation.^{2,5} Rare corneal presentations such as dendritic keratopathy or features similar to keratoconus have been reported due to chronic ocular rosacea.^{2,14}

Managing Ocular Rosacea

Your role in helping patients live with this chronic disease is aimed at reducing pro-inflammatory contributors to the disease, controlling symptoms and reducing exacerbations.

Management of ocular surface symptoms will include topical therapy, beginning with liberal lubrication with artificial tears. Inadequate lubrication can lead to abnormal corneal epithelial sloughing and corneal damage.

Furthermore, the avascular cornea needs many components of the tears for normal wound healing and reduced tear quality and quantity adds further insult.¹⁵ Lipid-based artificial tears make sense given the meibomian gland involvement.

More severe manifestations can be treated with autologous serum drops, which are rich in vitamin A, epidermal growth factor and fibronectin, which promote healthy development, proliferation, migration and differentiation of conjunctival and corneal epithelium; the serum contains bacteriostatic factors including lysozymes, complement and IgG.^{18,19} They are derived by centrifuging the patient's whole blood (making them naturally non-allergenic) after it clots, reaping the plasma serum, filtering it and compounding it with preservative-free saline into the desired concentration; it's packaged into single-use vials to be used liberally.^{18,19}

Routine eyelid hygiene, massage and warm compresses are a mainstay. Devices for the expression of meibum are also available, which warm and massage the meibomian glands, improving meibum fluidity and flow onto the tear film.⁵ Thorough reviews of treatment for blepharitis, meibomian gland dysfunction and *Demodex* infestations are readily available elsewhere in the literature. Note that consistency with these lid considerations and liberal lubrication are founda-

The Many Faces of Rosacea

Rosacea is a chronic inflammatory dermatologic condition that affects the central face: most commonly the cheeks, forehead, chin and nose.¹⁻³ Other than ocular rosacea, three subtypes and one variant exist^{2,3}:

Erythematotelangiectatic rosacea involves persistent flushing of the mid-face, which can occur with or without visible telangiectatic vessels. The central facial skin may be scaly or rough, mildly edematous and can often burn or sting.² It is four times more common than the next most prevalent subtype, papulopustular.³ Sun exposure appears to significantly correlate with both its precipitation and severity.⁴

Papulopustular presents with papules or pustules or both overlying erythematous skin on the central face or around the nose, eyes or mouth. The papules and pustules may wax and wane, resembling acne vulgaris. It often occurs concomitantly with the erythematotelangiectatic presentation.^{2,3}

Phymatous acne rosacea involves enlargement and thicken-

ing of the skin; this is most frequently seen as rhinophyma, but can also affect the cheeks, chin, forehead and even the ears. This subtype is generally uncommon, but is usually seen along with the other subtypes; it is more predominant in males.^{2,3}

The variant **granulomatous** rosacea can be diagnosed even in the absence of other rosacea signs. It presents with non-inflammatory, hard cutaneous papules or nodules which can vary in color from yellow to brown to red; interestingly, they tend to appear over relatively normal, non-inflamed skin, but can lead to scarring.^{2,3}

1. Kharod-Dholakia B, Loft ES, Song CD, et al. Ocular Rosacea. eMedicine. 18 Aug 2014. Available at <http://emedicine.medscape.com/article/1197341-overview>.
2. Wilin J, Dahl M, Detmar M, et al. Standard classification of rosacea: Report of the National Rosacea Society Expert Committee on the Classification and Staging of Rosacea. *J Am Acad Dermatol*. 2002;46:584-7.
3. Tan J, Berg M. Rosacea: Current state of epidemiology. *J Am Acad Dermatol*. 2013;69(6):S27-S35.
4. Bae YI, Yun SJ, Lee JB, et al. Clinical evaluation of 168 Korean patients with rosacea: the sun exposure coorelates with the erythematotelangiectatic subtype. *Ann Dermatol*. 2009;21(3):243-9.

tional and cannot be overstated for preventing and managing both generalized rosacea and corneal manifestations of the disease.

Oral tetracyclines (doxycycline, tetracycline, minocycline) are the most effective treatment for dermatologic rosacea, and are also clinically useful in ocular rosacea.⁶ Interestingly, the antibiotic properties of the medication aren't the main desired effect, but rather their anti-inflammatory actions. Tetracyclines, even at sub-antimicrobial levels, inhibit neutrophil chemotactic factors from bacterial flora, suppress pro-inflammatory cytokines and inhibit bacterial protein synthesis, therefore decreasing bacterial lipase and esterase.^{5-8,10,20} They also inhibit keratinization, and these effects are useful for the meibomian gland dysfunction associated with ocular rosacea.⁹ Tetracyclines also inhibit collagenase, an inflammatory product that degrades collagen, and suppress MMP-9 production.^{5,15} Thus, tetracyclines protect the cornea from the inflammation seen in ocular rosacea.⁶

Lastly, antiangiogenic effects, which can prevent corneal neovascularization, are achieved due to the inhibition of smooth-muscle cell migration and of vascular endothelial growth factor.⁷

In patients where tetracyclines are contraindicated (children, pregnant women, patients with hepatic dysfunction, or those who are allergic or intolerant), macrolides may be used; however, little clinical data supports their efficacy and tetracyclines are preferred.⁵

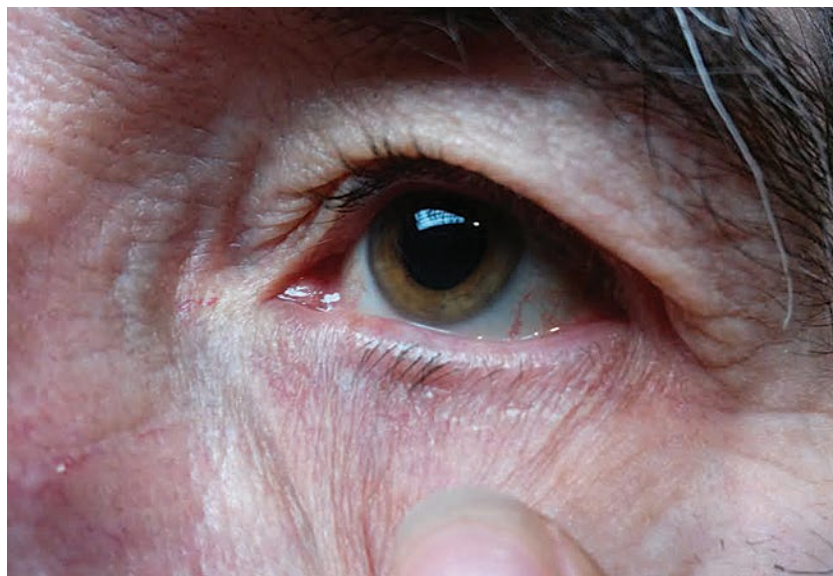Oral antibiotics can be discontinued when symptomatic control is achieved or can be maintained chronically at low doses, with pulses as needed for exacerbations. Sub-antimicrobial dosages are typically for chronic use, and

evidence of effective improvement in clinical signs and symptoms of the disease typically require around two months of treatment.⁵ Doxycycline is generally preferred over tetracycline due to its longer half-life, and therefore less frequent dosing.⁶ Doxycycline for ocular rosacea is typically dosed at 50mg to 100mg daily, though off-label and lower dosages—such as Oracea (Galderma Laboratories), a 40mg doxycycline tablet, 10mg of which is delayed-release, and Periostat (CollaGenex Pharmaceuticals), a 20mg formulation dosed twice daily—have been shown effective and are gaining popularity.^{3,6,7,21}

Off-label use of topical ophthalmic antibiotics (such as erythromycin ointment) and antibiotic-steroid combinations are helpful in reducing eyelid bacterial proliferation, eyelid margin disease and meibomian gland dysfunction associated with ocular rosacea. Topical ophthalmic corticosteroids can be used in pulses for exacerbations. Chronic use is generally discouraged due to concern over steroid-induced cor-

neal thinning or melting in an eye that is already at higher risk due to ocular rosacea-associated thinning and inflammation. Corticosteroids reduce the production of MMP-9 and other inflammatory products, so steroid use is a balance that needs to be monitored clinically; lower potency steroids are generally preferred when possible.^{6,15}

Cyclosporine ophthalmic emulsion 0.05% (Restasis, Allergan) may be helpful as well. Similar to corticosteroids, cyclosporine reduces the production of inflammatory markers, including MMP-9.^{15,17} A clinical trial of topical cyclosporine in patients with ocular rosacea found that three months of use produced both symptomatic improvement and improvement in clinical signs, including tear production and degree of corneal staining.^{5,17} Other trials found a reduction in inflammatory markers after six months of cyclosporine use in patients with keratitis sicca and dry eye.¹⁵ This may be a very viable option for many ocular rosacea patients.



Typical eyelid findings with ocular rosacea; note eyelid margin keratinization and telangiectasias.

Don't Forget Contact Lenses in Ocular Rosacea

By Amy Lagina, OD

Ocular rosacea has long been deemed a contraindication to contact lens wear. But we can often return these patients to safe contact lens wear by: (1) confirming the diagnosis, (2) working to treat the underlying disease, (3) addressing the eyelid and ocular surface factors and (4) carefully educating the patient on the do's and don'ts.

Mainstays of CL use in these patients are to protect the cornea and promote healing, or to alleviate symptoms. Specific goals can include vision correction, pain management, exposure and lid protection, and assistance with corneal reepithelialization.

Contact lenses used for therapeutic purposes can be either bandage soft contact lenses or scleral gas permeable lenses. Continuous use of the approved lenses may vary from one to four weeks, depending on the ocular surface condition.

Scleral lenses are common for the management of ocular surface diseases because they provide constant surface protection and enable more continuous lubrication. Scleral lenses are filled with a sterile saline prior to insertion and are fit to vault over the entire cornea, eliminating any interaction between the cornea and the lens.¹ Lens materials with high oxygen transmissibility are recommended to prevent corneal hypoxia since scleral lenses are substantially thicker than standard gas permeable lenses.

If the ocular surface presentation is mild and is properly managed, patients can continue to wear regular lenses. Important characteristics to consider when prescribing are: water content, oxygen permeability, ionicity, lens modulus, replacement schedule and maintenance.

Ideal soft lenses have low water content, high oxygen permeability and a non-ionic surface. Soft HEMA (hydroxyethyl methacrylate) lenses will have decreased oxygen permeability as the lens dehydrates. Conversely, silicone hydrogel lenses will have increased oxygen permeability with lens dehydration. Silicone hydrogels also have high oxygen permeability, which significantly reduces the corneal hypoxia that can lead to contact lens discomfort.² The ionicity is important to consider, as non-ionic lenses will have less protein accumulation and deposition. Lens modulus relates to the stiffness of the lens, with higher modulus lenses being stiffer, which generally creates more lens awareness. Most silicone hydrogel lenses have lower water content and a higher modulus, except Biofinity (comfilcon A 48%, CooperVision).

Daily, two-week and monthly replacement lenses are becoming increasingly available. Daily lenses are ideal because they can be worn on an as-needed basis and discarded after each use. Finally, vigilant lens hygiene is important to prevent additional exacerbations with ocular rosacea. Reminding patients to rub their lenses nightly, use fresh solution daily, or switching to a hydrogen peroxide solution can greatly improve lens disinfection, compliance and overall success.

Dr. Lagina practices at both the VA Ann Arbor Healthcare System and the Kellogg Eye Center in Ann Arbor, MI. She is a clinical instructor with the University of Michigan Department of Ophthalmology and Visual Sciences.

1. Schormack MM, Pyle J, Patel SV. Scleral lenses in the management of ocular surface disease. *Ophthalmology*. 2014;121:1398-1405.

2. Stapleton F, Papas E, et al. Silicone hydrogel contact lenses and the ocular surface. *Ocul Surf*. 2006;4(1):24-43.

Other emerging treatments for severe corneal involvement include topical hormonal therapy such as dehydroepiandrosterone (DHEA) and medroxyprogesterone acetate (MPA). DHEA, an androgen, supports meibomian gland function.¹⁸ MPA, a synthetic progestin, inhibits MMP expression and interleukin-induced corneal collagen degradation by corneal fibroblasts.²² Their use is off-label, and there is limited evidence to date as to their efficacy.

Corneal neovascularization can be addressed in several different ways. Oral tetracyclines, as mentioned above, can play a preventative role, and topical corticosteroids or non-steroidal anti-inflammatory drugs can reduce the immunologic factors that trigger corneal neovascularization.¹² Anti-VEGF agents bevacizumab and ranibizumab,

which have made a profound difference in eye care, have been shown to reduce corneal neovascularization when applied via subconjunctival injection or with topical administration; however, long-term data is not available, route of delivery and dosing have not been standardized, and this is an off-label use of these drugs.^{12,23,24} Neovascularization could also be targeted with Nd:YAG or argon laser ablation, photodynamic therapy (PDT) or fine needle thermal cautery.¹²

Severe corneal involvement in ocular rosacea may require surgical intervention. Corneal perforations require urgent ophthalmologic treatment, ranging from cyanoacrylate tissue glue to partial- or full-thickness keratoplasty.⁶ Severe neovascularization could also be a cause for corneal transplantation

or the use of a keratoprosthesis.¹² Because of chronic inflammation with ocular rosacea, post-keratoplasty patients may have an increased risk of graft neovascularization.⁵ The use of therapeutic amniotic membranes, which inherently have anti-inflammatory properties and promote healing and corneal epithelialization, may also be helpful in severe cases of ocular rosacea with corneal involvement.⁶

While the eyelids are more often involved in ocular rosacea, don't forget the cornea! It's involvement is potentially sight-threatening, so appropriate management is key. ■

Dr. Weidmayer practices at the VA Ann Arbor Healthcare System in Ann Arbor, MI. She is also a clinical instructor for the University of Michigan Department of Ophthalmology and Visual Sciences.

- Ghanem VC, Mehra N, Wong S, Mannis M. The prevalence of ocular signs in acne rosacea. *Cornea*. 2003;22(3):230-3.
- Lee WB, Darlington JK, Mannis MJ, Schwab IR. Dendritic keratopathy in ocular rosacea. *Cornea*. 2005;24(5):632-3.
- Donaldson KE, Karp CL, Dunbar MT. Evaluation and treatment of children with ocular rosacea. *Cornea*. 2007;26(1):42-6.
- Onaran Z, Karabulut AA, Usta G, Örnek K. Central corneal thickness in patients with mild to moderate rosacea. *Can J Ophthalmol*. 2012;47(6):504-8.
- Bron A. Ocular rosacea. Up To Date. 11 Dec 2013. Available at <http://uptodate.com/contents/ocular-rosacea>.
- Kharod-Dholakia B, Loft ES, Song CD, et al. Ocular Rosacea. *eMedicine*. 18 Aug 2014. Available at <http://emedicine.medscape.com/article/1197341-overview>.
- Sobolewska B, Doycheva D, Deuter C, et al. Treatment of ocular rosacea with once-daily low-dose doxycycline. *Cornea*. 2014;33(3):257-60.
- Ta CN, Shine WE, McCulley JP, et al. Effects of minocycline on the ocular flora of patients with acne rosacea or seborrheic blepharitis. *Cornea*. 2003;22(6):545-8.
- Mastrota K. Ocular surface disease. *Optometric Management*. 1 May 2009. Available at www.optometricmanagement.com/printarticle.aspx?articleID=102974.
- Dougherty JM, McCulley JP. Bacterial Lipases and Chronic Blepharitis. *Invest Ophthalmol Vis Sci*. 1986;27(4):486-91.
- O'Reilly N, Gallagher C, Katikireddy KR, et al. Demodex-associated bacillus proteins induce an aberrant wound healing response in a corneal epithelial cell line: possible implications for corneal ulcer formation in ocular rosacea. *Invest Ophthalmol Vis Sci*. 2012;53(6):3250-9.
- Chiang HH, Hemmati HD. Treatment of Corneal Neovascularization. *Eye Net Clinical Pearls*. 2013;35-6.
- Kim BY, Rias KM, Bakhtiari P, et al. Medically reversible limbal stem cell disease. *Ophthalmol*. 2014;121(10):2053-8.
- Dursun D, Piniella AM, Pflugfelder SC. Pseudokeratococcus caused by rosacea. *Cornea*. 2001;29(6):668-9.
- Kaufman HE. The practical detection of MMP-9 diagnoses ocular surface disease and may help prevent its complications. *Cornea*. 2013;32(2):211-6.
- Kaufman HE. MMP-9 and its role in dry eyes. *Advanced Ocular Care*. 2011;40-2.
- Schechter BA, Katz RS, Lriedman LS. Efficacy of topical cyclosporine for the treatment of ocular rosacea. *Adv Ther*. 2009;26(6):651-9.
- Reed K. Dry eye treatment: the unusual suspects. *Review of Cornea and Contact Lenses*. March 2013. Available at www.reviewofcontactlenses.com/content/dry_eye/c/39490/.
- Mangan R, Lehman S. How (and why) to make autologous serum. *Review of Optometry*. March 2012. Available at www.reviewofoptometry.com/content/dry_eye/c/33139/.
- Stone DU, Chodosh J. Oral tetracyclines for ocular rosacea: an evidence-based review of the literature. *Cornea*. 2004;23(1):106-9.
- Shovlin JP. Which antibiotic for rosacea? *Review of Optometry*. March 2007. Available at www.reviewofoptometry.com/content/d/cornea/c/15521/.
- Zhou H, Kimura K, Orita T, et al. Inhibition by medroxyprogesterone acetate of interleukin-1-induced collagen degradation by corneal fibroblasts. *Invest Ophthalmol & Vis Sci*. 2012;53(7):4213-9.
- Chang J-H, Garg NK, Lunde E, et al. Corneal neovascularization: an anti-VEGF therapy review. *Surv Ophthalmol*. 2012;57(5): 415-29.
- Stephenson M. Anti-VEGF for CNV: questions remain. *Review of Ophthalmology*. Sept. 2011. Available at www.reviewofophthalmology.com/content/i/1628/c/29956/.

Rely on something that **STAYS PUT**



Parosol®

92%*
RETENTION

We've taken the worry out of plug retention, so you can concentrate on patient retention. The Parosol® Punctal Occluder trumps the competition with an unprecedented 92% retention rate. Use the Parosol® Punctal Occluder, designed for easy insertion and guaranteed to stay put.

TO ORDER: 866-906-8080
customersupport@beaver-visitec.com
odysseymed.com or beaver-visitec.com

bvi Beaver Visitec
Keeping Your Vision in Sight

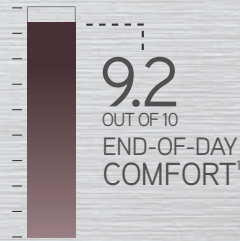
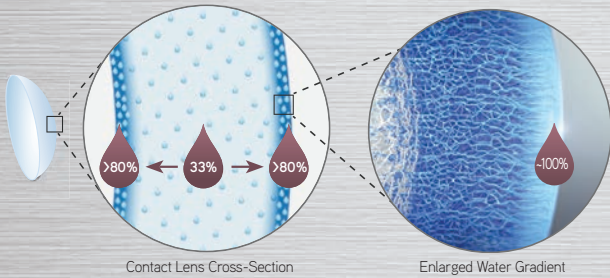
* "Plugs Reduce Dry Eye Symptoms, Improve Vision", Craig McCabe, M.D., *Review of Ophthalmology*, 2009. BVI, BVI Logo and all other trademarks (unless noted otherwise) are property of a Beaver-Visitec International ("BVI") company © 2015 BVI

PREFERRED
13 TO 1

THIS IS WHY more patients prefer our lenses.

DAILIES TOTAL1® Water Gradient Contact Lenses feature a unique water gradient for lasting lubricity and end-of-day comfort.¹ No wonder patients preferred DAILIES TOTAL1® Contact Lenses 13 to 1 over their habitual lenses.^{2*}

The First and Only Water Gradient Contact Lens



UNIQUE WATER GRADIENT

Features different surface and core water content

LASTING LUBRICITY

Ultrasoft surface gel approaches 100% water at the outermost surface^{3**}

ALL DAY COMFORT

Outstanding comfort from beginning to end of day¹

Let your patients experience the DAILIES TOTAL1® contact lens difference today.

PERFORMANCE DRIVEN BY SCIENCE™



*Percentage of wearers agreeing with the statement "I prefer these lenses to my previous contact lenses" among those with a preference.

**Based on *in vitro* measurement of unworn lenses.

1. In a randomized, subject-masked clinical study, n=40. Alcon data on file, 2011.

2. Based on an ongoing survey in Europe of 24 ECPs fitting 280 customers in DAILIES TOTAL1® contact lenses. Alcon data on file, 2012.

3. Angelini TE, Nixon RM, Dunn AC, et al. Viscoelasticity and mesh-size at the surface of hydrogels characterized with microrheology. ARVO 2013; E-abstract 1614872.

See product instructions for complete wear, care and safety information. © 2013 Novartis 7/13 DAL13315JAD

Alcon

a Novartis company

2 CE
Credits
(COPE approval pending)

Corneal Disease Report



Corneal Harbingers of Systemic Disease

A routine slit lamp exam may reveal telltale findings of health concerns elsewhere in the body. Here are the most common to look for. **By Aaron Bronner, OD**

Though retinal vasculature disorders or iritis come to mind first when we think about systemic disease and the eye, the cornea—with its unique clarity and dual zones of immune function—provides a unique window into a wide variety of systemic diseases that otherwise would require laboratory or imaging-based evaluation. Systemic manifestations in the cornea range from the mundane, as with arcus senilis, to the unusual and life-threatening, as with multiple myeloma or vasculopathic disease. Reviewing many of these manifestations—ignoring the well-described or general associations, such as hypercholesterolemia with arcus and keratitis sicca associ-

ated with its myriad autoimmune diseases—will ensure you are prepared to see even the most unusual corneal issues stemming from systemic disease.

Diabetes Mellitus

One of the most important systemic diseases monitored by optometrists for its ocular effects is diabetes. We are all aware of the retinopathy and neovascularization of the iris and/or the angle with potential for subsequent glaucoma, as well as the severe extraocular effects of diabetes; namely, nephropathy and neuropathy. Given that the eye is such a prominent site for diabetic involvement and in light of the potential for the disease to manifest as neuropathy,

it should come as no surprise that the cornea, which is the most densely innervated tissue in the body, may also be impacted by diabetes.

Diabetic keratopathy is thought to manifest as a result of changes in the density of corneal innervation, particularly within the sub-basal nerve plexus. Based on the results of at least one study group assessing Type I diabetes, these changes result in reduced corneal sensation, increasing corneal thickness and cellular polymorphism of both the corneal epithelium and endothelium. What's more, the level of diabetic keratopathy correlates well with the levels of retinopathy, systemic polyneuropathy and nephropathy.^{1,2}

Release Date: April 2015

Expiration Date: April 1, 2018

Goal Statement: Although ocular manifestations of systemic diseases most often present with retinal involvement, several systemic conditions—such as diabetes, autoimmune disorders and infectious diseases—can be diagnosed via corneal presentation. This article educates optometrists on how to recognize the corneal signs of systemic diseases and understand their role in disease management.

Faculty/Editorial Board: Aaron Bronner, OD

Credit Statement: COPE approval for 2 hours of CE credit is pending for this course. Check with your local state licensing board to see if this counts toward your CE requirement for relicensure.

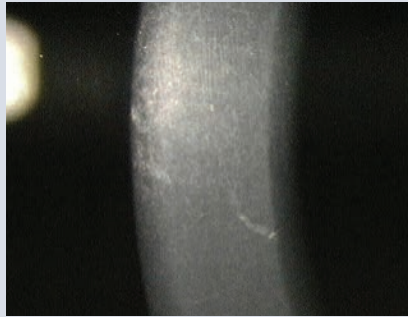
Joint-Sponsorship Statement: This continuing education course is joint-sponsored by the Pennsylvania College of Optometry.

Disclosure Statement: Dr. Bronner has no relevant financial relationships to disclose.

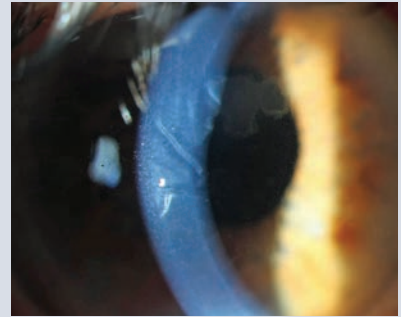
Corneal Lines Comparison



Waite-Beetham lines in a 73-year-old diabetic.



Vogt's striae in a 31-year-old keratoconic patient. Note how much finer, more tightly organized and more vertically arranged the Vogt's striae are compared to Waite-Beetham lines.



Corneal stromal edema. Edematous lines are much broader and less organized than Waite-Beetham lines.

While these changes can be assessed to some degree with formal esthesiometry and pachymetry, diabetic corneal neuropathy can only be objectively defined by confocal microscopy and so falls outside the optometrist's ability to quantify. It is useful to know, however, that as the disease progresses, patients with diabetes may become more neurotrophic and develop thicker corneas. In the study referenced, patients without diabetes had an average corneal thickness of 526 μm , patients with mild neuropathy had 558 μm and patients with severe neuropathy had corneal thickness of 625 μm .¹

A frequently encountered but infrequently recognized ocular manifestation of diabetes is the presence of pleats in either the deep stroma or Descemet's membrane of the non-ectatic eye—sometimes simply referred to as Descemet's wrinkles and formally known as Waite-Beetham lines. They are more prominent, though arranged with less density and precision, than Vogt's striae seen in keratoectasias. They are also not as thick and irregular as pleats seen in edematous corneas.

Descemet's wrinkles may be single or multiple, are longer than

Vogt's striae as seen in keratoconus, and tend to be somewhat wavy, though generally are arranged vertically or, less commonly, obliquely (unlike edematous pleats, which may be arranged in any direction).

These disturbances do not seem to create pathology of the cornea, nor do they appear to be the harbinger of worsening systemic disease. In fact, while Descemet's wrinkles are more common in diabetes (27% to 38% prevalence), they occur in unaffected patients as well (8% to 10.5%).^{3,4} They become more common with age in both populations, and occur earlier in patients with diabetes.³ Their presence—particularly in a patient for whom you may already suspect diabetes—may be a warning sign that a patient has developed the condition.

Peripheral Ulcerative Keratitis

Isolated corneal effects of iritis, scleritis and episcleritis—often associated with autoimmune disease—are also possible, and given their significant relationship with ocular morbidity and overall mortality, it is important for doctors to be aware of them.

The cornea can be roughly thought of as having two distinct immune zones:

- The *central cornea*, characterized by its avascularity and lack of lymphatics, is relatively remote from the immune response and therefore sheltered to a certain degree, from destructive systemic infectious as well as autoimmune processes.
- The *peripheral cornea*, however, with its proximity to the vasculature, lymphatic channels and secondary lymph tissue of the conjunctiva, sclera and episclera, is in a prime location to manifest immune processes associated with systemic infectious and autoimmune disease.

Peripheral ulcerative keratitis (PUK) is a significant ocular manifestation of systemic vasculitides, connective tissue diseases and infectious disease of the juxtalimbal cornea.

While there are a number of other corneal manifestations of autoimmune disease more common than PUK, it remains a very important pathology to be aware of because of its potential for being the presenting manifestation of autoimmune disease; one

study showed it preceded systemic diagnosis in 28% of cases.⁵⁻⁸ Additionally, among some forms of the disease it is associated with a mortality rate as high as 50% over five years if systemic immunomodulatory agents are not implemented.⁵⁻⁸

Though many autoimmune or systemic infectious diseases may result in PUK, the underlying mechanism of a perilimbal vasculitis seems to be relatively uniform. Characterized by a crescentic infiltrate with an overlying epithelial defect along the peripheral cornea, PUK lesions will progressively thin in the absence of appropriate treatment and may lead to perforation of the cornea.

Though it's most typically associated with adjacent areas of scleritis, PUK may occur as a primary manifestation as well; when isolated to the cornea without any systemic etiology it is known as a Mooren's ulcer, though some argue that Mooren's ulcer is actually associated with hepatitis.^{5,9}

As topical corticosteroids are contraindicated due to their possible promotion of collagenase activity (thereby enhancing keratolysis), topical treatment is limited primarily to aggressive lubrication. Surgical and parasurgical procedures such as application of a bandage contact lens, tissue glue, conjunctival resection and keratoplasty may temporarily avert any risk of perforation or even act to stunt the ulcerative process, but ultimately systemic treatment is needed to abate the attack and reduce risk of recurrence.⁶ Though matrix metalloproteinases are implicated in the disease process, adjunctive use of tetracyclines is often ineffective.

In the treatment of autoimmune-associated PUK, it is imperative to recognize the condition's role as a herald of worsening systemic disease; widespread vasculopathic dis-

Systemic Etiologies of PUK

- Rheumatoid arthritis
- Wegener's granulomatosis
- Polyarteritis nodosa
- Relapsing polychondritis
- Systemic lupus erythematosus
- Sjögren's syndrome
- Churg-Strauss syndrome
- Syphilis
- Lyme disease
- Herpes zoster

ease can lead to the patient's death. In addition to difficult treatment of their ocular disease, which may generally be managed with oral corticosteroids, these patients need to be placed on potent cytotoxic or immunomodulatory agents to control their underlying condition.⁷

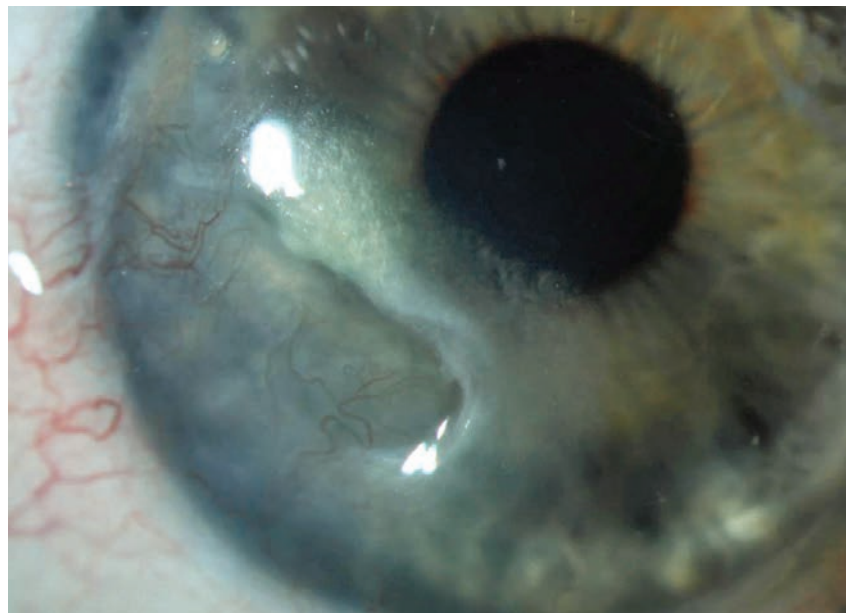
Corneal Deposits

Perhaps no corneal manifestation of systemic disease is as recognizable as the verticillata seen with the use of the anti-arrhythmic medication amiodarone. These

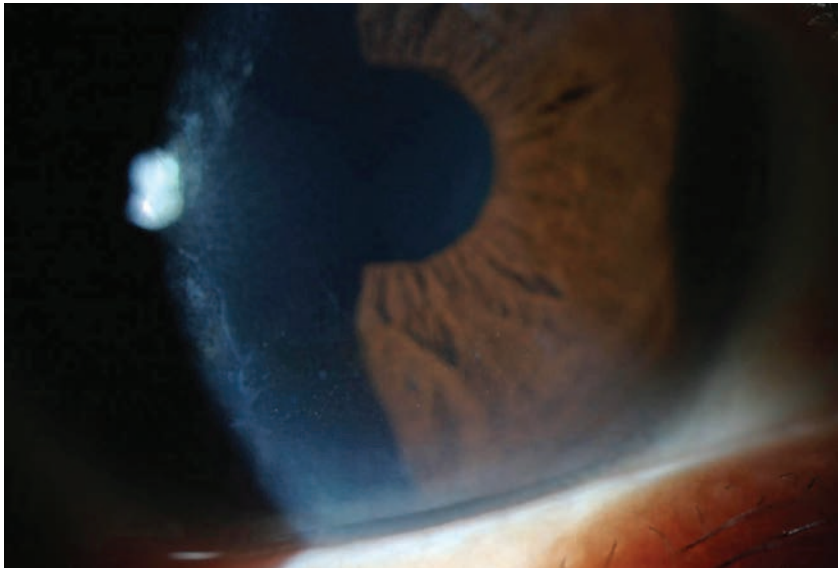
gray to golden whorled deposits in the interpalpebral region of cornea occur almost universally in patients on this drug and generally dissipate upon cessation of the medication.¹⁰ The rate of appearance upon initiation of the medication (days to months) and the disappearance upon cessation (months to years) varies widely from individual to individual.¹⁰

While quite prominent with biomicroscopy, verticillata generally have no effect on vision beyond occasional reports of glare and halos. Amiodarone is the most common source of verticillata, but there are other sources as well, including chloroquine, hydroxychloroquine—where, in the setting of corneal deposits, there is also a higher rate of retinopathy—tamoxifen, phenothiazine, suramin and indomethacin, among others.^{10,11}

While it may seem confusing for this widely varied group of medications to share the potential for creating verticillata, it is not their respective mechanisms that result in the manifestation, but the



Active peripheral ulcerative keratitis in a 35-year-old with thinning, vascularization and lipid deposit.



Corneal crystals in a 56-year-old man with multiple myeloma. While they appear granular in this direct illumination photo, the crystals scintillated with movement of light across their surface.

biochemical behavior of the molecules. They all share amphiphilic properties, which allows the molecules to penetrate and create lipid-based complexes within lysosomes.¹⁰ This eventually leads to the whorl keratopathy.

These lysosome-born deposits are generally held in the basal epithelium. Confocal microscopy has also identified abnormalities within the anterior stroma. The deposits and other abnormalities appear to develop as medication precipitates through the tear film, a reason why concomitant contact lens use may result in more dramatic whorls.^{10,12}

Beyond pharmaceuticals, Fabry's disease—an X-linked recessive disorder of lipid metabolism and one of many metabolic diseases that results in corneal deposits—has a near-universal link to verticillata as well.¹³ Though the verticillata seen with Fabry's tend to display more well-formed vortices (whereas drug-induced variants have more of a "cat's whisker appearance"), the underlying deposit, again, is lipid complexes within lysosomes of the

deep epithelium.^{10,13}

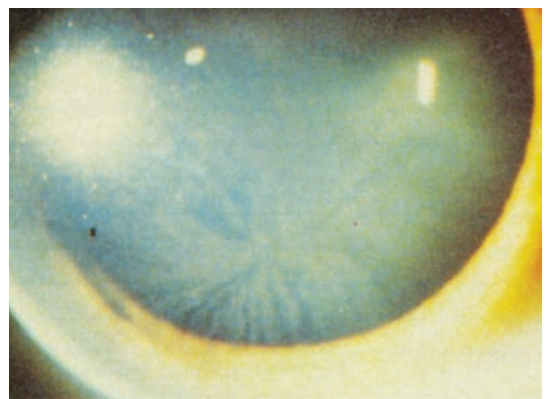
While the link between Fabry's and corneal deposits is very strong, the chances of diagnosing the condition based on ocular exam is quite low due to the limited symptomology associated with its ocular manifestations. In fact, in a study that looked at the utility of community ocular screening for Fabry's disease, only one case was discovered in over eight million patients—a fact that led the authors to question the utility of community eye screenings for this disease. The authors, however, then go on to point out how important it is to seize these rare opportunities to recognize the findings of verticillata when they could potentially yield a diagnosis of Fabry's.¹⁴

Though much less common than verticillate corneal deposits, corneal crystals are important to be aware of given their association with poten-

tially fatal systemic conditions. Beyond localized crystalline corneal dystrophies such as Schnyder's and Bietti's corneo-retinal dystrophy, metabolic disease, neoplastic and pre-neoplastic disorders are other sources of corneal crystals.

Cystinosis is an X-linked recessive metabolic disease of the amino acid cystine, which becomes trapped in lysosomes, potentially affecting tissue function systemically. There are three types of cystinosis, classified based on the time of development: infantile, intermediate and adult-onset, with infantile being the most severe and possible fatal. The corneal crystals that develop regardless of subtype are generally fine and, given sufficient time, are diffusely distributed throughout the anterior cornea. Though they may be very prominent, a patient's visual acuity is generally not affected, barring photophobia.¹⁵

Corneal crystals that develop in middle age may be caused by either local dystrophy or systemic metabolic disease. This group of patients must also have plasma cell dyscrasias on the differential diagnosis. Plasma cell dyscrasias—which include multiple myeloma, monoclonal gammopathy of unde-



Fabry's associated corneal verticillata. Note how much more well formed the pattern is than with typical medication-associated vortices.

Photo: Genzyme Corp.

terminated significance (MGUS) and Waldenstrom's macroglobulinemia, among others—are characterized by an atypical population of plasma or B cells, which redundantly produce a single, monoclonal form of immunoglobulin (IG) or an IG fragment, which then may become deposited in tissue.

The distribution and exact appearance of the corneal crystals seen in patients with these conditions vary widely: from diffuse fine through-and-through crystals, to very localized needle-like changes, to lattice and granular-like deposits and even those with verticillate appearance.^{11,16-18} They generally share the common feature of being crystalline and iridescent upon close examination.¹⁶ Despite the clear cornea being an ideal location to see systemically-derived protein deposits, crystals are not common findings, with one study reporting only a 1% incidence in patients with MGUS.¹⁶

Though an uncommon manifestation of uncommon systemic diseases, corneal crystals in this setting have diagnostic value, as symptoms of these diseases are relatively non-specific, and the presence of corneal crystals can help steer the clinician toward an

Metabolic Dysfunction and the Cornea

There are close to 40 recognized lysosomal storage diseases that may result in ocular findings, many of which will generate cornea-specific findings. All of these disorders share the common mechanism of metabolic products becoming trapped in lysosomes due to lack of a variety of metabolic enzymes. For more on metabolic diseases affecting the cornea, Holland's *Cornea* (specifically, chapter 64 by Kenyon, Navon and Haritoglou) covers this broad group of disorders and their wide range of possible effects on the cornea.¹⁵

important diagnosis. In the absence of other diagnostic clues, it may justify a hematology referral.

Band Keratopathy

A frequently encountered sequela of chronic ocular inflammation, band keratopathy is characterized by a sub-Bowman's layer opacification via deposition of calcium phosphate. In addition to being caused by various ocular pathologies, systemic diseases that cause hypercalcemia may also lead to band keratopathy.¹⁹

In hyperparathyroidism, which results in systemic hypercalcemia, band keratopathy may be among the presenting signs. Interestingly, as opposed to ocular band keratopathy, this keratopathy may spontaneously regress when the underlying etiology has been treated. Other systemic etiologies of band keratopathy are sarcoidosis, gout, chronic renal failure, multiple myeloma and metastatic disease.¹⁹

In general, band keratopathy in an otherwise unremarkable eye should generate an appropriate level of clinical suspicion that systemic hypercalcemia may be playing a role. These patients should be asked about symptoms of bone pain or frequent urination, and be sent for urinalysis and blood tests.

Infection

Although corneal manifestations of endogenous infectious disease are rare, given the significance of their underlying etiologies it's important for clinicians to be aware of them. Perhaps the most well-described form is phlyctenular keratoconjunctivitis and its association with systemic *Mycobacterium tuberculosis* infection.

Corneal phlyctenules are nodular lesions made up of lymphoid tissue; they may either be limbal or, when on the clear cornea, remain attached

Local and Systemic Causes of Corneal Phlyctenules

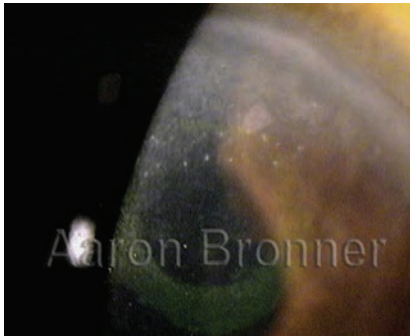- *Staphylococcus*
- *Mycobacterium tuberculosis*
- Chlamydia
- Coccidioides
- Fungal infections
- Protozoan infection
- Parasitic disease
- Rosacea

by a vascular tuft to the limbus. Their nodules may be smooth or ulcerated depending on their staging, and when isolated to the limbus they leave no clear zone between limbus and cornea.

The lesions represent a delayed-onset hypersensitivity reaction to a wide variety of microbial and viral antigens, the most common being blepharitis associated with *Staphylococcus*.²⁰ When associated with tuberculosis, these will occur almost exclusively at a young age, as the body eventually becomes desensitized to the causative antigen as it ages.²⁰

Though the precise etiology will dictate treatment, all phlyctenules will respond locally to topical corticosteroids. As phlyctenules are a hypersensitivity reaction, the topical use of corticosteroids is safe and in no way contraindicated by the underlying infectious etiology, though of course when a systemic etiology is suspected concurrent systemic treatment is necessary.^{20,21}

A second mycobacterial infection, *Mycobacterium leprae*, is actually reported to have the highest rate of ocular involvement in an infected individual of any systemic infectious disease, with estimates of ocular involvement being as high as 100% in an untreated population.^{22,23} Though the worldwide burden has been significantly reduced with effective multidrug therapy (MDT) and the disease



Leprosy keratitis in a patient with previously undiagnosed leprosy who presented to clinic in the US for cataract evaluation.

is currently most associated with developing countries, leprosy does still constitute a significant worldwide source of ocular morbidity. In the United States, a country of immigrants, it is something with which the eye care provider should at least have passing familiarity.

As the organism has a predilection for cooler temperatures, the anterior segment and adnexa, which are 4° to 6° C cooler than the deep orbit, are the affected tissues. Nearly all other forms of ocular disease associated with systemic infection generally show predilection for the posterior segment; however, whether leprosy affects the posterior segment at all is a matter of debate.²⁴ The sight-threatening impact of leprosy generally has to do with lagophthalmos resulting in corneal opacification or chronic plastic iritis resulting in gradual destruction of the ciliary body; however, direct involvement of the cornea is not uncommon.

While most corneal findings in leprosy are general—punctate epithelial erosions, prominence of corneal nerves (with greater specificity if beading of nerves occurs) and varying degrees of neurotrophy—the subepithelial infiltrate seen with leprosy is nearly pathognomonic,

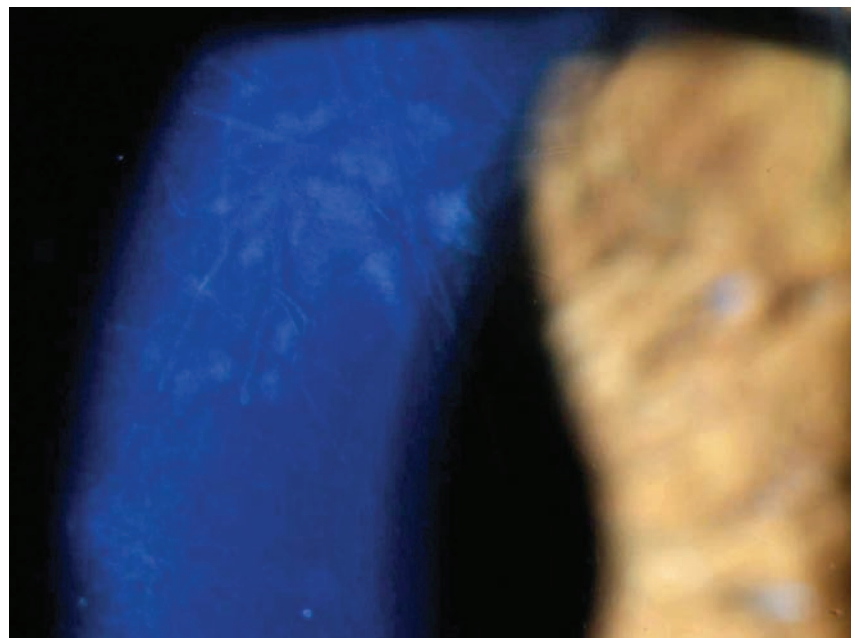
sharing a similar appearance with the perineuritis seen in *Acanthamoeba* keratitis.²³ They manifest as focal chalky-white, pinhead-sized subepithelial opacities within an area of avascular pannus, and unlike similar lesions seen with *Acanthamoeba*, which usually begin centrally, those seen with leprosy most often begin in the superior cornea.^{25,26} These lesions represent accumulations of active bacillus within “foam cell” monocytes; however, given the down-regulation of the immune response to *M. leprae* over time, they display little to no local infiltration of white cells.²⁷ Further, as no culture media exists for *M. leprae*, they cannot be effectively processed for microbiologic studies.

Treatment regimens for ocular disease resulting from leprosy is similar to that of tuberculosis: local corticosteroids are fine when indicated, but refer to infectious disease for confirmation of diagnosis (in this case with skin biopsy) and initiation of multidrug therapy.

Syphilis

Interstitial keratitis associated with syphilis is among the most widely recognized corneal effects of infectious systemic disease. Syphilitic keratitis, in and of itself, is an atypical manifestation of an increasingly uncommon disease, accounting for only 5% of all cases of syphilitic eye disease, with most of these cases being caused by the congenital form of the disease.¹⁵ Though the rate of acquired syphilis is increasing again, the congenital disease remains uncommon, affecting only one in one million.^{15,28} Bilateral presentation is most frequently associated with the congenital disease, as is the tendency to develop ghost vessels upon resolution.

Though the term “congenital syphilis” may lead the practitioner to view this disease as one of gestation and infancy, syphilitic interstitial keratitis is a late manifestation of congenital disease that commonly develops between the ages of five and 20. Likewise, with the acquired disease, keratitis is most typically a



Deep interstitial ghost vessels in a patient with contact lens induced keratitis mimicking syphilitic keratitis.

late manifestation, occurring years after the original infection.

In both congenital and acquired disease, the keratitis initially creates a deep focal inflammation of the stroma, typically starting in the periphery with a slight predilection for the superior cornea. In congenital cases, this will sequentially develop within months in the fellow eye. Vascularization typically follows the initial inflammation and perpetuates it, before ultimately burning out and regressing.

In acquired syphilis, the initial keratitis resembles congenital disease, though tends to remain less severe, unilateral and avascular.¹⁵

Though uncommon—and in the acquired form limited primarily to those who practice risky sexual behaviors or intravenous drug use—syphilis should be suspected in any case of bilateral stromal keratitis or deep stromal keratitis without a previous episode of more superficial disease (i.e., if it's not herpetic).

Unfortunately, patients without a previous diagnosis do not tell you they have congenital syphilis and I've yet to have a patient write "risky sexual behavior" or voluntarily document "intravenous drug user" on their initial health intake form. Because of this lack of transparency, serologic testing for syphilis should be ordered in cases where clinical suspicion puts syphilis on a differential.^{15,28} But keep in mind that there are a number of non-syphilitic causes of interstitial keratitis and corneal ghost vessels, with some being as simple as contact lens use. Within the United States, herpetic disease is twice as likely as any other pathology to cause the presentation.²⁹

While this review is far from complete—with important manifestations such as copper deposits

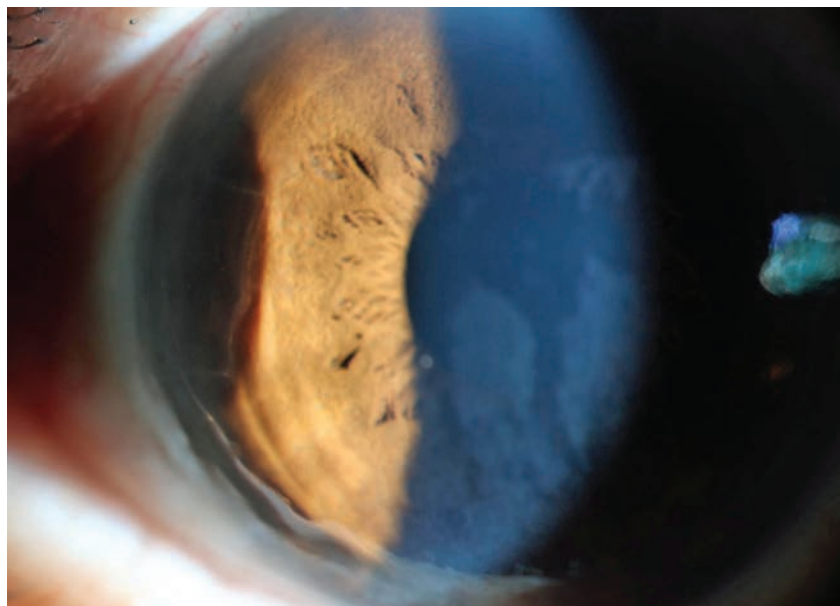


Photo: Jeff Unness, OD

Peripheral thinning in a patient previously treated for syphilitic peripheral ulcerative keratitis.

in the corneal periphery as seen with Wilson's disease being omitted—hopefully it serves as a useful review and reminder of the spectrum and possible seriousness of these manifestations both locally to the cornea itself and systemically. It's important to periodically be reminded that although our focus and attention is on the organ of the eye, the overall health of the patient is ultimately the most important consideration for us as optometrists. Where ocular and systemic diseases converge, it is our responsibility as the nation's primary eye care provider to be astute in our observation and conscientious in our assessments so we can refer patients in an appropriate and timely manner. You might just be saving someone's life! ■

Dr. Bronner is a staff optometrist at the Pacific Cataract and Laser Institute of Kennewick, Wash.

1. Rosenberg M, et al. Corneal structure and sensitivity in type 1 diabetes mellitus. *Invest Ophthalmol Vis Sci.* 2000;41:2915-21.
2. Petropoulos IN, et al. Rapid automated diagnosis of peripheral neuropathy with in vivo corneal confocal microscopy. *Invest Ophthalmol Vis Sci.* 2014;55:2071-8.

3. Henkind P, Wise GN. Descemet's wrinkles in diabetes. *Am J Ophthalmol.* 1961;52:371-4.
4. Mocan MC, Irkc M, Orhan M. Evidence of Waite-Beetham lines in the corneas of diabetic patients as detected by in vivo confocal microscopy. *Eye.* 2006;20:1488-90.
5. Ladas JG, Mondion BJ. Systemic disorders associated with peripheral corneal ulceration. *Current Opinion in Ophthalmology.* 2000;11:468-71.
6. Messmer EM, Foster CS. Vasculitic Peripheral Ulcerative Keratitis. *Survey of Ophthalmology.* 1999;43:379-96.
7. Foster CS, Forstot SL, Wilson LA. Mortality rate in rheumatoid arthritis patients developing necrotizing scleritis or peripheral ulcerative keratitis: Effects of systemic immune suppression. *Ophthalmology.* 1984;91:1253-63.
8. Tauber J, et al. An Analysis of therapeutic decision making regarding immunosuppressive chemotherapy for peripheral ulcerative keratitis. *Cornea.* 1990;9:66-73.
9. Wilson SE, et al. Mooren's ulcers and hepatitis C virus Infection. *N Engl J Med.* 1993;329:62.
10. Hollander DA, Aldave AJ. Drug-induced corneal complications. *Current Opinion in Ophthalmology.* 2004;15:541-8.
11. Sharma P, et al. Cloudy corneas as an initial presentation of multiple myeloma. *Clinical Ophthalmology.* 214;8:813-7.
12. Falke K, et al. The microstructure of cornea verticillata in Fabry disease and amiodarone-induced keratopathy: a confocal laser scanning microscopy study. *Graefes Arch Clin Exp Ophthalmol.* 2009;247:523-34.
13. Sodi A, Ioannidis A, Pitz S. Ophthalmological manifestations of Fabry disease. In: Mehta A, Beck M, Sunder-Plassmann G, eds. *Fabry Disease: Perspectives from 5 Years of FOS.* Oxford: Oxford PharmaGenesis; 2006. Available from: <http://www.ncbi.nlm.nih.gov/books/NBK11599/>.
14. Hauser AC, et al. Results of an ophthalmologic screening programme for identification of cases with Anderson-Fabry disease. *Ophthalmologica.* 2004;218:207-9.
15. Kenyon KR, Navon SE, Haritoglou C. Corneal manifestations of metabolic disease. In: Krachmer JH, Mannis MJ, Holland EJ, eds. *Cornea.* 2nd ed. St. Louis: Mosby;2004:749-76.
16. Spiegel P, et al. Unusual presentation of paraproteinemic corneal Infiltrates. *Cornea.* 1990;9:81-5.
17. Lisch W, et al. Chameleon-like appearance of immunotactoid keratopathy. *Cornea.* 2012;31:55-58.
18. Chou JL, Sink ML. Corneal crystals: a precursor to cancer. *Optometry and Vision Science.* 2011;88:E543-7.

19. Mora ML, Smith RE. Corneal and systemic diseases. In: Tasman W, Jaeger EA eds. *Duane's Ophthalmology*. Lipincott Williams Wilkins; 2006.
 20. Mondino BJ. Inflammatory diseases of the peripheral cornea. *Ophthalmology*. 1998;95:463-72.
 21. Rapuano C, Luchs JI, Kim T. Corneal infections, inflammations, and surface disorders. In: *Anterior Segment: The Requisites in Ophthalmology*. Mosby; 2000:115-8.
 22. Dethlefs R. Prevalence of ocular manifestations of leprosy in Port Moresby, Papua New Guinea. *British Journal of Ophthalmology*. 1981;65:223-5.

23. Choyce DP. Ocular leprosy, with reference to certain cases shown. *Proceedings of the Royal Society of Medicine*. 1955;48(2):108-12.
 24. Flytche TJ. Role of iris changes as a cause of blindness in lepromatous leprosy. *British Journal of Ophthalmology*. 1981;65:231-9.
 25. Choyce DP. Diagnosis and management of ocular leprosy. *British Journal of Ophthalmology*. 1969;53:217-23.
 26. Krachmer JH, Palay D. *Corneal Atlas*. 2nd 466 Edition. Mosby Elsevier; 2006.

27. Myrvang B, et al. Immune responsiveness to mycobacterium leprae and other mycobacterial antigens throughout the clinical and histopathological spectrum of leprosy. *Clinical Exp. Immunology*. 1973;14:541-53.
 28. Wilhelmus KR. Syphilitic interstitial keratitis. In: Krachmer JH, Mannis MJ, Holland EJ, eds. *Cornea*. 2nd ed. St. Louis: Mosby; 2004:1133-59.
 29. Schwartz GS, Harrison AR, Holland EJ. Etiology of immune stromal (interstitial) keratitis. *Cornea*. 1998;17(3):278-81.

OSC QUIZ

You can obtain transcript-quality continuing education credit through the Optometric Study Center. Complete the test form (page 61), and return it with the \$35 fee to: Optometric CE, P.O. Box 488, Canal Street Station, New York, NY 10013. To be eligible, please return the card within one year of publication.

You can also access the test form and submit your answers and payment via credit card at *Review of Optometry* online, www.reviewofoptometry.com.

You must achieve a score of 70 or higher to receive credit. Allow eight to 10 weeks for processing. For each Optometric Study Center course you pass, you earn 2 hours of transcript-quality credit from Pennsylvania College of Optometry and double credit toward the AOA Optometric Recognition Award—Category 1.

Please check with your state licensing board to see if this approval counts toward your CE requirement for relicensure.

1. Which is NOT a manifestation of diabetic keratopathy?

- Mild corneal edema.
- Reduced nerve density of the sub-basal plexus.
- Epithelial polymorphism.
- Endothelial polymorphism.

2. Diabetic keratopathy:

- Is associated with thinning of the cornea.
- Is associated with hypersensitivity of corneal nerves.
- Can be roughly correlated with level of retinopathy.
- Cannot be roughly correlated with systemic polyneuropathy.

3. Waite-Beetham lines:

- Are only found in diabetics.
- Tend to indicate worsening systemic disease.
- Manifest as very fine, densely distributed and vertically oriented lines in the deep cornea.
- Were first described in the 1930s.

4. Diabetic corneal neuropathy can be

quantified with:

- Confocal microscopy.
- Esthesiometry.
- Pachymetry.
- Careful slit lamp examination.

5. Due to its association with worsening systemic vasculitis, peripheral ulcerative keratitis is associated with a mortality rate as high as:

- 10% if systemic immune modulatory treatment is not initiated.
- 25% if systemic immune modulatory treatment is not initiated.
- 50% if systemic immune modulatory treatment is not initiated.
- 75% if systemic immune modulatory treatment is not initiated.

6. Which of the following is not a cause of peripheral ulcerative keratitis?

- Wegener's granulomatosis.
- Vitamin A deficiency.
- Rheumatoid arthritis.
- Herpes zoster.

7. Which treatment(s) is/are contraindicated in management of peripheral ulcerative keratitis?

- Oral corticosteroids.
- Topical corticosteroids.
- Sub-Tenon's corticosteroids.
- Both b and c.

8. Which of the following is NOT true regarding corneal verticillata?

- They occur nearly universally in patients on amiodarone.
- They are associated with a higher risk of retinopathy when seen in association with hydroxychloroquine.
- They are caused by carbohydrate deposits within lysozymes.
- They may be more prominent in contact lens wearers who use causative medications.

9. Fabry's disease:

- Results in corneal whorls that are biochemically similar to those seen in drug-induced verticillata.

b. Is an X-linked disorder of carbohydrate metabolism.

- Typically generates less prominent whorls than those seen with medically-induced verticillata.
- Is often initially suspected based on corneal findings.

10. Which of the following should NOT be considering in a differential diagnosis of a patient with corneal crystals?

- Metabolic disease.
- Multiple myeloma.
- Chronic myelogenous leukemia.
- Bietti's corneo-retinal dystrophy.

11. The plasma cell dyscrasias are a family of hematologic conditions that result in:

- Excess production of immunoglobulin.
- Proliferation of lymphatic tissue.
- Too much hemoglobin within the blood.
- Accumulation of carbohydrate within lysozymes.

12. Which is true regarding cystinosis?

- It is the only metabolic disease that may cause corneal findings.
- The infantile form may cause death.
- The adult onset form is the most severe.
- Only the infantile form may result in corneal crystals.

13. Band keratopathy is NOT associated with this systemic condition:

- Hyperparathyroidism.
- Hyperthyroidism.
- Sarcoidosis.
- Gout.

14. Which is true regarding corneal phlyctenules?

- They represent a Type III hypersensitivity response.
- There will always be a lucid zone between the lesion and the limbus.
- Though they are related to systemic disease, they represent an active local ocular infection.
- They are most associated with tuberculosis

OSC QUIZ

when seen in children.

15. Which is NOT a possible cause of phlyctenules?

- a. *Mycobacterium tuberculosis*.
- b. *Mycobacterium leprae*.
- c. *Staphylococcus*.
- d. Rosacea.

16. Which systemic infection has the highest rate of ocular involvement?

- a. Herpes simplex.
- b. Herpes zoster.
- c. Syphilis.
- d. Leprosy.

17. Which is true regarding leprosy?

- a. The most common ocular manifestation is posterior uveitis.
- b. The keratitis associated with the disease may be cultured to aid in the diagnosis.
- c. Culture material is Lowenstein-Jensen medium.
- d. The diagnosis can only be achieved by a skin biopsy.

18. The keratitis associated with leprosy:

- a. Is associated with vascularization.
- b. Generally begins in the inferior cornea.
- c. Manifests as discrete, chalky, subepithelial opacities.
- d. Is associated with significant corneal inflammation.

19. Which is the most common cause of interstitial keratitis in the US?

- a. Lyme disease.
- b. Herpetic eye disease.
- c. Cogan's syndrome.
- d. Syphilis.

20. Which is true regarding syphilitic interstitial keratitis?

- a. It's most commonly a manifestation of early congenital disease.
- b. It's most commonly a manifestation of late acquired disease.
- c. Vascularization and ghost vessels are most associated with congenital disease.



TAKE THE TEST ONLINE TODAY!
[www.reviewofoptometry.com/
 continuing_education/](http://www.reviewofoptometry.com/continuing_education/)

Examination Answer Sheet

Valid for credit through April 1, 2018

This exam can be taken online at www.revoptom.com/continuing_education. Upon passing the exam, you can view your results immediately and download a real-time CE certificate. You can also view your test history at any time from the website.

Corneal Harbingers of Systemic Disease

Directions: Select one answer for each question in the exam and completely darken the appropriate circle. A minimum score of 70% is required to earn credit.

Mail to: Jobson - Optometric CE, PO Box 488, Canal Street Station, New York, NY 10013

Payment: Remit \$35 with this exam. Make check payable to Jobson Medical Information LLC.

COPE approval for 2 hours of CE credit is pending for this course.

This course is joint-sponsored by the Pennsylvania College of Optometry

There is an eight-to-ten week processing time for this exam.

1 = Excellent 2 = Very Good 3 = Good 4 = Fair 5 = Poor

1. (A) (B) (C) (D)
2. (A) (B) (C) (D)
3. (A) (B) (C) (D)
4. (A) (B) (C) (D)
5. (A) (B) (C) (D)
6. (A) (B) (C) (D)
7. (A) (B) (C) (D)
8. (A) (B) (C) (D)
9. (A) (B) (C) (D)
10. (A) (B) (C) (D)
11. (A) (B) (C) (D)
12. (A) (B) (C) (D)
13. (A) (B) (C) (D)
14. (A) (B) (C) (D)
15. (A) (B) (C) (D)
16. (A) (B) (C) (D)
17. (A) (B) (C) (D)
18. (A) (B) (C) (D)
19. (A) (B) (C) (D)
20. (A) (B) (C) (D)

Rate the effectiveness of how well the activity:

21. Met the goal statement: (1) (2) (3) (4) (5)

22. Related to your practice needs: (1) (2) (3) (4) (5)

23. Will help you improve patient care: (1) (2) (3) (4) (5)

24. Avoided commercial bias/influence: (1) (2) (3) (4) (5)

25. How would you rate the overall quality of the material presented? (1) (2) (3) (4) (5)

26. Your knowledge of the subject was increased:
 Greatly Somewhat Little

27. The difficulty of the course was:
 Complex Appropriate Basic

How long did it take to complete this course?

Comments on this course:

Suggested topics for future CE articles:

Please retain a copy for your records. Please print clearly.

First Name _____

Last Name _____

E-Mail _____

The following is your: Home Address Business Address

Business Name _____

Address _____

City _____ State _____

ZIP _____

Telephone # _____ - _____ - _____

Fax # _____ - _____ - _____

By submitting this answer sheet, I certify that I have read the lesson in its entirety and completed the self-assessment exam personally based on the material presented. I have not obtained the answers to this exam by any fraudulent or improper means.

Signature _____ Date _____

Lesson 111213

RO-OSC-0415

10 Tips For Improving Visual Fields

Perimetry may seem like second nature, but these recommendations can help you obtain better results by refining your understanding of the technology.

By **Matt Horton, OD**

Visual field testing is an essential part of eye care, necessary for diagnosis and management of multiple conditions we see on a daily basis. Perimetry is subjective in nature, and it is necessary to take care in both the acquisition and analysis of the testing data. Many barriers to successful visual field testing exist, but much of the frustration encountered can be avoided by following some basic guidelines and using all the technological features today's devices offer.

1. Pick the right test

Most visual field testing is “standard automated perimetry” (SAP). SAP is a computerized, threshold static perimetry that tests the central visual field with a white stimulus on a white background. Threshold testing has been the standard for glaucoma care since the mid 1980s, offering many

advantages over the older standard of manual kinetic perimetry.¹⁻²

SAP test patterns can be categorized as threshold or screening. Common threshold patterns are 10-2, 24-2, 30-2 and 60-4. Field analysis in glaucoma relies primarily on the 24-2 and 30-2 patterns, as the majority of ganglion cells lie within the central 30 degrees of fixation.³ Use of 24-2 has become increasingly prevalent as the test of choice in glaucoma due to its faster testing time and reduced trial lens and lid artifact errors. A 24-2 has 54 test points and is identical to the 72-point 30-2 testing protocol except for the removal of most outer ring test points (24-2 retains the two outermost nasal points from the 30-2 pattern).

Both of these patterns have test points spaced six degrees apart. Points straddle the mid-line, allowing for better identification of glaucomatous defects.

Swedish Interactive Thresholding Algorithm (SITA) Standard in 24-2 pattern with stimulus size III is generally the preferable test for most routine glaucoma and neurological testing.⁴ Clinicians often have the misconception that SITA Fast strategy is an easier test for patients who have difficulty taking a SITA Standard or full threshold strategy test. SITA Fast does take 2-5 minutes per eye to perform (compared with 3-7 minutes per eye for SITA Standard). However, the algorithm it uses presents points requiring more discretion from the patient, and it is best used in experienced test takers or young patients.⁵

2. Know when to modify the testing strategy

Stimulus size III is standard for most situations and should be used in patients with 20/200 or better. Increase size to V in patients with

poorer vision (this may be indicated in some patients with advanced glaucoma). When altering the stimulus, keep in mind that the normative database, SITA test strategy, and progression analysis will no longer be available. When severe field loss in advanced glaucoma is present, change to a 10-2 pattern to allow for more accurate assessment of the remaining visual field. In cases where vision is reduced due to macular disease or central scotoma, use a diamond fixation target—this displays four LEDs, allowing the patient to center their gaze between the targets.⁶

3. Don't overlook the central field in early glaucoma

The macula is +/-8 degrees from fixation and represents only a small portion of the retinal area, but contains about 30% of the retinal ganglion cells.³ A 24-2 test only includes four points within this highly sensitive region. The 24-2 test protocol was designed to detect nasal and arcuate glaucomatous defects. These defects originate from damage to the arcuate nerve fiber bundles—often visible on funduscopy with retinal nerve fiber layer (RNFL) wedge defects or neuroretinal rim notching.

Research shows significant sections of the inferior macula are associated with the inferior arcuate bundle (the majority of macular ganglion cells associated with the

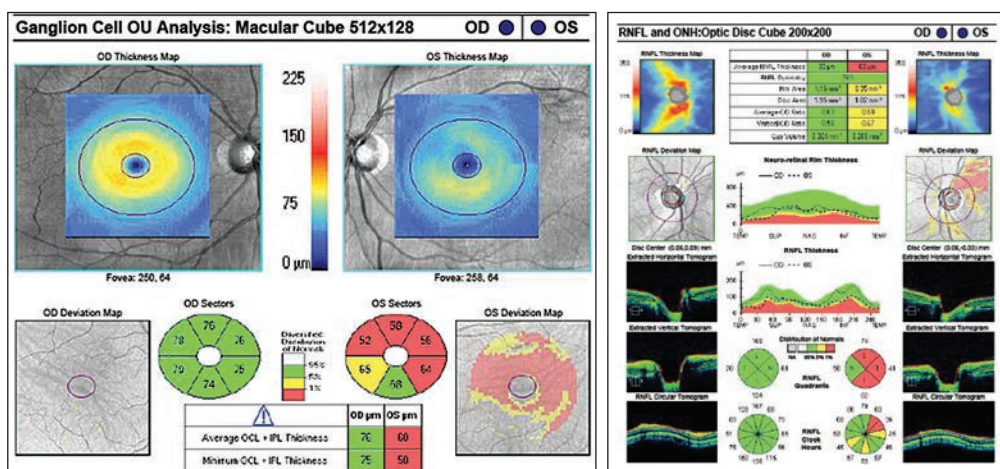


Fig. 1. A 10-2 visual field can be a valuable addition to standard 24-2 and 30-2 testing. Alternating these tests will allow for better detecting of defects that threaten fixation. This 58-year-old black male has early normal-tension glaucoma associated with extensive macular ganglion cell loss and a visual field defect that surrounds fixation. BCVA was 20/20 OD and 20/25 OS.

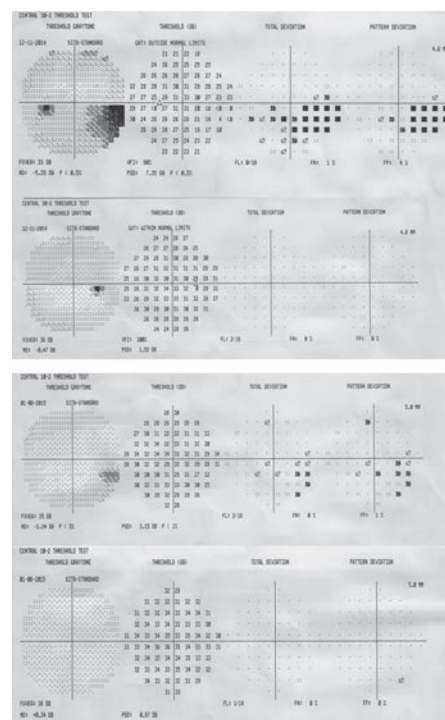
temporal quadrant of the optic nerve which is often preserved in early glaucomatous disease).⁷

If there is even a single central point defect with a 24-2 or 30-2 pattern, consider adding a 10-2 test to your assessment (figure 1). This will allow proper detection of early macular damage. The inferior temporal quadrant of the circumpapillary RNFL is particularly susceptible to this damage and will correlate with a small arcuate defect in superior central visual field. This 35-degree region of the RNFL has been termed the “macular vulnerability zone.”⁷

Also, be aware that macular damage can present diffusely rather than sectorally.

4. Understand the roles of the technician and physician

It's important that the staff and physician maintain positive atti-



tudes about the value of perimetry to encourage the patient to provide optimal results during testing.⁸ Although the physician should not administer the test personally, they should take time during the exam to stress to the patient the importance of perimetry in the management of their ocular disease. Physicians should continue to encourage patients when subsequent testing is ordered or reviewed.

Technicians should periodically get a refresher on the importance of perimetry. Those performing perimetry should take the test themselves, so they can more effectively explain it to patients. Technicians should always be present during the testing period so they may provide re-education, as necessary, and feedback regarding testing reliability. A technician who does not properly respond to patients' perimetry complaints promotes poor test taking.

5. Recognize, reduce artifact

Peripheral points, particularly in a 30-2 test, are susceptible to variability and artifact. Trial lens artifacts usually produce sharp depressions at peripheral points, often in a ring pattern. These artifacts are more common in moderate-high hyperopic corrections and when two trial lenses are used. Make certain the lens is placed as close to the eye as possible; also, using spherical equivalent up to 2.00D of refractive cylinder will help reduce some of these errors.

Pupil size smaller than 2mm or larger than 6mm can induce artifacts. If you decide to dilate a patient due to miosis, make certain to remain consistent on subsequent testing. If ptosis or dermatochalasis produce obstruction of the superior field, then the eyelids may be taped for testing (again, this should be noted on the field report to maintain consistency on all testing).

6. Interpreting results systematically

Don't take shortcuts in reviewing data from visual fields—the professional component of testing is the interpretation, and each analysis report contains a wealth of data.

Know if a test is reliable; fixa-

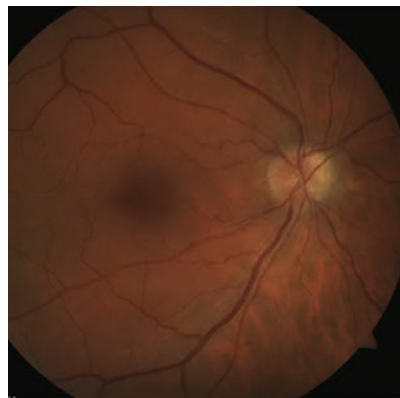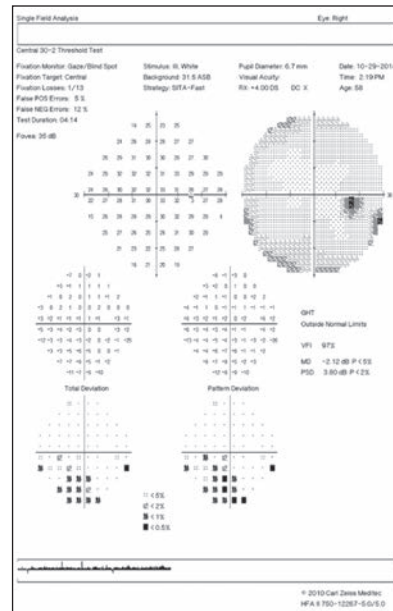


Fig. 2. Optic disc drusen may produce visual field defects similar to those seen in glaucoma. This 58-year-old white male was found to have an inferior visual field defect correlating to superior disc drusen (evident in the fundus photo).

tion losses greater than 20% can indicate poor reliability, but improper mapping of the blind spot can cause false elevation of this index. Gaze tracking allows for more accurate interpretation of patient fixation stability. Gaze tracking measures up to one degree, whereas traditional fixation monitoring is sensitive for three degrees (half the size of the physiologic blind spot).

False positives are a key reliability index. "Trigger happy" patients will push the response button in the absence of a stimulus. False positives are primarily important in tests that have defects—they are not a reason to invalidate an otherwise unremarkable or clear visual field test. If this index is higher than 15%, the test needs to be invalidated or repeated (even 5% to 10% should be scrutinized). Tests with high false positives are automatically removed from a Humphrey Guided Progression Analysis (GPA).

False negatives represent variability in patient responses and are seen at increasing levels in



depressed visual fields. A false negative value of 10% to 15% or more is suggestive of inattention in a patient without a significant field defect. If significant glaucomatous loss is present, false negatives should not deem a test unreliable if it otherwise appears reliable.⁹

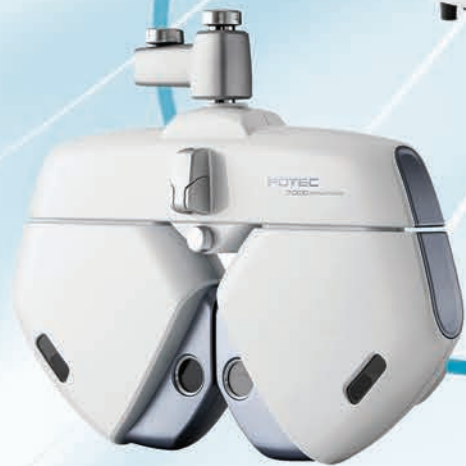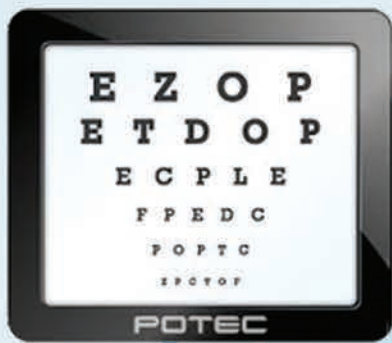Age matters—the Humphrey database uses norms grouped by age in 10-year intervals. Keep in mind that a patient's results may appear to improve due to this grouping effect. For instance, if testing was performed at age 59 and, on subsequent examinations, age 60, the second test would be compared with a different database than the first test.

Know if you are detecting or monitoring a defect. Your interpretation strategy should differ in patients being evaluated for the presence of a glaucomatous defect and patients who have established visual field loss.

In patients who are glaucoma suspects, rely on the Glaucoma Hemifield Test (GHT) and the pattern deviation probability map. GHT was designed to have high

YOUR EXAM... ONLY BETTER!

The Veatch Digital Refraction System eliminates costly inefficiencies, enhances your practice, and makes the exam process more enjoyable for you and your patients.



FREE
Visual Acuity System*
with purchase of
Digital Refractor

- Increased efficiency • Combat reductions in reimbursements
- Enhanced practice image • EMR integration • Patient referrals
- Increased optical sales • Competitive advantage
- Eliminate back and shoulder pain and bursitis

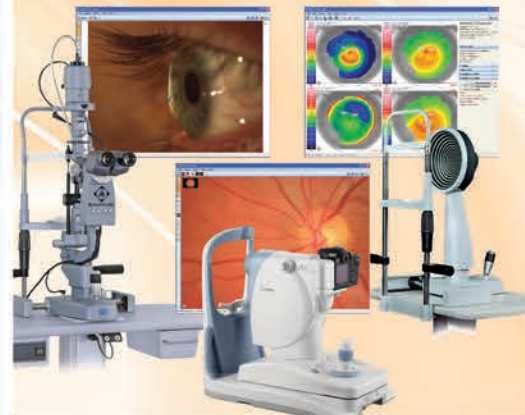
ADDITIONAL OFFERS FROM VEATCH

Exam Lane Packages
Starting at \$12,995



ReSeeVit™

- Anterior Segment Imaging
- Retinal Imaging
- Corneal Wavefront Topography



Insight Visual Acuity System
ONLY \$1,295



TOLL FREE: 800.447.7511 E-MAIL: ad@voi2020.com www.voi2020.com



sensitivity and specificity for glaucomatous defects.¹⁰ It uses five zones in each hemifield and tests them for symmetry based on a normative database.

GHT outside normal limits is displayed when at least one zone is at $p < 1\%$. This finding has been shown to have 94% specificity.¹¹ GHT borderline is displayed when the p value is between 1% and 3%. Generalized depression indicates that the most sensitive test points are less than 50% of normal. Abnormally high sensitivity is a red flag and indicates low reliability (usually associated with a high rate of positives).

If a field shows scattered non-specific depressions, keep in mind that a diagnostic early glaucomatous defect is generally recognized as a repeatable cluster of three or more points on the same side of the horizontal meridian all reaching statistical significance (with one or more points having $p < 1\%$ significance)—the test points adjacent to the blind spot may be ignored.

If a patient with visual field loss is being monitored with serial examination, use the mean deviation (MD), pattern standard deviation (PSD) and visual field index (VFI) to track progression.

MD is sensitive to media opacity, uncorrected refractive error, and miosis. MD will be less sensitive in early-stage glaucoma and other cases with localized field loss.

The GHT can better aid in identifying early, localized defects, and PSD can be useful for tracking these milder defects. In the presence of other suspicious findings, a PSD of $p < 5\%$ is a strong indicator of glaucomatous loss. PSD, however, will spike in early disease and peak in the early part of advanced disease; however, it will then however decrease due to reduced

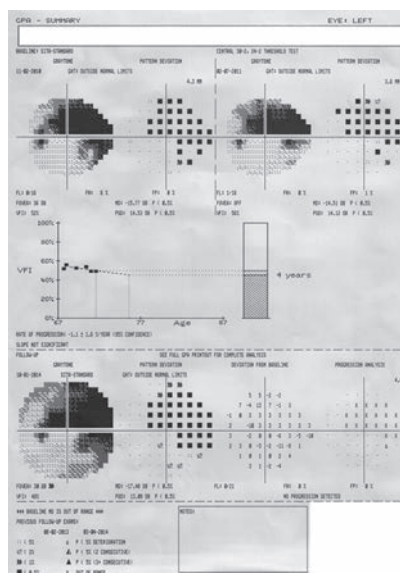


Fig. 3. The GPA summary report will show two baseline fields: a Glaucoma Change Probability Map (an event analysis) of the most current test and a VFI graph (trend analysis) for all available fields. This is a patient with advanced glaucoma and progressing cataract. No progression is detected adjacent to the dense arcuate scotoma, which itself is too depressed to allow for progression analysis.

overall field sensitivity (worsening cataract may also decrease PSD).

VFI is a metric that was created to help with staging and progression of glaucoma. It is intended to reflect ganglion cell loss and function. VFI is displayed in a percentage from 0 to 100. It is weighted preferentially to central points and more resistance to cataract.¹²

7. Test, test, repeat

The real utility of visual fields lies in tracking progression of glaucomatous defects. The European Glaucoma Society (EGS) recommends visual field testing several times yearly for the first two years after diagnosis.¹³ This will help establish a rate of progression and identify the roughly one in

six glaucoma patients who progress at a dangerously high rate (greater than 2dB per year).¹⁴ If this frequency is not reasonable in your practice setting, then test at least twice yearly during the first two years. Testing frequency can decrease at the two-year and five-year marks once a progression rate is reliably established.

Also, keep in mind that an artifactual reduction in sensitivity may be seen on the first perimetric test in approximately 10% of patients.¹⁵

These patients may require two or three tests to produce an accurate and reliable baseline result.

8. Be on the look out for masquerading retinal and optic nerve conditions

Concomitant retinal or neurological disease can confound interpretation of visual field defects in many patients. Altitudinal or arcuate field defects may be seen in anterior ischemic optic neuropathy, vascular occlusion, optic disc drusen (figure 2) or sectoral retinal photocoagulation treatment. Peripheral field constriction may be present in optic neuritis, nonglaucomatous optic atrophy, advanced retinitis pigmentosa or acute zonal occult ocular retinopathy (AZOOR). Nonproliferative diabetic retinopathy can also cause scattered visual field deviations, even in mild stages.¹⁶ Moderate and severe diabetic retinopathy will more likely have a dense and repeatable visual field defect.

9. Use progression analysis tools

We expect progression in the majority of glaucoma patients. In fact, the Early Manifest Glaucoma Treatment Trial showed that 59% of glaucoma patients will progress

Discover Biotrue® ONEday Lenses

Made from HyperGel™, a bio-inspired material designed to work like the eye



Meets

oxygen level the open eye needs¹



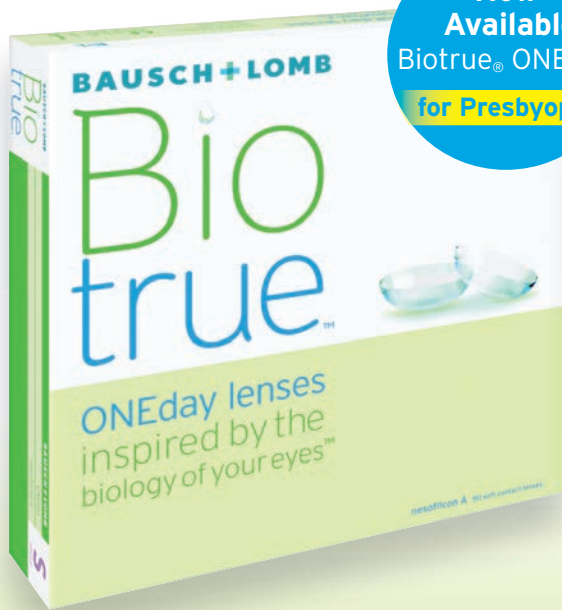Matches

water content of the cornea – 78%²



Mimics

lipid layer of the tear film³



Recommend comfortable vision throughout the day with **Biotrue ONEday** and **Biotrue ONEday for Presbyopia**.

For more information, call **1-800-828-9030**, contact your Sales Representative or visit **biotrue.com**

Distributed by Bausch + Lomb, a Division of Valeant Pharmaceuticals, North America LLC, Bridgewater, N.J. © 2014 Bausch & Lomb Incorporated. ®/™ are trademarks of Bausch & Lomb Incorporated or its affiliates. PNS07134 US/BPR/14/0013

REFERENCES: 1. Brennan NA. A Model of Oxygen Flux Through Contact Lenses. *Cornea* 20(1):104-108, 2001. 2. Bergmanson J. *Clinical Ocular Anatomy and Physiology*, 14th ed. Houston, Texas: Texas Eye Research and Technology Center; 2007. 3. Twenty-two subjects participated in a randomized, double-masked, contralateral eye study to evaluate water loss of Biotrue® ONEday, 1-Day ACUVUE MOIST, and 1-Day ACUVUE TruEye. After 4, 8, 12, and 16 hours of wear, lenses were removed and immediately weighed (wet weight). The lenses were then completely dried and reweighed (dry weight). The percent water loss was then calculated for each lens from the wet and dry weights.

BAUSCH + LOMB
See better. Live better.

in eight years, even if treated and well controlled.¹⁷ Determining if the rate of progression will affect visual function and quality of life is important when making the decision to proceed with escalating therapy that carries increased risk of side effect. Even in light of 21st century technology, serial visual field testing remains the most accurate means of determining progression in glaucoma. Modern perimeters are equipped with powerful software tools that allow practitioners to accurately track these metrics.

The best tools for progression analysis on HFA units are GPA Change Probability, VFI trend, and MD trend, and linear regression and cluster regression analysis on Octopus units. GPA requires a minimum of five tests to fully utilize its features. Two tests will be selected automatically for baseline, but these tests may be manually selected. From this baseline, GPA is able to provide both event- and trend-based progression analysis on future tests (*figure 3*).

Event-based progression determines whether or not progression has occurred on a point-by-point basis. Trend-based progression will determine the rate of progression. Event-based progression analysis has been used in several landmark glaucoma clinical trials (such as EMGT, AGIS and CIGTS).¹⁸⁻²⁰ The GPA Change Probability Map displays a point-by-point analysis and identifies progression if at least three points have worsened (marked as “possible progression” if repeated in two tests and “likely progression” if repeated in three tests). These criteria for progression were established by the EMGT.¹⁸ Using this method has 96% sensitivity in 30-2 and 91% in 24-2. Keep in mind that detecting pro-

gression often takes two or more years. EMGT had a mean of 33 months to progression in 30-2 protocols and 37 months for 24-2.⁵

Trend-based progression will display linear regression analysis of VFI. If the tests span two or more years, the software will plot a future prediction of progression. Prior to VFI, MD was used for progression analysis, but VFI provides a more accurate determination in the presence of cataract and cataract surgery.²¹

If a patient experiences non-glaucomatous loss due to vascular occlusion, ischemic optic neuropathy or panretinal laser, it is necessary to establish a new baseline for visual field testing as well as change the tests used in progression analysis. Make certain to check the two baseline tests in GPA for accuracy. Any tests are usable unless false positives are higher than 15%. Avoid using fields that are further than 6-12 months apart for baseline. Update to new baselines if there is a significant change in therapy (such as filtration procedure). Also note that GPA is not available when MD is over 20dB.

Using progression analysis for nonglaucomatous field loss should be limited to VFI linear regression/trend analysis (the GPA change probability was designed for use in glaucoma). Some conditions, such as optic neuritis, may have such a high inherent variability that quantitative progression analysis is not possible. For neurological field loss, the overview report is preferred.

10. Make the correlation between structure, function

Conventional wisdom holds that structural change precedes functional loss in glaucoma. However, we often see patients who demonstrate significant RNFL loss prior

to repeated visual field defects as well as patients progressing on their fields without detectable progression of RNFL or ganglion cell loss. Clinicians should nonetheless seek to find correlation of structure and function to help strengthen diagnosis and bring attention to specific areas in complementary testing components.

Understand that early glaucomatous defects may have variable depth and location (although they will be in the same area). The defect will deepen into a repeatable defect with time. The nasal and superior fields are more likely to show early glaucomatous defects.

Extensive RNFL loss (~30%) is necessary to produce a visual field defect.^{22,23} An individual (especially a patient with a large optic nerve) may have as much as one third of her or his RNFL deteriorate while still maintaining “green” normative levels on OCT analysis (this is often referred to as “green disease”).²⁴ A recent study reported the highest correlation between progression on OCT and visual field to occur at a 10µm RNFL loss on SD-OCT.²⁵ For many patients, advanced glaucomatous optic atrophy will result in a severely depressed RNFL that does not allow for proper detection of progression. For these patients in particular, visual field testing will best provide information about the progression of their disease.

Having an idea of the patient’s independent risk factors for glaucoma, aside from structural and functional testing, can allow clinicians to either raise or lower their threshold for diagnosis. If a patient is high risk given IOP and age, then a structure and function correlation is certainly not necessary to establish good certainty of a diagnosis. Conversely, you would

hold testing on a healthy 40-year-old patient to a high degree of specificity—the condition is much less commonly seen in that population and the diagnosis carries with it the potential of significant burden due to the long life expectancy. ■

Dr. Horton is a staff optometrist at the Cincinnati VA Medical Center. He is also an adjunct faculty member at Ohio State University College of Optometry.

- Heijl A. Automatic perimetry in glaucoma visual field screening. A Clinic Study. Albrecht Von Graefes Arch Klin. Exp Ophthalmol. 1976;200(1):21-37.
- Herbolzheimer W. Computer program controlled perimetry, its advantages and disadvantages. Klin Monbl Augenheilkd. 1986;189(4):270-7.
- Hebel R, Hollander H. Size and distribution of ganglion cells in the human retina. Anatomy and Embryology. 1983;168(1):125-136.
- Khouri J, Donahue S, Lavin P, Tsai J. Comparison of 24-2 and 30-2 perimetry in glaucomatous and nonglaucomatous optic neuropathies. J Neuroophthalmol. 1999;19(2):100-8.
- Heijl A, Bengtsson B, Chauhan B, et al. A comparison of visual field progression criteria of 3 major glaucoma trials in early manifest glaucoma trial patients. Ophthalmology. 2008;115(9):1557-65.
- Humphrey Field Analyzer User Manual. Dublin, CA: Carl Zeiss Meditec, Inc.; 2010.
- Hood D, Raza A, de Moraes C, et al. Glaucomatous damage of the macula. Prog Retin Eye Res. 2013; 32: 1-21. doi: 10.1016/j.preteyeres.2012.08.003. Epub 2012 Sep 17.
- Kutzko K, Brito C, Wall M. Effect of instructions on conventional automated perimetry. Invest Ophthalmol Vis Sci. 2000;41(7):2006-13.
- Bengtsson B, Heijl A. False-negative responses in glaucoma perimetry: indicators of patient performance or test reliability? Invest Ophthalmol Vis Sci. 2000;41(8):2201-4.
- Katz J, Sommer A, Gaasterland D, Anderson D. Comparison of analytical algorithms for detecting glaucomatous visual field loss. Arch Ophthalmol. 1991;109(12):1684-9.
- Asman P, Heijl A. Glaucoma Hemifield Test. Automated visual field evaluation. Arch Ophthalmol. 1992;110(6):812-9.
- Bengtsson B, Heijl A. A visual field index for calculation of glaucoma rate of progression. Am J Ophthalmol. 2008;145(2):343-53.
- European Glaucoma Society. Terminology and Guidelines for Glaucoma. 3rd ed. Savona: Editrice Dogma S.r.l.; 2008.
- Chauhan BC, Garway-Heath DF, Goñi FJ, et al. Practical recommendations for measuring rates of visual field change in glaucoma. The British Journal of Ophthalmology. 2008;92(4):569-73.
- Heijl A, Bengtsson B. The effect of perimetric experience in patients with glaucoma. Arch Ophthalmol. 1996;114(1):19-22.
- Trick G, Trick L, Kilo C. Visual field defects in patients with insulin-dependent and noninsulin-dependent diabetes. Ophthalmology. 1990;97(4):475-82.
- Leske M, Heijl A, Hyman L, et al. EMGT Group. Predictors of long-term progression in the early manifest glaucoma trial. Ophthalmology. 2007;114(11):1965-72.
- Leske M, Heijl A, Hyman L, Bengtsson B. Early Manifest Glaucoma Trial: design and baseline data. Ophthalmology. 1999;106(11):2144-53.
- Advanced Glaucoma Intervention Study 2 Visual field test scoring and reliability. Ophthalmology. 1994;101(8):1445-55.
- Musch D, Lichter P, Guire K, Standardi C. The Collaborative Initial Glaucoma Treatment Study: study design, methods, and baseline characteristics of enrolled patients. Ophthalmology. 1999;106(4):653-62.
- Rao H, Jonnadula G, Addepalli U, et al. Effect of cataract extraction on Visual Field Index in glaucoma. J Glaucoma. 2013;22(2):164-8.
- Kerrigan-Baumrind L, Quigley H, Pease M et al. Number of ganglion cells in glaucoma eyes compared with threshold visual field tests in the same persons. Invest Ophthalmol Vis Sci. 2000;41(3):741-8.
- Reis A, Vidal K, Kreuz A, et al. Nerve fiber layer in glaucomatous hemifield loss: a case-control study with time- and spectral-domain optical coherence tomography. Arq Bras Oftalmol. 2012;75(1):53-8.
- Jampel H, Vitale S, Ding Y, et al. Test-retest variability in structural and functional parameters of glaucoma damage in the glaucoma imaging longitudinal study. J Glaucoma. 2006;15(2):152-7.
- Kaushik S, Mulkutkar S, Pandav S, et al. Comparison of event-based analysis of glaucoma progression assessed subjectively on visual fields and retinal nerve fiber layer attenuation measured by optical coherence tomography. Int Ophthalmol. 2014 Dec 13. [Epub ahead of print]



Are you prepared for National Sunglasses Day?

The Vision Council is working to educate consumers on the negative health effects of UV rays, and steer them into your stores and offices to find the UV-protective eyewear that they need.

Increase your sales of sunglasses! Join us in spreading the message of UV protection.

thevisioncouncil.brandmuscle.net



Promotional items are now available online to help engage consumers and patients in discussions about sun-safe behaviors, inform them of the UV protective eyewear options available, and raise awareness of National Sunglasses Day, June 27, 2015.

Items can be downloaded as-is or customized with your branding, and can be printed directly or via print-on-demand services.



Beat These Modern Day Prescribing Challenges

Today's optometrists face difficult Rx decisions—from managing pregnant patients to deciding whether a generic can be substituted for a brand.

By Jane Cole, Contributing Editor

The maiden battle to gain prescription rights was first won by optometrists in West Virginia in 1976. Other states have all followed suit, but with these privileges often come challenges.

From insurance coverage strangleholds to deciding whether a patient with financial constraints will do as well on a more affordable generic (instead of the brand name you'd prefer), optometrists often face difficult prescribing decisions even before they pick up their Rx pad.

"The fact that many of the branded prescriptions we typically write are becoming more and more difficult to obtain for a patient because of medical insurance and pharmacy plans is a major problem," says optometrist Ben Gaddie of Louisville, Ky. "We're often advised to use a drug perhaps two or three generations old that just doesn't get the job done. And when

the patient fails on it, then we have to prescribe multiple drugs in that category or in multiple categories just to cover the original drug we prescribed. And when we can actually get a drug that is covered, sometimes it's financially out of reach for the patient."

This article looks at some typical and not-so-typical modern day prescribing challenges, and how to tackle them.

Challenge #1: Brand name or generic?

The idea that a generic drug is an adequate Plan B for a brand-name drug is still hotly debated.

The FDA requires that generic drug manufacturers demonstrate bioequivalence to the branded drug, so the generic must contain the same concentration of active ingredients as the branded drug's formulation. But other variations are permitted in the generic, such as inactive ingredients and preserva-

tives, which can alter characteristics of the medication and change the efficacy and side effects of the drug.

"As a general rule, the doctor should always prescribe the most appropriate medication for each patient's condition," says optometrist Jimmy Bartlett of Birmingham, Ala.

In practice, however, managed care, insurance and economic issues must be considered, and these often supersede the theoretical optimum, Dr. Bartlett adds.

"We always want to use what is in the best interest of each patient, and therapeutic care may entail using a somewhat less desirable generic substitute, particularly if the alternative is no therapeutic care at all," he says. "Unfortunately, in this age of managed care, we are forced to have these discussions with the patient as a matter of routine, whereas in years past these issues required only an occasional discussion in problematic situations."

Here are some considerations to keep in mind when deciding whether to prescribe a brand-name drug or a generic:

- **Generics are not necessarily cheaper.** In some cases, generic alternatives are not a lower-cost option. In fact, Freehold, NJ, optometrist William Potter says some generic prices are “through the ceiling.”

“To some degree, it’s an upside-down world,” Dr. Potter says.

Dr. Potter says he writes a fair amount of prescriptions for Tobradex ST (tobramycin 0.3%/dexamethasone 0.05%, Alcon) and gives his patients coupons to help offset the price, so the final cost of the brand-name medication is approximately \$40 to \$50.

“We wrote for Tobradex generically a few months ago,” Dr. Potter says. “The patient called from the pharmacy and said, ‘I can’t do this. This generic drug costs \$100.’ Now remember, this is a drug that’s been on the market for 25 years, and it’s been generic for three years. We called the pharmacist who told us, ‘If it wasn’t for the patient’s insurance, generic Tobradex would have cost \$250.’ And that’s for a little, ‘white bottle’ legacy drug. This is the kind of thing we’re up against.”

- **Assess the clinical need.** Looking at the patient’s clinical condition, when should an OD write for brand name only?

“Some brands trump generics, but not necessarily in every patient,” says Jill Autry, OD, RPh, of Houston.

For example, Dr. Autry generally prescribes brand-name Pred Forte (prednisolone acetate 1%, Allergan) rather than the generic equivalent. “It is fairly well established that the Pred Forte brand has better suspension qualities than the generic, especially with a more

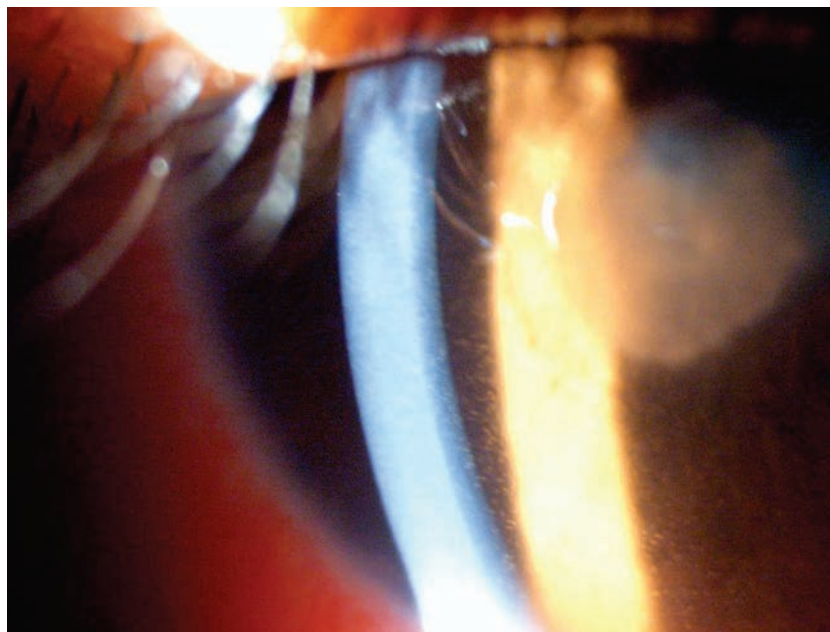


Photo: Paul M. Karpecki, OD

For a serious condition such as uveitis, many doctors will insist on a brand-name medication—no generic substitution allowed.

severe pathology,” she says. “In those cases, I write for branded Pred Forte, but I also tell the patient that I’m writing for brand name only and they should not allow the pharmacist to substitute.”

Dr. Autry reinforces to patients that the brand name should be visible on the side of the bottle, and she stresses they should not leave the pharmacy unless they have the right medication. “I don’t really get any pushback because of the way I present it to the patient, and pharmacies in the Houston area often carry the brand.”

When considering a brand name or generic, Dr. Gaddie first looks at the urgency or degree of the patient’s condition. If a patient has a very aggressive uveitis, for instance, he prescribes a brand-name steroid and not a generic.

“We know in the steroid class of medication, the gold standard has always been Pred Forte. There are many generic drug manufacturers, and we know from studies the

generics aren’t nearly as efficacious as the branded drug,” Dr. Gaddie says.

This has much to do with the particle size of the steroid molecule. Because the steroid is a suspension, the patient has to shake the bottle in order to get the concentration of the drug correct. But many patients just don’t shake medications, he adds.

Additionally, the size of the actual steroid particle can make an impact on the solubility of the drug and therefore affect how well it treats the inflammation, he adds. “If I’m treating someone with just a mild ocular surface problem, a generic steroid may be fine. But if I’m treating someone with a serious inflammatory condition, then I really feel like the branded drugs work better and are quicker and safer than the generic drugs.”

Similarly, if a patient has a low-risk bacterial conjunctivitis, Dr. Gaddie will consider a generic antibiotic because most of the bacterial



Photo: Aaron Bromner, OD

If the patient's insurance won't cover the medication you prescribe for this corneal ulcer, or if the drug is in short supply, have a second option in mind.

strains that cause conjunctivitis are fairly responsive to most generic topical antibiotics, he says.

Looking at glaucoma drugs, Xalatan (latanoprost, Pfizer) now has a generic equivalent that is produced by numerous manufacturers in various countries. Thus, a patient may not be given the same generic version when refilling the Rx. Dr. Gaddie says that some patients do well on the generic, but other times, when a patient obtains a different generic version of latanoprost, it doesn't work as well, he says.

"If I had a choice, I would want every patient to be on branded glaucoma drugs," Dr. Gaddie says. "If a generic doesn't work as well, then we have to add a second medication or maybe a third medication just to get the pressure down to where it needs to be than if we used a branded prostaglandin to start with. It costs the system more money, there are potentially more side effects for the patient, and what you have is a more complex treatment regimen because it takes two to three drugs to have the efficacy of one of the branded glaucoma prostaglandins."

• **Fight pharmacy substitution.**

Optometrist Melvin Friedman of Memphis, Tenn., requires his patients to sign an Rx waiver citing they have been told the difference between generic vs. brand-name drugs.

He also trains his staff to handle calls from pharmacists who want to substitute with a generic. For example, Dr. Friedman recently wrote a prescription for Besivance (besifloxacin, Bausch + Lomb) and the pharmacist called the practice to see if generic ciprofloxacin could be used as a substitute, but the staff refused. Dr. Friedman called the pharmacist directly and told him ciprofloxacin and Besivance are not equivalent. The pharmacist blamed the insurance company for the switch, he says.

"I told the pharmacist if he ever put my patient at risk again, I would report him and his staff to the pharmacy board," Dr. Friedman says. "Not enough physicians are willing to take a stand, and that's a problem."

• **Find a solution.** But what happens if the patient can't afford the brand-name drug you prescribe?

Prescribing With Hands Tied

What's it like to practice in a state that still has restrictive prescribing privileges? For optometrist Dawn Chivers, who practices in New York—one of the few states that allows ODs to treat patients only with topical or OTC meds—the current prescribing limitations impact her patients and her practice, especially when a patient is sitting in her chair on weekends or in the evening when most primary care physicians and ophthalmologists don't have office hours.

If a patient has an acute condition, needs an oral medication and it's a Saturday, chances are they'll have to go to the emergency room. This scenario can often lead to delayed treatment, increased cost to the patient and even incorrect treatment, she adds.

Dr. Chivers, who is the vice president of the New York State Optometric Association (NYSOA), recently sent a patient to the ER on a Friday afternoon for herpes keratitis with a note with the correct diagnosis and recommended course of treatment for oral acyclovir. The patient came back to Dr. Chivers' office first thing Monday morning with extreme discomfort and declining vision. The ER doctor had prescribed topical Vigamox (moxifloxacin, Alcon) instead of Dr. Chivers' recommendation.

The patient had a \$50 co-pay at the emergency room, waited four hours and was given a prescription for a drop that cost about \$100, all to have her condition worsen. "The patient now has a central scar on her cornea and reduced vision in that eye," Dr. Chivers adds.

Since 1998, New York ODs have been fighting to expand their oral prescribing privileges. On the upside, Dr. Chivers says the NYSOA has made significant strides over the past year in building support in the state legislature regarding oral prescriptive authority. "We believe 2015 could be the year we are finally able to see this common sense legislation enacted into law," she says.

COST OF GOODS SAVINGS CAN ONLY HELP YOU GROW SO MUCH

IN THE NEW ERA OF
POPULATION HEALTH MANAGEMENT,
WHAT'S YOUR PLAN
TO WIN:

- More Patients
- More Profits
- More Time
- All of the Above

Go To **VisionSourcePlan.com** and
We'll Give You Ours



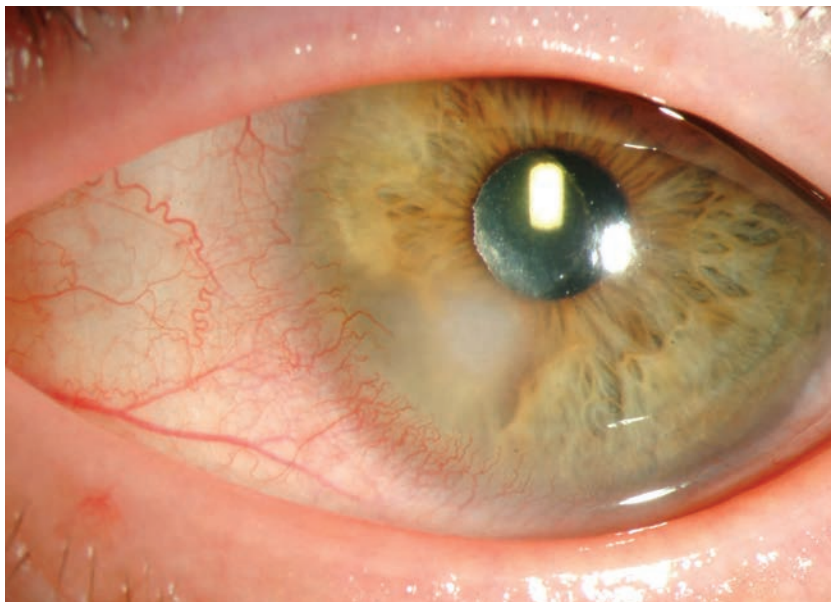


Photo: Christine Smith, OD

If a needed medication isn't available topically—such as fortified ceftazidime for gram-negative coverage against *Pseudomonas*—consider special ordering it from a compounding pharmacy.

Dr. Autry always tells the patient what she thinks is the best treatment option available.

“If it’s not doable, then certainly we need to talk and see if there is a combination or a different medication that will work,” she says. “I tell this to the patient on the front end because \$250 a month can be a big difference from \$50 a month. For some people \$50 is a lot, so you have to make a judgment call. In these cases, I’ll say, ‘There is another medication I can try, and we’ll see how it goes.’ And the patient will often say, ‘Well, \$50 I can do.’”

If the brand-name drug is the best treatment option, optometrists can often help lessen the burden of the cost by offering manufacturers’ coupons or advising about patient assistance programs they may be eligible for. “I can’t tell you how many times patients don’t know these options are available,” Dr. Friedman says. “If the patient can’t afford it, we can help.”

Challenge #2: How do you deal with state restrictions or limited supply?

While a few states don’t allow ODs to prescribe oral meds (see “*Prescribing With Hands Tied*,” page 72), optometrists from these states should already have established working relationships with primary care physicians or ophthalmologists who can assist with prescribing needs, Dr. Bartlett says. ODs who work in the same office with ophthalmologists should have established “standing orders” whereby prescriptions can be written, e-prescribed or called in to the pharmacy on behalf of the patient but under the order (and thus shared legal responsibility) of the MD.

“It is much more cumbersome to establish relationships with physicians in other offices, but this was routinely done in most states prior to the enabling of statutory privileges to allow independent prescribing by optometrists,” Dr. Bartlett says.

In the event of drug shortage or if a pharmacy doesn’t immediately have the drug you want, always have a work-around, the experts say. For example, if a certain fixed-combination antibiotic/steroid is not available, prescribe a combination using a desirable topical antibiotic along with a separate topical steroid, Dr. Bartlett says.

When AzaSite (azithromycin, Akorn) was in limited supply to treat blepharitis off-label, Dr. Autry instead prescribed oral doxycycline or oral azithromycin. She says these drugs have worked well as a substitute, and they are generally cheaper.

Also in the case of blepharitis, Dr. Potter has three alternate options ahead of time—erythromycin ointment, oral doxycycline or azithromycin—if his preferred drug is unavailable.

“Really, for any medicine you prescribe, you have to be ready to have a work-around,” says optometrist Jeffry Gerson of Kansas City, Kan. “Although you always have a best choice in mind, you also need to have a second choice—whether there’s a shortage and lack of availability, or because the patient has a financial issue, or if the patient lives in a rural area and the pharmacy doesn’t have what you want and the pharmacist can’t get the medication for a few days.”

For example, if a patient has a corneal ulcer, Dr. Gerson’s first option is Zymaxid (gatifloxacin 0.5%, Allergan). If the pharmacy doesn’t have that in stock, he’s ready with his second choices, Moxeza (moxifloxacin 0.5%, Alcon) or Besivance. If neither of those is available, Dr. Gerson would ask what is in stock in the same drug class, followed by considering a generic that would be a close equivalent.

NEW
Lombart CS-5 Package
Quality, Style & Value

Package includes:

- The Lombart CS-5 Chair & Stand 
- Topcon VT-10 Refractor
- Topcon SL-2G Slit Lamp
- Reichert LongLife Chart Projector 
with mount, slide & screen
- Upgrade to the Lombart CVS-PC for only \$1500
or to the CVSi21 for only \$2000 more
- Additional upgrades & configurations available.

\$13,995

Or lease for \$277/mo.
for 60 months*

*Lease rate subject to credit approval, 1st payment is due at signing with 59 remaining rental payments of \$265 and a \$1.00 purchase option. Taxes, freight and installation additional. Hand Instruments optional. Subject to change without notice.

1-800-566-2278

Call 1-800-Lombart

Or Your Local Lombart Representative

Corporate Office - 5358 Robin Hood Road, Norfolk, VA 23513-2430
757-853-8888 | FAX 757-855-1232 | 800-566-2278

www.lombartinstrument.com
lombart@lombartinstrument.com

Sales and Service Centers Coast to Coast

ATLANTA • BALTIMORE/WASHINGTON D.C. • BOSTON • BOYNTON BEACH/MIAMI • BRADENTON • CHARLOTTE • CHICAGO • CINCINNATI • DALLAS • DENVER • DETROIT • GREENSBORO • HOUSTON
JACKSON • KANSAS CITY • KNOXVILLE • LOS ANGELES • MILWAUKEE • MINNEAPOLIS • NEW JERSEY/NEW YORK/PENNSYLVANIA • NORFOLK • PORTLAND • SAN ANTONIO • SAN DIEGO • SAN FRANCISCO



The 'Non-Prescribing' and Rx Switch Challenge

What do you do when a patient assumes he or she needs a prescription and expects you to get out your Rx pad before leaving the office?

This *non-prescribing* challenge is a common one, Dr. Gerson says. "If someone comes in with a watery, red eye that looks viral, it's a challenge to satisfy the patient without an antibiotic fix."

In this case, explain that the condition is viral like the flu. And, in the same way an oral antibiotic is ineffective against the flu, an antibiotic eye drop won't help either, Dr. Gerson says.

Another Rx conundrum is when an ER or primary care doctor refers a patient to you, and the patient has already purchased a drug the referring doctor has prescribed that you don't think will work. "It's even more of a challenge if you want to prescribe them a brand drug, but the prescription they got from the emergency room cost \$4 and the drug you want them to buy instead is \$60," Dr. Gerson says.

If the patient has already started the other medication and has had no improvement by the time he or she comes to see you, the discussion is easier. However, it's more difficult if the patient has been on the other drug for only a day or two.

"It's a delicate situation," Dr. Gerson says. "You don't want to discredit the other physician who saw them. You need to tell the patient, 'I know the other doctor gave you a prescription for an antibiotic, but I would really like you to try this because I think it is going to work much better.' It's important to explain and be up front with the patient."

Challenge #3: How do you effectively manage patients who have allergies, are taking other medications for concomitant disease, or are nursing/pregnant?

Know the issues that may arise from the patient's medical history, such as:

- **Managing medication allergies.** A careful medication history almost always reveals the class of medications to which the patient may be allergic or sensitive, says Dr. Bartlett. It is usually possible to select an alternate drug class that can be safely prescribed, he adds.

Dr. Gaddie finds many of his glaucoma patients can become allergic to brimonidine. The drug, developed in the late 1990s, was originally formulated at 0.2%. "There was a 15% to 20% allergy rate for glaucoma patients taking this drug," Dr. Gaddie says. Allergan subsequently lowered the concentration but maintained the drug's efficacy, and the

allergy problem was for the most part mitigated, he says.

However, that original 0.2% concentration was used in the development of Combigan (brimonidine 0.2%/timolol 0.5%, Allergan) and Simbrinza (brinzolamide 1%/brimonidine 0.2%, Alcon).

"The problem is the development of this combo agent started before the newer concentration of brimonidine was available, so these two combination medicines contain the higher percentage formulation of brimonidine and its higher rate of allergy," Dr. Gaddie says. "So for patients who are allergic, it knocks out two or three glaucoma medications."

In such cases, Dr. Gaddie tries a different class of medications or even considers laser trabeculoplasty as an option.

- **Cautious concomitant prescribing.** Doctors often treat patients for ophthalmic conditions who are also on other concomitant medica-

tions for systemic diseases, he adds. For example, topical beta-blockers are staple glaucoma drugs, but the patient may also be taking oral beta-blockers for their blood pressure. Studies have found the concomitant use of topical and oral beta-blocker drugs reduces the efficacy of both.¹

Other patients have systemic medical conditions such as asthma, COPD, heart failure and arrhythmias, so the optometrist needs to be aware of the patient's health history and not put the patient at cardiac or pulmonary risk when using a beta-blocker or alpha agonists, for example, Dr. Gaddie says.

"You really need to stay on top of the literature to recognize the trade names of certain drugs," he says. "There are newer drugs that maybe we weren't exposed to when we were in optometry school, but it's still our responsibility to stay up-to-date and make sure there are no contraindications to any topical medications."

- **Prescribing for pregnant/nursing patients.** Another challenge you face is managing pregnant or nursing patients. "Prescribing during pregnancy is always a risk-benefit consideration," Dr. Bartlett says.

Although the general rule is to avoid medications during pregnancy, this is often not practical, especially for chronic conditions such as allergies, glaucoma or ocular hypertension, he adds. Doctors may be able to select a drug in the comparatively safer FDA pregnancy category B, Dr. Bartlett says. When drugs in the more risky category C (such as topical steroids) are needed, the patient can be instructed on the technique of nasolacrimal occlusion for one to two minutes after each drop instillation.

Dr. Gaddie is currently managing a pregnant 32-year-old patient diagnosed with glaucoma. The patient is

THE SHIELD INSTITUTE AND PURE VISION ARTS
CELEBRATE AN EXTRAORDINARY FAMILY

SOMMOZA PALOOZA

SAVE THE DATE

MAY 6, 2015

METROPOLITAN WEST
635 West 46 Street, NYC

.....
SPECIAL GUEST

AMY POEHLER
.....

CO-CHAIRS

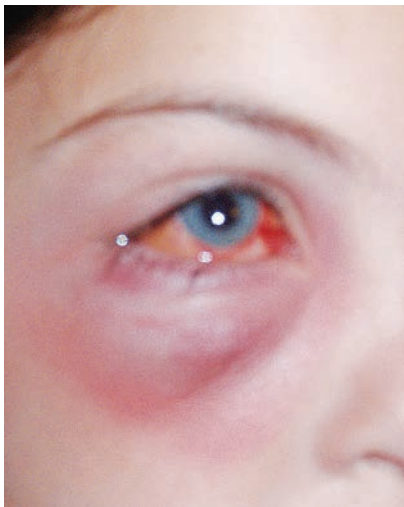Chris & Marianne Leone Cooper
Kevin Genis
Lori & John Reinsberg

To celebrate with us, go to

.....
www.shield.org
.....

Or call 212 243-7300

Photo: Leonard J. Press, OD



Prescribing a drug for children, such as amoxicillin for a case of preseptal cellulitis, requires specific dosing based on the child's age and weight.

three months pregnant and planning to breastfeed. “All glaucoma medications are really contraindicated during pregnancy and breastfeeding, so I have to consider whether this patient is going to have significant vision loss or potentially go blind in a year-and-a-half and weigh that against the risk to the developing baby if the mother takes the medication.”

In this case, Dr. Gaddie is working closely with the patient's obstetrician to determine the best treatment decision.

Challenge #4: When should you consider compounding medications for off-label use?

Compounding ophthalmic medications may be a necessity if you need a different strength, dosage, formulation or ingredients.

Dr. Autry frequently prescribes compounded drugs, most commonly to increase the concentration of medications to treat corneal ulcers.

She also turns to compounding if a medication isn't available

topically. For example, because vancomycin is not available in a topical form for *Staph.* coverage in severe corneal ulcers, compounding is an option. Another example is fortified, compounded ceftazidime for gram-negative coverage against *Pseudomonas*.

Additionally, if a patient with ocular surface disease needs more than Restasis (cyclosporine, Allergan), a compounding pharmacist can create cyclosporine ophthalmic ointment, autologous serum drops, tacrolimus solution or ointment, or albumin drops, she says.

Your pharmacist down the street is not necessarily going to be able to compound ocular preparations from scratch, so find a good compounding pharmacist ahead of time before a patient walks through the door, Dr. Autry suggests. (To find one, visit: www.pccarx.com/contact-us/find-a-compounder.)

One caveat about compounding medications is whether insurance will pay for it. “Once you get into these homebrews, insurance is going to be a question,” Dr. Potter says. “It's never going to be a question on a corneal ulcer, but if I say, ‘I think the Restasis should be twice as strong and I think the insurance should pay for it,’ the answer is often no.”

Challenge #5: How do you prescribe for pediatric patients?

“Many practitioners are uncomfortable with using systemic medications in children, but this is simply a matter of gaining clinical experience,” Dr. Bartlett says. Get started by prescribing broad-spectrum antibiotics for internal hordeolum and preseptal cellulitis in children, he suggests.

“Dosage calculations are typically straightforward, and most of these

medications have a wide range of safety,” he says.

Dr. Autry also suggests working up a pediatric dosing chart to have on-hand in the office. This resource could include the proper dosing of a typical drug you'd prescribe, such as amoxicillin or azithromycin, based on the child's age and weight.

She provides this example:

Body Weight (kg)	Volume of Augmentin ES-600 Powder for Oral Suspension providing 90mg/kg/day
8	3.0mL twice daily
12	4.5mL twice daily
16	6.0mL twice daily
20	7.5mL twice daily
24	9.0mL twice daily
28	10.5mL twice daily
32	12.0mL twice daily
36	13.5mL twice daily

One of the key challenges Dr. Gaddie sees: optometrists not gaining confidence in prescribing while being exposed to more ophthalmic diseases.

“Optometrists may have all the clinical knowledge in the world, but they still can be hesitant to prescribe,” he says. “I encourage doctors to start prescribing with low-risk conditions as a stepping stone to managing more complicated ocular diseases. Once optometrists start treating conditions such as allergy and dry eye, it gives them the confidence to tackle conditions such as glaucoma.” ■

1. Schuman JS. Effects of systemic beta-blocker therapy on the efficacy and safety of topical brimonidine and timolol. Brimonidine Study Groups 1 and 2. Ophthalmology. 2000;107:1171-7.



Exclusive Optical Shop Distribution

The New Non-Rx, 1st Step to Longer, Lusher, Fuller Looking Lashes and Brows

#1 Recommended Among Eyecare Professionals



2

Special LASH ADVANCE offers — Choose 1 or Both:

PROFESSIONAL COURTESY PRICING OFFER :

provides you and your staff an opportunity to try new Lash Advance at a very low price (just \$10 + S & H — 80% off the regular retail price). Visit www.mediniche.com/LAprofessionalpricing.html or call MediNiche at 1-888-325-2395 for more details.

TRY IT!

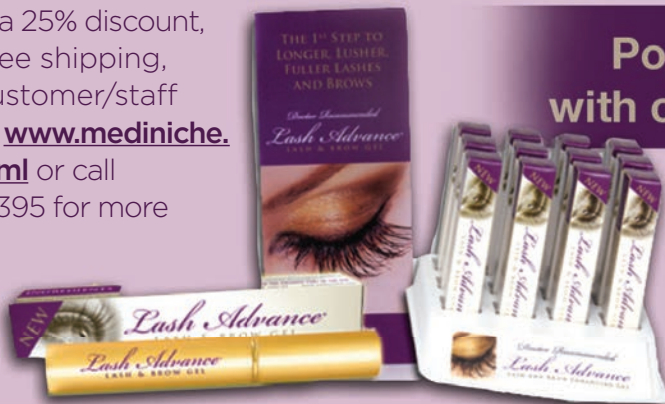Introduced exclusively for eyecare professionals, new LASH ADVANCE® is a non-prescription cosmeceutical developed in conjunction with a female optometrist as a sensible start to healthier lashes and brows. LASH ADVANCE is suggested for use prior to expensive prescription products.

- Natural; no drugs or known sensitizers.
- Contains PeptiPlex®, advanced peptide complex, supports the growth cycle of lashes and brows.
- Unlike other lash products, not sold at major drug and food retailers.
- Easy application; will not run, clear gel absorbs with no residue.
- Reasonably priced; affordable.

INTRODUCTORY PURCHASE OFFER :

buy a dozen (12) packages of Lash Advance at the regular wholesale price of \$24/package and receive a 25% discount, two (2) free packages, free shipping, a free counter display, customer/staff materials and more. Visit www.mediniche.com/lashadvanceoffer.html or call MediNiche at 1-888-325-2395 for more details.

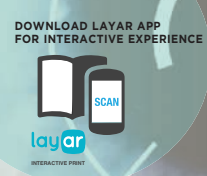BUY IT!



Positive RESULTS with one tube of use!

1





First 150 app downloads & completed forms will be entered into a drawing for FREE MEETING & REGISTRATION VALUED AT \$495

REGISTRATION OPEN!

REVIEW OF OPTOMETRY
EDUCATIONAL MEETINGS OF CLINICAL EXCELLENCE



CHARLESTON, SC
JUNE 12-14

FRANCIS MARION HOTEL
387 KING STREET CHARLESTON, SC 29403

CE COURSE TOPICS:

- New Developments in Cornea and Contact Lenses
- Innovations in Eye Care
- Management of Ocular Surface Disease
- Grand Rounds in Anterior Segment Disease
- Modern Management of Periocular Malignancies
- Ocular Urgencies and Emergencies
- Ocular Occlusive Disease
- HSV, HZO, EKC: Viral Eye Disease Alphabet Soup
- Beyond Glaucoma: A Primer for Retinal OCT Interpretation

NEW! Dry Eye and Glaucoma Workshops

FACULTY



Watch video with meeting chair, Paul Karpecki for more reasons to attend!

Paul Karpecki, OD
[Program Chair]



Doug Devries, OD



Andrew Gurwood, OD



Nathan Lighthizer, OD



Marc Myers, OD



Jack Schaeffer, OD



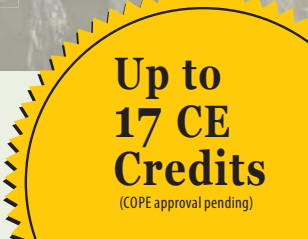
3 WAYS TO REGISTER

- ONLINE: WWW.REVOPTOM.COM/CHARLESTON2015
- EMAIL LOIS DIDOMENICO: REVIEWMEETINGS@JOBSON.COM
- PHONE: 866-658-1772

Stock Image: ©iStock.com/JobsonHealthcare



Administered By
Review of Optometry®



Up to
17 CE
Credits
(COPE approval pending)

FRANCIS MARION HOTEL

387 KING STREET-CHARLESTON, SC 29403

**Discounted Room Rate: Standard Room \$239/night
Deluxe Room \$269/night**

Discounted Room Rate Limited

**For reservations, call 877-756-2121 and identify yourself as a
participant of "Review of Optometry" for group rate.**

www.revoptom.com/Charleston2015

Stock Images: ©iStock.com/JobsonHealthcare

Registration Information

Name		NPI # (NPI numbers will only be used for HCP reporting purposes)	
Practice Affiliation			
Mailing Address		City	State Zip Code
Telephone	Fax	Email	

Name Badge Information (please print clearly)

My Name	My Guest	Additional Guests
---------	----------	-------------------

Payment Information

	Rate per person	No. in party	Subtotal
OD Registration - \$495 (includes 15 hours of CE, breakfasts, reception) <small>Call for daily and student rates.</small>	\$495	x _____	= \$ _____
Additional Guest(s) - \$45 (12 years and older, includes reception)	\$45	x _____	= \$ _____
Concurrent Optional Workshop Sessions (Saturday, June 13, 2:00pm - 4:00pm) <small>Select only one if interested in additional session and credits.</small>			
Dry Eye Workshop - \$70 (Earn 2 additional CE Credits)	\$70	x _____	= \$ _____
Glaucoma Workshop - \$70 (Earn 2 additional CE Credits)	\$70	x _____	= \$ _____
		TOTAL	= \$ _____

Check enclosed (make checks payable to *Review of Optometry*)

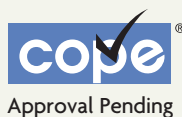Charge my: American Express Mastercard Visa

Credit Card Number	Exp Date
Cardholder (print name)	
Signature	

CONFERENCE CANCELLATION POLICY

- Full refund on registration fee until April 10, 2015
- 50% refund on registration fee until June 1, 2015
- No refund past June 1, 2015

For more information or to register,
contact Lois DiDomenico at 866-658-1772
or at ReviewMeetings@Jobson.com.



Administered By
Review of Optometry[®]





Navigating the Slippery Slope

Is it ever okay for a patient with corneal ectasia to wear a scleral contact lens with corneal touch? **Edited by Joseph P. Shovlin, OD**

Q I have recently started to fit scleral lenses. One of my first cases is an extremely steep, peripherally thinned grafted cornea that now has ectasia. Regardless of what diameter lens and design I've tried, I can't get the lens to clear the steep portion of the corneal ectasia. There's about 0.5mm touch below the center of the cornea. Are there any frank contraindications to allowing a patient who finds the lens comfortable to wear this lens?

A Generally, every attempt should be made to clear the apical region; however, depending on the patient, some corneal touch may be okay.

"The standard definition for a well-fit scleral lens is that it completely vaults over the corneal surface," says Greg DeNaeyer, OD, clinical director for Arena Eye Surgeons in Columbus, Ohio. "However, a complete vault is not always achieved for patients with severe corneal irregularity or for a scleral lens that significantly decenters."

Dr. DeNaeyer points out there

are studies that suggest flat-fitting contact lenses are associated with corneal incident scarring.¹ Other research suggests that oxidative stress, including mechanical trauma, contributes to keratoconus.² In the case of this particular patient, however, "the lens is probably acceptable as long as the patient is comfortable and the epithelium is healthy," he says. "Monitor the patient at least every six months and advise them to return immediately if they experience discomfort."

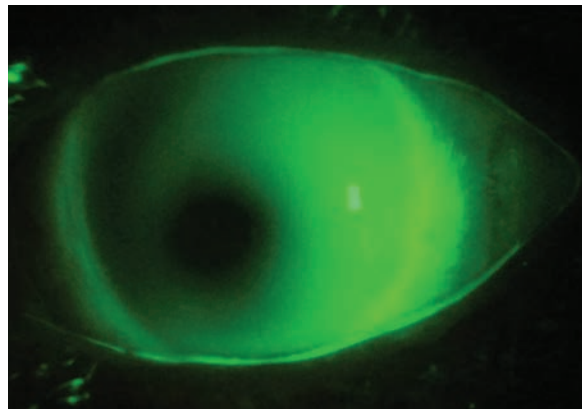
If the patient does in fact demonstrate epithelial disruption, Dr. DeNaeyer suggests piggybacking a scleral lens on a silicone hydrogel daily disposable. "The soft lens will act as a cushion to help protect the epithelium," he says. "Silicone hydrogel lenses maximize transmissibility, and daily disposables help to reduce care complexity and deposit-related complications."

Christine W. Sindt, OD, clinical associate professor at the University of Iowa, notes that this issue, referred to as a tilted graft or recurrence of keratoconus, is common. Typically seen in older grafts, it occurs when the host tissue thins and stretches, she adds.

In some cases, "these grafts need

to be fit with a reverse geometry design, meaning the secondary curve is steeper than the base curve," Dr. Sindt says. "You may need to steepen and lengthen the secondary curve more or increase the optic zone size if the lens still touches the graft."


Regardless, before even fitting the lens, Dr. Sindt recommends getting an endothelial cell count to make sure the cornea can support scleral lens wear. "It is common to experience corneal edema with endothelial cell counts under 800 cells/mm²," she says. If the cornea is deemed healthy enough, Dr. Sindt suggests fitting a full scleral lens, rather than a mini scleral lens, since full sclerals have larger landing zones, making it easier to manipulate the intermediate curves. ■



A flat-fitting scleral contact lens on a keratoconus patient.

Photo: Greg DeNaeyer, OD

Photo: Christine W. Sindt, OD



A theoretical lens on the eye with the secondary curve zone steeper than the base curve.

1. Barr JT, Wilson BS, Gordon MO, et al. Estimation of the incidence and factors predictive of corneal scarring in the Collaborative Longitudinal Evaluation of Keratoconus (CLEK) study. *Cornea*. 2006 Jan;25(1):16-25.
2. Kenney MC, Brown DJ. The cascade hypothesis of keratoconus. *Cont Lens Anterior Eye*. 2003 Sep;26(3):139-46.

1-DAY ACUVUE[®] MOIST BRAND CONTACT LENSES

Exceptional all-day
lens wear, every day,
for every eye

UNSURPASSED COMFORT

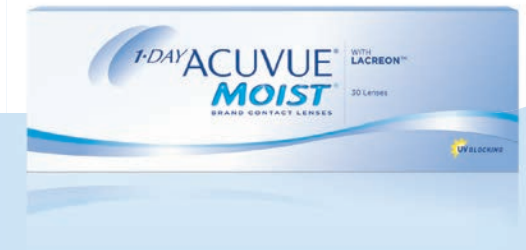Clinically unsurpassed in overall comfort and rated superior to Dailies[®] AquaComfort Plus[®] in beginning to end-of-day comfort

EXCELLENT SAFETY PROFILE^{1†}

Confirmed in an unprecedented, year-long, observational study of 570 wearers—no other lens has published this kind of safety data, including Dailies[®] AquaComfort Plus[®]

UV PROTECTION[‡]

Blocks approximately 97% UVB and 82% UVA rays.[‡] Dailies[®] AquaComfort Plus[®] does not meet ANSI/ISO standards for UV blocking



ANSI—American National Standards Institute; ISO—International Organization for Standardization.

ACUVUE[®] Brand Contact Lenses are indicated for vision correction. As with any contact lens, eye problems, including corneal ulcers, can develop. Some wearers may experience mild irritation, itching or discomfort. Lenses should not be prescribed if patients have any eye infection, or experience eye discomfort, excessive tearing, vision changes, redness or other eye problems. Consult the package insert for complete information. Complete information is also available from VISTAKON[®] Division of Johnson & Johnson Vision Care, Inc., by calling 1-800-843-2020 or by visiting acuvueprofessional.com.

[†]Helps protect against transmission of harmful UV radiation to the cornea and into the eye.

WARNING: UV-absorbing contact lenses are NOT substitutes for protective UV-absorbing eyewear such as UV-absorbing goggles or sunglasses, because they do not completely cover the eye and surrounding area. You should continue to use UV-absorbing eyewear as directed. **NOTE:** Long-term exposure to UV radiation is one of the risk factors associated with cataracts. Exposure is based on a number of factors such as environmental conditions (altitude, geography, cloud cover) and personal factors (extent and nature of outdoor activities). UV-blocking contact lenses help provide protection against harmful UV radiation. However, clinical studies have not been done to demonstrate that wearing UV-blocking contact lenses reduces the risk of developing cataracts or other eye disorders. Consult your eye care practitioner for more information.

[‡]UV-blocking percentages are based on an average across the wavelength spectrum.

¹This observational/surveillance registry relied on patient reports of symptomatic adverse events that led them to seek clinical care. These results should be considered in conjunction with other clinical results on the safety and efficacy of daily disposable etafilcon A contact lenses, which also generally show low rates of such events. Although no symptomatic infiltrative events were reported in this study, such events can occur with daily disposable lenses, including 1-DAY ACUVUE[®] MOIST, as noted in the product labeling.

1. Chalmers RL, Hickson-Curran SB, Keay LJ, Gleason W. Safety of hydrogel and silicone hydrogel daily disposables in a large post-market surveillance registry—the TEMPO registry. Presented at: ARVO 2014 Annual Meeting; May 4-8, 2014; Orlando, FL.

The third party trademarks used herein are trademarks of their respective owners.

ACUVUE[®], 1-DAY ACUVUE[®] MOIST, and VISTAKON[®] are trademarks of Johnson & Johnson Vision Care, Inc.

© Johnson & Johnson Vision Care, Inc. 2015 ACU-A44516-C March 2015



Get Your Priorities in Order

A patient presents with eye pain, elevated IOP, cataracts and vein occlusion. To get all your ducks in a row, which problem do you address first? **By James L. Fanelli, OD**

In February 2015, an 86-year-old white female presented on an urgent basis referred from a local urgent care center due to the possibility of zoster, with a note of “blisters” on the eyelid. She had been to the urgent care center the previous day with complaints of blurred vision in the right eye as well as periocular pain on the right side.

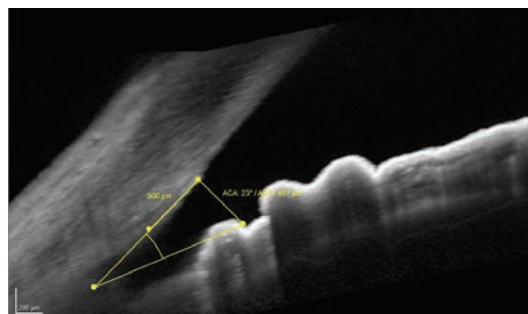
The patient was in no acute distress. She complained of intermittent pain and redness in and around the right eye for the past couple of weeks. She mentioned that she had received the shingles vaccine about two years earlier. She denied any photopsia.

The last time I saw her in my office was in 2012, and she was lost to follow up until this presentation. What initially brought her into the urgent care center was the discomfort in her right eye, which she described as a dull, non-stabbing pain that had worsened in the past three days.

Current medications included omeprazole QD, metoprolol QD and an unknown Rx sleep aid HS. She had no allergies to medications.

Diagnostic Data

Her visual acuity was hand motions at three feet in her right eye, 20/40 in her left, neither improving with pinhole. She displayed an equivocal afferent pupillary defect in the right eye, with both pupils sluggishly reacting to light. Extraocular motilities were full in all positions of gaze.



Gonioscopy could not confirm neovascularization in the angle, although OCT shows that it is open. The question remains whether a vascularization is present.

Slit lamp examination of the anterior segment was remarkable for several items. Of minimal significance was mild blepharitis and dermatochalasis in both eyes. The cornea in the right eye was mildly hazy, with moderate striate keratopathy and guttatae. The cornea of the left was clear, except for a symmetric presentation of the guttatae. Examination of the anterior chambers—specifically looking for cells and flare—was difficult in the right eye because of the corneal haze, so no cells were appreciated; the left anterior chamber was unremarkable. Iris details were also somewhat obscured in the right eye, and were normal in the left. The right eye also showed moderate episcleral injection.

Intraocular pressure measured 42mm Hg OD and 26mm Hg OS at 2:15 PM. Angles appeared to be open by Van Herick estimation.

Upon dilation, her crystalline lenses were characterized by 2+ anterior and posterior cortical cataracts, 3+ nuclear cataracts and mild

posterior subcapsular haze in both eyes. The posterior cortical cataract in the right eye was on the visual axis; that of the left eye was off the visual axis.

Her cup-to-disc ratios were 0.35 x 0.35 OD and 0.20 x 0.20 OS. Disc margins were distinct, although the right was somewhat hyperemic, and fine details were dif-

icult to ascertain due to the media opacities in that eye.

Both maculae were characterized by retinal pigment epithelial granulation and drusen, consistent with mild nonangiogenic age-related macular degeneration. But the significant finding in the right eye was a central retinal vein occlusion (CRVO) with what appeared to be resorbing intraretinal hemorrhages in all quadrants. The retinal vasculature was characterized by moderate arteriolar sclerotic retinopathy in both eyes, clearly discernable in the left eye. The retinal venules were moderately tortuous OD>OS. Peripheral retinal evaluation was unremarkable OU.

Upon gonioscopic examination, details of the angle anatomy in the right eye were obscured by the hazy cornea. In the left eye, the angle was normal and open. Anterior segment OCT imaging confirmed the presence of open angles in both eyes.

OCT evaluation of the macula was unremarkable in the left eye, but the right was consistent with

DOWNLOAD LAYAR APP
FOR INTERACTIVE EXPERIENCE



First 150 app downloads & completed forms will be entered into a drawing for FREE MEETING & REGISTRATION VALUED AT \$495

REGISTRATION OPEN!

REVIEW OF OPTOMETRY EDUCATIONAL MEETINGS OF CLINICAL EXCELLENCE



MAUI, HAWAII JULY 23-26

WAILEA BEACH MARRIOTT RESORT & SPA
3700 WAILEA ALANUI DRIVE, MAUI, HI 96753

**\$100 OFF BY
MAY 23RD**

CE COURSE TOPICS:

- New Advances in the Management of Lid Margin Disease
- Clinical Management of Ocular Surface Disease
- Technological Innovations in Eye Care
- Cancer and the Eye: Ocular Tumors, Malignancies and Neoplasms
- Expert Panel on Glaucoma Diagnosis and Treatment
- What the Primary Care Optometrist Should Never Miss
- Don't Let Swollen Optic Nerves Make You Nervous
- Conquering Therapeutic Dilemmas



Watch video with meeting chair, Paul Karpecki for more reasons to attend!

FACULTY



Paul Karpecki, OD
Program Chair



Ron Melton, OD



Brad Sutton, OD



Randall Thomas, OD

3 WAYS TO REGISTER

ONLINE: WWW.REVOPTOM.COM/MAUI2015

EMAIL LOIS DIDOMENICO: REVIEWMEETINGS@JOBSON.COM

PHONE: 866-658-1772

Administered By

Review of Optometry®



Up to
**14 CE
Credits**
(COPE approval pending)

20TH ANNUAL

OPHTHALMIC PRODUCT GUIDE



Innovative products to
enhance your practice

The **future**
is in your
hands. One
tap, many
possibilities.

Experience the digital edition on your handheld device.
Use your smart device to scan the code below or visit:



www.reviewofoptometry.com/supplements/

Download a QR scanner app. Launch app and hold your mobile device over
the code to view <http://www.reviewofoptometry.com/supplements>

REVIEW
OF OPTOMETRY

macular edema associated with the CRVO. Lastly, I took fundus photos to document the state of the CRVO at this initial presentation.

Diagnosis

The patient's right eye certainly has a CRVO of unknown duration, associated macular edema and significantly elevated IOP, OD>OS. The elevated IOP was very likely the source of her intermittent pain in the right eye. She had no evidence of an active outbreak of herpes zoster.

Management and Discussion

Elevated IOP can induce a CRVO. Also, one of the sequelae of long-standing CRVO is the development of neovascularization of the posterior and anterior segments, and subsequently, due to neovascularization of the iris and anterior chamber angle, neovascular glaucoma. Because the media were not clear, neovascularization of neither the posterior segment nor anterior segment were visible. The quandary at this visit pertained to the presence of two distinct clinical entities, each of which can induce the other.

So which came first? Did the VO induce neovascularization and subsequent neovascular glaucoma? Or, did elevated IOP (of non-neovascular origin) induce the VO?

In preparing a management plan for this patient, multiple problems need to be sorted out; so, it's the optometrist's duty to direct the patient's care with the help of other subspecialties. It's important to also include evaluations that may in fact help shed light on the ultimate cause of these two problems. Obviously, IOP needs to be lowered, not only to reduce the likelihood of neuroretinal rim damage, but also to mitigate the role that IOP may have had in inducing the VO. Given the

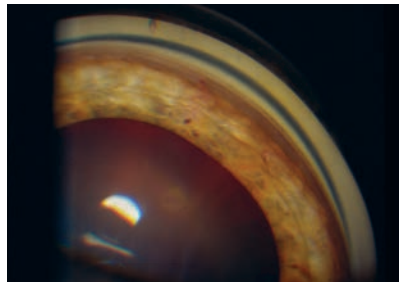


Photo: Greg Black, OD and Julie Tyler, OD

While difficult to see by gonioscopy, our patient had neovascularization of the angle, as seen in this similar patient.

macular edema associated with the VO, a retinal consult is in order, but not necessarily specifically for the reduction of the macular edema. On the contrary, a retinal consult was ordered primarily to obtain a fluorescein angiogram (FA) to help determine whether an occult retinal neovascularization was present. The presence of neovascularization of the retina can be a good indicator that the underlying etiology of the elevated IOP is, in fact, sequelae from the neovascularization due to retinal hypoxia.

At the completion of the initial visit, we scheduled the patient for a fluorescein angiogram, and I prescribed Lumigan (bimatoprost 0.01%, Allergan) HS OD as well as Alphagan P (brimonidine 0.1%, Allergan) BID OD.

When the patient returned for follow up, she was still in as much pain, but her IOP now measured 44mm Hg OD and 25mm Hg OS. Obviously, the IOP-lowering agents were having little effect, so the likelihood that her ocular hypertension was neovascular in origin seemed more plausible. The patient's FA was scheduled the following day, so I did not make any changes in her medications pending the results.

Sure enough, the FA revealed occult neovascularization of the retina, and possible anterior segment late fluorescein staining was noted.

In light of the FA findings, and given that the IOP-lowering agents had no effect, we can safely assume that we are dealing with neovascular glaucoma. To answer the original question—which came first?—the vein occlusion was probably the precipitating factor that led to the patient's current constellation of problems.

But there are a few other items that were put on the back burner until the clinical picture became clearer, and now need to be dealt with. One is her rather dense cataracts. The other is establishing the etiology of the VO in the first place as these are often associated with elevated blood pressure, elevated cholesterol and diabetes. This of course is managed by the patient's primary health care provider, and I've contacted him for consultation.

The retinal specialist, whose view in the right eye was likewise limited, felt that the cataract in that eye should be removed prior to performing panretinal photocoagulation (PRP). My opinion was that the patient would be best served if the cataract surgery was performed by a glaucoma surgeon comfortable in lens extractions.

Ultimately, after consultation with a glaucoma surgeon, the current plan is to proceed with lens extraction with IOL in the right eye, with the combination of Ahmed valve implantation at the same time (to facilitate quicker IOP reduction and better long-term IOP stability), followed shortly by PRP.

For now, the patient is continuing with follow-up visits here. In such cases, the optometrist must maintain visits with these patients during surgical interventions. After all, the patient will return to the OD for long-term care, so it's critical that the optometrist be involved with all aspects of the perioperative care. ■



Vision Loss With Wet AMD

A new outlook on an easily misinterpreted finding. **By Mark T. Dunbar, OD**

An 86-year-old Hispanic male with a history of wet age-related macular degeneration in both eyes presented with a chief complaint of painless, progressive vision loss in both eyes. He received multiple intravitreal Avastin injections, most recently three months prior in the left eye.

His past ocular history was significant for a recent intraocular lens exchange and anterior vitrectomy in the left eye.

His ocular medications included prednisolone acetate in the left eye four times a day, as well as Timolol twice a day in the left eye due to a history of ocular hypertension from steroid response. He admitted to very poor compliance with both of his topical ophthalmic medications.

His medical history was significant for multiple systemic pathologies, including benign prostatic hyperplasia, arthritis, hypertension, osteoporosis and a pacemaker. His systemic medication list was extensive, although none with known significant ocular side effects.

Upon examination, his distance BCVA was 20/60+ in the right eye and counting fingers at one foot in the left eye. His intraocular pressure was 18mm Hg in the right eye and 31mm Hg in the left eye. The slit lamp examination of his right eye revealed a posterior chamber intraocular lens, geographic atrophy without obvious fluid or heme in the macula, and old laser scars around a horseshoe tear in the peripheral retina. The slit lamp examination of his left eye revealed an anterior chamber intraocular

lens with a patent peripheral iridotomy and superior corneal sutures intact. The anterior chamber of his left eye revealed 1+ cell. Fundus findings of the left eye are represented in *figure 1*. Heidelberg SD-OCT images of his left eye are available for review in *figures 2 and 3*.

Take The Retina Quiz

- What is the likely cause for vision loss in this patient's left eye?
 - High IOP causing glaucomatous damage from chronic steroid response.
 - Inflammation from recent IOL exchange.
 - Fibrosis and geographic atrophy from age-related macular degeneration.
 - All of the above.
- What finding is represented by the arrows in *figure 2 and 3*?
 - Irvine-Gass macular edema.
 - Outer retinal tubulation.
 - Cystoid macular edema.
 - Subretinal fluid.
- What other diagnostic test would be helpful in determining the etiology of the findings in *figures 2 and 3*?
 - B-scan echography.
 - Fundus autofluorescence.
 - Fluorescein angiography.
 - Time-domain ocular coherence tomography.
- What is the appropriate treatment for the findings highlighted in

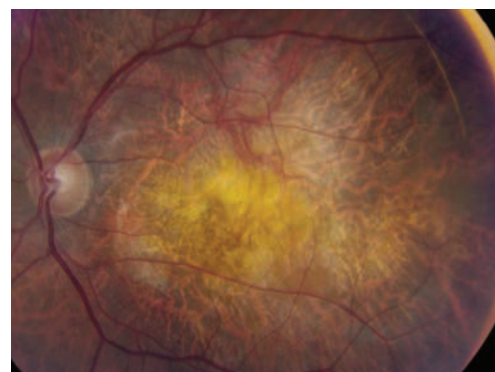


Fig. 1. This fundus photo shows the left eye of an 86-year-old presenting with painless, progressive vision loss. Can you identify the cause?

figures 2 and 3?

- Anti-VEGF injection.
- Focal laser photocoagulation.
- Combination of topical NSAID and steroid.
- Observation.

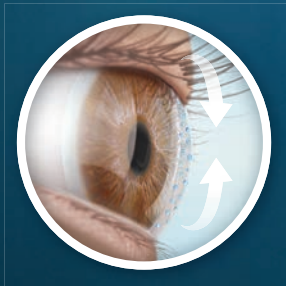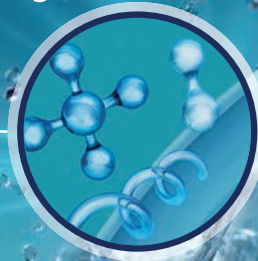
For answers, turn to page 106.

Diagnosis

The structures denoted with arrows on the SD-OCT (*figures 2 and 3*) represent outer retinal tubules. Thanks to the precision of SD-OCT, investigators in 2009 detected a “peculiar” change in the outer retina in their study of 63 patients with advanced retinal disease.¹ They described round or ovoid spaces with a hyporeflective center and hyperreflective border within the outer nuclear layer that simulated the appearance of cystoid macular edema or subretinal fluid on isolated scans. The study also made use of SD-OCT C-scans to allow en face visualization of the outer retina, which showed that these spaces

THIS IS WHY patients can[®] enjoy refreshing comfort with every blink—no matter what the day may bring.

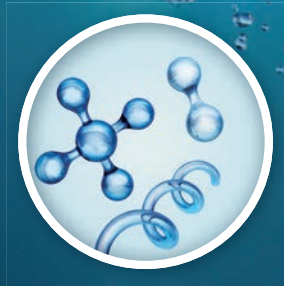
BLINK-ACTIVATED
MOISTURIZING AGENTS



BLINK-ACTIVATED MOISTURE

Moisture is released with every blink, which helps result in a stable tear film.

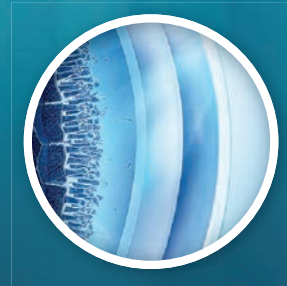
+



MOISTURIZING AGENTS

PVA, PEG and HPMC help deliver comfort from insertion to the end of the day.

=

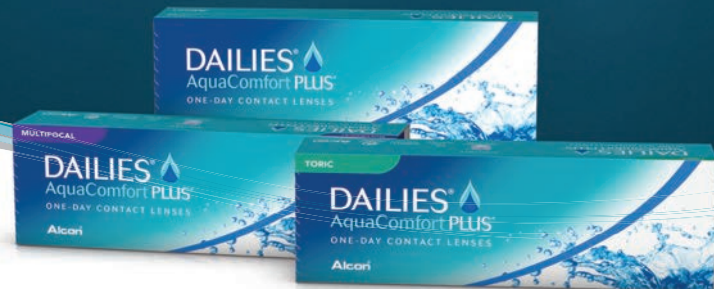

TEAR FILM STABILITY

Tear film stability helps support clear vision.

Offer your patients innovative technologies that provide outstanding all-day comfort.
Visit myalcon.com

PERFORMANCE DRIVEN BY SCIENCE™



*Based on DAILIES® AquaComfort Plus® sphere contact lenses.

Reference: 1. Wolffsohn J, Hunt O, Chowdhury A. Objective clinical performance of 'comfort-enhanced' daily disposable soft contact lenses. *Cont Lens Anterior Eye*. 2010;33(2):88-92.

See product instructions for complete wear, care, and safety information.

© 2014 Novartis 12/14 DAF15001JAD

Rx only

Alcon[®]
a Novartis company

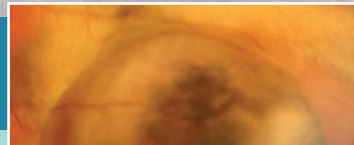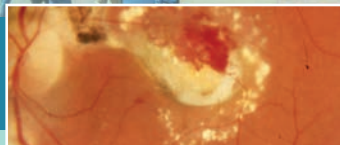
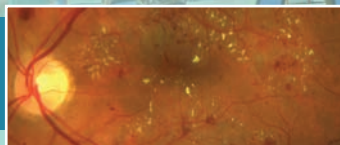
Up to
12 CE
Credits
(COPE approval pending)

REGISTRATION OPEN: DECEMBER 4-5, 2015 ANAHEIM, CA



THE OPTOMETRIC RETINA SOCIETY
AND *REVIEW OF OPTOMETRY* PRESENT:

RETINA UPDATE 2015



Featured Faculty



Hajir Dadgostar, MD, PhD



Brad Sutton, OD



Stuart Richer, OD



Blair Lonsberry, OD



Jeffrey Gerson, OD



Steve Ferrucci, OD

ORS Mission Statement

“The mission of the Optometric Retina Society (ORS) is to promote the advancement of vitreoretinal knowledge for clinicians, ophthalmic educators, residents, and students. The ORS is dedicated to posterior segment disease prevention, diagnosis, management and co-management.”

Sheraton Park Hotel

At the Anaheim Resort
1855 S. Harbor Boulevard
Anaheim, CA 92802

For hotel reservations call: 866-837-4197
Standard Room Rate: \$149/night

3 Ways to Register

Online:

www.revoptom.com/ORSRETUPDATE2015

Email Lois DiDomenico:

ReviewMeetings@Jobson.com

Phone:

877-451-6510

Course Topics

- Nutrition and Genetics in Retinal Wellness
- New Paradigms in Retinal Vascular Disease
- Vitreoretinal Grand Rounds
- Medical and Surgical Retina Update
- Macular Holes and Epiretinal Membranes
- What's New in Retinal Imaging

Stock Image: ©iStock.com/JobsonHealthcare

Administered By
Review of Optometry®



often continued linearly throughout the outer nuclear layer in branching tubular structures. They determined these changes represented “outer retinal tubulation.”

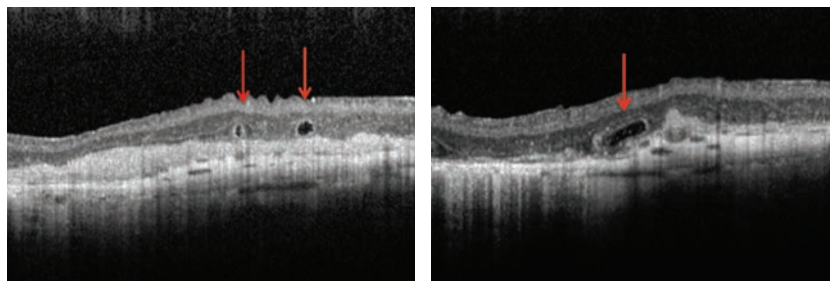
Outer retinal tubules are commonly seen in advanced AMD patients. In the CATT study, outer retinal tubules were present in 10.1% of AMD patients at 56 weeks after initial treatment with anti-VEGF and 17.4% at 104 weeks after treatment.²

In patients with geographic atrophy, outer retinal tubules may be present in 21% to 26% of patients.³ Outer retinal tubules can also be found in other advanced retinal diseases such as associated CNVM and subretinal fibrosis, pattern dystrophy, AZOOR, multifocal choroiditis, pseudoxanthoma elasticum, Stargardt disease, gyrate atrophy, choroideremia, chronic central serous chorioretinopathy, retinitis pigmentosa, cone dystrophy and Bietti crystalline dystrophy.

Interestingly, Christine Curcio and colleagues first described outer retinal tubules in a histopathologic study of AMD in 1996.⁴ They found that surviving photoreceptors in advanced AMD had an apparent reorganization into interconnecting tubes over areas of scarring. However, it was not until the advent and common clinical use of SD-OCT that a clearer understanding of outer retinal tubules was realized.

Initial studies postulated the process of outer retinal tubulation likely begins with sublethal injury of photoreceptors leading to invagination of the photoreceptor layer until opposing ends establish connections and form tubular structures.

Another study compared the appearance of outer retinal tubulation in patients with advanced AMD on SD-OCT to their actual histology in post-mortem



Figs. 2. and 3. Can you identify what the red arrows are pointing to in this patient's Heidelberg SD-OCT images?

retinal tubule specimens, allowing researchers to definitively correspond OCT appearance to anatomical composition.⁵ That team determined the defining features of outer retinal tubulation on histology as a circular or ovoid external limiting membrane border made by Müller cell processes with radially oriented photoreceptors in four phases of degeneration, ranging from both outer and inner segments to minimal or no photoreceptor segments.

Beyond the clinical appearance, they also determined the location of the outer retinal tubulation to be in the outer nuclear layer with a hyperreflective band in either a closed or open configuration, with often overlying dysmorphic or absent retinal pigment epithelium. These defining features help differentiate these lesions from cystoid macular edema, which is more commonly found in the outer plexiform and inner nuclear layer and does not have a hyperreflective border on SD-OCT.

It is easy to confuse the clinical appearance of outer retinal tubules and cystoid macular edema. It is clinically important to make the distinction because improper diagnosis may prompt physicians to unnecessarily treat with anti-VEGF injections or focal laser photocoagulation when no actual fluid is present. In fact, outer retinal tubules are

relatively refractory to treatment and the mere presence suggests the disease is end-stage and relatively quiescent and therefore this finding alone shouldn't prompt intervention.

Our patient was treated with an intravitreal Avastin injection in the left eye solely due to his preference for a treat-and-extends approach, as his fundus exam and SD-OCT did not reveal any intra-retinal fluid. He was also counseled extensively on the importance of compliance with his topical ocular medications, and was told to resume Prednisolone Acetate in the left eye with a weekly taper, and well as Timolol twice a day in the left eye.

The presence of outer retinal tubulation on the SD-OCT images of this patient's left eye likely indicates quiescent and end-stage age-related macular degeneration. ■

This case was written and provided by Savannah Brunt, OD, ocular disease resident at Bascom Palmer Eye Institute.

1. Zweifel S, Engelbert M, Laud K, et al. Outer retinal tubulation. *Arch Ophthalmol*. 2009;127(12):1596-602.
2. Lee J, Folgar F, Maguire M, et al. Outer retinal tubulation in comparison of age-related macular degeneration treatment trials (CATT). *Ophthalmology*. 2014;121:2423-31.
3. Hariri A, Nittala M, Sadda S, et al. Outer retinal tubulation as a predictor of the enlargement amount of geographic atrophy in age-related macular degeneration. *Ophthalmology*. 2015;122:407-13.
4. Curcio C, Medeiros N, Millican C. Photoreceptor loss in age-related macular degeneration. *Invest Ophthalmol Vis Sci*. 1996;37(7):1236-49.
5. Schaal K, Freund K, Litts K, et al. Outer retinal tubulation in advanced age-related macular degeneration: Optical Coherence Tomographic Findings Correspond to Histology. *Retina*. 2015 Jan. [Epub ahead of print]. Accessed: March 17, 2015.



Wearable Therapy for Dry Eye

Can this decidedly old-school measure hold its own in a more sophisticated era?

By Alan G. Kabat, OD and Joseph W. Sowka, OD

Ask the average person what an optometrist does, and chances are the response will include the term “glasses.” As sophisticated as our profession becomes, and as much as we continue to expand our scope of practice, spectacle frames and corrective lenses will always reside at the heart and soul of optometry.

Even today, eyewear plays a major role in how we make a living. According to a report published by the Academy for Eye Care Excellence, private practice optometrists derive about 44% of their gross income from the sale of prescription eyeglasses; this exceeds even the revenue earned from professional examination fees, which amounts to only 38%.¹

But can we gain something more with the use of these devices? Could this workhorse of optometric practice pull double-duty and help to address a growing health problem in eye care; namely, ocular surface disease? Recent developments suggest it may be possible.

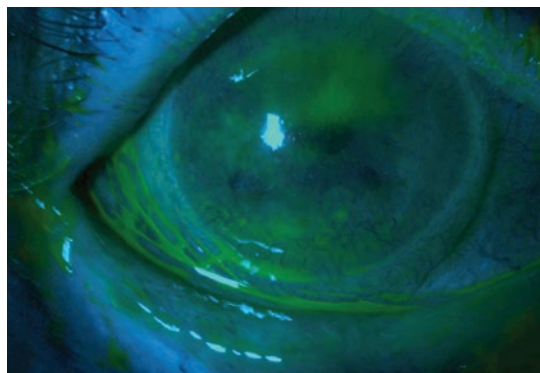
Moisture-Retention Eyewear

The concept of moisture-retention eyewear is not new. Publications detailing the design of moist-chamber spectacles date back nearly 70 years and explicit instruction on how to fabricate moisture chamber eyeglasses is available in the optometric literature from 20 years ago.^{2,3} Highly respected clinician-scientists have consistently touted the potential benefits of increased

periocular humidity for alleviating the signs and symptoms of dry eye.⁴⁻⁶ A meta-analysis of seven prior studies even found that the use of moisture chambers or goggles provided more effective corneal protection than lubricating drops in critical care patients with the potential for exposure keratopathy.⁷

Two of the more highly regarded and comprehensive publications in recent history regarding dry eye disease—the Delphi Panel report and the DEWS report—both recommend moisture-conserving spectacles as part of their treatment algorithms.^{8,9} However, this therapeutic modality seems to have always been perceived as a last resort treatment; in fact, the Delphi panel placed moisture goggles in the same category (DTS Level 4 Severity) with punctal cautery, oral cyclosporine therapy and surgical tarsorrhaphy.

Why would this be the case? We speculate that the cumbersome nature of these devices and poor cosmetics noted with the most common options, such as swim goggles or acrylic side-shields, has precluded their widespread acceptance by patients. Additionally, these devices possess no curative effect and do not address the root cause of ocular surface disorders.




Severe dry eye can result in corneal epithelial disruption. In one study, half the subjects ranked their symptoms as severe, but after one-month one month of using moisture retention eyewear, only 3% did so.

Such a statement, however, is akin to suggesting that, since artificial tear preparations are merely palliative in nature, they should be used only as a last resort. Of course, we all know that these topical agents actually represent first-line therapy for virtually all patients with dry eye complaints. Could moisture-retention devices be similarly placed in the front line?

Research

Despite the apparent stigma, recent research has evaluated a new generation of moisture-retention eyewear and the results are most compelling. In an independent study, researchers evaluated 11 patients with evaporative dry eye over three months.¹⁰

Inclusion criteria consisted of symptomatic dry eye complaints, a tear breakup time (TBUT) less than five seconds, Schirmer score greater than 8mm and corneal fluorescein



THE RICK BAY FOUNDATION

for Excellence in Eyecare Education

www.rickbayfoundation.org

Support the Education of Future Healthcare & Eyecare Professionals



About Rick

Rick Bay served as the publisher of *The Review* Group since 1991.

To those who worked for him, he was a leader whose essence was based in a fierce and boundless loyalty.




To those in the industry and the professions he served, he will be remembered for his unique array of skills and for his dedication to exceeding the expectations of his customers, making many of them fast friends.

Scholarships are awarded to advance the education of students in both **Optometry** and **Ophthalmology**, and are chosen by their school based on qualities that embody Rick's commitment to the profession, including integrity, compassion, partnership and dedication to the greater good.

Interested in being a partner with us?

Visit www.rickbayfoundation.org

(Contributions are tax-deductible in accordance with section 170 of the Internal Revenue Code.)



THE RICK BAY FOUNDATION
for Excellence in Eyecare Education

(The Rick Bay Foundation for Excellence in Eyecare Education is a nonprofit, tax-exempt organization under section 501(c)(3) of the Internal Revenue Code.)

CONTINUE YOUR EDUCATION WITH REVIEW

OUR FLAGSHIP TITLE, *REVIEW OF OPTOMETRY*, IS THE MARKET'S LEADING RESOURCE FOR ALL OF YOUR OPTOMETRY NEEDS.

Review of Optometry is your primary source for ground-breaking clinical information as well as timely news, market trend information and continuing education programs.

Review of Cornea & Contact Lenses serves as a valuable resource for all practitioners and features detailed articles focusing on various fitting methods, solutions and corneal cases. Also available is the *Review of Cornea & Contact Lenses "Annual Contact Lenses & Lens Care" Guide*, a yearly publication detailing the newest lenses and lens care products.

The *Review* Group's *Ophthalmic Product Guide* brings you the newest and most innovative products on the market. Published every February and July, the guide provides concise information about new literature, drugs and equipment designed to help your practice thrive.

The *Review* Group also offers valuable **continuing education** sessions in both print and online formats, allowing a convenient way for you to earn **CE credits**. In addition, *Review* also offers an impressive fleet of **free e-newsletters**, such as *Optometric Physician*, the *Optometric Retina Society* quarterly e-newsletter and the *Optometric Glaucoma Society E-Journal*, so you can keep up to date on breaking news and the latest research online.



The *Review* Group is dedicated to the constant growth and education of the profession. *Review* offers many different publications and services to help enhance your practice and patient care.



On top of these products, the *Review* Group also spearheads meetings and conferences, bringing together experts in the field and providing a forum for practitioners to earn CE credits and learn from others in the profession.

www.reviewofoptometry.com



Jobson Medical Information LLC
The *Review* Group

staining present in at least one quadrant of one eye.

Individuals with punctal plugs or punctal cautery and those wearing contact lenses were excluded from the study. All subjects were prescribed 7eye (formerly Panoptyx) moisture-retention eyewear and were able to select from a variety of sizes, styles and tints to allow for an optimal fit while maximizing both appearance and function. Subjects were instructed to use the eyewear in addition to their usual treatment and were evaluated before and after the three months for dry eye severity using the Symptom Assessment in Dry Eye (SANDE) index and corneal fluorescein staining.¹¹

At the conclusion of the study, subjects reported an overall acceptability rate of 72% (Likert score 6.48 out of 9) for the eyewear in terms of tolerability and symptom relief. The SANDE score diminished by an impressive 55% and both a clinically and statistically significant reduction in mean corneal staining was seen in all corneal quadrants. Frequency of artificial tear instillation also decreased from a mean of eight times per day to just four and a half times per day, or 44%. Tear break-up time was the only factor not impacted.

The authors concluded that moisture retention eyewear might be a valuable adjunct in the management of evaporative dry eye and that the low profile design of the 7eye product line provided better cosmetics, increasing compliance.

That study echoes an earlier, unpublished multicenter study that followed 110 patients suffering from transient or chronic dry eye symptoms for a month. Surveys conducted before and after this trial show a distinct improvement after wearing moisture-retaining



In a three-month study, patients using moisture retention glasses (7eye) were able to cut their dry eye severity by more than half.



In the past, swim goggles were used as moisture chambers for dry eye.

eyewear in nine specific complaints including burning, redness, itching, diminished vision, light sensitivity, discomfort in air conditioning, grittiness, dryness and excessive tearing, with a mean overall reduction of 57%. Initially, half of the subjects ranked their symptoms as severe, but at the one-month visit only 3% did so.

Thirty percent of subjects reported their overall symptoms were eliminated when wearing the moisture-retaining eyewear.¹²

An Old-School Approach

The most recent studies of dry eye in the United States suggest a prevalence rate of nearly 15%.¹³ Given the disease's pervasive nature—growing ever more common with the aging of our population—it seems inappropriate that a noninvasive, potentially beneficial treatment option, such as moisture-

retention eyewear, is relegated to such an obscure and limited status. If the studies are correct, this treatment modality can alleviate symptomatic irritation in dry eye patients by 50% or more.

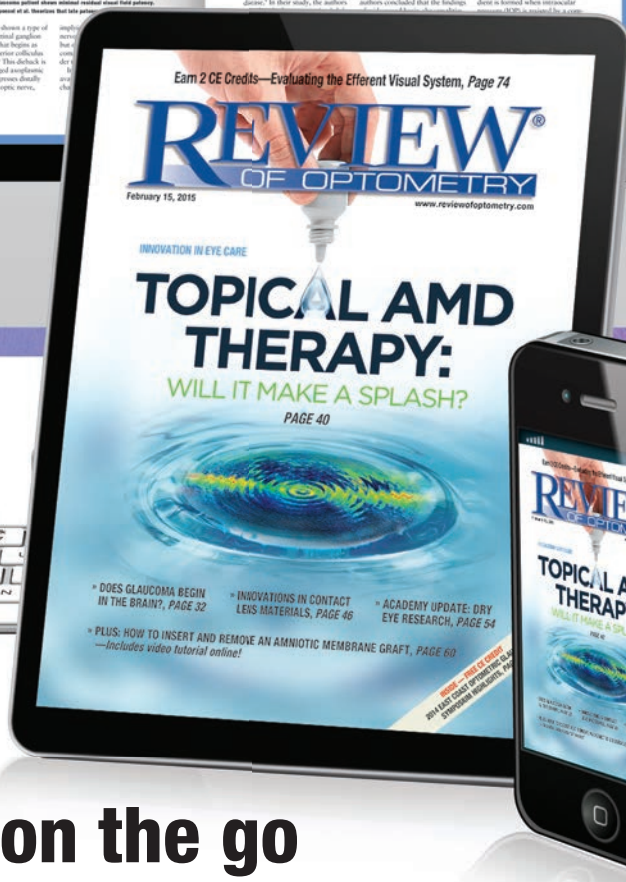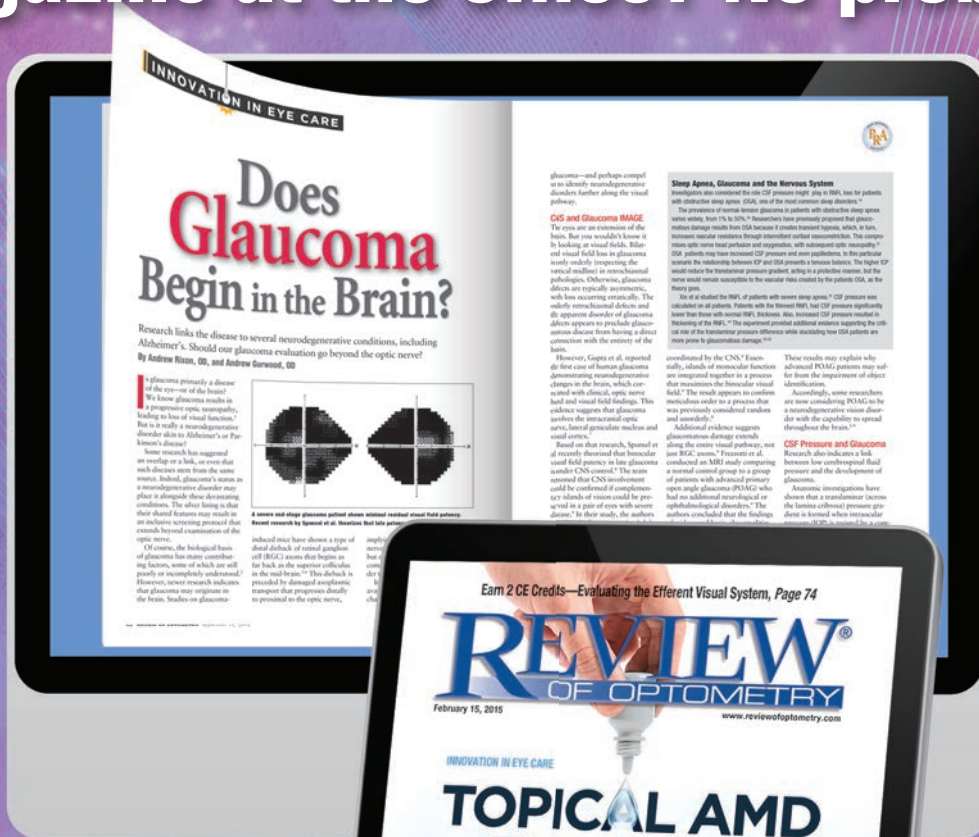Given our profession's historical expertise with the fabrication, handling and dispensing of corrective eyewear, this approach to dry eye seems like a natural fit.

Perhaps the time has come to reexamine the benefits of moisture-retention eyewear for the adjunctive therapy of dry eye disease. Sometimes, an old-school approach is the best way to tackle a new-age problem. ■

Dr. Kabat is Clinical Care Consultant at TearWell Advanced Dry Eye Treatment Center in Memphis, Tenn. Neither he nor Dr. Sowka has any direct financial interest in the products mentioned in this article.

1. Profile of Independent Practice Optometry. Academy for Eye Care Excellence. Accessed: February 13, 2015. Available at: www.mvalcon.com/docs/Profile_Private_Practice_Optomtry.pdf
2. Hallett JW, Pittler S. Individually made acrylic moisture-chamber spectacles and pinhole glasses. *Am J Ophthalmol.* 1946 Jun;29:725-8.
3. Hart DE, Simko M, Harris E. How to produce moisture chamber eyeglasses for the dry eye patient. *J Am Optom Assoc.* 1994 Jul;65(7):517-22.
4. Tsubota K. The effect of wearing spectacles on the humidity of the eye. *Am J Ophthalmol.* 1989 Jul 15;108(1):92-3.
5. Korb DR, Greiner JV, Glonek T, et al. Effect of periorcular humidity on the tear film lipid layer. *Cornea.* 1996 Mar;15(2):129-34.
6. Korb DR, Blackie CA. Using goggles to increase periorcular humidity and reduce dry eye symptoms. *Eye Contact Lens.* 2013 Jul;39(4):273-6.
7. Zhou Y, Liu J, Cui Y, et al. Moisture chamber versus lubrication for corneal protection in critically ill patients: a meta-analysis. *Cornea.* 2014 Nov;33(11):1179-85.
8. Dysfunctional tear syndrome study group. Dysfunctional tear syndrome: a Delphi approach to treatment recommendations. *Cornea.* 2006 Sep;25(8):900-7.
9. Management and therapy of dry eye disease: report of the Management and Therapy Subcommittee of the International Dry Eye WorkShop (2007). *Ocul Surf.* 2007 Apr;5(2):163-78.
10. Waduthantri S, Tan CH, Fong YW, Tong L. Specialized Moisture Retention Eyewear for Evaporative Dry Eye. *Curr Eye Res.* 2014 Jun 30:1-6. [Epub ahead of print]
11. Schaumberg DA, Gulati A, Mathers WD, et al. Development and validation of a short global dry eye symptom index. *Ocul Surf.* 2007 Jan;5(1):50-7.
12. Research Digest: Panoptyx Eye Wear Shown to Relieve Dry-Eye Symptoms. *Ophthalmology Management*, May 1, 2004. Accessed: February 13, 2015. Available at: www.opthalmologymanagement.com/articleviewer.aspx?articleid=86091
13. Paulsen AJ, Cruickshanks KJ, Fischer ME, et al. Dry eye in the beaver dam offspring study: prevalence, risk factors, and health-related quality of life. *Am J Ophthalmol.* 2014 Apr;157(4):799-806.

Left your *Review of Optometry* magazine at the office? No problem!



Read *Review* on the go from any mobile device!

Just simply go to www.reviewofoptometry.com and click on the digimag link to get your current issue.



By Derek N. Cunningham, OD, and Walter O. Whitley, OD, MBA

Caution! Traumatic Cataracts Ahead

What to expect when you're expecting the unexpected during cataract surgery.

As well-defined, predictable and refined as routine cataract surgery has become, there is one situation in which the surgeon must always plan on surprises and have multiple alternate techniques at the ready: traumatic cataracts. These pose a unique set of problems for surgeons, and even the most thorough slit lamp exam can't fully prepare surgeons for what they'll experience in the operating room.

Hope for the Best, Prepare for the Worst

Any amount of injury that causes a traumatic cataract to form will also likely affect collateral tissues. If the eye is stable, the most common associated structural defects would include: iris synechiae, angle recession, iridodialysis, weakened or lost zonular support and lens capsule defects. Careful slit lamp examination will allow you to see much, but not all, of the extent of these defects.

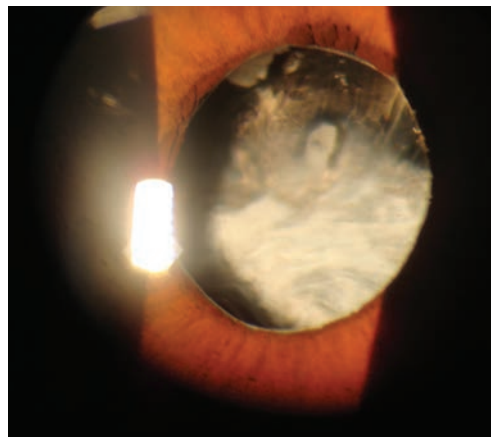
During pre-op evaluation, the surgeon will pay extra attention to any areas that show angle recession or iridodialysis, as this will suggest localized lens zonule defects. The one thing we can't always see well, or ever confidently guess, is the amount and extent of zonular compromise or posterior capsule integrity. For this reason, any traumatic cataract is approached with a worst-case scenario mindset, and alternative options are planned based on intraoperative findings.

The surgeon will not know what they are truly dealing with until entering the eye and assessing the structural support of the lens. In almost all circumstances, the surgeon will attempt an extracapsular cataract extraction (leaving the capsular bag intact) and place a new lens in the bag, if possible. When zonules are compromised or missing, the surgeon can use capsular tension rings to maintain the size and circumference of the capsule to allow insertion and centration of a new lens.

Intraoperative Concerns

A significant concern with these cases is the risk of intraoperative vitreous prolapse. When the eye is fully dilated and the lens capsule is manipulated, vitreous may escape anteriorly around the capsule or newly placed IOL, leading to further complications or the need for a vitrectomy. Dispersive viscoelastics, often used to maintain anterior chamber volume, can both keep the capsular bag inflated and tamponade any incipient vitreous prolapse.

If the capsular bag is not suitable for lens insertion, alternative options include: placing the lens in the sulcus (in front of the capsular bag but behind the iris) if there is enough anatomy remaining; suturing a posterior chamber lens to the iris; placing an anterior chamber lens; or leaving the patient aphakic.

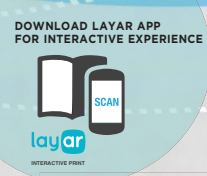

Surgeons must approach traumatic cataract cases differently than a typical senile cataract—with numerous contingency plans ready, given the potential for intraoperative surprises.

Each of these scenarios requires unique lenses, apart from aphakics, that would have to be on hand and preselected based on the patient's biometry data.

Knowing is Half the Battle

Because of the unknown variables and extensive contingency planning necessary, it is critical to identify these patients before they enter the operating room. A thorough history of all cataract patients should be performed—including always asking about a history of eye trauma. This is especially important for patients of routine cataract age where natural senile lens changes can be hastily assumed. If any history of eye trauma is reported, it should be relayed to the surgeon as early as possible to allow for adequate preparation. ■



First 150 app downloads and completed forms will be entered into a drawing for FREE MEETING AND REGISTRATION VALUED AT \$495




REVIEW OF OPTOMETRY

EDUCATIONAL MEETINGS OF CLINICAL EXCELLENCE




PAUL KARPECKI, OD
PROGRAM CHAIR

REGISTRATION OPEN



CHARLESTON, SC
JUNE 12-14




MAUI, HI*
JULY 23-26



PHILADELPHIA, PA
NOVEMBER 6-8

Includes hands-on workshops



Up to 17 CE Credits
(COPE approval pending)

For more information visit www.reviewofoptometry.com

Administered By
Review of Optometry®



Stock Images: ©iStock.com/JobsonHealthcare

* Workshops not available - See website for information about snorkeling catamaran activity

Product Review

Practice Management

Website Personalization Service

Let patients hear your unique take on what makes your practice special—in your own voice. A new service offered by Clompus Consulting analyzes the strategic advantages of your office and creates a personalized script for you. Record a message at home or at the office using headphones provided by the company and the service will edit it into a broadcast-quality audio file that you can embed on your website.

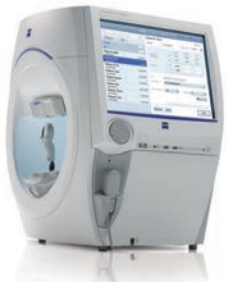Digital audio services offer a better way to make an emotional connection with patients on your website, according to the company. You can also change the audio message several times a year to highlight new services and products.

Visit www.clompusconsulting.com.

Diagnostic Equipment

New Field Analyzer

A new visual field analyzer is designed to improve the speed and accuracy of perimetry tests, according to manufacturer Zeiss. The Humphrey Field Analyzer 3 (HFA3) automates trial lens correction based on the patient's refractive data, to reduce setup time. It also captures images of eye position at each stimulus point, allowing you to check for false negatives due to ptosis or misalignment. Zeiss also says the gaze tracker on the HFA3 provides faster initialization and works on a wider spectrum of patients compared



with earlier HFA models, and that the touch screen interface for technicians is faster and more intuitive.

HFA3 test results are equal to and interchangeable with results from prior generations of the HFA, according to the manufacturer.

Visit www.meditec.zeiss.com.

Contact Lenses

Expanded Power Range for Multifocal CLs

Now, more presbyopes who previously could not wear contact lenses have a new option to consider. Biotrue OneDay for Presbyopia (nesofilcon A) contact lenses are now available in an expanded power range for those with low-add needs, according to Bausch + Lomb.

Launched last summer with low-add correction through the powers of +3.00D to -6.00D, the range has been expanded to +6.00D to -9.00D (0.25D steps), increasing multifocal options for more patients.

Additional high-add powers through the same range are expected later this year, B+L says.

Visit www.bausch.com.

Plus Powers for Air Optix Colors

Hyperopic patients interested in color-enhancing contact lenses now can consider Air Optix Colors from Alcon, as the company has just added plus powers to its monthly replacement SiHy product line. The full power range is now +6.00D to -6.00D in quarter-diopter steps and -6.50D to -8.00D in half-diopter steps. All nine colors are available at all powers, Alcon says.

Visit www.alcon.com.

Simplifying Lens Care

A new contact lens case can help make the lens cleaning and disinfecting process simpler for patients by color-coding the storage chambers, according to manufacturer Alcon. The new case that comes with Clear Care solution has blue and white lens baskets to help patients more easily differentiate between left and right lenses before and after cleaning. Also, lens baskets in the new case now have tabs to enable easier opening.

Alcon says Clear Care patients are more compliant with lens care regimens, and is encouraging doctors to see the product as a “problem preventer” rather than a problem solver and offer it more routinely to patients.

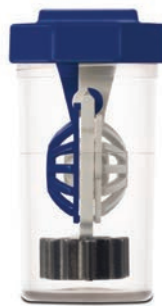Visit www.alcon.com.

Dry Eye Care

Preservative-Free Eye Drops

Patients who experience dry eye symptoms and routinely need an artificial tear can now use a preservative-free product in a multi-use bottle.

Oasis Tears PF Preservative-Free lubricant eye drops are packaged in a 10mL bottle that prevents contamination with a specially designed closing tip, valve and air venting system that prevents microbial entry into the bottle, according to Oasis Medical. Replacing the usual unit-dose vials, this system keeps the drops sterile for up to 90 days after opening, the company says. ■



Meetings + Conferences

April 2015

■ **17-19.** *NOA Spring Conference-CE Event.* Embassy Suites, Lincoln, NE. Hosted by: Nebraska Optometric Association. To register, email ajohnson@assocoffice.net.

■ **17-22.** *ASCRS-ASOA Symposium and Congress 2015.* San Diego Convention Center, San Diego, CA. Hosted by: ASCRS/ASOA. To register, go to: <http://annualmeeting.ascrs.org>.

■ **18-19.** *Miami Nice Educational Symposium 2015.* Westin Colonnade, Coral Gables, FL. Hosted by: Miami-Dade Optometric Physicians Association. CE Hours: 17 COPE-approved, 12 transcript quality. Key Faculty: Ken Lebow, John McGreal, Carl Spear, Al Morier, John McClane, Albert Woods. To register, go to www.miamieyes.org or email Steve Morris at mdopa.board@gmail.com.

■ **22-26.** *13th Annual Educational Conference.* Hilton Embassy Suites at Kingston Plantation, Myrtle Beach, SC. Hosted by: American Academy of Optometry New Jersey Chapter. CE Hours: 16. Key Faculty: Mark Friedberg, Alan Kabat. To register, call Dennis Lyons at (732) 920-0110 or email dhl2020@aol.com.

■ **23-25.** *Mountain West Council of Optometrists (MWCO) Annual Congress.* Bally's, Las Vegas, NV. Hosted by: Mountain West Council of Optometrists. CE Hours: 24. To register, go to www.mwco.org or call (888) 376-6926.

■ **23-26.** *2015 Annual Spring Convention.* Marriott Hotel & Little Rock Convention Center, Little Rock, AR. Hosted by: Arkansas Optometric Association. To register, email Vicki Farmer at vicki@arkansasoptometric.org.

■ **29-May 7.** *Annual Educational Conference and Exposition.* Red Lion Colonial Hotel, Helena, MT. Hosted by: Montana Optometric Association. To register, call (406) 443-1160 or email sweingartner@rmsmanagement.com.

■ **30-May 1.** *Spring 2015 Convention.* Pierre Ramkota, Pierre, SD. Hosted by: South Dakota Optometric Society. To register, email Deb Mortenson at deb.mortenson@pie.midco.net or go to southdakota.aoa.org.

May 2015

■ **2-3.** *8th Annual Evidence Based Care in Optometry Conference.* Turf Valley Conference Center and Resort, Ellicott City, MD. Hosted by: Maryland Optometric Association & Johns Hopkins-Wilmer Eye Institute. To register, email Annie Phan at aphan@marylandoptometry.org.

■ **3.** *OptoWest Regional Conference.* Anaheim Marriott Suites, Anaheim, CA. Hosted by: California Optometric Association. CE Hours: 6. Key Faculty: Steven Ferrucci, Bruce Onofrey, Mary Schmidt. To register, go to www.optowest.com, call Sarah Harbin at (916) 266-5022 or email sharbin@coavision.org.

■ **3.** *NECO Sunday Seminar Series CE.* New England College of Optometry, Boston, MA. Hosted by: New England College of

Optometry Alumni Association. CE Hours: 5. Key Faculty: Mark Dunbar, Michael Springer. To register, go to www.neco.edu/academics/continuing-education/sunday-series, call Margery Warren at (617) 587-5687 or email ce@neco.edu.

■ **3-5.** *CE in Italy.* Hotel Silla, Florence, Italy. Hosted by: James Fanelli. CE Hours: 12. Key Faculty: James Fanelli, Carlo Pelino. To register, email James Fanelli at jamesfanelli@CEinItaly.com or go to www.CEinItaly.com.

■ **3-7.** *ARVO 2015.* Colorado Convention Center, Denver. Hosted by: The Association for Research in Vision and Ophthalmology. To register, go to www.arvo.org/AnnualMeeting.

■ **7-9.** *CE in Italy.* Palazzo Al Valabro, Rome, Italy. Hosted by James Fanelli. CE Hours: 12. Key Faculty: James Fanelli, Carlo Pelino, Joseph Pizzimenti. To register, email James Fanelli at jamesfanelli@CEinItaly.com or go to www.CEinItaly.com.

■ **15-17.** *Arizona Optometric Association 2015 Spring Congress.* Hilton Tucson El Conquistador Golf & Tennis Resort, Tucson, AZ. Hosted by: Arizona Optometric Association. To register, go to: <http://arizona.aoa.org>.

June 2015

■ **5-7.** *June "Summer" Conference.* Harborside Hotel & Marina, Bar Harbor, ME. Hosted by: Maine Optometric Association. To register, call (207) 288-5033 or toll-free (800) 328-5033.

■ **12-14.** *2015 Annual Meeting.* Myrtle Beach, SC. Hosted by: North Carolina State Optometric Society. To register, email Adrienne Drollette at adrienne@nceyes.org.

■ **19-21.** *2015 VOA Annual Conference.* Hilton, McLean, VA. Hosted by: Virginia Optometric Association. To register, call Bo Keeney at (804) 643-0309.

■ **24-28.** *Optometry's Meeting 2015.* Washington State Convention Center, Seattle, WA. Hosted by: American Optometric Association and American Optometric Student Association. To register, go to <http://optometrysmeeeting.org>.

■ **26-July 5.** *A Comprehensive Update on Contemporary Eye Care.* Northern European Capitals Cruise, departs Copenhagen, Denmark. Hosted by: Dr. Travel Seminars/The New Jersey Society of Optometric Physicians. Key Faculty: Randall Thomas. CE Hours: 12. To register, email Robert Pascal at info@DrTravel.com or visit DrTravel.com.

July 2015

■ **4-11.** *Tropical CE Puerto Rico.* El Conquistador—Waldorf Astoria, Puerto Rico. Hosted by: Tropical CE. Key Faculty: Jimmy Bartlett, Kim Reed. CE Hours: 20. To register, call Stuart Autry at (281) 808-5763, email sautry@tropicalce.com or go to www.tropicalce.com.

■ **10-12.** *21st Conference on Clinical Vision Care.* Southern

Advertisers Index

College of Optometry, Memphis, TN. Hosted by: OEP Foundation. CE Hours: 17. To register, email Theresa Krejci at theresakrejciOEP@verizon.net or go to www.oepf.org.

■ **16-19.** *2015 Victoria Conference.* Inn at Laurel Point, Victoria, British Columbia, Canada. Hosted by: Pacific University. Key Faculty: Terry Burris, Danica Marelli, Curtis Baxstrom, Tad Buckingham. CE Hours: 20. To register, email Jeanne Oliver at Jeanne@pacificu.edu or go to www.pacificu.edu.

■ **16-19.** *Florida Optometric Association Annual Convention.* The Breakers, Palm Beach, FL. Hosted by: Florida Optometric Association. Key Faculty: William Marcolini, Ian Gaddie, Mark Dunbar, Christian Guier, Paul Palmer, April Jasper. CE Hours: 30 Total, 22 per OD. To register, call Jessica Brewton at (805) 877-4697, email jessica@floridaeyes.org or go to www.floridaeyes.org.

■ **17-18.** *OOPA Summer CE Event.* The Resort at the Mountain, Welches, OR. Hosted by: Oregon Optometric Physicians Association. Key Faculty: Gordon Johns, Beth Kinoshita, Lorne Yudcovitch, Rebecca Uhlig, Robert Egan, Stan Teplick. CE Hours: 13. To register, email Lynne Olson at lynne@oregonoptometry.org or go to www.oregonoptometry.org.

■ **22-25.** *Northern Rockies Optometric Conference.* Snow King Hotel, Jackson, WY. Host: Northern Rockies Optometric Conference. Key Faculty: Ben Gaddie, Mark Dunbar, Rebecca Wartman. CE Hours: 16. To register, email Kari Cline at director@nrocmeeting.com, or visit www.nrocmeeting.com.

■ **23-26.** *New Technologies and Treatments in Vision Care.* Wailea Beach Marriott Resort & Spa, Wailea, HI. Host: Review of Optometry. Key Faculty: Paul Karpecki, Brad Sutton, Randall Thomas, Ron Melton. CE Hours: 14. To register, email Lois DiDomenico at ReviewMeetings@jobson.com, call (866) 658-1772 or visit www.reviewofoptometry.com.

■ **23-26.** *CE in the Rockies.* Rocky Mountain Park Inn, Estes Park, CO. Host: University of Houston College of Optometry. Key Faculty: Danica Marrelli. CE Hours: 21. To register, email optce@uh.edu, call (713) 743-1900 or visit ce.opt.uh.edu/.

■ **31-Aug. 2.** *Southwest Florida Educational Retreat.* South Seas Island Resort, Ft. Myers, FL. Host: Southwest Florida Optometric Association. Key Faculty: Jimmy Bartlett, Tammy Than, Ron Foreman. CE Hours: 18. To register, email Brad Middaugh at swfoa@att.net or visit www.swfoa.com.

To list your meeting, please send the details to:

Rebecca Hepp, Senior Associate Editor

Email: rhepp@jobson.com

Phone: (610) 492-1005

For advertising opportunities contact:

Michele Barrett (215) 519-1414 or mbarrett@jobson.com

James Henne (610) 492-1017 or jhenne@jobson.com

Michael Hoster (610) 492-1028 or mhoster@jobson.com

Akorn Consumer Health 17	MediNiche 79
Phone (800) 579-8327	Phone (888) 325-2395
..... www.akorn.com info@mediniche.com
..... www.mediniche.com	
Alcon Laboratories ... 52, 89, 108	NovaBay
Phone (800) 451-3937	Pharmaceuticals, Inc. 10
Fax..... (817) 551-4352	Phone (800) 890-0329
 sales@avenova.com
 www.avenova.com
Alden Optical 31	Odyssey Medical (now part of
Phone (800) 253-3669	Beaver-Visitec International,
..... info@aldenoptical.com	Inc.) 51
..... www.aldenoptical.com	Phone (866) 906-8080
 www.odysseymed.com
Allergan, Inc. 9	
Phone (800) 347-4500	
Bausch + Lomb 39	Regeneron Pharmaceuticals,
Phone (866) 246-8245	Inc. 19, 20
..... www.bausch.com	Phone (914) 847-7000
 www.regeneron.com
Bausch + Lomb 7, 33, 34	SynergEyes, Inc. 21
..... 43, 67, 107	Phone (877) 733-2012
Phone (800) 323-0000 Marketing@SynergEyes.com
Fax..... (813) 975-7762 www.SynergEyes.com
Carl Zeiss Meditec Inc. 13	The Shield 77
Phone (877) 486-7473	Phone (212) 243-7300
Fax..... (925) 557-4101 www.shield.org
CooperVision 15, 45	Veatch 65
Phone (800) 341-2020	Phone (800) 447-7511
	Fax..... (602) 838-4934
Haag-Streit 41	Vision Source 73
Phone (800) 627-6286	Phone (281) 312-1111
Fax..... (603) 742-7217	Fax..... (281) 312-1153
 www.visionsource.com
Keeler Instruments 5	
Phone (800) 523-5620	
Fax..... (610) 353-7814	
Lombart Instruments 75	Vistakon 2-3, 83
Phone (800) 446-8092	Phone (800) 874-5278
Fax..... (757) 855-1232	Fax..... (904) 443-1252
M&S Technologies 27	
Phone (877) 225-6101	
Fax..... (847) 763-9170	

This advertiser index is published as a convenience and not as part of the advertising contract. Every care will be taken to index correctly. No allowance will be made for errors due to spelling, incorrect page number, or failure to insert.

Career Opportunities / Merchandise Offered / Equipment and Supplies / Electronic Medical Records/Billing

EYEDESIGNS
 BUILDING YOU A BETTER BUSINESS
 SPACE PLANNING
 INTERIOR DESIGN
 DISPLAY INNOVATION
 MANUFACTURING
 WWW.EYEDESIGNS.COM
 800.346.8890



FREE GIFT for the first 25 people to contact us.
 Ref code OPT0415 exp. 04/30/15

ASCRS 2453



**FORM
 FUNCTION**
Style
 opticaldisplays.com™
 INFO@OPTICALDISPLAYS.COM TO REQUEST OUR CATALOG & DESIGN SERVICES CALL 610.489.7620
FREE GIFT for the first 25 people to contact us. Ref code: OPT0415 exp. 04/30/15

ASCRS 2453

Superior Quality • Competitive Pricing • Worldwide Shipping
 www. **GuldenOphthalmics** .com
HOT PRODUCT: Trial Lens Holders from Gulden

- Pictured right-top: Gulden's most popular trial lens flipper, the 8 Well
- Gulden's trial lens flippers feature a sturdy, modular design
- Pictured right-bottom: The Universal Trial Frame
 - Gulden offers adult trial frames, lightweight trial frames, and child trial frames!

ORDER NOW ONLINE
 OR BY PHONE (215-884-8105)

Gulden's **New** and **Innovative** Products are Proudly Made in the U.S.A.



OPTINOMICS
 Pretesting Solutions
 It's What the Best Pretest on!
(800) 522-2275
 www.optinomics.com
 sales@optinomics.com

INCOME DOWN ???
 JB BILLING SERVICES INC.
 "FULL service medical billing & consulting for ODs by ODs"
 JBBSINC.ORG OR 212-213-3737

Place Your Ad Here!
 Toll free: 888-498-1460
 E-mail: sales@kerhgroup.com

FULL-TIME ASSOCIATE OPTOMETRIST
 Full-time opportunity as associate optometrist in DC Metro Area, MD, and VA. We practice full scope optometry. Outstanding compensation package, benefits and incentives.
 Send CV to
 schwartzberg1@doctorsonsight.com
 or call Ed 301.843.1000

Merchandise Offered

NEW!
MODULAR SOLUTIONS
FOR EVERY PART
OF YOUR PRACTICE



0% FREE FINANCING FOR 3 YEARS*
* For purchase over \$10K. Offer is valid until DEC 31, 2015.

FREE COMPLETE PRACTICE DESIGN SERVICES

Frame Displays.com

1-877-274-9300 An Essilor Company



Optical Dispensary



Pre-Testing / Eye Exam Room



Contact Lens Room



Business Office



Career Opportunities

Here we grow again!

TWO MOTIVATED OPTOMETRISTS ILLINOIS

One of the largest eye care providers to extended care and assisted living residents in our great state of Illinois needs two motivated Optometrists to join our practice!

Both positions are in the Springfield and Central Illinois areas. One position is full time and one position is part time.

Our physicians are proficient in refracting, diagnosing & treating ocular pathology, and dispensing spectacles on-site. If you are proficient in these areas and you are comfortable driving, here are your benefits: Excellent Pay + bonuses (=145K+), travel bonuses that will exceed expenses incurred, new optical equipment, a personal assistant, but most important helping people in need of our professional services.

Interested? Contact Michael at Michael@ovitskyvisioncare.com or at 773-588-3090.

Only serious inquiries please. We will help with relocation expenses, if necessary.

Software

Take a closer look...

at **Eyecom** for your **electronic health record needs!**



tablet compliant
share patient data securely
over 25 years experience
cloud-based access anytime, anywhere



Eyecom³ EHR
WEB-BASED OPTOMETRIC SOFTWARE

800.788.3356 www.eyecom3.com



Put your vision to work for you.

Become Board Certified by the AMERICAN BOARD OF OPTOMETRY



Exam held each January & July

Register at americanboardofoptometry.org

The American Board of Optometry Board Certification program is certified by the National Commission for Certifying Agencies, and its Maintenance of Certification process is approved by the Centers for Medicare and Medicaid Services.

ACCESS HEALTHCARE CAPITAL

The key to making Professional Healthcare Practice Financing simple. Whether you are buying, starting, or updating your practice, Access Healthcare capital is here to help you with your financing needs with one common goal. We want to help you maximize your cash flow. Let us help you unleash your Entrepreneurial Spirit:

Easy App Up To \$250,000

- 100% Financing plus working capital
- Simplified Processing for loans up to \$350,000
- Partnership Buy-In Programs
- * Terms up to 15 years
- Application Only for equipment and technology purchases

www.accesshealthcarecapital.com • info@narxeye.com

Access Healthcare Capital • 1-888-727-4470 • P.O. Box 349, Gladwyne, PA 19035

OPTOMETRIC PRACTICE FOR SALE NORTHEASTERN PA

Very Successful ongoing optometric practice for sale in Northeastern PA. The practice is grossing 600K/yr. This practice is one of a kind with a very large and broad patient base and large contact lens base. The practice services many vision care programs that lends to its success, along with a full complement of direct paying patients. I will be willing to work in the practice.

Serious replies only.

Email: resume6@kerhgroup.com
WITH COMPLETE NAME AND CONTACT INFO

PRACTICE SALES & APPRAISAL

Expert Services for:

- ✓ **Buying or Selling a Practice**
- ✓ **Practice Appraisal**
- ✓ **Practice Financing**
- ✓ **Partner Buy-in or Buy-out**

Call for a Free Consultation
(800) 416-2055
www.TransitionConsultants.com



QuikEyes Optometry EHR

- \$198 per month after low cost set-up fee
- Quick Set-Up and Easy to Use
- No Server Needed
- Corporate and Private OD practices
- 14 Day Free Demo Trial
- Email/Text Communications

www.quikeyes.com

PACKAGE DEAL

EAST CENTRAL FLORIDA, long established optometric practice located in 100 year old historic building.

PRACTICE GROSS 276K. Building worth about 150k. Will sell both for 189k or practice alone for 79k.

I'M RETIRING AND MOTIVATED. For more info email floridapractice@yahoo.com.



Practice Sales • Appraisals • Consulting
www.PracticeConsultants.com

PRACTICES FOR SALE NATIONWIDE

Visit us on the Web or call us to learn more about our company and the practices we have available.
info@PracticeConsultants.com
800-576-6935

www.PracticeConsultants.com

Continuing Education

EYE-SIGHT 20/20, Inc.
Presents Spring 2015

Saturday/Sunday, June 6-7, 2015
16 hours of Advanced COPE
Approved CE for Optometrists

Our Respected Presenters:
JEROME SHERMAN, OD, FAAO
SHERRY BASS, OD, FAAO
JIMMY BARTLETT, OD, FAAO
ANTHONY LITWAK, OD, FAAO

Join US.

*"Where Doctors Gather to
Share Knowledge & Experience"*

FOXWOODS CASINO- Ledyard, CT
Contact:
Dr. Antoinette D. Parvis 508-987-9679
or visit the website for all details:


www.eyesightce.com


Upcoming Events
All 8 hours in Natick, Mass
April 19th
Sept 27th
Oct 18th
and Nov 15th


In Partnership with The NJ Society of Optometric Physicians

Danube River Cruise
July 24 - 31, 2016
12 CE with Ron Melton, O.D., F.A.A.O.

Deluxe Ship Special Group Pricing


All Programs Are in Partnership
With the New Jersey Society of
Optometric Physicians


Dr. TRAVEL, LLC
is a COPE approved provider



Celebrating 20 years Continuing Education

Sailing From Budapest to:
Bratislava, Vienna, Dürstein, Melk/Emmersdorf, Liz, Regensburg, Passau

Additional Seminar Cruises (12-16 CE):
NCL Cruises Choose[®] Deluxe Beverage Package / Dining Package / up to \$300 Credit
*Alaska Glacier Bay Cruise - July 26 - Aug. 2, 2015 - D. Shechtman, OD
*Christmas New Year's Week Cruise - NCL Spirit - Dec. 26, 2015 - Jan. 2, 2016
President's Week - Royal Caribbean's Oasis of the Seas - Feb. 13 - 20, 2016

www.DrTravel.com 800-436-1028

Career Opportunities

STAFF OPTOMETRIST

Bard Optical is a leading Midwest vision care organization in business for over 70 years and we are still growing. The company is based in Peoria, IL with 20 retail offices throughout the central Illinois area, as far north as Sterling and as far south as Jacksonville. Once again this year we were named to the Top 50 Optical Retailers in the United States by Vision Monday - currently ranking 37th. A progressive optometric staff is vital to the continued growth of our organization whose foundation is based on one-on-one patient service. We are currently accepting CV/resumes for optometrists focused on full scope primary medical patient care. The candidate must have an Illinois license with therapeutics. The practice includes (but is not limited to) general optometry, contact lenses, and geriatric care. Salaried, full-time positions are available with excellent growth programs and benefits. Some part-time opportunities may be available also. Please email your information to hr@bardoptical.com or fax to 309-693-9754. Mailing address if more convenient is Bard Optical, Attn: HR, 8309 N Knoxville Avenue, Peoria, IL 61615. Ask about opportunities within Bard Optical. *We have openings in several existing and new offices opening soon in central Illinois.*

Bard Optical is a proud Associate Member of the Illinois Optometric Association.



www.bardoptical.com

OCULAR SYMPOSIUM
Lectures in Ocular Diagnosis and Treatment

Formal Lectures for Optometrists
by Noted Subspecialists in Ophthalmology

Friday, Saturday, Sunday, June 5-7, 2015
24 hours CE credits (8 hours each day)

SAN FRANCISCO, CALIFORNIA

TOPICS TO INCLUDE

Refractive Surgery	Glaucoma	Cataract Surgery
Oculoplastics	Ocular Trauma	Ocular Oncology
Neuro-Ophthalmology	Retina, OCT	Ocular Pediatrics

For information call or write:
Ocular Symposium • P.O. Box 640327 • San Francisco • CA • 94164
(415) 278-9940 • FAX (415) 345-1165
e-mail: ocularsymp@aol.com

Do you have Equipment and Supplies for Sale?



Contact us today for classified advertising:
Toll free: 888-498-1460 • E-mail: sales@kerhgroup.com



Head First Into the Exam Room

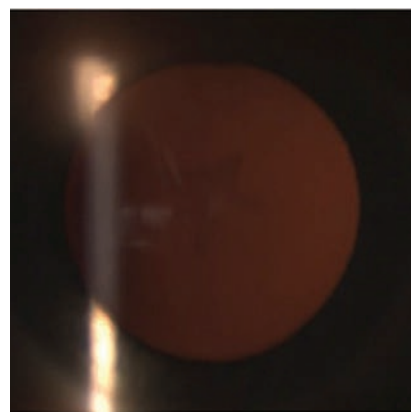
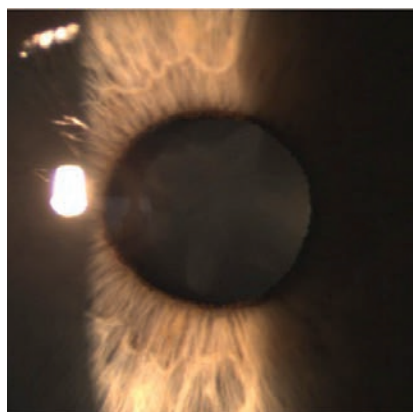
By Andrew S. Gurwood, OD

History

A 33-year-old white female presented with a chief complaint of blurry vision in both eyes, more so in the left than the right, for the previous three months. She was able to pinpoint that the constant blur developed just after she was in an auto accident. She reported hitting the left side of her head on the back of the passenger seat, in a slow moving vehicle accident while not wearing a seat belt. Her previous ocular and systemic histories were unremarkable and she denied any known allergies to medications or other substances.

Diagnostic Data

Her best corrected entering Snellen visual acuity was 20/20 in the right eye and 20/30 in the left eye at distance and near. Refraction revealed hyperopia of +0.75D in the right eye and +1.50D in the left eye, with no improvement in vision for either eye. The pertinent biomicroscopic findings are illustrated in the photographs. Her intraocular pressure was measured as 15mm



Slit lamp images of a 33-year-old white female who presented with a chief complaint of blurry vision in both eyes, but more so in the left eye.

Hg in the right eye and 18mm Hg in the left eye using Goldmann applanation tonometry. Dilated fundus examination revealed no significant posterior pole or peripheral retinal findings. The nerves were distinct, with cup-to-disc ratios of 0.3/0.35 in both eyes.

An optical coherence tomography scan was performed and revealed no sign of macular edema, hole, sustained vitreomacular traction or retinal detachment in either eye. Laser interferometry was per-

formed, with improved visual acuity measuring 20/25.

Your Diagnosis

What is your diagnosis and presumed cause of the condition? How would you approach this case? What is the likely prognosis?

To find out, please visit *Review of Optometry* online at www.reviewofoptometry.com. Click on the cover icon for this month's issue and select "Diagnostic Quiz" from the table of contents. ■

Retina Quiz Answers (from page 88): 1) c; 2) b; 3) c; 4) d.

Next Month in the Mag

May is *Review of Optometry's* annual dry eye report

Topics include:

- *Subjective vs. Objective Mismatch in Dry Eye: What To Do?*

- *Rx Dry Eye Drugs in the Pipeline*
- *Slit Lamp Essentials: Meibomian Gland Expression*
- Plus — *Women's Eye Health: Gender Distinctions and Treatment Decisions* (earn 2 CE credits)

REVIEW OF OPTOMETRY (ISSN 0147-7633) IS PUBLISHED MONTHLY, 12 TIMES A YEAR BY JOBSON MEDICAL INFORMATION LLC, 100 AVENUE OF THE AMERICAS, NEW YORK, NY 10013-1678. PERIODICALS POSTAGE PAID AT NEW YORK, NY AND ADDITIONAL MAILING OFFICES. POSTMASTER: SEND ADDRESS CHANGES TO REVIEW OF OPTOMETRY, PO BOX 81, CONGERS, NY 10920-0081. SUBSCRIPTION PRICES: US: ONE YEAR \$56; TWO YEARS \$97, CANADA: ONE YEAR \$88, TWO YEARS \$160, INT'L: ONE YEAR \$209, TWO YEARS \$299. FOR SUBSCRIPTION INFORMATION CALL TOLL-FREE (877) 529-1746 (USA); OUTSIDE USA, CALL (845) 267-3065. OR EMAIL US AT REVOPOTOMETRY@CAMBEYWEST.COM. PUBLICATIONS MAIL AGREEMENT NO: 40612608. CANADA RETURNS TO BE SENT TO BLEUCHIP INTERNATIONAL, P.O. BOX 25542, LONDON, ON N6C 6B2.

Best-in-class properties for best-in-class performance¹

Bausch + Lomb ULTRA[®] contact lenses with MoistureSeal[®] technology combine best-in-class physical properties for a revolutionary silicone hydrogel lens.¹

	Dk/t	MODULUS	ASPHERIC OPTICS	THIN EDGE DESIGN
Bausch + Lomb ULTRA [®] contact lenses	163	70	✓	✓
ACUVUE OASYS	147	73		✓
AIR OPTIX AQUA	138	102		
Biofinity	160	82	✓	

Patient preferred for end-of-day comfort over the leading silicone hydrogel lenses²

2 to 1
vs.
ACUVUE OASYS

3 to 1
vs.
AIR OPTIX AQUA

4 to 1
vs.
Biofinity

Retains moisture for a full 16 hours.¹



Go to www.blultra.com or contact a Bausch + Lomb sales representative today

REFERENCES: 1. Data on file. Bausch & Lomb Incorporated. Rochester NY; 2013. 2. Results from a 22-investigator, multi-site study of Bausch + Lomb Ultra contact lenses with MoistureSeal technology, on 327 current silicone hydrogel lens wearers. After 7 days of wear, subjects completed an online survey. Subjects rated performance across a range of attributes. Preference comparisons represent only those subjects expressing a preference. Ratio is based on the average across the silicone hydrogel lenses represented in the study.

®/™ are trademarks of Bausch & Lomb Incorporated or its affiliates. All other product/brand names are trademarks of their respective owners. ©2014 Bausch & Lomb Incorporated. US/ZUS/14/0149

BAUSCH + LOMB
See better. Live better.

NOW APPROVED

Pazeo[™]

(olopatadine hydrochloride
ophthalmic solution) 0.7%



ANTICIPATED RETAIL AVAILABILITY MARCH 10

From Alcon, committed to providing new treatment options for patients.

Alcon[®]
a Novartis company

Olopatadine is licensed from Kyowa Hakko Kirin Co., Ltd. Japan
©2015 Novartis 01/15 PAZ15017JAD

Pazeo[™]
(olopatadine hydrochloride
ophthalmic solution) 0.7%

