

# REVIEW<sup>®</sup> OF OPTOMETRY

March 15, 2015

www.reviewofoptometry.com



## Diagnostic Skills & Techniques

*Expert advice to  
help you make  
the call with  
confidence.*

» **SELF-TEST: DIFFERENTIAL DIAGNOSIS  
OF RETINAL DISEASE, PAGE 34**

» **POINT-OF-CARE TESTING: A LAB IN  
THE PALM OF YOUR HAND?, PAGE 52**

» **DON'T OVERLOOK THE EYELIDS: WHAT A  
THOROUGH EXAM CAN REVEAL, PAGE 44**

» **Earn 2 CE Credits: THE URGENT AND  
CHRONIC CAUSES OF DIPLOPIA, PAGE 63**

» **PLUS — CASE REPORT: IDIOPATHIC JUXTAFOVEAL RETINAL TELANGIECTASIS, PAGE 82**

NATURAL  
BEAUTY **EN**

Amelia is wearing NATURAL SHIMMER™

# HANCED

A **NEW CATEGORY** of contact lenses that accentuates **NATURAL BEAUTY**. Based on the **PROVEN DESIGN** of 1-DAY ACUVUE® MOIST, the **#1 DAILY DISPOSABLE BRAND**

WITHOUT

WITH



The iris-inspired design of **NEW 1-DAY ACUVUE® DEFINE™ Brand Contact Lenses** uniquely complements every iris pattern to help make your patients' eyes look whiter and brighter.



**TRY 1-DAY ACUVUE® DEFINE™ BRAND CONTACT LENSES TODAY TO PUT YOUR PRACTICE ON THE CUTTING EDGE OF NATURAL-LOOKING EYE ENHANCEMENT.**

1-DAY ACUVUE® DEFINE™ Brand Contact Lenses are available with and without vision correction. As with any contact lens, eye problems including corneal ulcers can develop. Some wearers may experience mild irritation, itching or discomfort. Lenses should not be prescribed if patients have any eye infection, or experience eye discomfort, excessive tearing, vision changes, redness, or other eye problems. Consult the package insert for complete information, available from VISTAKON®, Division of Johnson & Johnson Vision Care, Inc., by calling 1-800-843-2020 or by visiting [www.acuvueprofessional.com](http://www.acuvueprofessional.com).

1-DAY ACUVUE® DEFINE™, 1-DAY ACUVUE® MOIST, NATURAL SHIMMER™, LACREON®, and VISTAKON® are trademarks of Johnson & Johnson Vision Care, Inc.

© Johnson & Johnson Vision Care, Inc. 2015 ACU-10314367-F February 2015

## IN THE NEWS

A recent clinical trial reported in *The New England Journal of Medicine* compared three drugs for **diabetic macular edema**—**Eylea** (afibercept, Regeneron), **Avastin** (bevacizumab, Genentech) and **Lucentis** (ranibizumab, Genentech)—and found all three resulted in **similar average improvement** when initial vision was 20/40 to 20/32. However, the study found Eylea provided greater visual improvement on average when vision was 20/50 or worse at the start of the trial. Investigators found no major differences in the safety of the three drugs.

A novel **intravitreal injection** of an immunomodulatory protein provided a **long-lasting anti-inflammatory** effect in mice with a form of **age-related macular degeneration**, according to molecular genetics researchers at the University of Florida College of Medicine. The researchers also found the drug works for **uveitis** and could ultimately be used for various other inflammatory eye diseases in humans. In the study, published in the January issue of *Human Gene Therapy*, the researchers used an adeno-associated viral vector to inject the inflammation-blocking protein M013 into the eye. Additional studies are needed before the therapy will be tested in humans, the researchers say.

People with **Parkinson's disease** have significantly **worse vision for low-contrast images** at both near and far distances, according to a recent study in the *Journal of Parkinson's Disease*. Even for high-contrast images, vision of patients with Parkinson's disease was deficient at far distances.

## AOA to Oppose 1-800's Pricing Bills in 14 States

1-800-Contacts backs legislation to ban UPP. AOA aims to rally states in opposition. **By Jane Cole, Contributing Editor**

The AOA is sending out a rallying cry to all state optometric associations and optometrists to combat a set of 1-800-Contacts backed legislative bills that would ban unilateral pricing policies (UPP) for contact lenses.

“Although there are 14 states that are being immediately targeted by 1-800-Contacts, it’s really an attack on our profession and the essential care we provide to our patients,” says AOA president David A. Cockrell, OD. “The AOA and state associations have mobilized quickly to fight back, but we need every optometrist and optometry student to get involved and help get our message out to legislators and to the public.”

Bills are currently pending or in the works in Arizona, California, Florida, Idaho, Illinois, Louisiana, Minnesota, Mississippi, New York, Oregon, Rhode Island, Tennessee, Utah and Washington, according to the AOA.

At press time, an anti-UPP bill in Mississippi has already died in the legislature, a bill in Idaho has been approved in committee, and a bill in Utah—the home state of 1-800-Contacts—has been approved by the state Senate and introduced into the state House of Representatives.

Officials from 1-800-Contacts told Congress last July that the



**Sen. Deidre M. Henderson called for a vote in the Utah Senate in favor of a bill that bans unilateral pricing policies in the state. She acknowledged that the American Optometric Association was opposed to the bill. The vote passed 21 to 8 in the Senate and, at press time, was introduced to the Utah House.**

decision made by contact lens manufacturers to set price minimums on specific brands of their contacts would raise prices for consumers and prohibit consumers’ ability to “shop around” for their contact lenses.

Now, the AOA says optometrists are being placed in the middle of a fight between contact lens manufacturers and online retailers such as 1-800-Contacts. “The AOA believes that the announced goal of blocking unilateral pricing policies is part of a larger effort to misrepresent how ODs provide care for patients and, ultimately, to prohibit patients from obtaining contact lenses from community-based practices of independent eye

*(Continued on page 6)*

# NOW APPROVED

**Pazeo**<sup>™</sup>

(olopatadine hydrochloride  
ophthalmic solution) 0.7%



## ANTICIPATED RETAIL AVAILABILITY MARCH 10

*From Alcon, committed to providing new treatment options for patients.*

**Alcon**<sup>®</sup>  
a Novartis company

Olopatadine is licensed from Kyowa Hakko Kirin Co., Ltd. Japan  
©2015 Novartis 01/15 PAZ15017JAD

**Pazeo**<sup>™</sup>  
(olopatadine hydrochloride  
ophthalmic solution) 0.7%



# 1-800 Backs Bills Against UPP Pricing

(Continued from page 4)

doctors,” the AOA state government relations committee wrote in a memo to its state affiliates.

The AOA says optometrists should defend against 1-800’s allegations by bringing the following key points to the attention of their

state legislators as well as concerned doctors and patients:

- **Contact lenses are medical devices and optometrists need to be involved in patient use.** Any review of the scientific literature or even the lay press confirms the fact that a patient’s vision and overall health

are at risk with improper contact lens wear, care or fit.

- **Doctors recommend specific lenses for medical and safety reasons.** Substitution of a prescribed medical device like a contact lens is wrong and poses unintended health risks to the patient.

- **More needs to be done to target unscrupulous contact lens sellers and profiteers.** The legislature should empower the state optometry board with the tools it needs to target contact lens sellers who threaten public health and hold them accountable for the harm they cause.

Sen. Deidre M. Henderson, who introduced the anti-UPP legislation in Utah, acknowledged to the state Senate that, “The American Optometric Association does not like this bill ... But their arguments that this bill will weaken the quality of eye health care standards and undermine the doctor-patient relationship doesn’t make any sense to me.”

She added, “[This bill] does not in any way change or hinder [optometrists’] ability to care for their patients at all.”

## Contact Lens Pricing Bills by State

Where do these pending anti-UPP bills stand? Here’s a roundup from the AOA, as of press time:

### Arizona

- HB 2038. Bill passed committee and is sitting in the House Rules Committee.
- SB 1444. Bill is pending and not moving.

### Idaho

- HB 149. Unanimously approved in the House Health & Welfare Committee and sent to the House floor for a full vote.

### Illinois

- HB 2450. Pending in the House Rules Committee.
- SB 1259. Sent to the Committee on Assignments.

### Mississippi

- SB 2016. Failed to pass committee.

### New York

- Assembly Bill 4530. Pending in the

Assembly Consumer Affairs and Protection Committee.

### Oregon

- HB 2891. Pending in the House Consumer Protection and Government Effectiveness Committee.

### Rhode Island

- HB 5314. Pending in House Corporations Committee.

### Utah

- SB 169. Approved in state Senate .

### Washington

- SB 5489. Pending in Senate Health Care Committee.
- HB 1847. Pending in House Business & Financial Services Committee.

Meanwhile, bills in California, Florida, Louisiana, Minnesota and Tennessee are expected to be introduced in those legislatures soon.

# Switch to Generic Glaucoma Drug Boosts Adherence by 25%, Study Says

Eye care professionals looking to improve their patients’ adherence to glaucoma medications might have a new—and surprisingly simple—trick up their sleeves. In a recent longitudinal cohort analysis, the results of which were published online in *Ophthalmology*, researchers found

that switching to a generic drug improved adherence by as much as 25%.<sup>1</sup>

Medication adherence is a major problem, considering more than half of glaucoma patients do not take their medications as prescribed.<sup>2</sup> The cost of glaucoma medication could be part of the

problem, say researchers from the University of Michigan Medical School and University of Michigan College of Pharmacy.

“Individuals’ out-of-pocket costs for glaucoma medications can exceed \$100 per month, and the high drug cost may deter patients on a

*Continued on page 8*

# Tonometry Done Right

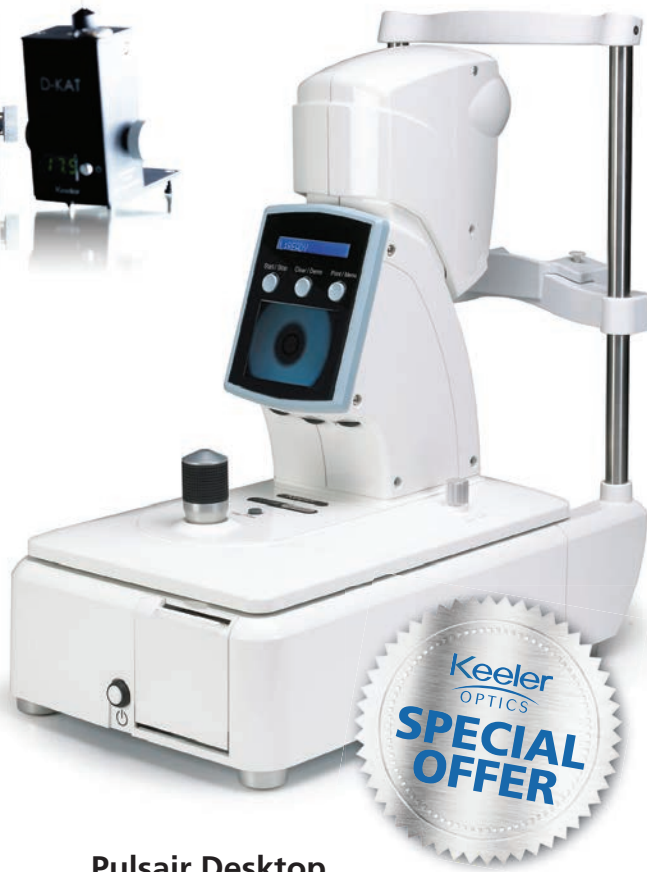**new**



**D-KAT Digital**  
Keeler quality.



**Intellipuff**  
The standard for hand held mobility.



**Pulsair Desktop**  
Smallest footprint and simple to use!

*Purchase a Pulsair Desktop  
by March 31, 2015 and get  
a \$1,300 Instant Rebate!*

Buy Online!  
[keelerusa.com](http://keelerusa.com)



**Keeler**  
OPTICS

# Adherence Improves with Generic

(Continued from page 6)

tight budget from consistently buying and taking their medications as prescribed,” says Joshua D. Stein, MD, associate professor of ophthalmology and visual sciences at the University of Michigan Kellogg Eye Center and lead author of the study. “If clinicians suspect that a patient is struggling with medication adherence, it may be a good idea to switch them from a brand name to a generic drug.”

The 2011 release of generic latanoprost gave patients a cheaper option—and researchers the opportunity to find out if cost was in fact a motivating factor.

Dr. Stein and colleagues ex-

amined claims data from 8,427 glaucoma patients for the 18 months before and after generic latanoprost became available. They found that medication adherence improved on average among all patients who switched to the generic, but the rate of adherence differed among certain subgroups. Those who were on bimatoprost prior to switching to generic latanoprost increased adherence from an average 47% to 61%; those who switched from travoprost increased adherence from 43% to 54%.

The study also showed the subset of black patients who switched to the generic drug had a substantial improvement in adherence

compared to blacks who remained on brand-name products.

“It’s reassuring to find that switching patients to more affordable, generic drugs could be an effective solution for a subgroup of patients who have difficulty with adherence,” Dr. Stein says.


One finding that the researchers could not explain: A considerable number of patients discontinued glaucoma drug use altogether when generic latanoprost became available.

1. Stein J, Shekawat N, Talwar N, Balkrishnan R. Impact of the introduction of generic latanoprost on glaucoma medication adherence. *Ophthalmology*. 2015 Feb 2. [Epub ahead of print.]
2. Schwartz GF, Quigley HA. Adherence and persistence with glaucoma therapy. *Surv Ophthalmol*. 2008 Nov;53 Suppl1:S57-68.

# Drug-Delivering Nanowafer Shows Better Efficacy Than Topical Drops

Researchers at Baylor College of Medicine have developed a new nanowafer that could one day revolutionize how you care for patients in need of topical drug therapy.

Investigators set out to see if a slow-release delivery system could improve treatment for corneal neovascularization (CNV) due to ocular burns in mouse eyes. They used a nanowafer (a tiny circular disc 2mm in diameter and 100µm thick) made of polyvinyl alcohol (PVA), a water-soluble polymer used in artificial tears. The researchers found PVA to be nonstimulatory and nonimmunogenic—an important factor when trying to deliver drugs without disrupting the cornea’s natural healing process. The polymer also dissolves after



**Could this 2mm nanowafer replace topical drops? A new study shows promise.**

the predetermined period of drug release.

Results revealed a nanowafer loaded with 5µg of the antiangiogenic drug axitinib, delivered once a day, was more effective in inhibiting CNV compared with axitinib eye drops delivered twice a day (10µg total). After 10 days of treatment, the nanowafer-treated cornea

closely resembled the healthy uninjured cornea.

“Development of a nanowafer drug delivery system that can be readily instilled on the ocular surface by the patient’s fingertip without any clinical procedure will be not only very convenient but also most desirable for treating eye injuries, infections, chronic dry eye, glaucoma and other ocular inflammatory conditions,” the researchers concluded.

Also, they’re hopeful this device can move through human clinical trials in a timely manner, considering the materials and drugs they used in this study are already in clinical use. ■

- Yuan X, Marciano D, Shin C, et al. Ocular drug delivery nanowafer with enhanced therapeutic efficacy. *ACS Nano*. 2015;9(2):1749–1758.



# REVIEW<sup>®</sup> OF OPTOMETRY

#### BUSINESS OFFICES

11 CAMPUS BLVD., SUITE 100  
NEWTOWN SQUARE, PA 19073

#### CEO, INFORMATION SERVICES GROUP

MARC FERRARA  
(212) 274-7062 • MFERRARA@JOBSON.COM

#### PUBLISHER

JAMES HENNE  
(610) 492-1017 • JHENNE@JOBSON.COM

#### REGIONAL SALES MANAGER

MICHELE BARRETT  
(610) 492-1014 • MBARRETT@JOBSON.COM

#### REGIONAL SALES MANAGER

MICHAEL HOSTER  
(610) 492-1028 • MHOSTER@JOBSON.COM

#### VICE PRESIDENT, OPERATIONS

CASEY FOSTER  
(610) 492-1007 • CFOSTER@JOBSON.COM

#### VICE PRESIDENT, CLINICAL CONTENT

PAUL M. KARPECKI, OD, FFAO  
PKARPECKI@JOBSON.COM

#### PRODUCTION MANAGER

SCOTT TOBIN  
(610) 492-1011 • STOBIN@JOBSON.COM

#### SENIOR CIRCULATION MANAGER

HAMILTON MAHER  
(212) 219-7870 • HMAHER@JHIHEALTH.COM

#### CLASSIFIED ADVERTISING

(888) 498-1460

#### SUBSCRIPTIONS

\$56 A YEAR, \$88 (US) IN CANADA,  
\$209 (US) IN ALL OTHER COUNTRIES.

#### SUBSCRIPTION INQUIRIES

(877) 529-1746 (US ONLY);  
OUTSIDE US, CALL (847) 763-9630

#### CIRCULATION

PO Box 2025  
SKOKIE, IL 60076  
TEL: (TOLL FREE) 1-877-529-1746  
OUTSIDE US: (847) 763-9630  
FAX: (847) 763-9631



CEO, INFORMATION SERVICES GROUP  
MARC FERRARA

SENIOR VICE PRESIDENT, OPERATIONS  
JEFF LEVITZ

SENIOR VICE PRESIDENT, HUMAN RESOURCES  
LORRAINE ORLANDO

VICE PRESIDENT, CREATIVE SERVICES & PRODUCTION  
MONICA TETTAMANZI

VICE PRESIDENT, CIRCULATION  
EMELDA BAREA

Rely on something that  
**STAYS PUT**



Parosol<sup>®</sup>

**92%\***  
RETENTION

We've taken the worry out of plug retention, so you can concentrate on patient retention. The Parosol<sup>®</sup> Punctal Occluder trumps the competition with an unprecedented 92% retention rate. Use the Parosol<sup>®</sup> Punctal Occluder, designed for easy insertion and guaranteed to stay put.

**TO ORDER:** 866-906-8080  
customersupport@beaver-visitec.com  
odyssey.med.com or beaver-visitec.com

**bvi** Beaver Visitec  
*Keeping Your Vision in Sight*

\* "Plugs Reduce Dry Eye Symptoms, Improve Vision", Craig McCabe, M.D., Review of Ophthalmology, 2009.  
BVI, BVI Logo and all other trademarks (unless noted otherwise) are property of a Beaver-Visitec International ("BVI") company © 2015 BVI



INTRODUCING  
**THE NEW RANGE OF VARILUX® PROGRESSIVE LENSES**  
**EAGLE-EYE VISION FOR ALL**

**EMPOWER YOUR PATIENTS WITH THE SHARPEST VISION AVAILABLE**

---

- **NEW Varilux Comfort® W2+** lenses offer sharper vision even in low light
- **NEW Varilux® Physio® W3+** lenses provide sharper vision and smoother transitions from distance to near
- **Varilux S Series™** lenses have it all, virtually eliminating the off-balance feeling to provide unprecedented stability in motion

**Come see us at  
Vision Expo East  
Booth #7235**

BE THE BEST, PRESCRIBE THE BEST.

**VARILUX®**  
Natural Vision. Forever.

# Contents

Review of Optometry March 2015

## Diagnostic Skills & Techniques



### 34 Pathology in Perspective: Differential Diagnosis of Retinal Disease

Many retinal conditions can be easily confused. Can you spot the masqueraders?

By **Mohammad Rafieetary, OD, Stephen Huddleston, MD, and Eric Sigler, MD**

### 44 Don't Overlook the Eyelids

A thorough eyelid examination can be critical to keeping your patients healthy. Here's what you should look for.

By **Christine Sindt, OD**

### 52 A Lab in the Palm of Your Hand?

Point-of-care testing helps take the guesswork out of diagnosis by bringing data into the clinic—quickly.

By **Blair Lonsberry, OD**

### 63 Earn 2 CE Credits: Seeing Double: The Urgent and Chronic Causes of Diplopia

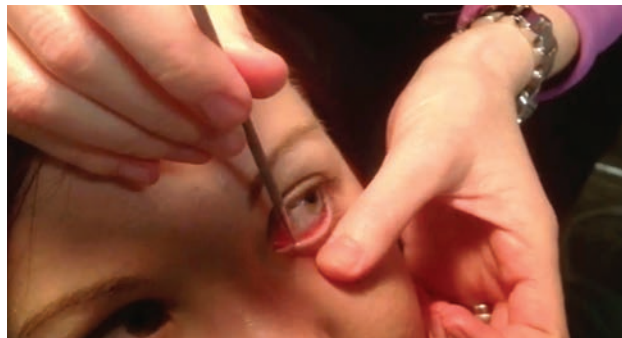Double vision can originate from many conditions. Learn to recognize when this presentation is an emergency and when it's indicative of a long-term issue.

By **Jim Williamson, OD**

### 72 Essential Procedures at the Slit Lamp: How to Make Your Patients Stop Crying

Follow these simple steps to confidently perform lacrimal dilation and irrigation.

By **Megan Provence-Perry, OD, Andrea Smith, OD, and Nathan Lighthizer, OD**



### 80 Vision Expo East 2015: A Focus on Education

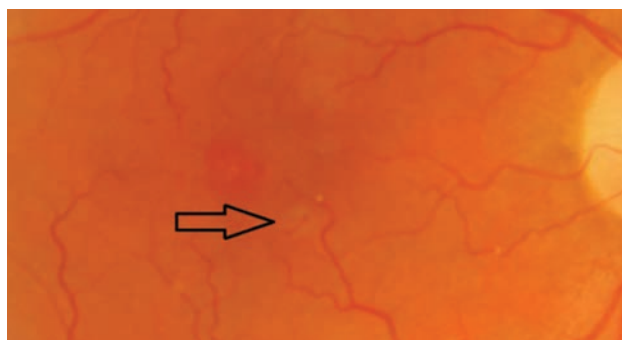
Contact lenses, wellness and ocular diseases are hot topics this year—as is new technology to keep Expo attendees engaged. See what else is in store for VEE 2015.

By **Cheryl G. Murphy, OD, Contributing Editor**

### 82 Case Report: Exam Reveals Subtle Macular Disease

A middle-aged patient was seeing spots, prompting an uncommon diagnosis of idiopathic juxtafoveal retinal telangiectasis.

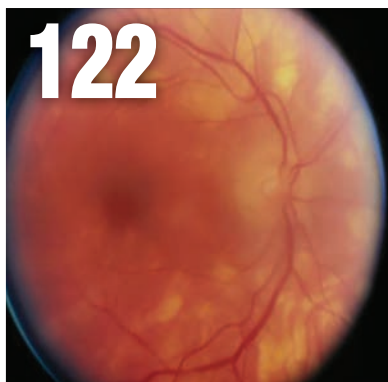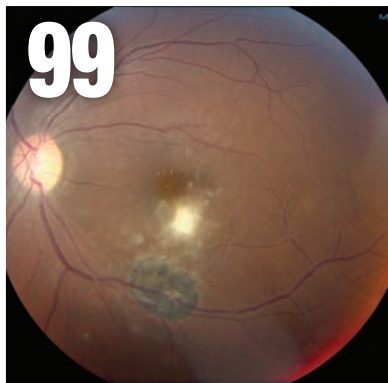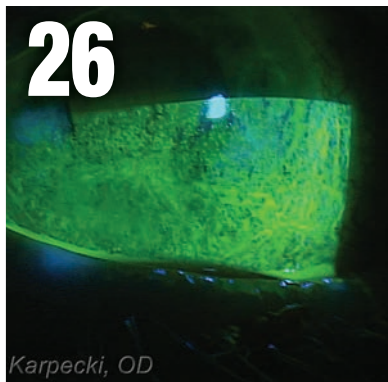
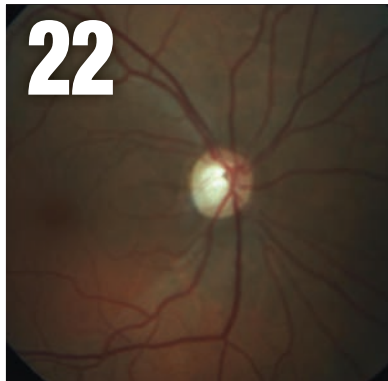By **Erin S. Cooper, OD, Paul J. Grusso, OD, and Joseph Miller, OD**



# Departments

Review of Optometry March 2015

- 4 News Review**
- 16 Letters to the Editor**
- 18 Outlook**  
All in a Day's Work  
**JACK PERSICO**
- 20 Chairside**  
Must the 'No Shows' Go on?  
**MONTGOMERY VICKERS, OD**
- 22 Neuro Clinic**  
Pale Disc Points to Trouble  
**MICHAEL TROTTINI, OD, AND  
MICHAEL DELGIODICE, OD**
- 26 Ocular Surface Review**  
Risky Business  
**PAUL KARPECKI, OD**
- 30 Clinical Quandaries**  
Detached Staff, Detached Retina  
**PAUL C. AJAMIAN, OD**
- 94 Coding Connection**  
Coding Point-of-Care Testing  
**JOHN RUMPAKIS, OD**
- 96 Cornea + Contact Lens Q+A**  
Checks and Balances  
**JOSEPH P. SHOVLIN, OD**
- 99 Retina Quiz**  
Gone Girl  
**MARK T. DUNBAR, OD**
- 103 Review of Systems**  
AIDS in America: 30 Years Later  
**CARLO J. PELINO, OD, AND  
JOSEPH J. PIZZIMENTI, OD**
- 107 Therapeutic Review**  
The Throwback Thursday Option  
**JOSEPH W. SOWKA, OD, AND  
ALAN G. KABAT, OD**
- 111 Surgical Minute**  
Measure Twice, Cut Once  
**DEREK N. CUNNINGHAM, OD, AND  
WALTER O. WHITLEY, OD, MBA**
- 113 Product Review**
- 114 Meetings + Conferences**
- 115 Advertisers Index**
- 117 Classifieds**
- 122 Diagnostic Quiz**  
Salt and Pepper Fundus?  
**ANDREW S. GURWOOD, OD**



## On The Web >> and more

Check out our multimedia and continuing education online at:  
[www.reviewofoptometry.com](http://www.reviewofoptometry.com)

### Digital Edition



Left your copy of *Review of Optometry* at the office? No problem! Access *Review* on your computer or mobile device!

Go to [www.reviewofoptometry.com](http://www.reviewofoptometry.com) and click on the digimag link for the current issue.

### Facebook and Twitter



For daily updates, "Like" our page on Facebook or "Follow" us on Twitter!


- [www.facebook.com/revoptom](http://www.facebook.com/revoptom)
- <http://twitter.com/#!/revoptom>

Look for augmented content and special offers from *Review* and our advertisers. Specified pages work in conjunction with your smartphone or other mobile device to enhance the experience. With Layar, interactive content leaps off the page!



**Step 1:** Download the free Layar app for iPhone or Android.



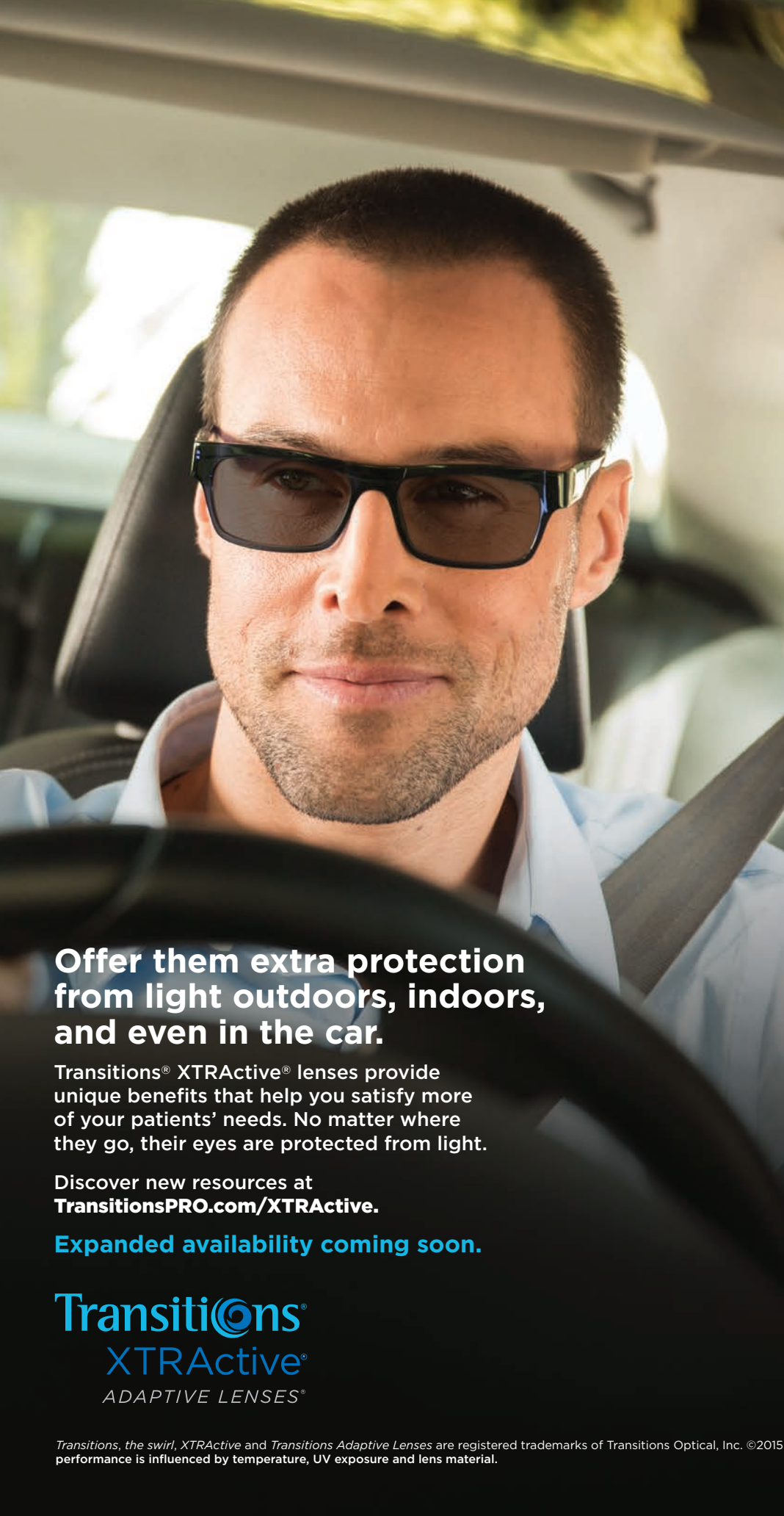**Step 2:** Look for pages with the Layar Logo.  INTERACTIVE PRINT



**Step 3:** Open the Layar app, hold the phone above the page and tap to scan it. Hold the phone above the page to view the interactive content.

The first 150 app downloads and completed forms will be entered into a drawing for a complimentary registration to one of *Review's* 14-hour CE meetings, valued at \$495.

Stock Images: ©iStock.com/JobsonHealthcare



**Offer them extra protection  
from light outdoors, indoors,  
and even in the car.**

Transitions® XTRActive® lenses provide unique benefits that help you satisfy more of your patients' needs. No matter where they go, their eyes are protected from light.

Discover new resources at  
**[TransitionsPRO.com/XTRActive](http://TransitionsPRO.com/XTRActive).**

**Expanded availability coming soon.**

**Transitions®**  
**XTRActive®**  
ADAPTIVE LENSES®



## CONTRIBUTING EDITORS

PAUL C. AJAMIAN, OD, ATLANTA  
AARON BRONNER, OD, KENNEWICK, WASH.  
MILE BRUJIC, OD, BOWLING GREEN, OHIO  
DEREK N. CUNNINGHAM, OD, AUSTIN, TEXAS  
MARK T. DUNBAR, OD, MIAMI  
ARTHUR B. EPSTEIN, OD, PHOENIX  
JAMES L. FANELLI, OD, WILMINGTON, NC  
FRANK FONTANA, OD, ST. LOUIS  
GARY S. GERBER, OD, HAWTHORNE, NJ  
ANDREW S. GURWOOD, OD, PHILADELPHIA  
ALAN G. KABAT, OD, MEMPHIS, TENN.  
DAVID KADING, OD, SEATTLE  
PAUL M. KARPECKI, OD, LEXINGTON, KY.  
JEROME A. LEGERTON, OD, MBA, SAN DIEGO  
JASON R. MILLER, OD, MBA, POWELL, OHIO  
CHERYL G. MURPHY, OD, HOLBROOK, NY  
CARLO J. PELINO, OD, JENKINTOWN, PA.  
JOSEPH PIZZIMENTI, OD, FORT LAUDERDALE, FLA.  
JOHN RUMPAKIS, OD, MBA, PORTLAND, ORE.  
DIANA L. SHECHTMAN, OD, FORT LAUDERDALE, FLA.  
JEROME SHERMAN, OD, NEW YORK  
JOSEPH P. SHOVLIN, OD, SCRANTON, PA.  
JOSEPH W. SOWKA, OD, FORT LAUDERDALE, FLA.  
MONTGOMERY VICKERS, OD, ST. ALBANS, W.VA.  
WALTER O. WHITLEY, OD, MBA, VIRGINIA BEACH, VA.

## EDITORIAL REVIEW BOARD

JEFFREY R. ANSHEL, OD, CARLSBAD, CALIF.  
JILL AUTRY, OD, RPH, HOUSTON  
SHERRY J. BASS, OD, NEW YORK  
EDWARD S. BENNETT, OD, ST. LOUIS  
MARC R. BLOOMENSTEIN, OD, SCOTTSDALE, ARIZ.  
CHRIS J. CAKANAC, OD, MURRYSVILLE, PA.

JERRY CAVALLERANO, OD, PHD, BOSTON  
WALTER L. CHOATE, OD, MADISON, TENN.  
BRIAN CHOU, OD, SAN DIEGO  
A. PAUL CHOUS, MA, OD, TACOMA, WASH.  
ROBERT M. COLE, III, OD, BRIDGETON, NJ  
GLENN S. CORBIN, OD, WYOMISSING, PA.  
ANTHONY S. DECIDUE, OD, STROUDSBURG, PA.  
S. BARRY EIDEN, OD, DEERFIELD, ILL.  
STEVEN FERRUCCI, OD, SEPULVEDA, CALIF.  
MURRAY FINGERET, OD, HEWLETT, NY  
IAN BEN GADDIE, OD, LOUISVILLE, KY.  
MILTON HOM, OD, AZUSA, CALIF.  
BLAIR B. LONSBERRY, MS, OD, MED, PORTLAND, ORE.  
THOMAS L. LEWIS, OD, PHD, PHILADELPHIA  
DOMINICK MAINO, OD, MED, CHICAGO  
KELLY A. MALLOY, OD, PHILADELPHIA  
RICHARD B. MANGAN, OD, LEXINGTON, KY.  
RON MELTON, OD, CHARLOTTE, NC  
PAMELA J. MILLER, OD, JD, HIGHLAND, CALIF.  
BRUCE MUCHNICK, OD, COATESVILLE, PA.  
MARC MYERS, OD, COATESVILLE, PA.  
WILLIAM B. POTTER, OD, FREEHOLD, NJ  
CHRISTOPHER J. QUINN, OD, ISELIN, NJ  
JOHN L. SCHACHET, OD, ENGLEWOOD, COLO.  
JACK SCHAEFFER, OD, BIRMINGHAM, ALA.  
MICHAEL C. RADOIU, OD, STAUNTON, VA.  
KIMBERLY K. REED, OD, FORT LAUDERDALE, FLA.  
LEO P. SEMES, OD, BIRMINGHAM, ALA.  
LEONID SKORIN, JR., OD, DO, ROCHESTER, MINN.  
BRAD M. SUTTON, OD, INDIANAPOLIS  
LORETTA B. SZCZOTKA, OD, PHD, CLEVELAND  
TAMMY P. THAN, MS, OD, BIRMINGHAM, ALA.  
RANDALL THOMAS, OD, CONCORD, NC  
KATHY C. WILLIAMS, OD, SEATTLE

Icare is a trusted portable device for

# QUICK & EASY IOP MEASUREMENTS

**icare**  
tonometer

RANDALL THOMAS, OD  
& RON MELTON, OD

“As soon as we had the Icare tonometry performed on ourselves, our skepticism turned to amazed acceptance and we couldn't wait to use it on our patients. It is indeed asymptomatic in virtually all instances and certainly atraumatic in all cases.”

Come see what you've been missing!  
Visit **Vision Expo East Booth MS7016**



LEARN MORE: **888.422.7313**

[icare-usa.com](http://icare-usa.com)



**NO CALIBRATION  
NO DROPS, NO AIR**

**NEW**  
**Lombart CS-5 Package**  
Quality, Style & Value

Package includes:

- The Lombart CS-5 Chair & Stand 
- Topcon VT-10 Refractor
- Topcon SL-2G Slit Lamp
- Reichert LongLife Chart Projector   
with mount, slide & screen
- Upgrade to the Lombart CVS-PC for only \$1500  
or to the CVSi21 for only \$2000 more
- Additional upgrades & configurations available.

**\$13,995**

Or lease for \$277/mo.  
for 60 months\*

\*Lease rate subject to credit approval, 1st payment is due at signing with 59 remaining rental payments of \$265 and a \$1.00 purchase option. Taxes, freight and installation additional. Hand Instruments optional. Subject to change without notice.

1-800-566-2278

**Call 1-800-Lombart**

**Or Your Local Lombart Representative**

Corporate Office - 5358 Robin Hood Road, Norfolk, VA 23513-2430  
757-853-8888 | FAX 757-855-1232 | 800-566-2278

[www.lombartinstrument.com](http://www.lombartinstrument.com)  
[lombart@lombartinstrument.com](mailto:lombart@lombartinstrument.com)

**Sales and Service Centers Coast to Coast**

ATLANTA • BALTIMORE/WASHINGTON D.C. • BOSTON • BOYNTON BEACH/MIAMI • BRADENTON • CHARLOTTE • CHICAGO • CINCINNATI • DALLAS • DENVER • DETROIT • GREENSBORO • HOUSTON  
JACKSON • KANSAS CITY • KNOXVILLE • LOS ANGELES • MILWAUKEE • MINNEAPOLIS • NEW JERSEY/NEW YORK/PENNSYLVANIA • NORFOLK • PORTLAND • SAN ANTONIO • SAN DIEGO • SAN FRANCISCO



*"I fear that this treatment approach may delay definitive care and should be avoided until controlled studies contradict what is known to be true."*

## Off-Label Use is Off Target?

I thoroughly enjoyed "Off Label, But On Target" (January 2015). Off-label uses are necessary for successful practice, yet they present us with dilemmas to navigate on a daily basis. We tread forward when perfect, or even imperfect, clinical science is lacking and the article shed great light on this issue.

One such off-label dilemma is the notion of topical Restasis (cyclosporine A 0.05%, Allergan) for uveitis. Dr. Lou Catania is one of our greatest thought leaders, and I respect his opinion and poster citation with great humility.<sup>1</sup> However, the broad evidence for uveitis treatment with Restasis just does not add up. Yes, the drug is a potent anti-inflammatory agent via its white blood cell suppression. However, it has demonstrated poor ocular penetration even at a formulated 2% concentration, which is 40 times the concentration found in commercial Restasis. The 1990 study by BenEzra and colleagues showed *no* cyclosporine detectable in the anterior chamber at a 2% dosage concentration.<sup>2</sup>

Top uveitis specialist Stephen Foster, MD, addressed this issue at an American Academy of Ophthalmol-

ogy lecture, asserting that low concentration and poor penetration via topical route would doom this modality to failure in treating uveitis. My own clinical experience indicates that Restasis patients suffer uveitis in the same manner as everyone else.

Given the logistical difficulties in getting Restasis for many patients, even on label, I fear that this treatment approach may delay definitive care and should be avoided until controlled studies contradict what is known to be true.

—William B. Potter, OD, Freehold, NJ

*Dr. Catania responds:*

Your letter regarding my comments about Restasis' use in anterior uveitis and its penetration provides some important information about a topic that has confused me for years.

My history (and comments) regarding topical cyclosporine A (CSA) dates back to the 1990s and through the FDA approval process for Restasis in 2003. Given the positive history of topical CSA with canines (and other animal studies) in ocular inflammation as well as studies proving its value in human use (a list of citations available on request) and, finally, the FDA Restasis Application Research Report (NDA21-023) with pharmacological science and a supportive comment regarding its use in uveitis ("The effects of CSA has been demonstrated in several inflammatory conditions including autoimmune uveitis..."), I found (albeit anecdotally) that use of Restasis at higher than label-recommended dosages and with topical steroids seemed to shorten the course of a number of anterior uveitic inflammations treated.

Nonetheless, you raise a valid point that I have questioned myself about CSA's ocular penetration. Some literature (e.g., BenEzra study) identifies it as a limitation and some (e.g., Nussenblatt et al.) dispute its relevance.<sup>3</sup> I agree with you that further clinical evaluations on pharmacodynamic properties, concentrations and dosages vis-a-vis therapeutic ocular tissue levels with Restasis would be valuable. ■

## Sight Gags By Scott Lee, OD



1. Michelotti M, Shtein RM, Prabhu SS, Cooney T. Topical cyclosporine A 0.05% for recurrent anterior uveitis. Poster presented at American Society of Cataract and Refractive Surgery Annual Symposium. April 25, 2014; Boston, MA.

2. BenEzra D, Maftzir G, de Courten C, Timonen P. Ocular penetration of cyclosporin A. III: The human eye. *Br J Ophthalmol*. 1990 Jun;74(6):350-2.

3. Nussenblatt RB, Palestine AG, Chan CC. Cyclosporin A therapy in the treatment of intraocular inflammatory disease resistant to systemic corticosteroids and cytotoxic agents. *Am J Ophthalmol*. 1983 Sep;96(3):275-82.



# Best-in-class properties for best-in-class performance<sup>1</sup>

**Bausch + Lomb ULTRA<sup>®</sup> contact lenses with MoistureSeal<sup>®</sup> technology** combine best-in-class physical properties for a revolutionary silicone hydrogel lens.<sup>1</sup>

	Dk/t	MODULUS	ASPHERIC OPTICS	THIN EDGE DESIGN
<b>Bausch + Lomb ULTRA<sup>®</sup> contact lenses</b>	<b>163</b>	<b>70</b>	✓	✓
ACUVUE OASYS	147	73		✓
AIR OPTIX AQUA	138	102		
Biofinity	160	82	✓	

Patient preferred for end-of-day comfort over the leading silicone hydrogel lenses<sup>2</sup>

**2 to 1**  
vs.  
ACUVUE OASYS

**3 to 1**  
vs.  
AIR OPTIX AQUA

**4 to 1**  
vs.  
Biofinity

Retains moisture for a full 16 hours.<sup>1</sup>



Go to [www.blultra.com](http://www.blultra.com) or contact a Bausch + Lomb sales representative today

**REFERENCES:** 1. Data on file. Bausch & Lomb Incorporated. Rochester NY; 2013. 2. Results from a 22-investigator, multi-site study of Bausch + Lomb Ultra contact lenses with MoistureSeal technology, on 327 current silicone hydrogel lens wearers. After 7 days of wear, subjects completed an online survey. Subjects rated performance across a range of attributes. Preference comparisons represent only those subjects expressing a preference. Ratio is based on the average across the silicone hydrogel lenses represented in the study.

®/™ are trademarks of Bausch & Lomb Incorporated or its affiliates. All other product/brand names are trademarks of their respective owners. ©2014 Bausch & Lomb Incorporated. US/ZUS/14/0149

**BAUSCH + LOMB**  
See better. Live better.



PRINTED IN USA

**FOUNDING EDITOR**  
FREDERICK BOGER  
1891-1913

**EDITORIAL OFFICES**

11 CAMPUS BLVD., SUITE 100  
NEWTOWN SQUARE, PA 19073

EMAIL • REVIEWOFOPTOMETRY@JOBSON.COM

WEBSITE • WWW.REVOPTOM.COM

**SUBSCRIPTION INQUIRIES**

1-877-529-1746

**CONTINUING EDUCATION INQUIRIES**

1-800-825-4696

**EDITOR-IN-CHIEF • JACK PERSICO**

(610) 492-1006 • JPERSICO@JOBSON.COM

**EXECUTIVE EDITOR • JOHN MURPHY**

(610) 492-1021 • JMURPHY@JOBSON.COM

**SENIOR EDITOR • BILL KEKEVIAN**

(610) 492-1003 • BKEKEVIAN@JOBSON.COM

**ASSOCIATE EDITOR • ALIZA MARTIN**

(610) 492-1043 • AMARTIN@JOBSON.COM

**DIRECTOR ART/PRODUCTION • JOE MORRIS**

(610) 492-1027 • JMORRIS@JOBSON.COM

**ART DIRECTOR • JARED ARAUJO**

(610) 492-1032 • JARAJO@JOBSON.COM

**DIRECTOR OF CE ADMINISTRATION • REGINA COMBS**

(212) 274-7160 • RCOMBS@JOBSON.COM

**SPECIAL PROJECTS/E-PRODUCTS MANAGER • KAREN ROMAN**

(610) 492-1037 • KROMAN@JOBSON.COM

**EDITORIAL BOARD**

**CHIEF CLINICAL EDITOR • PAUL M. KARPECKI, OD**

**ASSOCIATE CLINICAL EDITORS • JOSEPH P. SHOVLIN, OD;**

ALAN G. KABAT, OD; CHRISTINE W. SINDT, OD

**DIRECTOR OPTOMETRIC PROGRAMS • ARTHUR EPSTEIN, OD**

**CLINICAL & EDUCATION CONFERENCE ADVISOR**

PAUL M. KARPECKI, OD

**CASE REPORTS COORDINATOR • ANDREW S. GURWOOD, OD**

**CLINICAL CODING EDITOR • JOHN RUMPAKIS, OD, MBA**

**CONSULTING EDITOR • FRANK FONTANA, OD**

**COLUMNISTS**

**CHAIRSIDE • MONTGOMERY VICKERS, OD**

**CLINICAL QUANDARIES • PAUL C. AJAMIAN, OD**

**CORNEA & CONTACT LENS Q+A • JOSEPH P. SHOVLIN, OD**

**DIAGNOSTIC QUIZ • ANDREW S. GURWOOD, OD**

**GLAUCOMA GRAND ROUNDS • JAMES L. FANELLI, OD**

**OCULAR SURFACE REVIEW • PAUL M. KARPECKI, OD**

**URGENT CARE • RICHARD B. MANGAN, OD**

**RETINA QUIZ • MARK T. DUNBAR, OD**

**REVIEW OF SYSTEMS • CARLO J. PELINO, OD;**

JOSEPH J. PIZZIMENTI, OD

**SURGICAL MINUTE • DEREK N. CUNNINGHAM, OD;**

WALTER O. WHITLEY, OD, MBA

**THERAPEUTIC REVIEW • JOSEPH W. SOWKA, OD;**

ALAN G. KABAT, OD

**NEURO CLINIC • MICHAEL TROTTINI, OD;**

MICHAEL DELGIODICE, OD

**FOCUS ON REFRACTION • MARC TAUB, OD;**

PAUL HARRIS, OD

JOBSON MEDICAL INFORMATION LLC



# All in a Day's Work

From the Snellen chart to the surgical suite, and everywhere in between. **By Jack Persico, Editor-in-Chief**

A few months ago, I got a piece of glass in my eye while repairing a window, causing a conjunctival laceration. It was a Saturday evening, and my eye was starting to bleed.

Instead of going to the ER, I called my optometrist. The office was closed, but she provided her cell number for emergencies. She took a detailed history over the phone, called in a prescription for an antibiotic and advised me of signs of infection to look for. If it worsened, she said, I should come in for an urgent visit on Monday morning. Then she went back to baking her Christmas cookies. No big deal; all in a day's work.

It didn't occur to me until later just how radical all that would have seemed not that long ago—after-hours call service by an OD, ocular injury risk assessment and triage, even the prescribing of a therapeutic pharmaceutical agent. But it all felt perfectly natural.

When I started in this field (24 years ago!), none of that would have happened. Most optometrists subsisted on vision care—refraction and dispensing were their bread and butter. Clinical care didn't go much beyond routine screenings.

It's exciting to see how much the profession has evolved and flourished, and truly gratifying to have played a small part in encouraging it through my efforts as a medical editor serving the field. *Review of Optometry* has always championed the advancement of optometrists' clinical skills, and we continue that mission to this day.


In addition to launching a new column in January called Urgent Care that covers just such a scenario as I experienced myself, this month we kick off another forward-thinking department: Neuro Clinic. New columnists Michael Trottini, OD, and Michael DelGiodice, OD delve into topics in neuro-ophthalmic care for the practicing optometrist in 2015. Their debut column discusses a case of suspicious optic disc pallor that led them to order an MRI, identify an aneurysm and refer to neurosurgery. From the OD to the OR! Impressive, most impressive.

Also this month, we emphasize diagnostic skills and techniques so that you can make the all-important call with confidence. "Outside of laboratory settings, hard data is hard to come by; we often must rely on clinical instincts and expertise," Blair Lonsberry, OD, says in his article about point-of-care testing on page 52. Building up those instincts is this month's issue focus.

Optometry has progressed by leaps and bounds in the last two decades, and *Review* is pleased to be in the vanguard with you. But we're glad to stay grounded too, having also launched a column on tried-and-true refraction last month. "Thank you for the recent Focus on Refraction article," a reader wrote. "We in the trenches see so few things on these subjects we deal with day in and day out, as we do everything we can to help our patients to see clearly and comfortably." Vision is just as vital as eye health, and we honor that great strength while still helping the profession to grow. ■

# CAN'T WAIT UNTIL NEXT MONTH?

Optometric Physician delivers **UP-TO-DATE** news and research to your inbox every Monday morning, allowing you to view all of the latest clinical information on a convenient and consistent basis.



Subscribing to Optometric Physician is an efficient and easy way to stay current with all of the information and events going on in the field. To order your free subscription, e-mail: [optometricphysician@jobson.com](mailto:optometricphysician@jobson.com) today.

Optometric  
Physician™

# Must the ‘No Shows’ Go On?

Those two little words will drive me to an early grave. Until then, I will spend my time concocting elaborate revenge plots against these patients. **By Montgomery Vickers, OD**

**A**s optometrists, one thing we all have in common, other than our ability to break dance, is that we all have *no shows*, what we list in my office as “NS.”

And these NS patients seem to travel in packs, because one day half your schedule is obliterated by the initials NS. Throughout my career, I have found NS patients fascinating, just like kidney stones are fascinating. They are often patients who don’t even pay a dime, as their examinations are my tax dollars at work. A statistically significant number of them called *me* for the appointment. Why set up an appointment yourself and then just not come?

We’ve tried everything: (a) sent them a bill, (b) sent them a bill with a personal note saying “this one time the accountant will NOT charge a fee because I know how busy life can be,” (c) told them we cannot reserve an appointment for them but would be happy to work them in the same day they call, (d) sent a handwritten apology that I was not in when they showed up for their appointment, and even (e) reappointed them for Friday (we are closed on Fridays). So far, nothing has helped, but I’ve only been working on solutions for 35 years.

Many, many “experts” have ideas about this very issue, such as:

**1. Pre-appoint.** If I had a nickel for every practice management guru who says “pre-appointing reduces no shows,” I’d be chillin’ in the Caymans right now. I do pre-appoint, and all things con-

sidered, it does help keep you booked up sometimes. On the other hand, patients routinely forget the Wednesday appointment they made on Monday. Can they remember the one they made 13 months ago? Apparently not!

**2. Mail a reminder.** We do. The postal service has an amazing record of reliable delivery, except, of course, for my appointment reminders. No shows “never got one.” I’m thinking of writing the reminders on a \$10 check so when they cash them I can prove they actually *did* receive them!

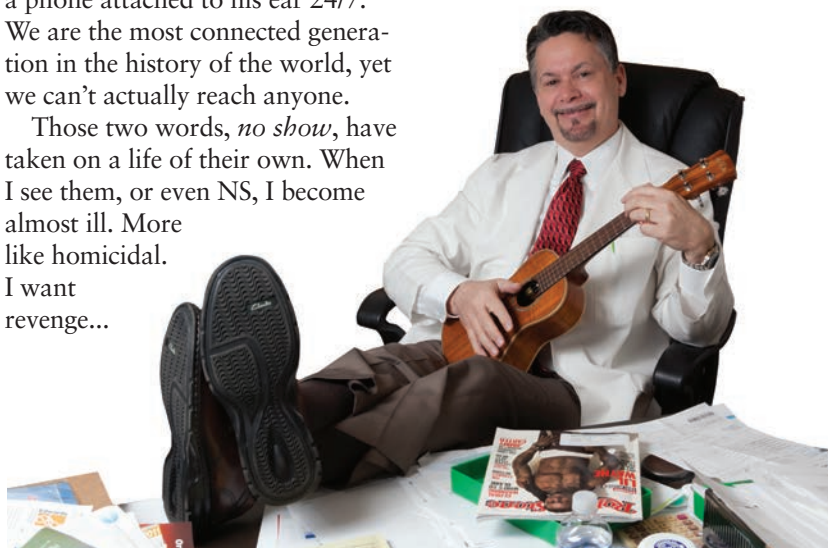
**3. Call and remind them.** We call them the week before and the day before. Well, of course, that depends upon your definition of “we call them.” Back in the day, each family had one phone, and when you called a person answered, and you could actually reach them. Now, every person has a phone attached to his ear 24/7. We are the most connected generation in the history of the world, yet we can’t actually reach anyone.

Those two words, *no show*, have taken on a life of their own. When I see them, or even NS, I become almost ill. More like homicidal. I want revenge...

*Don’t complain, No Show! You should have come to your appointment instead. And, if perchance you do happen to wander in for your appointment, you will ALWAYS be dilated—I think 50% atropine should do the trick. Don’t worry. It will wear off a couple weeks before you are due next year.*

*Do I sound bitter? One man’s bitterness is another man’s honesty. We all have to live and die by our decisions and YOU missed the appointment, NS. Not me ... unless it was one of those appointments we rescheduled to a Friday when we are closed, in which case, NYAH-NA-NA-NA-NYAH, I wasn’t there!*

Thank you all for allowing me to vent about no shows. Now I gotta go. I have a patient waiting. Wonder what he’d say if I no showed? ■





# SYMPTOMATIC VITREOMACULAR ADHESION (VMA)

SYMPTOMATIC VMA MAY LEAD TO VISUAL IMPAIRMENT FOR YOUR PATIENTS<sup>1-3</sup>

## IDENTIFY

Recognize metamorphopsia as a key sign of symptomatic VMA and utilize OCT scans to confirm vitreomacular traction.

## REFER

Because symptomatic VMA is a progressive condition that may lead to a loss of vision, your partnering retina specialist can determine if treatment is necessary.<sup>1-3</sup>

THE STEPS YOU TAKE TODAY MAY MAKE A DIFFERENCE  
FOR YOUR PATIENTS TOMORROW

 ThromboGenics®

© 2014 ThromboGenics, Inc. All rights reserved. ThromboGenics, Inc., 101 Wood Avenue South, Suite 610, Iselin, NJ 08830 – USA. THROMBOGENICS and the THROMBOGENICS logo are trademarks or registered trademarks of ThromboGenics NV. 10/14 OCRVMA0220

**References:** 1. Sonmez K, Capone A, Trese M, et al. Vitreomacular traction syndrome: impact of anatomical configuration on anatomical and visual outcomes. *Retina*. 2008;28:1207-1214. 2. Hikichi T, Yoshida A, Trempe CL. Course of vitreomacular traction syndrome. *Am J Ophthalmol*. 1995;119(1):55-56. 3. Stalmans P, Lescauwaet B, Blot K. A retrospective cohort study in patients with diseases of the vitreomacular interface (ReCoVit). Poster presented at: The Association for Research in Vision and Ophthalmology (ARVO) 2014 Annual Meeting; May 4-8, 2014; Orlando, Florida.



# Pale Disc Points to Trouble

An asymptomatic patient presented with optic disc pallor and asymmetric cupping. Neuroimaging found something more. **By Michael Trottni, OD, and Michael DelGiodice, OD**

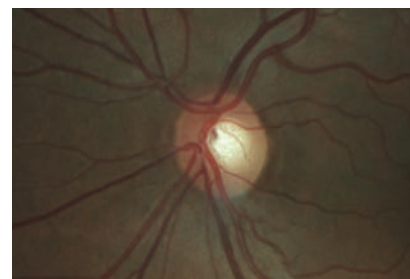
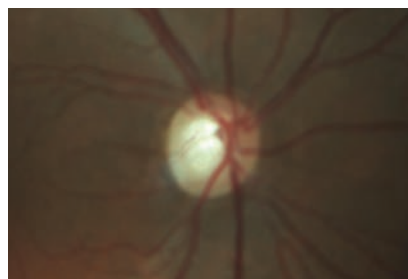
A 43-year-old white female presented for a routine examination. Her only complaint was near vision difficulty related to presbyopia. She had a history of breast cancer with mastectomy, for which she was taking tamoxifen. Her other medications included Lupron (leuprolide acetate, AbbVie) and vitamin D. Her past ocular, family and social history was unremarkable.

Her best-corrected visual acuity was 20/20 OD and OS. Ocular motility was full with no limitation, with no afferent pupillary defect, and she was orthophoric in primary and lateral gazes in both eyes. She noted 10/10 color plates in each eye.

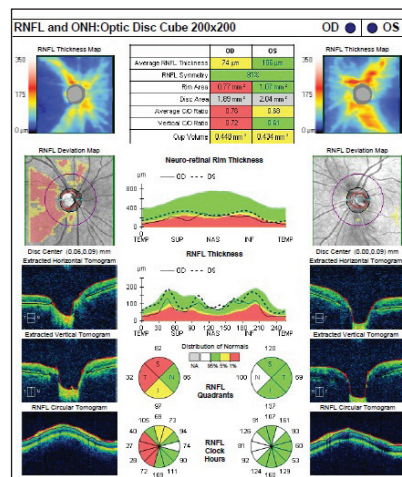
Intraocular pressure measured 15mm Hg OD and 16mm Hg OS. The anterior segment exam was unremarkable. Fundus exam showed cup-to-disc asymmetry OD>OS, and evidence of disc pallor in the right eye.

Although she was asymptomatic, we ordered spectral-domain optical coherence tomography (OCT) and visual field testing due to the presence of both cup asymmetry and optic nerve pallor. The SD-OCT showed significant nerve fiber layer thinning of the right disc, with moderate asymmetry compared to the left. Her left optic nerve was normal. Visual field showed subtle temporal field defects in the right eye that respected the vertical meridian. The left field was normal.

The findings of cupping and pallor, generalized depression of the



**Fundus exam shows asymmetric cupping, with the right eye (left) greater than the left eye (right), and evidence of disc pallor in the right eye.**



**SD-OCT shows significant nerve fiber layer thinning of the right disc, as well as moderate asymmetry compared to the left disc.**

nerve fiber layer and centralized temporal field defects respecting the vertical midline pointed to a non-glaucomatous etiology. Given her history and demographics, the differential diagnosis included demyelinating disease, a primary or metastatic intracranial space occupying lesion and immune-related optic neuropathy. Consequently, she was scheduled her for magnetic

resonance imaging (MRI) of the brain and orbits with and without contrast and fat suppression.

Imaging studies revealed a lobulated aneurysm on the right side in the region at or above the cavernous sinus, which compressed the right optic nerve.

The patient was referred to neurosurgery, where she had cerebral angiography that localized a bilobed right internal carotid artery para-ophthalmic aneurysm. The two lobes measured 8mm and 6mm. She underwent successful pipeline embolization of the aneurysm. As of her last follow-up, she was doing wonderfully. There was no further damage to her optic nerve.

## Discussion

Optic atrophy is caused by damage to ganglion cells and axons of the optic nerve.<sup>1</sup> This can be a result of ischemia, inflammation, compression, infection or trauma.<sup>1</sup> Ischemic optic neuropathy, optic neuritis and papilledema are the more common conditions that can lead to optic atrophy, although the complete list of differentials is extensive.



# Choose BAK-free TRAVATAN Z<sup>®</sup> Solution for sustained IOP lowering

Sustained **30%** IOP lowering  
at 12, 14, and 20 hours post-dose in a 3-month study<sup>1,2\*</sup>

**TRAVATAN Z<sup>®</sup> Solution has no FDA-approved therapeutic equivalent<sup>3</sup>**

Help patients start strong and stay on track with the  **Openings**  
Patient Support Program

#### INDICATIONS AND USAGE

TRAVATAN Z<sup>®</sup> (travoprost ophthalmic solution) 0.004% is indicated for the reduction of elevated intraocular pressure (IOP) in patients with open-angle glaucoma or ocular hypertension.

#### Dosage and Administration

The recommended dosage is 1 drop in the affected eye(s) once daily in the evening. TRAVATAN Z<sup>®</sup> Solution should not be administered more than once daily since it has been shown that more frequent administration of prostaglandin analogs may decrease the IOP-lowering effect.

TRAVATAN Z<sup>®</sup> Solution may be used concomitantly with other topical ophthalmic drug products to lower IOP. If more than 1 topical ophthalmic drug is being used, the drugs should be administered at least 5 minutes apart.

#### IMPORTANT SAFETY INFORMATION

##### Warnings and Precautions

**Pigmentation**—Travoprost ophthalmic solution has been reported to increase the pigmentation of the iris, periorbital tissue (eyelid), and eyelashes. Pigmentation is expected to increase as long as travoprost is administered. After discontinuation of travoprost, pigmentation of the iris is likely to be permanent, while pigmentation of the periorbital tissue and eyelash changes have been reported to be reversible in some patients. The long-term effects of increased pigmentation are not known. While treatment with TRAVATAN Z<sup>®</sup> Solution can be continued in patients who develop noticeably increased iris pigmentation, these patients should be examined regularly.

**Eyelash Changes**—TRAVATAN Z<sup>®</sup> Solution may gradually change eyelashes and vellus hair in the treated eye. These changes include increased length, thickness, and number of lashes. Eyelash changes are usually reversible upon discontinuation of treatment.

**Use With Contact Lenses**—Contact lenses should be removed prior to instillation of TRAVATAN Z<sup>®</sup> Solution and may be reinserted 15 minutes following its administration.

#### Adverse Reactions

The most common adverse reaction observed in controlled clinical studies with TRAVATAN Z<sup>®</sup> Solution was ocular hyperemia, which was reported in 30 to 50% of patients. Up to 3% of patients discontinued therapy due to conjunctival hyperemia. Ocular adverse reactions reported at an incidence of 5 to 10% in these clinical studies included decreased visual acuity, eye discomfort, foreign body sensation, pain, and pruritus. In postmarketing use with prostaglandin analogs, periorbital and lid changes including deepening of the eyelid sulcus have been observed.

#### Use in Specific Populations

Use in pediatric patients below the age of 16 years is not recommended because of potential safety concerns related to increased pigmentation following long-term chronic use.

**For additional information about TRAVATAN Z<sup>®</sup> Solution, please see the brief summary of Prescribing Information on the adjacent page.**

**\*Study Design:** Double-masked, randomized, parallel-group, multicenter non-inferiority comparison of the efficacy and safety of travoprost 0.004% preserved with benzalkonium chloride (BAK) to TRAVATAN Z<sup>®</sup> Solution after 3 months of treatment in patients with open-angle glaucoma or ocular hypertension. Baseline IOPs were 27.0 mm Hg (n=322), 25.5 mm Hg (n=322), and 24.8 mm Hg (n=322) at 8 AM, 10 AM, and 4 PM for TRAVATAN Z<sup>®</sup> Solution. At the end of Month 3, the TRAVATAN Z<sup>®</sup> Solution group had mean IOPs (95% CI) of 18.7 mm Hg (-0.4, 0.5), 17.7 mm Hg (-0.4, 0.6), and 17.4 mm Hg (-0.2, 0.8) at 8 AM, 10 AM, and 4 PM, respectively. Statistical equivalent reductions in IOP (95% confidence interval about the treatment differences were entirely within  $\pm 1.5$  mm Hg) were demonstrated between the treatments at all study visits during the 3 months of treatment.

**References:** 1. Data on file, 2013. 2. Lewis RA, Katz GJ, Weiss MJ, et al. Travoprost 0.004% with and without benzalkonium chloride: a comparison of safety and efficacy. *J Glaucoma*. 2007;16(11): 98-103. 3. Drugs@FDA. FDA Approved Drug Products: TRAVATAN Z. [www.accessdata.fda.gov/scripts/cder/drugsatfda/index.cfm?fuseaction=Search DrugDetails](http://www.accessdata.fda.gov/scripts/cder/drugsatfda/index.cfm?fuseaction=Search DrugDetails). Accessed July 31, 2014.

**Alcon**<sup>®</sup>  
a Novartis company

© 2014 Novartis 9/14 TRV14066JAD

**TRAVATAN Z**<sup>®</sup>

(travoprost ophthalmic solution) 0.004%

# TRAVATAN Z<sup>®</sup>

(travoprost ophthalmic solution) 0.004%

## BRIEF SUMMARY OF PRESCRIBING INFORMATION

### INDICATIONS AND USAGE

TRAVATAN Z<sup>®</sup> (travoprost ophthalmic solution) 0.004% is indicated for the reduction of elevated intraocular pressure in patients with open-angle glaucoma or ocular hypertension.

### DOSAGE AND ADMINISTRATION

The recommended dosage is one drop in the affected eye(s) once daily in the evening. TRAVATAN Z<sup>®</sup> (travoprost ophthalmic solution) should not be administered more than once daily since it has been shown that more frequent administration of prostaglandin analogs may decrease the intraocular pressure lowering effect.

Reduction of the intraocular pressure starts approximately 2 hours after the first administration with maximum effect reached after 12 hours.

TRAVATAN Z<sup>®</sup> Solution may be used concomitantly with other topical ophthalmic drug products to lower intraocular pressure. If more than one topical ophthalmic drug is being used, the drugs should be administered at least five (5) minutes apart.

### CONTRAINDICATIONS

None

### WARNINGS AND PRECAUTIONS

#### Pigmentation

Travoprost ophthalmic solution has been reported to cause changes to pigmented tissues. The most frequently reported changes have been increased pigmentation of the iris, periorbital tissue (eyelid) and eyelashes. Pigmentation is expected to increase as long as travoprost is administered. The pigmentation change is due to increased melanin content in the melanocytes rather than to an increase in the number of melanocytes. After discontinuation of travoprost, pigmentation of the iris is likely to be permanent, while pigmentation of the periorbital tissue and eyelash changes have been reported to be reversible in some patients. Patients who receive treatment should be informed of the possibility of increased pigmentation. The long term effects of increased pigmentation are not known.

Iris color change may not be noticeable for several months to years. Typically, the brown pigmentation around the pupil spreads concentrically towards the periphery of the iris and the entire iris or parts of the iris become more brownish. Neither nevi nor freckles of the iris appear to be affected by treatment. While treatment with TRAVATAN Z<sup>®</sup> (travoprost ophthalmic solution) 0.004% can be continued in patients who develop noticeably increased iris pigmentation, these patients should be examined regularly.

#### Eyelash Changes

TRAVATAN Z<sup>®</sup> Solution may gradually change eyelashes and vellus hair in the treated eye. These changes include increased length, thickness, and number of lashes. Eyelash changes are usually reversible upon discontinuation of treatment.

#### Intraocular Inflammation

TRAVATAN Z<sup>®</sup> Solution should be used with caution in patients with active intraocular inflammation (e.g., uveitis) because the inflammation may be exacerbated.

#### Macular Edema

Macular edema, including cystoid macular edema, has been reported during treatment with travoprost ophthalmic solution. TRAVATAN Z<sup>®</sup> Solution should be used with caution in aphakic patients, in pseudophakic patients with a torn posterior lens capsule, or in patients with known risk factors for macular edema.

#### Angle-closure, Inflammatory or Neovascular Glaucoma

TRAVATAN Z<sup>®</sup> Solution has not been evaluated for the treatment of angle-closure, inflammatory or neovascular glaucoma.

#### Bacterial Keratitis

There have been reports of bacterial keratitis associated with the use of multiple-dose containers of topical ophthalmic products. These containers had been inadvertently contaminated by patients who, in most cases, had a concurrent corneal disease or a disruption of the ocular epithelial surface.

#### Use with Contact Lenses

Contact lenses should be removed prior to instillation of TRAVATAN Z<sup>®</sup> Solution and may be reinserted 15 minutes following its administration.

### ADVERSE REACTIONS

#### Clinical Studies Experience

Because clinical studies are conducted under widely varying conditions, adverse reaction rates observed in the clinical studies of a drug cannot be directly compared to rates in the clinical studies of another drug and may not reflect the rates observed in practice. The most common adverse reaction observed in controlled clinical studies with TRAVATAN<sup>®</sup> (travoprost ophthalmic solution) 0.004% and TRAVATAN Z<sup>®</sup> (travoprost ophthalmic solution) 0.004% was ocular hyperemia which was reported in 30 to 50% of patients. Up to 3% of patients discontinued therapy due to conjunctival hyperemia. Ocular adverse reactions reported at an incidence of 5 to 10% in these clinical studies included decreased visual acuity, eye discomfort, foreign body sensation, pain and pruritus. Ocular adverse reactions reported at an incidence of 1 to 4% in clinical studies with TRAVATAN<sup>®</sup> or TRAVATAN Z<sup>®</sup> Solutions included abnormal vision, blepharitis, blurred vision, cataract, conjunctivitis, corneal staining, dry eye, iris discoloration, keratitis, lid margin crusting, ocular inflammation, photophobia, subconjunctival hemorrhage and tearing.

Nonocular adverse reactions reported at an incidence of 1 to 5% in these clinical studies were allergy, angina pectoris, anxiety, arthritis, back pain, bradycardia, bronchitis, chest pain, cold/flu syndrome, depression, dyspepsia, gastrointestinal disorder, headache, hypercholesterolemia, hypertension, hypotension, infection, pain, prostate disorder, sinusitis, urinary incontinence and urinary tract infections.

In postmarketing use with prostaglandin analogs, periorbital and lid changes including deepening of the eyelid sulcus have been observed.

### USE IN SPECIFIC POPULATIONS

#### Pregnancy

Pregnancy Category C

Teratogenic effects: Travoprost was teratogenic in rats, at an intravenous (IV) dose up to 10 mcg/kg/day (250 times the maximal recommended human ocular dose (MRHOD), evidenced by an increase in the incidence of skeletal malformations as well as external and visceral malformations, such as fused sternebrae, domed head and hydrocephaly. Travoprost was not teratogenic in rats at IV doses up to 3 mcg/kg/day (75 times the MRHOD), or in mice at subcutaneous doses up to 1 mcg/kg/day (25 times the MRHOD). Travoprost produced an increase in post-implantation losses and a decrease in fetal viability in rats at IV doses > 3 mcg/kg/day (75 times the MRHOD) and in mice at subcutaneous doses > 0.3 mcg/kg/day (7.5 times the MRHOD).

In the offspring of female rats that received travoprost subcutaneously from Day 7 of pregnancy to lactation Day 21 at doses of  $\geq 0.12$  mcg/kg/day (3 times the MRHOD), the incidence of postnatal mortality was increased, and neonatal body weight gain was decreased. Neonatal development was also affected, evidenced by delayed eye opening, pinna detachment and preputial separation, and by decreased motor activity.

There are no adequate and well-controlled studies of TRAVATAN Z<sup>®</sup> (travoprost ophthalmic solution) 0.004% administration in pregnant women. Because animal reproductive studies are not always predictive of human response, TRAVATAN Z<sup>®</sup> Solution should be administered during pregnancy only if the potential benefit justifies the potential risk to the fetus.

#### Nursing Mothers

A study in lactating rats demonstrated that radiolabeled travoprost and/or its metabolites were excreted in milk. It is not known whether this drug or its metabolites are excreted in human milk. Because many drugs are excreted in human milk, caution should be exercised when TRAVATAN Z<sup>®</sup> Solution is administered to a nursing woman.

#### Pediatric Use

Use in pediatric patients below the age of 16 years is not recommended because of potential safety concerns related to increased pigmentation following long-term chronic use.

#### Geriatric Use

No overall clinical differences in safety or effectiveness have been observed between elderly and other adult patients.

#### Hepatic and Renal Impairment

Travoprost ophthalmic solution 0.004% has been studied in patients with hepatic impairment and also in patients with renal impairment. No clinically relevant changes in hematology, blood chemistry, or urinalysis laboratory data were observed in these patients.

### NONCLINICAL TOXICOLOGY

#### Carcinogenesis, Mutagenesis, Impairment of Fertility

Two-year carcinogenicity studies in mice and rats at subcutaneous doses of 10, 30, or 100 mcg/kg/day did not show any evidence of carcinogenic potential. However, at 100 mcg/kg/day, male rats were only treated for 82 weeks, and the maximum tolerated dose (MTD) was not reached in the mouse study. The high dose (100 mcg/kg) corresponds to exposure levels over 400 times the human exposure at the maximum recommended human ocular dose (MRHOD) of 0.04 mcg/kg, based on plasma active drug levels. Travoprost was not mutagenic in the Ames test, mouse micronucleus test or rat chromosome aberration assay. A slight increase in the mutant frequency was observed in one of two mouse lymphoma assays in the presence of rat S-9 activation enzymes.

Travoprost did not affect mating or fertility indices in male or female rats at subcutaneous doses up to 10 mcg/kg/day [250 times the maximum recommended human ocular dose of 0.04 mcg/kg/day on a mcg/kg basis (MRHOD)]. At 10 mcg/kg/day, the mean number of corpora lutea was reduced, and the post-implantation losses were increased. These effects were not observed at 3 mcg/kg/day (75 times the MRHOD).

### PATIENT COUNSELING INFORMATION

#### Potential for Pigmentation

Patients should be advised about the potential for increased brown pigmentation of the iris, which may be permanent. Patients should also be informed about the possibility of eyelid skin darkening, which may be reversible after discontinuation of TRAVATAN Z<sup>®</sup> (travoprost ophthalmic solution) 0.004%.

#### Potential for Eyelash Changes

Patients should also be informed of the possibility of eyelash and vellus hair changes in the treated eye during treatment with TRAVATAN Z<sup>®</sup> Solution. These changes may result in a disparity between eyes in length, thickness, pigmentation, number of eyelashes or vellus hairs, and/or direction of eyelash growth. Eyelash changes are usually reversible upon discontinuation of treatment.

#### Handling the Container

Patients should be instructed to avoid allowing the tip of the dispensing container to contact the eye, surrounding structures, fingers, or any other surface in order to avoid contamination of the solution by common bacteria known to cause ocular infections. Serious damage to the eye and subsequent loss of vision may result from using contaminated solutions.

#### When to Seek Physician Advice

Patients should also be advised that if they develop an intercurrent ocular condition (e.g., trauma or infection), have ocular surgery, or develop any ocular reactions, particularly conjunctivitis and eyelid reactions, they should immediately seek their physician's advice concerning the continued use of TRAVATAN Z<sup>®</sup> Solution.

#### Use with Contact Lenses

Contact lenses should be removed prior to instillation of TRAVATAN Z<sup>®</sup> Solution and may be reinserted 15 minutes following its administration.

#### Use with Other Ophthalmic Drugs

If more than one topical ophthalmic drug is being used, the drugs should be administered at least five (5) minutes between applications.

#### Rx Only

U.S. Patent Nos. 5,631,287; 5,889,052; 6,011,062; 6,235,781; 6,503,497; and 6,849,253

**Alcon**<sup>®</sup>

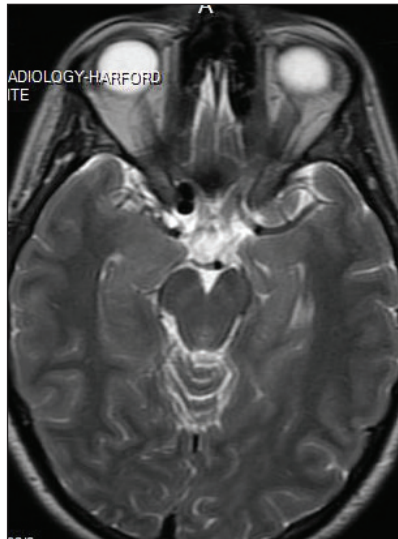ALCON LABORATORIES, INC.  
Fort Worth, Texas 76134 USA  
© 2006, 2010, 2011, 2012 Novartis  
9/14 TRV14066JAD



Determining the etiology of optic atrophy can be challenging, as there are multiple causes. A careful history and examination often pinpoints the cause, but unexplained optic atrophy needs to be explored. In one study, compressive lesions were the etiology in 20% of patients with isolated and unexplained optic atrophy.<sup>2</sup> As a result, neuroimaging is warranted in all patients with unexplained optic atrophy. The preferred modality is MRI of the brain and orbits with and without contrast and with fat suppression.<sup>2</sup> If there is a contraindication to MRI, computed tomography (CT) may be used instead.<sup>2</sup>

Lab testing is of low yield unless historical or exam elements suggest an underlying etiology.<sup>2</sup> Common lab tests for evaluation of optic atrophy include Lyme titer, fluorescent treponemal antibody absorption (FTA-ABS), rapid plasma reagin (RPR), angiotensin converting enzyme (ACE), *Bartonella* titer, antinuclear antibody (ANA), erythrocyte sedimentation rate (ESR) and C-reactive protein (CRP). The recommendation when considering lab studies is to tailor based on suggestive history, exam findings or endemic locations that may suggest a greater likelihood of diagnosing conditions such as syphilis, Lyme disease or sarcoidosis.<sup>2</sup> If the patient has a prior diagnosis of optic atrophy, be sure to obtain past medical records, imaging reports or laboratory studies, and document those in the patient's chart.

This case also highlights the importance of distinguishing glaucomatous optic neuropathy (GON) from non-glaucomatous optic neuropathy (NGON), the latter of which was seen in our patient. Optic nerve cupping is most frequently caused by glaucoma, yet compressive lesions can cause sec-



**MRI shows a lobulated aneurysm on the right side in the region at or above the cavernous sinus, which compressed the right optic nerve.**

ondary optic disc excavation and mimic glaucoma.<sup>1</sup> While cupping asymmetry has a high predictive value of GON, the key clinical finding that helped distinguish GON from NGON in this patient was pallor of the neuroretinal rim, which is 94% specific for a non-glaucomatous etiology.<sup>3,4</sup>

Ancillary studies that helped to confirm NGON were the use of formal visual field testing and SD-OCT. Visual fields are an invaluable asset in distinguishing glaucoma from neuro-ophthalmic-related optic nerve disorders. In the setting of presumed optic atrophy, a vertically-oriented centralized temporal field defect indicates an etiology other than glaucoma and prompts further investigation. Additionally, SD-OCT has been shown to distinguish glaucomatous from compressive optic neuropathies by analyzing patterns of nerve fiber layer loss. Specifically, cupping from NGON is associated with thinner nasal and temporal sectors when compared to that

of glaucomatous disease.<sup>5</sup> In our patient, the SD-OCT revealed significant nerve fiber layer loss in all quadrants when compared to the fellow eye. Lastly, her younger age, normotensive and symmetric IOPs and healthy disc in the fellow eye were all red flags for NGON.

Assuming there have been no acute vision changes or neurologic deficits, working up optic atrophy is generally non-urgent because the atrophic process takes a minimum of six weeks to develop. So, visual field, OCT and MRI/laboratory studies can be obtained within a few weeks.

This case highlights the importance of evaluating unexplained optic atrophy and differentiating GON from NGON. In-office assessment of the disc with digital photography, visual field testing and SD-OCT are invaluable in differentiating glaucoma from alternative neuro-ophthalmic pathology.

In this patient's case, while there were subtle findings of pallor, there was no afferent pupillary defect, the visual acuity and color vision were normal and the patient was asymptomatic. So, in the presence of optic nerve asymmetry, consider alternative diagnoses and perform a detailed inspection of the neuroretinal rim for color changes that are not consistent with a glaucomatous process. ■

1. Fraser CL, White AJ, Plant GT, Martin KR. Optic nerve cupping and the neuro-ophthalmologist. *J Neuroophthalmol*. 2013 Dec;33(4):377-89.
2. Lee AG, Chau FY, Golnik KC, et al. The diagnostic yield of the evaluation for isolated unexplained optic atrophy. *Ophthalmology*. 2005 May;112(5):757-9.
3. Sharma BD, Chaturvedi RP. Disc-cup asymmetry in normal and chronic simple glaucoma. *Indian J Ophthalmol*. 1982 May;30(3):133-4.
4. Miller NR, Newman NJ, Bioussé V, Kerrison JB, Walsh & Hoyt's Clinical Neuro-Ophthalmology: The Essentials. 2nd ed. Philadelphia: Lippincott; 2007.
5. Danesh-Meyer HV, Yap J, Frampton C, Savino PJ. Differentiation of compressive from glaucomatous optic neuropathy with spectral-domain optical coherence tomography. *Ophthalmology*. 2014 Aug;121(8):1516-23.

# Risky Business

If you understand the influence of predisposing risk factors on dry eye, you'll improve your odds of successful diagnosis. **By Paul M. Karpecki, OD**

Clinicians are well aware of the hallmark symptoms of dry eye, but if you based your decision to treat solely on symptoms, you might be missing some diagnoses; research shows that fewer than 60% of patients with dry eye disease (DED) are symptomatic.<sup>1</sup> Often overlooked, but equally critical, is an awareness of predisposing factors that raise a patient's risk level. Connecting these two is one of the most important steps in developing a successful ocular surface disease protocol.

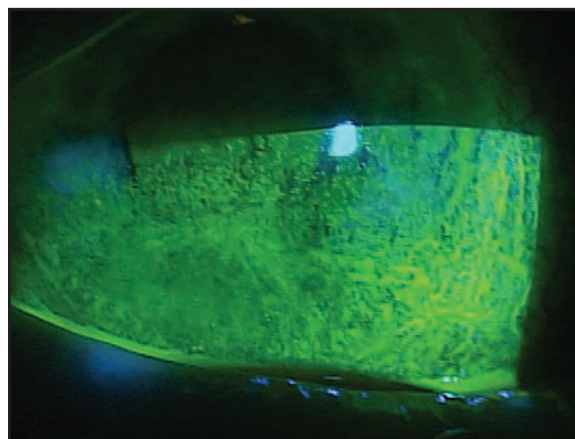
This article will consider how predisposing factors combined with key findings become paramount to making a proper diagnosis and eventual treatment.

## When Signs and Symptoms Don't Correlate

In most conditions we encounter as optometrists, symptoms are paramount. For example, we judge our management of allergic conjunctivitis to be a success when a patient responds to treatment with an absence of itching, redness and swelling. Adopting this strategy—

basing success on the relief of symptoms—works well for most ocular disease states and results in happy patients and a successful clinical outcome. But in DED, many patients with symptoms of dryness, grittiness, burning or stinging may not actually have “dry eyes,” and thus a treatment that targets dry eye would likely not alleviate symptoms.<sup>2</sup> The result would be a patient returning with the same symptoms, and often more frustrated than before. They may even seek out another doctor.

For example, a patient experiencing dryness, fluctuating vision and gritty, burning eyes (especially late in the day or while using a computer) may actually have convergence insufficiency, vertical disparity computer vision syndrome or other eye alignment issues.<sup>3</sup> This patient would receive a much bet-



**Advanced neurotrophic keratitis, a condition that can decrease corneal sensitivity—and thus reduce symptomatic complaints. That could lead to a missed diagnosis.**

ter response from visual training or prism in their spectacles, or both, than any dry eye therapy. Other non-DED causes of similar symptoms include anterior blepharitis etiologies (e.g., *Demodex*), contact lens solution issues (e.g., corneal infiltrates), allergic conjunctivitis, epithelial membrane dystrophy/mild recurrent corneal erosion, pingueculitis, giant papillary conjunctivitis, Salzmann's nodular degeneration, conjunctivochalasis and others.<sup>4,8</sup>

In some circumstances, a patient with one of these conditions may experience mild resolution of symptoms when treated with classic dry eye therapies, but in many cases it will never fully resolve with an approach that targets DED.

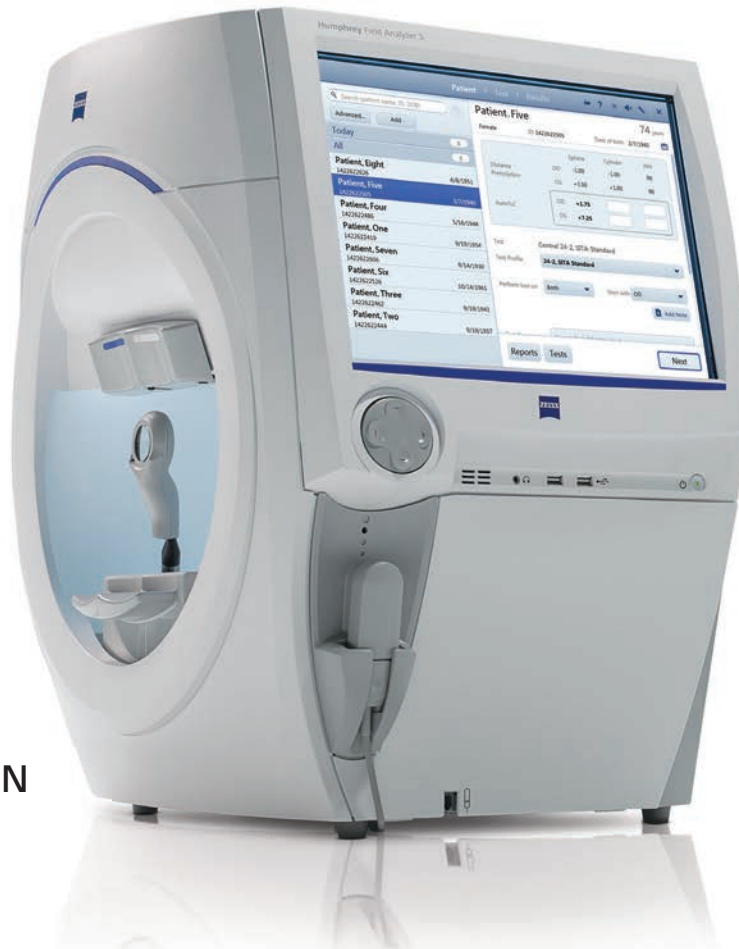At the other extreme, some of the worst cases of DED actually present with little to no symptoms. A patient suffering from severe dry eye who is largely asymptomatic (other

### Blur: Consistently Present, Consistently Misconstrued

Perhaps the only key symptom reported with almost all levels of dry eye disease is blurred vision, whether it's transient blurred vision secondary to tear film instability in early disease or persistent blurred vision secondary to central corneal staining in advanced disease. The problem: most clinicians don't consider dry eye as the primary diagnosis when they encounter a complaint of blurred vision. If the patient can be corrected to 20/20, that is often assumed to be the solution and the patient receives a non-medical diagnosis; in actuality, dry eye is perhaps the most common cause of blurred vision—and is truly a medical condition.

# The moment your perimeter accelerates clinic flow. **The NEW Humphrey Field Analyzer 3.**

**NEW!**  
Liquid Lens  
Technology



// **INNOVATION**  
MADE BY ZEISS

ZEISS introduces the NEW HFA3 with Liquid Lens technology that combines the power of many lenses into one.\*  
Discover how the new HFA3 is faster, easier and more reliable than ever – and see how Liquid Lens technology works.

- Accelerate clinic flow
- Reduce errors
- Improve confidence in test results

Visit [www.zeiss.com/HFA3](http://www.zeiss.com/HFA3).

**Come experience the NEW ZEISS Humphrey Field Analyzer 3  
at Vision Expo East, Booth LP7403.**

Carl Zeiss Meditec, Inc. 800.342.9821 [www.meditec.zeiss.com](http://www.meditec.zeiss.com)  
HFA.6832 Rev B ©2015 Carl Zeiss Meditec, Inc. All rights reserved. Specification subject to change.

\*Some patients may require a separate lens. Liquid Trial Lens available on the HFA3 model 860.



We make it visible.

than perhaps blurred vision from the advanced ocular surface disease findings) likely has a neurotrophic cornea.<sup>9</sup> These include patients with active Sjögren's syndrome, diabetes and those in the immediate aftermath of a herpes simplex keratitis, herpes zoster outbreak, a course of chemotherapy or radiation treatment. New research into neurotrophic keratitis shows a decreased corneal sensitivity secondary to decreased sub-basal corneal nerve length.<sup>10</sup> This decreased sensitivity results in loss of sensation and a decreased blink rate, which only further exacerbates the condition.<sup>11</sup>

These patients are most in need of care; if symptoms were your sole determinant, they would be missed. Unfortunately, many such patients are overlooked, frustrated and seeking doctors who understand ocular surface disease management. A recent Harris Interactive study showed that only 29% of patients with true DED felt their optometrist provided adequate care and knowledge of their disease.

## Suspicious Minds

It is a foundational principle of medical care that a proper diagnosis is the most important step to treatment. But if symptoms are not reliable, how might we make the proper diagnosis?

One way to raise your probability of success is to employ advanced testing such as osmolarity, meibography, true dry eye staining, meibomian gland expression, blink analysis and other precise measures now clinically available.<sup>12</sup> But as many doctors just starting out may not have access to these technologies, another important determinant is to look at the number of predisposing factors a patient may display.

This approach alone may not be 100% accurate in establishing a

## Key Predisposing Factors

- Advanced age
- Female gender
- Hormone replacement therapy
- Systemic antihistamine use
- Lack of healthy essential fatty acid intake (e.g. omega-3 fatty acids)
- Connective tissue disorders
- Refractive surgery
- Androgen deficiency
- Contact lens use
- Rosacea
- Certain medications (e.g., some antidepressants, diuretics, beta-blockers, isotretinoin)
- Diabetes
- Chemotherapy
- Low humidity environments
- Cigarette smoking

Source: *The Dry Eye Workshop*

diagnosis, but combined with testing, it can help confirm the disease.

A patient with a significant number of these predisposing factors may heighten the clinician's suspicion of DED. When the level of suspicion is commensurate with risk factors, implementing and understanding dry eye diagnostics can point to the cause and true diagnosis.

## Advanced Testing Options

As an example, I recall using osmolarity testing when it was first approved and had a series of patients with consistently normal osmolarity measurements. I'd look at the patient and ask them about their symptoms; they described their eyes as dry, gritty and burning with fluctuating vision that worsened late in the day and especially while reading or spending significant time on a computer. An expert in the field of binocular vision and eye alignment enlightened me and visited my clinic to help. He discovered that nine out of 10 patients that day had eye alignment issues, and he was able to

resolve all of their symptoms with appropriate binocular vision management. I had a whole new respect for the accuracy of these advanced testing options and a newfound humility about what I thought was my advanced clinical knowledge in the field.

Since then, I've gleaned many other insights that have changed how we run our ocular surface disease clinic to achieve highly successful outcomes in some of the most advanced OSD referrals.

Dry eye is a complex condition to manage. But the critical first step is identification—with as much specificity as possible. Understanding the predisposing factors, realizing that signs and symptoms may not align and learning about new diagnostic technologies will aid clinicians in making the right diagnosis.

From there, an appropriate treatment becomes much more likely, resulting in successfully managed OSD patients. ■

1. Bron AJ, Tomlinson A, Foulks GN. Rethinking dry eye disease: a perspective on clinical implications. *Ocul Surf*. 2014 Apr;12(2 Suppl):S1-31.
2. Sullivan BD, Crews LA, Messmer EM. Correlations between commonly used objective signs and symptoms for the diagnosis of dry eye disease: clinical implications. *Acta Ophthalmol*. 2014 Mar;92(2):161-6.
3. Jaiinder B, Naveen N, Renu TB. Computer vision syndrome: A review. *Journal of Clinical Ophthalmol*. 2014;2(1):61-8
4. Guillon M, Maissa C, Wong S. Symptomatic relief associated with eyelid hygiene in anterior blepharitis and MGD. *Eye Contact Lens*. 2012 Sep;38(5):306-12.
5. Sankaridurg PR, Sweeney DF, Holden BA, et al. Comparison of adverse events with daily disposable hydrogels and spectacle wear: results from a 12-month prospective clinical trial. *Ophthalmology*. 2003 Dec;110(12):2327-34.
6. Hom MM, Nguyen AL, Bielory L. Allergic conjunctivitis and dry eye syndrome. *Ann Allergy Asthma Immunol*. 2012 Mar;108(3):163-6
7. Asbell PA, Torres MA. Therapeutic dilemmas in external ocular diseases. *Drugs*. 1991 Oct;42(4):606-15.
8. Balci O. Clinical characteristics of patients with conjunctivochalasis. *Clin Ophthalmol*. 2014 Aug;8:1655-60
9. Sacchetti M, Lambiase A. Diagnosis and management of neurotrophic keratitis. *Clin Ophthalmol*. 2014 Mar;8:571-9.
10. Lambiase A, Sacchetti M, Mastropasqua A, et al. Corneal changes in neurosurgically induced neurotrophic keratitis. *JAMA Ophthalmol*. 2013 Dec;131(12):1547-53.
11. Gillan WDH. Repeatability and reproducibility of Tearlab. *S Afr Optom*. 2013;72(1):19-24.
12. Shaheen BS, Bakir M, Jain S. Corneal nerves in health and disease. *Surv Ophthalmol*. 2014 May-Jun;59(3):263-85.
13. Dry Eye Workshop. *The Ocular Surface Journal*. April 2007 5(2).

# THE **STRENGTH** TO HEAL

*our nation's defenders.*

As an optometrist and officer on the U.S. Army Reserve health care team, your responsibilities will include caring for Soldiers when they need it most. You'll work alongside dedicated professionals in a collaborative environment. You'll utilize the most advanced technology and enjoy the resources of one of the most comprehensive health care organizations in the world. You'll make a difference.

To learn more, call 800-431-6731 or visit [healthcare.goarmy.com/at66](http://healthcare.goarmy.com/at66)





# Detached Staff, Detached Retina

A poorly handled phone call likely worsened this young woman's outcome. Don't let this happen to your patients. **Edited by Paul C. Ajamian, OD**

**Q** A 21-year-old white female, a regular contact lens patient, called my office with a complaint of recent-onset blurry vision. My office was booked up that day, and my front desk staff recommended the patient see her primary care doctor. We later learned that the primary care doctor told the patient she probably had a migraine.

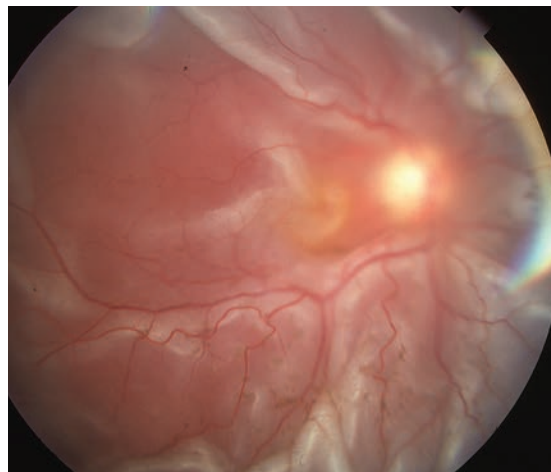
Afterward, I happened to check this patient's chart and saw that she had a history of lattice degeneration. Now I'm concerned. What can I do to make sure such a snafu doesn't happen again?

**A** "No matter what the patient's complaint is—even if it's itchy eyes—the staff should pull up the record at the time of the phone call," says Steven Holbrook, OD, of The Eye Center of Southern Indiana.

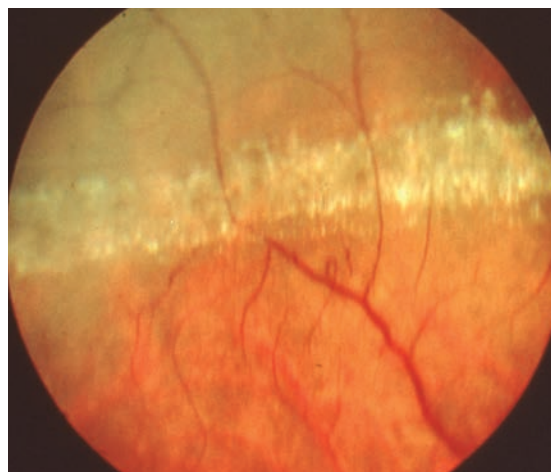Dr. Holbrook recounts the situation of a similar patient who wound up at his secondary-care center upon referral from the ER. In this young woman's case, she too had called her eye doctor's office with a complaint of sudden loss of vision and was referred to her PCP on suspicion of migraine.

The patient's symptoms worsened over the weekend and she went to the ER. A CT scan performed at the ER was negative and she was referred to Dr. Holbrook's practice.

"When she came in to my office on Monday, I found she had a macula-off retinal detachment with hand motion vision. In her other eye, she had extensive lattice degeneration," he says.



**The patient called complaining of sudden loss of vision. Turned out, she had a retinal detachment.**



**In the patient's other eye, she had extensive lattice degeneration.**

Dr. Holbrook sent the patient to a retina specialist, who performed a scleral buckle the next day. At the patient's most recent follow-up visit, her visual acuity had improved to 20/150.

Had her original eye doctor seen

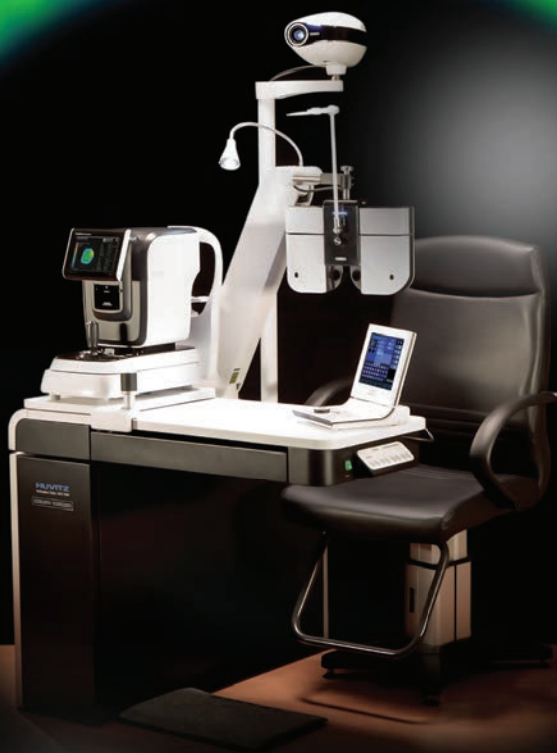the patient that day, the situation might have turned out much better.

As it is, "I feel so bad for this girl. In all likelihood, she's going to have permanent vision loss," Dr. Holbrook says. In these cases, every clinician should be able to look back at an old record and see the results of a dilated peripheral retinal exam.

Also, be sure to train your staff—with regular reminders—to check the record of every patient before making a recommendation, Dr. Holbrook says.

And if there is something in the chart that raises a red flag, err on the side of bringing the patient in! But in the hopefully rare instance where you are unable to see the patient, send him or her to your nearest comanagement center. (Optometrists

have worked for many years to gain diagnostic and therapeutic privileges, so we shouldn't abdicate them to someone else at the patient's expense.) Both the patient and your practice will be the victors with this strategy. ■



# COMPLETE PATIENT LUXURY

DIGITAL REFRACTION SYSTEM

DON'T WAIT FOR EXPO PRICES, CONTACT US FOR DETAILS

1.800.COBURN1  
COBURNTECHNOLOGIES.COM

VEE 2015 BOOTH LP7519  
NEW YORK, NY MARCH 20-22

**eyeVOTE**  
READER'S CHOICE 2014  
OPTICAL EQUIPMENT & SUPPLIES BRAND: SURFACING

**COBURN  
TECHNOLOGIES**



# How to Educate Patients About the Dangers of HARMFUL LIGHT

By Kirk Smick, OD

From the moment we wake up until we fall back to sleep, most of us are using some sort of digital device, including tablets, laptops and smartphones. In fact, nearly one-third of our adult patients spend more than half of their waking hours using a digital device.<sup>1</sup>

While the benefits of digital technology can be life-changing, so can the hazards. Unfortunately, most adults (72.5%) are unaware of the potential dangers of blue light.<sup>1</sup> In the following pages, I'll review the latest research on the risks posed by blue light exposure, examine its increasing presence in our everyday lives, and provide practical advice on what optometrists can do to better educate patients about protection.

## THE ROLE OF LIGHT IN OUR LIVES

Misunderstandings abound with respect to the role that light plays in both helping and harming us. In fact, light is a biological requirement essential to health, and it plays an essential role in visual and systemic functions.

From the perspective of sight and visual functioning, light is essential for us to see and recognize colors, and it also plays a key role in contrast sensitivity. In particular, Blue-Turquoise light that ranges from 465 nm to 495 nm is essential to our vision, as it adjusts the size of the pupil to allow enough light through. Any way you look at it, light helps in providing visual acuity; without enough of it, vision is affected and is not clear.

Light is also necessary for various nonvisual functions of the body. It's

well known that some sun exposure is vital as it delivers vitamin D to the body. Beyond basic sunlight requirements, however, Blue-Turquoise light aids in the regulation of our sleep/wake cycle and also helps us distinguish day from night. This in turn, enables us to maintain and regulate memory, mood and hormonal balance.

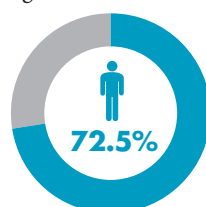
## NOT ALL LIGHT IS CREATED EQUAL

Although some light is good, too much can lead to cumulative damage to the eye tissues. The damaging effects of ultraviolet light on the cornea and the lens are well-established. Many of our patients are familiar with the potential dangers of ultraviolet light, however, very few patients are aware that certain wavelengths of visible light could also damage their eyes.

Even within the eyecare profession, we've questioned and have sought to understand the wavelengths at which blue light can cause damage. This is especially

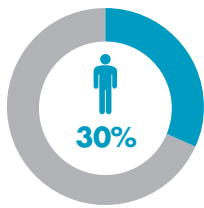important because, while only 1 percent of ultraviolet radiation reaches the retina in adults, visible blue light easily penetrates to the retina<sup>2</sup> and can cause oxidative stress in both the photoreceptor outer segment and the retinal pigment epithelium. As a result, increasing attention is being paid to blue light—how its cumulative effects can cause damage to the retina and its implications in the development of age-related macular degeneration (AMD).<sup>3-5</sup>

In 2008, the Paris Vision Institute began ground-breaking research to better understand blue light.<sup>6</sup> To determine whether specific bands within the Blue-Violet spectrum are responsible for blue light's phototoxic effects on the retinal pigment epithelium (RPE), researchers developed a unique illumination system that allowed cultured porcine retinal cells to be exposed to narrow (10-nm) bands of light at moderate irradiances normalized to typical retinal sunlight exposure. Using this test system, it was discovered that RPE phototoxicity was concentrated in a relatively narrow band. They found that maximum cell damage occurs from 415 nm to 455 nm, with a peak at 435 nm ± 20 nm. This damaging band of light was termed Blue-Violet light and therefore, is a risk factor for age-related macular degeneration.



72.5% of adults are unaware of the potential dangers of blue light to eyes.<sup>1</sup>





Nearly one-third of adults (30%) spend more than half their waking hours (9+) using a digital device.<sup>1</sup>

### THE Pervasiveness of Patient Exposure to Blue Light

Unfortunately, exposure to harmful blue light is almost unavoidable. Many Americans have made the switch to new energy-saving bulbs in their homes and offices. This, together with the increasing use of smartphones, tablets and laptops, is causing a rise in blue light exposure.

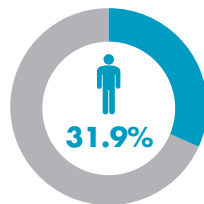According to the literature, the amount of blue light from light-emitting diode (LED) and compact fluorescent light (CFL) sources is substantial and can pose a risk of retinal damage to the eye.<sup>7</sup> Approximately 26 percent of the light from the energy-efficient and increasingly popular CFLs is in the blue portion of the spectrum, and 35 percent of the optical radiation from cool white LEDs is blue.<sup>8</sup>

Similarly, there is no question that digital devices emit blue light, but just how much of it are patients being exposed to? The Vision Council recently released its third annual survey to examine the increasing usage of digital devices and consumer knowledge about its impact on vision.<sup>1</sup> Nationwide, 9,749 adults participated in the survey. The findings show a stunning increase in the everyday use of digital devices across all age groups.<sup>1</sup> As the 2015 report reveals, on average, more than nine in 10 adults (93.3%) spend more than two hours each day using a digital device, and this is taking a significant toll on patients' eyes.

Specifically, nearly seven in 10 millennials (born 1981 to 1996) report symptoms of digital eye strain, with more than 37 percent spending at least nine hours each day on digital devices.<sup>1</sup> In the generation X group (born 1965 to 1980), nearly one-third spends at least nine hours each day on digital devices and six in 10 report symptoms of digital eye strain.<sup>1</sup> Kids and baby boom-

ers are likewise engaged in long hours of digital device use. One in four baby boomers spend at least nine hours each day on digital devices.<sup>9</sup> And, among children, one in four kids spend more than three hours a day using digital devices,<sup>1</sup> despite reports that too much screen time may cause accelerated myopia.<sup>10</sup>

Patients are being exposed to blue light in their homes and in their everyday lives at higher levels than ever before. Since these levels will only continue to rise in the coming years,<sup>11</sup> it's time we do something about it. The connection between blue light and ocular diseases, such as AMD, makes it imperative for us to educate patients and help



31.9% of adults do not take any action to reduce symptoms of digital eye strain.<sup>1</sup>

them protect their eyes from these potentially damaging elements.

### INTERVENTION

In addition to teaching patients about ergonomics and offering strategies for reducing digital eye strain, we now can also confidently offer lens treatments that limit the amount of blue light that penetrates to the eyes. The early blue blockers typically featured amber lenses that filtered out 100 percent of blue light. More recently introduced melanin-tinted blue blockers have advanced and are designed to protect the eyes from blue light, improve contrast, reduce eye fatigue and maintain color balance. However, these melanin lenses deflect 45 percent of the blue light spectrum, including both harmful Blue-Violet and

beneficial Blue-Turquoise light.

A newer choice was inspired by the 2008 research out of Paris that identified the narrow Blue-Violet band at which most RPE phototoxicity occurs. This knowledge paved the way for selective photofiltration: the creation of lenses that reduce the level of exposure to the harmful portion of the Blue-Violet spectrum while permitting the rest of the visible spectrum to enter the eye at a normal level. Thus, the eye's necessary visual and nonvisual functions can be maintained while exposure to hazardous wavelengths is reduced. The lens that was born of this research was Crizal® Prevensia™.

Crizal Prevensia No-Glare lenses are able to deflect up to 20 percent of the harmful Blue-Violet light that our patients are exposed to on a daily basis. The Paris Vision Institute's *in vitro* study showed that this amount of deflection reduced retinal cell death in porcine cells by an impressive 25 percent.<sup>12</sup>

### THE NEW NORMAL

Make no mistake, digital devices are part of our lives and are here to stay. By 2020, it is estimated that 90 percent of all light sources will be based on LED products. Furthermore, LED light is expected to increase in residential settings by 50 percent for 2016 and 70 percent for 2020.<sup>11</sup>

As more and more patients spend longer periods of time engaged in digitally based activities, we have an increasing responsibility to find solutions aimed at protecting their vision. Crizal Prevensia No-Glare lenses are an excellent place to start.

*Dr. Smick is Chief of Optometry Services at Clayton Eye Center and an owner of the facility. He also serves as a technical advisor to many companies in the ophthalmic industry and has helped pioneer several visual advances.*

1. The Vision Council. Hindsight Is 20/20/20: Protect Your Eyes From Digital Devices. 2015 Dry Eye Strain Report. Available at: [http://www.thevisioncouncil.org/sites/default/files/VC\\_DigitalEyeStrain\\_Report2015.pdf](http://www.thevisioncouncil.org/sites/default/files/VC_DigitalEyeStrain_Report2015.pdf). Accessed February 7, 2015.  
 2. World Health Organization. Ultraviolet radiation and the INTERSUN Programme: Do UVA and UVB affect the body in different ways? Available at: <http://www.who.int/uv/faq/uvhealth-fac/en/>. Accessed: March 2014.  
 3. Beatty S, Koh HH, Henson D, Boulton M. The role of oxidative stress in the pathogenesis of age-related macular degeneration. *Surv Ophthalmol.* 2000;45(2):115-134.  
 4. Algereve PV, Marshall J, Seregard S. Age-related maculopathy and the impact of blue light hazard. *Acta Ophthalmol Scand.* 2006;84(1):4-15.  
 5. Dillon J, Zheng L, Merriam JC, Gaillard ER. Transmission of light to the aging human retina: possible implications for age related macular degeneration. *Exp Eye Res.* 2004;79(6):753-759.  
 6. Smick K et al. Blue light hazard: New knowledge, new approaches to maintaining ocular health. Report of a roundtable sponsored by Essilor of America. March 16, 2013, NYC, NY. Available online at <http://www.crizalusa.com/ecp-tools-information/research-compendium.html>  
 7. Behar Cohen F, Martinsons C, Vienot F, et al. Light-emitting diodes (LED) for domestic lighting:

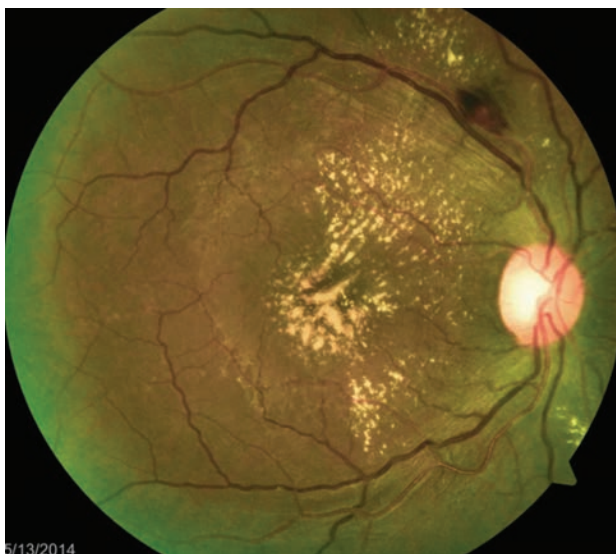any risks for the eye? *Prog Retin Eye Res.* 2011;30(4):239-57.  
 8. Barrau C, Villette T, Cohen-Tannoudji D. Blue light: Scientific discovery. *Essilor.* 2013; February: 1-49.  
 9. The Vision Council. Hindsight is 20/20/20: Protect your eyes from digital devices. 2015 Dry Eye Report. Available at: [http://www.thevisioncouncil.org/sites/default/files/VC\\_DigitalEyeStrain\\_Report2015.pdf](http://www.thevisioncouncil.org/sites/default/files/VC_DigitalEyeStrain_Report2015.pdf). Accessed February 7, 2015.  
 10. Kalthryn A, Rose, PhD, Ian G. Morgan, BSc, PhD, Jenny Ip, MBBS, Annette Kifley, MBBS, MAppStat, Son Huynh, MBBS, MMed (ClinEpi), Wayne Smith, BMed, PhD, Paul Mitchell, MD, PhD. "Outdoor Activity Reduces the Prevalence of Myopia in Children." *Ophthalmology.* Volume 115, Issue 8, Pages 1279-1285, August 2008. [www.aaojournal.org/article/S0161-6420\(07\)01364-4/abstract](http://www.aaojournal.org/article/S0161-6420(07)01364-4/abstract).  
 11. Lighting the way: perspectives on the global lighting market. Second edition. August 2012. McKinsey & Company Inc. p. 8.  
 12. Smick K et al. Blue light hazard: New knowledge, new approaches to main-taining ocular health. Report of a roundtable sponsored by Essilor of America. March 16, 2013, NYC, NY. Available at: [www.crizalusa.com/content/dam/crizal/us/en/pdf/blue-light/Blue-Light-Roundtable\\_White-Paper.pdf](http://www.crizalusa.com/content/dam/crizal/us/en/pdf/blue-light/Blue-Light-Roundtable_White-Paper.pdf).

# Pathology in Perspective: Differential Diagnosis of Retinal Disease

Many retinal conditions can be easily confused. Can you spot the masqueraders?

By **Mohammad Rafieetary, OD, Stephen Huddleston, MD, and Eric Sigler, MD**

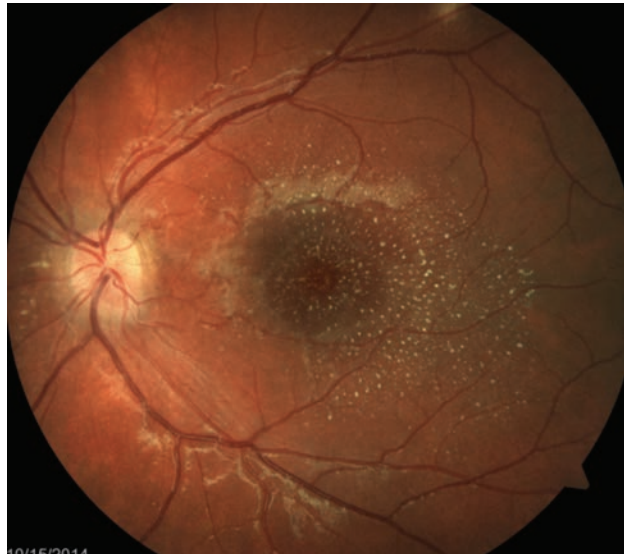**M**asquerading features of various retinal and chorioretinal disorders can result in a diagnostic conundrum. By familiarizing oneself with the differentiating nuances of these findings, we can overcome many of these clinical challenges. This article demonstrates a few examples of such cases and presents a series of self-test questions to sharpen your diagnostic skills.



## CASE #1:

The above fundus photographs depict two separate patients, each complaining of blurred vision for a short but indeterminate length of time.

Both are new to your practice and have never had an eye exam before.



## Questions

1. Which systemic processes may be involved in each patient presentation?

a. The patient on the left has poorly controlled diabetes, hypertension or a mix of both. The patient on the right may have a sub-clinical systemic infection.

- b. The patient on the left has poorly controlled diabetes, whereas the patient on the right has high blood pressure.
- c. The patient on the left has a branch vein occlusion, while the patient on the right has increased intracranial pressure.
- d. Both patients have no systemic disease related to their ocular findings.
2. What does not need to be included in the differential diagnosis for the patient on the right, who has no prior medical history and normal vital signs?
- Bartonella henselae*.
  - Acute viral illness.
  - Sarcoidosis.
  - Punctate inner choroidopathy.
3. Assuming the patient on the right is a 10-year-old with no significant past medical history, what is the best course of action?
- Intravitreal dexamethasone.
  - Intravitreal anti-VEGF.
  - Topical third-generation quinolone antibiotic.
  - Short course of oral azithromycin.
4. You determine that the patient on the left has not been compliant with his antihypertensive medications. What do you do next?
- Observe closely after counseling.
  - Contact patient's primary care provider.
  - Treat with topical steroids and NSAIDs.
  - Prescribe oral steroids.

### Answers

1) a; 2) d; 3) d; 4) b

### Diagnoses

The patient on the right has hypertensive retinopathy

### Possible Causes of Retinal Exudates

Vascular Disorders	Diabetic retinopathy	Hypertensive retinopathy	Retinal vein occlusion	Coats' disease	Retinal macroaneurysm
Infectious Disorders	Toxoplasmosis	Viral disease (e.g., herpes, HIV, CMV)	Syphilis	Bartonella	Tuberculosis
Inflammatory Autoimmune Disease	Sarcoidosis	Systemic lupus erythematosus	Posterior uveitic disorders (multifocal choroiditis)		Vogt-Koyanagi-Harada disease
Miscellaneous	Choroidal neovascularization (any etiology)				

### CASE #2:

Two new patients come into your clinic. Both are accompanied by their entire immediate families. Both are 22 years old, and both are excellent historians. This is the first eye exam for each patient and neither one has

whereas patient on the left has neuroretinitis caused by seropositive *Bartonella henselae* (cat scratch disease).

### Discussion

Exudates appear in the intra- or subretinal space when the blood/retina barrier is interrupted within the retinal and/or choroidal circulation. The etiology of the vascular breakdown is wide-ranging and potential mechanisms include vascular disorders, such as hypertension or diabetes, as well as inflammatory and infectious diseases (see "Possible Causes of Retinal Exudates," below).

In each of these conditions, the pattern of exudate—or lipid deposits resulting from leakage—may be different. For example, the two common conditions resulting in a so-called "macular star" exudate are hypertensive retinopathy and neuroretinitis. In other conditions, the exudate may be noted in the localized region of disease involvement, such as around aneurysms or along the involved vessels in a vein occlusion.

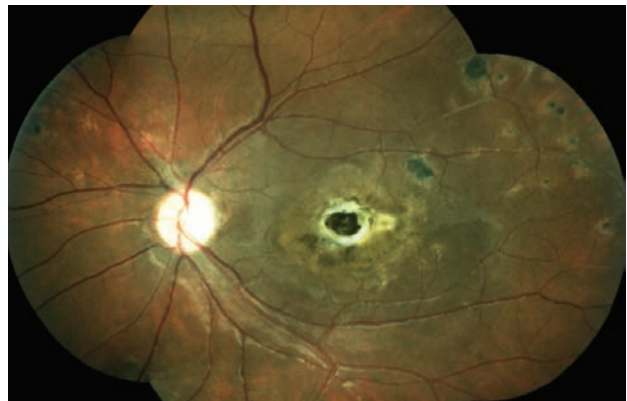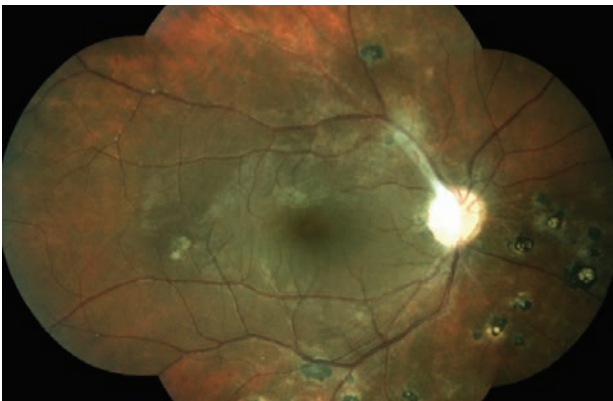
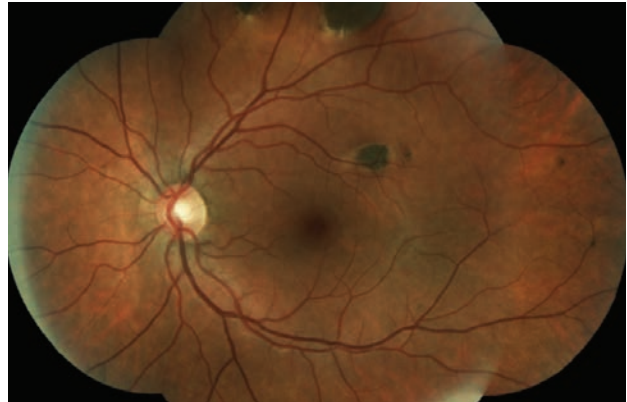
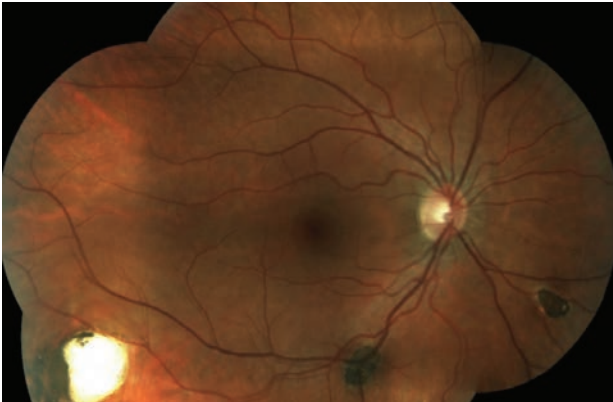
In neuroretinitis (right image), the exudates tend to have a perivascular distribution, located surrounding blood vessel terminations. Therefore, by combining the patient's history (including existing medical conditions) and clinical presentation, you can develop a focused differential diagnosis and investigative process by which the cause, and the course of treatment, is determined.

Some investigators have speculated that a macular star is formed by transudation from capillaries deep in the optic nerve through the intermediate tissue of Kuhnt—a barrier that separates the optic nerve from the retina. Therefore, this type of exudative pattern is more common when there is both optic nerve and retinal ("neuroretinal") involvement.

any complaints. Their fundi are shown on page 36.

### Questions

1. Both patients are surprised by your exam findings, but only one family is shocked. This patient's family has suffered through



a string of relatives who had cancer diagnoses at a young age. Which patient has the strong family cancer history and what kind of cancer has her family suffered from?

- Top patient, colorectal.
- Bottom patient, lung.
- Top patient, lung.
- Bottom patient, colorectal.

2. Which patient has an underlying infectious etiology? What is the causative agent?

- Top patient, histoplasmosis.
- Bottom patient, toxoplasmosis.
- Top patient, toxoplasmosis.
- Bottom patient, histoplasmosis.

3. During your extensive counseling with the patient on the top, you recommend:

- A six-week course of erythromycin by mouth.
- Observe and return in six months to ensure no change.
- Immediate referral to the appropriate gastroenterologist.
- Referral for retina evaluation.

4. When explaining the diagnosis to the patient on the bottom, you decide to:

- Start a six-week course of sulfamethoxazole/trimethoprim by mouth.
- Refer for retina evaluation.
- Refer to a pulmonologist.
- Order serology studies to confirm the diagnosis.

### Answers

1) a; 2) b; 3) c; 4) d

### Diagnoses

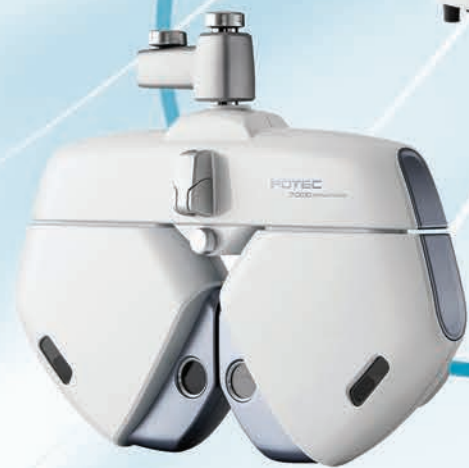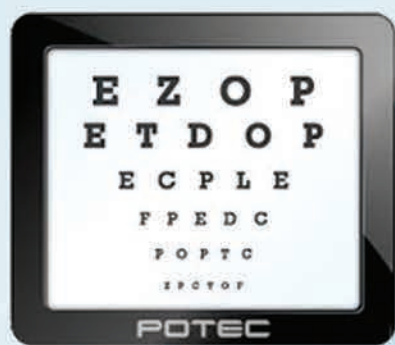The patient in the top set of images has Gardner's syndrome. The patient in the bottom set of images has toxoplasmosis.

### Discussion

Pigmentary lesions of a nonchoroidal origin represent reactive changes occurring in the retinal pigment epithelium (RPE). Both hyperplastic and hypertrophic changes may result in any combination of increased pigmentation, increased number or increased size of the RPE cells. Toxoplasmosis causes these changes on either a congenital or acquired basis. Most occur from a single systemic infection, resulting in static lesions of varying size and significance to vision. However, the typical ocular

# YOUR EXAM... ONLY BETTER!

The Veatch Digital Refraction System eliminates costly inefficiencies, enhances your practice, and makes the exam process more enjoyable for you and your patients.



**FREE**  
Visual Acuity System\*  
with purchase of  
Digital Refractor

- Increased efficiency • Combat reductions in reimbursements
- Enhanced practice image • EMR integration • Patient referrals
- Increased optical sales • Competitive advantage
- Eliminate back and shoulder pain and bursitis

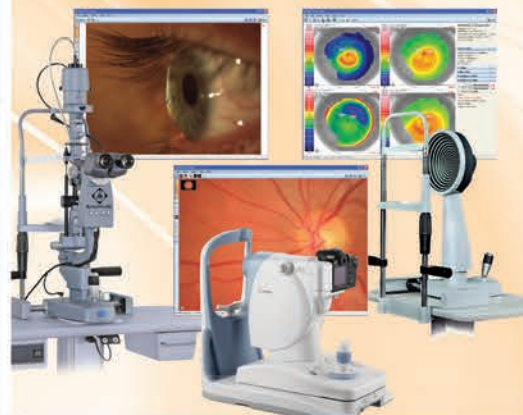
## ADDITIONAL OFFERS FROM VEATCH

Exam Lane Packages  
Starting at \$12,995



### ReSeeVit™

- Anterior Segment Imaging
- Retinal Imaging
- Corneal Wavefront Topography



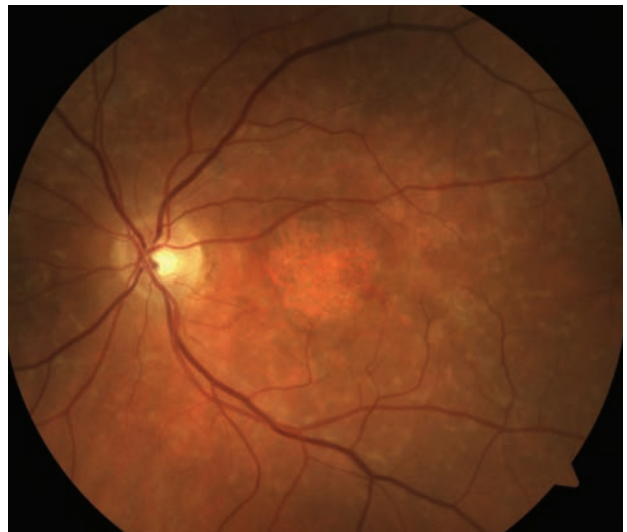
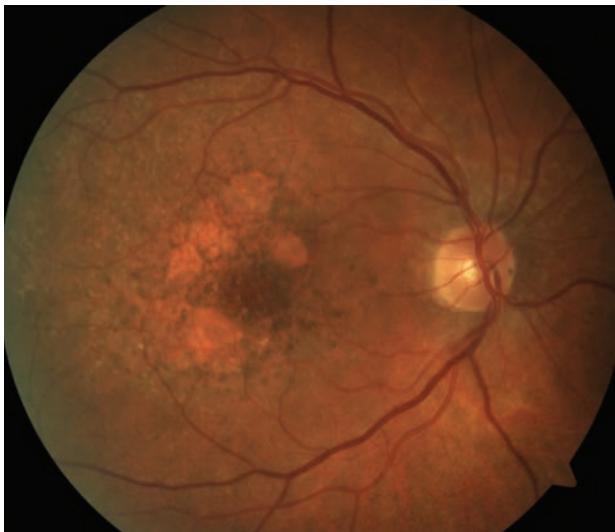
Insight Visual Acuity System  
ONLY \$1,295



findings in Gardner’s syndrome, a subtype of familial adenomatous polyposis, result in the progressive accumulation of lesions mimicking congenital hypertrophy of the RPE. The presence of an unusually high number of hypertrophic retinal pigment epithelial lesions (similar to congenital hypertrophy of retinal pigment epithelium [CHRPE]) and a typical teardrop appearance should clue the clinician in to a possible diagnosis

of Gardner’s syndrome and the need for referral to a gastroenterologist.

While typical old, inactive non-macular toxoplasmosis lesions can be observed, patients with lesions involving the macula or of a significant size should be sent for a retina evaluation. So, the patient in this case (bottom images) has significant macular lesions and should be referred to a retinal specialist.



### CASE #3:

Two new patients come into your clinic with similar complaints of gradual loss of central vision. Both measure 20/200 centrally, and both report a decade of worsening. Both patients have smoked cigarettes for years.

Their fundus photos are shown above.

### Questions

1. What is your best assessment based on the presented information?
  - a. Both have dry AMD.
  - b. Both have wet AMD.
  - c. The patient on the right has AMD and the patient on the left has macular dystrophy.
  - d. The patient on the left has AMD and the patient on the right has macular dystrophy.
2. Assuming one of these patients suffers from a macular dystrophy, which of the following is the most likely form?
  - a. Best disease.
  - b. Adult vitelliform.
  - c. Multifocal pattern dystrophy.
  - d. Sorsbys.

3. Which test is the least invasive, yet particularly beneficial to aid with the differential diagnosis in either patient?
  - a. Electroretinography.
  - b. Fundus autofluorescence imaging.
  - c. Genetic testing.
  - d. Fluorescein angiography.
4. For the patient on the left, which is the most significant counseling you need to provide?
  - a. Smoking cessation.
  - b. Genetic testing.
  - c. Recommend anti-VEGF therapy.
  - d. Annual eye health examination.

### Answers

1) d; 2) c; 3) b; 4) a

### Diagnoses

The patient on the right has atrophic AMD. The patient on the left has multifocal pattern dystrophy.

### Discussion

Fundus autofluorescence has become a valuable diagnostic tool for multiple retinal conditions, particularly



*Exclusive Optical Shop Distribution*  
**The New Non-Rx, 1st Step to Longer, Lusher,  
 Fuller Looking Lashes and Brows**

#1 Recommended Among Eyecare Professionals



**2** Special LASH ADVANCE offers — Choose 1 or Both:

**PROFESSIONAL COURTESY PRICING OFFER :**

provides you and your staff an opportunity to try new Lash Advance at a very low price (just \$10 + S & H — 80% off the regular retail price). Visit [www.mediniche.com/LAprofessionalpricing.html](http://www.mediniche.com/LAprofessionalpricing.html) or call MediNiche at 1-888-325-2395 for more details.

**TRY IT!**

**INTRODUCTORY PURCHASE OFFER :**

buy a dozen (12) packages of Lash Advance at the regular wholesale price of \$24/package and receive a 25% discount, two (2) free packages, free shipping, a free counter display, customer/staff materials and more. Visit [www.mediniche.com/lashadvanceoffer.html](http://www.mediniche.com/lashadvanceoffer.html) or call MediNiche at 1-888-325-2395 for more details.

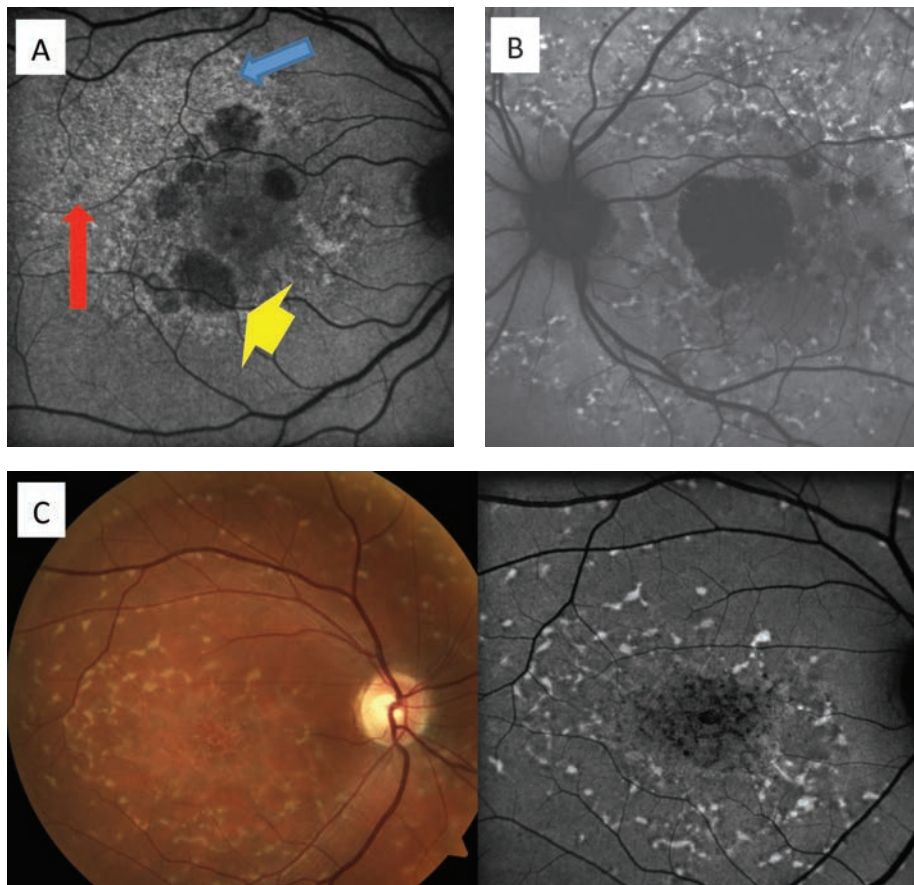
**BUY IT!**

Introduced exclusively for eyecare professionals, new LASH ADVANCE® is a non-prescription cosmeceutical developed in conjunction with a female optometrist as a sensible start to healthier lashes and brows. LASH ADVANCE is suggested for use prior to expensive prescription products.

- Natural; no drugs or known sensitizers.
- Contains PeptiPlex®, advanced peptide complex, supports the growth cycle of lashes and brows.
- Unlike other lash products, not sold at major drug and food retailers.
- Easy application; will not run, clear gel absorbs with no residue.
- Reasonably priced; affordable.

**Positive RESULTS with one tube of use!**





In fundus autofluorescent photography, drusen has a discrete blocking effect that causes reduced fluorescence. RPE atrophy does not fluoresce, so the degree and size of hypofluorescence or hypoa autofluorescence depends on the extent and geographic area of RPE atrophy. Diseased RPE and lipofuscin cause hyperautofluorescence that may convert over time to hypofluorescence with the demise of the RPE.

In the patient with dry AMD (A), the red arrow indicates hypoa autofluorescence from drusen. The blue arrow points to diffuse hyperautofluorescence. The yellow arrow indicates absence of autofluorescence caused by geographic atrophy.

In multifocal pattern dystrophy (B), the RPE disease can be seen in a reticular pattern, whereas in fundus flavimaculatus (C), these lesions are in the so-called pisciform (fish bone) pattern.

in the management of patients within the spectrum of macular degenerative and dystrophic conditions. For example, in age-related macular degeneration, drusen as an early indicator for the disease shows subtle and varying degrees of hypo- or hyperautofluorescence, whereas the diseased retinal pigment epithelium (RPE) accumulating lipofuscin typically demonstrates hyperautofluorescence corresponding to the so-called “vitelliform” lesions.

Eventually, the death of RPE (clinically known as geographic atrophy) represents the total absence of autofluorescence (A).

The RPE involvement in various macular dystrophies can have a distinctive appearance. For example, in multifocal pattern dystrophy (B), the RPE disease can be seen in a reticular pattern, whereas in fundus flavimaculatus these lesions are in the so-called pisciform (fish bone) pattern (C).

## CASE #4:

Two asymptomatic male patients were referred for evaluation of the lesions seen in the photos on page 42.

### Questions

1. Based on the OCT scans shown, what is the primary site of the lesions?

- Inner retina.
- Outer retina.
- Retinal pigment epithelium.
- Choroid.

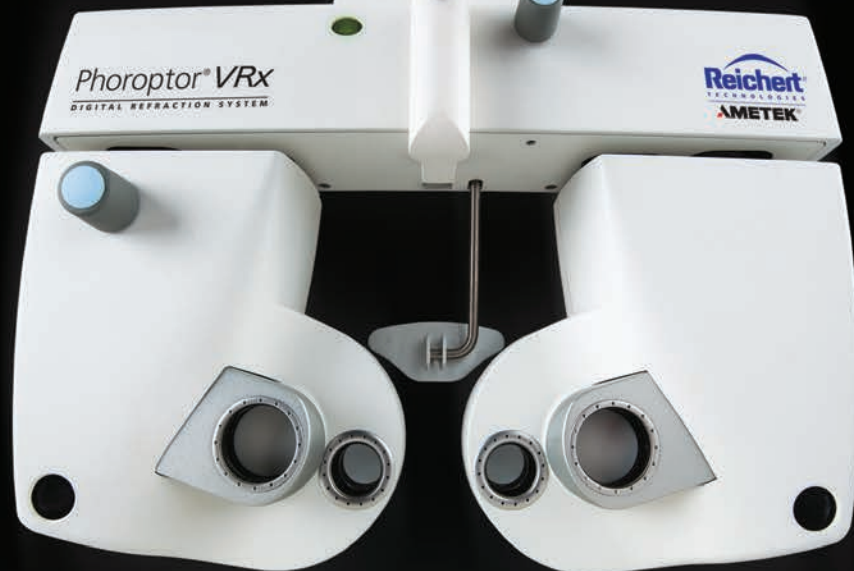2. Which of the following would you use to evaluate and diagnose these lesions?

- Lesion’s height.
- Presence of subretinal fluid.
- Presence of orange pigment.
- All of the above.

3. Which is the most appropriate referral for further management of these patients?

- To patient’s primary care provider.
- To a general ophthalmologist.





# REFRACT *IN THE* FAST LANE

DRIVE PRACTICE EFFICIENCY



**NEW** **PHOROPTOR® VRx**  
DIGITAL REFRACTION SYSTEM

Thinnest & most compact. Incredibly fast. Ultra-quiet.  
Effortless integration. Made in the USA.

The most advanced Phoroptor® ever built.  
[www.reichert.com/vrx](http://www.reichert.com/vrx)

Take a **test drive** at Vision Expo East #MS 6713,  
or with your authorized Reichert® distributor.



- c. To an ophthalmic oncologist.  
d. Follow-up only; no referral needed.

4. If the patient on the right elects to have treatment, which is the most likely plan?

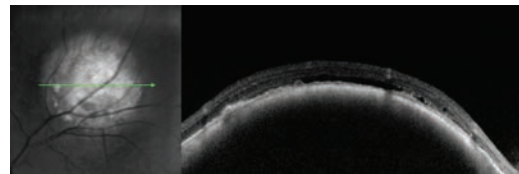
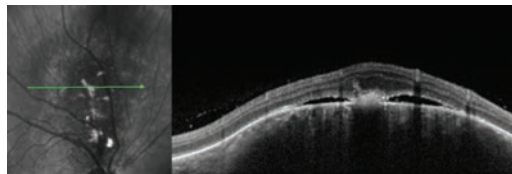
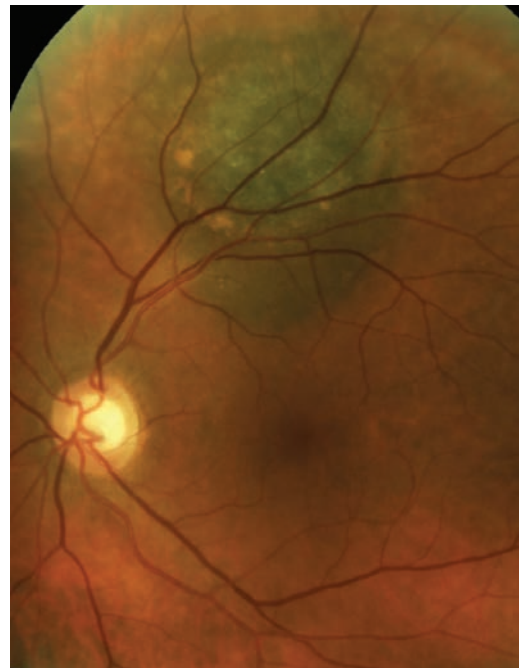
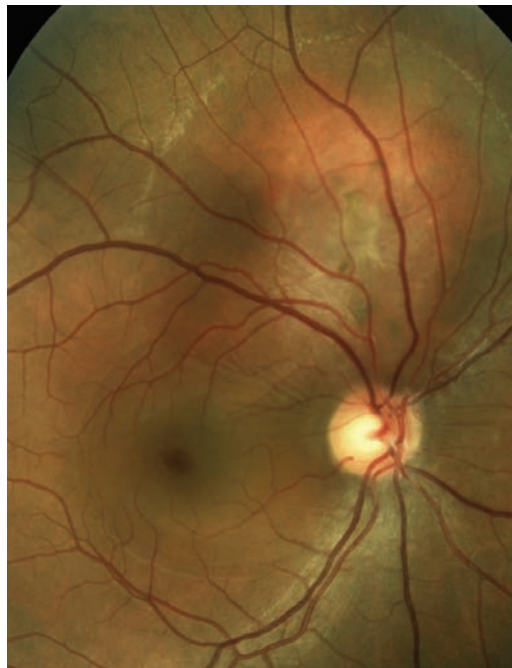- a. Retinal photocoagulation.  
b. Brachytherapy.  
c. Enucleation.  
d. Intravitreal anti-VEGF.

## Answers

- 1) d; 2) d; 3) c;  
4) b

## Diagnoses

The patient on the left has a choroidal hemangioma. The patient on the right has a choroidal melanoma.



## Discussion

Both of these patients have vision-threatening lesions that require urgent or emergent referral for evaluation by an ocular oncologist, but only one of the lesions is life threatening. Correctly identifying an ocular mass as a choroidal melanoma instead of a choroidal hemangioma involves adequate counseling and coordination with your collaborating ocular oncologist.

Recognizing high-risk features—such as the presence of orange pigment, subretinal fluid and change in tumor size—are crucial for differentiating a melanoma from a nevus.

Choroidal hemangiomas (left) are non-malignant vascular tumors that either exhibit an indolent course without growth or leakage or an aggressive course with growth and leakage. Diagnosis can be made with OCT, FA and B-scan. FA will show a distinctive, course, vascular pattern and B-scan will exhibit high internal reflectivity.

Choroidal melanomas (right) are the most common primary malignant intraocular tumor and they are missed or misdiagnosed daily. Indolent peripheral choroidal hemangiomas may be safely observed, while

vision-threatening lesions are treated with anti-VEGF agents or PDT. With appropriate management, successful outcomes are common.

Once a diagnosis is made, correctly classifying the tumor (based on its ultrasonographic size into the small, medium and large categories described by the Collaborative Ocular Melanoma Study publications) can give patients a better idea of their chance of successful treatment and mortality rates.

Remember, essentially all primary choroidal melanoma metastases are to the liver, and routine surveillance with abdominal ultrasound or CT is required for detection of early metastatic disease after diagnosis and treatment.

Performing thorough exams and keeping your clinical skills honed are the keys to providing the level of care your patients deserve. ■

*Dr. Rafieetary is a consultative optometric physician at the Charles Retina Institute in Memphis.*

*Dr. Huddleston is an ophthalmologist in vitreoretinal fellowship also at the Charles Retina Institute.*

*Dr. Sigler is a retina specialist at Ophthalmic Consultants of Long Island.*



# All eyes deserve clariti.



**clariti 1 day—now available for practices everywhere.**

The world's first and only family of silicone hydrogel daily disposable contact lenses designed *for every patient type*—sphere, toric and multifocal.

**High Oxygen  
Transmissibility**

**High Water  
Content**

**Low  
Modulus**

**UV  
Protection**

**Affordable  
Upgrade**

Now you can prescribe all of your patients with healthy, comfortable, affordable silicone hydrogel 1 day lenses—which will make all eyes very happy indeed.

To learn more, contact your CooperVision representative today or visit **[CooperVision.com/practitioner](http://CooperVision.com/practitioner)**.



**CooperVision®**  
Live Brightly.®

# Don't Overlook the Eyelids

A thorough eyelid examination can be critical to keeping your patients healthy. Here's what you should look for. **By Christine Sindt, OD**

**T**he eyelids provide several important functions: they protect the globe from external threats, supply lipid secretions necessary to create and maintain a healthy tear film, and they distribute and drain the tears. Unfortunately, when evaluating a patient at the slit lamp, it is altogether too easy to overlook the lids and zoom in on the ocular surface. A thorough examination of the lids can be critical for systemic health in addition to ocular integrity. Let's review some of the critical factors to consider and signs to look for.

## Position

Lid examination begins during the patient intake. While reviewing the patient history, note the position of the lids. When the eye is open, the upper lid should cover 1/6th of the cornea, with the lower lid just touching the inferior limbus. The lid should approximate the globe along the entire lid margin, without turning in or out.

Unequal apertures could indicate a serious condition such as thyroid disease or a space-occupying lesion. It must be determined whether there is proptosis or an enophthalmos

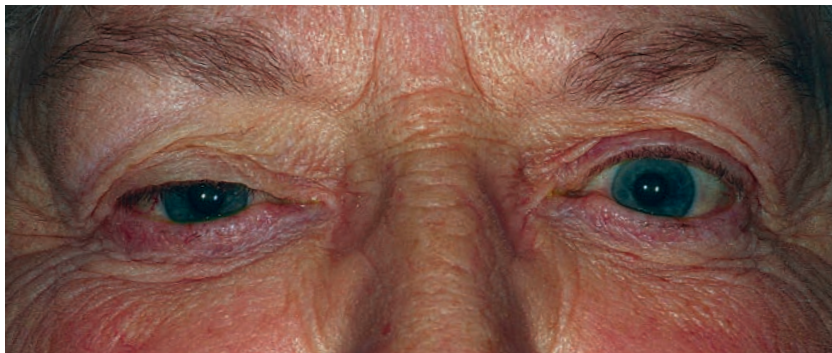of the contralateral eye. A Hertel ophthalmometer is useful for determining globe position disparity; a difference of 2mm is considered abnormal.

## Entropion and Ectropion

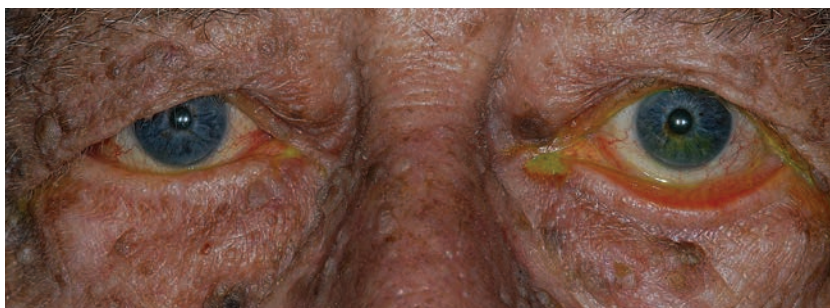A turning in of the lid margin represents *entropion*, which is one cause of lashes dragging across the ocular surface (*trichiasis*). Symptoms include redness and pain around the eye, sensitivity to light and wind, sagging skin around the eye, epiphora and decreased vision, especially if the cornea is damaged. Causes include congenital abnormalities, aging (which creates loose skin), stretched and loose ligaments and muscles, scarring, trauma, trachoma and involution spasms.

Entropion may not be seen when the patient is at rest in the chair but generally can be elicited when the patient squeezes the lids.

*Ectropion*, by contrast, is a condition in which the eyelid margin turns outward. A myogenic ectropion in particular is caused by a weakness



Left/right asymmetry in lid apertures can be secondary to proptosis, as seen here OS.



**Age-related cicatricial ectropion of the left eye with symptomatic dryness.**

in the lid muscles. Ectropion may be a natural result of age or a consequence of facial paralysis caused by Bell's palsy or tumor. Other potential etiologies include scarring from burns or trauma, benign or cancerous lid lesions, blepharoplasty, radiation for neoplasms or cosmetic laser skin resurfacing, cicatrizing conditions like Stevens-Johnson syndrome or ocular cicatricial pemphigoid; or it may be congenital, as in Down's syndrome.

### Blepharoptosis

Ptosis can be either congenital or acquired. *Congenital ptosis* is present at birth and is prevalent equally in both males and females. It is caused by levator development abnormality, resulting in fibrosis and fatty infiltration of the muscle. A congenital ptosis may be either unilateral or bilateral. The lid crease will be poorly formed in the affected eye(s) and individuals with congenital ptosis may suffer from nocturnal lagophthalmos. Bilateral cases develop a chin-up posture to see under the drooping lid, while unilateral cases are at risk for amblyopia. Sixteen percent of congenital ptosis cases will have abnormal superior rectus function.<sup>1</sup>

*Acquired ptosis* may arise from floppy lid syndrome, levator dehiscence from contact lens wear or aging, mechanical/traumatic conditions or neurogenic causes.

*Floppy lid syndrome* is defined by easily everted eyelids with a thickened, elastic tarsal plate and lash ptosis. It has been associated with giant papillary conjunctivitis and keratoconus, chronic eye rubbing and obesity.<sup>2</sup> Up to 85% of patients with floppy eyelids may have obstructive sleep apnea, a potentially life-threatening condition, and therefore should be evaluated in a sleep clinic.<sup>3</sup>

The majority of levator dehiscence is associated with rigid contact lens wear. It is generally accepted that removal of lenses by tugging on the upper lid and harsh blinking is the cause.<sup>4</sup>

Slippage of the aponeurosis is the most common cause of mild to moderate ptosis in the elderly. It should be differentiated from neurogenic causes of ptosis. Other conditions that mimic lid ptosis are dermatochalasis and brow ptosis. Patients with ptosis may complain about vision loss (especially when reading), headaches, eyebrow strain and cosmesis. The palpebral aperture should be documented, and it may be helpful to compare the lid position to old photographs. Medicare requires at least 20 degrees of documented visual field restriction to pay for repair.

Other, more rare, causes of acquired ptosis include neoplasm, neurofibromas and cicatricial disease.

## A Systematic Approach to Eyelid Examination and Documentation

### 1. Begin the examination while talking to the patient:

- a. Are the lids even?
  - i. Aperture size
  - ii. Position of lid at rest
  - iii. Blink ability
  - iv. Brow placement
  - v. Dermatochalasis
- b. Is the periorbital skin consistent?
  - i. Color
  - ii. Texture

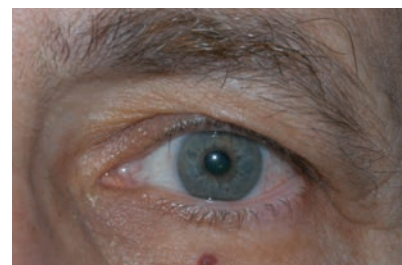### 2. While at the slit lamp, evaluate:

- a. Lashes
  - i. Presence
  - ii. Color/texture
  - iii. Debris/collarettes
- b. Lid margin
  - i. Integrity of the lid margin
    1. Notching/bumps
    2. Telangiectasia
    3. Keratinization
  - ii. Position against the globe
- c. Meibomian glands
  - i. Quality of secretions
    1. Color
    2. Turbidity
  - ii. Distention, blunting, drop out

### Innervation

The eyelids are innervated by the oculomotor nerve (CN III), the facial nerve (CN VII), the trigeminal nerve (CN V) and sympathetic fibers.

The orbicularis oculi is responsible for shutting the eye and is innervated by the facial nerve. The oculomotor nerve innervates the levator and tarsal plate and opens the eye. The ophthalmic division of the trigeminal



**Dermatochalasis and brow ptosis reducing the visual field, while lid margin remains in the proper position.**

## Eyelids

nerve is purely sensory. Sympathetic nerve fibers of the lids innervate Müller's muscles.

*Marcus-Gunn jaw winking* is an aberrant connection of the oculomotor nerve fibers that innervate the levator and the trigeminal nerve fibers of the muscles of mastication (motor nerve). Jaw winking is present in approximately 5% of congenital ptosis cases, with nearly 4% being bilateral.<sup>5</sup>

*A seventh, or facial, nerve palsy* causes an inability to close the eyelid. Bell's palsy is the most common subset of conditions causing facial nerve paralysis. Bell's palsy affects 11 to 40 persons per 100,000 each year, with peak incidence between the ages of 15 and 50.<sup>6-8</sup>

Reactivation of herpes simplex and herpes zoster is postulated to account for the majority of cases of

Bell's palsy.<sup>9</sup> The condition typically presents with a sudden and rapid onset of unilateral facial weakness, often within a few hours. Less than 1% of cases are bilateral. While the majority of cases are self-limiting with complete recovery, recent evidence shows the early treatment with corticosteroids may improve recovery results.<sup>9</sup> Antiviral therapy does not improve chance of recovery.<sup>10</sup> Differential diagnosis includes brain tumor, stroke, myasthenia gravis and Lyme disease.

In contrast to facial nerve palsy, several conditions result in the inability to open the eyes.

*Horner's syndrome* is impaired innervation of sympathetic to Müller's muscle. It is often associated with the classic triad of ptosis, miosis and anhidrosis, although patients rarely present with all three signs. It

can be either congenital or acquired, and the risk to patient health varies from benign to life threatening based on the underlying cause.<sup>11</sup> Patients should undergo a thorough neurological work-up.

*Third nerve palsy* also results in an inability to open the lid. Examination may show a dilated, poorly reactive pupil; reduced ocular movements; and ocular misalignment, where the eye is located down and out. Pupil-sparing third nerve palsy involves ischemic cranial neuropathy (such as in diabetes or hypertension), while pupil-affecting third nerve palsy involves compressive lesions or aneurysm.

*Acquired myasthenia gravis* involves inability to open the eye, which may be variable throughout the day and worsen when tired. This autoimmune condition affects 20 in

JOIN THE CLASS OF

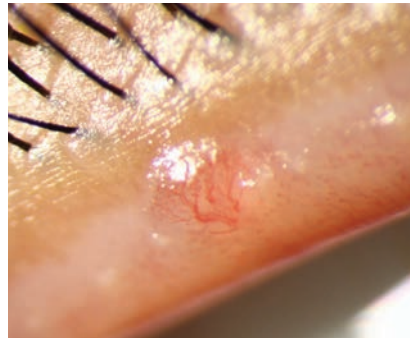
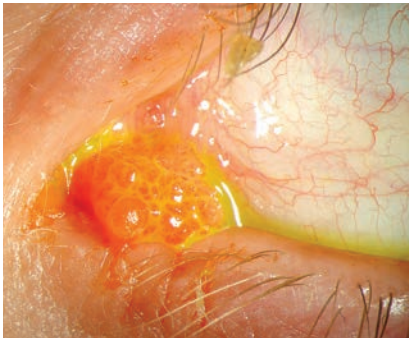
**20/20**

Select SECO 2015 courses available by June!

**SECO University - the new online Education Resource Center from SECO International - is built on a decade of experience providing online optometric CE.**

Enroll today and get access to more than 50 hours of COPE-approved online CE credit along with dozens of more exclusive learning and training tools.





**Lid papillomas may not always be as obvious as that seen in the left image. They may in fact be more subtle and difficult to spot, as in the lid margin papilloma at right.**

100,000 people and is caused by a reduction in acetylcholine receptor sites. Common symptoms of myasthenia gravis include a drooping eyelid, blurred or double vision, slurred speech, difficulty chewing and swallowing, weakness in the arms and legs, chronic muscle fatigue and difficulty breathing.<sup>12</sup>

### Lesions

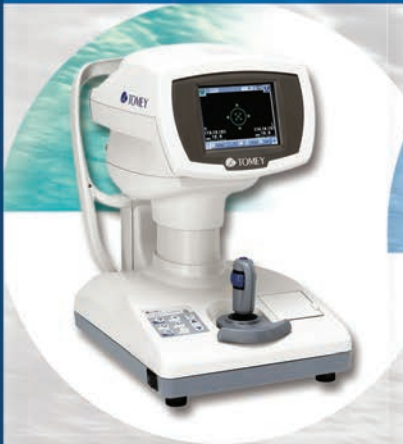Skin lesions found around the eye can be confusing—benign ones may have a dramatic appearance while malignant lesions look unassuming.

*Papillomas* most commonly present in middle-aged adults and the elderly. Squamous papillomas represent a benign hyperplasia of squa-

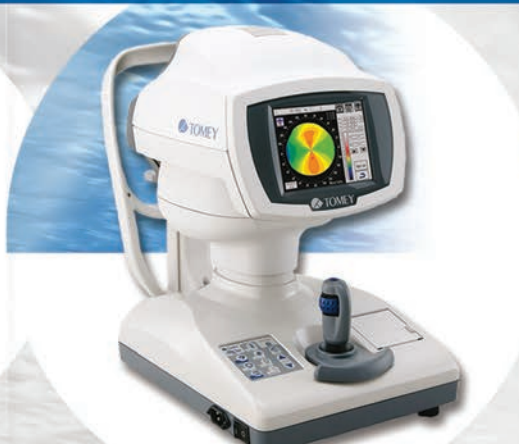mous epithelium. Viral papillomas are associated with local infection involving the human papilloma virus (HPV). Papillomas on the skin will appear skin-colored, tan or brown. They may be round or pedunculated. They are easily removed with excision. On the conjunctiva, a papilloma may appear as a mass of vessels or a cluster of hyperemic cells and must be differentiated from a squamous cell carcinoma.<sup>13</sup>

*Actinic keratosis* is rare under 30 years of age. It presents as a flat, light tan lesion, most common on the face, trunk and upper extremities, which becomes pigmented, elevated and warty over time. There is a 20% risk of progression to squamous cell carcinoma. The etiology is presumed to be sun exposure and the treatment is biopsy, excision and cautery.<sup>14</sup>

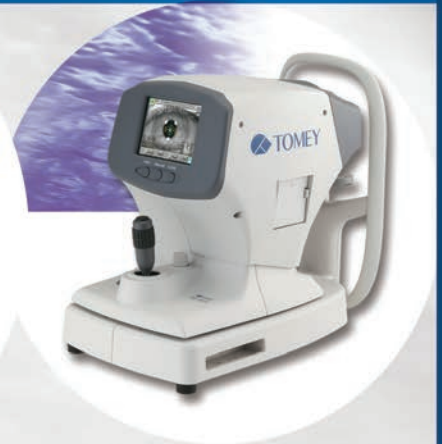## TOMEY AutoRefractor Family



**RC-5000 "Advanced"**  
(AutoRefractor/Keratometer)  
with touch screen



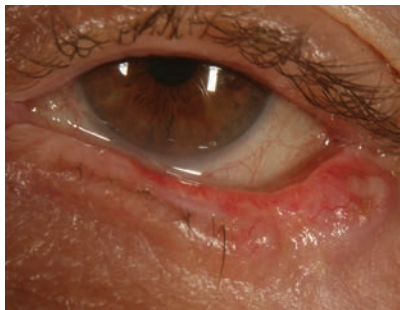
**RT-7000 "Ultimate"**  
(AutoRefractor/Keratometer/Topographer)  
with touch screen & tear stability analysis



**RC-800 "Basic"**  
(AutoRefractor/  
Keratometer)

 **TOMEY**<sup>®</sup> 888-449-4045  
[WWW.TOMEYUSA.COM](http://WWW.TOMEYUSA.COM)

Visit us at the Vision Expo East Meeting Booth MS-6503



**Lid notching, ectropion and missing lashes accompany this case of eyelid basal cell carcinoma.**

*Epidermal inclusion cysts* can occur at any age and are equally prevalent in males and females. They arise from hair follicles and appear as smooth, round elevated cysts filled with keratin. Ablation of entire cyst walls is necessary for eradication.

*Sebaceous cysts* clinically look like epidermal inclusion cysts; however, they arise from blocked glands of Zeis, meibomian or sebaceous glands. They are filled with epithelial cells, keratin, fat and cholesterol crystals. They are treated with expression or surgical excision.

*Acquired nevus* begins in childhood when the basal epithelium migrates to the dermis surface. They may appear deeply pigmented or amelanotic. The lesion may be flat or pedunculated. A key characteristic is maintenance of lashes through the lesion. While lid nevi are benign, about 5% will transform to malignant melanoma and therefore should be photo-documented and closely monitored.<sup>15</sup>

*Sebaceous cell carcinoma* arises from the glands of Zeis at the lid margin or the meibomian glands in the deep tarsus. Sebaceous cell carcinomas account for 2% to 7% of eyelid tumors.<sup>16</sup> Clinically, they appear as a solitary lesion with diffuse lid thickening. There is a loss of lashes. They are frequently mis-

diagnosed as recurrent chalazion, chronic meibomitis or blepharoconjunctivitis.<sup>16</sup> These can be aggressive tumors, with orbital extension in 17% of cases and systemic metastasis in 8% of cases. Biopsy/excision is recommended for suspected sebaceous cell carcinomas.<sup>16</sup>

*Basal cell carcinoma* is the most common tumor of the skin with >400,000 people treated annually.<sup>17</sup> It has been associated with sunlight exposure and *Demodex* infestation. On the eyelids, 65% will involve the lower lid, 15% the medial canthus, 15% the upper lid and 5% the lateral canthus.<sup>17</sup> They appear as pearly, waxy translucent lesions with rolled borders. There is often telangiectasia near borders and loss of lashes. Tumor extensions are possible, but no distant metastasis. The mortality rate is <1%.<sup>17</sup>

*Primary malignant melanoma* accounts for only 1% of malignant eyelid tumors.<sup>18</sup> They may be either a primary lesion or a metastasis from another location. They generally appear in sun-exposed areas as a variably pigmented mass, which can bleed or ulcerate. Malignant melanoma must be histopathologically proven, and early diagnosis is critical, since prognosis depends on if the lesion metastasizes.<sup>18</sup>

## Disorders of the Lashes

Growth of lashes from within the meibomian glands is *distichiasis*.

Congenital distichiasis is caused by the epithelial germ cell's failure to differentiate completely to meibomian glands. It is dominantly inherited with complete penetrance and may be isolated or associated with ptosis, strabismus

or congenital heart defects. Acquired distichiasis is seen on the lower lid, where the lashes may be either pigmented or non-pigmented. It is associated with chronic inflammation.

*Madarosis* is a decrease or loss of lashes. It is commonly seen in patients with long-standing anterior blepharitis, but is also seen with tumor, thermal burns and trichotillomania. It can be associated with alopecia, atopic dermatitis, systemic lupus and ichthyosis.

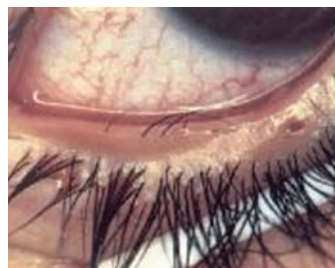*Hypertrichosis* is a benign condition with excess or abnormally long lashes. It can either be congenital or drug induced. Some drugs that have been known to cause hypertrichosis include: prostaglandins (e.g., latanoprost, travoprost, bimatoprost), phenytoin, acetazolamide, streptomycin, cyclosporine, psoralen, diazoxide and minoxidil.

*Poliosis* is premature whitening of the hair, lashes and eyebrows. It is associated with vitiligo, Waardenburg syndrome (iris heterochromia, white forelock) or chronic lid margin inflammation.

## Infection

The eyelids are prone to infection from multiple sources. *Molluscum contagiosum* is an itchy viral infection (poxvirus) of the skin that presents with white/pink dome-shaped, smooth, waxy or pearly umbilicated papules 2mm to 5mm in diameter. It is spread either by direct contact

or via fomites. Immunocompromised individuals may have more widespread infection and can be difficult to treat. Lesions generally regress spontaneously after one to two years, and treatment is only indicated for



**Distichiasis results when lashes grow outward from within the meibomian glands.**





## What we do every day matters.



Avenova™ with Neutrox™ (pure hypochlorous acid) removes microorganisms and debris from the lids and lashes. Avenova is an ideal addition to any daily lid and lash hygiene regimen, including for use by patients with Blepharitis and Dry Eye. Avenova may also be used after make-up removal as well as pre and post contact lens wear.

**NovaBay**

# Avenova™

*Daily lid and lash hygiene.*

Visit us at Vision Expo East!  
March 20-22, 2015  
Booth #: MS6944



**OPHTHALMOLOGIST AND OPTOMETRIST TESTED | RX ONLY**

**AVENOVA.COM | 1-800-890-0329**

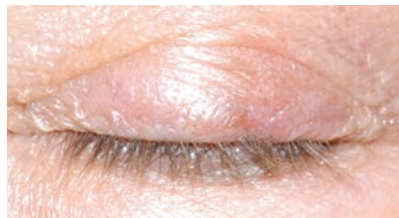cosmesis and prevention of spread. The condition is most common in children as a benign childhood entity; when seen in adults, it may represent a sexually transmitted disorder and should be treated as such until discovered otherwise.

**Blepharitis** is a common condition (found in 70% of the population) affecting the eyelid margins. Because of its ubiquity, it is often overlooked in the early stages. Associated morbidities include dry eye, loss of visual function and loss of well being and ability to carry out activities of daily living. Over time, damage to the lids occurs, including trichiasis, notching, entropion and ectropion. The cornea may be damaged due to inflammation and limbal stem cell deficiency, leading to scarring, loss of surface smoothness and optical clarity. Other signs of chronic blepharitis include crusting and collarettes, margin telangiectasia, marginal keratinization, decreased and brittle lashes, poliosis and distended or blunting of meibomian glands.

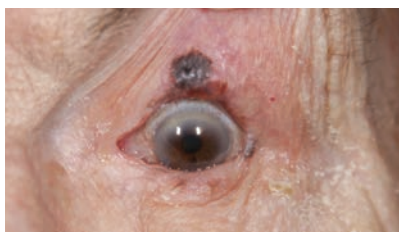Blepharitis has been separated into anterior vs. posterior blepharitis. Anterior blepharitis involves the anterior portion of the lid margin, including the lash follicle, while posterior blepharitis involves the meibomian glands.

Normal (common) bacteria of the eyelids include *Staphylococcus epidermidis* (95.8%), *Propionibacterium acnes* (92.8%), *Corynebacterium sp.* (76.8%), *Acinetobacter sp.* (11.4%), and *Staphylococcus aureus* (10.5%).<sup>19</sup> The lids may also be colonized with *Demodex*.

*Demodex* is an eight-legged mite that lives in hair follicles and oil glands. There are 65+ species of *Demodex*, only two of which live on humans (*D. folliculorum* and *D. brevis*), with a life span of two to three weeks. They are spread either



**Mild actinic keratitis may go unnoticed without careful attention to the lid exam.**



**Malignant melanoma. Be sure to raise the upper lid if you suspect a lesion is within the folds of skin.**

through direct contact or in dust and towels containing eggs. They eat skin cells, hormones and oils in the follicles and glands. In addition to lid margin dysfunction, *Demodex* has been implicated in rosacea, seborrheic dermatitis and other skin conditions.<sup>20</sup>

*Demodex* signs include cylindrical dandruff around a “volcano-like” lash base. Dry eye symptoms increase with *Demodex* infestation with more than 85% of patients showing evaporative dry eye.<sup>21</sup>

*Demodex* is acquired shortly after birth, and bio load increases with age. *Demodex* has been correlated with other inflammatory ocular states such as Salzmann’s nodular degeneration, ocular rosacea and peripheral ulcers. Studies show nearly 90% to 100% of people with blepharitis have *Demodex*.<sup>22</sup>

## Blink and You’ll Miss It

The eyelids are easy to pass over during an ocular exam. The periorbital region feels oddly foreign to many eye care professionals. Yet, the lids are vitally important to not

only the health of the eye, but can indicate systemic health integrity as well. A systematic approach to lid examination, which begins chairside, ensures the eyelids will not be overlooked. ■

- Stein A, Kelly JP, Weiss AH. Congenital eyelid ptosis: onset and prevalence of amblyopia, associations with systemic disorders, and treatment outcomes. *J Pediatr.* 2014;165(4):820-4.e2. doi: 10.1016/j.jpeds.2014.06.053.
- Diaper CJ. Wake up to floppy eyelid syndrome. *Br J Ophthalmol.* 2013;97(11):1363-4.
- Muniesa MJ, Huerva V, Sánchez-de-la-Torre M, et al. The relationship between floppy eyelid syndrome and obstructive sleep apnoea. *Br J Ophthalmol.* 2013;97(11):1387-90. doi: 10.1136/bjophthalmol-2012-303051.
- Thean JH, McNab AA. Blepharoptosis in RGP and PMMA hard contact lens wearers. *Clin Exp Optom.* 2004;87(1):11-4.
- Sobel RK, Allen RC. Incidence of bilateral Marcus Gunn jaw-wink. *Ophthalm Plast Reconstr Surg.* 2014;30(3):e54-5. doi: 10.1097/OP.0b013e31829bb405.
- De Diego-Sastre JJ, Prim-Espada MP, Fernandez-Garcia F. The epidemiology of Bell’s palsy. *Rev Neurol.* 2005;41:287-90.
- Holland NJ, Weiner GM. Recent developments in Bell’s palsy. [Review] *BMJ.* 2004;329(7465):553-57.
- Prescott CA. Idiopathic facial nerve palsy (the effect of treatment with steroids) *J Laryngol Otol.* 1988;102:403-7
- Zandian A, Osiro S, Hudson R, et al. The neurologist’s dilemma: a comprehensive clinical review of Bell’s palsy, with emphasis on current management trends. *Med Sci Monit.* 2014;20:83-90. doi: 10.12659/MSM.889876.
- Turgeon RD, Wilby KJ, Ensom MH. Antiviral treatment of Bell’s palsy based on baseline severity: A systematic review and meta-analysis. *Am J Med.* 2014;pii: S0002-9343(14):01215-7. doi: 10.1016/j.amjmed.2014.11.033. [Epub ahead of print].
- Davagnanam I, Fraser CL, Miskiel K, et al. Adult Horner’s syndrome: a combined clinical, pharmacological, and imaging algorithm. *Eye (Lond).* 2013;27(3):291-8. doi: 10.1038/eye.2012.281.
- Renton AE, Pliner HA, Provenzano C, et al. A genome-wide association study of myasthenia gravis. *JAMA Neurol.* 2015. doi: 10.1001/jamaneurol.2014.4103. [Epub ahead of print].
- Mlakar J, Kocjan BJ, Hošriak L, et al. Morphological characteristics of conjunctival squamous papillomas in relation to human papillomavirus infection. *Br J Ophthalmol.* 2014;pii: bjophthalmol-2014-306087. doi: 10.1136/bjophthalmol-2014-306087. Epub ahead of print.
- Chetty P, Choi F, Mitchell T. Primary Care Review of Actinic Keratosis and Its Therapeutic Options: A Global Perspective. *Dermatol Ther (Heidelb).* 2015. [Epub ahead of print].
- Loghavi S, Curry JL, Torres-Cabala CA, et al. Melanoma arising in association with blue nevus: a clinical and pathologic study of 24 cases and comprehensive review of the literature. *Mod Pathol.* 2014;27(11):1468-78. doi: 10.1038/modpathol.2014.62. Epub 2014 Apr 18.
- Sullivan TJ. Squamous cell carcinoma of eyelid, periorcular, and periorbital skin. *Int Ophthalmol Clin.* 2009;49(4):17-24. doi: 10.1097/IIO.0b013e3181b7ecd1.
- Allali J, D’Hermies F, Renard G. Basal cell carcinomas of the eyelids. *Ophthalmologica.* 2005;219(2):57-71.
- Sanchez R, Ivan D, Esmali B. Eyelid and periorbital cutaneous malignant melanoma. *Int Ophthalmol Clin.* 2009;49(4):25-43.
- Osato MS. Normal ocular flora. In: Pepose JS, Holland GN, Wilhelmus KR, eds. *Ocular Infection and Immunity.* St Louis: Mosby;1996:191-9.
- Horn MM, Mastrota KM, Schachter SE. *Demodex.* *Optom Vis Sci.* 2013;90(7):e198-205. doi: 10.1097/OPX.0b013e3182968c77.
- Rusiecka-Ziółkowska J, Nokiel M, Fleischer M. *Demodex* - an old pathogen or a new one? *Adv Clin Exp Med.* 2014;23(2):295-8.
- Bhandari V, Reddy JK. Blepharitis: always remember *Demodex.* *Middle East Afr J Ophthalmol.* 2014;21(4):317-20. doi: 10.4103/0974-9233.142268.



MANUFACTURED  
IN THE USA

# Quality Comes Standard

**At M&S Technologies, we understand that a quality product makes for a quality customer experience.**

But there's more to a quality product than just what comes out of the box. There's service, there's support, there's reliability. M&S provides all of that. Our sales team is available to walk you through the many features and functions of the Smart System<sup>®</sup>, and our in-house technical team is standing by to respond to all of your service issues or questions.

We've been in business for almost 25 years and we take your business as seriously as you do. "Good enough" isn't good enough. If you're looking for a high-quality, comprehensive visual acuity testing system that comes with the best customer service and most attentive technical support in the industry, give us a call.

**See us at VISION EXPO EAST, Booth MS6716!  
Ask about our new Sports Testing Protocol**



*The Smart System 20/20 USA,  
shown with optional Glare Lights*



M&S holds US Patents 7,354,155; 7,926,948; 8,425,040;  
8,167,429; 8,419,184 & 8,550,631. Other Patents Pending.

©2015 M&S Technologies, Inc. Smart System and M&S are registered  
trademarks of M&S Technologies, Inc. All Rights Reserved.

**M&S**<sup>®</sup>  
**TECHNOLOGIES**

**The First Choice in  
Vision Testing Systems**

**[www.mstech-eyes.com](http://www.mstech-eyes.com)  
1-877-225-6101**

# A Lab in the Palm of Your Hand?

Point-of-care testing helps take the guesswork out of diagnosis by bringing data into the clinic—quickly. **By Blair Lonsberry, OD**

**D**iagnosis is rarely an exact science. Patients suffering from a multitude of ailments might display strikingly similar signs and symptoms, and subtle distinctions between different classifications of disease types can easily go unrecognized. Optometrists today benefit from an ever-increasing sophistication in our understanding of the causes and presentations of ocular disease. Still, outside of laboratory settings, hard data is hard to come by; we often must rely on clinical instincts and expertise when making the call.

That clinical conundrum has given rise to various in-office testing services. These seek to bridge the gap between the lab and the clinic by delivering hard, measureable evidence that may yield a diagnosis in relatively short order. With the advent of point-of-care (POC) testing, the clinician is able to obtain a result in a timely fashion—essentially in real time, for many—avoiding the hassle of sending the patient

to a different facility, risking incomplete or inaccurate testing.

While many of our most confounding differential diagnoses remain purely clinical, several conditions now allow us to turn to POC testing to provide a more comprehensive exam than ever before. Let's look at its use in practice, with a general overview of what the literature documents on the available tests and a series of illustrative cases.

## Adenoviral Conjunctivitis

Red eye is one of the top emergent reasons a patient will report to an eye clinic. A child with a red eye is often kept home from daycare or school until infectious “pink eye” is ruled out. Health care workers and individuals who work with the public also take the day for fear of spreading an infection. However, a patient presenting with acute-onset ocular redness can have any number of potential underlying etiologies. Clinicians prefer to treat these patients empirically.

• **Pathogen screening.** AdenoPlus (RPS) is the only currently available CLIA-waived point-of-care test that detects adenoviral infections. Incorporating the AdenoPlus test into a red eye work-up can help increase the accurate diagnosis of viral conjunctivitis, narrow down appropriate treatment options and help reduce the potential spread of the virus.

In a recent study, researchers looked at the specificity and sensitivity of AdenoPlus at detecting the presence of adenovirus in tear fluid as compared with both viral cell culture with confirmatory immunofluorescence assay (CC-IFA) and polymerase chain reaction (PCR).<sup>1</sup> Viral culture uses a series of primary cell lines that allow the replication of a wide variety of clinically relevant viruses. Specimens are inoculated onto cell culture monolayers and monitored for changes that occur in response to viral infection.<sup>2</sup> Immunofluorescence assay (IFA) uses fluorescent-labeled antibodies to detect

specific target antigens and is used extensively scientifically and clinically to identify specific antigens.<sup>2</sup> PCR allows for the synthesis of a new strand of DNA complementary to the offered template strand (e.g., adenovirus). DNA polymerase can synthesize DNA complementary to a presented target sequence, resulting in the production of billions of copies of the unknown virus.<sup>2</sup>

The study results demonstrated that when compared with CC-IFA, AdenoPlus showed a sensitivity of 90% and specificity of 96%. When AdenoPlus was compared only with PCR, it showed a sensitivity of 85% and specificity of 98%. When compared with both CC-IFA and PCR, AdenoPlus showed a sensitivity of 93% (27/29) and specificity of 98%.<sup>1</sup>

## Dry Eye

Numerous factors can predispose patients to dry eye, including increasing age, contact lens wear, meibomian gland dysfunction and autoimmune disease.<sup>3</sup> However, diagnosis is challenging, as patients may report with significant symptoms but no obvious signs of ocular surface compromise, or vice versa.<sup>3</sup>

Dry eye patients often experience inflammation associated with an increase in matrix metalloproteinases (MMPs). These proteolytic enzymes are produced by compromised epithelial cells on the ocular surface. Investigators have consistently shown MMP-9 elevated in the tears of patients with dry eyes.<sup>4</sup>

- **Measuring MMP.** InflammADry (RPS) samples tears for the presence of elevated MMP-9. Sambursky

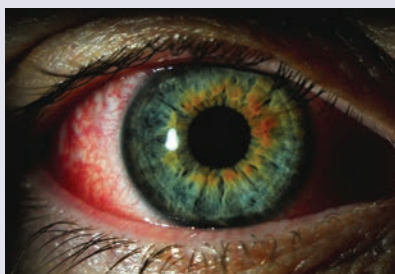xet al. evaluated 143 patients with clinical signs and symptoms of dry eye, and 63 healthy individuals serving as controls. Participants were assessed as healthy controls or clinically diagnosed with dry eye using a combination of the Ocular Surface Disease Index, Schirmer tear test, tear break-up time, and corneal and conjunctival staining. InflammADry demonstrated a sensitivity of 85% and specificity of 94% in diagnosing the dry eye cohort as compared with the healthy cohort.<sup>5</sup>

The ability to rapidly and reliably assess MMP-9 levels may lead to the clinician making an earlier diagnosis of dry eye and initiating management. Patients with MMP-9 levels less than 40ng/mL are thought to be in the “normal range” and not suffering from ocular surface disease,

## Adenoviral Conjunctivitis Case

*Courtesy of Blair Lonsberry, OD*

A 42-year-old white male presented on an emergent basis, with a red eye. His employer (at a fast food restaurant) expressed concern that he may be carrying “pink eye” and shouldn’t be at work until it was ruled out. The patient, however, reported that working around the heat of the cooking fryers occasionally triggers his allergies and causes eye redness.



**Is this patient’s ocular redness caused by allergies or a viral infection? A POC test was able to help find the answer.**

The patient reported that his right eye became red a “couple of days ago” and he has noticed the eye feeling “tender,” but not itchy. He reported taking Claritin for allergies. He stated that he hasn’t been sick recently, is not a contact lens wearer and notices some excess watering, especially outside. He reports his wife and daughter recently developed red eyes and were being treated.

- **Testing.** VA was measured at 20/25 uncorrected in both eyes with EOMs, pupils and visual fields unremarkable. A slit lamp examination (see image) revealed 2+ injection of the right eye and trace injection in the left eye. His cornea was clear, with no staining by sodium fluorescein or lissamine green, and trace papillae were noted on the upper lids. We performed the AdenoPlus test, collecting a sample from his right eye.

The results of the test are indicated through two lines, which appear in the result window: the control line and the result line. The control line is blue and indicates the correct application and performance of the test, and must appear for the test to be valid.<sup>1</sup>

The presence of both a blue and red or pink line in the result zone indicates a positive result. Even if the red or pink line is faint in color, incomplete over the width of the test strip or uneven in color, it must be interpreted as positive. A positive result indicates the presence of Adenovirus antigens.<sup>1</sup> The AdenoPlus test we performed presented with a dark red or pink line and the blue line, confirming a positive result for adenovirus.

- **Diagnosis and Treatment.** We diagnosed the patient with epidemic keratoconjunctivitis (EKC) secondary to the severity of the patient’s symptoms, his family members having a similar red eye and the intensity of the positive response on the AdenoPlus test. We treated him with betadine, prescribed a topical steroid to be used QID and informed him that he would not be able to return to work due to the potential infectious etiology of his condition. Educating him included advising him to limit contact with others, not share towels or washcloths and to wash his hands frequently. He was asked to return to the clinic the next day for follow up.

- **Analysis.** This case demonstrates the importance of being able to provide a patient with a concrete diagnosis, the appropriate management and patient education, in a timely manner. Until the AdenoPlus test confirmed a viral infection, the patient was convinced his symptoms were a result of allergies and dryness, and sought clearance to return to work. Performing the AdenoPlus test gave us an objective result indicating that his red eye was secondary to a viral infection and not allergies. The test prevented his coworkers and customers from exposure.

## MMP-9 and Sjögren's Case

*Courtesy of Douglas Devries, OD*

A 59-year-old pseudophakic Hispanic female returned to the clinic reporting constant foreign body sensation and dryness in both eyes. She had undergone cataract surgery 13 months earlier. She reported no relief with preservative-free artificial tears. She also reported a dry mouth and her speed score was recorded as 10.

- **Testing.** Slit lamp evaluation revealed 2+ MGD OU, 3+c conjunctival chalasis OU, and 1 to 2+ inferior SPK OU. RPS InflammADry testing was positive OU. The results of the Sjög test was positive for the salivary protein (SP-1) EgA antibodies.

- **Diagnosis and Treatment.** She was diagnosed with conjunctivochalasis, early Sjögren's syndrome with keratoconjunctivitis sicca. She was placed on Restasis, warm compresses, and scheduled for LipiView. She was also scheduled for conjunctival resection with fornix rebuild.

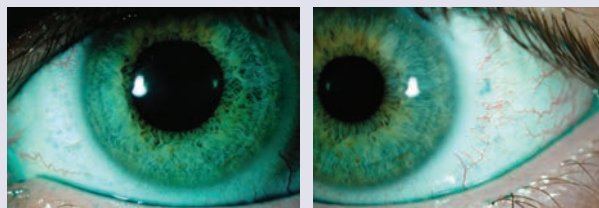
- **Analysis.** This patient has 3+ conjunctivochalasis, which likely contributed to her foreign body sensation as well as the inferior SPK due to poor wetting. The positive InflammADry testing suggests a moderate MMP-9 level, which appears as a result of stressed epithelial cells, a common finding in both dry eye disease and conjunctivochalasis. This patient will require comprehensive treatment for all of her ocular surface disorders.

and levels above 40ng/mL is considered elevated and abnormal and indicative of some form of ocular surface disease.<sup>4</sup> The determination of a patient having elevated MMP-9 levels, and therefore elevated inflammatory makers, may provide the clinician with an avenue of treatment that may have better efficacy, such as the use of anti-inflammatory agents (topical steroids, cyclosporine and other immunomodulators). An accurate measure of MMP-9 as an indication of inflammation on the ocular surface could be particularly important for the management of refractive or cataract surgery patients, where a stable tear film

## Tear Osmolarity Case

*Courtesy of Blair Lonsberry, OD*

A 55-year-old white female presented to the office on referral from her oculoplas-



**The patient exhibited positive lissamine green conjunctival staining nasally and temporally, with a reduced tear prism.**

tics surgeon to have a Schirmer test performed prior to blepharoplasty. The patient had a history of wearing a +2.00 contact lens only in her left eye (for near) and had been successful with a monovision correction for approximately 10 years. She noted her left eye sometimes feels a bit dry towards the end of the day while wearing her contacts, but had no problems with her right eye. Her medical history was unremarkable and she was not taking any medications.

- **Testing.** Uncorrected VA at distance was 20/20 in both eyes. Entrance skills were unremarkable. Prior to performing a slit lamp exam, a TearLab test was performed. The right eye's osmolarity was measured at 306mOsmol/L while the left was 347mOsmol/L.

Examination revealed an unremarkable right eye (no staining, adequate tear prism), but the left eye had positive lissamine green conjunctival staining both nasally and temporally, with a reduced tear prism (see images). A Schirmer test was then performed with anesthetic (as requested by the surgeon); it revealed the right eye contained 14mm of moisture while the left eye contained 12mm over five minutes.

- **Diagnosis and treatment.** We shared our results with the surgeon and indicated that her osmolarity and staining results indicated a dry eye condition even though the Schirmer results weren't significantly different. The surgeon recommended the patient begin Restasis (cyclosporine, Allergan) treatment prior to blepharoplasty surgery.

- **Analysis.** Although the Schirmer values were slightly lower in the left eye, they weren't low enough to be considered significant. However, the elevated osmolarity and positive staining made it evident that the patient was experiencing dryness in her left eye, likely associated with contact lens use. Performing the tear osmolarity and combining that with the positive staining resulted in the patient beginning treatment for her dry eye and potentially averting a more serious condition post-blepharoplasty.

is important in post-operative outcomes.

- **Testing tear osmolarity.** The Dry Eye Workshop consensus opinion published in 2007 included tear osmolarity changes in its dry eye definition. This is now seen as a hallmark sign, and a possible central mechanism, of the pathogenesis of dry eye.<sup>6</sup> A study by Bron et al. showed that, in healthy subjects, tear osmolarity is maintained in a relatively narrow range, with an average value of approximately 302mOsmol/L. Also of note, the study showed no significant difference in osmolarity between eyes (average around 6.9mOsmol/L).<sup>6</sup>

The study shows that increased osmolarity has a predictive relationship with dry eye inflammation.

TearLab provides a POC testing unit able to measure a patient's tear osmolarity in-office. The unit obtains a 50nL sample of tears from a patient's tear film and analyzes the sample, providing a measure of the patient's tear osmolarity.<sup>7</sup> The process of acquiring the tears is brief and straightforward, typically obtained from the lower temporal canthal area, resulting in minimal stimulation of reflex tearing.

In determining what "normal" osmolarity levels are for this protocol, 300 subjects were analyzed and

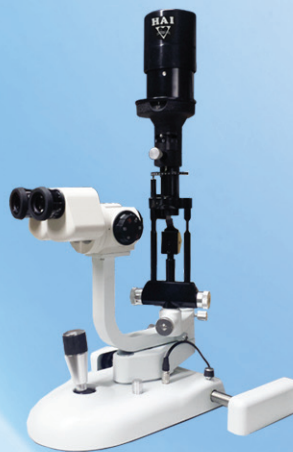**Visit us at Vision Expo East  
Booth #MS6403!**



**2015 NEW INVENTORY SALE PRICES**

	LIST PRICE	SALE PRICE
Basic Exam Lane Package*	\$12,998	\$12,850
SL-5000p Plus Slit Lamp	\$6,300	\$4,995
SL-5000s Standard Lamp	\$4,800	\$2,980
SL-5000bx Basic Slit Lamp	\$3,800	\$1,950
SL-5000h Handheld Slit Lamp	\$3,150	\$2,200
VC-170 17" LED Vision Chart	\$2,500	\$1,500
CL-1000eva Specular Attachment	\$14,800	\$13,500

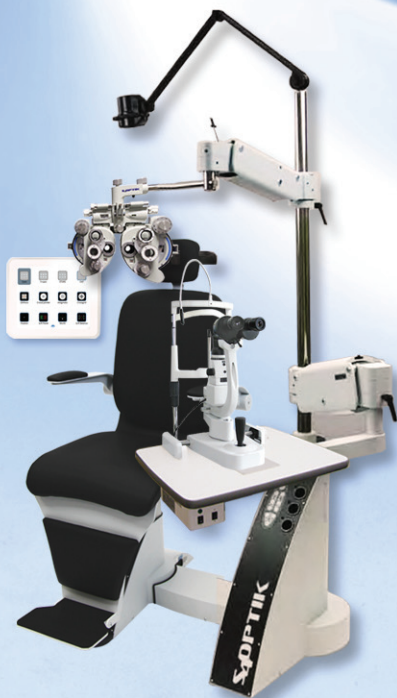\* Includes: HAI SL-5000b Basic Slit Lamp, HAI VC-170 17" LED Vision Chart, S4OPTIK CB-1600 Chair & Stand Combo and SL-Y100 Refractor



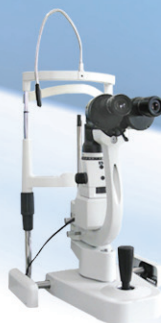**HAI SL-5000e  
Elevate Slit Lamp**

Introducing the world's first full-featured slit lamp designed for plus-sized patients and patients with limited mobility. By raising the first point of contact between patient and tabletop to the upper chest, the patient can comfortably reach the chinrest and the operator can conduct a thorough exam. Patent pending.

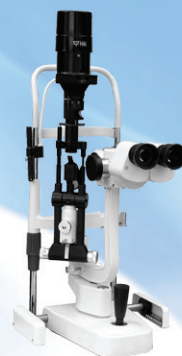*Call for pricing.*



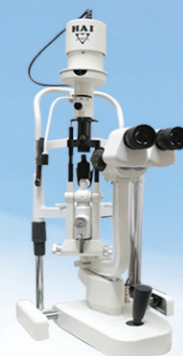**Basic Exam Lane Package**



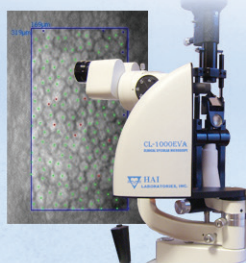
**HAI SL-5000bx  
Basic Slit Lamp**




**HAI SL-5000s  
Standard Slit Lamp**



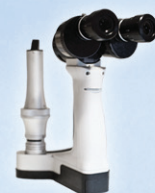**HAI SL-5000p  
Plus Slit Lamp**



**HAI CL-1000eva Endothelium  
Viewing Attachment**



**HAI CL-1000nc Non-Contact  
Specular Microscope**



**HAI SL-5000h  
Handheld Slit Lamp**

**RENT FROM  
\$385/mo**  
52-month term for  
rent-to-own

*Digital slit lamps • Specular microscopes • Corneal topographers • Keratometers • Ultrasounds • Vision charts  
Autorefractors • Lensmeters • Pachymeters • Tonometers • Trial lens sets • Chairs and instrument stands*



HAI Ophthalmic is a division of HAI Laboratories, Inc., an ISO 13485-certified US manufacturer.  
Call (781) 862-9884 or e-mail [sales@haiophthalmic.com](mailto:sales@haiophthalmic.com) for a free consultation.

## Diabetes Case

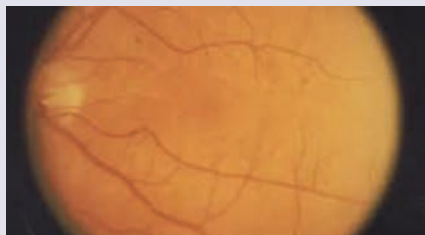
*Courtesy of Paul Chous, OD*

A 27-year-old white male presented for an eye exam. He has had Type 1 diabetes for 15 years. When asked what his last A1c value was, he said 120. He said his vision was fine, but his sister insisted that he get his eyes checked. The patient was taking Lantus and Humalog, his vision is correctable to 20/20 with an additional -1.25D (obvious myopic shift).

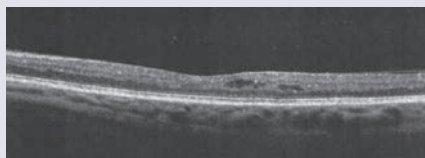
• **Testing.** His dilated fundus exam showed mild nonproliferative diabetic retinopathy in both eyes with no observable diabetic macular edema; however, an OCT image revealed significant macular thickening and the presence of diabetic macular edema. Using the A1cNow test, his level was determined to be 12%.

• **Diagnosis and Treatment.** The patient returned with his spouse to discuss what was observed on the OCT and his current diabetes control. The patient was educated that his control is not at an acceptable level and he was referred to an endocrinologist. He was placed on an insulin pump with continuous blood sugar monitoring. His A1c dropped to 7% over the next year with no changes in his nonproliferative diabetic retinopathy or OCT over 23 months. He has since referred some 20 patients to the office for vision exams—patients with and without diabetes.

• **Analysis.** Optometric physicians can order other tests and even obtain the necessary sample from the patient to be analyzed, but these tests do not provide a result immediately and often require a day or two to obtain the results.



**This diabetes patient's fundus shows mild non-proliferative diabetic retinopathy while the OCT image reveals significant macular thickening and diabetic macular edema.**



a composite disease severity index was created from the following standard dry eye tests: TBUT, Schirmer I, corneal and conjunctival staining, meibomian grading, osmolarity and the Ocular Surface Disease Index (OSDI) for symptomology.<sup>7</sup> Each patient was assigned a severity grade between 0 and 1, with 0 representing the absence of disease and 1 representing the most severe form of dry eye.<sup>7</sup> TearLab correctly identified 88% of the normal subjects, 75% of the mild and moderate disease patients, and 95% of the severe dry eye patients. Investigators determined a value of 308mOsmol/L was the diagnostic cut off between “normal” and “mild dry eye.”<sup>7</sup>

According to colleagues who have incorporated TearLab into their practices, regional variability does exist for what is considered “nor-

mal” tear osmolarity. Geographical areas featuring lower humidity levels tend to show a higher baseline tear osmolarity. It may be important to evaluate your patient population and determine a normal range of osmolarity for your area.

Measurement of tear osmolarity is not only a diagnostic tool; it has potential for use in patient education and compliance. Patients who undergo treatment for dry eye and have repeated osmolarity testing will often ask for their “number” in hope that whatever treatment has been initiated has lowered their osmolarity score. You can use that concrete number, and patients’ interest in it, to spur adherence on their part.

• **Testing for Sjögren’s.** The autoimmune disease Sjögren’s syndrome affects the exocrine-producing glands throughout the body. Clas-

## Get CLIA Certified for POC Testing

*By John Rumpakis, OD, MBA,  
Clinical Coding Editor*

Many tests performed at the point of care require that your office have a Clinical Lab Improvement Amendments (CLIA) waiver.

• **What is CLIA?** In 1988, Congress passed CLIA to establish quality standards for all laboratory testing to ensure the accuracy, reliability and timeliness of patient test results, regardless of where the test is performed.<sup>1</sup>

CLIA-waived tests were also defined as simple laboratory examinations and procedures that are cleared by the Food and Drug Administration (FDA) for home use, employ methodologies that are so simple and accurate as to render the likelihood of erroneous results negligible, or pose no reasonable risk of harm to the patient if the test is performed incorrectly. These regulations were further revised in 1997 to make it clear that tests approved by the FDA for home use automatically qualify for CLIA waiver.

• **How do you become CLIA certified?** Performing CLIA-waived tests, and obtaining reimbursements for them, require your office be designated as a CLIA-approved laboratory and one of your doctors be designated and approved as a clinical lab director.

Apply with CMS to get your CLIA certification ([www.cms.gov/Regulations-and-Guidance/Legislation/CLIA/How to Apply for a CLIA Certificate International Laboratories.html](http://www.cms.gov/Regulations-and-Guidance/Legislation/CLIA/How%20to%20Apply%20for%20a%20CLIA%20Certificate%20International%20Laboratories.html)). Having this certification for both the office and the physician is absolutely critical to perform and bill for these point-of-care tests.

1. Centers for Medicare & Medicaid Services website. Clinical Laboratory Improvement Amendments (CLIA). Available at: [www.cms.gov/Regulations-and-Guidance/Legislation/CLIA/index.html](http://www.cms.gov/Regulations-and-Guidance/Legislation/CLIA/index.html). Accessed February 17, 2015.

sically, patients who present with Sjögren’s suffer from dry eyes and dry mouth. Due to its multisystem involvement, this condition

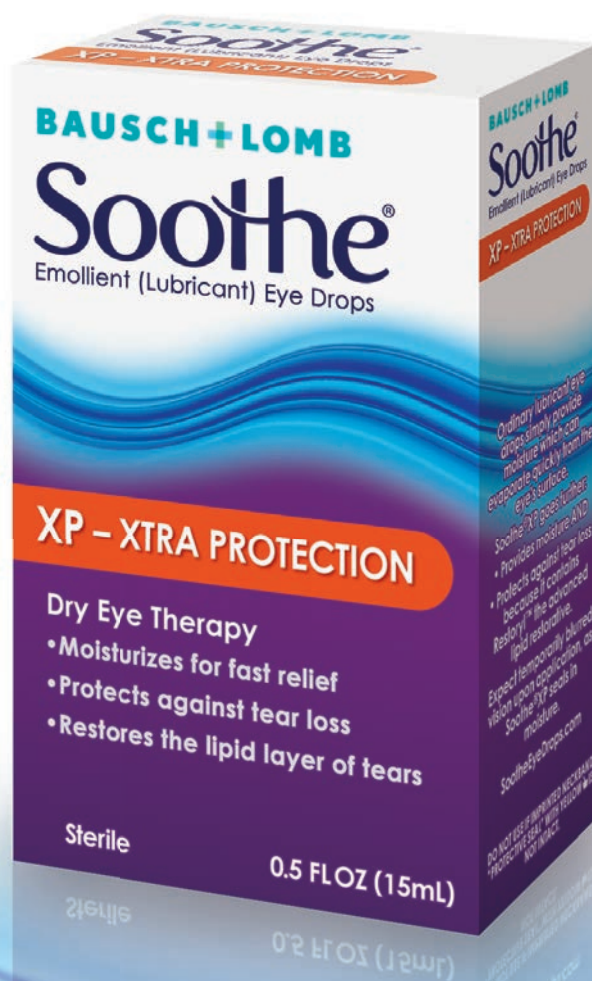

# RELIEF AT THE MAIN SOURCE of dry eye symptoms

Target Lipid Layer Deficiency:

## Soothe<sup>®</sup> XP

With Restoryl<sup>®</sup> Mineral Oils



**Recommend Soothe XP as your first choice for dry eye patients.  
To request samples, please call 1-800-778-0980.**

Now available at major retailers nationwide.

Distributed by Bausch + Lomb, a Division of Valeant Pharmaceuticals North America LLC, Bridgewater, N.J. © 2015 Bausch & Lomb Incorporated. Soothe and Restoryl are trademarks of Bausch & Lomb Incorporated or its affiliates. All other brand/product names are trademarks of their respective owners. PNS07412 US/SXP/14/0006

**BAUSCH + LOMB**  
See better. Live better.

# In-Office Testing

is often difficult to diagnose, as a patient may end up seeking care from multiple specialists, who may overlook the overall condition, as each specialist only addresses their particular area of expertise without putting the entire picture together. Two forms of Sjögren's syndrome exist: primary Sjögren's syndrome, which has no additional autoimmune disease associated, and secondary Sjögren's syndrome, which can present in conjunction with an additional autoimmune disease (usually rheumatoid arthritis).<sup>8</sup> Patients are often symptomatic with Sjögren's syndrome for upwards of 10 years before being diagnosed with the condition.<sup>8</sup> This can result in significant quality of life concerns

and may also be life-threatening, as Sjögren's syndrome is associated with a 16-fold increased risk of development of lymphoma.<sup>8</sup>

The Sjö (Nicox) test can help determine if a patient's dry eye can be attributed to an underlying systemic etiology. A doctor or technician obtains blood on a collection card and sends it to a lab for analysis. A report is generated with results including rheumatoid factors, antinuclear antibodies, rho and la (Sjögren's syndrome antibodies) and three biomarkers (salivary gland protein-1, carbonic anhydrase-6 and parotid secretory protein) unique to the test that the company says can pick up Sjögren's earlier than the others.

An early diagnosis of Sjögren's syndrome is crucial for the long-term management of these patients.

## Diabetes

Diabetes is a major public health concern. Dealing with diabetes involves a complicated dance of managing blood sugar, blood pressure and cholesterol. Patients are asked to routinely check blood sugar levels, which gives them an indication of daily fluctuation. Additionally, an A1c (glycosolated hemoglobin) is a measure of a patient's blood sugar over a three-month time period with normal values between 4% and 6%. A1c tests give the patient and practitioner an indication of the patient's blood sugar control over an extended period of time.<sup>9</sup>

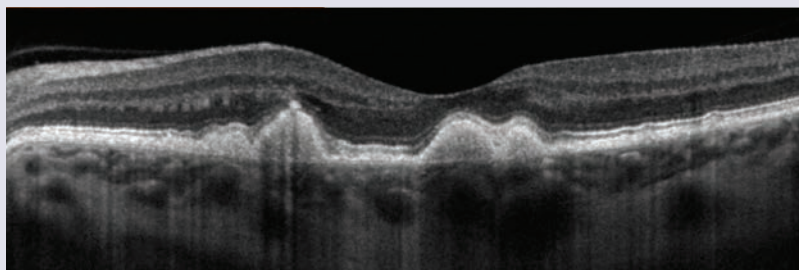
When reviewing diabetic patients' medical histories, patients are often hard-pressed to give concrete numbers with respect to blood sugar control and, in particular, being able to recall A1c values.

- **A1c testing units.** In-office A1c testing units provide POC testing that can give doctors those concrete numbers. Several CLIA waived POC A1c testing units are available on the market. Some check only A1c. Others have a combined function and analyze a variety of lab tests.

Patients' development of complications secondary to diabetes, such as diabetic retinopathy, kidney and heart disease, and peripheral neuropathy, is dependent on a combination of length of the disease state, blood sugar, blood pressure and cholesterol control.

The ability for an optometric physician to obtain a current A1c value provides valuable management information.

Spaeth et al. assessed the use of point-of-care A1c testing in a



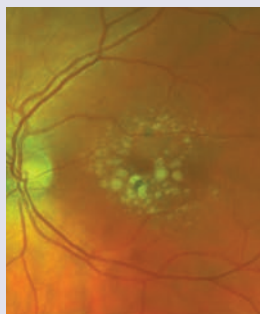
This OCT image and the fundus image below show a patient with AMD who has a concerning phenotype. Genetic testing helped her live with her diagnosis.

## AMD Case

*Courtesy of Jeffrey Gerson, OD*

A 55-year-old female patient presented to the clinic concerned that she is "going to go blind" from AMD. The patient currently takes supplements.

- **Testing.** Evaluating her fundus and performing an OCT (see images) shows that the patient has a concerning phenotype with significant drusen in/surrounding the macular area. We discussed with her the potential role of genetic testing and that the costs would be covered by her medical insurance. She agreed to undergo testing.



- **Diagnosis and Treatment.** The test categorized her as being at risk level MR2, i.e., no more at risk than average. Her phenotype is a lot more "scary" than her genotype.

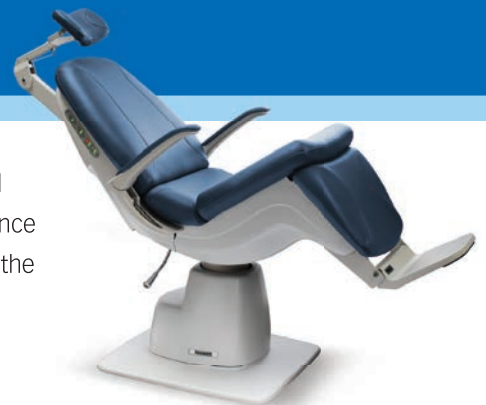- **Analysis.** The patient is still monitored every four months, but is much less worried because she knows the results of the genetic test. The genetic testing result eased the patient's anxiety and helped her calmly live with her diagnosis.

1. Quick Reference Guide. AdenoPlus: An RPS Diagnostic Solution. [http://www.rpsdetectors.com/en/wp-content/uploads/2013/08/FORM-MKT-014.2-AdenoPlus-QRG\\_Rev.pdf](http://www.rpsdetectors.com/en/wp-content/uploads/2013/08/FORM-MKT-014.2-AdenoPlus-QRG_Rev.pdf). Accessed 2/18/2015



## Boxer Randall Jones comments on the strength of Reliance arms.

Reliance chairs are built to take a beating. The armrests, footrest, chair back and apron can all withstand a patient's full weight. It's not surprising, then, that Reliance chairs last longer, and require very little maintenance. This is why they're one of the world's best-selling brand of chairs and stools. Call today for the name of your nearest authorized dealer.



800.787.5426  
[haag-streit-usa.com](http://haag-streit-usa.com)

© 2015 Haag-Streit USA. All Rights Reserved.

 **RELIANCE  
INTERNATIONAL**

# In-Office Testing

remote village in Australia and determined that the use of POC A1c testing improved patient A1c values as compared to laboratory A1c testing.<sup>10</sup> On average the testing was able to lower A1c values by 1.5% by providing patients with a reliable and rapid indication of blood sugar control as compared with lab testing, where blood samples had to be sent off for analysis and results often took several days to weeks.<sup>10</sup>

## AMD

Most patients with age-related macular degeneration are in the “dry” or non-exudative category where vision loss is modest and presents with retinal findings such as drusen, RPE clumping and potential atrophy. Patients who develop significant vision loss are typically in the “wet” or exudative stage, where patients have developed a choroidal neovascular membrane in the macular area, resulting in significant scarring.<sup>11</sup>

• **Genetic tests.** Risk factors for the development of AMD include increasing age, smoking, UV exposure, family history and genetic profile. Genetic tests may provide a sense of risk of developing AMD.<sup>12</sup>

Macula Risk PGx (ArcticDx) combines a patient’s current AMD status, genetic predisposition and non-genetic risk factors to determine the two-, five- and 10-year risk of developing advanced AMD, defined as either geographic atrophy or choroidal neovascularization (CNV).<sup>12</sup>

RetnaGene (Valeant) is a genetic test for Caucasian patients age 55 and older with early or intermediate AMD that evaluates genotype, phenotype, age and environmental risk (e.g., smoking status) and predicts a patient’s individual risk for disease progression to CNV within

two-, five- and 10 years. RetnaGene predicts a patient’s individual lifetime risk at age  $\geq 55$  for developing advanced AMD.<sup>12</sup>

Macula Risk PGx and RetnaGene tests rely on a sample of epithelial cells obtained by a buccal (cheek) swab and sent for analysis.

The addition of point-of-care testing gives optometrists a greater variety of diagnostic tools to consider and reduces our reliance on the old “wait-and-see” approach. Using these tests can provide doctors with first-hand evidence of disease—yielding an advantage in time and confidence that we can use to deliver early, targeted treatment.

The tests aren’t foolproof, and hundreds of other conditions are not currently within their purview, but this newer approach is a welcome complement to a clinical work-up. ■

1. Sambursky R, Trattler W, Tauber S, et al. Sensitivity and specificity of the AdenoPlus test for diagnosing adenoviral conjunctivitis. *JAMA Ophthalmology*. 2013;131(1):17-22.
2. Seal, DV, & Pleyer, U. *Ocular Infection*. New York: CRC Press; 2007.
3. Lin H, Yiu S. Dry eye disease: A review of diagnostic approaches and treatments. *Saudi Journal of Ophthalmology: Official Journal of the Saudi Ophthalmological Society*. 2014;28(3):173-81.
4. Sambursky R, Davitt W, Friedberg M, Tauber S. Prospective, multicenter, clinical evaluation of point-of-care matrix metalloproteinase-9 test for confirming dry eye disease. *Cornea*. 2014;33(8):812-8.
5. Sambursky R, Davitt W, Latkany R, et al. Sensitivity and specificity of a point-of-care matrix metalloproteinase 9 immunoassay for diagnosing inflammation related to dry eye. *JAMA Ophthalmology*. 2013;131(1):24-8.
6. Bron A, Tomlinson A, Foulks G, et al. Rethinking dry eye disease: a perspective on clinical implications. *The Ocular Surface*. 2014;12(2):S1-31.
7. Versura P, Campos EC. TearLab Osmolarity System for diagnosing dry eye. *Expert Review of Molecular Diagnostics*. 2013;13(2):119-29.
8. Goules A, Tzioufas A, Moutsopoulos H. Classification criteria of Sjögren’s syndrome. *Journal of Autoimmunity*. 2014;48:49-42-5.
9. Kovacic J, Castellano J, Farkouh M, Fuster V. The relationships between cardiovascular disease and diabetes: focus on pathogenesis. *Endocrinology and Metabolism Clinics of North America*. 2014;43(1):41-57.
10. Spaeth B, Shephard M, Schatz S. Point-of-care testing for haemoglobin A1c in remote Australian Indigenous communities improves timeliness of diabetes care. *Rural and Remote Health*. 2014;14(4):2849.
11. Solans-Laqué R, Lopez-Hernandez A, Bosch-Gil J, et al. Risk, predictors, and clinical characteristics of lymphoma development in primary Sjögren’s syndrome. *Seminars in Arthritis and Rheumatism*. 2011;41(3):415-23.
12. Seddon J, Reynolds R, Yu Y, et al. Risk models for progression to advanced age-related macular degeneration using demographic, environmental, genetic, and ocular factors. *Ophthalmology*. 2011;118(11):2203-11.

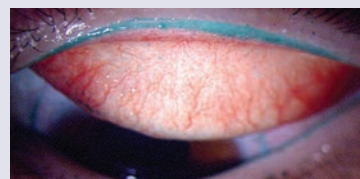


Photo: Centre for Contact Lens Research

Lid wiper epitheliopathy (shown here in a different patient) was also present in this case.

## Sjögren’s Syndrome Case

Courtesy of Dave Kading, OD

A 38-year-old female presented with irritation and dryness. She noted the irritation had been increasing over the last few years. Dry eye evaluation noted a slight decrease in tear volume (through tear meniscus height evaluation), but what a decrease in the length of her meibomian glands was significant. A blink evaluation showed partial blinks in both eyes.

• **Testing.** The lids were normal in appearance, but with pressure (using the TearScience Meibomian Gland Expresser) we noted a significant decrease in the flow of meibum. Her InflammADry test was negative for inflammation. We performed Sjög testing. Staining was grade 1 corneal and positive on the lid wiper area (defined as that portion of the marginal conjunctiva of the upper lid that wipes the ocular surface during blinking)

• **Diagnosis and Treatment.** After reviewing the tests, our assessment was dry eye secondary to MGD and gland atrophy. Our treatment plan involved treatment with Lipiflow, lipid-based artificial tears and blink exercises.

• **Analysis.** At the patient’s follow up, she indicated improvement in symptoms. Clinically, we observed decreased lid wiper staining, normal meibomian gland secretion and resolution of the previous corneal staining. At the follow-up, we went over the Sjög test results; it indicated positive markers for Sjögren’s. This gave us the evidence we needed to begin the patient on a long-term Restasis (cyclosporine, Allergan) regimen, continue blink exercises and refer her to rheumatology for further evaluation and management.

OCULUS Easyfield® C

# Speed and Accuracy



**Celebrating 15 years  
of Innovative Perimetry and  
Customer Satisfaction!**

For a \$350 Discount-  
Voucher\* please visit  
[OCULUSvoucher.com](http://OCULUSvoucher.com)  
or come see us at  
Vision Expo East,  
Booth MS 7049

**All essential features  
in a compact body:**



- SPARK: Threshold perimetry in less than 3 minutes!
- Static perimetry: screening and threshold exams
- 30-2, 24-2, 10-2 and customizable patterns
- Chinrest and eye-shields for maximum patient comfort

\* This offer cannot be combined with any other discounts or special offers. Only for a new Easyfield®. Non-refundable. Non-transferable. No cash value. US Customers only. Expiration date 12/31/2015

Toll free 888-519-5375  
[ads@oculususa.com](mailto:ads@oculususa.com) [www.oculususa.com](http://www.oculususa.com)

  
[facebook.com/OCULUSusa](https://facebook.com/OCULUSusa)  
 **OCULUS®**



## Go Further—Without Leaving Home



Expand your clinical skills and catch up on your CE requirements, all from the comfort of your own home.

*Review* offers **nearly 100 hours** of COPE-approved continuing education — right now! It's **just a click away**. Our extensive library of exams runs the gamut from keratoconus to fundus autofluorescence, and everything in between.



[www.reviewofoptometry.com/continuing\\_education](http://www.reviewofoptometry.com/continuing_education)

Download a QR scanner app. Launch app and hold your mobile device over the code to view [www.reviewofoptometry.com/continuing\\_education](http://www.reviewofoptometry.com/continuing_education).

**REVIEW**<sup>®</sup>  
OF OPTOMETRY

## Diagnostic Skills &amp; Techniques



# Seeing Double:

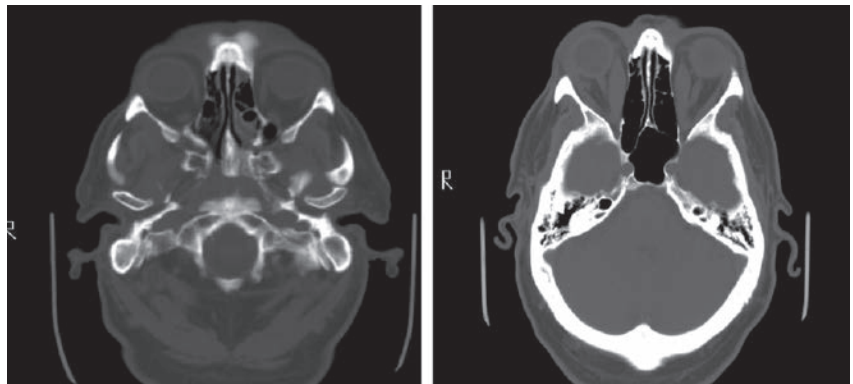
## The Urgent and Chronic Causes of Diplopia

Double vision can originate from many conditions. Learn to recognize when this presentation is an emergency and when it's indicative of a long-term issue.

By Jim Williamson, OD

Optometrists are no strangers to double vision, but when a patient presents with it, ensuring that we correctly identify the cause can be a daunting task. While diplopia can present for numerous reasons, the first thing we need to do is either recognize or rule out urgent conditions, and then (in the latter case) explore the possibility that it may stem from a chronic condition. This article will focus on recognizing the chronic and urgent medical causes of diplopia. These will be loosely grouped by systemic disease, neurological etiologies and eye or orbital conditions.

First, we'll review oculomotor control, as the diagnosis may involve systemic or neurological factors with potentially serious consequences.



CT scan of the same patient before and after the diagnosis of Graves' disease. Note the markedly enlarged medial recti.

### Oculomotor Control

Two main pathways are involved in oculomotor function: the supranuclear and infranuclear pathways. The supranuclear route controls pursuits, saccades, vergences and

horizontal and vertical gaze. As these are all symmetrical ocular movements, lesions here generally do not prompt diplopic complaints, though exceptions exist which will be discussed later.

**Release Date:** March 2015

**Expiration Date:** March 1, 2018

**Goal Statement:** Double vision can occur from many serious conditions involving the neuromuscular anatomy and ocular media. This article will review the chronic conditions (e.g., myasthenia gravis, Graves' disease, multiple sclerosis, diabetes) as well as urgent presentations (e.g., stroke, aneurysm, tumor, giant cell arteritis) that may cause it.

**Faculty/Editorial Board:** Jim Williamson, OD

**Credit Statement:** COPE approval for 2 hours of CE credit is pending for this course. Check with your local state licensing board to see if this counts toward your CE requirement for relicensure.

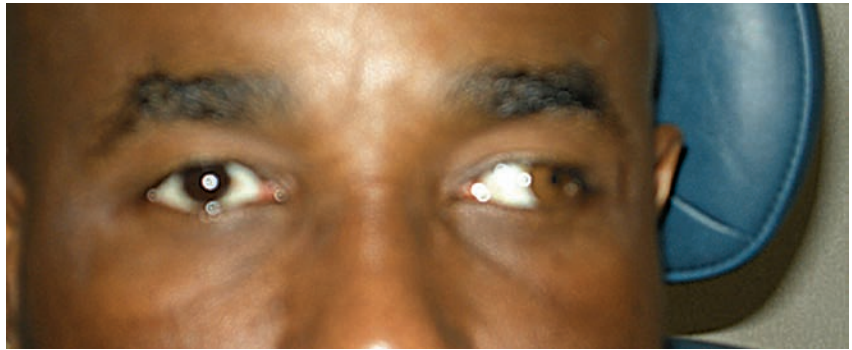**Joint-Sponsorship Statement:** This continuing education course is joint-sponsored by the Pennsylvania College of Optometry.

**Disclosure Statement:** Dr. Williamson has no relevant financial relationships to disclose.

The infranuclear pathway begins in each cranial nerve nucleus and proceeds to innervate the respective extraocular muscles (EOMs), as follows:

The oculomotor nerve, CN III, emerges from the anterior aspect of the midbrain. From there, it enters the subarachnoid space in the interpeduncular cistern between the posterior cerebral and superior cerebellar arteries and then runs lateral to the posterior communicating artery (PCA).<sup>1,2</sup> After penetrating the arachnoid and internal layer of the dura, it moves into the cavernous sinus, where it lies superior to the trochlear nerve and lateral to the internal carotid artery. The nerve then splits into a smaller superior and larger inferior division, which enter the orbit through the superior orbital fissure.<sup>1,2</sup> The superior division supplies the superior rectus and the levator palpebrae. The inferior division further divides into three branches to innervate the inferior oblique and the medial and inferior recti.<sup>3</sup> Additionally, the longest inferior oblique branch has parasympathetic fibers that synapse in the ciliary ganglion. The postganglionic fibers pass through the short ciliary nerves to the sphincter pupillae and ciliary muscles.<sup>1,2</sup>

The trochlear nerve, CN IV, is the only cranial nerve to emerge from the posterior aspect of the midbrain.<sup>3</sup> As it supplies just one muscle—the superior oblique—the trochlear is the smallest of all cranial nerves and yet has the longest intracranial course.<sup>1,2</sup> It moves laterally and forward in the subarachnoid space around the cerebral peduncle and enters the lateral wall of the cavernous sinus inferior to the oculomotor nerve. Continuing through the superior orbital fissure above the fibrous ring, it arrives at the superior oblique muscle as a series of small branches.<sup>1,2</sup>



**Due to its often transient nature and variability, treating pathologic diplopia can be challenging. Often, treatment consists of use of Fresnel prisms or occlusion. Younger patients or those concerned with cosmesis can further limit the choices. Such was the case for this MS patient with a right INO. The solution entailed fitting the patient in a tinted soft contact lens with an opaque pupil.**

The abducens nerve, CN VI, leaves the ventral aspect of the brainstem between the border of the pons and medulla oblongata. It ascends through the subarachnoid space along the clivus as it courses anterolaterally through the pontine cistern.<sup>1,2</sup> Following a sharp bend over the petrous part of the temporal bone (which makes it vulnerable to injury and increased intracranial pressure), it passes through the cavernous sinus where it first lies lateral and then inferolateral to the internal carotid artery.<sup>3</sup> Like CN III and IV, the superior orbital fissure provides orbital access to the abducens nerve, where it enters the medial side of the lateral rectus muscle.<sup>1,2</sup>

### Systemic Diseases

Eye care practitioners must evaluate whether the onset of diplopia is a sign of a larger, systemic disease. Patients presenting with diplopia may or may not be aware of systemic conditions behind their visual symptom. These can include life-altering diagnoses such as Alzheimer's, Parkinson's or giant cell arteritis. Here are ways optometrists can learn to recognize the signs associated with these diplopia-causing systemic diseases:

- *Myasthenia gravis.* Optome-

trists are often the first to encounter myasthenia gravis (MG), as many of these patients have ocular sequelae such as ptosis and diplopia.<sup>4</sup> In MG, acetylcholine receptor (AChR) antibodies block effective transmission of the chemical to muscle synapses, resulting in weakness. In addition to ophthalmic involvement, MG may also lead to arm and leg fatigue, difficulty chewing and swallowing, speech problems and, in severe cases, breathing impairment.

The key to distinguishing this from other neurological disorders lies with the fluctuation in symptoms, which are typically worse as the day progresses. Remember that ptotic patients may not complain of diplopia, due to occlusion. Extraocular muscles should be examined with the lid retracted. Statin use has been associated with MG and, though rare, should be considered, given the widespread use of this drug class.<sup>5</sup>

Three quick and simple in-office tests can help confirm the suspicion of MG. First, ask the patient to sustain upgaze while you look for superior rectus or levator fatigue. Second, perform the highly specific ice pack test by placing ice on the eyelid for two minutes and evaluating for ptosis improvement.<sup>6</sup>

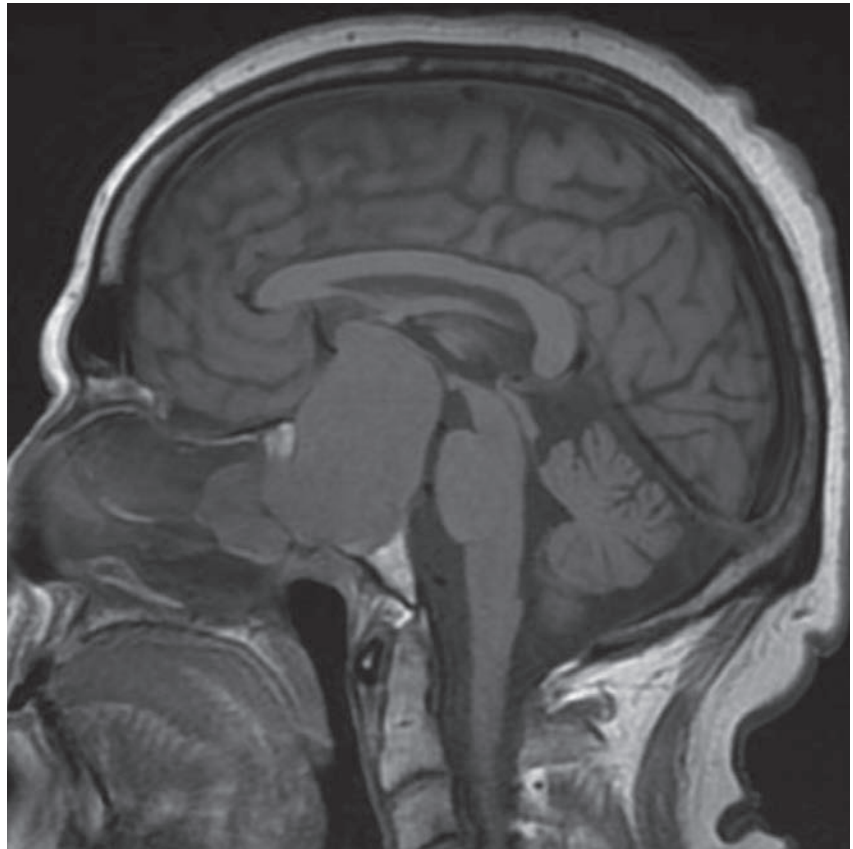


Third, evaluate for orbicularis oculi weakness by attempting to open the patient's eyelids after forceful closure. For bloodwork, order the AChR-antibody tests (binding, blocking and modulating), but keep in mind that this can be negative in 45% to 65% of patients with ocular symptoms only (i.e., ocular myasthenia gravis).<sup>7</sup>

- **Parkinson's disease.** Among the neurological conditions that can cause diplopia, only Alzheimer's has a higher prevalence than Parkinson's disease, so optometrists can expect to see many of these patients.<sup>8</sup> Degenerating cells within the substantia nigra result in a biochemical loss of the neurotransmitter dopamine, which in turn may affect oculomotor control. Saccades, pursuits and vergences can all be involved. Dopaminergic treatment, though effective in providing some improvement in gross motor skills, has little effect on oculomotor deficits, so even well-controlled Parkinson's disease patients can report visual changes.<sup>9</sup> Remember when assessing EOMs in elderly patients that some restriction may occur even without a pathological cause. This typically involves upgaze and could be due to changes in orbital tissue.<sup>10</sup> Though optometrists don't treat Parkinson's disease, some authors suggest obtaining an OCT scan to measure macular ganglion cell/inner plexiform layer thickness as a way to monitor its progression.<sup>11</sup>

- **Microvascular disease.** In 2013 researchers reviewed 109 patients with isolated CN III, IV and VI palsies and identified microvascular ischemia as the cause in nearly 85% of cases.<sup>12,13</sup> At risk are those with diabetes, hypertension or hyperlipidemia, as well as patients over 60.

Because of this, consensus opinion varies regarding the need for costly neuroimaging of these infranuclear incidents.<sup>12,14</sup> The deci-



**A 63-year-old patient presented with a complaint of decreased visual acuity OU. Confrontational visual fields picked up a bitemporal hemianopsia. Subsequent MRI showed a massive 5.7cm x 6.0cm x 8.8cm pituitary macroadenoma.**

sion to delay should coincide with the clinician's ability to obtain a thorough history, uncover systemic symptoms and locate relevant ophthalmic findings. Experts agree, however, on the need for an immediate radiological work-up in the following scenarios:<sup>14</sup>

- patients younger than 50
- history of cancer
- evidence of combined cranial neuropathies
- incomplete or pupil-involving CN III palsies

Regarding the latter, up to 20% of ischemic CN III palsies have anisocoria, but often less than 2mm.

Features of aberrant regeneration of CN III indicate a non-microvascular etiology necessitating immediate work-up.

If the CN palsy is microvascular in etiology, it should show significant resolution in three months (the 90-day rule). If neuroimaging is not done, the patient needs to be monitored closely over the first several months. If the magnitude of the deviation worsens, or does not improve as expected with microvascular disease, obtain prompt neuroimaging.

- **Orbital inflammatory disease.** Thyroid eye disease can be caused by hyperthyroidism, Hashimoto's thyroiditis and primary hypothyroidism. Of these, Graves' disease is the most common. In this autoimmune disorder, antibodies bind to the thyroid surface and stimulate the overproduction of thyroid hormones, which leads to hyperthyroid-

ism. Approximately half of patients will develop thyroid-associated orbitopathy (TAO)—a type of orbital inflammatory disease.<sup>15</sup> Extraocular muscle inflammation or fibrosis limits eye movement and produces diplopia. The inferior rectus is often affected first, followed by the medial, superior and lateral recti.<sup>16</sup>

Smoking is a well-known, though not completely understood, risk factor for TAO. Some say it activates the pathways associated with adipogenesis and inflammation.<sup>17</sup> Regardless, Graves' disease patients should be advised to quit.

Several recent studies suggest a relationship between TAO and elevated immunoglobulin G4 (IgG4).<sup>18,19</sup> They advocate screening for these levels to determine the likelihood of developing TAO.<sup>19</sup> Patients with increased IgG4 tended to be older, responded well to anti-thyroid medications, and were more prone to hypothyroid after drug treatment.<sup>18</sup>

Other systemic inflammatory conditions associated with orbital inflammatory disease include sarcoidosis and granulomatosis with polyangiitis (GPA), formerly known as Wegener's. Non-caseating granulomas characterize sarcoidosis, along with hilar lymphadenopathy seen on chest X-ray and elevated serums levels of angiotension converting enzyme (ACE). GPA is a disease of small- and medium-sized blood vessels, with patients having abnormal levels of cytoplasmic antineutrophil cytoplasmic antibody (c-ANCA). Additionally, infection and tumor must be considered in orbital inflammatory disease cases.

- **Giant cell arteritis.** The most common systemic vasculitis, giant cell arteritis is also the most feared from an ophthalmic standpoint due to the potential for permanent vision loss.<sup>20</sup> While the incidence of diplopia with giant cell arteritis

### Table 1. Questions to Ask Patients with Diplopia

- Does it go away when you cover one eye?
- Are the images side-by-side or on top of each other?
- Is it better or worse at distance or near?
- Is it constant or variable?
- Do you experience any associated pain?
- How long has this been occurring?
- Have there been any previous episodes?
- Have you noticed a droopy eyelid?

is small (between 2-15%),<sup>21,22</sup> it deserves mentioning, especially if it occurs with other symptoms such as headache, neck pain, fever, malaise, weight loss, jaw claudication and temporal artery tenderness. Also, diplopia usually precedes visual loss and may be an early indication of giant cell arteritis.<sup>21</sup> If suspected, immediately order an erythrocyte sedimentation rate and C-reactive protein. A positive temporal artery biopsy confirms the diagnosis,<sup>22</sup> but a negative result does not exclude it.<sup>21</sup> Prompt diagnosis and treatment with high-dose systemic corticosteroids are keys to a more favorable outcome.

### Neurological Etiologies

When double vision begins in the brain, the cause can range from a mild injury to serious conditions such as a tumor or aneurysm. To narrow down the possibilities, get a proper history and understand which patients are at-risk with the following guide:

- **Traumatic brain injury.** Types and severities of TBI range broadly from a mild concussion to those involving loss of consciousness, post-traumatic amnesia, disorientation or other neurological disorders.<sup>23</sup> Dysfunctions of oculomotor control may be seen with all classi-

fications. Symptoms include blurred vision, difficulty following targets, reading problems and diplopia.<sup>24</sup>

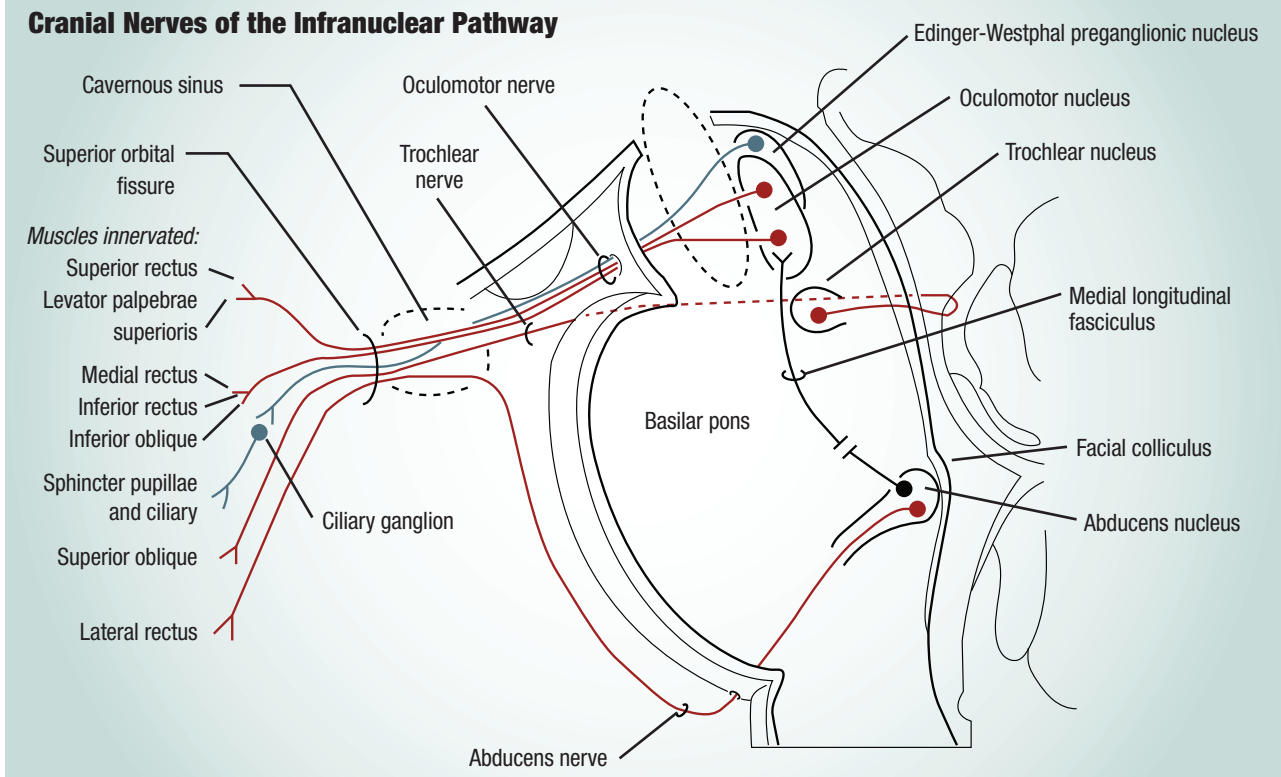
It is important to note that some patients experience a delayed onset of symptoms—therefore, a remote history of head trauma could prove significant. One of the most common issues in mild TBI is convergence insufficiency.

- **Supranuclear lesions.** As noted previously, the supranuclear pathway controls symmetrical eye movements; thus, lesions here should not cause diplopia. The two main exceptions are internuclear ophthalmoplegia (INO) and skew deviation. INO stems from a lesion in the highly myelinated medial longitudinal fasciculus, which connects the abducens nuclei in the pons to the oculomotor nuclei in the midbrain.<sup>25</sup>

Patients with INO are unable to adduct and may have a nystagmus when abducting the fellow eye. A bilateral INO presentation or occurrence in a young individual frequently indicates multiple sclerosis (MS), while vascular ischemia accounts for the majority of unilateral or elderly INO cases.<sup>26</sup> Convergence may be affected in some patients, depending on the location of the lesion. The center for convergence is in the midbrain. So, midbrain lesions affect convergence while pontine lesions spare it.

Skew deviation is a vertical misalignment that does not localize to any one particular cranial nerve or cyclovertical muscle (i.e., superior and inferior recti or obliques). Skew deviation most commonly results from faulty prenuclear vestibular input to the ocular motor nuclei or damage to the MLF in the brainstem.<sup>27,28</sup> It is most commonly associated with cerebellum, brainstem or vestibular lesions. When skew deviation is accompanied by ocular torsion and head tilt, it is called the ocular tilt reaction.<sup>28</sup>

## Cranial Nerves of the Infranuclear Pathway



The oculomotor nerve (CN III), the trochlear nerve (CN IV) and the abducens nerve (CN VI) are key to the infranuclear pathway, one of the two main pathways involved in ocular motor controls. Such functions may be affected by systemic or neurological diseases that cause diplopia. These diseases can have potentially serious side consequences.

- **Aneurysm.** A common location for intracranial aneurysms is the junction of the internal carotid artery and the posterior communicating artery.<sup>29</sup> It should be no surprise, then, that an aneurysm in this area puts the oculomotor nerve at risk, since it runs lateral to the PCA. Also, since pupillomotor fibers run on the surface of CN III, a compressive aneurysm would likely produce pupillary involvement, which may be the first feature. An aneurysm should be ruled out in any CN III palsy with associated pain or full/partial pupillary involvement, especially in patients less than age 50 or without vasculopathic risk factors.<sup>30</sup>

Standard of care in these patients dictates emergent referral with immediate imaging. While the gold standard for aneurysm detection is cerebral catheter angiography, com-

puterized tomographic angiography (CTA) is preferred.<sup>31</sup> Should a contraindication exist for contrast dye (e.g., pregnancy, allergy, impaired renal function), a magnetic resonance angiography (MRA) would be performed. CTA takes only a few minutes, with the bulk of time spent on image post-processing. It outperforms MRA in detecting aneurysms <5mm by an impressive 94% to 54% margin, making it an ideal test, given the typical size of a third-nerve palsy aneurysm.<sup>31</sup>

- **Cavernous sinus.** Since the cavernous sinus plays host to all the oculomotor nerves, any primary or extending secondary pathology affecting this structure may produce diplopic complaints. Two processes that originate here are carotid-cavernous fistula (CCF) and Tolosa-Hunt syndrome (THS).

A CCF is an abnormal communication that allows blood to flow from the carotid artery into the cavernous sinus. The broad classifications of CCF are direct vs. indirect.

A direct CCF arises from a traumatic or aneurysmal rupture etiology, progresses rapidly and requires urgent treatment.<sup>32</sup> In contrast, an indirect CCF tends to be more insidious in onset, leading to a delay in diagnosis due to its chronic nature.<sup>32</sup> Clinicians should add indirect CCF to their differentials when treating conjunctival injection, as this is a common ocular sequelae.

THS is an idiopathic, nonspecific inflammation of the cavernous sinus, causing painful ophthalmoplegia. These changes should be evident on neuroimaging, but not always. The term “benign THS” applies when this occurs.<sup>33</sup>

• **Tumor.** A pituitary adenoma is a familiar entity in the eye care field due to its potential ophthalmic manifestations. Two types exist, differentiated by size: microadenoma (<10mm) and macroadenoma (>10mm). Only the latter produces ocular findings, due to compression of the optic chiasm and resulting visual field defects. Further expansion of the tumor into the cavernous sinus may elicit a CN III, IV or VI palsy. Of those, CN III and the levator palpebrae superioris are the most affected nerve and muscle, respectively.<sup>34</sup>

While a macroadenoma itself is not typically an urgent situation, acute hemorrhage or ischemia within the pituitary tumor produces the emergent and possible life-threatening condition pituitary apoplexy (PA). Headache, nausea and impaired mental status join decreased visual acuity and ophthalmoplegia as common presenting symptoms, which develop from hours to days, or longer.<sup>35</sup>

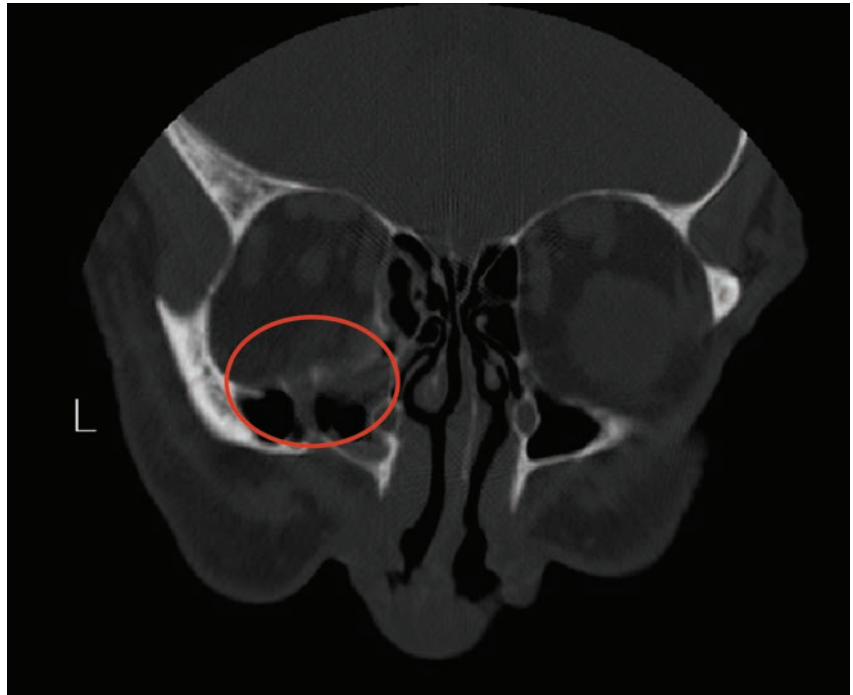
### Eye and Orbital Conditions

When neither a systemic disease nor a neurological condition can explain diplopia, the problem may be limited to the eye itself. Here are several possible eye and orbital conditions that can lead to double vision:

• **Herpes zoster ophthalmicus.**

Ocular complications arise when the latent varicella zoster virus (VZV) invades the ophthalmic division of CN V during a shingles outbreak, resulting in herpes zoster ophthalmicus (HZO). Cranial nerve palsies occur in up to 30% of HZO patients.<sup>36</sup> CN III is affected the most, followed by CN VI and CN IV.<sup>37</sup> Perform a careful EOM evaluation, as over 25% remain asymptomatic with diplopia only being noticed in extreme gaze.<sup>38</sup>

A gradual decline in immunity to varicella zoster virus has led to



CT scan showing orbital floor blow-out fracture.

increased rates of herpes zoster (HZ) and postherpetic neuralgia (PHN).<sup>39</sup> Some suggest the cause is decreased exposure to VZV stemming from the 1996 recommendation for immunization in children. Repeated exposure, they say, boosts a person's cell-mediated immunity against the virus. However, one of several studies does not support that conclusion and notes accelerated rates even before the vaccine's introduction.<sup>40</sup>

The Advisory Committee on Immunization Practices (ACIP) and Centers for Disease Control (CDC) recommend the 2006 FDA approved zoster vaccine Zostavax for patients age 60 or older. The Shingles Prevention Study showed markedly reduced morbidity from HZ and PHN and an over 50% reduction in HZ incidence.<sup>41</sup> Screen younger patients with HZ for an underlying immunocompromising etiology, such as HIV.

• **Idiopathic orbital inflammatory disease.** After ruling out

### Table 2. Tests for Diplopia

- Ductions and Versions
- Cover test
- Phoria
- Maddox rod
- Fixation disparity
- Park's 3-step
- Worth 4-dot
- Bielschowsky head-tilt
- Bagolini striated lenses
- Comitant vs. incomitant (this would be cover testing in nine positions of gaze); may want to combine with cover test above
- Hess screen test
- Forced ductions

all potential causes of OID, the clinician is left with the diagnosis of exclusion—idiopathic orbital inflammatory disease (IOID). Oral steroids remain the definitive treatment for IOID, with the expected course being rapid improvement

on these agents. It is of note that lymphoma can mimic IOID, and can initially respond to steroid treatment, delaying its diagnosis and proper treatment.

Immunosuppressive drugs can also be used. Some cases are associated with abnormal IgG4 levels, where patients initially respond to glucocorticoids but relapse during taper.<sup>42</sup> Several have reported successful treatment using rituximab—a monoclonal antibody also used in GPA.<sup>42,43</sup>

• **Orbital blow-out fractures.**

Ocular trauma renders the small and thin orbital bones susceptible to damage, with orbital floor fractures being the most common.<sup>44</sup> Since the infraorbital nerve runs through this area, patients often cite hypoesthesia along its distribution (i.e., cheek and upper lip). The incidence of diplopia, usually involving upgaze, varies; it has been reported to be from 20% to 45%.<sup>44,45</sup> The diplopia occurs due to extraocular muscle edema, nerve palsy or an entrapped muscle within the fracture. A longstanding entrapment often leads to fibrosis.

Though typically not emergencies, urgent surgery should occur if the oculocardiac reflex can be stimulated, a muscle is entrapped or the optic nerve is affected.<sup>46</sup> Non-urgent repair (within two weeks) depends on diplopic complaints and the extent of patient distress from the ensuing enophthalmos.

• **Superior orbital fissure syndrome.** The superior orbital fissure provides orbital access to not only CN III, IV and VI as previously discussed but also the frontal, lacrimal and nasociliary branches of the ophthalmic nerve.<sup>1,2</sup> An infiltrative, inflammatory, ischemic or traumatic event affecting this 3mm x 22mm area is called superior orbital fissure syndrome (SOFS).<sup>47</sup> With all the nerves traversing through this location, SOFS results in ophthal-

moplegia, forehead and upper eyelid hypoesthesia, ptosis and pupillary mydriasis.

Loss of extraocular muscle tone—which usually exerts a retracting force on the globe—leads to proptosis.<sup>47</sup> Vision loss indicates optic nerve involvement, and when this occurs the diagnosis changes from SOFS to orbital apex syndrome (OAS). The latter is a more urgent condition that may require early intervention such as high-dose corticosteroids or surgical decompression of the optic canal, depending on the etiology.<sup>48</sup>

**Conclusion**

Though neurologic imaging is important when dealing with diplopia, it is only helpful when one knows the anatomic location upon which to focus attention. Nothing can replace a thorough history and clinical exam. Using these, optometrists can try to localize the diplopia and determine if it is likely a process of systemic or neurologic disease, or an orbital condition. This will help establish the urgency of the situation and the need for additional imaging, treatment or further referral. ■

1. Snell R, Lemp M. The Orbital Nerves. In: Clinical Anatomy of the Eye. Cambridge: Blackwell;1989:267-76.
2. Moore, Keith L. Clinically Oriented Anatomy, 3rd ed. Baltimore: Williams & Wilkins; 1992:859-65.
3. Koskas P, Héran F. Towards understanding ocular motility: III, IV and VI. *Diagn Interv Imaging.* 2013;94(10):1017-31.
4. Silvestri NJ, Wolfe GI. Myasthenia gravis. *Semin Neurol.* 2012;32(3):215-26.
5. Gale J, Danesh-Meyer H. Statins can induce myasthenia gravis. *J Clin Neurosci.* 2014;21(2):195-7.
6. Rajasekharan C, Anishkumar V, Suresh MK. Ice pack test: is it obsolete? *BMJ Case Rep.* 2011;2011:1-2.
7. Lee J, Koh K, Kim U. The anti-acetylcholine receptor antibody test in suspected ocular myasthenia gravis. *J Ophthalmol.* doi:10.1155/2014/689792
8. Goetz C, Pal G. Initial management of Parkinson's disease. *BMJ.* 2014;349:g6258.
9. Pinkhardt EH, Jürgens R, Lulé D, et al. Eye movement impairments in Parkinson's disease: possible role of extradopaminergic mechanisms. *BMC Neurol.* 2012;12(1):5.
10. Demer JL. Pivotal role of orbital connective tissues in binocular alignment and strabismus. The Friedenwald Lecture. *Invest Ophthalmol Vis Sci.* 2004;45(3):729-38.
11. Sari E, Koc R, Yazici A, et al. Ganglion cell-inner plexiform layer thickness in patients with Parkinson disease and association with disease severity and duration. *J Neuroophthalmol.* 2014;(6). doi: 10.1097/WNO.0000000000000203

12. Tamhankar M, Biousse V, Ying G, et al. Isolated third, fourth, and sixth cranial nerve palsies from presumed microvascular versus other causes: a prospective study. *Ophthalmology.* e2013;120(11):2264-9.
13. Chou K, Galetta S, Liu G, et al. Acute ocular motor mononeuropathies: prospective study of the roles of neuroimaging and clinical assessment. *J Neurol Sci.* 2004;219(1-2):35-9.
14. Murchison A, Gilbert M, Savino P. Neuroimaging and acute ocular motor mononeuropathies: A prospective study. *Arch Ophthalmol.* 2011;129(3):301-5.
15. Stein J, Childers D, Gupta S, et al. Risk factors for developing thyroid-associated ophthalmopathy among individuals with Graves disease. *JAMA Ophthalmol.* 2014;48105:1-7.
16. Kanski, Jack J. *Clinical Ophthalmology*, 6th ed. Edinburgh: Butterworth-Heinemann; 2007:171-174.
17. Planck T, Shahida B, Parikh H, et al. Smoking Induces Overexpression of Immediate Early Genes in Active Graves' Ophthalmopathy. *Thyroid.* 2014;24(10):1524-1532.
18. Takeshima K, Inaba H, Furukawa Y, et al. Elevated Serum Immunoglobulin G4 Levels in Patients with Graves' Disease and Their Clinical Implications. *Thyroid.* 2013;24(4):736-743.
19. Bozkirli E, Bakiner OS, Ersozlu Bozkirli ED, et al. Serum Immunoglobulin G4 levels are elevated in patients with Graves' ophthalmopathy. *Clin Endocrinol (Oxf).* 2014:1-6.
20. Gonzalez-Gay M, Garcia-Porrúa C, Llorca J, et al. Visual Manifestations of Giant Cell Arteritis. *Medicine (Baltimore).* 2000;79(5):283-92.
21. Rahman W, Rahman F. Giant cell (temporal) arteritis: an overview and update. *Surv Ophthalmol.* 2005;50(5):415-28.
22. Hayreh S, Podhajsky P, Zimmerman B. Ocular manifestations of giant cell arteritis. *Am J Ophthalmol.* 1998;125(4):509-20.
23. Goodrich GL, Martensen GL, Flyg HM, et al. Development of a mild traumatic brain injury-specific vision screening protocol: a Delphi study. *J Rehabil Res Dev.* 2013;50(6):757-768.
24. Ciuffreda K, Kapoor N, Rulner D, et al. Occurrence of oculomotor dysfunctions in acquired brain injury: A retrospective analysis. *Optom - J Am Optom Assoc.* 2007;78(4):155-61.
25. Wang C, Paling D, Chen L, et al. Axonal conduction in multiple sclerosis: A combined magnetic resonance imaging and electrophysiological study of the medial longitudinal fasciculus. *Mult Scler.* 2014:1-11.
26. Karatas M. Internuclear and supranuclear disorders of eye movements: clinical features and causes. *Eur J Neurol.* 2009;16(12):1265-77.
27. Hernowo A, Eggenberger E. Skew deviation: clinical updates for ophthalmologists. *Curr Opin Ophthalmol.* 2014;25(6):485-87.
28. Brodsky MC, Donahue SP, Vaphiades M, Brandt T. Skew deviation revisited. *Surv Ophthalmol.* 2005;51(2):105-28.
29. Chang S, Tsai M, Wei C. Posterior communicating aneurysm with oculomotor nerve palsy: clinical outcome after aneurysm clipping. *Turk Neurosurg.* 2014;24(2):170-3.
30. Eggers SDZ, Bundrick JB, Litin SC. Clinical pearls in neurology. *Mayo Clin Proc.* 2012;87(3):280-5.
31. Chaudhary N, Davagnanam I, Ansari SA, Pandey A, Thompson BG, Gemmete JJ. Imaging of intracranial aneurysms causing isolated third cranial nerve palsy. *J Neuroophthalmol.* Sep 2009;3(238-44.
32. Ellis JA, Goldstein H, Connolly ES, Meyers PM. Carotid-cavernous fistulas. *Neurosurg Focus.* 2012;32(5):E9.
33. Hung C-H, Chang K-H, Chu C-C, et al. Painful ophthalmoplegia with normal cranial imaging. *BMC Neurol.* 2014;14:7.
34. Fraser C, Biousse V, Newman N. Visual outcomes after treatment of pituitary adenomas. *Neurosurg Clin N Am.* 2012;23(4):607-19.
35. Bi W, Dunn I, Laws Jr E. Pituitary apoplexy. *Endocrine.* 2014:1-7.
36. Chaker N, Bouladi M, Chebil A, Jemmel M, Mghaieth F, El Matri L. Herpes zoster ophthalmicus associated with abducens palsy. *Journal of Neurosciences in Rural Practice* 2014;5(2):180-2.
37. Harthan J, Borgman C. Herpes zoster ophthalmicus-induced oculomotor nerve palsy. *J Optom.* 2013;6(1):60-5.
38. Marsh R, Dullely B, Kelly V. External ocular motor palsies in ophthalmic zoster: a review. *Br J Ophthalmol.* 1977;61(11):777-82.
39. Centers for Disease Control and Prevention. <http://www.cdc.gov/shingles/hcp/clinical-overview.html>. Accessed January 5, 2015.
40. Hales C, Harpaz R, Joeseof M, Bialek S. Examination of links between herpes zoster incidence and childhood varicella vaccination. *Annals of Internal Medicine.* 2013;159(11):739-45.

41. Oxman M, Levin M, Johnson G, et al. A vaccine to prevent herpes zoster and postherpetic neuralgia in older adults. *N Engl J Med*. 2005;352(22):2271-84.

42. Wallace Z, Khosroshahi A, Jakobiec F, et al. IgG4-related systemic disease as a cause of "idiopathic" orbital inflammation, including orbital myositis, and trigeminal nerve involvement. *Surv Ophthalmol*. 2012;57(1):26-33.

43. Shao E, Karydis A, Gemenetzi M, Taylor S. Successful corticosteroid-sparing effect of rituximab in the treatment of refractory idiopathic orbital inflammatory disease. *Case Rep Ophthalmol*. 2013;4(3):216-8.

44. Bartoli D, Fadda M, Battisti A, et al. Retrospective analysis of 301 patients with orbital floor fracture. *J Craniomaxillofac Surg*. 2014;1-4.

45. Chi M, Ku M, Shin K, Baik S. An analysis of 733 surgically treated blowout fractures. *Ophthalmologica*. 2010;224(3):167-75.

46. Gart M, Gosain A. Evidence-based medicine: orbital floor fractures. *Plast Reconstr Surg*. 2014;134(6):1345-55.

47. Heath H, Wurth B, Penna K. Superior orbital fissure syndrome: A case report. *Craniomaxillofac Trauma Reconstr*. 2012; 5(2): 115-20.

48. Sugamata A. Orbital apex syndrome associated with fractures of the inferomedial orbital wall. *Clin Ophthalmol*. 2013; 7: 475-78.

## OSC QUIZ

**Y**ou can obtain transcript-quality continuing education credit through the Optometric Study Center. Complete the test form (page 71), and return it with the \$35 fee to: Optometric CE, P.O. Box 488, Canal Street Station, New York, NY 10013. To be eligible, please return the card within one year of publication.

You can also access the test form and submit your answers and payment via credit card at *Review of Optometry* online, [www.reviewofoptometry.com](http://www.reviewofoptometry.com).

You must achieve a score of 70 or higher to receive credit. Allow eight to 10 weeks for processing. For each Optometric Study Center course you pass, you earn 2 hours of transcript-quality credit from Pennsylvania College of Optometry and double credit toward the AOA Optometric Recognition Award—Category 1.

Please check with your state licensing board to see if this approval counts toward your CE requirement for relicensure.

- The oculomotor nerve, CN III, runs lateral to this artery:
  - Posterior cerebral artery.
  - Anterior communicating artery.
  - Posterior communicating artery.
  - Anterior cerebral artery.
- Which of the following cranial nerves makes a sharp bend over the petrous part of the temporal bone, making it vulnerable to injury and increased intracranial pressure?
  - VI.
  - IV.
  - III.
  - II.
- The ice pack test is performed by placing ice on the eyelid for:
  - Two hours.
  - Two minutes.
  - Two seconds.
  - 10 minutes.

- Patients at risk for a microvascular cranial nerve palsy are those with:
  - Diabetes.
  - Hypertension.
  - Hyperlipidemia.
  - All of the above.

- All of the following require immediate neurological imaging, except:
  - Patients with combined cranial nerve palsies.
  - A 35-year-old with diplopia and a history of cancer.
  - Incomplete or pupil-involving CN III palsy.
  - Isolated CN VI palsy in a 65-year-old uncontrolled diabetic.

- Which rectus muscle is often affected first in Graves' disease?
  - Superior.
  - Medial.
  - Inferior.
  - Lateral.

- Several studies suggest a link between thyroid-associated orbitopathy (TAO) and elevated:
  - IgG4.
  - IgG3.
  - IgG2.
  - IgG1.

- Patients with INO from a midbrain lesion are unable to \_\_\_\_\_ and also unable to \_\_\_\_\_.
  - Abduct, diverge.
  - Adduct, converge.
  - Abduct, converge.
  - Adduct, diverge.

- Which of the following is false regarding a skew deviation?
  - Commonly associated with cerebellum, brain stem or vestibular lesions.
  - Results from faulty prenuclear vestibular input to the ocular motor nuclei.

- Will localize to one specific cyclovertical muscle (i.e., superior and inferior recti or obliques).
- May be accompanied by ocular torsion and head tilt.

- The preferred imaging technique for aneurysm detection is:
  - MRA.
  - CTA.
  - X-ray.
  - MRI.

- The cavernous sinus plays host to which of the following cranial nerves?
  - CN III.
  - CN IV.
  - CN VI.
  - All of the above.

- An idiopathic, nonspecific inflammation of the cavernous sinus causing painful ophthalmoplegia is called:
  - Ophthalmoplegic migraine.
  - Traumatic brain injury.
  - Tolosa-Hunt syndrome.
  - Cavernous sinus fistula.

- A microadenoma:
  - Measures <10mm.
  - Always compresses the optic chiasm.
  - Frequently causes visual field defects.
  - Measures >10mm.

- Approximately what percentage of patients with herpes zoster ophthalmicus (HZO) experience cranial nerve palsy?
  - 90%.
  - 60%.
  - 30%.
  - 10%.

- All of the following are true, except:
  - There has been a gradual decline in immunity against the varicella zoster virus.
  - CN III is affected the most, followed by CN

## OSC QUIZ

VI and CN IV.

- c. Ocular complications arise when the latent varicella zoster virus invades the ophthalmic division of CN V.
- d. All herpes zoster patients with cranial nerve palsies are symptomatic.

16. Regarding the zoster vaccine Zostavax:

- a. It is recommended for patients age 40 or older.
- b. It resulted in an over 50% reduction in herpes zoster incidence.
- c. It resulted in increased morbidity from herpes zoster.
- d. It is only recommended in immunocompromised patients.

17. Idiopathic orbital inflammatory disease is treated with:

- a. Topical steroids.
- b. Oral steroids.
- c. Oral antibiotics.
- d. Tylenol.

18. Diplopia from an orbital blow-out fracture usually involves:

- a. Upgaze.
- b. Downgaze.
- c. Lateral gaze.
- d. None of the above.

19. The superior orbital fissure provides orbital access to all of the following cranial nerves, except:

- a. CN III.
- b. CN IV.
- c. CN VI.
- d. CN VII.

20. Which of the following is/are signs of superior orbital fissure syndrome (SOFS):

- a. Ptosis and pupillary mydriasis.
- b. Forehead and upper eyelid hypoesthesia.
- c. Enophthalmos.
- d. Only a and b.



TAKE THE TEST ONLINE TODAY!  
[www.reviewofoptometry.com/  
continuing\\_education/](http://www.reviewofoptometry.com/continuing_education/)

## Examination Answer Sheet

Valid for credit through March 1, 2018

This exam can be taken online at [www.revoptom.com/continuing\\_education](http://www.revoptom.com/continuing_education). Upon passing the exam, you can view your results immediately and download a real-time CE certificate. You can also view your test history at any time from the website.

### Seeing Double: The Urgent and Chronic Causes of Diplopia

**Directions:** Select one answer for each question in the exam and completely darken the appropriate circle. A minimum score of 70% is required to earn credit.

**Mail to:** Jobson - Optometric CE, PO Box 488, Canal Street Station, New York, NY 10013

**Payment:** Remit \$35 with this exam. Make check payable to Jobson Medical Information LLC.

COPE approval for 2 hours of CE credit is pending for this course.

This course is joint-sponsored by the Pennsylvania College of Optometry

There is an eight-to-ten week processing time for this exam.

1 = Excellent 2 = Very Good 3 = Good 4 = Fair 5 = Poor

1. (A) (B) (C) (D)
2. (A) (B) (C) (D)
3. (A) (B) (C) (D)
4. (A) (B) (C) (D)
5. (A) (B) (C) (D)
6. (A) (B) (C) (D)
7. (A) (B) (C) (D)
8. (A) (B) (C) (D)
9. (A) (B) (C) (D)
10. (A) (B) (C) (D)
11. (A) (B) (C) (D)
12. (A) (B) (C) (D)
13. (A) (B) (C) (D)
14. (A) (B) (C) (D)
15. (A) (B) (C) (D)
16. (A) (B) (C) (D)
17. (A) (B) (C) (D)
18. (A) (B) (C) (D)
19. (A) (B) (C) (D)
20. (A) (B) (C) (D)

Rate the effectiveness of how well the activity:

21. Met the goal statement: (1) (2) (3) (4) (5)
22. Related to your practice needs: (1) (2) (3) (4) (5)
23. Will help you improve patient care: (1) (2) (3) (4) (5)
24. Avoided commercial bias/influence: (1) (2) (3) (4) (5)
25. How would you rate the overall quality of the material presented? (1) (2) (3) (4) (5)
26. Your knowledge of the subject was increased:  
 Greatly  Somewhat  Little
27. The difficulty of the course was:  
 Complex  Appropriate  Basic

How long did it take to complete this course?

\_\_\_\_\_

Comments on this course:

\_\_\_\_\_

Suggested topics for future CE articles:

\_\_\_\_\_

Please retain a copy for your records. Please print clearly.

First Name \_\_\_\_\_

Last Name \_\_\_\_\_

E-Mail \_\_\_\_\_

The following is your:  Home Address  Business Address

Business Name \_\_\_\_\_

Address \_\_\_\_\_

City \_\_\_\_\_ State \_\_\_\_\_

ZIP \_\_\_\_\_

Telephone # \_\_\_\_\_ - \_\_\_\_\_ - \_\_\_\_\_

Fax # \_\_\_\_\_ - \_\_\_\_\_ - \_\_\_\_\_

By submitting this answer sheet, I certify that I have read the lesson in its entirety and completed the self-assessment exam personally based on the material presented. I have not obtained the answers to this exam by any fraudulent or improper means.

Signature \_\_\_\_\_ Date \_\_\_\_\_

Lesson 111044

RO-OSC-0315



## Essential Procedures at the Slit Lamp:

# How to Make Your Patients Stop Crying

Follow these simple steps to confidently perform lacrimal dilation and irrigation.

**By Megan Provence-Perry, OD, Andrea Smith, OD, and Nathan Lighthizer, OD**

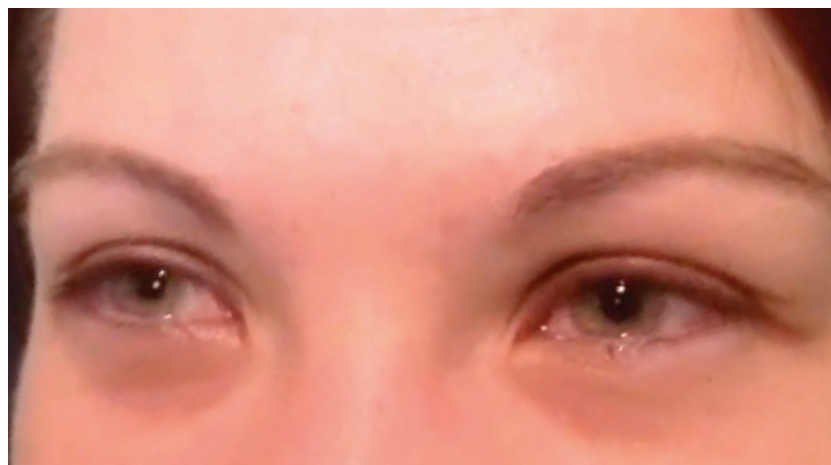It's the end of a busy morning and you're just about to see your last patient before a well-deserved lunch. You walk in and the patient says, "Doctor, I have tears running down my left cheek all the time."

Put lunch on hold.

For most doctors, epiphora may not be as daunting as the dreaded double vision complaint; however, determining the cause of epiphora can be stressful and time-consuming.

For whatever reason, many eye care providers dread or fear performing lacrimal dilation and irrigation, which often is essential to determine the cause of the patient's epiphora.

Perhaps this is because it involves putting an extremely sharp, pointed metal object into the patient's punctum. Or maybe it's because you remember learning it in optometry school, but you haven't performed it in quite a



**Epiphora has a number of possible causes. Determine the etiology in your patient's case before considering lacrimal dilation and irrigation.**

long time.

Fear not. It's a relatively simple procedure that's often indicated to treat or diagnose several common ocular conditions. The aim of lacrimal irrigation is straightforward: to open an obstructed tear duct and allow the tears to flow properly. This article—the third in a six-part, print-and-video, how-to series—explains how easily lacrimal dilation and irrigation can be done.

### Know the Anatomy

Before performing lacrimal dilation and irrigation (D&I), be sure you understand the anatomy of the nasolacrimal drainage system. The puncta are the openings to the drainage system, with aperture sizes that vary from patient to patient. Both the superior and inferior punctum open into a superior and inferior canaliculus, respectively.

The canaliculus has a vertical



To see a narrated video of this procedure, visit [www.reviewofoptometry.com](http://www.reviewofoptometry.com), or scan this QR code.



portion that extends approximately 2mm in length before bending horizontally and running another 8mm in length nasally. The two canaliculi join at the common canaliculus just before entering into the nasolacrimal sac, which is located within a fossa in the medial orbital wall.

The nasolacrimal sac extends roughly 10mm before draining into the nasolacrimal duct, which is located within the maxillary bone. This extends to the inferior meatus of the nose and ends at the valve of Hasner. This valve prevents the backflow of fluid from the nasal cavity up into the duct.<sup>1</sup>

### Causes of Epiphora

Potential causes of epiphora include:

- **Lid appositional abnormalities**—entropion, ectropion and floppy eyelid syndrome
- **Ocular surface disorders**—including trichiasis, abrasion, foreign body, dry eye syndrome and recurrent corneal erosion
- **Obstructed tear flow tract**—canalicular, punctal or nasolacrimal duct obstruction
- **Infectious causes**—canaliculitis and dacryocystitis

Nasolacrimal duct obstruction can be acquired, which is often due to aging, or the obstruction can be congenital. Infants may suffer from congenital obstruction of the nasolacrimal duct when the valve of Hasner fails to spontaneously open at birth. This resolves on its own in about 90% of cases before the child is one year old. So, it's not usually recommended to perform dilation and irrigation on a child younger than one year.<sup>2</sup>

You must determine the underlying cause of the epiphora prior to considering lacrimal dilation and irrigation, as it's not indicated in all

of these cases. A diagnosis of dacryostenosis is typically considered after you rule out lid malposition and ocular surface disorders. Dry eye syndrome is usually the fallback diagnosis, but consider it only after exhausting other possibilities.

Be sure to perform a thorough slit lamp examination to determine if dilation and irrigation is indicated. If a patient complains of sudden-onset tearing and a painful eye upon waking, for instance, then the diagnosis and cause of the tearing is most likely a recurrent corneal erosion, and D&I is likely not needed.

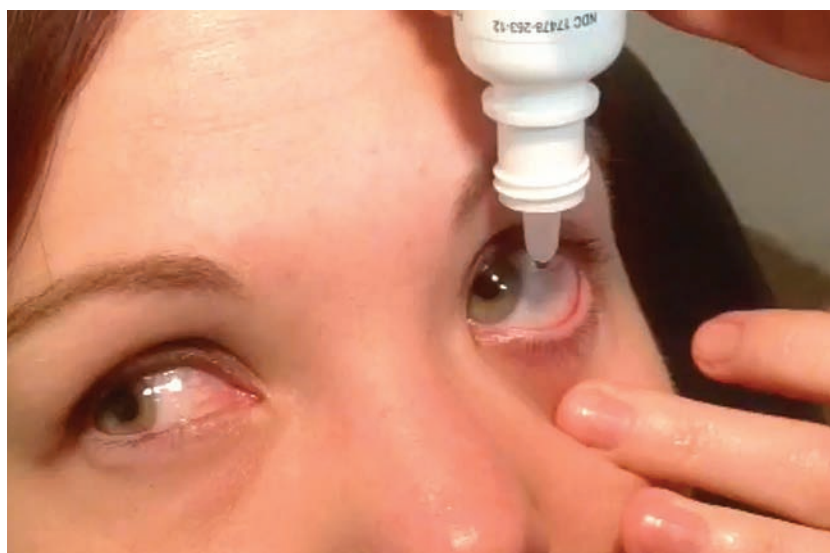### Indications

Consider performing lacrimal dilation and irrigation when a patient has a complaint of epiphora and you suspect an obstruction in the nasolacrimal drainage system. Lacrimal irrigation is advised in canalicular obstruction, which often occurs from stenosis, mucous plugs or small stones in the tear ducts. In this case, the patient will exhibit epiphora, typically unilaterally, in a white and quiet eye.

Performing irrigation will either clear the obstruction or allow you to determine the location of the blockage. Depending on the cause and severity of the obstruction, a dacryocystorhinostomy (DCR) may be indicated.<sup>2</sup>

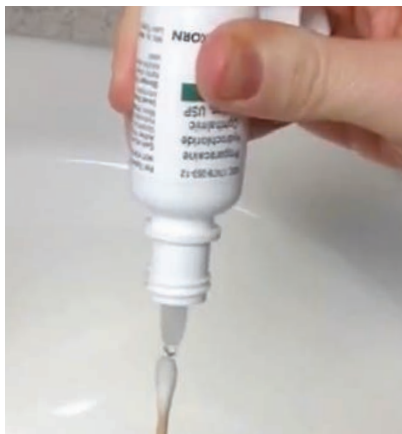

Thorough evaluation is also necessary to rule out infectious causes of epiphora, such as canaliculitis and dacryocystitis. In the case of canaliculitis, the puncta will be "pouting" (red and turning outward), and the surrounding area will be erythematous. With slight palpation, you'll often be able to excrete mucopurulent discharge or concretions from the punctum. Treatment varies among clinicians; however, lacrimal irrigation with an antibiotic solution is a viable option to consider, as well as topical and/or oral antibiotics.

In cases of dacryocystitis, more swelling, tenderness and pain over the lacrimal sac will be observed. Don't perform irrigation in the case of dacryocystitis; instead, prescribe oral antibiotic treatment, such as amoxicillin/clavulanate 500/125mg TID.<sup>2,3</sup>



**Lacrimal dilation and irrigation can be performed behind the slit lamp or outside of it. Once the patient is in position, apply a drop of topical anesthetic to the eye.**

# Slit Lamp Essentials



**Apply the topical anesthetic to a cotton-tip applicator and gently rest it on the patient's punctum for at least 30 to 60 seconds.**

## Equipment

- Lacrimal dilator
- 27- to 19-gauge cannula (depending on the patient's punctum size)
- 3cc syringe
- 1cc to 3cc sterile saline

## Get in Position

Lacrimal dilation and irrigation can be performed either behind or outside the slit lamp. A benefit of performing D&I outside the slit lamp is the easier accessibility to the patient and more freedom of movement; however, one of the downsides is not having the mag-

nification the slit lamp offers. A benefit of performing D&I behind the slit lamp is that it allows you to more accurately assess the punctum with the increased magnification. The increased magnification enables you to better determine exactly where to place the dilator and the cannula.

We prefer performing dilation and irrigation outside the slit lamp with our patient reclined to a height that is comfortable for us to easily manipulate the punctum from above. Keep in mind, with her or his head reclined, the patient may experience a slight gag reflex

when they taste the saline.

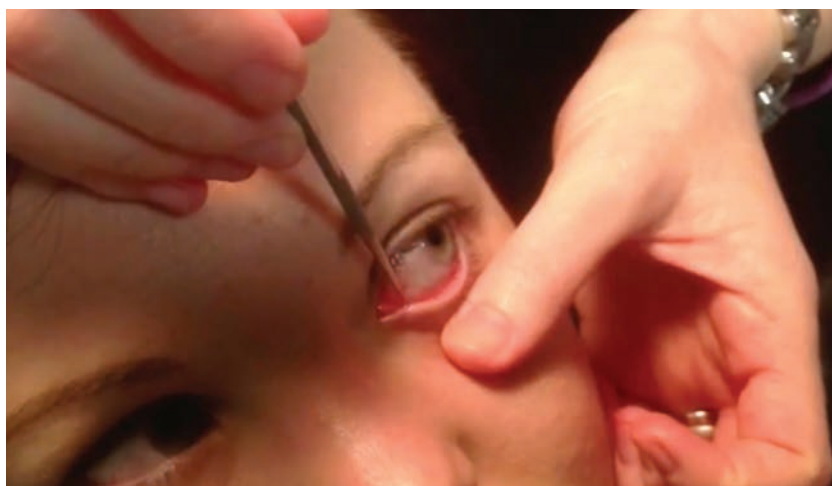We also adjust the stand lamp so the light shines directly on the eye undergoing the procedure.

## How to D&I

Before dilation and irrigation (D&I), numb the punctum for patient comfort.

- Apply proparacaine or another topical anesthetic to a cotton-tip applicator and gently rest it on the patient's punctum for 30 to 60 seconds.

A drop of proparacaine into each eye also helps eliminate a blink reflex.



**Pull the patient's lid temporally and insert the dilator vertically approximately 1mm to 2mm into the punctum.**



**Roll the dilator between your thumb and index finger to achieve proper dilation.**



# BE THE PRACTICE SUPERSTAR

**Competitive discounts** and pricing  
to reduce your cost of goods.

Marketing solutions designed to **attract new patients**  
and keep current patients returning.

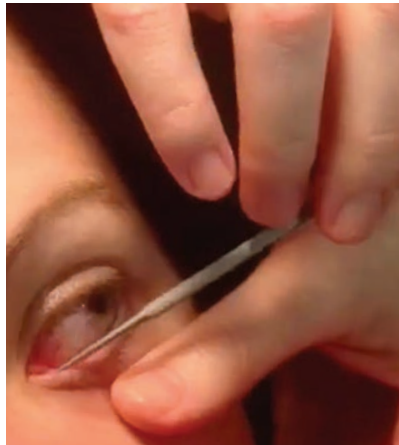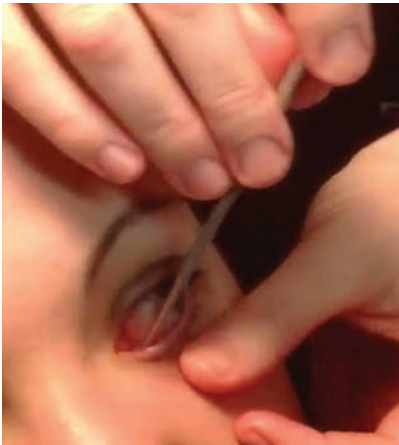Providing you with the tools and services you need to  
**manage your business effectively** & efficiently.

*The Alliance*  
Your Growth is our Vision. Your Success our Mission.

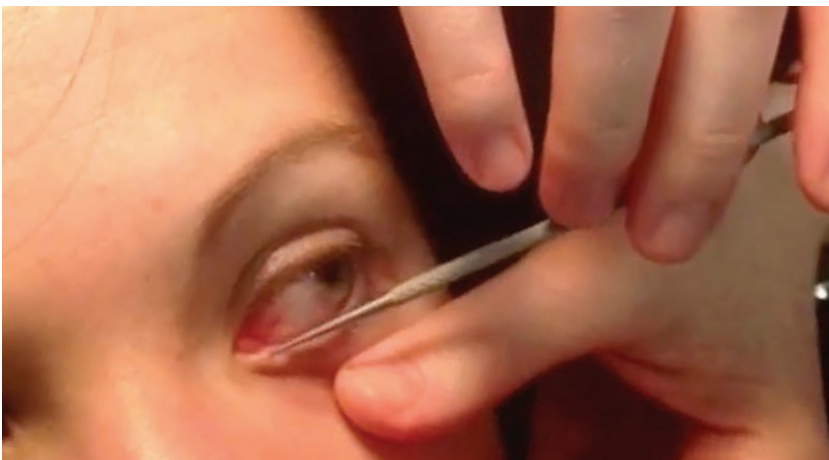We make **your job easier.**

888.466.8263 | [thealliancebg.com](http://thealliancebg.com)

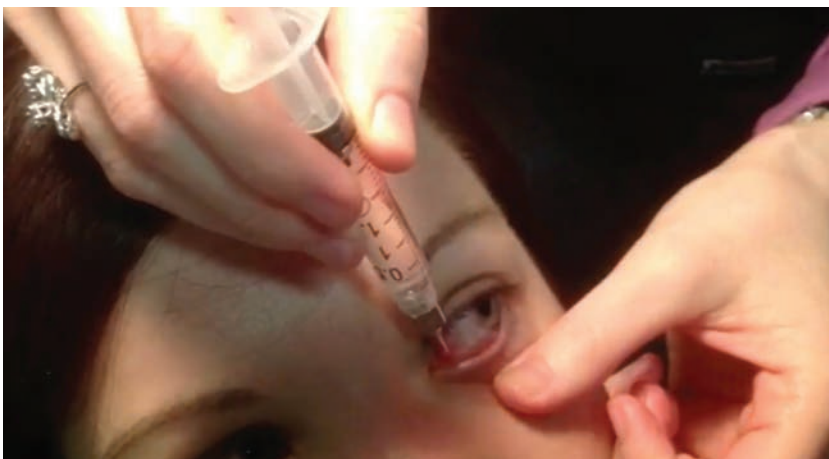
# Slit Lamp Essentials



**After sufficient vertical dilation, re-orient your dilator almost 90 degrees horizontally, all the while keeping your dilator in the patient's punctum. Continue rolling and circling the dilator in the same manner.**



**Once you've dilated the punctum enough for your cannula to comfortably fit, you know you've achieved sufficient dilation.**



**Next, remove the dilator and insert the cannula attached to the saline-filled syringe, in the same manner as the dilator: vertically 1mm to 2mm with the lid pulled temporally.**

Once the patient is sufficiently numbed, begin the procedure.

- It's a good idea to tell your patients to look "up and away" or "down and away" from the punctum being dilated, so they don't become apprehensive at seeing the lacrimal dilator.

- Pull the patient's lid temporarily and insert the dilator approximately 1mm to 2mm vertically into the punctum. Start with the smaller end of the dilator and switch to the larger end once the punctum is sufficiently dilated.

- To achieve proper dilation, roll the dilator with your thumb and index finger or move it in a circular manner.

- After sufficient vertical dilation, re-orient your dilator almost 90 degrees horizontally, all the while keeping your dilator in the patient's punctum, and continue in the same rolling or circular manner.

Once you've dilated the punctum enough for your cannula to comfortably fit, you know you've achieved sufficient dilation.

- After you've dilated the punctum, remove the dilator and insert the cannula attached to the saline-filled syringe. Insert the cannula in the same manner as the dilator; first vertically 1mm to 2mm with the lid pulled temporarily, then re-orient it horizontally approximately 8mm. Take caution when moving the cannula horizontally and nasally; if you go too far, you'll hit nasal bone and cause some discomfort for the patient.

- Gently press the plunger on the syringe to release the sterile saline into the patient's lacrimal system.

## Results

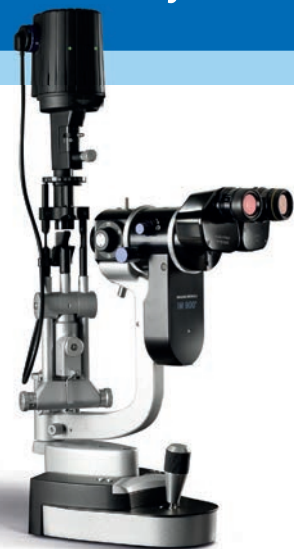If the lacrimal system is open, the patient will feel or taste the salty



## Imaging With Depth-of-field. Just Dandy.

What if none of your slit images or video had blurry edges? You would have a Haag-Streit, of course. Invest in one and submerge yourself into our extreme world of depth of field.

Visit [haag-streit-usa.com](http://haag-streit-usa.com) to learn about our entire range of slit lamps and imaging systems.

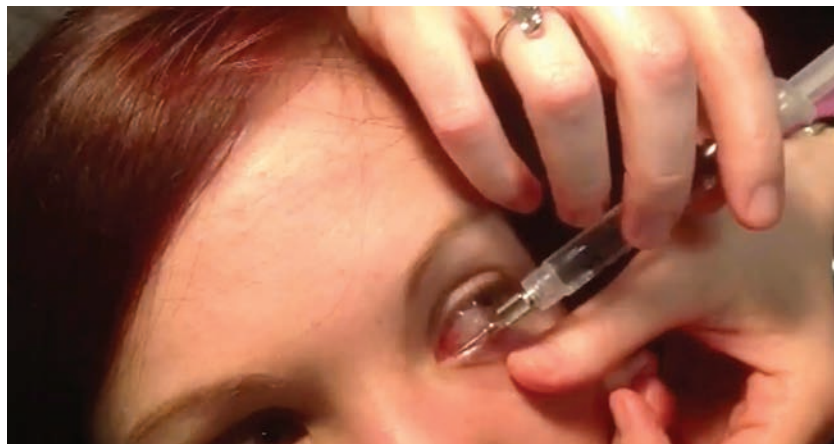

800.787.5426  
[haag-streit-usa.com](http://haag-streit-usa.com)

© 2015 Haag-Streit USA. All Rights Reserved.

 **HAAG-STREIT**  
USA

# Slit Lamp Essentials



Now orient the cannula horizontally, then insert it further nasally into the canaliculus to approximately 8mm. Don't go too far or you'll hit nasal bone and cause discomfort for the patient. Gently press the plunger on the syringe to release the saline into the patient's lacrimal system.

saline in the back of his or her throat. With this result, the cause of the epiphora is likely not nasolacrimal duct obstruction.

If the lacrimal system is blocked, you'll feel resistance of the plunger and see regurgitation of the saline. If regurgitation is coming out of the punctum being irrigated, then the blockage is proximal to the common canaliculus. If regurgitation happens in the opposite punctum, then the blockage is distal to the common canaliculus. Either way, further lacrimal probing is indicated.

Or, you can attempt to remove the blockage, or move it farther down the lacrimal drainage system, by irrigating multiple times—you may need to irrigate more forcefully for this to occur.

If you are still unsuccessful after several attempts to move the blockage, refer the patient for lacrimal probing.

If, however, you are able to successfully move the blockage and the patient can taste or feel the saline, no further treatment is necessary—these patients generally do not need to be seen for follow-up.

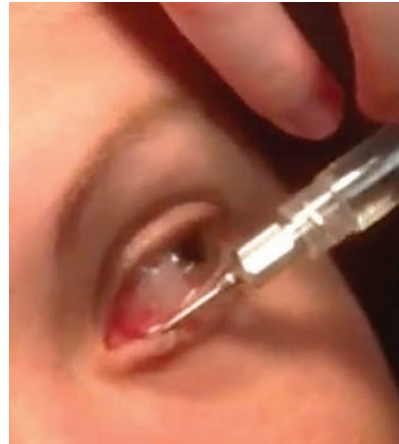## Billing and Coding

A simple procedure code of 68810 (“Probing of nasolacrimal duct, with or without irrigation”) is used with a –LT or –RT modifier stating which punctum was dilated and irrigated. The ICD-9 diagnosis codes to accompany the procedure code may include epiphora (375.20), nasolacrimal duct obstruction (375.55) and nasolacrimal duct stenosis (375.56).

As with any patient, always document thoroughly. Include the patient's symptoms, why you chose to dilate, how you performed the procedure and the results you achieved. Also document how the patient tolerated the procedure and when you expect them to return for follow-up.

As you can see, lacrimal D&I is actually a simple procedure to perform and needn't be dreaded or avoided when clinically indicated. Knowing the anatomy of the nasolacrimal drainage system well will remind you of the proper placement and movement of the dilator and cannula.

When performed correctly,



If the lacrimal system is open, the patient will feel or taste the saline. If the system is blocked, you'll feel resistance and see regurgitation of the saline.

this quick procedure helps your patients stop crying, gets them smiling again and gets you on your way to an enjoyable lunch. ■

*Dr. Provence-Perry is currently completing an ocular disease and family practice residency, with an emphasis in disease management and anterior segment laser procedures, at Northeastern State University Oklahoma College of Optometry.*

*Dr. Smith is currently completing a residency in vision rehabilitation: low vision and neuro-optometry at NSU Oklahoma College of Optometry.*

*Dr. Lighthizer is the assistant dean for clinical care services, director of continuing education, and chief of both the specialty care clinic and the electrodiagnostics clinic at NSU Oklahoma College of Optometry.*

1. Remington LA. Nasolacrimal drainage system. In: Clinical Anatomy of the Visual System. 2nd ed. Philadelphia: Elsevier; 2005: 173-4.

2. Canaliculitis. In: Gerstenblith AT, Rabinowitz MP, eds. The Wills Eye Manual: Office and Emergency Room Diagnosis and Treatment of Eye Disease. 6th ed. Philadelphia: Lippincott Williams & Wilkins; 2012:143-6.

3. Hurwitz JJ. The lacrimal drainage system. In: Yanoff M, Duker JS. Ophthalmology. 3rd ed. London: Mosby Elsevier; 2009: 1482-7.

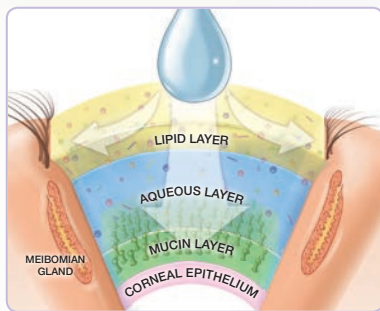
For the 75% of dry eye patients worldwide with evaporative dry eye (MGD) symptoms<sup>1</sup>...

**DRY EYE CAN BE RELENTLESS**

**CALM THE STORM WITH LASTING RELIEF**

### SYSTANE® BALANCE Lubricant Eye Drops:

Protecting the Ocular Surface by Increasing Lipid Layer Thickness (LLT)



SYSTANE® BALANCE Lubricant Eye Drops forms a protective matrix that is designed to replenish the lipid layer for long-lasting relief from the symptoms associated with evaporative dry eye (MGD). This unique formulation is designed to work on all 3 layers of the tear film, specifically increasing LLT. This helps create a protective environment for the ocular surface.<sup>2</sup>

SYSTANE® Brand products are formulated for the temporary relief of burning and irritation due to dryness of the eye.

References: 1. Akpek EK, Smith RA. Overview of age-related ocular conditions. *Am J Manag Care*. 2013;19 (5 suppl):S67-S75. 2. Korb DR, Blackie CA, Meadows DL, Christensen M, Tudor M. Evaluation of extended tear stability by two emulsion based artificial tears. Poster presented at: 6th International Conference on the Tear Film and Ocular Surface: Basic Science and Clinical Relevance; September 22-25, 2010; Florence, Italy.

**Your recommendation counts.**

Make sure your patients get the lasting symptom relief they need by offering them SYSTANE® BALANCE Lubricant Eye Drops.<sup>2</sup>



**Alcon**  
a Novartis company

© 2014 Novartis 05/14 SYS14005JAD-B

**Systane**  
Family of Products

Relief that lasts

# Vision Expo East 2015: A Focus on Education

Contact lenses, wellness and ocular diseases are hot topics this year—as is new technology to keep Expo attendees engaged. See what else is in store for VEE 2015.

By Cheryl G. Murphy, OD, Contributing Editor

**C**ontinuing education classes at Vision Expo East, held March 19-22, allow eye care professionals from around the world to explore new ideas and exchange updates on the latest in health, technology and business-building strategies.

## Cultivating CL Knowledge

Returning to Expo after what Mark Dunbar, OD, co-chairman of the VEE Conference Advisory Board, deemed a “hugely successful debut last year at Vision Expos East and West,” the Global Contact Lens Forum (GCLF) once again hosts an ample supply of classes pertaining to the business and the craft of fitting contact lenses. This forum marks the 7:00 AM start to classes at Expo on Thursday. Topics include: the art and science of managing astigmatism with contact lenses; successful scleral lens fitting; troubleshooting cases; and how to ensure that the dollars and “sense” of a contact lens practice allow room for growth.

Experts will envision advance-



**This year's meeting offers more than 330 hours of CE.**

ments and predict upcoming trends by sharing updates on disease and technology, as well as a “farmer’s almanac” view of the future of contact lenses. Although pre-registration is required, there is no fee for signing up, and those who register may accrue six CE credit hours.

If the early start to classes on Thursday poses an issue, don’t fret. There are over 15 credit hours of other contact lens-related courses available outside of the GCLF. These courses are scattered throughout the class schedule, with the first one, “Hashtag Contact Lens: What’s

New and What’s Coming,” held on Thursday at 1:30 PM.

## Sowing Seeds of Wellness

Healthy eyes begin with healthy bodies, so it is essential for eye care practitioners to have the tools to educate patients on the importance of regular checkups and keeping their eyes and bodies well nourished.

“For the very first time at Vision Expo, we are introducing our Ocular Wellness Program, which will debut on Thursday afternoon,” says Dr. Dunbar. “Optometry needs to take a leading role in helping to inform and educate our patients on the need for ocular wellness.”

This three-hour program uses evidence-based medicine to provide clinical guidelines that emphasize the advantages of preventive medicine and focus on improving each patient’s quality of life. “Through our Ocular Wellness Program, we are hoping to create awareness to our patients and colleagues of the importance of preventing ocular problems before they develop, with



the overall goal for our patients of maintaining good vision and healthy eyes for a lifetime,” Dr. Dunbar says.

Other classes that highlight health and wellness can be found throughout the lineup at Expo, including: “Feed Your Retina: Nutrition and Retinal Health”; “Diabetes: What we ALL Need to Know”; and “Omega 3 Fish Oil—Benefits for Your Patients and Practice.”

### Combating Disease

Another way we can help our patients’ health thrive is to arm ourselves with the knowledge necessary to recognize problems early and to treat them successfully with the most up-to-date, proven techniques. “We will have the full armament of ocular disease clinical courses [at Expo],” says Dr. Dunbar, “focusing on glaucoma, external disease, nutrition and retinal disease among others.”

Within the Friday schedule is the “Greatest Ever” series—a set of courses on managing ocular disease. The first class of the series, “The Greatest Anterior Segment Disease and Medical Management of Contact Lens Complications Course—Ever!” takes place in the morning, and its complement, “The Greatest Posterior Segment Disease Course—Ever!” takes place in the afternoon. These classes are designed to enhance the practitioner’s clinical diagnostic and treatment skills and provide strategies on handling a patient suffering from problems related to medical vision correction options as well as retinal disease.

On Saturday, the entertaining and knowledgeable duo of Drs. Ron Melton and Rondall Thomas is back, offering six hours of disease-oriented continuing education classes, including: “What the Primary Care Optometrist Should Never Miss,” “Separating the



**Like last year, Vision Expo East 2015 will have more than five football fields of exhibits encompassing fashion, accessories and medical equipment.**

Good, the Bad and the Ugly—Is it Glaucoma or Not?” and “Mystery Solved—Conquering Anterior Segment Pathology.”

### Exploring New Technologies

One of the enhancements to some lectures this year is the use of technology to increase speaker-attendee interaction. “This past year we have broadened our approach to deliver education in more interesting and creative ways, including our Crowd-Sourced Learning courses that use smartphone and polling technologies,” says Dr. Dunbar. Specific classes will allow audience members to participate through their mobile device or audience response system (ARS) technology. These technologies will help attendees become more engaged by being able to answer poll questions, suggest topics and request specific information. “We launched this at Vision Expo West, and it was a huge success. We think it will be even better for Vision Expo East this year,” says Dr. Dunbar.

There are also plenty of classes to help businesses reach new heights. This year they “have expanded the Business Solutions curriculum to include over 100 hours of education on a broad range of topics, including the popular Visionomics Program, Frame Buyers Program, billing and coding, as well as a Retail track and

the Wearable Technology track. We have even brought in The Ritz-Carlton for our Spotlight series discussing Memorable Customer Service Experiences,” Dr. Dunbar says.

He adds that there will also be “unique courses delivered through our Optical Technology tracks by some of the top lecturers in the industry, including Edward De Gennaro, Laurie Pierce, Michael Vitale and Barry Santini, among others. Courses will include the latest in lens technologies as well as the popular Optical Bootcamp.”

### Eye Care for Athletes

Sundays aren’t always for resting; they’re also for sporting events—and Sunday has a lineup of eight credit hours that cannot be defeated. Kicking off at 7:15 AM, the Sports Vision CE classes are designed to give eye care professionals proficiency and an appropriate game plan on how to draft athletes to their practice, help them enhance their performance, protect them from injury—and grow profits in the process. By pairing these classes with the wide variety of courses available at Vision Expo East this year, attendees are sure to walk away with a record-breaking score of eye care and eye wear know-how.

Visit [www.visionexpeast.com](http://www.visionexpeast.com) to see the full program. ■

# Exam Reveals Subtle Macular Disease

A middle-aged patient was seeing spots, prompting an uncommon diagnosis of idiopathic juxtafoveal retinal telangiectasis. **By Erin S. Cooper, OD, Paul J. Gruosso, OD, and Joseph Miller, OD**

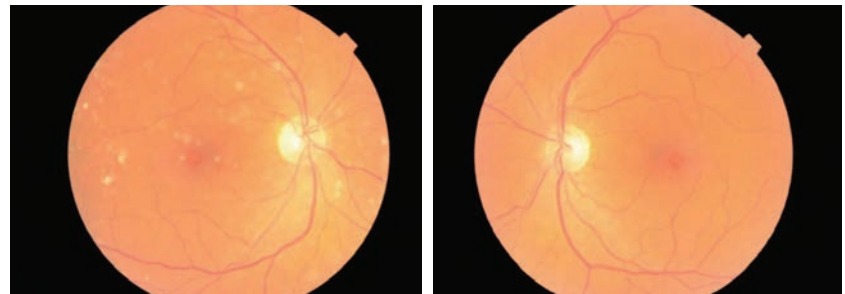
Idiopathic juxtafoveal retinal telangiectasis (IJRT) is a rare disorder. The condition is discernible by clinical presentation along with the use of fluorescein angiography and ocular coherence tomography.

IJRT is subdivided into different types, and further subdivided into subtypes and stages. The treatment of the disease is controversial and mostly depends on the patient's level of symptoms and clinical signs.

## History

A 55-year-old white male presented with an emergent complaint of increased black spots in the vision of his right eye. He had noticed that the black spots had been increasing in size and number, along with increased blurry vision over the past six to eight months. His past ocular history was unremarkable. He had not had an eye exam in over three years.

His systemic history was positive for poorly controlled Type 1 diabetes; his last A1c reading was



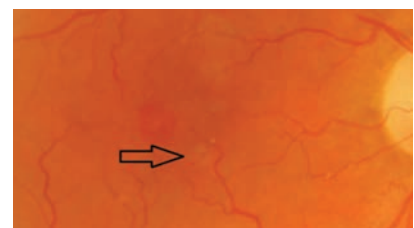
**Fundus photographs show dot and scattered hemorrhages OD (left) and pigment mottling OS (right). Both eyes have a pseudohole appearance.**

9.8. He also reported hyperlipidemia and hypertension. His blood pressure was 132/78 the morning of the exam. Systemic medications included temazepam, atenolol, glipizide, insulin, metformin, omeprazole, multivitamins and aspirin (325mg).

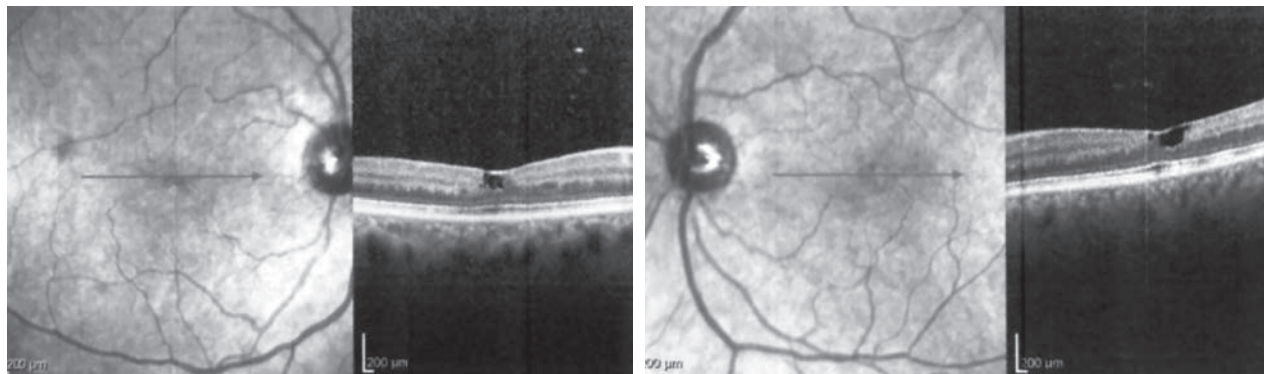
## Diagnostic Data

Visual acuity at presentation was 20/60 OD with pinhole to 20/40 and 20/30 OS with pinhole to 20/25. Following refraction, the patient's best-corrected visual acuity was 20/40 OD and 20/25 OS. The refraction yielded -1.00 DS

in the right eye and -0.50 DS in the left eye. The patient had no deficiencies on extraocular motility or confrontation visual field testing. He had equal, round, reactive pupils with no afferent defect. Amsler grid revealed metamorphopsia nasally in both eyes.



**Arrow points to telangiectatic vessel, OD.**



**OCT scans, both OD (left) and OS (right), show subfoveal macular cyst-like appearance due to atrophy affecting the foveal contour.**

Biomicroscopy uncovered trace seasonal allergic conjunctivitis with mild papillae and punctate keratitis. He had mild nuclear sclerosis in the lenses of both eyes. Goldmann applanation tonometry pressures measured 18mm Hg OU.

Dilated fundus exam revealed two small dot hemorrhages inferior to the central macula with a few scattered hemorrhages temporally, along with a pseudohole appearance in the macula of the right eye. The macula of left eye had a slightly elevated appearance with pigment mottling and a few small hemorrhages surrounding it. The left eye also had a pseudohole appearance. Both eyes had a negative Watske-Allen sign.

Optical coherence tomography (OCT) showed a subfoveal macular cyst-like appearance secondary to atrophy that affected the foveal contour in both eyes.

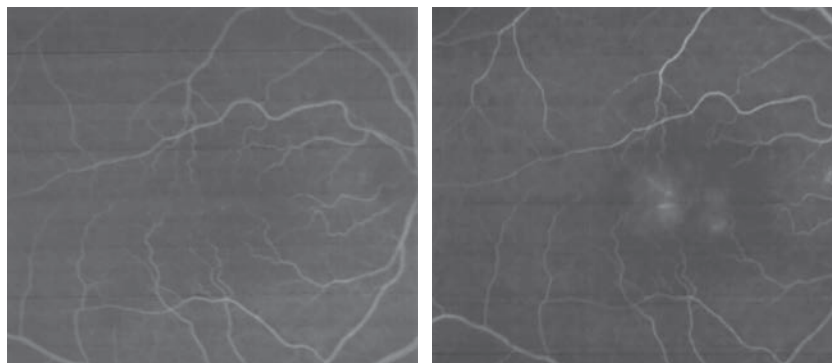
### Diagnosis

Based on the OCT results, we tentatively diagnosed the patient with idiopathic juxtafoveal retinal telangiectasis. We referred the patient to a retina specialist, who confirmed the diagnosis of type 2 IJRT using fluorescein angiography.

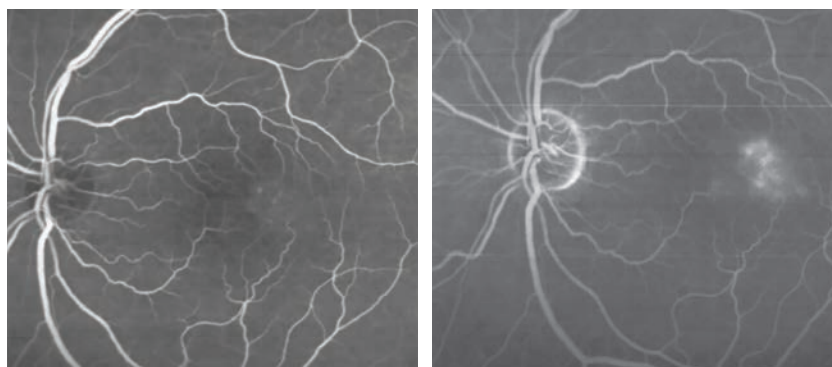
Flourescein angiography is the diagnostic tool of choice for IJRT. The irregular dilation of capillaries is easily seen on the arteriove-

nous phase, along with leakage of dye from the affected capillaries into the intracellular spaces of the retina.<sup>1</sup> In our patient, both eyes showed punctate hyperfluorescent spots within the central macula in the early phases, along with leakage seen in the late phases.

OCT is another important diagnostic tool used in this disease. Features of IJRT seen on OCT are most commonly loss and disruption of the photoreceptor layer, cyst-like structures in the fovea and within intra-retinal layers, possible neovascularization, and intra-retinal



**Fluorescein angiography (FA) in the patient's right eye: early arteriovenous phase (left) and late arteriovenous phase (right).**



**FA in the left eye: early arteriovenous phase (left) and late arteriovenous phase (right). Both eyes show punctate hyperfluorescent spots within the central macula in the early phases, and leakage in the late phases.**

# Case Report

deposits and plaques. The discontinuity of the photoreceptors is correlated with loss of visual acuity. If the photoreceptor layer is intact, the visual acuity is usually preserved.<sup>2</sup> Gass concluded the loss of central vision is due to photoreceptor atrophy in the absence of macular edema.<sup>3</sup>

Another unique feature seen on OCT is the internal limiting membrane (ILM) drape, as seen in our patient. The draping of the ILM over the fovea is due to underlying loss of tissue, causing a cystoid space. This draping shows the loss of the outer plexiform layer due to a cystoid space underneath the fovea that allows the retina to have a normal foveal contour and foveal thickness.<sup>2</sup> Foveolar atrophy is easily seen on OCT and may mimic a lamellar macular hole. This atrophy is the main cause of slow progressive vision loss over time, whereas rapid and severe vision loss occurs with the development of a neovascular membrane.<sup>3</sup>

## Treatment and Follow-up

The patient did not receive any treatment for this condition. He will be monitored by the retina specialist

closely on a monthly basis initially, with the goal of every other month for the balance of the year.

He was dispensed an Amsler grid and educated on the signs and symptoms of decompensation. After his initial visit, the patient missed his two follow-up appointments and returned for a three-month follow-up and then again two months later. The patient's visual acuity had slightly decreased in subsequent follow-up visits.

## Discussion

Idiopathic juxtafoveolar retinal telangiectasias are a group of rare retinal vascular disorders characterized by alterations of the juxtafoveolar capillary network in one or both eyes that is detectable even in asymptomatic patients.<sup>4</sup> This disease is more specific to the parafoveal region of the retina. Therefore, it becomes easily distinguishable from other generalized retinal telangiectasias such as Coats' disease or a secondary telangiectasis found in retinal vein occlusions, carotid artery disease or diabetes.<sup>3</sup>

IJRT was first identified by Gass and Oyakawa in 1982.<sup>5</sup> They classified the disease into four groups

based on clinical features and results from fluorescein angiography. Gass and Blodi updated this classification system in 1993.<sup>3</sup> They divided IJRT into three groups with smaller subgroups within the first group. (See "Classification of IJRT by Type," below.) This most recent classification system is widely accepted and described as follows:<sup>3</sup>

- **Type 1.** The hallmark characteristic of type 1 is variable sized aneurysmal dilations and easily visible telangiectasis of the retinal capillaries.<sup>3</sup>

Type 1 is subdivided into types 1A and 1B.<sup>5</sup> Each are unilateral and congenital, typically affecting men in their 30s and 40s.<sup>6</sup> The vision loss in type 1A is more significant than in type 1B.<sup>3</sup>

*Subgroup 1A* is the second most common of all types and can be found in males ranging in age from 15 to 54.<sup>1</sup> The telangiectasis of the capillaries is typically found in the temporal half of the macula involving an area of two disc diameters or greater.<sup>7</sup> In these patients, the decreased vision ranges from 20/25 to 20/40.

*Subgroup 1B* is rare and affects mostly middle-aged men between

## Classification of IJRT by Type

Type	1A	1B	2	3
Frequency	2nd most common	Rare	Most common	Very rare
Gender	Male (90%)	Male	Male = Female	Male = Female
Age	15-54	40-50	35-65	40-60
Congenital/acquired	Congenital	Congenital	Acquired	Acquired
Laterality	Unilateral	Unilateral	Bilateral	Bilateral
Visual acuity at presentation	Around 20/40	≥20/25	20/20 to 20/300	20/25 to 20/50
Classic signs	Exudates and macular edema	Exudates and macular edema	Foveolar atrophy or CNV (stage 5)	Capillary obliteration
Systemic associations	None	None	Possible diabetes	CNS involvement

# COST OF GOODS SAVINGS CAN ONLY HELP YOU GROW SO MUCH

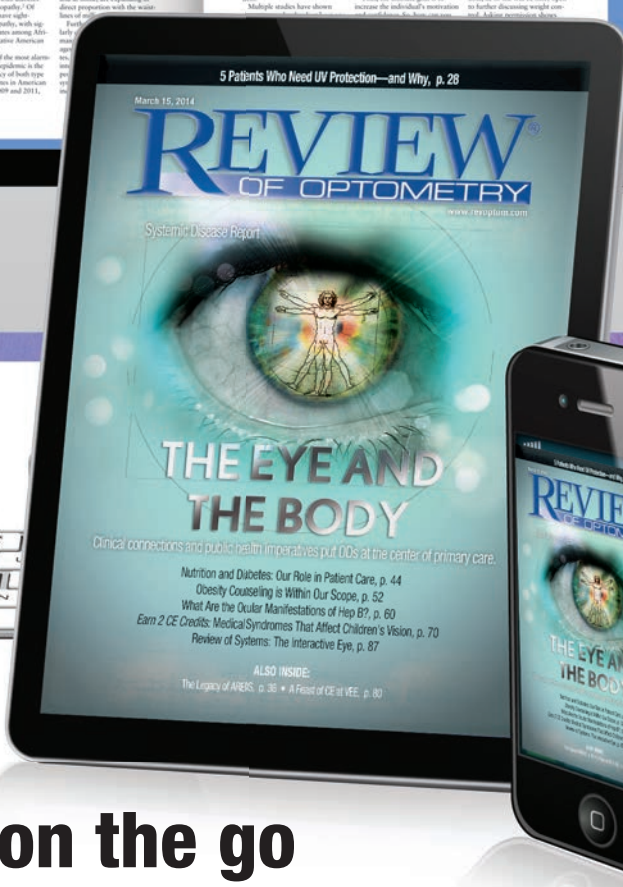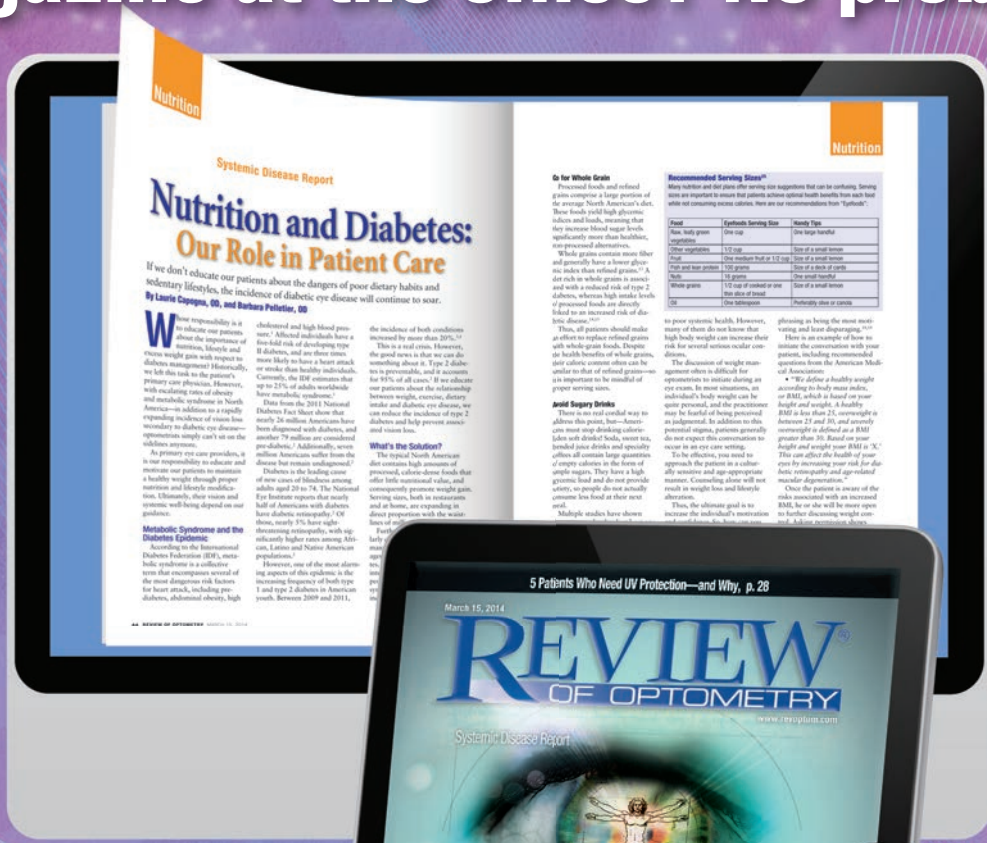IN THE NEW ERA OF  
POPULATION HEALTH MANAGEMENT,  
**WHAT'S YOUR PLAN**  
**TO WIN:**

- More Patients
- More Profits
- More Time
- All of the Above

Go To **VisionSourcePlan.com** and  
We'll Give You Ours



# Left your *Review of Optometry* magazine at the office? No problem!



**Read *Review* on the go from any mobile device!**

Just simply go to [www.reviewofoptometry.com](http://www.reviewofoptometry.com) and click on the digimag link to get your current issue.

the ages of 40 and 54.<sup>6</sup> The difference between subgroup 1B and 1A differs primarily in the size of the area of telangiectases. These telangiectases occupy small focal areas less than one disc diameter adjacent to the foveal avascular zone.<sup>7,8</sup> The amount of vision loss in this subgroup is much less where the men are either asymptomatic or have vision better than 20/25.<sup>6</sup>

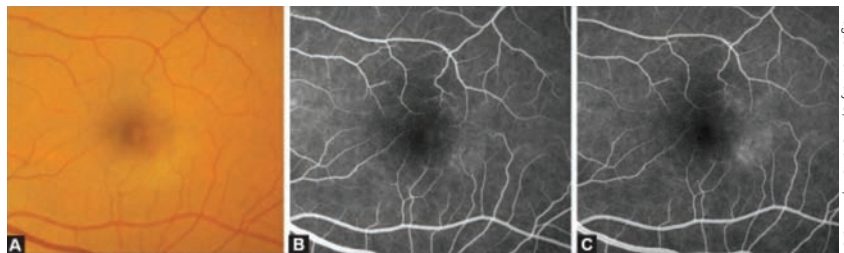In both subtypes, cystoid macular edema may develop and will show classic petalloid leakage on fluorescein angiography.<sup>6</sup> Macular edema and lipid exudation are the main cause of vision loss in type 1.<sup>3</sup>

- **Type 2.** Type 2 is bilateral, acquired and has no gender predilection. This is the most common type of IJRT and is significantly different from type 1.<sup>3</sup> Although type 2 is considered the most common, its prevalence was found to be very low—0.1%—by the Beaver Dam Eye Study and even lower—0.004% to 0.022%—in the Melbourne Collaborative Cohort Study.<sup>9</sup> Age of onset is typically in the 40s or 50s.

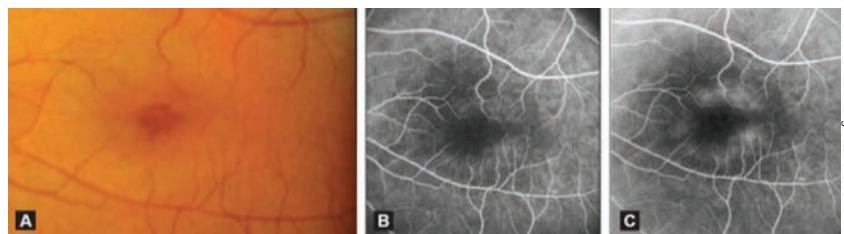
The most common clinical sign in type 2 is foveolar atrophy. The characteristics are usually symmetric, but vision loss may be asymmetric. Vision loss ranges from asymptomatic to mild blurring of central vision to slow progressive loss of central vision. The vision loss can occur slowly, but may become rapid with the development of intra-retinal neovascularization.<sup>10</sup> Some research suggests that diabetes may be an underlying cause for this group.<sup>11</sup>

IJRT type 2 is further subdivided into five stages (*see “Stages of Type 2 IJRT,” right*) by characteristics of the different signs and symptoms:

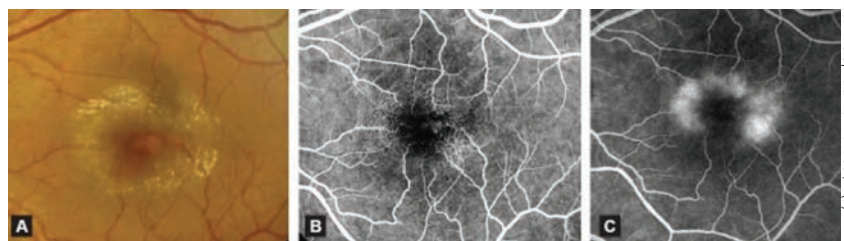
**Stage 1.** Patients are typically asymptomatic in stage 1. The retina typically looks slightly grayish and



**Type 2, stage 1 IJRT: fundus photo (A) with images of early phase FA that shows punctate staining (B) and late phase shows mild leakage (C).**



**Type 2, stage 2 IJRT: fundus photo (A) with early phase (B) and late phase showing leakage (C).**



**Type 2, stage 3 IJRT: fundus photo (A) shows grayish ring with crystals surrounding the macula. Early phase of FA shows visible telangiectasis (B) and late phase shows late leakage (C).**

## Stages of Type 2 IJRT

	Signs	Symptoms
Stage 1	Retina appears grayish; telangiectasis visible by IVFA only	Typically asymptomatic
Stage 2	Graying of parafoveal region on temporal aspect of macula; thinning of foveal region seen	Typically asymptomatic
Stage 3	Right-angle venules mostly temporal to fovea; blunted foveal reflex	Mild vision loss (usually when patient presents to clinic)
Stage 4	Clumps of RPE hyperplasia seen around right angle venules; pseudo-vitelliform lesion sometimes seen	Vision loss worsens
Stage 5	Development of a neovascular membrane; superficial crystalline deposits may develop	Most detrimental vision loss

Images: Nowlitzky S, Al-Shamsi H, Al-Khars W. Idiopathic juxtafoveal retinal telangiectasis: a current review. Middle East Afr J Ophthalmol. 2010; Jul; 17(9):224-41.



# THE RICK BAY FOUNDATION

*for Excellence in Eyecare Education*

[www.rickbayfoundation.org](http://www.rickbayfoundation.org)

*Support the Education of Future Healthcare & Eyecare Professionals*



## **About Rick**

Rick Bay served as the publisher of *The Review* Group since 1991.

To those who worked for him, he was a leader whose essence was based in a fierce and boundless loyalty.



To those in the industry and the professions he served, he will be remembered for his unique array of skills and for his dedication to exceeding the expectations of his customers, making many of them fast friends.

Scholarships will be awarded to advance the education of students in both **Optometry** and **Ophthalmology**, and will be chosen by their school based on qualities that embody Rick's commitment to the profession, including integrity, compassion, partnership and dedication to the greater good.

## Interested in being a partner with us?

Visit [www.rickbayfoundation.org](http://www.rickbayfoundation.org)

*(Contributions are tax-deductible in accordance with section 170 of the Internal Revenue Code.)*



**THE RICK BAY FOUNDATION**  
*for Excellence in Eyecare Education*

*(The Rick Bay Foundation for Excellence in Eyecare Education is a nonprofit, tax-exempt organization under section 501(c)(3) of the Internal Revenue Code.)*



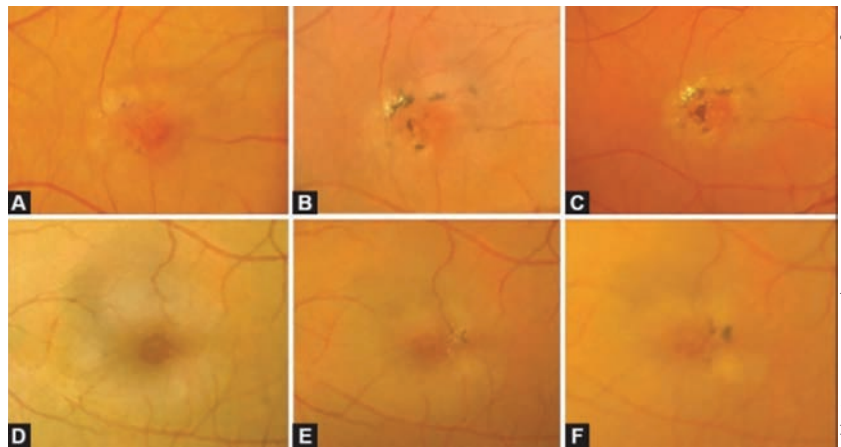
there could be a loss of retinal transparency.<sup>3</sup> Stage 1 signs may be difficult to identify by biomicroscopy alone. Fluorescein angiography will show juxtafoveal telangiectasis in stage 1 even if there are no abnormalities seen during clinical examination.<sup>10</sup>

**Stage 2.** In stage 2, evidence of the disease starts to be slightly more obvious with biomicroscopy. There is graying of the parafoveal region that is usually confined to the temporal side or forming a horizontal oval around the fovea while sparing the foveal center. Although the fovea is spared, it may look slightly thinner than the surrounding retina. Minimal telangiectatic changes usually occur at this stage, giving it a subtler appearance than type 1 IJRT.<sup>3</sup>

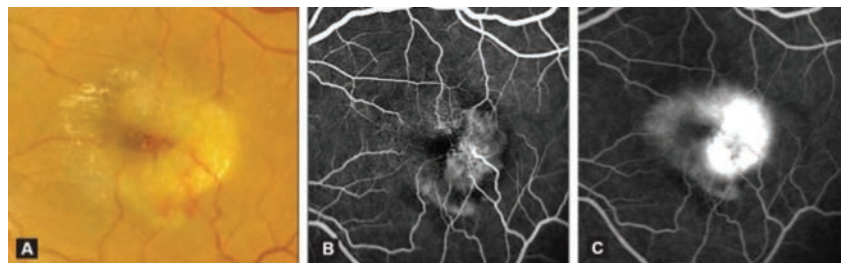
**Stage 3.** Stage 3 exhibits right-angle venules, mostly found temporal to the fovea, but they can also surround the fovea with a blunting of the foveal reflex.<sup>6</sup> Most patients present to clinic during stage 3 due to the complaint of mild vision loss. This vision loss appears to be due to progressive foveolar atrophy.<sup>10</sup> The foveolar depression may mimic a macular hole in this stage when viewed by biomicroscopy, but is easily distinguishable by fluorescein angiography.<sup>3</sup>

**Stage 4.** Stage 4 is characterized by clumps of retinal pigmented epithelial hyperplasia seen around the right-angled vessels in the parafoveal region that are associated with chorioretinal anastomosis.<sup>3,10</sup> A stellate pattern of retinal pigmented epithelial hyperplasia may envelop the macula during this stage, and some patients may develop a pseudovitelliform lesion.<sup>3,6</sup>

**Stage 5.** Stage 5 is the final stage of type 2 IJRT. This is the stage that is most detrimental to vision due to the development of an intra-



**Type 2, stage 4 IJRT: Serial fundus photos of a patient's right eye (A-C) and left eye (D-F) shows RPE hyperplasia.**



**Type 2, stage 5 IJRT: Fundus photo of subretinal neovascularization shows refractile crystals (A) with corresponding early phase (B) and late phase (C) FA images.**

retinal neovascular membrane (NVM). The NVM may occur as a result of retinal capillary remodeling, proliferation and invasion of the outer retina that has progressively atrophied from the disease.<sup>3</sup> In 40% to 45% of eyes in stage 5, superficial retinal crystalline deposits of unknown etiology have been reported. The significance of these refractile deposits is currently unknown, and they may occur at any time between stages 2 and 5.<sup>10</sup>

Refractile crystals may be present in other retinal disorders, but these crystals have distinguishing characteristics, such as showing specular reflection and being distributed in an annular pattern around the fovea, sparing it centrally.<sup>12</sup>

• **Type 3.** The final group is type 3, which is bilateral perifoveal telangiectasis with capillary oblit-

eration. This type is extremely rare and usually occurs in a patient's 40s with no gender predilection. Aneurysmal dilation occurs, along with the capillary obliteration without leakage. This causes slow, progressive vision loss in patients. This type is associated with other sequelae such as optic nerve head pallor, hyperactive deep tendon reflexes and central nervous system (CNS) symptoms.<sup>6</sup>

Type 3 is suspected to be autosomal dominant in inheritance pattern and is known to be associated with cerebroretinal vasculopathy.<sup>8</sup> Researchers have shown evidence of CNS pseudotumor characterized by unusual vasculopathy with fibrinoid necrosis and necrosis of white matter.<sup>8</sup> If you suspect CNS symptoms, refer patients to a neurologist.<sup>6</sup>

Overall, the most common symptoms reported by patients are blurred vision, metamorphopsia and possible scotomas when checked with Amsler grid.<sup>1</sup> This contrasts with the many asymptomatic patients with type 1 or the early stages of type 2. (*See Classification of IJRT by Type,*” page 84.)

## Pathogenesis

The pathogenesis and etiology of IJRT are unknown at this time. One study by Sallo et al. suggested looking into the physical and chemical properties of the retinal crystals to find information on the metabolic pathways involved in the pathogenesis of the disease.<sup>12</sup>

Other researchers have suggested that the histopathology of IJRT may be linked to dysfunction of the Muller cells.<sup>3</sup> The crystalline deposits have been thought to be remnants of degenerated Muller cells due to the location near the ILM.

## Management

Although a number of studies have attempted to determine the best treatment of IJRT, no treatment modality has been able to show consistent efficacy.<sup>7,13,14</sup> Some of these studies are contradicting, but the current treatments include intravitreal bevacizumab injections, focal grid laser photocoagulation or photodynamic therapy (PDT).<sup>7,13,14</sup>

If patients are asymptomatic or have minimal vision loss, usually no treatment is recommended.<sup>6</sup>

If a pronounced macular edema is seen in type 1, patients may benefit from intravitreal bevacizumab injections.<sup>13</sup> One study of type 1 patients used laser photocoagulation to prevent the accumulation of lipids in the fovea, especially if no prior accumulation of exudates existed.<sup>11</sup>

The treatment of type 2 IJRT

is more controversial. A study concluded that if minimal cystic changes are seen on OCT, repeated injections will not produce functional improvement.<sup>13</sup> Another study found intravitreal bevacizumab provided short-term improvement in vision due to decrease in retinal thickness and a reduction of angiographic leakage.<sup>14</sup> The use of focal laser photocoagulation is performed only if neovascularization is present outside the foveal area.<sup>6</sup>

Again, this treatment is controversial because some studies have shown no significant improvement of visual outcome with focal/grid photocoagulation. Reports show an increased risk of the development of subsequent neovascularization after treatment.

Recently, PDT has been used to resolve leakage of a neovascular membrane, but there is no effect on edema associated with telangiectasis.<sup>10</sup>

Currently there are no treatments available for the ocular manifestations of type three IJRT.

Unfortunately, the rarity of this disease makes the treatment difficult to assess in a controlled but random manner. Gass and Blodi did not recommend laser photocoagulation in type 2 if it is non-proliferative due the long-term prognosis already being poor. If type 2 is proliferative, anti-VEGF treatment such as bevacizumab may be efficacious.<sup>3</sup>

Comanage the treatment of these patients with a retinal specialist, as a fluorescein angiography is necessary to confirm the diagnosis and staging of IJRT.

IJRT is not a common disease entity. It is often misdiagnosed as retinopathy secondary to other diseases such as diabetes or sequelae

of an old venous occlusion. Fluorescein angiography and ocular coherence tomography are tools that aid in the definitive diagnosis of this retinal disease. The different groupings and stages assist the clinician in determining an accurate prognosis and the best course of treatment. ■

*Dr. Cooper is a fee-basis optometrist at the C.W. Bill Young VA Medical Center in Bay Pines, Florida.*

*Dr. Gruosso is a staff optometrist also at the C.W. Bill Young VA Medical Center, where he is the director of the low vision clinic and student externship program.*

*Dr. Miller is a staff optometrist and residency program coordinator at the C.W. Bill Young VA Medical Center.*

- Gass JD, Oyakawa RT. Idiopathic juxtafoveal retinal telangiectasis. *Arch Ophthalmol.* 1982 May;100(5):769-80.
- Paunescu L, Ko T, Duker JS, et al. Idiopathic juxtafoveal retinal telangiectasia: new findings by ultrahigh-resolution optical coherence tomography. *Ophthalmology.* 2006 Jan;113(1):48-57.
- Nowilaty S, Al-Shamsi H, Al-Khars W. Idiopathic juxtafoveal retinal telangiectasis: a current review. *Middle East Afr J Ophthalmol.* 2010 Jul;17(3):224-41.
- Wu J, Ferrucci S. Idiopathic juxtafoveal retinal telangiectasia. *Optometry.* 2008 Nov;79(11):653-62.
- Chhablani J, Kozak I. Multimodal imaging in idiopathic juxtafoveal retinal telangiectasia. *Retinal Physician.* 2013 Jan;10:62-64.
- Friedman N, Kaiser P, Pineda R. *The Massachusetts Eye and Ear Infirmary Illustrated Manual of Ophthalmology.* 3rd ed. Philadelphia: Saunders Elsevier; 2009: 352-3.
- Lee S, Kim S, Kim Y, Kang SW. Clinical features of idiopathic juxtafoveal telangiectasis in Koreans. *Korean J Ophthalmol.* 2011 Aug;25(4):225-30.
- Pauleikhoff D, Padge B. Vascular Abnormalities: Idiopathic Juxtafoveal Retinal Telangiectasis. In: Joussen AM, Gardner TW, Kirchhof B, Ryan SJ. *Retinal Vascular Disease.* Berlin/Heidelberg: Springer; 2007: 528-534.
- Klein R, Blodi B, Meuer S, et al. The prevalence of macular telangiectasis type 2 in the Beaver Dam Eye Study. *Am J Ophthalmol.* 2010 Jul;150(1):55-62.
- Engelbrecht NE, Aaberg TM Jr, Sung J, Lewis ML. Neovascular membranes associated with idiopathic juxtafoveal telangiectasis. *Arch Ophthalmol.* 2002 Mar;120(3):320-4.
- Bonyadi M, Moradian S. Large juxtafoveal telangiectasia. *J Ophthalmic Vis Res.* 2010 Jul;5(3):202-4.
- Sallo FB, Leung I, Chung M, et al; MacTel Study Group. Retinal crystals in type 2 idiopathic macular telangiectasia. *Ophthalmology.* 2011 Dec;118(12):2461-7.
- Gamulescu MA, Walter A, Sachs H, Helbig H. Bevacizumab in the treatment of idiopathic macular telangiectasia. *Graefes Arch Clin Exp Ophthalmol.* 2008 Aug;246(8):1189-93.
- Charbel Issa P, Holz FG, Scholl HP. Findings in fluorescein angiography and optical coherence tomography after intravitreal bevacizumab in type 2 idiopathic macular telangiectasia. *Ophthalmology.* 2007 Sep;114(9):1736-42.

DOWNLOAD LAYAR APP FOR INTERACTIVE EXPERIENCE



layar

INTERACTIVE PRINT

First 150 app downloads and completed forms will be entered into a drawing for **FREE MEETING AND REGISTRATION VALUED AT \$495**



**REVIEW OF OPTOMETRY**  
EDUCATIONAL MEETINGS OF CLINICAL EXCELLENCE

**PAUL KARPECKI, OD**  
PROGRAM CHAIR




**REGISTRATION OPEN**



**SAN DIEGO, CA**  
**APRIL 10-12**



**CHARLESTON, SC**  
**JUNE 12-14**



**MAUI, HI\***  
**JULY 23-26**



**PHILADELPHIA, PA**  
**NOVEMBER 6-8**

**NEW** Includes hands-on workshop

**Up to 17 CE Credits**  
(COPE approval pending)

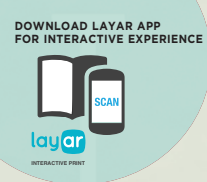For more information visit [www.reviewofoptometry.com](http://www.reviewofoptometry.com)

Administered By  
**Review of Optometry®**



Stock Images: ©iStock.com/JobsonHealthcare

\* Workshops not available - See website for information about snorkeling catamaran activity



First 150 app downloads and completed forms will be entered into a drawing for FREE MEETING AND REGISTRATION VALUED AT \$495

REGISTRATION OPEN!

# REVIEW OF OPTOMETRY

EDUCATIONAL MEETINGS OF CLINICAL EXCELLENCE



# SAN DIEGO, CA

# APRIL 10-12

# OMNI SAN DIEGO HOTEL

## CE COURSE TOPICS:

- Management of Lid Margin Disease
- Innovations in Eye Care
- Glaucoma Diagnostic Dilemmas and Solutions
- Emergency and Urgency Diagnosis and Treatment
- Anterior Segment Disease Diagnosis and Treatment
- Looking at the Optic Nerve in Glaucoma
- Comanagement of Cataract and Refractive Surgery
- Writing Oral Prescriptions

**NEW!!**

Dry Eye Workshop • Glaucoma Workshop

## FACULTY

Paul Karpecki, OD  
[Program Chair]



Marc Bloomenstein, OD



Derek Cunningham, OD



Doug Devries, OD



Ben Gaddie, OD



## 5 WAYS TO REGISTER

ONLINE: [WWW.REVOPTOM.COM/SANDIEGO2015](http://WWW.REVOPTOM.COM/SANDIEGO2015)

EMAIL LOIS DIDOMENICO: [REVIEWMEETINGS@JOBSON.COM](mailto:REVIEWMEETINGS@JOBSON.COM)

MAIL: REVIEW GROUP MEETINGS c/o JOBSON

11 Campus Blvd, Ste 100

Newtown Square, PA 19073

PHONE: 866-658-1772

FAX: 610-492-1039



Watch video with meeting chair, Paul Karpecki for more reasons to attend!

Administered By

Review of Optometry®



Up to  
17 CE  
Credits  
(COPE approval pending)

# OMNI SAN DIEGO HOTEL

675 L STREET SAN DIEGO, CA 92101

Discounted Room Rate: \$249/night single,  
\$269/night double

For Hotel reservations, call 800-843-6664

Discounted Room Rates Limited.

Identify yourself as a participant of

“Review of Optometry” for group rate.

## Up to 17 Credits

(COPE Approval Pending)

[www.revoptom.com/SanDiego2015](http://www.revoptom.com/SanDiego2015)

## Registration Information

Name		NPI # (NPI numbers will only be used for HCP reporting purposes)	
Practice Affiliation			
Mailing Address	City	State	Zip Code
Telephone	Fax	Email	

## Name Badge Information (please print clearly)

My Name	My Guest	Additional Guests
---------	----------	-------------------

## Payment Information

	Rate per person	No. in party	Subtotal
OD Registration - \$495 (includes 15 hours of CE, breakfasts, reception) <small>Call for daily and student rates.</small>	\$495	x _____	= \$ _____
Additional Guest(s) - \$45 (12 years and older, includes reception)	\$45	x _____	= \$ _____
Concurrent Workshop Sessions (Saturday, April 11, 2:30pm - 4:30pm) <small>Select only one if interested in additional session and credits</small>			
Dry Eye Workshop - \$70 (Earn 2 additional CE Credits)	\$70	x _____	= \$ _____
Glaucoma Workshop - \$70 (Earn 2 additional CE Credits)	\$70	x _____	= \$ _____
		TOTAL	= \$ _____

Check enclosed (make checks payable to *Review of Optometry*)

Charge my:  American Express  Mastercard  Visa

Credit Card Number \_\_\_\_\_ Exp Date \_\_\_\_\_

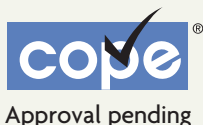Cardholder (print name) \_\_\_\_\_

Signature \_\_\_\_\_

**CONFERENCE CANCELLATION POLICY**

- Full refund on registration fee until March 10, 2015
- 50% refund on registration fee until March 28, 2015
- No refund past March 29, 2015

For more information or to register,  
contact Lois DiDomenico at 866-658-1772  
or at [ReviewMeetings@Jobson.com](mailto:ReviewMeetings@Jobson.com).



Administered By  
*Review of Optometry*®



# Coding Point-of-Care Testing

Take care when coding for point-of-care tests, and be aware that carrier rules are ever-changing. **By John Rumpakis, OD, MBA, Clinical Coding Editor**

Point-of-care testing is becoming more popular in the average optometric practice as technology improves and weaves its way into our daily clinical care. Many of the testing devices are small and simple to use—but that doesn't mean that coding for point-of-care testing can be taken lightly, nor is it something you should assume is "bundled" into an office visit. In fact, many point of care tests require that your office have a Clinical Lab Improvement Amendments (CLIA) waiver. (See "Get CLIA Certified for POC Testing," page 56.)

Lab tests are paid from a national laboratory fee schedule and don't follow the RBRVS reimbursement model. CPT codes are designated in the 8XXXX range. Only those tests that have the "waived" designation can be performed in your office. For coding purposes, CLIA-waived tests are designated by the -QW modifier.

Here are some common point-of-care tests that ODs perform:

**TearLab (TearLab).** CPT code 83861-QW: Microfluidic analysis using an integrated collection and analysis device, tear osmolarity.

If you're testing both eyes and coding for it, this is what the claim form would look like:

- 83861-QW-LT
- 83861-QW-RT

**AdenoPlus (Rapid Pathogen Screening).** CPT code 87809-QW: Infectious agent antigen detection by immunoassay with direct optical observation, adenovirus.

If you're testing both eyes and coding for it, this is what the claim form would look like:

- 87809-QW-RT
- 87809-QW-LT

**InflammaDry (Rapid Pathogen Screening).** CPT Code 83516-QW: Immunoassay for analyte other than infectious agent antibody or infectious agent antigen, qualitative or semiquantitative, multiple step method.

If you're testing both eyes and coding for it, this is what the claim form would look like:

- 83516-QW-RT
- 83516-QW-LT

## Not All Tests Are Created Equal

However, not all point-of-care tests are clinical lab tests or require CLIA certification. For example, both point-of-care tests for macular degeneration—Macula Risk NXG (ArcticDx) and RetnaGene AMD (Sequenom)—are not billable tests because the test itself is performed by an outside lab and the OD only collects the clinical sample by method of a buccal (cheek) swab. Swabbing is not a distinct and separate procedure according to the CPT and therefore is part of the office visit.

Tests for Sjögren's disease (Sjö) and diabetes both require collection of blood, which may not be within the scope of practice in your state. Keep in mind that the patient may stick his or her own finger for the blood sample, but you may not be able to. Again, this is a sample collection only, but

## Tear Testing May No Longer Be Covered?

Be aware of a recent development in dry eye testing (TearLab and InflammaDry): Some CMS carriers are proposing that neither test be covered due to inconclusive medical evidence that they affect the outcome of treatment.

Here is an excerpt from one CMS carrier (Novitas):

"Due to the lack of supporting data to demonstrate patient benefit from microfluidic analysis (tear osmolarity) or immunoassay analysis of tears relative to treatment choice and planning, disease outcome or evolution, Novitas considers tear testing for osmolarity and immunoassay analysis for other than infectious agent, antigen or antibody not medically reasonable and necessary. Subsequently, tear testing (83516, 83861) for the evaluation of dry eye or its associated disease entities is non-covered."

in this case is described with CPT code 36415 (routine venipuncture) and pays about \$3. Be cautious, as one could argue that you really didn't perform the procedure if the patient stuck himself or herself.

Point-of-care testing is certainly on the rise in optometry. Be sure that you follow the rules of medical necessity when ordering any tests. Follow the guidelines by properly obtaining your CLIA certification. Finally, be aware that carrier rules are ever-changing and may not support the use of testing as you see fit. ■

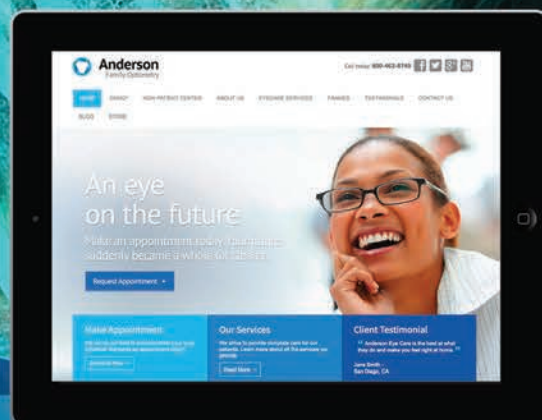
Send questions and comments to [ROcodingconnection@gmail.com](mailto:ROcodingconnection@gmail.com).

# You Help Patients See. We Help New Patients See You.



A strong web presence helps new patients find you.

- ✓ Appointment requests make it easy for new patients to contact you.
- ✓ Online forms streamline first time visits and reduce paperwork.
- ✓ An interactive Google map gets patients to your door.
- ✓ Blogs, social media, and video improve patient retention and referrals.
- ✓ Educate patients about medical procedures with unlimited web pages.



Get the solution you need to create a powerful web presence.



# Checks and Balances

Reestablishing a pH balance is key to controlling ocular damage from chemical burns.

Edited by Joseph P. Shovlin, OD

**Q** I recently saw a patient referred from the local emergency department with a severe alkali burn (fertilizer) to the conjunctiva and cornea. His eye was irrigated copiously for 40 minutes for the chemical insult prior to presenting to our office. How valuable is pH testing in cases like this one, i.e., those that have been copiously irrigated? Is it considered passé?

**A** Litmus paper can be helpful in certain instances; however, it does not take precedence over immediate and aggressive irrigation following an ocular chemical injury.

“Alkalis penetrate the conjunctiva and cornea quite readily, while acids precipitate on the surface, which tends to limit their penetration and injury severity. Consequently, alkali injuries are generally more damaging than acid injuries,” says Christopher J. Rapuano, MD, director of cornea service at Wills Eye Hospital in Philadelphia. Examples of alkali offenders include ammonia (fertilizers or refrigerants), lye (cleaning agents) or lime (building materials). Damage can vary depending on the type of chemical, how much entered the eye and when initial irrigation began.

The primary goal of irrigation following a chemical injury is to reestablish a pH level of approximately 7.5, the pH level of healthy human tears, Dr. Rapuano explains. “If the initial pH is much higher or lower than that, it will usually take more fluid for longer periods of time than if the initial pH is close to 7.5,” he says. Consequently, he adds, there is no exact quantity of fluid or duration of effort established as a mini-

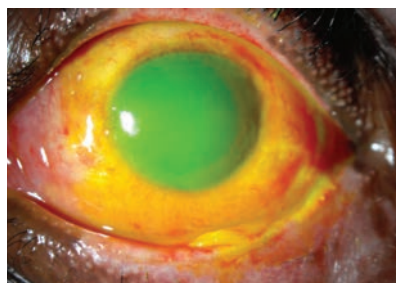


Photo: Chris J. Cakranac, OD

**There is a total corneal epithelial defect and a large conjunctival epithelial defect after a severe chemical injury in the left eye of this patient. Note that the conjunctiva has begun to epithelialize nasally, near the canthus.**

mum to achieve adequate irrigation.

It is in this situation that pH testing is useful: first, to check initial pH before irrigation (if possible) or upon arrival after being irrigated elsewhere, and then once or twice at 20-minute intervals to monitor irrigation efforts. Note, however, that the effectiveness of irrigation by evaluating with litmus paper has never been scientifically studied.<sup>1</sup>

Ocular irrigation can be performed by dripping either water or saline from an IV bag or nasal cannula, or using a Morgan lens, Dr. Rapuano says. He suggests considering the possibility that foreign material—for example, wet concrete, which is alkaline in nature—might adhere to the eye if the pH remains abnormal after copious irrigation. Check the lid area and fornix with double eversion, then carefully remove any particulate material and excise devitalized tissue.

J. James Thimons, OD, ophthalmic medical director at Ophthalmic

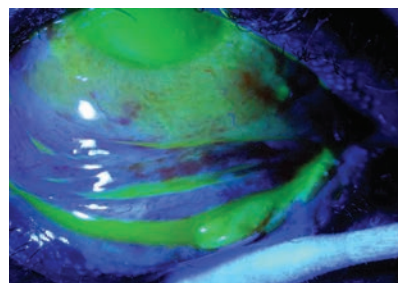


Photo: Chris J. Cakranac, OD

**Using cobalt blue light after fluorescein dye, the corneal and conjunctival epithelial defects are highlighted. Note the large bulbar conjunctival epithelial defect, but the majority of the palpebral conjunctival epithelium is intact.**

Consultants of Connecticut, points out that pH testing can also help in certain unique cases. “In patients exposed to chemical agents, pH testing is a useful adjunctive tool for the clinician in cases where either the agent is unknown or the actual pH is outside of the routine chemicals that are seen in primary care practice,” he says.

However, Dr. Thimons cautions, the somewhat limited shelf-life of test strips can confound pH testing. “Due to infrequent use, test strips can become ineffective and demonstrate inaccurate pH levels,” he says. “The remedy to this concern is to periodically test the strips on normal patients to ensure accuracy.” Error can also result from the presence of too little or too much tear film, which can alter pigment levels in the strip response, and from using the strips too soon after irrigation. ■

1. Foster CS, Azar DT, Dohlman CH, Smolin and Thoft's The Cornea: Scientific Foundations and Practice. 4th ed. Philadelphia: Lippincott, Williams & Wilkins; 2004.



The only silicone hydrogel technology clinically compared to the natural eye

## EXCEPTIONAL COMFORT<sup>1</sup>

No other lens has been shown to be clinically comparable in comfort to the natural eye, including Dailies Total1®

## EXCELLENT HEALTH PROFILE<sup>1</sup>

No other lens has been shown to be clinically comparable to the natural eye in 5 of 6 key measures of ocular health,\* including Dailies Total1®

## SUPERIOR UV PROTECTION<sup>†</sup>

The highest level of UV protection available in a contact lens: 99.9% UVB blocking, 96.9% UVA blocking.<sup>††</sup> Dailies Total1® does not meet ANSI/ISO standards for UV blocking



ANSI—American National Standards Institute; ISO—International Organization for Standardization.

ACUVUE® Brand Contact Lenses are indicated for vision correction. As with any contact lens, eye problems, including corneal ulcers, can develop. Some wearers may experience mild irritation, itching or discomfort. Lenses should not be prescribed if patients have any eye infection, or experience eye discomfort, excessive tearing, vision changes, redness or other eye problems. Consult the package insert for complete information. Complete information is also available from VISTAKON® Division of Johnson & Johnson Vision Care, Inc., by calling 1-800-843-2020 or by visiting [acuvueprofessional.com](http://acuvueprofessional.com).

\* Conjunctival hyperemia, limbal hyperemia, corneal staining, papillary conjunctivitis, corneal vascularization. The average incidence of conjunctival staining was not clinically equivalent to the naked eye, but results were consistent with another etafilcon A neophyte study and the level does not require clinical management.

<sup>†</sup> Helps protect against transmission of harmful UV radiation to the cornea and into the eye.

**WARNING:** UV-absorbing contact lenses are NOT substitutes for protective UV-absorbing eyewear such as UV-absorbing goggles or sunglasses, because they do not completely cover the eye and surrounding area. You should continue to use UV-absorbing eyewear as directed. **NOTE:** Long-term exposure to UV radiation is one of the risk factors associated with cataracts. Exposure is based on a number of factors such as environmental conditions (altitude, geography, cloud cover) and personal factors (extent and nature of outdoor activities). UV-blocking contact lenses help provide protection against harmful UV radiation. However, clinical studies have not been done to demonstrate that wearing UV-blocking contact lenses reduces the risk of developing cataracts or other eye disorders. Consult your eye care practitioner for more information.

<sup>††</sup> UV-blocking percentages are based on an average across the wavelength spectrum.

**Reference:** 1. Morgan PB, Chamberlain P, Moody K, Maldonado-Codina C. Ocular physiology and comfort in neophyte subjects fitted with daily disposable silicone hydrogel contact lenses. *Cont Lens Anterior Eye*. 2013;36(3):118-125.

The third-party trademarks used herein are trademarks of their respective owners.

ACUVUE®, 1-DAY ACUVUE® TruEye®, HYDRACLEAR®, and VISTAKON® are trademarks of Johnson & Johnson Vision Care, Inc.

© Johnson & Johnson Vision Care, Inc. 2015 ACU-A44407-B February 2015

Up to  
**12 CE**  
Credits  
(COPE approval pending)

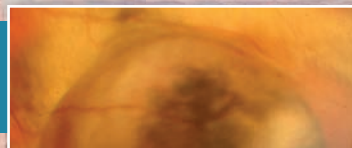
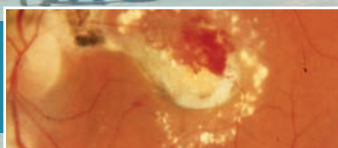
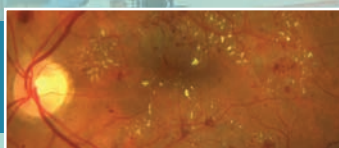
# REGISTRATION OPEN: DECEMBER 4-5, 2015 ANAHEIM, CA

THE OPTOMETRIC RETINA SOCIETY  
AND *REVIEW OF OPTOMETRY* PRESENT:

## RETINA UPDATE 2015



# ANAHEIM CALIFORNIA



## ORS Mission Statement

“The mission of the Optometric Retina Society (ORS) is to promote the advancement of vitreoretinal knowledge for clinicians, ophthalmic educators, residents, and students. The ORS is dedicated to posterior segment disease prevention, diagnosis, management and co-management.”

## 3 Ways to Register

### Online:

[www.revoptom.com/ORSRETUPDATE2015](http://www.revoptom.com/ORSRETUPDATE2015)

### Email Lois DiDomenico:

[ReviewMeetings@Jobson.com](mailto:ReviewMeetings@Jobson.com)

### Phone:

877-451-6510

## Sheraton Park Hotel

At the Anaheim Resort  
1855 S. Harbor Boulevard  
Anaheim, CA 92802

## Course Topics

- Nutrition and Genetics in Retinal Wellness
- New Paradigms in Retinal Vascular Disease
- Vitreoretinal Grand Rounds
- Medical and Surgical Retina Update
- Macular Holes and Epiretinal Membranes
- What's New in Retinal Imaging

Stock Image: ©iStock.com/JobsonHealthcare

Administered By  
*Review of Optometry*®

**cope**®  
Approval Pending



## Gone Girl

Can this patient's fundus exam help you find the cause of her sudden loss of vision?

By Mark T. Dunbar, OD

A 38-year-old Hispanic female from Honduras presented with a painless, sudden onset of blurred vision in the left eye of unknown duration. She stated that her central vision was most affected. She denied any pain, discomfort, flashes, floaters, nausea, fever or weight loss. She reported her right eye was unaffected.

Her past ocular history was unremarkable and she reported good health. She neither takes any medications nor has a history of any prior ocular trauma or surgeries. She was not nursing or pregnant.

Upon examination, her best-corrected visual acuity was 20/20 in her right eye and hand motion vision in her left eye. The confrontation fields were full to careful finger counting in her right eye and constricted in her left eye.

Ocular motilities were normal and her pupils were equal, round and responsive to light with no afferent pupillary defect. The anterior segment in the left eye was positive for trace cell, but otherwise normal in both eyes.

On dilated fundus exam, the right eye was unremarkable. The vitreous of the left eye was positive for 1+ vitreous cells with vitreal haze. Other changes are seen in *figure 1*. Lattice degeneration was present inferiorly in both eyes.

An SD-OCT of the macula in the left eye was obtained and is available for review (*figure 2*). An autofluorescence image (*figure 3*) was also obtained.

### Take the Retina Quiz

1. What do the fundus changes in the right eye macula show?

- a. Papilledema.
- b. "Headlights in the fog."
- c. "Snowballing."
- d. Macular star.

2. What additional testing would be most helpful in making the correct diagnosis?

- a. Blood test for IgG and IgM.
- b. Blood test for FTA-ABS, RPR.
- c. PPD.
- d. HLA-B27, HLA-A29.

3. What is the treatment for this patient?

- a. Bactrim PO, clindamycin PO, steroids PO, folic acid.
- b. Azithromycin PO.
- c. Doxycycline PO.
- d. Steroids IV.

4. What is most likely the diagnosis?

- a. Histoplasmosis.
- b. Tuberculosis.
- c. Toxoplasmosis.
- d. Toxocariasis.

For answers, turn to page 122.

### Diagnosis

Our patient has a white, chorioretinal, inflammatory lesion with an overlying vitritis adjacent to a dark, chorioretinal scar. The lesion was directly overlying the macula. This presentation is more commonly known as "headlights in the fog," which represents an active vitritis

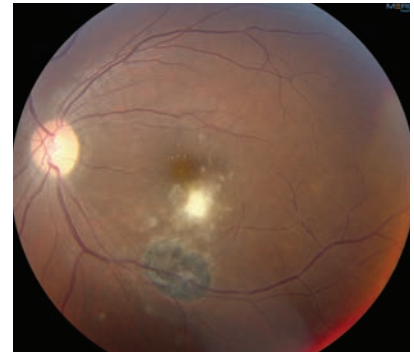

Fig. 1. Dilated fundus of the left eye.

overlying a white foci of retino-choroiditis. Adjacent to the active lesions is an old chorioretinal scar from a previous active lesion. This presentation most likely represents ocular toxoplasmosis. The patient did not admit to having any cats nor eating any raw or undercooked pork, lamb or venison.

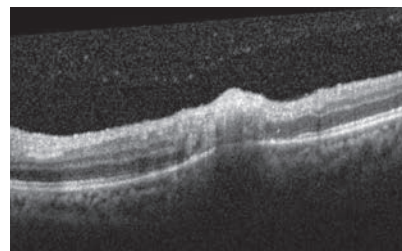
Toxoplasmosis, the most common cause of posterior uveitis, accounts for approximately 90% of focal necrotizing retinitis.<sup>1</sup> *Toxoplasma gondii* is a small, oblong shaped, intracellular protozoan parasite known to cause toxoplasmosis. The rate of seropositivity for toxoplasmosis is estimated around 22.5% in the United States.<sup>2</sup> More than 60 million in the United States may have been affected by the parasite but, of those, few display symptoms.<sup>1</sup> This is because a healthy immune system usually keeps the parasite from causing illness.

The diagnosis is usually made based on the clinical presentation. Blood work can be performed, but a positive result does not always

## Retina Quiz

ensure a diagnosis. Interestingly, there is a high seropositivity in the general population, which means that a positive titer does not necessarily confirm the diagnosis, but a negative titer should prompt strong deliberation of alternate diagnoses. IgG antibodies are produced within two weeks of infection and peak at two months, then later present for life.<sup>3</sup> Detection of IgM antibody titers are usually possible within the first two weeks of infection and suggest a recently acquired infection.<sup>3</sup> Blood work-up was not performed on our patient because it was a pretty “classic” presentation.

The disease can be transmitted via several potential methods. Ingesting undercooked meats such as pork, lamb or venison could be a culprit. Another involves consuming water contaminated with the parasite or



**Fig. 2. OCT of the macula in the left eye.**

accidental exposure through contact with cat feces. The most common transmission is mother-to-child (transplacentally).

Mothers who are seropositive for toxoplasmosis show rates of transmission that range between 60% and 81%, which can be more noticeable in the third trimester.<sup>4</sup> Manifestations of congenital toxoplasmosis include: hydrocephalus, seizures, intracranial calcifications and retinochoroiditis.

Clinical symptoms of active toxoplasmosis included blurred vision, floaters and potential redness or photophobia or both. Pain is typically absent, except with iridocyclitis. The clinical appearance of a toxoplasmosis lesion may vary depending on whether the infection is active or inactive. The active state usually appears as a unilateral, whitish, fluffy, retinal lesion with blurred margins. When the disease reoccurs, it often does so next to a “satellite lesion” also known as an old chorioretinal scar.

Toxoplasmosis is generally self-limiting in immunocompetent patients, and treatment is reserved for lesions threatening or involving the macular or optic nerve. We elected to treat our patient in two ways. Since the lesion was active and directly involving the macula

# FOCUS ON YOUR FUTURE

AT SECO &  
VISION EXPO EAST

 Local Eye Site  
JOBS IN EYE CARE

Visit Our Booth for  
Discounted Job Postings!

SECO  
BOOTH  
#439

EXPO  
BOOTH  
#3785

Visit [localeyesite.com/show](http://localeyesite.com/show) for more info.

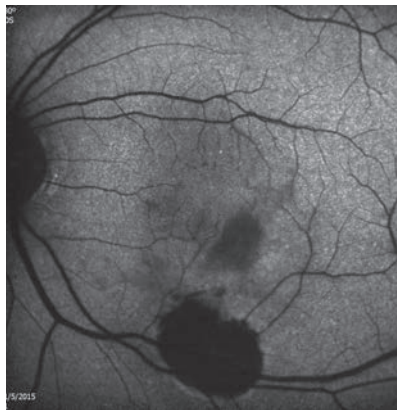
 Local Eye Site  
JOBS IN EYE CARE

**SECO2015**  
WHERE SIGHT MEETS VISION

 INTERNATIONAL  
VISION  
EXPO  
& CONFERENCE  
NEW YORK

and her vision was drastically affected, the patient was given an intravitreal injection of dexamethasone 0.4mg/clindamycin 1mg in office. Studies show that intravitreal injection of clindamycin and dexamethasone is as effective as conventional oral therapy in treatment of ocular toxoplasmosis with fewer systemic side effects.<sup>5</sup> A study at the Nikookari Eye Hospital in Iran tested oral therapy vs. intravitreal for ocular toxoplasmosis, and within six months the results were equally effective in terms of increased BCVA, a decrease in lesion size and a termination of the vitritis.

After the injection, the patient was placed on clindamycin 30mg PO TID, Bactrim DS PO BID and prednisolone 40mg PO QD. She will continue this oral dosage for a month. At her two-week follow-up,



**Fig. 3. Autofluorescence of the left eye.**

the vitritis resolved and the acuity improved to 20/800 OS. The visual prognosis is guarded secondary to macular involvement. Spiramycin is reserved for fetal prophylaxis or to decrease disease severity in cases of maternal infection without fetal infection. It is prescribed as 1g every

eight hours for the duration of pregnancy once diagnosed.<sup>4</sup>

In cases of confirmed infection of the mother and the fetus (through cranial ultrasound or amniocentesis), the mother is given oral Bactrim PO until delivery. ■

*This case was written and provided by Nikolaos C. Zagorianos, OD, an optometric resident at Bascom Palmer Eye Institute.*

1. Gerstenblith A, Rabin M. The Wills Eye Manual: office and emergency room diagnosis and treatment of eye disease, 6th edition. Philadelphia, Lippincott Williams & Wilkins 2012; 369-371.
2. Yanhoff N, Duker J. Uveitis and Other Intraocular Inflammations<sup>®</sup> Ophthalmology: Expert consult, 3rd edition. Mosby November 2008; 828-831
3. Onofrey B, Skorin L, Holdeman N. Ocular Therapeutics Handbook: A Clinical Manual, 3rd edition. Philadelphia, Wolters Kluwer Health, 2011; 477-481
4. Chaudhry S, Gad N, Koren G. Toxoplasmosis and Pregnancy. Can Fam Physician April 2014; PMID: PMC4046541.
5. Baharivan N, Mahdaviard A, Fouladi R. Intravitreal clindamycin plus dexamethasone versus classic oral therapy in toxoplasmic retinochoroiditis: a prospective randomized clinical trial. Int Ophthalmology 28 September 2012. doi: 10.1007/s10792-012-9634-1

# Your own custom App

for iPhone, Android, iPad and Mobile Website!

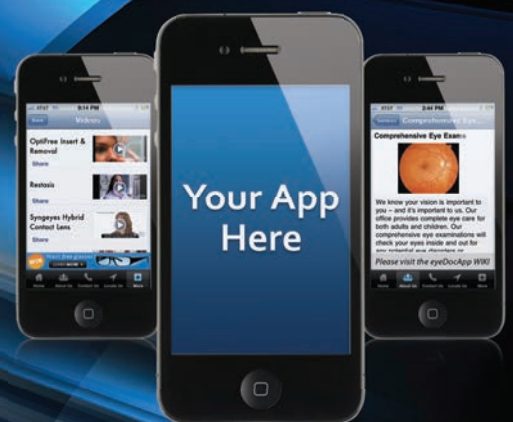**EyeDocApp** makes it easy for Individuals and Businesses to have their own custom App for iPhone, Android and iPad. Now you can use the same technology that Fortune 500 companies are using, for a fraction of the cost!

**Apps are the most powerful mobile marketing tools in the world!** Your custom App can be downloaded by anyone in the world via the iTunes and Android Marketplace. Now all your customers can have your business in their pocket, and at their fingertips. You can even send PUSH Notifications which instantly pop up on their phone, just like a text message.

Unlimited upgrades, push notifications, features and a user friendly interface –  
**All for \$49.<sup>99</sup>/month**

Learn more at [EyeDocApp.com](http://EyeDocApp.com)

EyeDocApp



Exclusively Marketed by  
**ECP**  
BUSINESS SERVICES  
Understand. Manage. Grow.

# TECH TALKS ONLY AT VISION EXPO

Tech Talks are an interactive forum providing a snapshot of the next generation of eyewear and eyecare. Hear directly from manufacturer's reps, see live demonstrations and get your questions answered.

## SUNDAY, MARCH 22

- 10:00 AM-10:15 AM **GUNNAR: COMPUTERS - EVIL FOR YOUR EYE** Joe Croft, CEO
- 10:30 AM-10:45 AM **SMART VISION LABS: VISION ACCESS FOR ALL** Yaopeng Zhou, Co-founder and CEO
- 11:00 AM-11:15 AM **TOTAL 3D SOLUTIONS: THE COMING AGE OF VR** Annette Tindall, Principal
- 11:30 AM-11:45 AM **VISIONCARE OPHTHALMIC TECHNOLOGIES, INC.: THE IMPLANTABLE MINIATURE TELESCOPE FOR INDIVIDUALS WITH END-STAGE AMD** Karen Murphy, MS OTR/L, SCLV
- 12:00 PM-12:15 PM **3-D FRAME SOLUTIONS: PRINTING YOUR PRACTICE PROFITS** Dr. Elvin Fenton
- 12:30 PM-12:45 PM **PIVOTHEAD: PIVOTHEAD SMART** Jordan Elder, Sales Account Executive
- 1:00 PM-1:15 PM **AVI WEAR: HOW SMART GLASSES WILL BE CHANGING THE WAY WE LIVE** Dan Shannon, Vice President and Co-Founder
- 1:30 PM-1:45 PM **VUZIX: SMART GLASSES - GEEK OR SHEIK?** Dan Cui, Vice President, Sales and Business Development
- 2:00 PM-2:15 PM **ROCHESTER OPTICAL: GETTING OVER FUTURE SHOCK** Timothy Moore, CMO
- 2:30 PM-2:45 PM **MINT: INCREASING ECP PROFITABILITY THROUGH INDUSTRY** Jack Gill, MBA
- 3:00 PM-3:15 PM **SIX-15: WEARABLE DISPLAYS BEYOND THE ENTERPRISE MARKET** James Donnelly, VP Business Development

LOCATED IN THE  
LENSES AND  
PROCESSING  
TECHNOLOGY  
PAVILION



## TECHNOLOGY THEATER



The Technology Theater is your destination for dynamic programming delivered in a stimulating environment. Take the Retail and Wearable Technology Track courses here or catch a Tech Talk from exhibitors in the exciting *Vision Monday Eye<sup>2</sup> Zone*.

## WEARABLE TECH ONLY AT VISION EXPO

13 VISIONARY COMPANIES SHOWCASE NEW,  
NON-TRADITIONAL VISION TECHNOLOGIES – THE  
FUTURE YOU CAN'T AFFORD TO IGNORE

- Unique opportunity to learn about new non-traditional vision technologies hitting the markets.
- Be in a better position to advise patients on overall visual needs after testing products that enhance vision or athletic performance, communicate or view media, measure and monitor biometric data, promote wellness and more.
- See vision-related products for consumers that we know will eventually end up in the chairs of eyecare professionals.

REGISTER TODAY AT [VisionExpoEast.com/R00](http://VisionExpoEast.com/R00)



## INTERNATIONAL VISION EXPO 2015

EDUCATION: THURSDAY, MARCH 19-SUNDAY, MARCH 22

EXHIBITION: FRIDAY, MARCH 20-SUNDAY, MARCH 22

JAVITS CENTER | NEW YORK, NY | [VisionExpoEast.com](http://VisionExpoEast.com) | #VisionExpo

PROUD SUPPORTER OF:





# AIDS in America: 30 Years Later

The CDC estimates 1.2 million people in the US are living with HIV. Do you know the ocular signs? **By Carlo J. Pelino, OD, and Joseph J. Pizzimenti, OD**

**H**uman immunodeficiency virus (HIV) is a blood-borne retrovirus. Acquired immune-deficiency syndrome (AIDS) is caused by HIV and is characterized by profound immune suppression that leads to opportunistic infections (OIs), secondary neoplasms, neurological manifestations and possible death.

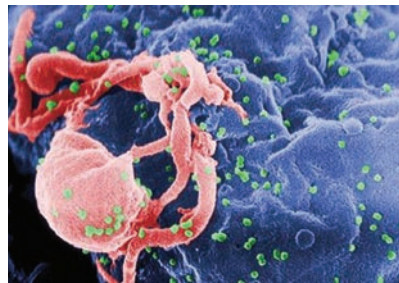
In the United States, HIV was first described in 1981 among two groups, one in San Francisco and the other in New York. Numerous young homosexual men presented with opportunistic infections that were typically associated with severe immune deficiency: Pneumocystis pneumonia (PCP) and aggressive Kaposi sarcoma.<sup>1</sup> HIV itself was not identified for another two years.<sup>2</sup>

## People at Risk

Men who have sex with men continue to bear the greatest burden of infection. Among races/ethnicities, African Americans and Hispanic/Latinos are disproportionately affected, as are injection drug users.<sup>3,4</sup> People with sexually-transmitted diseases (STDs) often also have, or are more likely to get, HIV.<sup>4,5</sup>

## Transmission and Transcription

HIV is typically transmitted via sexual intercourse, shared intravenous drug paraphernalia and mother-to-child transmission, which can occur during birth or breastfeeding. HIV disease is caused by infection with



**This scanning electron micrograph shows HIV-1 budding from a cultured lymphocyte.**

HIV-1 or HIV-2, which are retroviruses in the *Retroviridae* family, *Lentivirus* genus.

Retroviruses use RNA as their genetic material, but the host cell must synthesize a “DNA copy” of the RNA before it can be transcribed or translated. This task is aided by the action of an enzyme known as *reverse transcriptase*.<sup>6</sup>

Like others in the lentiviral genus, HIV creates a long interval between initial infection and serious symptoms. It targets the immune system by primarily affecting an arm of adaptive immunity called “cell-mediated immunity.”

The cluster of differentiation 4 (CD4) molecule, found on T helper (T<sub>h</sub>) and other immune system cells, is a high-affinity receptor for HIV. Binding to CD4 is not sufficient for infection, so HIV must also bind to other surface molecules for entry. Mature T<sub>h</sub> cells that express CD4 (CD4+T cells), along with macrophages and follicular dendritic cells contained in lymphoid tissues, are the major sites for HIV infection and persistence.<sup>7</sup>

## Clinical Signs

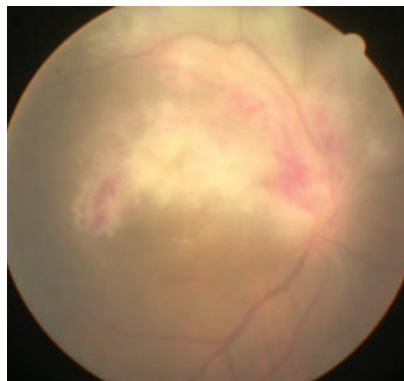Viral replication occurs in the regional lymph nodes and leads to viremia with eventual seeding of lymphoid tissue. Acute retroviral syndrome, the initial response to HIV infection, occurs approximately four weeks after infection. Clinically, this phase is a self-limited acute illness with flu-like symptoms such as rash, sore throat, vomiting, myalgias, fever, weight loss and fatigue.

The following chronic stage may last for several years. The patient may be asymptomatic, but generalized lymphadenopathy, thrush, herpes zoster and thrombocytopenia may be noted during this time. Activation of CD8+ cytotoxic T cells appears to be the primary mechanism for immunologic control of HIV. T cell responses are correlated with the steady-state viral load and thus the rate of progression.<sup>5,7</sup>

## The Eye and HIV

These are the most frequent ocular complications of HIV/AIDS.<sup>7,8</sup>

- Irritation of the conjunctiva
- Keratoconjunctivitis sicca
- HIV-related retinal microangiopathy
- Cytomegalovirus
- Immune recovery uveitis
- Acute retinal necrosis
- Progressive outer retinal necrosis
- *Molluscum contagiosum*
- Syphilis
- Toxoplasmosis
- *Pneumocystis jiroveci*
- *Mycobacterium tuberculosis*
- Neoplasm (Kaposi sarcoma)



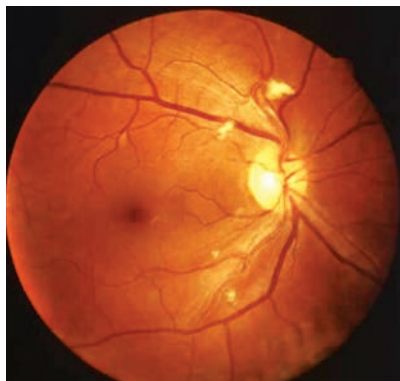**Cytomegalovirus retinitis in a patient with AIDS.**

The final phase is progression to AIDS. In the United States, a CD4+T cell count less than 200/ $\mu\text{L}$  is used as a measure to diagnose AIDS. Long-lasting fever, fatigue, weight loss and diarrhea may occur, as well as OIs, secondary neoplasms and neurological disease. These account for the majority of deaths in patients with AIDS.<sup>2,7</sup>

A high-sensitivity enzyme-linked immunoabsorbent assay (ELISA) should be used for screening; a positive result should be followed with confirmatory testing. The CD4+T cell count reliably reflects the current risk of acquiring OIs. Viral load in peripheral blood is used as a surrogate marker of viral replication rate. Patients with viral loads greater than 30,000/ $\mu\text{L}$  are 18.5 times more likely to die of AIDS than those with undetectable viral loads.<sup>7</sup>

## Antiretroviral Treatment

The use of combination antiretroviral therapies and prophylaxis for IOs dramatically improves survival.<sup>7,8</sup> The US Food and Drug Administration has approved a once-daily, fixed-dose triple-combination pill (Triumeq, ViiV Healthcare) containing the antivirals dolutegravir, abacavir and



**HIV retinopathy may present with cotton-wool spots and vascular changes.**

lamivudine for the treatment of patients aged 18 years or older. Overall, with the increasing use of antiretroviral therapy and the introduction of better regimens, survival with HIV has increased.

Society has made substantial progress, but we continue to face challenges. Patients with HIV should be counseled on the risks of infecting sexual partners. Safe sex practices and treatment of STDs, in the patient and sexual partners, considerably reduces the risk of transmission. Intravenous drug users should be counseled on the risks of sharing paraphernalia.

## Ocular Complications

Approximately 80% of HIV-infected patients will be treated for an HIV-associated eye disorder.<sup>9</sup> The optometrist may be presented with adnexal, anterior segment, posterior segment or orbital manifestations. Adnexal manifestations may include herpes zoster or conjunctival microvasculopathy, among others. Anterior segment findings include tumors of the periocular tissues and a variety of external infections. Posterior segment changes include an HIV-associated retinopathy/vasculopathy and a number of OIs of the retina and

choroid. Orbital manifestations of HIV are rare; however, the most common complications include orbital lymphoma and orbital cellulitis due to *Aspergillus* infection.<sup>9</sup>

Increasing longevity of individuals with HIV may result in greater numbers of patients with ocular complications. Fortunately, many of these are now treatable. Partial immune system recovery following initiation of effective antiretroviral therapy may modify clinical presentation of OI and can affect response to treatment. In addition, several infections may occur in a single eye at the same time, rendering diagnosis and therapeutic intervention more difficult.

Due to the potentially devastating and rapid course of OI, patients with HIV should undergo regular evaluations. With early-stage HIV, ocular syndromes associated with immunosuppression are uncommon. Nonetheless, ocular infections associated with STDs may be more frequent in patients with HIV; therefore, clinicians should screen for HIV in the presence of these infections. ■

1. Friedman-Kien A, Laubenstein L, Marmor M, et al. Kaposi's sarcoma and Pneumocystis pneumonia among homosexual men—New York City and California. *MMWR Morb Mortal Wkly Rep.* 1981;30(25):305-8.
2. Barre-Sinoussi F, Chermann JC, Rey F, et al. Isolation of a T-lymphotropic retrovirus from a patient at risk for acquired immune deficiency syndrome (AIDS). *Science.* 1983;220(4599):868-71.
3. CDC. Monitoring selected national HIV prevention and care objectives by using HIV surveillance data—United States and 6 dependent areas—2012. *HIV Surveillance Supplemental Report.* 2014;19(3).
4. CDC. Estimated HIV incidence in the United States, 2007–2010. *HIV Surveillance Supplemental Report.* 2012;17(4).
5. CDC. *HIV Surveillance Report.* 2012;24.
6. Carter J, Saunders V. *Virology: Principles and Applications (Paperback).* 2013:1-65.
7. Kumar V, Abbas A, Fausto N. Robbins and Cotran *Pathologic Basis of Disease*, 7th ed. Philadelphia: Elsevier Saunders; 2005:245-258.
8. Hirsch DA, Jones S, Wallach F, et al. Ocular manifestations in individuals infected with the human immunodeficiency virus. *Comprehensive Ophthalmology Update.* 2004;5(1):3-14.
9. Copeland Jr R, Phillipotts B. Ocular Manifestations of HIV Infection. <http://emedicine.medscape.com/article/1216172-overview#aw2aab6b5>.





INTERNATIONAL  
**VISION  
EXPO**  
& CONFERENCE  
NEW YORK

# VISIONARIES

IN EDUCATION, FASHION AND TECHNOLOGY

As the forum where eyecare business operates at a higher level than anywhere else in the industry, it's easy to see why International Vision Expo is often labeled the "Writing Show." That's why the most renowned brands in the industry build their biggest customer experiences exclusively for International Vision Expo. Nothing else compares – and they know it.

Attendees are primed to lay eyes on sought-after items on their sourcing lists. Some have been waiting all year for the opportunity to test, touch and hold products they know they will be buying at the show – while others are shopping for the most desirable items to expand their current offerings. They're all looking for the next big thing, and International Vision Expo is where they'll find it.

The best keeps getting better. The growth of the International Vision Expo partner program sets this event apart to convene visionaries in fashion, education and technology under one roof.

From early morning until late at night, thousands of like-minded professionals from more than 50 unique groups gather for co-located meetings, participate in education and host events.

These alliances, state and national associations, and buying groups choose International Vision Expo as the global hub for the eyecare industry. It has become the premier destination for partnerships to flourish and business-building relationships to thrive.

## INTERNATIONAL VISION EXPO 2015

EDUCATION: THURSDAY, MARCH 19–SUNDAY, MARCH 22

EXHIBITION: FRIDAY, MARCH 20–SUNDAY, MARCH 22

JAVITS CENTER | NEW YORK, NY | [VisionExpoEast.com](http://VisionExpoEast.com) | [#VisionExpo](https://twitter.com/VisionExpo)

REGISTER TODAY AT [VisionExpoEast.com/R00](http://VisionExpoEast.com/R00)

PROUD SUPPORTER OF: **thinkabout  
youreyes**  
thinkaboutyoureyes.com  
MEMBER SINCE 2014  
AMERICAN OPTOMETRIC ASSOCIATION

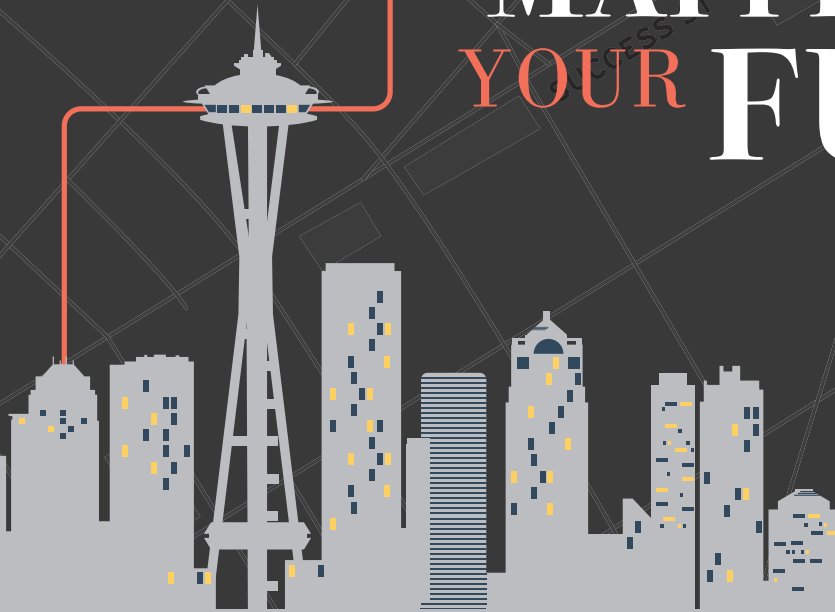FUTURE ST

TECHNOLOGY AVE

NETWORKING ST

CONTACTS RD

# MAPPING YOUR FUTURE



Optometry's  
meeting®

## MAKE THE RIGHT CONNECTIONS.

**Benefit your career, advance your knowledge, and better position yourself for future success with one right turn,** Optometry's Meeting®. With prominent ODs and their staff from every state, an abundance of technology, and a stellar education program, Optometry's Meeting is the only event focused on defining the future of Optometry. Plan to be informed, plan to be engaged...plan to attend this June in Seattle. For more information or to register visit [optometrysmeeeting.org](http://optometrysmeeeting.org) today.

**\*OD members act now to save \$25 off your full-conference registration by using the code CONNECT when you register online.**

*\*The code is available to the first 50 respondents and is good through April, 30 2015.*

OPHTHALMIC ST

ADVANCE RD

CAREER DRIVE



SEATTLE, WA  
JUNE 24-28, 2015





# The Throwback Thursday Option

Recognize when a situation calls for doctors to revert to old-model drugs.

By Joseph W. Sowka, OD and Alan G. Kabat, OD

Today, optometrists can access an impressive drug armamentarium to treat our patients. The anti-infectives, steroids, anti-histamines and glaucoma medications currently available are second to none and represent a huge step forward from the options of only a few years ago. With the potency and efficacy of new therapies, often there comes a high price. Clinically, these new medications are outstanding, but when patients cannot afford them, how should an optometrist respond? Are clinicians justified in reaching back to an older, tried-and-true standby?

This month's column is a "Throwback Thursday" edition (with author photos to match), wherein we'll explore older medicines that still have a place today.

## Infectious Bacterial Keratitis

The first case we'll look at involves a 45-year-old woman recently released from eight months of incarceration. A high myope, she never disclosed to prison officials that she wore soft contact lenses, and used a single pair of lenses incessantly for the duration. She presented with a painful, red, right eye. Her findings included profound conjunctival injection, a significant secondary anterior chamber reaction, dense paracentral corneal infiltration—which fortunately did not immediately threaten her visual axis—and epithelial excavation. In short, she had an infectious keratitis, presumably of bacterial nature.

After explaining the diagnosis and risk of permanent vision loss, we discussed therapeutic options and the need for potent antibiotics. We felt that a fourth generation fluoroquinolone such as moxifloxacin, gatifloxacin or besifloxacin would be best. However, after discussing the cost of these branded medications, the patient emphatically stated that she would not be able to afford them and could not possibly use them. After a discussion about the need for aggressive treatment, a compromise was reached. We prescribed generic Ocuflax (ofloxacin 0.3%) which cost her about \$9.00. Though Ocuflax is an older generation fluoroquinolone, it eradicated the infection successfully.

## Ocuflax and Ciloxan

Ocuflax and Ciloxan (ciprofloxacin 0.3%) are second-generation fluoroquinolone antibiotics FDA approved for the topical treatment of bacterial conjunctivitis and bacterial keratitis caused by susceptible organisms. These medications have in vitro and in vivo activity against a broad range of gram-positive and gram-negative aerobic and anaerobic bacteria. Ofloxacin and ciprofloxacin are bactericidal at concentrations equal to or slightly greater than inhibitory concentrations. Ofloxacin

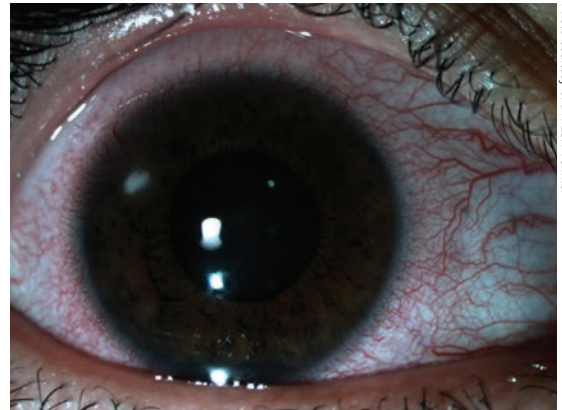

Photo courtesy of Dr. Lori Vollmer

**Patient 1 presented with infectious keratitis, which responded to treatment with ofloxacin.**

and ciprofloxacin exert bactericidal effects on susceptible bacterial cells by inhibiting DNA gyrase (which is a type II topoisomerase) or topoisomerase IV, which is an enzyme necessary to separate replicated DNA, thereby inhibiting bacterial cell division, or both.

## Topical Fluoroquinolones

The development in the 1990s of topical fluoroquinolones offered a highly effective alternative to fortified antibiotics for patients with bacterial keratitis. For the first time, commercially available antibiotics were scientifically compared with the standard treatment of fortified antibiotics. Historically, bacterial keratitis was treated with compounded, fortified solutions of aminoglycosides and cefazolins. Often, this involved diluting antibiotics originally designed for intravenous use. The results of the Bacterial Keratitis Study Group, as well as

more recent studies, showed that ofloxacin and ciprofloxacin were equivalent to fortified ceftazolin and tobramycin solutions in the management of patients with bacterial keratitis.<sup>1-5</sup> The reduced frequency of ocular toxic effects and the relative ease of use of these fluoroquinolones was seen as additionally beneficial in these studies.

## Efficacy

However, bacteria have grown increasingly resistant to second generation fluoroquinolones, and some researchers suggest that later generation fluoroquinolones, such as gatifloxacin 0.3%, provide superior coverage.<sup>6</sup> Inspection of at least one medication pricing website, [www.goodrx.com](http://www.goodrx.com), indicates that the cost of gatifloxacin 2.5ml is \$131.28 for the branded form and \$50.72 for the generic version. In comparison, 5ml of generic ofloxacin is \$9.37 and generic ciprofloxacin is \$11.74. Unquestionably, the fourth generation fluoroquinolones are outstanding in terms of antibiotic efficacy and superior choices for sight-threatening infections. But the most effective medication will not work if the patient can't afford it. Don't discount older generation fluoroquinolones. They remain effective and accessible to most patients.

## Non-infectious Keratopathy

In another case, a 30-year-old female contact lens wearer presented with a red, moderately irritated right eye. She had diffuse injection of her bulbar conjunctiva and a non-staining peripheral corneal infiltrate. Additionally, she had a mild diffuse epitheliopathy. We diagnosed a contact lens-related hypoxia and non-infectious keratopathy. We told her to temporarily discontinue contact lens wear. We wanted to reduce inflammation

while providing some degree of antibiotic coverage and recommended a combination antibiotic-steroid medication.

When she reported that she had no insurance, we again consulted [www.goodrx.com](http://www.goodrx.com) to get an idea of her anticipated costs. We looked at two branded steroid-antibiotic combination agents and found that a 5ml bottle would cost her from \$158.88 to \$197.97. Her facial expression gave us her answer. We prescribed an alternative, generic Maxitrol solution, which she purchased for \$4.00. Within a week, her condition resolved.

## Maxitrol

Maxitrol is an antibiotic-steroid combination of neomycin sulfate 3.5mg, polymyxin B sulfate 10,000 units, and dexamethasone 0.1%. As with most antibiotic-steroid combinations, it is appropriate for steroid-responsive inflammatory ocular conditions for which a corticosteroid is indicated and where bacterial ocular infection or a risk of infection exists. Polymyxin B is an antibiotic used for resistant gram-negative infections, altering bacterial outer membrane permeability by binding to a negatively charged site in the lipopolysaccharide layer, which results in a destabilized bacterial outer membrane.

Neomycin is an aminoglycoside antibiotic that, like others in the category, has excellent activity against gram-negative bacteria, and has partial activity against gram-positive bacteria. It is relatively toxic. Much has been said about the potential allergic responses that patients have to neomycin, making it a lesser choice for clinicians. However, the majority of allergic reactions that we have seen have involved over-the-counter dermatologic preparations where patients

used it off-label for the eyes. We cannot recall any instance where Maxitrol caused a toxic ocular reaction, quite possibly due to the steroid combating any allergic responses. Lately, we have seen more cataract surgeons providing Maxitrol in postoperative kits, likely due to its efficacy and price. While branded antibiotic-steroid combinations are excellent choices, we never hesitate to prescribe Maxitrol.

## Ocular Hypertension

The final patient is a 58-year-old male with ocular hypertension, also with no prescription drug coverage. His untreated IOP was 25mm Hg OD and 26mm Hg OS and his central cornea was thin at 456 $\mu$ m OD and 464 $\mu$ m OS. He mentioned his mother lost vision due to glaucoma. After a detailed discussion about the risks and benefits of prophylactic IOP reduction, we prescribed generic latanoprost, which gave him an unacceptable degree of hyperemia.

We discontinued the latanoprost and instead prescribed generic timolol 0.5%, which was tolerable and affordable at \$4.00 a bottle. Using timolol, this patient achieved adequate IOP reduction.

## Timolol

Since the advent of the prostaglandin medications, clinicians' reliance on topical beta blocker therapy has significantly reduced. However, prior to the development of prostaglandins, doctors used beta blockers extensively with few problems. Like prostaglandin analogs, the earlier introduction of branded Timoptic (timolol maleate 0.5%) revolutionized glaucoma management.

While specific contraindications exist, it appears that many of the propagated fears about topical beta blockers stem from anecdotal case reports rather than evidence-based

sources. These drugs are actually quite safe for the vast majority of patients, and virtually no confirmation shows they directly induce clinical depression, sexual dysfunction, claudication, prolonged hypoglycemia or hypoglycemic unawareness.<sup>7</sup>

However, practitioners must remain aware of potential complications and be alert for any unusual systemic complaints in patients using beta blocker therapy. Always obtain a thorough health history, check in-office pulse rate, and refer patients for medical evaluation when indicated prior to initiating topical beta blockers. With these minimal precautions appropriately taken, timolol is an excellent first-line medication, which gives impressive IOP reduction at a low cost.

The field has developed a number of ophthalmic medications in the last several years with unprecedented efficacy. However, it is important to remember medications we used successfully in the past. Just because something is old doesn't mean it isn't good. ■

*The authors would like to thank Dr. Amanda Brown for suggesting this column.*

1. O'Brien TP, Maguire MG, Fink NE, et al. Efficacy of ofloxacin vs cefazolin and tobramycin in the therapy for bacterial keratitis. Report from the Bacterial Keratitis Study Research Group. Arch Ophthalmol. 1995;113(10):1257-65.
2. The Ofloxacin Study Group. Ofloxacin monotherapy for the primary treatment of microbial keratitis: a double-masked, randomized, controlled trial with conventional dual therapy. Ophthalmology. 1997;104(11):1902-9.
3. Hyndiuk RA, Eiferman RA, Caldwell DR, et al. Comparison of ciprofloxacin ophthalmic solution 0.3% to fortified tobramycin-cefazolin in treating bacterial corneal ulcers. Ciprofloxacin Bacterial Keratitis Study Group. Ophthalmology. 1996;103(11):1854-62.
4. Khokhar S, Sindhu N, Mirdha BR. Comparison of topical 0.3% ofloxacin to fortified tobramycin-cefazolin in the therapy of bacterial keratitis. Infection. 2000;(3):149-52.
5. McDonald EM, Ram FS, Patel DV, McGhee CN. Topical antibiotics for the management of bacterial keratitis: an evidence-based review of high quality randomised controlled trials. Br J Ophthalmol. 2014;98(11):1470-7.
6. Parmar P, Salman A, Kalavathy CM, et al. Comparison of topical gatifloxacin 0.3% and ciprofloxacin 0.3% for the treatment of bacterial keratitis. Am J Ophthalmol. 2006;141(2):282-286.
7. Lama PJ. Systemic adverse effects of beta-adrenergic blockers: an evidence-based assessment. Am J Ophthalmol. 2002;134(5):749-60.

Better  
comfort.  
Better  
retention.  
Better  
results.



Take the **VeraPlug™** challenge.

Compare the new VeraPlug to the plug you're using now and see the difference for yourself.

☞ Visit [lacriversa.com/challenge](http://lacriversa.com/challenge) for your free sample

A FRESH PERSPECTIVE™

  
**LACRIVERA®**

[lacriversa.com](http://lacriversa.com) (855) 857-0518

2500 Sandersville Rd • Lexington KY 40511 USA

DOWNLOAD LAYAR APP  
FOR INTERACTIVE EXPERIENCE



First 150 app downloads & completed forms will be entered into a drawing for FREE MEETING & REGISTRATION VALUED AT \$495

REGISTRATION OPEN!

## REVIEW OF OPTOMETRY EDUCATIONAL MEETINGS OF CLINICAL EXCELLENCE



# MAUI, HAWAII JULY 23-26

WAILEA BEACH MARRIOTT RESORT & SPA  
3700 WAILEA ALANUI DRIVE, MAUI, HI 96753

**\$100 OFF BY  
MAY 23RD**

## CE COURSE TOPICS:

- New Advances in the Management of Lid Margin Disease
- Clinical Management of Ocular Surface Disease
- Technological Innovations in Eye Care
- Cancer and the Eye: Ocular Tumors, Malignancies and Neoplasms
- Expert Panel on Glaucoma Diagnosis and Treatment
- What the Primary Care Optometrist Should Never Miss
- Don't Let Swollen Optic Nerves Make You Nervous
- Conquering Therapeutic Dilemmas



Watch video with meeting chair, Paul Karpecki for more reasons to attend!

## FACULTY



Paul Karpecki, OD  
Program Chair



Ron Melton, OD



Brad Sutton, OD



Randall Thomas, OD

## 3 WAYS TO REGISTER

ONLINE: [WWW.REVOPTOM.COM/MAUI2015](http://WWW.REVOPTOM.COM/MAUI2015)

EMAIL LOIS DIDOMENICO: [REVIEWMEETINGS@JOBSON.COM](mailto:REVIEWMEETINGS@JOBSON.COM)

PHONE: 866-658-1772

Administered By

Review of Optometry®



Up to  
**14 CE  
Credits**  
(COPE approval pending)



By Derek N. Cunningham, OD, and Walter O. Whitley, OD, MBA

## Measure Twice, Cut Once

Pre-op diagnostic testing is critical to cataract surgery outcomes. And you play a vital role.

Cataract surgery is a once in a lifetime opportunity to provide our patients with greatly improved vision. As the comanaging OD, any information we can gather prior to the surgical referral will help determine the procedure and outcome. For instance, if a patient has corneal astigmatism and a toric IOL would be appropriate, send the corneal topographies along with the referral notes, so the surgeon can look for consistency in the readings.

This month, let's review how pre-op testing can aid surgical planning.

### Biometry

Precise biometry is essential in cataract surgery. Simply put, outcomes depend on it. Measurement of axial length by ultrasound has been the gold standard for many years. The introduction of optical biometry has increased accuracy and added the ability to measure anterior chamber depth, lens thickness, pachymetry, pupillometry, keratometry and white-to-white distance.

Popular optical biometers include the Lenstar LS900 (Haag-Streit) and the IOLMaster 500 (Zeiss). Both measure corneal curvature; the IOLMaster makes six measurements at 3mm of the central cornea and the Lenstar performs 16 central corneal readings—eight at 1.7mm and eight at 2.3 mm. All the standard IOL prediction formulas (Holladay I and II, SRK-T, Haigis and Hoffer Q) are built into the software.

If optical biometry cannot be performed, use applanation biometry. Compared to traditional biometry, A-scan biometry by immersion has better reproducibility, which leads to an overall increase in accuracy.

### Corneal Measurements

Accurate corneal measurements are critical in IOL calculations and surgical planning, and they also determine which patients would benefit from limbal relaxing incisions or toric IOLs. Several technologies can provide this important data, and

many practices capture corneal measurements on a number of devices to ensure consistency and accuracy of the measurements. Options include:

- **Keratometry.** A mainstay of optometry, this reflection-based test measures four points over a central zone of 2.88mm to 4mm, two at the steep axis and the other two 90 degrees away.
- **Placido disk topography** reflects a series of concentric rings, or mires, off the cornea. Placido disk systems have certain advantages over the keratometer in that they are able to measure more points over the corneal surface and over an infinite corneal power range.
- **Scanning slit topography** such as the Orbscan (Bausch + Lomb) is a projection-based method that uses a series of slit-beam images to generate data regarding anterior surface curvature, posterior surface curvature and pachymetry.

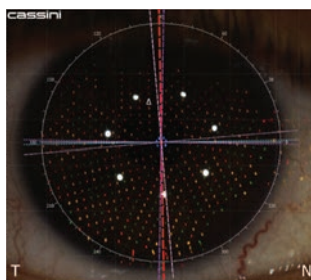
- **Scheimpflug-based systems.** The Pentacam (Oculus) is a combination device consisting of a slit illumination system and a Scheimpflug camera that rotates around the eye. Rotating around the central corneal axis, the slit-camera device generates a series of radially oriented images of the anterior eye chamber. Results can be used to generate data on elevation, curvature, pachymetry and depth of the anterior eye chamber.

- **Color LED Topography.** The Cassini (i-optics) technology uses ray-tracing principles to measure the relative position of each point, using the three different colors as 'triangulation' points to determine elevation, depression and curvature.

If we are unable to take accurate pre-op measurements—e.g., in patients who could not easily access the diagnostic technology due to physical limitation—many surgeons rely on average corneal readings and approximations of axial length.

### Additional Diagnostic Tests

- **Endothelial cell count.** Assessing endothelial cell counts and density is useful in spotting patients at higher risk of corneal decompensation.
- **Pachymetry** determines corneal thickness and helps identify patients at risk of corneal decompensation; it also aids in glaucoma management.
- **B-scan ultrasound** is indicated for mature cataracts and to detect any posterior segment pathology prior to surgery. ■



Measuring the relative distance between points allows precise mapping of corneal curvature, improving toric IOL planning.

1. Hill W. IOL Power Calculation Formulas. 2015. [www.doc-tor-hill.com/iol-main/formulas.htm](http://www.doc-tor-hill.com/iol-main/formulas.htm). Accessed Feb. 14, 2015.  
2. [haag-streit-usa.com/mylenstar.aspx](http://haag-streit-usa.com/mylenstar.aspx). Accessed Feb. 14, 2015.  
3. [www.meditec.zeiss.com/C1256CAC0038CEFF/ContainerTitel/IOLMaster500/\\$File/index.html](http://www.meditec.zeiss.com/C1256CAC0038CEFF/ContainerTitel/IOLMaster500/$File/index.html). Accessed Feb. 14, 2015.

20<sup>TH</sup> ANNUAL

# OPHTHALMIC PRODUCT GUIDE



Innovative products to  
enhance your practice

The **future**  
is in your  
hands. One  
tap, many  
possibilities.

Experience the digital edition on your handheld device.  
Use your smart device to scan the code below or visit:



[www.reviewofoptometry.com/supplements/](http://www.reviewofoptometry.com/supplements/)

Download a QR scanner app. Launch app and hold your mobile device over  
the code to view <http://www.reviewofoptometry.com/supplements>

**REVIEW**  
OF OPTOMETRY



# Product Review

## Diagnostic Equipment

### New Portable Autorefractor

If space in your exam lane is hard to come by or you do a lot of clinical exams at various locations in and out of the office, the new SVOne autorefractor from Smart Vision Labs might help. The handheld device, which measures refractive error using a wavefront sensor, connects to an iPhone and uploads information to a HIPAA-compliant cloud. Its open-field design reduces instrument-induced myopia, the company says. The



device also allows for instantaneous smartphone-based digital prescriptions. The portability and long-lasting battery—which is said to last through 56 hours of continuous refracting—helps optometrists work in limited space and non-clinical conditions.

Visit [www.smartvisionlabs.com](http://www.smartvisionlabs.com).

## Ophthalmic Lenses

### Next Generation of Unbreakable Lenses

Athletic and other outdoorsy patients will appreciate hearing about new photochromic lenses called ImpactX-2 that provide faster color transition and enhanced contrast in an unbreakable lens, according to manufacturer Rudy Project.

ImpactX-2 lenses have the ability to automatically lighten and darken from a semitransparent tone to a specific color according to lighting conditions. ImpactX-2 comes in five variations that transition from clear to either black, laser black, red, laser red or laser brown.

These lenses offer a wider photochromic range of up to 65% light transmission difference, Rudy



Project says. This photochromic activation occurs in all natural light within seconds, including behind surfaces that screen UV rays such as windows or car windshields.

For patients with refractive error, ImpactX-2 can be crafted with their specific correction parameters; back-side surfacing applies the prescription to the back of each lens.

Visit [www.e-rudy.com](http://www.e-rudy.com).

### “Change Your View” Sweepstakes

Want to win a sightseeing trip to Alaska, or other fun prizes like a GoPro camera or a Microsoft Surface tablet? You can enter the “Change Your View” sweepstakes from Essilor of America, running through April 30, 2015, to register. Doctors who complete a training session on the use of Transitions photochromic lenses are eligible for the contest.

Prizes are awarded weekly and monthly. The grand prize winner will receive round-trip airfare for two to Fairbanks and Anchorage, accommodations in both cities, an expedition to the Spencer Glacier and a rafting adventure in Anchorage. The winner will also receive a digital camera, photography classes and a voucher redeemable for a pair of Transitions lenses and frames.

Monthly prizes include an HD camera, a 32GB tablet and an airlines gift card. Weekly prizes include Amazon, Teavana and iTunes gift cards.

Visit [www.essilortransitions.com](http://www.essilortransitions.com).

## Eyewear

### Spring 2015 Collection

Shauns California recently debuted its Spring 2015 collection, which includes five new sun styles and four ophthalmic styles.

The women’s Rona frame and Spey optical style have a metal temple design with recessed enamel color fill. The women’s Tacit boasts an asymmetrical front with a raised right brow, and the unisex More style has a front-on silhouette. Featuring a high



Rona

metal bridge frame between two separate pieces of acetate, the absence of a traditional nose bridge brings a completely new perspective to a timeless shape.

Spring 2015 offers a selection of tortoise shell acetates (Rona, Hoy, Annan and Luss styles). Gradiated acetate in a deep black cherry makes its debut in this collection as well, flowing from a near black to a cherry color (Carron, Hoy and Spey styles).

This gradation technique is also used in a Bistre to topaz blue (Spey, Annan and Hoy

styles). The popular mirrored lens is back in multiple colors, as well as in two different treatments. The “Super” family of mirrors is a multi-layered mirror for a strong, highly reflective effect (seen in blue and silver in the collection). A lighter “flash” application is used for a subtle mirror effect with a greater degree of translucency.

Visit [www.shaunscalifornia.com](http://www.shaunscalifornia.com).



More



Spey

## March 2015

■ **20-22.** *Vision Expo East.* Jacob K. Javits Convention Center. New York, NY. Hosted by: International Vision Expo and Conference. To register, go to [www.visionexpoeast.com](http://www.visionexpoeast.com).

■ **26-28.** *OAOP Vision Summit.* Embassy Suites Hotel and Conference Center, Norman, OK. Hosted by: Oklahoma Association of Optometric Physicians. CE hours: 18. To register, go to [www.oaop.org](http://www.oaop.org).

## April 2015

■ **11-12.** *MOS Annual Spring Conference.* Cincinnati Marriott Northeast, Cincinnati, OH. Hosted by: Midwest Optometric Society. CE hours 16. To register or view agenda go to [www.midwestoptometricsociety.com](http://www.midwestoptometricsociety.com).

■ **15-17.** *World Cornea Congress VII.* San Diego Convention Center, San Diego, CA. Hosted by: ASCRS. To register, go to: <http://corneacongress.org>.

■ **17-19.** *NOA Spring Conference-CE Event.* Embassy Suites, Lincoln, NE. Hosted by: Nebraska Optometric Association. To register, email [ajohnson@assocoffice.net](mailto:ajohnson@assocoffice.net).

■ **17-22.** *ASCRS-ASOA Symposium and Congress 2015.* San Diego Convention Center, San Diego, CA. Hosted by: ASCRS/ASOA. To register, go to: <http://annualmeeting.ascrs.org>.

■ **18-19.** *Miami Nice Educational Symposium 2015.* Westin Colonnade, Coral Gables, FL. Hosted by: Miami-Dade Optometric Physicians Association. CE Hours: 17 COPE-approved, 12 transcript quality. Key Faculty: Ken Lebow, John McGreal, Carl Spear, Al Morier, John McClane, Albert Woods. To register, go to [www.miamieyes.org](http://www.miamieyes.org) or email Steve Morris at [mdopa.board@gmail.com](mailto:mdopa.board@gmail.com).

■ **22-26.** *13th Annual Educational Conference.* Hilton Embassy Suites at Kingston Plantation, Myrtle Beach, SC. Hosted by: American Academy of Optometry New Jersey Chapter. CE Hours: 16. Key Faculty: Mark Friedberg, Alan Kabat. To register, call Dennis Lyons at (732) 920-0110 or email [dhi2020@aol.com](mailto:dhi2020@aol.com).

■ **23-25.** *Mountain West Council of Optometrists (MWCO) Annual Congress.* Bally's, Las Vegas, NV. Hosted by: Mountain West Council of Optometrists. CE Hours: 24. To register, go to [www.mwco.org](http://www.mwco.org) or call (888) 376-6926.

■ **23-26.** *2015 Annual Spring Convention.* Marriott Hotel & Little Rock Convention Center, Little Rock, AR. Hosted by: Arkansas Optometric Association. To register, email Vicki Farmer at [vicki@arkansasoptometric.org](mailto:vicki@arkansasoptometric.org).

■ **29-May 7.** *Annual Educational Conference and Exposition.* Red Lion Colonial Hotel, Helena, MT. Hosted by: Montana Optometric Association. To register, call (406) 443-1160 or email [sweingartner@rmsmanagement.com](mailto:sweingartner@rmsmanagement.com).

■ **30-May 1.** *Spring 2015 Convention.* Pierre Ramkota, Pierre, SD. Hosted by: South Dakota Optometric Society. To register,

email Deb Mortenson at [deb.mortenson@pie.midco.net](mailto:deb.mortenson@pie.midco.net) or go to [southdakota.aoa.org](http://southdakota.aoa.org).

## May 2015

■ **2-3.** *8th Annual Evidence Based Care in Optometry Conference.* Turf Valley Conference Center and Resort, Ellicott City, MD. Hosted by: Maryland Optometric Association & John Hopkins-Wilmer Eye Institute. To register, call Annie Phan at (410) 486-9662 or email [aphan@marylandoptometry.org](mailto:aphan@marylandoptometry.org).

■ **3.** *OptoWest Regional Conference.* Anaheim Marriott Suites, Anaheim, CA. Hosted by: California Optometric Association. CE Hours: 6. Key Faculty: Steven Ferrucci, Bruce Onofrey, Mary Schmidt. To register, go to [www.optowest.com](http://www.optowest.com), call Sarah Harbin at (916) 266-5022 or email [sharbin@coavision.org](mailto:sharbin@coavision.org).

■ **3.** *NECO Sunday Seminar Series CE.* New England College of Optometry, Boston, MA. Hosted by: New England College of Optometry Alumni Association. CE Hours: 5. Key Faculty: Mark Dunbar, Michael Springer. To register, go to [www.neco.edu/academics/continuing-education/sunday-series](http://www.neco.edu/academics/continuing-education/sunday-series), call Margery Warren at (617) 587-5687 or email [ce@neco.edu](mailto:ce@neco.edu).

■ **3-5.** *CE in Italy.* Hotel Silla, Florence, Italy. Hosted by: James Fanelli. CE Hours: 12. Key Faculty: James Fanelli, Carlo Pelino. To register, call James Fanelli at (910) 452-7225, go to [www.CEinItaly.com](http://www.CEinItaly.com) or email [jamesfanelli@CEinItaly.com](mailto:jamesfanelli@CEinItaly.com).

■ **3-7.** *ARVO 2015.* Colorado Convention Center, Denver, CO. Hosted by: The Association for Research in Vision and Ophthalmology. For information and registration, go to [www.arvo.org/Annual\\_Meeting](http://www.arvo.org/Annual_Meeting).

■ **7-9.** *CE in Italy.* Palazzo Al Valabro, Rome, Italy. Hosted by James Fanelli. CE Hours: 12. Key Faculty: James Fanelli, Carlo Pelino, Joseph Pizzimenti. To register, call James Fanelli at (910) 452-7225, go to [www.CEinItaly.com](http://www.CEinItaly.com) or email [jamesfanelli@CEinItaly.com](mailto:jamesfanelli@CEinItaly.com).

■ **15-17.** *Arizona Optometric Association 2015 Spring Congress.* Hilton Tucson El Conquistador Golf & Tennis Resort, Tucson, AZ. Hosted by: Arizona Optometric Association. To register, go to: <http://arizona.aoa.org>.

## June 2015

■ **5-7.** *June "Summer" Conference.* Harborside Hotel & Marina, Bar Harbor, ME. Hosted by: Maine Optometric Association. To register, call (207) 288-5033 or toll-free (800) 328-5033.

■ **12-14.** *2015 Annual Meeting.* Myrtle Beach, SC. Hosted by: North Carolina State Optometric Society. To register, email Adrienne Drollette at [adrienne@nceyes.org](mailto:adrienne@nceyes.org).

■ **19-21.** *2015 VOA Annual Conference.* Hilton, McLean, VA. Hosted by: Virginia Optometric Association. To register, call Bo Keeney at (804) 643-0309.

# Advertisers Index

- **24-28.** *Optometry's Meeting 2015.* Washington State Convention Center, Seattle, WA. Hosted by: American Optometric Association and American Optometric Student Association. To register, go to <http://optometrismeeing.org>.
- **26-July 5.** *A Comprehensive Update on Contemporary Eye Care.* Northern European Capitals Cruise, departs Copenhagen, Denmark. Hosted by: Dr. Travel Seminars/The New Jersey Society of Optometric Physicians. Key Faculty: Randall Thomas. CE Hours: 12. To register, call Robert Pascal at (800) 436-1028, email [info@DrTravel.com](mailto:info@DrTravel.com) or visit [DrTravel.com](http://DrTravel.com).

## July 2015

- **4-11.** *Tropical CE Puerto Rico.* El Conquistador—Waldorf Astoria, Puerto Rico. Hosted by: Tropical CE. Key Faculty: Jimmy Bartlett, Kim Reed. CE Hours: 20. To register, call Stuart Autry at (281) 808-5763, email [sautry@tropicalce.com](mailto:sautry@tropicalce.com) or go to [www.tropicalce.com](http://www.tropicalce.com).
- **10-12.** *21st Conference on Clinical Vision Care.* Southern College of Optometry, Memphis. Hosted by: OEP Foundation. CE Hours: 17. For information and registration, call Theresa Krejci at 800-447-0370, email [theresakrejciOEP@verizon.net](mailto:theresakrejciOEP@verizon.net) or go to [www.oepf.org](http://www.oepf.org).
- **16-19.** *2015 Victoria Conference.* Inn at Laurel Point, Victoria, British Columbia, Canada. Hosted by: Pacific University. Key Faculty: Terry Burris, Danica Marelli, Curtis Baxstrom, Tad Buckingham. CE Hours: 20. To register, email Jeanne Oliver at [Jeanne@pacificu.edu](mailto:Jeanne@pacificu.edu) or go to [www.pacificu.edu/future-graduate-professional/colleges/college-optometry/continuing-education/conferences-events](http://www.pacificu.edu/future-graduate-professional/colleges/college-optometry/continuing-education/conferences-events).
- **16-19.** *Florida Optometric Association Annual Convention.* The Breakers, Palm Beach, FL. Hosted by: Florida Optometric Association. Key Faculty: William Marcolini, Ian Gaddie, Mark Dunbar, Christian Guier, Paul Palmer, April Jasper. CE Hours: 30 Total, 22 per OD. To register, call Jessica Brewton at 805-877-4697, email [jessica@floridaeyes.org](mailto:jessica@floridaeyes.org) or go to [www.floridaeyes.org](http://www.floridaeyes.org).
- **17-18.** *OOPA Summer CE Event.* The Resort at the Mountain, Welches, OR. Hosted by: Oregon Optometric Physicians Association. Key Faculty: Gordon Johns, Beth Kinoshita, Lorne Yudcovitch, Rebecca Uhlig, Robert Egan, Stan Teplick. CE Hours: 13. To register, email Lynne Olson at [lynne@oregonoptometry.org](mailto:lynne@oregonoptometry.org) or go to [www.oregonoptometry.org](http://www.oregonoptometry.org).

### To list your meeting, please send the details to:

Rebecca Hepp, Senior Associate Editor

Email: [rhepp@jobson.com](mailto:rhepp@jobson.com)

Phone: (610) 492-1005

<b>Abbott Medical Optics, Inc. (AMO)</b> .....	<b>18 A-L</b>	<b>NovaBay Pharmaceuticals, Inc.</b> .....	<b>49</b>
Phone .....	(800) 366-6554	Phone .....	(800) 890-0329
		.....	sales@avenova.com
		.....	www.avenova.com
<b>Alcon Laboratories</b> .....	<b>5, 23</b>	<b>Oculus, Inc.</b> .....	<b>61</b>
.....	<b>24, 79, 124</b>	Phone .....	(888) 284-8004
Phone .....	(800) 451-3937	Fax .....	(425) 867-1881
Fax.....	(817) 551-4352	<b>Odyssey Medical (now part of Beaver-Visitec International, Inc.)</b> .....	<b>9</b>
<b>Bausch + Lomb</b> .....	<b>17, 57</b>	Phone .....	(866) 906-8080
Phone .....	(800) 323-0000	.....	www.odysseymed.com
Fax.....	(813) 975-7762	<b>Reichert Technologies</b> .....	<b>41</b>
<b>Carl Zeiss Meditec Inc.</b> .....	<b>27</b>	Phone .....	(888) 849-8955
Phone .....	(877) 486-7473	Fax.....	(716) 686-4545
Fax.....	(925) 557-4101	.....	www.reichert.com
<b>Coburn Technologies</b> .....	<b>31</b>	<b>Reliance Medical</b> .....	<b>59</b>
Phone .....	(800) 262-8761	Phone .....	(800) 735-0357
.....	www.coburntechnologies.com	Fax.....	(513) 398-0256
<b>CooperVision</b> .....	<b>43, 123</b>	<b>The Alliance</b> .....	<b>75</b>
Phone .....	(800) 341-2020	Phone .....	(888) 466-8263
<b>Essilor of America</b> .....	<b>10, 32-33</b>	.....	www.thealliancebg.com
.....	www.essilorusa.com	<b>ThromboGenics Inc.</b> .....	<b>21</b>
<b>Haag-Streit</b> .....	<b>77</b>	Phone .....	(732) 590-2901
Phone .....	(800) 627-6286	Fax.....	(866) 936-6676
Fax.....	(603) 742-7217	<b>Tomey</b> .....	<b>47</b>
<b>HAI Laboratories</b> .....	<b>55</b>	Phone .....	(888) 449-4045
Phone .....	(781) 862-9884	.....	www.tomeyusa.com
Fax.....	(781) 860-7722	<b>Transitions Optical</b> .....	<b>13</b>
<b>Icare USA</b> .....	<b>14</b>	Phone .....	(800) 848-1506
Phone .....	(888) 389-4022	Fax.....	(813) 546-4732
.....	www.icare-usa.com	<b>U.S. Army</b> .....	<b>29</b>
<b>Keeler Instruments</b> .....	<b>7</b>	Phone .....	(800) 431-6731
Phone .....	(800) 523-5620	.....	www.healthcare.goarmy.com/at66
Fax.....	(610) 353-7814	<b>Veatch</b> .....	<b>37</b>
<b>Lacrivera</b> .....	<b>109</b>	Phone .....	(800) 447-7511
Phone .....	(855) 857-0518	Fax.....	(602) 838-4934
.....	www.lacrivera.com	<b>Vision Source</b> .....	<b>85</b>
<b>Lombart Instruments</b> .....	<b>15</b>	Phone .....	(281) 312-1111
Phone .....	(800) 446-8092	Fax.....	(281) 312-1153
Fax.....	(757) 855-1232	.....	www.visionsource.com
<b>M&amp;S Technologies</b> .....	<b>51</b>	<b>Vistakon</b> .....	<b>2-3, 97</b>
Phone .....	(877) 225-6101	Phone .....	(800) 874-5278
Fax.....	(847) 763-9170	Fax.....	(904) 443-1252
<b>MediNiche</b> .....	<b>39</b>		
Phone .....	(888) 325-2395		
.....	info@mediniche.com		
.....	www.mediniche.com		

*This advertiser index is published as a convenience and not as part of the advertising contract. Every care will be taken to index correctly. No allowance will be made for errors due to spelling, incorrect page number, or failure to insert.*

DOWNLOAD LAYAR APP FOR INTERACTIVE EXPERIENCE



First 150 app downloads & completed forms will be entered into a drawing for FREE MEETING & REGISTRATION VALUED AT \$495

REGISTRATION OPEN!

# REVIEW OF OPTOMETRY

EDUCATIONAL MEETINGS OF CLINICAL EXCELLENCE



# CHARLESTON, SC

## JUNE 12-14

### FRANCIS MARION HOTEL

387 KING STREET CHARLESTON, SC 29403

## CE COURSE TOPICS:

- New Developments in Cornea and Contact Lenses
- Innovations in Eye Care
- Management of Ocular Surface Disease
- Grand Rounds in Anterior Segment Disease
- Modern Management of Periocular Malignancies
- Ocular Urgencies and Emergencies
- Ocular Occlusive Disease
- HSV, HZO, EKC: Viral Eye Disease Alphabet Soup
- Beyond Glaucoma: A Primer for OCT Interpretation

**\$100 OFF BY APRIL 10TH**

## NEW! Dry Eye and Glaucoma Workshops



Watch video with meeting chair, Paul Karpecki for more reasons to attend!

## FACULTY

Paul Karpecki, OD  
[Program Chair]



Doug Devries, OD



Andrew Gurwood, OD



Nathan Lighthizer, OD



Marc Myers, OD



Jack Schaeffer, OD



## 3 WAYS TO REGISTER

ONLINE: [WWW.REVOPTOM.COM/CHARLESTON2015](http://WWW.REVOPTOM.COM/CHARLESTON2015)

EMAIL LOIS DIDOMENICO: [REVIEWMEETINGS@JOBSON.COM](mailto:REVIEWMEETINGS@JOBSON.COM)

PHONE: 866-658-1772

Administered By  
*Review of Optometry*<sup>®</sup>



Up to  
**17 CE Credits**  
(COPE approval pending)

**Merchandise Offered**



OPTICAL DISPLAYS  
& FURNITURE

Free Dispensary Design

Free Financing\*

Fast Delivery

Largest Selection

\* For all orders above \$10K.  
Offer is valid until DEC 31, 2015.

**1-877-274-9300**



**ESSILOR'S FRAME DISPLAYS GROUP**

Innovative Dispensary Planning & Design – Authentic Craftsmanship & Integrity

Visit the website to view examples of what Frame Displays can create for you, and schedule a free consultation with one of the design professionals.

Come see us at **SECO2015** March 5-7 | Atlanta, GA | Booth 620

**VISION EXPO & CONFERENCE** NY, NY | March 20-22 | Booth 3540

**Equipment and Supplies**



It's What the Best  
Pretest on!  
**(800) 522-2275**  
www.optinomics.com  
sales@optinomics.com

*Superior Quality • Competitive Pricing • Worldwide Shipping*

Enter "AZ16"  
at checkout  
for 15% off  
your order!

WWW. **GuldenOphthalmics** .COM

Offer valid  
online or  
by phone:  
800-659-2250



**Eye Models • Prisms & Prism Bars • Occluders**

- Great for patient demonstrations
- Astigmatism
- Cataract/IOL
- Cornea disorders
- Floaters & more!

- Hand-made since 1938
- Laser calibrated for accuracy
- Gulden is the only manufacturer of the patented EZ View™ Prism Bar
- Prism re-polish service available

- Large assortment:
- Maddox/Occluders
- Clip-on Occluders
- Spielmanns
- Lorgnettes & more online!



Gulden's **New and Innovative** Products are Proudly Made in the U.S.A.



Targeting Optometrists?

**CLASSIFIED ADVERTISING WORKS**

Contact us today for classified advertising:

Toll free: **888.498.1460** • E-mail: sales@kerhgroup.com



**Merchandise Offered**

**EYEDESIGNS.**  
 BUILDING YOU A BETTER BUSINESS

SPACE PLANNING  
 INTERIOR DESIGN  
 DISPLAY INNOVATION  
 MANUFACTURING

WWW.EYEDESIGNS.COM  
 800.346.8890



**FREE GIFT** for the first 25 people to contact us.  
 Ref. code OPT0315 exp. 03/31/15



4741  
 SECO2015 1319



FORM  
FUNCTION

Style

opticaldisplays.com™

INFO@OPTICALDISPLAYS.COM TO REQUEST OUR CATALOG & DESIGN SERVICES CALL 610.489.7620

**FREE GIFT** for the first 25 people to contact us. Ref. code: OPT0315 exp. 03/31/15



4741  
 SECO2015 1319

**Software**

*Take a closer look...*

**at Eyecom for your electronic health record needs!**

tablet compliant

share patient data securely

over 25 years experience

cloud-based access anytime, anywhere



*Eyecom*<sup>3</sup> **EHR**

WEB-BASED OPTOMETRIC SOFTWARE

800.788.3356 [www.eyecom3.com](http://www.eyecom3.com)



QUIKEYES<sup>SM</sup>

Ocular Medical Records

The quickest, easiest way to paperless eye exams

QuikEyes  
Optometry EHR

- \$198 per month after low cost set-up fee
- Quick Set-Up and Easy to Use
- No Server Needed
- Corporate and Private OD practices
- 14 Day Free Demo Trial
- Email/Text Communications

[www.quikeyes.com](http://www.quikeyes.com)

Continuing Education

**Medical Facility Optometrists**

The American Board of Certification in Medical Optometry is utilized at accredited medical facilities to verify specialist-level competence in medical optometry. ABCMO certifies specialized competence of a higher level than that required for licensure and general practice.

Visit [www.abcmo.org](http://www.abcmo.org) to learn why medical facilities require board certification of specialists and why only ABCMO board certification in the specialty of medical optometry is accepted. Questions? [myers.kenj@gmail.com](mailto:myers.kenj@gmail.com).

**NOTICE:** After August 1, 2003, all applicants for ABCMO board certification must have completed an ACOE residency in medical optometry and passed the Advanced Competence in Medical Optometry examination of the NBEO.

[www.abcmo.org](http://www.abcmo.org)



Scientia est Potentia

Continuing Medical Education

**American Academy of Optometry  
New Jersey Chapter**

**13th Annual Educational Conference**

April 22-26, 2015

Myrtle Beach, South Carolina

Hilton Embassy Suites at Kingston Plantation

Dr. Mark Friedberg, M.D.

Founding Editor of the  
Wills Eye Manual

Dr. Alan Kabat, OD., F.A.A.O.

16 HOURS  
COPE CE

Registration: \$475.00

One, Two or Three Bedroom Suites

Accommodations Include a Daily Breakfast Buffet  
and Evening Cocktail Reception

**PACK YOUR CLUBS!**

Golf details to follow.

For Accommodation and Additional Information, contact:

Dennis H. Lyons, OD, F.A.A.O.

Phone: (732) 920-0110

E-Mail: [dhl2020@aol.com](mailto:dhl2020@aol.com)



In Partnership With The NJ Society of Optometric Physicians

**Danube River Cruise**

July 24 - 31, 2016

**12 CE With Ron Melton, O.D., F.A.A.O.**

Deluxe Ship

Special Group Pricing



All Programs Are in Partnership  
With the New Jersey Society of  
Optometric Physicians



Dr. TRAVEL, LLC  
is a COPE approved provider

Celebrating 20 years

Continuing Education

Sailing From Budapest to:

Bratislava, Vienna, Durstein, Melk/Emmersdorf, Liz, Regensburg, Passau

Additional Seminar Cruises (12-16 CE):

Northern European Capitals - June 26 - July 5, 2015 - Randall Thomas, OD, NPOL, F.A.A.O.

Alaska Glacier Bay Cruise - July 26 - Aug. 2, 2015 - D. Shechtman, OD

Christmas New Year's Week Cruise - NCL Sprit - Dec. 26, 2015 - Jan. 2, 2016

President's Week - Royal Caribbean's Oasis of the Seas - Feb 13 - 20, 2016

[www.DrTravel.com](http://www.DrTravel.com)

800-436-1028

**OCULAR SYMPOSIUM**

Lectures in Ocular Diagnosis and Treatment

Formal Lectures for Optometrists  
by Noted Subspecialists in Ophthalmology

Friday, Saturday, Sunday, June 5-7, 2015

24 hours CE credits (8 hours each day)

SAN FRANCISCO, CALIFORNIA

TOPICS TO INCLUDE

- |                     |               |                   |
|---------------------|---------------|-------------------|
| Refractive Surgery  | Glaucoma      | Cataract Surgery  |
| Oculoplastics       | Ocular Trauma | Ocular Oncology   |
| Neuro-Ophthalmology | Retina, OCT   | Ocular Pediatrics |

For information call or write:

Ocular Symposium • P.O. Box 640327 • San Francisco • CA • 94164

(415) 278-9940 • FAX (415) 345-1165

e-mail: [ocularsymp@aol.com](mailto:ocularsymp@aol.com)

**REVIEW**  
OF OPTOMETRY

**Do you have  
CE Programs?**

CONTACT US TODAY  
FOR CLASSIFIED ADVERTISING

Toll free: 888-498-1460

E-mail: [sales@kerhgroup.com](mailto:sales@kerhgroup.com)

Do you have Equipment  
and Supplies for Sale?

**REVIEW**  
OF OPTOMETRY

Contact us today for classified advertising:

Toll free: 888-498-1460 • E-mail: [sales@kerhgroup.com](mailto:sales@kerhgroup.com)

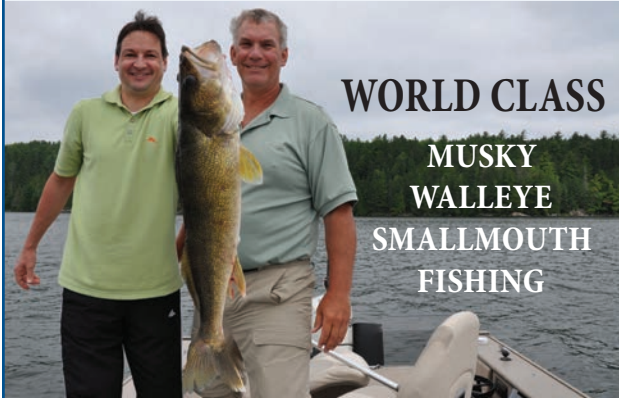**Continuing Education**

**EAGLE EYE SEMINARS**

JULY 18-25, 2015      JULY 16-23, 2016

Erik Schmidt OD, FAAO      Nathan Lighthizer OD, FAAO

**2013 Speaker Dr. Paul Kerpecki**



**WORLD CLASS  
MUSKY  
WALLEYE  
SMALLMOUTH  
FISHING**

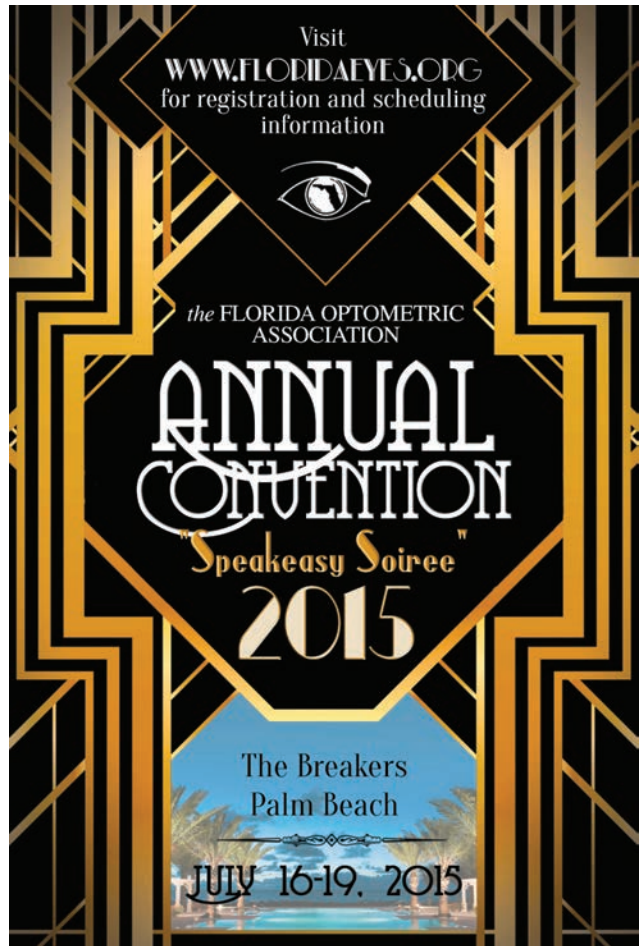
- Eagle Lake Island lodge
- Eagle Lake Ontario
- 12 hours of CE

**Contact Dean Springer OD**

[SPRINGEREYE@CHIBARDUN.NET](mailto:SPRINGEREYE@CHIBARDUN.NET)

**Phone: 715-637-2020**

**Conference**



**Products and Services**

**ACCESS**  
HEALTHCARE CAPITAL

The key to making Professional Healthcare Practice Financing simple. Whether you are buying, starting, or updating your practice, Access Healthcare capital is here to help you with your financing needs with one common goal. We want to help you maximize your cash flow. Let us help you unleash your Entrepreneurial Spirit:

**Easy App Up To \$250,000**

- 100% Financing plus working capital
- Simplified Processing for loans up to \$350,000
- Partnership Buy-In Programs
- Terms up to 15 years
- Application Only for equipment and technology purchases

[www.accesshealthcarecapital.com](http://www.accesshealthcarecapital.com) • [info@narxeye.com](mailto:info@narxeye.com)

Access Healthcare Capital • 1-888-727-4470 • P.O. Box 349, Gladwyne, PA 19035

**Become Board Certified by the American Board of Optometry**

Exam is held each January & July.

Apply today at

[americanboardofoptometry.org](http://americanboardofoptometry.org)



Program certified by the National Commission for Certifying Agencies

**REVIEW**  
OF OPTOMETRY

Do you have Products and Services to offer?

**PLACE YOUR AD HERE**

Contact us today for classified advertising:

Toll free: 888-498-1460 • E-mail: [sales@kerhgroup.com](mailto:sales@kerhgroup.com)





**Practice For Sale**



Practice Sales • Appraisals • Consulting  
[www.PracticeConsultants.com](http://www.PracticeConsultants.com)

**PRACTICES FOR SALE  
 NATIONWIDE**

Visit us on the Web or call us to learn more about our company and the practices we have available.  
[info@PracticeConsultants.com](mailto:info@PracticeConsultants.com)  
**800-576-6935**  
[www.PracticeConsultants.com](http://www.PracticeConsultants.com)

**OPTOMETRIC PRACTICE FOR SALE  
 NORTHEASTERN PA**

Very Successful ongoing optometric practice for sale in Northeastern PA. The practice is grossing 600K/yr. This practice is one of a kind with a very large and broad patient base and large contact lens base. The practice services many vision care programs that lends to its success, along with a full complement of direct paying patients. I will be willing to work in the practice.

*Serious replies only.*

Email: [resume6@kerhgroup.com](mailto:resume6@kerhgroup.com)  
 WITH COMPLETE NAME AND CONTACT INFO

**PRACTICE SALES  
 & APPRAISAL**

Expert Services for:

- ✓ **Buying or Selling a Practice**
- ✓ **Practice Appraisal**
- ✓ **Practice Financing**
- ✓ **Partner Buy-in or Buy-out**

Call for a Free Consultation  
**(800) 416-2055**  
[www.TransitionConsultants.com](http://www.TransitionConsultants.com)

Contact us today for classified advertising:  
 Toll free: **888-498-1460**  
 E-mail: [sales@kerhgroup.com](mailto:sales@kerhgroup.com)

**Professional Opportunities**

*Here we grow again!*

**TWO MOTIVATED OPTOMETRISTS  
 ILLINOIS**

One of the largest eye care providers to extended care and assisted living residents in our great state of Illinois needs two motivated Optometrists to join our practice!

Both positions are in the Springfield and Central Illinois areas. One position is full time and one position is part time.

Our physicians are proficient in refracting, diagnosing & treating ocular pathology, and dispensing spectacles on-site. If you are proficient in these areas and you are comfortable driving, here are your benefits: Excellent Pay + bonuses (=145K+), travel bonuses that will exceed expenses incurred, new optical equipment, a personal assistant, but most important helping people in need of our professional services.


**Interested? Contact Michael at  
[Michael@ovitskyvisioncare.com](mailto:Michael@ovitskyvisioncare.com)  
 or at 773-588-3090.**

*Only serious inquiries please. We will help with relocation expenses, if necessary.*

**STAFF OPTOMETRIST**

Bard Optical is a leading Midwest vision care organization in business for over 70 years and we are still growing. The company is based in Peoria, IL with 20 retail offices throughout the central Illinois area, as far north as Sterling and as far south as Jacksonville. Once again this year we were named to the Top 50 Optical Retailers in the United States by Vision Monday – currently ranking 37th. A progressive optometric staff is vital to the continued growth of our organization whose foundation is based on one-on-one patient service. We are currently accepting CV/resumes for optometrists focused on full scope primary medical patient care. The candidate must have an Illinois license with therapeutics. The practice includes (but is not limited to) general optometry, contact lenses, and geriatric care. Salaried, full-time positions are available with excellent growth programs and benefits. Some part-time opportunities may be available also. Please email your information to [hr@bardoptical.com](mailto:hr@bardoptical.com) or fax to 309-693-9754. Mailing address if more convenient is Bard Optical, Attn: HR, 8309 N Knoxville Avenue, Peoria, IL 61615. Ask about opportunities within Bard Optical. We have openings in several existing and new offices opening soon in central Illinois.

Bard Optical is a proud Associate Member of the Illinois Optometric Association.



[www.bardoptical.com](http://www.bardoptical.com)

**Equipment and Supplies**

**SOFT CONTACTS • SOFT PRICES**

*Bradford Optical, Inc.*

**800.435.5535**

[www.BradfordOpticalInc.com](http://www.BradfordOpticalInc.com)

**REVIEW  
 OF OPTOMETRY**

**Do You Have  
 Positions Available?**  
**PLACE YOUR AD HERE**

Contact us today for classified advertising:  
 Toll free: **888-498-1460**  
 E-mail: [sales@kerhgroup.com](mailto:sales@kerhgroup.com)





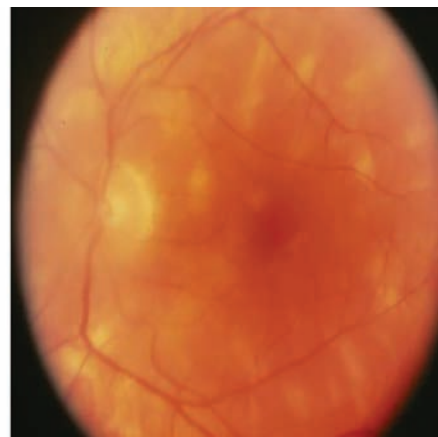
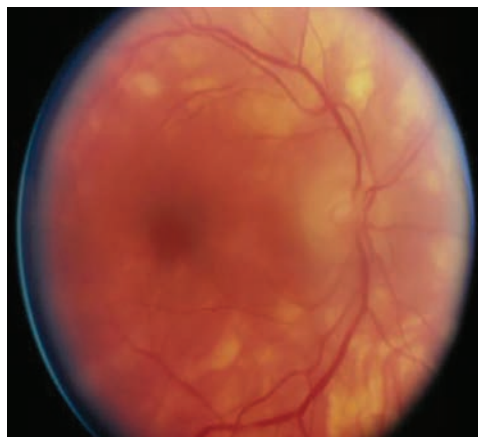# Salt and Pepper Fundus?

By Andrew S. Gurwood, OD

## History

A 37-year-old female presented to the office with a chief complaint of blurry vision at near. Her systemic history was remarkable for arrhythmia and hypertension for which she was properly medicated. She had no known allergies.

Her last eye exam was estimated at being seven years ago with no reported abnormalities or unusual diagnoses.



**Fundus photographs of a 37-year-old female with a chief complaint of blurry vision at near. What follow up questions might you consider based on these findings?**

## Diagnostic Data

The patient's best-corrected acuity was 20/20 OU at distance and 20/25 OU at near. Her external examination was normal and there was no afferent pupillary defect.

Refraction uncovered mild hyperopia measuring 0.50 DS. The cornea and internal ocular

health examination was normal, OU. Goldmann intraocular pressures measured 14mm Hg, both eyes. The pertinent dilated fundus findings are demonstrated in the photograph.

## Your Diagnosis

How would you approach this case? Does this case require any

additional tests? What is your diagnosis? How would you manage this patient? What's the likely prognosis?

To find out, please visit *Review of Optometry* online at [www.reviewofoptometry.com](http://www.reviewofoptometry.com). Click on the cover icon for this month's issue and select "Diagnostic Quiz" from the table of contents. ■

**Retina Quiz Answers (from page 99):** 1) b; 2) a; 3) a; 4) c.

## Next Month in the Mag

April's is *Review of Optometry's* "Corneal Disease Report" issue.

Topics include:

- *Corneal Harbingers of Systemic Disease* (earn 2 CE credits)
- *Slit Lamp Essentials: Anterior Stromal Puncture*

- *Comprehensive Evaluation and Management of Keratoconus/Ectasia*
- *Corneal Complications of Ocular Rosacea*
- *10 Tips for Obtaining Better Visual Fields*
- *Overcome These Real-World Prescribing Challenges*

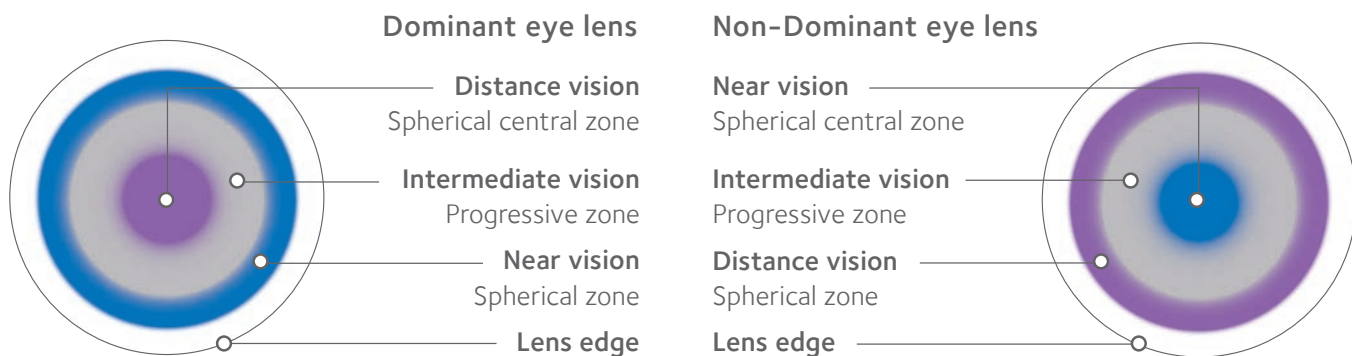
REVIEW OF OPTOMETRY (ISSN 0147-7633) IS PUBLISHED MONTHLY, 12 TIMES A YEAR BY JOBSON MEDICAL INFORMATION LLC, 100 AVENUE OF THE AMERICAS, NEW YORK, NY 10013-1678. PERIODICALS POSTAGE PAID AT NEW YORK, NY AND ADDITIONAL MAILING OFFICES. POSTMASTER: SEND ADDRESS CHANGES TO REVIEW OF OPTOMETRY, PO BOX 81, CONGERS, NY 10920-0081. SUBSCRIPTION PRICES: US: ONE YEAR \$56; TWO YEARS \$97, CANADA: ONE YEAR \$88, TWO YEARS \$160, INT'L: ONE YEAR \$209, TWO YEARS \$299. FOR SUBSCRIPTION INFORMATION CALL TOLL-FREE (877) 529-1746 (USA); OUTSIDE USA, CALL (845) 267-3065. OR EMAIL US AT REVOPOTOMETRY@CAMBEYWEST.COM. PUBLICATIONS MAIL AGREEMENT NO: 40612608. CANADA RETURNS TO BE SENT TO BLEUCHIP INTERNATIONAL, P.O. BOX 25542, LONDON, ON N6C 6B2.

# An easy fit for you and your presbyopic patients.

CooperVision Biofinity® multifocal lenses combine a high-performing 3rd generation material with a streamlined fitting process. Now even your most challenging presbyopic patients can enjoy the freedom of **all-distance clarity and lasting comfort.**



**Balanced Progressive™ Technology** enhances vision near, far and intermediate. It also allows for an individualized fitting for each wearer and each eye.



Biofinity & Biofinity XR    Biofinity toric    **Biofinity multifocal**

Download your Biofinity multifocal 3-step fitting guide at [coopervision.com/fitting-guide](http://coopervision.com/fitting-guide)



PERMANENT PLASMA  
SURFACE TECHNOLOGY

# THIS IS WHY the smallest details make the biggest difference in patients' comfort.

AIR OPTIX® AQUA contact lenses feature our unique permanent plasma treatment, creating a hydrophilic layer that leaves **less than 1% surface silicon**<sup>1</sup>. Less exposed silicone helps to resist lipid deposits, which can impact comfort. Now your patients can experience **consistent comfort**.<sup>2</sup>

## Permanent Plasma Surface Technology



Ask your sales representative about AIR OPTIX® family of contact lenses or visit [MYALCON.COM](http://MYALCON.COM)

PERFORMANCE DRIVEN BY SCIENCE™



\*AIR OPTIX® AQUA (lotrafilcon B) and AIR OPTIX® AQUA Multifocal (lotrafilcon B) contact lenses: Dk/t = 138 @ -3.00D. AIR OPTIX® NIGHT & DAY® AQUA (lotrafilcon A) contact lenses: Dk/t = 175 @ -3.00D. AIR OPTIX® for Astigmatism (lotrafilcon B) contact lenses: Dk/t = 108 @ -3.00D -1.25 x 180.

**Important information for AIR OPTIX® AQUA (lotrafilcon B), AIR OPTIX® AQUA Multifocal (lotrafilcon B) and AIR OPTIX® for Astigmatism (lotrafilcon B) contact lenses:** For daily wear or extended wear up to 6 nights for near/far-sightedness, presbyopia and/or astigmatism. Risk of serious eye problems (i.e., corneal ulcer) is greater for extended wear. In rare cases, loss of vision may result. Side effects like discomfort, mild burning or stinging may occur.

**Important information for AIR OPTIX® NIGHT & DAY® AQUA (lotrafilcon A) contact lenses:** Indicated for vision correction for daily wear (worn only while awake) or extended wear (worn while awake and asleep) for up to 30 nights. **Relevant Warnings:** A corneal ulcer may develop rapidly and cause eye pain, redness or blurry vision as it progresses. If left untreated, a scar, and in rare cases loss of vision, may result. The risk of serious problems is greater for extended wear vs. daily wear and smoking increases this risk. A one-year post-market study found 0.18% (18 out of 10,000) of wearers developed a severe corneal infection, with 0.04% (4 out of 10,000) of wearers experiencing a permanent reduction in vision by two or more rows of letters on an eye chart. **Relevant Precautions:** Not everyone can wear for 30 nights. Approximately 80% of wearers can wear the lenses for extended wear. About two-thirds of wearers achieve the full 30 nights continuous wear. **Side Effects:** In clinical trials, approximately 3-5% of wearers experience at least one episode of infiltrative keratitis, a localized inflammation of the cornea which may be accompanied by mild to severe pain and may require the use of antibiotic eye drops for up to one week. Other less serious side effects were conjunctivitis, lid irritation or lens discomfort including dryness, mild burning or stinging. **Contraindications:** Contact lenses should not be worn if you have: eye infection or inflammation (redness and/or swelling); eye disease, injury or dryness that interferes with contact lens wear; systemic disease that may be affected by or impact lens wear; certain allergic conditions or using certain medications (ex. some eye medications). **Additional Information:** Lenses should be replaced every month. If removed before then, lenses should be cleaned and disinfected before wearing again. Always follow the eye care professional's recommended lens wear, care and replacement schedule. Consult package insert for complete information, available without charge by calling (800) 241-5999 or go to [myalcon.com](http://myalcon.com).

**References:** 1. Alcon data on file, 2011. 2. Eiden SB, Davis R, Bergenske P. Prospective study of lotrafilcon B lenses comparing 2 week versus 4 weeks of wear for objective and subjective measures of health, comfort and vision. Eye & Contact Lenses. 2013; 39(4):290-294.

See product instructions for complete wear, care, and safety information. © 2014 Novartis 10/14 AOA14005JAD-A

**Alcon**  
a Novartis company

Rx only