

Earn 2 CE Credits—Evaluating the Efferent Visual System, Page 74

# REVIEW<sup>®</sup> OF OPTOMETRY

February 15, 2015

www.reviewofoptometry.com

INNOVATION IN EYE CARE

## TOPICAL AMD THERAPY:

WILL IT MAKE A SPLASH?

PAGE 40

» DOES GLAUCOMA BEGIN  
IN THE BRAIN?, PAGE 32

» INNOVATIONS IN CONTACT  
LENS MATERIALS, PAGE 46

» ACADEMY UPDATE: DRY  
EYE RESEARCH, PAGE 54

» PLUS: HOW TO INSERT AND REMOVE AN AMNIOTIC MEMBRANE GRAFT, PAGE 60  
—Includes video tutorial online!

INSIDE — FREE CE CREDIT  
2014 EAST COAST OPTOMETRIC GLAUCOMA  
SYMPOSIUM HIGHLIGHTS, PAGE 84

# Exceptional all-day lens wear, every day, *for every eye*

## UNSURPASSED COMFORT

Clinically unsurpassed in overall comfort and rated superior to Dailies<sup>®</sup> AquaComfort Plus<sup>®</sup> in beginning to end-of-day comfort

## EXCELLENT SAFETY PROFILE<sup>1¶</sup>

Confirmed in an unprecedented, year-long, observational study of 570 wearers—no other lens has published this kind of safety data, including Dailies<sup>®</sup> AquaComfort Plus<sup>®</sup>

## UV PROTECTION<sup>†</sup>

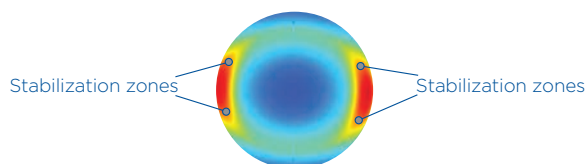
Blocks approximately 97% UVB & 82% UVA rays.<sup>†</sup> Dailies<sup>®</sup> AquaComfort Plus<sup>®</sup> does not meet ANSI/ISO standards for UV blocking

## 1-DAY ACUVUE<sup>®</sup> MOIST<sup>®</sup> Brand Contact Lenses for ASTIGMATISM

### SAME COMFORT, SAFETY, AND UV PROTECTION WITH ENHANCED STABILITY

- BLINK STABILIZED™ Design creates equal/opposite forces to limit rotation and better stabilize vision
- Nearly 200 more parameters than Dailies<sup>®</sup> AquaComfort Plus<sup>®</sup> Toric Lenses<sup>||</sup>

REALIGNS WITH EVERY BLINK





ANSI=American National Standards Institute; ISO=International Organization for Standardization.

ACUVUE® Brand Contact Lenses are indicated for vision correction. As with any contact lens, eye problems, including corneal ulcers, can develop. Some wearers may experience mild irritation, itching or discomfort. Lenses should not be prescribed if patients have any eye infection, or experience eye discomfort, excessive tearing, vision changes, redness or other eye problems. Consult the package insert for complete information. Complete information is also available from VISTAKON® Division of Johnson & Johnson Vision Care, Inc., by calling 1-800-843-2020 or by visiting [acuvueprofessional.com](http://acuvueprofessional.com).

<sup>†</sup>Helps protect against transmission of harmful UV radiation to the cornea and into the eye.

**WARNING:** UV-absorbing contact lenses are NOT substitutes for protective UV-absorbing eyewear such as UV-absorbing goggles or sunglasses, because they do not completely cover the eye and surrounding area. You should continue to use UV-absorbing eyewear as directed. **NOTE:** Long-term exposure to UV radiation is one of the risk factors associated with cataracts. Exposure is based on a number of factors such as environmental conditions (altitude, geography, cloud cover) and personal factors (extent and nature of outdoor activities). UV-blocking contact lenses help provide protection against harmful UV radiation. However, clinical studies have not been done to demonstrate that wearing UV-blocking contact lenses reduces the risk of developing cataracts or other eye disorders. Consult your eye care practitioner for more information.

<sup>‡</sup>UV-blocking percentages are based on an average across the wavelength spectrum.

<sup>§</sup>This observational/surveillance registry relied on patient reports of symptomatic adverse events that led them to seek clinical care. These results should be considered in conjunction with other clinical results on the safety and efficacy of daily disposable etafilcon A contact lenses, which also generally show low rates of such events. Although no symptomatic infiltrative events were reported in this study, such events can occur with daily disposable lenses, including 1-DAY ACUVUE® MOIST®, as noted in the product labeling.

<sup>||</sup>Based on *Tyler's Quarterly Soft Contact Lens Parameter Guide*; June 2014.

**1.** Chalmers RL, Hickson-Curran SB, Keay LJ, Gleason W. Safety of hydrogel and silicone hydrogel daily disposables in a large post-market surveillance registry—the TEMPO registry. Presented at: ARVO 2014 Annual Meeting; May 4-8, 2014; Orlando, FL.

The third party trademarks used herein are trademarks of their respective owners.

ACUVUE®, 1-DAY ACUVUE® MOIST®, BLINK STABILIZED™, and VISTAKON® are trademarks of Johnson & Johnson Vision Care, Inc.

© Johnson & Johnson Vision Care, Inc. 2014 ACU-A44519 November 2014



## IN THE NEWS

Optometry mourns the loss of **Robert J. Morrison, OD**, a pioneer of soft contact lenses and “the eye doctor of the rich and famous,” who died January 7 at the age of 90.



In the early 1960s, Dr. Morrison became aware of the work by Czech chemist Otto Wichterle on the **hydrophilic polymer HEMA**. He traveled to the former Czechoslovakia to apply this material in the development of a soft contact lens. Dr. Morrison became a co-patent holder in the Western hemisphere for this technology. The patent was sold to **Bausch + Lomb**, which launched the original **Soflens** in 1971. Dr. Morrison’s expertise in contact lenses brought an international clientele to his practice in Harrisburg, Pa., from celebrities in Hollywood to royal families throughout Europe—he once received a Rolls Royce from Queen Juliana of the Netherlands as payment for his services. In 1993, Morrison launched **Morr-Sight**, a mobile clinic for providing free eyewear to deserving people around the world. In 1995, he founded **eyeglass.com**, an online eyewear retailer.

**University of Central Arkansas** will begin a feasibility study to assess the possibility of a **new school of optometry** on its campus. A consulting group will provide an analysis of the pros and cons of developing a school of optometry at UCA. The study is scheduled to be completed by May 31.

# Calcium Deposits in Drusen May Signal AMD

This advance could help clinicians diagnose AMD a decade earlier. **By John Murphy, Executive Editor**

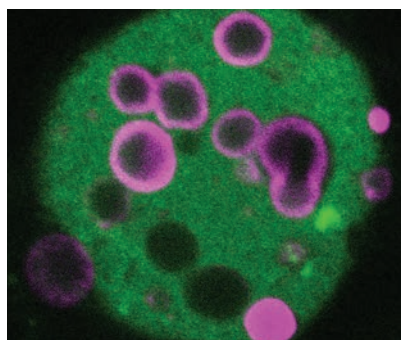


Image: Imre Lengyel, PhD

**Thousands of hydroxyapatite spheres (in magenta), each just a few microns across, are found in large drusen deposits within the eye.**

**T**iny calcium-based hydroxyapatite, commonly found in bones and teeth, could explain the origin of drusen, according to a new study published in *Proceedings of the National Academy of Sciences*. This not only offers a possible explanation for how age-related macular degeneration develops, but also opens up new ways to diagnose and treat the disease, the researchers say.

Through postmortem examination of 30 eyes from donors between 43 and 96 years old, the researchers used fluorescent dyes to identify the tiny spheres, each just a few microns across. The researchers believe that these calcium-based spheres attract proteins and fats to their surface, which build up over years to form drusen.

“We found these miniscule hollow spheres inside all of the eyes and all the deposits that we examined, from donors with and without AMD,” explains study leader Imre Lengyel, PhD, senior

research fellow at University College of London’s Institute of Ophthalmology. “Eyes with more of these spheres contained more drusen. The spheres appear long before drusen become visible on clinical examination.”

Whether these spheres are a cause or a symptom of AMD is still unclear, but their diagnostic value is significant, the researchers say. As drusen are hallmarks of AMD, strategies to prevent buildup could potentially stop AMD from developing altogether.

“The dyes that we used should be compatible with existing diagnostic machines,” Dr. Lengyel says. “If we could develop a safe way of getting these dyes into the eye, we could advance AMD diagnoses by a decade or more and could follow early progression more precisely.”

The researchers also found that some of the spheres were coated with amyloid beta, which is linked to Alzheimer’s disease. If a technique were developed to identify these spheres for AMD diagnosis, they predict it could also aid early diagnosis of Alzheimer’s.

Thompson RB, Reffatto V, Bundy JG, et al. Identification of hydroxyapatite spherules provides new insight into subretinal pigment epithelial deposit formation in the aging eye. *Proc Natl Acad Sci USA*. 2015 Jan 20. [Epub ahead of print.]





# SYMPTOMATIC VITREOMACULAR ADHESION (VMA)

SYMPTOMATIC VMA MAY LEAD TO VISUAL IMPAIRMENT FOR YOUR PATIENTS<sup>1-3</sup>

## IDENTIFY

Recognize metamorphopsia as a key sign of symptomatic VMA and utilize OCT scans to confirm vitreomacular traction.

## REFER

Because symptomatic VMA is a progressive condition that may lead to a loss of vision, your partnering retina specialist can determine if treatment is necessary.<sup>1-3</sup>

THE STEPS YOU TAKE TODAY MAY MAKE A DIFFERENCE  
FOR YOUR PATIENTS TOMORROW

 ThromboGenics®

© 2014 ThromboGenics, Inc. All rights reserved. ThromboGenics, Inc., 101 Wood Avenue South, Suite 610, Iselin, NJ 08830 – USA. THROMBOGENICS and the THROMBOGENICS logo are trademarks or registered trademarks of ThromboGenics NV. 10/14 OCRVMA0220

**References:** 1. Sonmez K, Capone A, Trese M, et al. Vitreomacular traction syndrome: impact of anatomical configuration on anatomical and visual outcomes. *Retina*. 2008;28:1207-1214. 2. Hikichi T, Yoshida A, Trempe CL. Course of vitreomacular traction syndrome. *Am J Ophthalmol*. 1995;119(1):55-56. 3. Stalmans P, Lescauwaet B, Blot K. A retrospective cohort study in patients with diseases of the vitreomacular interface (ReCoVit). Poster presented at: The Association for Research in Vision and Ophthalmology (ARVO) 2014 Annual Meeting; May 4-8, 2014; Orlando, Florida.

# Challenge to ACA Threatens Children's Access to Vision Coverage

By Richard Mark Kirkner, Contributing Writer

The Affordable Care Act (ACA) requires vision coverage for all children, but that could change next month when the Supreme Court hears arguments in *King v. Burwell*, a case that challenges the legality of a key component of the law: tax credits to people who purchase health insurance on the federal exchange.

A Supreme Court ruling against the tax credits (expected by July 4) could set off what the Rand Corporation called a “death spiral” for the law. Major overhaul of the ACA—if not outright repeal—becomes all the more likely, according to Jeff Anderson, executive director of the 2017 Project, a

think tank promoting a conservative alternative to the act.

“The politics here are going to be exceedingly volatile,” says Nicholas Bagley, a University of Michigan law professor who’s written frequently about the legal machinations of the ACA.

Dismantling the law could mean a “huge mess” for vision care coverage of children in lower- to middle-income families, says

Julian Roberts, executive director of the National Association of Vision Care Plans (NAVCP).

Another potential fallout from a ruling against the ACA: the revival of an argument in eye care between vision plans and the AOA (and American Academy of Ophthalmology). These groups have differed on how people should be able to purchase children’s vision

*“Do more children have vision care due to the exchanges? Probably so. The issue is whether they’re utilizing it.”*

coverage on the state and federal exchanges. Physicians’ groups prevailed in getting language into the ACA that limits the exchanges to only sell vision plans that are bundled with health insurance, while Vision Service Plan (VSP) and the NAVCP sought to let the exchanges sell vision coverage separately from health insurance—so-called stand-alone vision plans.

## ACA’s Impact on Eye Care

As the second year of mandated coverage begins, the impact the ACA has had on optometric office visits is still in question. No data have quantified how many more children gained vision coverage.

“Do more children have vision care due to the exchanges? Probably so,” Mr. Roberts says. “The issue is whether they’re utilizing it.”

AOA President-elect Steven A. Loomis, OD, says early evidence shows that they are. “Optometrists

*Continued on page 8*

## Optometry Office Gets ‘Drive-Thru’ Window



A driver pulled her SUV into the wrong lane, swerved to avoid oncoming traffic and collided with three parked vehicles—two of which belonged to employees of Vision Quest Eye Clinic, in Hammond, Ind. The impact was so great that it launched one of those vehicles through the front window of the office, says the practice’s owner Alexander Kouklakis, OD.

Fortunately, nobody was injured, according to another doctor at the practice, Megan Mosely, OD, who managed to snap this picture of the damage.



For patients with decreased tear production presumed to be due to  
ocular inflammation associated with Chronic Dry Eye

## THE DRY EYE TREATMENT SHE NEEDS TODAY. BECAUSE TOMORROW MATTERS.



### RESTASIS® twice a day, every day, helps patients experience increased tear production

Increased tear production was seen at 6 months.<sup>1</sup>

#### Indication and Usage

RESTASIS® (cyclosporine ophthalmic emulsion) 0.05% is indicated to increase tear production in patients whose tear production is presumed to be suppressed due to ocular inflammation associated with keratoconjunctivitis sicca. Increased tear production was not seen in patients currently taking topical anti-inflammatory drugs or using punctal plugs.

#### Important Safety Information

##### Contraindications

RESTASIS® is contraindicated in patients with known or suspected hypersensitivity to any of the ingredients in the formulation.

##### Warnings and Precautions

**Potential for Eye Injury and Contamination:** To avoid the potential for eye injury and contamination, individuals prescribed RESTASIS® should not touch the vial tip to their eye or other surfaces.

**Use With Contact Lenses:** RESTASIS® should not be administered while wearing contact lenses. If contact lenses are worn, they should be removed prior to the administration of the emulsion.

##### Adverse Reactions

In clinical trials, the most common adverse reaction following the use of RESTASIS® was ocular burning (upon instillation)—17%. Other reactions reported in 1% to 5% of patients included conjunctival hyperemia, discharge, epiphora, eye pain, foreign body sensation, pruritus, stinging, and visual disturbance (most often blurring).

**Please see Brief Summary of the full Prescribing Information on adjacent page.**

Reference: 1. RESTASIS® Prescribing Information.



©2014 Allergan, Inc., Irvine, CA 92612  
® marks owned by Allergan, Inc.  
APC20AF14 141005



# Children's Vision Access Under Threat

(Continued from page 6)

will continue to see a boost from the ACA's pediatric benefit," said Dr. Loomis in an email. "Many ODs have seen an uptick in pediatric patients." How many depends on how far along a state is with ACA implementation, he noted.

Vision Council's 2014 Economic Situation Study, released last May, reported the ACA "had not had too much of an immediate impact" on the optical industry, and its long-term impact on the eyewear industry was "in doubt."

Back when the ACA was being drafted, the vision carriers had warned that bundling vision plans with health insurance for children would result in a lack of awareness about eye exams. Last year, the AOA's American Eye-Q Survey found that two-thirds of people surveyed did not know ACA covered children's eye examinations.

Dr. Loomis pointed to two key ACA components that should drive more patients into optometrists' offices: any-willing-provider provisions, known as the Harkin law, which prompted Ford Motor Corporation to include optometry in its coverage for medical eye care; and incentives for accountable care organizations (ACOs, which are provider panels that coordinate care for selected groups of Medicare patients) to seek out optometrists to join their networks. "The AOA views ACOs as a model of care ODs should learn more about," Dr. Loomis said.

That is, if all those pieces of the ACA survive the year.

## RESTASIS® (Cyclosporine Ophthalmic Emulsion) 0.05%

**BRIEF SUMMARY—PLEASE SEE THE RESTASIS® PACKAGE INSERT FOR FULL PRESCRIBING INFORMATION.**

### INDICATION AND USAGE

RESTASIS® ophthalmic emulsion is indicated to increase tear production in patients whose tear production is presumed to be suppressed due to ocular inflammation associated with keratoconjunctivitis sicca. Increased tear production was not seen in patients currently taking topical anti-inflammatory drugs or using punctal plugs.

### CONTRAINDICATIONS

RESTASIS® is contraindicated in patients with known or suspected hypersensitivity to any of the ingredients in the formulation.

### WARNINGS AND PRECAUTIONS

#### Potential for Eye Injury and Contamination

To avoid the potential for eye injury and contamination, be careful not to touch the vial tip to your eye or other surfaces.

#### Use with Contact Lenses

RESTASIS® should not be administered while wearing contact lenses. Patients with decreased tear production typically should not wear contact lenses. If contact lenses are worn, they should be removed prior to the administration of the emulsion. Lenses may be reinserted 15 minutes following administration of RESTASIS® ophthalmic emulsion.

### ADVERSE REACTIONS

#### Clinical Trials Experience

Because clinical trials are conducted under widely varying conditions, adverse reaction rates observed in the clinical trials of a drug cannot be directly compared to rates in the clinical trials of another drug and may not reflect the rates observed in practice.

In clinical trials, the most common adverse reaction following the use of RESTASIS® was ocular burning (17%).

Other reactions reported in 1% to 5% of patients included conjunctival hyperemia, discharge, epiphora, eye pain, foreign body sensation, pruritus, stinging, and visual disturbance (most often blurring).

#### Post-marketing Experience

The following adverse reactions have been identified during post approval use of RESTASIS®: Because these reactions are reported voluntarily from a population of uncertain size, it is not always possible to reliably estimate their frequency or establish a causal relationship to drug exposure.

Reported reactions have included: hypersensitivity (including eye swelling, urticaria, rare cases of severe angioedema, face swelling, tongue swelling, pharyngeal edema, and dyspnea); and superficial injury of the eye (from the vial tip touching the eye during administration).

### USE IN SPECIFIC POPULATIONS

#### Pregnancy

##### Teratogenic Effects: Pregnancy Category C

Adverse effects were seen in reproduction studies in rats and rabbits only at dose levels toxic to dams. At toxic doses (rats at 30 mg/kg/day and rabbits at 100 mg/kg/day), cyclosporine oral solution, USP, was embryo- and fetotoxic as indicated by increased pre- and postnatal mortality and reduced fetal weight together with related skeletal retardations. These doses are 5,000 and 32,000 times greater (normalized to body surface area), respectively, than the daily human dose of one drop (approximately 28 mcL) of 0.05% RESTASIS® twice daily into each eye of a 60 kg person (0.001 mg/kg/day), assuming that the entire dose is absorbed. No evidence of embryofetal toxicity was observed in rats or rabbits receiving cyclosporine at oral doses up to 17 mg/kg/day or 30 mg/kg/day, respectively, during organogenesis. These doses in rats and rabbits are approximately 3,000 and 10,000 times greater (normalized to body surface area), respectively, than the daily human dose.

Offspring of rats receiving a 45 mg/kg/day oral dose of cyclosporine from Day 15 of pregnancy until Day 21 postpartum, a maternally toxic level, exhibited an increase in postnatal mortality; this dose is 7,000 times greater than the daily human topical dose (0.001 mg/kg/day) normalized to body surface area assuming that the entire dose is absorbed. No adverse events were observed at oral doses up to 15 mg/kg/day (2,000 times greater than the daily human dose).

There are no adequate and well-controlled studies of RESTASIS® in pregnant women. RESTASIS® should be administered to a pregnant woman only if clearly needed.

#### Nursing Mothers

Cyclosporine is known to be excreted in human milk following systemic administration, but excretion in human milk after topical treatment has not been investigated. Although blood concentrations are undetectable after topical administration of RESTASIS® ophthalmic emulsion, caution should be exercised when RESTASIS® is administered to a nursing woman.

#### Pediatric Use

The safety and efficacy of RESTASIS® ophthalmic emulsion have not been established in pediatric patients below the age of 16.

#### Geriatric Use

No overall difference in safety or effectiveness has been observed between elderly and younger patients.

### NONCLINICAL TOXICOLOGY

#### Carcinogenesis, Mutagenesis, Impairment of Fertility

**Carcinogenesis:** Systemic carcinogenicity studies were carried out in male and female mice and rats. In the 78-week oral (diet) mouse study, at doses of 1, 4, and 16 mg/kg/day, evidence of a statistically significant trend was found for lymphocytic lymphomas in females, and the incidence of hepatocellular carcinomas in mid-dose males significantly exceeded the control value.

In the 24-month oral (diet) rat study, conducted at 0.5, 2, and 8 mg/kg/day, pancreatic islet cell adenomas significantly exceeded the control rate in the low-dose level. The hepatocellular carcinomas and pancreatic islet cell adenomas were not dose related. The low doses in mice and rats are approximately 80 times greater (normalized to body surface area) than the daily human dose of one drop (approximately 28 mcL) of 0.05% RESTASIS® twice daily into each eye of a 60 kg person (0.001 mg/kg/day), assuming that the entire dose is absorbed.

**Mutagenesis:** Cyclosporine has not been found to be mutagenic/genotoxic in the Ames Test, the V79-HGPRT Test, the micronucleus test in mice and Chinese hamsters, the chromosome-aberration tests in Chinese hamster bone-marrow, the mouse dominant lethal assay, and the DNA-repair test in sperm from treated mice. A study analyzing sister chromatid exchange (SCE) induction by cyclosporine using human lymphocytes *in vitro* gave indication of a positive effect (i.e., induction of SCE).

**Impairment of Fertility:** No impairment in fertility was demonstrated in studies in male and female rats receiving oral doses of cyclosporine up to 15 mg/kg/day (approximately 2,000 times the human daily dose of 0.001 mg/kg/day normalized to body surface area) for 9 weeks (male) and 2 weeks (female) prior to mating.

### PATIENT COUNSELING INFORMATION

#### Handling the Container

Advise patients to not allow the tip of the vial to touch the eye or any surface, as this may contaminate the emulsion. To avoid the potential for injury to the eye, advise patients to not touch the vial tip to their eye.

#### Use with Contact Lenses

RESTASIS® should not be administered while wearing contact lenses. Patients with decreased tear production typically should not wear contact lenses. Advise patients that if contact lenses are worn, they should be removed prior to the administration of the emulsion. Lenses may be reinserted 15 minutes following administration of RESTASIS® ophthalmic emulsion.

#### Administration

Advise patients that the emulsion from one individual single-use vial is to be used immediately after opening for administration to one or both eyes, and the remaining contents should be discarded immediately after administration.

#### Rx Only

 ALLERGAN

Based on package insert 71876US18

© 2014 Allergan, Inc.

Irvine, CA 92612, U.S.A.

® marks owned by Allergan, Inc. APC21XT14

Patented. See [www.allergan.com/products/patent\\_notices](http://www.allergan.com/products/patent_notices)

Made in the U.S.A.

# Show Patients How to Use Glaucoma Drops

**E**ducating glaucoma patients about how to use their drops is the only communication factor that improves adherence—yet such education occurs during only 14% of visits, according to a new study that video recorded provider-patient interactions.

“Whether physicians educated patients about how to administer their drops during visits was associated significantly with both whether patients took their drops on time and whether they took the correct number of doses each day,” wrote the authors, whose article appeared online in *Ophthalmology*. “This suggests that providers should consider taking the time to educate patients about how to administer their drops.”

Explaining how to administer drops included statements such as: telling patients to lean back their head; suggesting they use a mirror; giving them tips on how to get the drop in the eye; and telling them

how long to wait between administering two different eye drops.

Patient education of any kind about glaucoma occurred during two-thirds of the visits, but was not significantly associated with whether patients took their doses on time during the 60-day period after the visit. Also, educating glaucoma patients about side effects, adherence or the purpose of the drops didn’t significantly affect whether patients took their doses on time either.

Another significant finding: African-American patients were significantly less likely to take the prescribed number of doses each day. “This finding emphasizes the importance of providers educating black patients about ... when to take their glaucoma medications each day and how many doses to take each day,” the authors wrote. ■

Sleath B, Blalock SJ, Carpenter DM, et al. Ophthalmologist-patient communication, self-efficacy, and glaucoma medication adherence. *Ophthalmology*. 2014 Dec 24. [Epub ahead of print.]

## Dry Eye Implant Stimulates Tear Production

A company called Oculeve, which came out of the Stanford Biodesign program, has developed a tiny electronic implant that would boost tear production in dry eye patients who don’t make enough tears.




Photo: Michael Ackermann, PhD

The device is designed to deliver small electrical currents to the lacrimal nerve, which induces tear production and provides symptomatic lubrication. Investigators are testing two models of the device: One is inserted into the mucous membrane in the nasal cavity, and the other is implanted under the skin below the eyebrow.

Patients can then use a wireless controller to manually adjust the frequency of their tears.

Clinical trials of the implant are underway in Australia, New Zealand and Mexico. In the United States, Oculeve completed a Phase I trial in December 2014, but has yet to announce its results.

## REVIEW<sup>®</sup> OF OPTOMETRY

### BUSINESS OFFICES

11 CAMPUS BLVD., SUITE 100  
NEWTOWN SQUARE, PA 19073

### CEO, INFORMATION SERVICES GROUP

MARC FERRARA  
(212) 274-7062 • MFERRARA@JOBSON.COM

### PUBLISHER

JAMES HENNE  
(610) 492-1017 • JHENNE@JOBSON.COM

### REGIONAL SALES MANAGER

MICHELE BARRETT  
(610) 492-1014 • MBARRETT@JOBSON.COM

### REGIONAL SALES MANAGER

MICHAEL HOSTER  
(610) 492-1028 • MHOSTER@JOBSON.COM

### VICE PRESIDENT, OPERATIONS

CASEY FOSTER  
(610) 492-1007 • CFOSTER@JOBSON.COM

### VICE PRESIDENT, CLINICAL CONTENT

PAUL M. KARPECKI, OD, FAAO  
PKARPECKI@JOBSON.COM

### PRODUCTION MANAGER

SCOTT TOBIN  
(610) 492-1011 • STOBIN@JOBSON.COM

### SENIOR CIRCULATION MANAGER

HAMILTON MAHER  
(212) 219-7870 • HMAHER@JHIHEALTH.COM

### CLASSIFIED ADVERTISING

(888) 498-1460

### SUBSCRIPTIONS

\$56 A YEAR, \$88 (US) IN CANADA,  
\$209 (US) IN ALL OTHER COUNTRIES.

### SUBSCRIPTION INQUIRIES

(877) 529-1746 (US ONLY);  
OUTSIDE US, CALL (847) 763-9630

### CIRCULATION

PO Box 2025  
SKOKIE, IL 60076  
TEL: (TOLL FREE) 1-877-529-1746  
OUTSIDE US: (847)763-9630  
FAX: (847)763-9631



### CEO, INFORMATION SERVICES GROUP

MARC FERRARA

### SENIOR VICE PRESIDENT, OPERATIONS

JEFF LEVITZ

### SENIOR VICE PRESIDENT, HUMAN RESOURCES

LORRAINE ORLANDO

### VICE PRESIDENT, CREATIVE SERVICES & PRODUCTION

MONICA TETTAMANZI

### VICE PRESIDENT, CIRCULATION

EMELDA BAREA



*Exclusive Optical Shop Distribution*  
**The New Non-Rx, 1st Step to Longer, Lusher,  
 Fuller Looking Lashes and Brows**

#1 Recommended Among Eyecare Professionals



**2** **Special LASH ADVANCE offers — Choose 1 or Both:**

**PROFESSIONAL COURTESY PRICING OFFER :**

provides you and your staff an opportunity to try new Lash Advance at a very low price (just \$10 + S & H — 80% off the regular retail price). Visit [www.mediniche.com/LAprofessionalpricing.html](http://www.mediniche.com/LAprofessionalpricing.html) or call MediNiche at 1-888-325-2395 for more details.

**TRY IT!**

Introduced exclusively for eyecare professionals, new LASH ADVANCE® is a non-prescription cosmeceutical developed in conjunction with a female optometrist as a sensible start to healthier lashes and brows. LASH ADVANCE is suggested for use prior to expensive prescription products.

- Natural; no drugs or known sensitizers.
- Contains PeptiPlex®, advanced peptide complex, supports the growth cycle of lashes and brows.
- Unlike other lash products, not sold at major drug and food retailers.
- Easy application; will not run, clear gel absorbs with no residue.
- Reasonably priced; affordable.

**INTRODUCTORY PURCHASE OFFER :**

buy a dozen (12) packages of Lash Advance at the regular wholesale price of \$24/package and receive a 25% discount, two (2) free packages, free shipping, a free counter display, customer/staff materials and more. Visit [www.mediniche.com/lashadvanceoffer.html](http://www.mediniche.com/lashadvanceoffer.html) or call MediNiche at 1-888-325-2395 for more details.

**BUY IT!**



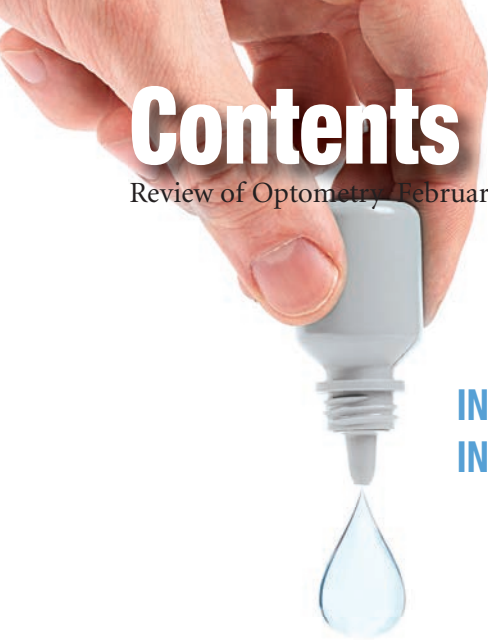**Positive RESULTS with one tube of use!**





# Contents

Review of Optometry February 2015



**INNOVATION  
IN EYE CARE**

## 32 Does Glaucoma Begin in the Brain?

Research links the disease to several neurodegenerative conditions, including Alzheimer's. Should our glaucoma evaluation go beyond the optic nerve?

**By Andrew Rixon, OD, and Andrew Gurwood, OD**

## 40 Topical AMD Therapy: Will it Make a Splash?

The new agent squalamine looks to improve outcomes—and could potentially expand the OD's role.

**By Robert Murphy, Contributing Writer**

## 46 Current Innovations in Contact Lens Materials

Today's contact lenses are better than ever—but there's still room for improvement. Here's an update on research to make them more useful and more comfortable.

**By Sruthi Srinivasan, PhD, BSOptom, and Lakshman N. Subbaraman, PhD, MSc, BSOptom**

## 54 Academy Update: Dry Eye Research

If you're trying to keep up with what's new in dry eye, a wealth of new information came out at the 2014 American Academy of Optometry meeting in Denver.

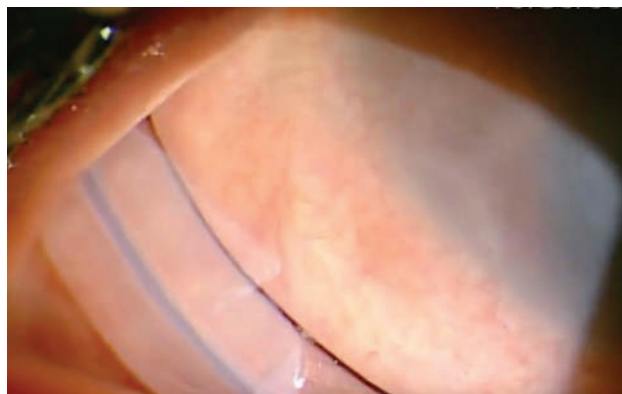
**By Barbara Caffery, OD, PhD**

Essential Procedures at the Slit Lamp:

## 60 How to Insert and Remove an Amniotic Membrane Graft

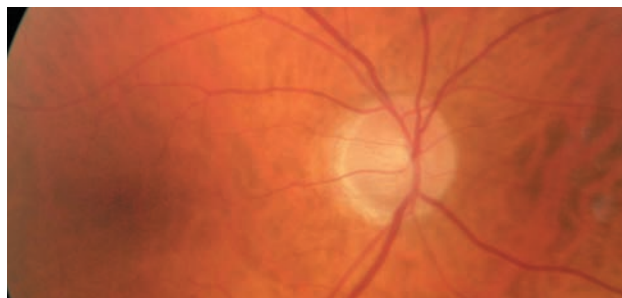
For a variety of corneal insults, amniotic membrane devices can speed healing, reduce scarring and improve comfort. Here's how to apply one.

**By Kyle Ryff, OD, Brianna Ryff, OD, and Nathan Lighthizer, OD**



## 72 SECO preview: Be a Visionary at SECO 2015

For cutting-edge CE, there's no place like SECO, "Where Sight Meets Vision." **By Jane Cole, Contributing Editor**



Earn 2 CE Credits:

## 74 Neuro-Ophthalmic Disease Basics: Evaluating the Efferent Visual System

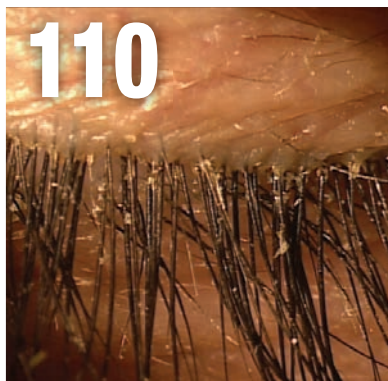
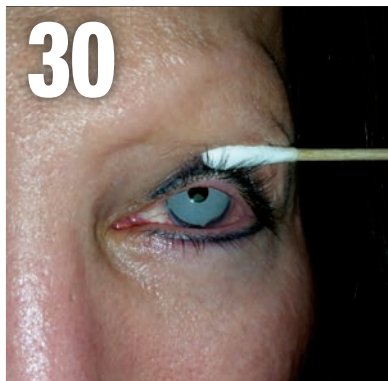
Accurately diagnosing neuro-ophthalmic disease can be difficult and intimidating. But a stepwise approach can make the task less daunting and keep you on track.

**By Kelly A. Malloy, OD**

# Departments

Review of Optometry February 2015

- 4 News Review**
- 16 Letters to the Editor**
- 18 Outlook**  
Is the 'Next Big Thing' Already Here?  
**JACK PERSICO**
- 20 Chairside**  
Knowledge from the Nail Salon  
**MONTGOMERY VICKERS, OD**
- 22 Urgent Care**  
Quickly Douse Chemical Burns  
**RICHARD MANGAN, OD**
- 26 Focus on Refraction**  
The Case of the Blinking Girl  
**MARC B. TAUB, OD, MS,**  
**AND PAUL HARRIS, OD**
- 30 Clinical Quandaries**  
When Iris Eyes Aren't Smiling  
**PAUL C. AJAMIAN, OD**
- 96 Cornea + Contact Lens Q+A**  
The Lay of The Land  
**JOSEPH P. SHOVLIN, OD**
- 99 Glaucoma Grand Rounds**  
All About That Baseline  
**JAMES L. FANELLI, OD**
- 103 Retina Quiz**  
Look What the Cat Dragged In  
**MARK T. DUNBAR, OD**
- 106 Therapeutic Review**  
Fighting Filamentary Keratitis  
**ALAN G. KABAT, OD**  
**JOSEPH W. SOWKA, OD**
- 110 Surgical Minute**  
The Secret to Surgical Success  
**DEREK N. CUNNINGHAM, OD**  
**WALTER O. WHITLEY, OD, MBA**
- 113 Product Review**
- 114 Meetings + Conferences**
- 115 Advertisers Index**
- 117 Classifieds**
- 122 Diagnostic Quiz**  
Weight Gain and Vision Loss  
**ANDREW S. GURWOOD, OD**



Stock Images: ©iStock.com/JobsonHealthcare

## On The Web >> and more

Check out our multimedia and continuing education online at:  
[www.reviewofoptometry.com](http://www.reviewofoptometry.com)

### Digital Edition



Left your copy of *Review of Optometry* at the office? No problem! Access *Review* on your computer or mobile device!

Go to [www.reviewofoptometry.com](http://www.reviewofoptometry.com) and click on the digimag link for the current issue.

### Facebook and Twitter



For daily updates, "Like" our page on Facebook or "Follow" us on Twitter!


- [www.facebook.com/revoptom](http://www.facebook.com/revoptom)
- <http://twitter.com/#!/revoptom>

Look for augmented content and special offers from *Review* and our advertisers. Specified pages work in conjunction with your smartphone or other mobile device to enhance the experience. With Layar, interactive content leaps off the page!



**Step 1:** Download the free Layar app for iPhone or Android.



**Step 2:** Look for pages with the Layar Logo.  INTERACTIVE PRINT



**Step 3:** Open the Layar app, hold the phone above the page and tap to scan it. Hold the phone above the page to view the interactive content.

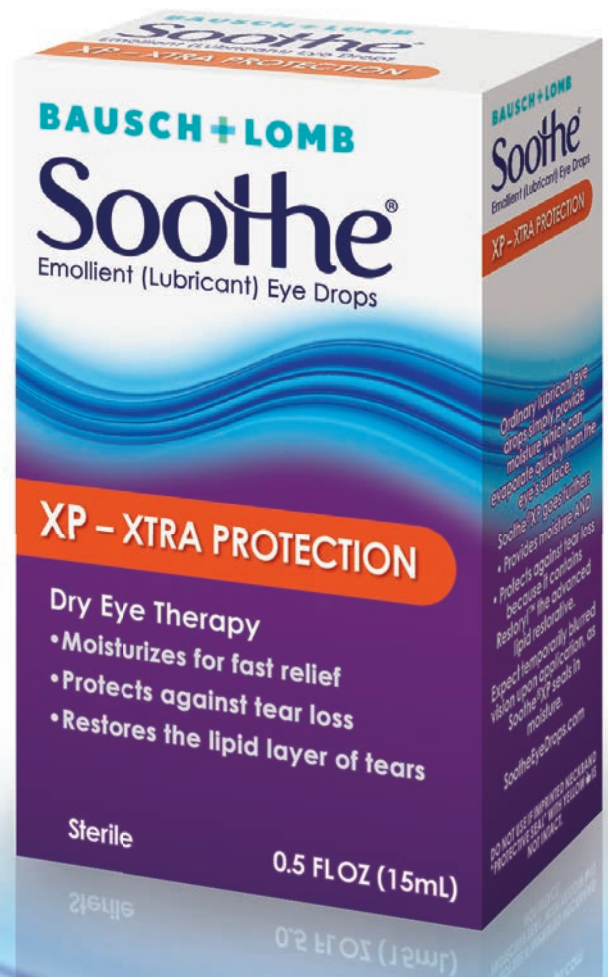The first 150 app downloads and completed forms will be entered into a drawing for a complimentary registration to one of *Review's* 14-hour CE meetings, valued at \$495.

# RELIEF AT THE MAIN SOURCE of dry eye symptoms

Target Lipid Layer Deficiency:

## Soothe<sup>®</sup> XP

With Restoryl<sup>®</sup> Mineral Oils



**Recommend Soothe XP as your first choice for dry eye patients.  
To request samples, please call 1-800-778-0980.**

Now available at major retailers nationwide.

Distributed by Bausch + Lomb, a Division of Valeant Pharmaceuticals North America LLC, Bridgewater, N.J. © 2015 Bausch & Lomb Incorporated. Soothe and Restoryl are trademarks of Bausch & Lomb Incorporated or its affiliates. All other brand/product names are trademarks of their respective owners. PNS07412 US/SXP/14/0006

**BAUSCH + LOMB**  
See better. Live better.



## CONTRIBUTING EDITORS

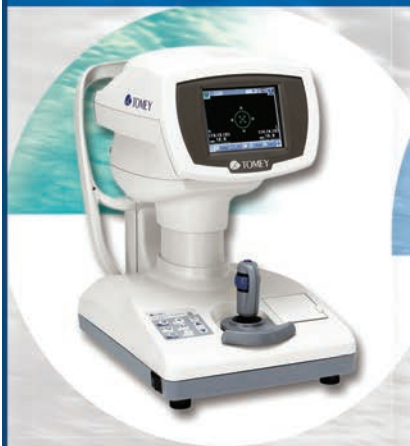PAUL C. AJAMIAN, OD, ATLANTA  
AARON BRONNER, OD, KENNEWICK, WASH.  
MILE BRUJIC, OD, BOWLING GREEN, OHIO  
DEREK N. CUNNINGHAM, OD, AUSTIN, TEXAS  
MARK T. DUNBAR, OD, MIAMI  
ARTHUR B. EPSTEIN, OD, PHOENIX  
JAMES L. FANELLI, OD, WILMINGTON, NC  
FRANK FONTANA, OD, ST. LOUIS  
GARY S. GERBER, OD, HAWTHORNE, NJ  
ANDREW S. GURWOOD, OD, PHILADELPHIA  
ALAN G. KABAT, OD, MEMPHIS, TENN.  
DAVID KADING, OD, SEATTLE  
PAUL M. KARPECKI, OD, LEXINGTON, KY.  
JEROME A. LEGERTON, OD, MBA, SAN DIEGO  
JASON R. MILLER, OD, MBA, POWELL, OHIO  
CHERYL G. MURPHY, OD, HOLBROOK, NY  
CARLO J. PELINO, OD, JENKINTOWN, PA.  
JOSEPH PIZZIMENTI, OD, FORT LAUDERDALE, FLA.  
JOHN RUMPAKIS, OD, MBA, PORTLAND, ORE.  
DIANA L. SHECHTMAN, OD, FORT LAUDERDALE, FLA.  
JEROME SHERMAN, OD, NEW YORK  
JOSEPH P. SHOVLIN, OD, SCRANTON, PA.  
JOSEPH W. SOWKA, OD, FORT LAUDERDALE, FLA.  
MONTGOMERY VICKERS, OD, ST. ALBANS, W.VA.  
WALTER O. WHITLEY, OD, MBA, VIRGINIA BEACH, VA.

## EDITORIAL REVIEW BOARD

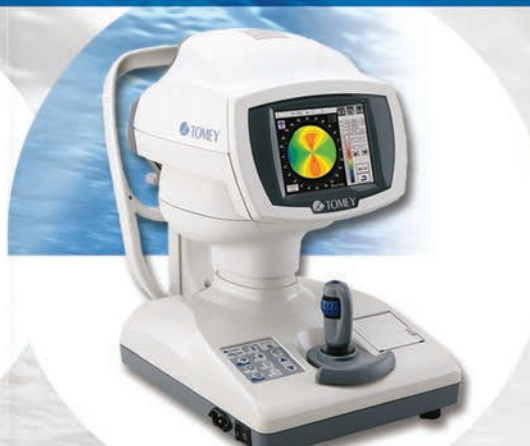JEFFREY R. ANSHEL, OD, CARLSBAD, CALIF.  
JILL AUTRY, OD, RPH, HOUSTON  
SHERRY J. BASS, OD, NEW YORK  
EDWARD S. BENNETT, OD, ST. LOUIS  
MARC R. BLOOMENSTEIN, OD, SCOTTSDALE, ARIZ.  
CHRIS J. CAKANAC, OD, MURRYSVILLE, PA.

JERRY CAVALLERANO, OD, PHD, BOSTON  
WALTER L. CHOATE, OD, MADISON, TENN.  
BRIAN CHOU, OD, SAN DIEGO  
A. PAUL CHOUS, MA, OD, TACOMA, WASH.  
ROBERT M. COLE, III, OD, BRIDGETON, NJ  
GLENN S. CORBIN, OD, WYOMISSING, PA.  
ANTHONY S. DECIDUE, OD, STROUDSBURG, PA.  
S. BARRY EIDEN, OD, DEERFIELD, ILL.  
STEVEN FERRUCCI, OD, SEPULVEDA, CALIF.  
MURRAY FINGERET, OD, HEWLETT, NY  
IAN BEN GADDIE, OD, LOUISVILLE, KY.  
MILTON HOM, OD, AZUSA, CALIF.  
BLAIR B. LONSBERRY, MS, OD, MED, PORTLAND, ORE.  
THOMAS L. LEWIS, OD, PHD, PHILADELPHIA  
DOMINICK MAINO, OD, MED, CHICAGO  
KELLY A. MALLOY, OD, PHILADELPHIA  
RICHARD B. MANGAN, OD, LEXINGTON, KY.  
RON MELTON, OD, CHARLOTTE, NC  
PAMELA J. MILLER, OD, JD, HIGHLAND, CALIF.  
BRUCE MUCHNICK, OD, COATESVILLE, PA.  
MARC MYERS, OD, COATESVILLE, PA.  
WILLIAM B. POTTER, OD, FREEHOLD, NJ  
CHRISTOPHER J. QUINN, OD, ISELIN, NJ  
JOHN L. SCHACHET, OD, ENGLEWOOD, COLO.  
JACK SCHAEFFER, OD, BIRMINGHAM, ALA.  
MICHAEL C. RADOIU, OD, STAUNTON, VA.  
KIMBERLY K. REED, OD, FORT LAUDERDALE, FLA.  
LEO P. SEMES, OD, BIRMINGHAM, ALA.  
LEONID SKORIN, JR., OD, DO, ROCHESTER, MINN.  
BRAD M. SUTTON, OD, INDIANAPOLIS  
LORETTA B. SZCZOTKA, OD, PHD, CLEVELAND  
TAMMY P. THAN, MS, OD, BIRMINGHAM, ALA.  
RANDALL THOMAS, OD, CONCORD, NC  
KATHY C. WILLIAMS, OD, SEATTLE

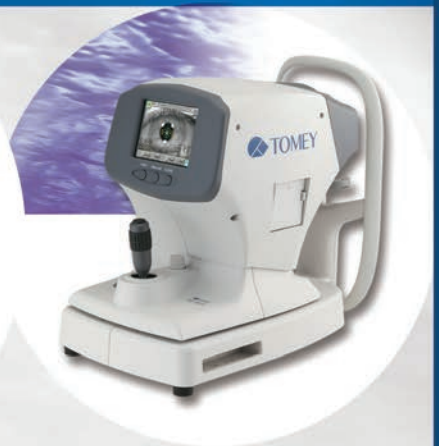# TOMEY AutoRefractor Family



**RC-5000 "Advanced"**  
(AutoRefractor/Keratometer)  
with touch screen



**RT-7000 "Ultimate"**  
(AutoRefractor/Keratometer/Topographer)  
with touch screen & tear stability analysis



**RC-800 "Basic"**  
(AutoRefractor/  
Keratometer)

 **TOMEY**<sup>®</sup> 888-449-4045  
[WWW.TOMEYUSA.COM](http://WWW.TOMEYUSA.COM)

Visit us at the Vision Expo East Meeting Booth MS-6503



## What we do every day matters.



Avenova™ with Neutrox™ (pure hypochlorous acid) removes microorganisms and debris from the lids and lashes. Avenova is an ideal addition to any daily lid and lash hygiene regimen, including for use by patients with Blepharitis and Dry Eye. Avenova may also be used after make-up removal as well as pre and post contact lens wear.

**NovaBay®**

# Avenova™

*Daily lid and lash hygiene.*



**OPHTHALMOLOGIST AND OPTOMETRIST TESTED | RX ONLY**

**AVENOVA.COM | 1-800-890-0329**

*"It was the influence of the comanaging optometrist that made the difference and trumped anything that the surgeon or I could have said."*

## A Surgeon Asks: Who's the Boss?

I am a 65-year-old ophthalmologist, recently retired from 35+ years of cataract surgery. Somewhere along the way, I began to receive *Review of Optometry* and have actually found it quite enjoyable to read.

In the article, "Successful Comanagement of Ocular Surgery Patients" (December 2014), Paul Karpecki, OD, appropriately urges his colleagues to be active participants in the patient's surgical journey. Yet, he then states: "our influence goes much further than anyone else's and has more of an impact in the patient's success than the surgery center or the surgeon."

Really? Surely Dr. Karpecki cannot believe, and teach others to believe, that the surgical referrer is a more powerful determinant of cataract surgery outcome than the surgeon!

Regarding ocular surgery, I would like to request a different mindset from current optometric academia; namely, that surgery is not just another tool to be delegated or ordered, as if all the nuances and demands of a surgical experience were the equivalent of having an associate or a tech do an IOP check.

After 40+ years seeing patients, I believe—even though at times it won't seem trendy nor good business—that patient advocacy is a successful decision-making common denominator that creates unity of purpose among the professions. Also, we should say "thank you" no less than three times a day.

—J.R. McCue, MD, Bastrop, La.

### Dr. Karpecki responds:

First, thank you for taking the time to share your perspective. While I have worked in ophthalmology practices my entire career, I am an optometrist who sees referrals from optometric colleagues daily.

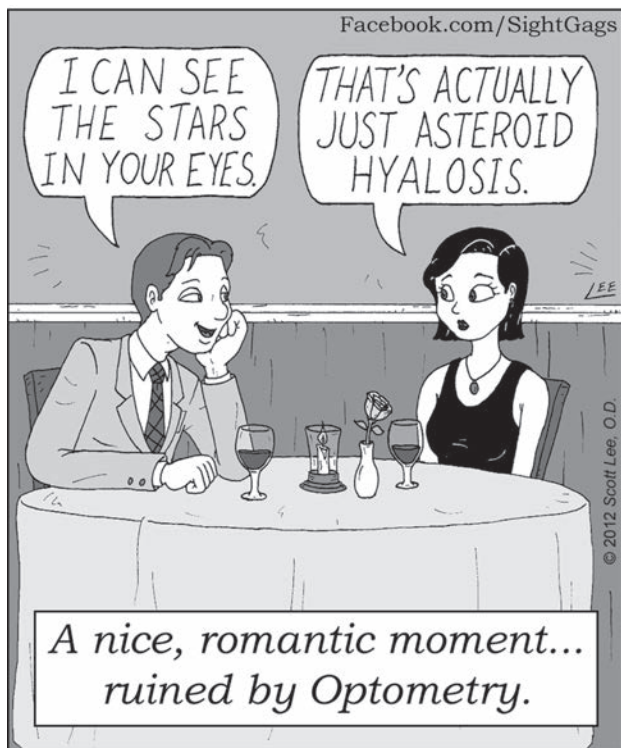The phrase you cite is a little out of context, but the concept is simply this: In cases where I see a patient referred to our clinic for cataract surgery, the optometrist who has seen this patient for the last 20 to 30 years holds more influence than I (the optometrist at the secondary care center) or even the surgeon does over that patient's decisions about cataract surgery. That's simply because the referring doctor has been trusted more in the last two to three decades than a patient will trust me during my 10- to 15-minute portion of the examination at the secondary/tertiary-care center or surgery center.

For example, if I bring up the subject of a premium IOL to a patient who has never heard of the concept, and then I mention the premium charge, one thing goes through the patient's mind: "If it's such a good option, why didn't my eye doctor mention it?" In my experience, fewer than half of these patients will proceed with a premium IOL.

But when a referring or comanaging optometrist first mentions that premium IOL options will be discussed at the surgical center and the patient seems like a good candidate, it tends to be an easy conversion. In this case, nearly 90% opt for the premium IOL option. Keep in mind that in both cases, the premium IOL is in the patient's best interest. It was the influence of the referring/comanaging optometrist that made the difference and truthfully trumped anything that either the surgeon or I could have said.

Thus, it's incumbent upon all of us to stay educated about the latest cataract surgery technologies and IOLs, and to discuss them with patients so they can be guided to the most appropriate option available. That's not to diminish the surgeon's expertise—just allow it to be put to use for the patient's sake. We are indeed all working toward that common goal. ■

## Sight Gags By Scott Lee, OD







# All eyes deserve clariti.



**clariti 1 day—now available for practices everywhere.**

The world's first and only family of silicone hydrogel daily disposable contact lenses designed *for every patient type*—sphere, toric and multifocal.

**High Oxygen  
Transmissibility**

**High Water  
Content**

**Low  
Modulus**

**UV  
Protection**

**Affordable  
Upgrade**

Now you can prescribe all of your patients with healthy, comfortable, affordable silicone hydrogel 1 day lenses—which will make all eyes very happy indeed.

To learn more, contact your CooperVision representative today or visit **[CooperVision.com/practitioner](http://CooperVision.com/practitioner)**.



**CooperVision®**  
Live Brightly.®



PRINTED IN USA

**FOUNDING EDITOR**  
FREDERICK BOGER  
1891-1913

**EDITORIAL OFFICES**

11 CAMPUS BLVD., SUITE 100  
NEWTOWN SQUARE, PA 19073

EMAIL • REVIEWOFOPTOMETRY@JOBSON.COM

WEBSITE • WWW.REVOPTOM.COM

**SUBSCRIPTION INQUIRIES**

1-877-529-1746

**CONTINUING EDUCATION INQUIRIES**

1-800-825-4696

**EDITOR-IN-CHIEF** • JACK PERSICO

(610) 492-1006 • JPERSICO@JOBSON.COM

**EXECUTIVE EDITOR** • JOHN MURPHY

(610) 492-1021 • JMURPHY@JOBSON.COM

**SENIOR EDITOR** • BILL KEKEVIAN

(610) 492-1003 • BKEKEVIAN@JOBSON.COM

**ASSOCIATE EDITOR** • ALIZA MARTIN

(610) 492-1043 • AMARTIN@JOBSON.COM

**DIRECTOR ART/PRODUCTION** • JOE MORRIS

(610) 492-1027 • JMORRIS@JOBSON.COM

**ART DIRECTOR** • JARED ARAUJO

(610) 492-1032 • JARAJO@JOBSON.COM

**DIRECTOR OF CE ADMINISTRATION** • REGINA COMBS

(212) 274-7160 • RCOMBS@JOBSON.COM

**SPECIAL PROJECTS/E-PRODUCTS MANAGER** • KAREN ROMAN

(610) 492-1037 • KROMAN@JOBSON.COM

**EDITORIAL BOARD**

**CHIEF CLINICAL EDITOR** • PAUL M. KARPECKI, OD

**ASSOCIATE CLINICAL EDITORS** • JOSEPH P. SHOVLIN, OD;

ALAN G. KABAT, OD; CHRISTINE W. SINDT, OD

**DIRECTOR OPTOMETRIC PROGRAMS** • ARTHUR EPSTEIN, OD

**CLINICAL & EDUCATION CONFERENCE ADVISOR**

PAUL M. KARPECKI, OD

**CASE REPORTS COORDINATOR** • ANDREW S. GURWOOD, OD

**CLINICAL CODING EDITOR** • JOHN RUMPAKIS, OD, MBA

**CONSULTING EDITOR** • FRANK FONTANA, OD

**COLUMNISTS**

**CHAIRSIDE** • MONTGOMERY VICKERS, OD

**CLINICAL QUANDARIES** • PAUL C. AJAMIAN, OD

**CORNEA & CONTACT LENS Q+A** • JOSEPH P. SHOVLIN, OD

**DIAGNOSTIC QUIZ** • ANDREW S. GURWOOD, OD

**GLAUCOMA GRAND ROUNDS** • JAMES L. FANELLI, OD

**OCULAR SURFACE REVIEW** • PAUL M. KARPECKI, OD

**URGENT CARE** • RICHARD B. MANGAN, OD

**RETINA QUIZ** • MARK T. DUNBAR, OD

**REVIEW OF SYSTEMS** • CARLO J. PELINO, OD;

JOSEPH J. PIZZIMENTI, OD

**SURGICAL MINUTE** • DEREK N. CUNNINGHAM, OD;

WALTER O. WHITLEY, OD, MBA

**THERAPEUTIC REVIEW** • JOSEPH W. SOWKA, OD;

ALAN G. KABAT, OD

**NEURO CLINIC** • MICHAEL TROTTINI, OD;

MICHAEL DELGODICE, OD

**FOCUS ON REFRACTION** • MARC TAUB, OD;

PAUL HARRIS, OD

JOBSON MEDICAL INFORMATION LLC



# Is the ‘Next Big Thing’ Already Here?

By Jack Persico, Editor-in-Chief

Innovation can be hard to notice sometimes, even when it’s staring you right in the face. “There is no reason anyone would want a computer in their home,” Ken Olsen, founder of Digital Equipment Corp., said in 1977, just as the PC revolution was beginning. Similar bad calls have been made whenever something new challenged the existing way of things—radio, TV, the Internet, you name it. In 1962 an executive at Decca Records rejected an audition tape from a new band called The Beatles. He even went so far as to say that they “have no future in show business.” Whoops.

In business circles, people talk about the “innovator’s dilemma,” referencing a book of the same name that describes how companies are prone to miss or dismiss the impact of ground-breaking new technology or ideas. The concept is that companies can be so focused on their current model of serving customers that they fail to see how people’s needs might change in response to innovation. In other words they suffer from, “If it ain’t broke, don’t fix it” disease. The company’s dilemma, then: abandon a successful business model in favor of a leap of faith into the unknown, or stick with what they know... and risk being overtaken by more nimble competitors.

Is there an innovator’s dilemma in health and science too? Less so than in other circles, as this is such a data-driven field, but it’s true that old ways of providing care are sometimes hard to give up. When ophthalmologist Charles Kelman invented phaco, it wasn’t welcomed

as a safer alternative to intracapsular cataract extraction; rather, it was dismissed as “ridiculous” by the establishment and called malpractice.

By the way, Dr. Kelman got the idea for phaco while having his teeth cleaned at the dentist—the ultrasound probe triggered a flash of insight—proving that innovative ideas can arise anywhere, any time.

## You Say You Want a Revolution

This month we shine the spotlight on several frontiers of innovation in eye care. Some are applicable right now, like the many new technologies that are improving dry eye diagnosis and therapy (see page 54), while others are more about new ways of thinking, like glaucoma’s link to the central nervous system (page 32). The notion that glaucoma may be governed by the same processes as Alzheimer’s and Parkinson’s is indeed a radical idea that opens up new avenues to explore. Some are high-profile sci-fi concepts like Google’s “smart” contact lens (page 46) or the notion that an eye drop might be able to treat a posterior segment disease (page 40). Others are more workaday and unglamorous, but perhaps a bit more practical. Either way, you’ll find plenty of great ideas this month from people who are challenging the status quo.

It’s hard to question tried-and-true ways of treating your patients, and in fact standard of care tends to favor protocols with a long track record of success. But keep your ear to the ground for the “next big thing.” It could be here before you know it. Perhaps it already is. ■





# THE RICK BAY FOUNDATION

*for Excellence in Eyecare Education*

[www.rickbayfoundation.org](http://www.rickbayfoundation.org)

*Support the Education of Future Healthcare & Eyecare Professionals*



## **About Rick**

Rick Bay served as the publisher of *The Review* Group since 1991.

To those who worked for him, he was a leader whose essence was based in a fierce and boundless loyalty.



To those in the industry and the professions he served, he will be remembered for his unique array of skills and for his dedication to exceeding the expectations of his customers, making many of them fast friends.

Scholarships will be awarded to advance the education of students in both **Optometry** and **Ophthalmology**, and will be chosen by their school based on qualities that embody Rick's commitment to the profession, including integrity, compassion, partnership and dedication to the greater good.

## Interested in being a partner with us?

Visit [www.rickbayfoundation.org](http://www.rickbayfoundation.org)

*(Contributions are tax-deductible in accordance with section 170 of the Internal Revenue Code.)*



**THE RICK BAY FOUNDATION**  
*for Excellence in Eyecare Education*

*(The Rick Bay Foundation for Excellence in Eyecare Education is a nonprofit, tax-exempt organization under section 501(c)(3) of the Internal Revenue Code.)*



# Knowledge from the Nail Salon

The customer is always right—especially when it’s Mom. So, if you want to raise your Yelp score, get in touch with your feminine side. **By Montgomery Vickers, OD**

So, I was just minding my own business while having a manicure and pedicure... when a cheery, little teenage girl said to me, “My dad would NEVER do that!” I smiled and responded that any guy who wants girls to like him had better get in touch with his feminine side.

There’s an old saying: “If Mama’s happy, everyone’s happy!” In optometry, we know this to be true, and for those of us who don’t have the advantage of being female, we’d better get in touch with our feminine side if we expect any family to stay with us for more than one measly examination. Guys don’t want the responsibility of choosing doctors. Even guys who *are* doctors don’t want that responsibility. We’d rather spend our valuable time performing important tasks like checking air pressure in tires—which, by the way, is hell on your nails.

Moms are the medical decision makers, so they deserve most of our attention. If you don’t believe me, try this experiment: If your 25-year-old male contact lens patient misses his yearly exam, call his Dad and tattle. You’ll never see the patient again. Instead, call Mom. The kid will be at the door when you get there tomorrow morning.

Oh, I know—calling Mom about her adult son’s tardiness is probably some kind of a HIPAA violation, right? I’m willing to face the Federales as long as the Mom is there to defend me. Even the Feds fade when Mama’s not happy.

Oddly, I hear that sometimes female patients don’t give female doctors the respect they deserve, and even sometimes assume the doctor is the assistant. Part of that is just innocent ignorance or maybe even unwarranted prejudice. Like the man said, you can’t fix stupid.

But those moments are, I believe, becoming rarer each year as highly qualified women enter the medical field and take great care of patients while we old buzzards still spend half the exam chatting about a trophy fish or that amazing putt three years ago. Women listen to the patients. Guys listen to themselves.

So, fellas, it’s time for a change. I know you hate to change. (So do I.) But here are a few tips to get you in touch with your very own feminine side while not losing what little testosterone you have left.

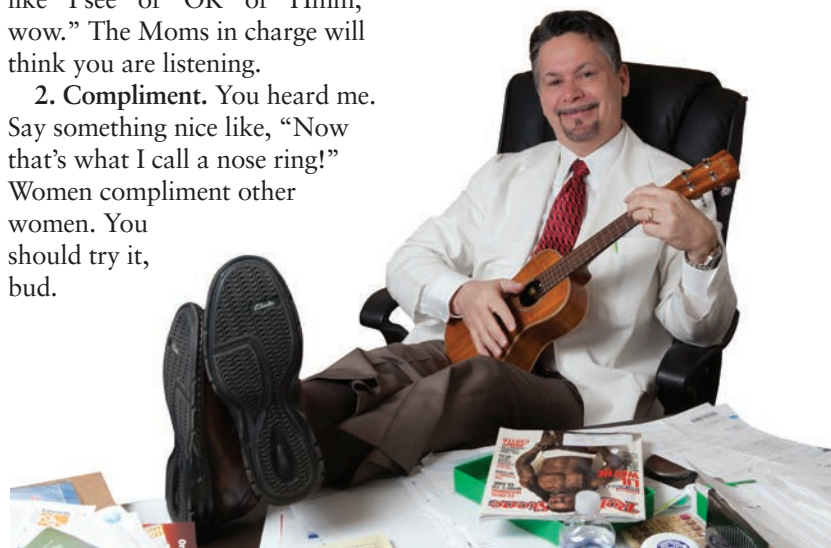**1. Listen.** If you just can’t listen, then keep your comments to things like “I see” or “OK” or “Hmm, wow.” The Moms in charge will think you are listening.

**2. Compliment.** You heard me. Say something nice like, “Now that’s what I call a nose ring!” Women compliment other women. You should try it, bud.

**3. Speak “easy.”** Ask them to choose the lens that makes them “see easier” not “better.” Men think in terms of “Which is better, one or two?” because we are too goofy to pay attention to all the lovely shades of grey that lie between. Use “easier.” Mom will know just what you mean.

**4. Sell the truth.** We all know the right frame is like an instant facelift, and costs a lot less money. This is the time it pays to be honest—be excited and tell them that your assistant will be able to find the frame that makes their eyes and whole face look younger... Done! Sold! Even old men want that!

After work, go get a manicure and pedicure. They’ll never see your feet, but trust me—your little piggies will be in hog heaven. And your hands? Your hands look like crap! Deal with them and watch your practice grow! ■



Phoroptor<sup>®</sup> VRx  
DIGITAL REFRACTION SYSTEM

Reichert  
TECHNOLOGIES  
AMETEK

**REFRACT** IN THE  
**FAST LANE**  
DRIVE PRACTICE EFFICIENCY



**NEW** **PHOROPTOR<sup>®</sup> VRx**  
DIGITAL REFRACTION SYSTEM

Thinnest & most compact. Incredibly fast. Ultra-quiet.  
Effortless integration. Made in the USA.

The most advanced Phoroptor<sup>®</sup> ever built.  
[www.reichert.com/vrx](http://www.reichert.com/vrx)

Take a **test drive** at SECO, Vision Expo East,  
or with your authorized Reichert<sup>®</sup> distributor.

Reichert<sup>®</sup>  
TECHNOLOGIES

AMETEK<sup>®</sup>

© 2015 AMETEK, Inc. & Reichert, Inc. (1-2015) · All rights reserved · Phoroptor is a registered trademark of Reichert, Inc. · [www.reichert.com](http://www.reichert.com)





# Quickly Douse Chemical Burns

Copious eye washing is the necessary first step in combating chemical splashes.

By Richard Mangan, OD

A long-standing patient is on the phone with your receptionist. She's in a panic because her husband accidentally got splashed in the eye with a chemical he uses for fertilizing his crops. He's in severe pain and can barely open his eye. He's currently in the shower with the water running over his eyes and face. She's sure you and your staff will help her through this crisis. You hear your receptionist tell her to bring him into the office immediately.

Is this really the right suggestion? What response can she recommend they take before leaving? Should she ask any other questions? What can you do to prepare for this patient? In other words, are you and your staff prepared for such a phone call?

## Types of Chemical Burns

An ocular chemical burn is considered a true ocular emergency. Whether by gas, liquid or solid, an acid or alkaline base can cause irreversible damage to the eye and adnexa if urgent action is not taken.

Alkali agents (pH of 10 or greater) such as ammonia (found in cleaning agents, fertilizers and refrigerants), lye (drain and oven cleaners, air bags), magnesium hydroxide (in firework sparklers, flares) and lime (in plaster, mortar,

cement, white wash) are lipophilic and penetrate the corneal stroma through saponification of fatty acids in cellular membranes. Once stromal tissue is damaged, proteolytic enzymes are released that furthers tissue damage, also known as liquefactive necrosis.

Acid-based agents (pH of 4 or less) such as sulfuric acid (in car batteries), acetic acid (vinegar) and hydrochloric acid (swimming pool cleaners) are generally considered less harmful than alkali substances. Acids usually bind with tissue proteins, causing coagulation and stopping further penetration. One exception is hydrofluoric acid (found in refrigerants, fluorescent bulbs, glass polishing and mineral refining) where the fluoride ion can rapidly penetrate corneal tissue and cause severe, sight-threatening damage.

## Irrigation

Certain substances can rapidly penetrate into the eye and cause irreversible intraocular damage in as little as five minutes. The first and most important step in management of an acute ocular chemical splash injury is copious irrigation. This, ideally, should begin wherever the injury took place. At home, the patient can perform this irrigation in the shower or using an outdoor hose, or at the

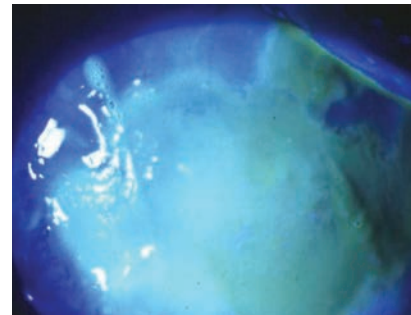


Photo: Bradley Sutton, OD

This slit lamp image shows a patient who splashed bleach in her eye while cleaning.

workplace using a sink or designated eye wash station.

If irrigation begins immediately after the splash occurs, pH levels often normalize within 30 minutes of continuous irrigation (about one to three liters).

If delayed, irrigating volumes can sometimes exceed 20 liters before reaching physiologic pH levels. This is largely due to chemical deposition in ocular tissue that becomes more recalcitrant to irrigation. When triaging the patient over the phone, ask about the timing and severity of the burn.

Irrigation in the office or emergency room can be performed with either a Morgan lens or a standard nasal cannula that is positioned and sometimes taped to the bridge of the nose, to provide a similar steady flow to both eyes.

**Table 1. Roper-Hall Classification Method for Ocular Chemical Burns**

Grade	Prognosis	Cornea	Conjunctiva / Limbus
I.....	Good .....	Corneal epithelial damage.....	No limbal ischemia
II.....	Good .....	Corneal haze, iris details visible .....	<1/3 limbal ischemia
III.....	Guarded .....	Total epithelial loss, stromal haze, iris details obscured .....	1/3 to 1/2 limbal ischemia
IV.....	Poor .....	Cornea opaque, iris and pupil obscured .....	>1/2 limbal ischemia



# Broad Managed Care Coverage<sup>1</sup>

## THE NUMBER OF DAILY DOSES DECLINES, BUT THE EFFICACY DOESN'T

### Once-daily post-op dosing when you're managing patients after cataract surgery.

ILEVRO® Suspension dosed once daily post-op has been shown to be noninferior to NEVANAC® (nepafenac ophthalmic suspension) 0.1% dosed three times daily for the resolution of inflammation and pain associated with cataract surgery.<sup>2,3</sup>

One drop of ILEVRO® Suspension should be applied once daily beginning 1 day prior to cataract surgery through 14 days post-surgery, with an additional drop administered 30 to 120 minutes prior to surgery.<sup>2</sup>

Use of ILEVRO® Suspension more than 1 day prior to surgery or use beyond 14 days post-surgery may increase patient risk and severity of corneal adverse events.<sup>2</sup>

Available in 1.7 mL and new 3 mL fill sizes

#### INDICATIONS AND USAGE

ILEVRO® Suspension is a nonsteroidal, anti-inflammatory prodrug indicated for the treatment of pain and inflammation associated with cataract surgery.

#### IMPORTANT SAFETY INFORMATION

##### Contraindications

ILEVRO® Suspension is contraindicated in patients with previously demonstrated hypersensitivity to any of the ingredients in the formula or to other NSAIDs.

##### Warnings and Precautions

- Increased Bleeding Time – With some nonsteroidal anti-inflammatory drugs including ILEVRO® Suspension there exists the potential for increased bleeding time. Ocularly applied nonsteroidal anti-inflammatory drugs may cause increased bleeding of ocular tissues (including hyphema) in conjunction with ocular surgery.
- Delayed Healing – Topical nonsteroidal anti-inflammatory drugs (NSAIDs) including ILEVRO® Suspension may slow or delay healing. Concomitant use of topical NSAIDs and topical steroids may increase the potential for healing problems.
- Corneal Effects – Use of topical NSAIDs may result in keratitis. In some patients, continued use of topical NSAIDs may result in epithelial breakdown, corneal thinning, corneal erosion, corneal ulceration or corneal perforation. These events may be sight threatening. Patients with evidence of corneal epithelial breakdown should immediately discontinue use.

Patients with complicated ocular surgeries, corneal denervation, corneal epithelial defects, diabetes mellitus, ocular surface diseases (e.g., dry eye syndrome), rheumatoid arthritis, or repeat ocular surgeries within a short period of time may be at increased risk for corneal adverse events which may become sight threatening. Topical NSAIDs should be used with caution in these patients.

Use more than 1 day prior to surgery or use beyond 14 days post-surgery may increase patient risk and severity of corneal adverse events.

- Contact Lens Wear – ILEVRO® Suspension should not be administered while using contact lenses.

##### Adverse Reactions

The most frequently reported ocular adverse reactions following cataract surgery occurring in approximately 5 to 10% of patients were capsular opacity, decreased visual acuity, foreign body sensation, increased intraocular pressure, and sticky sensation.

**For additional information about ILEVRO® Suspension, please refer to the brief summary of prescribing information on adjacent page.**

**References:** 1. Formulary data provided by Pinsonault Associates, LLC, PathfinderRx, June 2014. 2. ILEVRO® Suspension prescribing information. 3. NEVANAC® Suspension prescribing information.

**For more resources for eye care professionals, visit [MYALCON.COM/ILEVRO](http://MYALCON.COM/ILEVRO)**

# ILEVRO®

(nepafenac ophthalmic suspension) 0.3%

## BRIEF SUMMARY OF PRESCRIBING INFORMATION

### INDICATIONS AND USAGE

ILEVRO® Suspension is indicated for the treatment of pain and inflammation associated with cataract surgery.

### DOSE AND ADMINISTRATION

#### Recommended Dosing

One drop of ILEVRO® Suspension should be applied to the affected eye one-time-daily beginning 1 day prior to cataract surgery, continued on the day of surgery and through the first 2 weeks of the postoperative period. An additional drop should be administered 30 to 120 minutes prior to surgery.

#### Use with Other Topical Ophthalmic Medications

ILEVRO® Suspension may be administered in conjunction with other topical ophthalmic medications such as beta-blockers, carbonic anhydrase inhibitors, alpha-agonists, cycloplegics, and mydriatics. If more than one topical ophthalmic medication is being used, the medicines must be administered at least 5 minutes apart.

### CONTRAINDICATIONS

ILEVRO® Suspension is contraindicated in patients with previously demonstrated hypersensitivity to any of the ingredients in the formula or to other NSAIDs.

### WARNINGS AND PRECAUTIONS

#### Increased Bleeding Time

With some nonsteroidal anti-inflammatory drugs including ILEVRO® Suspension, there exists the potential for increased bleeding time due to interference with thrombocyte aggregation. There have been reports that ocularly applied nonsteroidal anti-inflammatory drugs may cause increased bleeding of ocular tissues (including phemas) in conjunction with ocular surgery. It is recommended that ILEVRO® Suspension be used with caution in patients with known bleeding tendencies or who are receiving other medications which may prolong bleeding time.

#### Delayed Healing

Topical nonsteroidal anti-inflammatory drugs (NSAIDs) including ILEVRO® Suspension, may slow or delay healing. Topical corticosteroids are also known to slow or delay healing. Concomitant use of topical NSAIDs and topical steroids may increase the potential for healing problems.

#### Corneal Effects

Use of topical NSAIDs may result in keratitis. In some susceptible patients, continued use of topical NSAIDs may result in epithelial breakdown, corneal thinning, corneal erosion, corneal ulceration or corneal perforation. These events may be sight threatening. Patients with evidence of corneal epithelial breakdown should immediately discontinue use of topical NSAIDs including ILEVRO® Suspension and should be closely monitored for corneal health. Postmarketing experience with topical NSAIDs suggests that patients with complicated ocular surgeries, corneal denervation, corneal epithelial defects, diabetes mellitus, ocular surface diseases (e.g., dry eye syndrome), rheumatoid arthritis, or repeat ocular surgeries within a short period of time may be at increased risk for corneal adverse events which may become sight threatening. Topical NSAIDs should be used with caution in these patients.

Postmarketing experience with topical NSAIDs also suggests that use more than 1 day prior to surgery or use beyond 14 days post surgery may increase patient risk and severity of corneal adverse events.

#### Contact Lens Wear

ILEVRO® Suspension should not be administered while using contact lenses.

### ADVERSE REACTIONS

Because clinical studies are conducted under widely varying conditions, adverse reaction rates observed in the clinical studies of a drug cannot be directly compared to the rates in the clinical studies of another drug and may not reflect the rates observed in practice.

#### Ocular Adverse Reactions

The most frequently reported ocular adverse reactions following cataract surgery were capsular opacity, decreased visual acuity, foreign body sensation, increased intraocular pressure, and sticky sensation. These events occurred in approximately 5 to 10% of patients.

Other ocular adverse reactions occurring at an incidence of approximately 1 to 5% included conjunctival edema, corneal edema, dry eye, lid margin crusting, ocular discomfort, ocular hyperemia, ocular pain, ocular pruritus, photophobia, tearing and vitreous detachment.

Some of these events may be the consequence of the cataract surgical procedure.

#### Non-Ocular Adverse Reactions

Non-ocular adverse reactions reported at an incidence of 1 to 4% included headache, hypertension, nausea/vomiting, and sinusitis.

### USE IN SPECIFIC POPULATIONS

#### Pregnancy

##### Teratogenic Effects.

**Pregnancy Category C:** Reproduction studies performed with nepafenac in rabbits and rats at oral doses up to 10 mg/kg/day have revealed no evidence of teratogenicity due to nepafenac, despite the induction of maternal toxicity. At this dose, the animal plasma exposure to nepafenac and amfenac was approximately 70 and 630 times human plasma exposure at the recommended human topical ophthalmic dose for rats and 20 and 180 times human plasma exposure for rabbits, respectively. In rats, maternally toxic doses  $\geq 10$  mg/kg were associated with dystocia, increased postimplantation loss, reduced fetal weights and growth, and reduced fetal survival.

Nepafenac has been shown to cross the placental barrier in rats. There are no adequate and well-controlled studies in pregnant women. Because animal reproduction studies are not always predictive of human response, ILEVRO® Suspension should be used during pregnancy only if the potential benefit justifies the potential risk to the fetus.

##### Non-teratogenic Effects.

Because of the known effects of prostaglandin biosynthesis inhibiting drugs on the fetal cardiovascular system (closure of the ductus arteriosus), the use of ILEVRO® Suspension during late pregnancy should be avoided.

#### Nursing Mothers

ILEVRO® Suspension is excreted in the milk of lactating rats. It is not known whether this drug is excreted in human milk. Because many drugs are excreted in human milk, caution should be exercised when ILEVRO® Suspension is administered to a nursing woman.

#### Pediatric Use

The safety and effectiveness of ILEVRO® Suspension in pediatric patients below the age of 10 years have not been established.

#### Geriatric Use

No overall differences in safety and effectiveness have been observed between elderly and younger patients.

### NONCLINICAL TOXICOLOGY

#### Carcinogenesis, Mutagenesis, Impairment of Fertility

Nepafenac has not been evaluated in long-term carcinogenicity studies. Increased chromosomal aberrations were observed in Chinese hamster ovary cells exposed in vitro to nepafenac suspension. Nepafenac was not mutagenic in the Ames assay or in the mouse lymphoma forward mutation assay. Oral doses up to 5,000 mg/kg did not result in an increase in the formation of micronucleated polychromatic erythrocytes in vivo in the mouse micronucleus assay in the bone marrow of mice. Nepafenac did not impair fertility when administered orally to male and female rats at 3 mg/kg.

### PATIENT COUNSELING INFORMATION

#### Slow or Delayed Healing

Patients should be informed of the possibility that slow or delayed healing may occur while using nonsteroidal anti-inflammatory drugs (NSAIDs).

#### Avoiding Contamination of the Product

Patients should be instructed to avoid allowing the tip of the dispensing container to contact the eye or surrounding structures because this could cause the tip to become contaminated by common bacteria known to cause ocular infections. Serious damage to the eye and subsequent loss of vision may result from using contaminated solutions.

Use of the same bottle for both eyes is not recommended with topical eye drops that are used in association with surgery.

#### Contact Lens Wear

ILEVRO® Suspension should not be administered while wearing contact lenses.

#### Intercurrent Ocular Conditions

Patients should be advised that if they develop an intercurrent ocular condition (e.g., trauma, or infection) or have ocular surgery, they should immediately seek their physician's advice concerning the continued use of the multi-dose container.

#### Concomitant Topical Ocular Therapy

If more than one topical ophthalmic medication is being used, the medicines must be administered at least 5 minutes apart.

#### Shake Well Before Use

Patients should be instructed to shake well before each use. U.S. Patent Nos. 5,475,034; 6,403,609; and 7,169,767.

**Alcon**<sup>®</sup>  
a Novartis company

ALCON LABORATORIES, INC.  
Fort Worth, Texas 76134 USA  
© 2014 Novartis 7/14 ILV14058JAD

**Table 2. Treatment Considerations for Chemical Burns**

Grade I	Prednisolone acetate 1% QID Topical antibiotic ung (e.g., erythromycin) QHS to QID Preservative-free artificial tears PRN Consider cycloplegic for pain PRN
Grade II	Topical antibiotic (e.g., fluoroquinolone) QID Prednisolone acetate 1% Q1H while awake with rapid taper between days 10-14 Long-acting cycloplegic (i.e., atropine 1%) Oral pain medication PRN Oral doxycycline to reduce risk of corneal melting through MMP inhibition Oral vitamin C (1,000mg to 2,000mg) QID Sodium ascorbate drops (10%) Q1H while awake Preservative-free artificial tears PRN Debridement of necrotic tissue, using tissue adhesive as needed
Grade III	Same as Grade II Amniotic membrane application (e.g., Prokera)—best if used during the first two weeks of injury
Grade IV	Same as Grades II & III For significant necrosis, a tenoplasty can help re-establish limbal vascularity Stem cell transplantation Penetrating keratoplasty Keratoprosthesis

### Evaluating Severity

Once the ocular surface pH is stable, perform a thorough case history and ocular examination to ascertain the extent and depth of injury. The most common symptoms are severe pain, photophobia, epiphora, blepharospasm and reduced vision. Slit-lamp exam should focus not only on the cornea, limbus and conjunctiva but external adnexa as well.

IOP readings are important too, as alkaline chemical burns may cause immediate, near-immediate or delayed rises in IOP.

While no “cookie-cutter” approach to managing acute ocular chemical burns exists, more than one classification scheme is available to assist in formulating a prognosis and secondary treatment plan. One such scheme is the Roper-Hall classification method (*Table 1*).

### Treatment Goals

The goal of treatment is to promote reepithelialization, while controlling inflammation and minimizing the adverse sequelae that often follow a chemical injury. Acute phase

treatment often includes a broad-spectrum antibiotic, cycloplegic and anti-glaucoma therapy. Other treatment considerations are included in *Table 2*.

If an eye shows elevated IOP, aqueous suppression is the first choice. Oral therapy is preferable, barring any contraindications, until reepithelialization occurs. For some chemical burns, reepithelialization

may take 10 to 14 days. If it doesn't occur within 21 days, the risk of permanent vision loss is significant. Consult a corneal specialist early in the management process so that the patient can undergo timely surgical treatment, should medical management prove insufficient.

### Time is of the Essence


An ocular chemical burn can be devastating to the eye and to vision. Time is of the essence for this ocular emergency. Establish a practice-wide ocular injury protocol that includes chemical splashes to the eye. Telephone triage is vital in these cases, so make sure staff is properly trained on how to handle such calls. By doing so, you may make a tremendous difference in the lives of one or more of your patients. ■

1. Tuft SJ, Shortt AJ. Surgical rehabilitation following severe ocular burns. *Eye (Lond)* 2009;23:1966–71.
2. Kuckelkorn R, Makropoulos W, Kottek A, Reim M. Retrospective study of severe alkali burns of the eyes. *Klin Monbl Augenheilkd*. 1993;203:397–402.
3. Fish R, Davidson RS. Management of ocular thermal and chemical injuries, including amniotic membrane therapy. *Curr Opin Ophthalmol* 2010, Jul;21(4):317–21
4. Herr RD, White GL, Bernhisel K, et al. Clinical comparison of ocular irrigation fluids following chemical injury. *Am J Emerg Med* 1991;9:228–31.
5. Cavanagh, HD. Contact Lenses in the Industrial Workplace: Are They Safe? *The CLAO Journal*, 1992, Jan;18(1):11.

### 10 Telephone Triage Tips for Chemical Splashes and Burns

1. Upon hearing of a chemical splash injury, make sure that the preliminary irrigation process begins on site before the patient seeks care.
2. If the chemical splash occurred outside of the workplace, remind the caller that the shower or an outdoor hose is an adequate option.
3. Attempt to determine time lapse between burn event and when irrigation started.
4. Attempt to determine the type of chemical that entered the eye(s).
5. Attempt to determine if the patient is wearing contact lenses. Irrigation should not stop in an effort to remove contact lenses.
6. Irrigation should take place for a minimum of 20 to 30 minutes before the patient is brought to the office or emergency room.
7. When the patient is ready to make the trip to the ER or office, remind them to bring the container that held the offending chemical. Important information may be obtained from the labeling.
8. If the injury occurred in the workplace, ask the patient to bring the MSDS (material safety data sheet) if available.
9. If the injury occurred where there is no or limited access to water for irrigation, refer them to the nearest emergency room or your office, whichever is closer.
10. Assist with dispatching emergency services as needed.





# The Case of the Blinking Girl

Could this child's chronic blinking be due to a visual problem? If so, how would you help her? **By Marc B. Taub, OD, MS, and Paul Harris, OD**

*This is the first installment of a bimonthly column dedicated to topics in refraction and binocular vision. We'll bring you actual cases that we've seen and explain how we handled them, and we'll also answer case-based questions from readers. We're thrilled to cover optometry's stock-in-trade, and hope that it generates thought and perhaps even a little controversy.*

*Please send any feedback or ideas for future columns to Marc Taub, OD, MS, at [mtaub@sco.edu](mailto:mtaub@sco.edu).*

I (Marc) was hosting my son's eighth birthday party at my house and, amid the chaos, I noticed that one of the girls was blinking excessively. It didn't seem to matter much what she was looking at, distance or near, but she was literally blinking every few seconds. Not only was she blinking unusually often, but she was also blinking fairly hard, and seemed bothered when she had to do so.

As the party wound down, I questioned her mother, who said the girl's excessive blinking had been going on for the past two months. She was doing well in school and had no trouble with reading or copying from the board. Her mother also revealed that her daughter had started medication for attention deficit hyperactivity disorder (ADHD) four months prior.

When I suggested the girl have an eye exam, the mother stated her daughter needed to see a local pediatric ophthalmologist first due to a



**Our young, blinking patient showed a reduced near point of convergence.**

family obligation. I explained the differences in approach, and asked her to let me know the outcome of that examination. I told the mother that the examination would not likely produce an explanation for the blinking, as ophthalmologists do not routinely test beyond sight-related issues.

## Diagnostic Data

After the pediatric ophthalmologist's examination showed that the child did not need glasses and that she did not have a visual acuity-based issue, she came into our clinic for a second examination with a focus on binocular vision and accommodation.

Her history included the Quality of Life Symptoms checklist, which we use to gauge the impact of the potential visual issue. She scored

a four; a score of 20 or greater is considered a red flag. While her score didn't correlate with the subsequent examination data, it was not surprising—whatever was occurring wasn't affecting her academically or causing an inordinate amount of symptoms. As this was only one piece of the examination puzzle, I pressed on.

Her visual acuity was 20/20 OD and OS at distance and near. Stereopsis, which is a great way to assess fine binocular functioning, was 25 seconds of arc. Cover test was orthophoric at distance and 6 prism diopters of exophoria at near. Extraocular muscle testing revealed head movement in right and left gazes, and heavy blinking when crossing the midline.

The near point of convergence (NPC) broke at 40cm three times

# Tonometry Done Right

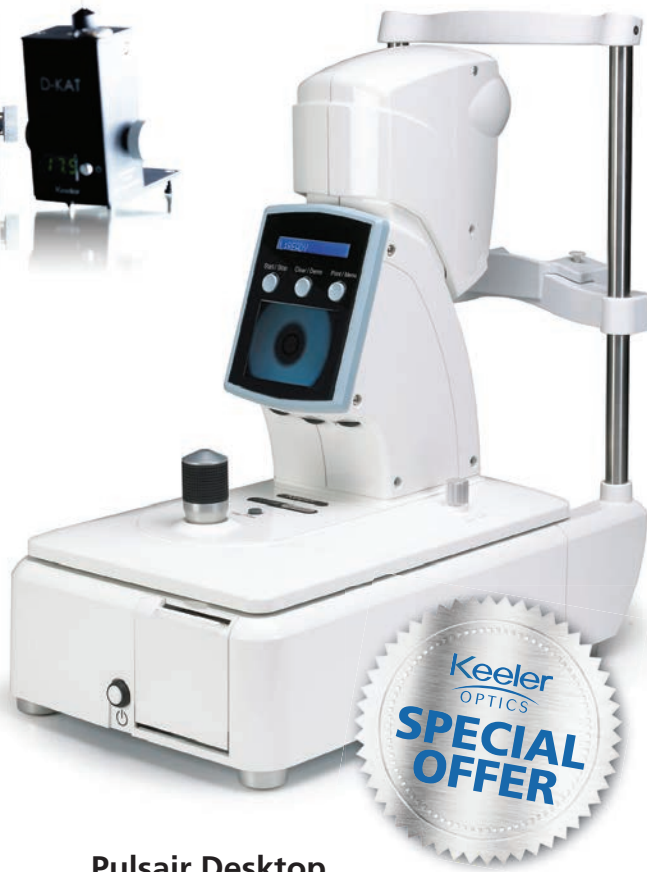**new**



**D-KAT Digital**  
Keeler quality.



**Intellipuff**  
The standard for hand held mobility.



**Pulsair Desktop**  
Smallest footprint and simple to use!

*Purchase a Pulsair Desktop  
by March 31, 2015 and get  
a \$1,300 Instant Rebate!*

Buy Online!  
[keelerusa.com](http://keelerusa.com)



**Keeler**  
OPTICS



**With lenses in place, her near point of convergence improved—and the frequent blinking soon stopped. Most likely, the blinking was essentially a symptom of a pseudo-convergence insufficiency.**

and her accommodative amplitudes were 6.00D OD and OS. Distance retinoscopy was -0.50 OD and -0.25 OS, and near retinoscopy by monocular estimated method (MEM) was +1.00 OU.

## Diagnosis and Management

Based on her normal visual acuity, low minus on dry retinoscopy, and lag on MEM, we decided to trial frame +0.75D OU. Besides witnessing an immediate positive subjective response, the following testing was performed with the trial frame in place:

- Phoria: orthophoria @ distance, 4 exophoria @ near
- NPC: 8cm break/18cm recovery

The subjective difference and the improvement in the NPC and near phoria with the low plus prescription lead to a diagnosis of pseudo-convergence insufficiency. What differentiates this condition from true convergence insufficiency is the improvement in the NPC and reduced exophoria at near with the plus lenses.

The blinking was essentially a symptom of the pseudo-convergence insufficiency; she was apparently attempting to clear the image as the planes of accommodation and vergence were constantly shifting. Also, the patient had recently started medication for ADHD. Both ADHD and some of the medications used to treat it are known to cause visual disturbances related to visual acuity, accommodation and vergence; however, it's unclear if the medication played a part in these findings.<sup>1,2</sup>

We decided on a full-time prescription of +0.75D and scheduled the patient return in five to six weeks to assess the impact.

You may ask: Why prescribe full-time and not near only? We've found it a hassle for the patient to constantly be taking the glasses on and off, so we solve this issue by leaving them on. Also, this patient and her mother wanted no part of a bifocal.

At the two-month follow-up, both the mother and child reported that she complied with the use of the glasses and that the blinking stopped within days of wearing them. Her visual acuity remained excellent at 20/20 OD and OS at distance and near both with and without the glasses on. Stereopsis was 20 seconds of arc. Cover test was orthophoria at distance and 4 exophoria at near. NPC was "to the nose" three times.

Since that first visit, we've seen her several times. The blinking has dissipated and not returned. She is still wearing the glasses for school and homework. We'll evaluate her need for the glasses on a yearly basis with a full eye examination, including binocular vision and accommodative testing.

When looking at this case, we see a girl in visual distress, which was alleviated with low plus lenses. The key to this case was performing a basic evaluation of near functions both with and without the tentative prescription in place. We found an immediate response on the cover test and more so with the NPC. Without these data points, we would not have been able to offer the proper treatment. ■

## Clinical Pearl

If you suspect your patient has convergence insufficiency, with low plus in place, retest the near point of convergence, cover test and stereopsis again. If there is a positive change (improved NPC, reduced exophoria on cover test and/or improved stereopsis), consider prescribing the lenses; the patient may actually have a pseudo-convergence insufficiency.

1. Grönlund MA, Aring E, Landgren M, Hellström A. Visual function and ocular features in children and adolescents with attention deficit hyperactivity disorder, with and without treatment with stimulants. *Eye (Lond)*. 2007 Apr;21(4):494-502.  
2. Concerta prescribing information. Janssen Pharmaceuticals, Inc. Dec 2013. Available at: [www.concerta.net/adult/prescribing-information.html](http://www.concerta.net/adult/prescribing-information.html).





# THE TRAINING YOU NEED TO GROW YOUR MEDICAL PRACTICE


## Attention all Optometrists

Attend a boot camp to learn the latest techniques for practicing **full-scope optometry**. Get a step-by-step implementation plan that includes:

- Understanding and implementing *ICD-10* codes
- Improving billing and medical record compliance
- Differentiating vision plan visits vs medical plan visits
- Gaining access to insurance panels
- Maximizing practice productivity and performance
- Motivating and training your staff

Expert faculty:

Scot Morris, OD, FAAO  
John Rumpakis, OD, MBA  
Allergan Eye Care Business Advisors



### Upcoming PATHWAYS IN MEDICAL OPTOMETRY™ Courses

Location	Date
Houston, TX	Saturday, 1/31/2015
Orange County, CA	Saturday, 2/28/2015
Las Vegas, NV	Saturday, 3/14/2015
Ft Lauderdale, FL	Saturday, 4/11/2015
Ledyard, CT	Saturday, 4/18/2015
Memphis, TN	Saturday, 5/9/2015
Teaneck, NJ	Saturday, 5/16/2015
St Louis, MO	Saturday, 9/12/2015
Chicago, IL	Saturday, 10/24/2015
Atlanta, GA	Saturday, 11/14/2015

Each boot camp consists of 1 full-day course.

Cost per course:

First OD registration per practice **\$399 per course\***

All additional practice registrations **\$199 per course\***

\*Cost required per PhRMA guidelines.

Register today at: [AllerganODPathways.com](http://AllerganODPathways.com)

Questions? Call 1-844-750-2020



# When Iris Eyes Aren't Smiling

Cosmetic iris implants aren't approved in the United States. But that doesn't mean you won't see them in your chair. **Edited by Paul C. Ajamian, OD**

**Q** My patient said she heard about iris implants to change her eye color. Have you seen a patient who has had them, and are there any complications?

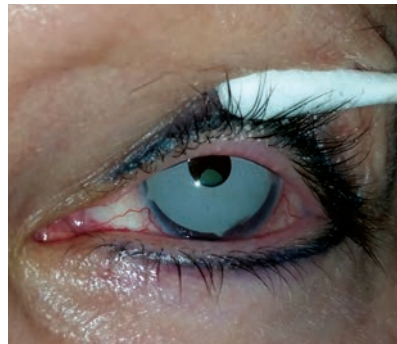**A** For quite some time, people have been seeking ways to change their eye color. The most common method is through colored contact lenses. Yet, some people have sought more permanent solutions.

“Currently, there is no way approved by the FDA to permanently change the color of the iris,” says corneal surgeon Rishi Parikh, MD, of Omni Eye Services, in Atlanta. “However, other countries offer a cosmetic, implantable iris prosthesis that can change the perceived color of the eyes.” So, some patients will get on a plane to have this done.

These silicone prosthetic devices are inserted into the anterior chamber of the eye and essentially sit on the iris. “Unfortunately, the implants are not secured in any way, so they can ‘bounce’ around and cause multiple complications,” Dr. Parikh says.

Potential complications include endothelial cell loss and subsequent corneal edema, elevated intraocular pressure from damage to the trabecular meshwork and angle structures leading to glaucoma, chronic anterior chamber inflammation, anterior and posterior synechia, cataract formation, and decreased visual acuity.<sup>1</sup>

Because of these significant dangers, our professional organizations



**Iris implants, which are not approved by the FDA, can cause corneal edema, decreased visual acuity, cataracts and anterior and posterior synechiae—just to name a few complications.**

strongly discourage implantation of these devices, and doctors should recommend immediate removal if they have already been implanted in a patient, Dr. Parikh says.<sup>2</sup>

He has seen these problems in his own practice. Currently, Dr. Parikh is managing a 48-year-old female patient who presented with gradual decrease in vision in both eyes over the last several years. The patient lives in the United States, but after finding no American surgeon who would do the procedure, she flew to Istanbul in 2011 to have the iris prostheses implanted.

When Dr. Parikh first evaluated the patient, her vision was 20/400 in both eyes. She had severe corneal edema with bullae on both corneas. Both eyes showed multiple areas of peripheral anterior synechia. The iris implants were visible, though somewhat obscuring both pupils. Severe posterior synechia caused both pupils to be fixed. Dense, 3 to

4+ nuclear sclerotic cataracts were visible in both eyes. Endothelial cell counts were greatly reduced and pachymetries were elevated, although her intraocular pressures were within normal limits.

“I attempted iris prosthesis removal, posterior synechialysis and cataract extraction in the right eye, which was successful,” Dr. Parikh says. “However, it has now been two weeks since the surgery and her cornea remains extremely edematous. If it does not resolve—and at this point I don’t expect it to—I’ll likely have to do a DSAEK [Descemet’s stripping automated endothelial keratoplasty] corneal transplant on this eye. If this ends up being successful, I’ll assume her left eye will behave similarly, so I’ll likely do a combined cataract extraction and DSAEK corneal transplant on the left eye.”

After all these surgeries, he hopes to restore her vision to 20/30 in both eyes.

“It’s a great example of an unnecessary cosmetic procedure severely debilitating a patient and producing a great burden on the medical health care system to repair the damage,” Dr. Parikh says. “And she’s lucky it can be repaired—there are many people who may have permanent vision loss.” ■

1. Hoguet A, Ritterband D, Koplín R, et al. Serious ocular complications of cosmetic iris implants in 14 eyes. *J Cataract Refract Surg*. 2012 Mar;38(3):387-93.

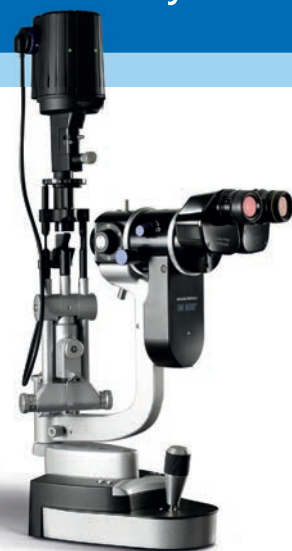2. AAO.org website. Press release: American Academy of Ophthalmology Issues Warning About Iris Implant Surgery to Change Eye Color. Oct 31, 2014, Available at: [www.aao.org/newsroom/release/iris-implant-surgery-warning.cfm](http://www.aao.org/newsroom/release/iris-implant-surgery-warning.cfm).



## Imaging With Depth-of-field. Just Dandy.

What if none of your slit images or video had blurry edges? You would have a Haag-Streit, of course. Invest in one and submerge yourself into our extreme world of depth of field.

Visit [haag-streit-usa.com](http://haag-streit-usa.com) to learn about our entire range of slit lamps and imaging systems.



800.787.5426  
[haag-streit-usa.com](http://haag-streit-usa.com)

© 2015 Haag-Streit USA. All Rights Reserved.

 **HAAG-STREIT**  
USA



# Does Glaucoma Begin in the Brain?

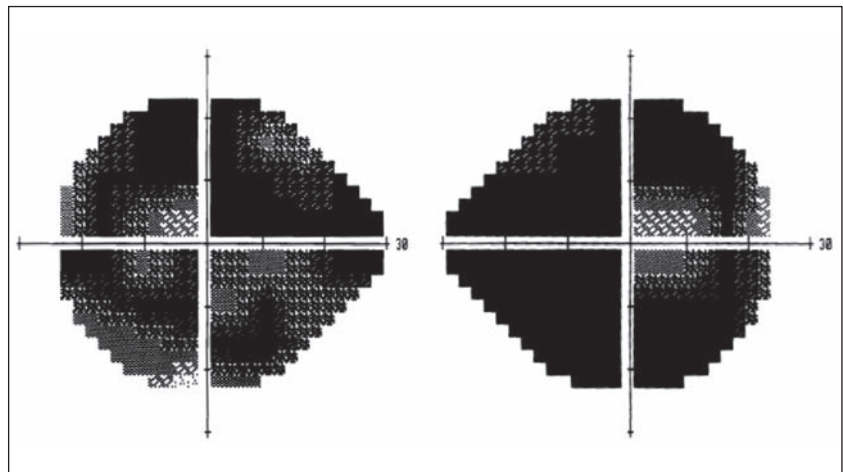
Research links the disease to several neurodegenerative conditions, including Alzheimer's. Should our glaucoma evaluation go beyond the optic nerve?

By Andrew Rixon, OD, and Andrew Gurwood, OD

Is glaucoma primarily a disease of the eye—or of the brain? We know glaucoma results in a progressive optic neuropathy, leading to loss of visual function.<sup>1</sup> But is it really a neurodegenerative disorder akin to Alzheimer's or Parkinson's disease?

Some research has suggested an overlap or a link, or even that such diseases stem from the same source. Indeed, glaucoma's status as a neurodegenerative disorder may place it alongside these devastating conditions. The silver lining is that their shared features may result in an inclusive screening protocol that extends beyond examination of the optic nerve.

Of course, the biological basis of glaucoma has many contributing factors, some of which are still poorly or incompletely understood.<sup>2</sup> However, newer research indicates that glaucoma may originate in the brain. Studies on glaucoma-



**A severe end-stage glaucoma patient shows minimal residual visual field patency. Recent research by Sponsel et al. theorizes that late patency is under CNS control.<sup>8</sup>**

induced mice have shown a type of distal dieback of retinal ganglion cell (RGC) axons that begins as far back as the superior colliculus in the mid-brain.<sup>3-6</sup> This dieback is preceded by damaged axoplasmic transport that progresses distally to proximal to the optic nerve,

implying a direct link to the central nervous system (CNS).<sup>3-6</sup> This is but one scrap of evidence that glaucoma may be more of a brain disorder than an ocular disease.

In this article, we'll discuss the available research, and how it may change the way that we evaluate

glaucoma—and perhaps compel us to identify neurodegenerative disorders further along the visual pathway.

### CNS and Glaucoma IMAGE

The eyes are an extension of the brain. But you wouldn't know it by looking at visual fields. Bilateral visual field loss in glaucoma is only orderly (respecting the vertical midline) in retrochiasmal pathologies. Otherwise, glaucoma defects are typically asymmetric, with loss occurring erratically. The orderly retrochiasmal defects and the apparent disorder of glaucoma defects appears to preclude glaucomatous disease from having a direct connection with the entirety of the brain.

However, Gupta et al. reported the first case of human glaucoma demonstrating neurodegenerative changes in the brain, which correlated with clinical, optic nerve head and visual field findings. This evidence suggests that glaucoma involves the intracranial optic nerve, lateral geniculate nucleus and visual cortex.<sup>7</sup>

Based on that research, Sponsel et al. recently theorized that binocular visual field patency in late glaucoma is under CNS control.<sup>8</sup> The team reasoned that CNS involvement could be confirmed if complementary islands of vision could be preserved in a pair of eyes with severe disease.<sup>9</sup> In their study, the authors paired each glaucoma patient's left visual field locus with its directly corresponding right locus.<sup>8</sup> This pairing resulted in a non-random sparing of the loci corresponding to the defect in the opposite eye. The result was analogous to a jigsaw puzzle fitting together as the corresponding fields matched. This "jigsaw" phenomenon is highly suggestive of focal neurodegeneration

### Sleep Apnea, Glaucoma and the Nervous System

Investigators also considered the role CSF pressure might play in RNFL loss for patients with obstructive sleep apnea (OSA), one of the most common sleep disorders.<sup>19</sup>

The prevalence of normal-tension glaucoma in patients with obstructive sleep apnea varies widely, from 1% to 50%.<sup>20</sup> Researchers have previously proposed that glaucomatous damage results from OSA because it creates transient hypoxia, which, in turn, increases vascular resistance through intermittent cortisol vasoconstriction. This compromises optic nerve head perfusion and oxygenation, with subsequent optic neuropathy.<sup>21</sup> OSA patients may have increased CSF pressure and even papilledema. In this particular scenario the relationship between ICP and OSA presents a tenuous balance. The higher ICP would reduce the translaminal pressure gradient, acting in a protective manner, but the nerve would remain susceptible to the vascular risks created by the patients OSA, as the theory goes.

Xin et al studied the RNFL of patients with severe sleep apnea.<sup>22</sup> CSF pressure was calculated on all patients. Patients with the thinnest RNFL had CSF pressure significantly lower than those with normal RNFL thickness. Also, increased CSF pressure resulted in thickening of the RNFL.<sup>19</sup> The experiment provided additional evidence supporting the critical role of the translaminal pressure difference while elucidating how OSA patients are more prone to glaucomatous damage.<sup>19-22</sup>

coordinated by the CNS.<sup>8</sup> Essentially, islands of monocular function are integrated together in a process that maximizes the binocular visual field.<sup>9</sup> The result appears to confirm meticulous order to a process that was previously considered random and unordered.<sup>8</sup>

Additional evidence suggests glaucomatous damage extends along the entire visual pathway, not just RGC axons.<sup>9</sup> Frezzotti et al. conducted an MRI study comparing a normal control group to a group of patients with advanced primary open angle glaucoma (POAG) who had no additional neurological or ophthalmological disorders.<sup>9</sup> The authors concluded that the findings of widespread brain abnormalities in POAG (such as alterations of the integrity of the white matter and alterations in the volume of the grey matter) extended beyond the visual system in these patients.<sup>9</sup> In addition to structural alterations, the authors found functional connectivity changes among the resting brain networks—specifically the visual and working memory networks.

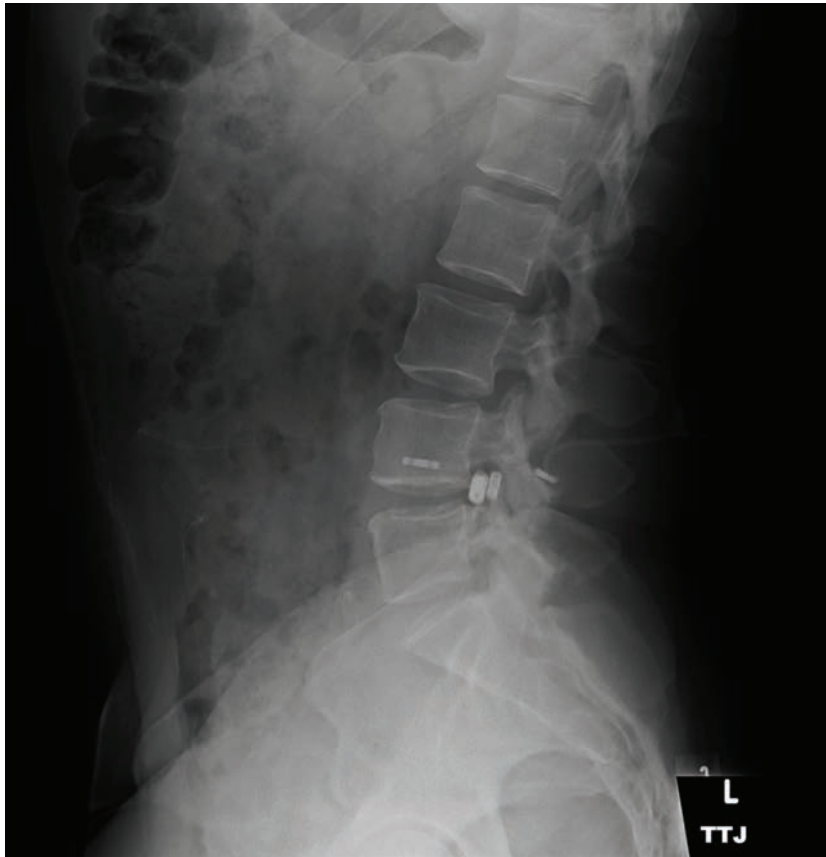
These results may explain why advanced POAG patients may suffer from the impairment of object identification.

Accordingly, some researchers are now considering POAG to be a neurodegenerative vision disorder with the capability to spread throughout the brain.<sup>3-9</sup>

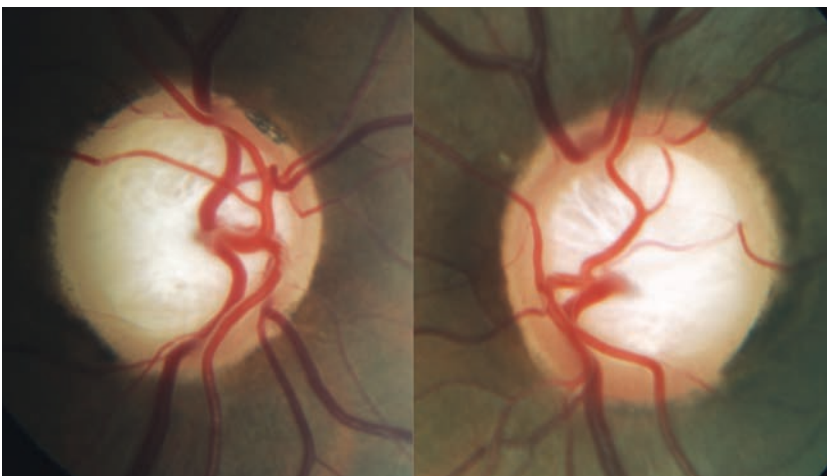
### CSF Pressure and Glaucoma

Research also indicates a link between low cerebrospinal fluid pressure and the development of glaucoma.

Anatomic investigations have shown that a translaminal (across the lamina cribrosa) pressure gradient is formed when intraocular pressure (IOP) is resisted by a combination of retrolaminar tissue pressure and orbital cerebrospinal fluid (CSF) pressure.<sup>10</sup> This translaminal pressure difference may play a role in the pathogenesis of optic nerve disease, including glaucoma.<sup>11</sup> Low CSF pressure, leading to a high translaminal pressure gradient, may to result in barotrauma and subsequent damage to the lamina.<sup>11</sup>



**A pseudotumor cerebri patient with intrathecal spinal catheter, used to determine lumbar peritoneal shunt function by continuous monitoring of CSF pressure. Increased cerebrospinal fluid pressure has been shown to reduce the translaminar pressure gradient, acting in a protective manner.**



**A moderate stage glaucoma patient with substantial loss and reconfiguration of lamellar tissue. Anatomic investigations have shown that a translaminar pressure gradient is formed when IOP is resisted by a combination of retrolaminar tissue pressure and orbital cerebrospinal fluid pressure.**

Conversely, an increased CSF pressure has been shown to be protective in ocular hypertension patients. Here, as the overall translaminar pressure gradient is balanced and, in effect, decreased compared with what it would have been if the CSF pressure was lower, the lamina does not pathologically bow backward to induce classic glaucomatous loss.<sup>11</sup>

Past clinical studies have shown lower lumbar CSF pressure measurements in patients with normal tension glaucoma vs. patients with high tension glaucoma.<sup>13,14</sup>

A recent primate study further enforces the notion that low CSF pressure alone might contribute toward retinal ganglion cell injury and loss. Yang et al. subjected rhesus monkeys to implantation of a lumbar-peritoneal cerebrospinal fluid shunt. In the study, the shunt group had the CSF pressure lowered to 40mm H<sub>2</sub>O, while the shunt remained closed in the control group. Fifty percent of the study monkeys developed morphological disc changes, including progressive reduction in retinal nerve fiber layer thickness, reduction in neuroretinal rim area and volume, and increased cup-to-disc ratio. No morphological changes developed in the control group eyes.<sup>17</sup>

If these findings are applicable to humans, low cerebrospinal fluid pressure may be a risk factor for all forms of optic neuropathy, including glaucoma.<sup>13-17</sup>

The population-based Beijing Eye Study of 3,468 individuals further supports the possible role of low CSF pressure in the pathogenesis of human OAG. It shows that an estimated trans-lamina cribrosa pressure difference has a better association with glaucoma presence and extent of glaucomatous optic neuropathy than IOP.<sup>18</sup>

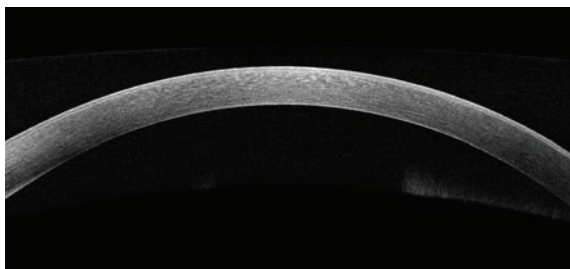


# Advancing Smart OCT with New Imaging Applications

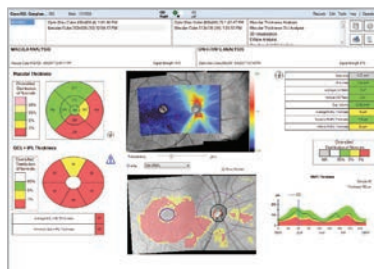
*for Glaucoma & Anterior Segment*



The first retinal OCT with full chamber scan – **NEW! ChamberView™ (15 mm)**



NEW! HD Cornea Scan (9mm)



NEW! PanoMap™ Analysis

## Introducing New Smart OCT Imaging Applications

ZEISS has been at the forefront of industry-defining advancements that have made OCT a standard of care. Today, that leadership continues with NEW imaging applications, including:

- Anterior segment premier module – see the anterior segment like never before.
- PanoMap™ wide-field view helps assess structural damage in glaucoma.

Discover what's new with CIRRUS HD-OCT at  
SECO, booth 813, and Vision Expo East, booth LP7403.



## Alzheimer's Disease and Glaucoma

Recent studies associate glaucoma with Alzheimer's disease (AD), drawing comparisons between the two as they share many mechanistic and biological similarities.<sup>23</sup> AD and glaucoma are both chronic neurodegenerative conditions occurring with higher incidence in patients with advanced age. Both diseases present as a continuum, with greater uncertainty of diagnosis earlier rather than later in the disease process. However, the relationship between the two disorders remains obscure.

Alzheimer's disease is a progressive neurodegenerative disorder characterized by cognitive and memory deterioration, as well as changes in personality, behavioral disturbances and an impaired ability to perform activities of daily living.<sup>24</sup> It is the most common form of dementia in the elderly, accounting for an estimated 60% to 80% of cases.<sup>25</sup> The current diagnosis relies on neuropathology testing, which is both costly and invasive. Correlation between neuropathology and clinical features may be poor because the signs and symptoms can vary with the extent of brain location and involvement.<sup>26,27</sup>

Brains of Alzheimer's patients are characterized by the presence of extracellular senile plaques containing the protein amyloid- $\beta$  and intracellular neurofibrillary tangles (NFTs) of abnormally phosphorylated protein tau.<sup>24,28</sup> The accumulation of amyloid- $\beta$  is believed to interfere with the neuron-to-neuron communication at synapses, and contribute to cell death.<sup>25</sup> This neurotoxic damage and neuronal death occurs across the brain, including the visual cortex.<sup>26</sup> Neurotransmitter function is also impaired, particularly levels of acetylcholine,

### Can SD-OCT Detect Alzheimer's Disease?

A study by Kirbas et al. compared RNFL thickness in patients with Alzheimer's disease (AD) vs. healthy controls. The diagnosis of AD in this study was made only after a full neurological exam and MRI to rule out alternative diagnoses.

The results, using spectral-domain optical coherence tomography (SD-OCT), demonstrated a significant reduction in the total RNFL thickness in the AD group vs. healthy controls.<sup>35</sup>

Overall RNFL thickness was most influenced by selective thinning of the superior quadrant.<sup>35</sup> The other three quadrants were similar to the healthy controls.<sup>35</sup> This selective thinning of the superior quadrant was found in previous studies using time-domain OCT.<sup>36-39</sup> Superior RNFL thinning is consistent with the classic inferior visual field defects seen in patients with both AD and OAG.

To explain this relationship, investigators cite primary involvement of axons from the superior retina in the cuneal gyrus of the primary visual cortex.<sup>35</sup> The authors propose, however, the cause of RNFL thinning in AD is likely due to the death of retinal ganglion cells coupled with retrograde degeneration from loss of cortical neurons.<sup>35</sup> They conclude the use of SD-OCT is rapid, repeatable, noninvasive and could operate as a form of early detection for AD.<sup>35</sup> The study also seems to imply doctors consider the presence of AD in normal-tension glaucoma cases.<sup>35</sup>

known to be crucial to the functioning of retinal cells.<sup>30,31</sup>

The axons of the RGCs create the nerve fiber layer, the optic nerve and then synapse directly with multiple regions of the brain.<sup>26-34</sup> Hinton and associates, who in 1986 first reported histopathologic evidence of retinal degeneration in AD patients,<sup>32</sup> conducted a postmortem analysis on the optic nerves and retinas of patients with and without AD. The AD samples demonstrated widespread axonal degeneration in the optic nerves. This degeneration was accompanied by substantially reduced RNFL thickness and significant loss of RGCs.<sup>32</sup> Large diameter RGCs (magnocellular, or M, cells) and axons were predominantly affected.<sup>33</sup> Aggregates of amyloid- $\beta$  and neurofibrillary plaques of tau were found in the retina of AD patients.<sup>26</sup>

Retinal neurons are now known to be sensitive to the neurotoxicity of amyloid- $\beta$  aggregates.<sup>30</sup> Further, research associates amyloid- $\beta$  deposition in the RGC layer with RGC

apoptosis.<sup>26-34</sup> This also accounts for, and contributes to, thinning of the RNFL along with the morphological changes characteristically seen in optic nerve heads of known glaucoma patients.

Several studies using multiple imaging technologies have examined the relationship between RNFL and AD.<sup>36-39</sup> As RGC apoptosis is associated with proteins found in AD, the RNFL can serve as a biomarker for AD. Noninvasive in vivo measurements of that biomarker could lead to easier AD diagnosis.<sup>26-36</sup>

Reports also suggest fluid biomarkers in the CSF reveal shared characteristics between AD and glaucoma.<sup>29</sup> Additionally, aqueous humor itself may be useful in detecting AD biomarkers that may be involved in the development or progression of both diseases.<sup>42</sup> A recent study investigated aqueous humor samples collected from patients with cataracts, POAG and exfoliation glaucoma.<sup>42</sup> Specifically, they evaluated apolipoprotein (Apo)



MANUFACTURED  
IN THE USA

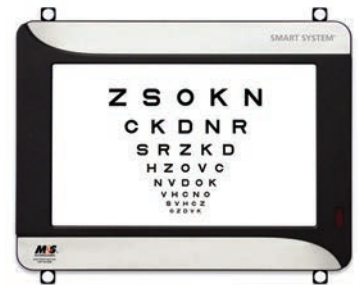# Quality Comes Standard

**At M&S Technologies, we understand that a quality product makes for a quality customer experience.**

But there's more to a quality product than just what comes out of the box. There's service, there's support, there's reliability. M&S provides all of that. Our sales team is available to walk you through the many features and functions of the Smart System®, and our in-house technical team is standing by to respond to all of your service issues or questions.

We've been in business for almost 25 years and we take your business as seriously as you do. "Good enough" isn't good enough. If you're looking for a high-quality, comprehensive visual acuity testing system that comes with the best customer service and most attentive technical support in the industry, give us a call.

**Attending SECO? Stop by Booth 1413 and demo our NEW Sports Vision Performance protocol!**



*The Smart System 20/20 USA, shown with optional Glare Lights*



M&S holds US Patents 7,354,155; 7,926,948; 8,425,040; 8,167,429; 8,419,184 & 8,550,631. Other Patents Pending.

©2015 M&S Technologies, Inc. Smart System and M&S are registered trademarks of M&S Technologies, Inc. All Rights Reserved.

**M&S**  
TECHNOLOGIES®

The First Choice in  
Vision Testing Systems

[www.mstech-eyes.com](http://www.mstech-eyes.com)  
1-877-225-6101



and transthyretin (TTR).<sup>42</sup> Finding an ApoE marker increases the risk of AD threefold. Further, it is often detected during the aggregation and clearance of amyloid- $\beta$ , the major component of senile plaques in AD.<sup>31</sup> The aqueous samples evaluated revealed multiple elevated biomarkers of AD in patients with POAG and exfoliation glaucoma, but not in normal controls.<sup>42</sup> The study also found that patients' visual field mean deviation values positively correlated with the aqueous levels of ApoE and TTR (the higher the deviation, the higher the biomarkers and the more severe the ocular neuronal loss).<sup>42</sup>

This information implies a positive association between glaucoma and AD.<sup>26-42</sup> If there were a positive association, patients diagnosed with one condition might be automatically screened for the other condition, streamlining the process.

However, not all research shows a link between AD and glaucoma. Keenan, et al. found no additional risk of AD following diagnosis of POAG.<sup>43</sup> The authors concluded that, although POAG and AD are neurodegenerative diseases that share some pathological features, their coexistence at the individual level is no greater than chance.<sup>43</sup> A study from Denmark investigating the 25-year rate of developing dementia/Alzheimer's disease in patients previously diagnosed with normal-tension glaucoma found no association between the two diseases.<sup>44</sup>

Ou et al. also concluded no positive association between the two diseases. In fact, the OAG patients were actually found to have a decreased rate of AD diagnoses.<sup>45</sup>

In contrast to the above results, a longitudinal record linkage study randomly sampled a data set of two million beneficiaries from the

Taiwan National Health Insurance Research database who were followed for eight years.<sup>46</sup> Investigators concluded that in elderly patients, POAG is a significant predictor of AD, but not of Parkinson's disease.

The first prospective longitudinal study evaluating the relationship between OAG and dementia, with active screening for both dementia and glaucoma, found a strong association between OAG and dementia.<sup>50</sup> Although their analysis did not detail the etiology of dementia, the authors inferred a link between AD and glaucoma given that AD was represented as the cause of dementia for most of the patients.<sup>44</sup>

All in all, the multitude of biological and mechanistic similarities between these two neurodegenerative disorders is vast. But, to date, no consensus on the association exists in the literature.<sup>27-47</sup>

Glaucoma's complexity is astounding, and the evidence for co-contributing CNS disease is truly compelling. Although these initial reports are critical in furthering our understanding of the disease, more investigation is needed before widespread adoption of new evaluation and treatment strategies.

The future possibility of unlocking the seemingly intangible mysteries of the brain and glaucoma becomes more tangible with each additional scientific report. At present we must hone our skill in early diagnosis and management of this disease with technology and knowledge that is clinically applicable today. ■

1. American Optometric Association. Optometric Clinical Practice Guideline: Care of the Patient with Open Angle Glaucoma. Available at: <http://www.aoa.org/documents/optometrists/CPG-9.pdf> (accessed December 14, 2014).

2. Weinreb RN, Aung T, Medeiros FA. The Pathophysiology and Treatment of Glaucoma A Review JAMA. 2014;311(18):1901-11

3. Crish SD, Sappington RM, Inman DM, et al. Distal axonopathy with structural persistence in glaucomatous neurodegeneration. *Proc Natl Acad Sci U S A*. 2010;107:5196-5201.

4. Schlamp CL, Li Y, Dietz JA, et al. Progressive ganglion cell loss and optic nerve degeneration in DBA/2J mice is variable and asymmetric. *BMC Neurosci*. 2006;7:66.

5. Crish SD, Dapper JD, MacNamee SE, et al. Failure of axonal transport induces a spatially coincident increase in astrocyte BDNF prior to synapse loss in a central target. *Neuroscience*. 2013;229:55-70.

6. Zhang S, Wang H, Lu Q, et al. Detection of early neuron degeneration and accompanying glial responses in the visual pathway in a rat model of acute intraocular hypertension. *Brain Res*. 2009;1303:131-143.

7. Gupta N, Ang LC, Noël de Tilly L, et al. Human glaucoma and neural degeneration in intracranial optic nerve, lateral geniculate nucleus, and visual cortex. *Br J Ophthalmol*. 2006;90:674-8.

8. Sponsel WE, Groth SL, Satsangi N, et al. Refined data analysis provides clinical evidence for central nervous system control of chronic glaucomatous neurodegeneration. *Trans Vis Sci Technol*. 2014 May 6;3(3):1.

9. Frezzotti P, Giorgio A, Motolese I, et al. Structural and Functional Brain Changes beyond Visual System in Patients with Advanced Glaucoma. *PLoS ONE*. 2014 Aug 27;9(8):e105931. doi:10.1371/journal.pone.0105931

10. Jonas JB, Berenshtein E, Holzbach L. Anatomic relationship between lamina cribrosa, intraocular space, and cerebrospinal fluid space. *Invest Ophthalmol Vis Sci* 2003;44: 5189-95.

11. Yang D, Fu J, Hou R, et al. Optic neuropathy induced by experimentally reduced cerebrospinal fluid pressure in monkeys. *Invest Ophthalmol Vis Sci*. 2014;55:3067-73.

12. Wostyn P, De Groot V, Van Dam D, et al. *Invest Ophthalmol Vis Sci*. 2014;55:5351-2.

13. Berdahl JP, Fautsch MP, Stinnett SS, Allingham RR. Intraocular pressure in primary open angle glaucoma, normal tension glaucoma, and ocular hypertension: a case-control study. *Invest Ophthalmol Vis Sci*. 2008;49:5412-18.

14. Ren R, Jonas JB, Tian G, et al. Cerebrospinal fluid pressure in glaucoma: a prospective study. *Ophthalmology*. 2010;117:259-66.

15. Wang N, Xie X, Yang D, et al. Orbital cerebrospinal fluid space in glaucoma: the Beijing intracranial and intraocular pressure (iCOP) study. *Ophthalmology* 2012 Oct;119(10):2065-73.

16. Xie XB, Zhang XJ, Fu J, et al. Noninvasive intracranial pressure estimation by orbital subarachnoid space measurement: the Beijing Intracranial and Intraocular Pressure (iCOP) study. *Crit Care* 2013 Jul 24;17(4):R162. doi:10.1186/cc12841.

17. Yang D, Fu J, Hou R, et al. Optic neuropathy induced by experimentally reduced cerebrospinal fluid pressure in monkeys. *Invest Ophthalmol Vis Sci*. 2014;55:3067-73.

18. Jonas JB, Wang NL, Wang YX, et al. Estimated trans-lamina cribrosa pressure difference versus intraocular pressure as biomarker for open-angle glaucoma. *The Beijing Eye Study 2011*. *Acta Ophthalmol*. 2014 Jun 24. doi: 10.1111/aos.12480. [Epub ahead of print].

19. Xin C, Zhang W, Wang L, et al. Changes of visual field and optic nerve fiber layer in patients with OSAS. *Sleep Breath*. 2014 May 8. [Epub ahead of print].

20. Sergi M, Salerno DE, Rizzi M, et al. Prevalence of Normal Tension Glaucoma in Obstructive Sleep Apnea Syndrome Patients. *J Glaucoma* 2007 Jan;16(1):42-46.

21. Lin PW, Friedman P, Lin HC, et al. Normal Tension Glaucoma in Patients With Obstructive Sleep Apnea/Hypopnea Syndrome. *J Glaucoma* 2011;Dec;20(9):553-558

22. Lee AG, Golnik K, Kardon R, et al. (2002) Sleep apnea and intracranial hypertension in men. *Ophthalmology*. 2002 Mar;109(3):482-485

23. Wostyn P, Audenaert K, De Dyn PP. Alzheimer's disease: Cerebral Glaucoma? *Medical Hypotheses*. 2010 Jun;74(6):973-977

24. Bullock R, Hammond G. Realistic expectations: the management of severe Alzheimer disease. *Alzheimer Dis Assoc Disord* 2003;17(Suppl. 3):S80-5.

25. 2104 Alzheimer's Disease Facts and Figures. Available

at: [http://www.alz.org/downloads/Facts\\_Figures\\_2014.pdf](http://www.alz.org/downloads/Facts_Figures_2014.pdf) (accessed December 13, 2014).

26. Chang LY, Lowe J, Ardiles A, et al. Alzheimer's disease in the human eye. Clinical tests that identify ocular and visual information processing deficit as biomarkers. *Alzheimers Dement*. 2014 Mar;10(2):251-61.
27. Guo L, Duggan J, Cordeiro MF. Alzheimer's Disease and Retinal Neurodegeneration. *Current Alzheimer Research*. 2010 Feb;7(1):3-14.
28. Stancu IC, Vasconcelos B, Terwel D, Dewachter I. Models of  $\beta$ -amyloid induced Tau-pathology: the long and "folded" road to understand the mechanism. *Mol Neurodegener*. 2014 Nov 18;9:51.
29. Fagan AM, Perrin RJ. Upcoming candidate cerebrospinal fluid biomarkers of Alzheimer's disease. *Biomarkers Med*. 2012 Aug;6(4):455-476
30. Ohno-Matsu K. Parallel findings in age-related macular degeneration and Alzheimer's disease. *Prog Retin Eye Res*. 2011;30:217-238.
31. Albert MS, Dekosky ST, et al. The diagnosis of mild cognitive impairment due to Alzheimer's disease: Recommendations from the National Institute on Aging-Alzheimer's Association workgroups on diagnostic guidelines for Alzheimer's disease. *AlzheimersDementia* 2011 May;7(3):270-9
32. Hinton DR, Sadun AA, Blanks JC, Miller CA. Optic-nerve degeneration in Alzheimer's disease. *N Engl J Med*. 1986 Aug 21;315(8):485-7
33. Sadun AA, Bassi CJ. Optic nerve damage in Alzheimer's disease. *Ophthalmology* 1990 Jan;97(1): 9-17
34. Guo L, Salt TE, Luong V, et al. Targeting amyloid-beta in glaucoma treatment. *Proc Natl Acad Sci U S A*. 2007 Aug 14;104(33):13444-9.
35. Kirbas S, Turkyilmaz K, Anlar O, et al. Retinal nerve fiber layer thickness in Patients with Alzheimer Disease. *J Neuro-ophthalmol*. 2013 Mar;33(1):58-61
36. Berisha F, Fekke GT, Trempe CL, et al. Retinal Abnormalities in early Alzheimer's disease. *Invest Ophthalmol Vis Sci*. 2007 May;48(5):2285-9.
37. Kesler A, Vakhapova V, Korczyn AD, et al. Retinal thickness in patients with mild cognitive impairment and Alzheimer's disease. *Clin Neurol Neurosurg*. 2011;113:523-6.
38. Paquet C, Boissonnot M, Roger F, et al. Abnormal retinal thickness in patients with mild cognitive impairment and Alzheimer's disease. *Neurosci Lett*. 2007 Jun 13;420(2):97-99.
39. Iseri PK, Altinas Ö, Tokay T, Yüksel N. Relationship between cognitive impairment and retinal morphological and visual functional abnormalities in Alzheimer disease. *J Neuro-ophthalmol*. 2006 Mar;26(1):18-24.
40. Danesh-Meyer HV, Birch H, Ku JY, et al. Reduction of optic nerve fibers in patients with Alzheimer disease identified by laser imaging. *Neurology* 2006 Nov 28;67(10):1852-4.
41. Kurma SA, Akar G, Altun A, et al. Confocal scanning laser tomography of the optic nerve head on the patients with Alzheimer's disease compared. *Int Ophthalmol* 2014 Dec;34(6):1203-11.
42. Inoue T, Kawaji T, Tanihara H. Elevated levels of multiple biomarkers of Alzheimer's disease in the aqueous humor of eyes with open angle glaucoma. *Invest Ophthalmol Vis Sci*. 2013 Aug 9;54(8):5353-8.
43. Keenan TDL, Goldacre R, Goldacre MJ. Associations between primary open angle glaucoma, Alzheimer's disease and vascular dementia: record linkage study. *Br J Ophthalmol*. 2014 Nov 4;0:1-4 doi: 10.1136/bjophthalmol-2014-305863. [Epub ahead of print]
44. Bach-Holm D, Kessing SV, Mogensen U, et al. Normal tension glaucoma and Alzheimer disease: comorbidity? *Acta Ophthalmol* 2012 Nov;90(7):683-5
45. Ou Y, Grossman DS, Lee PP, et al. Glaucoma, Alzheimer disease and other dementia: a longitudinal analysis. *Ophthalmic Epidemiol* 2012 Oct;19(5):285-92.
46. Lin IC, Wang YH, Wang TJ, et al. Glaucoma, Alzheimer's Disease, and Parkinson's Disease: An 8-Year Population-Based Follow-Up Study. *PLoS ONE* 2014 Oct 2;9(9):e108938. doi: 10.1371/journal.pone.0108938.
47. Helmer C, Malet F, et al. Is There a Link between Open-Angle Glaucoma and Dementia?: The Three-City-Alienor Cohort. *Ann Neurol* 2013;74:171-179.

Better  
comfort.  
Better  
retention.  
Better  
results.



Take the **VeraPlug™** challenge.

Compare the new VeraPlug to the plug you're using now and see the difference for yourself.

 Visit [lacrivera.com/challenge](http://lacrivera.com/challenge) for your free sample

A FRESH PERSPECTIVE™



LACRIVERA

[lacrivera.com](http://lacrivera.com) (855) 857-0518

2500 Sandersville Rd • Lexington KY 40511 USA

# Topical AMD Therapy: Will it Make a Splash?

The new agent squalamine looks to improve outcomes—and could potentially expand the OD’s role. **By Robert Murphy, Contributing Writer**

**T**he vision loss that may accompany wet age-related macular degeneration is vexing not only owing to the toll it exacts on the patient’s quality of life but also because the disease often resists an eye doctor’s best efforts to prevent such an outcome. This is tremendously frustrating to any clinician who manages these patients. While the concern of eye doctors is to act in their patients’ best interests, outcomes may not always match intentions. Clinicians are then left to accept a rather dismal course of events, with patients undergoing chronic therapy and not necessarily showing notable improvement.

With the introduction of the injectable anti-vascular endothelial growth factor (VEGF) agent Avastin (bevacizumab, Genentech) in 2004 as an ingenious off-label use and then the FDA approval of Lucentis (ranibizumab, Genentech) in 2006, doctors finally had treat-

ments with which to arrest the advance of macular degeneration in some patients, and to improve vision to by potentially as much as three lines of Snellen acuity. The introduction of Eylea (aflibercept, Regeneron) in 2011 brought to the scene a third medication of this kind. Its duration of activity is said to be longer than that of its counterparts, thus perhaps allowing for greater intervals between injections, although clinical response can vary. “It seems to do a much better job of ‘drying’ the area, with less frequent injections,” says Paul M. Karpecki, OD.

“Currently, the best available treatment for wet AMD is intravitreal anti-VEGF, which has been a tremendous boon for a disease where there was previously little hope of vision stabilization, let alone any sort of recovery,” says Elyse L. Chaglasian, OD, an associate professor at the Illinois College of Optometry in Chicago.

In some patients with wet AMD, however, intravitreal anti-VEGF injections have resulted in little more than marginal visual improvement. Their limited clinical efficacy is not the only problem. The injections themselves may not be painful—retina specialists of course use topical lidocaine to numb the site—but no one looks forward to having a needle stuck in their eye. Returning for monthly or otherwise periodic injections is inconvenient not only for the patient but also in many cases for the caregiver who must drive the patient to the clinic. The cost to insurers, and by extension to society—the on-label drugs cost about \$2,000 per injection—cannot be gainsaid. Fortunately, most patients can participate in copay assistance programs, often making the cost less than that of off-label options, says Dr. Karpecki.

All of which leaves eye doctors in something of a quandary. “The current system of inject, inject, inject is



really not sustainable,” says Steven Ferrucci, OD, of the US Department of Veteran Affairs in North Hills, Calif., and a professor at the Southern California College of Optometry at Marshall B. Ketchum University in Los Angeles. “So, we have to find other ways—whether it’s longer-acting injections, or drops, or an oral agent that works as an adjunct to allow for fewer injections. I don’t know what the answer is, but we do need to do something.”

Anti-VEGF injections, while demonstrably beneficial, suffer from some fundamental drawbacks. A care protocol revolutionized a decade ago is already in need of another leap forward.

This is why ongoing development of the topical anti-angiogenic agent squalamine lactate 0.2% (Ohr Pharmaceutical) is exciting to the eye doctors who follow its progress. The prospect of an eye drop that patients may instill daily to inhibit neovascular growth in wet AMD and forestall the consequent vision loss is one eye doctors look to as a promising potential means to counteract the frustration that occurs with present treatment options.

### Swimming With Sharks

Squalamine is a small-molecule anti-angiogenic aminosterol agent that inhibits multiple growth factors and pathways responsible for angiogenesis. These include not only VEGF, but also platelet-derived growth factor (PDGF) and basic fibroblast growth factor (bFGF). It binds to and “chaperones” the messenger protein calmodulin to prevent growth factor signaling.

Discovered in the tissues of the dogfish shark (*Squalus acanthias*), squalamine was found early on to have potent broad-spectrum antimicrobial activity, which may

### AMD Drug Delivery Developments

The unpleasantness and inconvenience of intravitreal injections in treating wet AMD, plus their high cost, put a premium on innovative ways to lengthen an anti-angiogenic medication’s activity through sustained release once it is injected. Alternatively, researchers are looking for effective ways to deliver a compound through topical means to complement, or perhaps one day supplant, intravitreal injections in these patients.

Exploring the topical route, researchers wish to develop means to penetrate the eye’s anatomical barriers so that an agent can arrive at the target tissue in adequately potent therapeutic concentrations. Using animal models, researchers at University College of London were able to create formulations of tiny nanoparticles loaded with Avastin to deliver significant topical concentrations of the drug to the macula. This is especially notable in that Avastin and Lucentis were thought to consist of molecules too large to penetrate the cornea as an eye drop.

Lucentis-maker Genentech has reported progress in using a device known as a port delivery system aimed at reducing the number of injections in wet AMD patients. The tiny capsule is implanted in the eye above the iris. In subsequent visits, the doctor can then refill the capsule with an anti-VEGF agent such as Lucentis. Early research showed that the delivery system can provide four months of therapy before the next refill.

Another new sustained-release drug-delivery device is under development at pSivida, whose Durasert technology is designed to deliver Avastin through an injection of a powdery, bioerodable and porous silicon capsule. The drug is released as the silicon erodes. The Durasert is also designed to treat diabetic macular edema, posterior uveitis and glaucoma.

Meantime, Ophthotech has completed a Phase II study of Fovista, an anti-platelet-derived growth factor (PDGF) agent designed for use with anti-VEGF drugs. The study found that patients treated with a combination of Fovista and Lucentis gained an average of 10.6 letters vs. 6.5 letters for those receiving Lucentis monotherapy. Phase III studies are underway.

Fovista prevents PDGF from binding to receptors on pericytes, the external cells of new blood vessels, thereby stripping off these cells. This leaves the endothelial cells unprotected and thus more readily vulnerable to the effects of anti-VEGF agents. This combined activity would enhance the treatment’s efficacy and thereby reduce the number of injections needed to bring about a desirable therapeutic effect.

explain the predator’s hardy resistance to infection. Besides its use in wet AMD, squalamine is currently being investigated for the treatment of diabetic retinopathy.

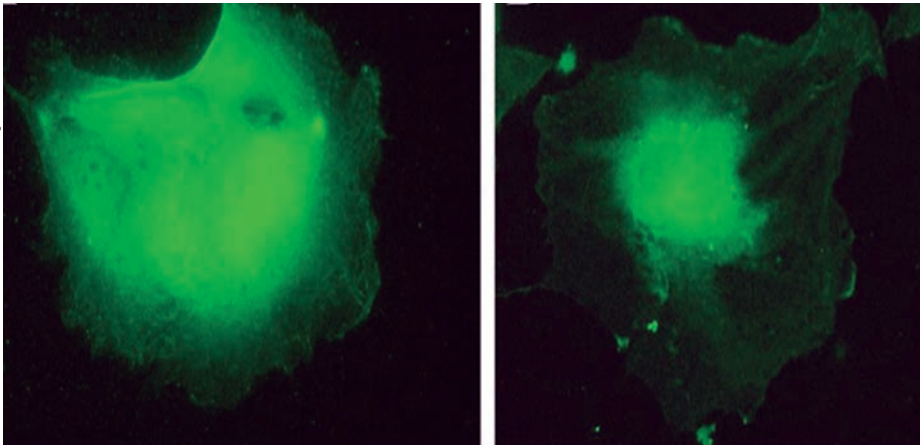
Its numerous avenues of anti-angiogenic activity give reason to suspect that squalamine may yield clinically salutary effects in a synergistic mechanism with anti-VEGF injectable medications. “The drug addresses multiple endogenous protein growth factors of angiogenesis,” says Joseph J. Pizzimenti, OD, an attending optometric physician at the Nova Southeastern Univer-

sity College of Optometry in Ft. Lauderdale. “Attacking choroidal neovascularization from several pathways represents the best chance of minimizing vision loss.”

Which sounds good in theory, but how much of the topical drop actually reaches the target tissue in the posterior segment? There’s no way to know other than what might be inferred from clinical outcomes. But the molecule’s mechanism of drug delivery suggests it may achieve therapeutic levels.

Dr. Chaglasian charts the drop’s itinerary on its journey to the

Image: Ohr Pharmaceutical



**At left is an untreated endothelial cell. At right is a cell treated with squalamine—the drug binds to the messenger protein calmodulin to prevent growth factor signaling.**

macula. Squalamine first enters the conjunctiva and anterior sclera, and begins penetrating the corneal epithelium. “A mucoadhesive agent increases corneal residence time so that the drug diffuses slowly to the posterior sclera, resulting in delivery of sustained concentrations of squalamine via retardation of loss of the drug through nasolacrimal duct drainage.” Viscosity-enhancing properties soothe the ocular surface, a penetration-enhancing agent allows for greater diffusion into the corneal epithelium and a stabilizing agent acts as an antioxidant and can thwart the chemical degradation of the formulation, she explains. “Buffering agents allow for the drug to be at a near-neutral pH, compatible with ocular administration,” Dr. Chaglasian says. “The tonicity modifier in the formulation produces the appropriate osmolality of the ophthalmic formulation.”

## **Trials and Ministrations**

Even the most glorious drug delivery mechanism is worth little if the drug being delivered arrives at its target with little to say for itself. The results from the recently completed Phase II FDA trials show

visual improvement at nine months in wet AMD patients receiving a combination of Lucentis injections plus squalamine vs. monotherapy with just Lucentis.<sup>1</sup>

Ohr’s interim data show that 48.3% of those receiving the combination therapy had gains of three lines or more of best-corrected visual acuity on the ETDRS chart, vs. 21.2% treated solely with Lucentis. Not only that, those getting squalamine plus Lucentis were twice as likely to gain five or more lines of vision compared with the study’s monotherapy arm. Overall, patients treated with the combined topical/injectable regimen went home with a mean visual acuity gain of 10.4 letters compared with 6.3 for those treated only with Lucentis.<sup>1</sup>

The visual gains sometimes come swiftly. “One of the interesting things is that a lot of these patients recovered vision in the short term,” says Sherrol A. Reynolds, OD, associate professor at Nova Southeastern University College of Optometry. “The study was nine months, but some of them had improvement of their vision in four to eight weeks.”

While visual acuity is where the

rubber hits the road, there was also improvement in physiological parameters. The combination treatment resulted in an average decrease of 139 $\mu$ m in central subfield thickness vs. 117 $\mu$ m in the monotherapy group. A series of cases reported last year were characterized by resolution of subretinal hyperreflective material as well as intraretinal and subretinal edema.<sup>2</sup>

This may look promising, but there’s a catch. Ohr’s primary endpoint in the

study looked at the potential for reducing the number of injections needed to manage these patients optimally, and this didn’t happen. “The really disappointing fact is that it did not result in a decrease in the number of injections,” says Mark T. Dunbar, OD, director of optometry at the Bascom Palmer Eye Institute in Miami. “So, this is not a medication that can stand alone as monotherapy, or at least it would seem that way.”

Patients still receive the same amount of injections, albeit with some improvements in visual acuity because of the additional agent added to the regimen. “I’m not sure that it’s really significantly better,” Dr. Dunbar says, “but it is a little bit better in the eyes that received the combination.”

Phase III studies are set to begin sometime in the first half of this year. Here again the visual endpoints will be the same as those of Phase II, yet with a larger patient population.

“The FDA has agreed to a nine-month primary efficacy endpoint based on the proportion of patients achieving a greater than or equal to three-line gain in visual acuity,” Dr. Chaglasian says. “Considering that



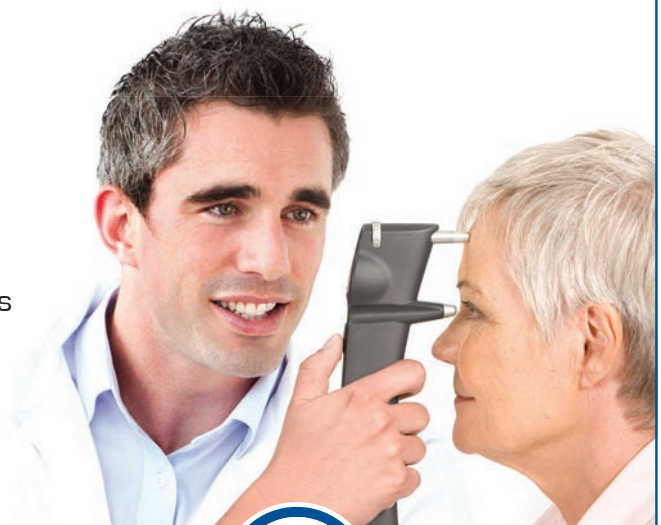# MEASURE IN COLOR

ICARE COLORS AT A TRADE SHOW NEAR YOU!\*

RANDALL THOMAS, OD  
& RON MELTON, OD

“As soon as we had the Icare tonometry performed on ourselves, our skepticism turned to amazed acceptance and we couldn’t wait to use it on our patients. It is indeed asymptomatic in virtually all instances and certainly atraumatic in all cases.”

\* Call 609.617.3403 or visit Icare at SECO Booth #407 for show specials and colored Icare Tonometers at no additional cost, while supplies last.

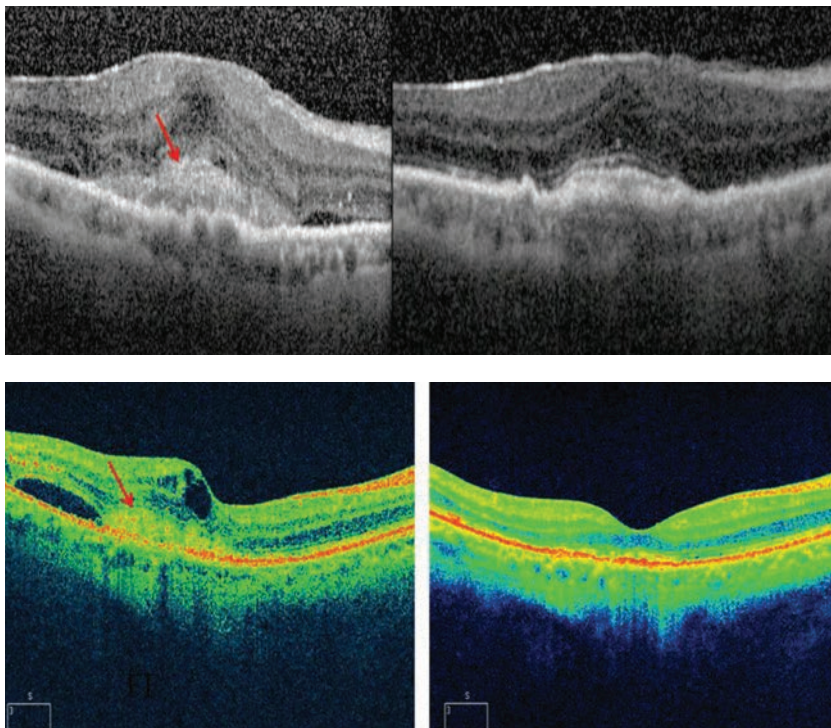


VISIT ICARE AT SECO BOOTH #407



NO CALIBRATION  
NO DROPS, NO AIR





Images: Oti Pharmaceuticals

**Subretinal hyperreflective material is a marker for choroidal neovascular activity (images on right). Combination therapy with squalamine and ranibizumab resulted in the resolution of subretinal hyperreflective material as well as intraretinal and subretinal edema (images on left). The top images show a patient on combination therapy who had improvement of 21 letters of vision. A similar patient on the bottom improved by 26 letters.**

the nine-month data of the Phase II study showed twice the number of patients who received squalamine twice daily with ranibizumab as needed achieved this goal compared to those receiving ranibizumab monotherapy, this would appear to be a very achievable endpoint.”

Dr. Chaglasian describes the upcoming study’s design and timeline. During the first year of the study, she says, patients will be randomized to receive monthly ranibizumab injections with squalamine drops twice daily or monthly ranibizumab injections with placebo eye drops. During the second year, they will receive ranibizumab injections as needed plus squalamine or placebo drops. “Though it will be a two-year study, the FDA will look

at the data at nine months,” she says. “Considering this drug was fast-tracked in 2012, there is a possibility it will be approved prior to 2017.”

### Purview of Optometry?

The most fundamental benefit of a potentially efficacious topical treatment for wet AMD, which is also readily amenable to patient satisfaction and compliance, is of course improved visual outcomes. Meanwhile, what might the prospective FDA approval of topical squalamine mean for the role of optometrists in managing these patients?

Dr. Chaglasian is optimistic. “The approval of a topical eye drop for AMD would be groundbreaking,” she says. “Up until now, once

an optometrist detected wet AMD, that patient was most likely lost to our practice. We will no longer need to refer every patient for painful, costly, frequent injections to a retinal specialist. Having the capability to prescribe a safe, effective drop for this disease is equivalent to what we already do for our glaucoma patients. This would be an absolute win-win for our patients and our profession.”

Maybe so, but we still must await the Phase III results and further clinical experience with topical squalamine in treating wet AMD to gain a fuller sense of its ultimate implications for the OD’s role in managing these patients. Time will tell.

“I think as it stands now, this is going to remain a disease in the hands of the retinal specialists,” Dr. Dunbar says. Patients will still be followed closely by the treating ophthalmologist, as they’ll continue to need intravitreal injections on a regular basis. “If you’ve got a good relationship with a retinal specialist and you’re following a treat-and-extend protocol, an ophthalmologist or treating retinal specialist may be comfortable having an optometrist follow that patient until they develop fluid, and then at that point you refer them back,” he says. “But I don’t see a situation where an optometrist is going to be following these patients alone only on a topical eye drop, unless they get to a point where they’re stable.” He says the data have not yet borne out that possibility. Should that eventually happen, perhaps the patient may remain under the abiding purview of the optometrist’s care.

That is, the optometrist’s role in managing patients with wet AMD extends beyond treatment to the kinds of things they already do, namely diagnosis, monitoring and patient education.

For instance, we know that the AREDS study found that the long-term use of the antioxidant carotenoids lutein and zeaxanthin may forestall to some degree the progression of macular degeneration in some patients. Optometrists may wish to encourage patients to take these as supplements as well as to embrace a diet rich in antioxidants, including certain fruits and vegetables, especially dark, leafy ones.

Initial diagnosis and ongoing monitoring of wet AMD patients will remain key roles for optometrists. The use of spectral-domain ocular coherence tomography (SD-OCT) is a critical tool in doing so.

“You still need to closely monitor and educate patients, so they understand when there are changes in their vision,” Dr. Reynolds says. Instruct patients to regularly use the Amsler grid at home, for example.

### ‘It’s Getting Better All the Time’

Paul McCartney had reason for optimism when he wrote that lyric in 1967, and it’s not a stretch to say that optometrists have reason for, let’s say, measured optimism when contemplating potential advances in the management of wet AMD patients.

Topical squalamine may not represent the Holy Grail. Yet, its multi-pronged mechanism of anti-angiogenic activity coupled with its convenient and noninvasive delivery method suggest a potentially useful addition to the treatment of these patients, not to mention significant prospective cost savings in a global sense.

The potential impact on optometry may readily be inferred. “I would like to think that we could start prescribing the drop, and that would allow us to be more engaged with retinal specialists, and to follow these patients and comanage them with retinal specialists more,” Dr. Ferrucci says.

If topical squalamine is shown to improve visual outcomes in treating AMD in a safe, effective and patient-friendly manner, patients may stand to benefit in a significant way. Optometrists likewise figure to expand their role in managing these patients. And not just to expand this role, but to enjoy the satisfaction of seeing their patients experience better outcomes. Talk about a win-win scenario. ■

*Robert Murphy is a freelance medical writer in Watertown, NY.*

1. Abraham P. Interim Phase 2 Results of Squalamine Lactate Ophthalmic Solution 0.2% (OHR -102) in Neovascular Age-Related Macular Degeneration. Paper presented at American Academy of Ophthalmology 2014 Retina Subspecialty Day, October 18; Chicago.  
2. Ohrpharmaceutical.com. Press release: Ohr Pharmaceutical Announces Additional Squalamine Eye Drop (OHR-102) Phase II Clinical Data in Wet-AMD; The IMPACT Study. August 13, 2014.

# COMPLETE PATIENT LUXURY



HCP-7000  
CHART PROJECTOR

HRK-8000A  
AUTO  
REF-KERATOMETER

HDR-7000  
DIGITAL  
REFRACTOR



HRT-7000  
INTEGRATED TABLE WITH POWER ARM & CHAIR

## DIGITAL REFRACTION SYSTEM



**COBURN  
TECHNOLOGIES**



COBURNTECHNOLOGIES.COM | 1.800.COUBURN1

**eyeVOTE**  
READER'S CHOICE 2014  
OPTICAL EQUIPMENT & SUPPLIES BRAND: SURFACING

# Current Innovations in Contact Lens Materials

Today's contact lenses are better than ever—but there's still room for improvement. Here's an update on research to make them more useful and more comfortable.

By **Sruthi Srinivasan, PhD, BSOptom**, and **Lakshman N. Subbaraman, PhD, MSc, BSOptom**

A recent report indicates that 2014 was a good year for the contact lens field, with healthy growth.<sup>1</sup> Currently, the contact lens market is estimated at approximately \$2.5 billion in the United States and \$7.6 billion worldwide. Despite this buoyant market, contact lens-related discomfort (CLD) remains one of the major problems associated with contact lens wear, with up to 50% of patients reporting CLD.<sup>2</sup>

An international panel of experts organized by the Tear Film and Ocular Surface Society (TFOS) defined CLD as: “a condition characterized by episodic or persistent adverse ocular sensations related to lens wear, either with or without visual disturbance, resulting from reduced compatibility between the contact lens and the ocular environment, which can lead to decreased wearing time and discontinuation of contact lens wear.” The majority of dissatisfied lens wearers report that this discomfort and dryness, particularly at the end of the day, are major

reasons for cessation of contact lens wear; this discontinuation is believed to have huge financial ramifications for both the contact lens industry and clinical practice.<sup>3</sup>

The purpose of this article is to provide a brief overview of our current understanding of the impact of contact lens materials on CLD. In addition, this article covers recent developments and potential new applications of contact lenses.

## How Lens Materials Impact CLD

The TFOS report on CLD showed that the onset of this condition is influenced by many factors, including some related to the patient and lens composition.<sup>4</sup> There are several material-related factors believed to play a role in determining comfort during contact lens wear.<sup>5</sup> These include water content and ionicity, oxygen transmissibility, modulus, dehydration, wettability, deposition and coefficient of friction.<sup>5</sup> Interestingly, the TFOS report demonstrated that coefficient of friction

was the only material-related factor that actually correlated with CLD. Other soft contact lens physical properties that were found to relate to CLD include denatured protein on contact lenses, lens replacement frequency, lens design, thickness/bulk and edge configuration.<sup>5</sup>

It is a well-established fact that CLD is multifactorial, and it is likely that an interaction exists between the posterior surface of the lens with the corneal surface, and also the anterior surface of the contact lens with the posterior surface of the eyelid during the blink. Within only a few minutes of wear, contact lenses rapidly attract various components from the tear film, including proteins, lipids and mucins.<sup>6</sup> These deposits have the potential to alter the properties of the contact lens surface, which can impact the frictional forces created when the eyelid rubs against the contact lens during blinking. Moreover, the lenses can dehydrate, leading to an increase in lid/lens interaction due to a reduction in lens front-surface wettability



# Postoperative Inflammation and Pain Can Make a Bad Impression

CHOOSE **DUREZOL® EMULSION** TO HELP RESOLVE INFLAMMATION AND PAIN<sup>1</sup>

BROAD MANAGED CARE COVERAGE<sup>2</sup>



## INDICATIONS AND USAGE:

DUREZOL® Emulsion is a topical corticosteroid that is indicated for:

- The treatment of inflammation and pain associated with ocular surgery.
- The treatment of endogenous anterior uveitis.

## Dosage and Administration

- For the treatment of inflammation and pain associated with ocular surgery instill one drop into the conjunctival sac of the affected eye 4 times daily beginning 24 hours after surgery and continuing throughout the first 2 weeks of the postoperative period, followed by 2 times daily for a week and then a taper based on the response.
- For the treatment of endogenous anterior uveitis, instill one drop into the conjunctival sac of the affected eye 4 times daily for 14 days followed by tapering as clinically indicated.

## IMPORTANT SAFETY INFORMATION

**Contraindications:** DUREZOL® Emulsion, as with other ophthalmic corticosteroids, is contraindicated in most active viral diseases of the cornea and conjunctiva including epithelial herpes simplex keratitis (dendritic keratitis), vaccinia, and varicella, and also in mycobacterial infection of the eye and fungal diseases of ocular structures.

## Warnings and Precautions

- Intraocular pressure (IOP) increase – Prolonged use of corticosteroids may result in glaucoma with damage to the optic nerve, defects in visual acuity and fields of vision. If this product is used for 10 days or longer, IOP should be monitored.
- Cataracts – Use of corticosteroids may result in posterior subcapsular cataract formation.
- Delayed healing – The use of steroids after cataract surgery may delay healing and increase the incidence of bleb formation. In those diseases causing thinning of the cornea or sclera, perforations have been known to occur with the use of topical steroids. The initial prescription and renewal of the medication order beyond 28 days should be made by a physician only after examination of the patient with the aid of magnification such as slit lamp biomicroscopy and, where appropriate, fluorescein staining.

- Bacterial infections – Prolonged use of corticosteroids may suppress the host response and thus increase the hazard of secondary ocular infections. In acute purulent conditions, steroids may mask infection or enhance existing infection. If signs and symptoms fail to improve after 2 days, the patient should be re-evaluated.
- Viral infections – Employment of a corticosteroid medication in the treatment of patients with a history of herpes simplex requires great caution. Use of ocular steroids may prolong the course and may exacerbate the severity of many viral infections of the eye (including herpes simplex).
- Fungal infections – Fungal infections of the cornea are particularly prone to develop coincidentally with long-term local steroid application. Fungus invasion must be considered in any persistent corneal ulceration where a steroid has been used or is in use.
- Contact lens wear – DUREZOL® Emulsion should not be instilled while wearing contact lenses. Remove contact lenses prior to instillation of DUREZOL® Emulsion. The preservative in DUREZOL® Emulsion may be absorbed by soft contact lenses. Lenses may be reinserted after 10 minutes following administration of DUREZOL® Emulsion.

## Most Common Adverse Reactions

- Post Operative Ocular Inflammation and Pain – Ocular adverse reactions occurring in 5-15% of subjects included corneal edema, ciliary and conjunctival hyperemia, eye pain, photophobia, posterior capsule opacification, anterior chamber cells, anterior chamber flare, conjunctival edema, and blepharitis.
- In the endogenous anterior uveitis studies, the most common adverse reactions occurring in 5-10% of subjects included blurred vision, eye irritation, eye pain, headache, increased IOP, iritis, limbal and conjunctival hyperemia, punctate keratitis, and uveitis.

For additional information about DUREZOL® Emulsion, please refer to the brief summary of prescribing information on adjacent page.

For more resources for eye care professionals, visit [MYALCON.COM/DUREZOL](http://MYALCON.COM/DUREZOL)

References: 1. DUREZOL® Emulsion prescribing information. 2. Formulary data provided by Pinsonault Associates, LLC, PathfinderRx, March 2014.

**Alcon**  
a Novartis company

© 2014 Novartis 3/14 DUR14031JAD

**DUREZOL®**  
(difluprednate ophthalmic emulsion) 0.05%

**THE RESULTS YOU WANT. THE RELIEF THEY NEED.**



## BRIEF SUMMARY OF PRESCRIBING INFORMATION

### INDICATIONS AND USAGE

#### Ocular Surgery

DUREZOL<sup>®</sup> (difluprednate ophthalmic emulsion) 0.05%, a topical corticosteroid, is indicated for the treatment of inflammation and pain associated with ocular surgery.

#### Endogenous Anterior Uveitis

DUREZOL<sup>®</sup> Emulsion is also indicated for the treatment of endogenous anterior uveitis.

### DOSAGE AND ADMINISTRATION

#### Ocular Surgery

Instill one drop into the conjunctival sac of the affected eye 4 times daily beginning 24 hours after surgery and continuing throughout the first 2 weeks of the postoperative period, followed by 2 times daily for a week and then a taper based on the response.

#### Endogenous Anterior Uveitis

Instill one drop into the conjunctival sac of the affected eye 4 times daily for 14 days followed by tapering as clinically indicated.

### DOSAGE FORMS AND STRENGTHS

DUREZOL<sup>®</sup> Emulsion contains 0.05% difluprednate as a sterile preserved emulsion for topical ophthalmic administration.

### CONTRAINDICATIONS

The use of DUREZOL<sup>®</sup> Emulsion, as with other ophthalmic corticosteroids, is contraindicated in most active viral diseases of the cornea and conjunctiva including epithelial herpes simplex keratitis (dendritic keratitis), vaccinia, and varicella, and also in mycobacterial infection of the eye and fungal disease of ocular structures.

### WARNINGS AND PRECAUTIONS

#### IOP Increase

Prolonged use of corticosteroids may result in glaucoma with damage to the optic nerve, defects in visual acuity and fields of vision. Steroids should be used with caution in the presence of glaucoma. If this product is used for 10 days or longer, intraocular pressure should be monitored.

#### Cataracts

Use of corticosteroids may result in posterior subcapsular cataract formation.

#### Delayed Healing

The use of steroids after cataract surgery may delay healing and increase the incidence of bleb formation. In those diseases causing thinning of the cornea or sclera, perforations have been known to occur with the use of topical steroids. The initial prescription and renewal of the medication order beyond 28 days should be made by a physician only after examination of the patient with the aid of magnification such as slit lamp biomicroscopy and, where appropriate, fluorescein staining.

#### Bacterial Infections

Prolonged use of corticosteroids may suppress the host response and thus increase the hazard of secondary ocular infections. In acute purulent conditions, steroids may mask infection or enhance existing infection. If signs and symptoms fail to improve after 2 days, the patient should be re-evaluated.

#### Viral Infections

Employment of a corticosteroid medication in the treatment of patients with a history of herpes simplex requires great caution. Use of ocular steroids may prolong the course and may exacerbate the severity of many viral infections of the eye (including herpes simplex).

#### Fungal Infections

Fungal infections of the cornea are particularly prone to develop coincidentally with long-term local steroid application. Fungus invasion must be considered in

any persistent corneal ulceration where a steroid has been used or is in use. Fungal culture should be taken when appropriate.

### Topical Ophthalmic Use Only

DUREZOL<sup>®</sup> Emulsion is not indicated for intraocular administration.

### Contact Lens Wear

DUREZOL<sup>®</sup> Emulsion should not be instilled while wearing contact lenses. Remove contact lenses prior to instillation of DUREZOL<sup>®</sup> Emulsion. The preservative in DUREZOL<sup>®</sup> Emulsion may be absorbed by soft contact lenses. Lenses may be reinserted after 10 minutes following administration of DUREZOL<sup>®</sup> Emulsion.

### ADVERSE REACTIONS

Adverse reactions associated with ophthalmic steroids include elevated intraocular pressure, which may be associated with optic nerve damage, visual acuity and field defects; posterior subcapsular cataract formation; secondary ocular infection from pathogens including herpes simplex, and perforation of the globe where there is thinning of the cornea or sclera.

### Ocular Surgery

Ocular adverse reactions occurring in 5-15% of subjects in clinical studies with DUREZOL<sup>®</sup> Emulsion included corneal edema, ciliary and conjunctival hyperemia, eye pain, photophobia, posterior capsule opacification, anterior chamber cells, anterior chamber flare, conjunctival edema, and blepharitis. Other ocular adverse reactions occurring in 1-5% of subjects included reduced visual acuity, punctate keratitis, eye inflammation, and iritis. Ocular adverse reactions occurring in < 1% of subjects included application site discomfort or irritation, corneal pigmentation and striae, episcleritis, eye pruritus, eyelid irritation and crusting, foreign body sensation, increased lacrimation, macular edema, sclera hyperemia, and uveitis. Most of these reactions may have been the consequence of the surgical procedure.

### Endogenous Anterior Uveitis

A total of 200 subjects participated in the clinical trials for endogenous anterior uveitis, of which 106 were exposed to DUREZOL<sup>®</sup> Emulsion. The most common adverse reactions of those exposed to DUREZOL<sup>®</sup> Emulsion occurring in 5-10% of subjects included blurred vision, eye irritation, eye pain, headache, increased IOP, iritis, limbal and conjunctival hyperemia, punctate keratitis, and uveitis. Adverse reactions occurring in 2-5% of subjects included anterior chamber flare, corneal edema, dry eye, iridocyclitis, photophobia, and reduced visual acuity.

### USE IN SPECIFIC POPULATIONS

#### Pregnancy

##### Teratogenic Effects

Pregnancy Category C. Difluprednate has been shown to be embryotoxic (decrease in embryonic body weight and a delay in embryonic ossification) and teratogenic (left palate and skeletal) anomalies when administered subcutaneously to rabbits during organogenesis at a dose of 1-10 mcg/kg/day. The no-observed-effect-level (NOEL) for these effects was 1 mcg/kg/day, and 10 mcg/kg/day was considered to be a teratogenic dose that was concurrently found in the toxic dose range for fetuses and pregnant females. Treatment of rats with 10 mcg/kg/day subcutaneously during organogenesis did not result in any reproductive toxicity, nor was it maternally toxic. At 100 mcg/kg/day after subcutaneous administration in rats, there was a decrease in fetal weights and delay in ossification, and effects on weight gain in the pregnant females. It is difficult to extrapolate these doses of difluprednate to maximum daily human doses of DUREZOL<sup>®</sup> Emulsion, since DUREZOL<sup>®</sup> Emulsion is administered topically with minimal systemic absorption, and difluprednate blood levels were not measured in the reproductive animal studies. However, since use of difluprednate during human pregnancy has not been evaluated and cannot rule out the possibility of harm, DUREZOL<sup>®</sup> Emulsion should be used during pregnancy only if the potential benefit justifies the potential risk to the embryo or fetus.

### Nursing Mothers

It is not known whether topical ophthalmic administration of corticosteroids could result in sufficient systemic absorption to produce detectable quantities in breast milk. Systemically administered corticosteroids appear in human milk and could suppress growth, interfere with endogenous corticosteroid production, or cause other untoward effects. Caution should be exercised when DUREZOL<sup>®</sup> Emulsion is administered to a nursing woman.

### Pediatric Use

DUREZOL<sup>®</sup> Emulsion was evaluated in a 3-month, multicenter, double-masked, trial in 79 pediatric patients (39 DUREZOL<sup>®</sup> Emulsion; 40 prednisolone acetate) 0 to 3 years of age for the treatment of inflammation following cataract surgery. A similar safety profile was observed in pediatric patients comparing DUREZOL<sup>®</sup> Emulsion to prednisolone acetate ophthalmic suspension, 1%.

### Geriatric Use

No overall differences in safety or effectiveness have been observed between elderly and younger patients.

### NONCLINICAL TOXICOLOGY

#### Carcinogenesis, Mutagenesis, and Impairment of Fertility

Difluprednate was not genotoxic *in vitro* in the Ames test, and in cultured mammalian cells CHL/IU (a fibroblastic cell line derived from the lungs of newborn female Chinese hamsters). An *in vivo* micronucleus test of difluprednate in mice was also negative. Treatment of male and female rats with subcutaneous difluprednate up to 10 mcg/kg/day prior to and during mating did not impair fertility in either gender. Long term studies have not been conducted to evaluate the carcinogenic potential of difluprednate.

#### Animal Toxicology and/or Pharmacology

In multiple studies performed in rodents and non-rodents, subchronic and chronic toxicity tests of difluprednate showed systemic effects such as suppression of body weight gain; a decrease in lymphocyte count; atrophy of the lymphatic glands and adrenal gland; and for local effects, thinning of the skin; all of which were due to the pharmacologic action of the molecule and are well known glucocorticosteroid effects. Most, if not all of these effects were reversible after drug withdrawal. The NOEL for the subchronic and chronic toxicity tests were consistent between species and ranged from 1-1.25 mcg/kg/day.

### PATIENT COUNSELING INFORMATION

#### Risk of Contamination

This product is sterile when packaged. Patients should be advised not to allow the dropper tip to touch any surface, as this may contaminate the emulsion. Use of the same bottle for both eyes is not recommended with topical eye drops that are used in association with surgery.

#### Risk of Secondary Infection

If pain develops, or if redness, itching, or inflammation becomes aggravated, the patient should be advised to consult a physician.

#### Contact Lens Wear

DUREZOL<sup>®</sup> Emulsion should not be instilled while wearing contact lenses. Patients should be advised to remove contact lenses prior to instillation of DUREZOL<sup>®</sup> Emulsion. The preservative in DUREZOL<sup>®</sup> Emulsion may be absorbed by soft contact lenses. Lenses may be reinserted after 10 minutes following administration of DUREZOL<sup>®</sup> Emulsion.

#### Revised: May 2013

U.S. Patent 6,114,319

Manufactured For:

**Alcon**<sup>®</sup>  
a Novartis company

Alcon Laboratories, Inc.  
6201 South Freeway  
Fort Worth, Texas 76134 USA  
1-800-757-9195  
Manufactured By:  
Alcon Laboratories, Inc.  
6201 South Freeway  
Fort Worth, Texas 76134 USA  
or  
Catalent Pharma Solutions  
Woodstock, IL 60098

and the development of epithelial staining due to pervaporation and subsequent desiccation.<sup>7</sup> Lens friction may also be associated with clinically observable conditions, including lid wiper epitheliopathy (*figure 1*) and lid parallel conjunctival folds.<sup>8,9</sup> Under extreme conditions, the mechanical interaction of the palpebral conjunctiva with the lens surface can lead to contact lens associated papillary conjunctivitis.<sup>10</sup>

Sufficient evidence suggests that different care solutions interact differently with contact lens materials and that this interaction is strongly dependent on the contact lens material properties and the composition of the lens care solution. Thus, clinicians should remember that the mechanisms contributing to symptomatology are significantly affected by the manner in which the components in a lens care product interact with the lens material.

Overall, further research studies are required to develop novel technologies that will reduce or eradicate the problems experienced by contact lens wearers.

### Delivering the Goods

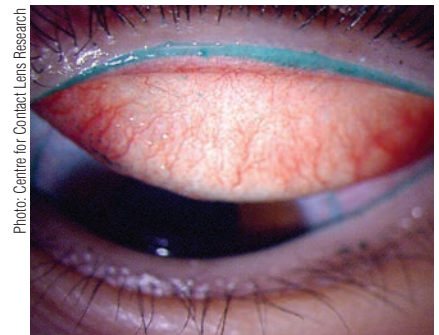
While contact lenses are primarily used as a means to correct vision, research in recent years has turned toward the use of lenses for other applications, including disease detection, drug delivery and myopia control. For instance, researchers have incorporated novel components into lens materials; these embedded contact lenses have been successfully used to monitor intraocular pressure and tear glucose levels.

• **CLs for IOP monitoring.** Glaucoma is a chronic, neurodegenerative disease considered to be one of the leading causes of irreversible blindness worldwide. While sound prediction methods for developing the disease remain uncertain, there

has been a recent increased interest in developing methods to monitor IOP over a 24-hour period, as some studies have suggested fluctuations in IOP may be an important contributor to the risk of glaucoma progression. Technology capable of constant monitoring of IOP could be attractive to practicing clinicians who prefer to manage glaucoma efficiently.

The Sensimed Triggerfish device (*figure 2*) is a contact lens sensor that has been successfully used to monitor intraocular pressure over a period of 24 hours.<sup>11,12</sup> This sensor consists of two platinum/titanium sensing-resistive strain gauges capable of recording circumferential changes at the corneoscleral area.<sup>13</sup> Together with a microprocessor, this sensor is embedded within a silicone-based disposable contact lens material. The disposable lens is available in three different base curves with an approximate thickness of 585µm at the centre and 260µm at the periphery.<sup>13</sup> Triggerfish is currently available in several countries in Africa, Asia, Europe and South America. In North America, it is available in Canada and Mexico, but not approved for use in the United States.

• **CLs for glucose monitoring.** Diabetes is a global health crisis, and it's only getting worse. In 2013, an estimated 382 million people had diabetes worldwide.<sup>14</sup> The World Health Organization reported diabetes caused over 1.1 million deaths in 2005, and that death related to diabetes is estimated to double by 2020. Currently, diabetes is managed by monitoring blood glucose levels, an invasive procedure that patients with diabetes self-administer several times a day. Other bodily fluids such as urine, saliva and tears can also be monitored; indeed, it has been shown that tear glucose levels can be



**Fig. 1. Lens friction may be associated with clinically observable conditions such as lid wiper epitheliopathy (above).**

elevated in hyperglycemic individuals.<sup>15,16</sup> But, while tears are easily accessible, collection of an adequate sample for testing is time consuming.

One means of determining tear glucose under investigation is to incorporate sensors within a contact lens to monitor tear glucose levels. Contact lens prototypes have been developed previously to monitor tear glucose levels; however, they were never made available for clinical trials.<sup>17-19</sup> More recently, Google announced that its life sciences division, Google X, has been working on a contact lens that could monitor tear glucose levels. The lens would contain an embedded glucose sensor, wireless chip and antenna (*figure 3*). A tiny hole in the lens would enable the tear fluid to penetrate into the lens, where it would come in contact with the sensor. The antenna then transmits information to an external wireless device.

Because this lens is still in the design stage, the performance of this device in adverse environments and eyes of varying tear profiles is currently unknown; however, this could be a significant advancement that will likely lead to more medical and vision devices for future generations. Google's smart contact lens is currently licensed to Novartis' eye care division, Alcon Vision Care.

Photo: Centre for Contact Lens Research

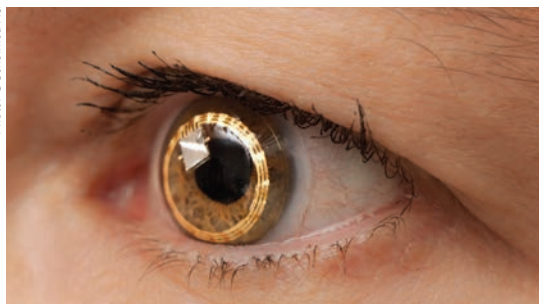

• **Drug-eluting CLs.** For years, contact lenses have been used as bandage lenses to manage pain and promote re-epithelialization following surgery or ocular trauma.<sup>20</sup> In most of these cases, antibiotics and anti-inflammatory drugs are administered topically over the bandage lenses.<sup>19</sup> Research has been ongoing, however, in a contact lens that is specifically developed for use as a drug-delivering therapeutic lens.<sup>20</sup>

The use of soft contact lenses as drug delivery devices was first proposed by Waltman and Kaufman in 1970 and, since then, more than 200 papers have been published that investigate the release of anti-glaucoma drugs, antibiotics, antiviral agents, epithelial growth factors and anti-inflammatory medications.

One advantage of using lenses as ocular drug delivery devices is their

Photo: ©Sensimed AG



**Fig. 2. The Triggerfish contact lens sensor monitors IOP over a 24-hour period.**

ability to overcome several barriers that limit the effective use of eye drops. When released by the lens, the drug is eluted directly into the post-lens tear film, where it would have prolonged contact time with the cornea, resulting in increased bioavailability.<sup>21</sup> Such a method has been shown to be 35 times more efficient than conventional eye drops.<sup>22</sup>

Another advantage of using contact lenses as drug delivery devices is the ability to release the drug over an extended period of time. Extensive research has been conducted in the last few years to develop contact lenses that release drugs at a slow and sustained rate, and in vitro results obtained

thus far have been extremely promising. Strategies such as molecular imprinting, vitamin E coatings and nanoparticles have been shown to be effective in retaining the drug within the contact lens.<sup>23-25</sup> This is particularly useful in cases of ocular infections, such as microbial keratitis, where eye drop application should be hourly or even more frequent.<sup>26</sup>



**SECO2015**  
Atlanta, GA | March 4-8  
WHERE SIGHT MEETS VISION™

## Two Registration Options

- 1 All-Inclusive Package includes everything at SECO - CE courses, exhibit hall, social events and access to SECO University.
- 2 A la Carte Package includes access to the exhibit hall and social events, but lets you choose and pay only for the CE courses you want.

**Register today**

Find out more at [SECO2015.com](http://SECO2015.com)

[SECOINTERNATIONAL.COM](http://SECOINTERNATIONAL.COM)



The SECO Champion Program is an elite partnership between leaders of the ophthalmic industry and SECO International. Their goal is to provide optometric professionals with the tools to achieve the highest levels of clinical knowledge and performance.

### PREMIER PARTNERS

**Alcon**  
a Novartis company

**ACUVUE**  
BRAND CONTACT LENSES  
INNOVATION FOR HEALTHY VISION™

**vsp**  
Global

**ALLERGAN**

**HOYA**

### PARTNERS

**BAUSCH+LOMB**

**Abbott**  
Medical Optics



# Don't just meet the needs of your patients—**exceed them.**



**Bausch + Lomb PeroxiClear® - the most advanced\* peroxide solution.**

	PeroxiClear®	Clear Care
Kills 99.9% of Germs <sup>1</sup>	✓	✓
Preservative Free	✓	✓
Provides Superior All-Day Comfort <sup>1*</sup>	✓	
Lenses Feel Cleaner and Moister for Longer <sup>1*</sup>	✓	
Lenses Are Ready to Wear in <b>Only 4 Hours</b>	✓	

**Switch your patients to the most advanced\* peroxide solution. Request your care kits today at [Bausch.com/Peroxiclear](http://Bausch.com/Peroxiclear).**

\*Compared to Clear Care

Reference: 1. Bausch + Lomb Data on File.

Distributed by Bausch + Lomb, a Division of Valeant Pharmaceuticals North America LLC, Bridgewater, N.J. PeroxiClear is a trademark of Bausch & Lomb Incorporated or its affiliates. All other brand/product names are trademarks of their respective owners. ©2015 Bausch & Lomb Incorporated. BLS07386 US/OCD/14/0002a

**BAUSCH + LOMB**  
See better. Live better.


Although there has been a significant progress in the last few years in the development of contact lenses capable of releasing drugs at a slow and sustained rate, one major limitation is a shortage of in vivo clinical studies that can validate the viability of the drug-delivering devices. Further, drug delivery is also limited by the molecular weight of the substance eluted. Overall, however, while the cost of such a system will likely be higher than the conventional eye drop method, the treatment efficacy and the system's ability to reduce the frequency of topical application will likely make this commercially attractive to clinicians.

## Controlling Myopia

Myopia affects an estimated 1.5 billion people worldwide (roughly 22% of the current global population).<sup>27</sup> Approximately 33% of Americans are myopic, with roughly 2% of kindergarteners and 15% of high school students affected.<sup>27</sup> Various strategies and treatment options to prevent myopia progression exist, including spectacles, contact lenses and anti-muscarinic medications.<sup>28</sup> The prescription of contact lenses for myopia control in particular has recently increased.<sup>1</sup>

Rigid gas permeable contact lenses were found to have no evidence of effect on myopic children's eye growth; however, progressive addition lenses (PALs) and bifocal spectacles were found to yield a small slowing of myopia progression.<sup>28</sup> Furthermore, children wearing multifocal lenses, either PALs or bifocals, progressed on average 0.16D less than children wearing single-vision lenses.<sup>28</sup> A more recent study that involved the use of contact lenses to reduce hyperopic defocus in the peripheral retina found that these contact lenses slow the

Photo: ©Google



**Fig. 3. This investigational “smart” contact lens monitors tear glucose levels with an embedded sensor.**

progression of myopia by 40% per year.<sup>29</sup> Thus, contact lenses designed to induce peripheral hyperopia appear to be an attractive, efficient and safe means of controlling the progression of myopia.

Several independent studies have shown orthokeratology (ortho-k) lenses slow ocular elongation.<sup>30,31</sup> The changes induced with ortho-K treatment are directly related to the initial myopia level, and thus variable. These lenses are considered by many to be the most trustworthy index of myopia control; however, adverse events should be carefully evaluated. There have been case reports on severe microbial keratitis infections in children wearing these lenses.<sup>32</sup>

A few other contact lenses are also available for clinicians to try as a treatment option to prevent the progression of myopia, including the five-zone dual power MySight design from New Zealand and another lens based on the Fresnel design from Hong Kong.<sup>28</sup>

In conclusion, contact lens-related discomfort continues to be a major problem that can drastically impact the success of contact lens wear. Researchers, clinicians and the contact lens industry have made

considerable efforts to identify the causes and manage this condition. Contact lens researchers have made significant strides in identifying the causes of this condition and are continuing to improve the properties of lens materials. Furthermore, several novel designs of lens materials that can be applied

for conditions other than refractive correction have also been developed and launched. The development and innovations that have occurred over the past few years offer the promise of a wider application of contact lenses that could be attractive to both practitioners and patients. ■

*Dr. Srinivasan is a research assistant professor and a clinical research manager at the Centre for Contact Lens Research (CCLR), School of Optometry and Vision Science, University of Waterloo, Canada. She is actively involved in various clinical trials conducted at the CCLR.*

*Dr. Subbaraman is the head of biological sciences and a senior clinical scientist at CCLR. He has authored several peer-reviewed and professional articles in the area of contact lens discomfort and tear film biochemistry, and has presented at national and international conferences.*

*Disclosure: Over the past three years, CCLR has received research support or honoraria from the following companies: Advanced Vision Research, Alcon, AlgiPharma, Allergan, Ciba Vision, CooperVision, Contamac US, Eleven Biotherapeutics, Essilor, Johnson & Johnson Vision Care, Ocular Dynamics, Oculus, Ocusense, TearScience,*



*Visioneering Technologies. However, Drs. Srinivasan and Subbaraman do not serve on an advisory board or own shares in any optometric company.*

- Nichols J. Contact Lenses 2014. Contact Lens Spectrum 2015; January 2015.
- Dumbleton K, Caffery B, Dogru M, et al. The TFOS International Workshop on Contact Lens Discomfort: report of the subcommittee on epidemiology. Invest Ophthalmol Vis Sci. 2013;54(11):TFOS20-36.
- Fonn D. Targeting contact lens induced dryness and discomfort: what properties will make lenses more comfortable. Optom Vis Sci. 2007 Apr;84(4):279-85.
- Nichols JJ, Willcox MD, Bron AJ, et al. The TFOS International Workshop on Contact Lens Discomfort: executive summary. Invest Ophthalmol Vis Sci. 2013;54(11):TFOS7-TFOS13.
- Jones L, Brennan NA, Gonzalez-Mejome J, et al. The TFOS International Workshop on Contact Lens Discomfort: report of the contact lens materials, design, and care subcommittee. Invest Ophthalmol Vis Sci. 2013;54(11):TFOS37-70.
- Bontempo AR, Rapp J. Protein and lipid deposition onto hydrophilic contact lenses in vivo. CLAO J. 2001;27(2):75-80.
- Pritchard N, Fonn D. Dehydration, lens movement and dryness ratings of hydrogel contact lenses. Ophthalmol Physiol Opt. 1995;15(4):281-6.
- Berry M, Pult H, Purslow C, Murphy PJ. Mucins and ocular signs in symptomatic and asymptomatic contact lens wear. Optom Vis Sci. 2008;85(1):E930-8.
- Pult H, Purslow C, Berry M, Murphy PJ. Clinical tests for successful contact lens wear: relationship and predictive potential. Optom Vis Sci 2008;85(1):E924-9.
- Donszhik PC. Contact lens chemistry and giant papillary conjunctivitis. Eye Contact Lens. 2003;29(1 Suppl):S37-9; discussion S57-9, S192-4.
- Mansouri K, Medeiros FA, Weinreb RN. Twenty-four-hour intraocular pressure patterns in a symptomatic patient after ab interno trabeculotomy surgery. Clin Ophthalmol 2014 7;8:2195-7.
- Mansouri K, Medeiros FA, Tafreshi A, Weinreb RN. Continuous 24-hour monitoring of intraocular pressure patterns with a contact lens sensor: safety, tolerability, and reproducibility in patients with glaucoma. Arch Ophthalmol 2012;130(12):1534-9.
- Mansouri K, Weinreb R. Continuous 24-hour intraocular pressure monitoring for glaucoma—time for a paradigm change. Swiss Med Wkly 2012;142:w13545.
- Guariguata L, Whiting DR, Hambleton I, et al. Global estimates of diabetes prevalence for 2013 and projections for 2035. Diabetes Res Clin Pract. 2014 Feb;103(2):137-49.
- Michail D, Vancea P, Zolog N. Sur l'élimination lacrymale du glucose chez les diabétiques. C R Soc Biol, Paris 1937;125:1095.
- Michail D, Zolog N. Sur l'élimination lacrymale du glucose au cours de l'hyperglycémie alimentaire. C R Soc Biol Paris 1937;126:1042.
- Alexeev VL, Das S, Finegold DN, Asher SA. Photonic crystal glucose-sensing material for noninvasive monitoring of glucose in tear fluid. Clin Chem 2004;50(12):2353-60.
- Badugu R, Lakowicz JR, Geddes CD. Ophthalmic glucose sensing: a novel monosaccharide sensing disposable and colorless contact lens. Analyst 2004;129(6):516-21.
- Badugu R, Lakowicz JR, Geddes CD. Noninvasive continuous monitoring of physiological glucose using a monosaccharide-sensing contact lens. Anal Chem 2004;76(3):610-8.
- Karlgard CC, Jones LW, Moresoli C. Survey of bandage lens use in North America, October-December 2002. Eye Contact Lens 2004;30(1):25-30.
- Hehl EM, Beck R, Luthard K, et al. Improved penetration of aminoglycosides and fluorozinolones into the aqueous humour of patients by means of Acuvue contact lenses. Eur J Clin Pharmacol 1999;55(4):317-23.
- Li CC, Chauhan A. Modeling ophthalmic drug delivery by soaked contact lenses. Ind Eng Chem Res 2006;45(10):3718-34.
- Peng CC, Kim J, Chauhan A. Extended delivery of hydrophilic drugs from silicone-hydrogel contact lenses containing vitamin E diffusion barriers. Biomaterials 2010;31(14):4032-47.
- Phan CM, Subbaraman L, Liu S, Gu F, Jones L. In vitro uptake and release of natamycin Dex-B-PLA nanoparticles from model contact lens materials. J Biomater Sci Polym Ed 2014;25(1):18-31.
- Ciolino JB, Hudson SP, Mobbs AN, et al. A prototype antifungal contact lens. Invest Ophthalmol Vis Sci 2011;52(9):6286-91.
- Yolton DP. Antimicrobial drugs. In: Bartlett JD, Jaanus SD, ed. Clinical Ocular Pharmacology. 4th edition ed. Woburn, MA: Butterworth-Heinemann, 2001: 219-64.
- Yu L, Li ZK, Gao JR, Liu JR, Xu CT. Epidemiology, genetics and treatments for myopia. Int J Ophthalmol. 2011;4(6):658-69.
- Walline JJ, Lindsley K, Vedula SS, et al. Interventions to slow progression of myopia in children. Cochrane Database Syst Rev 2011 Dec 7;(12):CD004916.
- Holden B, Sankaridurg P, Smith E, et al. Myopia, an underrated global challenge to vision: where the current data takes us on myopia control. Eye (Lond) 2014;28(2):142-6.
- Santodomingo-Rubido J, Villa-Collar C, Gilmartin B, Gutierrez-Ortega R. Myopia control with orthokeratology contact lenses in Spain: refractive and biometric changes. Invest Ophthalmol Vis Sci 2012;53(8):5060-5.
- Cho P, Cheung SW. Retardation of myopia in Orthokeratology (ROMIO) study: a 2-year randomized clinical trial. Invest Ophthalmol Vis Sci 2012;53(11):7077-85.
- Tran T, Samarawickrama C, Petsoglou C, Watson S. Recent cluster of childhood microbial keratitis due to orthokeratology. Clin Experiment Ophthalmol 2014;42(8):793-4.



## Are you prepared for National Sunglasses Day?

The Vision Council is working to educate consumers on the negative health effects of UV rays, and steer them into your stores and offices to find the UV-protective eyewear that they need.

**Increase your sales of sunglasses! Join us in spreading the message of UV protection.**

[thevisioncouncil.brandmuscle.net](http://thevisioncouncil.brandmuscle.net)

**CELEBRATE YOUR SHADES!**

Wear your UV-protective shades for National Sunglasses Day and every day to help keep your eyes healthy!

**NATIONAL SUNGLASSES DAY JUNE 27**  
THE VISION COUNCIL

Keep your eyes healthy by wearing UV-protective sunwear

#NationalSunglassesDay

Promotional items are now available online to help engage consumers and patients in discussions about sun-safe behaviors, inform them of the UV protective eyewear options available, and raise awareness of National Sunglasses Day, June 27, 2015.

Items can be downloaded as-is or customized with your branding, and can be printed directly or via print-on-demand services.



THE VISION COUNCIL

# Academy Update: Dry Eye Research

If you're trying to keep up with what's new in dry eye, a wealth of new information came out at the 2014 American Academy of Optometry meeting in Denver.

By **Barbara Caffery, OD, PhD**

**J**ust when you think we've discovered everything there is to know about dry eye, new information arises. For instance, the November 2014 *Canadian Journal of Optometry* included a standalone supplement on "Screening, Diagnosis and Management of Dry Eye Disease." Also, a Dry Eye Summit took place in December in Dallas. And soon, the Tear Film and Ocular Surface Society will hold a news conference to revisit the exhaustive International Dry Eye WorkShop (DEWS) report, and revamp it with the new knowledge of the day.

So, we still have a good deal to learn.

To that end, here is a recap of what we learned at the 2014 American Academy of Optometry meeting.

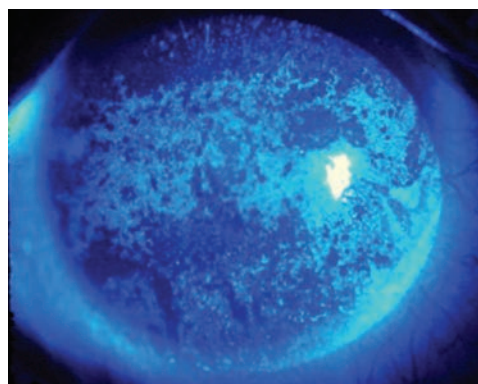
## Pathophysiology

Many of the scientific papers presented at the Academy meeting

added to our understanding of the pathophysiology of dry eye disease. The complexity at a clinical level may be overwhelming. No matter; as eye care clinicians, the better we understand the diseases that we are dealing with, the better we will manage them.

- *Aqueous deficient vs. evaporative dry eye.* Too often, we lump all forms of dry eye together and skip the differentiation of phenotype by ignoring the Schirmer test or phenol red thread test.

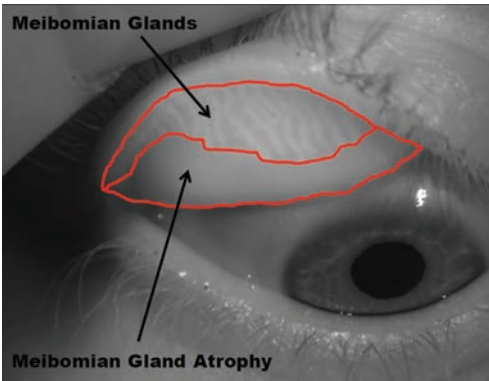
One paper differentiated aqueous deficient (ADDE) and evaporative dry eye (EDE) at a molecular level.<sup>1</sup> Jillian F. Meadows, OD, and colleagues found that T-helper cells 1, 2 and 17 are active in dry eye disease regardless of etiology. However, ADDE has increased inflammation, as measured by cytokine levels, compared to EDE and mixed disease.



**Researchers recognized a molecular biomarker for Sjögren's-related dry eye.**

On a practical level, this suggests that topical corticosteroids may be more effective as an initial treatment of ADDE than in other forms of dry eye syndrome.

- *Biomarker for Sjögren's.* In earlier work in mice, Nancy A. McNamara, OD, PhD, and colleagues found that the PAX-6 molecule is decreased in Sjögren's syndrome (SS). PAX-6 regulates stem cells to



**Contact lenses don't appear to affect meibomian glands. That is, meibomian gland atrophy is no worse in CL wearers than in non-wearers.**

commit to being corneal cells, thus preventing squamous metaplasia and damage of ocular surface cells from the inflammatory cytokine IL-1 $\beta$ .

In this study, researchers performed impression cytology of the bulbar conjunctiva of human subjects with and without SS to analyze the level of PAX-6.<sup>2</sup> This molecule was significantly lower in SS patients and was highly correlated with ocular surface staining. This molecule may serve as a biomarker for SS as well as a target for treatment. Specifically, CD4 T-cells seem to be the main regulators of the loss of PAX-6 in ocular surface cells. Therefore, a topical medication that would change the CD4 T-cell expressions might prevent the loss of PAX-6.

• **Vitamin D and ocular inflammation.** Vitamin D is believed to play a major role in modulating inflammation. In human corneal epithelial cells in vitro, vitamin D lessened inflammation induced from toll-like receptors, which activate immune cell responses. Also, vitamin D influences gene expression to increase proteins that are used in innate immunity.<sup>3</sup> This study, by Rose Y. Reins, PhD, and colleagues, furthers our understanding of vitamin D's protective function, showing that vitamin D is able to diminish

inflammation even after removal of the stimulus.

• **CLs don't induce MGD.**

Meibomian gland disease is an important factor in dry eye, and some evidence suggests that contact lens wearers have greater meibomian gland loss than non-lens wearers.<sup>4</sup> As clinicians, we worry about causing harm to our patients, but we also know the value of contact lenses. Two papers put these worries to rest.

Sruthi Srinivasan, PhD, BSOptom, and Andrew D. Pucker, MS, OD, each studied contact lens wearers and non-contact lens wearers and, using meibography, found no difference in meibomian gland dropout in the two groups.<sup>5,6</sup>

**Diagnosis**

As an eye care clinician, I'm always interested in diagnostic testing. Diagnosis is a tricky business in clinical practice. There are many questions: Which patients do we test, and which tests do we use? How many tests are needed? Who should have a full tear film and ocular surface disease work-up? What does this cost?

Bear in mind that one recent study found that up to 60% of patients with clinically significant dry eye are asymptomatic.<sup>7</sup> This study used osmolarity as the diagnostic criterion for dry eye. Because many of us don't have the ability to measure osmolarity in our offices, we must use symptoms and other signs, such as staining, to determine dry eye. So, symptoms of any kind do play a big role in clinical practice. We want all of our patients

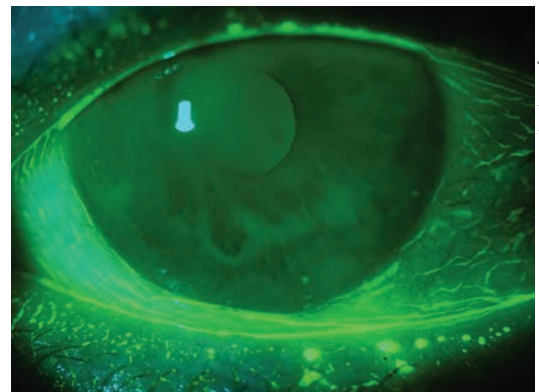
to feel better, so it's one of the main goals in our treatment plans.

• **Do some patients feel more pain?**

Speaking of symptoms, an interesting paper presented by Eric Li, OD, suggested that we temper our rating of dry eye disease by learning the global pain sensitivity of our patients.<sup>8</sup> There is a general pain sensitivity questionnaire that can differentiate those of us who feel pain too much and those who feel pain too little. This understanding may help to explain the very real clinical dilemma of painfully sore eyes with few signs vs. terribly stained ocular surfaces with few symptoms.

• **The other reason for dry eye.**

When a patient presents with ocular discomfort and epiphora, dry eye is usually at the forefront of our differential diagnosis. A poster described two cases presenting with severe dry eye symptoms (OSDI >33/100) including discomfort, tearing and ocular irritation.<sup>9</sup> However, full dry eye exams ruled out MGD, lid wiper



**Look out for conjunctivochalasis, which masquerades as dry eye. Note the redundant folds in an otherwise transparent conjunctiva.**

epitheliopathy and hyperosmolar tear film, but did show shortened tear film breakup time.

The diagnosis: conjunctivochalasis, which is characterized as redundant conjunctival tissue that often presents with symptoms similar to



## What's New in Dry Eye Diagnostic Technology?

The new tools of the trade in diagnosis help us to determine if dry eye is present and what the core dry eye mechanism is in a particular patient. The newer diagnostic measures include tear osmolarity (TearLab), interferometry (LipiView, TearScience), cytokine assays, enzyme assays (MMP-9, InflammDry) and meibography. Some of these are used frequently and others fall outside the realm of typical clinical practice.

- **Osmolarity** is now used in a number of dry eye practices and, although there is still controversy over its true clinical value, many dry eye experts say that they could not do their job without it. The testing involves a tear sample that is automatically taken up by the tip of the TearLab instrument. The two arms are placed in a well and the osmolarity is read out almost instantly. Normal tears would have an osmolarity of 308mOsm/l or less. Also, both eyes should have readings that are within 5mOsm/l of each other. We may need to monitor patients over time to ensure the consistency of the osmolarity. Normal eyes would have little variability over time, but dry eyes would have greater variability both over time and between eyes.

- **Interferometry**, performed by the LipiView instrument, allows us to see the lipid layer moving on the eye and gives us an assessment of the stability of the tear film. It is used for that purpose alone and to decide whether the LipiFlow (TearScience) treatment is recommended. The rough-and-ready clinical test that simulates this stability test is tear break-up time.

- **Cytokine assays**, common in the realm of research, may gain clinical application one day. The hope is that we will be able to take a tear sample, place it in a portable device and determine the exact composition of the tear film, and then customize our treatment for individual dry eye patients. To date, this analysis is limited to the research lab.

However, the enzyme MMP-9 is readily measured in office using the InflammDry kit. This works and looks like a pregnancy test in that the tear sample delivers a pink line to the stick reader if the enzyme is in a higher concentration than normal. MMP-9 is a useful molecule at a normal level but in higher concentrations can cause intercellular matrices to dissolve on the ocular surface. There is evidence that this enzyme is overproduced by meibomian glands, conjunctival cells and lacrimal glands in dry eye.<sup>1-3</sup>

The clinical endpoint of excess MMP-9 is likely our observation of corneal and conjunctival staining.<sup>4</sup>

- **Antibody analysis** appears to identify Sjögren's syndrome-associated dry eye, the most severe form of dry eye disease.

Perhaps the biggest problem facing patients with Sjögren's syndrome is getting a diagnosis. Rheumatology has used blood testing to determine the presence of Sjögren's syndrome by analyzing many antibodies, including ANA, RF, Anti-Ro/SSA and Anti-La/SSB in serum. Unfortunately, dentists, optometrists, ophthalmologists and family practice physicians often overlook the presenting symptoms of dry eye and dry mouth.

Indeed, many patients with "idiopathic" dry eyes have autoantibodies consistent with early SS, at a frequency higher than currently reported in the literature.<sup>4</sup>

Sjö (Nicox) is test in which a pinprick sample of blood is analyzed for markers of salivary inflammation that may identify Sjögren's syndrome in the absence of the traditional antibodies alone. The report includes the presence and levels of salivary protein (SP-1) and parotid secretory protein (PSP), which are considered to be early signs of syndrome, as well as other traditional markers. This type of simple in-office lab analysis could offer earlier diagnosis and lead to better management of dry eye and other systemic manifestations in patients with Sjögren's syndrome.

- **Meibography** is a fascinating diagnostic tool. It requires expensive instrumentation, but the images that result are clinically important. One can see the number of meibomian glands, the number of dropouts and those that are enlarged easily. Meibomian glands are a very important aspect of dry eye disease, so seeing them clearly is a wonderful clinical tool. For now, we press on the lids and estimate the numbers of glands that are functioning and what the secretions look like.

1. Acera A, Veccio E, Duran JA. Tear MMP-9 levels as a marker of ocular surface inflammation in conjunctivochalasis. *Invest Ophthalmol Vis Sci.* 2013 Dec 23;54(13):8285-91.
2. Ding J, Kam WR, Dieckow J, Sullivan DA. The influence of 13-cis retinoic acid on human meibomian gland epithelial cells. *Invest Ophthalmol Vis Sci.* 2013 Jun 26;54(6):4341-50.
3. Luo L, Li DQ, Doshi A, et al. Experimental dry eye stimulates production of inflammatory cytokines and MMP-9 and activates MAPK signalling pathways on the ocular surface. *Invest Ophthalmol Vis Sci.* 2004 Dec;45(12):4293-301.
4. Pflugfelder SC, Farley W, Luo L, et al. Matrix metalloproteinase-9 knockout confers resistance to corneal epithelial barrier disruption in experimental dry eye. *Am J Pathol.* 2005 Jan;166(1):61-71.
5. Pardo DP, Malyavantham K, Suresh L, et al. Detecting the Root Cause of Your Patients' Dry Eye: Sjög, an Advanced Diagnostic for Detection of Sjögren's Syndrome Autoantibodies. Poster presented at American Academy of Optometry Meeting 2014, November 13, Denver, CO.

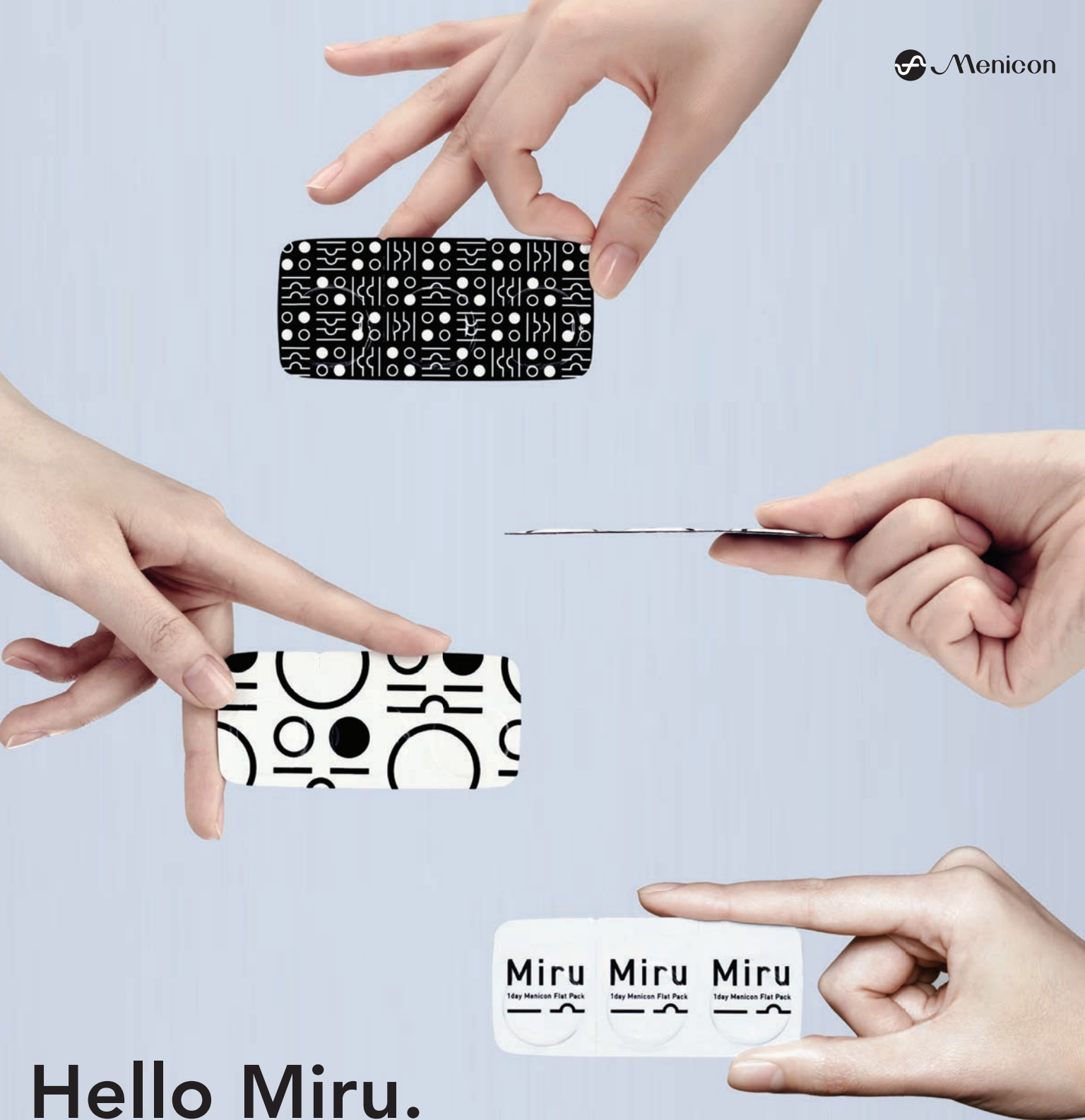dry eye (including epiphora, foreign body sensation and ocular irritation). Ophthalmic dyes highlight the redundant folds in the otherwise transparent conjunctiva, and can alert us to an early presentation along the lower fornix. So, be sure to add conjunctivochalasis in your dif-

ferential for dry eye, especially in the presence of normal osmolarity.

## Treatment

Our treatment of dry eye is becoming more focused. Anti-inflammatory therapies include pulse-dosed steroids and Restasis

(cyclosporine A, Allergan), as well as oral doxycycline, minocycline and azithromycin. It has been suggested recently that Restasis may be more efficacious when used with greater frequency (more than twice daily) in certain patients with severe dry eye.<sup>10</sup> Also, azithromycin may



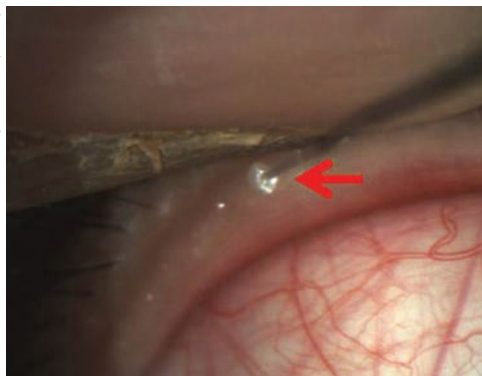
# Hello Miru. Bye, bye blister pack.

Introducing Miru 1day, the world's thinnest package for daily disposable contact lenses.

Miru's ultra lightweight 1mm thin package is about 1/8th the thickness of a traditional blister pack and was specifically developed to reduce the risk of microbial contamination. When opened, the lens is presented on a special disk, oriented correctly for proper insertion.

To learn more and request trials, please visit: [miru.meniconamerica.com](http://miru.meniconamerica.com)

©2014 Menicon America, Inc. Miru is a registered trademark of Menicon Company Ltd.



**Intraductal probing of blocked meibomian glands can be a more effective treatment than artificial tears in dry eye patients.**

be more valuable than tetracycline derivatives in treating meibomian gland disease; it would certainly be a much shorter-term therapy.<sup>11,12</sup>

Other interesting treatment research:

- **Intraductal meibomian gland probing.** Blockage of the meibomian glands is a major cause of increased tear evaporation. So, Srihari Narayanan, OD, PhD, and colleagues presented a poster on intraductal meibomian gland probing (IMGP).<sup>13</sup> Their study treated MGD patients with either IMGP or an artificial tear designed to treat evaporative dry eye. They determined that IMGP is more effective than artificial tears alone for MGD. Specifically, subjects in the IMGP group showed more than 50% improvement in symptoms, as well as a doubling of TBUT.

- **Phase III results of lifitegrast.** An interesting paper by Paul Karpecki, OD, and colleagues reported on Phase III results using lifitegrast as an anti-inflammatory treatment for dry eye.<sup>14</sup> Lifitegrast acts as an ICAM-1 decoy, thus preventing some of the cascade of inflammation and initiating treatment further back in the inflammatory process.

In this study, half of the 718 subjects enrolled received topical lifite-

grast 5.0% and the other half were given vehicle only. The main outcome measures were inferior corneal staining and reduced symptoms on a visual analog scale. Although there was no difference found in the staining scores, there was significant reduction in dryness symptoms with the use of lifitegrast. The secondary outcomes were total corneal staining, nasal lissamine green staining of the conjunctiva and symptoms. The treatment group had reduced ocular discomfort and decreased itching and foreign body sensation.

An NDA for lifitegrast is expected to be submitted to the FDA early this year. These and other efforts to create unique and better anti-inflammatory drops continue to be an important area of dry eye research.

## More to Come

We still have a good deal to learn about dry eye, but we are making progress. The various phenotypes of dry eye are being elucidated. The pathophysiology is better understood. Diagnostic testing is improving, and some of the more innovative tests may become commonly used in private practice. Also, the effort to discover better treatments is well under way.

Meanwhile, we have groups of specialists in North America and around the world that are working to create clinical guidelines and important summaries that will serve to update all of us on evidence-based care and management of dry eye disease.

There are still so many questions. Can we prevent meibomian gland dropout? Are non-preserved drops really better? Is QID better than PRN? Can dry eye disease be a pure neuropathy?

For now, I am determined to take a thorough case history, perform the appropriate testing, consider the inflammatory process associated with dry eye, and to explain the disease clearly to my patients. ■

*Dr. Caffery is in group practice in Toronto, teaches part time at the University of Waterloo School of Optometry, and is secretary-treasurer of the board of the American Academy of Optometry.*

1. Meadows JF, Dionne K, Nichols KK. Differential Profiling of Inflammatory Cytokines as Measured by Quantitative MicroArray Across Dry Eye Subgroups. Paper presented at American Academy of Optometry Meeting 2014, November 12; Denver, CO.
2. McNamara NA, Gallup M. Establishing PAX6 as a Biomarker to Detect Early Loss of Ocular Phenotype in Human Patients with Sjögren's Syndrome. Paper presented at American Academy of Optometry Meeting 2014, November 12; Denver, CO.
3. Reins R, McDermott AM, Badour H. Vitamin D Decreases IL-8 Expression after Induction of Inflammation and Influences Gene Expression in Human Corneal Epithelial Cells. Paper presented at American Academy of Optometry Meeting 2014, November 12; Denver, CO.
4. Arita R, Itoh K, Inoue K, et al. Contact lens wear is associated with decrease of meibomian glands. *Ophthalmology*. 2009 Mar;116(3):379-84.
5. Srinivasan S, Pucker AD, Jones-Jordan LA, et al. Meibomian Gland Atrophy Rate in Pre-Presbyopic Contact Lens and Non-Contact Lens Wearers. Paper presented at American Academy of Optometry Meeting 2014, November 15; Denver, CO.
6. Pucker AD, Jones-Jordan LA, Li W, et al. Factors Associated with Meibomian Gland Atrophy in Daily Contact Lens Wearers. Paper presented at American Academy of Optometry Meeting 2014, November 15; Denver, CO.
7. Bron AJ, Tomlinson A, Foulks GN, et al. Rethinking dry eye disease: a perspective on clinical implications. *Ocul Surf*. 2014 Apr;12(2 Suppl):S1-31.
8. Li W, Graham AD, Lin MC. Understanding Ocular Discomfort and Dryness Using the Pain Sensitivity Questionnaire. Paper presented at American Academy of Optometry Meeting 2014, November 13; Denver, CO.
9. Leger S, Lacroix Z, Bitton E. Conjunctivochalasis: The other reason for dry eye. Poster presented at American Academy of Optometry Meeting 2014, November 13; Denver, CO.
10. Dastjerdi MH, Hamrah P, Dana R. High-frequency topical cyclosporine 0.05% in the treatment of severe dry eye refractory to twice-daily regimen. *Cornea*. 2009 Dec;28(10):1091-6.
11. Greene JB, Jeng BH, Fintelmann RE, Margolis TP. Oral azithromycin for treatment of meibomitis. *JAMA Ophthalmol*. 2014 Jan;132(1):121-2.
12. Kashkoui MB, Fazel AJ, Kiavash V, et al. Oral azithromycin versus doxycycline in meibomian gland dysfunction: a randomised double-masked open-label clinical trial. *Br J Ophthalmol*. 2015 Feb;99(2):199-204.
13. Narayanan S, Mickles C, Connor C, et al. Evaporative dry eye treatment with Retaine MGD artificial tears OR intraductal Meibomian gland probing...a comparison. Poster presented at American Academy of Optometry Meeting 2014, November 13; Denver, CO.
14. Karpecki PM, Tauber J, Raychaudhuri A, Semba C. Lifitegrast Ophthalmic Solution 5.0% vs. Placebo for Treatment of Dry Eye Disease: Results of a Phase 3, Randomized, Controlled Trial (Opus-2). Paper presented at American Academy of Optometry Meeting 2014, November 13; Denver, CO.



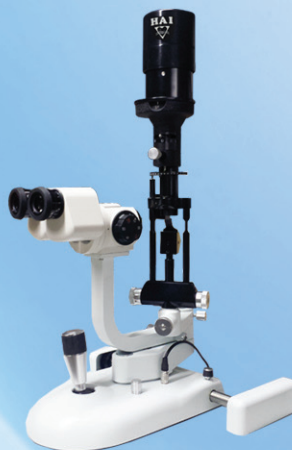Visit us at SECO booth #125 and  
Vision Expo East booth #MS6403!



**2015 NEW INVENTORY SALE PRICES**

	LIST PRICE	SALE PRICE
Basic Exam Lane Package*	\$12,998	\$12,850
SL-5000p Plus Slit Lamp	\$6,300	\$4,995
SL-5000s Standard Lamp	\$4,800	\$2,980
SL-5000bx Basic Slit Lamp	\$3,800	\$1,950
SL-5000h Handheld Slit Lamp	\$3,150	\$2,200
VC-170 17" LED Vision Chart	\$2,500	\$1,500
CL-1000eva Specular Attachment	\$14,800	\$13,500
CL-1000nc Non-Contact Specular	\$23,850	\$19,995

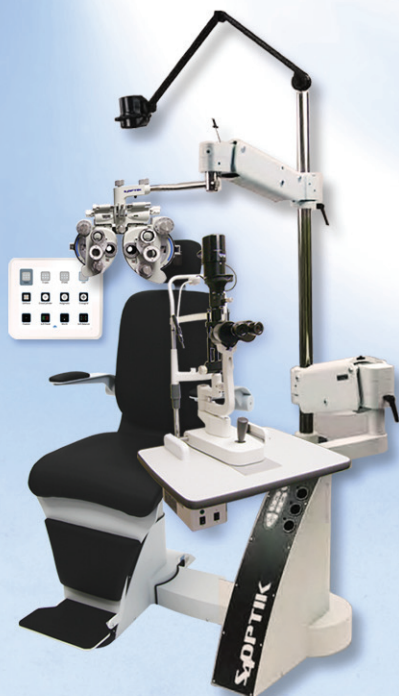\* Includes: HAI SL-5000b Basic Slit Lamp, HAI VC-170 17" LED Vision Chart, S4OPTIK CB-1600 Chair & Stand Combo and SL-Y100 Refractor



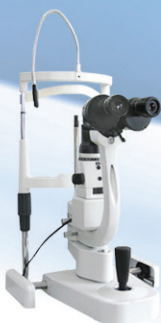**HAI SL-5000e  
Elevate Slit Lamp**

Introducing the world's first full-featured slit lamp designed for plus-sized patients and patients with limited mobility. By raising the first point of contact between patient and tabletop to the upper chest, the patient can comfortably reach the chinrest and the operator can conduct a thorough exam. Patent pending.

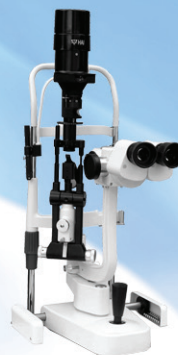*Call for pricing.*



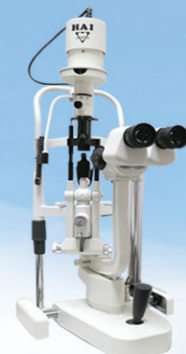**Basic Exam Lane Package**



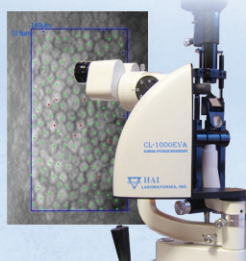
**HAI SL-5000bx  
Basic Slit Lamp**




**HAI SL-5000s  
Standard Slit Lamp**



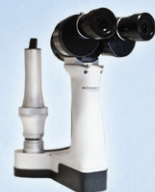**HAI SL-5000p  
Plus Slit Lamp**



**HAI CL-1000eva Endothelium  
Viewing Attachment**



**HAI CL-1000nc Non-Contact  
Specular Microscope**



**HAI SL-5000h  
Handheld Slit Lamp**

**RENT FROM  
\$385/mo**  
52-month term for  
rent-to-own

Digital slit lamps • Specular microscopes • Corneal topographers • Keratometers • Ultrasounds • Vision charts  
Autorefractors • Lensmeters • Pachymeters • Tonometers • Trial lens sets • Chairs and instrument stands



HAI Ophthalmic is a division of HAI Laboratories, Inc., an ISO 13485-certified US manufacturer.  
Call (781) 862-9884 or e-mail [sales@haiophthalmic.com](mailto:sales@haiophthalmic.com) for a free consultation.

## Essential Procedures at the Slit Lamp: How to Insert and Remove an Amniotic Membrane Graft

For a variety of corneal insults, amniotic membrane devices can speed healing, reduce scarring and improve comfort. Here's how to apply one.

**By Kyle Ryff, OD, Brianna Ryff, OD, and Nathan Lighthizer, OD**

It's Monday morning. As you're reading over your patient schedule for the day, your receptionist asks if you can take a walk-in to start the morning: Mr. Jones woke up with a very painful right eye.

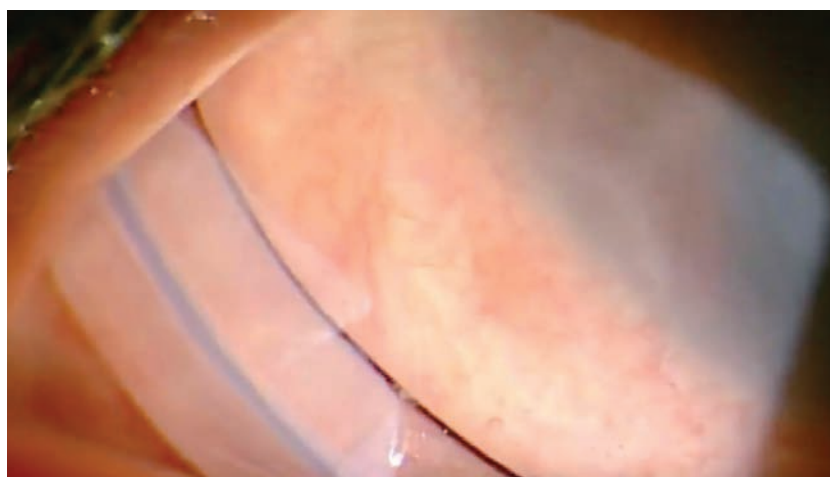
"Another recurrent corneal erosion!" you think to yourself. It's the fourth one in the last 10 months.

You wish there were a better way to manage these erosions and help prevent future recurrence. You've heard about amniotic membranes; maybe that's the solution you're looking for.

But how exactly do you use one? In this article, the second of a six-part, print-and-video instructional series, we'll show you how.

### What AMGs Can Do

Amniotic membrane grafts (AMG) were first introduced in eye care more than 60 years ago, but stable application to the eye was not



**Amniotic membrane grafts (such as the Prokera Slim, shown here) promote epithelialization, decrease inflammation and scarring, prevent new blood vessel growth and improve comfort.**

successful for the management of many ophthalmic indications until 1995.<sup>1</sup> The popularity of AMGs over the past two decades has grown immensely, perpetuated by their ability to speed healing and encourage regeneration of ocular

tissues.<sup>1-3</sup> AMGs promote epithelialization, decrease inflammation



To see a narrated video of this procedure, visit [www.reviewofoptometry.com](http://www.reviewofoptometry.com), or scan this QR code.



# NEW

## Lombart CS-5 Package

Quality, Style & Value

Package includes:

- The Lombart CS-5 Chair & Stand 
- Topcon VT-10 Refractor
- Topcon SL-2G Slit Lamp
- Reichert LongLife Chart Projector  with mount, slide & screen
- Upgrade to the Lombart CVS-PC for only \$1500 or to the CVSi21 for only \$2000 more
- Additional upgrades & configurations available.

# \$13,595

Or lease for \$265/mo.  
for 60 months\*

\*Lease rate subject to credit approval, 1st payment is due at signing with 59 remaining rental payments of \$265 and a \$1.00 purchase option. Taxes, freight and installation additional. Hand Instruments optional. Subject to change without notice.

1-800-566-2278

## Call 1-800-Lombart

Or Your Local Lombart Representative

Corporate Office - 5358 Robin Hood Road, Norfolk, VA 23513-2430  
757-853-8888 | FAX 757-855-1232 | 800-566-2278

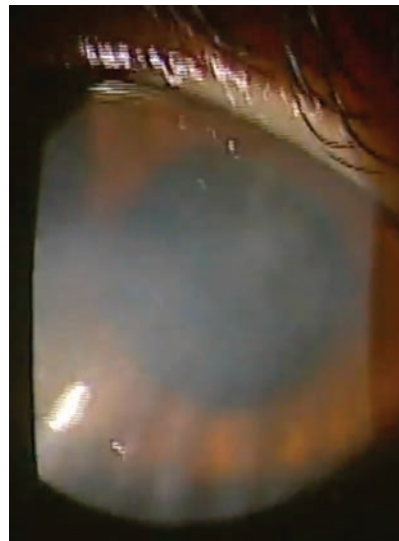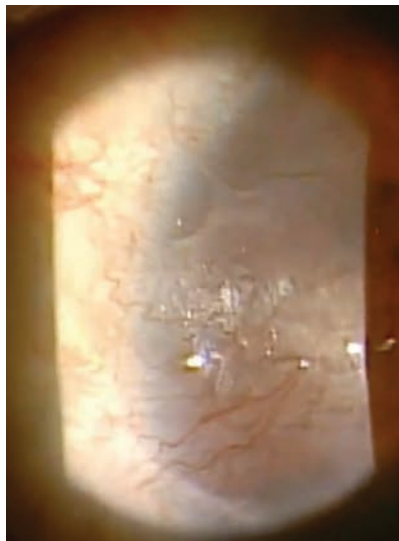
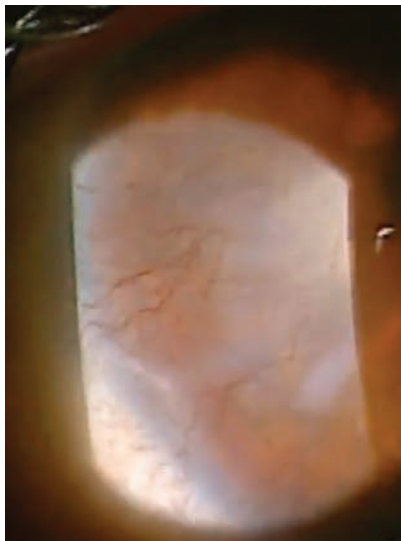[www.lombartinstrument.com](http://www.lombartinstrument.com)  
[lombart@lombartinstrument.com](mailto:lombart@lombartinstrument.com)



Sales and Service Centers Coast to Coast

ATLANTA • BALTIMORE/WASHINGTON D.C. • BOSTON • BOYNTON BEACH/MIAMI • BRADENTON • CHARLOTTE • CHICAGO • CINCINNATI • DALLAS • DENVER • DETROIT • GREENSBORO • HOUSTON  
JACKSON • KANSAS CITY • KNOXVILLE • LOS ANGELES • MILWAUKEE • MINNEAPOLIS • NEW JERSEY/NEW YORK/PENNSYLVANIA • NORFOLK • PORTLAND • SAN ANTONIO • SAN DIEGO • SAN FRANCISCO





**Our patient in this case is a 32-year-old female who had spilled bleach particles in both eyes in a work-related accident. In the right eye, which was 20/400, she had a marginal ulcer as well as extensive neovascularization, haze and scarring.**

and scarring, prevent new blood vessel growth and improve patient comfort by reducing pain.

The membrane is composed of three layers: a single layer of epithelial cells, a thick basement membrane, and an avascular stromal layer. The stromal layer is believed to help downregulate major inflammatory complexes that are found in many ocular surface conditions that can lead to scarring.<sup>4,5</sup> While anti-inflammatory mediators can indirectly reduce scarring, amniotic membranes also have a direct anti-scarring effect through inhibition of fibroblasts at a transcriptional level.<sup>6</sup>

In addition to less scarring, corneal surfaces fit with an AMG have also shown reduced neovascularization. Amniotic membrane tissue is naturally avascular, and it inhibits the migration of vascular endothelial growth factor (VEGF). Prepared AMGs seem to have this same property also; they prevent the migration of VEGF, allowing the underlying cornea to receive the inherent antiangiogenic properties of the AMG.<sup>7</sup>

## Types of AMGs

Since the discovery that AMGs accelerate corneal healing, three different types of AMGs have been developed: permanent surgical grafts, dehydrated sutureless grafts and cryopreserved sutureless grafts.

- **Surgical grafts.** Corneal surgeons use this type when a more permanent graft needs to be sutured onto the tissue; it will later dissolve. This is commonly used during conjunctival reconstruction surgeries such as pterygium resection.

- **Dehydrated sutureless grafts.** These are becoming an increasingly popular treatment by optometrists and ophthalmologists for conditions that may lead to corneal scarring. Two of the most common are the AmbioDisk (IOP Ophthalmics) and BioDOptix (BioD).

Dehydrated sutureless grafts—a flat disc of tissue without a stabilizing outer ring—require the doctor to have slightly more finesse and dexterity during application. A lid speculum is required for applying the AMG to the cornea. After the graft is smoothed out and centered over the involved area, a bandage

contact lens is applied over the top of the AMG. Special care must be taken when removing the lid speculum in order to not disrupt the graft by bumping it or the contact lens.

- **Cryopreserved sutureless grafts.** Because dehydrated AMGs may be more challenging to insert and require a lid speculum, the third type of AMG, a cryopreserved sutureless graft—the Prokera (Bio-Tissue)—is a popular choice for optometrists interested in using this treatment in their practice.

The Prokera amniotic membrane is fastened within an ophthalmic conformer ring. All cell activity of the tissue has been inactivated to eliminate the possibility of graft rejection. It is stored in a medium that contains ciprofloxacin and amphotericin B, and must be kept cold during shipping and storage.<sup>8</sup>

The grafts come in three thicknesses: Prokera (~100µm thick), Prokera Slim (~100µm, with a low profile) and Prokera Plus (~200µm). The recommended thickness is based on the severity of the corneal defect being treated—the more severe the condition, the thicker

# COST OF GOODS SAVINGS CAN ONLY HELP YOU GROW SO MUCH

IN THE NEW ERA OF  
POPULATION HEALTH MANAGEMENT,  
**WHAT'S YOUR PLAN**  
**TO WIN:**

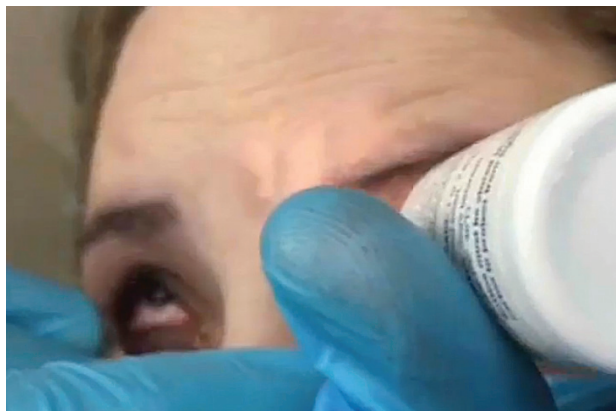- More Patients
- More Profits
- More Time
- All of the Above

Go To **VisionSourcePlan.com** and  
We'll Give You Ours



**VISION  
SOURCE**  
SIGNATURE EYE CARE

# Slit Lamp Essentials



**The first step: instill anesthetic into the involved eye.**

the AMG must be. Prokera Slim is for mild to moderate indications (such as recurrent corneal erosion), Prokera is for moderate to severe indications (neurotrophic epithelial defect) and Prokera Plus is for very severe indications (chemical burns). For most indications, we use the Prokera Slim in our offices with good success and patient comfort.

## Indications and Contraindications

Use of an AMG is clinically indicated for any condition causing damage to the ocular surface cells, underlying stromal inflammation or, most importantly, any condition that could lead to permanent scarring affecting the patient's vision. Some of these include recurrent corneal erosion, corneal sequelae of severe dry eye syndrome, neurotrophic ulcer, persistent corneal epithelial defect, chemical and

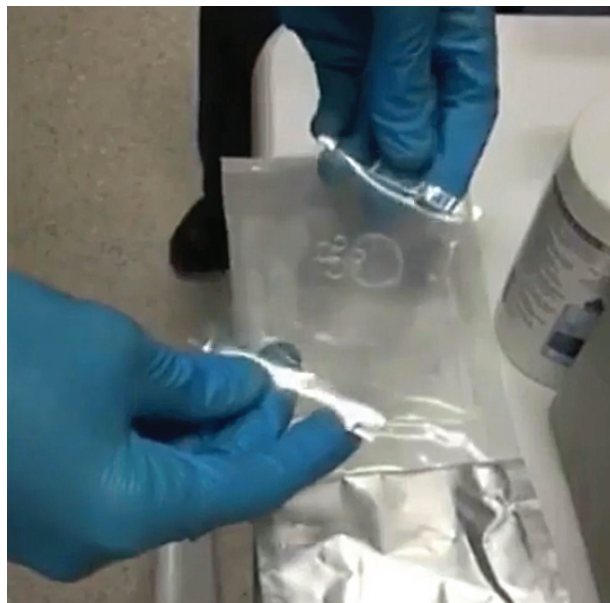thermal burn, post-DSEK for bullous keratopathy, Salzmann's nodular degeneration, acute Stevens-Johnson syndrome, microbial ulcers, herpes simplex keratitis and herpes zoster keratitis.

While a bandage contact lens may increase the incidence of microbial keratitis, no studies have demonstrated a similar occurrence with AMGs.<sup>9</sup> Therefore, unlike a bandage contact lens, an AMG may be used at any point to treat the above conditions. Maintaining adjunct pharmaceutical therapy is important when active infection is present. So, instruct patients to continue their antibiotic drop right over the top of the AMG when indicated. (We're not aware of any studies stating that topical absorption of medications is diminished by the presence of AMGs.)

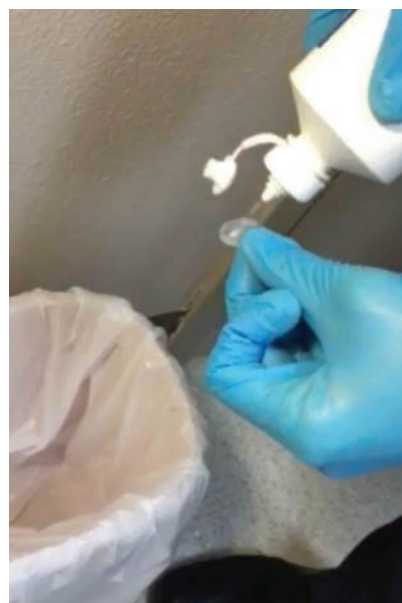
There are two main contraindications for AMGs: patients with glaucoma drainage devices or filtering blebs. Other contraindications specific to Prokera include

### AMG or BCL?

A question often posed is: "When do you use an amniotic membrane graft instead of a bandage contact lens?" The answer goes back to the inherent healing properties of the AMG. Bandage contact lenses certainly improve patient comfort, but they have no effect in scar inhibition. Strongly consider an AMG instead of a bandage contact lens in any corneal condition that has trouble healing on its own or may result in corneal scarring, such as a central corneal ulcer.



**Because the graft is stored in the freezer, allow it to thaw for a few minutes before insertion. It's OK to handle it gingerly with gloves. Forceps aren't necessary.**



**Using sterile saline, thoroughly rinse off the storage solution from the graft.**

patient allergies to ciprofloxacin or amphotericin B.<sup>10</sup>

## How to Insert the AMG


Because the Prokera has a conformer ring that makes handling



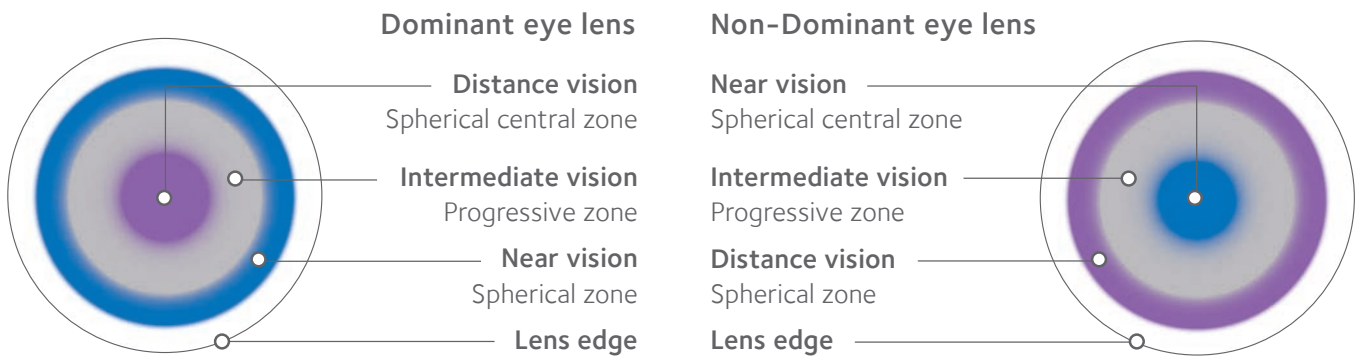
# An easy fit

for you and your presbyopic patients.

CooperVision Biofinity® multifocal lenses combine a high-performing 3rd generation material with a streamlined fitting process. Now even your most challenging presbyopic patients can enjoy the freedom of **all-distance clarity and lasting comfort.**



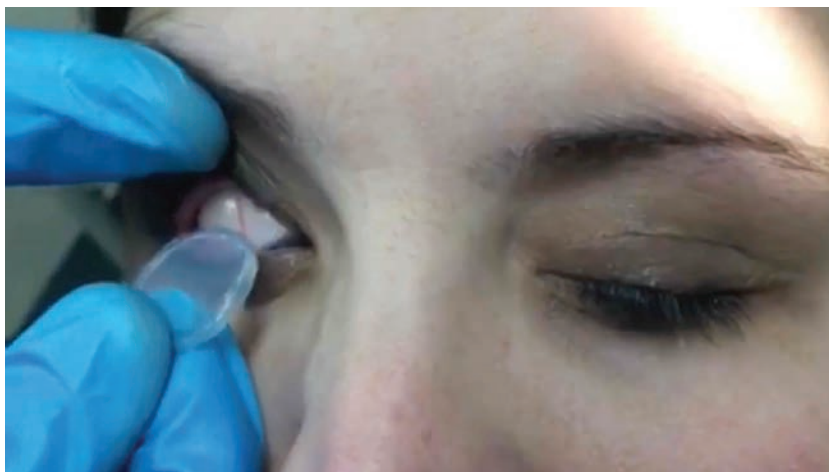**Balanced Progressive™ Technology** enhances vision near, far and intermediate. It also allows for an individualized fitting for each wearer and each eye.



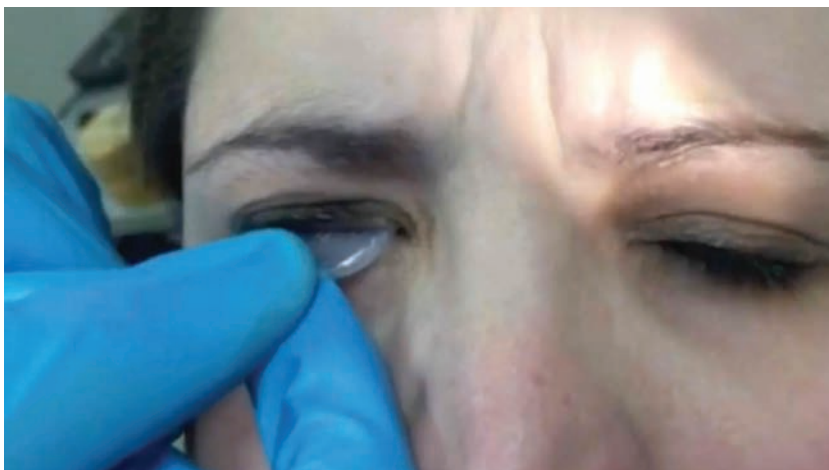
Biofinity & Biofinity XR | Biofinity toric | **Biofinity multifocal**

Download your Biofinity multifocal 3-step fitting guide at [coopervision.com/fitting-guide](http://coopervision.com/fitting-guide)

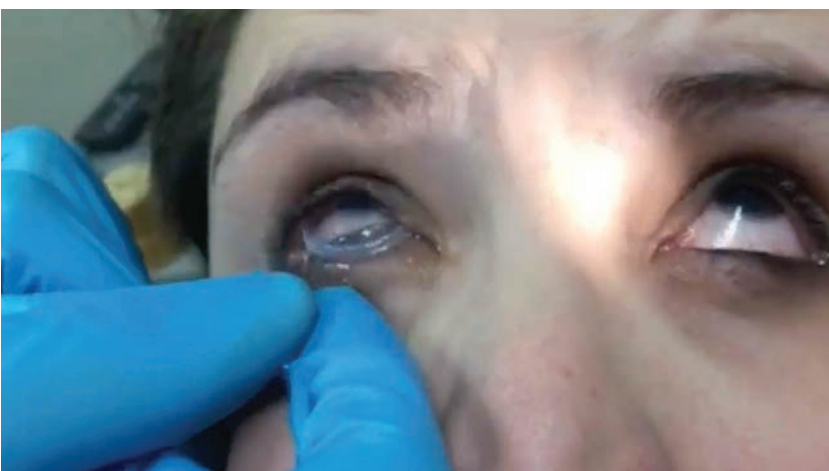# Slit Lamp Essentials



**To insert the graft, hold the upper eyelid and ask the patient to look down.**



**Slide the device into the superior fornix. The patient may feel some discomfort.**



**Ask the patient to look upward. Pull down the lower eyelid and slide the graft into the inferior fornix.**

relatively easy, application and removal is not a problem for most clinicians. Due to this, and because it's readily available to most optometrists, this article focuses on the Prokera device.

When the AMG first arrives from the manufacturer, store it at an appropriate temperature based on when it may be used. It can be stored in a standard refrigerator for up to three months or stored in a freezer for up to one year.

Once a patient is a candidate for an AMG, remove the Prokera from the fridge or freezer, and let it sit at room temperature in its unopened package for at least 10 to 15 minutes.

To insert the device:

- First, instill one drop of anesthetic into the involved eye. Note: Some conditions, such as recurrent corneal erosions or Salzmann's nodular degeneration, may benefit from corneal debridement before applying the Prokera.

- Once you open the package, be sure to handle the AMG with sterile gloves or forceps to maintain asepsis.

- Thoroughly rinse the AMG with sterile saline to remove the preservative storage solution. This will also increase initial patient comfort by reducing the stinging sensation.

- Hold the patient's upper eyelid and instruct the patient to look down. Insert the Prokera into the superior fornix. Then, instruct the patient to look straight or slightly upward. While pulling down the lower eyelid, slide the Prokera into the inferior fornix.

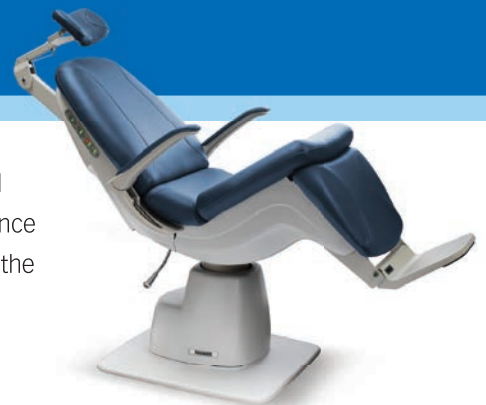- After the AMG is fully inserted, check for good centration of the AMG.

- Optional: Apply a tape tarsorrhaphy over the superior lid crease or lateral canthus to help keep the



## Boxer Randall Jones comments on the strength of Reliance arms.

Reliance chairs are built to take a beating. The armrests, footrest, chair back and apron can all withstand a patient's full weight. It's not surprising, then, that Reliance chairs last longer, and require very little maintenance. This is why they're one of the world's best-selling brand of chairs and stools. Call today for the name of your nearest authorized dealer.



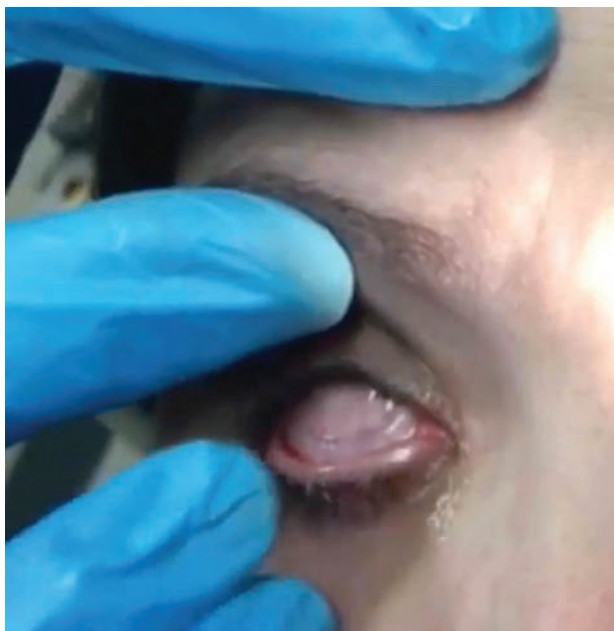800.787.5426  
[haag-streit-usa.com](http://haag-streit-usa.com)

© 2015 Haag-Streit USA. All Rights Reserved.

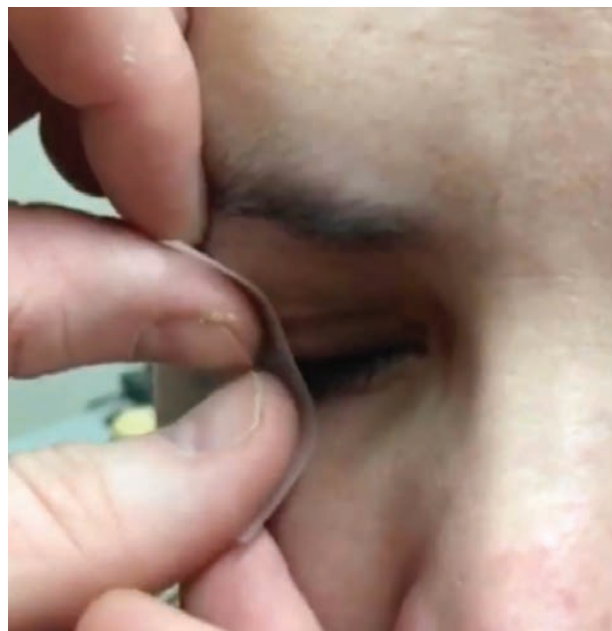 **RELIANCE  
INTERNATIONAL**



# Slit Lamp Essentials



**Ask the patient to blink gently and then check for centration.**



**A tape tarsorrhaphy can lessen the discomfort of blinking.**

Prokera centered and minimize discomfort; however, many practitioners find this unnecessary when using the Prokera Slim. The necessity and duration of the tape tarsorrhaphy varies among individual patients and their pain threshold.

Follow-up depends on the ocular condition. For example, if treating a central bacterial corneal ulcer, patient follow-up would likely be

every one to two days while using an appropriate antibiotic medication.

## How to Remove the AMG

FDA regulations require that a sutureless amniotic membrane graft cannot stay on the eye for more than 29 days. That's not usually a concern with an AMG. In most cases, it will dissolve in five to 10 days, depending on the severity of the condition. For instance, in a severe chemical burn with intense inflammation, the AMG will likely dissolve quickly in a matter of three to four days. On the other hand, a neurotrophic ulcer that has little inflammation may need the AMG for two to four weeks to fully heal. For most conditions, the Prokera

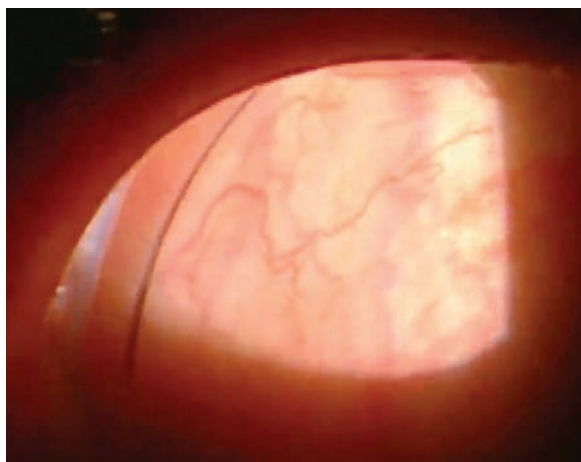
is on the ocular surface five to seven days.

Once the AMG dissolves, remove the conformer ring. If the AMG is still intact, but the ocular condition has fully healed, then remove the conformer ring and remaining AMG.

To remove the Prokera:

- First, instill one drop of topical anesthetic.
- Pull the lower eyelid down and instruct the patient to look up. Lift the lower edge of the Prokera with blunt forceps.
- Instruct the patient to look down and apply a gentle pressure in a downward motion on the superior eyelid. This allows you to pull the Prokera down and off the globe.
- While no other lubrication drops or saline are necessary, preservative-free artificial tears may be instilled after removal to improve patient comfort.

For patients battling recurrent corneal erosions or severe dry eye



**The graft's conformer ring is visible in the lateral canthus. Once the amniotic membrane graft dissolves (usually within about a week) and the eye has healed, remove the ring.**



# Monotherapy Maintained.

Proven IOP reduction<sup>1</sup>

Established tolerability with  
low discontinuation rate<sup>2</sup>

## On Your Terms.

Broad preferred coverage<sup>3</sup>

Comprehensive patient support

### INDICATION

LUMIGAN<sup>®</sup> (bimatoprost ophthalmic solution) 0.01% is indicated for the reduction of elevated intraocular pressure in patients with open angle glaucoma or ocular hypertension.

### IMPORTANT SAFETY INFORMATION

#### WARNINGS AND PRECAUTIONS

LUMIGAN<sup>®</sup> 0.01% causes changes to pigmented tissues, mostly increased pigmentation of the iris, eyelid, and eyelashes as long as LUMIGAN<sup>®</sup> 0.01% is administered. Iris color change may not be noticeable for several months to years. After discontinuation of bimatoprost, iris pigmentation is likely to be permanent, while eyelid and eyelash changes have been reported to be reversible in some patients. Patients should be informed of the possibility of increased pigmentation. The long term effects of increased pigmentation are not known.

Prostaglandin analogs, including bimatoprost, have been reported to cause intraocular inflammation. These products may also exacerbate inflammation, so use with caution in patients with active intraocular inflammation (e.g., uveitis). Macular edema, including cystoid macular edema, has been reported with LUMIGAN<sup>®</sup> 0.01%. LUMIGAN<sup>®</sup> 0.01% should be used with caution in aphakic patients, in pseudophakic patients with a torn posterior lens capsule, or in patients with known risk factors for macular edema. Remove contact lenses prior to instillation of LUMIGAN<sup>®</sup> 0.01% and reinsert after 15 minutes.

#### ADVERSE REACTIONS


The most common adverse reaction was conjunctival hyperemia (31%). Approximately 1.6% of patients discontinued therapy due to conjunctival hyperemia. Other adverse drug reactions (reported in 1 to 4% of patients) with LUMIGAN<sup>®</sup> 0.01% included conjunctival edema, conjunctival hemorrhage, eye irritation, eye pain, eye pruritus, erythema of eyelid, eyelids pruritus, growth of eyelashes, hypertrichosis, instillation site irritation, punctate keratitis, skin hyperpigmentation, vision blurred, and visual acuity reduced.

**Please see Brief Summary of the full Prescribing Information on adjacent page.**

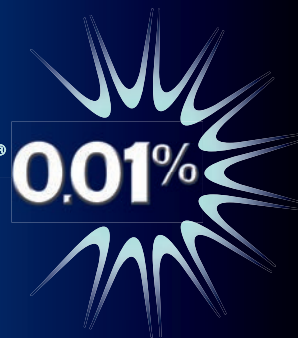1. LUMIGAN<sup>®</sup> Prescribing Information. 2. Katz LJ, Cohen JS, Batoosingh AL, Felix C, Shu V, Schiffman RM. Twelve-month, randomized, controlled trial of bimatoprost 0.01%, 0.0125%, and 0.03% in patients with glaucoma or ocular hypertension. *Am J Ophthalmol.* 2010;149(4):661-671. 3. Managed Markets Insight & Technology, LLC, database, as of October 2014.

 ALLERGAN

©2014 Allergan, Inc., Irvine, CA 92612. ®marks owned by Allergan, Inc. Managed Markets Insight & Technology is a portfolio company of Susquehanna Growth Equity. [www.lumigan.com](http://www.lumigan.com) APC43HN14 143788



**LUMIGAN<sup>®</sup> 0.01%**  
(bimatoprost ophthalmic solution) 0.01%



# LUMIGAN® 0.01%

(bimatoprost ophthalmic solution)

**Brief Summary—Please see the LUMIGAN® 0.01% package insert for full Prescribing Information.**

## INDICATIONS AND USAGE

**LUMIGAN®** (bimatoprost ophthalmic solution) 0.01% is indicated for the reduction of elevated intraocular pressure in patients with open angle glaucoma or ocular hypertension.

## CONTRAINDICATIONS

None

## WARNINGS AND PRECAUTIONS

**Pigmentation:** Bimatoprost ophthalmic solution has been reported to cause changes to pigmented tissues. The most frequently reported changes have been increased pigmentation of the iris, periorbital tissue (eyelid) and eyelashes. Pigmentation is expected to increase as long as bimatoprost is administered. The pigmentation change is due to increased melanin content in the melanocytes rather than to an increase in the number of melanocytes. After discontinuation of bimatoprost, pigmentation of the iris is likely to be permanent, while pigmentation of the periorbital tissue and eyelash changes have been reported to be reversible in some patients. Patients who receive treatment should be informed of the possibility of increased pigmentation. The long term effects of increased pigmentation are not known.

Iris color change may not be noticeable for several months to years. Typically, the brown pigmentation around the pupil spreads concentrically towards the periphery of the iris and the entire iris or parts of the iris become more brownish. Neither nevi nor freckles of the iris appear to be affected by treatment. While treatment with **LUMIGAN®** (bimatoprost ophthalmic solution) 0.01% can be continued in patients who develop noticeably increased iris pigmentation, these patients should be examined regularly [see Patient Counseling Information (17.1)].

**Eyelash Changes:** **LUMIGAN®** 0.01% may gradually change eyelashes and vellus hair in the treated eye. These changes include increased length, thickness, and number of lashes. Eyelash changes are usually reversible upon discontinuation of treatment.

**Intraocular Inflammation:** Prostaglandin analogs, including bimatoprost, have been reported to cause intraocular inflammation. In addition, because these products may exacerbate inflammation, caution should be used in patients with active intraocular inflammation (e.g., uveitis).

**Macular Edema:** Macular edema, including cystoid macular edema, has been reported during treatment with bimatoprost ophthalmic solution. **LUMIGAN®** 0.01% should be used with caution in aphakic patients, in pseudophakic patients with a torn posterior lens capsule, or in patients with known risk factors for macular edema.

**Bacterial Keratitis:** There have been reports of bacterial keratitis associated with the use of multiple-dose containers of topical ophthalmic products. These containers had been inadvertently contaminated by patients who, in most cases, had a concurrent corneal disease or a disruption of the ocular epithelial surface [see Patient Counseling Information (17.3)].

**Use with Contact Lenses:** Contact lenses should be removed prior to instillation of **LUMIGAN®** 0.01% and may be reinserted 15 minutes following its administration.

## ADVERSE REACTIONS

**Clinical Studies Experience:** Because clinical studies are conducted under widely varying conditions, adverse reaction rates observed in the clinical studies of a drug cannot be directly compared to rates in the clinical studies of another drug and may not reflect the rates observed in practice.

In a 12-month clinical study with bimatoprost ophthalmic solutions 0.01%, the most common adverse reaction was conjunctival hyperemia (31%). Approximately 1.6% of patients discontinued therapy due to conjunctival hyperemia. Other adverse drug reactions (reported in 1 to 4% of patients) with **LUMIGAN®** 0.01% in this study included conjunctival edema, conjunctival hemorrhage, eye irritation, eye pain, eye pruritus, erythema of eyelid, eyelids pruritus, growth of eyelashes, hypertrichosis, instillation site irritation, punctate keratitis, skin hyperpigmentation, vision blurred, and visual acuity reduced.

**Postmarketing Experience:** The following reaction has been identified during postmarketing use of **LUMIGAN®** 0.01% in clinical practice. Because it was reported voluntarily from a population of unknown size, estimates of frequency cannot be made. The reaction, which has been chosen for inclusion due to either its seriousness, frequency of reporting, possible causal connection to **LUMIGAN®** 0.01%, or a combination of these factors, includes headache.

In postmarketing use with prostaglandin analogs, periorbital and lid changes including deepening of the eyelid sulcus have been observed.

## USE IN SPECIFIC POPULATIONS

**Pregnancy:** Pregnancy Category C

Teratogenic effects: In embryo/fetal developmental studies in pregnant mice and rats, abortion was observed at oral doses of bimatoprost which achieved at least 33 or 97 times, respectively, the maximum intended human exposure based on blood AUC levels.

At doses at least 41 times the maximum intended human exposure based on blood AUC levels, the gestation length was reduced in the dams, the incidence of dead fetuses, late resorptions, peri- and postnatal pup mortality was increased, and pup body weights were reduced.

There are no adequate and well-controlled studies of **LUMIGAN®** (bimatoprost ophthalmic solution) 0.01% administration in pregnant women. Because animal reproductive studies are not always predictive of human response **LUMIGAN®** 0.01% should be administered during pregnancy only if the potential benefit justifies the potential risk to the fetus.

**Nursing Mothers:** It is not known whether **LUMIGAN®** 0.01% is excreted in human milk, although in animal studies, bimatoprost has been shown to be excreted in breast milk. Because many drugs are excreted in human milk, caution should be exercised when **LUMIGAN®** 0.01% is administered to a nursing woman.

**Pediatric Use:** Use in pediatric patients below the age of 16 years is not recommended because of potential safety concerns related to increased pigmentation following long-term chronic use.

**Geriatric Use:** No overall clinical differences in safety or effectiveness have been observed between elderly and other adult patients.

**Hepatic Impairment:** In patients with a history of liver disease or abnormal ALT, AST and/or bilirubin at baseline, bimatoprost 0.03% had no adverse effect on liver function over 48 months.

## OVERDOSAGE

No information is available on overdosage in humans. If overdose with **LUMIGAN®** (bimatoprost ophthalmic solution) 0.01% occurs, treatment should be symptomatic. In oral (by gavage) mouse and rat studies, doses up to 100 mg/kg/day did not produce any toxicity. This dose expressed as mg/m<sup>2</sup> is at least 210 times higher than the accidental dose of one bottle of **LUMIGAN®** 0.01% for a 10 kg child.

## NONCLINICAL TOXICOLOGY

**Carcinogenesis, Mutagenesis, Impairment of Fertility:** Bimatoprost was not carcinogenic in either mice or rats when administered by oral gavage at doses of up to 2 mg/kg/day and 1 mg/kg/day respectively (at least 192 and 291 times the recommended human exposure based on blood AUC levels respectively) for 104 weeks.

Bimatoprost was not mutagenic or clastogenic in the Ames test, in the mouse lymphoma test, or in the *in vivo* mouse micronucleus tests.

Bimatoprost did not impair fertility in male or female rats up to doses of 0.6 mg/kg/day (at least 103 times the recommended human exposure based on blood AUC levels).

## PATIENT COUNSELING INFORMATION

**Potential for Pigmentation:** Advise patients about the potential for increased brown pigmentation of the iris, which may be permanent. Also inform patients about the possibility of eyelid skin darkening, which may be reversible after discontinuation of **LUMIGAN®** (bimatoprost ophthalmic solution) 0.01%.

**Potential for Eyelash Changes:** Inform patients of the possibility of eyelash and vellus hair changes in the treated eye during treatment with **LUMIGAN®** 0.01%. These changes may result in a disparity between eyes in length, thickness, pigmentation, number of eyelashes or vellus hairs, and/or direction of eyelash growth. Eyelash changes are usually reversible upon discontinuation of treatment.

**Handling the Container:** Instruct patients to avoid allowing the tip of the dispensing container to contact the eye, surrounding structures, fingers, or any other surface in order to avoid contamination of the solution by common bacteria known to cause ocular infections. Serious damage to the eye and subsequent loss of vision may result from using contaminated solutions.

**When to Seek Physician Advice:** Advise patients that if they develop an intercurrent ocular condition (e.g., trauma or infection), have ocular surgery, or develop any ocular reactions, particularly conjunctivitis and eyelid reactions, they should immediately seek their physician's advice concerning the continued use of **LUMIGAN®** 0.01%.

**Use with Contact Lenses:** Advise patients that **LUMIGAN®** 0.01% contains benzalkonium chloride, which may be absorbed by soft contact lenses. Contact lenses should be removed prior to instillation of **LUMIGAN®** 0.01% and may be reinserted 15 minutes following its administration.

**Use with Other Ophthalmic Drugs:** Advise patients that if more than one topical ophthalmic drug is being used, the drugs should be administered at least five (5) minutes between applications.

©2014 Allergan, Inc., Irvine, CA 92612

® marks owned by Allergan, Inc.

Patented. See: [www.allergan.com/products/patent\\_notices](http://www.allergan.com/products/patent_notices)

Made in the U.S.A.

APC87B014 based on 71807US14.

Rx only

 ALLERGAN



syndrome, do not let them continue to suffer using standard treatments. What about those patients with central corneal ulcers or chemical burns and the threat of permanent vision loss? Consider an AMG.

By improving a patient's severe corneal condition and restoring their quality of life, you'll gain the patient's deepest loyalty. If you're able to provide a treatment that reduces scarring, promotes healing, decreases pain and helps to preserve vision, these patients will open the door to a number of new referrals. ■

*Dr. Kyle Ryff is a graduate of the Southern California College of Optometry and is currently completing an Ocular Disease and Family Practice Residency at the Oklahoma College of Optometry with an emphasis in disease management and anterior segment laser procedures.*

*Dr. Brianna Ryff graduated from the Southern California College of Optometry and is the Cornea and Contact Lens resident at the Oklahoma College of Optometry. She is joining a private practice in Tempe, AZ to fit specialty contact lenses.*

*Dr. Lighthizer is the assistant dean for clinical care services, director of continuing education, and chief of both the specialty care clinic and the electrodiagnostics clinic at the Oklahoma College of Optometry.*

*The authors have no conflict of interest or financial relationship with Bio-Tissue.*

## Coding Connection: Coding for Prokera

**By John Rumpakis, OD, MBA, Clinical Coding Editor**

Inserting a Prokera may seem as simple as applying a bandage contact lens—but take care when coding and billing, or you may make an alarming mistake.

Amniotic products are used in medicine for a wide array of problems, and the eye is no different. The American Medical Association created CPT Code 65778 (currently defined as: “Placement of amniotic membrane on the ocular surface; without sutures,” with a 10-day global period) because it recognized the importance of delivering the wound healing properties of cryopreserved amniotic membrane to the ocular surface without the use of sutures.

Subsequently, the Center for Medicare and Medicaid Services (CMS) authorized payment policies for the procedure to be performed in both facility and non-facility settings, and all local Medicare carriers established coverage policies for this procedure.

Although CPT references it as a surgical procedure, clinical application of a Prokera amniotic membrane device is virtually identical to the insertion of a bandage contact lens. So can this “surgical procedure” be performed by an optometrist?

The answer is, it depends. Most state boards of optometry have deemed this procedure to be well within the optometric scope of practice. In fact, a recent consideration by CMS on the use of amniotic membranes for ocular surface disease states: “our medical advisors indicated that the procedure described by CPT code 65778 is not significantly different than placing a bandage contact lens on the surface of the eye to cover a corneal epithelial defect. CPT code 65778 describes the simple placement of a special type of bandage (a self-retaining amniotic membrane device) on the surface of the eye, which would most commonly be used in the HOPD [hospital outpatient department] to cover the surface of the eye after a procedure that results in a corneal epithelial defect.”<sup>1</sup>

Keep in mind that for CMS, a separate charge and reimbursement for the supply of the amniotic membrane is not allowed; it's bundled into the reimbursement for the procedure itself (not unlike the rationale used for punctal plugs).

However, other commercial carriers may have policies that allow for reimbursement of the procedure and the materials, and if so, the appropriate HCPCS Level II code is V2790 (“Amniotic membrane for surgical reconstruction, per procedure.”)

Most importantly, because this is considered to be a minor surgical procedure, and in accordance with minor surgical rules, an office visit (either 920XX or 992XX) is generally *not* separately billable when performed on the same date of service as CPT code 65778. That's because reimbursement for the 65778 code itself already includes compensation for the office visit related to the decision to perform this minor surgical procedure. So it would be the rare occasion to append modifier -25 to an E/M office visit performed on the same day as the application of a Prokera.

*Question or comments? E-mail [ROcodingconnection@gmail.com](mailto:ROcodingconnection@gmail.com).*

1. Ocular Services: Placement of Amniotic Membrane (APC 0233). Federal Register. Rules and Regulations. 2012 Nov 15;77(221): 68339-41. Available at: <http://69.175.53.6/register/2012/Nov/15/2012-26902.pdf>.

1. Liu J, Sheha H, Fu Y, et al. Update on amniotic membrane transplantation. *Expert Rev Ophthalmol*. 2010 October; 5(5): 645-61.  
 2. Mast BA, Diegelmann RF, Krummel TM, Cohen IK. Scarless wound healing in mammalian fetus. *Surgery*. 1992; 174:441-51.  
 3. Adzick NS, Lorenz HP. Cells, matrix, growth factors, and the surgeon. The biology of scarless fetal wound repair. *Ann Surg*. 1994; 220:10-18.  
 4. Heiligenhaus A, Meller D, Meller D, Steuhl K-P, Tseng SCG. Improvement of HSV-1 necrotizing keratitis with amniotic membrane transplantation. *Invest Ophthalmol Vis Sci*.

2001;42:1969-74.

5. He H, Li W, Chen SY, et al. Suppression of activation and induction of apoptosis in RAW264.7 cells by amniotic membrane extract. *Invest Ophthalmol Vis Sci*. 2008; 49(10):4468-75.  
 6. Tseng SCG, Li D-Q, Ma X. Suppression of transforming growth factor isoforms, TGF-β receptor II, and myofibroblast differentiation in cultured human corneal and limbal fibroblasts by amniotic membrane matrix. *J Cell Physiol*. 1999; 179:325-35.  
 7. Jiang A, Li C, Gao Y, et al. In vivo and in vitro inhibitory

effect of amniotic extraction on neovascularization. *Cornea*. 2006; 25(10 Suppl. 1):S36-S40.  
 8. Prokera Slim Product Insert. Bio-Tissue website: [www.biotissue.com/downloads/prokera-slim-insert\\_PI-BT-004E\\_V1.pdf](http://www.biotissue.com/downloads/prokera-slim-insert_PI-BT-004E_V1.pdf). Accessed Dec 10, 2014.  
 9. Kent HD, Cohen EJ, Laibson PR, et al. Microbial keratitis and corneal ulceration associated with therapeutic soft contact lenses. *CLAO J*. 1990;16(1):49-52.  
 10. Prasher P, Lehmann JD, Aggarwal NK. Ahmed tube exposure secondary to prokera implantation. *Eye Contact Lens*; 34 (4); 244-5.



# Be a Visionary at SECO 2015

For cutting-edge CE, there's no place like SECO, "Where Sight Meets Vision."

**By Jane Cole, Contributing Editor**

**V**ision isn't just being able to see with your eyes. "Where Sight Meets Vision," the theme for SECO's 2015 congress, plays on the other definition of vision as the ability to plan for the future with imagination and knowledge.

SECO International has crafted its upcoming congress—held in Atlanta from March 4 to 8—with just this philosophy in mind.

## Can't Miss CE

"SECO has long been known as the meeting to attend if you are looking for cutting-edge optometric education, and this year is no exception," says optometrist James Herman, president of SECO International. "Our profession is changing rapidly, and we have designed the courses at SECO 2015 to meet today's needs while still expanding the boundaries of optometric practice. SECO International is committed to providing a quality education to everyone in the eye care profes-

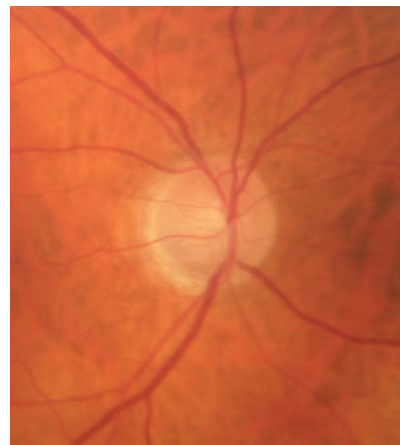
sion with courses that allow both optometrists and allied ophthalmic professionals to get ahead of the curve and focused on success."

Education highlights you won't want to miss:

- More than 250 courses, including six special sessions for optometrists, SECO's symposium series and more than 100 additional courses.

- Special session "New Angles on Glaucoma," featuring world-renowned glaucoma specialist David Friedman, MD, PhD, of the Wilmer Eye Institute, along with his moderator and co-speaker, one of optometry's key leaders in glaucoma, Murray Fingeret, OD. The duo will cover the latest news in glaucoma, including advanced diagnostic testing, the role of the central field, macular imaging and compliance.

- Cataract experts Lawrence Woodard, MD, and Brett Fisher, MD, will present on current and future advances in cataract surgery



**At SECO 2015, glaucoma specialists David Friedman, MD, PhD, and Murray Fingeret, OD, will present a special session on "New Angles on Glaucoma."**

and will discuss the optometrist's role in counseling and comanaging this large patient population during the "The Future of Cataract Surgery" special session.

- The "Cutting Edge Cornea" special session will take a look at the latest developments in the medical and surgical management of the





**SECO 2015 offers nearly 400 hours of continuing education for optometrists, opticians, paraoptometrics, ophthalmic technicians and administrative staff. Education includes Special Sessions, an AOP General Session, hourly lectures, hands-on workshops, certification reviews and Team-Centered Learning for the entire office.**

anterior segment from one of the nation's leading corneal specialists, Terry Kim, MD.

- “Stay Out of the Fire: Managing Your Practice Within the Law,” will help guide you through the regulatory and legal challenges facing your practice, with solutions to help minimize liability.

- SECO's Learning Labs—topics for these hands-on courses include low vision, injections, fundus photography and minor surgical procedures.

- SECO's team-centered learning courses will focus on practice management, technology and compliance. Some of the topics for 2015 are the HIPAA/HITECH Act, EHR Stage 2 and beyond, ICD-10 and low vision.

- A jurisprudence course will be back by popular demand this year. It will review the Florida Optometric Practice Act and help Florida ODs meet the jurisprudence requirement for their state.

- The Optometry's Marketplace Advanced Media Learning Center will showcase multimedia educational posters and the opportunity for optometrists to earn up to three hours of free CE credit.

### Education Like No Other

“SECO continues its tradition of creating unique learning opportunities for attendees, with special sessions from experts like Dr. Terry Kim, chairman of the Corneal and Refractive Surgery Services at Duke University, who will explore the newest corneal conditions and techniques that most will be hearing about for the first time,” says optometrist Paul C. Ajamian, SECO optometric education program development committee chair.

Even before SECO 2015 kicks off, optometrists have the opportunity to gain CE credits with the recently launched SECO University ([secouniversity.com](http://secouniversity.com)). This online resource offers up to 50 hours of COPE-approved online CE from past SECO congresses along with course recordings and other resources. Anyone who regis-

ters for the all-inclusive package for SECO 2015 will also get a year's access to SECO University for free.

“No other meeting provides the hospitality, Southern charm and unique fellowship opportunities like SECO does,” Dr. Ajamian says. “Staff and doctors alike are exposed to a slew of ideas and leave the meeting with renewed energy to implement them.”

For more information or to register for SECO 2015, go to: [www.seco2015.com](http://www.seco2015.com). ■



**Last year's Eye Dissection Workshop with instructor Thomas Griffith, OD (right).**



# Neuro-Ophthalmic Disease Basics: Evaluating the Efferent Visual System

Accurately diagnosing neuro-ophthalmic disease can be difficult and intimidating. But a stepwise approach can make the task less daunting and keep you on track.

By Kelly A. Malloy, OD

**M**any optometrists feel uncomfortable with cases related to neuro-ophthalmic disease. Either you fear that you'll overlook an important finding and not refer a patient who truly does have neuro-ophthalmic disease, or you're concerned that you'll over-analyze a certain symptom and refer a patient for unnecessary consultation or testing.

What you should realize is that you already have all of the required tools to accurately examine and assess a patient who has a neuro-ophthalmic disease process. All you need now is to spend some time

sharpening those tools.

Previous articles have reviewed the afferent visual system. Here's the counterpart approach for assessing the *efferent* visual system.

It's impossible to include all aspects of the efferent visual system evaluation in one article. However, this article covers the important basics that will help you not only become more confident at diagnosing and monitoring neuro-ophthalmic disease of the efferent visual system, but also feel more confident in referring and comanaging a patient with an appropriate specialist.

## Afferent vs. Efferent

As referenced in the June 2008 article regarding the afferent visual system, separating your examination into tests that assess the afferent versus efferent visual system can make neuro-ophthalmic disease less overwhelming.<sup>1</sup> It is important to make this distinction so that you know which tests to do when checking for a certain disease process. Granted, a disease process may affect both systems. However, if you think of the afferent and efferent systems separately, it will be easier to determine which tools and tests to employ to make a proper diagnosis.

**Release Date:** February 2015

**Expiration Date:** February 1, 2018

**Goal Statement:** Many optometrists are uncomfortable with cases of neuro-ophthalmic disease. This article will help you not only become more confident at diagnosing and monitoring neuro-ophthalmic disease of the efferent visual system, but also feel more confident in referring and comanaging a patient with a specialist.

**Faculty/Editorial Board:** Kelly A. Malloy, OD

**Credit Statement:** COPE approval for 2 hours of CE credit is pending for this course. Check with your local state licensing board to see if this counts toward your CE requirement for relicensure.

**Joint-Sponsorship Statement:** This continuing education course is joint-sponsored by the Pennsylvania College of Optometry.

**Disclosure Statement:** Dr. Malloy has no relationships to disclose.



The afferent system carries impulses from the eye to the central nervous system, whereas the efferent system carries impulses from the central nervous system to the eye. Therefore, the afferent system deals with optic nerve function. The efferent system is associated with ocular motility issues, ptosis or eyelid retraction, anisocoria and nystagmus.

When dealing with any issue involving pupil sizes, eyelids or eye movements, you must know how to test all measures of the efferent visual system. Many times, a disease process that affects the efferent visual system can manifest through a combination of findings related to eyelid position, pupil size and ocular motility. This could, therefore, indicate possible involvement of a combination of muscles, the neuromuscular junction, various nerves (cranial nerves or autonomic nervous system) and/or the brain/brainstem/cerebellum. A good understanding of neuro-anatomy is critical in localizing a disease process. In addition, a cursory neurologic examination assessing all cranial nerves, motor function, sensory function and coordination is also helpful in localizing a lesion.

### Patient History

Just as patient history is a key factor in assessing the afferent visual system, it's also essential in assessing the efferent visual system. You must consider the patient's systemic and ocular health, as well as lifestyle habits.

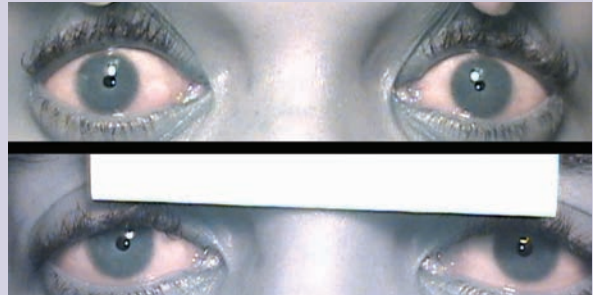
- **Systemic history.** Important aspects of the systemic history include any condition that can contribute to an ischemic, inflammatory or infectious process. Be sure to ask about specific disease states such as multiple sclerosis, myasthenia gravis, thyroid disease, stroke, systemic infections or inflammations, or any other known health conditions. Also,

### How to Rule Out Horner Syndrome

An in-office diagnostic test for Horner syndrome is the use of readily available apraclonidine ophthalmic solution. Instill either 0.5% or 1% apraclonidine into both eyes and assess the pupil sizes for change. A positive result is a dilation of the smaller pupil, and therefore a reversal of anisocoria. The eye with the Horner syndrome dilates due to upregulation of the alpha-1 receptors. If the test remains negative at 30 minutes, you need to repeat the measurements at one hour.

Note that a false negative result may occur with acute Horner syndrome, such as in acute internal carotid artery dissection.<sup>6-8</sup>

In determining the urgency of a workup, an important reminder is that Horner syndrome with any pain in the neck or head region needs to be considered a carotid dissection until that can be ruled out. This is a medical emergency because of its risk of impending stroke; send the patient to the emergency room for urgent evaluation and treatment.<sup>9</sup>



**Pre-drop presentation (top) shows anisocoria OD>OS, which was greatest in dim illumination, signifying a sympathetic issue, and suggestive of Horner syndrome. After instillation of apraclonidine 0.5% (bottom), dilation OS — with reversal of anisocoria — confirms Horner syndrome.**

any history of cancer is important. If there is a history of cancer, always consider that recurrence or a metastatic lesion could be the cause of the clinical presentation.

Additionally, if the patient has had a stroke or other intracranial pathology in the past, you must obtain a copy of the imaging report to determine the location of the abnormality. If it's not in an anatomic region that would explain the efferent visual system findings, additional work-up is needed to find the cause.

- **Ocular history.** Clearly, ocular history is important in determining the differential diagnoses for an efferent visual system issue. Find out if the patient has a history of trauma, which could contribute to changes in pupil size and shape, eyelid positioning, ocular alignment and motility. Often, patients may either forget about or deny a history of trauma to their eyes or head, but then on

external evaluation you'll note scars or other telltale signs of past trauma or surgery. However, don't assume that an efferent visual system issue is a result of past trauma unless you have substantive proof from previous records or examinations, or until other etiologies have been ruled out.

- **Medications.** Know all medications and supplements your patient is using. Some medications can contribute to muscle weakness and therefore contribute to ptosis or ocular motility problems. For example, statins have been proven to cause diplopia.<sup>2</sup> Anti-seizure medications such as phenytoin can cause nystagmus.<sup>3</sup>

- **Social history.** Because substance abuse could be related to the patient's condition, ask about the patient's history of tobacco, alcohol and drug use. All of these can be risk factors for stroke. In addition, tobacco use increases the likelihood of ocular involvement from thyroid

disease, and alcohol use can cause nystagmus.<sup>4,5</sup>

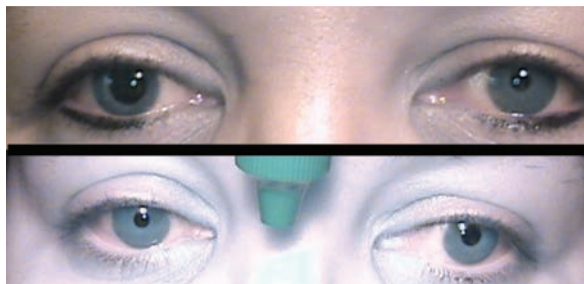## Assessment Tools

The main tools needed to evaluate efferent visual function are pupil measurements, eyelid measurements, exophthalmometry, ductions and versions, as well as cover testing. You're already familiar with these tools, and likely use them regularly. However, you need to be sure you're using them to their maximum capacity. Often, efferent visual system problems can affect multiple components of the efferent visual system. Therefore, no value or measurement should be assessed in isolation. For example, whenever you note a difference in pupil sizes, also keep in mind the results of eyelid measurements and ocular motility findings. Such is the case when considering a Horner syndrome or cranial nerve (CN) III palsy.

- **Measuring pupil sizes.** Too often, doctors simply estimate or "eyeball" pupil sizes; we need to be sure to measure them as accurately as possible. Sometimes critical—even life-threatening—diagnoses are made because the difference in pupil sizes is 0.5mm or less.

For all pupil measurements, be sure the patient is looking at a distant target. If the patient looks at a near target, you'll confuse the reaction to light with the accommodative response.

If the pupils are the same size, or isocoric, there is no efferent pupil problem. If the pupils are anisocoric, the cause could be either physiologic or pathologic, and careful pupil measurements can help make that distinction. The best way to measure pupil size is with the half circle indicators. These half circles are present in 1mm increments. Of course, pupil sizes do not just come in 1mm steps.



**Diagnostic drops for pupil testing: pre-drop presentation (top) is anisocoria OD>OS, which was greatest in bright illumination, signifying a parasympathetic issue. Differential includes CN III, pharmacologic dilation, tonic pupil. After instillation of 0.12% pilocarpine (bottom), constriction OD confirms a tonic pupil.**

Therefore, you must interpolate the pupil size to at least the nearest 0.5mm. This will be much harder to do using a millimeter rule.

- **Pupil size in bright vs. dim illumination.** Pupil sizes need to be measured in contrasting illuminations. They should be measured with the illumination as high as possible, and then again with the illumination as low as possible. To measure pupils in bright illumination, have the room and overhead lights on, with the light equally illuminating both eyes. When measuring pupils in dim illumination, all lights should be off. Use a transilluminator directed from below, with just enough illumination that you can see and measure the pupils. Be careful not to place more illumination on one eye than the other, or measure the pupils at two different times with unequal amounts of illumination. Try to hold the light at a comparable distance and angle from each eye. This will help to ensure consistency in measurements.

Take note of the difference in pupil sizes in bright illumination. Compare this to the difference in pupil sizes in dim illumination. If the difference in pupil sizes in each illumination is the same, this is consistent with physiologic anisocoria, and no additional work-up is needed.

One exception is if there is a ptosis on the same side as the smaller pupil, in which case you should still rule out Horner syndrome.

If the anisocoria is greater in either bright or dim illumination, this signifies a pathologic process of the autonomic nervous system. Because the sympathetic system acts to dilate the pupil, damage to the sympathetic pathway results in a smaller pupil and anisocoria that is greater in dim illumination.

This, especially in the setting of a smaller palpebral aperture on the same side, is indicative of Horner syndrome. Because there is a characteristic dilation lag in Horner syndrome, you'll note the anisocoria in dim illumination is greatest as soon as the lights are turned off, and somewhat less several seconds later. (See "How to Rule Out Horner Syndrome," page 75.)

Conversely, because the parasympathetic system acts to constrict the pupil, damage to the iris sphincter leads to anisocoria, which is greater in bright illumination. When this is present, we must consider differentials, including a CN III palsy, pharmacologic dilation and tonic pupil. Of course, other tests of efferent visual function, such as eyelid measurements and ocular motilities, help in this distinction. Keep in mind that the pupil does not have to be fixed and dilated in a pupil-involved CN III palsy. It is possible to have a partial pupil-involved CN III palsy, which could manifest as anisocoria greater in bright illumination.

If you think the patient may have a CN III palsy, do not put any drops in the eye so that when the care is transferred to the emergency room, an accurate pupil assessment can be made. On the other hand, if you think the patient likely does



have pharmacologic dilation of the pupil, diagnostic testing is helpful to prevent unnecessary work-up. If the patient's pupils are pharmacologically dilated, the receptors are already bound by the substance that is dilating the pupils. For this reason, if any concentration of pilocarpine is instilled, it will not constrict the pupil. If it really is a CN III palsy, the receptors are not occupied, and 1% pilocarpine would constrict the pupil.

In terms of using diagnostic drops to assess for a tonic pupil, use a weak concentration—0.125% pilocarpine. To make it in the office, dilute the pilocarpine with the appropriate amount of saline. For example, you can place a drop of 1% pilocarpine into a contact lens case and then dilute it with eight drops from a single-use vial of non-preserved artificial tears and mix. Discard the remaining tears from the vial, which can now be easily used to suck back up the mixture and instill a single drop into the eye. Wait 30 minutes or up to one hour to check for a result. In this case, a positive result is constriction with this weak pilocarpine dosage, which would not constrict a normal eye.<sup>10</sup> Be sure to assess the need to use diagnostic drops before doing tonometry because you should not touch the cornea prior to using these drops.

• **Comparison of pupil reaction to light vs. pupil reaction to near.** Assess pupillary reaction to light in each eye. If it is absent, or less than expected, be sure to check the pupil reaction to a near stimulus. This is a step that is often overlooked, and it can have great diagnostic potential. When testing for the accommodative response, have the patient hold up a finger in front of their nose and tap the finger to trigger the proprioceptive cues. Have them alternate from fixating on their finger to a distant target. Watch for the change in pupil

### Differential Diagnosis for Pupillary Light-Near Dissociation

- **Blind eye** (amaurotic pupil)
- **Tonic pupil**—sector paralysis, stromal spread, stromal streaming
- **Argyll Robertson pupil** (neurosyphilis)—small pupils, 2.5mm or less
- **Aberrant regeneration of CN III**—eyelid up on infraduction and adduction
- **Dorsal midbrain syndrome** (tectal pupil)—upgaze or downgaze problems, eyelid retraction

size either from distance to near, or near to distance.

Compare this response with that to a light stimulus. Whenever the reaction to accommodation is greater than the reaction to light, there is presence of light-near dissociation. There are five main causes (see “*Differential Diagnosis for Pupillary Light-Near Dissociation*,” above), and careful testing of other aspects of the efferent visual system can help differentiate among these.<sup>11-16</sup>

#### • **Eyelid measurements.**

1. **Palpebral apertures.** Palpebral apertures need to be measured any time there is anisocoria and any time there is ocular misalignment. Assess palpebral apertures by measuring the distance between the lower lash line and the upper lash line while the patient is fixating on a distant target. It is essential that the frontalis muscle is held and immobilized during these measurements, so that the patient cannot raise their eyelids and possibly increase their palpebral aperture. Take note of any asymmetry—if asymmetry is noted, determine which eyelid is abnormal. Differentiate between ptosis in one eye vs. eyelid retraction in the fellow eye.

If you suspect myasthenia gravis, measure the palpebral aperture with fatigue and icepack testing. When assessing for fatigue, first measure pre-fatigue palpebral apertures. Then have the patient sustain upgaze for

two minutes, being sure the patient is looking up and not moving their chin up. Watch for any lid droop during the two minutes. Even if no lid droop is noted, measure palpebral apertures again immediately after the two minutes of upgaze. Remember, be sure to hold the frontalis muscle; the patient should look at the same distance target used for the pre-fatigue measurements. Any decrease in palpebral aperture after the two minutes of sustained upgaze indicates fatigue, and could be consistent with myasthenia gravis.<sup>17</sup>

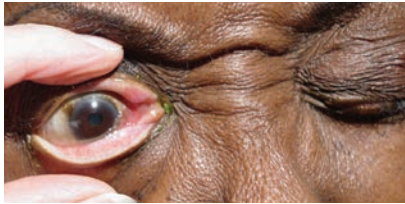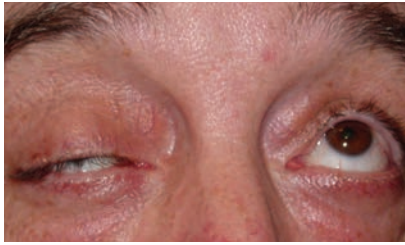To further assess for myasthenia gravis, look for an increase in palpebral apertures after holding an icepack on the eyelids for two minutes. But first, measure pre-icepack palpebral apertures to assess for interval change immediately following the two minutes of eyelid cooling. An increase in palpebral aperture after the application of ice suggests myasthenia gravis.<sup>18-19</sup>

Assessing the strength of the orbicularis oculi muscles also helps in assessing for myasthenia gravis. Have the patient forcefully close their eyes; you should not be able to pry the eyelids open. If you can, this suggests weakness that can be a feature of myasthenia gravis.

2. **Lid crease.** In order to measure the lid crease, have the patient look down, and measure the distance from the upper lash line to any eyelid creases. There may be one or several creases in each eye. The lid crease signifies the insertion of the levator muscle. Asymmetric lid creases may signify disinsertion of the levator, which could be a cause of ptosis.

### Main Causes of Ptosis

- CN III palsy (any amount)
- Horner syndrome (few mm)
- Myasthenia gravis (any amount)
- Levator disinsertion



**To assess for myasthenia gravis, check the lid function. The top photo shows lid droop with sustained upgaze/fatigue. Bottom photo shows orbicularis oculi weakness when prying lids apart.**

3. *Levator function.* In order to measure levator function, be sure the patient's head remains still during the testing. First, have the patient look down, and put the zero of the ruler in a position consistent with the upper lash line. Do not move the ruler. Now, ask the patient to look up as high as possible, and note where the upper lash line now intersects the ruler. This maximum excursion of the upper lid from extreme downgaze to extreme upgaze is the measurement of levator function. Since CN III innervates the levator muscle, a CN III palsy is an important cause of reduced levator function.

• *Exophthalmometry.* Problems with the efferent visual system can localize to the orbit, so it's important to measure exophthalmometry. Hertel exophthalmometry is superior to Luedde exophthalmometry because of the ability to measure the base, which signifies the distance between the lateral orbital rim in both eyes. Be sure to use the same base on all

follow-up measurements to accurately assess for interval change. If you don't have an exophthalmometer, you can assess for ease of retropulsion of the globe, as well as have the patient lean forward with their face parallel to the floor to see if an asymmetry becomes more apparent with the help of gravity, as seen with an orbital varix or mass.

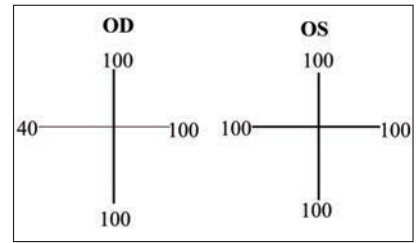
• *Ductions and versions.* Ductions and versions need to be performed, looking for even subtle limitations. Do versions first (eye movements with both eyes open). If versions are not 100% normal in each eye in every direction, then do ductions, assessing movements with each eye individually.

Comparing versions with ductions can help to differentiate a restrictive from a neurogenic cause of limited motility. In a restrictive process, such as thyroid eye disease or orbital mass, the degree of movement will be equal with ductions and versions. However, with a neurogenic etiology, such as a vasculopathic

cause, the degree of movement will be better on ductions than on versions. Similarly, forced duction can also help in this regard.

A restrictive process would demonstrate a positive forced duction test in which the eye cannot be moved into its full ductional range. A neurogenic process would demonstrate a negative forced duction test, in which the eye would be able to easily be moved into its full ductional range.<sup>20</sup> To perform this test, anesthetize the eye, use a cotton swab placed on the limbus opposite the ductional limitation, and gently roll the eye in the direction of the ductional limitation. Avoid pushing the eye back in the socket, which can produce a false positive result.

The patient's full range of motion



**This is an example of the documentation of a right abduction deficit, where the right eye moves out only 40% of normal capacity. The 100s represent 100% or full ductional capacity in all other positions of gaze. If the patient did not move in a particular direction from midline, a 0 is noted.**

		10 eso	
30 eso	12 eso	4 eso	
		14 eso	

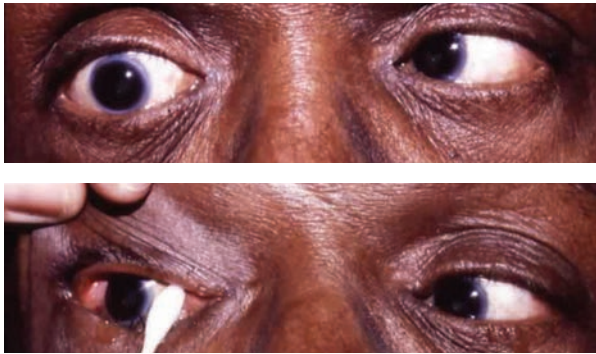**This is an example of the documentation of the cover test results on the same patient as above. There is an eso deviation, which increases in right gaze; this is consistent with a right abduction deficit. Note: If there were both a horizontal and vertical deviation, both would be noted in the same box.**

of each eye in all directions needs to be evaluated using a large circle so that every position of gaze is assessed—using an H pattern or a cross pattern can miss some positions of gaze. Make the circle large enough to assess full range of motion; with the arm completely outstretched and moved in a full circle.

Look for subtle limitations. In lateral gazes, that would be best detected by looking for complete burying of the sclera in abduction and adduction. Any subtle asymmetry can be

**Most common muscles involved in thyroid eye disease:**

1. Inferior rectus (limited upgaze)
2. Medial rectus (limited abduction)



**Forced duction testing moves the eye into full abduction; this is a negative test, indicating no restriction. This is not thyroid, but could be either myasthenia gravis, or a problem anywhere along the course of CN VI from pons to orbit.**

important—there are times when a CN VI palsy presents with 90% or even 95% normal abduction. We need to compare the ductions with the cover test results and not rely on ocular motility assessment alone to diagnose a cranial nerve palsy. A patient who truly has a right abduction deficit will also have cover test results that get more eso on right gaze.

- **Alternate cover test in nine positions of gaze.** To do cover testing in different positions of gaze, have the patient remove his/her eyeglasses to avoid induced prismatic effect when the patient is looking in different positions of gaze. This means you may need to give them a larger target they can see without their glasses, if possible. If the patient cannot fixate a large target without their glasses, they may have to keep them on. Do cover testing in primary gaze. Then, turn the patient's head in different directions and have them continue to fixate on the distance target in the cardinal positions of gaze.

Neutralize the cover test using both horizontal and vertical prism bars as appropriate. Neutralize the largest component (horizontal or vertical) first, keep that prism bar in place, and then neutralize the remaining component with the prism bar over the other eye. Be sure to hold the prism bars in a position so that the patient is looking directly through them. This means that in different positions of gaze, the bars

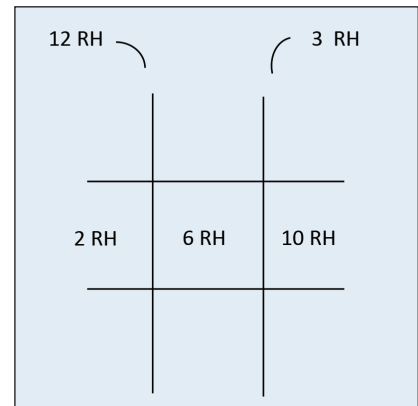
may not be sitting in the same plane as eyeglasses would sit.

Remember, if there is a significant duational limitation, you will need to put up the prism first in order to get the patient to find the target in the limited direction of gaze. Also, if there is a vertical misalignment, doing cover testing in both right and left head tilt helps to determine if the pattern is consistent with a CN IV palsy.

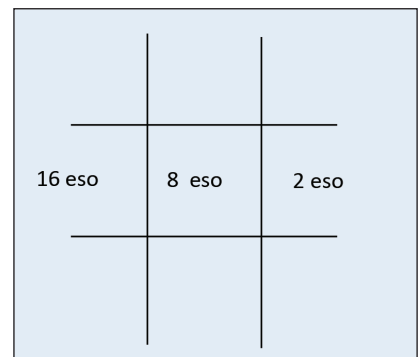
To differentiate between a CN IV palsy and a skew deviation, try assessing torsion with double Maddox rod testing. In a CN IV palsy, there may be mild excyclotorsion of the hyper eye, whereas in a skew deviation there may be incyclotorsion of the higher eye and excyclotorsion of the lower eye.<sup>21</sup> Thyroid eye disease or myasthenia gravis can also mimic a CN IV palsy.<sup>22</sup>

Record the cover test result on a grid so that you can assess the pattern for any potential CN palsy, or other recognizable diagnostic pattern.

- **Assessing for nystagmus.** Have the patient hold their fixation as steady as possible in each position of gaze. Note any rhythmic movements, which can be pendular or jerk. Jerk nystagmus is named for the fast phase. Nystagmus is otherwise classified based on the amplitude and frequency of its movements. Congenital nystagmus remains horizontal and symmetric. Any new, vertical or asymmetric nystagmus is concern-



**Pattern of a right CN IV palsy: Possible excyclotorsion <10 degrees if acute. No torsion likely if chronic. Torsion viewed by double Maddox rod testing or downward deviation of the macula. Hyperdeviation worse in contralateral gaze and ipsilateral head tilt.**



**Pattern of a right CN VI palsy: Eso deviation greatest in ipsilateral gaze. (Pattern is the same for any abduction deficit, not just for CN VI palsy.)**

ing for pathology. Neuroimaging is warranted in these cases. Nystagmus often localizes to the cerebellum, brainstem or vestibular system.

### Further Assessing Efferent Findings

When you determine that a patient has an abnormality of the efferent visual system based on the above noted tools for measuring eyelids, pupils and ocular motilities, it is time to develop differential diagnoses.

- **Work-up.** When a problem is found with the efferent visual system,

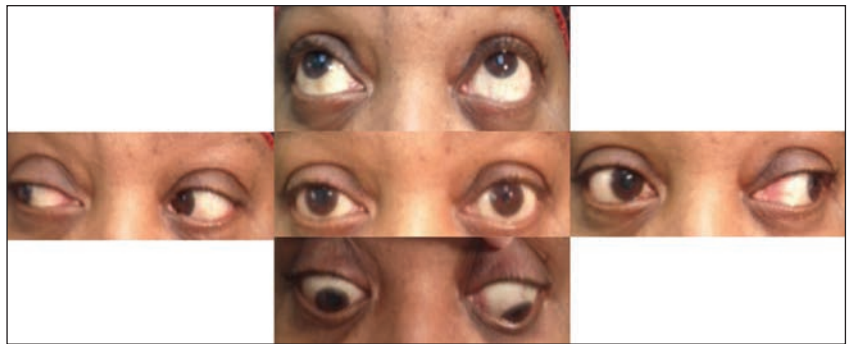


	6 LH	
2 exo	2 LH 6 exo	10 exo
	4 RH	

**Pattern of a right CN III palsy: Possible right ptosis. Possible anisocoria greater in bright illumination.**

appropriate work-up and/or referral is warranted. Depending on your practice locale, the urgency of the condition and many other factors, you may opt to order the work-up yourself and/or refer to a neuro-ophthalmologist, neurologist or perhaps to the emergency room. The work-up typically includes neuroimaging and lab testing.

An MRI is not possible if the patient has a pacemaker or defibrillator, cochlear implants, a bullet or



**Partial, pupil-involved right CN III palsy. Note that the eye is *not* down and out. Instead, note the reversing hyperdeviation and greater exo across from the vertically limited eye, along with the mild right ptosis. This is a *medical emergency*—work-up is needed to rule out an aneurysm.**

other metal in the body, or recent placement of stents. Other contraindications may include excessive weight (more than 350lbs.) and claustrophobia, which may preclude someone from having an MRI in a closed gantry. The contrast used in MRI is gadolinium, which causes relatively few adverse effects. However, facilities request a blood urea nitrogen (BUN) and creatinine level in patients over age 50 or with diabetes and hypertension to check for

kidney problems. If the BUN or creatinine is elevated, use of gadolinium may be contraindicated because of the possibility of nephrogenic systemic fibrosis.<sup>23</sup>

If an MRI is contraindicated, a CT scan may be warranted. CT scans are generally contraindicated in children and pregnant women due to radiation exposure. The contrast used in a CT scan is iodine-based, which may cause allergic reactions. This contrast is contraindicated in patients with iodine

or shellfish allergies, as well as in patients with kidney problems. Therefore, BUN and creatinine levels are often needed before contrast administration.<sup>24</sup>

A CT scan is better at imaging blood and bone than an MRI, and is the test of choice for detecting trauma. An MRI with diffusion-weighted imaging is best at detecting acute strokes, as in an older patient with an internuclear ophthalmoplegia (INO).<sup>25</sup> T2 and FLAIR MRI sequences are best at detecting white matter changes from multiple sclerosis, as in a younger patient with an INO from that disease process.<sup>26</sup>

Neuroimaging is critical in many cases of efferent visual system issues. A patient with a partial, painful or pupil-involved CN III palsy needs an emergent CTA to rule out aneurysm. In children or pregnant women, MRA would be preferable due to radiation. If an aneurysm is equivocal on CTA or MRA, then a digital subtraction angiography is the gold standard to rule out an aneurysm.<sup>27,28</sup> With a painful Horner syndrome, MRA, CTA or angiogram is needed emergently to rule out a carotid dissection. With an isolated non-painful Horner syndrome, imaging of the brain, cervical spine (c-spine), lung, soft-tissue neck and orbits may be needed due to the long course of the

### Main Differential Diagnosis for Vertical Diplopia/Vertical Ocular Misalignment

- Thyroid orbitopathy
- Myasthenia gravis
- CN III palsy
- CN IV palsy (higher eye extorted)
- Skew deviation (vertical misalignment, higher eye intorted, lower eye extorted)
- Orbital mass (proptosis)

### Main Differential Diagnosis for Horizontal Diplopia/Horizontal Ocular Misalignment

- Thyroid orbitopathy
- Myasthenia gravis
- CN III palsy
- CN VI palsy
- Other abduction deficit (e.g., Duane's retraction syndrome type I)
- Internuclear ophthalmoplegia (adduction deficit/abducting nystagmus in fellow eye)
- Decompensated phoria
- Orbital mass

sympathetic pathway. Contrast is preferred to rule out a mass.<sup>29</sup>

If you suspect thyroid eye disease, and are not very concerned about an alternate process, an orbital CT will assess for enlarged bellies of the muscles as well as any compression of the optic nerve. If you have a differential diagnosis that includes not only thyroid eye disease but also another condition, such as orbital mass, an MRI with contrast would be a better option. For myasthenia gravis, the imaging study that may be warranted is a CT of the chest to rule out thymoma, which occurs in up to 20% of patients with myasthenia gravis.<sup>30</sup>

Aside from structural abnormalities, other systemic causes of efferent visual system problems also need to be ruled out. This is mainly done with laboratory testing. For inflammatory conditions, order erythrocyte sedimentation rate (ESR) and C-reactive protein. A complete blood cell count (CBC), ESR, C-reactive protein and platelet count must be performed on patients over the age of 50 when considering the possibility of giant cell arteritis (GCA). Elevated ESR, C-reactive protein and platelet counts may be consistent with GCA, as may be a reduced hemoglobin level. Although classically thought of as a disease affecting the afferent visual system, GCA can cause diplopia and ocular misalignment.<sup>31</sup>

If you suspect thyroid eye disease, order not only thyroid function tests such as T3, T4 and TSH but also anti-thyroid antibodies (thyroperoxidase antibody and thyroglobulin antibody). Sometimes only the thyroid function tests are ordered, found to be normal, and the work-up ends there. It is possible to have thyroid eye disease with normal thyroid function tests. The anti-thyroid antibodies may be the only abnormal lab test in these cases.<sup>32</sup>

If you suspect myasthenia gravis,

### Common Lab Tests for Diplopia

- CBC
- C-reactive protein
- ESR
- Platelet count
- Lyme titer
- ANA with reflex titer (for autoimmune disease)
- ACE (for sarcoid)
- RPR (for syphilis)
- FTA-ABS (for syphilis)
- TSH
- T3/T4
- Thyroperoxidase antibody
- Thyroglobulin antibody
- Acetylcholine receptor antibodies—binding, blocking and modulating (for myasthenia gravis)

the initial work-up includes the acetylcholine receptor antibodies. There are three such antibodies: binding, blocking and modulating. These are more likely to be positive in generalized myasthenia gravis. There is only about a 50% chance that one of the tests will be positive in a patient with purely ocular myasthenia gravis.<sup>33</sup> If all three acetylcholine receptor antibodies are negative, and myasthenia is still suspected, other possible lab tests to perform are the antibodies to muscle-specific kinase (MuSK) and striated muscle antibodies (StrAbs).<sup>34,35</sup>

Another non-laboratory test for myasthenia gravis is a single fiber electromyogram (EMG). For ocular myasthenia gravis, this needs to be performed on the frontalis muscle or the orbicularis oculi muscle, not on the forearm, as is the more common version of the test.<sup>36</sup>

If the neuroimaging work-up and laboratory tests do not reveal a cause of the efferent visual system problem, ask yourself whether the work-up was complete and whether additional evaluation is warranted. Consult with neuro-ophthalmology and neurology as appropriate. But remember,

sometimes an efferent visual system problem can signify a medical emergency. If you suspect an aneurysmal CN III palsy or a carotid dissection, do not wait for the next available appointment with the specialist; call them immediately or send the patient to the ER with information about his clinical findings and concerning diagnosis.

### Put Your Knowledge and Experience to Work

When examining for neuro-ophthalmic disease processes, the most important tasks for the primary care optometrist are to fully assess the efferent visual system, determine if there is a concerning abnormality, assess the potential urgency of the situation, and determine when referral is indicated. Sometimes it may be difficult to determine whether the work-up is comprehensive enough or if the neuroimaging was done properly or read correctly. In those cases, referral to neuro-ophthalmology or neurology is warranted.

Do not underestimate your role in the care of a patient with a neuro-ophthalmic disease process—you have the important task of being the first individual to identify a problem that needs further evaluation, and determining how urgent or emergent that problem may be. You have the tools to make a proper diagnosis, and a difference! ■

*Dr. Malloy is the director of the Neuro-Ophthalmic Disease Service at Pennsylvania College of Optometry, Salus University, and clinical assistant professor of neurology at Hahnemann/Drexel College of Medicine in Philadelphia.*

1. Malloy KA. Neuro-ophthalmic disease basics: Focus on the afferent visual system evaluation. *Rev Optom.* 2008 Jun;145(6):67-82.
2. Fraunfelder FW, Richards AB. Diplopia, blepharoptosis, and ophthalmoplegia and 3-hydroxy-3-methyl-glutaryl-CoA reductase inhibitor use. *Ophthalmology.* 2008 Dec;115(12):2282-5.
3. Berger JR, Kovacs AG. Downbeat nystagmus with phenytoin. *J Clin Neuroophthalmol.* 1982 Sep;2(3):209-11.
4. Vestergaard P. Smoking and thyroid disorders—a meta-analysis. *Eur J Endocrinol.* 2002 Feb;146(2):153-61.

5. Fetter M, Haslwanter T, Bork M, Dichgans J. New insights into positional alcohol nystagmus using three-dimensional eye-movement analysis. *Ann Neurol*. 1999 Feb;45(2):216-23.
6. Freedman KA, Brown SM. Topical apraclonidine in the diagnosis of suspected Horner syndrome. *J Neuroophthalmol*. 2005 Jun;25(2):83-5.
7. Cooper-Knock J, Pepper I, Hodgson T, Sharrack B. Early diagnosis of Horner syndrome using topical apraclonidine. *J Neuroophthalmol*. 2011 Sep;31(3):214-6.
8. Moster ML, Galiani D, Garfinkle W. False negative hydroxyamphetamine test in Horner syndrome caused by acute internal carotid artery dissection. *J Neuroophthalmol*. 2003 Mar;23(1):22-3.
9. Patel RR, Adam R, Maldjian C, et al. Cervical carotid artery dissection: current review of diagnosis and treatment. *Cardiol Rev*. 2012 May-Jun;20(3):145-52.
10. Antonio-Santos AA, Santo RN, Eggenberger ER. Pharmacological testing of anisocoria. *Expert Opin Pharmacother*. 2005 Oct;6(12):2007-13.
11. Loewenfeld IE. The Argyll Robertson pupil 1869-1969. A critical survey of the literature. *Surv Ophthalmol* 1969;14:199Y299.
12. Thompson HS, Kardon RH. The Argyll Robertson pupil. *J Neuroophthalmol*. 2006 Jun;26(2):134-8.
13. Draper EM, Malloy KA. Progressive visual and hearing loss secondary to neurosyphilis. *Optom Vis Sci*. 2012 Nov;89(11):e65-71.
14. Gold DR, Shin RK, Bhatt NP, Eggenberger ER. Aberrant regeneration of the third nerve (oculomotor synkinesis). *Pract Neurol*. 2012 Dec;12(6):390-1.
15. Kelly-Sell M, Liu GT. "Tonic" but not "Adie" pupils. *J Neuroophthalmol*. 2011 Dec;31(4):393-5.
16. Kawasaki A, Kardon RH. Disorders of the pupil. *Ophthalmol Clin North Am*. 2001 Mar;14(1):149-68.
17. Morris OC, O'Day J. Fatigable ptosis and pseudoretraction caused by myasthenia gravis. *Clin Experiment Ophthalmol*. 2004 Jun;32(3):303-4.
18. Fakiri MO, Tavy DL, Hama-Amin AD, Wirtz PW. Accuracy of the ice test in the diagnosis of myasthenia gravis in patients with ptosis. *Muscle Nerve*. 2013 Dec;48(6):902-4.
19. Chatzistellanou KI, Kouris T, Iliakis E, et al. The ice pack test in the differential diagnosis of myasthenic diplopia. *Ophthalmology*. 2009 Nov;116(11):2236-43.
20. Metz HS. Forced duction, active force generation, and saccadic velocity tests. *Int Ophthalmol Clin*. 1976 Fall;16(3):47-73.
21. Hernowo A, Eggenberger E. Skew deviation: clinical updates for ophthalmologists. *Curr Opin Ophthalmol*. 2014 Nov;25(6):485-7.
22. Chen VM, Dagi LR. Ocular misalignment in Graves disease may mimic that of superior oblique palsy. *J Neuroophthalmol*. 2008 Dec;28(4):302-4.
23. Canga A, Kisilikova M, Martínez-Gálvez M, et al. Renal function, nephrogenic systemic fibrosis and other adverse reactions associated with gadolinium-based contrast media. *Nefrologia*. 2014;34(4):428-38.
24. Diogo LP, Bahlis LF, Carvalhal GF. Computerized Tomography Contrast Induced Nephropathy (CIN) among adult inpatients. *J Bras Nefrol*. 2014 Dec;36(4):446-50.
25. Chuang MT, Lin CC, Sung PS, et al. Diffusion-weighted imaging as an aid in the diagnosis of the etiology of medial longitudinal fasciculus syndrome. *Surg Radiol Anat*. 2014 Sep;36(7):675-80.
26. McNulty JP, Loneragan R, Brennan PC, et al. Diagnostic efficacy of conventional MRI pulse sequences in the detection of lesions causing internuclear ophthalmoplegia in multiple sclerosis patients. *Clin Neuro-radiol*. 2014 Mar 6. [Epub ahead of print.]
27. Lee AG, Hayman LA, Brazis PW. The evaluation of isolated third nerve palsy revisited: an update on the evolving role of magnetic resonance, computed tomography, and catheter angiography. *Surv Ophthalmol* 2002;47:137-157.
28. Vaphiades MS, Cure J, Kline LB. Management of intracranial aneurysm causing a third cranial nerve palsy: MRA, CTA or DSA? *Sem Ophthalmol* 2008;23:143-150.
29. Davagnanam I, Fraser CL, Miszkiel K, et al. Adult Horner's syndrome: a combined clinical, pharmacological, and imaging algorithm *Eye (Lond)*. Mar 2013; 27(3): 291-298.
30. Mao ZF, Mo XA, Qin C, et al. Incidence of thymoma in myasthenia gravis: a systematic review. *J Clin Neurol*. 2012 September; 8(3): 161-169.
31. Davies GE, Shakir RA. Giant cell arteritis presenting as oculomotor nerve palsy with pupillary dilatation. *Postgrad Med J*. Apr 1994; 70(B22): 298-299.
32. Khoo TK, Bahn RS. Pathogenesis of Graves' ophthalmopathy: the role of autoantibodies. *Thyroid*. 2007 October; 17(10): 1013-18.
33. Benatar M. A systematic review of diagnostic studies in myasthenia gravis. *Neuromuscular Disorders*. 2006;16(7):459-467.
34. Selcen D, Fukuda T, Shen XM, Engel AG. Are MuSK antibodies the primary cause of myasthenic symptoms? *Neurology*. 2004 Jun 8;62(11):1945-50.
35. Choi Decroos E, Hobson-Webb LD, Juel VC, et al. Do acetylcholine receptor and striated muscle antibodies predict the presence of thymoma in patients with myasthenia gravis? *Muscle Nerve*. 2014 Jan;49(1):30-4.
36. Valls-Canals J, Povedano M, Montero J, Pradas J. Stimulated single-fiber EMG of the frontalis and orbicularis oculi muscles in ocular myasthenia gravis. *Muscle Nerve*. 2003 Oct;28(4):501-3.

## OSC QUIZ

**Y**ou can obtain transcript-quality continuing education credit through the Optometric Study Center. Complete the test form (page 83), and return it with the \$35 fee to: Optometric CE, P.O. Box 488, Canal Street Station, New York, NY 10013. To be eligible, please return the card within one year of publication.

You can also access the test form and submit your answers and payment via credit card at *Review of Optometry* online, [www.reviewofoptometry.com](http://www.reviewofoptometry.com).

You must achieve a score of 70 or higher to receive credit. Allow eight to 10 weeks for processing. For each Optometric Study Center course you pass, you earn 2 hours of transcript-quality credit from Pennsylvania College of Optometry and double credit toward the AOA Optometric Recognition Award—Category 1.

Please check with your state licensing board to see if this approval counts toward your CE requirement for relicensure.

1. Statin use to treat hypercholesterolemia has been associated with:

- Diplopia.
- Anisocoria.
- Proptosis.
- Eyelid retraction.

2. Tobacco use increases the likelihood of ocular involvement from:

- Thyroid dysfunction.
- Myasthenia gravis.
- Sarcoid.
- Syphilis.

3. Which is used for a convenient, in-office diagnostic test to confirm the presence of Horner syndrome?

- Pilocarpine.
- Hydroxyamphetamine.
- Apraclonidine.
- Cocaine.

4. Anisocoria greatest in bright illumination could be associated with all of the following EXCEPT:

- CN III palsy.
- Tonic pupil.
- Pharmacologic dilation.
- Horner syndrome.

5. 1% pilocarpine DOES NOT constrict:

- Tonic pupil.
- Pharmacologically-dilated pupil.
- Aneurysmal CN III palsy.
- Normal pupil.

6. Which drop can be used as an in-office test for tonic pupil?

- 1% pilocarpine.
- 0.125% pilocarpine.
- 0.5% apraclonidine.
- 1.0% apraclonidine.

7. All of the following are causes of light-near dissociation EXCEPT:

- Tonic pupil.
- Dorsal midbrain syndrome.
- Neurosyphilis.
- Horner syndrome.

8. Which is NOT a cause of ptosis?

- CN III palsy.
- Myasthenia gravis.
- Horner syndrome.
- Dorsal midbrain syndrome.

9. Which is NOT a feature of myasthenia gravis?

- Vertical misalignment of eyes.
- Orbicularis oculi weakness.
- Ptosis worsens with ice testing.
- Ptosis worsens with fatigue.

10. Which would cause a positive forced duction test?

- Myasthenia gravis.
- CN VI palsy from diabetes.
- Thyroid orbitopathy.
- CN VI palsy from papilledema.

11. What is the most common muscle involved in thyroid eye disease?

- Superior rectus.
- Inferior rectus.
- Medial rectus.
- Lateral rectus.

12. All of the following may be causes of abduction deficit EXCEPT:

- Myasthenia gravis.
- Thyroid eye disease.
- Cranial nerve VI palsy.
- Internuclear ophthalmoplegia.

13. Which is consistent with the pattern of a left abduction deficit?

- Greater eso on right gaze.
- Greater eso on left gaze.
- Greater exo on right gaze.
- Greater exo on left gaze.

14. Which is NOT a feature of the pattern of a left CN III palsy?

- Right hyper in upgaze.



## OSC QUIZ

- b. Left hyper in downgaze.
- c. Increased exo in right gaze.
- d. Increased eso in right gaze.

15. Which is NOT a feature of the pattern of a left CN IV palsy?

- a. Left hyper in primary gaze.
- b. Left hyper worse in left gaze.
- c. Left hyper worse on left head tilt.
- d. Mild exocycloversion of left eye.

16. Prior to ordering an MRI with contrast in a patient with diabetes, which blood test is needed?

- a. CBC.
- b. ESR.
- c. Creatinine.
- d. Hemoglobin A1c.

17. Which is least concerning for aneurysm?

- a. Anisocoria greatest in dim illumination.
- b. Dilated pupil.
- c. Complaint of pain.
- d. Reversing hyperdeviation in up and down gazes.

18. Until proven otherwise, painful Horner syndrome is considered:

- a. CN III palsy.
- b. Carotid dissection.
- c. Aneurysm.
- d. Pancoast tumor.

19. Which finding is NOT consistent with Argyll Robertson pupil?

- a. Light-near dissociation.
- b. Pupil size of 1.5mm in bright illumination.
- c. Pupil size of 3.5mm in dim illumination.
- d. Positive FTA-ABS.

20. If you suspect ocular myasthenia gravis but laboratory testing, including acetylcholine receptor antibodies, is negative, which additional (non-laboratory) test may be helpful?

- a. Single fiber EMG.
- b. CT of chest.
- c. MRI of orbits.
- d. CT of brain.



TAKE THE TEST ONLINE TODAY!  
[www.reviewofoptometry.com/  
continuing\\_education/](http://www.reviewofoptometry.com/continuing_education/)

## Examination Answer Sheet

Valid for credit through February 1, 2018

This exam can be taken online at [www.revoptom.com/continuing\\_education](http://www.revoptom.com/continuing_education). Upon passing the exam, you can view your results immediately and download a real-time CE certificate. You can also view your test history at any time from the website.

### Neuro-Ophthalmic Disease Basics: Evaluating the Efferent Visual System

**Directions:** Select one answer for each question in the exam and completely darken the appropriate circle. A minimum score of 70% is required to earn credit.

**Mail to:** Jobson - Optometric CE, PO Box 488, Canal Street Station, New York, NY 10013

**Payment:** Remit \$35 with this exam. Make check payable to Jobson Medical Information LLC.

COPE approval for 2 hours of CE credit is pending for this course.

This course is joint-sponsored by the Pennsylvania College of Optometry

There is an eight-to-ten week processing time for this exam.

1 = Excellent 2 = Very Good 3 = Good 4 = Fair 5 = Poor

Rate the effectiveness of how well the activity:

- 1. (A) (B) (C) (D)
- 2. (A) (B) (C) (D)
- 3. (A) (B) (C) (D)
- 4. (A) (B) (C) (D)
- 5. (A) (B) (C) (D)
- 6. (A) (B) (C) (D)
- 7. (A) (B) (C) (D)
- 8. (A) (B) (C) (D)
- 9. (A) (B) (C) (D)
- 10. (A) (B) (C) (D)
- 11. (A) (B) (C) (D)
- 12. (A) (B) (C) (D)
- 13. (A) (B) (C) (D)
- 14. (A) (B) (C) (D)
- 15. (A) (B) (C) (D)
- 16. (A) (B) (C) (D)
- 17. (A) (B) (C) (D)
- 18. (A) (B) (C) (D)
- 19. (A) (B) (C) (D)
- 20. (A) (B) (C) (D)

21. Met the goal statement: (1) (2) (3) (4) (5)

22. Related to your practice needs: (1) (2) (3) (4) (5)

23. Will help you improve patient care: (1) (2) (3) (4) (5)

24. Avoided commercial bias/influence: (1) (2) (3) (4) (5)

25. How would you rate the overall quality of the material presented? (1) (2) (3) (4) (5)

26. Your knowledge of the subject was increased:

Greatly  Somewhat  Little

27. The difficulty of the course was:

Complex  Appropriate  Basic

How long did it take to complete this course?

\_\_\_\_\_

Comments on this course:

\_\_\_\_\_

Suggested topics for future CE articles:

\_\_\_\_\_

Please retain a copy for your records. Please print clearly.

First Name \_\_\_\_\_

Last Name \_\_\_\_\_

E-Mail \_\_\_\_\_

The following is your:  Home Address  Business Address

Business Name \_\_\_\_\_

Address \_\_\_\_\_

City \_\_\_\_\_ State \_\_\_\_\_

ZIP \_\_\_\_\_

Telephone # \_\_\_\_\_ - \_\_\_\_\_ - \_\_\_\_\_

Fax # \_\_\_\_\_ - \_\_\_\_\_ - \_\_\_\_\_

By submitting this answer sheet, I certify that I have read the lesson in its entirety and completed the self-assessment exam personally based on the material presented. I have not obtained the answers to this exam by any fraudulent or improper means.

Signature \_\_\_\_\_ Date \_\_\_\_\_

Lesson 110970

RO-OSC-0215

# 2014 EAST COAST OPTOMETRIC GLAUCOMA SYMPOSIUM

Highlights from the live event.

Each year, renowned glaucoma experts come together at the East Coast Optometric Glaucoma Symposium (ECOGS) to share their knowledge, experience and ideas with colleagues looking to find an edge in their glaucoma practice. The faculty for this meeting was chosen to ensure a comprehensive program that addressed new approaches to both the diagnosis and management of glaucoma. What you see before you is a follow-up piece to the live event, featuring highlights from selected presentations. We hope this information positively impacts your glaucoma patient outcomes.

– Murray Fingeret, OD, and Robert N. Weinreb, MD, Meeting Co-Chairs

**Release Date:** February 2015

**Expiration Date:** February 29, 2016

**Goal Statement:** This comprehensive glaucoma symposium will cover the steps taken in establishing the diagnosis of glaucoma, as well as information on new medications and changing paradigms with regard to glaucoma therapy.

**Faculty/Editorial Board:** Michael Chaglasian, OD; Murray Fingeret, OD; Ben Gaddie, OD; Nils Loewen, MD, PhD; Jonathan S. Myers, MD

**Credit Statement:** This course is COPE approved for 2 hours of CE credit. COPE ID is 43771-GL. Please check your state licensing board to see if this approval counts toward your CE requirement for relicensure.

**Joint-Sponsorship Statement:** This continuing education course is joint sponsored by the University of Alabama School of Optometry.

**Disclosure Statement:** Dr. Chaglasian is on the advisory boards for Allergan, Alcon and Carl Zeiss Meditec. Dr. Fingeret has no financial relationships to disclose. Dr. Gaddie is a consultant to Glaukos, Allergan, Alcon, Bausch + Lomb, Zeiss, Marco and Sucampo. He is on the advisory boards at Allergan, Alcon, Bausch + Lomb, Optovue, Zeiss and Nicox. Dr. Loewen is a Trabectome wet lab trainer. Dr. Myers is a consultant for Alcon, Allergan, Inotek and Sucampo; a speaker for Alcon, Allergan, Haag Streit, New World Medical and Sucampo; and has received research support from Aerie, Alcon, Allergan, Diopsys, Glaukos, Inotek and Merck.

# VISUAL FIELDS: WHAT IS PROGRESSION?

Jonathan S. Myers, MD

It's a reality we all know: some of our glaucoma patients will go blind in both eyes, but fortunately, most of our glaucoma patients are not going to go blind in either eye. So, the challenge for us as clinicians is to figure out which patients will and which will not. Visual fields (VFs) remain one of the most important tools for separating patients into one group or the other.

## DETERMINING PROGRESSION

You want to be sure a patient has real progression before moving them on to the next treatment, and VF gurus suggest that you may take seven fields to be sure of change because inherent fluctuation masks confirmation of progression. If you do yearly fields, that's seven years of waiting to tell a patient that now you think they were getting worse seven years ago. That's why I do VFs on most patients at least twice a year if they are at risk.

It's not about how fast you can do this; it's simply about getting to the same endpoint in less time and effort. VFs can be monitored over time by comparing sequential printouts, such as those generated by the Humphrey Visual Field Analyzer (Zeiss); by using Guided Progression Analysis (GPA) software (Zeiss); point-wise linear regression (Progressor); or Octopus EyeSuite perimetry (Haag-Streit). Looking at the series of fields and the thresholds takes some training and practice and is often hard, but we fortunately have these software tools that make it much easier.

The GPA software uses a series of triangles to compare a new VF to an average of two baseline VFs. Essentially, when you take the GPA, it averages the first two baseline fields and then compares each subsequent field at each point. Thus, at any given point, it defines a sort of threshold and allows you to identify which points have crossed a certain threshold of getting worse. We call that an event-based change.

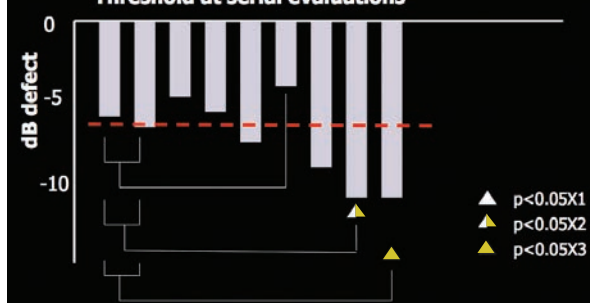
Another approach would be to do a *trend-based analysis* and look at each series of points as we add more fields and determine the slope of change at these points (how quickly they are getting worse). This linear regression analysis gives both the slope, or rate of deterioration, as well as a *p* value to determine whether there is confidence that this change is real.

The *event-based analysis* tends to pick up fast progression quicker than the trend-based analysis because you don't need to achieve statistical significance to cross a threshold. Conversely, the trend-based analysis tends to pick up slow progression a little later and has greater confidence/certainty.<sup>3</sup> The GPA possesses some elements of each.

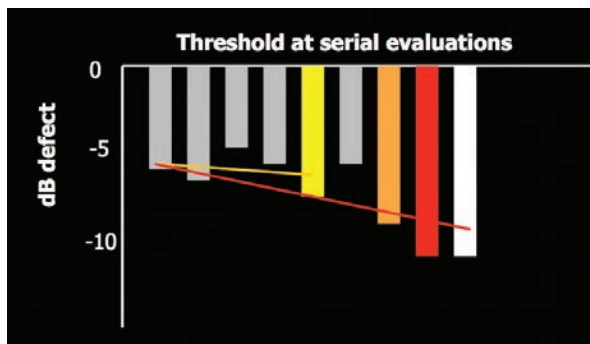The Octopus perimeter (Haag-Streit) produces colored grayscale plots and shows you the false-positives and false-negatives, while the EyeSuite (Haag-Streit) very quickly presents a lot of information showing you the linear regression for both the diffuse and the focal components of VF change. Red triangles highlight that the linear regression has achieved statistical significance at a high level. Additionally, clusters of points, for example a nasal step, are averaged, and the rate of change for that area's thresholds is displayed, with confidence measures as well.

## CONCLUSION

The summary algorithms are helpful, but they don't replace clinicians looking carefully at the data. We have to still look over all of this and make sure we're not missing anything. Now, a little reality check: patients and insurers are not going to agree to



EVENT-BASED ANALYSIS.



visual fields every two weeks in your office, so there's a limit as to how much data we can get. In the end, the variability of the field is going to limit how much we can conclude from a visual field series for a lot of patients.

Perimetry remains a very inexact science for so many different reasons, starting with the fact that our vision varies—even more so in glaucoma. There are many ways to look at progression analysis, and I think as you use the different automated algorithms more it will make your life easier. Just remember: if you see a small change, the key is to retest three months later because it's hard to be certain. Repeating tests and confirming change is the most valuable thing for you as a clinician and for our patients as well.

*Dr. Myers is an associate attending surgeon on the Glaucoma Service at Wills Eye Institute in Philadelphia, Pa., where he also serves as director of the Glaucoma Fellowship.*

1. Keltner JL, Johnson CA, Quigg JM, et al. Confirmation of visual field abnormalities in the Ocular Hypertension Treatment Study. Ocular Hypertension Treatment Study Group. Arch Ophthalmol. 2000;118(9):1187-94.
2. Keltner JL, Johnson CA, Levine RA, et al. Normal visual field test results following glaucomatous visual field end points in the Ocular Hypertension Treatment Study. Arch Ophthalmol. 2005;123(9):1201-6.
3. Casas-Llera P, Rebolloleda G. Visual field index rate and event-based glaucoma progression analysis: comparison in a glaucoma population. Br J Ophthalmol. 2009;93(12):1576-9.

## HOW DO I EVALUATE THE OCT PRINTOUT?

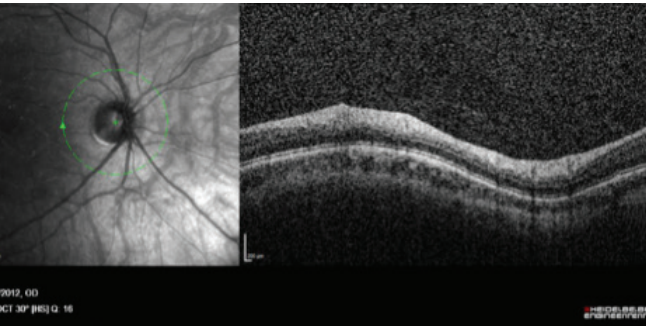
Murray Fingeret, MD

Optical coherence tomography (OCT) is a rapidly emerging biomedical imaging technology and an important adjunct in the evaluation of the optic nerve/retinal nerve fiber layer (RNFL) for glaucoma. It obtains high-resolution, cross-sectional images of biological microstructures *in situ* and in real time. Furthermore, it's noninvasive and doesn't require excision or processing of specimens. We use OCT to analyze three parts



## VALUATING OCT SCANS

Similar to a visual field printout, it's important to look at the validity of an OCT scan first. What's the quality score? Keep in mind this is just one part of the quality evaluation and that you can have a great quality score and a bad image due to factors such as a blink or eye movements. How well was the scan illuminated? Was the focus okay and the image centered? Are there any signs of eye movement or fixation movement? Were the B-scans centered and not cut off? And in terms of segmentation, were the layers indicated properly?



AS SHOWN HERE, DRY EYE CAN RESULT IN POOR IMAGE QUALITY.

It's necessary to look at the RNFL thickness maps. What are the colors? Are we looking at red and yellow, which would indicate greater thickness, or are the areas getting darker such as deep blue? Also, where are the areas and do they correlate with other clinical tests? When you look at nasal and temporal regions, those areas are always thin and blue compared to other parts of the printout, even in healthy individuals. Looking at the RNFL deviation map, are any areas flagged? If so, are the pixels yellow or red? Look at the TSNIT (temporal, superior, nasal, inferior, temporal) maps indicating the order that the circle is evaluated for thickness.

OCTs are meant to segment out or identify each layer, and how well each device does this varies from person to person and from device to device. While the devices segment out most of the time, they don't segment all the time and it is important to recognize this. The Cirrus HD-OCT (Carl Zeiss Meditec) and Spectralis OCT (Heidelberg Engineering) evaluate the optic nerve head with a new metric: the Bruch's membrane opening-minimum rim width (BMO-MRW), a parameter that quantifies the rim from its anatomical border, BMO, and accounts for its variable orientation. Several of the device companies are doing this now.

You want to also visually inspect the scan looking for artifacts, hypodense areas and areas of thinning. Don't rely entirely on the so-called computer-driven statistics (red, yellow, green) to recognize if something is amiss. Look at the results and compare the OCT and the fields, asking yourself if they agree. Evaluate the B scans visually looking for regions of thinning, holes, hypo-dense areas, location of vessels.

## VALUATING FOR ARTIFACTS

There are times when artifacts can lead to us misinterpreting the presence of loss. A paper by Sanjay Asrani found that upwards of almost 30% of macular scans, a little less for RNFL scans, had some type of imaging artifact when evaluated.<sup>1</sup> This has also been evaluated in another paper.<sup>2</sup>

Signal strength is important, whether it's due to an ocular

high angle or there is no segmentation failure that gives erroneous disc measurement. Epiretinal membranes can wreak havoc in terms of the interpretation, but if you don't look at the scans, it's easy to think everything is fine. Another example is a significant dry eye, which can cause an image to seem out of focus. That's why I keep a bottle of tears next to my OCTs. For many patients, we put a drop in right before or during the exam to improve the quality of the image.

It's important to assess the accuracy of the OCT and to keep in mind that what can lead to seeing some retinal loss that's not real.

*Dr. Fingeret is chief of the Optometry Section, Brooklyn/St. Albans Campus, Department of Veterans Administration New York Harbor Health Care System. He is also a clinical professor at the State University of New York, College of Optometry.*

1. Asrani S, Essaid L, Alder BD, Santiago-Turla C. Artifacts in spectral-domain optical coherence tomography measurements in glaucoma. *JAMA Ophthalmol.* 2014;132(4):396-402.
2. Iverson SM, Feuer WJ, Shi W, et al. Frequency of abnormal retinal nerve fibre layer and ganglion cell layer SDOCT scans in healthy eyes and glaucoma suspects in a prospective longitudinal study. *Br J Ophthalmol.* 2014;Mar 13. [Epub ahead of print].

## GLAUCOMA THERAPY

### FIXED-COMBINATION AGENTS

Ben Gaddie, OD

**W**e're all familiar with the use of prostaglandins in the care of glaucoma patients, but what happens when things get worse? Many times, it involves adding an adjunctive medication, but in my experience, if a patient is at a point where he needs one additional medication, chances are pretty good that he is going to soon need two additional medications.

#### THE CASE FOR COMBINATIONS

So, why combinations? There are many reasons: You get the power of two different medications while only dealing with one bottle; it's an efficient way to lower intraocular pressure (IOP); there's enhanced adherence to the medication; improved patient convenience; and decreased cumulative exposure to benzalkonium chloride (BAK). There's also a potential for reduced cost, better diurnal control if you have two different drugs that work better at different times of the day in a complementary way, reduced side effects, reduced washout effects and no waiting between instillation of drops.

There are, however, disadvantages to using combination medications for the treatment of glaucoma, and they include: not being able to change the dosing frequency of just one component of the combination; not being able to change the concentration of the separate drugs; and the need to carefully consider the side effect profiles and contraindications of each drug.

#### THE CURRENT LINEUP

From what I can tell, for a drug to be approved as a combination, it has to perform more than 1 mmHg better than the individual components of the drug used concomitantly. We currently have three FDA-approved fixed-dose combination medications in our glaucoma treatment armamentarium.

1) **Dorzolamide HCl/timolol maleate ophthalmic solution 2%/0.5% (Cosopt, Merck)** has been around since 1998, but is now available in a preservative-free formulation (Cosopt PF). This is a nice option if you're worried about BAK exposure because it's significantly more tolerable than the generic Cosopt. This may be particularly useful for someone who has a

lution 0.2%/0.5% (Morgan, Allergan) was approved in 2007. It and the newer brinzolamide/brimonidine tartrate ophthalmic suspension 1%/0.2% (Simbrinza, Alcon) have shown excellent efficacy in lowering IOP in patients with ocular hypertension and glaucoma. They both also have a significant rate of a follicular conjunctivitis-type response. It appears that the rate of this hypersensitivity reaction is reduced with both drugs relative to just using the 0.2% formulation of the brimonidine as stand-alone treatment, but it still happens, and in my personal experience, it is not as immediate as what I would see with the 0.2% formulation.

For primary therapy, **brinzolamide/brimonidine** is indicated for t.i.d. dosing, though many of us use it as adjunctive therapy and may therefore dose it slightly differently (off label), but either way, the drug is a suspension and needs to be shaken, similar to dorzolamide/timolol. Many of us find improved tolerability and less burning and stinging with the brinzolamide compared to the dorzolamide.

So, why don't we have a prostaglandin/beta-blocker combination? Pretty much every available prostaglandin has been combined with a beta-blocker, but when the efficacy is examined, as in the Chinese study by Zhao and colleagues, which compared the fixed versus unfixed combinations of latanoprost and timolol in patients with open-angle glaucoma or ocular hypertension, the unfixed combination has better IOP lowering than the fixed combination.<sup>1</sup>

## INTERESTING THOUGHTS ABOUT COMBINATION MEDICINES

A study by Holló et al. showed that the higher the baseline pressure, the better the IOP lowering,<sup>2</sup> and this is true with most of combination drugs. So when the baseline pressure was 21 mmHg, there was a 40% reduction in pressure. And if the baseline pressure was lower but still ocular hypertensive (15 mmHg) there was only a 30% reduction.

Another study compared the diurnal effects of dorzolamide/timolol and brimonidine/timolol and found that even though most of the time they work about the same at night, there's about a millimeter or so difference favoring the drug containing the carbonic anhydrase inhibitor (dorzolamide/timolol).<sup>3</sup> We all know that eye pressure tends to be higher at night, but if that's a concern and you feel like your patient's pressure is really slipping at night, then you need to consider what agents he's using nocturnally.

## ON THE HORIZON

Latanoprostene bunod 0.24% (Vesneo) is currently being marketed and developed by Nicox and Bausch + Lomb in the United States for the reduction of IOP in patients with glaucoma or ocular hypertension. It is a nitric oxide-donating prostaglandin F<sub>2</sub>-alpha analogue that has met the primary endpoint in Phase III studies and is getting closer to that 2 mmHg of additional lowering versus latanoprost by itself.

*Dr. Gaddie is the owner and director of Gaddie Eye Centers and president of the Ocular Hypertension Society.*

1. Zhao JL, Ge J, Li XX, et al; for the Xalacom Study Group in China. Comparative efficacy and safety of the fixed versus unfixed combination of latanoprost and timolol in Chinese patients with open-angle glaucoma or ocular hypertension. *BMC Ophthalmol.* 2011;11:23.

2. Holló G, Vuorinen J, Tuominen J, et al. Fixed-dose combination of tafluprost and timolol in the treatment of open-angle glaucoma and ocular hypertension: comparison with other fixed-combination products. *Adv Ther.* 2014;31:932-944.

3. Konstas AGP, Quaranta L, Yan DB, et al. Twenty-four hour efficacy with the dorzolamide/timolol combination compared with the brimonidine/timolol-fixed combination in primary open-angle glaucoma. *Eye.* 2012;26:80-87.

## OR CONSIDER SURGERY?

Jonathan S. Myers, MD

It is well known that elevated intraocular pressure (IOP) is a risk factor for glaucoma and that the only known treatment currently available is to reduce IOP. However, it's not the whole story on who is going to develop the disease. Consider the fact that most people with an IOP >21 mmHg will not develop glaucoma and that one-fifth of all patients with glaucoma have an IOP <21 mmHg. Fortunately, we have tools that help us quantify risk. I keep a risk calculator such as the Scoring Tool for Assessing Risk (STAR) calculator open on the computers in my exam rooms all the time. When I see a patient with ocular hypertension, I enter in his Ocular Hypertension Treatment Study (OHTS) data and tell him his five-year risk of developing glaucoma. Discussing the results of these calculators can serve as a good launching point for discussing the available treatment options.

## TREATMENT OPTIONS

The clinical progression of treatment typically starts with drops, then moves on to laser treatment, before ending with surgery.

**Medications** work well, but they have some unpleasant aspects, such as side effects, cost and inconvenience, and unfortunately, no medicine has significant efficacy without some potential downside(s). Therefore, treatment should be initiated when the risk of glaucoma outweighs the intervention risk.

**Selective laser trabeculoplasty (SLT)** typically lowers IOP four to seven points in early disease and is relatively safe. Some catastrophic outcomes can occur, but they are truly few and far between. That makes it an easy choice for patients who have trouble with compliance or who want to avoid the use of eye drops.

**Trabeculectomy** reduces IOP to the mid to low teens and carries about a 1% risk of severe vision loss. So, if you take 100 happy patients who have ocular hypertension, five of them will get worse. And if I cut their risk in half, then maybe two get worse and three don't. But if my trabeculectomy blinds one of these 100 patients, I've really cut into my therapeutic effect. It doesn't make sense to do 100 trabeculectomies to save two of five people from getting a little worse in their field. However, if I have a high-risk population, where 30% of patients are going to get significantly worse and I can do a trabeculectomy and cut that number in half, now I've saved 15 of 100 people from getting worse. So again, the treatment depends on the risk.

## SOME SCENARIOS

**Low-risk glaucoma suspect** (e.g., a 65-year-old man with cupped disc symmetry but no other risk factors). We typically don't treat these patients; instead, we monitor their IOP closely every six to 12 months. We also usually perform a dilated exam, visual fields and OCT every year.

**High-risk glaucoma suspect.** Most of us would agree that if your risk on the OHTS calculator is 20% or higher, that in a five-year period, you're going to get worse. This might well justify treatment with eye drops. But if you have a high risk factor (e.g., pseudoexfoliation), or two or more low-level risk factors (e.g., suspicious nerve and high IOP), then we need to monitor frequently and perhaps treat a little earlier.

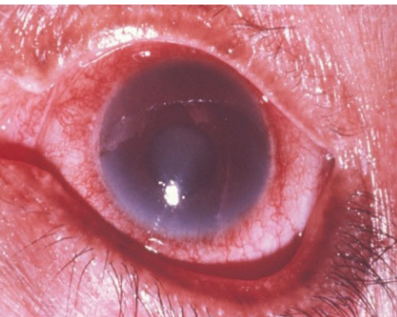## ADVANCING THERAPY

When it comes to advancing therapy, our choices are driven by the balance of several factors: disease severity; rate of progression; the patient's systemic health; the risk of the available treatments for that particular patient; and the patient's concerns.

## ANGLE-CLOSURE GLAUCOMA: MORE RARELY DIAGNOSED THAN RARE

Jonathan S. Myers, MD

Open-angle glaucoma (OAG) is the most common glaucoma in western populations, but secondary forms are also quite common. Angle-closure glaucoma (ACG), on the other hand, while less commonly diagnosed, is not rare. This may be due to the fact that gonioscopy is a forgotten art. In fact, many (54%) patients don't undergo gonioscopy within five years of being diagnosed with glaucoma.<sup>1</sup> Part of the reason we don't do as much gonioscopy as we should is because patients don't like it and sometimes it's not so easy to see what's going on. So, what is ACG?



CUTE ANGLE-CLOSURE GLAUCOMA.

### PROFILE OF AN OFTEN IGNORED GLAUCOMA

The definition of a closed angle is the iris covering the trabecular meshwork, and there are many reasons why that happens, but in my mind, I like to group these conditions into two mechanisms: anterior

pulling and posterior pushing. Something pulls or pushes the iris forward over the meshwork.

**Anterior pulling.** The membranes for anterior pulling (anterior synechia, Axenfeld/Rieger, iridocorneal endothelial syndrome, neovascular glaucoma, epithelial ingrowth) are often surprisingly strong.

**Posterior pushing.** The posterior pushing mechanisms of ACG range from acute to chronic, and they are plentiful. They include: relative pupillary block; secluded pupil with posterior synechia; phacomorphic; spherophakia; tumors; ciliary body swelling/cysts; tight scleral buckle; choroidal detachments; aqueous misdirection; non-rhegmatogenous retinal detachment; silicone oil/gas; nanophthalmos; and contracting retrolental tissue in retinopathy of prematurity.

### TREATMENT

In ACG related to relative pupillary block, we control the pressure medically. Once the pressure is stabilized and the cornea is clear, laser peripheral iridotomy (PI) makes sense. The main complications of iridotomy, besides a little bit of bleeding or a spike in pressure, are ghost images and diplopia. We need to tell patients there is a slight chance after iridotomy that they might have a little ghost image when light hits their eye just the wrong way. For most patients, as long as they know this beforehand it's not a big deal. If they ignore it, it almost always goes away anyway, given time. In a rare patient, this would be a symptomatic issue that is of real concern to them. There's a lower association with diplopia if the PI is performed temporally (horizontal meridian). In a patient who does experience photopsia following PI that does not improve with time, you can recommend a cosmetic contact lens to let less light in there, or you can suggest a tattoo on the cornea to block light

another thing that can really help is taking out the lens or the cataract, because it creates more space, letting the iris drop back.

### TAKE ON THE CHALLENGE!

ACGs are a diverse array of glaucomas that can present different ways, develop different pathologies and require different treatments. They're not rare—they're challenging! They're also quite interesting, but it all starts with gonioscopy.

1. Fremont et al. Arch Ophthalmol. 2003;121(6):777-83.

## MACULAR IMAGING IN GLAUCOMA: WHAT DOES IT ADD TO THE DIAGNOSTIC WORKUP?

Ben Gaddie, OD

The macula is definitely an area we want to pay attention to in glaucoma because 50% of ganglion cells are located in the central 4.5mm of the macula, with peak ganglion cell density being 15,000 cells/mm<sup>2</sup> in the macula.<sup>1</sup> To determine the specificity or sensitivity of finding glaucoma through the nerve fiber, many clinicians use optical coherence tomography (OCT), which measures the peripapillary retinal nerve fiber around the optic nerve. But people can have quite disparate volumes of nerve fiber around their optic nerve, whereas in the macula, everyone's ganglion cell density is fairly consistent.

### A CLOSE LOOK AT CHANGE

So, what changes first? It has been determined that structure damage often precedes functional damage in glaucoma.<sup>2</sup> We also know that retinal nerve fiber loss often precedes optic disc changes.<sup>3</sup> However, I have had plenty of cases where the nerve fiber looks great, there is a notch in the nerve and a corresponding visual field defect, and I've had no question that it was glaucoma. Conversely, I've seen people with retinal nerve fiber layer (RNFL) damage who never develop what I would clinically consider perimetric open-angle glaucoma. So that relationship is not always as chronological as it might seem.

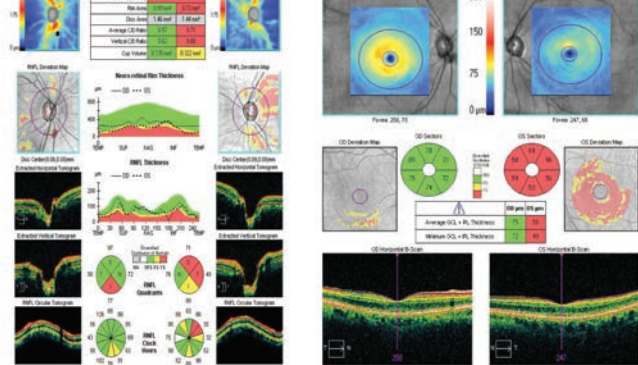
### A REFERENCE POINT

To remind you of the anatomy we're working with, keep in mind that *in* the macula, you have ganglion cell bodies and axons, but *through* the macula you also have axons that are traversing from more peripheral areas. So when you look in the macula, all the nerve fiber and ganglion cells are not necessarily residing here. Some of them may be just coursing through their normal anatomical path. The other thing that's really important are these ganglion cell dendrites, which interact with the inner nuclear and inner plexiform layer. One of the first things that we think happens in glaucoma is those dendrites begin to retract, pull away, shrink and decrease in density. So the macula is an important target for glaucoma simply based on the way that the axons course back to its temporal area.

### HELP FROM TECHNOLOGY

All of today's OCT instruments have software that allows us to parse out the ganglion cell layer, though each company defines this a little bit differently. Some companies include the retinal nerve fiber layer (RNFL), while others include the retinal ganglion cell layer and the inner plexiform and nuclear layers. One particular device lets you choose which layer you want to look at, but all help us visualize macular-associated RNFL loss.





SCANS CONFIRM SUSPICION OF RNFL LOSS IN PATIENT'S LEFT EYE.

**IN EXAMPLE**

Consider the 79-year-old white male whose baseline pressure, on average, was 23 mmHg OD and 28 mmHg OS. He had a thin cornea, which to me in the setting of ocular hypertension is a risk factor. His corneal hysteresis measurements were 8.8 OD and 9.0 OS (10+ normal) and he was currently on a prostaglandin in both eyes.

His optic nerve isn't that impressive, and if you didn't see a pressure of 27 mmHg you might not even work up this patient for glaucoma, but a closer look shows elongation of the cup, especially in the left eye. One of the first things I do is eyeball what the nerve fiber looks like, right eye versus left eye, and it did look fairly robust in the right eye. So is this truly RNFL loss, or just some junk in the OCT? This is where looking at the macula comes in handy. All of a sudden, you see in the left eye that the ganglion cells are significantly reduced in density versus the right eye (see above).

So now I start to put a lot more weight into what I'm seeing in the RNFL of that left eye. This really drives home and confirms my suspicion that there is RNFL loss in that left eye. There was no macular traction or evidence of anything else that might be responsible for apparent thinning in the macula.

Curcio CA, Allen KA. Topography of ganglion cells in human retina. *J Comparative Neurology*. 1990;300:5-25.  
 Sommer A. Clinically detected nerve fiber atrophy precedes the onset of glaucomatous field loss. *Arch Ophthalmol*. 1991;109:77-83.  
 Quigley HA, Katz J, Derick RJ, et al. An evaluation of optic disc and nerve fiber layer examinations for monitoring progression of early glaucoma damage. *Ophthalmology*. 1992;99:19-28.

**NEW DISCOVERIES IN GLAUCOMA**

**OCT AND THE DETECTION OF GLAUCOMA PROGRESSION**

Michael Chaglasian, OD, FAAO

Optical coherence tomography (OCT) and its role in glaucoma has continued to develop to the point that we're now able to use OCT as an additional tool—along with visual fields and optic nerve assessment—to monitor glaucoma progression.

In particular, OCT can help us answer the questions: what is the rate of progression, and can we quantify it so that we can get a better idea of the type of glaucoma our patient has? It would be a huge advantage if we could identify whether the patient is progressing slowly (and needs only minimal or moderate intervention) or if the patient is progressing rapidly (and requires more aggressive treatment). The earlier we can identify the rate of change in our patients, the better we can triage and

at a glance, rather than shuffling through a multitude of printouts and pages.

**IDENTIFYING CHANGE OVER TIME**

Very similar to the tools that are used in perimetry, OCT uses both event analysis and trend analysis of a series of images for a patient. Event analysis defines progression as when the difference between baseline and follow-up is greater than test-retest variability. Trend analysis defines progression as when there is a significant negative slope of a regression line, which is performed on a particular parameter.

**Event analysis.** Event analysis on OCT can help us identify certain patterns of retinal nerve fiber layer (RNFL) defects. When reviewing the printout of a series of images, identifiable patterns of progression include: initial appearance of a defect; widening of a defect; and deepening of a defect. Specifically, the coloration of the pixels that you'll see on the "deviation map" of the printout will get deeper and denser as more RNFL and retinal ganglion cell axons are lost in that particular region. The area of abnormality may also enlarge with time due to disease progression. The printout is optimized to highlight these changes. The appearance of an RNFL defect progressing on OCT corresponds to the way that grayscale visual field defect gets larger and denser over time.

**Trend analysis.** OCT performs trend analysis on four parameters: the average, superior and inferior RNFL thicknesses, and also the average cup-to-disc (C-D) ratio. While a positive slope on the C-D ratio plot indicates an increase in size of the cup-to-disc ratio (and thus likely progression), a negative slope on the average superior and inferior RNFL thickness indicates disease progression.

For quick identification, the thickness of the RNFL around the optic disc margin is highlighted to help you identify when change is evident. A yellow marker indicates that there is a change from baseline. If that change is repeated on follow-up testing, that color marker becomes red to help you identify with greater certainty that the change is truly due to disease and not just test-retest variability.

**LIMITATIONS TO OCT PROGRESSION**

The color coding is helpful to quickly spot a possible change, but remember that it is just a basic indicator—you must review the data to make sure it's not an artifact. Don't simply "treat the red." Also, be aware that age-related change is not (yet) factored into the progression analysis.

To summarize, structural assessment of progression is now in our hands with OCT progression analysis. It provides another piece of the puzzle—we still need to look at the visual fields, the optic nerve head, IOP, and all of the other information for our patients. Still, it has changed the way we practice by allowing us to identify the rate of glaucoma progression so we can better individualize our care and treatment.

*Dr. Chaglasian is an associate professor at the Illinois College of Optometry as well as chief of staff at the Illinois Eye Institute. He is also a founding member of the Optometric Glaucoma Society and is currently the organization's secretary.*

**THE ROLE OF TRABECULOPLASTY IN GLAUCOMA CARE**

Nils Loewen, MD, PhD

If you can perform gonioscopy, then you can do laser trabeculoplasty; it's not difficult. Here's a quick look at the different laser trabeculoplasty systems and their pre- and postop roles in the care of glaucoma patients. We will look at argon laser

## THE LINEUP

**ALT** is basically a small dot (50  $\mu\text{m}$ ) with a burn that is longer than the other lasers (100 ms), so you want to keep exactly where you intend to place the treatment. ALT has deeper penetration than SLT and TLT. Deeper penetration is achieved with a longer wavelength and the thinking is the biggest flow resistance is really closer to Schlemm's canal and where the meshwork gets the densest, so in theory, ALT sounds very good. But this is primarily a thermal effect that causes coagulative damage.

**SLT** treats more of the trabecular meshwork in one application. It has a much bigger spot (400  $\mu\text{m}$ ) and has a far shorter exposure (.003 ms). The short exposure causes a disruptive effect, including that of Schlemm's canal endothelium.

ALT and SLT are so fundamentally different, we expect different pressure effects. But from a biological perspective, we know that both modalities increase trabecular meshwork migration and cell division, and are involved in the induction of interleukin-1 and TNF-alpha, so there is some signaling happening as well. Additionally, matrix metalloproteinases are upregulated. SLT is definitely much more comfortable and causes less inflammation than ALT because it uses less energy, but there is really no pressure difference at three months.<sup>1</sup> ALT is very effective—it has the same failure rate as SLT at one year<sup>2</sup> and there is no difference at three years; it has the same success rate.<sup>3</sup>

**TLT.** I was involved in a study that compared SLT to TLT and over the course of 24 months, the pressure reduction is about the same.<sup>4</sup> So, in my opinion, whatever laser you have access to is the laser you should use. Just keep in mind that you can repeat SLT, but you can't safely repeat ALT because it causes true permanent damage to the meshwork where the laser spots are placed.

## TRABECULOPLASTY PROTOCOLS

	ALT	SLT	TLT
Premedication	brimonidine	brimonidine	brimonidine
Anesthetize	q5min x3	q5min x3	q5min x3
Laser technique	360° (#80-100) spots spaced	360° (#80-100) spots spaced	360° (#80-100) spots spaced
Irrigated to	collapsing small bubble, good focus	occasional bubbles	occasional bubbles
Postoperative	1 hour IOP check if: • on several gtts • advanced glaucoma • high IOP	1 hour IOP check if: • on several gtts • advanced glaucoma • high IOP	1 hour IOP check if: • on several gtts • advanced glaucoma • high IOP
Optional	prednisolone or ketorolac q.i.d. x 5 d bilateral treatment in same session consider pilocarpine for narrow angles to avoid peripheral anterior synechiae	prednisolone or ketorolac q.i.d. x 5 d bilateral treatment in same session Can be performed after dilation	prednisolone or ketorolac q.i.d. x 5 d bilateral treatment in same session Can be performed after dilation

## TRABECULOPLASTY PROTOCOLS

Whether you do ALT, SLT or TLT, you want to anesthetize the eyes with topical drops. With ALT, you space to the spots because it's only 50  $\mu\text{m}$ . With SLT and TLT, you can place them adjacent or slightly overlapping. The so-called champagne bubbles with ALT and with TLT are pretty small at best and if you get really big bubbles, then you are using too much energy.

al., SLT had a reduction of 8.3 mmHg (31%); whereaslatanoprost had a reduction of 7.7 mmHg (30.6%).<sup>5</sup> They also found no difference in patients treated postop with prednisolone or ketorolac q.i.d. for five days.

First and foremost postoperatively, you want to check pressures one hour after treatment if you are concerned that your patient can't tolerate a moderate pressure elevation. If he has ocular hypertension but otherwise good-looking nerves, it might not be necessary. Some doctors might treat with steroids or ketorolac, and that's fine—for five days. The most common postop complaint is soreness and light sensitivity, but that's limited and usually goes away. I tell my patients to try ibuprofen first and to call us if that's not enough.

## CONCLUSION

SLT, ALT and TLT are different in terms of physics, but they produce the same outcomes. You're also eliminating compliance issues in the eye that is lasered and it can be safely used whether someone is getting treatment or not. I like to treat both eyes at the same time, assuming they both have significant IOP elevation. It makes it much easier with the flow in the clinic and even though the second eye is only reimbursed 50%, I think this is easier decision making and better for everybody—the patient, the insurance and us. I encourage you to consider it as the first line of treatment.

*Dr. Loewen is an assistant professor in the Ophthalmology Department at the University of Pittsburgh, where he is the director of the Glaucoma Section, director of the Electronic Health Records and director of the Glaucoma Fellowship Program.*

1. Popiela G, Muzyka M, Zaelepin L, et al. Use of YAG-Selecta laser and argon laser in the treatment of open angle glaucoma. *Klin Oczna.* 2000;10(2):129-33.

2. Damji KF, Shah KC, Rock WJ, et al. Selective laser trabeculoplasty v argon laser trabeculoplasty: a prospective randomized clinical trial. *Br J Ophthalmol.* 1999;83(6):718-22.

3. Juzych MS, Chopra V, Baniitt MR, et al. Comparison of long-term outcomes of selective laser trabeculoplasty versus argon laser trabeculoplasty in open-angle glaucoma. *Ophthalmology.* 2004;111(10):1853-9.

4. Oatts JT, Kaplowitz K, Loewen NA. (2013, Feb/March). Post-procedure intraocular pressure of titanium-sapphire laser compared to standard selective trabeculoplasty. Poster presented at the American Glaucoma Society 23rd Annual Meeting. San Francisco, Calif.

5. McIlraith I, Strasfeld M, Colev G, et al. Selective laser trabeculoplasty as initial and adjunctive treatment for open-angle glaucoma. *J Glaucoma.* 2006;15(2):124-130.]

## NEW CONCEPTS IN GLAUCOMA

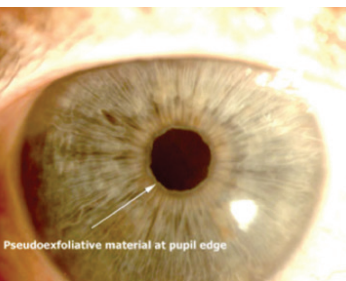
### EXFOLIATION SYNDROME AND GLAUCOMA

Michael Chaglasian, OD

The terms exfoliation glaucoma (XFG), exfoliation syndrome (XFS) and pseudoexfoliation (PEX) are used interchangeably to describe the same systemic condition characterized by the deposition of a protein-like material within the anterior segment of the eye, most notably on the anterior lens capsule, as well as other organs. Both genetic and environmental factors may play a role in its pathogenesis, and it is known to be a major risk factor for secondary open-angle glaucoma (OAG).<sup>1</sup>

It is characterized by excess synthesis and progressive accumulation of abnormal extracellular fibrillar material. The continuous accumulation of exfoliation material (XM) and pigment in the outflow system leads to elevated intraocular pressure (IOP) and eventually, to the development of XFG. An estimated 60 to 70 million individuals worldwide have XFS, and roughly 25% of those patients have elevated IOP.<sup>1</sup> One-third of these individuals have glaucoma.<sup>1</sup>

primary open-angle glaucoma (POAG), it is important to rule



## EVIDENCE OF PSEUDOEXFOLIATION.

compared to patients with POAG, those with XFG have: greater mean IOP; greater diurnal IOP fluctuation; more visual field loss and optic disc damage at the time of diagnosis poorer response to medications; greater need for surgical intervention; and greater proportion of blindness.<sup>2</sup> A differential diagnosis is important here, as XFG may need to be followed more closely and treated more aggressively, as it is known to progress more rapidly.

## FACTORS ASSOCIATED WITH XFS

XFS is strongly associated with variants of the gene lysyl oxidase-like 1 (LOXL1), which can cause either an excessive production of XM or an insufficient breakdown—or both.<sup>3</sup> Studies from around the world have shown that 98% to 99% of patients who have XFS have the LOXL1 gene variant,<sup>3,4</sup> but we also see it in a high percentage in control patients. Therefore, the LOXL1 gene is associated with the condition, but the presence of gene variants are not strongly correlated with a prevalence of the disease. This suggests that it's not just one causative mechanism and it's not just having the LOXL1 gene variant—it's having a combination of environmental and genetic factors that cause a situation that stresses the metabolism in the anterior segment and other organ systems, which leads to the development of XM.

Between 2001 and 2007, a retrospective study of 626,901 subjects from 47 U.S. states in a managed care network identified 3,367 incident XFS cases and found that patients who lived in the northern tier of the United States above 42° latitude had an increased risk or hazard of XFS.<sup>5</sup> It was also determined that in the southern tier below 37° latitude had a lower expression of XFS. They also factored in temperature, and found that for every 1° increase in July high temperature, the hazard of XFS decreased by 9%. Thus, ambient temperature and sun exposure may be important environmental triggers of XFS and the discovery of environmental factors linked to XFS could lead to primary prevention measures for this condition.

## OCULAR RISKS AND TREATMENT

The ocular risks from exfoliation include: pigment dispersion; age-related cataract; late-onset, spontaneous intraocular lens (IOL) dislocation; retinal vein occlusion (RVO); elevated IOP and narrow angles; and (aggressive) OAG. Clinical examination and awareness of this condition is really the starting point.

Treatment for XFS is similar to that for POAG; you just need to be more vigilant with your patients. Start with prostaglandin analogs; they work quite well at lowering IOP. Fixed combinations play an important adjunctive role. I don't use beta-blockers or alpha agonists because I find greater adjunctive pressure reduction with the fixed-combination products. Laser trabeculoplasty—specifically argon laser trabeculoplasty—is another

out secondary glaucomas and secondary mechanisms to avoid complications down the road. Careful slit lamp examination of the anterior chamber and gonioscopy will help identify these mechanisms. Patients with XFS and XFG tend to have narrow angles.

## WATCH FOR RED FLAGS

Once I see a certain amount of XM present in a patient's anterior chamber, I begin to follow them more regularly—on a three- to six-month basis. I do more frequent visual fields and optical coherence tomography and I do quick, dilated exams and look for significant IOP spikes. The take-home message here is to treat and watch these patients more aggressively because conversion from normal and stable or just mild pressure elevation can be rapid and dramatic.

1. Ritch R. Ocular and systemic manifestations of exfoliation syndrome. *J Glaucoma*. 2014;23(8):Suppl.
2. Heijl A, Bengtsson B, Hyman L, Leske MC; Early Manifest Glaucoma Trial Group. *Ophthalmology*. 2009;116(12):2271-6.
3. Thorleifsson G, Magnusson KP, Sulem P, et al. Common sequence variants in the LOXL1 gene confer susceptibility to exfoliation glaucoma. *Science*. 2007;317(5843):1397-400.
4. Hewitt AW, Sharma S, Burdon KP, et al. Ancestral LOXL1 variants are associated with pseudoexfoliation in Caucasian Australians but with markedly lower penetrance than in Nordic people. *Hum Mol Genet*. 2008;17(5):710-16.
5. Stein JD, Pasquale LR, Talwar N, et al. Geographic and climatic factors associated with exfoliation syndrome. *Arch Ophthalmol*. 2011;129(8):1053-1060.

## MIGS SURGERIES WITH OR WITHOUT CATARACT SURGERY

Nils Loewen, MD, PhD

As we all know, the prevalence of glaucoma is on the rise, and that's because we are living longer. In 2020, primary open-angle glaucoma (POAG) will have increased by 30% from 2010 and affect 59 million people, causing bilateral blindness in 5.9 million.<sup>1</sup> Faced with a greater number of patients with this disease, it's important that we are armed with the most recent and relevant information to help us manage them. Here, I will discuss different minimally invasive glaucoma surgeries (MIGS) and compare them with trabeculectomies and tube shunts.

## MAKE WAY FOR MIGS

Schlemm's canal is about 200 μm (about 20-fold smaller than structures that a cataract surgeon encounters), which makes these surgeries quite difficult. Glaucoma surgeons are no strangers to problems with hardware and the use of mitomycin C (MMC). These include shallow chambers; leaking blebs; kissing choroidals from hypopnea and fluid accumulation; tube shunts eroding through the conjunctiva; progressive thinning; blebitis; and endophthalmitis. Needless to say, the introduction of MIGS was a blessing. It allows us to address the disease where it essentially exists: the trabecular meshwork. MIGS can be performed with the following devices: Trabectome (NeoMedix Inc.); Hydrus Microstent (Ivantis—available soon); iStent Trabecular Micro Bypass (Glaukos); Xen Gel Stent (AqueSys); CyPass Micro-Stent (Transcend Medical); and Solx Gold Shunt (Solx Inc.).

Phacoemulsification is very similar to MIGS: it requires sophisticated technology and the work space is quite confined. Both phaco and MIGS are safe, offer predictable, standardized results and can be used in up to moderate disease. Additionally, they involve a small incision. In comparison, trabeculectomy and old-fashioned extracapsular cataract extraction are low-tech, appropriate for advanced disease and require a large incision. These procedures have variable results and can result in serious complications. I think we are experiencing a paradigm shift now with MIGS that is similar to what we saw with phaco, which means we're going to see more surgeries being performed much earlier on.

What I've mentioned are all angle surgeries, which are



endothelial growth factor agent-induced, acute angle closure, chronic angle closure, lower pressure). If you remove or bypass these, you get a good pressure reduction.

## DIFFERING COMPLICATIONS

The biggest difference between MIGS and trabeculectomy and tube shunts has to do with complications. MIGS is fast—maybe only one-tenth of the time of the other procedures—and the incisions are small; therefore, the complications are very minimal (early 10 mmHg IOP elevation that resolves and hyphema that resolves). Of course, I would not call hyphema a complication because the more of Schlemm's canal you access, the more hyphema you're going to see as an anticipated flow back.

On the other end of the scale here, 74% of trabeculectomies need manipulation and 27% of tube shunts need manipulation.<sup>2</sup> Furthermore, early and late vision-threatening complications were found in 77% of trabeculectomies and in 58% of tube shunts.<sup>2</sup> Still, these are important surgeries that aggressively lower pressure.

## GLOBAL OUTCOMES

Looking at the survival curve of MIGS only vs. MIGS plus

This enduring activity may contain discussion of published and/or investigational uses of agents and/or devices that are not indicated by the FDA. Off-label use of a medication or a biological is defined as use for an indication, or in a manner for which FDA approval has not yet been obtained and which is therefore not included on the FDA-approved label or product packaging. Please refer to the official prescribing information for each product for discussion of approved indications, contraindications and warnings. Practitioners should critically assess the information herein and are encouraged to consult appropriate resources for any product or device mentioned in this program.

The educational content of this activity has been peer reviewed and validated to ensure that it is a fair and balanced representation of the topic based on the best available evidence.

more than 20% of preop and IOP less than 21 mmHg at the last two follow-up visits and after three months postop.<sup>3,4</sup> Six-year outcomes, which are now available for Trabectome surgery as the most mature procedure, show that results last and medications are reduced effectively. When comparing MIGS-phaco to trabeculectomy-phaco, trabeculectomy still achieves lower pressure,<sup>5</sup> so clearly there is a role for this procedure.

So, in a nutshell, MIGS has one-tenth of the complication frequency seen with traditional surgery, and those are not serious. Also, MIGS does not induce additional astigmatism. Trabeculectomy and tube shunts can achieve slightly lower pressures in average at the cost of a higher surgical risk.

1. Quigley HA, Broman AT. The number of people with glaucoma worldwide in 2010 and 2020. *Br J Ophthalmol.* 2006;90(3):262-267.
2. Gedde SJ, et al. Postoperative complications in the Tube Versus Trabeculectomy (TVT) study during five years of follow-up. *Am J Ophthalmol.* 2012;153(5):804-814.
3. Kaplowitz K, Schuman JS, Loewen NA. Techniques and outcomes of minimally invasive trabecular ablation and bypass surgery. *Br J Ophthalmol.* 2014;98(5):579-585.
4. Bussell II, Kaplowitz K, Schuman JS, Loewen NA; Trabectome Study Group. Outcomes of ab interno trabeculectomy with the trabectome by degree of angle opening. *Br J Ophthalmol.* 2014; Oct 21. [Epub ahead of print]. DOI: 10.1136/bjophthalmol-2014-305577.
5. Francis BA, Winarko. Combined Trabectome and Cataract Surgery versus Combined Trabeculectomy and Cataract Surgery in Open-Angle Glaucoma. *Clin Surg Ophthalmol.* 2011;29:2/3.
6. Gedde SJ, et al. Postoperative complications in the Tube Versus Trabeculectomy (TVT) study during five years of follow-up. *Am J Ophthalmol.* 2012;153(5):804-814. e1.

## CE TEST FOR EAST COAST OPTOMETRIC GLAUCOMA SYMPOSIUM 2014

To obtain two hours of continuing education credit, complete the exam by recording the best answer to each self-assessment question online at: [www.revoptom.com/ECOGS2014](http://www.revoptom.com/ECOGS2014). Or, mail the Examination Answer Sheet on page 12 to: Optometric Education, P.O. Box 488, Canal Street Station, New York, NY 10013. A minimum score of 70% is required to obtain a certification of completion. There is no fee for this course.

### Which of the following is true:

- Trend-based analysis picks up fast progression quicker.
- Trend-based analysis has weaker confidence.
- Trend-based analysis picks up slow progression better.
- Trend-based analysis has weaker certainty.

### The nasal and temporal regions on RNFL thickness maps are always:

- Red.
- Blue.
- Yellow.
- White.

### The Bruch's membrane opening-minimum rim width:

- Quantifies the rim from its anatomic border.
- Accounts for the variable orientation of artifacts.
- Quantifies the optic nerve head from its anatomic border.
- Both a and b.

### 4. Which of the following factors can affect an OCT scan:

- a. Signal strength.
- b. Dry eye.
- c. Epiretinal membranes.
- d. All of the above.

### 5. A disadvantage to using combination medicines is:

- a. Increased cost.
- b. Not being able to change the dosing frequency of just one component of the combination.
- c. Inconvenient for patients.
- d. Risk of increased side effects.

### 6. Which of the three FDA-approved combination glaucoma drugs is an option for patients who are allergic to brimonidine?

- a. Dorzolamide HCl/timolol maleate ophthalmic solution 2%/0.5% (Cosopt).
- b. Brimonidine tartrate/timolol maleate ophthalmic solution 0.2%/0.5% (Combigan)
- c. Brinzolamide/brimonidine tartrate ophthalmic suspension 1%/0.2% (Simbrinza)
- d. All of the above drugs are an option for brimonidine-sensitive patients.

### 7. What percentage of glaucoma patients undergo gonioscopy within five years of being diagnosed?

- a. 46%.
- b. 54%.
- c. 20%.
- d. 15%

### 8. \_\_\_\_\_ is a complication of iridotomy.

- a. Diplopia.
- b. A spike in intraocular pressure.
- c. Ghost images.
- d. All of the above are complications of iridotomy.

### 9. Which of the following is *not* a treatment option for angle-closure glaucoma:

- a. Cornea tattoo.
- b. Peripheral iridotomy.
- c. Photodynamic therapy.
- d. Cosmetic contact lens.

### 10. \_\_\_\_\_ is commonly used to determine the specificity or sensitivity of finding glaucoma through the nerve fiber.

- a. Gonioscopy.
- b. OCT.
- c. Corneal hysteresis measurements.
- d. Trend analysis.

### 11. In glaucoma, \_\_\_\_\_ often precedes \_\_\_\_\_.

- a. Structure damage, functional damage.
- b. Functional damage, structure damage.
- c. Optic disc changes, retinal nerve fiber loss.
- d. None of the above.

### 12. Event analysis:

- a. Defines progression as when there is a significant negative slope of a regression line.
- b. Defines progression as when the difference between baseline and follow-up is less than test-retest variability.
- c. Highlights the thickness of the retinal nerve fiber layer around the optic disc margin.
- d. None of the above.



DOWNLOAD LAYAR APP  
FOR INTERACTIVE EXPERIENCE



layar

INTERACTIVE PRINT

First 150 app downloads and completed forms will be entered into a drawing for FREE MEETING AND REGISTRATION VALUED AT \$495

REGISTRATION OPEN!

## REVIEW OF OPTOMETRY

EDUCATIONAL MEETINGS OF CLINICAL EXCELLENCE

# SAN DIEGO, CA

## APRIL 10-12

### OMNI SAN DIEGO HOTEL



**\$100 OFF BY  
FEBRUARY 10TH**

### CE COURSE TOPICS:

- Management of Lid Margin Disease
- Innovations in Eye Care
- Glaucoma Diagnostic Dilemmas and Solutions
- Emergency and Urgency Diagnosis and Treatment
- Anterior Segment Disease Diagnosis and Treatment
- Looking at the Optic Nerve in Glaucoma
- Comanagement of Cataract and Refractive Surgery
- Writing Oral Prescriptions

**NEW!!**

Dry Eye Workshop • Glaucoma Workshop

### FACULTY

Paul Karpecki, OD  
[Program Chair]



Marc Bloomenstein, OD



Derek Cunningham, OD



Doug Devries, OD



Ben Gaddie, OD



### 5 WAYS TO REGISTER

ONLINE: [WWW.REVOPTOM.COM/SANDIEGO2015](http://WWW.REVOPTOM.COM/SANDIEGO2015)

EMAIL LOIS DIDOMENICO: [REVIEWMEETINGS@JOBSON.COM](mailto:REVIEWMEETINGS@JOBSON.COM)

MAIL: REVIEW GROUP MEETINGS c/o JOBSON

11 Campus Blvd, Ste 100

Newtown Square, PA 19073

PHONE: 866-658-1772

FAX: 610-492-1039



**Up to  
17 CE  
Credits**  
(COPE approval pending)



# OMNI SAN DIEGO HOTEL

675 L STREET SAN DIEGO, CA 92101

Discounted Room Rate: \$249/night single,  
\$269/night double

For Hotel reservations, call 800-843-6664

Discounted Room Rates Limited.

Identify yourself as a participant of

“Review of Optometry” for group rate.

## Up to 17 Credits

(COPE Approval Pending)

[www.revoptom.com/SanDiego2015](http://www.revoptom.com/SanDiego2015)

## Registration Information

Name		NPI # (NPI numbers will only be used for HCP reporting purposes)	
Practice Affiliation			
Mailing Address	City	State	Zip Code
Telephone	Fax	Email	

## Name Badge Information (please print clearly)

My Name	My Guest	Additional Guests
---------	----------	-------------------

## Payment Information

	Rate per person	No. in party	Subtotal
OD Registration - \$495 (\$100 off by February 10, 2015 - only \$395) (includes 15 hours of CE, breakfasts, reception) <small>Call for daily and student rates.</small>	\$495	x _____	= \$ _____
Additional Guest(s) - \$45 (12 years and older, includes reception)	\$45	x _____	= \$ _____
Concurrent Workshop Sessions (Saturday, April 11, 2:30pm - 4:30pm) <small>Select only one if interested in additional session and credits</small>			
Dry Eye Workshop - \$70 (Earn 2 additional CE Credits)	\$70	x _____	= \$ _____
Glaucoma Workshop - \$70 (Earn 2 additional CE Credits)	\$70	x _____	= \$ _____
		TOTAL	= \$ _____

Check enclosed (make checks payable to *Review of Optometry*)

Charge my:  American Express  Mastercard  Visa

Credit Card Number \_\_\_\_\_ Exp Date \_\_\_\_\_

Cardholder (print name) \_\_\_\_\_

Signature \_\_\_\_\_

**CONFERENCE CANCELLATION POLICY**

- Full refund on registration fee until March 10, 2015
- 50% refund on registration fee until March 28, 2015
- No refund past March 29, 2015

For more information or to register,  
contact Lois DiDomenico at 866-658-1772  
or at [ReviewMeetings@Jobson.com](mailto:ReviewMeetings@Jobson.com).





# The Lay of the Land

When considering IOL implementation following cataract surgery, the shape of the cornea plays a big role. **Edited by Joseph P. Shovlin, OD**

**Q** One of my keratoconus patients will need cataract surgery in the near future. Her topography shows classic inferior steepening with a relatively “normal” central cornea with moderate astigmatism on her Pentacam image. How do you best decide who might do well with a toric IOL option?

**A** Paying close attention to the patient’s corneal topography is key to selecting a toric IOL. “Cataract surgery—and specifically IOL selection—in keratoconus patients can be challenging. These patients often have steeper corneas and their astigmatism has varying degrees of irregularity, which makes predicting the correct magnitude and axis for toric IOL placement difficult,” says Eric Donnenfeld, MD, a Long Island ophthalmologist who specializes in refractive cataract surgery.

In the case of this particular patient, toric IOL implantation is possible because the ectasia pattern avoids the central cornea, says Martin Fox, MD, who serves as medical director at the Cornea and Refractive Surgery Practice of New York. However, he cautions, clinicians should adhere to a few conditions.

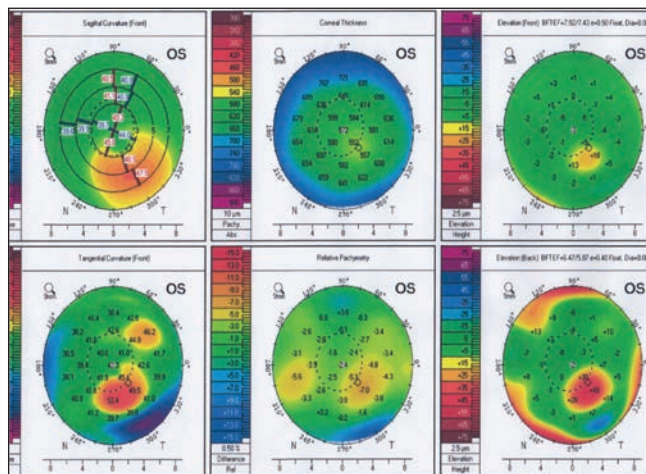
First, the patient must have a history of reasonably good spectacle-corrected visual acuity with moderate levels of astigmatism. If this condition is not met, the patient is unlikely to do well with the IOL, Dr. Fox explains. Additionally, when evaluating the patient’s astigmatism, axis and corneal power should be the same when measured

using both manual keratometry and elevation tomography. Any difference in measurements likely indicates the astigmatism is too irregular and could result in the lens being implanted in an inappropriate position.

These patients should instead be managed with standard monofocal intraocular lenses and then subsequently fit with a soft or GP contact lens to address residual refractive errors, says Dr. Fox. In any case, he adds, doctors should avoid multifocal IOL implants in all patients with confirmed keratoconus.

Dr. Donnenfeld says he generally prefers to avoid performing incisional surgery on patients who already have ectatic disease, but recommends evaluating a keratoconic patient using refraction and topography (or keratometry)—a toric IOL will generally do well if the axis of cylinder is the same with regards to both refraction and either topography or keratometry. If the axis is not the same, he suggests using a zero aberration IOL instead.

Both surgeons agree: some of the challenge in selecting an IOL starts with cataract removal. They each



**A Pentacam image of a keratoconus patient. Depending on corneal topography, these patients can do well with toric IOLs.**

Photo: Martin Fox, MD

recommend steps to improve the procedure to make IOL implementation easier. Dr. Donnenfeld suggests considering first performing Intacs to reduce and regularize the cylinder. “In the very near future, topographic ablations will be available in the United States,” he says. “That can help improve the corneal topography and improve post-cataract surgery visual rehabilitation.”

Dr. Fox suggests a two-step approach when faced with a highly irregular cornea and cataract. “Femtosecond laser keratoplasty (FLAK) should be performed as a first measure, with cataract surgery to follow after adequate corneal stabilization,” he says. FLAK is associated with rapid corneal healing with low levels of astigmatism, and “our patients have been able to move forward with follow-up cataract as early as three months post-corneal surgery, with excellent results.” ■

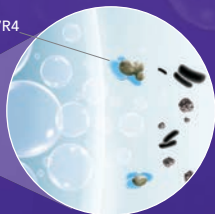
# THIS IS WHY 4 out of 5 patients agree their lenses feel like new.<sup>1</sup>

The scientifically proven formula of CLEAR CARE® Solution deeply cleans, then neutralizes, to create a gentle saline similar to natural tears. The result is pure comfort and is why CLEAR CARE® has the most loyal patients of any lens care brand.<sup>2</sup>

## The Science Behind a Pristine, Clean Lens:



Pluronic 17R4



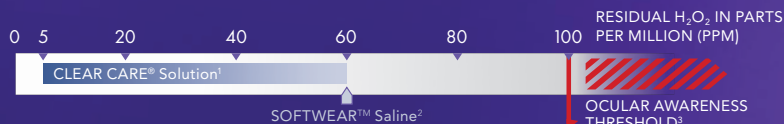
### Triple-Action Cleaning

- Patented formula deeply cleans
- Carries away dirt & debris
- Pluronic<sup>^</sup> 17R4 lifts away protein

### Pristine, Clean Lens

- Less residual H<sub>2</sub>O<sub>2</sub><sup>3-5</sup>
- Irritant-free comfort
- No added preservatives

## Range of Residual H<sub>2</sub>O<sub>2</sub> on Lens:



Recommend CLEAR CARE® Solution and learn more at [MYALCON.COM](http://MYALCON.COM)

PERFORMANCE DRIVEN BY SCIENCE™



<sup>^</sup>Trademarks are the property of their respective owners.

References: 1. A market research study conducted amongst 107 US contact lens wearers representative of CLEAR CARE® purchasers in the United States, 2007. 2. Based on third party industry report 52 weeks ending 12/29/12; Alcon data on file. 3. Alcon data on file, 2009. 4. SOFTWEAR™ Saline package insert. 5. Paugh, Jerry R, et al. Ocular response to hydrogen peroxide. *American Journal of Optometry & Physiological Optics*: 1988; 65:2,91-98.

© 2014 Novartis 02/14 CCS14004ADi

**Alcon**  
a Novartis company



20<sup>TH</sup> ANNUAL

# OPHTHALMIC PRODUCT GUIDE



Innovative products to  
enhance your practice

The **future**  
is in your  
hands. One  
tap, many  
possibilities.

Experience the digital edition on your handheld device.  
Use your smart device to scan the code below or visit:



[www.reviewofoptometry.com/supplements/](http://www.reviewofoptometry.com/supplements/)

Download a QR scanner app. Launch app and hold your mobile device over  
the code to view <http://www.reviewofoptometry.com/supplements>

**REVIEW**  
OF OPTOMETRY



## All About That Baseline

Two new glaucoma suspects presented on the same day with similar initial findings. Why wait to medicate? Their differences explain why. **By James L. Fanelli, OD**

I recently examined two new patients: one was referred for a diabetic retinal examination and the other to establish care. Each was referred by separate primary care providers. The patients' presentations seemed similar at first glance. But, first impressions can be misleading.

### Diagnostic Data

The first patient, Alice, is a 59-year-old white female diagnosed with Type 2 diabetes mellitus, for which she was recently prescribed metformin to help drive down her rising glucose levels. She was also on Zyrtec (cetirizine, McNeil), low-dose (81mg) aspirin QD, Aciphex (rabeprazole, Eisai) and Synthroid (levothyroxine, AbbVie).

The second patient, Barry, is a 64-year-old white male who hadn't had an eye exam in several years, but was nudged to do so by his family doctor. He was taking lisinopril, amlodipine and Crestor.

Alice was a low myope with best-corrected visual acuity of 20/20-1 OD and OS. Barry too was a myope and also best corrected to 20/20-1 OD and OS. Pupils were normal in each patient and their extraocular motilities were full in all positions of gaze.

Anterior chamber angles in each patient were open, as estimated by the Van Herick method. Alice's intraocular pressures measured 32mm Hg OD and 34mm Hg OS at 3:15pm. Barry's IOP measured 33mm Hg OD and 38mm Hg OS at 3:55pm. Corneal thicknesses for

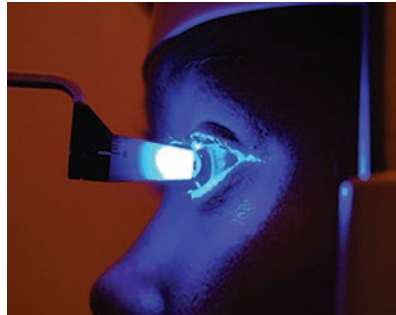


Photo: Mark M. Cheung, OD

**Both patients presented at their initial visits with uncontrolled glaucoma, with intraocular pressures measured in the 30s. Do you begin topical drops that day, or do you need more information first?**

Alice measured 542 $\mu$ m OD and 556 $\mu$ m OS, while Barry's were 560 $\mu$ m OD and 558 $\mu$ m OS.

Upon dilation, each had early nuclear sclerotic lens changes that correlated with their best-corrected visual acuities; Barry also had a few cortical spokes not encroaching on the visual axis. Each patient had posterior vitreous detachments OU.

Alice had normal-sized optic nerves, with cup-to-disc ratios of 0.50 x 0.65 OD and 0.60 x 0.65 OS, with a somewhat thinned neuroretinal rim inferotemporally. Barry also had normal-sized optic nerves, with cup-to-disc ratios of 0.55 x 0.70 OD and 0.60 x 0.75 OS, also with neuroretinal rims that do not follow the ISNT rule.

We obtained Heidelberg Retina Tomograph-3 (HRT-3, Heidelberg Engineering) imaging of the optic nerves at the initial visits, which corroborated the described cup-to-disc ratios and thinned neuroretinal rims.

Retinal vascular examination of each patient was similar in that mild arteriolar sclerotic retinopathy was present in both eyes. Alice's macular evaluation was unremarkable except for mild retinal pigment epithelium (RPE) granulation consistent with her age, whereas Barry had some fine RPE mottling OU with some drusen in the temporal foveal avascular zone (OD>OS). Peripheral retinal evaluations in each patient were unremarkable.

### Diagnosis

At each patient's initial visit, I diagnosed uncontrolled glaucoma.

The question now: What is the very next step for these two patients? Should they begin medication right away, or await further testing?

### Discussion

Clearly, both patients have glaucoma and need intervention to prevent further damage. However, it's not feasible to perform all necessary baseline testing during the initial work-up, so we scheduled both patients for follow-up visits to obtain the remaining information.

Now, why not just medicate these patients at the conclusion of their initial visits? After all, the patients will be on medications anyway. And with IOPs as elevated as they are, shouldn't the patients be medicated *now* to help stave off further damage?

The answer to those questions boils down to your level of suspicion for imminent damage during

that next week or two until the follow-up visit.

Progression can occur rapidly in open-angle glaucoma patients, typically when high IOP coincides with a frail neuroretinal rim, in “perfect storm” of risk.

Certainly, in the presence of advanced disease (and these patients have moderate to moderately advanced disease already) with a frail, thin neuroretinal rim that is clearly showing advanced damage, therapy at the conclusion of the initial visit is warranted.

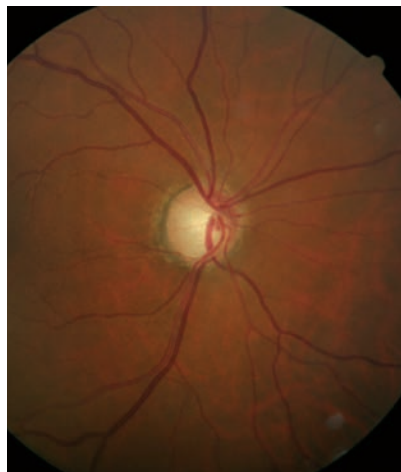
The same holds true for significantly elevated IOP (and the argument can be made here that each patient’s IOP *is* significantly elevated already) that puts the patient not only at risk for further nerve damage but also retinal vein occlusion or ischemia in the presence of poor ocular perfusion. Again, initiate therapy at that visit.

But, in cases such as these—involving open angles and no evidence of angle closure—keep in mind that glaucoma is chronic in nature.

## Build a Better Baseline

There is another important aspect to consider for patients who are going to be chronically medicated: establishment of a baseline untreated IOP, upon which the efficacy of all future therapy is based.

For each of these patients, we have only one set of IOP readings so far. Now, here’s where the two cases diverge—and it highlights the need to assess pre-treatment IOP. In both cases, though IOPs were high and damage existed, I chose not to medicate on the first visit, and instead will initiate therapy after their follow-up visits. Why wait to medicate? Because one IOP reading generally doesn’t tell us enough—and it’s simply not prudent to treat



**Patients diagnosed with open-angle glaucoma will be medicated for the rest of their lives. Make sure you have a good handle on the baseline IOP so you fully understand the therapeutic effect.**

glaucoma, or almost any disease, without having a good clinical assessment of the starting point.

So, their follow-up visits certainly included a second IOP measurement as well as those other remaining pieces to the glaucoma puzzle—threshold visual fields, gonioscopy, stereo photography, optical coherence tomography of the retinal nerve fiber and ganglion cell layers, and ultrasound biomicroscopy.

In both patients, results of follow-up testing were consistent with open-angle glaucoma, with good correlation between structure and function.

But the take-home lesson is in each patient’s *second* IOP readings. Alice’s IOPs measured 25mm Hg OD and 26mm Hg OS, while Barry had IOPs of 33mm Hg OD and 37mm Hg OS. Obviously, Alice had a larger variation from the initial readings, whereas Barry’s IOPs were about identical to his original pressures.

This, in turn, plays a big role in what we would consider our

starting point of unmedicated IOP. Barry’s case is straightforward: unmedicated IOPs were in the low 30s OD and mid-30s OS. Alice, on the other hand, had pre-medicated IOPs of upper 20s to low 30s OU—a broader range correlating with the variances in IOP.

At the end of each of their second visits, I prescribed Zioptan (tafluprost 0.0015%, Akorn) HS OU. I’ve seen each patient twice since that visit; Alice has average medicated IOPs of 24mm Hg OD and OS. Barry has average medicated IOPs of 23mm Hg OD and OS.

Both patients are experiencing a reduction in IOP on medication, but are they (relatively) equally controlled? I think Barry, at this point, is more stabilized than Alice, simply because he has had a 40% reduction in IOP from a relatively stable baseline. Alice, on the other hand, may be stabilized, but I can make the argument that she might not be fully stabilized. Because Alice had a greater variation from baseline to medicated, it hints that she might still fluctuate. Only time will tell.

So, these two patients, with similar initial findings and similar responses to medical therapy, differ in my assessment and certainty of stability at this early stage of therapy—all because of the second IOP measurement for each patient. Had I not obtained that second pre-treatment IOP for each patient, the therapeutic effect and assessment of stability may well have been considered equal.

Therefore, in the large majority of recently diagnosed glaucoma patients, obtain several pre-treatment IOP measurements to better assess a baseline. Remember, that baseline is the essential metric upon which all future therapy is judged, so get as accurate a measurement as possible. ■



DOWNLOAD LAYAR APP  
FOR INTERACTIVE EXPERIENCE



First 150 app downloads & completed forms will be entered into a drawing for FREE MEETING & REGISTRATION VALUED AT \$495

REGISTRATION OPEN!

## REVIEW OF OPTOMETRY

EDUCATIONAL MEETINGS OF CLINICAL EXCELLENCE



# CHARLESTON, SC

## JUNE 12-14

### FRANCIS MARION HOTEL

387 KING STREET CHARLESTON, SC 29403

### CE COURSE TOPICS:

- New Developments in Cornea and Contact Lenses
- Innovations in Eye Care
- Management of Ocular Surface Disease
- Grand Rounds in Anterior Segment Disease
- Modern Management of Periocular Malignancies
- Ocular Urgencies and Emergencies
- Ocular Occlusive Disease
- HSV, HZO, EKC: Viral Eye Disease Alphabet Soup
- Beyond Glaucoma: A Primer for OCT Interpretation

**\$100 OFF BY  
APRIL 10TH**

### NEW! Dry Eye and Glaucoma Workshops

### FACULTY

Paul Karpecki, OD  
[Program Chair]



Doug Devries, OD



Andrew Gurwood, OD



Nathan Lighthizer, OD



Marc Myers, OD



Jack Schaeffer, OD



### 3 WAYS TO REGISTER

ONLINE: [WWW.REVOPTOM.COM/CHARLESTON2015](http://WWW.REVOPTOM.COM/CHARLESTON2015)

EMAIL LOIS DIDOMENICO: [REVIEWMEETINGS@JOBSON.COM](mailto:REVIEWMEETINGS@JOBSON.COM)

PHONE: 866-658-1772



Up to  
**17 CE  
Credits**  
(COPE approval pending)



## Go Further—Without Leaving Home



Expand your clinical skills and catch up on your CE requirements, all from the comfort of your own home.

*Review* offers **nearly 100 hours** of COPE-approved continuing education — right now! It's **just a click away**. Our extensive library of exams runs the gamut from keratoconus to fundus autofluorescence, and everything in between.



[www.reviewofoptometry.com/continuing\\_education](http://www.reviewofoptometry.com/continuing_education)

Download a QR scanner app. Launch app and hold your mobile device over the code to view [www.reviewofoptometry.com/continuing\\_education](http://www.reviewofoptometry.com/continuing_education).

**REVIEW**<sup>®</sup>  
OF OPTOMETRY





# Look What the Cat Dragged In

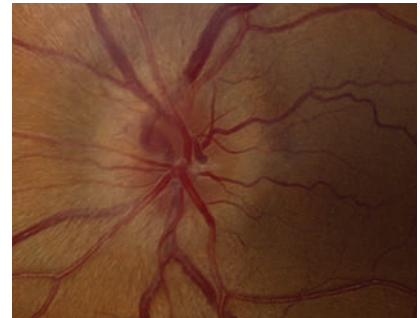
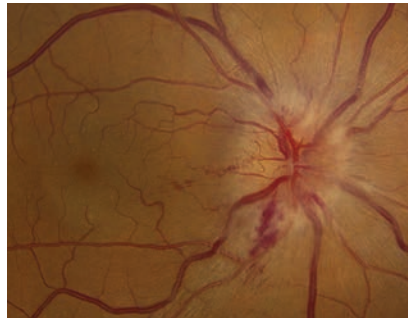
A young patient experiences vision problems without pain. Can you identify the cause? **By Mark T. Dunbar, OD**

An 11-year-old Hispanic female presented with complaints of sudden onset of blurred vision and floaters in her right eye for the past two weeks. She also reported that her peripheral vision in that eye was reduced. She denied any pain or discomfort. The left eye was unaffected.

Her ocular history was unremarkable and she reported good health. She took no medications.

On examination, her best-corrected visual acuity was 20/30 OD and 20/20 OS. Confrontation fields were full to careful finger counting OU. The pupils were equally round and reactive, with a 1+ afferent defect in the right eye. Anterior segments were unremarkable.

On dilated fundus exam, the vitreous was clear in both eyes. Exam of the right eye showed fundus changes (figure 1); the peripheral retina was normal. Fundus exam of the left eye showed a pink optic nerve with elevated disc margins (figure 2). The macula, vessels and periphery were normal. We performed spectral-domain optical coherence tomography (SD-OCT) (figure 3) as well as fluorescein



**Figs. 1 & 2. Fundus image of the right eye (left photo) shows fundus changes. Fundus image of the left eye (right) shows a pink optic nerve with elevated disc margins.**

angiography (figures 4 and 5) of the macular region of both eyes.

## Take the Retina Quiz

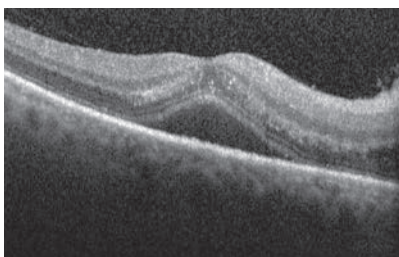
- What do the fundus changes in the right eye show?
  - Swollen optic nerve.
  - Disc swelling and macular star.
  - Neurosensory retinal detachment.
  - Papilledema.
- What additional testing would be most helpful in making the correct diagnosis?
  - Visual field.
  - Fasting blood glucose.
  - Blood test, including an ELISA for *Bartonella henselae*.
  - Neuroimaging, including MRI.
- What does the optic nerve of the left eye represent?
  - It's normal.
  - Disc swelling.
  - Optic nerve drusen.
  - Ischemic optic nerve.
- What is the most likely diagnosis?

- Idiopathic intracranial hypertension.
  - Optic neuritis.
  - Neuroretinitis.
  - Papilledema.
- What is the treatment for this patient?
    - Intravitreal Avastin.
    - Doxycycline PO.
    - Prednisone PO.
    - Weight loss.

For answers, turn to page 122.

## Diagnosis

Our patient has optic nerve swelling and a neurosensory retinal detachment in the right eye and optic nerve drusen in the left. If you look closely at her macula in the right eye, you'll also see that she has exudate in a "macular star" pattern. This presentation most likely represents a neuroretinitis caused by *Bartonella henselae*, or cat-scratch disease (CSD). Our patient admitted to having two cats and one dog. However, she didn't recall being scratched by her cats.



**Fig. 3. SD-OCT image of the patient's right eye.**



We ordered a blood work-up that included angiotensin-converting enzyme (ACE) and complete blood count with differential, IgG and IgM titers for *Bartonella henselae*, and antibodies to toxoplasmosis. She also underwent visual field testing, which showed an enlarged blind spot and an inferior arcuate-like defect in the right eye.

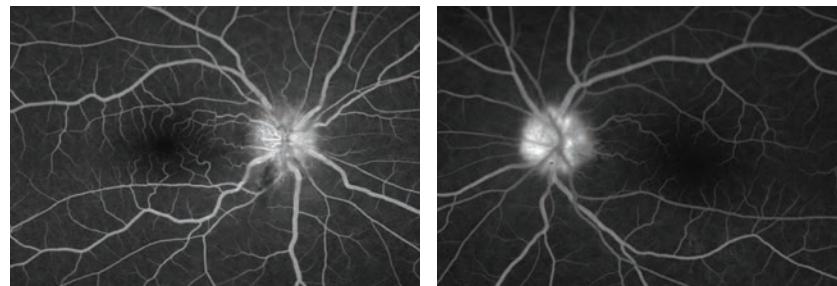
We elected to treat her empirically with doxycycline PO 100mg BID until the results of the blood studies were available. The IgG results came back strongly positive. When we questioned the patient further, although she didn't recall any cat scratches she admitted that she bites/chews on her fingernails, and related that quite often the cats lick her fingers. We surmised that was the likely route of her infection.

## Discussion

The term *neuroretinitis* is synonymous with *Leber's stellate neuroretinitis*, a condition that was originally identified in 1916 by Theodor Leber, who described a clinical syndrome in which patients had unilateral vision loss in the presence of a macular star.<sup>1</sup> He believed that the problem primarily involved the macula.

By 1977, Dr. J. Donald M. Gass showed that patients with macular star also had swelling of the optic disc before and often concurrently with the appearance of the star formation.<sup>1,2</sup> Dr. Gass concluded that the condition was not primarily a maculopathy but rather an optic neuritis that affected both the optic nerve and retina. Thus, he called it a neuroretinitis.<sup>1,2</sup>

Neuroretinitis affects persons of all ages, but is more commonly seen between ages 30 and 40. It's generally painless, but may include varying degrees of pain. Interestingly, about 50% of patients with



**Figs. 4 & 5. Fluorescein angiography OD (left image) and OS (right image).**

neuroretinitis will report having had a preceding viral-like illness.<sup>1</sup> As a result, for many years this condition was classified as a "post-viral neuroretinitis." The condition tends to be self-limiting, for a period of six to eight weeks.<sup>1</sup>

The clinical features of neuroretinitis include disc swelling in the presence of an exudative maculopathy that resembles a star-like pattern. The exudate may not be present during the initial stages of the disc swelling, but appears within days to weeks as the optic disc swelling begins to resolve.

Other inflammatory signs may also be present, including anterior chamber cells and flare, vitreous cells and venous sheathing. Interestingly, even though our patient reported seeing floaters, she did not have any cells in the anterior chamber or the vitreous. In addition, she had also developed a neurosensory retinal detachment as result of the extreme amount of disc swelling.

Only 5% to 10% of patients with CSD develop ocular involvement, and only about 1% to 2% develop neuroretinitis.<sup>3</sup> CSD is now recognized as the cause for the majority of neuroretinitis cases. Other infectious causes of neuroretinitis include syphilis, Lyme disease, *Leptospira*, toxoplasmosis and toxocarriasis.

The link between CSD and neuroretinitis was found thanks to advances in biomolecular labo-

ratory techniques in the 1990s, including specific serologic tests and polymerase chain reaction analyses.

Two types of serologic tests are used for the diagnosis of CSD. One is an indirect fluorescent assay specific for antibodies directed against *B. henselae*. It has a sensitivity and specificity above 90% but does not differentiate between IgM and IgG antibodies.<sup>4</sup> The other commercially available serologic test is an enzyme-linked immunoassay for both IgG and IgM anti-*B. henselae* antibodies.

Oral doxycycline 200mg BID for two to four weeks has emerged as the treatment of choice for neuroretinitis even though the disease is self-limiting, and this is what we prescribed our patient. When she returned for follow-up in two weeks, she reported a significant improvement in her symptoms. The neurosensory detachment had resolved and her acuity had improved to 20/20. By six weeks, she said she felt entirely better and her visual fields were completely normal. ■

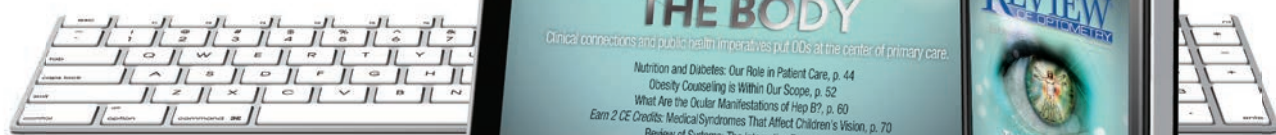
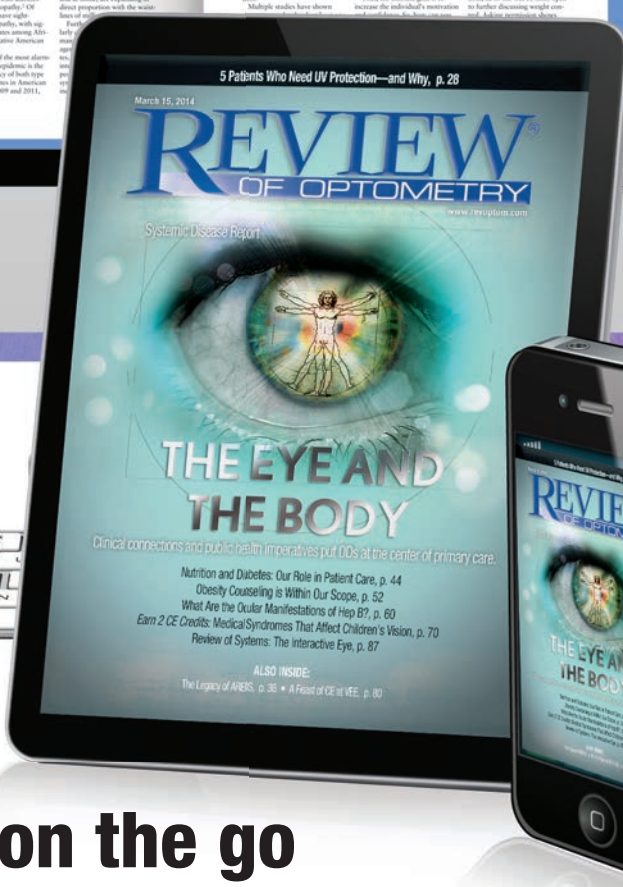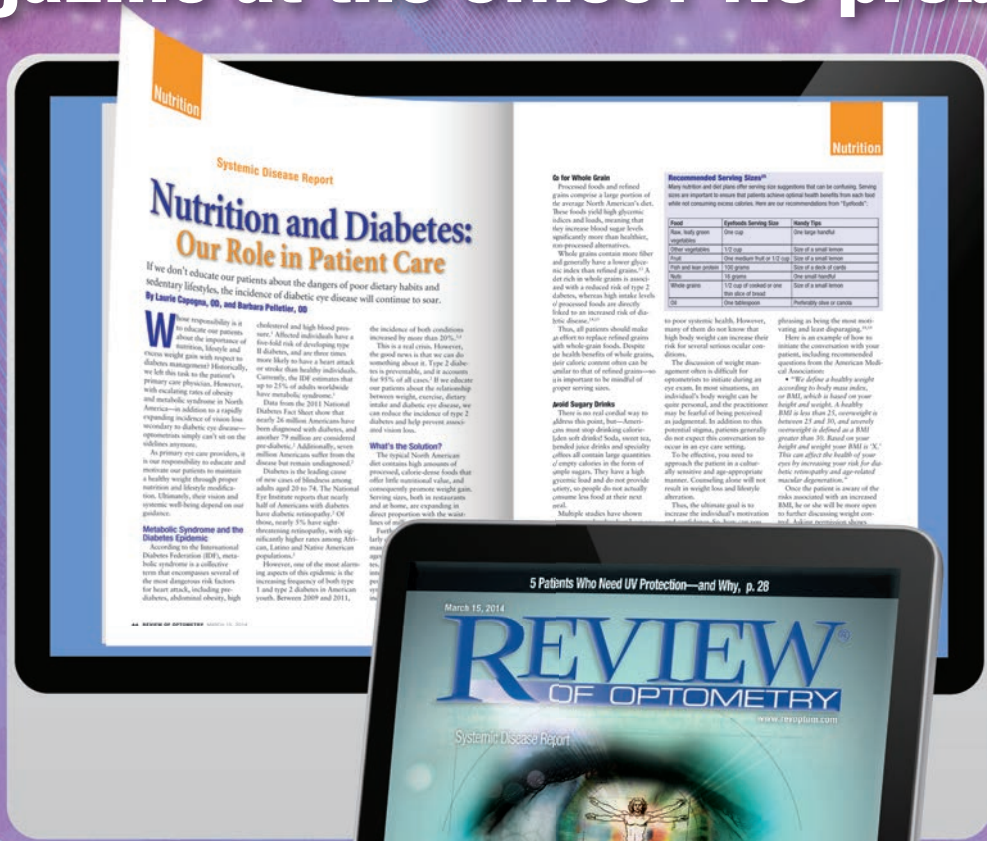1. Smith CH. Optic Neuritis. In: Walsh & Hoyt's Clinical Neuro-Ophthalmology. Miller NR, Newman NJ, eds, Vol. 1. 6th ed. Philadelphia: Lippincott Williams & Wilkins; 2005: 293-347.

2. Dreyer RF, Hopen G, Gass JDM, Smith JL. Leber's idiopathic stellate neuroretinitis. Arch Ophthalmol. 1984 Aug; 102(8):1140-5.

3. Suhler EB, Lauer AK, Rosenbaum JT. Prevalence of serologic evidence of cat scratch disease in patients with neuroretinitis. Ophthalmology. 2000 May;107(5):871-6.

4. Dalton MJ, Robinson LE, Cooper J, et al. Use of Bartonella antigens for serologic diagnosis of cat-scratch disease at a national referral center. Arch Intern Med. 1995 Aug 7-21; 155(15):1670-6.

# Left your *Review of Optometry* magazine at the office? No problem!



Read *Review* on the go from any mobile device!

Just simply go to [www.reviewofoptometry.com](http://www.reviewofoptometry.com) and click on the digimag link to get your current issue.



# Fighting Filamentary Keratitis

Don't confuse this complex condition for a more typical ocular surface disorder.

By Alan G. Kabat, OD, and Joseph W. Sowka, OD

One of the most common complaints we encounter in the clinical setting is ocular discomfort, typically in the form of dryness, irritation and foreign body sensation. These annoying symptoms are among the most pervasive and vague. While dry eye syndrome is an exceedingly prevalent diagnosis in our adult population, we must differentiate aqueous deficiency or evaporative dry eye from more complex and, potentially, refractory conditions. Filamentary keratitis is one such condition.

In this column, we'll discuss the keys to diagnosing filamentary keratitis, as well as the various treatment modalities for controlling the disorder.

## At-Risk Patients

While the exact prevalence of filamentary keratitis is unknown,<sup>1</sup> experience suggests it's more common in elderly patients, females and those with connective tissue disorders or immune deficiency.<sup>2</sup> The exact nature and severity of symptoms ranges from mild ocular discomfort to pronounced pain. Tearing, photophobia and even blepharospasm may accompany these symptoms in severe cases.<sup>3</sup>

## Associated Signs

Signs associated with filamentary keratitis include ocular hyperemia, particularly in the limbal area, as well as a pseudoptosis in some individuals. Corneo-mucus filaments are the hallmark finding. These

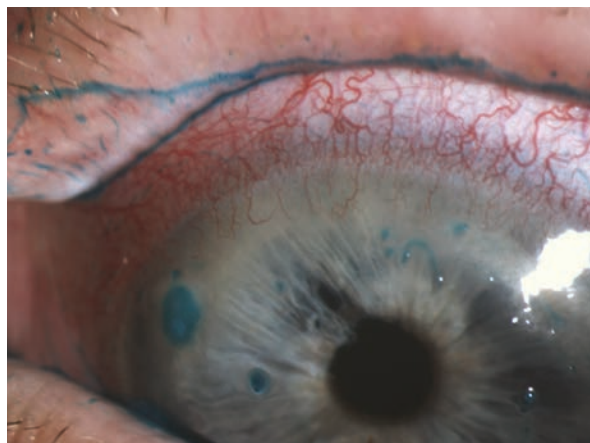usually consist of a focal "head" which may firmly adhere to compromised areas of the corneal epithelium, and a strand-like "tail" of varying length that extends across the ocular surface. Applying vital dyes, such as lissamine green, rose bengal and sodium fluorescein, can aid biomicroscopic filament

visualization.<sup>3</sup> A rapid tear breakup time and punctate epithelial keratopathy may also be present.

Not only does filamentary keratitis accompany dry eye, it also appears alongside a variety of other ocular surface disorders, including superior limbic keratoconjunctivitis, prolonged patching following ocular surgery, epitheliopathy due to aerosol or radiation keratitis, herpetic keratitis, recurrent corneal erosion, neurotrophic keratitis and bullous keratopathy.<sup>1-5</sup>

## Mechanism

Research suggests individual filaments consist of desquamated corneal epithelial cells (at their cores), surrounded primarily by degenerating conjunctival epithelial cells and entwined in a thick layer of membrane-associated mucins.<sup>4,5</sup> Patients with filamentary keratitis appear to suffer progressive dysfunction



Corneal filaments stained with lissamine green dye are evident in this red, inflamed eye.

within the basal epithelial and Bowman's layers of the cornea, leading to focal detachments at the level of the basement membrane. Under constant shear pressure from the eyelids, these corneal foci become inflamed, and sloughing of epithelial cells may ensue.<sup>6</sup> At the same time, frictional stress from blinking and eye movement combined with diminished tear volume and ocular surface inflammation results in abnormal tear mucin production and degeneration of conjunctival epithelial cells.<sup>5</sup>

These combined elements form filaments which may appear clinically as long strands, large clumps or irregular dendriform deposits, depending upon whether they are stretched, twisted or tightly coiled.<sup>4,7</sup> The filaments are motile in the tear film, but have an affinity for compromised areas of the corneal surface, where they form





strong adhesions. Lid movement across these bound filaments induces vertical traction and further shearing of the corneal epithelium with each blink, resulting in micro-trauma and stimulation of the pain-sensitive corneal nerves. Thus, a vicious cycle of epithelial damage, inflammation, filament formation and discomfort ensues.

### Management

The management of filamentary keratitis is aimed at alleviating the stressors that cause ocular surface inflammation and epithelial degradation. Elimination of the filaments is the initial step, but identifying and treating the underlying pathology is vital to breaking the cycle of this disease. Doctors can remove large filaments mechanically using fine-tipped forceps at the slit lamp

under topical anesthesia. Recognize, however, that this process can further contribute to epithelial damage and should be undertaken only by skilled and experienced clinicians. Ocular lubricants are helpful in addressing discomfort and also stabilizing the tear film in mild to moderate cases of filamentary keratitis. While some have advocated hypertonic saline,<sup>8,9</sup> we tend to prefer lipid-based artificial tears (e.g., Systane Balance or Soothe XP) based upon personal experience.<sup>10</sup>

In recalcitrant cases, topical N-acetylcysteine can help to dissolve cornea-bound mucus plaques.<sup>1</sup> This mucolytic agent is employed primarily as an oral inhalant for patients with bronchial disease (e.g. emphysema, cystic fibrosis), and hence it must be prepared by a compounding pharmacist for topical

ophthalmic use. In those patients with filamentary keratitis secondary to chronic dry eye disease, we have seen excellent results with 10% acetylcysteine eye drops used four times daily for several weeks. Other treatments for refractory cases of filamentary keratitis may include the use of bandage soft contact lenses, amniotic membrane therapy or Botox (onabotulinumtoxinA, Allergan) injection to the pretarsal orbicularis muscle.<sup>2,11</sup>

### Long-term Treatment

Addressing the underlying ocular surface disease may prove to be more challenging than temporary elimination of corneal filaments. Because an inflammatory etiology is often assumed, the use of anti-inflammatory pharmaceuticals has been widely advocated, often with

# Your own custom App

for iPhone, Android, iPad and Mobile Website!

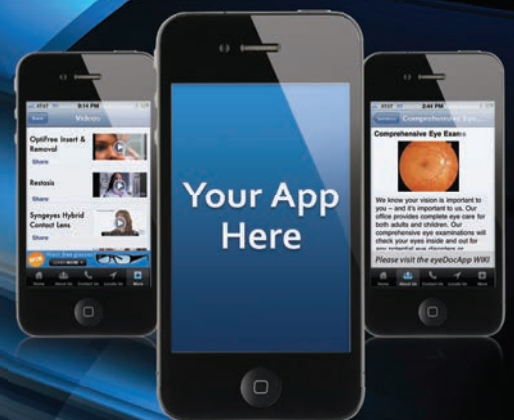**EyeDocApp** makes it easy for Individuals and Businesses to have their own custom App for iPhone, Android and iPad. Now you can use the same technology that Fortune 500 companies are using, for a fraction of the cost!

**Apps are the most powerful mobile marketing tools in the world!** Your custom App can be downloaded by anyone in the world via the iTunes and Android Marketplace. Now all your customers can have your business in their pocket, and at their fingertips. You can even send PUSH Notifications which instantly pop up on their phone, just like a text message.

Unlimited upgrades, push notifications, features and a user friendly interface –  
**All for \$49.<sup>99</sup>/month**

Learn more at [EyeDocApp.com](http://EyeDocApp.com)

EyeDocApp



Exclusively Marketed by  
  
BUSINESS SERVICES  
Understand. Manage. Grow.

# Therapeutic Review

success.<sup>12,13</sup> In those cases where dry eye disease is identified as the primary etiology of filamentary keratitis, short-term use of corticosteroids such as Lotemax (loteprednol etabonate 0.5%, Bausch + Lomb) QID combined with long-term use of Restasis (cyclosporine, Allergan) BID can help.<sup>14</sup> Severe cases may require treatment with autologous serum eye drops.<sup>15,16</sup>

Therapy for filamentary keratitis may take weeks or even months before adequate resolution is realized. Patients should understand that the underlying condition is often chronic and filaments may recur. Long-term care includes ongoing treatment for ocular surface disease with close monitoring three to four times annually. In addition, patients with chronic or severe dry eye disease may benefit

from a rheumatologic investigation to determine the presence of Sjögren's syndrome.<sup>17</sup> ■

*Dr. Kabat is a consultant for Alcon Laboratories, Bio-Tissue and BlephEx. Neither he nor Dr. Sowka have any direct financial interest in the products mentioned in this article.*

1. Albiets J, Sanfilippo P, Troutbeck R, Lenton LM. Management of filamentary keratitis associated with aqueous-deficient dry eye. *Optom Vis Sci.* 2003 Jun;80(6):420-30.
2. Gumus K, Lee S, Yen MT, Pflugfelder SC. Botulinum toxin injection for the management of refractory filamentary keratitis. *Arch Ophthalmol.* 2012 Apr;130(4):446-50.
3. Diller R, Sant S. A case report and review of filamentary keratitis. *Optometry.* 2005 Jan;76(1):30-6.
4. Tabery HM. Filamentary keratopathy: a non-contact photomicrographic in vivo study in the human cornea. *Eur J Ophthalmol.* 2003 Aug-Sep;13(7):599-605.
5. Tanioka H, Yokoi N, Komuro A, et al. Investigation of the corneal filament in filamentary keratitis. *Invest Ophthalmol Vis Sci.* 2009 Aug;50(8):3696-702.
6. Zaidman GW, Geeraets R, Paylor RR, Ferry AP. The histopathology of filamentary keratitis. *Arch Ophthalmol.* 1985 Aug;103(8):1178-81.
7. Pandit RT. Dendritic filamentary keratopathy. *Cornea.* 2009 Jan;28(1):123-5.

8. Hamilton W, Wood TO. Filamentary keratitis. *Am J Ophthalmol.* 1982 Apr;93(4):466-9.
9. Avisar R, Robinson A, Appel I, et al. Diclofenac sodium, 0.1% (Voltaren Ophtha), versus sodium chloride, 5%, in the treatment of filamentary keratitis. *Cornea.* 2000 Mar;19(2):145-7.
10. Greiner JV, Korb DR, Kabat AG, et al. Successful treatment of chronic idiopathic recurrent filamentary keratopathy using a topical oil-in-water emulsion: A report of 5 cases. Poster presented at the 25th Biennial Cornea Research Conference, Boston, MA, October 11-13, 2007.
11. Suri K, Kosker M, Raber IM, et al. Sutureless amniotic membrane ProKera for ocular surface disorders: short-term results. *Eye Contact Lens.* 2013 Sep;39(5):341-7.
12. Perry HD, Doshi-Carnevale S, Donnenfeld ED, Kornstein HS. Topical cyclosporine A 0.5% as a possible new treatment for superior limbic keratoconjunctivitis. *Ophthalmology.* 2003 Aug;110(8):1578-81.
13. Terry G, Coursey, Cintia S de Paiva. Managing Sjögren's Syndrome and non-Sjögren Syndrome dry eye with anti-inflammatory therapy. *Clin Ophthalmol.* 2014; 8: 1447-1458.
14. Sheppard JD, Donnenfeld ED, Holland EJ, et al. Effect of loteprednol etabonate 0.5% on initiation of dry eye treatment with topical cyclosporine 0.05%. *Eye Contact Lens.* 2014 Sep;40(5):289-96.
15. Jirsova K, Brejchova K, Krabcova I, et al. The application of autologous serum eye drops in severe dry eye patients; subjective and objective parameters before and after treatment. *Curr Eye Res.* 2014 Jan;39(1):21-30.
16. Hussain M, Shlein RM, Sugar A, et al. Long-term use of autologous serum 50% eye drops for the treatment of dry eye disease. *Cornea.* 2014 Dec;33(12):1245-51.
17. Shen L, Kapsogeorgou EK, Yu M, et al. Evaluation of salivary gland protein 1 antibodies in patients with primary and secondary Sjögren's syndrome. *Clin Immunol.* 2014 Nov;155(1):42-6.



 Local Eye Site  
JOBS IN EYE CARE

YOU'RE INVITED TO

LOCAL EYE SITE **LIVE!**

Eye Care's Online Career Fair

Thursday, February 19, 2015

11 AM - 2 PM & 6 PM - 9 PM EST

LIMITED  
SPACE  
REGISTER  
NOW!

REGISTER ONLINE >> [localeyesite.com/live](http://localeyesite.com/live)

SPONSORED BY







INTERNATIONAL  
**VISION  
EXPO**  
& CONFERENCE  
NEW YORK

# VISIONARIES

## IN EDUCATION, FASHION AND TECHNOLOGY

International Vision Expo integrates new technology throughout the show. Courses demonstrate how to maximize technology for better patient outcomes, and the exhibit hall offers hands-on demonstrations of the latest innovations.

Get exclusive access to next-generation technologies at the Technology Theater, Medical and Scientific Theater, and the *Vision Monday Eye<sup>2</sup> Zone*.

International Vision Expo is always enhancing its educational offerings and adding new tracks that address trending industry topics. New tracks in 2015 include Retail, in collaboration with the Accessories Council, Wearable Technology and the Ocular Wellness Program, and features spotlight sessions with topics delivered by the Ritz Carlton and other noted service experts.

International Vision Expo has created the Young Professionals Club, offering tools to jump-start your career.

Optometrists who have graduated within the past five years are invited to join. Enjoy six hours of complimentary education, free exhibit hall registration, resources to help you start a practice and networking opportunities with other young ODs.

### INTERNATIONAL VISION EXPO 2015

**EDUCATION:** THURSDAY, MARCH 19–SUNDAY, MARCH 22 **EXHIBITION:** FRIDAY, MARCH 20–SUNDAY, MARCH 22  
JAVITS CENTER | NEW YORK, NY | [VisionExpoEast.com](http://VisionExpoEast.com) | [#VisionExpo](https://twitter.com/VisionExpo)

PROUD SUPPORTER OF: **thinkabout  
youreyes**  
thinkaboutyoureyes.com  
AMERICAN OPTOMETRIC EDUCATION



By Derek N. Cunningham, OD, and Walter O. Whitley, OD, MBA



## The Secret to Surgical Success

Before tackling cataracts, make sure your patients are free of ocular surface disorders.

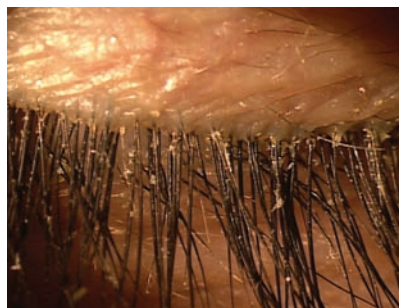
Modern cataract surgery is a highly refined procedure. Whereas previously it wasn't considered until a patient failed a driver's test or quality of life had been dramatically affected, today many patients pursue surgery as soon as they notice visual symptoms. In large part, this is due to the impact of cataracts on activities of daily living and the potential for significantly better uncorrected vision postoperatively. With safer, less invasive procedures, more reliable outcomes and IOL options that offer many post-op vision capabilities, cataract surgery is now akin to refractive surgery. Patients expect greater spectacle independence at a minimum.

The role of the OD is pivotal in achieving the best possible outcomes through careful pre-op care.

### Ocular Surface Quality

The first and most important rule is to remember that the results of any refractive surgical procedure will depend heavily on the quality of the ocular surface. Surgery should not be considered until the ocular surface is in good shape or stabilized with treatment. A compromised ocular surface will limit patients' intraocular lens options. Ocular surface disease will increase the risk of surgical complications, affect IOL measurements (e.g., biometry, keratometry) and impact patient comfort and quality of vision.

Accurate keratometry readings are critical for refractive success—these measurements become highly variable in a patient with a poor ocular surface. Preoperative ocular



**Untreated blepharitis could diminish the outcome of an otherwise routine cataract surgery. Be sure to treat it preoperatively.**

surface issues that could affect surgery include the following:

- **Blepharitis.** For a condition that is among the most significant causes of postoperative symptoms, blepharitis is still routinely overlooked.<sup>1</sup> Explain to these patients that they have a chronic condition that will need to be treated before surgery.

Treat any amount of lid margin inflammation or gland secretion turbidity. Preoperative treatments may include combination antibiotic/steroid drops, topical azithromycin and oral tetracycline analogs along with lipid-based tear supplements. Long-term management includes pulse-dosing steroids, warm compresses and lid scrubs, low-dose tetracycline analogs and oral omega-3 supplementation.

- **Dry eye.** There's no question that moderate to severe dry eye is a contraindication to refractive surgery, but for many patients even mild dry eye warrants attention, as it is often unavoidable. For at-risk patients such as women and those of advanced age, begin prophylactic pharmacological treatment (such as topical anti-inflammatories) in

addition to omega-3 and artificial tears. This will also hold true for asymptomatic patients with low tear prism height and anyone with mild superficial punctate corneal staining. Topical steroids can speed healing preoperatively, but are typically not used long term after surgery. For chronic dry eye, cyclosporine, nutraceuticals and punctal occlusion may be necessary.

- **Allergy.** Although allergic conjunctivitis patients typically control symptoms with an antihistamine/mast cell stabilizer eye drop, treating ocular allergy with topical corticosteroids in the perioperative period should be considered. Steroids will shut down the entire inflammatory cascade, creating a better environment for surgery and ensuring good control of moderate allergy. In the immediate postoperative period, antihistamine drops are then initiated based on need.

### Treat Early, Treat Often

A poor tear film will decrease contrast sensitivity and lead to inconsistent vision.<sup>2</sup> Attempting to only begin treatment postoperatively can be a fruitless task because of neuropathy-related decreased tear production.

Running into just a couple of these problem patients after surgery will forever change your attitude about treating any amount of pre-existing ocular surface disease. ■

1. Levinson BA, Rapuano CJ, Cohen EJ, et al. Referrals to the Wills Eye Institute Cornea Service after laser in situ keratomileusis: reasons for patient dissatisfaction. *J Cataract Refract Surg.* 2008 Jan;34(1):32-9.

2. Huang FC, Tseng SH, Shih, MH, Chen FK. Effect of artificial tears on corneal surface regularity, contrast sensitivity, and glare disability in dry eyes. *Ophthalmology.* 2002 Oct;109(10):1934-40.



# WEARABLE TECH ONLY AT VISION EXPO

OVER 15 VISIONARY COMPANIES SHOWCASE NEW, NON-TRADITIONAL VISION TECHNOLOGIES – THE FUTURE YOU CAN'T AFFORD TO IGNORE

- Unique opportunity to learn about new non-traditional vision technologies hitting the markets.
- Be in a better position to advise patients on overall visual needs after testing products that enhance vision or athletic performance, communicate or view media, measure and monitor biometric data, promote wellness and more.
- See vision-related products for consumers that we know will eventually end up in the chairs of eyecare professionals.

## TECHNOLOGY THEATER



The Technology Theater is your destination for dynamic programming delivered in a stimulating environment. Take the Retail and Wearable Technology Track courses here or catch a Tech Talk from exhibitors in the exciting *Vision Monday Eye<sup>2</sup> Zone*.

LOCATED IN THE LENSES AND PROCESSING TECHNOLOGY PAVILION

### FRIDAY MARCH 20 | RETAIL TRACK = 6 HOURS

In Collaboration with: Accessories Council | Exclusive Media Partner: *2020 Magazine*

- 22B2—10 Things You Can Do Today to Wow Tomorrow **SPEAKER: FRANCES COLE JONES**
- 23B2—Inside the Mind of Today's Changing Consumer **SPEAKER: CAROLYN COHEN FROM NPD GROUP**
- 24B2—Navigating New Technology — Real-Life Implementation and Implications **SPEAKER: DAVID JACOBY**
- 25B2—Trends — Fads — Reality: What's Next? **SPEAKER: SYL TANG**
- 26B2—The Scoop — What's Going On in Retail That You Can't Afford to Miss Out On! **SPEAKER: KAREN GIBERSON**
- 27B2—The Art of Customer Service and the Science of Hitting Your Numbers! **SPEAKER: PETE KRAINIK**

### SATURDAY, MARCH 21 | WEARABLE TECHNOLOGY TRACK = 4 HOURS

Exclusive Media Partner: *Vision Monday*

- 3103 — The Glass Class **MODERATOR: KEVIN WHEAT**
- 3203 — The Future of Digital Vision and Wearable Technology **SPEAKER: BRAD MAIN, TIM MOORE**
- 3403 — Eye<sup>2</sup>: What You Need to Know About Eyewear and Eyecare's Pivotal New Role in Wearable Technology **SPEAKER: ANDREW KARP**
- 3503 — The Digital Generation — Wired and Blurry! **SPEAKER: JOE CROFT**

REGISTER TODAY AT [VisionExpoEast.com/R00](http://VisionExpoEast.com/R00)



## INTERNATIONAL VISION EXPO 2015

EDUCATION: THURSDAY, MARCH 19–SUNDAY, MARCH 22

EXHIBITION: FRIDAY, MARCH 20–SUNDAY, MARCH 22

JAVITS CENTER | NEW YORK, NY | [VisionExpoEast.com](http://VisionExpoEast.com) | [#VisionExpo](https://twitter.com/VisionExpo)

PROUD SUPPORTER OF:



BRANDED BY THE AOA  
AMERICAN OPTOMETRIC ASSOCIATION



DOWNLOAD LAYAR APP FOR INTERACTIVE EXPERIENCE



First 150 app downloads and completed forms will be entered into a drawing for FREE MEETING AND REGISTRATION VALUED AT \$495

**New Technologies and Treatments**

**IN VISION CARE 2015**

**REVIEW OF OPTOMETRY**  
EDUCATIONAL MEETINGS OF CLINICAL EXCELLENCE

**PAUL KARPECKI, OD**  
PROGRAM CHAIR


**REGISTRATION OPEN**



**SAN DIEGO, CA**  
**APRIL 10-12**



**CHARLESTON, SC**  
**JUNE 12-14**



**MAUI, HI\***  
**JULY 23-26**



**PHILADELPHIA, PA**  
**NOVEMBER 6-8**

**NEW** Includes hands-on workshop

**Up to 17 CE Credits**  
(COPE approval pending)

For more information visit [www.reviewofoptometry.com](http://www.reviewofoptometry.com)



\* Workshops not available - See website for information about snorkeling catamaran activity



# Product Review

## Practice Management

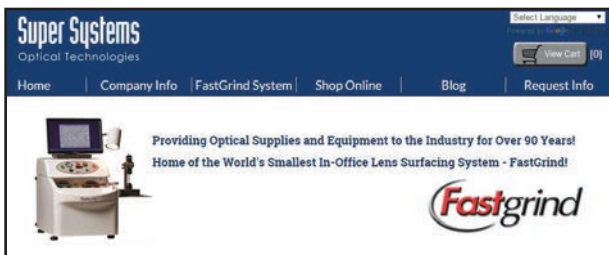### Business Analytics Software

New analytical software called Inzuzo offers a real-time look at various dynamics of a specific practice and how they compare to those of other practices, according to Inzuzo makers The Power Practice, working in cooperation with Glimpse. Practice owners can use this information to improve day-to-day business operations through access to real-time data on performance metrics, according to the company.

Visit [www.powerpractice.com](http://www.powerpractice.com)

### Super Systems Optical Technologies Website

Super Systems Optical Technologies has launched a new website that the company says embraces a stronger digital presence, with an easy-to-navigate look and a robust shopping experience for lab equipment and supplies.



The site's main feature is its FastGrind system, an "all-in-one" modified lens surfacing system that functions on continually upgraded software to accommodate the newest lenses. The company aims to make use of its FastGrind system easier with an enhanced customer login page. With tap water, electric and minimal training, FastGrind owners can be up and running in the same day ready to make lenses, according to the company.

Visit [www.superoptical.com](http://www.superoptical.com)

## Contact Lenses

### Astigmatic Hybrid Lenses with More Parameters

The Duette HD daily wear contact lens now features a greater range of possible parameters for better alignment, fitting and centration, says SynergEyes.

Practitioners can customize the hybrid lenses for astigmatic patients with base curves from 7.1mm to 8.3mm in 0.1mm increments and lens powers from +10.00 to -15.00. The lens features an 84 DK silicone hydrogel skirt and 130 DK RGP center, which provides both UVA and UVB protection.

In conjunction with this release, SynergEyes has also announced seven new video tutorials for Duette.

Visit [www.synergieyes.com](http://www.synergieyes.com)

## Glaucoma

### Corneal Hysteresis CPT Code

A specially designated CPT code went into effect last month for corneal hysteresis, a measurement provided by the Ocular Response Analyzer, according to the device's parent company Reichert. Corneal hysteresis is an indication of corneal biomechanical properties.

Low corneal hysteresis is considered a risk factor for glaucoma progression, Reichert says.

The test has now achieved Category I status, as the clinical utility was established and usage has grown since 2007, when the Category III code was implemented.

The new Category I CPT code, 92145 (Corneal hysteresis determination, by air impulse stimulation, unilateral or bilateral, with interpretation and report), replaces the prior code, 0181T.

Visit [www.reichert.com](http://www.reichert.com)



## Lid Hygiene

### An adjunct to Lid Scrub Use

A new formulation, available as either a spray or a gel, is designed to supplement existing eyelid cleansers for severe cases of dry eye and blepharitis, according to manufacturer Ocusoft.

HypoChlor, a 0.02% concentration of hypochlorous acid, is suggested to be used in combination with surfactant cleaners for daily lid hygiene, to dissolve and remove oil, scales, debris and desquamated skin, which can lead to conditions such as anterior blepharitis, according to the company.

Visit [www.ocusoft.com](http://www.ocusoft.com)

### Lid Hygienist Certification

A recently launched lid hygienist program aims to educate and certify eye care technicians who wish to obtain certification in the patient management and treatment protocols associated with the BlephEx microblepharoxfoliation delivery device for the treatment of blepharitis, according to BlephEx maker Rysurg.

The BlephEx is designed to remove excess oil, debris and inflammation-promoting biofilm from the eyelid margins. The certification is geared toward technicians, but the company adds it can apply to doctors who desire more thorough, hands-on instruction.

Visit [www.rysurg.com](http://www.rysurg.com)

## February 2015

■ **6-8.** *2015 PBCOA Winter Seminar.* PGA National Resort & Spa, Palm Beach Gardens, FL. Hosted by: Palm Beach County Optometric Association. CE hours: 20. Key faculty: Carl Pelino, OD and Kimberly Reed, OD. To register, go to: [www.pbcoa.org](http://www.pbcoa.org).

■ **7-8.** *Destination CE.* Crowne Plaza Hotel, New Orleans, LA. Hosted by: Southern College of Optometry. CE Hours: 12. Key Faculty: Michael Gerstner, OD, FAAO; Whitney Hauser, OD; Mike Dorkowski, OD, FAAO; John Rumpakis, OD, MBA. To register, call 800-238-0180, ext. 5, or email [ce@sco.edu](mailto:ce@sco.edu).

■ **13-15.** *54th Annual Contact Lens and Primary Care Congress.* Sheraton Kansas City Hotel at Crown Center. Kansas City, Mo. Hosted by: Heart of America Contact Lens Society. To register, go to [www.hoacis.org](http://www.hoacis.org).

■ **13-17.** *Ski Vision 2015.* Westin Snowmass Luxury Resort. Snowmass Village, Co. Hosted by: AAO and UABSO. CE hours: 20. Key faculty: Murray Fingeret, OD, Leo Semes, OD, Jack Schaeffer, OD, Jack Cioffi, MD, David Friedman, MD, PhD, and more. To register, go to <http://skivision.com>.

■ **19-22.** *115th TOA Annual Convention.* Downtown Austin Hilton Hotel, Austin. Hosted by: Texas Optometric Association. CE hours: 27. Key faculty: Ian Ben Gaddie, OD, FAAO, Steven Ferucci, OD, FAAO and Diana Shechtman, OD, FAAO. To register, call Sherry Balance at (512) 707-2020 or email [sherry@txeyedoctors.com](mailto:sherry@txeyedoctors.com).

■ **20-21.** *2015 Winter Conference.* Grand Summit Hotel Sugarloaf, USA, Carrabassett Valley, ME. Hosted by: Maine Optometric Association. To register, call (207) 237-2000.

■ **26-28.** *Montana Optometric Association Winter Education Symposium Big Sky 2015.* Big Sky Resort, Big Sky, MT. Hosted by: Montana Optometric Association. CE hours: 13. Key faculty: Bruce Onofrey, OD, RPH, FAAO, FOGS; Curtis R. Baxstrom, OD. To register, go to [www.mteyes.com](http://www.mteyes.com).

## March 2015

■ **4-8.** *SECO 2015.* Georgia World Congress Center, Atlanta, Ga. Hosted by: SECO. To register, go to: [www.seco2015.com](http://www.seco2015.com).

■ **20-22.** *Vision Expo East.* Jacob K. Javits Convention Center. New York, New York. Hosted by: International Vision Expo and Conference. To register, go to [www.visionexpoeast.com](http://www.visionexpoeast.com).

■ **26-28.** *OAOP Vision Summit.* Embassy Suites Hotel and Conference Center. Norman, OK. Hosted by: Oklahoma Association of Optometric Physicians. CE hours: 18. To register, go to [www.aoop.org](http://www.aoop.org).

## April 2015

■ **15-17.** *World Cornea Congress VII.* San Diego Convention

Center, San Diego, CA. Hosted by: ASCRS. To register, go to: <http://corneacongress.org>.

■ **17-19.** *NOA Spring Conference-CE Event.* Embassy Suites, Lincoln, NE. Hosted by: Nebraska Optometric Association. To register, call Alissa Johnson, CAE, at (402) 474-7716 or email [ajohnson@assocoffice.net](mailto:ajohnson@assocoffice.net).

■ **18-19.** *Miami Nice Educational Symposium 2015.* Westin Colonnade, Coral Gables, FL. Hosted by: Miami-Dade Optometric Physicians Association. CE Hours: 17 COPE-approved, 12 transcript quality. Key Faculty: Ken Lebow, OD; John McGreal, OD; Carl Spear, OD; Al Morier, OD; John McClane, OD; Albert Woods, OD. To register, go to [www.miami-eyes.org](http://www.miami-eyes.org), call Steve Morris at (305) 342-5473 or email [mdopa.board@gmail.com](mailto:mdopa.board@gmail.com).

■ **17-22.** *ASCRS-ASOA Symposium and Congress 2015.* San Diego Convention Center, San Diego, CA. Hosted by: ASCRS/ASOA. To register, go to: <http://annualmeeting.ascrs.org/>

■ **22-26.** *13th Annual Educational Conference.* Hilton Embassy Suites at Kingston Plantation, Myrtle Beach, SC. Hosted by: American Academy of Optometry New Jersey Chapter. CE Hours: 16. Key Faculty: Mark Friedberg, MD; Alan Kabat, OD, FAAO. To register, call Dennis H. Lyons, OD, FAAO at (732) 920-0110 or email [dhl2020@aol.com](mailto:dhl2020@aol.com).

■ **23-25.** *Mountain West Council of Optometrists (MWCO) Annual Congress.* Bally's, Las Vegas, NV. Hosted by: Mountain West Council of Optometrists. CE Hours: 24. To register, visit [www.mwco.org](http://www.mwco.org) or call 1-888-376-6926.

■ **23-26.** *2015 Annual Spring Convention.* Marriott Hotel & Little Rock Convention Center, Little Rock, AR. Hosted by: Arkansas Optometric Association. To register, email Vicki Farmer at [vicki@arkansasoptometric.org](mailto:vicki@arkansasoptometric.org).

■ **29-May 7.** *Annual Educational Conference and Exposition.* Red Lion Colonial Hotel, Helena, MT. Hosted by: Montana Optometric Association. To register, call (406) 443-1160 or email [sweingartner@rmsmanagement.com](mailto:sweingartner@rmsmanagement.com).

■ **30-May 1.** *Spring 2015 Convention.* Pierre Ramkota, Pierre, South Dakota. Hosted by: South Dakota Optometric Society. To register, email Deb Mortenson at [deb.mortenson@pie.midco.net](mailto:deb.mortenson@pie.midco.net).

## May 2015

■ **2-3.** *8th Annual Evidence Based Care in Optometry Conference.* Turf Valley Conference Center and Resort, Ellicott City, MD. Hosted by: Maryland Optometric Association & John Hopkins-Wilmer Eye Institute. To register, call Annie Phan at (410) 486-9662 or email [aphan@mary-landoptometry.org](mailto:aphan@mary-landoptometry.org).

■ **3.** *OptoWest Regional Conference.* Anaheim Marriott Suites, Anaheim, CA. Hosted by: California Optometric Association. CE Hours: 6. Key Faculty: Steven Ferrucci, OD, Bruce Onofrey, OD,

# Advertisers Index

For advertising opportunities contact:

Michele Barrett (215) 519-1414 or [mbarrett@jobson.com](mailto:mbarrett@jobson.com)

James Henne (610) 492-1017 or [jhenne@jobson.com](mailto:jhenne@jobson.com)

Michael Hoster (610) 492-1028 or [mhoster@jobson.com](mailto:mhoster@jobson.com)

Mary Schmidt, OD. To register, go to [www.optowest.com](http://www.optowest.com), call Sarah Harbin at (916) 266-5022 or email [sharbin@coavision.org](mailto:sharbin@coavision.org).

■ **3.** *NECO Sunday Seminar Series CE.* New England College of Optometry, Boston, MA. Hosted by: New England College of Optometry Alumni Association. CE Hours: 5. Key Faculty: Mark Dunbar, OD, Michael Springer, OD. To register, go to [www.neco.edu/academics/continuing-education/sunday-series](http://www.neco.edu/academics/continuing-education/sunday-series), call Margery Warren at (617) 587-5687 or email [ce@neco.edu](mailto:ce@neco.edu).

■ **3-5.** *CE in Italy.* Hotel Silla, Florence, Italy. Hosted by James Fanelli, OD. CE Hours: 12. Key Faculty: James Fanelli, OD, Carlo Pelino, OD. To register, go to [www.CEinItaly.com](http://www.CEinItaly.com), call James Fanelli, OD, at (910) 452-7225 or email [jamesfanelli@CEinItaly.com](mailto:jamesfanelli@CEinItaly.com).

■ **3-7.** *ARVO 2015.* Colorado Convention Center, Denver, CO. Hosted by: The Association for Research in Vision and Ophthalmology. For information and registration, go to [www.arvo.org/Annual\\_Meeting](http://www.arvo.org/Annual_Meeting).

■ **7-9.** *CE in Italy.* Palazzo Al Valabro, Rome, Italy. Hosted by James Fanelli, OD. CE Hours: 12. Key Faculty: James Fanelli, OD, Carlo Pelino, OD, Joseph Pizzimenti, OD. To register, go to [www.CEinItaly.com](http://www.CEinItaly.com), call James Fanelli, OD, at (910) 452-7225 or email [jamesfanelli@CEinItaly.com](mailto:jamesfanelli@CEinItaly.com).

■ **15-17.** *Arizona Optometric Association 2015 Spring Congress.* Hilton Tucson El Conquistador Golf & Tennis Resort, Tucson, AZ. Hosted by: Arizona Optometric Association. To register, go to: <http://arizona.aoa.org>.

## June 2015

■ **5-7.** *June "Summer" Conference.* Harborside Hotel & Marina, Bar Harbor, ME. Hosted by: Maine Optometric Association. To register, call (207) 288-5033 or toll-free 800-328-5033.

■ **12-14.** *2015 Annual Meeting.* Myrtle Beach, SC. Hosted by: North Carolina State Optometric Society. To register, call Adrienne Drollette at (919) 977-6964 or email [adrienne@nceyes.org](mailto:adrienne@nceyes.org).

■ **19-21.** *2015 VOA Annual Conference.* Hilton, McLean, VA. Hosted by: Virginia Optometric Association. To register, call Bo Keeney at (804) 643-0309.

■ **24-28.** *Optometry's Meeting 2015.* Washington State Convention Center, Seattle, WA. Hosted by: American Optometric Association and American Optometric Student Association. To register, go to: <http://optometrymeeting.org>.

### To list your meeting, please send the details to:

Jack Persico, Editor-in-Chief

Email: [jpersico@jobson.com](mailto:jpersico@jobson.com)

Phone: (610) 492-1006

<b>Alcon Laboratories</b> ..... 23, 24 ..... 47, 48, 97, 124 Phone ..... (800) 451-3937 Fax..... (817) 551-4352	<b>M&amp;S Technologies</b> ..... 37 Phone ..... (877) 225-6101 Fax..... (847) 763-9170
<b>Allergan, Inc.</b> .... 7, 8, 29, 69, 70 Phone ..... (800) 347-4500	<b>MediNiche</b> ..... 10 Phone ..... (888) 325-2395 info@mediniche.com www.mediniche.com
<b>Bausch + Lomb</b> ..... 13 ..... 18 A-H, 51, 123 Phone ..... (800) 323-0000 Fax..... (813) 975-7762	<b>Menicon</b> ..... 57 Phone ..... (800) MENICON information@menicon.com www.meniconamerica.com
<b>Carl Zeiss Meditec Inc.</b> ..... 35 Phone ..... (877) 486-7473 Fax..... (925) 557-4101	<b>NovaBay Pharmaceuticals, Inc.</b> ..... 15 Phone ..... (800) 890-0329 sales@avenova.com www.avenova.com
<b>Coburn Technologies</b> ..... 45 Phone ..... (800) 262-8761 www.coburntechnologies.com	<b>Reichert Technologies</b> ..... 21 Phone ..... (888) 849-8955 Fax..... (716) 686-4545 www.reichert.com
<b>CooperVision</b> ..... 17, 65 Phone ..... (800) 341-2020	<b>Reliance Medical</b> ..... 67 Phone ..... (800) 735-0357 Fax..... (513) 398-0256
<b>Haag-Streit</b> ..... 31 Phone ..... (800) 627-6286 Fax..... (603) 742-7217	<b>ThromboGenics Inc.</b> ..... 5 Phone ..... (732) 590-2901 Fax..... (866) 936-6676
<b>HAI Laboratories</b> ..... 59 Phone ..... (781) 862-9884 Fax..... (781) 860-7722	<b>Tomey</b> ..... 14 Phone ..... (888) 449-4045 www.tomeyusa.com
<b>Icare USA</b> ..... 43 Phone ..... (888) 389-4022 www.icare-usa.com	<b>Vision Source</b> ..... 63 Phone ..... (281) 312-1111 Fax..... (281) 312-1153 www.visionsource.com
<b>Keeler Instruments</b> ..... 27 Phone ..... (800) 523-5620 Fax..... (610) 353-7814	<b>Lombart Instruments</b> ..... 61 Phone ..... (800) 446-8092 Fax..... (757) 855-1232
<b>Lacrivera</b> ..... 39 Phone ..... (855) 857-0518 www.lacrivera.com	<b>Vistakon</b> ..... 2-3 Phone ..... (800) 874-5278 Fax..... (904) 443-1252

This advertiser index is published as a convenience and not as part of the advertising contract. Every care will be taken to index correctly. No allowance will be made for errors due to spelling, incorrect page number, or failure to insert.



Up to  
**12 CE**  
Credits\*

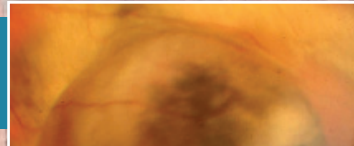
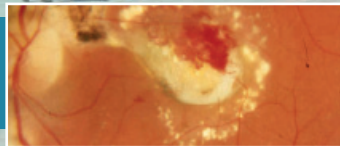
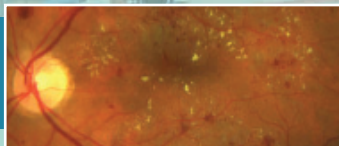
**SAVE THE DATE:**  
**DECEMBER 4-5, 2015**  
**ANAHEIM, CA**

**THE OPTOMETRIC RETINA SOCIETY  
AND *REVIEW OF OPTOMETRY* PRESENT:**

**RETINA  
UPDATE 2015**



**ANAHEIM, CALIFORNIA**



## **ORS Mission Statement**

“The mission of the Optometric Retina Society (ORS) is to promote the advancement of vitreoretinal knowledge for clinicians, ophthalmic educators, residents, and students. The ORS is dedicated to posterior segment disease prevention, diagnosis, management and comanagement.”

## **Registration Information Coming Soon!**

### **For Additional Information**

**Contact:**

Lois DiDomenico

**Email:**

[ReviewMeetings@Jobson.com](mailto:ReviewMeetings@Jobson.com)

### **Course Topics**

- Nutrition and Genetics in Retinal Wellness
- New Paradigms in Retinal Vascular Disease
- Vitreoretinal Grand Rounds
- Medical and Surgical Retina Update
- Macular Holes and Epiretinal Membranes
- What's New in Retinal Imaging

Stock Image: ©iStock.com/JobsonHealthcare

Administered by

***Review of Optometry***




\*Approval Pending

**Merchandise Offered**

**EYEDESIGNS**  
 BUILDING YOU A BETTER BUSINESS

SPACE PLANNING  
 INTERIOR DESIGN  
 DISPLAY INNOVATION  
 MANUFACTURING

WWW.EYEDESIGNS.COM  
 800.346.8890



**FREE GIFT** for the first 25 people to contact us.  
 Ref code OPT0215 exp. 02/28/15

VISION EXPO 4741  
 SECO2015 1319



FORM  
FUNCTION

Style

opticaldisplays.com™

INFO@OPTICALDISPLAYS.COM TO REQUEST OUR CATALOG & DESIGN SERVICES CALL 610.489.7620  
**FREE GIFT** for the first 25 people to contact us. Ref code: OPT0215 exp. 02/28/15

VISION EXPO 4741  
 SECO2015 1319

**Contact Lenses**

# National Lens

America's Leading Discount Lens Distributer  
 1-866-923-5600 Phone • 1-866-923-5601 Fax • www.national-lens.com

2015	LOW	LOWER	LOWEST	2015	LOW	LOWER	LOWEST
<b>Color</b>	<b>1 to 5</b>	<b>6 to 10</b>	<b>11 &amp; Over</b>	<b>Bausch &amp; Lomb</b>	<b>1 to 5</b>	<b>6 to 10</b>	<b>11 &amp; Over</b>
IMPRESSIONS COLOR <i>Available in Rx!</i>	23.95	22.95	21.95	PUREVISION / PUREVISION HD	27.50	26.95	25.95
<b>Alcon</b>	<b>1 to 5</b>	<b>6 to 10</b>	<b>11 &amp; Over</b>	SOFLENS 38	14.50	13.95	13.50
AIR OPTIX AQUA	25.75	24.95	22.95	SOFLENS ONE DAY 90 PACK	33.50	32.50	29.95
AIR OPTIX FOR ASTIGMATISM	36.50	35.95	33.95	SOFLENS 59	9.25	8.95	8.75
AIR OPTIX MULTIFOCAL	42.95	42.50	41.95	BIOTRUE 90 PACK	46.95	45.95	44.95
AIR OPTIX NIGHT & DAY AQUA	41.25	39.95	38.95	ULTRA	36.50	35.50	35.00
DAILIES AQUA COMFORT PLUS 90 PACK	37.95	36.95	35.50	<b>CooperVision</b>	<b>1 to 5</b>	<b>6 to 10</b>	<b>11 &amp; Over</b>
O2 OPTIX	16.50	16.25	15.95	AVAIRA	17.25	16.95	14.95
FRESHLOOK COLORBLENDS 2 PACK	10.50	9.75	9.25	BIOFINITY	24.50	22.50	20.50
FRESHLOOK 1 DAY COLORS-PLANO ONLY	10.95	10.50	9.95	BIOFINITY TORIC	36.00	34.00	32.00
<b>Johnson &amp; Johnson</b>	<b>1 to 5</b>	<b>6 to 10</b>	<b>11 &amp; Over</b>	BIOMEDICS XC, 38% & 55%	15.95	13.95	12.50
ACUVUE OASYS	21.50	20.95	19.95	BIOMEDICS PREMIER	15.95	13.95	13.50
ACUVUE OASYS FOR ASTIGMATISM	24.95	24.75	23.95	EXPRESSION OPAQUE-PLANO	25.95	24.95	23.95
ACUVUE 2	16.00	15.75	15.50	FREQUENCY 55% & ASPHERICS	14.95	13.95	11.95
ACUVUE ADVANCE	18.25	17.75	17.50	PROCLEAR 8.6 & 8.2	19.95	18.95	17.95
ACUVUE 1 DAY MOIST 30 PACK	18.95	18.50	17.95	PROCLEAR 1 DAY 90 PACK	37.95	37.50	35.95
ACUVUE 1 DAY MOIST 90 PACK	41.95	40.95	39.90				

Please call for prices on Ophthalmic Lenses

Please call for a full product and price list

**We'll Meet or Beat Any Competitors Price on Any Stock Lens**  
 Free Standard Shipping (when available) • Same Day Shipping • We Do Not Backorder Lenses



Merchandise Offered



**INNOVATIVE DISPENSARY  
PLANNING & DESIGN**

**WIDEST SELECTION ON  
PREMIUM DISPLAY PRODUCTS**

**0% FINANCING FOR 36 MONTHS\***

\* for well qualified applicants only

ESSILOR'S FRAME DISPLAYS GROUP  
Innovative Dispensary Planning & Design  
– Authentic Craftsmanship & Integrity

Visit the website to view examples of what Frame Displays can create for you, and schedule a free consultation with one of the design professionals.

**1-877-274-9300**



Equipment and Supplies

Superior Quality • Competitive Pricing • Worldwide Shipping

www. **GuldenOphthalmics** .com

**NEW PRODUCT: Kid's Universal Glasses Patch**

- The Patch is designed to fit over a child's eyeglasses
- The Patch can be used to occlude the right OR left eye
- The Patch occludes central AND peripheral vision
  - Designs for Boys and Girls
  - NO adhesive



**ORDER NOW ONLINE  
OR BY PHONE (215-884-8105)**



Gulden's **New** and **Innovative** Products are  
Proudly Made in the U.S.A.



It's What the Best  
Pretest on!  
**(800) 522-2275**  
www.optinomics.com  
sales@optinomics.com



Targeting Optometrists?

**CLASSIFIED ADVERTISING WORKS**

Contact us today for classified advertising:

Toll free: 888.498.1460 • E-mail: sales@kerhgroup.com





**Storage and Design**



Milan, Italy  
Feb 28 - Mar 2  
Hall 3 / Booth B27 C32

**SECO2015**

Atlanta, Ga  
March 4 - 8  
Booth 1053



New York, NY  
March 20 - 22  
Booth 3367

**.presenta nova**<sup>®</sup>  
interior & product design

Planning  
Design  
Production  
Installation



**Presenta Nova Inc.**

475 Park Avenue South  
New York City, NY 10016

p +1 888 959 1471  
f +1 888 959 1471

info@presenta-nova.com  
www.presenta-nova.com



European  
Design

**REVIEW**<sup>®</sup>  
OF OPTOMETRY

Do you have  
CE Programs?

**CLASSIFIED  
ADVERTISING  
WORKS**

Contact us today for  
classified advertising:

Toll free: **888-498-1460**

E-mail: [sales@kerhgroup.com](mailto:sales@kerhgroup.com)



**Software**

*Take a closer look...*  
**at EyeCom for your  
electronic health record needs!**

tablet compliant  
share patient data securely  
over 25 years experience  
cloud-based access anytime, anywhere

**EyeCom<sup>3</sup> EHR**  
WEB-BASED OPTOMETRIC SOFTWARE

800.788.3356 [www.eyecom3.com](http://www.eyecom3.com)

Continuing Education


In Partnership With The NJ Society of Optometric Physicians

## Alaska Glacier Bay Cruise

Norwegian Pearl - Freestyle Cruising - July 26, 2015 - August 02, 2015

**Special Offer - Choose: Unlimited Drinks, Ultimate Dining Package or \$200 Onboard Credit**


Deluxe Ship



16 CE

Celebrating 20 years

Special Group Pricing



Dr. TRAVEL, LLC  
is a COPE approved provider

Continuing Education

Getting Comfortable with Retinal Care: An Optometric View - D. Sheckman, OD, FFAO

Additional Seminar Cruises (12-16 CE):

Northern European Capitals - June 26 - July 5, 2015 - Randall Tomas, OD, MPH, FFAO

Christmas New Year's Week Cruise - NCL Sprit - Dec. 26, 2015 - Jan. 2, 2016

Royal Caribbean's Oasis of the Seas - Feb 13 - 20, 2016

Danube River Cruise - July 2016 - Ron Melton, OD, FFAO - Reserve Now!

**www.DrTravel.com                      800-436-1028**

EAGLE EYE  
SEMINARS

JULY 18-25, 2015  
Erik Schmidt OD, FFAO

JULY 16-23, 2016  
Nathan Lighthizer OD, FFAO

**WORLD CLASS MUSKY,  
WALLEYE, SMALLMOUTH  
FISHING**

- Eagle Lake Island lodge
- Eagle Lake Ontario
- 12 hours of CE

**Contact Dean Springer OD**  
[SPRINGEREYE@CHIBARDUN.NET](mailto:SPRINGEREYE@CHIBARDUN.NET)  
**Phone: 715-637-2020**

Products and Services



The key to making Professional Healthcare Practice Financing simple. Whether you are buying, starting, or updating your practice, Access Healthcare capital is here to help you with your financing needs with one common goal. We want to help you maximize your cash flow. Let us help you unleash your Entrepreneurial Spirit:

**Easy App Up To \$250,000**

- 100% Financing plus working capital
- Terms up to 15 years
- Simplified Processing for loans up to \$350,000
- Application Only for equipment and technology purchases
- Partnership Buy-In Programs

[www.accesshealthcarecapital.com](http://www.accesshealthcarecapital.com) • [info@narxeye.com](mailto:info@narxeye.com)

Access Healthcare Capital • 1-888-727-4470 • P.O. Box 349, Gladwyne, PA 19035

Conference

## Become Board Certified by the American Board of Optometry

Exam is held each January & July.

Apply today at

[americanboardofoptometry.org](http://americanboardofoptometry.org)



Program certified by the National Commission for Certifying Agencies

Continuing Medical Education

American Academy of Optometry  
New Jersey Chapter  
*13th Annual Educational Conference*  
April 22-26, 2015  
Myrtle Beach, South Carolina  
Hilton Embassy Suites at Kingston Plantation



Dr. Mark Friedberg, M.D.  
Founding Editor of the  
Wills Eye Manual

Dr. Alan Kabat, OD., F.A.A.O.

**16 HOURS  
COPE CE**

**Registration: \$475.00**  
One, Two or Three Bedroom Suites  
Accommodations Include a Daily Breakfast Buffet and Evening Cocktail Reception  
**PACK YOUR CLUBS!**  
*Golf details to follow.*

For Accommodation and Additional Information, contact:  
**Dennis H. Lyons, OD, F.A.A.O.**  
Phone: (732) 920-0110  
E-Mail: [dhl2020@aol.com](mailto:dhl2020@aol.com)

**REVIEW**  
OF OPTOMETRY

**Do you have CE Programs?**  
CONTACT US TODAY  
FOR CLASSIFIED ADVERTISING  
Toll free: 888-498-1460  
E-mail: [sales@kerhgroup.com](mailto:sales@kerhgroup.com)



**Practice For Sale**



Practice Sales • Appraisals • Consulting  
[www.PracticeConsultants.com](http://www.PracticeConsultants.com)

**PRACTICES FOR SALE  
 NATIONWIDE**

Visit us on the Web or call us to learn more about our company and the practices we have available.  
[info@PracticeConsultants.com](mailto:info@PracticeConsultants.com)  
**800-576-6935**

[www.PracticeConsultants.com](http://www.PracticeConsultants.com)

**OPTOMETRIC PRACTICE FOR SALE  
 NORTHEASTERN PA**

Very Successful ongoing optometric practice for sale in Northeastern PA. The practice is grossing 600K/yr. This practice is one of a kind with a very large and broad patient base and large contact lens base. The practice services many vision care programs that lends to its success, along with a full complement of direct paying patients. I will be willing to work in the practice.

*Serious replies only.*

Email: [resume6@kerhgroup.com](mailto:resume6@kerhgroup.com)  
 WITH COMPLETE NAME AND CONTACT INFO

**PRACTICE SALES  
 & APPRAISAL**

Expert Services for:

- ✓ **Buying or Selling a Practice**
- ✓ **Practice Appraisal**
- ✓ **Practice Financing**
- ✓ **Partner Buy-in or Buy-out**

Call for a Free Consultation  
**(800) 416-2055**  
[www.TransitionConsultants.com](http://www.TransitionConsultants.com)

Contact us today for classified advertising:  
 Toll free: **888-498-1460**  
 E-mail: [sales@kerhgroup.com](mailto:sales@kerhgroup.com)

**Professional Opportunities**

**WORCESTER**

**FT OD NEEDED**

Busy practice with two ophthalmologists and two optometrists seeks FT optometrist. Saturdays and one late evening required. Competitive compensation and benefits.

**Contact: Michele Rickert**  
**Phone: 508-853-2020**  
**Email: [ricketmi@aol.com](mailto:ricketmi@aol.com)**


**Place Your  
 Ad Here!**

Toll free: **888-498-1460**  
 E-mail: [sales@kerhgroup.com](mailto:sales@kerhgroup.com)

**STAFF OPTOMETRIST**

Bard Optical is a leading Midwest vision care organization in business for over 70 years and we are still growing. The company is based in Peoria, IL with 20 retail offices throughout the central Illinois area, as far north as Sterling and as far south as Jacksonville. Once again this year we were named to the Top 50 Optical Retailers in the United States by Vision Monday – currently ranking 37th. A progressive optometric staff is vital to the continued growth of our organization whose foundation is based on one-on-one patient service. We are currently accepting CV/resumes for optometrists focused on full scope primary medical patient care. The candidate must have an Illinois license with therapeutics. The practice includes (but is not limited to) general optometry, contact lenses, and geriatric care. Salaried, full-time positions are available with excellent growth programs and benefits. Some part-time opportunities may be available also. Please email your information to [hr@bardoptical.com](mailto:hr@bardoptical.com) or fax to 309-693-9754. Mailing address if more convenient is Bard Optical, Attn: HR, 8309 N Knoxville Avenue, Peoria, IL 61615. Ask about opportunities within Bard Optical. *We have openings in several existing and new offices opening soon in central Illinois.*

Bard Optical is a proud Associate Member of the Illinois Optometric Association.



[www.bardoptical.com](http://www.bardoptical.com)

**REVIEW<sup>®</sup>**  
 OF OPTOMETRY

Targeting Optometrists?  
**CLASSIFIED ADVERTISING WORKS**

Contact us today for classified advertising:  
 Toll free: **888-498-1460**  
 E-mail: [sales@kerhgroup.com](mailto:sales@kerhgroup.com)



Do you have Equipment  
 and Supplies for Sale?

**REVIEW<sup>®</sup>**  
 OF OPTOMETRY

Contact us today for classified advertising:  
 Toll free: **888-498-1460**  
 E-mail: [sales@kerhgroup.com](mailto:sales@kerhgroup.com)





## Weight Gain and Vision Loss

By Andrew S. Gurwood, OD

### History

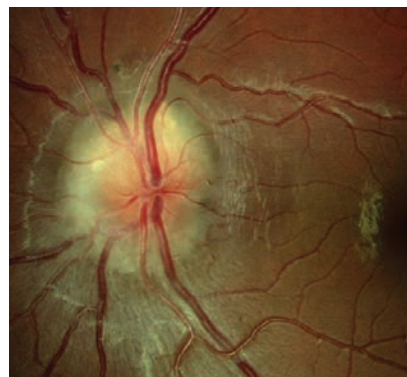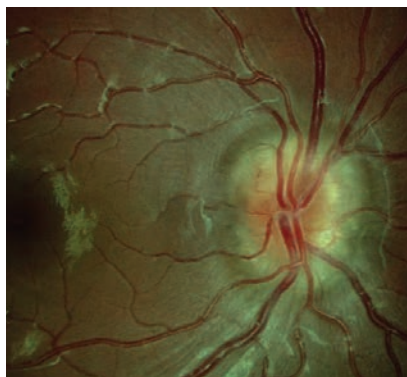
A 24-year-old black female presented with a chief complaint of cloudy vision in both eyes, worsening over the past week. She also complained that portions of her side vision in both eyes were missing and that she noticed balance problems. She denied diplopia, pulsatile tinnitus, vomiting, nausea or lower back pain.

Her systemic history was positive for hypertension for the past five years, as well as asthma and obesity. Her medications included Advair (fluticasone/salmeterol, GlaxoSmithKline), Benicar (olmesartan, Daiichi Sankyo), Aleve (naproxen, Bayer Healthcare) and albuterol. She reported having had a lumbar puncture one year prior for an “infection,” but no treatment was initiated.

She reported no allergies, and her ocular history was unremarkable.

### Diagnostic Data

Her best-corrected visual acuity



**Fundus images of a 24-year-old female patient presenting with cloudy vision in OD (left) and OS (right).**

was 20/25 OU. Pupils were normal with no afferent defect. Her extraocular muscle movements were full and smooth in both eyes. Confrontation visual fields were restricted 360° OU.

Biomicroscopy revealed normal external ocular structures in both eyes. Intraocular pressure measured 14mm Hg OU. Blood pressure was 173/92mm Hg, right arm sitting.

The photographs illustrate the dilated fundus examination.

### Your Diagnosis

How would you approach this case? Does this patient require any additional tests? What is your diagnosis? How would you manage this patient? What’s the likely prognosis?

To find out, please visit *Review of Optometry* online at [www.reviewofoptometry.com](http://www.reviewofoptometry.com). Click on the cover icon, and then click “Diagnostic Quiz” under this month’s table of contents. ■

**Retina Quiz Answers (from page 103):** 1) b; 2) c; 3) c; 4) c; 5) b.

### Next Month in the Mag

March’s theme is “Diagnostic Skills and Techniques.”

Topics include:

- *The Pros and Cons of Point-of-Care Testing*
- *Sharpen Your Posterior Segment Analysis Skills*

- *Slit Lamp Essentials: How to Perform Lacrimal Irrigation*
- *Blink and You’ll Miss It: Don’t Overlook the Lids*
- *Optometric Study Center: Diplopia: A Comprehensive Evaluation for ODs (earn 2 CE credits)*

REVIEW OF OPTOMETRY (ISSN 0147-7633) IS PUBLISHED MONTHLY, 12 TIMES A YEAR BY JOBSON MEDICAL INFORMATION LLC, 100 AVENUE OF THE AMERICAS, NEW YORK, NY 10013-1678. PERIODICALS POSTAGE PAID AT NEW YORK, NY AND ADDITIONAL MAILING OFFICES. POSTMASTER: SEND ADDRESS CHANGES TO REVIEW OF OPTOMETRY, PO BOX 81, CONGERS, NY 10920-0081. SUBSCRIPTION PRICES: US: ONE YEAR \$56; TWO YEARS \$97, CANADA: ONE YEAR \$88, TWO YEARS \$160, INT’L: ONE YEAR \$209, TWO YEARS \$299. FOR SUBSCRIPTION INFORMATION CALL TOLL-FREE (877) 529-1746 (USA); OUTSIDE USA, CALL (845) 267-3065. OR EMAIL US AT REVOPOTOMETRY@CAMBEYWEST.COM. PUBLICATIONS MAIL AGREEMENT NO: 40612608. CANADA RETURNS TO BE SENT TO BLEUCHIP INTERNATIONAL, P.O. BOX 25542, LONDON, ON N6C 6B2.

# Discover Biotrue® ONEday Lenses

Made from HyperGel™, a bio-inspired material designed to work like the eye



## Meets

oxygen level the open eye needs<sup>1</sup>



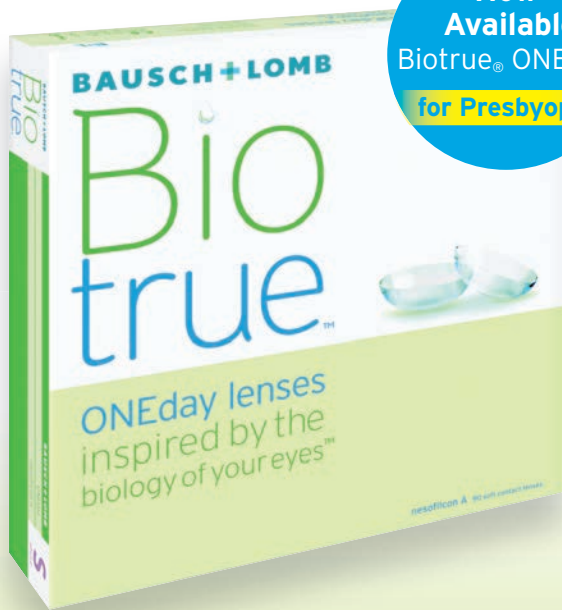## Matches

water content of the cornea – 78%<sup>2</sup>



## Mimics

lipid layer of the tear film<sup>3</sup>



Recommend comfortable vision throughout the day with **Biotrue ONEday** and **Biotrue ONEday for Presbyopia**.

For more information, call **1-800-828-9030**, contact your Sales Representative or visit **biotrue.com**

Distributed by Bausch + Lomb, a Division of Valeant Pharmaceuticals, North America LLC, Bridgewater, N.J. © 2014 Bausch & Lomb Incorporated. ®/™ are trademarks of Bausch & Lomb Incorporated or its affiliates. PNS07134 US/BPR/14/0013

**REFERENCES:** **1.** Brennan NA. A Model of Oxygen Flux Through Contact Lenses. *Cornea* 20(1):104-108, 2001. **2.** Bergmanson J. *Clinical Ocular Anatomy and Physiology*, 14th ed. Houston, Texas: Texas Eye Research and Technology Center; 2007. **3.** Twenty-two subjects participated in a randomized, double-masked, contralateral eye study to evaluate water loss of Biotrue® ONEday, 1-Day ACUVUE MOIST, and 1-Day ACUVUE TruEye. After 4, 8, 12, and 16 hours of wear, lenses were removed and immediately weighed (wet weight). The lenses were then completely dried and reweighed (dry weight). The percent water loss was then calculated for each lens from the wet and dry weights.

**BAUSCH + LOMB**  
See better. Live better.

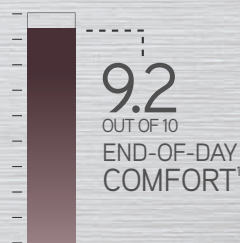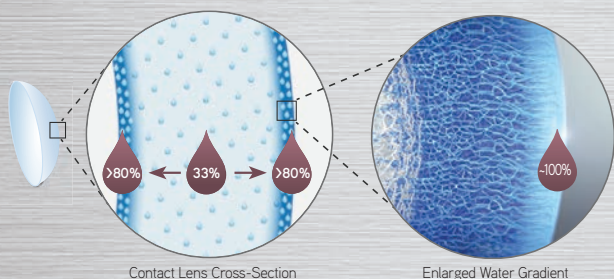


PREFERRED  
13 TO 1

# THIS IS WHY more patients prefer our lenses.

DAILIES TOTAL1® Water Gradient Contact Lenses feature a unique water gradient for lasting lubricity and end-of-day comfort.<sup>1</sup> No wonder patients preferred DAILIES TOTAL1® Contact Lenses 13 to 1 over their habitual lenses.<sup>2\*</sup>

## The First and Only Water Gradient Contact Lens



### UNIQUE WATER GRADIENT

Features different surface and core water content

### LASTING LUBRICITY

Ultrasoft surface gel approaches 100% water at the outermost surface<sup>3\*\*</sup>

### ALL DAY COMFORT

Outstanding comfort from beginning to end of day<sup>1</sup>

Let your patients experience the DAILIES TOTAL1® contact lens difference today.

PERFORMANCE DRIVEN BY SCIENCE™



\*Percentage of wearers agreeing with the statement "I prefer these lenses to my previous contact lenses" among those with a preference.

\*\*Based on *in vitro* measurement of unworn lenses.

1. In a randomized, subject-masked clinical study, n=40. Alcon data on file, 2011.

2. Based on an ongoing survey in Europe of 24 ECPs fitting 280 customers in DAILIES TOTAL1® contact lenses. Alcon data on file, 2012.

3. Angelini TE, Nixon RM, Dunn AC, et al. Viscoelasticity and mesh-size at the surface of hydrogels characterized with microrheology. ARVO 2013; E-abstract 1614872.

See product instructions for complete wear, care and safety information. © 2013 Novartis 7/13 DAL13315JAD

**Alcon**

a Novartis company