

SUPPLEMENT TO

NOVEMBER 2015

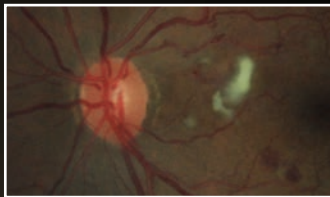
REVIEW[®] OF OPTOMETRY

www.reviewofoptometry.com

The 12th Annual
Guide to
**RETINAL
DISEASE**

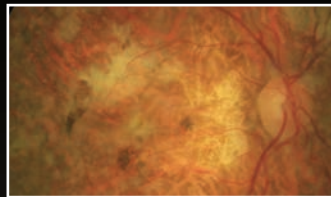
Anti-VEGF Agents in Practice

What have we learned from a decade of study and clinical use? Our experts review.



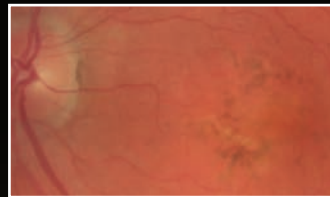
**Neovascularization:
What is it and
What Does it Mean?**

*By Mariem Abdou, OD, and
Joseph W. Sowka, OD*



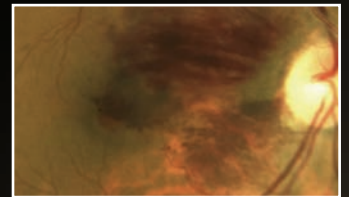
**Clinical Manifestations of
VEGF-Mediated Retinal
Disease**

*By Julie Rodman, OD, MS, and
Sherrol A. Reynolds, OD*



**Stemming the Tide:
How Anti-VEGF Therapies
Confront Neovascularization**

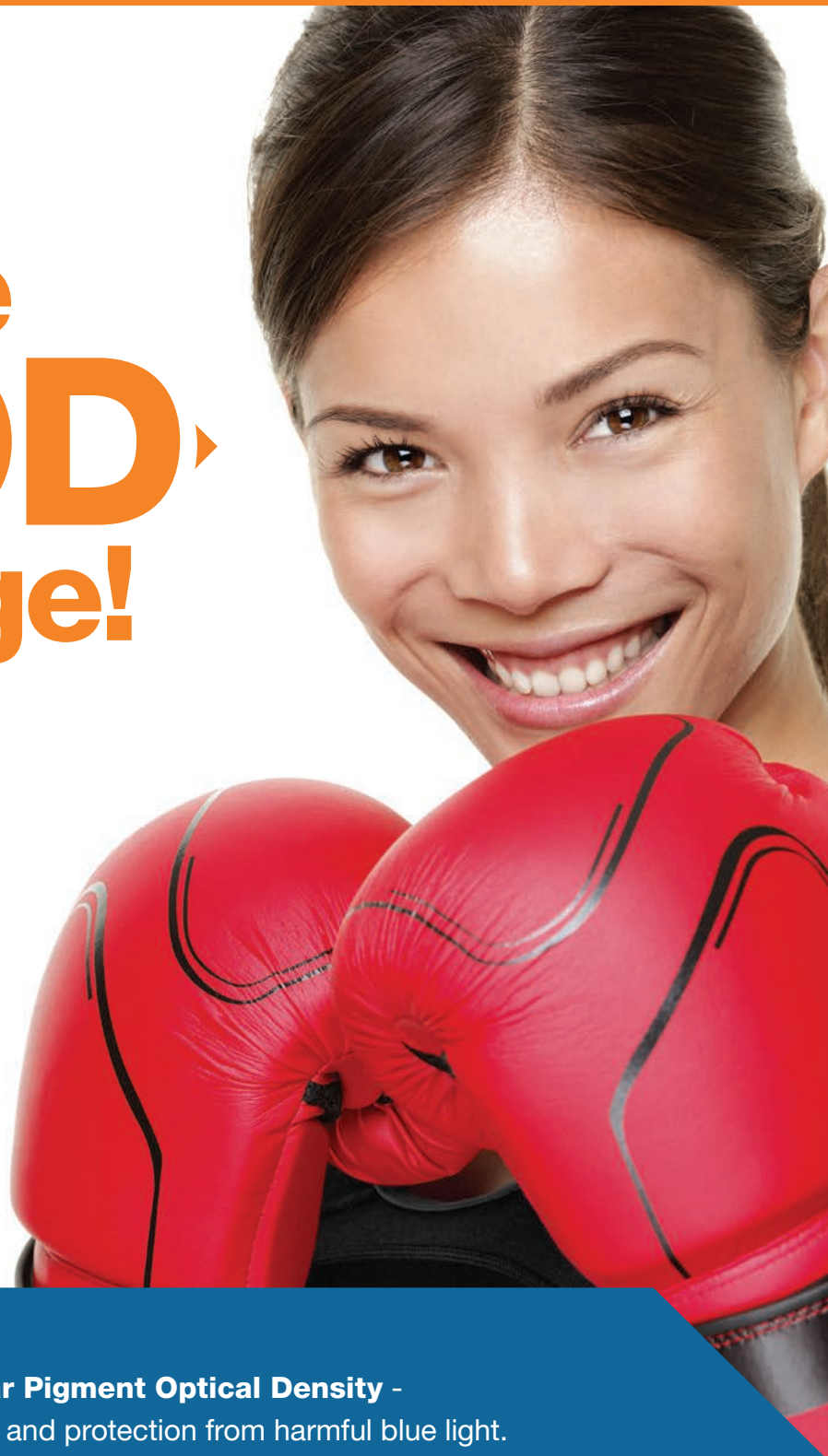By Christopher L. Suhr, OD



**The Optometrist's
Role in Anti-VEGF
Therapy**

*By Julie Torbit, OD and
Brad Sutton, OD*

Take the **MPOD** Challenge!



Knowing your patients' MPOD - **Macular Pigment Optical Density** - is important as a key risk factor for AMD and protection from harmful blue light.

START TODAY! Measure MPOD with *QuantifEye*, and supplement with *EyePromise* - the **ONLY** brand **Guaranteed to Increase MPOD!**



SCRATCH AND PLAY
at [www.MPODChallenge.com!](http://www.MPODChallenge.com)

Win great prizes and get a free MPOD Awareness Kit!





Ten Years On, Anti-VEGF Treatment Still Looms Large Throughout Retina Care

By Bill Kekevia, Senior Editor

As eye care enters into a second decade with anti-VEGF drugs among its armament, optometrists can expect to be confronted with an ever-growing patient base that has either undergone the treatment or is about to. This is particularly likely in light of the expected growth of retinal disease prevalence throughout the literature, coupled with expanded indications for anti-VEGF therapy beyond its roots in AMD. Although optometrists won't be the ones performing the injections, they are who patients will turn to for preoperative and postoperative care and any questions they may have.

For this reason, *Review of Optometry's* 12th Annual Guide to Retinal Disease is dedicated to providing a deeper understanding of these formulations, their potential, associated complications and, most importantly, how and when optometry is called upon to act.

The articles presented provide a careful analysis the pathophysiology, clinical presentation, pharmaceutical use and optometric comanagement concerns of anti-VEGF treatment.

This supplement would not have been possible without the contributions of the Optometric Retina Society, in particular the group's president, Brad Sutton, OD—whose efforts helped us identify our authors—and our clinical advisors, Andrew S. Gurwood, OD, and Mohammed Rafieetary, OD, both doctors whose reputations precede them and who provided us extraordinary insight into both the medical information presented and the OD's role in this still-budding avenue of treatment.

Keep this guide on your shelf (or bookmark a link to it online) for referral. Its lessons are designed to help you comanage patients, provide them top-quality education and better understand their experience yourself.

Neovascularization: What is it and What Does it Mean?

Tracing the pathophysiology of VEGF-mediated ocular disease.

By Mariem Abdou, OD, and Joseph W. Sowka, OD

THE RETINAL VASCULATURE has a critical job to do. It provides proper nourishment to the retina. It works like this: Light enters and travels through the retinal layers to reach the retinal photoreceptors, which are then stimulated to create impulses that are propagated through the visual pathway and processed in the visual cortex. A delicate intraretinal vascular system is located in the inner retinal layers, supplying the inner two-thirds of the retina. The photoreceptors access oxygen and nutrients predominantly from the underlying choroidal vasculature.

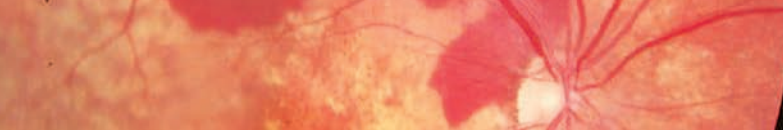
The blood-retinal barrier is made up of an inner blood-retinal barrier and an outer blood-retinal barrier. The inner barrier consists of the tight junctions of the

non-fenestrated retinal vascular endothelium, and the outer barrier consists of the zonula occludens junctions of the retinal pigment epithelium (RPE). Both barriers prohibit fluid from leaking into the retina.¹

Mechanical or ischemic disruption of this delicate vascular balance may stimulate the development of intraretinal or subretinal neovascularization, the process of angiogenesis from existing capillaries in response to hypoxic conditions. The retinal tissue naturally releases vascular endothelial growth factor (VEGF)—along with platelet-derived growth factor-B (PDGF-B), placental growth factor, stromal-derived growth factor-1 and their receptors and angiopoietin-2—in high quantities during

hypoxic events in an effort to stimulate development of additional routes for oxygenation.¹ The RPE fights vessel growth by producing pigment epithelium-derived factor (PEDF), a naturally occurring substance that limits the activity of VEGF. However, when the system is overloaded with VEGF, neovascularization can proliferate. These new vessels lack the appropriate tight junctions found in normal retinal blood vessels. In their absence, neovascular vessels become fenestrated and begin to leak blood, fluid, protein and lipids into the surrounding tissues.¹

Intra- or subretinal neovascularization originates from retinal capillaries and extends toward the vitreous. Because the tight junctions are absent in neovascular



membranes, these blood vessels may leak into the vitreal cavity, which damages and eventually collapses the vitreous. This results in visually degrading events as the system is progressively interrupted. The vitreous may succumb to the contractile forces of the fibrovascular tissue formation. This will cause excessive traction on the neovascular membrane itself or on the retina, which may produce vitreous hemorrhage or tractional retinal detachment.¹

Diabetic Causes of Retinal Neovascularization

Diabetic retinopathy is defined by retinal neovascularization.² Increase in serum glucose and hyperglycemic states leads to the destruction of vascular integrity through a variety of mechanisms.² One of these involves the degradation of pericytes, which are cells that line blood vessels.² They are engrained within the basement membrane of the endothelial cells in blood vessel walls.³ Pericytes provide a strong attachment, ensuring that no vascular leakage occurs.³ Investigators believe the destruction of pericytes in diabetic eye disease plays a major role in the process of diabetic retinopathy.³ With an increase in serum glucose (definitive for diabetes), there is resultant destruction of the pericytes, which contributes to increased vascular permeability. This process eventually progresses to an ischemic state of the surrounding tissue structures. As capillary nonperfusion contributes to an ischemic condition, release of VEGF and proliferation of growth factors occurs in an effort to supply appropriate oxygenation and nutrients to the damaged tissues.^{2,4}

Neovascularization in diabetes may occur on the optic disc

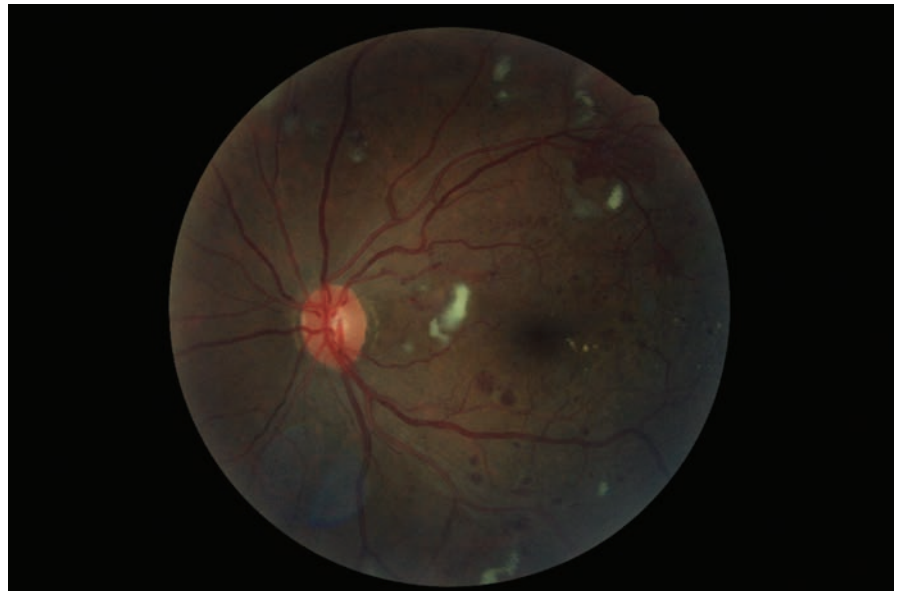

Fig. 1. Retinal neovascularization in proliferative diabetic retinopathy.

(NVD), elsewhere in the retina (NVE), on the iris (NVI) and in the anterior chamber angle (NVA).^{2,5} When NVI and NVA occur, the eye is at risk for a secondary angle closure and subsequent neovascular glaucoma (NVG).⁶

Whereas ocular angiogenesis is an undesired effect of diabetic retinopathy, neovascularization is well tolerated in other organ systems in concert with this disease. Proangiogenic factors promote wound healing by granulation of tissue. Researchers believe growth factors and neovascularization promotes endothelial cell proliferation and viability in other organ systems.⁷ Neovascularization is therefore considered a beneficial process for other organs.

Vein Occlusion and Retinal Neovascularization

Retinal neovascularization may also occur from central retinal vein occlusion (CRVO), hemispheric retinal vein occlusion (HRVO) or branch retinal vein occlusion (BRVO).

In CRVO, extensive atherosclerotic events within the vasculature lead to a narrowed lumen and, as a result, circulation stasis leads to thrombus formation posterior to the lamina cribrosa.⁶ Thrombus formation in the central retinal vein results in CRVO, which in turn leads to hemorrhaging in all four quadrants of the retina and nerve fiber layer infarcts.^{8,9} Resulting complications include macular edema, retinal neovascularization, angle neovascularization, vitreous hemorrhage and neovascular glaucoma.⁹⁻¹¹

CRVO can be categorized as either ischemic or nonischemic based on the clinical presentation and findings.⁹ Ischemic CRVO is a result of widespread capillary nonperfusion and retinal hypoxia. Complications include iris neovascularization and increased intraocular pressure (IOP), leading to a risk of neovascular glaucoma.⁹ Iris neovascularization results in nearly 50% of cases, and retinal neovascularization results in about 15% of cases of ischemic CRVO.⁹

Neovascularization occurs more commonly at the iris because the retina does not house enough viable capillaries for neovascular membranes to germinate. This explains why VEGF released from the hypoxic retina diffuses anterior to the iris where viable capillaries are found. Patients with CRVO should be monitored closely for NVI/NVA formation.⁹ Visual prognosis is generally poor due to macular ischemia.⁹

If rubeosis or angle neovascularization is detected, expeditious treatment with panretinal photocoagulation is necessary to prevent progression to neovascular glaucoma. Since this scenario plays out within three months of the initial occurrence, it is often called “90-day glaucoma.” Investigators found that the risk for this complication in cases of ischemic CRVO can be as high as 45% over several years, with the greatest risk existing during the first seven to eight months.⁶ Thorough monitoring on a biweekly basis, with careful iris assessment prior to dilation, gonioscopy and IOP measurement, can uncover these complications early.⁶

In contrast to the anterior segment neovascularization that occurs with CRVO, eyes with branch retinal vein occlusion (BRVO) are much more likely to develop retinal and disc neovascularization. In these conditions, the retina may become hypoxic secondary to the destruction of retinal capillaries, limited to one or two quadrants of the retina only. As a result, the adjacent retina contains viable retinal capillaries from which the released VEGF can stimulate angiogenesis. The most likely neovascular complications of BRVO is NVD or NVE, or both, with subsequent vitreous hemorrhage and tractional retinal detach-

ment. Treatment options such as VEGF injection, laser photocoagulation and pars plana vitrectomy may stabilize or improve vision.⁶

One ocular event that does not typically lead to neovascularization is retinal artery occlusion. An artery occlusion occurs primarily from emboli within the artery lumen, which becomes a barrier to vascular circulation. Emboli occur from multiple etiologies and include cholesterol plaques

(Hollenhorst plaque), calcific cardiac valvular material or thrombotic platelet aggregation. Entities associated with other causes of a central retinal artery occlusion (CRAO) specifically may include complications during coronary angiography, endocarditis, Takayasu’s arteritis, polyarteritis nodosa, Behcet’s disease, sickle cell disease, Wegener’s granulomatosis, sarcoidosis, carotid artery dissection, oral contraceptives, leukemia, lymphoma, cat-scratch disease, tumors, giant cell arteritis and vasospasm. Different causes associated with BRAO exist, including retinal vasculitis, Whipple’s disease, Lyme disease, toxoplasmosis, erectile dysfunction (ED) medications and Meniere’s disease.

The cilioretinal artery may also become obstructed in concert

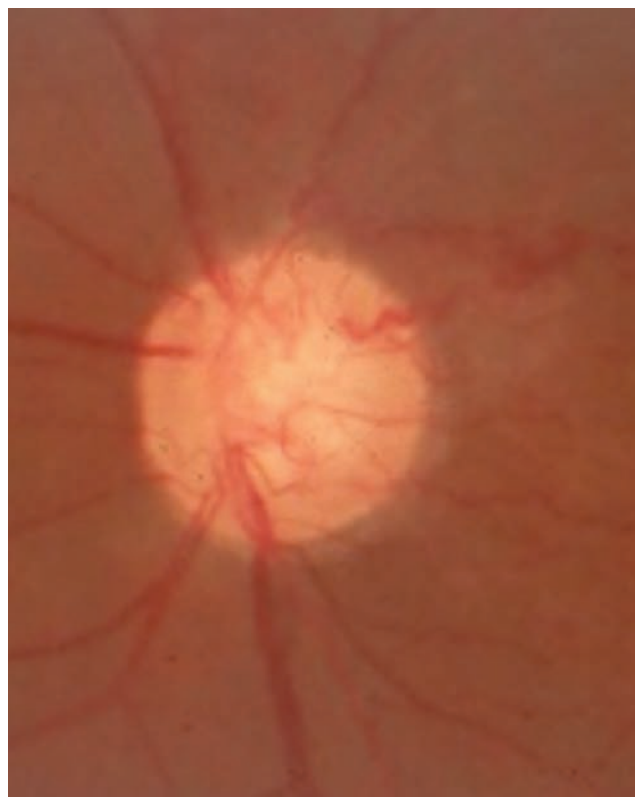
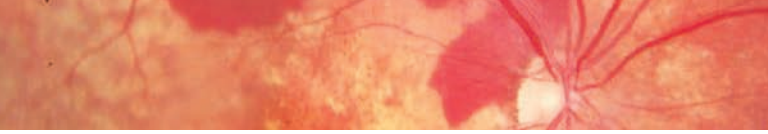


Fig. 2. This fundus image shows NVD from BRVO.

with a CRAO or BRAO in cases of systemic lupus erythematosus, antiphospholipid syndrome, ED medication use, migraine or pregnancy. Artery occlusions begin to result in progressive ganglion cell death after precisely 97 minutes of ischemia, leading to permanent irreversible ganglion cell death after 240 minutes of nonperfusion. Since the pathology induces death, rather than an ischemic state, there is no longer a need for neovascularization, which does not typically occur in these conditions.¹²

Choroidal Neovascularization

Another such disease resulting in neovascularization is age-related macular degeneration (AMD). The wet form of AMD manifests with neovascularization and leakage.¹³ Wet AMD may exhibit neovascularization beneath the macula,



resulting in devastating visual outcomes.¹³ This may present as subretinal fluid, subretinal hemorrhage, sub-RPE fluid or sub-RPE hemorrhage.¹³ When neovascularization regresses, it develops fibrovascular tissue along with atrophic disciform scarring, common in wet macular degenerative cases.¹³

Here, neovascularization differs from the intraretinal type as it forms beneath the RPE (subretinal neovascularization). This category of angiogenesis is induced by ischemic retinal changes and develops by either remaining separate from the RPE (type I membranes) or involving it (type II membranes).

In retinal angiomatous proliferation (RAP)—a variant of AMD—the choroidal neovascular membrane emerges from capillary beds within the retina and progresses to the

subretinal space, where it eventually may leak. In traditional CNV the neovascularization is derived from the choroidal vasculature. It has the potential to leak and bleed locally or grow up toward Bruch’s membrane.¹³

In some circumstances, the neovascularization may create discontinuities in Bruch’s membrane and emerge anteriorly into the RPE and subretinal space, where blood and fluid can readily accumulate. In both instances, increased VEGF expression ensues.¹ In AMD Bruch’s membrane is damaged as deposits of lipid and protein (drusen) accumulate.¹⁴ This, along with other oxidative stressors, affects the fluid exchange within the RPE, resulting in malfunctioning outer segment structures (photoreceptors and blood-retinal barrier).¹⁴

Dry AMD, with its various accumulations of macular drusen (including small, intermediate, large, soft or hard drusen), as well as focal pigmentary abnormalities, has the potential to convert to its proliferative, or wet, counterpart. Geographic atrophy is an advanced state of dry macular degeneration, signified as regions of atrophic RPE.¹⁴ The loss of the choriocapillaris in geographic atrophy generally doesn’t support the development of neovasculariza-

tion because the vascular germination bed is lost.¹⁴

Other Vascular Anomalies

Neovascularization may be confused with other retinal findings that have a similar appearance. These include intraretinal microvascular abnormalities (IRMAs) and collateral vessels. IRMAs are found in severe nonproliferative diabetic retinopathy and involve an abnormality within the vascular structure.⁶ Although the term “IRMA” was coined later as a description of the stages of diabetic retinopathy, it is likely a precursor to the development of true neovascularization.¹⁵ IRMAs may break through the internal limiting membrane of the retina and proliferate into the vitreous.⁴ Though this has yet to be confirmed histologically, the severity of IRMA is directly correlated to the risk of developing neovascularization.¹³

Collateral vessels arise from pre-existing vasculature when direct circulation from a vessel is obstructed. They are a good local adaptation designed to attempt restoration or circulation. Neither IRMAs nor collaterals cause direct lipid or blood leakage.¹⁶ Differentiation of IRMA and collateral vascularization from neovascularization is generally done by clinical observation. Investigators suggest that optical coherence tomography (OCT) may be helpful in differentiating between these conditions.⁵ In OCT analyses, neovascularization is viewed as vessels entering the posterior hyaloid cavity.⁵ When the hyaloid is still attached, the vessels can be seen protruding through the hyaloid into the vitreal cavity with a thickened hyaloid membrane.⁵ If the hyaloid is detached, the vessels are portrayed as hyperreflective images into the vitreous with shadowing of the inner and outer retinal layers.⁵

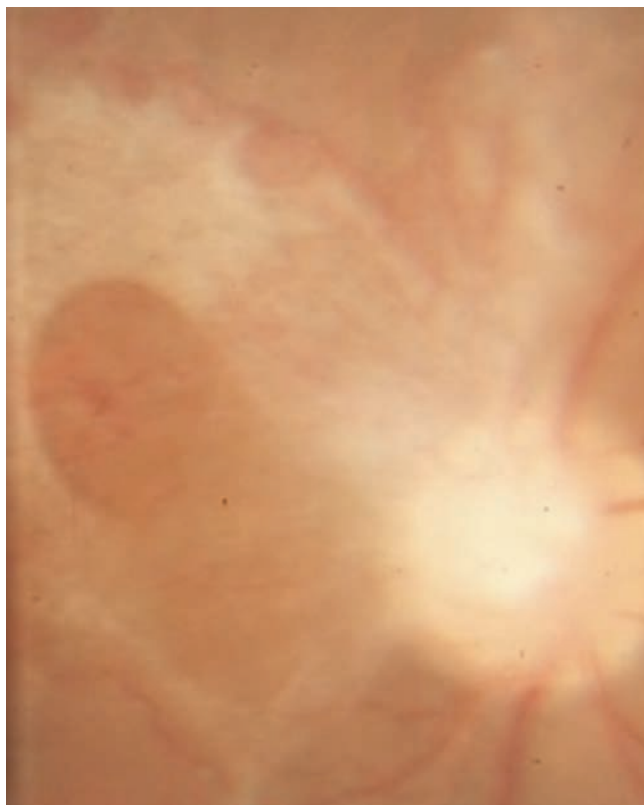


Fig. 3. This image of the same patient as page 5 shows fibrovascular traction and ensuing tractional retinal detachment as a result of untreated NVD.

Management

Today, treatment methods for neovascularization mainly revolve around the use of anti-VEGF agents. The current leading agents are Avastin (bevacizumab, Genentech), Lucentis (ranibizumab, Genentech) and Eylea (aflibercept, Regeneron). Avastin is a recombinant antibody to every isomer of vascular endothelial growth factor. Lucentis has a smaller binding site but is derived from the same antibody as bevacizumab. Its advantage over Avastin is that it has the ability to disperse throughout the entire retinal structure more effectively due to its smaller size.¹⁷ Eylea has a higher affinity for binding to VEGF sites, making blocking more complete and for a longer duration of time. Whereas Lucentis only binds to VEGF-A, Eylea additionally binds to both VEGF-B and placental growth factor. Eylea also effectively binds more tightly to VEGF molecules, which allows the duration of its effect to last longer. A recent retrospective study in treatment-naïve wet AMD patients showed no statistically significant difference between Eylea and Lucentis at one year.³

Several underlying factors and etiologies may promote neovascularization in the eye. A variety of genetic conditions, vascular diseases, ocular traumatic events, inflammatory conditions, neoplastic processes, infectious etiologies and ocular complications may instigate ischemic events that initiate the process. Neovascularization may occur in almost every ocular structure from posterior to anterior segment, depending on the severity of the hypoxic events. It is imperative to differentiate the appearance of neovascularization from other vascular abnormalities similar in form due to the differences in management.

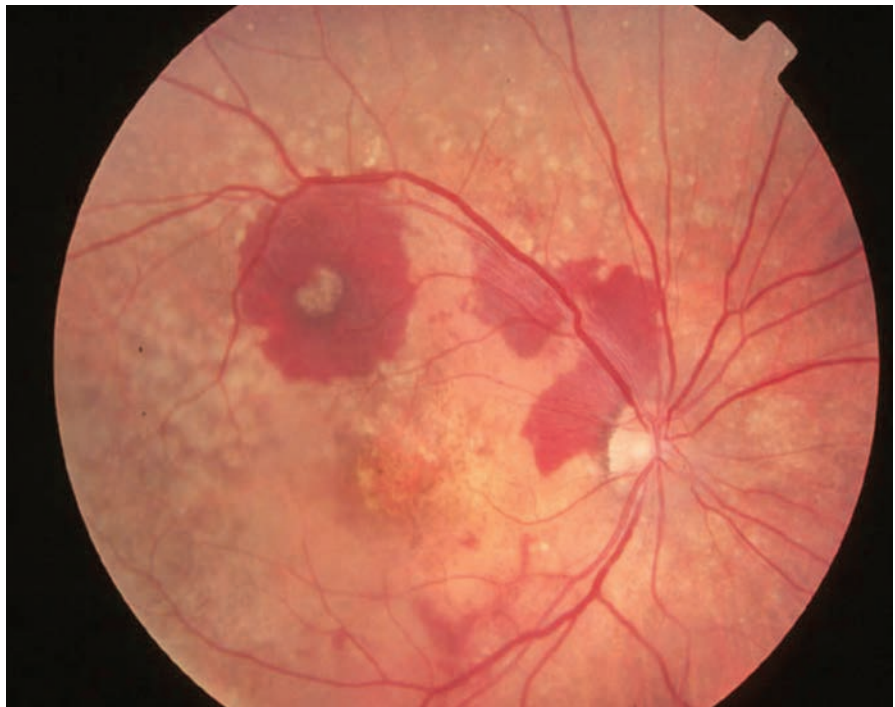


Fig. 4. This image shows a subretinal hemorrhage from choroidal neovascularization in an AMD patient.

Numerous advances in treatment options have evolved in recent years, the most significant being the advent of anti-VEGF agents. Even within this category of treatment, various agents have been identified and studied with promising results for each. As neovascularization is common in proliferative disease and can result in significant visual morbidity, the use of, and continued search for, better treatment techniques and agents is vital to preventing substantial vision loss. ■

Dr. Abdou, OD, is a faculty member at Nova Southeastern University College of Optometry. She graduated from Pennsylvania College of Optometry in 2013.

Dr. Sowka is chief of Advanced Care and director of the Glaucoma Service at Nova Southeastern University College of Optometry.

1. Campochiaro PA. Ocular neovascularization. *Journal of Molecular Medicine*. 2013;91(3):311-321.
2. Ciulla TA, Amador AG. Diabetic retinopathy and diabetic macular edema. *Diabetes Care*. 2003;26:2653-2664.
3. Bohni SC, Bittner M, Howell JP, et al. Comparison of Eylea and with Lucentis as first-line therapy in patients with treatment-naïve neovascular age-related macular degeneration in real-life clinical practice: retrospective case-series analysis. *BMC Ophthalmology*. 2015;15:109.

4. Yu Y, Chen H, Su SB. Neuroinflammatory responses in diabetic retinopathy. *Journal of Neuroinflammation*. 2015;12:1-15.
5. Cho H, Alwassia A, Regieatieri CV, et al. Retinal neovascularization secondary to proliferative diabetic retinopathy characterized by spectral domain optical coherence tomography. *Retina*. 2013 March 33(2):542-547.
6. Hayreh SS. Neovascular glaucoma. *Prog Retin Eye Res*. 2007;26(5):470-80.
7. Cobellis G, Maione C, Botti C, et al. Beneficial effects of VEGF secreted from stromal cells in supporting endothelial cell functions: Therapeutic implications for critical limb ischemia. *Cell Transplantation*. 2010;19:1425-1437.
8. Channa R, Smith M, Campochiaro P. Treatment of macular edema due to retinal vein occlusions. *Clinical Ophthalmology*. 2011;5(7):703-713.
9. Buddi R, Elliot D. Evaluation and management of retinal vein occlusion. *Review of Ophthalmology*. Nov. 2004.
10. Ford JA, Clar C, Lois N, et al. Treatments for macular edema following central retinal vein occlusion: a systematic review. *British Medical Journal*. 1 Jan. 2014.
11. Lahey JM, Kearney JF, Tunc M. Hypercoagulable states and central retinal vein occlusion. *Current Opinion in Pulmonary Medicine*. Lippincott Williams & Wilkins, 1 Jan. 2003.
12. Hayreh SS. Acute retinal arterial occlusive disorders. *Prog Retin Eye Res*. 2011;30(5): 359-394.
13. Nunes RP, Rosenfeld PJ, Filho CA, et al. Age-related macular degeneration. *Ophthalmology*. 6.28:580-599.
14. Rickman CB, Farsiu S, Toth CA, et al. Dry age-related macular degeneration: Mechanisms, therapeutic targets, and imaging. *IOVS*. 2013; 54(14).
15. Lee CS, Lee AY, Sim DA, et al. Reevaluating the definition of intraretinal microvascular abnormalities and neovascularization elsewhere in diabetic retinopathy using optical coherence tomography and fluorescein angiography. *Amer J of Ophthalmol*. 2015;159(1):101-110.
16. Marmor MF, Jampol LM, Wohl L. Cilioretinal collateral circulation after occlusion of the central retinal artery. *British Journal of Ophthalmology*. 1985;69:805-509.
17. Avery RL, Pearlman J, Pieramici DJ, et al. Intravitreal bevacizumab (Avastin) in the treatment of proliferative diabetic retinopathy. *Ophthalmology*. 2006.

Clinical Manifestations of VEGF-Mediated Retinal Disease

Numerous disease states can present with neovascular changes responsive to anti-VEGF therapy. By Julie Rodman, OD, MS, and Sherrol A. Reynolds, OD

THE INTRODUCTION OF injectable anti-vascular endothelial growth factor (VEGF) agents has transformed the care of a multitude of ocular conditions. The pathogenesis of vascular leakage and neovascular growth observed in these disorders share a common factor: an overexpression of angiogenic growth factors such as VEGF. New vessel growth may result from pre-existing vessels (angiogenesis) from vasculogenesis (de novo growth of blood vessels), or both.

Intravitreal injection of anti-VEGF has become a treatment of choice for a variety of disorders that affect the choroid, Bruch's membrane and the retinal pigment epithelium (RPE). It has become the standard of care for neovascular age-related macular degeneration (AMD) and other choroidal neovascular membrane (CNVM) variants, such as polypoidal choroidal vasculopathy (PCV), retinal angiomatous proliferation (RAP) and idiopathic juxtafoveal telangiectasia (IJFT). Anti-VEGF is used to treat diabetic retinopathy and retinal vein occlusions as well.

Age-related Macular Degeneration (AMD)

An estimated 15 million Americans have AMD. It is the leading cause of severe vision loss and legal blindness in adults over 50 years of age.^{1,2} AMD is a progressive disease, categorized into a spectrum of "dry" or atrophic AMD and "wet" or neovascular AMD. Roughly 10% to 15% of dry AMD patients progress to the advanced, sight-threatening neovascular form. It is estimated this percentage will increase by 2020.^{1,2} Furthermore, patients with neovascular AMD in

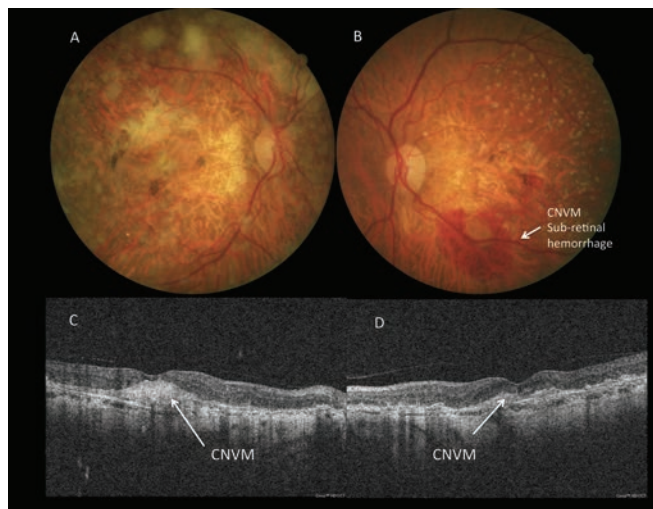


Fig. 1. A 75-year-old Caucasian female with intermediate AMD presented with complaints of distortion on a home Amsler grid in her left eye. Best-corrected visual acuity was 20/100 OD and 20/100 OS. OCT images reveal a CNVM in both eyes, with a subretinal hemorrhage in her left eye. The patient underwent IVFA, which confirmed the presence of CNVM. She was treated with monthly injections of Lucentis.

one eye have up to a 12% risk of developing neovascular AMD in the other eye.³

VEGF and other angiogenic mediators play a critical role in the pathophysiology of neovascular AMD. Drusen deposits in Bruch's membrane induce proinflammatory and proangiogenic mediators, including VEGF in the choroid.⁴ The result is an overexpression of VEGF, which leads to the development of choroidal neovascular membrane (CNV)—the hallmark of neovascular AMD—when naturally produced pigment epithelium-derived factor (PEDF) can no longer offset their effects.

The growth pattern of CNV can impact the patient's visual prognosis. In some cases, CNV can be observed clinically as a "gray or green" lesion beneath an elevated retina, while in others it may not be apparent. CNV may extend into the subretinal pigment epithelial space (Gass' type I) or into the subretinal space (Gass' type II).^{5,8} Recently observed type III CNV extends into the inner retina and

is commonly seen in RAP.⁵⁻⁹ Type I occurs more often in AMD patients, while type II is observed in younger patients with other CNV-producing entities such as ocular histoplasmosis (OHS) and angioid streaks.⁸ Patients with type I CNV have a worse visual prognosis than patients with type II CNV, given the propensity for greater structural damage.⁸

Choroidal neovascular membranes are also defined by their proximity to the foveal avascular zone (FAZ). Subfoveal CNV occurs underneath the fovea, juxtafoveal lesions are one to 199 microns from the FAZ and extrafoveal lesions occur outside of 200 microns from FAZ.¹⁰ Further classification includes "classic" or well-defined CNV and "occult" or poorly defined CNV based on their leakage pattern on intravenous fluorescein angiography (IVFA) and indocyanine green angiography (ICGA).¹⁰

Spectral-domain optical coherence tomography (SD-OCT) and fundus autofluorescence (FAF) are powerful adjunct tools in defining

the presence of CNV. All offer their advantages without the injection of anaphylactic allergy-producing dye. OCT allows anatomic identification of the presence of CNV and provides the location and nature of the CNV. Multimodal imaging, which incorporates OCT and FA and provides advantages over using FA alone, can facilitate a more accurate evaluation. These imaging techniques can also be efficiently used to monitor the patient's response to therapy.¹¹⁻¹⁵

Polypoidal Choroidal Vasculopathy

Polypoidal choroidal vasculopathy (PCV) has been referred to by various terms such as posterior uveal bleeding syndrome or multiple recurrent retinal pigment epithelial detachments.¹⁶ PCV is a distinct clinical entity from wet AMD and is characterized by a network of inner branching choroidal vessels with terminal aneurysmal dilatations or polyps, hemorrhagic and exudative detachments of the neurosensory retina and RPE.¹⁶ Clinically, these lesions appear as reddish-orange spheroidal shapes arising from the choroidal to subretinal space. The clinical appearance of PCV and AMD can appear similar; however, PCV occurs with limited serofibrinous exudation or fibrovascular membrane.¹⁶

PCV is often misdiagnosed as wet AMD and believed to be variant of type I CNV.^{16-18, 20-21} One study found that 23% of patients previously diagnosed with AMD had PCV.¹⁷ A number of distinctive features set PCV apart from classic wet AMD. Aside from the characteristics discussed above, PCV patients lack drusen, are typically between the ages of 50 and 65 and are commonly Asian or black.¹⁸

Because of its ability to remain in the choroidal vasculature, PCV is best diagnosed based upon epidemiology and clinical appearance and

confirmed using ICGA. The hallmark of PCV is the presence of terminal aneurysmal polyps seen as small, focal hyperfluorescent lesions, which persist into the late phase of ICGA. On SD-OCT, the hemorrhagic and exudative detachments of the retina and RPE are seen as sharp dome-like elevations. Two distinct signs associated with the polyps include the "double layer" sign described as a reflective band below the elevated pigment epithelial detachment (PED) and "Bola's sign" described as an RPE disruption, representing a small polyp adjacent to the PED.²⁰⁻²¹

Anti-VEGF has been explored as a therapeutic option in the management of PCV. However, the EVEREST study demonstrated that fewer anti-VEGF injections were needed in combination therapy with photodynamic therapy (PDT) using verteporfin compared with monotherapy of anti-VEGF or PDT with verteporfin alone.²²

Idiopathic Juxtafoveal Retinal Telangiectasias

IJRT, also called parafoveal telangiectasia or idiopathic macular telangiectasia, is a retinal anomaly that manifests with capillary telangiectatic changes in the juxtafoveolar area.²³ IJRT can be divided into three groups

based upon morphology, clinical and fluorescein angiographic (FA) features.²⁴ Group 1 (aneurysmal telangiectasia) is congenital and presents clinically as a unilateral aneurysmal telangiectasia primarily in men.

Macular edema is a complication that can result in vision loss.²⁵ Group 2 (perifoveal telangiectasia) has an acquired, bilateral, often asymmetric, presentation that can occur in either gender. Clinically, it presents with perifoveal telangiectasia without visible aneurysms that can result in retinal atrophy, CNV and vision loss.^{26,27} Group 3 (occlusive telangiectasia), extremely rare and associated with systemic disease, was eliminated in updated classification.²⁶

VEGF plays a critical pathophysiological role in IJRT Group 2. The retinal telangiectasia leads to a hypoxic environment, resulting in impaired oxygen exchange and an increase in VEGF release in the perifoveal area.^{28,29} Increased levels of VEGF can lead to CNV formation.

Patient symptomatology includes blurring of vision, scotoma and metamorphopsia.³⁰ The earliest sign on fundus examination is temporal parafoveal graying, ultimately resulting in an ovoid pattern.³¹ Early in the disease, the telangiectatic vessels will be absent or barely visible. FA is often

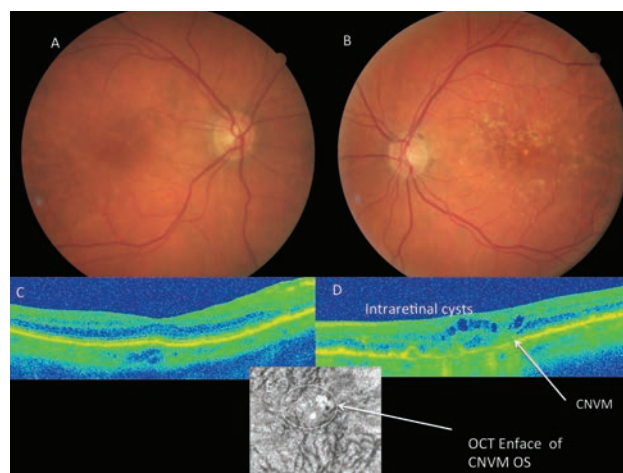
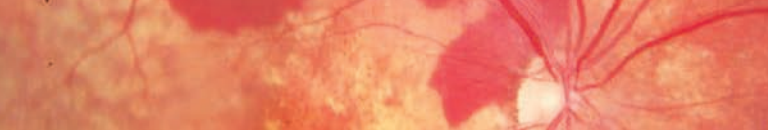


Fig. 2. This 65-year-old Caucasian male with AMD presented with complaints of decreased vision. His best-corrected visual acuity was 20/40 OD and 20/200 OS. OCT revealed CNVM in his left eye with intraretinal cysts. OCT en face imaging confirmed the presence of a CNVM and the patient underwent IVFA, which also confirmed the presence of CNVM. He was treated with monthly injections of Avastin.



needed to highlight the abnormal vessels.³² The telangiectatic vessels seen in IJRT Group 2 are typically not associated with exudate or hemorrhages; however, superficial crystalline deposits develop in nearly half of affected eyes.^{24,33} Over time, slightly dilated and blunted right-angle retinal venules extend temporal to the fovea. In addition, photoreceptor loss allows movement of RPE cells along the right-angled vessels, resulting in the appearance of intraretinal hyperpigmented black plaques. The plaques may contribute to a decrease in visual acuity. In approximately one-third of patients, CNV may occur as a complication and is referred to as proliferative Group 2 IJRT.³⁴

Fundus findings of IJRT Group 2 on biomicroscopy can be subtle early on. Therefore, imaging with FA and OCT is important in documenting the structural changes. FA shows hyperfluorescence of the dilated, abnormal foveal capillaries.³⁵ With time, the leakage may involve the whole parafoveal area (sparing the fovea), taking on an oval-shaped appearance.²⁷ SD-OCT has shown that eyes manifesting IJRT Type 2 exhibit decreased foveal thickness, rather than thickening as suggested by FA.^{36,37} Another unique feature of Group 2 IJRT seen on SD-OCT is the internal limiting membrane (ILM) drape. The draping of the ILM over the fovea represents loss of underlying tissue of the outer plexiform layer leading to a “cystoid space.”^{39,40} Disruption of the photoreceptor integrity line is another reported finding in IJRT Group 2.³⁸

SD-OCT will additionally exhibit intraretinal hyporeflective spaces that are not correlated with retinal thickening or patient symptomatology.³⁹ Areas of RPE hyperplasia will appear with superficial hyperreflectivity and resultant shadowing of the underlying retinal structures.^{39,40} SD-OCT of IJRT

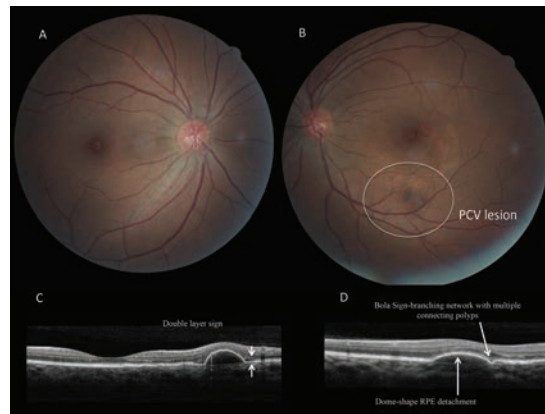


Fig. 3. A 34-year-old black female presented for a follow-up evaluation with complaints of mild blurry vision in her left eye. Her medical history was remarkable for hypertension. Her best-corrected visual acuity measured 20/20 OD and 20/30 OS. OCT demonstrated a dome-shape RPE detachment and Bola sign consistent with PCV CNV. The patient was eventually treated with Avastin.

with subretinal neovascularization will manifest with a thickened, hyper-reflective RPE band with or without serous detachment.^{41,42} SD-OCT imaging has become a mainstay ancillary test used in the diagnosis and management of IJRT.

Diabetic Retinopathy and Maculopathy

Diabetes and its comorbidities pose an enormous public health problem, with more than 29 million Americans affected, according to the Centers for Disease Control. Diabetic retinopathy remains the leading cause of blindness in adults age 20 to 74 in the United States.^{43,44}

Diabetic macular edema (DME) represents the most frequent cause of vision loss in patients with diabetes.⁴⁵ The prevalence of DME among US diabetes patients is approximately 30% in adults who have had diabetes for 20 years or more; it varies with the stage of diabetic retinopathy.⁴⁶ DME occurs in both Type 1 and Type 2 diabetes due to the microvascular changes occurring in the retina.⁴⁷ An individual with DME may be asymptomatic, mildly symptomatic or may present with profound vision loss. Blurred vision, metamorphopsia, floaters and changes in contrast sensitivity are the most common clinical presentations of DME.

VEGF has been shown to play a critical role in the pathogenesis of

diabetic macular edema.^{48,49} Retinal ischemia leads to an upregulation of VEGF and subsequent vascular leakage. High concentrations of VEGF promote retinal hemorrhage formation, which further exacerbates capillary nonperfusion. Studies have shown that VEGF is overexpressed in the vitreous and retina in diabetic eyes.^{48,50} Overexpression of VEGF results in a breakdown of the blood-retinal barrier, leading to fluid accumulation in the macula.^{48,50} DME is defined as retinal thickening located within one disc diameter of the center of the macula.⁵¹ The thickening may be focal or diffuse and associated with intraretinal cysts and exudation as a result of leaking microaneurysms and capillaries. Focal DME refers to edema from individual microaneurysms whereas diffuse DME refers to more extensive capillary leakage and breakdown of the inner blood-retinal barrier. DME can additionally be classified by its proximity to the foveal center.

Clinically significant macular edema (CSME) is a distinct form of DME that was succinctly defined by the Early Treatment Diabetic Retinopathy Study (ETDRS). It exists if any of the following criteria are met:^{43,44,52}

- (1) Retinal thickening at or within 500µm of the center of the macula.
- (2) Hard exudates at or within

500µm of the center of the macula that are associated with adjacent retinal thickening.

(3) An area of retinal thickening at least 1DD in size, any part of which is located within 1DD of the center of the macula.

Proper evaluation for DME requires slit lamp biomicroscopy and indirect funduscopy of the macula. Subtle changes in macular thickness are often hard to observe. Other diagnostic tools, such as SD-OCT, have proven useful in the detection and monitoring of the features characterizing DME. FA is used for identifying the area where treatment is to be placed (it is not used for diagnosis). SD-OCT can help in the clinical grading of DME and monitoring of therapeutic response.^{51,52}

SD-OCT can quantify retinal thickness in diabetic patients and will show one of three patterns of diabetic macular edema: retinal swelling, cystoid macular edema (CME) or serous retinal detachment.⁵² Retinal edema appears as increased retinal thickness with sponge-like swelling of the retina accompanied by an irregular, layered appearance. SD-OCT of CME will appear as intraretinal cystoid spaces at or near the outer plexiform layer. The cystoid spaces may coalesce into larger cystic cavities over time, resulting in a serous detachment with elevation of the sensory retina. Eyes with DME may show evidence of thickening, intraretinal cystic changes, subretinal fluid or vitreomacular traction. Commonly, a combination of these findings can be found.⁵³⁻⁵⁵

Retinal Vein Occlusion (RVO)

RVO is another common retinal disease.⁵⁶ The clinical variants include branch retinal vein occlusion (BRVO), central retinal vein occlusion (CRVO) and hemiretinal vein occlusion (HRVO). BRVO is the most prevalent type, occurring four to six

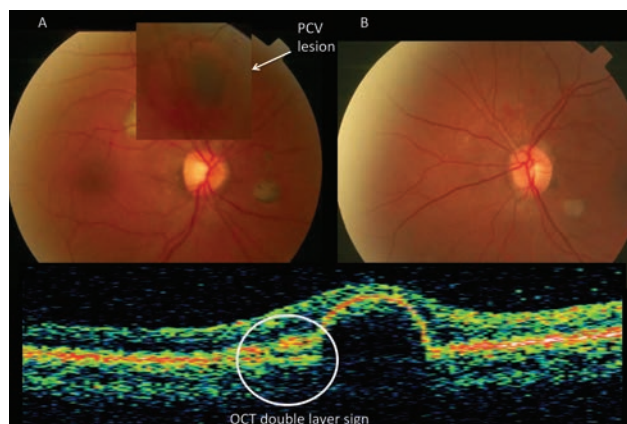


Fig. 4. A 45-year-old black female presented for routine eye examination. Her medical history was remarkable for diabetes, hypertension and hypercholesterolemia. Her best-corrected visual acuity measured 20/20 ODs and 20/20 OS. OCT demonstrated a dome-shape RPE detachment consistent with PCV and the double layer sign. Resolution of PCV was seen at the three-month follow-up.

times more than its counterparts.⁵⁷

BRVO typically occurs at a site of arteriovenous (AV) crossing, where the arteries and veins share a common adventitial sheath. Although the process is not clearly understood, it is thought to occur due to a combination of factors known as Virchow's triad, which includes compression of the veins by arteries, degenerative changes within venous walls and hypercoagulability.⁵⁸

CRVO occurs secondary to thrombus formation within the central retinal vein at the level of the lamina cribrosa of the optic nerve.

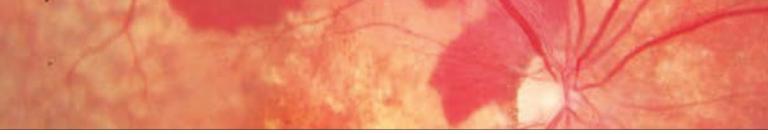
Occlusion within the retinal veins leads to an increase in intraluminal pressure, causing hypoxia and decreased blood flow, resulting in upregulation of VEGF expression.⁵⁹ An increase in circulating VEGF leads to an increase in vascular permeability, macular edema and neovascular proliferation in RVO.⁶⁰⁻⁶¹ Studies also demonstrated elevated aqueous levels of VEGF in CRVO patients.⁵⁹⁻⁶¹

The clinical presentations and symptomatology vary depending on the site, severity and chronicity of the occlusion. Clinical findings include intraretinal hemorrhages following the course of a vein with or without cotton-wool spots, edema and retinal vascular changes. RVO is categorized into two types, nonischemic RVO and ischemic RVO. In the ischemic

form, areas of capillary nonperfusion lead to neovascularization and other complications. Macular edema is the leading cause of vision loss in RVO patients.

Treatment for patients with retinal vein occlusion is directed at eliminating macular edema, retinal neovascularization and anterior segment neovascularization. Treatment also involves management of predisposing risk factors such as diabetes, hypertension, arteriosclerosis, smoking and other ocular diseases such as glaucoma.

Anti-VEGF therapy is currently a first-line intervention for macular edema produced by RVO. The BRAVO study (Ranibizumab for the treatment of macular edema following Branch Retinal Vein Occlusion) and CRUISE study (Ranibizumab for the treatment of macular edema after Central Retinal Vein Occlusion) have shown that there are benefits to using anti-VEGF agents in the treatment of macular edema and ischemic maculopathy in RVO.^{62,63} The COPERNICUS study (Intravitreal aflibercept injection for macular edema secondary to central retinal vein occlusion) and GALILEO study (VEGF Trap-Eye for macular edema secondary to central retinal vein occlusion) also demonstrated visual improvement following deployment of anti-VEGF agents.^{64,65} A poor



visual prognosis has been reported in patients with chronic macular edema or macular ischemia, despite treatment with the aforementioned options. Since the agents are often not a cure for the issue of retinal fluid accumulation or neovascularization formation, injections must be repeated frequently in a protocol known as “treat and extend.” In other circumstances, traditional laser photocoagulation is used in combination with injections; the injectable resolves the fluid issue to a minimal level and the laser addresses the remaining edema.

Angiogenic mediators such as VEGF play a key role in the pathogenesis of myriad ocular conditions. VEGF expression results in visually significant complications, which can have a profound impact on the patient’s function and quality of life. The development of injectable anti-VEGF therapy has significantly improved visual prognoses and outcomes. ■

Dr. Rodman OD, MS, is an associate professor of optometry at Nova Southeastern University in Ft. Lauderdale, FL. She serves as a residency supervisor and attending physician of fourth year optometry students. She is a member of the Optometric Retina Society.

Dr. Reynolds, OD is an associate professor of optometry at Nova Southeastern University in Ft. Lauderdale, FL. She is currently the instructor for the clinical medicine course and lectures on various topics in ocular disease. She is a member of the Optometric Retina Society.

1. Sunness JS. The natural history of geographic atrophy, the advanced atrophic form of age-related macular degeneration. *Mol Vis.* 1999;5:25.
2. Friedman DS, O’Colmain BJ, et al. Prevalence of age-related macular degeneration in the United States. *Arch Ophthalmol.* 2004;122(4):564–72.
3. Bressler NM, Bressler SB, Congdon NG, et al. Potential public health impact of Age-Related Eye Disease Study results: AREDS report no. 11. *Arch Ophthalmol.* 2003;121(11):1621–4.
4. Kvant A, Alverer PV, Berglin L, Seregard S. Subfoveal fibrovascular membranes in age-related macular degeneration express vascular endothelial growth factor. *Invest. Ophthalmol. Vis. Sci.* 1996;37(9):1929–34.
5. Abugreen S, Muldrew KA, Stevenson MR, et al. CNV subtype in first eyes predicts severity of ARM in fellow eyes. *Br J Ophthalmol.* 2003;87(3):307–11.
6. Lee JH, Lee WK. Choroidal neovascularization associated with focal choroidal excavation. *Am J Ophthalmol.* 2014;157(3):710–8.e1.
7. Jung JJ, et al. The incidence of neovascular subtypes in newly diagnosed neovascular age-related macular degeneration. *Am J Ophthalmol.*

- 2014;158:769–79.
8. Grossniklaus HA, Gass JDM. Clinicopathologic correlations of surgically excised type 1 and type 2 submacular choroidal neovascular membranes. *Am J Ophthalmol.* 1998;126:59–69.
9. Freund KB, Zweifel SA, Engelbert M. Do we need a new classification for choroidal neovascularization in age-related macular degeneration? *Retina.* 2010;30(9):1333–49.
10. Macular Photocoagulation Study Group. Laser photocoagulation of subfoveal neovascular lesions in age-related macular degeneration. Results of a randomized clinical trial. *Arch Ophthalmol.* 1991;109(9):1220–31.
11. Avery RL, Pieramici DJ, Rabena MD, et al. Intravitreal bevacizumab (Avastin) for neovascular age-related macular degeneration. *Ophthalmology.* 2006;113(3):363–72.
12. CATT Research Group. Martin DF, Maguire MG, et al. Ranibizumab and bevacizumab for neovascular age-related macular degeneration. *N Engl J Med.* 2011;364(20):1897–1908.
13. Rosenfeld PJ, Brown DM, Heier JS, et al. Ranibizumab for neovascular age-related macular degeneration. *N Engl J Med.* 2006;355(14):1419–31.
14. Brown DM, Kaser PK, Michels M, et al. Ranibizumab versus verteporfin for neovascular age-related macular degeneration. *N Engl J Med.* 2006;355(14):1432–44.
15. Heier JS, Brown DM, Chong V, et al. Intravitreal aflibercept (VEGF trap-eye) in wet age-related macular degeneration. *Ophthalmology.* 2012;119(12):2537–48.
16. Yannuzzi et al. Idiopathic polypoidal choroidal vasculopathy (IPCV). *Retina* 1990;10:1–8.
17. Sho K, Takahashi K, Yamada H, et al. Polypoidal choroidal vasculopathy: incidence, demographic features, and clinical characteristics. *Arch Ophthalmol.* 2003;121(10):1392–6. 54.
18. Imamura et al. polypoidal choroidal vasculopathy: A Review. *Surv Ophthalmol.* 2010;55(6):501-15.
19. Tong JF, Chan WM, Liu DT, Lai TY, Choy KW, Pang CP et al. Aqueous humor levels of vascular endothelial growth factor and pigment epithelium-derived factor in polypoidal choroidal vasculopathy and choroidal neovascularization. *Am J Ophthalmol* 2006;141:456–62.
20. Sato T, Kishi S, Watanabe G, et al. Tomographic features of branching vascular networks in polypoidal choroidal vasculopathy. *Retina.* 2007; 27:589-94.
21. Lim TH et al. Polypoidal choroidal vasculopathy: an angiographic discussion. *Eye.* 2010;24:483-90.
22. Koh A, Lee WK, Chen LJ, et al. EVEREST study: efficacy and safety of verteporfin photodynamic therapy in combination with ranibizumab or alone versus ranibizumab monotherapy in patients with symptomatic macular polypoidal choroidal vasculopathy. *Retina.* 2012;32:1453-64.
23. Nowlaty SR, Al-Shamsi HN, Al-Khars, W. Idiopathic juxtafoveolar retinal telangiectasia: A current review. *Middle East Afr J Ophthalmol.* 2010 Jul-Sep;17(3):224-41.
24. Gass JD, Oyakawa RT. Idiopathic juxtafoveolar retinal telangiectasia. *Arch Ophthalmol.* 1982;10:769-80.
25. Cahill M, O’Keefe M, Acheson R, et al. Classification of the spectrum of Coats’ disease as subtypes of idiopathic retinal telangiectasia with exudation. *Acta Ophthalmol Scand.* 2001;79:596-602.
26. Yannuzzi LA, Bardal AMC, Freund B, et al. Idiopathic macular telangiectasia. *Arch Ophthalmol.* 2006;124(4):450-60.
27. Gass JD, Blodi BA. Idiopathic juxtafoveolar retinal telangiectasia: update of classification and follow-up study. *Ophthalmology.* 1993;100:1536-46.
28. Charbel IP, Berendschot TT, Staurengli G, et al. Confocal blue reflectance imaging in type 2 idiopathic macular telangiectasia. *Invest Ophthalmol Vis Sci.* 2008;49:1172-7.
29. Wu L, Evans T, Arevalo F. Idiopathic macular telangiectasia type 2. *Surv Ophthalmol.* 2013;58:536-59.
30. Charbel IP, Holz FG, Scholl HP. Metamorphopsia in patients with macular telangiectasia type 2. *Doc Ophthalmol.* 2009;119:133-40.
31. Abujamra S, Bonanomi MT, Cresta FB, et al. Idiopathic juxtafoveolar retinal telangiectasia: clinical pattern in 19 cases. *Ophthalmologica.* 2000;214:406-11.
32. Ryan SJ. *Retina.* Philadelphia, PA: Elsevier Mosby; 2006.1409-15.
33. Casswell AG, Chaine G, Rush P, et al. Paramacular telangiectasia. *Trans Ophthalmol Soc UK.* 1986;105(Pt 6):683-92.
34. Watzke RC, Klein MI, Folk JC, et al. Long-term juxtafoveal retinal telangiectasia. *Retina* 2005;25:727-35.
35. Narayann R, Majji AB, Hussain N, et al. Characterization of idiopathic macular telangiectasia type 2 by fundus fluorescein angiography in Indian population. *Eur J Ophthalmol* 2008;18:587-90.
36. Cohen SM, Cohen MI, El-Jabali F, Pautler SE. Optical Coherence Tomography findings in nonproliferative group 2a idiopathic juxtafoveal retinal telangiectasia. *Retina.* 2007;27:59-66.
37. Charbel IP, Helb HM, Holz FG, et al. Correlation of macular function with retinal thickness in nonproliferative type 2 idiopathic macular telangiectasia. *Am J Ophthalmol.* 2008;145:169-75.
38. Gaudric A, Ducos de Lahitte G, Cohen SY, et al. Optical coherence

- tomography in group 2A idiopathic juxtafoveolar retinal telangiectasia. *Arch Ophthalmol.* 2006;124:1410-19.
39. Albini TA, Benz MS, Coffee RE, et al. Optical coherence tomography of idiopathic juxtafoveolar telangiectasia. *Ophthalmic Surg Lasers Imaging.* 2006;37:120-8.
40. Paunescu LA, Ko TH, Duker JS, et al. Idiopathic juxtafoveolar retinal telangiectasia: new findings by ultrahigh-resolution optical coherence tomography. *Ophthalmology.* 2006;113:48-57.
41. Gupta V, Gupta A, Dogra MR, et al. Optical coherence tomography in group 2A idiopathic juxtafoveolar telangiectasia. *Ophthalmic Surg Lasers Imaging.* 2005;36:482-6.
42. Clemons TE, Gillies MC, Chew EY, et al. Baseline characteristics of participants in the natural history study of macular telangiectasia (Mac Tel) Mac Tel Project Report No. 2. *Ophthalmic Epidemiol.* 2010;17:66-73.
43. Fong DS, Ferris III FL, David MD, Chew EY. The Early Treatment of Diabetic Retinopathy Study Research Group. Photocoagulation for diabetic macular edema. *ETDRS Report 1.* *Arch Ophthalmol.* 1985;103:1644-52.
44. Moss SE, Klein R, Klein BE. The 14-year incidence of visual loss in a diabetic population. *Ophthalmology.* 1998;105(6):998-1003.
45. Bandello F, Battaglia Parodi M, Lanzetta P, et al. Diabetic Macular Edema. *Dev Ophthalmol.* 2010;47:73-110.
46. Klein R, Klein BE, Linton KL. Prevalence of age-related maculopathy: The Beaver Dam Eye Study. *Ophthalmology.* 1992;99(6):933-43.
47. Grover D, Li TJ, Chong CCW. Intravitreal steroids for macular edema in diabetes. *Cochrane Database Syst Rev.* 2008;(1):CD005656.
48. Nguyen QD, Tatipinar S, Sha SM, et al. Vascular endothelial growth factor is a critical stimulus for diabetic macular edema. *Am J Ophthalmol.* 2006;142:961-69.
49. Spilisbury K, Garrett KL, Shen WY, et al. Overexpression of vascular endothelial growth factor (VEGF) in the retinal pigment epithelium leads to the development of choroidal neovascularization. *Am J Pathol.* 2000;157(1):135-44.
50. Arevalo JF, Fromow-Guerra J, Quiroz-Mercado H, et al. Primary intravitreal bevacizumab (Avastin) for diabetic macular edema: results from the Pan-American Collaborative Retina Study at 6-month follow-up. *Ophthalmology.* 2007;114:743-50.
51. Mathew C, Yunirakasiwi A, Sanjay S. Updates in the management of diabetic macular edema. *J Diabetes Res.* 2015;2015:794036.
52. Mitchell P, Foran S. Guidelines for the Management of Diabetic Retinopathy. The National Health and Medical Research Council. Canberra, Australia: Australian Diabetes Society for the Department of Health and Aging; 2008.
53. Otani T, Kishi S, Maruyama Y. Patterns of diabetic macular edema with optical coherence tomography. *Am J Ophthalmol.* 1999;127(6):688-93.
54. Ghazi NG, Ciralsky JB, Shah SM, et al. Optical coherence tomography findings in persistent diabetic macular edema; the vitreomacular interface. *Am J Ophthalmol.* 2007;144:747-54.
55. Trichonas G, Kaiser P. Optical coherence tomography imaging of macular edema. *Br J Ophthalmol.* 2014;98:ii24-ii29.
56. Rogers S, McIntosh RL, Cheung N, et al. The prevalence of retinal vein occlusion: pooled data from population studies from the United States, Europe, Asia, and Australia. *Ophthalmology.* 2010;117(2): 313–19.
57. Klein R, Klein BE, Moss SE, et al. The epidemiology of retinal vein occlusion: the beaver dam eye study. *Trans Am Ophthalm Soc.* 2000; 98:133–43.
58. Yau JW, Lee P, Wong TY, et al. Retinal vein occlusion: an approach to diagnosis, systemic risk factors and management. *Intern Med J.* 2008;38:904–10.
59. Yoshimura T, Sonoda KH, Sugahara M, et al. Comprehensive analysis of inflammatory immune mediators in vitreoretinal diseases. *PLoS ONE.* 2009;4(12).
60. Funk M, Kriechbaum K, Prager F, et al. Intraocular concentrations of growth factors and cytokines in retinal vein occlusion and the effect of therapy with bevacizumab. *Invest Ophthalmol Vis Sci.* 2009;50:1025–1032.
61. Aiello LP, Avery RL, Arrigg PG, et al. Vascular endothelial growth factor in ocular fluid of patients with diabetic retinopathy and other retinal disorders. *N Engl J Med.* 1994;331:1480–87.
62. Campochiaro PA, Heier JS, Feiner L, et al. BRAVO Investigators. Ranibizumab for macular edema following branch retinal vein occlusion: six-month primary end point results of a phase III study. *Ophthalmology.* 2010;117(6):1102-12.
63. Varma R, Bressler NM, Suñer I, et al. BRAVO and CRUISE Study Groups. Improved vision-related function after ranibizumab for macular edema after retinal vein occlusion: results from the BRAVO and CRUISE trials. *Ophthalmology.* 2012;119(10):2108-18.
64. Brown DM, Heier JS, Clark WL, et al. Intravitreal aflibercept injection for macular edema secondary to central retinal vein occlusion: 1-year results from the phase 3 COPERNICUS study. *Am J Ophthalmol.* 2013;155:429–37.
65. Holz FG, Roeder J, Ogura Y, et al. VEGF Trap-Eye for macular oedema secondary to central retinal vein occlusion: 6-month results of the phase III GALILEO study. *Br J Ophthalmol.* 2013; 97:278–84.

Stemming the Tide: How Anti-VEGF Therapies Confront Neovascularization

Travel through the past, present and future of the most successful therapeutic modality in the fight against wet AMD. By Christopher L. Suhr, OD

THE IDENTIFICATION OF the choroidal neovascular membrane (CNV) as the primary mediator of damage and central vision loss in wet age-related macular degeneration (AMD) gave rise to medical interventions affecting the manifestation and progression of this pernicious source of debilitating vision loss. Initially, the primary treatment was focal photocoagulation, which worked by cauterizing the neovasculation. Although this halted the growth of CNV, it also scarred the treatment area, resulting in functional loss.

As disease management evolved, verteporfin ocular photodynamic therapy (PDT) became the treatment of choice for classic and occult CNV, and treatment of smaller neovascular membranes was associated with more positive outcomes—the sooner the lesion was diagnosed and treated, the better the potential outcome.¹⁻³

Marketed under the trade name Visudyne (Bausch + Lomb), the drug works by inducing vessel occlusion following activation in the CNV and retina using non-thermal radiation.⁴

Discovering VEGF's role in mediating angiogenesis was like the "Rosetta stone" that opened the door to contemporary efforts in combating CNV growth by blocking the action of VEGF. As we will see, blocking VEGF by binding to the molecule yields different outcomes than when competitively inhibiting the molecule at the VEGF receptors (VEGFRs).

Macugen: the Anti-VEGF Vanguard

In 2004, Eyetech received FDA approval for the first ophthalmic use anti-VEGF medication in the United States. Originally intended for use as a cancer treatment, Macugen (pegaptanib) found its place as an anti-VEGF treatment for AMD.⁵ Macugen is an aptamer—a type of special nucleic acid molecule—capable of adopting a three-dimensional conformation that enables it to bind to extracellular VEGF, blocking its interaction with VEGFR on vascular endothelial cells and inhibiting angiogenesis. In this sense, it is the nucleic acid equivalent of an antibody. Macugen was the first approved aptamer in the United States.⁶ In vitro, Macugen binds to the major pathological VEGF isoform (165).⁷⁻⁹

Macugen is administered intravitreally, preloaded in a syringe with 0.3mg of drug within 90µl solution and initially approved for treatment intervals of six weeks.

During the FDA approval process,

its efficacy was confirmed by the VEGF Inhibition Study in Ocular Neovascularization-1 (VISION-1).¹⁰ Multiple dosages were evaluated and 0.3mg was determined to be the lowest effective dose.¹¹ Success was associated with how early the disease was treated subsequent to detection. Twelve to 20% of patients gained 15 or more letters of acuity with Macugen.¹² The study continued for two years to evaluate the drug for adverse effects and was deemed to have a good safety record, with only rare instances of endophthalmitis, retinal detachments and traumatic cataracts.¹³

Though the medication is only FDA approved for wet AMD, it has been used off-label for treating other conditions, such as diabetic retinopathy (DR). As we know, angiogenesis is a defining factor for proliferative diabetic retinopathy (PDR) and, in multiple cases, use of Macugen has shown benefit in the treatment of both PDR and diabetic macular edema (DME).¹⁴⁻¹⁶

More to Come

Although the selection of VEGF blockade drugs is currently limited, new medications are in the pipeline:

- The novel, topically administered medication squalamine is presently in Phase III trials.
- An oral option, vitalanib, has completed Phase I/II trials, according to the FDA.
- Another option, Rapamune (Wyeth Pharmaceuticals), has also completed Phase I/II trials, and if approved would be used adjunctively to Lucentis (Genentech). The unique aspect of this medication is that it is administered via subconjunctival injection. It is an mTOR inhibitor, a special protein kinase, and has the potential to treat geographic atrophy.⁵⁴
- A new intravitreal medication is recruiting for Phase III trials. Fovista, also known as E10030, targets platelet-derived growth factor (PDGF), which strips pericytes from newly-formed blood vessels, making them more susceptible to anti-VEGF therapy. It is being evaluated as monotherapy and as an adjunct therapy to Lucentis. Manufacturer Ophotech has shown greater efficacy with the dual therapeutic modality than with Lucentis monotherapy.⁵⁵

Increasing Efficacy: Avastin's Surprise Appearance

Another anti-VEGF agent, Avastin (bevacizumab, Genentech), was approved in 2004 for the treatment for colorectal cancer to combat tumor progression, and like Macugen, was found to be useful against wet AMD.

Avastin binds to the VEGF molecule, preventing angiogenesis.¹⁷ Prior to its administration intravitreally, a small study investigated the effects of systemic Avastin, which showed a decrease in the leakage of the neovascular membrane on fluorescein angiography (FA).¹⁸

The study was conducted during the period that Genentech was pursuing FDA approval of Lucentis (ranibizumab)—not Avastin—for wet AMD. Investigators, seeing the efficacy of intravitreal Lucentis, decided to administer Avastin in a similar manner.

This was an off-label use for Avastin, unsanctioned by Genentech.

Nevertheless, intravitreal administration for use in wet AMD gained traction. Its use became widespread, and more studies confirmed its safety and efficacy in treating wet AMD. Importantly, studies confirmed its equivalent efficacy relative to Lucentis. Studies of dosing found 1.25mg was as sufficient as a 2.5mg dose.^{19,20}

Avastin, unlike Macugen, binds to multiple VEGF isoforms. Macugen is specific for only the VEGF₁₆₅ isoform, while in some patients AMD is mediated by other VEGF isoforms; some patients with wet AMD who do not respond well to Macugen do respond to Avastin.^{18,21} Avastin improved both visual acuity and macular central thickness values on OCT and was found to be an effective and safe treatment in multiple studies.²²⁻²⁵

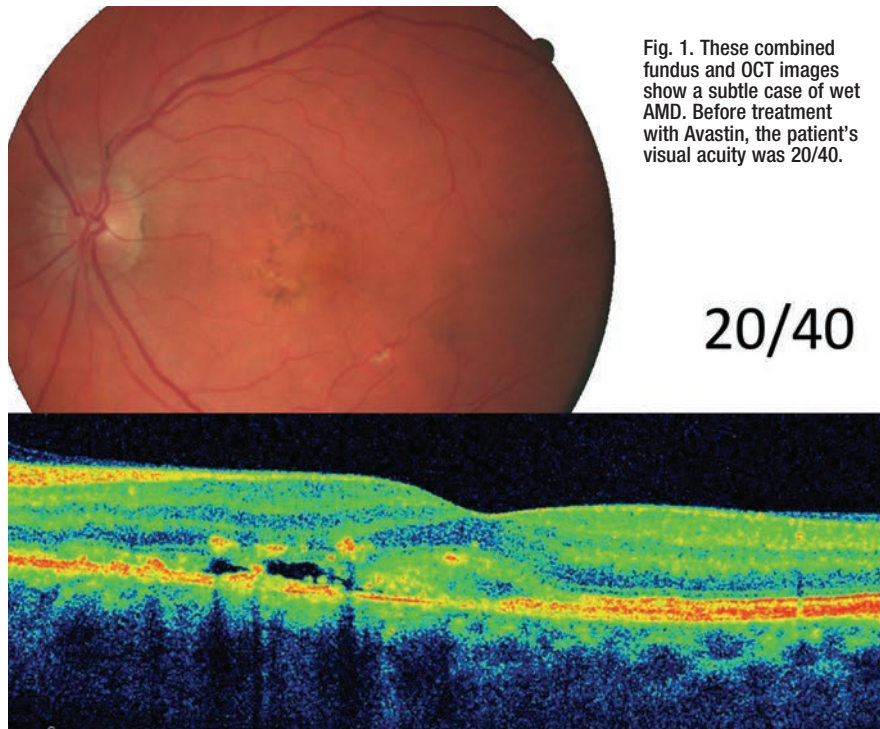

Fig. 1. These combined fundus and OCT images show a subtle case of wet AMD. Before treatment with Avastin, the patient's visual acuity was 20/40.

Photos: Diana Sheehy, MD

Lucentis Takes the Stage

In 2006, Genentech received FDA approval for Lucentis as a 0.5mg intravitreal injection. Like Avastin, Lucentis inhibits all VEGF-A isoforms, including the active VEGF₁₁₀ isoform, making it superior to Macugen, which fell out of favor. The size of the Lucentis molecule allows it to penetrate the internal limiting membrane, resulting in excellent penetration of the neovascular membrane.²⁶

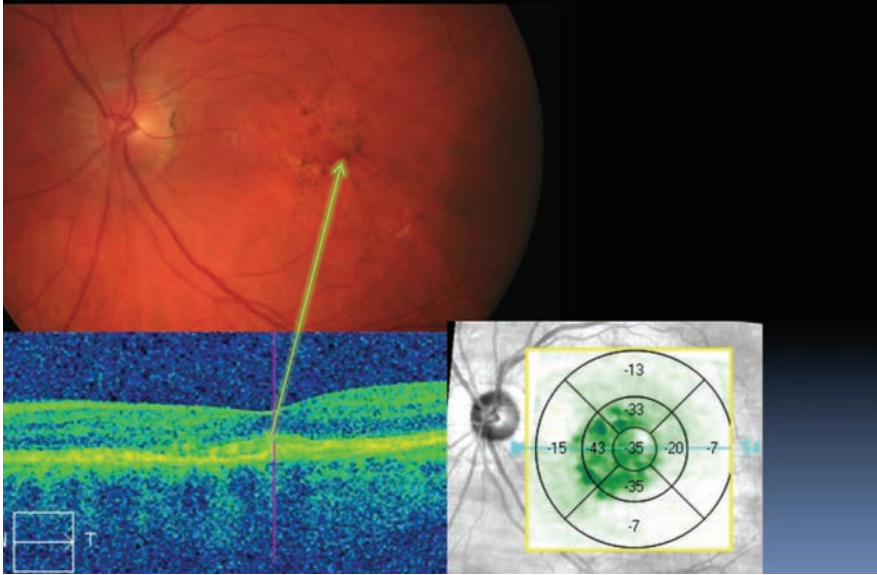
VEGF-A has been shown to cause neovascularization and leakage in models of ocular angiogenesis and vascular occlusion and is thought to contribute to the pathophysiology of neovascular AMD, macular edema following retinal vein occlusion (RVO), DR and DME. Lucentis reduces endothelial cell proliferation, vascular leakage and new blood vessel formation.²⁷ The drug was later approved for use in diabetic changes and RVO-induced edema.

Initial studies to evaluate the efficacy, safety and treatment courses for Lucentis included the anti-VEGF Antibody for the Treatment of Predominantly Classic Choroidal Neovascularization in AMD (ANCHOR) study and the Minimally Classic/Occult Trial of The Anti-VEGF antibody Ranibizumab in the Treatment of Neovascular AMD (MARINA) study, which both showed Lucentis patients improved visual function in a way unprecedented for any prior therapy, including Macugen, though the perceived efficacy of Lucentis relative to Macugen could be due to the differences in the representation of lesion subtypes in VISION-1 vs. ANCHOR and MARINA.^{28,29} Lucentis's effect on central retinal thickness reduction, visual acuity and visual function was significant, though geographic atrophy increased vs. baseline.³⁰⁻³²

As the therapy is essentially lifelong once begun, long-term

S/p several AVT
(20/25+)

Fig. 2. The same patient as seen on page 14, shows improvement after treatment with Avastin, both on the diagnostic images and in her visual function, now at 20/25.



outcomes continue to be studied. A pair of studies showed long-term Lucentis use preserved visual function, but most patients at a seven-year follow up had developed geographic atrophy, with lesion size and progression the primary factors in determining visual outcome.^{33,34}

Several recent studies have established excellent efficacy, tolerability and safety of Lucentis for neovascular AMD, and different dosages and intervals have been well studied. The PIER study showed that there was a benefit to three monthly injections followed by quarterly injections.³⁴

The SAILOR study used the same three-month injection protocol, but retreatment was used on an “as-needed” basis after the initial three injections.³⁶

Beyond the dosing schedule philosophies, the HARBOR study assessed different Lucentis dosing regimens and showed that there was no improved benefit to a high-

dose (2.0mg) compared with the standard (0.5mg) dose, and was seen both in the monthly and “as-needed” regimens.³⁷

Controversy and the CATT Study

Clinicians have long wondered which agent to use: Avastin or Lucentis? Lucentis is FDA approved for ophthalmic use, whereas Avastin remains FDA approved only for treatment in cancer. Every injection of Avastin is thus off-label—but does that mean it cannot be a consideration for retina specialists? Herein lies the debate.

One thing to consider is the formulation difference. Lucentis is packaged appropriately for single use, while Avastin requires modification of its formulation at a compounding pharmacy. This has not been associated with much added risk in broad-based use.³⁸ However, an outbreak of endophthalmitis in 2011 linked to tainted vials of compounded Avastin underscores the

risks inherent in off-label prescribing and gives pause to clinicians about use of medications from third-party providers.

Ultimately, some retina specialists may favor the use of Lucentis to Avastin, but this choice may not be in terms of efficacy. The Comparison of AMD Treatments Trials (CATT) study determined the equivalency of Avastin and Lucentis in efficacy and safety.³⁹⁻⁴¹ Price, however, is a major consideration. Lucentis costs approximately 40 times more per dose (approximately \$2,000) than Avastin (approximately \$50), so ethical and pragmatic questions influence the choice of drug.⁴²

Eylea in the Pipeline

A newer anti-VEGF agent, Eylea (afibercept, Regeneron), received approval in 2011. Eylea works a bit differently than Avastin, Lucentis and Macugen. Eylea acts as a soluble decoy receptor that binds VEGF-A and placental growth factor (PlGF), inhibiting the binding and activation of the cognate VEGF receptors.⁴³ VEGF-A and PlGF are members of the VEGF family of angiogenic factors that can act as mitogenic, chemotactic and vascular permeability factors for endothelial cells. VEGF acts via two receptor tyrosine kinases, VEGFR-1 and VEGFR-2, present on the surface of endothelial cells. PlGF binds only to VEGFR-1, which is also present on the surface of leukocytes. Activation of these receptors by VEGF-A can result in neovascularization and vascular permeability. In essence, Eylea is a decoy receptor for VEGF—a ‘VEGF trap’ (a name used during its clinical development)—making the free VEGF less available to bind to VEGFR and mediate angiogenesis.⁴⁴

Eylea 2mg is administered intravitreally monthly for three months, followed by 2mg intravitreally once

every eight weeks. Although Eylea may be dosed as frequently as 2mg every four weeks, doing so did not demonstrate greater efficacy.⁴³

The use of Eylea has shown promise in the treatment of wet AMD, with ongoing studies to determine its long-term efficacy and short-term research indicating that it is well-tolerated and efficacious, although patients that had previously used either Avastin or Lucentis and changed to Eylea did not experience an increase in visual function.^{43,45,46}

Eylea is a drug of interest for other neovascular and vascular ocular conditions, such as DR. The clinical efficacy and mechanistic evaluation of Eylea for proliferative diabetic retinopathy (CLARITY) study is currently underway, and others studies have already shown Eylea's potential to treat DME.⁴⁷⁻⁴⁹

Risk Considerations

In spite of intravitreal anti-VEGF therapy's good safety record, some debate over their systemic side effects exists. Studies of systemic Avastin for colorectal cancer treatment have shown an association with cardiovascular events, such as stroke.⁵⁰

A meta-analysis did not show a significant increase in cardiovascular or nonocular hemorrhagic events from intravitreal use, but more data is needed to make a conclusive determination regarding cardiovascular risk in intravitreal Avastin use.⁵¹

Transient (i.e., approximately one week) post-injection increase in IOP—likely due to the increased intraocular volume that occurs after treatment—has been observed but not linked to glaucomatous damage. The risk of neovascularization recurrence following incomplete treatment also necessitates appropriate follow-up.

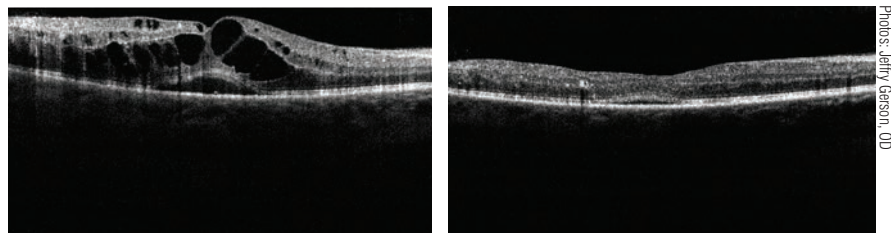


Fig. 3. These OCT images show a patient with CSME before and after treatment with Avastin. The image on the right was taken 10 days after the first.

Photos: Jeffrey Gerson, OD

Treatment Philosophies

Providers differ in terms of treatment philosophy. Some stick to the manufacturers' dosing regimens (one injection monthly for Lucentis, three monthly injections then bimonthly for Eylea, and none for the off-label Avastin). Others treat as needed—only if there is an indication of neovascularization or macular edema.

Lastly, the “treat and extend” philosophy holds that it is best to treat until the neovascularization has ceased followed by exams at four- to six-week intervals. If neovascularization is absent, the follow-up period is extended an extra two weeks. However, if neovascularization is noted, the follow-up time is reduced by two weeks and treatment may be resumed. The evidence indicates that “treat and extend” is an effective management philosophy, with good results and decreasing burdens on patients in terms of follow-ups and injections.⁵²

Intravitreal anti-VEGF has become a staple therapy for neovascular AMD due to its superiority in disease management. The downside is that anti-VEGF does not address the underlying disease, so therapy must be chronic to maintain visual acuity gains.

Beyond their original indications for exudative AMD, most agents have been expanded for use in other ocular conditions, including macular edema due to RVO or diabetes.

When patients present to our offices with signs and symptoms consistent with wet AMD, a referral to a retina specialist for consideration of treatment is necessary. The advances in therapy have taken us from laser photocoagulation and photodynamic therapy to anti-VEGF medications. With continued advances expected, hopefully our patients will have a better chance of preserving their vision and ultimately a greater quality of life. ■

Dr. Suhr, OD, MPH, practices at the Corporal Michael J. Crescenz VA Medical Center in Philadelphia.

1. Guidelines for using verteporfin (Visudyne) in photodynamic therapy for choroidal neovascularization due to age-related macular degeneration and other causes: update. *Retina*. 2005;25(2):119-34. (roundtable)
2. La cour M, Kilgaard JF, Nissen MH. Age-related macular degeneration: epidemiology and optimal treatment. *Drugs Aging*. 2002;19(2):101-33.
3. Blinder KJ, Bradley S, Bressler NM, et al. Effect of lesion size, visual acuity, and lesion composition on visual acuity change with and without verteporfin therapy for choroidal neovascularization secondary to age-related macular degeneration: TAP and VIP report no. 1. *Am J Ophthalmol*. 2003;136(3):407-18.
4. Valeant Ophthalmics. Visudyne (verteporfin for Injection). Prescribing Information. Bridgewater, NJ: Valeant Ophthalmics, n.d.
5. Viores SA. Technology evaluation: pegaptanib, Eyetech/Pfizer. *Curr Opin Mol Ther*. 2003;5(6):673-9.
6. Ni X, Castanares M, Mukherjee A, et al. Nucleic acid aptamers: clinical applications and promising new horizons. *Curr Med Chem*. 2011;18(27):4206-14.
7. Gilead Sciences, Inc. Macugen (pegaptanib Sodium Injection). Intravitreal Injection. Dimas, CA: Gilead Sciences, n.d. Package insert.
8. Doggrel SA. Pegaptanib: the first antiangiogenic agent approved for neovascular macular degeneration. *Expert Opin Pharmacother*. 2005;6(8):1421-3.
9. Gragoudas ES, Adamis AP, Cunningham ET, et al. Pegaptanib for neovascular age-related macular degeneration. *N Engl J Med*. 2004;351(27):2805-16.
10. Fine SL, Martin DF, Kirkpatrick P. Pegaptanib sodium. *Nat Rev Drug Discov*. 2005;4(3):187-8.
11. Siddiqui MA, Keating GM. Pegaptanib: in exudative age-related macular degeneration. *Drugs*. 2005;65(11):1571-7.
12. Gonzales CR. Enhanced efficacy associated with early treatment of neovascular age-related macular degeneration with pegaptanib sodium: an exploratory analysis. *Retina*. 2005;25(7):815-27.
13. VEGF Inhibition Study in Ocular Neovascularization (V.I.S.I.O.N.) Clinical Trial Group [D'Amico DJ, Masonson HN, Patel M, et al. Pegaptanib sodium for neovascular age-related macular degeneration: two-year safety results of the two prospective, multicenter, controlled clinical trials. *Ophthalmology*. 2006;113(6):992-1001.e6.
14. Krzysiolek MG, Filippopoulos T, Ducharme JF, Loewenstein JL.

Pegaptanib as an adjunctive treatment for complicated neovascular diabetic retinopathy. *Arch Ophthalmol*. 2006;124(6):920-1.

15. Cunningham ET, Adamis AP, Altaweel M, et al. A phase II randomized double-masked trial of pegaptanib, an anti-vascular endothelial growth factor aptamer, for diabetic macular edema. *Ophthalmology*. 2005;112(10):1747-57.
16. Adamis AP, Altaweel M, Bressler NM, et al. Changes in retinal neovascularization after pegaptanib (Macugen) therapy in diabetic individuals. *Ophthalmology*. 2006;113(1):23-8.
17. Genentech, Inc. AVASTIN (bevacizumab) Solution for intravenous infusion South San Francisco, CA: Genentech, 2015. Package insert.
18. Michels S, Rosenfeld PJ, Puliafito CA, et al. Systemic bevacizumab (Avastin) therapy for neovascular age-related macular degeneration: twelve-week results of an uncontrolled open-label clinical study. *Ophthalmology*. 2005;112(6):1035-47.
19. Rosenfeld PJ, Moshfeghi AA, Puliafito CA. Optical coherence tomography findings after an intravitreal injection of bevacizumab (avastin) for neovascular age-related macular degeneration. *Ophthalmic Surg Lasers Imaging*. 2005;36(4):331-5.
20. Modarres M, Naseripour M, Falavarjani KG, et al. Intravitreal injection of 2.5 mg versus 1.25 mg bevacizumab (Avastin) for treatment of CNV associated with AMD. *Retina*. 2009;29(3):319-24.
21. Ng EW, Adamis AP. Targeting angiogenesis, the underlying disorder in neovascular age-related macular degeneration. *Can J Ophthalmol*. 2005;40(3):352-68.
22. Rich RM, Rosenfeld PJ, Puliafito CA, et al. Short-term safety and efficacy of intravitreal bevacizumab (Avastin) for neovascular age-related macular degeneration. *Retina*. 2006;26(5):495-511.
23. Mandal S, Garg S, Venkatesh P, et al. Intravitreal bevacizumab for subfoveal idiopathic choroidal neovascularization. *Arch Ophthalmol*. 2007;125(11):1487-92.
24. Bashshur ZF, Haddad ZA, Schakal A, et al. Intravitreal bevacizumab for treatment of neovascular age-related macular degeneration: a one-year prospective study. *Am J Ophthalmol*. 2008;145(2):249-256.
25. Dimopoulos S, Leitritz MA, Ziemssen F, et al. Submacular predominantly hemorrhagic choroidal neovascularization: resolution of bleedings under anti-VEGF therapy. *Clin Ophthalmol*. 2015;9:1537-41.
26. Van wijngaarden P, Coster DJ, Williams KA. Inhibitors of ocular neovascularization: promises and potential problems. *JAMA*. 2005;293(12):1509-13.
27. Genentech, Inc. Lucentis (ranibizumab Injection), Intravitreal Injection. South San Francisco, CA: Genentech, 2015. Print.
28. Patel RD, Momi RS, Hariprasad SM. Review of ranibizumab trials for neovascular age-related macular degeneration. *Semin Ophthalmol*. 2011;26(6):372-9.
29. <http://www.ncbi.nlm.nih.gov/pmc/articles/PMC2694030/>
30. Menke MN, Zinkernagel MS, Ebner A, Wolf S. Functional and anatomical outcome of eyes with neovascular age-related macular degeneration treated with intravitreal ranibizumab following an exit strategy regimen. *Br J Ophthalmol*. 2014;98(9):1197-200.
31. Rothenbuehler SP, Waeber D, Brinkmann CK, et al. Effects of ranibizumab in patients with subfoveal choroidal neovascularization attributable to age-related macular degeneration. *Am J Ophthalmol*. 2009;147(5):831-7.
32. Eng KT, Kertes PJ. Ranibizumab in neovascular age-related macular degeneration. *Clin Interv Aging*. 2006;1(4):451-66.
33. Basheer K, Mensah E, Khanam T, Minakaran N. Visual outcomes of age-related macular degeneration patients undergoing intravitreal ranibizumab monotherapy in an urban population. *Clin Ophthalmol*. 2015;9:959-65.
34. Bhisitkul RB, Mendes TS, Rofagha S, et al. Macular atrophy progression and 7-year vision outcomes in subjects from the ANCHOR, MARINA, and HORIZON studies: the SEVEN-UP study. *Am J Ophthalmol*. 2015;159(5):915-24.e2.
35. Regillo CD, Brown DM, Abraham P, et al. Randomized, double-masked, sham-controlled trial of ranibizumab for neovascular age-related macular degeneration: PIERS study year 1. *Am J Ophthalmol*. 2008;145:239-248 (2008).
36. Boyer DS. Safety and efficacy of ranibizumab in subjects with wet age-related macular degeneration: SAILOR cohorts 1 and 2. Presented at: American Academy of Ophthalmology 2008 Annual Meeting. Atlanta, GA, 8-11 November 2008.
37. Busbee BG, Ho AC, Brown DM, et al. HARBOR Study Group. Twelve-month efficacy and safety of 0.5 mg or 2.0 mg ranibizumab in patients with subfoveal neovascular age-related macular degeneration. *Ophthalmology*. 2013 May;120(5):1046-56.
38. Colquitt JL, Jones J, Tan SC, et al. Ranibizumab and pegaptanib for the treatment of age-related macular degeneration: a systematic review and economic evaluation. *Health Technol Assess*. 2008;12(16):iii-iv, ix-201.
39. Schumcker C, Ehken C, Hansen LL, et al. Intravitreal bevacizumab (Avastin) vs. ranibizumab (Lucentis) for the treatment of age-related macular degeneration: a systematic review. *Curr Opin Ophthalmol*.

Study: Eylea Leads the Pack for Some DME Patients

By Rebecca Hepp, Senior Associate Editor

Laser photocoagulation was once considered the standard treatment for DME. But new evidence has led to a shift toward the use of anti-VEGF injections. A study published earlier this year set out to compare the efficacy and safety of anti-VEGF agents Eylea (afibercept, Regeneron), Avastin (bevacizumab, Genentech) and Lucentis (ranibizumab, Genentech). Generally considered to be comparable for most indications, the three agents were tested to identify potential agent-specific distinctions in patient response. That report, published in the *New England Journal of Medicine*, generated some interesting results.¹

Protocol T

Researchers from the Diabetic Retinopathy Clinical Research Network, through a randomized clinical trial called Protocol T, funded by the National Institutes of Health, found that Eylea provided more visual improvement for study participants with initial visual acuity of 20/50 or worse—a mean improvement of 19 letters on the visual acuity score, compared with 12 for Avastin and 14 for Lucentis. The same was not the case for participants with visual acuity between 20/32 and 20/40, however, as all three groups showed similar improvement: an eight-letter gain on average for each of the three drugs. In addition to studying visual acuity measures, researchers noted all three drugs also decreased retinal thickness, but more so for the Eylea and Lucentis groups than the Avastin group. Similar to the visual acuity measures, the treatment effect varied according to initial visual acuity. The study included 660 adults with either Type 1 or Type 2 diabetes, center-involved DME and at least one eye with visual acuity of 20/32 or worse.

Clinical Implications

Optometrists comanaging DME patients “should try to work with retina specialists who have a good understanding of the role of all three drugs,” Paul M. Karpecki, OD, recommends. “A patient who has DME and vision worse than 20/50 should likely be receiving Eylea if an anti-VEGF is the treatment of choice,” he says. Earlier studies have indicated approximately 75% of DME patients present with visual acuity of 20/40 or better.²

1. The Diabetic Retinopathy Clinical Research Network. Afibercept, bevacizumab, or ranibizumab for diabetic macular edema. *N Engl J Med*. DOI: 10.1056/NEJMoa1414264.
2. Early Treatment Diabetic Retinopathy Study Research Group. Focal photocoagulation treatment of diabetic macular edema—relationship of treatment effect to fluorescein angiographic and other retinal characteristics at baseline: ETDRS report no. 19. *Arch Ophthalmol*. 1995;113:1144-55.

- 2010;21(3):218-26.
40. Berg K, Pedersen TR, Sandvik L, Bragadottir R. Comparison of ranibizumab and bevacizumab for neovascular age-related macular degeneration according to LUCAS treat-and-extend protocol. *Ophthalmology*. 2015;122(1):146-52.
41. Martin D, Maguire M, Ying G, Grunwald, J. CATT Research Group. Ranibizumab and Bevacizumab for Neovascular Age-Related Macular Degeneration. *N Engl J Med*. 2011;364(20):1897-1908.
42. Raftery J, Clegg A, Jones J, et al. Ranibizumab (Lucentis) versus bevacizumab (Avastin): modelling cost effectiveness. *Br J Ophthalmol*. 2007;91(9):1244-6.
43. Regeneron Pharmaceuticals, Inc. Eylea (afibercept) Injection, For Intravitreal Injection. Aryto, NY: Regeneron Pharmaceuticals, 2011. Package insert.
44. Dixon JA, Oliver SC, Olson JL, Mandava N. VEGF Trap-Eye for the treatment of neovascular age-related macular degeneration. *Expert Opin Investig Drugs*. 2009;18(10):1573-80.
45. Ferrone PJ, Anwar F, Naysan J, et al. Early initial clinical experience with intravitreal afibercept for wet age-related macular degeneration. *Br J Ophthalmol*. 2014;98 Suppl 1:i17-21.
46. Böhm SC, Bittner M, Howell JP, et al. Comparison of Eylea with Lucentis as first-line therapy in patients with treatment-naïve neovascular age-related macular degeneration in real-life clinical practice: retrospective case-series analysis. *BMC Ophthalmol*. 2015;15:109.
47. Sivaprasad S, Prevost AT, Bainbridge J, et al. Clinical efficacy and

mechanistic evaluation of afibercept for proliferative diabetic retinopathy (acronym CLARITY): a multicentre phase IIb randomised active-controlled clinical trial. *BMJ Open*. 2015;5(9):e008405.

48. Bandello F, Cicinelli MV, Parodi MB. Anti-VEGF molecules for the management of diabetic macular edema. *Curr Pharm Des*. 2015. [Epub]
49. Agarwal A, Afridi R, Hassan M, et al. Novel therapies in development for diabetic macular edema. *Curr Diab Rep*. 2015;15(10):652.
50. Tsai HT, Marshall JL, Weiss SR, et al. Bevacizumab use and risk of cardiovascular adverse events among elderly patients with colorectal cancer receiving chemotherapy: a population-based study. *Ann Oncol*. 2013 Jun;24(6):1574-9.
51. Thulliez M, Angoultant D, Le Lez ML, et al. Cardiovascular events and bleeding risk associated with intravitreal anti-vascular endothelial growth factor monoclonal antibodies: systematic review and meta-analysis. *JAMA Ophthalmol*. 2014 Nov;132(11):1317-26.
52. Arnold JJ, Campain A, Barthelmes D, et al. Fight Retinal Blindness Study Group. Two-year outcomes of “treat and extend” intravitreal therapy for neovascular age-related macular degeneration. *Ophthalmology*. 2015 Jun;122(6):1212-9.
53. Wong WT, Dresner S, Feroozghan F, et al. Treatment of geographic atrophy with subconjunctival sirolimus: results of a phase III clinical trial. *Invest Ophthalmol Vis Sci*. 2013;54(4):2941-50.
54. Ophthotech. Ophthotech Fovista Comments. Web. 1 Sept. 2015. www.ophthotech.com/product-candidates/fovista.

The Optometrist's Role in Anti-VEGF Therapy

As we provide the first line of defense, the process begins in our offices—and often returns there following injection. By Julie Torbit, OD, and Brad Sutton, OD

THROUGHOUT THE PAST decade, anti-VEGF injections have dramatically changed how vision-threatening retinal disease is managed in the United States and around the world, especially for commonly encountered conditions such as neovascular age-related macular degeneration (AMD), diabetic macular edema (DME) and retinal vein occlusion. Over time, the off-label use of these agents has become commonplace in less frequently encountered, non-AMD conditions as well, such as choroidal neovascular membranes arising from sickle cell and other proliferative retinopathies, macular telangiectasia, intraocular tumors, neovascular glaucoma and retinopathy of prematurity.

This article provides an overview of these formulations, how they work and the optometrist's role in comanaging patients using them.

Pharmaceutical Treatments

Comanaging ODs should remain aware of the pharmaceutical options available to patients, as new treatments have come on the market in recent years and indications continue to expand. The original medication to achieve FDA approval was Macugen (pegaptanib sodium, Pfizer and OS/Eyetech Pharmaceuticals) in 2004. It was approved only for the treatment of neovascular AMD. While Macugen has fallen out of favor as newer anti-VEGF compounds have been developed, it does have one major advantage: its recommended dosing schedule is once every six weeks, as opposed to monthly.¹ However, this potential advantage has been

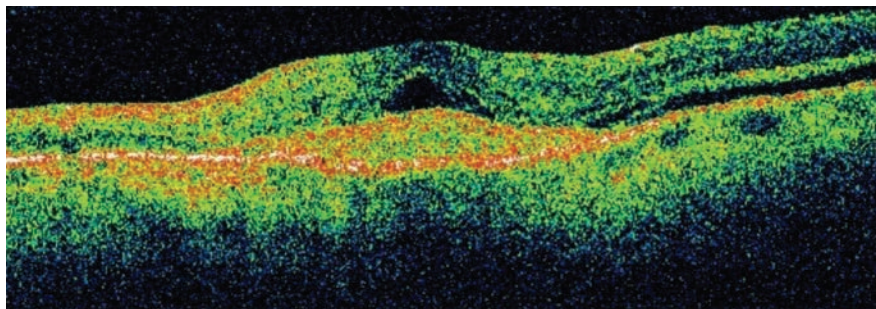


Fig. 1. This OCT image shows an eye with neovascular AMD.

minimized by as-needed treat-and-extend approaches being employed, with newer agents that also offer improved efficacy.

Within a few years of Macugen's approval, Lucentis (ranibizumab, Genentech) received FDA approval to treat neovascular AMD, and later, macular edema secondary to retinal vein occlusions and diabetic retinopathy. The recommended dosing schedule for Lucentis is one injection per month until the patient stabilizes, and then it's given based on different protocols such as on an as-needed basis.²

The most commonly used agent is likely Avastin (bevacizumab, Genentech), a drug approved to treat colorectal cancer that does not have FDA approval for use in the eye. However, because the price of Avastin is substantially lower than that of the other drugs, it has been widely used off-label by retina specialists to treat several retinal vascular diseases.

Eylea (afibercept, Regeneron) is the latest compound to receive FDA approval for treatment of neovascular AMD. It has also been approved for use in macular edema due to diabetic retinopathy and retinal vein

occlusion. The recommended dose for Eylea is 2mg every eight weeks after an induction period of three monthly injections.³

Monitoring

Optometrists are in a perfect position to detect pathology early and make an appropriate referral to a retina specialist. A thorough dilated eye examination serves as the entry point to any intervention the patient may ultimately require. Careful observation of the macula, posterior pole and peripheral fundus—along with optometry's mainstay, visual acuity testing—allows practitioners to discover areas of potential concern. After a condition is discovered and diagnosed, several imaging technologies play a key role in determining the need for intervention vs. observation.

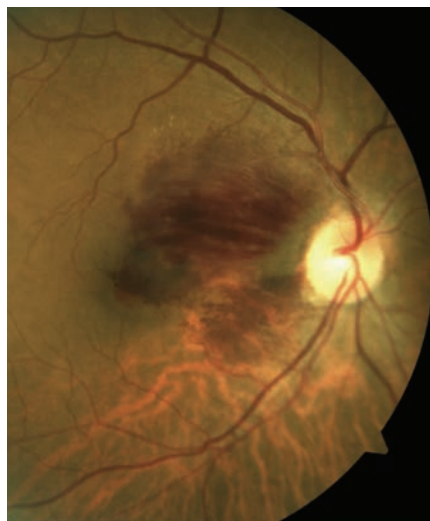
- **OCT.** Optical coherence tomography can be particularly useful because of its ability to detect retinal and subretinal fluid in patients with neovascular AMD, as well as its ability to image pigment epithelial detachments and even the choroidal neovascular membrane itself (*Figure 1*). These findings are often quite subtle upon observation

and are only discovered when performing OCT scans.

OCT is also extremely useful in detecting and quantifying macular edema in patients with vein occlusions or diabetic retinopathy. For example, you can detect and continue to monitor nonproliferative diabetic retinopathy and edema located well outside of the foveal area (frequently referred to as non-center-involved DME); at the same time, you can make the appropriate referral for intervention if you discover center-involved DME. The distinction between these two situations can be made relatively easily using OCT technology.

Regarding retinal vein occlusions, both central retinal vein occlusion and branch vein occlusion with associated macular edema require referral for intervention, while a branch vein occlusion without macular edema can be monitored unless other complications such as retinal neovascularization is noted (*Figure 2*). As with DME, optometrists can precisely locate and quantify any edema associated with a vein occlusion using OCT.

• *Other imaging technologies.* In addition to OCT, other diagnostic



imaging devices and technologies can help clinicians diagnose and manage retinal vascular disease. Fundus photography is particularly useful to augment and document serial observation, and it's readily available in many optometric practices.

Fluorescein and indocyanine green angiography can help evaluate retinal neovascularization and edema, but are far less likely to be available in non-specialty optometric practices than an OCT device.

The same is true for potential hyperacuity evaluation with the Foresee PHP (Reichert). This technology can be used both in office and in home with an Internet connection. It uses vertical Vernier acuity bars to detect visual field distortions associated with neovascular changes in AMD (*Figure 3*). Early detection of these visual field distortions can occur even before observable fundus changes, which allows optometrists to refer and provide patients with rapid intervention with anti-VEGF agents and improved visual outcomes.⁴

Clinical Care

After determining the need for a referral, it's up to the optometrist to educate the patient about the condition. Patients should be instructed to expect intraocular injections, and optometrists can help allay their inherent fears surrounding receiving multiple shots in the eye. Currently, no established clinical care guidelines exist between optometry and oph-

thalmology regarding comanaged care of intravitreal injections.

With a few exceptions, the optometrist's main role is to provide appropriate diagnosis and referral, then provide primary care services to these patients once their disease process has been stabilized, including close observation for disease reactivation. Optometrists working in integrated, referral-based practice settings may be more involved with post-injection care at an earlier stage, as may optometrists who practice in very rural settings where repeated, long distance travel to a retinal specialist presents a challenge for patients.

Comanaging Complications

Like all procedures, intravitreal injection of anti-VEGF agents is accompanied by potential risk. When administered systemically, these agents can raise arterial blood pressure and reduce vascular permeability, which could potentially increase the risk for developing arterial thromboembolic events (ATE). These are defined as nonfatal stroke and myocardial infarction or vascular death.^{5,6} To date, clinical trial data has not definitely demonstrated this risk, as multiple studies have reached contradictory conclusions.⁷⁻¹¹

The most significant and most feared ocular risk is endophthalmitis. Multiple large retrospective studies have found that endophthalmitis occurs in roughly one out of every

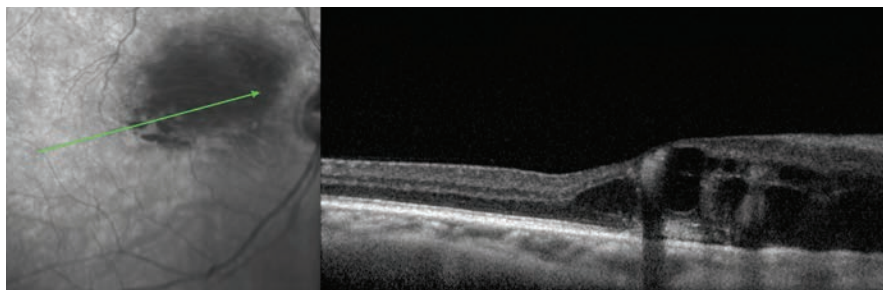


Fig. 2. These images portray a patient with branch retinal vein occlusion with macular edema.

Photos: Mohammad Rafieary, OD

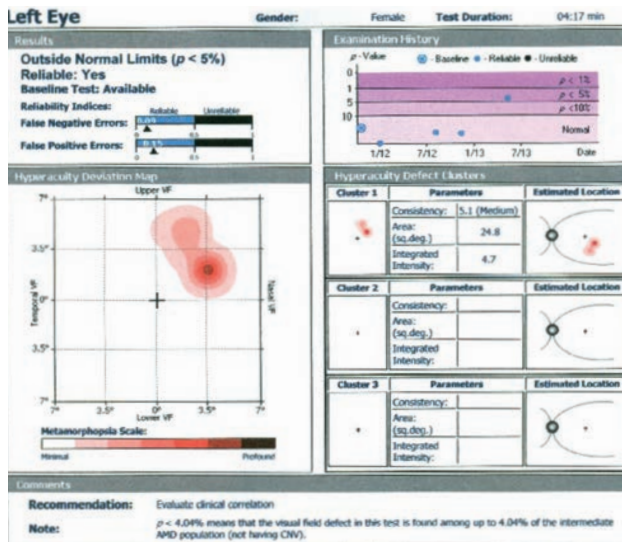
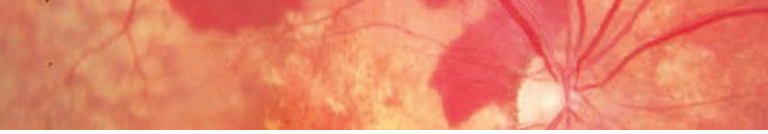


Fig. 3. Foresee PHP uses vertical Vernier acuity bars to detect visual field distortions associated with neovascular changes in AMD with defect, as is seen in this patient's print-out.

5,000, or 0.02%, anti-VEGF injections.¹² Many times, the causative agents are streptococcal species, which are particularly virulent and often lead to poor visual outcomes.^{13,14}

Several years ago, concern was raised regarding whether endophthalmitis was more likely to occur with Avastin, because it is a compounded medication, after an outbreak was traced to tainted vials that had been improperly prepared.¹⁵ Avastin can be contaminated during the compounding process, transportation from the pharmacy or during the storage of the drug, and outbreaks of endophthalmitis have been traced to improper techniques employed by specific compounding pharmacies.¹⁵ However, a large national study examining over 383,000 anti-VEGF injections showed no evidence of increased endophthalmitis risk with Avastin compared with Lucentis, which is not compounded.¹⁶ In fact, the rate of endophthalmitis in this study was found to be slightly lower with Avastin compared with Lucentis.¹⁶ In addition, the rate of endophthalmitis in

this study seen with intravitreal steroid injections is approximately seven times the rate encountered with anti-VEGF injections.¹⁷ These studies provide evidence that restricting the use of Avastin because it is a compounded medication may be unnecessary, and supports the idea that Avastin does not need additional regulation as long as there is strict adherence to current compounding protocols and practice

standards.¹⁶

Previously, pre- or post-injection topical antibiotics, or both, were given to reduce the risk of endophthalmitis.¹⁸ However, we now know this does not decrease the risk of endophthalmitis and is actually thought to create more antibiotic resistant bacteria.²¹ As a result, the use of pre- and post-injection prophylactic antibiotics is no longer advocated.^{19,20} However, many retina specialists have a “no talking” policy during the injection to lessen the potential spread of airborne pathogens, and some even advocate the wearing of surgical masks to further decrease risk.^{21,22}

Patients who do develop endophthalmitis often present with decreased vision, severe eye pain that worsens over time, photophobia, floaters, conjunctival injection, corneal edema, corneal keratic precipitates, substantial anterior chamber reaction with hypopyon and vitritis with decreased red reflex.²³ While this can occur up to a few weeks after the injection, it is most commonly encountered within the first several days, with day four post-injection

being the average onset of symptoms.²⁴

If any signs of endophthalmitis are present, an immediate referral back to the surgeon is necessary. Pseudo-endophthalmitis (which is sterile) is also a possibility, and can be extremely difficult to differentiate from true endophthalmitis. It occurs when there is a reaction to the drug or preservative in the injection, similar to what is seen with toxic anterior segment syndrome (TASS) after cataract surgery. It typically occurs within the first 24 to 48 hours, but can occur up to one week after the injection.²⁷⁻²⁹ A reaction usually produces greater anterior than posterior segment inflammation, and it is often accompanied by better vision and less severe pain than true endophthalmitis.^{25,26} Differentiating between endophthalmitis and pseudo-endophthalmitis often requires a vitreous tap, and injection of antibiotics may be performed as a precaution. Due to the potentially devastating loss of vision that can accompany true endophthalmitis, err on the side of caution.

Elevated IOP

Another common adverse reaction to intravitreal injection is superficial keratitis associated with the Betadine preparatory solution, which is used to sterilize the ocular surface. Eye pain that lessens over time is more likely due to the sterilizing solution, and artificial tears can help alleviate the discomfort immediately following injection.²⁸ Though rare, other risks with anti-VEGF treatment include retinal breaks or detachments, RPE tears, vitreous hemorrhage and elevated intraocular pressure (IOP) (Figure 4).^{7,10,27,28}

Of these, elevated IOP is by far the most common, with studies showing up to 11% of patients receiving chronic anti-VEGF compounds have

significant and sustained IOP elevations.^{29,33} While this risk is much lower than the risk of elevated IOP with intravitreal steroid injections, it is potentially significant nonetheless, especially in patients with pre-existing glaucoma. Short-term elevations in IOP are quite common because of the sudden intraocular fluid increase in the globe following injections. Generally speaking, IOP stabilizes within 30 minutes after injection without intervention.^{34,35}

Sustained increases in IOP may require the use of topical glaucoma medications or, rarely, surgical intervention.^{30,31,33} The exact mechanism of sustained ocular hypertension is controversial. Researchers speculate that repeated anti-VEGF injections raise IOP through trabecular dysfunction from repeated IOP spikes, toxicity to the drug or an immunologic reaction that causes inflammation.³⁶⁻³⁸ Furthermore, impaired trabecular meshwork outflow might occur from the anti-VEGF agents themselves, protein aggregates or silicone oil used to lubricate the syringes, which leads to a sustained increase in IOP.^{36,39}

Debate still exists regarding risk factors for sustained IOP after anti-VEGF injection. Risk factors reported

in the literature include: pre-existing diagnosis of glaucoma or ocular hypertension, elevated IOP at baseline, frequent injections and shorter time intervals between injections (<8 weeks).^{31,36,40} Even in the absence of risk factors, it is important that comanaging optometrists regularly monitor the IOP of all patients who undergo anti-VEGF injections.

Geographic Atrophy

An emerging area of concern with repeated anti-VEGF injections is the potential for the development or worsening of geographic atrophy (GA) in patients with macular degeneration (*Figure 5*). Mouse studies show VEGF plays an important role in the health and maintenance of the choriocapillaris.^{41,42} Investigators believe that therapies that block VEGF could lead to the development and progression of GA via damage to the choriocapillaris.⁴³

The frequency of injections also appears to play a role in GA development. Both the CATT and IVAN studies found a higher incidence of geographic atrophy when anti-VEGF injections were given on a monthly vs. an as-needed (PRN) basis for exudative macular degeneration.^{43,44} CATT investigators in particular

noted that monthly injections were associated with a 59% increase in risk of GA development compared with injections given PRN.⁴⁴ Within two years of beginning treatment, nearly 20% of patients in the CATT study developed GA.

Interestingly, those researchers also found a lower rate of GA when there was a higher amount of residual fluid on the OCT. This led the authors to speculate that excessive drying of the retina may promote the development of geographic atrophy, and may actually be counterproductive over time.⁴³

Currently, practitioners face a challenging dilemma. Anti-VEGF therapy has drastically changed how eye care practitioners manage neovascular AMD, and it is clearly the most effective means we have at our disposal today to preserve visual function in this devastating disease. Their chronic use, however, brings with it a host of potential concerns. It is becoming apparent that repeated injections have the ability to promote geographic RPE atrophy over time, thus potentially negatively impacting vision.⁴⁵ For now, limiting the number of injections to the minimum amount necessary appears to be warranted.

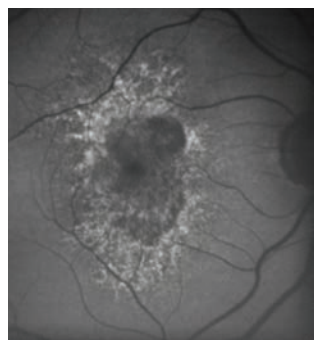


Fig. 4a. OCT and FAF before anti-VEGF therapy demonstrating an RPE tear.

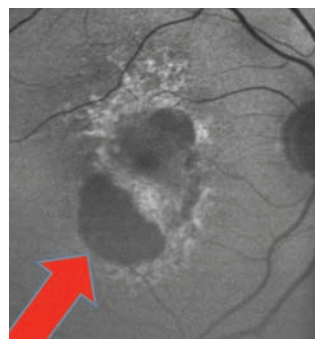
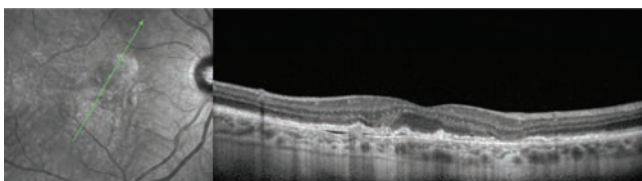
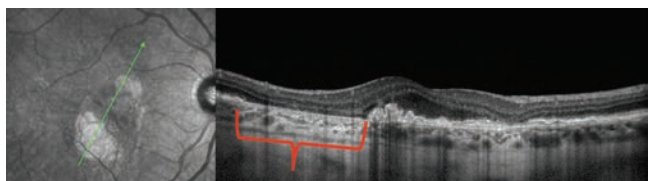


Fig. 4b. OCT and FAF of the same eye after anti-VEGF therapy.



Photos: Mohammed Rafeeq, OD

By evaluating patients and realizing the need for intervention, counseling patients on what to expect with treatment, and recognizing injection related complications, optometrists continue to play a vital role in the overall management of patients requiring anti-VEGF therapy. ■

Dr. Torbit is an associate clinical professor at Indiana University School of Optometry and a member of the Optometric Retina Society.

Dr. Sutton is a clinical professor at Indiana University School of Optometry and Service Chief of the Indianapolis Eye Care Center in Indianapolis, Ind. and the president of the Optometric Retina Society.

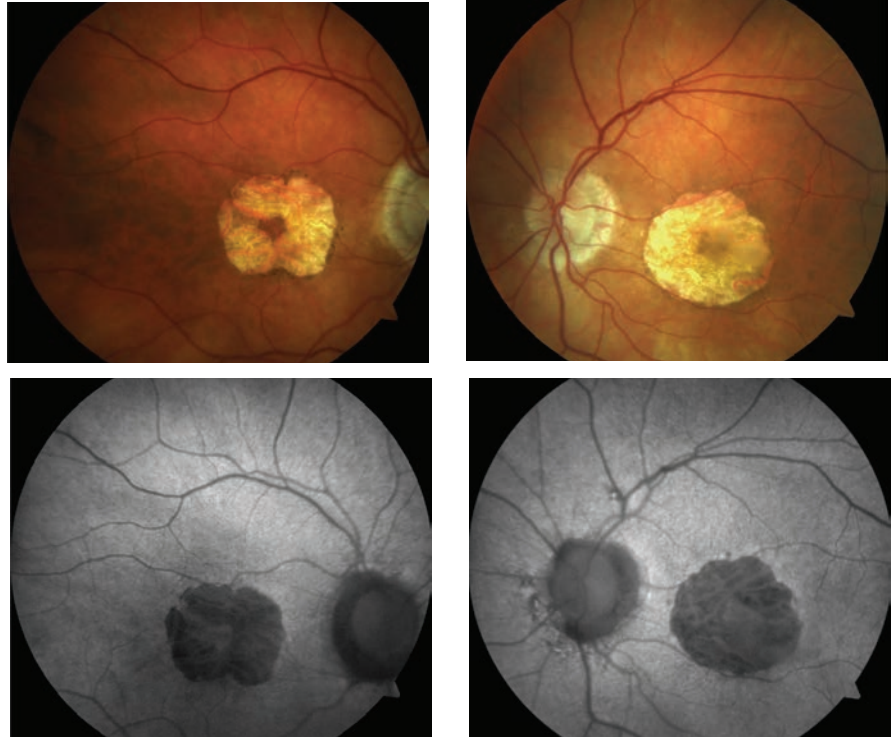


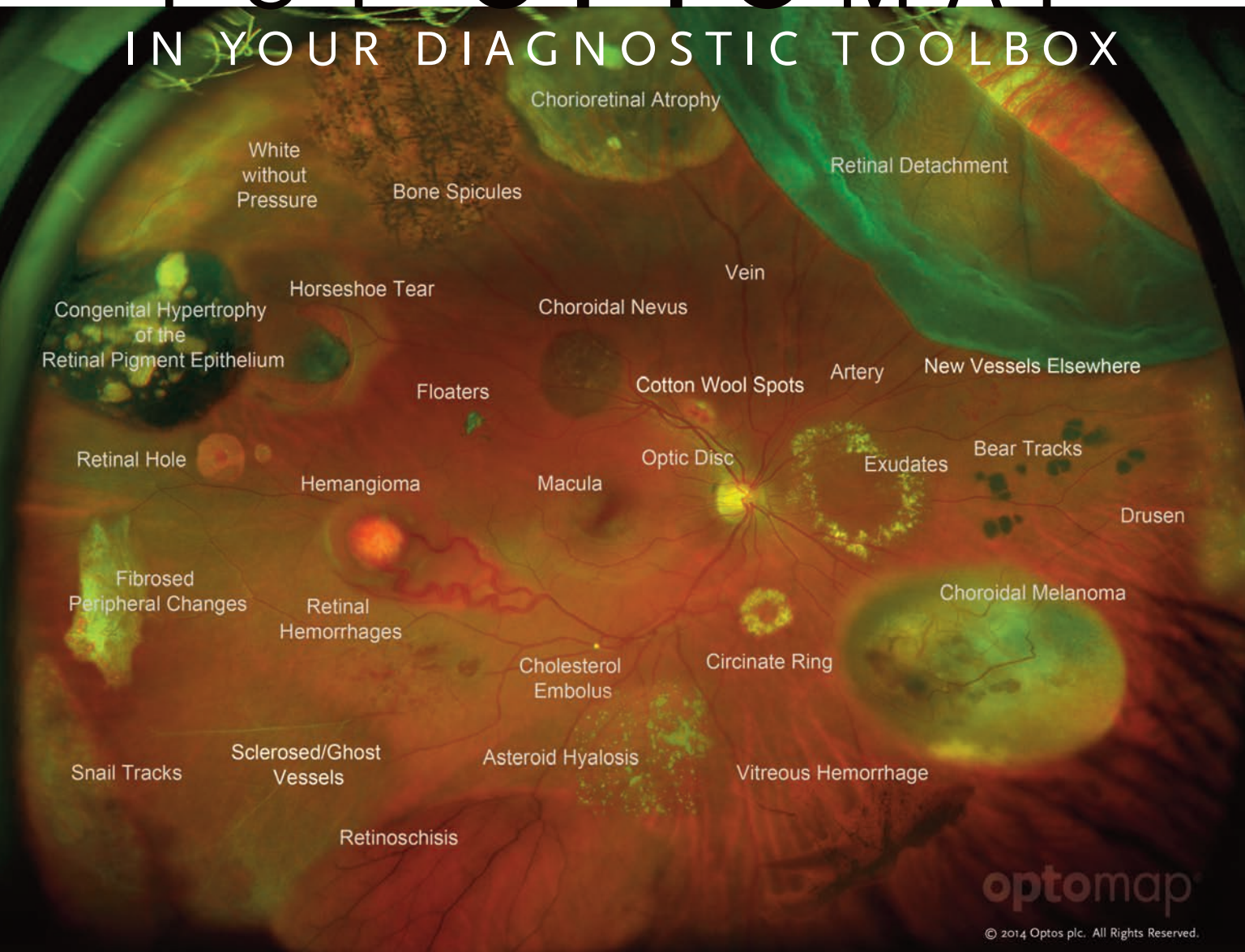
Fig. 5. Fundus and FAF images show a patient with geographic AMD in both eyes.

1. Alfaro VD. Age-related Macular Degeneration: A Comprehensive Textbook. Philadelphia: Lippincott, Williams & Wilkins; 2006:283
2. Lucentis (package insert). South San Francisco, CA: Genentech. 2013. www.gene.com/download/pdf/lucentis_prescribing.pdf.
3. Regeneron announces FDA approval of EYLEA (afibercept) injection for the treatment of wet age-related macular degeneration [press release]. Tarrytown, NY: Regeneron Pharmaceuticals, Inc; November 18, 2011.
4. Chew EY, Clemons TE, Bressler SB, et al. Randomized trial of a home monitoring system for early detection of choroidal neovascularization home monitoring of the eye (HOME) study. *Ophthalmology* 2014;121:535-44.
5. Stewart M. The expanding role of vascular endothelial growth factor inhibitors in ophthalmology. 2012 Mayo Foundation for Medical Education and Research. *Mayo Clin Proc*. 2012;87(1):77-88.
6. Semeraro F, Morescalchi F, Parmeggiani F, et al. Systemic adverse drug reactions secondary to anti-VEGF intravitreal injection in patients with neovascular age-related macular degeneration. *Curr Vasc Pharmacol*. 2011 Sep;9(5):629-46.
7. Tolentino M. Systemic and ocular safety of intravitreal anti-VEGF therapies for ocular neovascular disease. *Surv Ophthalmol*. 2011 Mar-Apr;56(2):95-113.
8. Moja L, Lucenteforte E, Kwag KH, et al. Systemic safety of bevacizumab versus ranibizumab for neovascular age-related macular degeneration. *Cochrane Database Syst Rev*. 2014 Sep 15;9:CD011230.
9. Ahfat FG, Zaidi FH. Bevacizumab vs. ranibizumab—an appraisal of the evidence from CATT and IVAN. *Eye*. 2014;27:289-90.
10. Falavarjani KG, Nguyen QD. Adverse events and complications associated with intravitreal injection of anti-VEGF agents: a review of literature. *Eye*. 2013;27:787-94.
11. Schmucker C, Loke YK, Ehklen C, et al. Intravitreal bevacizumab (Avastin) versus ranibizumab (Lucentis) for the treatment of age-related macular degeneration: a safety review. *Br J Ophthalmol*. 2011;95(3):308-17.
12. Moshfeghi AA, Rosenfeld PJ, Flynn HW Jr, et al. Endophthalmitis after intravitreal vascular [corrected] endothelial growth factor antagonists: A six-year experience at a university referral center. *Retina*. 2011;31:662-8.
13. Flieta JB, Scott IU, Flynn Jr. HW. Meta analysis of infectious endophthalmitis after intravitreal injection of anti-vascular endothelial growth factor agents. *Ophthalmic Surg Lasers Imaging Retina*. 2014;143-9.
14. McCannel CA. Meta-analysis of endophthalmitis after intravitreal injection of anti-vascular endothelial growth factor agents. *Retina*. 2011;31:654-61.
15. Gonzalez S, Rosenfeld PJ, Stewart MW, et al. Avastin doesn't blind people, people blind people. *Am J Ophthalmol*. 2012;153:196-203.
16. VanderBeek BL, Bonaffini SG, Liyuan BS. Association of compounded bevacizumab with postinjection endophthalmitis. *JAMA Ophthalmol*. August 13, 2015. [Epub].
17. VanderBeek BL, Bonaffini SG, Liyuan MA. The association between intravitreal steroids and post-injection endophthalmitis rates. *Ophthalmology*. 2015;1-5.
18. Jager RD, Aiello LP, Patel SC, Cunningham ET Jr. Risks of intravitreal injection: A comprehensive review. *Retina*. 2004;24:676-98.

19. Kim SJ, Toma HS. Antimicrobial resistance and ophthalmic antibiotics: 1-year results of a longitudinal controlled study of patients undergoing intravitreal injections. *Arch Ophthalmol*. 2011;129:1180-8.
20. Kim SJ, Toma HS. Ophthalmic antibiotics and antimicrobial resistance: A randomized, controlled study of patients undergoing intravitreal injections. *Ophthalmology*. 2011;118:1358-63.
21. Doshi RR, Leng T, Fung AE. Reducing oral flora contamination of intravitreal injections with face mask or silence. *Retina*. 2012;32(3):473-6.
22. Wen JC, McCannel CA, Mochon AB, Garner OB. Bacterial dispersal associated with speech in the setting of intravitreal injections. *Arch Ophthalmol*. 2011;129(12):1551-4.
23. Kernt M, Kampik A. Endophthalmitis: Pathogenesis, clinical presentation, management, and perspectives. *Clinical Ophthalmology*. 2010;4:121-35.
24. Durand ML. Endophthalmitis. *Clin Microbiol Infect*. 2013 Mar;19(3):227-34.
25. Agrawal S, Joshi M, Christoforidis JB. Vitreous inflammation associated with intravitreal anti-VEGF pharmacotherapy. *Mediators of Inflammation*. 2013. <http://dx.doi.org/10.1155/2013/943409>.
26. Maricorena J, Romano V, Francisco G. Sterile Endophthalmitis after Intravitreal Injections. *Mediators of Inflammation*. 2012. doi:10.1155/2012/928123.
27. Mezd-Koursh D, Goldstein M, Heilwail G, et al. Clinical characteristics of endophthalmitis after an injection of intravitreal anti-vascular endothelial growth factor. *Retina*. 2010;30:1051-7.
28. Dogulzi S, Ozdek S. Pigment epithelial tears associated with anti-VEGF therapy: incidence, long-term visual outcome, and relationship with pigment epithelial detachment in age-related macular degeneration. *Retina*. 2014 Jun;34(6):1156-62.
29. Tseng JJ, Vance SK, Della Torre KE, et al. Sustained increased intraocular pressure related to intravitreal anti vascular endothelial growth factor therapy for neovascular age-related macular degeneration. *J Glaucoma*. 2012 Apr-May;21(4):241-7.
30. Choi DY, Ortube MC, McCannel CA, et al. Sustained elevated intraocular pressures after intravitreal injection of bevacizumab, ranibizumab, and pegaptanib. *Retina*. 2011 Jun;31(6):1028-35.
31. Good TJ, Kimura AE, Mandava N, et al. Sustained elevation of intraocular pressure after intravitreal injections of anti-VEGF agents. *Br J Ophthalmol*. 2011 Aug;95(8):1111-4.
32. Mathalone N, Arodi-Golan A, Sar S, et al. Sustained elevation of

- intraocular pressure after intravitreal injections of bevacizumab in eyes with neovascular age-related macular degeneration. *Graefes Arch Clin Exp Ophthalmol*. 2012;250:1435-40.
33. Skalicky S, Ho I, Agar A, et al. Glaucoma filtering surgery following sustained elevation in IOP secondary to anti-VEGF injections. *Ophthalmic Surg Lasers Imaging*. 2012 Jul 1;43(4):328-34.
34. Sobaci G, Gungor R, Ozge G. Effects of multiple intravitreal anti-VEGF injections on retinal nerve fiber layer and intraocular pressure: a comparative clinical study. *Int J Ophthalmol*. 2013 Apr;6(2).
35. Lemos-Reis R, Moreira-Gonçalves N, Melo AB, et al. Immediate effect of intravitreal injection of bevacizumab on intraocular pressure. *Clinical Ophthalmology*. 2014;8:1383-8.
36. Hoang QV, Mendonca LS, Della Torre KE, et al. Effect on intraocular pressure in patients receiving unilateral intravitreal anti-vascular endothelial growth factors on cultured human trabecular meshwork cells. *J Glaucoma*. 2010 Sep;19(7):437-41.
37. Kahook MY, Ammar DA. In vitro effects of anti-vascular endothelial growth factors on cultured human trabecular meshwork cells. *J Glaucoma*. 2010 Sep;19(7):437-41.
38. Sniogowski M, Mandava N, Kahook MY. Sustained intraocular pressure elevation after intravitreal injection of bevacizumab and ranibizumab associated with trabeculitis. *Open Ophthalmol J*. 2010 Jun 22;4:28-9.
39. Liu L, Ammar DA, Ross LA, et al. Silicone oil microdroplets and protein aggregates in repackaged bevacizumab and ranibizumab: effects of long-term storage and product mishandling. *Invest Ophthalmol Vis Sci*. 2011 Feb 22;52(2):1023-34.
40. Agard EA, Elchehab H, Ract-Madoux G. Repeated intravitreal anti-vascular endothelial growth factor injections can induce iatrogenic ocular hypertension, especially in patients with open-angle glaucoma. *Clin J Ophthalmol*. 2015;50:127-131.
41. Ebrahem Q, Qi JH, Sugimoto M. Increased neovascularization in mice lacking tissue inhibitor of metalloproteinases-3. *Invest Ophthalmol Vis Sci*. 2011 Aug;52(9):6117-23.
42. Saint-Geniez M, Kurihara T, Sekiyama E, et al. An essential role for RPE-derived soluble VEGF in the maintenance of the choriocapillaris. *Proc Natl Acad Sci USA*. 2009;106:18751-6.
43. Grunwald JE, Daniel E, Huang J, et al. CATT Research Group. Risk of geographic atrophy in the Age-related Macular Degeneration Treatment Trials. 2014 Jan;121(1):150-61.
44. Chakravarthy U, Harding SP, Rogers CA, et al. IVAN study investigators. Alternative treatments to inhibit VEGF in age-related choroidal neovascularization: 2-year findings of the IVAN randomized controlled trial. *Lancet*. 2013 Oct 12;382(9900):1258-67.

PUT OPTOMAP IN YOUR DIAGNOSTIC TOOLBOX



See More and Treat More. Effectively.

- **Only optomap®** provides up to a 200° view of the retina in a single capture
- **The only** ultra-widefield, ultra-high definition color, autofluorescence and red-free retinal imaging device
- Simultaneous evaluation of the peripheral and central retina
- Clinically supported by more than 300 studies

Interested in adding ultra-widefield and ultra-widefield *af* capabilities to your practice?

Contact us today 800-854-3039
or email BDS@optos.com

Building *The* Retina Company


optos.com

As your dedicated partner in eye care
We Re-Envision Vision



Meeting the need. An increasing aging and diabetic population gives way to an increased number of patients diagnosed with retinal diseases. Regeneron is committed to delivering targeted therapies that can impact your patients' vision.

Learn more about our *science to medicine* approach at Regeneron.com.

REGENERON
science to medicine[®]

science to medicine is a registered trademark of Regeneron Pharmaceuticals, Inc.

©2015, Regeneron Pharmaceuticals, Inc.,
777 Old Saw Mill River Road, Tarrytown, NY 10591

All rights reserved

02/2015
RGN-0237