

A SUPPLEMENT TO

REVIEW[®] OF OPTOMETRY

MAY 15, 2013

CLINICAL GUIDE TO

OPHTHALMIC DRUGS



By
Ron Melton, OD and Randall Thomas, OD

Supported by an Unrestricted Grant from

BAUSCH+LOMB[®]

Dear Colleagues,

The publication of this annual *Clinical Guide to Ophthalmic Drugs* over the past decade would not have been possible without the leadership and vision of Mr. Richard Bay, the publisher of *Review of Optometry*. Our dear friend Rick succumbed to cancer in December 2012. He was truly one of the finest people we have ever had the pleasure of working with. It is with a deep sense of appreciation to Rick that we dedicate this 2013 *Clinical Guide to Ophthalmic Drugs* in his memory.

We continue to be thankful to the entire *Review of Optometry* team and to Bausch + Lomb for partnering to make this annual drug guide available to the community of optometric professionals.


Because few new ophthalmic pharmaceuticals came to market this year, we have directed our focus on how best to provide treatment with the drugs we use frequently. Thankfully, there is an abundance of peer-reviewed professional literature that guides us to enhanced use of these medicines. Furthermore, we've included some non-drug-related clinical insights into the publication that we believe can enable a higher level of patient care. Do keep in mind that this drug guide is as "evidence-based" as is practical; but as full-time clinicians, it is also seasoned with 64 combined years of our own insight and intensive clinical experience in medically managing eye diseases. Everything written in this *Clinical Guide to Ophthalmic Drugs* is intended to enhance your patient care, and our fine profession.

We thank you for taking your time to read and study this annual work.

Our very best wishes to each of you,

Randall Thomas, OD, MPH

Ron Melton, OD



Disclosure: Drs. Melton and Thomas are consultants to, but have no financial interests in, the following companies: Alcon Laboratories, Bausch + Lomb, Carl Zeiss Meditec, Icare, and Nicox.

Supported by an unrestricted grant from

BAUSCH + LOMB

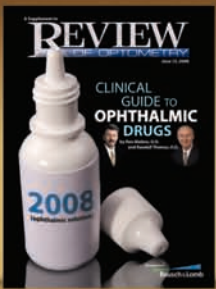
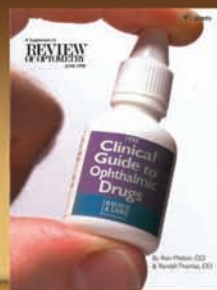





CONTENTS

Clinical Update on the NSAIDs	2A
A Clinical Look at Glaucoma	7A
AREDS2 and AMD	15A
Steroids	18A
Perspectives on Viral Eye Diseases.....	22A
Antibiotics.....	28A
Allergy Management	32A
Dry Eye Disease	35A
Medicine in Review.....	42A
Patient Handouts & Referral Forms.....	46A



A Peer-Reviewed Supplement

Note: The clinical views and advice expressed in this publication are those of the authors, and do not necessarily reflect those of the sponsor, Bausch + Lomb, or the publisher, *Review of Optometry*.



For more than 15 years, the annual *Clinical Guide to Ophthalmic Drugs* has been brought to you by Review of Optometry and supported by

BAUSCH+LOMB

Clinical Update on the NSAIDs

Topical NSAIDs are more applicable in perioperative care than in primary eye care; however, NSAIDs are useful in several clinical circumstances.

While oral NSAIDs are heavily used in systemic medicine, use of topical ophthalmic NSAIDs within nonsurgical eye care is relatively limited. The foundational perspective on this class of drugs is the acknowledgement that steroids reign supreme for inflammation control. Topical NSAIDs are never an appropriate substitute when the clinical condition merits a topical

corticosteroid.

NSAID use has much more applicability in perioperative care than in primary eye care; however, there are several clinical circumstances in which patient care can be enhanced through the use of such a drug.

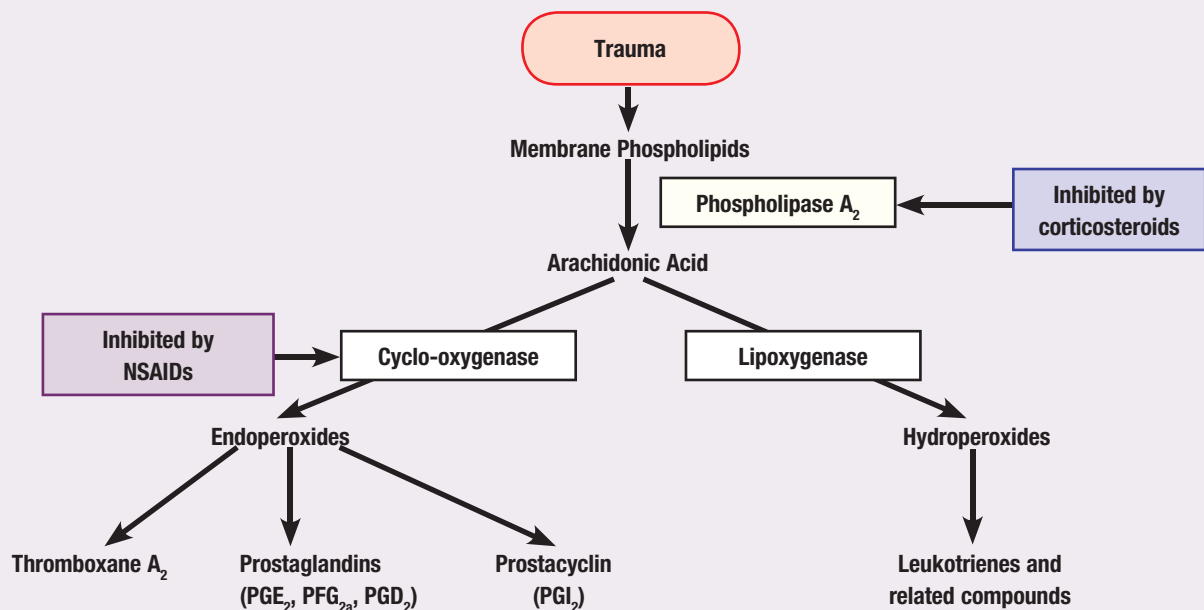
In 2013, the new entries in the topical NSAID group are advanced generations of two medicines with which we are all familiar: brom-

fenac (Xibrom and Bromday, and now in Prolensa) and nepafenac (Nevanac, and now in Ilevro).

Pharmacology of NSAIDs

Let's first understand the pharmacology of NSAIDs. First of all, they have less effect on inflammation than steroids because they target a lower site on the inflammation cascade. Specifically, they inhibit an enzyme along the

The Arachidonic Acid Pathway



Non-Steroidal Anti-Inflammatories

BRAND NAME	GENERIC NAME	MANUFACTURER	DOSAGE	PEDIATRIC USE	BOTTLE SIZE(S)
Acular LS	ketorolac tromethamine 0.4%	Allergan	QID	3 years	5ml
Acuvail	ketorolac tromethamine 0.45%	Allergan	BID	N/A	unit-dose
Ilevro	nepafenac 0.3%	Alcon	QD	10 years	1.7ml
Nevanac	nepafenac 0.1%	Alcon	TID	10 years	3ml
Prolensa	bromfenac 0.07%	Bausch + Lomb	QD	N/A	1.6ml, 3ml
Voltaren	diclofenac sodium 0.1%	Novartis	QID	N/A	2.5ml, 5ml

synthetic pathway to the production of prostaglandins, which are powerful mediators of inflammation. As doctors, it is vital that we have knowledge of this particular pathway, known as the arachidonic acid cascade.

As you can see in the diagram (*"The Arachidonic Acid Pathway," page 2a*), the origin substrate is phospholipids released from cell membranes as a generic response to multiple causes of cellular micro-trauma. Corticosteroids inhibit the conversion of these phospholipids to arachidonic acid by inhibiting the catalytic enzyme phospholipase A early in this synthetic cascade.

Once arachidonic acid (AA) is formed, two different enzymes convert it ultimately to either prostaglandin formation or leukotriene formation. Cyclooxygenase converts AA to prostaglandins, and lipoxygenase converts AA to leukotrienes. The key point here is that while NSAIDs inhibit the enzymatic activity of cyclooxygenase, they have no effect on lipoxygenase, thereby allowing the production of leukotrienes to go unchecked.

For clinical perspective, remember the early days of photorefractive keratectomy where NSAIDs were initially used postoperatively? Patients experienced problems with white blood cell corneal infiltrates until it was realized that steroids prevented their formation. Why? Leukotrienes are chemotactic for

leukocytes, for which NSAIDs do nothing because they only inhibit the synthesis of prostaglandins and have no activity against lipoxygenase-catalyzed production of leukotrienes.

Because steroids work higher up in the AA synthetic pathway, they inhibit both cyclooxygenase and lipoxygenase, thus inhibiting production of both prostaglandins and leukotrienes. They also bind to the steroid receptors on the nucleus of the cell to influence protein synthesis and the production of cytokines.

All this may sound like gibberish to some. The AA pathway is more easily grasped by studying the diagram, which illustrates the processes we have just described. Once you have a clear understanding of the AA pathway, then you can begin to prescribe with enhanced clinical authority and care.

Steroids and NSAIDs may demonstrate some synergy and therefore might be beneficial if used together (perhaps only if you administer the NSAID first and then add the steroid).

For example, standard-of-care treatment for postoperative cystoid macular edema is usually a topical NSAID (at its FDA-approved dosing frequency) and a potent corticosteroid. Contrarily, we find no literature supporting the use of both drug groups in the standard initial treatment of anterior uveitis. There is still a lot to be learned in how these drug classes modify tissue responses.

The Role of Topical NSAIDs

Compared to topical corticosteroids, NSAIDs have a limited role in primary eye care. Nonetheless, there are several situations in which NSAIDs can be beneficial.

Be aware that topical and systemic NSAIDs differ somewhat in effect. Systemic NSAIDs are true

Common Conditions That Call for Topical NSAIDs

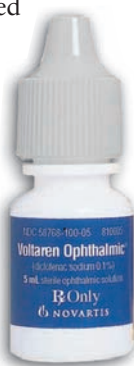These are the most common conditions for which topical NSAIDs can play an adjunctive beneficial role:

- Corneal abrasions
- Just before, and just after, in-office Betadine 5% Sterile Ophthalmic Prep Solution treatment for acute, symptomatic EKC
- Post foreign body removal
- Post anterior stromal puncture procedure
- Post PKP, or any surface-disruptive laser procedure
- Treating and/or preventing cystoid macular edema
- Adapting to punctal plugs
- Allergic conjunctivitis
- Some cases of photophobia
- Post cataract surgery care
- Supplemental to oral NSAIDs in treating scleritis
- Treating and/or preventing inflamed pterygia and pingueculae

NSAIDs

to their name and do indeed render a marked anti-inflammatory benefit, whereas topical NSAIDs have their forte in ocular surface pain amelioration. (See “Common Conditions That Call for Topical NSAIDs,” page 3A.)

Voltaren (diclofenac 0.1%, Novartis) and Acular LS (ketorolac 0.4%, Allergan) have been the standard bearers of topical NSAID care for years. Both are used QID and are largely clinical equivalents. One study that compared ketorolac and diclofenac head-to-head concluded: “The decrease in corneal sensitivity in normal human corneas



Note on Oral NSAIDs

Cyclooxygenase (COX) is the enzyme by which arachidonic acid is metabolized into prostaglandins. There are two subspecies of cyclooxygenase: COX-1 and COX-2.

COX-1 is a constitutive enzyme that synthesizes prostaglandins, which regulate physiological functions such as in the GI tract, kidneys, platelets and vascular endothelium.

COX-2, on the other hand, is an inducible enzyme, which is primarily activated during inflammatory tissue assaults. This is why there was great excitement years ago when COX-2 inhibitors came to market. These were purported to address inflammation while sparing the physiological prostaglandins, specifically sparing the GI tract from NSAID toxicity.

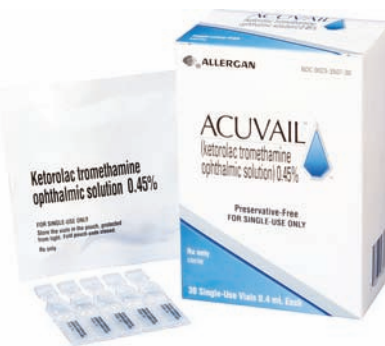Unfortunately, a couple of these products, Vioxx (rofecoxib) and Bextra (valdecoxib), were thought to significantly increase the risk for heart attack and stroke, and were removed from the market. Celebrex is now used more conservatively, but appears to be less likely to cause such untoward events. All three of these drugs were FDA approved around the year 2000.

We rarely prescribe oral NSAIDs, but do occasionally use Celebrex (100mg or 200mg BID) to help our patients in whom we have difficulty tapering off oral prednisone when treating orbital pseudotumor, stubborn uveitis or when treating scleritis. For example, if the anterior uveitis tends to rebound when the oral prednisone is tapered below 20mg per day, we have been successful using Celebrex along with prednisone 20mg/day for a week, then 10mg/day for a week or two, while concurrently using Celebrex for four to six weeks to facilitate the discontinuation of the oral prednisone. Aggressive use of Pred Forte and therapeutic cycloplegia is foundational to these oral supplementary therapies.

There is increased risk of peptic ulcer disease when using both oral prednisone and an oral NSAID (including Celebrex), so we usually also prescribe a proton pump inhibitor such as Prilosec OTC or Prevacid 20mg once daily when we are using such dual therapy.

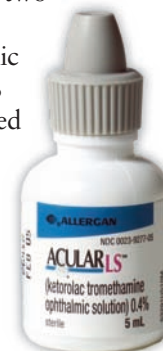
is more pronounced and longer lasting with diclofenac than with ketorolac.”¹

A more recent modification of ketorolac is the development of a 0.45% concentration of ketorolac: Acuvail (Allergan) comes as a preservative-free unit-dose and is indicated for perioperative use BID one day prior



to cataract surgery, and is continued for two weeks postoperatively.

The original formulation of ophthalmic ketorolac (Acular, Allergan) was a 0.5% solution, but its Achilles' heel was marked stinging upon instillation. The drug was reformulated several years ago to a 0.4% solution (Acular LS, Allergan) and is now quite tolerable—a very nice upgrade.



In the recent past, two more NSAIDs came to market. They are Bromday (bromfenac 0.09%, Bausch + Lomb) and Nevanac (nepafenac 0.1%, Alcon).



Bromday's uniqueness is that it is dosed once daily, and is well tolerated.

Nevanac is unique in that it is the first available NSAID pro-drug. Upon instillation, nepafenac enzymatically converts to amfenac sodium, which inhibits cyclooxygenase. Nevanac is dosed three times a day.

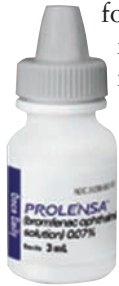

New NSAIDs

Now let's carefully examine the very recent generations of these two new premier products.

Prolensa (bromfenac 0.07%, Bausch + Lomb) is a new formulation that potentiates penetration of the bromfenac molecule, thereby allowing for a decreased concentration (0.07%) while maintaining once-daily dosing. Prolensa is 22% less drug than Bromday's 0.09% concentration, and its pH has been lowered from 8.3 to 7.8. This pH modification is what enables the lower concentration of Prolensa to clinically

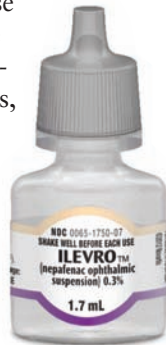perform as well as Bromday. How can the pH affect its clinical performance? The lower pH may alter its formulation, which may in turn increase its retention time in the eye, and hence increase its penetration.



Prolensa is pregnancy category C and has 0.005% BAK as the preservative. It comes in two sizes: 1.6mL and 3mL, both in 7.5mL bottles. Because Prolensa is a solution and not a suspension, shaking the bottle before use is not required.

Ilevro (nepafenac 0.3%, Alcon) achieves once-daily dosing by increasing the concentration from Nevanac (nepafenac 0.1%). Ilevro comes in a 1.7mL bottle, whereas Nevanac is dispensed as 3mL in a 4mL bottle. The innovative bottle design of Ilevro is identical to the bottle used by Travatan Z. Because Ilevro is a suspension, the bottle must be shaken before the drop is instilled. Its pediatric indication is down to age 10 years, and its pH is approximately 6.8.

Both of these new formulations are FDA approved for the treatment of pain and inflammation associated with cataract surgery. Both are dosed once daily the day before surgery, the day of surgery and for 14 days postsurgically.



Like Prolensa, Ilevro is also pregnancy category C and preserved with 0.005% BAK.

All of these NSAID drugs are generally approved by the FDA for treating postoperative inflammation, and as such, are used much more in a surgical context. Ketorolac 0.5% is also approved to treat ocular allergy, and there are a number of other applicable uses for NSAIDs relevant to primary eye care, as enumerated above.

Because of the rare—but real—potential for corneal toxicity and melting, these drugs should be used cautiously when there is preexisting corneal epithelial compromise. As a general rule, we never prescribe any topical NSAID for use beyond two weeks, with the exception of cystoid macular edema, which we treat with a topical NSAID for a month, concurrently with a potent steroid, such as Durezol. While steroids are often initially dosed as frequently as hourly for a few days, we recommend that NSAID use not exceed the FDA-approved dosing frequency.

In summary, there are several off-label uses for NSAIDs within the context of primary eye care. Their main use is in the prevention or treatment of cataract surgery-related CME concurrent with a potent corticosteroid. ■

1. Seitz B, Sorken K, LaBree LD, et al. Corneal sensitivity and burning sensation. Comparing topical ketorolac and diclofenac. Arch Ophthalmol. 1996 Aug;114(8):921-4.

'Ultimate Review' on NSAIDs

If you want the ultimate review of NSAIDs, we urge you to read "Nonsteroidal Anti-inflammatory Drugs in Ophthalmology," by Stephen J. Kim, MD, Allan J. Flach, MD, and Lee M. Jampol, MD, in *Survey of Ophthalmology*, March-April 2010. It is excellent. Some quotes (or in-context paraphrases) from this article, and our commentary (indicated in blue), follow:

- "NSAIDs do not inhibit lipooxygenase (LPO) and thus do not typically prevent generation of leukotrienes. This may explain, in part, their decreased anti-inflammatory effects compared to corticosteroids, which inhibit both LPO and COX (cyclooxygenase). However, celecoxib and diclofenac are notable exceptions and inhibit LPO by direct and indirect means, respectively. In addition, NSAIDs appear to have anti-inflammatory and anti-angiogenic effects independent of their inhibition of COX. Several reports suggest that ketorolac is the most potent inhibitor of COX-1, while both bromfenac and amfenac have staked the claim as being the most potent inhibitors of COX-2.

"The clinical importance of selective COX-1 and COX-2 inhibition for ocular disease remains to be established."

The prostaglandins produced via COX-1 are physiologic in their

action, whereas the prostaglandins produced from the upregulation of COX-2 result in pathologic expression: pain + inflammation.

- "There is good evidence that topical NSAIDs may be used in place of, or in addition to, topical corticosteroids after cataract surgery to avoid excessive inflammation and to improve visual acuity. Although none of the studies reviewed by the FDA used topical NSAIDs more than 24 hours before cataract surgery, well-designed studies suggest potential benefit from preoperative dosing regimens of up to three days. Furthermore, several clinical studies have reported that concurrent administration of NSAIDs and corticosteroids results in additive effects.

"Therefore at present, there is no evidence to suggest one topical NSAID treatment is better than another in controlling postoperative inflammation."

- "CME remains the most common cause of vision loss after cataract surgery. Despite its significance, the pathogenesis of this syndrome, and its relationship to and its associations with CME in other diseases, is not completely understood.

(continued on page 6A)

“Systemic NSAIDs provide insufficient drug levels to inhibit prostaglandin production in the anterior segment, especially when compared to topical administration.

“The true incidence of CME following cataract surgery is not precisely known. Despite this continued uncertainty, recent studies have reported incidences following small-incision cataract surgery as high as 9-19% using fluorescein angiography, and 41% as measured by OCT.

“It has long been recognized that the natural history of CME usually includes spontaneous resolution.

“Although there is no FDA-approved treatment for the prevention or treatment of CME following cataract surgery, an extensive review of the world literature ... concluded that prevention and treatment of CME with NSAIDs is beneficial.”

This is another example of where the scientific literature trumps FDA guidelines. “Off-label” use of medicines is becoming more and more commonplace; so don’t let a governmental bureaucracy override sound, rational and prudent use of a helpful drug.

- “Although there is no FDA-approved therapy for the prevention and treatment of CME following cataract surgery, available evidence suggests that topical NSAIDs may prevent and treat CME when used alone or concurrently with corticosteroids.

“Given the relatively low incidence of clinically significant CME, the cost/benefit of routine prophylactic use of NSAIDs in cataract surgery is a matter of ongoing debate.”

- “Although no other topical NSAID has been approved for allergic conjunctivitis besides ketorolac, there are studies suggesting that 0.1% diclofenac and 0.09% bromfenac may also be effective.

“Studies have reported that ketorolac 0.5%, diclofenac 0.1% and bromfenac 0.09% are all effective in treating vernal conjunctivitis.”

We would use a potent topical corticosteroid to gain full control of the vernal conjunctivitis first, and then perhaps try a topical NSAID to maintain that control. One could also consider antihistamine/mast cell stabilizer, or continue with loteprednol once to twice daily—whatever it takes to keep the condition under control.

- “Whereas topical corticosteroids are frequently helpful in relieving episcleritis, topical NSAIDs appear to be less effective. Systemic NSAIDs are of value in those unusual cases where topical treatments are ineffective.”

This is an excellent example that, when significant inflammation is present, it is a steroid that is needed—not an inferior quasi-anti-inflammatory agent.

- “Regarding scleritis, although topical NSAIDs are not effective, systemic NSAIDs are used as first-line agents. Although many NSAIDs may be effective, indomethacin at 25-50mg three times daily is most commonly used. Side effects include gastric upset

that may require concurrent use of an H2-blocker or proton pump inhibitor. A recent report indicated that the COX-2 selective NSAID, celecoxib, at a daily dosage ranging from 200 to 800mg q day was effective in controlling diffuse anterior scleritis in 92% of patients without producing any gastrointestinal effects.”

- “There is also evidence that NSAIDs are useful in the treatment of inflamed pingueculae and pterygia.”

We would always use a topical corticosteroid to first get inflammation controlled, then consider an NSAID to help keep the condition under control. We typically just maintain Lotemax once- or twice-daily for most of these patients.

- “One in seven Americans receives a prescription for orally administered NSAIDs each year.”

- “The most well known side effects accompanying systemic NSAID use relate to the GI and central nervous system ... Often the GI toxicity can be partially ameliorated by adding an H2-receptor antagonist, proton pump inhibitor, or prostaglandin analog; however, many patients will require discontinuation of the medicine.”

- “A recent prospective, randomized placebo-controlled trial observed no adverse events or changes in liver chemistries in a large number of patients treated twice daily for fourteen days with topical bromfenac. The off-label use of topical NSAIDs for durations longer than this is common, and clinicians should be vigilant for potential systemic toxicity. In addition, because eyelid closure and nasolacrimal occlusion can decrease systemic absorption of topically applied medications by almost 70%, explaining these techniques to all patients seems prudent.”

- “At present there is no evidence that one NSAID is less toxic than another.”

- “The over two dozen cases of corneal perforations reported with the introduction of topical corticosteroids over 30 years ago were likely related to improper clinical use and patient follow-up. Thus, many topical medications have the potential for toxicity if unmonitored or used inappropriately.”

Note that “over 30 years ago,” it was not doctors of optometry who performed “improper clinical use and patient follow up.”

- “Corneal perforations and melts have been reported with the use of topical NSAIDs. Therefore, the routine use of topical NSAIDs in dry eye patients may increase the risk of these adverse events.”

However, “A definite link between NSAID use and corneal melt remains tenuous. Application of topical NSAIDs for reasonable lengths of time in appropriate patients with proper monitoring appears safe. There is, however, evidence of the continued misuse of these medications.”

A Clinical Look at Glaucoma

The glaucoma workup is driven by the appearance of the optic nerve. Thus, the assessment of glaucoma risk is derived from this observation.

For eye doctors, the care and management of glaucoma is not rewarded through enhanced comfort or vision, but rather the inherent satisfaction of a service well provided. (This is comparable to a physician controlling systemic hypertension, another highly prevalent but largely asymptomatic disease.) Perhaps the essence of active glaucoma care lies in the mental challenge of finding the least intrusive medicine(s) to achieve target IOP.

While the medical treatment of glaucoma is relatively straightforward, the greatest challenge of overall glaucoma management is making the determination of *when* to initiate therapy. To arrive at such a decision with high sensitivity and specificity—that is, to treat those patients who merit treatment, and not treat those patients who would not benefit from treatment—requires considerable thought.

The crux of such thought is an assessment of various ocular and non-ocular risk factors. At the risk of oversimplifying, ocular risk factors are preeminent in assessing hypertensive glaucoma while non-ocular risk factors may play a larger role in assessing normoten-

sive glaucoma. However, before we take up either challenge, we must stress that the glaucoma workup is driven by, and centered upon, the appearance of the optic nerve, initially studied under slit-lamp-enabled ophthalmoscopy by attentive optometric eyes. It is the appearance of the optic nerve that drives and directs the assessment of risk.

Ocular Risk Factors

Because hypertensive glaucoma is more common, let's consider these risk factors first. Obviously, the higher the IOP, the greater is the concern for potential glaucomatous optic atrophy. However, IOP in a vacuum is relatively meaningless. The central corneal thickness is absolutely essential in characteriz-

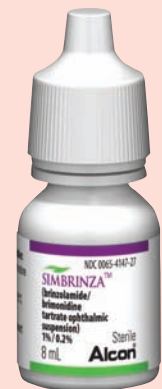Simbrinza Suspension— A New Fixed Combination Drug

Alcon just received FDA approval on an entirely new approach to combination therapy for glaucoma—one without a beta blocker. Simbrinza combines a carbonic anhydrase inhibitor, 1% brinzolamide (same as Azopt ophthalmic suspension, Alcon), with an alpha agonist, 0.2% brimonidine. Like its component ingredients, it is dosed TID.

Phase III studies of Simbrinza showed that it lowered IOP significantly more than either component drug dosed alone. Specifically, average IOP for “the brinzolamide/brimonidine fixed combination (BBFC) group was significantly lower than that of either monotherapy group across all time points. At three months, the BBFC group demonstrated the largest IOP reduction from baseline at all time points (21%-32%), compared with the brinzolamide group (17%-22%) and the brimonidine group (13%-25%).”

This new medicine may be a helpful addition for those patients in whom we know via trials of the individual medicines that each component contributes a clinically significant reduction in intraocular pressure.

We will know more about the intricacies of this new medicine once it comes to market and is subjected to widespread “real world” use.



Nguyen QH, McMenemy MG, Realini T, et al. Phase 3 randomized 3-month trial with an ongoing 3-month safety extension of fixed-combination brinzolamide 1%/brimonidine 0.2%. *J Ocul Pharmacol Ther.* 2013 Apr;29(3):290-7.

Glaucoma

ing the meaningfulness of the IOP. An IOP of 28mm Hg in a 640µm cornea with a 0.3 cup is most likely a normal eye. Conversely, an IOP of 16mm Hg in a 480µm cornea with a 0.7 cup may represent advanced (or advancing) glaucoma. Secondly, a physiologically thin cornea is an independent risk factor for glaucoma by mechanisms not fully elucidated.

Technology that quantifies the retinal nerve fiber layer, such as optical coherence tomography, can be very helpful in assessing the sub-biomicroscopic anatomy of the nerve fiber layer. However, such nerve fiber layer analyzers only assess structure, not function. Structural compromise generally precedes functional compromise. This is critical in that our goal as

patient caregivers is quite simple: to prevent “symptomatic visual loss” prior to the patient’s death. Therefore, life expectancy is a factor to consider in all forms of glaucoma. “The typical patient with glaucoma who is white lives with the disease for an average of 12.8 years, and one who is black lives an average of 16.3 years.”¹ Based on this reality, it is evident that visual field studies

Topical Glaucoma Drugs				
BRAND NAME	GENERIC NAME	MANUFACTURER	CONCENTRATION	BOTTLE SIZE
Beta Blockers				
Betagan, and generic	levobunolol hydrochloride	Allergan, and generic	0.25% 0.5%	5ml, 10ml 5ml, 10ml, 15ml
Betimol	timolol hemihydrate	Vistakon Pharm.	0.25% 0.5%	5ml 5ml, 10ml, 15ml
Betoptic-S	betaxolol hydrochloride	Alcon	0.25%	5ml, 10ml, 15ml
Istalol	timolol maleate	Bausch + Lomb	0.5%	2.5ml, 5ml
Timoptic, and generic	timolol maleate	Valeant Ophthalmics, and generic	0.25% 0.5%	5ml, 10ml, 15ml 5ml, 10ml, 15ml
Timoptic (preservative-free)	timolol maleate	Valeant Ophthalmics	0.25% 0.5%	unit-dose unit-dose
Timoptic-XE, and generic	timolol maleate	Valeant Ophthalmics, and generic	0.25% 0.5%	2.5ml, 5ml 2.5ml, 5ml
Prostaglandin Analogs				
Lumigan	bimatoprost	Allergan	0.01%	2.5ml, 5ml, 7.5ml
Travatan Z	travoprost	Alcon	0.004%	2.5ml, 5ml
Xalatan, and generic	latanoprost	Pfizer, and generic	0.005%	2.5ml
Zioptan	tafluprost	Merck	0.0015%	unit-dose
Docosanoid Compound				
Rescula	unoprostone isopropyl	Sucampo	0.15%	5ml
Alpha Agonists				
Alphagan P, and generic	brimonidine brimonidine	Allergan generic	0.1%, 0.15%, 0.2%	5ml, 10ml, 15ml 5ml, 10ml, 15ml
Carbonic Anhydrase Inhibitors				
Azopt	brinzolamide	Alcon	1%	5ml, 10ml, 15ml
Trusopt, and generic	dorzolamide	Merck	2%	5ml, 10ml
Combination Glaucoma Medications				
Combigan	brimonidine/timolol	Allergan	0.2%/0.5%	5ml, 10ml
Cosopt	dorzolamide/timolol	Merck	2%/0.5%	5ml, 10ml
Cosopt PF	dorzolamide/timolol	Merck	2%/0.5%	unit-dose
Simbrinza	brinzolamide/brimonidine	Alcon	1%/0.2%	8ml

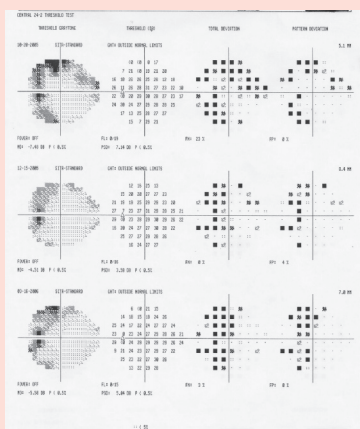
be conducted to search for functional compromise. (We generally use the 24-2 SITA-Fast protocol. Some experts recommend the SITA-Standard protocol, and this may be a tad more sensitive and specific, but we prefer the more rapid SITA-Fast approach.)

In summary, ocular risk factors are: increased IOP, decreased central corneal thickness, increased vertical cupping of the optic nerve head, diminished retinal nerve fiber layer thickness and repeatable defects in visual field testing, especially if a visual field defect is not correlated to optic nerve head anatomy. (See “*This Bears Repeating!*” below.)

This Bears Repeating!

Accepting a defective visual field result as “real” is a very common diagnostic pitfall. Remember, unless there is clearly evident structure/function concordance in the visual field defect, any abnormal, borderline or suspicious visual field defect *must* be verified by repeat testing.

Furthermore, it may take three to five sequential visual field tests to know with certainty that a visual field defect is indeed a reflection of reality. This critical point cannot be overemphasized.



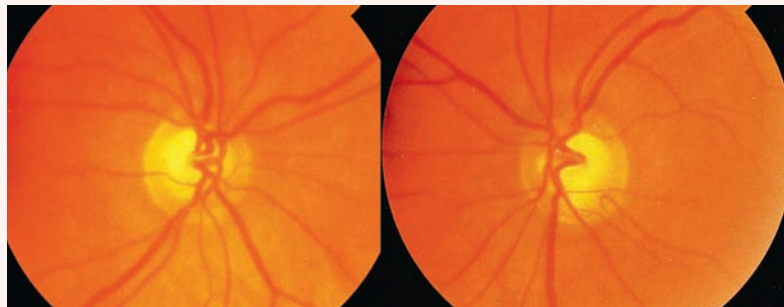
If the field is normal, believe it to be normal. If the field is borderline or questionable, repeat the testing.

The ‘Holy Grail’ of Glaucoma Management

“At the most basic level we have yet to determine ... at which stage of disease is the initiation of treatment superior to natural history.”

In other words, the ultimate management decision is *when* to initiate therapy.

Lieberman MF, Congdon NG, He M. The value of tests in the diagnosis and management of glaucoma. *Am J Ophthalmol.* 2011 Dec;152(6):889-899.



A patient with ocular hypertension on the cusp of converting to glaucoma.

Rescula Returns

This drug was marketed for a short while about a decade ago. Its debut in 2000 was at a time when “prostaglandin-mania” was sweeping the US market. As a result, this docosanoid drug was overshadowed by the success of latanoprost and subsequent prostaglandins. After struggling along for a few years, it was removed from the market.

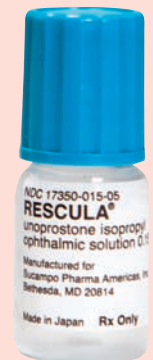Now that glaucoma therapy has further evolved, Rescula (unoprostone isopropyl 0.15%, Sucampo Pharmaceuticals) is being reintroduced into the glaucoma armamentarium.

Unoprostone isopropyl is a rather enigmatic molecule in that it shares many qualities with prostaglandins and yet it also has many different distinctive characteristics. While its exact mechanism of action is unknown, unoprostone appears to have little effect on uveoscleral outflow but rather enhances aqueous humor outflow at the site of the trabecular meshwork.¹ It is thought to relax the trabecular meshwork because of a local effect on the “big potassium” and chloride channels.

Rescula reduces intraocular pressure about 3 to 4mm Hg on average. In comparative studies, it reduces intraocular pressure about 70% as effectively as timolol.¹ Although Rescula is an analog of a metabolite of prostaglandin, it possesses little or no affinity for the FP receptor. Though not a powerful drug at decreasing intraocular pressure, unoprostone is an incredibly safe medicine. Also, unlike the prostaglandins, it is dosed twice daily.

Some scenarios in which we see the utility of Rescula are:

- When asthma precludes the use of a beta blocker.
- As a safe alternative to reduced intraocular pressure in low-risk glaucoma suspects (this could hold true for a topical CAI, as well).
- As an addition to a beta blocker, brimonidine or a carbonic anhydrase inhibitor (but not as effective as with a prostaglandin).
- When the other second-tier drugs do not achieve target intraocular pressure.



1. Toris CB, Gabelt BT, Kaufman PL. Update on the mechanism of action of topical prostaglandins for intraocular pressure reduction. *Surv Ophthalmol.* 2008 Nov;53 Suppl1:S107-20.

Glaucoma

Check Blood Pressure in Glaucoma Patients and Suspects

- A basic formula for ocular perfusion pressure is: $OPP = \text{diastolic BP} - IOP$

A more precise but more complex formula is:

$$\text{mean OPP} = 2/3 [\text{diastolic BP} + 1/3(\text{systolic BP} - \text{diastolic BP})] - IOP$$

- **Theory:** $OPP < 50\text{mm Hg}$ is a risk factor for glaucoma and glaucoma progression.

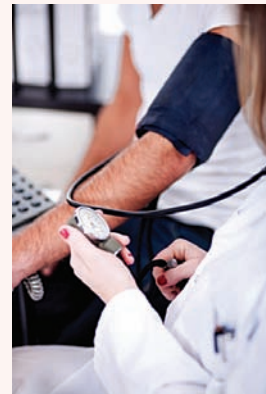Example:

$$DBP \text{ of } 65 \text{ and } IOP \text{ of } 15\text{mm Hg} = OPP \text{ of } 50\text{mm Hg}$$

$$DBP \text{ of } 85 \text{ and } IOP \text{ of } 35\text{mm Hg} = OPP \text{ of } 50\text{mm Hg}$$

These two patients may be at equal risk because they have the same theorized OPP of 50mm Hg.

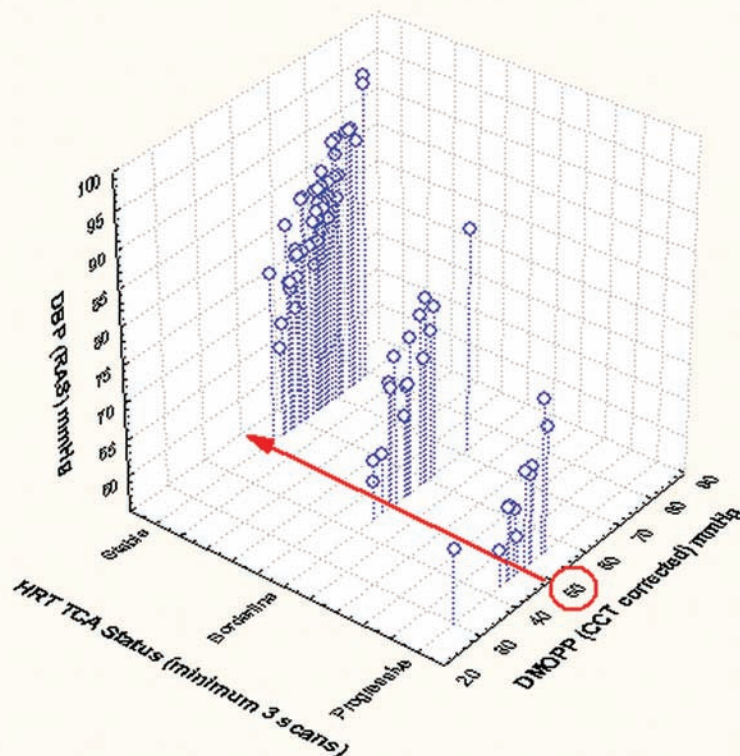
- **Take home message:** Check blood pressures on your glaucoma patients and glaucoma suspects, especially those with lower IOPs.



Sehi M, Flanagan JG, Zeng L, et al. Anterior optic nerve capillary blood flow response to diurnal variation of mean ocular perfusion pressure in early untreated primary open-angle glaucoma. Invest Ophthalmol Vis Sci. 2005 Dec;46(12):4581-7.

Ocular Perfusion Pressure and Risk for Glaucoma

A recent study shows that when the ocular perfusion pressure is $< 50\text{mm Hg}$, patients are at increased risk for progression, as determined by topographic change analysis. OPP of 50 to 56mm Hg is somewhat borderline, and patients with ocular perfusion pressure above 56mm Hg are generally not impacted by systemic hypotension.



Quaid P, Simpson T, Freddo T. Relationship between diastolic perfusion pressure and progressive optic neuropathy as determined by Heidelberg retinal tomography topographic change analysis. Invest Ophthalmol Vis Sci. 2013 Jan 28;54(1):789-98.

OPP as a Glaucoma Risk Factor

Low mean ocular perfusion pressure is associated with a 2.6 times increased risk for primary open angle glaucoma.

“As summarized in various reviews, lower perfusion pressures at the optic disc would compromise ocular blood flow and thus lead to glaucoma damage.”

Leske MC, Wu SY, Hennis A, Honkanen R, Nemesure B; BESs Study Group. Risk factors for incident open-angle glaucoma: the Barbados Eye Studies. Ophthalmology. 2008 Jan;115(1):85-93.

Non-ocular Risk Factors

In addition to these ocular risk factors, there are non-ocular risk factors that must also be considered in the comprehensive glaucoma evaluation, particularly when the true IOP is consistently in the teens and the central corneal thickness is normal or thin.

The impact of low diastolic blood pressure is rapidly becoming recognized as a non-ocular risk factor for the development of, and progression of, glaucoma. The impact of such is most noted in patients with normotensive glaucoma. Obviously, a good blood supply to the optic nerves is essential for

physiological function. If, however, a person has naturally low diastolic blood pressure, or their diastolic blood pressure is iatrogenically low from aggressive medical treatment for systemic hypertension, optic nerve perfusion may be compromised.

So, if you're managing a glaucoma patient with high blood pressure, be sure to ascertain if the patient is taking his/her antihypertensive medicine in the evening/bedtime. This is necessary because if such a patient were to have nocturnal hypotension, then adding insult to injury with a systemic antihypertensive medicine near bedtime could create a compromising microvascular situation for an "at risk" optic nerve.

Here's the bottom line: We need to assess patients' estimated ocular perfusion pressure (OPP), which is calculated as the diastolic blood pressure minus the intraocular pressure.

A recent study by one of our Canadian optometric colleagues shows that when the ocular perfusion pressure is <50mm Hg, patients are at increased risk for progression.² OPP of 50 to 56mm Hg is somewhat borderline, and patients with ocular perfusion pressure above 56mm Hg are generally not impacted by systemic hypotension.

In this regard, many glaucoma specialists now suggest that most patients with glaucoma, particularly those in the normotensive intraocular pressure range, should have their blood pressure assessed as part of the comprehensive glaucoma evaluation.³

Additionally, Raynaud's disease and/or migraine headaches may be markers for abnormal vascular autoregulation, which may portend a diagnosis of low-tension glaucoma.⁴

Diastolic Blood Pressure, Ocular Perfusion Pressure and Glaucoma

- "The driving force for ocular blood flow is the ocular perfusion pressure (OPP), defined as the ophthalmic artery pressure minus the IOP."
- "Large cross-sectional prevalence studies in different populations found a significant association between low diastolic OPP and the prevalence of OAG."
- "The greater incidence of progression in patients with lower blood pressure, seen mainly in patients with lower IOP, suggests a vascular risk factor for progression independent of IOP."
- "Low blood pressure ... may be the most important vascular risk factor for glaucoma progression."

Caprioli J, Coleman AL; Blood Flow in Glaucoma Discussion. Blood pressure, perfusion pressure, and glaucoma. Am J Ophthalmol. 2010 May;149(5):704-12.

Therapeutic Options

Once the decision to treat has been made, we face the choice of which medicine to prescribe. While one of the four prostaglandins is typically selected, we urge the prescriber to be attentive to cost (a major reason for noncompliance). We all have a sizable subset of patients who struggle financially. For many of these patients, we unhesitatingly initiate therapy with a beta blocker (timolol), unless there are relative contraindications such as asthma or other lung diseases.

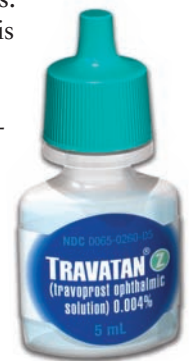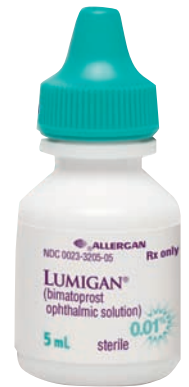For perspective, prostaglandins generally reduce IOP about 30%, yet nonselective beta blockers generally reduce IOP about 25%; usually this small difference is not clinically significant.

Now, let's dive deeper into these "initial" therapeutic options as well as the so-called second and third-line drugs.

• **Prostaglandins.** We now have four prostaglandin eyedrops, all of which perform very similarly.⁵ A few points, however, are worth noting.

We are hearing consistent reports of the inconsistent generic preparations of latanoprost—mainly

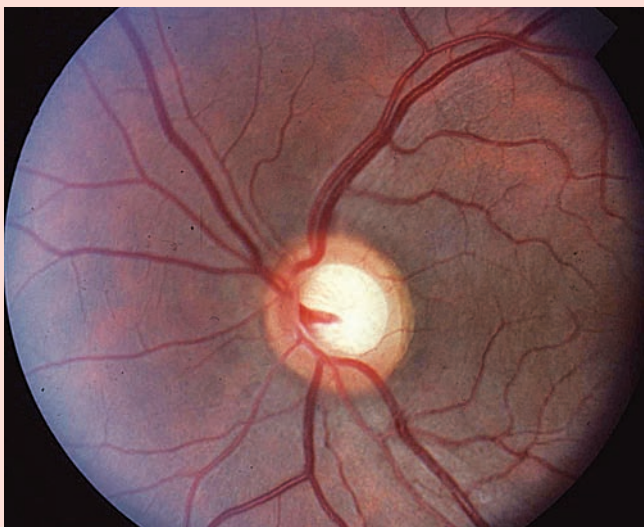that many patients are running out of their medication prior to the end of the month. This is a concern because pharmacies tend not to allow refills until 30 to 31 days have lapsed. We need a study to determine the number of drops in each of the various generic manufacturers' products. The variability of generic latanoprost products has caused us to write more and more for brand-name products. The good news in this regard is that Alcon, Allergan and Merck all have patient assistant discount programs that allow for quality products at a reasonable fee structure. We urge you to interact with all three of these companies to determine what programs are in place so you can provide information/assistance to your patients in obtaining quality, brand-name protected, cost-effective drugs.



Assorted Pearls from the Optometric Glaucoma Society Meeting

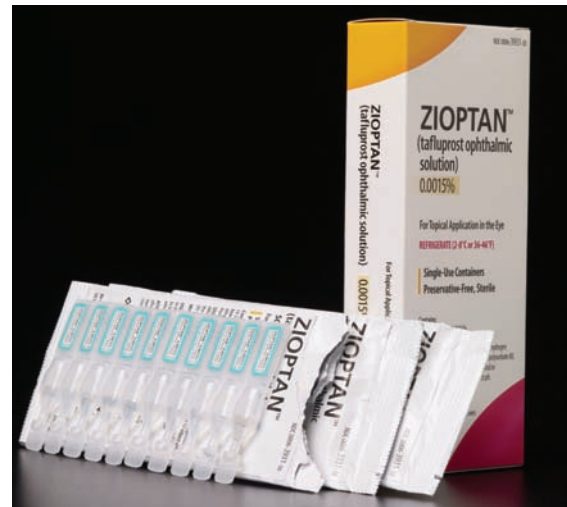Held in conjunction with the American Academy of Optometry, October 2012

- Since brimonidine has no clinically significant effect during the sleep cycle, and only has about eight hours of effectiveness, consider BID dosing on this schedule: first upon awakening, and again about eight hours later.
- IOP increases during the sleep cycle—regardless of treatment with any intervention.
- “Clinical significance of lowering nocturnal IOP has not been established.”—John Liu, PhD
- “Clinical significance of nocturnal IOP is hypothetical, but not yet proven.”—John Liu, PhD
- Carbonic anhydrase inhibitors exert 70% of the daytime effect during sleep, prostaglandins about 50%, whereas timolol and brimonidine show no nocturnal effect.
- About 30% of people have nocturnal systemic hypotension—which seems only to occur with deep sleep.
- Disc size is not associated with glaucoma susceptibility.
- In assessing the neuroretinal rim of the optic nerve head, the temporal rim is always the thinnest quadrant in a normal optic nerve.
- Disc hemorrhages typically persist for about two months.
- People lose about 4,000 retinal nerve fibers per year. Fortunately, we start out with about 1.2 million.
- Sloping rim tissue may be indicative of glaucomatous optic neuropathy, whereas a sharp neuroretinal rim drop-off is usually normal.
- About 10% of ocular hypertensives eventually develop glaucoma.
- Beta-zone atrophy is observed in about 25% of normals, but certainly can be associated with glaucoma.



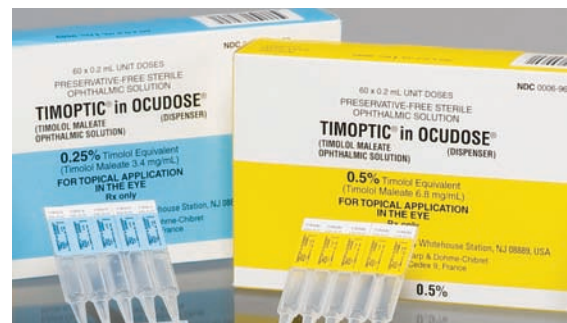In assessing the neuroretinal rim, the temporal rim is always the thinnest quadrant in a normal optic nerve.

For patients with significant dry eye syndrome or ocular surface disease, Zioptan (tafluprost, Merck) is an excellent preservative-free option. Like latanoprost, it must be stored under refrigeration at the pharmacy; but once the patient receives either of these products, they can be kept at room temperature. We find that patients enjoy the unit-dose delivery system of Zioptan. When they travel, they can simply take along the number of unit doses they will need.

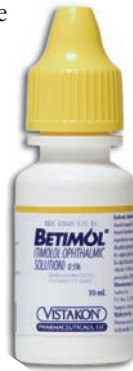

Always discuss with patients the time of day they feel they can most consistently use their medicine(s). We have found that many patients are more compliant with their glaucoma drops when they are instilled around their morning/breakfast time.⁶ Even though the Phase III studies over a decade ago found that prostaglandins perform at their maximum when instilled in the evening, these drops still perform robustly with morning instillation. We always need to have this brief conversation with our glaucoma patients, as consistent lowering of the intraocular pressure is the goal.

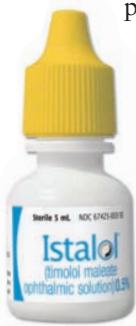- **Beta blockers.** Nonselective beta blockers



such as timolol reduce intraocular pressure about 25%, which is close to the prostaglandin reduction of 28 to 30%. And, like the prostaglandins, beta blockers are properly dosed once daily, and in the morning. We always urge our patients to instill their beta blocker within 30 minutes of waking.⁷



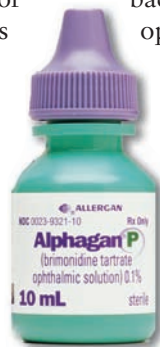If they are also using a prostaglandin during this time period, they are advised to wait at least 15 minutes between instillation of the two drops.



In our clinical experience, we have found that we can get about 85% of our glaucoma patients to

target intraocular pressure with a prostaglandin or a beta blocker, or a combination of the two.

• **Second-tier choices.** If target IOP cannot be achieved in this manner, then the decision making gets a bit more complicated. The next options are second-tier for two main reasons: these drops must be dosed BID, and they are not as robust as the first-tier options at reducing intraocular pressure. These second-tier options are brimonidine, unoprostone isopropyl (Rescula, Sucampo Pharmaceuticals), or a topical carbonic anhydrase inhibitor.



Brimonidine comes generically in 0.2% and 0.15% concentrations. Brimonidine also comes in a 0.1% concentration as brand name Alphagan P (Allergan).

We typically prescribe the generic 0.15% concentration because of its reduced concentration from

the original 0.2% formulation and, as expected, it is less expensive than the brand name.

Unoprostone, or Rescula, is now back again as another second-tier option. (See “Rescula Returns,” page 9A.)

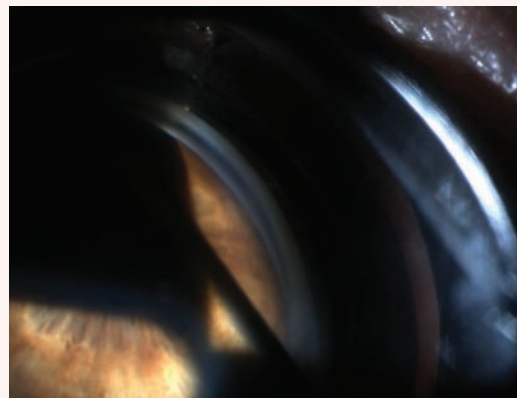
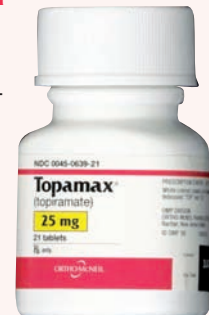The topical carbonic anhydrase inhibitors are Azopt (brinzolamide 1%, Alcon) ophthalmic suspension and generic dorzolamide 2% ophthalmic solution. Both brinzolamide and dorzolamide perform similarly,

yet the suspension is more comfortable upon instillation than is the solution; on the other hand, the solution does not have to be shaken before



Topamax Alert: Acute Angle Closure Glaucoma

- Topamax (topiramate, Janssen Pharmaceuticals) was approved in 1996 for seizure disorders.
- Unapproved uses: migraine headache, weight loss, depression, bipolar disorder.
- Mechanism of action is unknown.
- Numerous reported cases of acute, bilateral, simultaneous angle-closure glaucoma.
- Onset is usually within first two weeks of therapy.
- Most common presenting symptom: blurred vision.
- Exact mechanism of increased IOP is unknown.
- Tx: Stat consult with prescribing physician to begin to reduce topiramate dosage; then aqueous suppressants, oral CAI, cycloplegia (retracts ciliary body). No miotics.
- IOP normalizes in one to four days. No laser treatment is indicated.



A gonioscopic view of an angle in acute closure.

Fraunfelder FW, Fraunfelder FT, Keates EU. Topiramate-associated acute, bilateral, secondary angle-closure glaucoma. *Ophthalmology*. 2004 Jan;111(1):109-11.

instillation, as the suspension does.

• **Combinations.** Third-tier drugs are represented by the fixed combination drugs. Their component drugs should be tried and found effective, but not sufficiently so as a solo drop, before selecting a combination of the two drugs.

A few general principles apply to all combination glaucoma drugs. First, they are rarely ever used as initial therapy. Why? We estimate that there is about a 10% non-response rate to any of these drugs, so it is sound practice to know that a drug makes a meaningful reduction in intraocular pressure before using it.

Most importantly, one or the other of these ingredient drugs often achieves target intraocular pressure alone, and obviously, one medication is less expensive than two.

Glaucoma

Note that all combination glaucoma drugs are composed of generic (or generic-equivalent) drugs. Therefore, vast cost savings to the patient can result from a more thoughtful approach to prescribing, and since cost is the weak link in patient compliance, this is a major prescribing consideration.

Now let's look at the available options. We now have three fixed combination drugs from which to choose on those occasions when a combination is appropriate: Combigan (timolol/brimonidine, Allergan), Cosopt (timolol/dorzolamide, Merck), and newly-approved Simbrinza (brinzolamide/brimonidine, Alcon).

We've had Cosopt and Combigan for several years now, and anecdotally we find that their performance is about equivalent. It has always been odd to us to combine a once-daily medicine (0.5% timolol) with a TID medicine (dorzolamide or brimonidine). This means we have to overdose the beta blocker (timolol), or underdose the other component drug. (However, it could be argued that dorzolamide and brimonidine are actually used BID in clinical practice

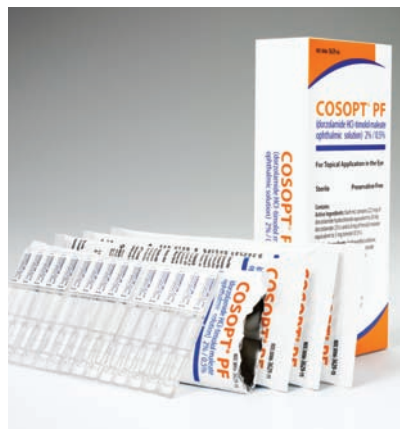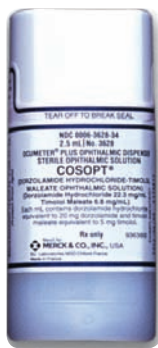anyway, and that the use of BID timolol really is of no clinical consequence.) But now, with the introduction of Simbrinza, which combines two TID drugs, this relieves such a concern. (See "Simbrinza: New Fixed Combination Drug," page 7A.)

Because all the glaucoma medicines

in common use perform better during waking hours than during sleep, we generally recommend the first drop to be dosed shortly after waking, and then the second drop about eight hours later. This should allow for maximal reduction in intraocular pressure during the times when it should be most effective (that is, during waking hours).

A couple of caveats: Brimonidine, alone or in combination, can cause follicular conjunctivitis. So, if conjunctival hyperemia becomes an issue with Combigan, this alpha-2 adrenergic agonist probably causes it.

Also, note that Cosopt PF is available as a preservative-free formulation from Merck. For those patients with delicate ocular surfaces, a preservative-free delivery system may be best. So, we now have three preservative-free glaucoma medicines to choose from: Timoptic, Zioptan and Cosopt.



• **Trabeculoplasty.** If, after reasonable drug trials, target intraocular pressure is still not achieved, then argon laser trabeculoplasty or selective laser trabeculoplasty must be considered. However, there is a critical diagnostic procedure that must be accomplished prior to deciding if a laser intervention is practical. These laser technologies require adequately pigmented

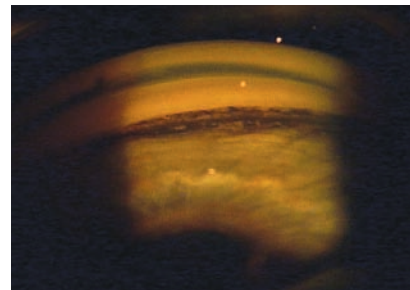


Photo: Howell Finley, OD

When considering laser trabeculoplasty as a treatment option, first perform gonioscopy to check the trabecular meshwork for pigment.

trabecular tissues to absorb the laser energy to accomplish the goal of augmenting trabecular outflow. So, the OD must perform attentive gonioscopy to assess the trabecular meshwork pigment in order to determine the appropriateness of laser trabeculoplasty.

It is our strong opinion that patients can receive optimal management in the areas of glaucoma (as well as dry eye) under the care of a doctor of optometry. We hope you share this perspective. ■

- Stein JD, Niziol LM, Musch DC, et al. Longitudinal trends in resource use in an incident cohort of open-angle glaucoma patients: resource use in open-angle glaucoma. *Am J Ophthalmol.* 2012 Sep;154(3):452-459.
- Quaid P, Simpson T, Fredro T. Relationship between diastolic perfusion pressure and progressive optic neuropathy as determined by Heidelberg retinal tomography topographic change analysis. *Invest Ophthalmol Vis Sci.* 2013 Jan 28;54(1):789-98.
- De Moraes CG, Link AR, Wells MT, et al. Large and sustained blood pressure dips are associated with visual field progression in normal-tension glaucoma. Paper presented at the 23rd Annual American Glaucoma Society Meeting; March 1, 2013; San Francisco, CA.
- Wang JJ, Mitchell P, Smith W. Is there an association between migraine headache and open-angle glaucoma? Findings from the Blue Mountains Eye Study. *Ophthalmology.* 1997 Oct;104(10):1714-9.
- Parrish RK, Palmberg P, Sheu WP; XLT Study Group. A comparison of latanoprost, bimatoprost, and travoprost in patients with elevated intraocular pressure: a 12-week, randomized, masked-evaluator multicenter study. *Am J Ophthalmol.* 2003 May;135(5):688-703.
- Ford BA, Goni M, Carlsson A, Crichton AC. Morning dosing of once-daily glaucoma medication is more convenient and may lead to greater adherence than evening dosing. *J Glaucoma.* 2013 Jan;22(1):1-4.
- Strahlman E, Tipping R, Vogel R. A double-masked, randomized 1-year study comparing dorzolamide (Trusopt), timolol, and betaxolol. *International Dorzolamide Study Group. Arch Ophthalmol.* 1995 Aug;113(8):1009-16.

AREDS2 and AMD

The new AREDS2 results have found that omega-3 essential fatty acids have no impact on disease progression.

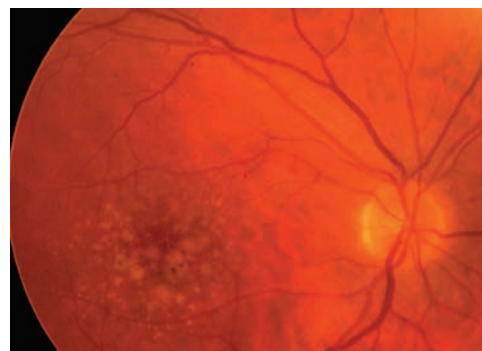
The long-awaited second rendition of the Age-Related Eye Disease Study (AREDS2) have recently been released.^{1,2}

As you will recall, the initial AREDS report was released more than a decade ago, where a combination of vitamin C, vitamin E and beta-carotene along with zinc was found to slow the rate of progression of advanced dry degenerative stages by about 25%.³

Since that time, there has been much attention paid to the presumably enhanced beneficial effects of lutein, zeaxanthin and omega-3 essential fatty acid supplementation (along with vitamins C, E and zinc) and their ability to attenuate the rate of progression of dry age-related macular degeneration.^{4,5} The underlying idea is that because there is a high concentration of lutein in the macular region, augmenting the lutein levels in these tissues may be beneficial.

Also, the concern about beta-carotene potentiating the development of lung cancer in patients who smoke or have a history of smoking was a significant factor in supplement decision-making.⁶ Of course, we should always encourage our smoking patients to do their best to stop smoking, as tobacco smoking is a well-established risk factor for the development of age-related macular degeneration.

We also explain to our patients that eating dark green, leafy vegetables is the best source of lutein, and that oily fish (salmon, mackerel, sardines, trout and herring) and flaxseed oil are the optimum sources of omega-3 essential fatty acids. Most patients, however, likely do not consume appropriate amounts of these foods, so supplementation is probably



Coalesced intermediate and large soft drusen represent a “high risk” macula for possible conversion to “wet” AMD.

a sound nutritional intervention. It is important for our patients to understand how to properly dose these supplements.

The New AREDS2 Findings

After much anticipation, the AREDS2 study results were recently released at the Association for Research in Vision and Ophthalmology (ARVO) meeting in early May and simultaneously published online.^{1,2} Both AREDS and AREDS2 were five-year studies. Five years is a very practical, yet still suboptimum, time period to study a long-term chronic disease process such as AMD. Based on this inherent weakness, the findings can only provide a limited trajectory on a degenerative process that typically evolves over 10 to 20

Risk Management with Family Hx of AMD

- “Modifying environmental factors is currently the only approach to reduce the genetic risk of AMD.”
- “In conclusion, our study shows that high dietary intake of antioxidants, zinc and omega-3 fatty acids may reduce the risk of early AMD among those at high genetic risk.”
- “Our findings stress the importance of sufficient intake of these nutrients in young, susceptible individuals to postpone or prevent the devastating effects of AMD.”

Ho L, van Leeuwen R, Witterman JC, et al. Reducing the genetic risk of age-related macular degeneration with dietary antioxidants, zinc, and -3 fatty acids: the Rotterdam study. *Arch Ophthalmol*. 2011 Jun;129(6):758-66.

Assessing Risk for Progression in AMD

- “Several genetic variants as well as modifiable factors including smoking, lower intake of dietary antioxidants and omega-3 fatty acids, and higher body mass index are known to be associated with higher rates of progression.”
- Macular drusen “are also associated with progression to advanced AMD,” especially the presence of intermediate to large drusen.
- Advanced AMD in one eye yields a seven to 10-fold risk of progression in the fellow eye.

Seddon JM, Reynolds R, Yu Y, et al. Risk models for progression to advanced age-related macular degeneration using demographic, environmental, genetic, and ocular factors. *Ophthalmology*. 2011 Nov;118(11):2203-11.

years.

That being said, here is a succinct summary of the key findings:^{1,2}

- Omega-3 essential fatty acids such as those obtained in fish and flaxseed oils have no impact on disease progression.
- It appears that the combination of lutein/zeaxanthin is equally effective as beta-carotene. (Since there is some risk of beta-carotene increasing the risks of lung cancer in smokers and recent ex-smokers, a formulation containing lutein/zeaxanthin can be recommended without regard to smoking status, thus can be more universally recommended.)
- AREDS2 specifically helped

Lifestyles and AMD

- Three key behaviors to diminish the risk of developing AMD
 - Healthy diet (ample carotenoids)
 - Physical activity
 - Not smoking
- “These results also serve to remind us that the risk for AMD is passed to subsequent generations not only through genes but also possibly through the lifestyle habits we model and encourage.”

Mares JA, Voland RP, Sondel SA, et al. Healthy lifestyles related to subsequent prevalence of age-related macular degeneration. *Arch Ophthalmol*. 2011 Apr;129(4):470-80.

Zeaxanthin and Visual Function

The Zeaxanthin and Visual Function Study investigated zeaxanthin’s effect on raising macula pigment optical density to improve visual function for patients with early AMD.

“Conclusion: In older male patients with AMD, zeaxanthin-induced foveal macula pigment optical density (MPOD) elevation mirrored that of lutein and provided complementary distinct visual benefits by improving foveal cone-based visual parameters, whereas lutein enhanced those parameters associated with gross detailed rod-based vision, with considerable overlap between the two carotenoids. The equally dosed (atypical dietary ratio) zeaxanthin plus lutein group fared worse in terms of raising MPOD, presumably because of duodenal, hepatic-lipoprotein or retinal carotenoid competition. These results make biological sense based on retinal distribution and zeaxanthin foveal predominance.”

Richer SP, Stiles W, Graham-Hoffman K, et al. Randomized, double-blind, placebo-controlled study of zeaxanthin and visual function in patients with atrophic age-related macular degeneration: the Zeaxanthin and Visual Function Study (ZVF) FDA IND #78, 973. *Optometry*. 2011 Nov;82(11):667-680.

two subgroups the most:

- Those not taking concurrent beta-carotene. (Carotenoids compete for intestinal absorption, so it may be that lutein/zeaxanthin would have demonstrated some additional benefit were they not competing with beta-carotene for absorption.)
- Those patients with diets having “very little” carotenoids.

Based upon our reading of the results, we conclude that a formulation containing lutein/zeaxanthin (or beta-carotene), vitamin C, vitamin E and zinc represents the only proven combination to reduce the rate of progression of moderate to advanced AMD.

For those patients with moderate AMD *and* dry eyes, a combination supplement that also contains omega-3 essential fatty acids may

simplify their lives by addressing both of their conditions with a single formulation.

Lastly, for those patients who express a desire to do “something, anything” that may decrease their risk of ever developing macular degeneration, we clearly tell them that there are no studies to support the supplement as a deterrent to macular degenerative disease, but that it is certainly an acceptable approach until we have even further research to confirm or refute its efficacy. ■

1. The Age-Related Eye Disease Study 2 (AREDS2) Research Group. Lutein/Zeaxanthin for the Treatment of Age-Related Cataract: AREDS2 Randomized Trial Report No. 4. *JAMA Ophthalmol*. 2013 May 5:1-7.
2. The Age-Related Eye Disease Study 2 (AREDS2) Research Group. Lutein + Zeaxanthin and Omega-3 Fatty Acids for Age-Related Macular Degeneration: The Age-Related Eye Disease Study 2 (AREDS2) Randomized Clinical Trial. *JAMA*. 2013 May 5:1-11.
3. Age-Related Eye Disease Study Research Group. A randomized, placebo-controlled, clinical trial of high-dose supplementation with vitamins C and E, beta carotene, and zinc for age-related macular degeneration and vision loss: AREDS report no. 8. *Arch Ophthalmol*. 2001 Oct;119(10):1417-36.
4. Age-Related Eye Disease Study Research Group, San-Giovanni JP, Chew EY, Clemons TE, et al. The relationship of dietary carotenoid and vitamin A, E, and C intake with age-related macular degeneration in a case-control study: AREDS Report No. 22. *Arch Ophthalmol*. 2007 Sep;125(9):1225-32.
5. SanGiovanni JP, Chew EY, Agrón E, et al; Age-Related Eye Disease Study Research Group. The relationship of dietary omega-3 long-chain polyunsaturated fatty acid intake with incident age-related macular degeneration: AREDS report no. 23. *Arch Ophthalmol*. 2008 Sep;126(9):1274-9.
6. Omenn GS, Goodman GE, Thornquist MD, et al. Risk factors for lung cancer and for intervention effects in CARET, the Beta-Carotene and Retinol Efficacy Trial. *J Natl Cancer Inst*. 1996 Nov 6;88(21):1550-9.

Ocriplasmin and Vitreomacular Traction

The vitreous and retina usually enjoy a quite intimate relationship. But sometimes the relationship is a bit too cozy; when the vitreous and retina stick together and traction ensues, the retinacular tissues can be compromised. This is termed vitreomacular adhesion, and if there is associated traction with the adhesion, normal tissue anatomy can be altered and may result in central vision compromise. “Symptomatic vitreomacular adhesion is a condition in which the vitreous adheres to the retina in an abnormally strong manner.”¹

Many of these adhesions are subclinical, but others can cause clinically significant visual loss. Such adhesions might be amenable to therapeutic intervention, a technique known as pharmacologic vitreolysis.

Jetrea (ocriplasmin, ThromboGenics), approved by the FDA in October 2012, is an intravitreal medication indicated for release of vitreomacular traction. “Jetrea acts as a selective proteolytic enzyme that cleaves fibronectin, laminin and collagen—the three major components of the vitreoretinal interface. It is delivered as a single, one-time, intravitreal injection.”¹

Do note that while pharmacologic vitreolysis is a cool idea, this is not a major breakthrough at this stage, and its full impact on these adhesions will not be fully known until after a year or two of clinical use. Also, be aware that a single injection costs the patient \$4,000. But for now, we simply want to acquaint you with the scientific information.

Pharmacologic Vitreolysis

Vitreomacular traction can cause retinal surface irregularity resulting in metamorphopsia and blurring of vision. Furthermore, such traction (especially tangential traction) can lead to the formation of macular holes. If such traction causes significant vision compromise, the traditional approach has been vitrectomy and membrane peel.

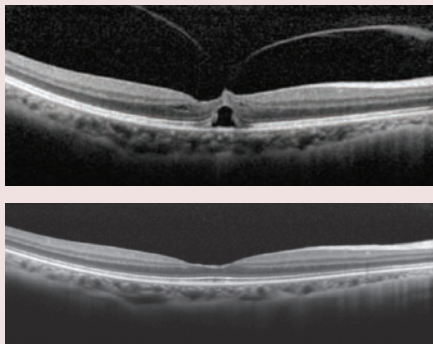
“Age-related posterior vitreous detachment (PVD) ... is known to progress slowly over many months or years before its culmination at the time of vitreopapillary separation ... Fibrocellular organization of vitreous remnants left on the retinal surface during vitreoretinal separation is considered by most authorities to the likely cause of idiopathic epiretinal membrane.”²

“Given the inherent limitations of vitrectomy, there is longstanding interest in developing pharmacologic methods for the nonsurgical induction of PVD.” However, “the less-than-robust results of the ocriplasmin trials point to the complexity of pharmacologic vitreolysis and suggest that the ideal vitreolytic agent (or

combination of agents) has yet to be identified.”²

Intravitreal gas can also release vitreoretinal traction. “Complete resolution of vitreomacular traction was achieved in 40% of eyes by one month after [intravitreal gas] and in 60% of eyes within six months of treatment. Disappointingly, the final mean visual acuity in this small cohort was unchanged from baseline.”²

Vitreous surgery “will continue for some time to be the preferred treatment in eyes with large vitreomacular traction sizes, an epiretinal membrane component, or both. Epiretinal membrane anchors the vitreous to the retina, and therefore inhibits ... pharmacologic vitreolysis.”²



OCT of the macula shows vitreomacular traction (top). About a month after Jetrea injection, the problem has resolved (bottom).

Clinical Results

So, how effective is this medicinal approach? Results from the Phase III clinical trials “showed that among patients without an epiretinal membrane, 37.4% in the ocriplasmin group had nonsurgical resolution of vitreomacular adhesion, as compared to 14.3% in the placebo group. Among patients with an epiretinal membrane, resolution of the vitreomacular

adhesion occurred in 8.7% of those in the ocriplasmin group as compared with 1.5% of those in the placebo group. Nonsurgical closure of a macular hole by day 28 was achieved in 40.6% of eyes injected with ocriplasmin, as compared with 10.6% of eyes injected with placebo.”³

“In the total population of patients, an improvement in best-corrected visual acuity of three or more lines was achieved in 12.3% of eyes injected with ocriplasmin, as compared with 6.4% injected with placebo.”³

The results are modest and the side effect profile (floaters, photopsia, injection-related eye pain and subconjunctival hemorrhage) is reasonable. So, it appears that for some patients with vitreomacular adhesion, with or without macular hole formation, ocriplasmin may be a reasonable nonsurgical alternative to vitrectomy. We don’t see any reason for great excitement here, but for some select patients this may be a very beneficial approach.

For instance, ocriplasmin is currently in Phase II surgical trials to evaluate its potential role in pediatric vitreoretinal surgery in place of autologous plasmin enzyme.⁴

1. Kiss S. Symptomatic vitreomacular adhesion. *Advanced Ocular Care*. 2012 Nov/Dec;16-17.

2. Johnson MW. How should we release vitreomacular traction: surgically, pharmacologically, or pneumatically? *Am J Ophthalmol*. 2013 Feb;155(2):203-205.

3. Stalmans P, Benz MS, Gandorfer A, et al; MIVI-TRUST Study Group. Enzymatic vitreolysis with ocriplasmin for vitreomacular traction and macular holes. *N Engl J Med*. 2012 Aug 16;367(7):606-15.

4. Wong SC, Capone A Jr. Microplasmin (ocriplasmin) in pediatric vitreoretinal surgery: update and review. *Retina*. 2013 Feb;33(2):339-48.

Steroids

The more we practice, the more we see the tremendous benefits of corticosteroids for our patients' inflammatory conditions.

We have long been advocates of the use of topical ophthalmic corticosteroids—either alone or in combination with an antibiotic—in the treatment of almost all cases of acute red eyes.

The more we practice, the more we see the benefits of corticosteroids for our patients. In our 64+ combined years of intense clinical practice using steroids on tens of thousands of patients, we have not experienced a single clinical

misadventure with the use of these wonderful medications. Quite honestly, we have become rather tired of hearing all about these side effects of steroids (because they are so rare):

- **Glaucoma.** Yes, the IOP can increase transiently, but only a completely incompetent doctor or noncompliant patient would allow such an increased IOP to progress to true glaucomatous optic neuropathy!
- **Cataract.** When they occur,

posterior subcapsular cataracts (PSC) are almost always associated with the long-term use of oral prednisone, but the incidence is less than 40% of long-term steroid users.¹

- **Secondary infection.** We have heard of bacterial superinfection with the use of corticosteroids, but have never seen it.

We have seen, at the hands of other eye doctors, steroid use on what turned out to be herpes simplex keratitis. So, we stopped the steroids and began the appropriate antiviral, and these patients did just fine.

- **Delayed healing.** Heard of this, but have never seen it!

There is no doubt that steroids have, and can, cause horrible outcomes—we just haven't seen any of these in our own practices. Why? Probably because we try really hard to have an accurate diagnosis before initiating any therapy. We limit the amount of medicine dispensed.

Perhaps most importantly, we really talk with our patients. We tell every patient we treat medically or optically something like this: "This should solve your problem, but if it does not, or certainly if your condition worsens, please

'Hit the Patient Over the Head' with Steroids

"You cannot overdose a steroid in the first couple of days. You want to hit the patient over the head," stated Jimmy Bartlett, OD, at a special session during the recent SECO International meeting in February. His discussion focused on anti-inflammatories, specifically on steroids. Dr. Bartlett said he was surprised to learn that many optometrists never use steroids.

"Don't be timid about using steroids. QID is not enough!" Dr. Bartlett said. "The more frequently you dose the steroid, the greater the anti-inflammatory effect. It's always better to give the patient too much than not enough."¹

In most cases, start with pulse-dosing of one drop every one to two hours for the first couple of days, and taper down from there, he said.

With the ketone-based steroids prednisolone and dexamethasone, 7% to 8% of the general population has a steroid response greater than 10mm Hg, he said, which happens only within the first month or so. With the ester-based steroid loteprednol 0.5%, only 2% of patients have a similar steroid response.

But don't be overly concerned about steroid-induced ocular hypertension. "Once you stop the steroid, the IOP will usually return to normal within one week," Dr. Bartlett said.

1. Leibowitz HM, Kupferman A. Optimal frequency of topical prednisolone administration. Arch Ophthalmol. 1979 Nov;97(11):2154-6.

let us know.” We also assure our patients that one of our doctors is always on call, so even if there is an eye emergency in the evening or on holidays or weekends, “a doctor is available to help you.” We think “managing the patient” is just as crucial as “managing the disease” to achieving good outcomes. If our patients are not happy with their glasses or contacts, or their medical care, we most certainly want to know so that we can help to resolve the problem.

Our Steroids of Choice

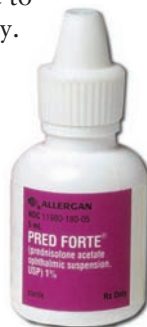While there are numerous topical ophthalmic corticosteroids available, we typically prescribe one of the following: Durezol (difluprednate 0.05%, Alcon), generic prednisolone acetate, Lotemax gel (loteprednol 0.5%, Bausch + Lomb), generic 0.1% fluorometholone or Alrex (loteprednol 0.2%, Bausch + Lomb).



• **Durezol.** We use Durezol as our “big gun” to treat advanced cases of iritis and episcleritis. Of note, we have essentially abandoned the use of brand name Pred Forte (prednisolone acetate 1%, Allergan) for two reasons: First, Durezol’s longer duration of action permits less frequent dosing—every two hours initially, rather than hourly. Second, pharmacists regularly dispense a generic for Pred Forte despite our written instruction to prescribe branded Pred Forte by name; so we just gave up the battle with pharmacies once Durezol became available.

Along with Durezol’s increased efficacy comes an increased risk of significant IOP elevation, especially in children.² So be sure to monitor IOP attentively.

• **Prednisolone acetate.** We find that generic prednisolone acetate is a reasonable choice for mild to moderate acute inflammatory conditions, especially if cost is a concern—but

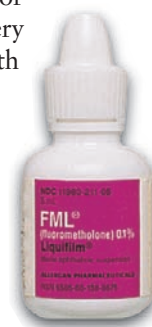

not in the setting of advanced iritis and episcleritis.

• **Lotemax gel.** We use Lotemax gel most often to help us care for our dry eye patients, but also to treat many other chronic, recurrent diseases such as stromal herpes simplex keratitis, Thygeson’s SPK, uveitis, inflamed pingueculae and pterygia, etc. (See “Lotemax Gel: A New Delivery Formulation,” page 21A.)

For perspective, only two out of 409 patients on Lotemax gel in Phase III studies had an increase in intraocular pressure greater than 10mm Hg.¹ This is very reassuring to us. In addition, loteprednol 0.5% suspension was recently documented to be as effective as prednisolone acetate for post-op cataract surgery inflammation, and with less effect on IOP.²

• **Fluorometholone 1%.** While there is no debate that an ester-based corticosteroid, such as loteprednol, is ideal for chronic disease management



Topical Corticosteroid Drugs

BRAND NAME	GENERIC NAME	MANUFACTURER	PREPARATION	BOTTLE/TUBE
Maximum Strength Steroids				
Durezol	difluprednate 0.05%	Alcon	emulsion	5ml
Lotemax	loteprednol etabonate 0.5%	Bausch + Lomb	suspension	5ml, 10ml, 15ml
Lotemax Gel	loteprednol etabonate 0.5%	Bausch + Lomb	gel-drops	5g
Lotemax Ointment	loteprednol etabonate 0.5%	Bausch + Lomb	ointment	3.5g
Pred Forte, and generic	prednisolone acetate 1%	Allergan, and generic	suspension	5ml, 10ml, 15ml
generic	prednisolone sodium phosphate 1%	generic	solution	5ml, 10ml, 15ml
Vexol	rimexolone 1%	Alcon	suspension	5ml, 10ml
Moderate and Lesser Strength Steroids				
Alrex	loteprednol etabonate 0.2%	Bausch + Lomb	suspension	5ml, 10ml
Flarex, and generic	fluorometholone acetate 0.1%	Alcon	suspension	5ml, 10ml
FML, and generic	fluorometholone alcohol 0.1%	Allergan	suspension	5ml, 10ml, 15ml
FML S.O.P.	fluorometholone alcohol 0.1%	Allergan	ointment	3.5g
Pred Mild, and generic	prednisolone acetate 0.12%	Allergan	suspension	5ml, 10ml

The Importance of Ocular Steroids

Given the therapeutic benefits and healing potential of these wonderful agents, consider these highlights on this topic from an article in the February 2013 issue of *EyeNet*. These clinically relevant quotes for the ophthalmologic audience are equally relevant for the optometric audience:

- The importance of ocular steroids to all of ophthalmology cannot be overstated. For more than 60 years, nothing has matched their effectiveness as fast-acting anti-inflammatory agents.
- Despite the fact that sequelae of uncontrolled inflammation are irreversible, many clinicians overlook corticosteroid therapy because they are concerned about side effects. "Far more harm has come from withholding steroids than from using them!" says John D. Sheppard Jr, MD, MMSc.
- Steroids disrupt the inflammatory cascade by immobilizing arachidonic acid, down-regulating multiple cytokine pathways including the vascular endothelial growth factor (VEGF) pathway, stabilizing cell membranes and mast cell granules, inhibiting leukocyte interaction, and slowing diapedesis, Dr. Sheppard explains.
- Steroids also are integral in treating conditions of immune hyperreactivity (e.g., noninfectious uveitis, graft rejection, allergic disorders such as atopic or vernal keratoconjunctivitis) and certain diseases that have both immune and infectious components (e.g., bacterial corneal ulcers). Moreover, steroids are key to damage control following ocular injuries.
- "One of the biggest problems we see in a referral practice is undertreatment," Dr. Sheppard says. "Many doctors are reluctant to prescribe adequate corticosteroid dosages because of fears of side effects." Paradoxically, this leads to protracted steroid use at higher-than-acceptable doses because of failure to gain complete control over the inflammation, making it difficult to taper the steroids.
- "Everyone is so paranoid about giving a patient a steroid cataract, but inflammation can be far more dangerous. If a patient takes so much steroid that he develops a cataract, then so be it. A cataract can be removed," Dr. Sheppard says.
- Steroid penetration through the cornea is quite effective, so cornea specialists often achieve success with topical steroids for ocular surface disease and anterior segment inflammation.
- "For blepharitis with a fair amount of skin involvement, the irritation can be quite trying for patients," says Stephen D. McLeod, MD. "In those cases, steroids can be helpful in shortening disease course and alleviating discomfort."

Weiner G. Corticosteroids: Still our best weapon against inflammation—when used wisely. *EyeNet*. 2013 Feb;12(2):44-53.

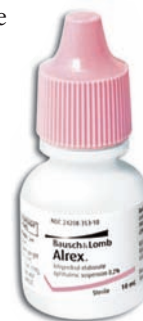Children and Steroids

- "A tapering regimen of FML for ocular surface disease in children constitutes a safe anti-inflammatory treatment option to avoid steroid-induced glaucoma."
 - "These patients may need prolonged treatment with FML to control the inflammation, a tapering regimen may help avoid steroid-induced glaucoma."
 - No participant had an increased IOP above 19mm Hg.
- We would be much more comfortable using an ester-based corticosteroid such as loteprednol with these patients.

Mataftsi A, Narang A, Moore W, Nischal KK. Do reducing regimens of fluorometholone for paediatric ocular surface disease cause glaucoma? *Br J Ophthalmol*. 2011 Nov;95(11):1531-3.

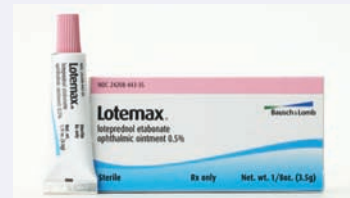(because of its enhanced safety profile vis-à-vis intraocular pressure), there are times when cost is a critical issue, and we reluctantly allow the substitution of generic 0.1% FML for Lotemax gel in those circumstances. We tend to follow the FML users more closely than the Lotemax gel users because of slightly more concern for increased IOP and cataracts.

• **Alex.** For allergic eye disease, it is important to prescribe a topical steroid when itching is accompanied by clinical signs of conjunctival injection,



Loteprednol Ophthalmic Ointment

- The only ester-based steroid ointment available.
- 0.5% concentration and preservative-free.
- FDA-approved for postoperative inflammation and pain.
- Numerous "off-label" clinical uses: dry eye, allergy, corneal transplant protection, blepharitis, giant papillary conjunctivitis, chronic uveitis, stromal immune herpetic keratitis, Thygeson's SPK, RCE, augmentation of steroid eye-drop therapy in acute advanced uveitis or episcleritis, following Betadine EKC Tx, contact dermatitis, and other inflammatory conditions.
- Available in a 3.5g tube as Lotemax 0.5% ophthalmic ointment by Bausch + Lomb.



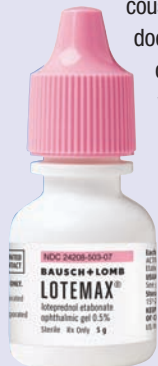Comstock TL, Paterno MR, Singh A, et al. Safety and efficacy of loteprednol etabonate ophthalmic ointment 0.5% for the treatment of inflammation and pain following cataract surgery. *Clin Ophthalmol*. 2011;5:177-86.

Lotemax Gel: A New Delivery Formulation

While eye doctors have been able to help many patients by using Lotemax suspension over the past decade, there is always room for improvement. Thus, a new formulation known as Lotemax gel (loteprednol 0.5%, Bausch + Lomb) came to market early this year.

So, what is so unique and special about this new “gel” formulation?

There are actually several innovative upgrades: A polycarboxophil adherent mucoadhesive molecule holds the loteprednol on the ocular surface longer. The delivery system is a gel formulation in the bottle, but through a process known as adaptive viscosity, it becomes a viscous liquid upon instillation in the eye. Because of the nature of this unique gel, it does not settle out of concentration, so it does not require shaking. (It is best to tip the bottle back and forth just once to make sure the drug enters the tip of the dropper prior to instillation, but no actual shaking is necessary.) Also, unlike with suspensions, this delivery system provides a perfectly uniform dose at every instillation. To enhance the moisturizing property of the gel, both glycerin and propylene glycol are in the mix. Also, the pH is even closer (at 6.5) to physiological pH than is Lotemax suspension (at pH 5.5). Further, Lotemax gel has 70% less BAK preservative than Lotemax suspension.



So, in our view, the new Lotemax gel drop is a significant update from its suspension predecessor. Our clinical experience indicates that, because of the nature of this formulation, patients can use it somewhat less frequently to achieve the desired clinical result. This has been very true for our many dry eye patients. (See our recommended algorithm for dry eye treatment on page 36A.)

In summary, Lotemax gel is a most welcome addition to our ophthalmic armamentarium. Do note that as a “gel,” it comes (by pharmaceutical convention) as a 5g (not a 5mL) bottle.

Clinical Pearl: Don't Blink an Eye!

Because the Lotemax gel drop is rather thick upon instillation, we advise patients to allow the drop to spread out on the ocular surface for four to five seconds before blinking, so that the initial blink does not displace the drop onto the eyelid. Advise patients that this will cause a few seconds of initial blur after instillation until the gel converts into a viscous liquid.

Fong R, Leitritz M, Siou-Mermet R, Erb T. Loteprednol etabonate gel 0.5% for postoperative pain and inflammation after cataract surgery: results of a multicenter trial. Clin Ophthalmol. 2012;6:1113-24.

chemosis or eyelid swelling. In these instances, Alrex (or even Lotemax gel) is our “workhorse” drug. We typically dose either Alrex (or Lotemax gel) QID for one week, then BID for one month, as needed.

The value of corticosteroid suppression for acute red eye is well appreciated by practicing clinicians. Inflammation is often the exclusive expression in these cases, and the benefits of corticosteroid suppression here greatly enhance patient care.

However, keep in mind that the “difficult-to-diagnose” red eye could be herpetic in nature, and more frequent follow-up may be in order in the management of unilateral red eye until the true nature of the condition becomes apparent. We've all learned, “when you hear hoof beats, think horses, not zebras,” as our friend, Lou Catania, OD, has often said. Yet we do oc-

asionally confront the “zebras” of orbital pseudotumor cerebri, low-flow cavernous sinus fistulas, etc., that present as a red eye. In these instances, topical corticosteroids are of zero value. An astute clinician always ponders all the diagnostic possibilities. As Dr. Catania also says, “It ain't rare if it's in your chair!” ■

1. Urban RC Jr, Cottler E. Corticosteroid-induced cataracts. Surv Ophthalmol. 1986 Sep-Oct;31(2):102-10.
2. Slabaugh MA, Herlihy E, Ongchin S, van Gelder RN. Efficacy and potential complications of difluprednate use for pediatric uveitis. Am J Ophthalmol. 2012 May;153(5):932-8.
3. US Food and Drug Administration. Center for Drug Evaluation and Research. Deputy Division Director Review for NDA 202-872. 2012 Sep 27. Available at: www.accessdata.fda.gov/drugsatfda_docs/nda/2012/202872Orig1s000MedR.pdf.
4. Lane SS, Holland EJ. Loteprednol etabonate 0.5% versus prednisolone acetate 1.0% for the treatment of inflammation after cataract surgery. J Cataract Refract Surg. 2013 Feb;39(2):168-73.

Long-Term FML Use After PKP

A recent study in Japan investigated the efficacy and safety of long-term use of corticosteroid eye drops after penetrating keratoplasty in a randomized, clinical trial.

“We found that the prolonged use of 0.1% fluorometholone was beneficial for the prevention of rejection after PKP. Because no adverse consequences associated with the use of the eye drops were noted, we recommend continuing the use of low-dose corticosteroids, even in non-high-risk cases,” the authors wrote.

In our view, if such prolonged use of a ketone-based steroid is safe and effective, it stands to reason that long-term use of loteprednol would be even safer. This has clear implications for long-term use in dry eye-related ocular surface inflammation.

Shimazaki J, Iseda A, Satake Y, Shimazaki-Den S. Efficacy and safety of long-term corticosteroid eye drops after penetrating keratoplasty: a prospective, randomized, clinical trial. Ophthalmology. 2012 Apr;119(4):668-73.

Perspectives on Viral Eye Diseases

Viral eye infections can be double trouble. If the initial infection is left untreated, it can go on to elicit an immune/inflammatory response.

Taking care of epithelial herpes simplex disease is straightforward. There are three therapeutic approaches:

- **Zirgan** (ganciclovir gel, Bausch + Lomb) five times daily for four to seven days, then TID for four to seven more days. Longer dosing may be required for larger geographic lesions.

- **Trifluridine** every two hours for four to seven days, then QID for four more days.

- **Oral antiviral**, such as generic acyclovir 400mg five times daily for one week, generic valacyclovir 500mg TID for one week, or generic famciclovir 250mg TID for one week.

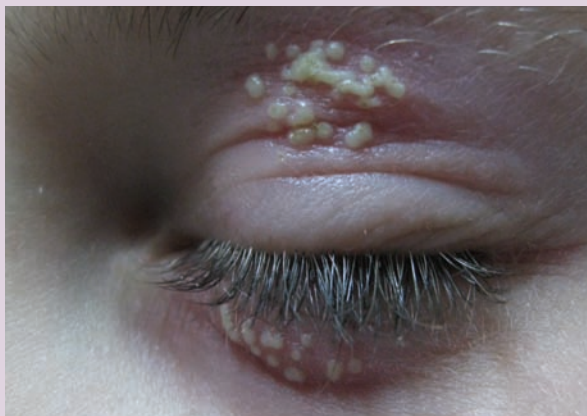The oral acyclovir is the least ex-

pensive option, while Zirgan is the most advanced topical approach.

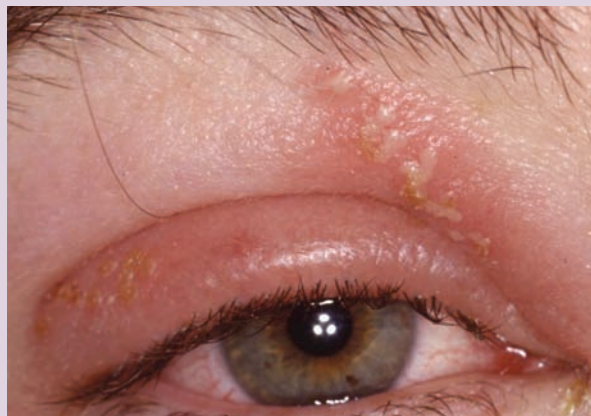
However, if the herpes simplex virus, varicella zoster virus or adenovirus is allowed to linger on the ocular surface without treatment, the viral antigenic particles can seep into the anterior stromal tissues, where secondary immune/inflammatory response can occur.

Primary HSV Infection

- Vesicular eruptions on the eyelid skin and/or eyelid margin.
- Can be limited to the skin or can also result in follicular conjunctivitis and/or corneal epithelial disease.
- Treatment:
 - Acyclovir: 400mg PO 5x/day x 1 week
 - Valacyclovir: 500mg PO TID x 1 week
 - Famciclovir 250mg PO TID x 1 week
- Vesicles resolve without scarring.



Vesicles in herpes simplex periorbital dermatitis.



Vesicles in herpes simplex blepharitis.

With herpetic viral diseases, the patient may present weeks or months later with a hot, steamy, red, inflamed eye with anterior chamber inflammation and an increased intraocular pressure. (With the adenoviruses, the secondary immune response manifests as subepithelial infiltrates. These appear as round or oval, whitish lesions. They do not stain with vital dyes because they are subepithelial.)

What's going on, and how can we heal these tissues?

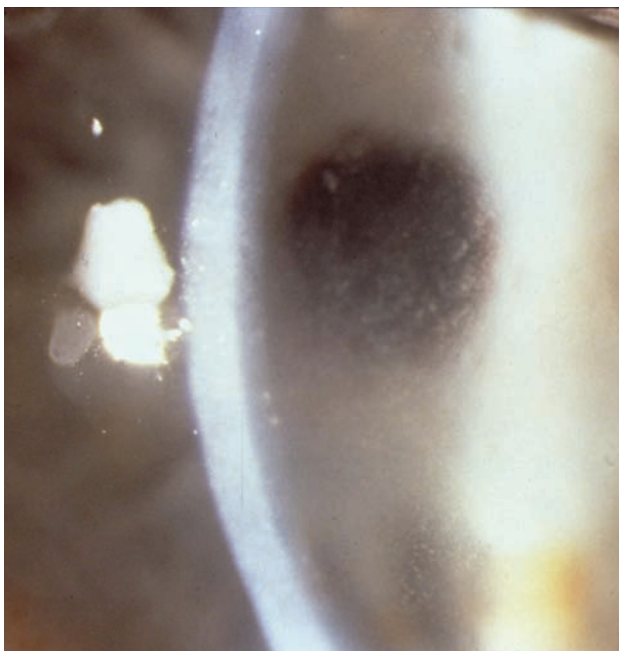
These herpes-family viruses can have two lives. That is, if the initial infection is left untreated, it can go on to elicit an immune/inflammatory response. The key to preventing this secondary sequela is early elimination of the primary infection.

This requires four things:

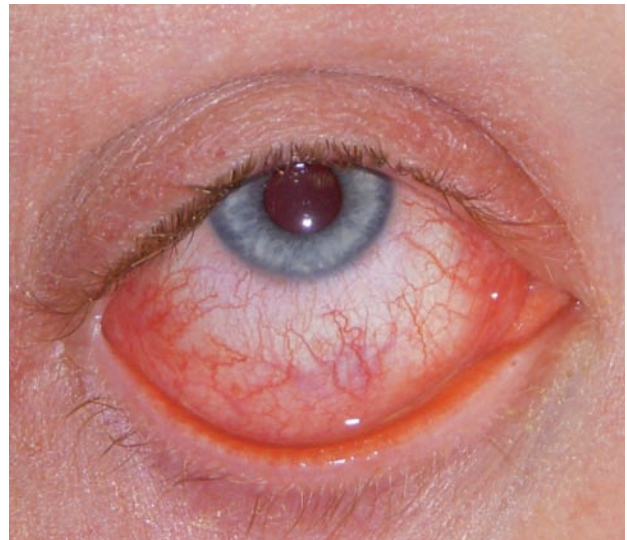
- *A timely patient presentation.*
- *An accurate diagnosis by the doctor.*
- *A prescription for the appropriate medicine.*
- *The patient must use the medicine as prescribed.*

If these four stars align, then the outcome is clinical success. However, if any one (or more) of these four components is missing, then prolonged viral residency time on the ocular surface occurs, which sets the stage for an immune response.

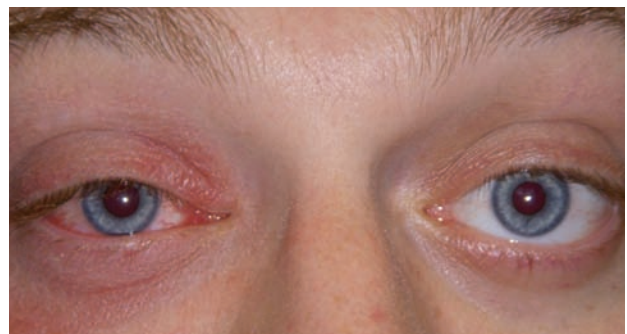This photo (*below*) shows an eye in which two or three of these four key initial factors were abridged. The result is a steamy cornea, markedly decreased vision, uveitis with a few keratic precipitates on the endothelium and an intraocular pressure around 50mm Hg. What to do?



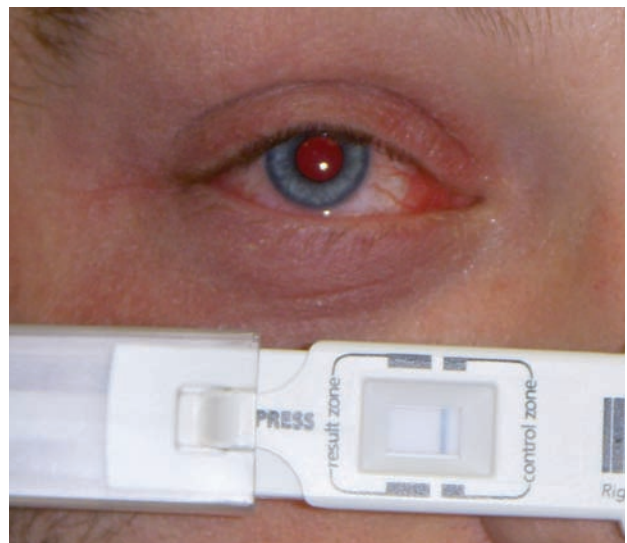
Herpetic stromal immune keratitis.



Look closely. Can you tell if this patient has adenoviral conjunctivitis or bacterial conjunctivitis?



The patient presented with unocular bulbar conjunctival injection, with no evident discharge.



In-office adenoviral testing displays a negative result. This patient does not have adenoviral conjunctivitis.

Antiviral Drugs

Herpes Zoster Disease

When patients present with facial shingles, either primarily or upon referral from a primary care physician, there are several medical approaches and options to consider: three oral antiviral choices, several topical corticosteroids, cycloplegic options, oral prednisone and oral analgesics. Not every patient needs all of these interventions, of course, so let's go through these choices step-by-step.

- **Oral antiviral.** First of all, every patient needs oral antiviral therapy. It is often said that these drugs perform best when used within the first three days of outbreak. While that is true, these medicines appear to still work adequately even if the patient has delayed in seeking care for up to a week.¹

The least expensive option is acyclovir 800mg, five times daily for one week. The other two antivirals, while also generic, are more expensive, perhaps because they only have to be taken every eight hours (TID). These are valacyclovir (original brand name: Valtrex) taken at 1,000mg TID for one week and famciclovir (original brand name: Famvir) prescribed at 500mg TID for one week.

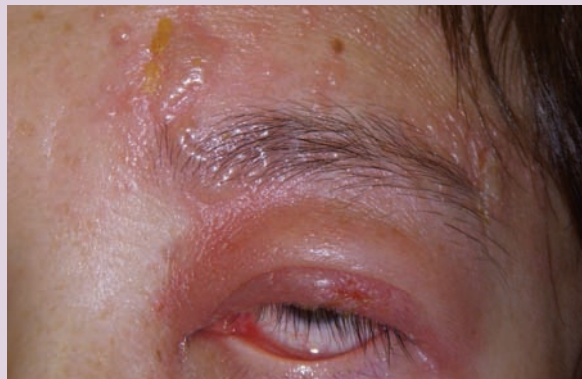The only real precaution with these medicines is that they are cleared through the kidneys; so if the patient has any significant renal disease, lower dosages are required. (Computer programs can calculate the correct dosage once the creatinine clearance and glomerular filtration rate is obtained from the patient's primary care physician or nephrologist. Ancillary staff can be a huge help with these telephone calls.)

- **Oral prednisone.** Older patients with more severe or painful herpes zoster disease often benefit from 40mg to 60mg of oral prednisone taken for several days. If the patient has peptic ulcer disease, also consider 20mg a day of over-the-counter Prilosec OTC (omeprazole, Procter & Gamble) to be taken along with the prednisone to help protect the stomach lining. Regardless, instruct the patient to take the prednisone with a meal.

The prednisone can help control pain and also somewhat dampen or guard against postherpetic neuralgia. If pain is severe, prescribe Lortab 5/500 (5mg hydrocodone/500mg of acetaminophen, UCB S.A.). The *sig* would be: Take 1 tablet PO Q4-6 hours as needed for pain; dispense #20 (or whatever reasonable number you think will be sufficient).

If the intraocular pressure elevates to 35mm to 40mm Hg or greater, consider prescribing timolol for the patient to use every morning and/or brimonidine BID to suppress the intraocular pressure spike. (A rapid-onset ocular hypotensive medicine such as a beta blocker or an alpha-adrenergic agonist will be more effective than any of the prostaglandins in this situation.) Once the topical and/or systemic steroids kick in to reduce panuveitis (including trabeculitis, the source of increased intraocular pressure), the IOP should return to reasonable levels within just a few days.

- **Topical corticosteroid.** The next question is whether the globe is involved in the zoster disease or not. Forget the



Facial shingles in a patient with herpes zoster ophthalmicus.

Hutchison's sign; just carefully examine the anterior chamber and cornea to look for uveitis and/or keratitis, the two most common ocular expressions of herpes zoster disease. Always check the intraocular pressure and perform a dilated retinal examination just to be thorough. If there is ocular expression of disease (uveitis, keratitis, increased IOP, etc.), then a potent topical corticosteroid is in order, probably every two to four hours for a few days.

- **Cycloplegia.** A cycloplegic, such as 5% homatropine or 0.25% scopolamine, BID to QID may also be appropriate.

- **Zoster vaccine.** Remember to suggest to all of your patients over age 50 that they inquire of their primary care provider about Zostavax vaccine (zoster live, Merck) for shingles. For patients who have already had shingles, we do not necessarily feel that they should have the vaccine, as the natural history of recurrence is about 6%.² Be aware that Zostavax only reduces the risk of getting shingles by 50% to 60%; but even if one does get shingles after vaccination, the clinical expression of the disease may be reduced.³

There is a small subset of mostly older patients who develop postherpetic neuralgia, and this is best managed by their primary care physician or pain clinic.

Also, even fewer, mostly older, patients will develop neurotrophic keratitis, which is managed with punctal plugs, oral doxycycline (50mg per day for three to four months), long-term daily use of 2,000mg of fish oil, and copious lipid-based artificial tears or ointment, and perhaps Lacrisert.

In short, most patients with facial zoster expression respond nicely to oral antivirals alone (if the globe is not involved) or with topical corticosteroids (if the globe is involved), especially if they don't delay in seeking care. Other interventions are brought into play on an individual, as-needed basis.

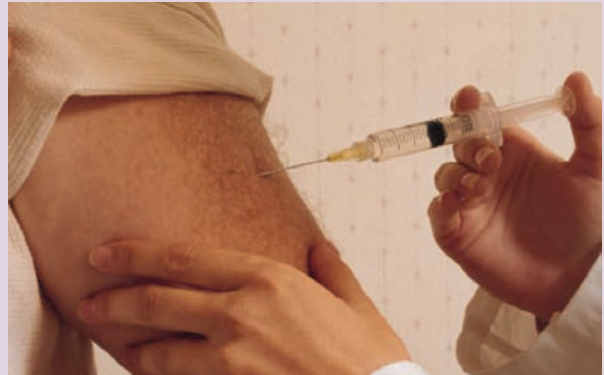1. Dworkin RH, Johnson RW, Breuer J, et al. Recommendations for the management of herpes zoster. *Clin Infect Dis.* 2007 Jan 1;44 Suppl 1:S1-26.

2. Yawn BP, Wollan PC, Kurland MJ, et al. Herpes zoster recurrences more frequent than previously reported. *Mayo Clin Proc.* 2011 Feb;86(2):88-93.

3. Oxman MN, Levin MJ, Johnson GR, et al; Shingles Prevention Study Group. A vaccine to prevent herpes zoster and postherpetic neuralgia in older adults. *N Engl J Med.* 2005 Jun 2;352(22):2271-84.

Give Zostavax a Shot

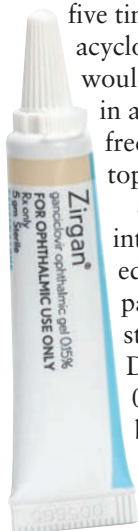
- Vaccine for prevention of shingles in adults age 50 and older.
- Marketed by Merck as Zostavax and given as a single dose by injection.
- Anyone who has been infected by chickenpox (more than 90% of adults in US) is at risk for developing shingles.
- Contraindicated if Hx of allergy to gelatin, neomycin; Hx of acquired immunodeficiency states; pregnancy.
- In landmark Shingles Prevention Study, Zostavax reduced risk of developing shingles by 51% (four years of follow-up) in all participants.
- Its effectiveness declines with increasing age. For people 50 to 59 years old, Zostavax reduced the risk of developing shingles by approximately 70%. It reduced the risk by 64% in people 60 to 69, by 41% for the 70 to 79 age group, and 18% for those 80 years of age and older.
- Duration of protection after vaccination is unknown.



US Food and Drug Administration website. Zostavax (Herpes Zoster Vaccine) Questions and Answers. Last Updated: 2012 Jan 12. Available at: www.fda.gov/BiologicsBloodVaccines/Vaccines/QuestionsaboutVaccines/ucm070418.htm. Accessed April 2013.

Recognize this clinical picture for what it is: a pronounced post-viral kerato-uveotrabeculitis. The intraocular pressure is elevated because of a panuveitis (which includes the trabecular tissues).

If this particular post-viral response is associated with a prior herpes simplex infection, treatment is a bit more onerous than if the initial infection was due to varicella zoster or adenovirus, because here topical or oral antiviral coverage is in order. One could use Zirgan five times per day or oral acyclovir 400mg BID. (We would use oral acyclovir in an effort to reduce the frequency and intensity of topical therapy.)

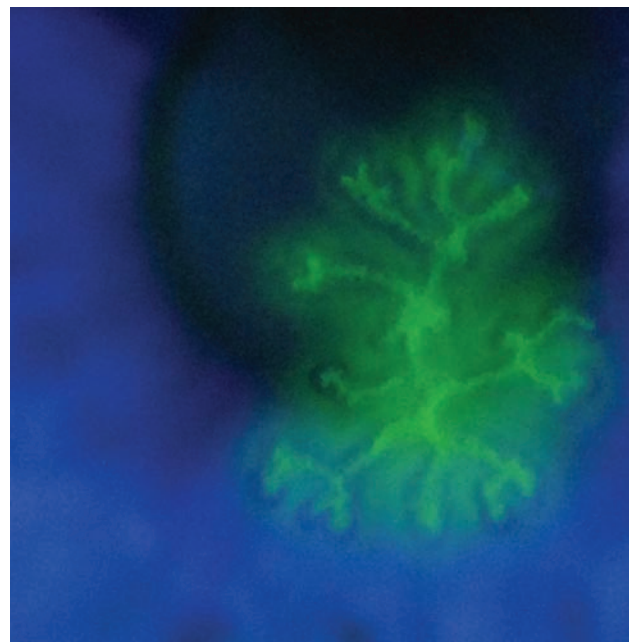


So, what topical interventions are needed? In such a case of panuveitis, the potent steroids of choice are Durezol (difluprednate 0.05%, Alcon) or brand name Pred Forte (prednisolone acetate 1%, Allergan), both of which penetrate

the intact cornea. Dose one of these drops every two hours until the tissues are quiet. Then begin a step-down taper of the drop over four to 10 weeks. Once the inflammation is markedly reduced (generally within a week or two), we prefer the Lotemax gel for the protracted taper. (If inflammation rebounds as the drop is tapered, then a longer, slower taper is required.) Also dose either 5% homatropine or 0.25% scopolamine TID for a week or so initially until the preponderance of the inflammation is well controlled, especially if the patient is experiencing pain or discomfort. Then, either decrease or dis-

continue the medication, depending upon your clinical judgment.

The intraocular pressure is elevated because of trabecular inflammation, so the steroid is the key to IOP reduction. A beta blocker—such as timolol once daily, or Combigan (brimonidine tartrate



Herpes simplex keratitis displays the classic branch-like dendritic lesion.

Antiviral Drugs

'Tips' to Make the Correct Diagnosis

Having a properly equipped office is foundational to meeting the needs of patients who trust us with their eye care. Every optometric office should have both of these at the ready.

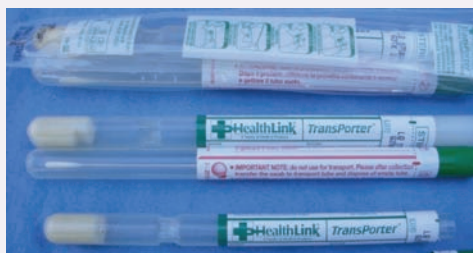

• **AdenoPlus.** Empirically differentiating adenoviral infection from bacterial infection is not always easy or exact. There can be an overlap of signs and symptoms, largely depending on the stage at presentation. So, a simple, inexpensive, medically-reimbursable, in-office assay can be tremendously helpful for differentially diagnosing bacterial from adenoviral infections.

The AdenoPlus (Nicox) is now a “must-have” assay device for all optometric offices. It can be immensely helpful for those uncommon, difficult-to-diagnose, acute red eye presentations.

Although AdenoPlus is a CLIA-waived point-of-care test, your office must still obtain CLIA registration (which is easy to do), and you or another doctor in your office must be designated as a clinical lab director. (For more information, see www.cms.gov/clia/.)

• **Culturette swabs.** Equally as valuable are the Mini-Tip Culturrectes (Becton, Dickinson and Company) for obtaining bacterial cultures. Put one of these to use when you encounter moderate to severe bacterial infection for which laboratory guidance as to the exact causative organism could be helpful in effecting a clinical cure. You collect the specimen in the office, then the lab's courier or your staff member takes the specimen to a hospital or private microbiology laboratory for processing. The lab will communicate back to your office as soon as the results are determined.



0.2%/timolol maleate 0.5%, Allergan) or preservative-free Cosopt PF (dorzolamide 2%/timolol maleate 0.5%, Merck) twice daily—for a few days can be added if desired, but the intraocular pressure will be greatly reduced within just a few days of topical steroid therapy.

The oral antiviral prophylactic

coverage usually can be discontinued after the steroid frequency is tapered to once or twice a day, if desired.

However, patients with stromal immune herpes simplex viral keratitis should be prescribed oral acyclovir 400mg BID or valacyclovir 500mg QD for five disease-free

years, and then a trial discontinuation can be done.

It is well known that herpes simplex disease tends to recur—the likelihood is about 27% at one year, 50% at five years and 63% at 20 years.¹ But a low-dose protocol of an oral antiviral diminishes the risk of recurrence by about 50%. Even if there is a recurrence, its clinical expression should be considerably muted if the patient has been taking one of the low-dose oral antiviral medicines.

Of course, such cases of post-viral response to herpes simplex are not common, but this “walk through” of the critical thought process should help you to maneuver through the assessment and decision-making for these more challenging clinical presentations. ■

Povidone-Iodine Treatment

- Betadine 5% Sterile Ophthalmic Prep Solution (30ml opaque bottle), Alcon
- A broad-spectrum microbicide.
- Indicated for “pre-operative prep and irrigation of the ocular and periocular surfaces.”
- Off label use: Tx adenoviral keratoconjunctivitis
 - Anesthetize with proparacaine
 - Instill one or two drops of NSAID
 - Instill several drops Betadine 5% in eye(s); close eye(s)
 - Swab or rub excess over eyelid margin
 - After one minute, irrigate with sterile saline
 - Instill one or two drops of NSAID
 - Rx steroid QID for four days
- Avoid use if patient is allergic to iodine.
- CPT code 99070—materials and supplies

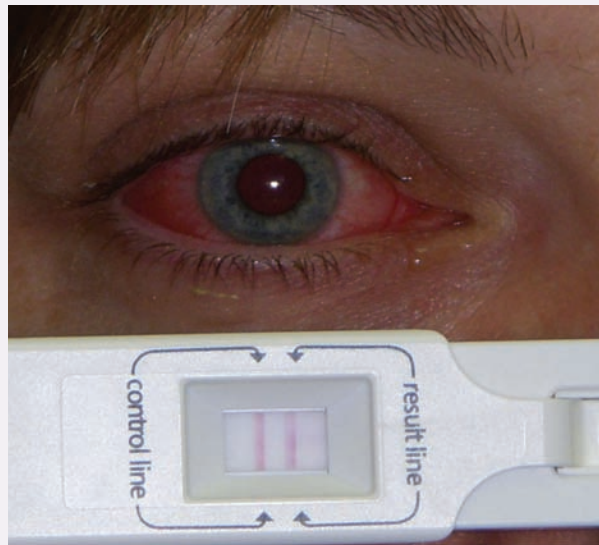


1. Young RC, Hodge DO, Liesegang TJ, Baratz KH. Incidence, recurrence, and outcomes of herpes simplex virus eye disease in Olmsted County, Minnesota, 1976-2007: the effect of oral antiviral prophylaxis. Arch Ophthalmol. 2010 Sep;128(9):1178-83.

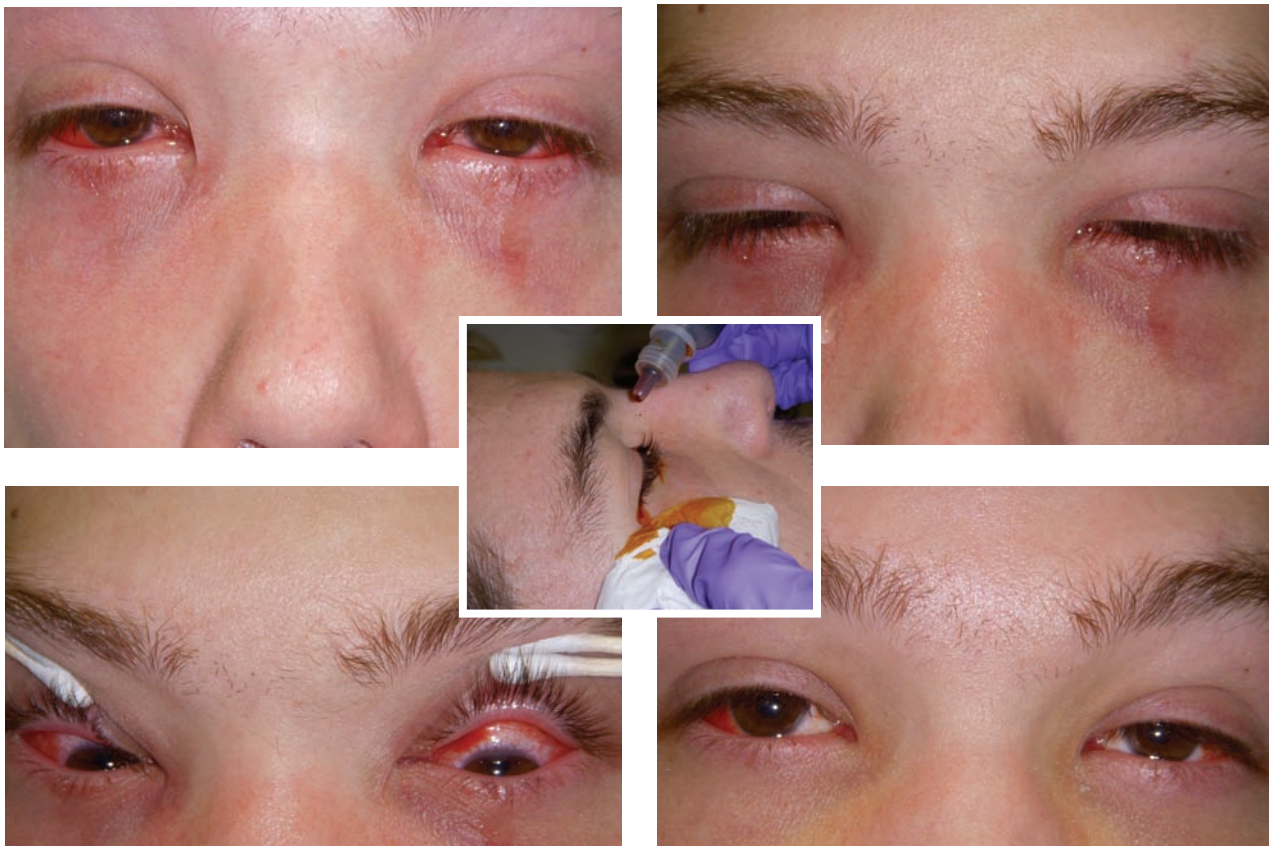Points on AdenoPlus 'Pink Eye' Test

- Convenient, in-office, 10 minute immunoassay.
- Detects all known serotypes of adenovirus.
- Has 90% sensitivity and 96% specificity. By comparison, clinical diagnostic accuracy ranges from 40% to 70%.
 - Test result correlates with disease infectivity (i.e., the intensity of the positive result line is directly proportional to the amount of antigen present).
- Helpful for challenging cases and for primary care physicians.
- Clinical Laboratory Improvement Amendments (CLIA) waived.
- CPT code: 87809-QW (also add –RT or –LT for each eye).
- Adenovirus can cause nonspecific follicular conjunctivitis, pharyngoconjunctival fever, acute hemorrhagic conjunctivitis and epidemic keratoconjunctivitis.
 - “In addition to the typical management strategy for adenovirus conjunctivitis, two novel treatments, topical povidone-iodine and ganciclovir gel, have become more widely used.”

Sambursky R, Trattler W, Tauber S, et al. Sensitivity and specificity of the AdenoPlus test for diagnosing adenoviral conjunctivitis. JAMA Ophthalmol. 2013 Jan;131(1):17-22.



Ten minutes after swiping the eye, the test displays a positive result for adenovirus in this patient.



This patient presented with classic acute adenoviral conjunctivitis (epidemic keratoconjunctivitis). Note the half-closed eyes due to foreign body sensation and photophobia. The patient also demonstrated the typical watery, serous discharge. She was given povidone-iodine lavage (center photo, in a different patient), and her symptoms began to resolve within a day or two.

Antibiotics

No new medications have been added to the antibiotic armamentarium in the past two years, so here we review some strategies behind antibiotic prescribing.

As ocular tissue is exposed to the environment, the cornea and conjunctiva have an opportunity to become infected. There is a wide variety of microorganisms that can use these tissues as nutrient sources. These are known as infections, and are an unpleasant intrusion into our lives.

For most viral afflictions to the body, especially upper respiratory infections, there is no effective

antiviral therapeutic available, so our body's innate defenses eventually eliminate these viruses. Viral eye disease, however, is primarily caused by viruses for which we have good chemotherapeutic agents.

When we generally think of antibiotics, our minds quickly turn to medicines that kill bacteria. Thankfully, most such bacterial infections are quickly eliminated from the

ocular surface tissues. (Corneal ulcers present a more formidable clinical challenge.)

Oral vs. Topical

There have been no new additions to the antibiotic armamentarium in the past two years, so this chapter reviews some strategies behind antibiotic prescribing. New articles have shed more light on the clinical efficacy of some of the antibiotics that are available to us, and these are shared here.

• *Take care with topicals.* In point of fact, we prescribe oral antibiotics more often than topical antibiotics. There are two main reasons for this: First is epidemiological—we simply encounter acute internal hordeola more often than bacterial conjunctivitis; second, when we do encounter a bacterial conjunctivitis, we usually treat it with an antibiotic/steroid combination drug. If we do prescribe a topical antibiotic, we generally prescribe trimethoprim/polymyxin B, an aminoglycoside or besifloxacin. Several independent articles in the professional literature warn

Topical Antibiotics in Perspective

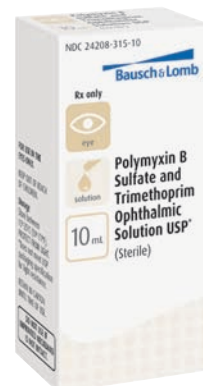- "In an era where products are heavily advertised by pharmaceutical companies, it is sometimes difficult to separate peer-reviewed scientific studies from promotional literature printed by the drug manufacturer."
- "The fourth-generation fluoroquinolones demonstrated an in vitro efficacy of less than 80%."
- "Many organisms, especially coagulase-negative staphylococci, are commonly resistant to the fourth-generation fluoroquinolones, which are the most popular topical antibiotics used in ophthalmology today."

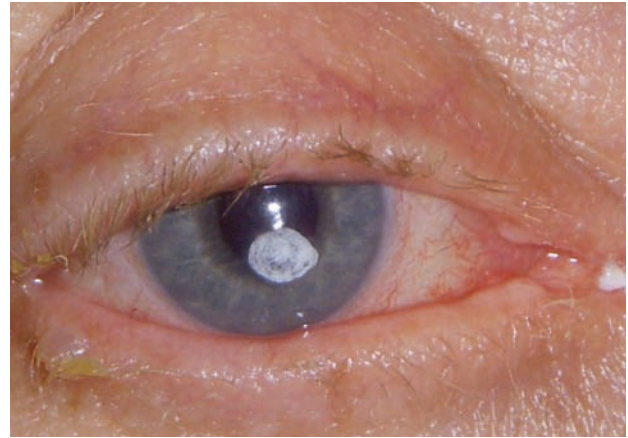
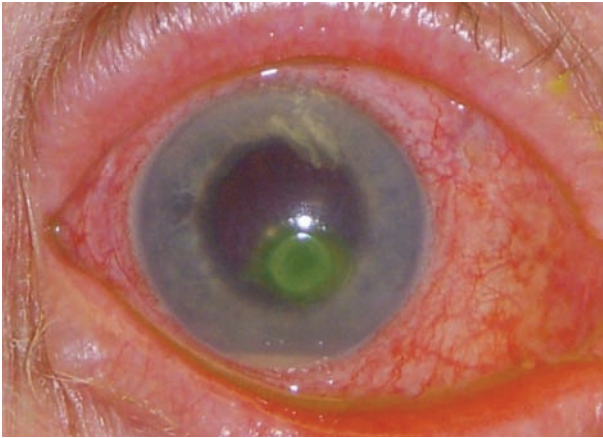
Scott IU, Flynn HW Jr. The role of topical antibiotic prophylaxis for intravitreal injections. *Arch Ophthalmol.* 2007 Jul;125(7):974-6.

Antimicrobial Resistance

- "The high prevalence of fluoroquinolone-resistant organisms among ocular and nasal flora in our patient population raises concern with regard to the usefulness of topical fluoroquinolones as the best first-line agent in the setting of ophthalmic prophylaxis and for empiric use in acute ophthalmic infectious processes."
- *Staph. epidermidis* was the most common pathogen in this study.
- 97% of all isolates were sensitive to gentamicin.
- Fluoroquinolone resistance ranged from 32% to 40%.

Alabiad CR, Miller D, Schiffman JC, Davis JL. Antimicrobial resistance profiles of ocular and nasal flora in patients undergoing intravitreal injections. *Am J Ophthalmol.* 2011 Dec;152(6):999-1004.





Here is a culture-proven infectious corneal ulcer. Intensive use of Besivance by day and Polysporin ointment at night successfully renormalized this cornea in about a week. A topical steroid was introduced QID after the third day of antibiotic use.

of increasing resistance, especially to methicillin-resistant *Staphylococcus aureus*, with the fourth-generation fluoroquinolones.

When we use an ointment, as we would when treating a severe conjunctivitis or bacterial

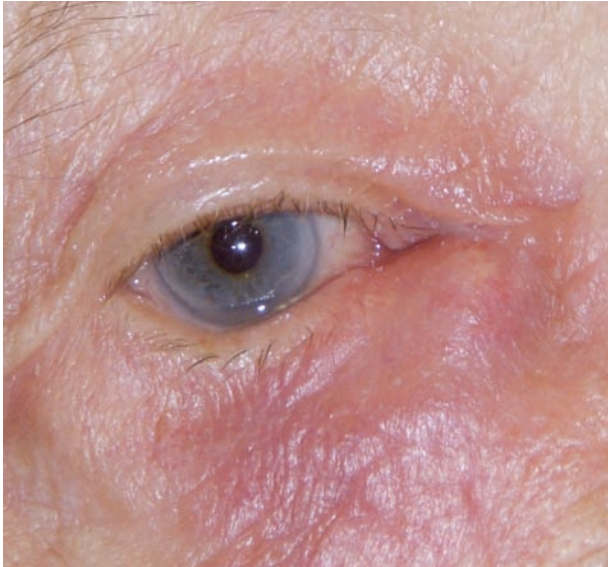
corneal ulcer, we generally use Polysporin, Neosporin or gentamicin ophthalmic ointment QHS.

• *Diligent dosing.* Regarding the topical antibiotic solutions, the important matter is not so much which one you prescribe as much

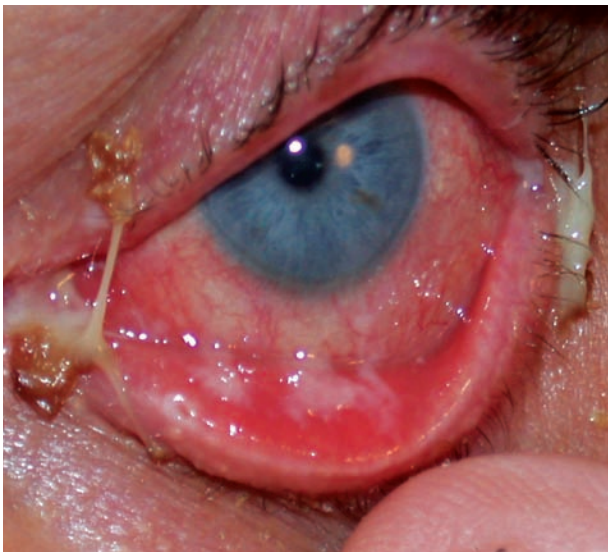as how frequently you dose it. As a very general rule, treat most acute ocular surface infections with an antibiotic drop every two hours for two days, then QID for four more days. Obviously, individualization of prescribing is essential.

Topical Antibiotic Drugs

BRAND NAME	GENERIC NAME	MANUFACTURER	PREPARATION	PEDIATRIC USE	BOTTLE/TUBE
Fluoroquinolones					
Besivance	besifloxacin 0.6%	Bausch + Lomb	suspension	≥ 1 yr.	5ml
Ciloxan, and generic	ciprofloxacin 0.3%	Alcon, and generic	sol./ung.	≥ 1 yr./ ≥ 2 yrs.	5ml, 10ml/3.5g
Iquix	levofloxacin 1.5%	Santen Pharm.	solution	≥ 6 yr.	5ml
Moxeza	moxifloxacin 0.5%	Alcon	solution	≥ 4 mos.	3ml
Ocuflox, and generic	ofloxacin 0.3%	Allergan, and generic	solution	≥ 1 yr.	5ml, 10ml
Quixin	levofloxacin 0.5%	Vistakon Pharm.	solution	≥ 1 yr.	5ml
Vigamox	moxifloxacin 0.5%	Alcon	solution	≥ 1 yr.	3ml
Zymaxid	gatifloxacin 0.5%	Allergan	solution	≥ 1 yr.	2.5ml
Aminoglycosides					
Tobrex, and generic	tobramycin 0.3%	Alcon, and generic	sol./ung.	≥ 2 mos.	5ml/3.5g
Garamycin, and generic	gentamicin 0.3%	Fera, and generic	sol./ung.	N/A	5ml/3.5g
Polymyxin B Combinations					
Polytrim	polymyxin B/trimethoprim	Allergan, and generic	solution	≥ 2 mos.	10ml
Polysporin	polymyxin B/bacitracin	generic	unguent	N/A	3.5g
Neosporin	polymyxin B/neomycin/gramicidin	generic	sol./ung.	N/A	10ml/3.5g
Other Antibiotics					
AzaSite	azithromycin 1%	Merck	solution	≥ 1 yr.	2.5ml
Ilotycin	erythromycin 0.5%	Fera	unguent	≥ 2 mos.	3.5g
Bacitracin	bacitracin 500u/g	Fera	unguent	N/A	3.5g



Management for this patient's case of acute dacryocystitis includes an oral antibiotic, topical antibiotic drops and warm compresses, as needed.



Mucopurulent conjunctivitis—including MRSA infection—calls for topical antibiotic treatment. Trimethoprim, in particular, has demonstrated significant activity against MRSA.

• **Options for oral antibiotics.** Among the oral antibiotics, Keflex (cephalexin, Victory Pharma) 500mg BID for seven to 10 days is the best option for most acute eyelid infections. But because it's a cephalosporin, cephalexin has the remote, but real, possibility of cross-reactivity with the penicillins; so if the patient is truly allergic to penicillin, then is it probably wisest to simply utilize an entirely different drug class.

Plan B in these instances is to use trimethoprim with

Antibiotic Use Causes Multidrug Resistance

- "Conjunctival *S. epidermidis* repeatedly exposed to fluoroquinolone or azithromycin antibiotics rapidly develop resistance."
- Gentamicin, Polytrim, doxycycline and vancomycin remain very highly effective medicines in eradicating *S. epidermidis*.
- The fluoroquinolones and macrolide antibiotics exhibit high levels of resistance.
- "These findings indicate the need for greater thought and more rational use of ophthalmic antibiotics to reduce the epidemic of antimicrobial resistance."

Dave SB, Toma HS, Kim SJ. Ophthalmic antibiotic use and multidrug-resistant staphylococcus epidermidis: a controlled, longitudinal study. *Ophthalmology*. 2011 Oct;118(10):2035-40.

Evolving Fluoroquinolone Resistance

"Fourth-generation fluoroquinolones are significantly more expensive than generic traditional antibiotic eyedrops such as gentamicin sulfate and polymyxin B sulfate/trimethoprim, which have been shown to cover endophthalmitis isolates at least as well ... Given the frequent and increasing resistance, subtherapeutic penetration and higher cost compared with other antibiotic eyedrops, the widespread perioperative and periprocedural use of fourth-generation fluoroquinolone antibiotic eyedrops should be reevaluated."

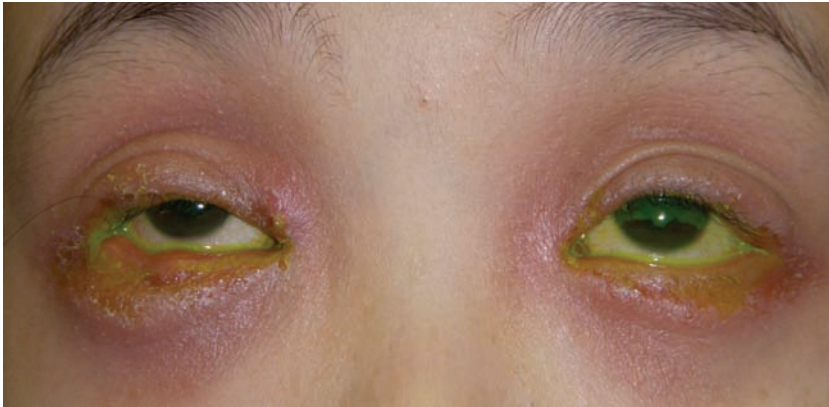
Schimmel AM, Miller D, Flynn HW. Evolving fluoroquinolone resistance among coagulase-negative Staphylococcus isolates causing endophthalmitis. *Arch Ophthalmol*. 2012 Dec 1;130(12):1617-8.

sulfamethoxazole (Bactrim and Septra are original brand names of this generic drug combination). Dosage is one or two DS (double-strength is the standard strength) tablets/capsules BID for seven to 10 days. Of course, if the patient also has an allergy to sulfa drugs, then avoid this class of drugs as well. Do note that trimethoprim with sulfamethoxazole is a drug of choice for systemic MRSA infections (as are clindamycin and doxycycline).

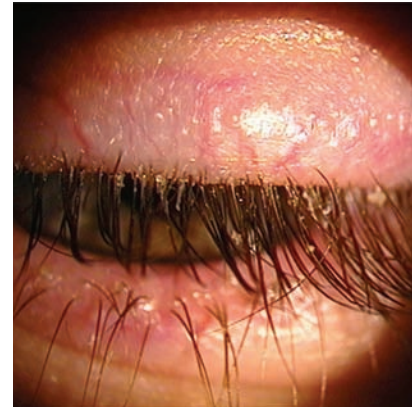"Plan C" could be either oral doxycycline 200mg per day for seven to 10 days or an oral fluoroquinolone such as Levaquin (levofloxacin, Janssen Pharmaceuticals) 500mg once daily for seven to 10 days.

Just to muddy the water a bit further, there is about a one in 1,000 chance that oral fluoroquinolones may cause a severe tendonitis, and a one in 2,500 chance that they may cause a rhegmatogenous retinal detachment.¹

• **Warm compresses.** Always remember to urge the patient to use warm compresses with any acute eyelid



This patient has internal hordeola and associated contact dermatitis. She was treated with warm soaks, cephalexin 500mg BID and triamcinolone cream TID.



Blepharitis requires good eyelid hygiene using lid scrubs, not baby shampoo.

infection, along with the oral antibiotic. Most such eyelid infections can be cured with aggressive use of warm soaks alone, but if the patient is in a fair amount of pain, or if the infection seems to be worsening, then do not hesitate to prescribe an oral antibiotic. A topical antibiotic for such eyelid infections is virtually worthless.

- **Chronic conditions.** For chronic conditions such as rosacea blepharitis and meibomian gland dysfunction, prescribe oral doxycycline 50mg once daily for three to four months, and a topical steroid such as Lotemax gel (loteprednol 0.5%, Bausch + Lomb) QID for two weeks, and then BID for one month. If there is significant staphylococcal blepharitis, we dose Zylet (loteprednol 0.5%/tobramycin 0.3%, Bausch + Lomb) ophthalmic suspension in the same manner. (We don't use dexamethasone for treatment of chronic conditions, or we would include TobraDex here, as well.)

- **Use scrubs, not shampoo.** Of course, eyelid scrubs should be employed if there is significant eyelid debris. We long ago replaced baby shampoo for use on the eyelids with commercially-prepared eyelid scrubs. These scrubs perform so much better, and are much more

convenient and user-friendly for the patient.

Regarding anterior segment disease, unless there is evidence of purulent discharge—either by gross or high magnification examination of the lacrimal lake to search for abundant microparticulate debris—then the diagnosis is very likely not bacterial in origin, and other etiologies or diagnoses should be sought.

Two reminders: infections have a discharge; and most acute red eyes are not caused by bacteria. Keep

these epidemiological and clinical characteristics in mind when assessing any red eye.

In summary, there is a clear role for antibiotics, both topical and oral, in caring for patients with bacterial eye and eyelid diseases. Used with great discretion, antibiotics can be enormously helpful in caring for bacterial infectious disease processes. ■

1. Albini TA, Karakousis PC, Abbey AM, et al. Association between oral fluoroquinolones and retinal detachment. *Am J Ophthalmol.* 2012 Dec;154(6):919-921.

Topical Antibiotics After Intravitreal Injection: Is There a Need?

- “Mounting evidence suggests that ocular surface organisms are becoming more resistant to fluoroquinolone, with up to 30% of cultured isolates being resistant.”
- In this prospective study, “one group (84 patients) received topical moxifloxacin QID for three days after each intravitreal injection, whereas the other group (94 patients) did not receive any prophylactic antibiotics ... The treated group had a higher culture-positive rate at post-injection month one, two and three, compared to the group that received no post-injection topical antibiotics.”
- “The use of povidone-iodine has been the only proven method in reducing the risk of endophthalmitis after intraocular surgery ... When povidone-iodine is used before injection, topical antibiotics have no additional benefit in reducing conjunctival colonization.”
- Conclusions and relevance: “Repeated use of topical moxifloxacin after intravitreal injection significantly increases antibiotic resistance of ocular surface flora. We recommend that routine use of prophylactic antibiotics after intravitreal injection be discouraged.”

This provides further support that there is overusage and overexposure to topical antibiotics in many areas of eye care. We need to think very carefully about “how, why and when” before we prescribe any type of antibiotic in our practices.

Yin VT, Weisbrod DJ, Eng KT, et al. Antibiotic resistance of ocular surface flora with repeated use of a topical antibiotic after intravitreal injection. *JAMA Ophthalmol.* 2013 Apr 1;131(4):456-61.

Allergy Management

We always ask, “Is it burning, or is it itching?” Sometimes patients say it’s both burning *and* itching. Be aware that allergy and dry eye sometimes come together.

How many hundreds of times have we heard this lament: “Doctor, my eyes just itch and burn all the time.” This common complaint brings us directly to the proverbial fork in the road. So, the first question we ask the patient is basic: “Is the burning or is the itching your main symptom?” Most patients can give a clear answer to this fundamental question.

For the few patients who feel the symptoms of burning and itching are about equal, or who can’t decide which symptom is most bothersome, treatment with a topical corticosteroid usually quells both complaints.

If itching is the predominant symptom,

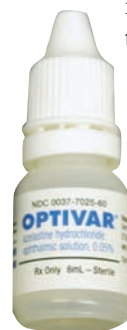
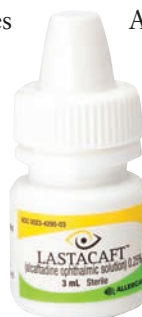
then medication selection takes one of two paths:

Symptoms Only

If there are minimal associated signs of allergy such as chemosis, conjunctival injection and/or eyelid edema, then an antihistamine/mast cell stabilizer is an excellent clinical approach. Within this class, there are six drugs from which to choose:

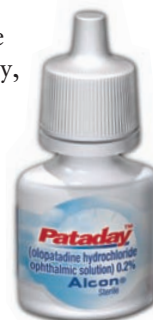- Alcaftadine (Lastacraft, Allergan)
- Azelastine (Optivar, Meda Pharmaceuticals, and generic)
- Bepotastine (Bepreve, Bausch + Lomb)
- Epinastine (Elestat, Allergan)
- Ketotifen (Zaditor, Alcon, and generic. This drop is OTC)



Alcon, and generic. This drop is OTC)

- Olopatadine (Patanol/Pataday, Alcon)

Of these, all are rated pregnancy category C except for Lastacraft, which is pregnancy category B.



Notwithstanding other fine differences, all of the antihistamine subtype 1 receptor blockers nicely suppress ocular itching. All are dosed initially BID (except Pataday and Lastacraft, which are dosed QD). We recommend that after two weeks at BID, have the patient try to reduce the drop to once-daily “maintenance” therapy. In our experience, once symptomatic itching has been brought under control, it takes less pharmacological intervention to maintain control. Then again, many patients seem best served with enduring BID therapy.

Perhaps the best news for the consumer was the loss of patent protection for Zaditor. Since 2007, ketotifen has been available



‘Is it Burning or is it Itching?’

• **Itching.** If itching is primarily expressed, determine if it is an isolated symptom or if it is associated with concurrent inflammatory signs, and then treat accordingly. Remember:

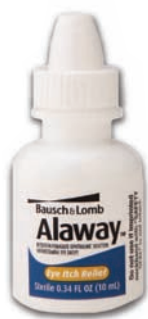Symptoms only—use an antihistamine/mast cell stabilizer.

Symptoms with signs—use a steroid such as Lotemax, Alex or FML.

• **Burning.** If itching is not the primary symptom, then be sure to consider dry eyes as the foundational condition and treat accordingly. If the main symptom is burning, then a thorough dry eye evaluation is in order.

There is no rule in the rulebook that says you can’t have two problems at the same time. So, because dry eye is very prevalent, always identify and manage this disease whether or not it is packaged with allergic eye disease.

generically and OTC. In addition to Zaditor, there are several “brand name” OTC ketotifen preparations, such as Alaway (Bausch + Lomb) and Refresh Eye Itch Relief (Allergan).



All come in 5mL bottles (except for Alaway, which comes as a 10mL bottle.) Interestingly, our casual observations in a variety of pharmacies reveal that the cost of 10mL Alaway is

very near (and occasionally cheaper) than the price of its 5mL competitors. So, dollar-for-dollar, OTC Alaway is the most cost-effective way to suppress ocular itch.

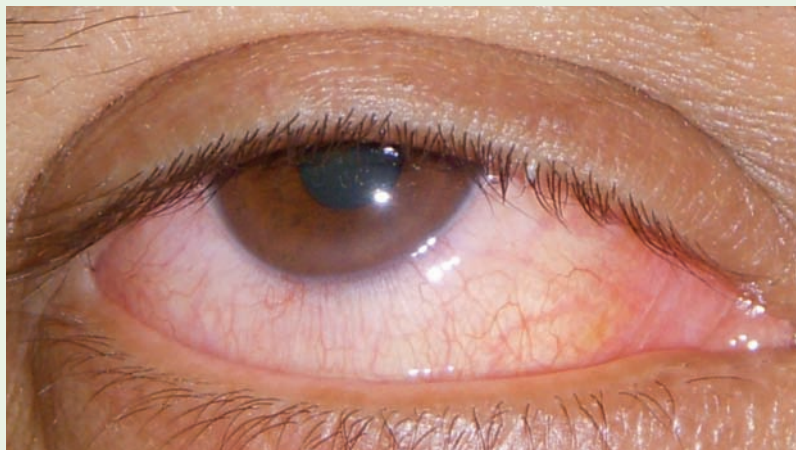When a prescription medication

Itchy Eyes Are Often Dry Eyes

Most patients with “itchy eyes” (consistent with allergic conjunctivitis) also have dry eyes and redness. Specifically, the odds of patients with “itchy eyes” who also have dry eyes are 2.11 times that of patients with non-itchy eyes. The odds of these patients also experiencing redness were 7.34 times that of patients with non-itchy eyes.

These results suggest that some symptomatic patients concomitantly have features of allergic conjunctivitis and dry eye syndrome.

Hom MM, Nguyen AL, Bielory L. Allergic conjunctivitis and dry eye syndrome. *Ann Allergy Asthma Immunol.* 2012 Mar;108(3):163-6.

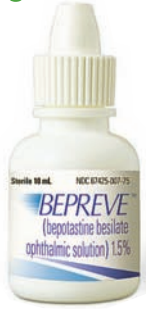

Ocular Allergy Medicines

BRAND NAME	GENERIC NAME	MANUFACTURER	PEDIATRIC USE	BOTTLE SIZE(S)	DOSING
Acute Care Products					
Acular LS	ketorolac tromethamine 0.4%	Allergan	3 years	5ml, 10ml	QID
Alaway (OTC)	ketotifen fumarate 0.025%	Bausch + Lomb	3 years	10ml	BID
Alrex	loteprednol etabonate 0.2%	Bausch + Lomb	12 years	5ml, 10ml	QID
Bepreve	bepotastine besilate 1.5%	Bausch + Lomb	2 years	5ml, 10ml	BID
Claritin Eye (OTC)	ketotifen fumarate 0.025%	Schering-Plough	3 years	5ml	BID
Elestat	epinastine HCl 0.05%	Allergan	3 years	5ml	BID
Emadine	emedastine difumarate 0.05%	Alcon	3 years	5ml	QID
Lastacaft	alcaftadine 0.25%	Allergan	2 years	3ml	QD
Optivar	azelastine hydrochloride 0.05%	Meda	3 years	6ml	BID
Pataday	olopatadine hydrochloride 0.2%	Alcon	3 years	2.5ml	QD
Patanol	olopatadine hydrochloride 0.1%	Alcon	3 years	5ml	BID
Refresh (OTC)	ketotifen fumarate 0.025%	Allergan	3 years	5ml	BID
Zaditor (OTC)	ketotifen fumarate 0.025%	Alcon	3 years	5ml	BID
Chronic Care Products					
Alamast	pemirolast potassium 0.1%	Santen	3 years	10ml	QID/BID
Alocril	nedocromil sodium 2%	Allergan	3 years	5ml	BID
Alomide	lodoxamide tromethamine 0.1%	Alcon	2 years	10ml	QID
Crolom	cromolyn sodium 4%	Bausch + Lomb	4 years	10ml	QID
Opticrom	cromolyn sodium 4%	Allergan	4 years	10ml	QID

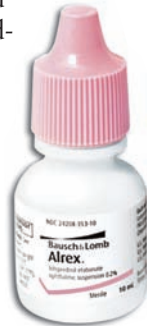Allergy Drugs

is preferred, perhaps a 10mL bottle of Bepreve (using a standard co-pay) would be of greatest cost value to the patient.



Symptoms Plus Signs

The other side of the dichotomous allergy presentation is the patient who presents with predominant itching plus one or more concurrent signs such as conjunctival redness, chemosis and/or eyelid edema. For this subset of patients, a topical corticosteroid such as Alrex (loteprednol 0.2%, Bausch + Lomb), Lotemax gel (loteprednol 0.5%, Bausch + Lomb) or FML ophthalmic suspension (fluorometholone 0.1%, Allergan) is more appropriate treatment.



The only other decision tree involves the frequency of instillation; we typically prescribe a steroid Q2H for two days, then QID for one week, followed by BID for one more week. Once the inflammatory signs are controlled, then consider switching the patient to an antihistamine/mast cell stabilizer for ongoing symptom control. Long-term treatment with Alrex BID as maintenance therapy can be done if a steroid is what best controls their disease.

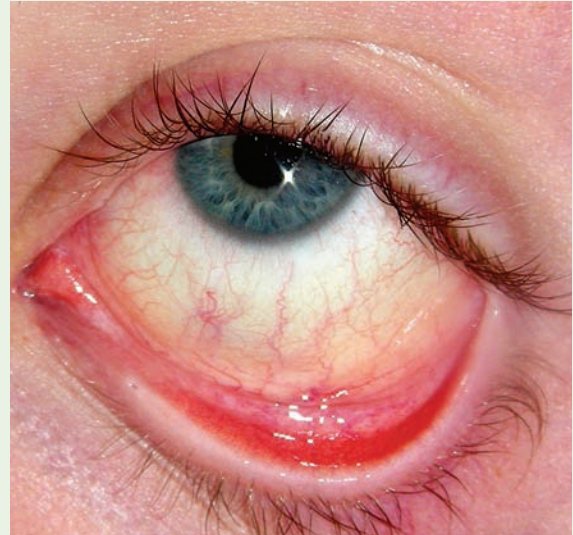According to a conversation we had with Mark Abelson, MD, a world-renowned ocular allergist at Harvard Medical School, there is little or no clinical use for pure mast cell stabilizing drugs. He says that the antihistamine/mast cell stabilizer drugs more effectively stabilize the mast cell membranes than stand-alone mast cell stabilizers such as pemirolast

Dosing of Topical Antihistamine

Which is better: a once-daily drop or a twice-daily drop? We've found that many of our allergy patients simply tend to dose their allergy drops as needed. So, for many patients (especially those with suboptimum tear function), a second drop in the afternoon provides therapeutic enhancement.¹ This is particularly true if the patient has been working outdoors (mowing the grass, for instance). In these situations, a second drop tends to flush out allergens and further suppresses the downstream sequelae of histamine release.

On the other hand, for patients whose allergic symptoms are well controlled with once-daily instillation, then one drop a day is the preferred approach for them. In the end, as always, patient care must be individualized.

For patients with severe allergy expression, consider both an antihistamine/mast cell stabilizer twice daily and Alrex (loteprednol 0.2%, Bausch + Lomb) or Lotemax gel (loteprednol 0.5%, Bausch + Lomb) QID along with cold compresses. After the condition has settled down, maintain the patient on the antihistamine/mast cell stabilizer once or twice daily as needed.



1. McCabe CF, McCabe SE. Comparative efficacy of bepotastine besilate 1.5% ophthalmic solution versus olopatadine hydrochloride 0.2% ophthalmic solution evaluated by patient preference. *Clin Ophthalmol.* 2012;6:1731-8.

(Alamast), nedocromil (Alocril), or cromolyn sodium (generic). Based on this expert opinion, we no longer prescribe these pure mast cell stabilizers.

Remember, allergy is an expres-

sion of inflammation. Cold compresses can be helpful in all ocular surface inflammatory diseases. Infectious processes, on the other hand, are often helped by the application of warm soaks. ■

Intranasal Steroids for Ocular Symptoms in Allergic Rhinitis

In a randomized trial, intranasal steroids relieved both nasal and ocular symptoms.

- Because intranasal steroids are the most effective medications for allergic rhinitis symptoms (especially congestion), guidelines recommend them as first-line agents for moderate-to-severe disease.
- As many as 85% of patients with seasonal allergic rhinitis also have ocular symptoms.
- For these patients, many clinicians prescribe oral antihistamines or ocular products rather than (or in addition to) intranasal steroids.

Origlieri C, Bielory L. Intranasal corticosteroids and allergic rhinoconjunctivitis. *Curr Opin Allergy Clin Immunol.* 2008 Oct;8(5):450-6.

Dry Eye Disease

Two key points about dry eye: Most all cases are related to lipid-layer deficiency, and ocular surface inflammation is a significant component to symptomatic dry eye.

Glaucoma and dry eye disease compose the vast majority of chronic diseases we see in clinical practice. As full-time clinicians, we often anguish at how poorly these conditions are cared for, and feel a special obligation to our patients and to our profession to focus more time on these conditions. Most patients can achieve a target IOP and, in the case of symptomatic dry eyes, achieve a level of ocular comfort.

Dry eye, in particular, is the most common challenge we all face as eye doctors. So we need to diligently read the peer-reviewed literature each month, as well as integrate new approaches into our daily clinical activities, while also drawing upon our own clinical experience. Medical care is an art as well as a science, and good doctors have varied approaches to caring for their patients; here, we present ours.

Two-Pronged Approach

There are two fundamentals that underpin the entirety of our approach to dry eye: First, many (if not most) cases of dry eye are, in one way or another, due to a lipid-layer deficiency.¹ Second, ocular surface inflammation is a significant component to most cases of symptomatic dry eyes.²

- **Artificial tears.** Based on the scientific validity of these two fundamentals, we start all of our dry eye patients on a lipid-based artificial tear to address the lipid deficiency. (Our favorite is Systane Balance, originally developed by Donald Korb, OD.) We encourage our patients to use the drop at least QID for several weeks, then we began to attempt

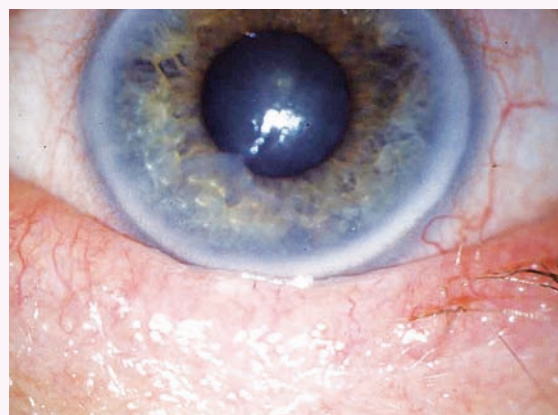

Artificial Tears for the Management of Evaporative Dry Eye

“Seventy-five subjects with dry eye were randomly divided into three groups to compare the efficacies of sodium hyaluronate, hydroxypropyl methylcellulose (HPMC) and an emulsion in the management of lipid-deficient dry eye. Each was allocated sodium hyaluronate, HPMC or emulsion eyedrops to be used four times daily for 90 days. Parameters were measured at baseline, 30 days and 90 days.”

“The emulsion drops were shown to perform best, improving tear stability, and decreasing osmolarity and corneal staining. These results are consistent with improvements in the lipid layer of the tear film as a result of prolonged use of emulsion drops.”

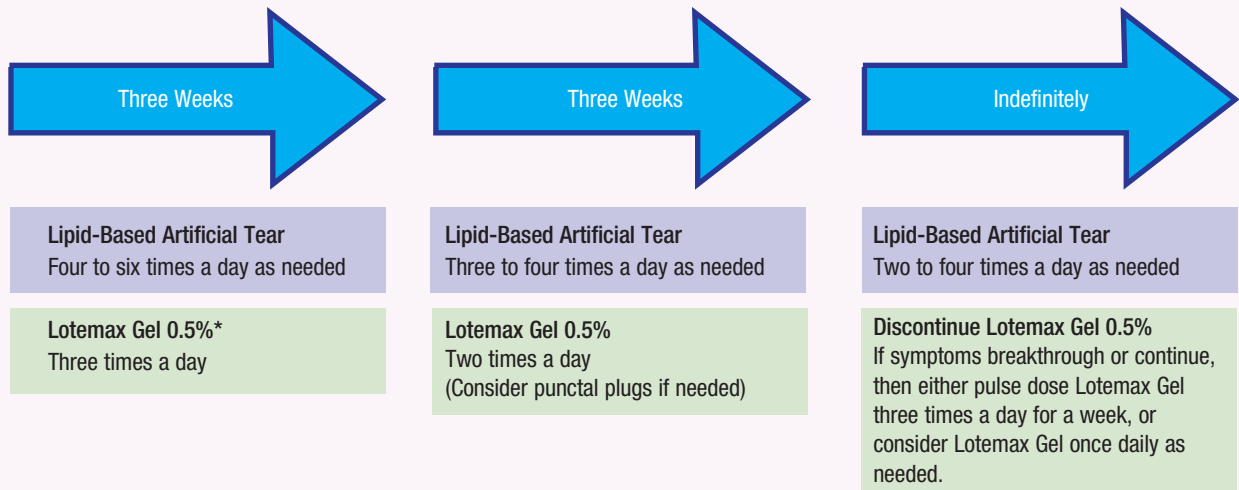
McCann LC, Tomlinson A, Pearce EI, Papa V. Effectiveness of artificial tears in the management of evaporative dry eye. *Cornea*. 2012 Jan;31(1):1-5.



This patient has advanced dry eye, reduced lacrimal lake and meibomian gland dysfunction, suggesting a poor tear film lipid layer. A lipid-based tear is needed, for starters.

Our Dry Eye Management Algorithm

All therapy—dry eye included—should be individualized to the patient. That said, here is our usual approach to dry eye management.



The risk of increased IOP with loteprednol is uncommon at high dosage and rare at low dosage. Our experience has been that if an increase in IOP is going to occur, it will do so during the initial four- to six-week period, and not later.

Omega-3 essential fatty acids (derived from fish and/or flaxseed oil)
Recommend 2,000mg of fish oil daily with a meal (this may take 4 to 6 months to realize an effect)
This can be initiated at any stage, based on clinical judgment.

*Alternatively, instill Lotemax Gel FOUR times a day for TWO weeks, then TWO times a day for FOUR more weeks. Or, another option: instill Lotemax Ointment daily at bedtime for three weeks, then M-W-F for three weeks. Lotemax therapy for inflammation due to dry eye disease is considered an "off-label" use.

to reduce instillation frequency to determine how little drop use is needed to maintain comfort.

- **Steroid anti-inflammatory.**

Next, depending upon the degree

of symptoms and/or clinical signs, we begin most of our patients on Lotemax gel drops (or Lotemax ointment) to address the inflammation component (an "off label"

use). The gel drops are more viscous and have a longer ocular surface residency time than the suspension formulation, so they can be dosed a bit less frequently. We ask most patients to instill the gel drops TID for three weeks, then BID for three more weeks. We have found that this amount of anti-inflammatory suppression nicely quells any ocular surface inflammation.

- **Punctal occlusion.** Remembering that the "horse" is corticosteroid suppression and the "cart" is punctal plugs, we often consider punctal plugging at the four- to six-week follow-up visit, depending on the perceived need for such therapeutic intervention. We commonly give our patients an

Anti-inflammatory Treatment for Dry Eye

- "The beneficial effects of cyclosporine A treatment in DED are well established; however, it is clear that many patients with DED do not show a consistent therapeutic response to topical cyclosporine A ... Although higher dosing frequencies may increase treatment efficacy, some patients experience bothersome adverse effects (e.g., burning or irritation) that impair medication tolerability."
- "Clinical trials have demonstrated the efficacy of topical corticosteroid treatment at diminishing symptom severity and minimizing ocular surface staining."
- "Repetitive short-term pulsatile administration of topical corticosteroids is a promising method of harnessing their beneficial effects, while minimizing the risk of adverse events."

Stevenson W, Chauhan SK, Dana R. Dry eye disease: an immune-mediated ocular surface disorder. Arch Ophthalmol. 2012 Jan;130(1):90-100

Tear Dysfunction Perspectives

- Encompasses changes in tear composition rather than tear volume.
- In dry eye, tear osmolarity is 20 to 40mOsm/L greater than normal (314 to 365mOsm/L).
- MMP-9 is increased in dry eye, and regulates epithelial shedding.
- “Over the past decade there has been a trend towards increased use of anti-inflammatory therapies to improve comfort, corneal smoothness and barrier function.”
- Corticosteroids, doxycycline and essential fatty acids have been found to decrease production of a variety of inflammatory mediators and improve corneal epithelial disease.

Pflugfelder SC. Tear dysfunction and the cornea: LXVIII Edward Jackson Memorial Lecture. Am J Ophthalmol. 2011 Dec;152(6):900-909.

educational brochure early on that details this technology so that they can be pre-educated about punctal plug therapy. This nicely facilitates a discussion if/when such therapy is in the best interest of the patient.

• Omega-3 supplementation.

We also encourage all of our dry eye patients to take 2,000mg of fish oil every morning at breakfast. We are cognizant that not all omega-3 oils have identical levels of DHA and EPA, but we steadfastly refuse to get sucked into such micromanagement.

We are more focused on practical issues such as “swallowability.” We ask all patients something like this: “Do you have any problems swallowing horse pills?” (Here in the South, everyone gets the idea of what we mean.) By asking this or a similar question, you will find about one person in 10 has difficul-



ty swallowing these larger capsules. So, what is “Plan B?” (Always have a Plan B!) There are at least two excellent options: Coromega Omega-3 Orange squeeze packets (cheapest via Amazon.com) or Nordic Naturals Omega-3 Liquid.



Essential Fatty Acids (EFAs) in Dry Eye Disease (DED)

- “Most of the available evidence suggests that administration of omega-3 EFAs can lessen DED severity.”
- Regarding omega-3 EFAs, “more evidence is needed to identify the most efficacious forms and doses.”
- “The evidence implicating inflammation in pathogenesis of DED has opened new avenues for the treatment of this complex disorder. The successful application of anti-inflammatory medications in the treatment of DED provides hope for the millions of individuals who daily experience this deleterious condition.”

Stevenson W, Chauhan SK, Dana R. Dry eye disease: an immune-mediated ocular surface disorder. Arch Ophthalmol. 2012 Jan;130(1):90-100.

Lipid-Containing Lubricants for Dry Eye

“In summary, randomized controlled interventional studies have shown that lipid-containing lubricants are effective in the signs and symptoms of dry eye under certain situations. Despite the presence of some flaws in the studies reviewed, the conclusions of all the studies were clear, and there is now sufficiently strong evidence that lipid-containing lubricants can be recommended.”

Lee SY, Tong L. Lipid-containing lubricants for dry eye: a systematic review. Optom Vis Sci. 2012 Nov;89(11):1654-61.

We tell our patients that it will take four to six months until they begin to feel improvement with the omega-3 supplements, and we explain to them in lay terms how these oils help the glands in the eyelids perform better. We explain to them that the goal is to help them be able to reduce (not eliminate) their dependency on artificial tears, quite similarly to that with punctal plugs.

Ongoing Dry Eye Management

So, we prescribe lipid-based artificial tears on a continuing basis as well as Lotemax gel drops for six weeks, then stop—then what?

If the patient remains comfortable using only the lipid-based artificial tears (with or without punctal plugs), then all is well. Stay the course.

If, however, your patient experiences symptomatic breakthrough within a few days after stopping the corticosteroid therapy, you may have one of those uncommon patients who should stay on a drop or two of loteprednol indefinitely (or at least for a few months until the fish oil supplementation achieves steady state concentrations).

Pulse Dosing Corticosteroids

The management of many chronic inflammatory conditions is optimized (clinically and functionally) using the concept of pulse dosing. This technique is a highly effective, steroid-sparing, cost-effective and patient-friendly way to gain and maintain control of most chronic ocular surface inflammatory conditions.

Regarding the use of topical corticosteroid anti-inflammatory therapy in patients with dry eye associated with Sjögren's syndrome, one study (using topical methylprednisolone) of 106 eyes found that TBUT and Schirmer test results significantly improved while subjective symptoms and fluorescein staining decreased.¹ Also, impression cytology showed that the number of conjunctival goblet cells had significantly increased. After the first pulse therapy, mean drug-free remission time was 56.6 weeks; 11 patients (20.8%) had a recurrence of symptoms and signs. After the second pulse therapy, mean drug-free remission was 72.4 weeks, and only one patient had a recurrence. No serious complications, including intraocular pressure elevation and cataract formation, occurred during the entire follow-up period.

Some patients may need more than pulse dosing, and instead require daily or alternate day instillation of a steroid. (For comparison, long-term daily or intermittent dosing of inhaled steroids are used in children with asthma.²) Ophthalmic examples of such patients include those with corneal transplant, stromal-immune keratitis, chronic uveitis, etc. As always, patient care must be individualized.

1. Hong S, Kim T, Chung SH, et al. Recurrence after topical nonpreserved methylprednisolone therapy for keratoconjunctivitis sicca in Sjögren's syndrome. *J Ocul Pharmacol Ther.* 2007 Feb;23(1):78-82.
2. Zeiger RS, Mauger D, Bacharier LB, et al; CARE Network of the National Heart, Lung and Blood Institute. Daily or intermittent budesonide in preschool children with recurrent wheezing. *N Engl J Med.* 2011 Nov 24;365(21):1990-2001.

How to 'Pulse Dose' a Steroid

This is the optimum way to enjoy the roses without the thorns. Start with the standard (off-label) approach to gain control (e.g., Lotemax gel TID or QID for three weeks, then BID or TID for three more weeks). But, if the patient becomes symptomatic again shortly after stopping the steroid, have them pulse-dose it: Instruct the patient to use Lotemax gel TID to QID for one week, then stop (thus, a "pulse" of corticosteroid). They may need to repeat this pulse-dose once or twice a year.

In our experience, our dry eye patients use less than one bottle (5g) of Lotemax gel over the course of a year. In our opinion, pulse dosing is the quintessential therapeutic maneuver in managing the inflammatory component of dry eye disease.

For perspective, in the Phase III studies, only two in 409 patients on Lotemax gel had an IOP increase of 10mm Hg or more.³ Furthermore, if a patient's intraocular pressure is going to elevate, it will occur within the first four to six weeks of induction therapy, not after a drop or two a day for months or even years. (As an anecdotal example, we have a 50-ish female endocrinologist who can only be kept comfortable using loteprednol once or twice a day; she has done this for nearly

eight years now without any problems at all.) If one understands that ester-based corticosteroid formulations are far less likely than ketone-based corticosteroids to cause significantly elevated IOP, then this is in no way surprising.⁴ We have dozens of patients who have to use loteprednol daily to keep them comfortable, and we have never had a single problem in prescribing loteprednol in this manner.

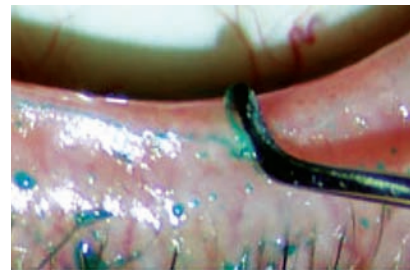Nonetheless, we much prefer "pulse-dosing" of loteprednol than

ongoing daily dosing. (See "How to 'Pulse Dose' a Steroid," at left.)

Other Considerations


A few other items bear special attention:

- **'Spud' the lids.** Beyond biochemical dysfunction of the meibomian glands, these glands also commonly become blocked at their orifices. One method is to apply warm compresses to loosen up the blockage. But in addition, Donald Korb, OD, has ingeniously found that simply scraping the posterior portion of the eyelids with a golf club spud significantly helps to regain some function of these glands.⁵ (Why didn't any of the rest of us think of this?!)



To debride the lower lid margin, gently wipe a golf club spud repeatedly across the lid margin to remove debris.

- **Put the squeeze on MGD.** We also know that meibomian gland dysfunction is probably the single most common cause of dry eye.⁶ To clinically treat this, the Lipi-View/LipiFlow technology (again, invented by Dr. Korb and his team of scientists, and produced by Tear-Science) can heat and massage the eyelids to achieve asymptotology from inadequate meibomian gland function for about a year following such a treatment. (For more information, visit the Duke Eye Center website: www.dukehealth.org/eye_center/health_library/news/duke-eye-center-integrates-tear-science-system-to-improve-care-for-evaporative-dry-eye-patients).



LipiFlow system heats the eyelid while simultaneously massaging the glands.

• *Remember the Lacrisert.*

Though not needed often, Lacriserts (hydroxypropyl cellulose ophthalmic inserts, Valeant Ophthalmics) are for patients for whom “time-release” artificial tears are the answer.

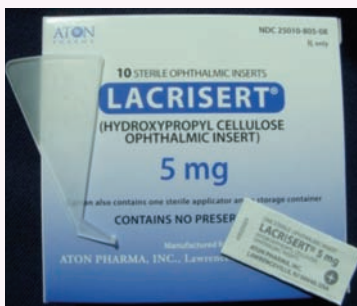We have our contact lens technicians teach the insertion technique, and have found this to be the perfect extension of their instructional abilities.

• *Where does Restasis fit in?*

Some patients do benefit from this approach; six months of therapy results in moderate improvement in

Lacrisert

- A sterile, translucent, rod-shaped, water-soluble, ophthalmic insert (1.27mm x 3.5mm) made of hydroxypropyl cellulose.
- For moderate to severe dry eye sufferers.
- Insert into inferior cul-de-sac of eye beneath base of tarsus.
- Supplied by Valeant Pharmaceuticals in packages containing 60 unit doses.



Evaluation of Dry Eye

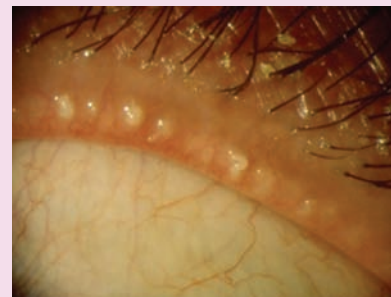
Accurate evaluation of dry eye is crucial to optimal management of the condition. The following are select quotes from a major review article about evaluation of dry eye.

• **Signs vs. symptoms.** “Examination of a patient with dry eyes invariably starts with history and symptoms; there is often a lack of correlation between the severity of the symptoms and ocular signs of dry eye, however. Symptoms of dry eye have been found to be quite severe, even with relatively mild surface changes; yet paradoxically when the severity of dry eye reaches a certain level, symptoms decrease as a result of loss of corneal sensitivity. Reduced ocular surface sensitivity has been documented as a normal age-related change and as a consequence of contact lens wear.”

• **Lipid layer.** “The superficial lipid layer can be observed and measured by interferometry, but a straightforward relationship between the thickness of the lipid layer and the rate of tear evaporation has not been proven. The composition and structure of this layer, rather than its overall thickness, seems to determine the rate of tear thinning.”

• **Measuring osmolarity.** “Osmolarity is a colligative property and therefore independent of temperature and not subject to interpolation. The difference between normal, mild, moderate or severe values are so small that precision is critical. Attempts to obtain sufficient quantities of tears in severe dry eye may induce reflex tearing, contaminating the sample and giving inaccurate lower osmolarity readings. The variation of osmolarity across the tear film and the potential for increased osmolarity in the lower meniscus (the most common sampling location) may also lead to inaccuracy.”

• **Meibomian gland dysfunction.** “Meibomian gland dysfunction denotes functional abnormalities of the meibomian glands, whereas meibomianitis or meibomitis indicates the presence of inflammation. Anterior blepharitis is normally associated with bacteria, particularly *Staphylococcus*, and posterior blepharitis results from inflammatory conditions of the posterior lid margin.”



“The most common form of meibomian gland dysfunction may start with minimal signs (non-obvious obstructive meibomian gland dysfunction), requiring clinical evaluation of meibomian gland expressibility. The International Workshop on Meibomian Gland Dysfunction recommends that gland expression should be included routinely in asymptomatic patients.”

• **Go easy on fluorescein.** “The amount of dye instilled should be minimized, particularly in dry eyes, as fluorescein is not fluorescent at concentrations above 2%. This is called ‘quenching,’ and the dye remains dark in appearance.”

• **No single test for dry eye.** “There is as yet no gold-standard test to diagnose dry eye disease, or even a battery of tests that are universally accepted. The clinical picture of dry eye disease changes through its course; therefore, different tests and diagnostic criteria may be appropriate at different stages. Paradoxically, some putative new and improved methods have been shown to offer poor accuracy and reproducibility.”

• **Aqueous deficiency.** “Aqueous deficient dry eye is a high osmolarity, low volume disorder. Evaporative dry eye is a high osmolarity, high volume disorder. Compensatory lacrimal flow is lost due to inflammatory damage as the disease progresses and aqueous production is reduced, resulting in an aqueous deficient component.”

McGinnigle S, Naroo SA, Eperjesi F. Evaluation of dry eye. *Surv Ophthalmol.* 2012 Jul-Aug;57(4):293-316.

Doxycycline and Minocycline

From time to time, there are reports about shortages of doxycycline. If doxycycline is not available, minocycline is an acceptable substitute.

Because minocycline is the most lipophilic of the tetracycline class, it can therefore more completely cross the blood/brain barrier and potentially cause intracranial hypertension. In the eye, we would see the downstream effect as papilledema; but this is a very rare occurrence, and the literature portrays minocycline as an excellent substitute for doxycycline.

We generally prescribe minocycline just like doxycycline: 50mg per day.

Minocycline, MGD and Dry Eye

Oral minocycline can provide clinical benefits in treating moderate and severe meibomian gland dysfunction by reducing inflammatory cytokine levels.

- "Lid hygiene plus minocycline showed significant improvements in clinical signs and remarkable changes in fatty acid composition."
- "There is no agreement on the ideal dosage of minocycline."
- "Our study showed remarkable benefit with 50mg oral minocycline twice daily for two months."
- "To obtain meaningful patient satisfaction and favorable clinical results, we should consider minocycline as a first-line therapy for the treatment of moderate and severe MGD."

Lee H, Min K, Kim EK, Kim TI. Minocycline controls clinical outcomes and inflammatory cytokines in moderate and severe meibomian gland dysfunction. *Am J Ophthalmol.* 2012 Dec;154(6):949-957.

Inflammation and Dry Eye Disease

- "Inflammation has a prominent role in the development and amplification of the signs and symptoms of DED."
- "Regardless of the origin, a self-perpetuating cycle of inflammation develops that is central to the pathogenesis of DED."
- "Doxycycline ameliorates DED by inhibiting the activity of MMPs (e.g. MMP-9) and supports ocular surface integrity."

Stevenson W, Chauhan SK, Dana R. Dry eye disease: an immune-mediated ocular surface disorder. *Arch Ophthalmol.* 2012 Jan;130(1):90-100.

about 36% of patients, according to clinical trials of Restasis (cyclosporine, Allergan).⁷ However, in our experience, we have found that loteprednol 0.5% suppresses inflammation very quickly, and that pulse-dosing of the steroid is much more effective and less expensive than therapy with Restasis.

• **Try a tetracycline.** For patients who have considerable meibomian gland disease, with or without rosacea lid disease (as evidenced by considerable telangiectatic vessels

on the lid margin and eyelid skin), we often prescribe 50mg of oral doxycycline or minocycline daily for three to six months. Warm soaks and eyelid massage are used to augment the pharmacotherapy of the doxycycline or minocycline.

After three to six months of oral doxycycline/minocycline therapy, we try to maintain meibomian gland function with ongoing omega-3 supplementation.

What about AzaSite (azithromycin 1%, Merck)? The FDA

Treatment of Blepharitis-Related Dry Eye

- "Antibiotic/steroid combination agents can play an important role in a rational, stepwise dry eye treatment plan."
- "These drugs do not appear to alter meibomian gland secretions. However, they can effectively reduce both bacterial proliferation and inflammation of the lid margins."
- "Use combination antibiotic/steroids as needed on a pulsed basis as part of a long-term treatment plan for recalcitrant or recurrent blepharitis." In chronic conditions, an aminoglycoside combined with loteprednol would probably be the wisest choice.

Foulks GN. Combination Drugs for Dry Eye. *Refractive Eyecare.* 2011 Dec. Available at: www.refractiveeyecare.com/2011/12/combination-drugs-for-dry-eye.

has made it abundantly clear that AzaSite has no significant anti-inflammatory properties, and the Ocular TRUST data reveals that AzaSite has poor activity against *Staph.* species.^{8,9} ■

1. Heiligenhaus A, Koch JM, Kruse FE, et al. [Diagnosis and differentiation of dry eye disorders]. *Ophthalmologe.* 1995 Feb;92(1):6-11.
2. Pflugfelder SC, Jones D, Ji Z, et al. Altered cytokine balance in the tear fluid and conjunctiva of patients with Sjögren's syndrome keratoconjunctivitis sicca. *Curr Eye Res.* 1999 Sep;19(3):201-11.
3. U.S. Food and Drug Administration. Center for Drug Evaluation and Research. Deputy Division Director Review for NDA 202-872. 2012 Sep 27. Available at: www.accessdata.fda.gov/drugsatfda_docs/nda/2012/202872Orig1s000MedR.pdf.
4. Amon M, Busin M. Loteprednol etabonate ophthalmic suspension 0.5%: efficacy and safety for postoperative anti-inflammatory use. *Int Ophthalmol.* 2012 Oct;32(5):507-17.
5. Personal communication with Donald Korb, OD.
6. Nichols KK, Foulks GN, Bron AJ, et al. The international workshop on meibomian gland dysfunction: executive summary. *Invest Ophthalmol Vis Sci.* 2011 Mar 30;52(4):1922-9.
7. Sall K, Stevenson OD, Mundorf TK, Reis BL. Two multicenter, randomized studies of the efficacy and safety of cyclosporine ophthalmic emulsion in moderate to severe dry eye disease. *Ophthalmology.* 2000 Apr;107(4):631-9.
8. FDA sends warning letter for AzaSite ads. *Rev Optom.* 2011 May;148(5):12.
9. Asbell PA, Sahn DF, Shedden A; Ocular TRUST Study Group. Ocular TRUST 3: Ongoing Longitudinal Surveillance of Antimicrobial Susceptibility in Ocular Isolates. Poster presented at: Annual Meeting of the American Society of Cataract and Refractive Surgery; April 3-8, 2009; San Francisco.

Amniotic Membrane Device

We all encounter patients who develop non-healing (or painfully slow healing) epithelial defects. This ProKera device (Bio-Tissue Inc.) is a scleral-type lens made from amniotic membrane tissue that has been shown to greatly hasten epithelial recovery and regeneration.

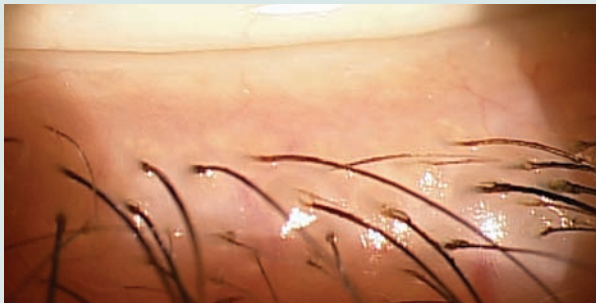The ProKera device is quite expensive (around \$900), but is often covered by medical insurance. The device is to be kept refrigerated until time of placement. Granted, this is not a device that one would use every day, but optometrists need to be both aware and knowledgeable of this useful new technology.

Pachigolla G, Prasher P, Di Pascuale MA, et al. Evaluation of the role of ProKera in the management of ocular surface and orbital disorders. *Eye Contact Lens*. 2009 Jul;35(4):172-5.



Cliradex for Demodex

After years of searching for a means to eliminate the *Demodex* ectoparasite from eyelash follicles, researchers found that application of tea tree oil was an effective measure.



***Demodex folliculorum* resemble “sleeves” wrapped around the base of the eyelashes.**

Like most organic oils, tea tree oil is not monomolecular in nature but rather is a complex of numerous components. There are approximately 15 subcomponent constituents to tea tree oil; of these, 4-terpineol has been found to be the most effective ingredient for eradicating this parasite.

The commercialization of tea tree oil compound has led to the development of Cliradex cleanser (Bio-Tissue Inc.). This is packaged as a towelette soaked in a preservative-free formulation of 4.5% 4-terpineol, and is used once or twice daily for six to eight weeks, depending upon the severity of the clinical expression. It is best applied by gentle wiping (not scrubbing) across the eyelids at bedtime. Nighttime application is most effective at eliminating the *Demodex* mites because they come out and mate during our sleep cycles.

The eyelids should be closed lightly, not tightly, so that the

towelette-applied liquid can get to the base of the eyelashes. This liquid can be irritating to the ocular surface tissues, so advise patients of this possibility and instruct them to instill a few drops of an artificial tear if ocular surface contact should occur.

Another pearl in maximizing the benefit of application of Cliradex is to keep the eyes closed for several seconds to allow the solution to air dry prior to opening the eyes. Note that this cleanser causes a menthol-like sensation that may be disconcerting to some patients. Be sure to explain to them the cleanser's nature and character so that they will not be alarmed.

This innovation was introduced into eye care by Scheffer Tseng, MD, PhD, a corneal and external ocular disease subspecialist who has spent decades in study and research on the clinical entity of the *Demodex* parasite.

Cliradex comes in cartons of 24 towelettes and is shipped in cases of 20 cartons.



Gao YY, Di Pascuale MA, Li W, et al. In vitro and in vivo killing of ocular *Demodex* by tea tree oil. *Br J Ophthalmol*. 2005 Nov;89(11):1468-73.

Medicine in Review

Keeping current with topics in general medicine can be rewarding. Here are a variety of items culled from *Journal Watch* on contemporary medical reports.

Journal Watch (*General Medicine*) is published by the same publisher as *The New England Journal of Medicine*. This newsletter-like booklet comes every two weeks and gives a Cliffs Notes-like summary (with expert commentary) of contemporary issues in general medicine (www.jwatch.org).

Here, we have selected a few topics we feel may be of interest to help expand your scope of clinical knowledge.

Dual Blockade of the Renin-Angiotensin System Doesn't Prevent Mortality

Journal Watch: February 26, 2013

"The combination of an angiotensin-converting-enzyme (ACE) inhibitor plus an angiotensin-receptor blocker (ARB) sometimes is prescribed to patients with heart failure, hypertension, or diabetes, despite limited evidence of efficacy and lukewarm or no support from clinical guidelines ... Compared with monotherapy, dual therapy did not prevent all-cause mortality or cardiovascular (CV)-related mortality."

Comments: Although dual blockade of the renin-angiotensin system may have seemingly benefi-

cial effects on certain endpoints, it failed to reduce mortality and was associated with an excessive risk of adverse events such as hyperkalemia, hypotension and renal failure. The risk-to-benefit ratio argues against the use of dual therapy.

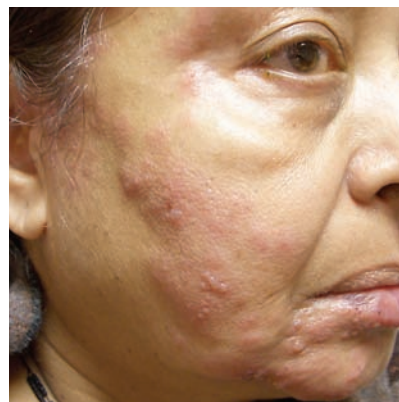Makani H, Bangalore S, Desouza KA, et al. Efficacy and safety of dual blockade of the renin-angiotensin system: meta-analysis of randomised trials. *BMJ*. 2013 Jan 28;346:f360.

Shingles Vaccine Protection Wanes

Journal Watch: November 8, 2012

"In the original study, overall incidence of herpes zoster (HZ) was halved in vaccine recipients. Incidence of postherpetic neuralgia also was lower in the vaccine group, but not significantly so. The vaccine efficacy for all three outcome measures generally was lower than that seen in the initial study and, for all the measures, efficacy reached a low point in year six—a finding due, at least in part, to a rise in the incidence of HZ among vaccine recipients."

Comments: The vaccine is reportedly effective through year five, but its efficacy seems to decrease over time (along with the aging of the study population). "It seems



The efficacy of the shingles vaccine appears to decrease over time.

likely that booster doses eventually will be needed."

Schmader KE, Oxman MN, Levin MJ, et al; Shingles Prevention Study Group. Persistence of the efficacy of zoster vaccine in the shingles prevention study and the short-term persistence substudy. *Clin Infect Dis*. 2012 Nov 15;55(10):1320-8.

Brain Infarction is Associated With Monocular Visual Loss

Journal Watch: October 4, 2012

This retrospective study of patients with monocular visual loss examined the prevalence of concurrent acute brain infarction.

Comments: This study demonstrates that monocular visual loss of presumed ischemic origin does not always represent an isolated disease of the retina; approximately

one out of every four patients with such monocular visual loss also demonstrates acute brain infarcts.

“This finding ... might seem obvious. However, the authors emphasize that many patients with retinal ischemic symptoms are not referred for additional diagnostic evaluations that, in some cases, could trigger timely interventions to prevent future stroke.”

Helenius J, Arsava EM, Goldstein JN, et al. Concurrent acute brain infarcts in patients with monocular visual loss. *Ann Neurol*. 2012 Aug;72(2):286-93.

Telling Dad to Get Off the Road

Journal Watch: September 27, 2012

“Physicians often dread the ‘Dad is too old to drive’ conversation, which forces them to weigh public safety against the interests of an individual patient ... In Ontario, Canada, doctors are mandated to confront patients whom they judge to be potentially unfit drivers and to report such patients to authorities.”

“From 2006 to 2009, most of the 100,000 patients who received physicians’ formal warning against driving were suffering from such common medical conditions as syncope (26%), diabetes (18%), and dementia (14%); epilepsy accounted for 10% ... Compared with the baseline accident rates among patients during the three years before their warnings, rates following warnings fell by about 45% in the next year.”

“Patients’ visits to physicians responsible for issuing warnings fell by about 25% in the year following warnings.”

Comments: This study found that physicians’ warnings to patients who are potentially unfit to drive may contribute to a decrease in subsequent trauma from road



Warning older drivers about their risk of danger may be good policy, but bad for the doctor-patient relationship.

crashes, yet they may also exacerbate mood disorders and compromise the doctor-patient relationship. “These researchers suggest that a half-way measure, in which driver’s licenses are limited, but are not rescinded, merits more research as a compromise position.”

Redelmeier DA, Yarnell CJ, Thiruchelvam D, Tibshirani RJ. Physicians’ warnings for unfit drivers and the risk of trauma from road crashes. *N Engl J Med*. 2012 Sep 27;367(13):1228-36.

New Position Statement for Managing Type 2 Diabetes

Journal Watch: July 24, 2012

“The American Diabetes Association and the European Association for the Study of Diabetes have published a new position statement entitled, ‘Management of Hyperglycemia in Type 2 Diabetes: A Patient-Centered Approach.’ ... Two aspects of the report are particularly noteworthy: ... The authors emphasize a patient-centered approach with individual targets for glycemic control. For example, they recommend more stringent control (e.g., glycosylated hemoglobin [HbA1c] target, <7%) for motivated patients with new-onset diabetes and long life expectancy, and less stringent control (e.g., HbA1c goal 8% or even higher) for less-motivated patients with longstanding diabetes,

limited life expectancies, and high risk for adverse outcomes from hypoglycemia.”

“The authors reject a one-size-fits-all approach... ‘Utilizing the percentage of diabetic patients who are achieving HbA1c <7% as a quality indicator, as promulgated by various healthcare organizations, is inconsistent with the emphasis on individualization of treatment goals.’”

Comments: This position statement supports a more reasoned approach that involves shared decision-making and flexible goals.

Inzucchi SE, Bergenstal RM, Buse JB, et al; American Diabetes Association (ADA); European Association for the Study of Diabetes (EASD). Management of hyperglycemia in type 2 diabetes: a patient-centered approach: position statement of the American Diabetes Association (ADA) and the European Association for the Study of Diabetes (EASD). *Diabetes Care*. 2012 Jun;35(6):1364-79.

Should Anyone *Not* Take a Statin?

Journal Watch: June 12, 2012

“Meta-analyses have shown that statins safely lower the incidence of major vascular events (MVEs, including nonfatal myocardial infarction or coronary death, any stroke, or coronary revascularization) by about 20% for every 40mg/dL reduction in LDL cholesterol level. But the net benefit of statin therapy in patients at low vascular risk has been unclear.”

Comments: Under current guidelines, individuals at low vascular risk are not typically regarded as suitable for LDL-lowering statin therapy. However, the researchers wrote, this benefit greatly exceeds any known hazards of statin therapy. This report suggests that these guidelines might need to be reconsidered.

Cholesterol Treatment Trialists’ (CTT) Collaborators, Mihaylova B, Emberson J, Blackwell L, et al. The effects of lowering LDL cholesterol with statin therapy in people at low risk of vascular disease: meta-analysis of individual data from 27 randomised trials. *Lancet*. 2012 Aug 11;380(9841):581-90.

Zinc for the Common Cold

Journal Watch: May 31, 2012

“Despite many published studies and reviews, zinc’s reputation as a treatment for the common cold has yet to be validated conclusively.”

Comments: The results of this meta-analysis showed that oral zinc formulations may shorten the duration of symptoms of the common cold. However, adverse effects were common and large, high-quality trials are needed before definitive recommendations for clinical practice can be made. “Thus, clinicians overall have only a weak rationale for recommending it.”

Science M, Johnstone J, Roth DE, et al. Zinc for the treatment of the common cold: a systematic review and meta-analysis of randomized controlled trials. *CMAJ*. 2012 Jul 10;184(10):E551-61.

Does Drinking Coffee Lower Mortality?

Journal Watch: May 17, 2012

“After adjusting for many potential confounders [smoking status in particular], a graded and inverse-relation was found between the amount of coffee consumed and total mortality from heart disease, stroke, respiratory disease, diabetes and infection, but not death from cancer. The results were similar in men and women, and for caffeinated and decaffeinated coffee.”

Comments: This was the largest study ever conducted on the health effects of coffee drinking. Results showed an inverse association between coffee drinking and total mortality. And the association was dose-dependent; the more

coffee people drink, the lower their mortality risk. Specifically, men who drank six or more cups of coffee per day had a 10% lower risk of death than men who didn’t drink coffee, and women who consumed this amount had a 15% lower risk. But, because it was an observational study, the researchers couldn’t confirm a causal link. They speculated that the many compounds in coffee (such as antioxidants, e.g. polyphenols) could play an important role.

Freedman ND, Park Y, Abnet CC, et al. Association of coffee drinking with total and cause-specific mortality. *N Engl J Med*. 2012 May 17;366(20):1891-904.

Omega-3 Fatty Acid Supplements—No Benefit for Secondary Prevention of Heart Disease

Journal Watch: May 24, 2012

“Two omega-3 polyunsaturated fatty acids—eicosapentaenoic acid (EPA) and docosahexaenoic acid (DHA)—have anti-inflammatory, antiatherogenic and antithrombotic properties that make them attractive for prevention of cardiovascular disease (CVD).”

“Dosages of EPA or DHA ranged from 0.4g to 4.8g daily, and several oils (e.g., olive, sunflower, corn) were used for placebo. At a mean follow-up of two years, the groups did not differ in risk for CVD events, all-cause mortality, sudden cardiac death, fatal or nonfatal myocardial infarction,

angina, congestive heart failure or stroke.”

Comments: Among patients with a history of cardiovascular disease,

this meta-analysis found insufficient evidence of a secondary preventive effect of omega-3 fatty acid supplements against overall cardiovascular events. “These results depart from those of earlier meta-analyses for two reasons: Two large open-label trials were excluded from this meta-analysis, and a much higher proportion of the patients in these more rigorous studies used cardio-protective agents such as statins. Editorialists note no clear bias for recommending supplementation with omega-3 fatty acids but do recommend a diet rich in fatty fish and plant-derived omega-3 fatty acids.”

Kwak SM, Myung SK, Lee YJ, Seo HG; Korean Meta-analysis Study Group. Efficacy of omega-3 fatty acid supplements (eicosapentaenoic acid and docosahexaenoic acid) in the secondary prevention of cardiovascular disease: a meta-analysis of randomized, double-blind, placebo-controlled trials. *Arch Intern Med*. 2012 May 14;172(9):686-94.
Hu FB, Manson JE. Omega-3 fatty acids and secondary prevention of cardiovascular disease—is it just a fish tale? *Arch Intern Med*. 2012 May 14;172(9):694-6.

Must We Stop Prophylactic Aspirin in Patients Who Develop Peptic Ulcers?

Journal Watch: July 26, 2012

Aspirin-related peptic ulcers are a common disorder. However, whether or not aspirin should be continued during treatment for aspirin-related ulcers remains unclear. “To address this dilemma, researchers in Taiwan identified 178 patients who developed dyspepsia while taking low-dose aspirin for primary or secondary cardiovascular prophylaxis and who exhibited gastric or duodenal ulceration at endoscopy.”

Comments: “In these patients with aspirin-related peptic ulceration, the short-term effectiveness of proton-pump inhibitor (PPI) therapy was not compromised when aspirin was continued ... If indications for aspirin are marginal (as often is the case when low-risk patients use aspirin for primary pre-



Drinking coffee provides an extra buzz: It lowers your risk of mortality.

vention), stopping aspirin if peptic ulcers develop is prudent.”

Liu CP, Chen WC, Lai KH, et al; Formosa Acid-Related Disease (FARD) Study Group. Esomeprazole alone compared with esomeprazole plus aspirin for the treatment of aspirin-related peptic ulcers. *Am J Gastroenterol*. 2012 Jul;107(7):1022-9.

Rate of Physician Referrals is on the Rise

Journal Watch: February 2, 2012

Physician referrals play a central role in ambulatory care in the United States; however, little is known about national trends in physician referrals over time. The objective of this study was to assess changes in the annual rate of referrals to other physicians.

Investigators found that the percentage and absolute number of ambulatory visits resulting in a referral in the United States nearly doubled—from 4.8% to 9.3%—between 1999 to 2009. The increase was particularly significant for visits from patients with cardiovascular, gastrointestinal, orthopedic, dermatologic and ear/nose/throat symptoms.

Comments: Although “visit time” remained stable, physicians (primary care physicians in particular) may not have enough time to address increasing patient issues, resulting in rising rates of referrals. In addition, the increasing numbers of specialists and the greater availability of specialist physicians may also be driving referral rates.

Barnett ML, Song Z, Landon BE. Trends in physician referrals in the United States, 1999-2009. *Arch Intern Med*. 2012 Jan 23;172(2):163-70.

Chocolate Consumption is Linked to Lower Risk of Adverse Cardiovascular Outcomes

Journal Watch: September 20, 2011

“Cocoa products contain polyphenols, which have salutary



Finally, some good news! Eating chocolate has been found to lower the risk of cardiovascular disease and stroke.

cardiovascular (CV) effects ... Seven observational studies involving 114,000 adults were included in this analysis ... High chocolate consumption (i.e., >5 times weekly) was associated with significantly lower risk for any CV disease compared with low chocolate consumption.”

Comments: Based on observational evidence, levels of chocolate consumption seem to be associated with a substantial reduction in the risk of cardiometabolic disorders. Further, the highest levels of chocolate consumption were associated with a 37% reduction in cardiovascular disease and a 29% reduction in stroke, compared with the lowest levels. (This is some of the best news we have read in a long time!)

“Excessive consumption of sugar-laden chocolate confections is unhealthy. In the absence of results of randomized trials comparing chocolate with placebo (in which few people would likely participate), chocolate should be enjoyed in moderation.” ■

Buitrago-Lopez A, Sanderson J, Johnson L, et al. Chocolate consumption and cardiometabolic disorders: systematic review and meta-analysis. *BMJ*. 2011 Aug 26;343:d4488.

Patient Handouts & Referral Forms

On the following pages, you'll find patient handouts and referral forms for your use.

- The first patient is intended to help patients with diabetes to understand the importance of knowing their HbA_{1C} status.

- The second handout explains pulse dosing of topical steroids in the treatment of dry eye.

We also use two specific forms to enhance our communications with referral physicians.

- The first of these relates the diabetes status of our mutual patients.

- The second refers to Plaquenil (hydroxychloroquine, Sanofi-Aventis) retinal evaluations.

Feel free to copy these pages on your letterhead and use them to enhance your patient care and interprofessional communications.

What is a Diabetes A1C Test?

During the course of diabetes care, most patients have a special blood test done every three or four months. It is called the hemoglobin A1C test. The major benefit of the A1C test is that it provides a measure of how your blood glucose levels have averaged over the past two to three months, and so gives more of a “big picture” if your overall blood sugar control. The daily blood glucose checks that you do yourself give you a measure of your blood glucose level at that moment, but daily blood glucose levels can fluctuate quite a bit. The A1C test is extremely important for monitoring how well your diabetes is controlled.

The good news is this is a very simple test to understand. It is reported as a small number, and should be below “7.” For most people with diabetes, the A1C should be between “6” and “7”—this indicates good, consistent control. If your A1C number is lower than “6,” that is even better. But any reading below “7” is generally considered acceptable.

Many times, health care providers are too busy and/or patients simply don’t ask about their blood work. The purpose of the handout is to encourage you to take a more active role in your diabetes care. One very important factor in your diabetes care is for you to always ask your doctor, nurse or diabetic counselor to inform you of your A1C number. They will be glad to share this important information with you.

Knowing your A1C number will enable you to know how your overall diabetic control is. Be sure to ask any member of your diabetes care team any questions that you may have about your care.

A final note: The retina within the eye is the only place in the body where blood vessels can be observed and evaluated. Since diabetes primarily affects the blood vessels, it is very important to have a dilated eye examination every year. This is even more important if your A1C readings tend to be higher than “7.”

Pulse Dosing in Dry Eye Treatment

You have been prescribed a medicine known as loteprednol, which comes as a gel drop or as an ointment. The gel drop is a thick drop, so wait a few seconds after instillation before blinking. Then after several blinks, the brief blur will clear.

No shaking of the bottle is required.

Loteprednol is used off-label to treat the inflammatory component of dry eye disease. Suppressing the ocular surface inflammation is a key step in setting the stage for the artificial tears and fish oil to provide the most help.

We ask that you use the medicine in the following way:

For the gel drop formulation, use one drop in each eye every ____ hours throughout the day for ____ weeks, then just in the morning and evening for ____ more weeks, then stop. It is best to turn your face straight up toward the ceiling when instilling eye drops.

For the ointment formulation, instill a $\frac{1}{4}$ to $\frac{1}{2}$ inch strip into the inside of your lower eyelids at bedtime for ____ weeks, then just every other night for two weeks, then stop.

It takes a few weeks to get the inflammatory component of your dry eye disease controlled. From this point, you may go for many weeks or many months where your eyes feel better. It is very important to consistently use your artificial tears and fish oil as directed every day.

Now, after weeks or months, your eyes may become uncomfortable again. This is called “symptomatic breakthrough.” If or when this occurs, use the eye drops four times a day for one week, then stop. Or, if using the ointment, instill at bedtime for a week, then stop.

This therapeutic maneuver is called “pulse dosing,” and has been shown to be very beneficial in regaining control of dry eye symptoms. Most patients need to do this only once or twice a year.

Loteprednol is a relatively safe corticosteroid, especially when used as described above. There is a slight risk that loteprednol can increase the pressure inside your eyes. For this reason, your eye doctor will monitor your eye pressure from time to time, just to be completely safe.

Always call us if you have any questions.

Diabetes Evaluation

Dilated Diabetic Exam Report

To: _____

Patient: _____ DOB: _____

Date of Exam: _____ Duration of Diabetes: _____

Best corrected visual acuity: OD _____ OS _____

	Right	Left
No retinopathy	<input type="checkbox"/>	<input type="checkbox"/>
Mild background diabetic retinopathy	<input type="checkbox"/>	<input type="checkbox"/>
Moderate background diabetic retinopathy	<input type="checkbox"/>	<input type="checkbox"/>
Severe background diabetic retinopathy	<input type="checkbox"/>	<input type="checkbox"/>
Diabetic retinopathy with macular edema	<input type="checkbox"/>	<input type="checkbox"/>
Proliferative diabetic retinopathy	<input type="checkbox"/>	<input type="checkbox"/>

Recommended Follow Up: 3 Mos. 6 Mos. 12 Mos.

[Your name, and the names of all the doctors in your practice, should go here.]

Comments:

Thank you very much for entrusting your patient to us for their eye care.
(If you have any questions, please contact us.)

[The name of your practice, phone number and e-mail should go here.]

Hydroxychloroquine (Plaquenil) Evaluation

Patient Name _____ D.O.B. _____

Referring Physician _____

Consultant Optometrist _____

Date ____/____/____

Plaquenil dose _____ mg _____ Number of years taking HCQ _____

Acuity Right 20/____ Left 20/____ Patient's Weight _____ lbs.

Estimated Lean Weight _____ lbs.

Fundus exam Normal _____ Other _____

Macular Visual Field Testing (10-2) Normal _____ Other _____

Additional Testing _____

Recheck Annually _____ Other _____

Comments:

Thank you very much for entrusting us with the eye care of your patient.

